THE CONNECTIVE TISSUES

46

Digitized by Arya Samaj Foundation Chennai and eGangotri

Digitized by Arya Samaj Foundation Chennai and eGangotri

गुरुकुल कांगड़ी विश्वविद्यालय
कृपया पुस्तक के ऊपर कोई निशान आदि
न लगायें।

CC-0. In Public Domain. Gurukul Kangri Collection, Haridwar

Digitized by Arya Samaj Foundation Chennai and eGangotri

पुस्तकालय

गुरुकुल कांगड़ी विश्वविद्यालय, हरिद्वार

वर्ग संख्या ...

आगत संख्या ...

पुस्तक विवरण की तिथि नीचे अंकित है। इस तिथि सहित ३० वें दिन यह पुस्तक पुस्तकालय में वापस आ जानी चाहिए। अन्यथा ५० पैसे प्रति दिन के हिसाब से विलम्ब दण्ड लगेगा।

CC-0. In Public Domain. Gurukul Kangri Collection, Haridwar

Digitized by Arya Samaj Foundation Chennai and eGangotri

CC-0. In Public Domain. Gurukul Kangri Collection, Haridwar

Digitized by Arya Samaj Foundation Chennai and eGangotri

cap which exhibits well-defined vertical striations. Columnar epithelium line nearly the whole gastro-intestinal tract and its glands, the greater part of the male urethra, the ductus deferens, the tubules and ducts of the prostate, the bulbo-urethral glands of Cowper, and the vestibular glands of Bartholin. In a modified form it also covers the ovary.

Fig. 5.—Goblet cells of a frog × 500.

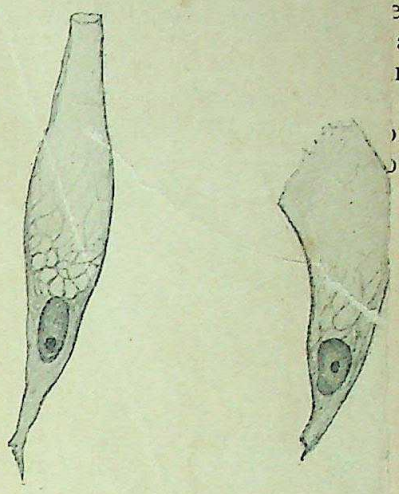

Goblet- or *chalice-cells* are modified columnar cells. Each appears to be formed by an alteration in shape of a columnar cell (ciliated or otherwise) consequent on the formation of granules, which consist of a substance called *mucinogen*, in the interior of the cell. This distends the upper part of the cell, while the nucleus is pressed down towards its deep part, until the cell bursts and the mucus is discharged on to the surface of the mucous membrane (fig. 5), the cell then assuming the shape of an open cup or chalice. A double centriole is found in the mucin-containing part of the goblet-cell. Cells of this kind are especially numerous in the mucous membrane of the stomach, and in the glands of the large intestine; they also occur in the epithelial covering of the villi of the small intestine and in that lining the respiratory tract (fig. 7).

The epithelium of glands is usually columnar, but in some the cells are

गंग्य धमदत्त

Fig. 6.—Isolated liver-cells of a rabbit. × 500.

स्मृति संग्रह

Fig. 7.—Ciliated epithelium from the trachea of a kitten. × 255.

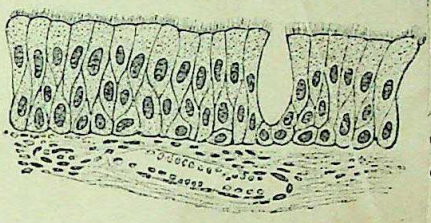

04581

Fig. 8.—An isolated ciliated cell (semidiagrammatic).

cubical, in others they are polyhedral, in shape. The protoplasm shows a fine reticulum, which gives to the cells a granular appearance (fig. 6). Besides these protoplasmic 'granules,' gland-cells usually contain true granules which are the products of their own activity. These are in many cases zymogenic in nature, that is, they are, or contain, the precursors of enzymes or ferments.

Ciliated epithelium (fig. 7) is generally columnar in shape. It is distinguished by the presence of minute processes, resembling eyelashes (cilia), standing up from the free surface. The cilia (fig. 8), at their points of attachment to the free border of the cell, possess small nodular enlargements (*basal knobs* of Engelmann); from these knobs fine beaded filaments extend through the cell, and converge to a point near the fixed extremity. The basal knobs or particles have been supposed to be formed by division of the centriole. If the cells be examined during life or immediately on removal from the living body (for which in the human subject the removal of a nasal polypus offers a convenient opportunity) in a weak solution of salt, the cilia will be seen in lashing motion; and if the cells be separated, they will often be seen to be moved about in the field by this ciliary action.

CC-0. In Public Domain. Gurukul Kangri Collection, Haridwar

Digitized by Arya Samaj Foundation Chennai and eGangotri

Ciliated epithelium lines the respiratory tract from the nose downwards to the smallest ramifications of the bronchial tubes (except in the lower part of the pharynx and on the surfaces of the vocal folds); the tympanic cavity and auditory tube; the uterine tube and the cavity of the body of the uterus; the vasa efferentia, coni vasculosi and the first part of the ductus deferens; the ventricles of the brain and the central canal of the medulla spinalis.

FIG. 9.—Stratified epithelium from the œsophagus.



FIG. 10.—Epithelial cells from the oral cavity of man. × 350.

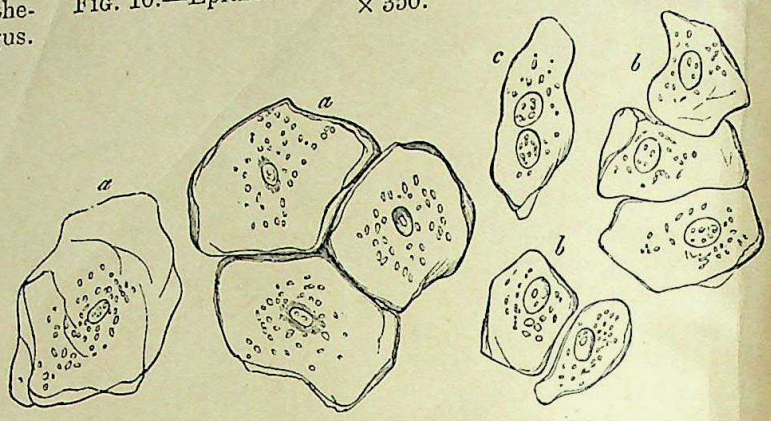

a. Superficial. *b.* From deeper layers. *c.* Cell with two nuclei.

Stratified epithelium (figs. 9 and 11) consists of several layers of cells. The cells vary greatly in shape; those of the deepest layer are for the most part columnar, and are placed vertically on the basement-membrane; above these are several layers of polyhedral cells, which as they approach the surface become more and more compressed, until the superficial ones are found to consist of flattened scales (fig. 10),

FIG. 11.—A section through the epidermis of the skin of the sole of the foot, stained with hæmatoxylin and van Gieson's stain. × 250.

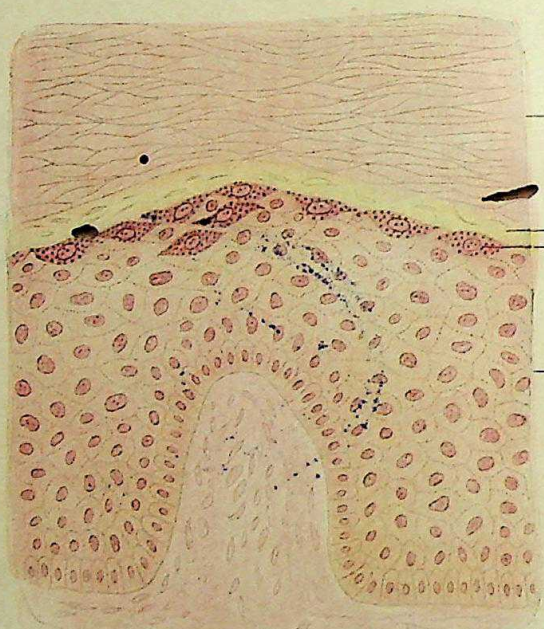

which overlap one another so as to present an imbricated appearance. The epithelium of the skin, or epidermis, is peculiar in that it shows four distinct layers. The deep layer consists of columnar and polyhedral cells as in stratified squamous epithelium generally (stratum mucosum). In the next layer, or stratum granulosum, the cells are fusiform in section, and contain granules of a substance called *eleidin*. The third layer, or stratum lucidum, consists of cells in which the eleidin has undergone a transformation into a substance called *keratohyalin*; and the cells of the

CC-0. In Public Domain. Gurukul Kangri Collection, Haridwar

Digitized by Arya Samaj Foundation Chennai and eGangotri

most superficial layer (stratum corneum) are completely converted into a horny material, known as *keratin* (fig. 11).

The cells of the deeper layers of stratified squamous epithelium are called *prickle-cells*; they are not closely joined together by cement-substance, but are separated from each other by intercellular channels, between which are protoplasmic bridges containing fine fibrils which connect the adjacent cells with each other. When a cell is isolated, it appears to be covered over with a number of short spines, in consequence of the bridges being broken through.

Stratified epithelium is found in the skin, in the conjunctiva, on the anterior surface of the cornea, and in the mucous membrane of the mouth, lower part of the pharynx, œsophagus, vagina and part of the cervix uteri.

FIG. 12.—Transitional epithelium.

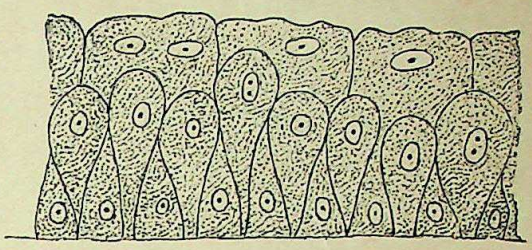

Transitional epithelium occurs in the ureters and urinary bladder. Here the cells of the most superficial layer are large and flattened, with depressions on their under surfaces to fit on to the rounded ends of the cells of the second layer, which are pear-shaped, the apices touching the basement-membrane. Between the tapering points of the cells of the second layer is a third variety of cells of smaller size than those of the other two layers (fig. 12). In the distended condition of the bladder the superficial cells are more flattened, and the pear-shaped cells are shorter and broader than they are when the bladder is contracted.

THE CONNECTIVE TISSUES

The term **connective tissue** includes a number of tissues which have a passive function, that of binding together or supporting the functionally active structures; they differ considerably from each other in appearance, but present many points of relationship, and are, moreover, developed from the same layer of the embryo, the mesoderm. They are divided into three great groups: (1) the connective tissues proper, (2) cartilage, and (3) bone.

The circulating fluids (although functionally different) are regarded by some histologists as a form of connective tissue, and are dealt with in this section.

THE CONNECTIVE TISSUES PROPER

Several varieties of connective tissue are recognised: (1) Areolar tissue. (2) White fibrous tissue. (3) Yellow elastic tissue. (4) Mucoid tissue. (5) Retiform tissue. They are all composed of a homogeneous matrix, in which are imbedded cells and fibres—the latter of two kinds, white, and yellow or elastic. The distinction between the different varieties depends upon the relative preponderance of one or other kind of fibre, of cells, or of matrix.

Areolar tissue (fig. 13) is so called because, when artificially distended with air or fluid, it exhibits intercommunicating areolæ or spaces. It is extensively distributed and its chief use is to bind parts together, though allowing, in virtue of its extensibility and elasticity, a considerable amount of movement to take place. It occurs as subcutaneous tissue, as the submucous coat in the digestive tract, and as subserous tissue. It is also found between muscles, vessels, and nerves, forming investing sheaths for them, and connecting them with surrounding structures. It is present in the interior of organs, binding together the lobes and lobules of the compound glands, the various coats of the hollow viscera, and the fibres of muscles and nerves.

When areolar tissue is stretched it is seen to be made up of soft elastic threads, resembling spun silk, and interlacing in all directions. A thin layer, examined under the microscope, shows fibres and cells, imbedded in a homogeneous ground-substance or *matrix*.

The fibres form an irregular meshwork, and are of two kinds, white and yellow. The *white fibres* are exceedingly fine; they are colourless, homogeneous and transparent, and are arranged parallel to each other in bundles, which have a wavy

CC-0. In Public Domain. Gurukul Kangri Collection, Haridwar

Digitized by Arya Samaj Foundation Chennai and eGangotri

course. The individual fibres do not branch, but small bundles of them may leave one large bundle to join another. The *yellow* or *elastic fibres* have well-defined out-

FIG. 13.—Subcutaneous tissue from a young rabbit. Highly magnified. (From Sir Edward Sharpey Schafer's Essentials of Histology.)

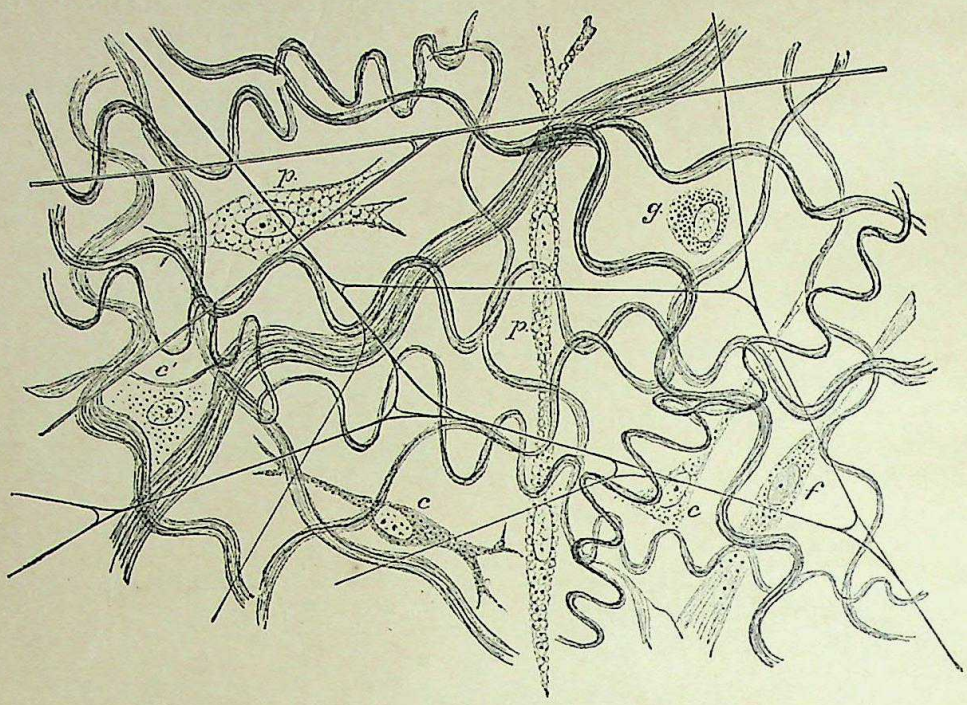

c. c'. Lamellar cell. *f.* Fibrillated cell. *g.* Plasma-cell. *p.* Clasmatocytes.

lines, and are usually somewhat larger than the white fibres, varying in diameter from 1μ to 6μ.* They are pale yellow in colour, homogeneous in appearance, run a

FIG. 14.—Areolar tissue of a rabbit, silvered. × 255. Ground-substance stained, cells unstained.

comparatively straight course, branch, and anastomose freely with each other. When they are broken across, the ends tend to curl up. They also differ from the white fibres in staining a dark red colour with orcein.

* A micromillimetre (μ) is $\frac{1}{1000}$ of a millimetre or $\frac{1}{25400}$ of an inch.

CC-0. In Public Domain. Gurukul Kangri Collection, Haridwar

Digitized by Arya Samaj Foundation Chennai and eGangotri

The cells of areolar tissue are of four principal kinds: (1) Flattened *lamellar cells*, may be either branched or unbranched. The branched lamellar cells are composed of clear protoplasm, with few granules, and contain oval nuclei; their processes may unite with those of neighbouring cells, so as to form a syncytium, as in the cornea. Occasionally a cell may be found which shows fibrillation of its protoplasm. Some observers believe such a condition to be a stage in the formation of the white fibres. The unbranched cells are joined edge to edge like the cells of an epithelium; the flattened cells lining the serous cavities are examples of this variety. (2) *Clasmatocytes* are large irregular cells characterised by the presence of granules or vacuoles in their protoplasm, and containing oval nuclei. (3) *Granule-cells* are ovoid or spheroidal in shape and contain basiphil granules. (4) *Plasma-cells* of Waldeyer are usually spheroidal in shape and distinguished by containing a vacuolated protoplasm; the vacuoles are filled with fluid, and the protoplasm between them is clear, with occasionally a few scattered basiphil granules.

In addition to these four types of cells, areolar tissue may contain *wandering cells*, i.e. leucocytes which have emigrated from the neighbouring vessels; in some instances, as in the chorioid coat of the eye, cells filled with granules of pigment (*pigment-cells*) are found.

The cells lie in spaces in the ground-substance between the bundles of fibres, and these spaces may be brought into view by treating the tissue with nitrate of silver and exposing it to the light; this will colour the ground-substance and leave the cell-spaces unstained (fig. 14).

Adipose tissue.—In almost all parts of the body areolar tissue contains a variable quantity of adipose tissue or fat. The principal situations where it is not found are the subcutaneous tissue of the eyelids, of the penis and scrotum, of the labia minora; within the cavity of the cranium; and in the lungs, except near their

FIG. 15.—Adipose tissue, from the omentum. Stained with Sudan III. and hæmatoxylin. ×350.

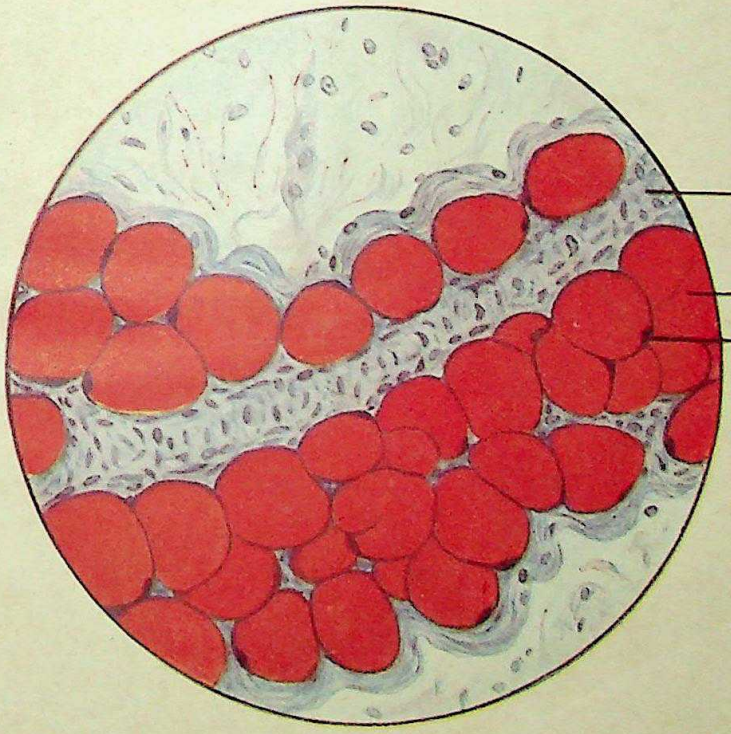

roots. The distribution of adipose tissue is not uniform; in some parts it is in great abundance, as in the subcutaneous tissue, especially of the abdomen, around the kidneys, and in the mesentery and omentum. Lastly, fat enters largely into the formation of the marrow of bones.

Adipose tissue consists of *fat-cells*, lodged in the meshes of areolar tissue. Fat-cells (fig. 15) vary in size, the average diameter being about 50μ; each consists of an exceedingly delicate protoplasmic membrane, filled with fatty substance, which is liquid during life, but solidifies after death. They are round or spherical where they are not subjected to pressure; otherwise they are more or less polygonal.

CC-0. In Public Domain. Gurukul Kangri Collection, Haridwar

Digitized by Arya Samaj Foundation Chennai and eGangotri

A nucleus is always present under the cell-membrane and can be demonstrated by staining with hæmatoxylin; in the natural condition it is so compressed by the contained oily matter as to be scarcely recognisable. The fat-cells are held together mainly by the network of capillary blood-vessels which is distributed to them.

Fig. 16.—Development of fat. (Klein and Noble Smith.)

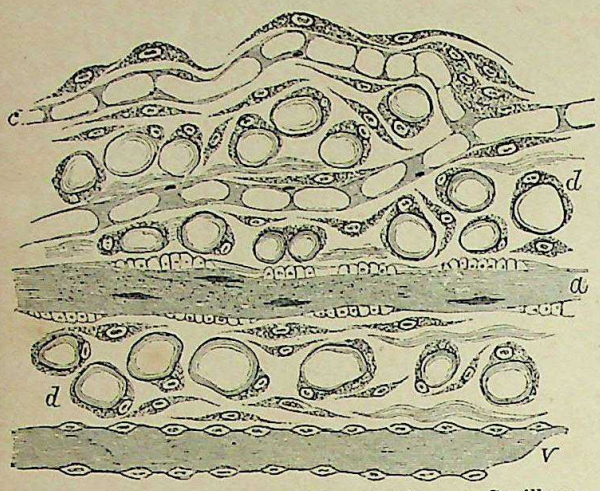

a. Minute artery. *v*. Minute vein. *c*. Capillary blood-vessels in the course of formation; they are not yet completely hollowed out, there being still left in them protoplasmic septa. *d*. The ground-substance, containing numerous nucleated cells, some of which are more distinctly branched and flattened than others, and appear therefore more spindle-shaped.

Chemically the oily material is composed of olein, palmitin, and stearin, which are glycerol esters of fatty acids. Sometimes fat-crystals form in the cells after death. By boiling the tissue in ether or strong alcohol, the fat may be extracted from the cells, leaving them empty and shrunken.

Fat first appears in the human embryo about the fourteenth week. The fat-cells are formed by the transformation of connective tissue cells. Small droplets of oil are formed in the protoplasm, and these coalesce to produce a larger drop, which increases until it distends the cell, the remaining protoplasm and the nucleus being displaced towards the periphery (fig. 16).

White fibrous tissue is a true connecting structure, and serves three purposes in the animal economy. In the form of ligaments it binds bones together; in the form of tendons it connects muscles with bones or other structures; it constitutes investing or protecting membranes to various organs. Examples of such membranes are to be found in the muscular fasciæ or sheaths, the periosteum, and the perichondrium; the capsules of the various glands; the investing sheaths of the nerves (perineurium), and of various organs, as the penis and the eye.

Fig. 17.—White fibres. × 350.



Fig. 18.—Tendon of a rat's tail, stained with gold chloride, showing chains of cells between the tendon-bundles. × 250.

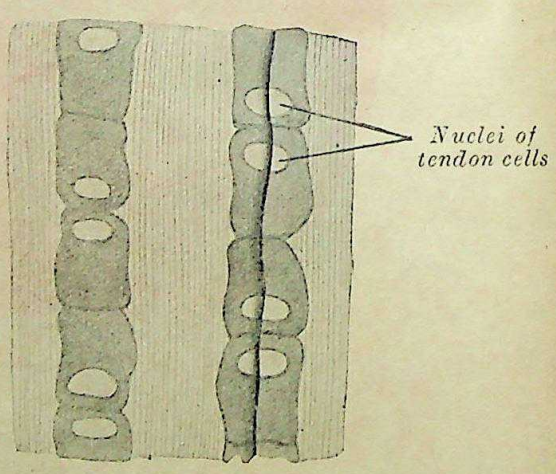

In white fibrous tissue, as its name implies, the white fibres (fig. 17) predominate; the matrix is apparent only as a cement-substance, yellow elastic fibres are comparatively few, while the tissue-cells are arranged in a special manner. It presents to the naked eye a silvery white glistening appearance; it is devoid of elasticity, and has only the very slightest extensibility; it is exceedingly strong, so that upon the application of any external violence, a bone with which it is

CC-0. In Public Domain. Gurukul Kangri Collection, Haridwar

Digitized by Arya Samaj Foundation Chennai and eGangotri

connected may fracture before the fibrous tissue gives way. In ligaments and tendons the bundles of fibres run parallel with each other; in membranes they intersect one another. The cells found in white fibrous tissue are often called 'tendon-cells.' They are situated on the surfaces of groups of fibres, and are arranged in rows, each cell being separated from its neighbours by a narrow line of cement-substance. The nucleus is generally situated at one end of the cell, the nucleus of the adjoining cell being in close proximity to it (fig. 18). The tendon-cells have

FIG. 19.—A transverse section through a tendon of a rat. × 120.

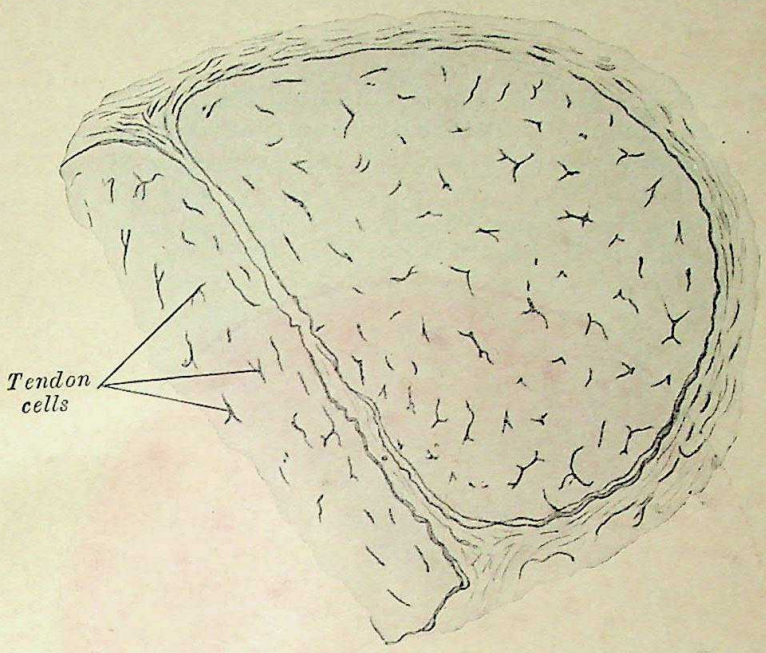

wing-like processes which pass between the bundles of fibres, giving a stellate appearance in transverse section (fig. 19). When viewed from the side, the cell with its wings is quadrangular, and there may be the appearance of a vertical line on the body of the cell owing to the projection of a wing towards the eye of the observer (fig. 18). Upon the addition of acetic acid, white fibrous tissue swells up into a glassy-looking indistinguishable mass. When boiled in water it is converted almost completely into gelatin, the white fibres being composed of *collagen*, which is regarded as the anhydride of gelatin.

Yellow elastic tissue.—In certain parts of the body a tissue is found which is of a yellowish colour, and possessed of great elasticity. It is capable of considerable extension, and when the extending force is withdrawn returns at once to its original condition. This is *yellow elastic tissue*; it may be regarded as a connective tissue in which the yellow elastic fibres have developed to the practical exclusion of the other elements. It is found in the ligamenta flava, in the vocal folds and conus elasticus of the larynx, in the mucous membrane of the trachea and bronchi, in the walls of the pulmonary air-vesicles, in the coats of the blood-vessels, especially the larger arteries, and to a very considerable extent in the hyothyreoid and stylohyoid ligaments. It is also found in the ligamentum nuchæ of the lower animals (fig. 20). Where the fibres are broad and large and the network close, the tissue presents the appearance of a membrane, with gaps or perforations corresponding with the

FIG. 20.—Ligamentum nuchæ of the ox, stained with picrocarmine. × 280.

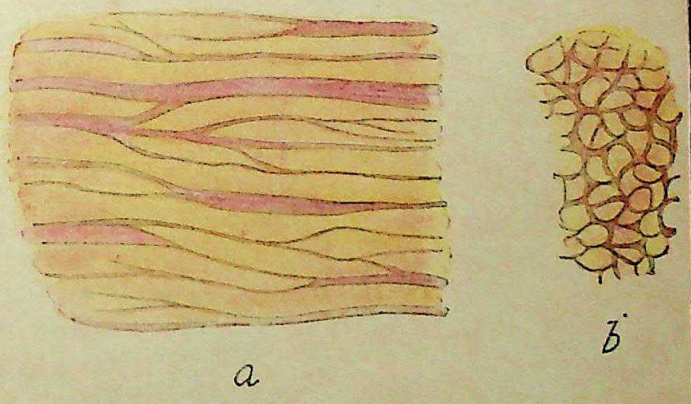

a. Longitudinal section. *b*. Transverse section.

CC-0. In Public Domain. Gurukul Kangri Collection, Haridwar

Digitized by Arya Samaj Foundation Chennai and eGangotri

intervening spaces. This is found in the inner coat of the arteries, and to it the name of *fenestrated membrane* has been given by Henle. Yellow elastic fibres remain unaltered by acetic acid; chemically they are composed of the sclero-protein known as *elastin*.

Mucoid tissue exists in the 'jelly of Wharton,' which forms the bulk of the umbilical cord, but is also found in the fœtus, chiefly as a stage in the development of connective tissue. It consists of a matrix, largely made up of mucin, in which are nucleated cells with branching and anastomosing processes (fig. 21). Few fibres are seen in typical mucoid tissue, though at birth the umbilical cord shows a considerable development of fibres. In the adult the vitreous body of the eye is a persistent form of mucoid tissue, in which the fibres and cells are very few in number.

Retiform or reticular tissue (fig. 22) is found extensively in many parts of the body, constituting the framework of some organs and entering into the construction of many mucous membranes. It is a variety of connective tissue, in which the

FIG. 21.—Mucoid tissue from the umbilical cord of a human embryo of four months, stained with hæmatoxylin and eosin. × 255.

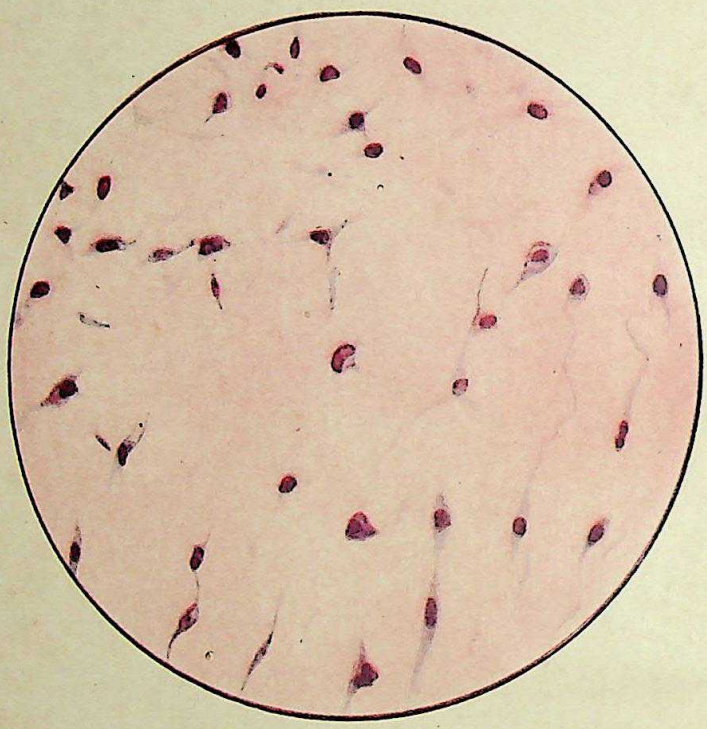

intercellular or ground-substance is, in a great measure, replaced by fluid. It is composed almost entirely of extremely fine bundles of white fibrous tissue, forming an intricate meshwork, and chemically it yields *gelatin* on boiling. The fibres are covered and concealed in places by flattened branched connective tissue-cells. In many situations the interstices of the network are filled with rounded lymph-corpuscles, and the tissue is then termed **lymphoid tissue.**

Basement-membranes consist of thin sheets of modified connective tissue, and are found underlying layers of epithelial cells, for example, in mucous membranes and secreting glands. They may be formed of cells or of condensed ground-substance. In the former case, flattened cells, which are modified connective tissue corpuscles, are united by their edges by means of cement-substance, which can be demonstrated by staining with silver nitrate; if the cells are unbranched, the membrane is continuous; if they are branched, the processes are united, and the membrane is fenestrated. The basement-membrane underlying the epithelium on the anterior surface of the cornea is composed of ground-substance.

Vessels and nerves of connective tissue.—The *blood-vessels* of connective tissue are very few—that is to say, few are supplied to the tissue itself, although many carrying blood to other structures may permeate one of its forms, the areolar tissue. In white fibrous tissue the blood-vessels usually run parallel to and between the longitudinal bundles, sending communicating branches across the bundles; in some forms, as in the periosteum and dura mater, they are fairly numerous. In

CC-0. In Public Domain. Gurukul Kangri Collection, Haridwar

Digitized by Arya Samaj Foundation Chennai and eGangotri

yellow elastic tissue, the blood-vessels also run between the fibres. *Lymphatic vessels* are very numerous in most forms of connective tissue, especially in the areolar tissue beneath the skin and the mucous and serous surfaces. They are also found in abundance in the sheaths of tendons, as well as in the tendons themselves.

FIG. 22.—Retiform and lymphoid tissue from a lymph-gland, stained with picrocarmine. × 255.

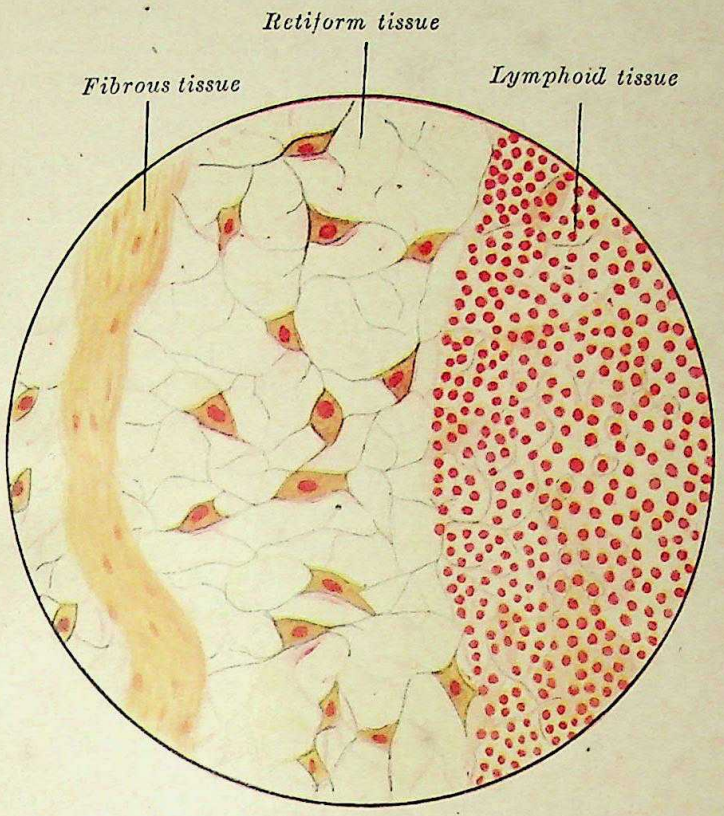

Nerves are found in white fibrous tissue, where they end in a special manner; but it is doubtful whether any nerves end in areolar tissue; at all events, they have not yet been demonstrated, and the tissue is possessed of very little sensibility.

Pigment.—Pigment is found in various parts of the body; most frequently in epithelial cells and in the cells of connective tissue. Pigmented *epithelial cells* form the external layer of the retina, and are present on the posterior surface of the iris, in the olfactory region of the nose, in the membranous labyrinth of the ear, in the deeper layers of the cuticle, and in the hairs. Pigment is abundantly present in the skin of the coloured races, but in the skin of white races it is well-marked only in the areolæ round the mammary papillæ and in irregular coloured patches. Pigmented *connective tissue-cells* are frequently met with in the lower vertebrates. In man they are found in the chorioid coat of the eye (fig. 23), and in the iris of all but the light blue eyes and the albino. The cells are usually large and branched, and are filled with brown or black granules, consisting of *melanin*. In the retina the processes of the cells extend between the rods and cones; when the eye is exposed to light the pigment-granules extend into these processes, and under the influence of darkness they are withdrawn into the body of the cell.

FIG. 23.—Pigment-cells from the chorioid coat of the eyeball.

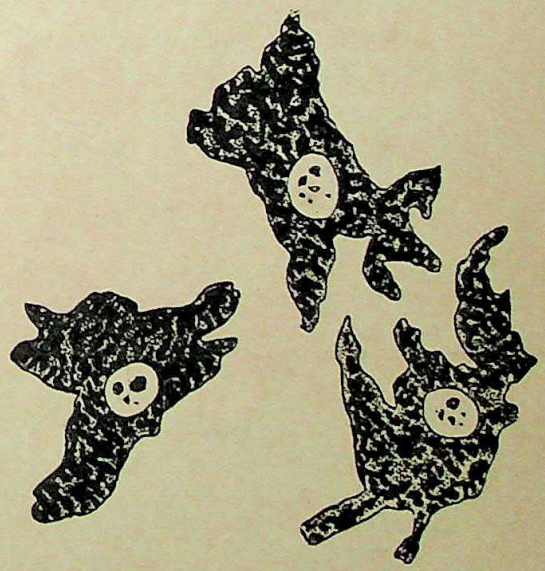

CC-0. In Public Domain. Gurukul Kangri Collection, Haridwar

Digitized by Arya Samaj Foundation Chennai and eGangotri

The pigment-granules are of very small size and are closely packed within the cells, but do not invade the nuclei. Occasionally they are yellow, and when occurring in the cells of the cuticle constitute 'freckles.' In the retina another variety of pigment occurs, known as *rhodopsin* or *visual purple*, which is bleached on exposure to light.

Applied Anatomy.—Congenital absence of pigment from the skin and other tissues constitutes the condition known as albinism. Localised patches of skin from which pigment is absent are found in leucoderma; linear white streaks may result from old scars or from overdistension of the skin, particularly that over the abdomen following pregnancy or ascites. A congenital excessive pigmentation may be general, or may occur locally in the form of dark brown or black nævi (moles). Pigmented patches occasionally follow the continued action of local irritants, and a general swarthiness may result from excessive exposure to the sun, particularly in association with uncleanliness (vagabondinismus). A rare form of general pigmentation ensues on the prolonged administration of salts of silver or of arsenic. Disorders of the endocrine organs may be associated with much discoloration of the skin; this is particularly noticeable in Addison's disease (suprarenal glands) where the pigmentation occurs mostly on the face, exposed parts of the neck, backs of hands, axillary and umbilical regions, genital organs, and medial surfaces of the thighs, but invades also the buccal and lingual mucous membranes. In pregnancy and in some uterine disorders patches of discoloration may be seen round the nipples, over the linea alba, and on the face. Many chronic wasting diseases are accompanied by peculiar colorations of the skin, notably cancer and phthisis; in the latter there may be much deepening of the tint over the zygomatic bones and round the orbits.

Development of connective tissue.—Connective tissue is developed from cells of the mesoderm. These cells multiply and form a syncytium containing many nuclei. The ground-substance appears in spaces between the cells as an albuminous fluid. Later, granules are deposited in the ground-substance by the activity of the cells, and become fused to form the fibres of the tissue.

Cartilage

Cartilage is a non-vascular structure found in various parts of the body—in the joints, parietes of the thorax, trachea, bronchi, nose, and ears. In the fœtus,

Fig. 24.—Cartilage cells in the costal cartilage of a kitten, stained with picrocarmine. × 350.

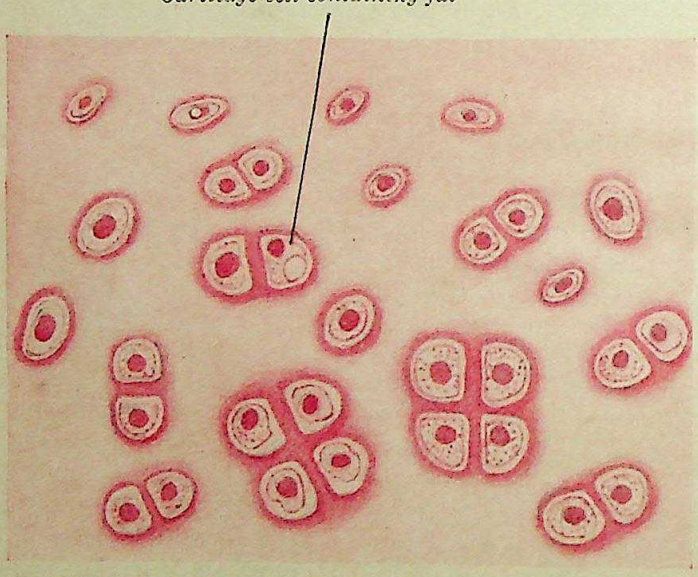

at an early period, the greater part of the skeleton is cartilaginous; as this cartilage is afterwards replaced by bone, it is called *temporary*, in contradistinction to that which remains unossified and is called *permanent*.

Cartilage is divided, according to its minute structure, into *hyaline cartilage*, *white fibrocartilage*, and *yellow* or *elastic fibrocartilage*. Besides these varieties met with in the adult human subject, there is a variety called *cellular cartilage*, formed entirely, or almost entirely, of cells, separated from each other by their capsules only, which in this kind of cartilage are extremely well marked. Cellular cartilage is found in the external ears of rats, mice, and some other animals, and it also forms a stage in the development of cartilage in human embryonic life.

CC-0. In Public Domain. Panini Kanya Maha Vidyalaya Collection.

Digitized by Arya Samaj Foundation Chennai and eGangotri

Hyaline cartilage has a pearly bluish colour and consists of a gristly mass of a firm consistence, but of considerable elasticity. Except where it coats the articular ends of bones, it is covered by a fibrous membrane, the *perichondrium*, from the vessels of which it imbibes its nutritive fluids, being itself destitute of blood-vessels. It contains no nerves. If a thin slice be examined under the microscope, it is seen to consist of cells of a rounded or bluntly angular form, lying in spaces in a granular or almost homogeneous matrix (fig. 24). The cells are frequently arranged in groups of two or more, and, when this is so, they have generally straight outlines where they are in contact with each other, but are rounded in the rest of their circumference. They consist of clear translucent protoplasm in which fine interlacing filaments and minute granules are sometimes present; imbedded in the protoplasm are one or two round nuclei, having the usual intranuclear network.

The matrix is transparent and apparently without structure, or else presents a dimly granular appearance, like ground glass. The portion immediately surrounding each cell-space is often well-defined, and is further characterised by its affinity for basic dyes. It is known as the *capsule* of the space. The matrix of hyaline cartilage, and especially that of the articular variety, can be broken up into fine fibrils after prolonged maceration. These fibrils are probably of the same nature, chemically, as the white fibres of connective tissue. It is believed by some histologists that the matrix is permeated by a number of fine channels, which connect the cell-spaces with each other and with the lymphatics of the perichondrium, and that in this way nutrient fluid obtains access to the cartilage-cells.

FIG. 25.—A vertical section through articular cartilage.

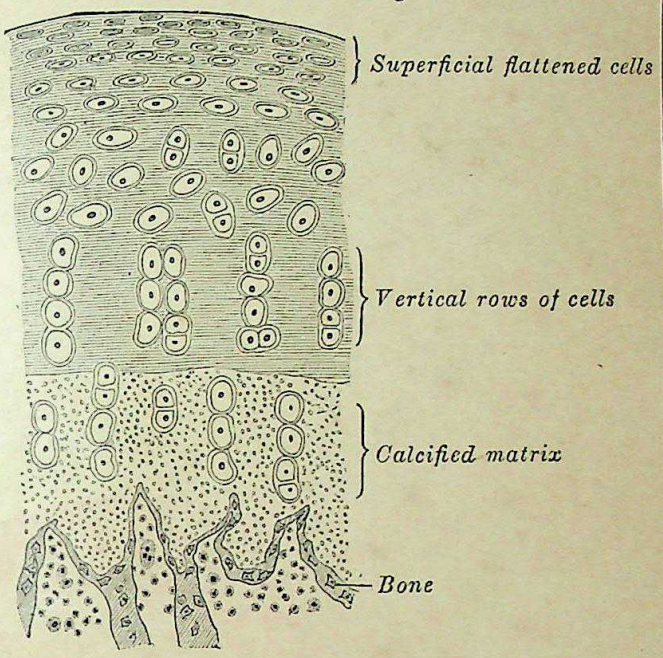

Articular cartilage, costal cartilage, and temporary cartilage are all of the hyaline variety, but they present differences in the size, shape, and arrangement of their cells.

Articular cartilage (fig. 25) shows no tendency to ossification; its matrix is finely granular, and its cells are flattened and disposed parallel to the surface in the superficial part of the cartilage, while nearer to the bone they are oval and are arranged in vertical rows. It has a tendency to split in a vertical direction. Its free surface is not covered by perichondrium, but the synovial stratum of the articular capsule can be traced over a small part of its circumference, and here the cartilage-cells are more or less branched and pass insensibly into the branched connective tissue-cells of the synovial stratum. It forms a thin layer upon the joint-surfaces of the bones, and its elasticity enables it to break the force of concussions, while its smoothness gives ease and freedom of movement. It varies in thickness according to the shape of the articular surface on which it lies; where this is convex the cartilage is thickest at the centre, the reverse being the case on concave articular surfaces. It appears to derive its nutriment partly from the vessels of the synovial stratum of the joint-capsule and partly from those of the bone upon which it is implanted. The minute vessels of the spongy bone dilate and form arches as they approach the articular lamella, and then return into the substance of the bone.

In **costal cartilage** the cells and nuclei are large, and the matrix, which is usually homogeneous and transparent, has a tendency to fibrous striation, especially in old age (fig. 26). In the thickest parts of the costal cartilages a few large vascular channels may be detected. This appears, at first sight, to be an exception to the statement that cartilage is non-vascular, but is not so really, for the vessels give no branches to the cartilage itself, and the channels may rather be looked upon as involutions of the perichondrium. The xiphoid process of the sternum and the

CC-0. In Public Domain. Gurukul Kangri Collection, Haridwar

Digitized by Arya Samaj Foundation Chennai and eGangotri

cartilages of the nose, larynx, and trachea (except the epiglottis and corniculate cartilages of the larynx, which are composed of elastic fibrocartilage) resemble the costal cartilages in microscopical characteristics. The arytænoid cartilage of the larynx shows a transition from hyaline cartilage at its base to elastic cartilage at the apex.

The hyaline cartilages, especially in adult and advanced life, are prone to calcify—that is to say, their matrix becomes permeated by calcium salts. Calcification occurs frequently in the costal cartilages, and in the cartilages of the trachea, and may be succeeded by ossification.

FIG. 26.—Costal cartilage from a man seventy-six years of age, showing the development of fibrous structure in the matrix. In several portions of the specimen two or three generations of cells are seen enclosed in a parent cell-wall. Highly magnified.

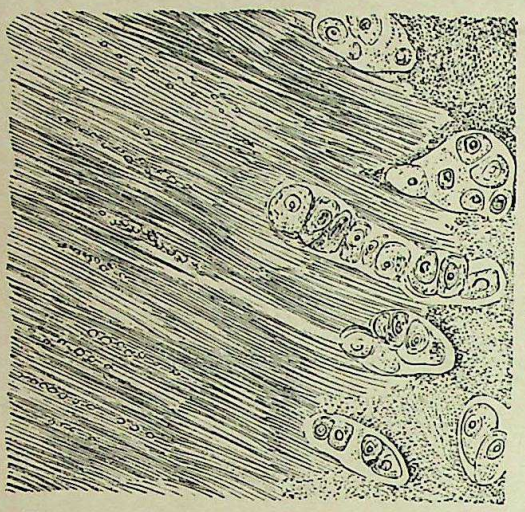

White fibrocartilage consists of fibrous connective tissue arranged in bundles, with cartilage-cells between the bundles; the cells are roughly ovoid in shape, and are surrounded by concentrically striated areas of cartilage-matrix (fig. 27). The white fibrocartilages admit of arrangement into four groups—interarticular, connecting, circumferential, and stratiform.

1. The *interarticular fibrocartilages* (*menisci*) are flattened fibrocartilaginous plates, of a round, oval, triangular, or sickle-like form, interposed between the articular cartilages of certain joints; the synovial stratum of the articular capsule covers their free surfaces. They are found in the temporomandibular, sternoclavicular, acromioclavicular, wrist- and knee-joints. Their uses are to obliterate the intervals between opposed surfaces in their various motions; to increase the depths of the articular surfaces

FIG. 27.—White fibrocartilage from the intervertebral fibrocartilage of a sheep, stained with borax-carmine. × 300.

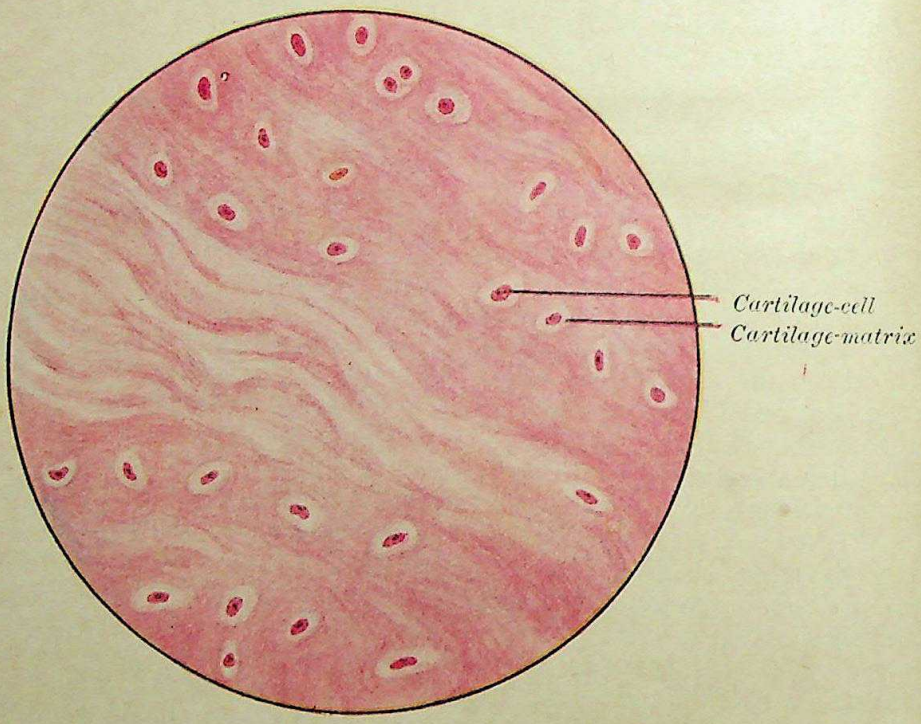

and give ease to the gliding movements; they also increase the varieties of movement in a joint.

2. The *connecting fibrocartilages* are interposed between the bony surfaces of

CC-0. In Public Domain. Gurukul Kangri Collection, Haridwar

Digitized by Arya Samaj Foundation Chennai and eGangotri

those joints which admit of only slight mobility, as between the bodies of th vertebræ. They form discs which are closely adherent to the opposed surface Each disc is composed of concentric layers of fibrous tissue, with cartilaginou laminæ interposed, the former tissue predominating towards the circumferenc the latter towards the centre.

3. The *circumferential fibrocartilages* consist of rims of fibrocartilage, whic surround the margins of some of the articular cavities, e.g. the glenoidal labru of the hip-joint and that of the shoulder-joint; they serve to deepen the articula cavities and to protect their edges.

4. The *stratiform fibrocartilages* form thin coatings to osseous grooves throug which the tendons of certain muscles glide.

Small masses of fibrocartilage are also developed in the tendons of some muscle where they glide over bones, as in the tendons of the Peronæus longus and Tibialis posterior.

Yellow or elastic fibrocartilage is found in the ears, the corniculate cartilages of the larynx, and the epiglottis. It consists of cartilage-cells and a matrix, the latter being pervaded by a network of yellow elastic fibres, branching and anastomosing in all directions, except immediately around the cells, where there is a variable amount of hyaline substance (fig. 28). The fibres resemble those of yellow elastic tissue, not only in appearance, and in being unaffected by acetic acid, but also in their affinity for orcein; according to Rollett their continuity with the elastic fibres of the neighbouring tissue is demonstrable.

FIG. 28.—Yellow or elastic fibrocartilage from th epiglottis of a cat. × 250.

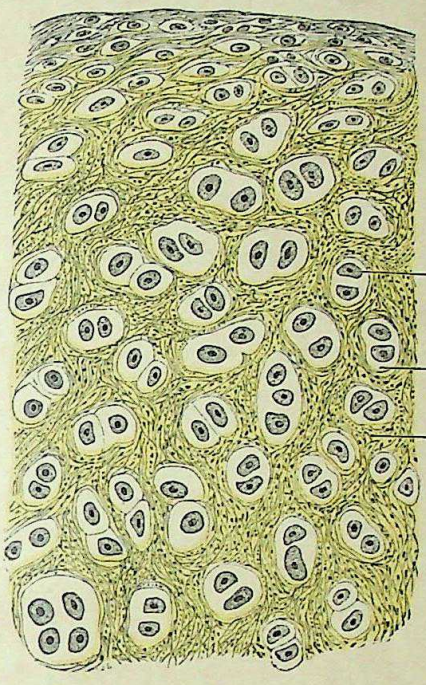

The distinguishing feature of cartilage, chemically, is that it yields on boiling a substance called *chondrin*, a mixture of gelatin with mucinoid substances, chief among which is a compound termed *chondromucoid*.

BONE

Structure and physical properties.—Bone is one of the hardest structures o the animal body; it possesses also a certain degree of toughness and elasticity. Its colour, in a fresh state, is pinkish white externally, and deep red within. In section it is seen to be composed of two kinds of tissue, one of which is dense in texture, like ivory, and is termed *substantia compacta*; the other consists of slender fibres and lamellæ, which join to form a reticular structure; this is called *substantia spongiosa* or, from its resemblance to lattice work, *cancellous tissue*. The compact substance is always placed on the exterior of the bone, the spongy in the interior. The relative quantities of these vary in different bones and in different parts of the same bone, according as strength or lightness is requisite. Close examination of the compact substance shows it to be extremely porous, so that the difference between it and the spongy substance depends merely upon the relative amount of solid matter and the size and number of spaces in each; in the compact substance the spaces are small and the solid matter abundant, while in the spongy substance the spaces are large and the solid matter small in quantity.

During life, bone is permeated by vessels, and enclosed, except where it is coated with articular cartilage, in a fibrous membrane, the *periosteum*, by means of which many of these vessels reach the bone. If the periosteum be stripped from the surface of the living bone, small bleeding points are seen which mark the entrance of the periosteal vessels, and on section every part of the bone exudes blood from

CC-0. In Public Domain. Gurukul Kangri Collection, Haridwar

Digitized by Arya Samaj Foundation Chennai and eGangotri

he minute vessels which ramify in it. In the interior of the long bones of the imbs is a cylindrical cavity (*cavum medullare*) filled with *medulla ossium* or *marrow*, nd lined with a membrane composed of highly vascular areolar tissue, called the *nedullary membrane* or *internal periosteum*.

The **periosteum** adheres to the surfaces of the bones in nearly every part, but not to the cartilage covering their articular surfaces. When strong tendons or igaments are attached to a bone, the periosteum is incorporated with them. It onsists of two layers closely united together, the outer formed chiefly of white ibrous tissue, containing occasionally a few fat-cells; the inner, of elastic fibres of he finer kind, forming dense membranous networks, which can be again separated nto several layers. In young bones the periosteum is thick and very vascular, nd is intimately connected at either end of the bone with the epiphysial cartilage, but less closely with the body of the bone, from which it is separated by a layer of oft tissue, containing a number of granular corpuscles or 'osteoblasts,' by which ssification proceeds on the exterior of the young bone. Later in life the periosteum s thinner and less vascular, and the osteoblasts are represented by a single layer of lattened cells on its deep surface. The periosteum serves as a nidus for the ramification of the vessels previous to their distribution in the bone; hence the liability of one to exfoliation or necrosis when denuded of this membrane by injury or disease. Fine nerves and lymphatics, which generally accompany the arteries, may also e demonstrated in the periosteum.

The **medulla ossium** or **marrow** not only fills up the cylindrical cavities in the odies of the long bones, but also occupies the spaces of the cancellous tissue and xtends into the larger Haversian canals. It differs in composition in different ones. In the bodies of the long bones the marrow is of a *yellow* colour (*medulla ssium flava*), and consists of a basis of connective tissue supporting numerous lood-vessels and cells, most of which are fat-cells, but some are 'marrow-cells,'

FIG. 29.—Human bone-marrow. Highly magnified.

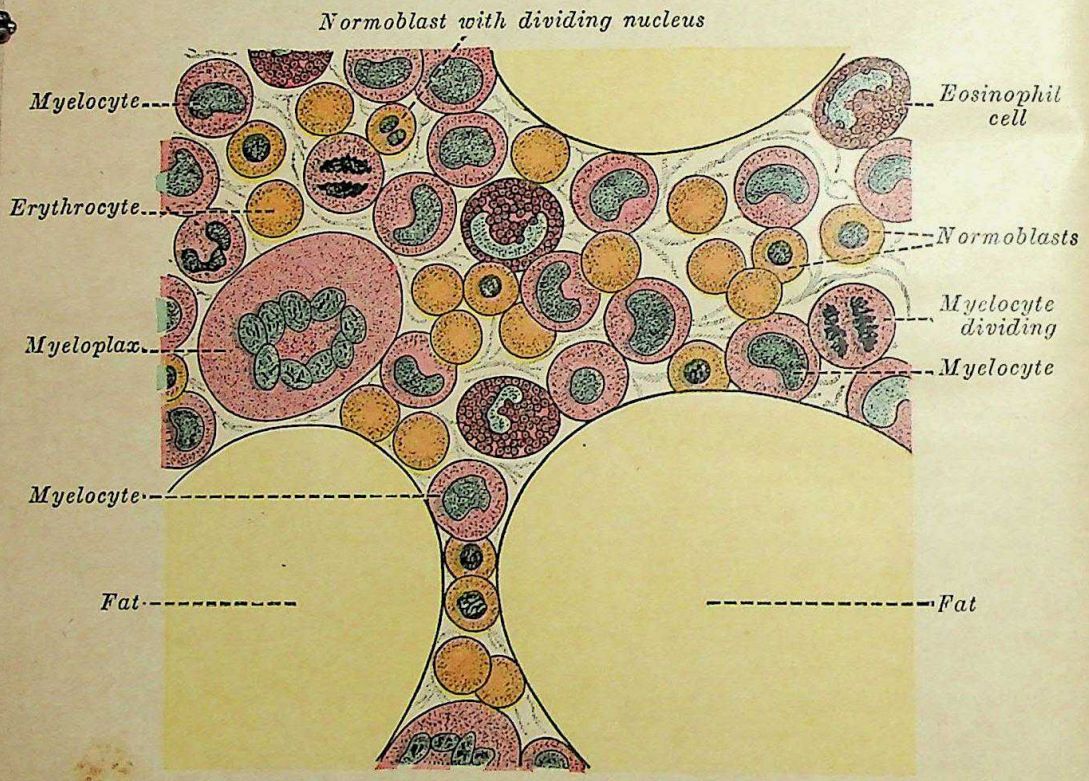

such as occur in the red marrow. In the flat and short bones, in the articular ends of the long bones, in the bodies of the vertebræ, in the cranial diploë, and in the sternum and ribs, the marrow is of a *red* colour (*medulla ossium rubra*).* Red marrow consists of a small quantity of connective tissue, blood-vessels, and numerous cells (fig. 29), a few of which are fat-cells but the great majority are spherical,

* Alfred Pinney (*Lancet*, Sept. 9th, 1922, p. 572) has investigated the naked-eye anatomy of the bone marrow in 1700 post-mortem cases, and concludes that all the bones, except those of the cranium, contain red marrow until puberty.

CC-0. In Public Domain. Gurukul Kangri Collection, Haridwar

Digitized by Arya Samaj Foundation Chennai and eGangotri

nucleated cells, termed *myelocytes* or *marrow-cells*. The myelocytes resemble the leucocytes of the blood, and like them are amœboid; they contain granules, either oxyphil, basiphil or neutrophil in reaction. A number of eosinophil cells and a few basiphil cells are also present. Amongst the myelocytes may be seen smaller nucleated cells, of a yellowish colour; these are the *erythroblasts* or *normoblasts* from which the red corpuscles of the blood are derived by the disappearance of the nuclei. Giant-cells (*myeloplaxes* or *megakaryocytes*) similar to the osteoclasts described in connexion with the development of bone are also found in red marrow. In post-natal life the red marrow is the chief seat of the formation of the corpuscles of the blood.

Vessels and nerves of bone.—The *blood-vessels* of bone are very numerous. Those of the compact substance are derived from a close network of vessels in the periosteum. Vessels pass from this network into the minute orifices in the compact substance, and run in the Haversian canals which traverse it. The spongy substance is supplied in a similar way by larger vessels, which perforate the outer compact substance, and are distributed to the cavities of the spongy portion of the bone. In the long bones, numerous apertures may be seen at the ends near the articular surfaces; some of these give passage to arteries, but the greater number transmit veins from the spongy substance. The marrow of a long bone is supplied by an artery which enters the bone at the nutrient foramen (*foramen nutricium*). The *nutrient* artery, usually accompanied by one or two veins, sends branches upwards and downwards, which ramify in the medullary membrane, and give twigs to the adjoining Haversian canals. The ramifications of this vessel anastomose with the arteries of the spongy and compact substances. In most of the flat, and in many of the short, bones there are one or more large apertures for the transmission of nutrient vessels. Veins emerge from the long bones as follows:—(1) one or two accompany the nutrient artery; (2) numerous large and small veins emerge near the articular extremities; (3) many small veins pass out of the compact substance. In the flat cranial bones the veins are large and run in tortuous canals in the diploic tissue, the walls of the canals being formed by thin lamellæ of bone, perforated here and there for the passage of branches from the adjacent diploë. The same condition is found in all spongy substance, the veins being enclosed and supported by osseous material, and having exceedingly thin coats. When a bone is divided, the vessels remain open, and do not contract in the canals in which they are contained. *Lymphatic vessels*, which communicate with those in the periosteum, are found in the Haversian canals. *Nerves* are distributed freely to the periosteum, and accompany the nutrient arteries into the interior of the bone. They are said to be most numerous in the articular extremities of the long bones, in the vertebræ, and in the larger flat bones.

FIG. 30.—A transverse section through the compact substance of bone. Magnified. (Sharpey.) (From Quain's Elements of Anatomy.)

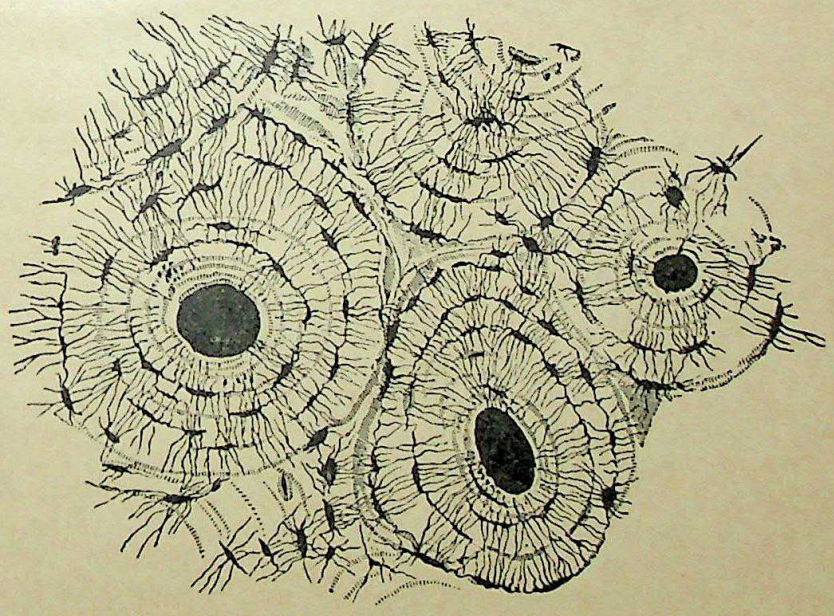

Minute anatomy.—If a thin transverse section of dense bone be examined with a low power of the microscope it will be seen to be mapped out into a number of

CC-0. In Public Domain. Gurukul Kangri Collection, Haridwar

Digitized by Arya Samaj Foundation Chennai and eGangotri

circular districts, each consisting of a central hole surrounded by a number of concentric rings. These districts are termed *Haversian systems*; the central hole is a *Haversian canal*, and the rings are *lamellæ* of bony tissue arranged concentrically around the central canal. Between these lamellæ are a number of small spaces termed *lacunæ*, which are connected with each other and with the central Haversian canal by many fine radiating channels called *canaliculi*. Filling in the irregular intervals between these circular districts are *interstitial* lamellæ, with their lacunæ and canaliculi, running in various directions, but more or less parallel with the surface (fig. 30). Again, other lamellæ are found on the surface of the bone completely encircling it; they are termed *circumferential* or *primary* lamellæ, to distinguish them from those surrounding the Haversian canals, which are termed *secondary* lamellæ.

FIG. 31.—A longitudinal section of the body of the femur. × 100.

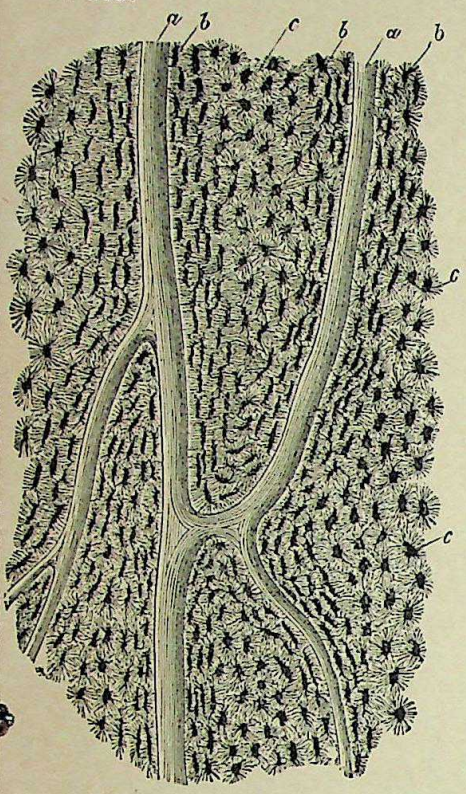

a. Haversian canals. *b*. Lacunæ seen from the side. *c*. Others seen from the surface in lamellæ which are cut horizontally.

In a longitudinal section it will be seen that the Haversian canals run parallel with the long axis of the bone but branch and communicate at short intervals (fig. 31). They vary considerably in size, but their average diameter is about 0·05 mm. The canals near the medullary cavity are larger than those near the surface of the bone. Each canal usually contains a minute artery and vein, a small quantity of delicate connective tissue, and some nerve-filaments; in the larger ones there are also lymphatic vessels, and cells with branching processes.

The *lamellæ* are thin plates of bony tissue. They may be stripped off as thin films from a piece of bone which has been macerated in dilute mineral acid. If one of these films be examined with a high power of the microscope, it will be found

FIG. 32.—The perforating fibres of a human parietal bone, decalcified. (H. Müller.) (From Quain's Elements of Anatomy, vol. ii. pt. i., Microscopic Anatomy.)

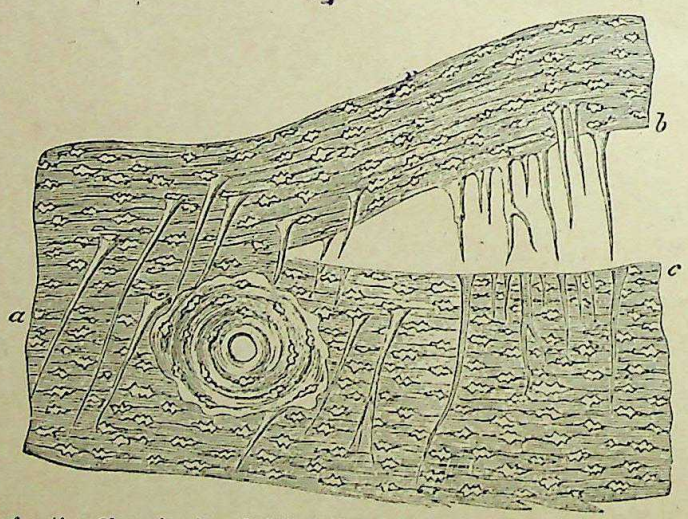

a. Perforating fibres *in situ*; *b*. Fibres drawn out of their sockets; *c*. Sockets.

to be composed of fine fibres identical with the white fibres of connective tissue. The matrix between the fibres is impregnated with lime-salts which the acid dissolves. The fibres are arranged in bundles, and fibres leave the bundles of one lamella to join those of adjacent lamellæ. In this way the fibres of one lamella usually form an acute

CC-0. In Public Domain. Gurukul Kangri Collection, Haridwar

Digitized by Arya Samaj Foundation Chennai and eGangotri

angle with those of the contiguous layer; in the Haversian systems, however, the fibres of adjacent lamellæ run at right angles to each other. In many places the various lamellæ are held together by tapering fibres, which run obliquely through them, pinning or bolting them together; these fibres were first described by Sharpey, and were named by him *perforating fibres* (fig. 32.)

The *lacunæ* are oblong spaces situated between the lamellæ, and each lacuna is occupied during life by a branched *bone-cell* (fig. 33), the processes from which extend into the canaliculi.

The *canaliculi* are minute channels, crossing the lamellæ and connecting the lacunæ of a Haversian system with one another, and with the Haversian canal. The canaliculi at the periphery of a Haversian system do not as a rule communicate with those of neighbouring systems, but form loops and return to their own lacunæ. Thus every part of a Haversian system is supplied with nutrient fluids derived from the vessels in the Haversian canal and distributed through the canaliculi and lacunæ.

The *bone-cells* occupy, but do not fill, the lacunæ. They are flattened nucleated branched cells, homologous with the lamellar cells of connective tissue; their branches pass into the canaliculi.

FIG. 33.—Nucleated bone-cells and their processes, contained in the bone-lacunæ and their canaliculi respectively. From a section through the vertebra of an adult mouse. (Klein and Noble Smith.)

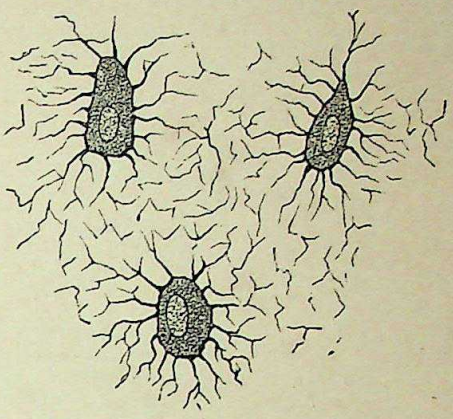

In thin plates of bone Haversian canals are absent.

Chemical composition.—Bone consists of animal or organic, and mineral or inorganic, substances intimately combined.

The animal substance forms about 33 per cent. of the total weight,* and may be obtained by immersing a bone for a considerable time in dilute mineral acid which will dissolve the mineral matter. The bone retains its shape, but is now

FIG. 34.—A transverse section through a portion of the body of a human fibula, decalcified. × 250.

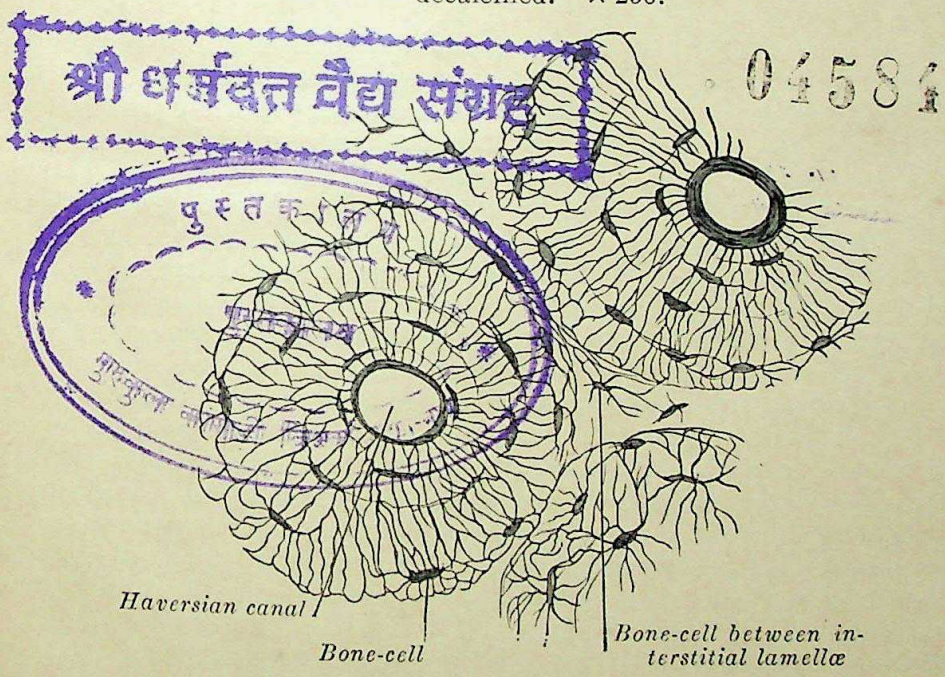

श्री धर्मदत्त वैद्य संग्रह
04584

perfectly flexible, so that a long bone (one of the ribs, for example) can easily be tied in a knot. In a transverse section of such a softened bone (fig. 34), the arrangement of the Haversian canals, lamellæ, lacunæ, and canaliculi can be recognised.

* H. E. Radasch (*Proceedings of the American Association of Anatomists, Anatomical Record*, vol. 21) states that in [illegible] organic substance averages 10·75 per cent.

CC-0. In Public Domain. Gurukul Kangri Collection, Haridwar

Digitized by Arya Samaj Foundation Chennai and eGangotri

The mineral substance may be obtained by calcination which destroys the animal matter. The bone retains its original form, but is white and brittle, has lost about one-third of its original weight, and crumbles under the slightest force. The mineral substance, composed chiefly of calcium phosphate, forms about 66·7 per cent. of the weight of the bone; it confers on bone its hardness and rigidity, while the animal matter (*ossein*) determines its resiliency and tenacity.

Ossification.—Some bones, such as those of the roof and sides of the skull, are preceded by membrane, but most bones are preceded by rods or masses of cartilage. Hence two kinds of ossification are described; the *intramembranous* and the *intracartilaginous*.

Intramembranous ossification.—The membrane which occupies the place of the future bone is of the nature of connective tissue, and ultimately forms the

FIG. 35.—A part of the growing edge of the developing parietal bone of a fœtal cat. (From Quain's Elements of Anatomy: Sir Edward Sharpey Schafer.)

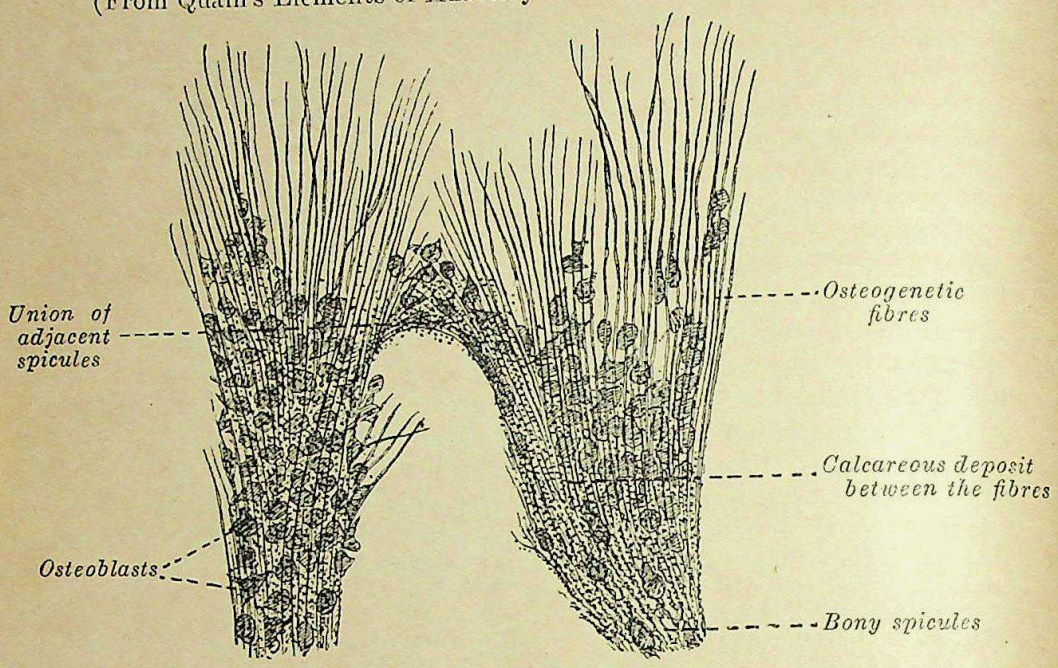

periosteum; it is composed of fibres and granular cells in a matrix richly supplied with blood-vessels. The peripheral portion is more fibrous, while in the central portion the cells or *osteoblasts* predominate. At the outset of the process of bone formation a little network of fibres radiates from the centre of ossification. These rays consist at their growing points of a network of fine clear fibres and granular corpuscles with an intervening ground-substance (fig. 35). The fibres are termed *osteogenetic* fibres, and differ little from those of white fibrous tissue. The membrane assumes a dark and granular appearance from the deposition of calcareous granules in the matrix between the fibres, and in the calcified material some of the granular cells or osteoblasts are enclosed. By the fusion of the calcareous granules the tissue again assumes a more transparent appearance, but the fibres are no longer so distinctly seen. The osteoblasts form the bone-cells of the future bone, the spaces in which they are enclosed constituting the lacunæ. As this process advances, a network of bone is formed, the meshes of which contain the blood-vessels and a delicate connective tissue crowded with osteoblasts. The bony trabeculæ thicken by the addition of fresh layers formed by the osteoblasts on their surface, and the meshes are correspondingly encroached upon. Subsequently the bone increases in thickness by the deposition of successive layers under the periosteum and round the larger vascular channels which become the Haversian canals.

Intracartilaginous ossification.—Most of the bones are ossified in cartilage. Each long bone, for example, is represented in early fœtal life by a rod of hyaline cartilage. Ossification commences in the centre of the rod and proceeds towards the ends, which for some time remain cartilaginous. Subsequently ossification begins at one or more centres in either end, and gradually extends, but a superficial layer of cartilage persists, constituting the articular cartilage. The ossified extremities do not, however, fuse with the body of the bone until growth has ceased;

CC-0. In Public Domain. Gurukul Kangri Collection, Haridwar

Digitized by Arya Samaj Foundation Chennai and eGangotri

between the body and either end a plate of cartilage termed the *epiphysial cartilage* persists throughout the period of growth.

At the *centre of ossification*, or point where the ossifying process begins, the cartilage-cells multiply and enlarge and become arranged in rows radiating from the centre (fig. 36). The matrix in which the cells are imbedded increases in quantity, so that the latter are further separated from each other.

A deposit of calcareous material now takes place in this matrix, so that it presents a granular and opaque appearance. The cartilage-cells are enclosed in oblong cavities, the walls of which are formed of calcified matrix which cuts off all nutrition from the cells; the cells, in consequence, atrophy, leaving spaces called the *primary areolæ*.

While this process is going on in the centre of the bar of cartilage, certain changes are taking place on its surface. This is covered by a very vascular membrane, the *perichondrium*, formed of connective tissue similar to that already described as constituting the basis of membrane-bone; on the inner surface of this—that is to say, on the surface in contact with the cartilage—are gathered the formative cells, the *osteoblasts*. By the agency of these cells a thin layer of bony tissue is laid down, between the perichondrium and the cartilage, by the *intramembranous* mode of ossification just described. There are then, in this first stage, two processes going on simultaneously: in the centre of the cartilage the formation of a number of oblong spaces, bounded by calcified matrix and containing the withered cartilage-cells, and on the surface of the cartilage the formation of a layer of true membrane-bone. The second stage consists in the prolongation into the cartilage of processes of the deeper or osteogenetic layer of the perichondrium (now periosteum) (fig. 36, *ir*). The processes consist of blood-vessels and cells—*osteoblasts*, or bone-formers, and *osteoclasts*, or bone-destroyers. The latter are large, multinucleated protoplasmic masses, and they excavate passages through the new-formed bony layer by absorption, and pass through it into the calcified matrix (fig. 38). Wherever these processes of the osteogenetic layer come in contact with the calcified walls of the primary areolæ they absorb them, and thus cause a fusion of the original cavities and the formation of larger spaces, which are termed the *secondary areolæ* or *medullary spaces*. These secondary spaces are filled with embryonic marrow, consisting of osteoblasts and vessels, derived, in the manner described above, from the osteogenetic layer of the periosteum (fig. 37).

FIG. 36.—A section through a fœtal bone of a cat. (From Quain's Elements of Anatomy: Sir Edward Sharpey Schafer.)

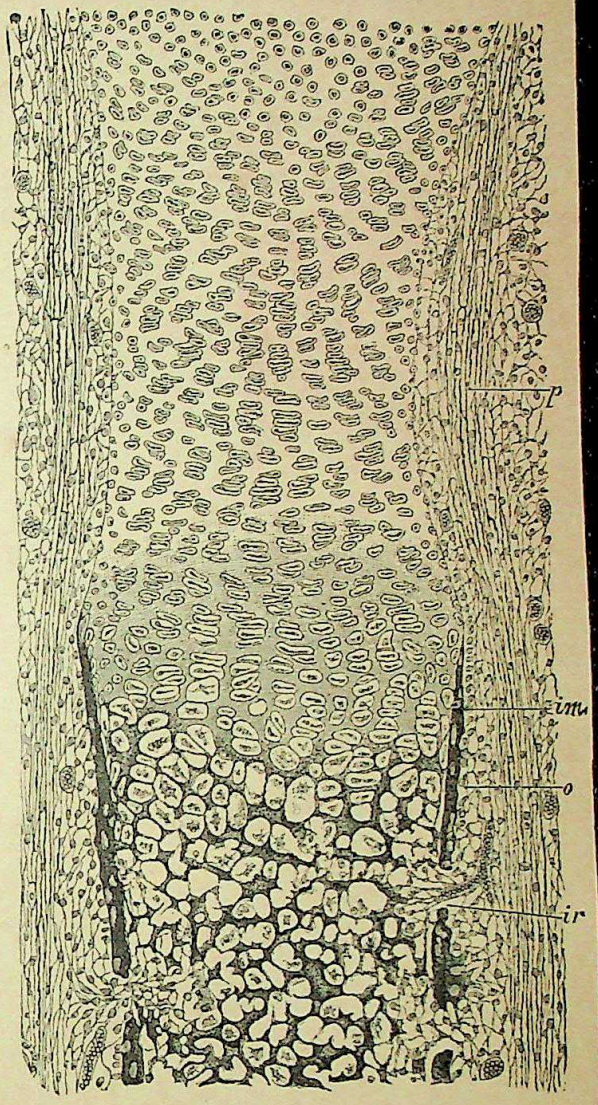

im. Subperiosteal bony deposit. *ir.* Irruption of the subperiosteal tissue. *o.* Layer of osteoblasts. *p.* Fibrous layer of the periosteum.

The walls of the secondary areolæ increase in thickness by the deposition of layers of bone on their surface. This process takes place in the following manner. Some of the osteoblasts of the embryonic marrow, after undergoing rapid division, arrange themselves as a layer on the surface of the wall of the space (fig. 37). This layer of osteoblasts forms a bony stratum, which gradually covers the wall of the space and in which some of the osteoblasts are included as bone-cells. The next

CC-0. In Public Domain. Gurukul Kangri Collection, Haridwar

Digitized by Arya Samaj Foundation Chennai and eGangotri

stage in the process consists in the removal of these primary bone-spicules by the osteoclasts, one of which may be seen lying in a Howship's foveola at the free end of each spicule (fig. 38). The removal of the primary spicules goes on *pari passu* with the formation of permanent bone by the periosteum, and in this way the medullary cavity of the bone is formed.

FIG. 37.—A part of a longitudinal section through the developing femur of a human fœtus. Stained with borax carmine. × 100.

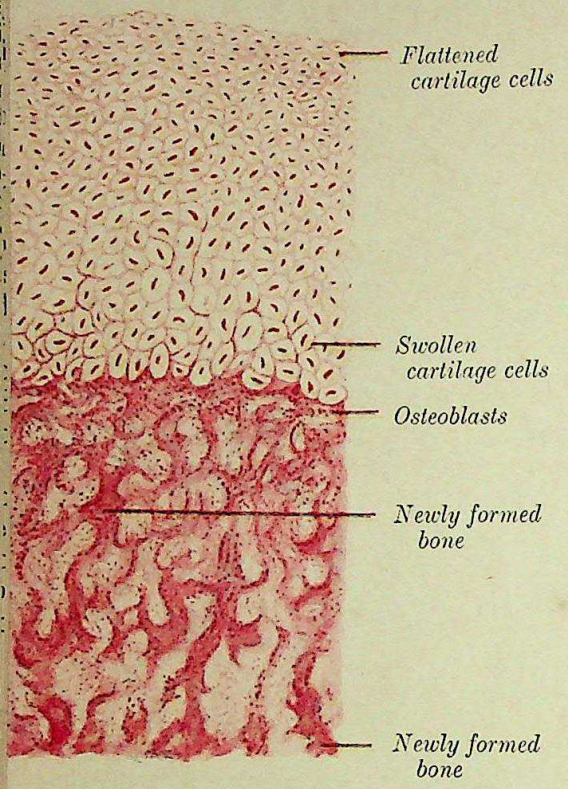

This series of changes proceeds gradually towards the ends of the bone, so that all the changes described above may be seen in different parts, from the true bone at the centre of the body to the hyaline cartilage at the extremities.

While the ossification of the cartilaginous body is extending towards the articular ends, the epiphysial cartilage immediately in advance of the osseous tissue continues to grow until the length of the adult bone is reached.

The articular end remains for some time cartilaginous, and then one or more secondary bony centres appear, and initiate in it the process of ossification; but the extremity remains separated from the body of the bone by the epiphysial cartilage for a definite time. This cartilage ultimately ossifies, and the bone assumes its completed form and shape. The same remark applies to such processes of bone as are ossified from separate epiphyses, e.g. the trochanters of the femur. Bones increase in length by ossification continuing to extend into the epiphysial cartilage, which goes on growing in advance of the ossifying process. They increase in circumference by

FIG. 38.—Osteoblasts and osteoclasts in the developing femur of a kitten. × 350.

deposition of new bone, from the deep layer of the periosteum, on their external surfaces, and at the same time an absorption takes place from within, by which the medullary cavities are increased.

The permanent bone formed by the periosteum when first laid down is spongy in structure. Later the osteoblasts contained in its spaces form the concentric layers characteristic of the Haversian systems, and are included as bone-cells.

CC-0. In Public Domain. Gurukul Kangri Collection, Haridwar

Digitized by Arya Samaj Foundation Chennai and eGangotri

The number of ossific centres varies in different bones. Most of the short bones are ossified from a single centre. In each long bone there is a primary centre for the body, or diaphysis; and one or more secondary or epiphysial centres for each extremity. That for the body is the first to appear. The times of union of the epiphyses with the body vary inversely with the dates at which their ossifications begin (with the exception of the fibula) and regulate the direction of the nutrient arteries of the bones. Thus, the nutrient arteries of the bones of the arm and forearm are directed towards the elbow, since the epiphyses at this joint become united with the bodies of the bones before those at the opposite extremities. In the lower limb, on the contrary, the nutrient arteries are directed away from the knee; that is, upwards in the femur, downwards in the tibia and fibula; and in them it is observed that the epiphyses at the upper end of the femur, and those at the lower ends of the tibia and fibula, unite first with the bodies. Where there is only one epiphysis, the nutrient artery is directed towards the other end of the bone.

Parsons * groups epiphyses under three headings, viz. (1) *pressure epiphyses*, appearing at the articular ends of the bones and transmitting 'the weight of the body from bone to bone'; (2) *traction epiphyses*, associated with the insertion of muscles, and 'originally sesamoid structures though not necessarily sesamoid bones'; and (3) *atavistic epiphyses*, representing parts of the skeleton which at one time formed separate bones, but which have lost their function 'and only appear as separate ossifications in early life.'

The description here given of the development and growth of bone is in accordance with the generally accepted view. Macewen † has, however, given another account. He asserts that the osteoblasts are produced by division of the nuclei of the cartilage-cells, and that bone-formation is brought about by these cells, the periosteum taking no part in the process. He concludes that the function of the periosteum in the development of bone is mechanical, and is confined to limiting the degree of growth and deciding its direction.

Applied Anatomy.—A knowledge of the arrangements of the nutrient vessels of bones is important in studying injuries and inflammatory conditions to which bones are liable. The free supply of blood to the epiphyses of the long bones is one reason why necrosis does not extend the whole length of the bone. The outer portion of the compact tissue is supplied by periosteal vessels, many of which reach the periosteum through the attachments of the muscles. Where the muscles are well-developed their blood-supply is abundant, and the periosteum is also well supplied with blood, so that the bones are strongly developed and their ridges prominently marked. Conversely, if the muscular development be poor, the bones are thin and light.

When the periosteum becomes separated by extensive injury or inflammatory exudation, the underlying compact tissue, being deprived of its blood-supply, undergoes *necrosis*, i.e. dies, and the dead part is termed a *sequestrum*. In cases of *acute infective periostitis* the inflammatory process affects the whole or a great portion of the diaphysis of a long bone, and the body of the bone dies very rapidly, especially if the single nutrient artery be thrombosed at the same time. The pus which has formed beneath the periosteum is set free by the bursting of the periosteum or by a timely incision; the periosteum then falls back on the necrosed diaphysis and rapidly forms a layer of new bone surrounding the sequestrum. This layer is called the *involucrum*, and the openings in it through which the pus escapes are termed *cloacæ*.

In another type of inflammation of bone the process begins deeply in the growing portion of the epiphysis, and affects mainly the medullary canal, and is known as *osteomyelitis*; very frequently it coexists with acute infective periostitis and the condition is then spoken of as *acute infective necrosis* of bone, or *acute diaphysitis*. When the medullary cavity is filled with pus, septic thrombosis of the veins in the Haversian canals takes place, and there is great danger of septic emboli being displaced and carried into the general circulation, thus setting up a fatal *pyæmia*; in fact pyæmia is more frequently due to septic bone conditions than to any other cause.

The factors involved in the development and growth of bone must be remembered in dealing with the various injuries and diseases that occur during childhood and adolescence. A bone increases in *circumference* by the deposition on its external surface of new bone from the deeper layer of the periosteum, and in *length* by ossification continuing to extend in the epiphysial cartilage, which goes on growing in advance of the ossifying process.

In *infantile paralysis* where several muscles of a limb become paralysed at a very early period of childhood, the muscles become flaccid and atonic, and their blood-supply is greatly diminished. The periosteal blood-supply suffers and consequently very little

* *Journal of Anatomy and Physiology*, vols. xxxviii., xxxix., and xlii.

† *The growth of bone*, by Sir William Macewen.

CC-0. In Public Domain. Gurukul Kangri Collection, Haridwar

Digitized by Arya Samaj Foundation Chennai and eGangotri

fresh osseous tissue is added to the outer surfaces of the bones. In such cases, although the limb continues to grow in length at the epiphysial cartilages, its length is less than that of the normal side, owing to the imperfect nutrition; but the most striking feature about all the long bones of the limb is their extreme thinness.

Since increase in the length of a bone depends on continued growth at the epiphysial cartilages, it is necessary that great care should be taken not to interfere with these in dealing with disease in the neighbourhood of an epiphysis. A knowledge of the periods when the epiphyses join the diaphyses is often of importance in medico-legal enquiries. It is also of practical utility in deciding the nature of an injury in the neighbourhood of a joint, since separation of an epiphysis may simulate a fracture or a dislocation. Further, when amputation through one of the long bones is called for in a young subject the activity of growth at the epiphysial cartilage must be borne in mind. As special cases, amputation through the humerus or tibia may be cited, since in these bones the proximal epiphyses are late in joining the diaphyses. If sufficient allowance be not made for this by cutting long flaps, the portion of the diaphysis remaining will continue to grow till its distal end projects through the stump—a condition known as *conical stump*.

Some of the epiphyses lie entirely within the articular capsules of their corresponding joints, and in such cases disease of the epiphysis is practically synonymous with disease of the joint. The best examples of intra-articular epiphyses are those of the head of the femur and the head of the humerus; the vast majority of cases of tuberculous disease of the hip start as a tuberculous epiphysitis about the intra-articular epiphysial cartilage of the femur; cases of acute septic arthritis of the shoulder- or hip-joints generally have their origins in the intra-articular epiphysial cartilages, and often result in separation of the affected epiphysis. Where an epiphysial cartilage is extra-articular, disease in it does not tend so readily to involve the joint; thus the epiphysial cartilage of the greater trochanter of the femur and that of the upper end of the tibia are outside the joint-capsules, so that if a chronic tuberculous abscess should form in either of these cartilages, its spread into the joint may be prevented by early operation.

Premature arrest of growth of the epiphysial cartilages results in too early junction of the epiphyses with the diaphyses (*premature synostosis*). This brings to an end the growth in length of the bones, and is one of the causes of dwarfism. Persons in whom this has occurred will have the head and trunk of normal size, but the legs and arms disproportionately short though often very strong.

THE CIRCULATING FLUIDS

The **circulating fluids** of the body are the blood and the lymph.

The Blood

The **blood** is an opaque, rather viscid fluid, of a bright red or scarlet colour when it flows from the arteries, of a dark red or purple colour when it flows from the veins. It is salt to the taste, and has a peculiar faint odour and an alkaline reaction. Its specific gravity is about 1·059, and its temperature is generally about 37° C., though varying slightly in different parts of the body.

If a thin film of blood be examined under the microscope it is seen to consist of a faintly yellow fluid, the *plasma* or *liquor sanguinis*, in which are suspended numerous minute particles, the *blood-corpuscles*.

The **blood-corpuscles** are of three kinds: (1) coloured corpuscles or erythrocytes, (2) colourless corpuscles or leucocytes, (3) blood-platelets.

1. The **coloured or red corpuscles** (*erythrocytes*) are circular discs, biconcave in profile. The disc has no nucleus, but, in consequence of its biconcave shape, it presents, when seen on the flat, a central area which, when the more prominent peripheral zone of the corpuscle is in focus, appears dark, and so simulates a nucleus (fig. 39, *a*). The corpuscles vary slightly in size even in the same drop of blood, but the average diameter of each is about 7·5μ, and the thickness about 2μ. Besides these there are certain smaller corpuscles of about one-half of the size just indicated; these are termed *microcytes*, and are very scarce in normal blood; in diseased conditions (e.g. anæmia), however, they are more numerous. It is to the aggregation of the red corpuscles that the blood owes its red hue, although when examined by transmitted light their colour appears to be only a faint reddish yellow. The number of red corpuscles in a cubic millimetre of blood is about 5,000,000 in a man, and 4,500,000 in a woman. Power states that the red corpuscles of an adult would present an aggregate surface of about 3,000 square yards.

CC-0. In Public Domain. Gurukul Kangri Collection, Haridwar

Digitized by Arya Samaj Foundation Chennai and eGangotri

If the mesentery of a living animal be spread out and examined under the microscope, the blood is seen to flow in a continuous stream through the vessels, and the corpuscles show no tendency to adhere to each other or to the walls of the vessels. But when blood is drawn and examined on a slide, the corpuscles tend to collect into heaps like rouleaux of coins (fig. 39, *c*). During life the red corpuscles may be seen to change their shape under pressure so as to adapt themselves, to some extent, to the size of the vessel. They are, however, highly elastic, and speedily regain their form when the pressure is removed. They are readily influenced by the medium in which they are placed. In 0·9 per cent. sodium chloride solution, which is isotonic with human blood-plasma, they are unaltered in shape. In hypotonic solutions they swell up, become globular, and finally rupture, owing to the passage of water from the surrounding medium into the corpuscle (*endosmosis*). In hypertonic solutions, e.g. 2 per cent. sodium chloride, water passes in the reverse direction (*exosmosis*) and the corpuscle shrinks and becomes crenated in appearance (fig. 39, *d*). The surface layer of the erythrocyte thus behaves as a membrane which is permeable to water, but not to salts (semi-permeable membrane), and, for this and other reasons, Sharpey Schafer believes that each corpuscle consists of an envelope containing the coloured substance, hæmoglobin. According to another view, the erythrocyte consists of a stroma or sponge-work permeated by the hæmoglobin. The stroma or envelope consists mainly of cholesterol, lecithin, and nucleoprotein.

FIG. 39.—Human red blood-corpuscles. × 1500.

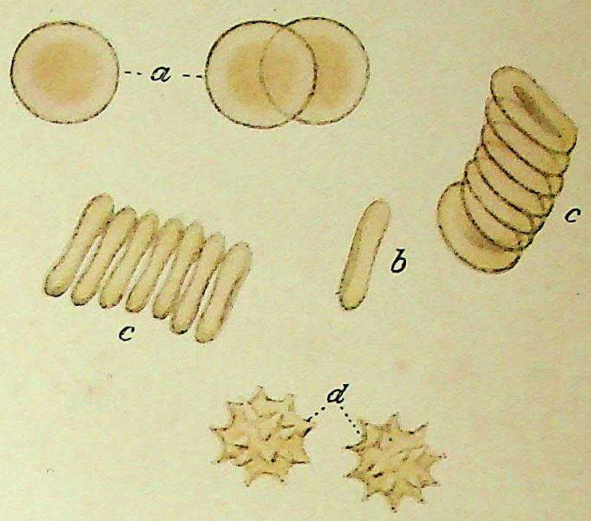

a. Seen from the surface. *b*. Seen in profile. *c*. Forming rouleaux. *d*. Rendered crenate by salt solution.

The **colourless corpuscles** or *leucocytes* are of various sizes. In human blood the majority are rather larger than the red corpuscles, and measure about 10μ in diameter. On the average from 7,000 to 12,000 leucocytes are found in each cubic millimetre of blood.

FIG. 40.—Varieties of colourless corpuscles found in human blood, stained with Leishman's stain. × 1500.

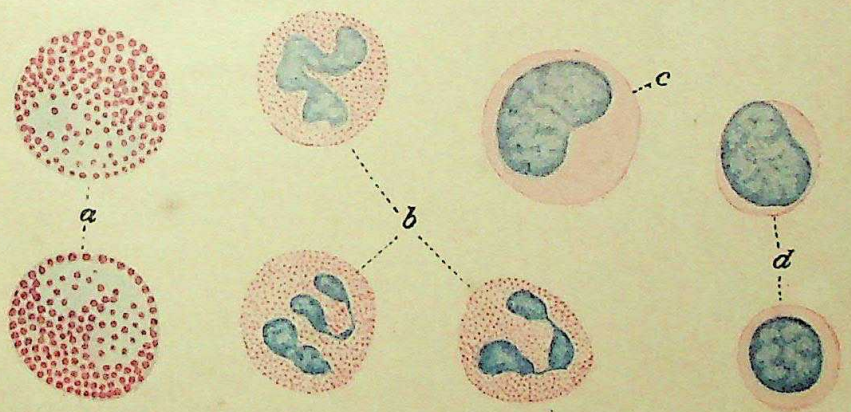

a. Eosinophil corpuscles. *b*. Polymorphonuclear leucocytes. *c*. Hyaline cell or macrocyte *d*. Lymphocytes.

They consist of minute nucleated masses of protoplasm, and exhibit several varieties, which are differentiated from each other chiefly by the occurrence or non-occurrence of granules in their protoplasm, and by the staining reactions of these granules when present (fig. 40). (1) The most numerous and important

CC-0. In Public Domain. Gurukul Kangri Collection, Haridwar

Digitized by Arya Samaj Foundation Chennai and eGangotri

are termed *polymorphonuclear* leucocytes; they are irregular in shape in the living condition, are possessed of the power of amœboid movement, and contain nuclei which often consist of two or three parts (multipartite) connected together by fine threads of chromatin. When at rest or dead, they are spherical in shape as a rule. The protoplasm contains a number of very fine granules, some of which stain with acid dyes, others with neutral dyes, and are therefore called *oxyphil* or *neutrophil* respectively. They constitute 60 to 70 per cent. of the total number of the colourless corpuscles. (2) A second variety comprises from 1 to 4 per cent. of the leucocytes; they are larger than the previous kind, and are made up of coarsely granular protoplasm, the granules being highly refractile and grouped round single nuclei of horseshoe shape. The granules stain deeply with eosin, and the cells are therefore often termed *eosinophil* corpuscles. (3) A third variety is called the *hyaline* cell or *macrocyte*. This is usually about the same size as the eosinophil cell, and, when at rest, is spherical in shape and contains a single round or oval nucleus. The protoplasm is free from granules, but is not quite

Fig. 41.—Human colourless blood-corpuscle, showing its successive changes of outline within ten minutes when kept moist on a warm stage. (Schofield.)

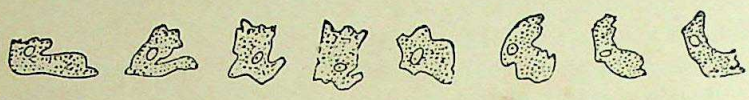

transparent, having the appearance of ground glass. (4) A fourth kind is designated the *lymphocyte*, because it is identical with the cells derived from the lymph-glands, or other lymphoid tissue. They are the smallest of the leucocytes, and each consists of a spheroidal nucleus surrounded by a small quantity of homogeneous protoplasm. The third and fourth varieties together constitute from 20 to 30 per cent. of the colourless corpuscles, but of the two varieties the lymphocytes are by far the more numerous. Leucocytes having in their protoplasm granules which stain with basic dyes (*basiphil*) have been described as occurring in human blood, but they are rarely found except in disease.

The colourless corpuscles are very various in shape in living blood (fig. 41), because many of them have the power of constantly changing their form by protruding finger-shaped or filamentous processes of their substance, by which they move and take up granules from the surrounding medium. In locomotion the corpuscle pushes out a process of its substance—a *pseudopodium*, as it is called—and gradually the rest of the body flows into it. In the same way when any granule or particle comes in its way the corpuscle protrudes a pseudopodium towards it, and then draws the particle into its own substance. By means of these amœboid properties the cells have the power of wandering or emigrating from the blood-capillaries by penetrating between the cells which form their walls and thus finding their way into the extravascular spaces. The solid chemical constituents of leucocytes are nucleo-protein, globulin, fat, cholesterol, lecithin, glycogen, and salts.

Fig. 42.—Blood-platelets. Highly magnified. (After Kopsch.) (From Sharpey Schafer's Essentials of Histology.)

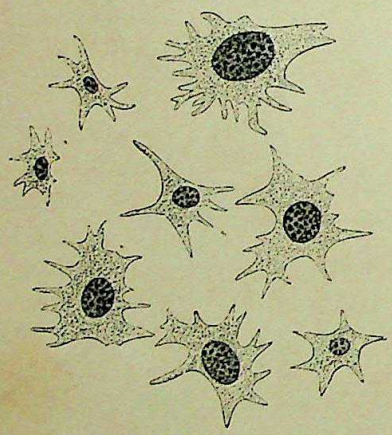

The **blood-platelets** (fig. 42) are discoid or irregularly shaped, colourless, refractile bodies, much smaller than the red corpuscles. Each contains a central chromatin mass resembling a nucleus. Blood-platelets possess the power of amœboid movement. When blood is shed they rapidly disintegrate and form granular masses, setting free *thrombokinase*, a substance which takes part in the production of fibrin and so is concerned in bringing about the coagulation of the blood. It is doubtful whether platelets exist normally in circulating blood.

The development of the blood-corpuscles is described on pp. 109, 110.

CC-0. In Public Domain. Gurukul Kangri Collection, Haridwar

Digitized by Arya Samaj Foundation Chennai and eGangotri

The Lymph

The **lymph** is a transparent, colourless or slightly yellow fluid, which is conveyed into the blood by a set of vessels named *lymphatics*. These vessels arise in nearly all parts of the body as *lymph-capillaries*. They take up the fluid which has exuded from the blood-capillaries for the nourishment of the tissues, and return it into the veins. The greater number of these lymphatic vessels empty themselves into the *thoracic duct*, which ascends in front of the vertebral column and opens into the junction of the internal jugular and subclavian veins on the left side of the root of the neck. The remainder empty themselves into a smaller duct which ends in the corresponding veins on the right side of the neck.

Lymph is a watery fluid of sp. gr. about 1·015 ; it closely resembles the blood-plasma, but is more dilute. When it is examined under the microscope, leucocytes of the lymphocyte class are found floating in the transparent fluid ; they are always increased in number after the passage of the lymph through lymphoid tissue, as in lymph-glands.

MUSCULAR TISSUE

Muscular tissue is composed of bundles of reddish fibres endowed with the property of contractility. There are three varieties of muscle, (1) *striped* or *voluntary*, (2) *unstriped* or *involuntary*, and (3) *cardiac*. The muscles which are concerned with the movements of the bony skeleton, the skeletal muscles, are composed of striped fibres, and are under the control of the will. The muscular coats of the stomach and intestines, uterus, bladder and blood-vessels, on the contrary, are formed of unstriped fibres, and their movements are involuntary. Some striped muscles, however, are not under voluntary control, namely, those forming the walls of the pharynx and upper part of the œsophagus. Cardiac muscle is intermediate in position between the other two varieties. Its fibres are striped, but involuntary, and they differ from both striped and unstriped muscle in structure.

Fig. 43.—A transverse section through human striped muscle fibres. × 255.

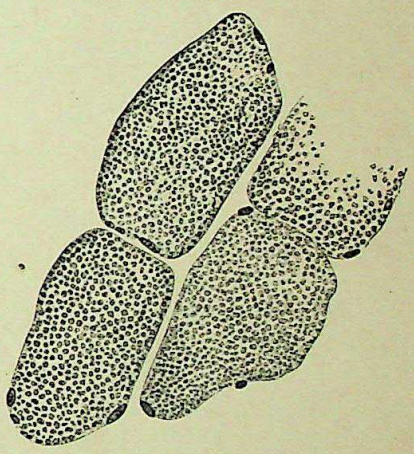

The **striped muscular fibres** are arranged in bundles or *fasciculi*, in which the individual fibres are parallel to each other. Each fasciculus has a connective tissue sheath, called the *perimysium*, prolongations of which run into the bundle, binding the fibres together and constituting the *endomysium*. A muscle is composed of a number of fasciculi, held together and surrounded by connective tissue which is known as the *epimysium*. The fasciculi are of different sizes in different muscles, and are for the most part placed parallel to each other, though they usually converge towards the tendinous attachments. The connective tissue framework of the muscle contains the blood-vessels and nerves which supply it.

A *muscular fibre* consists of a soft contractile substance, enclosed in a tubular sheath called the *sarcolemma*. The fibres are cylindrical or prismatic in shape (fig. 43), and are of no great length, not exceeding as a rule 40 mm. Their breadth varies in man from 0·01 mm. to 0·1 mm. As a rule, the fibres do not divide or anastomose ; but occasionally, especially in the tongue and facial muscles, they may be seen to divide into several branches. In the substance of the muscle, the fibres end by tapering extremities which are joined to the ends of other fibres by the sarcolemma. Where a muscle joins its tendon, the sarcolemma covering the end of each muscle-fibre blends with a corresponding group of the fine fibres of the tendon. The muscular substance of the fibre can readily be made to retract from the point of junction. The areolar tissue between the fibres is prolonged

CC-0. In Public Domain. Gurukul Kangri Collection, Haridwar

Digitized by Arya Samaj Foundation Chennai and eGangotri

into the tendon, so as to form a kind of sheath around the tendon-bundles for a longer or shorter distance. When muscular fibres are attached to skin or mucous membranes, this sheath becomes continuous with the areolar tissue of these structures.

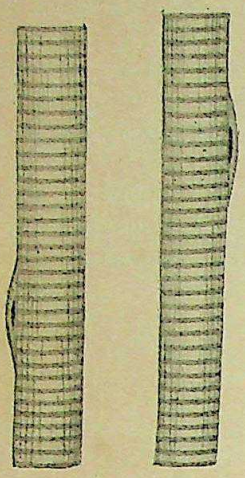

Fig. 44.—Striped muscle-fibres from the tongue of a cat. × 250.

The *sarcolemma*, or tubular sheath of the fibre, is a transparent, elastic, and apparently homogeneous membrane of considerable toughness, so that it sometimes remains entire when the included substance is ruptured. On the internal surface of the sarcolemma in mammalia, and also in the substance of the fibre in frogs, elongated nuclei are seen, and surrounding each of these is a little granular protoplasm.

Upon examination of a voluntary muscular fibre by transmitted light, it is found to be marked by alternate light and dark bands or striæ, which pass transversely across the fibre (fig. 44). When examined by polarised light the dark bands are found to be doubly refracting (anisotropic), while the clear stripes are singly refracting (isotropic). The dark and light bands are of nearly equal breadth, and alternate with great regularity; they vary in breadth from about 1μ to 2μ. When the fibre is deeply focussed a dark line may be seen running in the middle of the clear stripe. This is known as *Dobie's line* or *Krause's membrane*. In fibres which are in the extended condition the dim stripe is often seen to be divided by a clearer line, *Hensen's line*.

Under high magnification there are indications that the striped muscle-fibre is made up of a large number of fibrils, known as *sarcostyles*, together with an interfibrillar material, or *sarcoplasm* (fig. 45, B). When a fibre is treated with weak acid it becomes clearer, and the sarcoplasm is visible as fine, longitudinal, parallel lines. At the junction of the dim and clear stripes these lines often show bead-like enlargements in the extended condition of the fibre. Examination of transverse sections of individual fibres shows that each sarcostyle is surrounded by sarcoplasm, and that the sarcostyles are arranged in groups called *muscle-columns*, the groups being separated by a relatively larger amount of sarcoplasm than the separate fibrils. The sections of muscle-columns, defined in this way, constitute what are known as *Cohnheim's areas*.

Fig. 45.—A. A portion of a medium-sized human muscular fibre. Magnified nearly 800 diameters. B. Separated bundles of fibrils, equally magnified. (From Quain's Elements of Anatomy.)

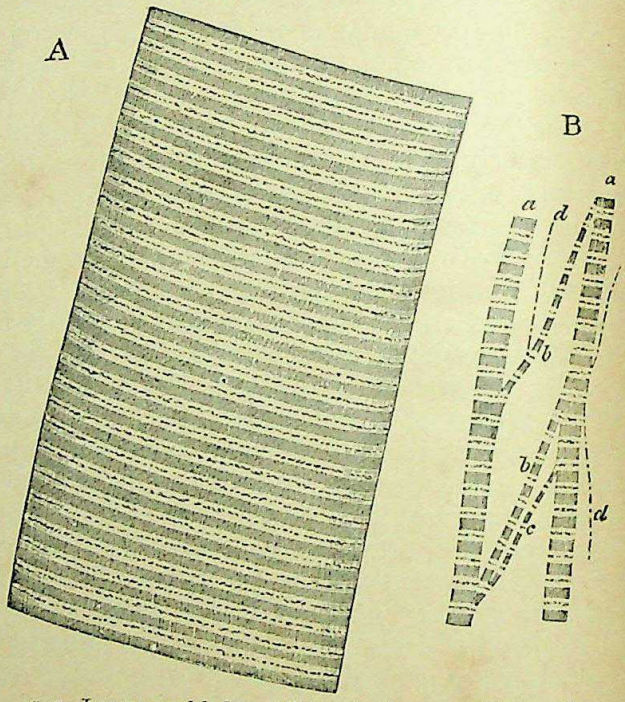

a, a. Larger, and *b, b,* smaller collections. *c.* Still smaller. *d, d.* The smallest which could be detached.

When the sarcostyles are separated by suitable methods it becomes evident that each exhibits alternate dim and clear portions, with Dobie's and Hensen's lines, and that the striped appearance of the fibre is due to the apposition of the corresponding segments of the fibrils of which it is composed.

Sharpey Schafer has worked out the minute anatomy of muscular fibre, particularly in the wing-muscles of insects, which are peculiarly adapted for this purpose on account of the relatively large size of the sarcostyles and the ease with which they can be separated. In the following description that given by Sharpey Schafer is closely followed.

CC-0. In Public Domain. Gurukul Kangri Collection, Haridwar

Digitized by Arya Samaj Foundation Chennai and eGangotri

A sarcostyle may be said to be made up of successive portions, each of which is termed a *sarcomere*. The sarcomere is situated between two membranes of Krause, and consists of (1) a central dark part, which forms a portion of the dark band of the whole fibre, and (2) a clear area at either end, each forming, with the corresponding clear part of the adjacent sarcomere, the light band of the fibril. The central dark segment really consists of two parts, and when the fibre is stretched these two parts become separated from each other at the line of Hensen (fig. 46, A). The clear areas are well marked in the extended sarcostyle, but in the contracted sarcostyle they are small or altogether absent (fig. 46, B).

The central dim portion, or *sarcous element*, does not lie free in the sarcomere, for when the sarcostyle is stretched, very fine lines, which are probably septa, may be seen running through the clear portion from the sarcous element to the membrane of Krause.

Sharpey Schafer explains these phenomena in the following way. He considers that each dim segment contains a number of longitudinal channels, which open into the clear part towards the membrane of Krause but are closed at the line of Hensen. When the muscular fibre contracts the clear part of the muscular substance passes into these channels or tubes, and is therefore hidden from sight, but at the same time it swells up the sarcous element and widens and shortens the sarcomere.

FIG. 46.—A diagram of a sarcomere. (After Sharpey Schafer.)

A. In a moderately extended condition. B. In a contracted condition.

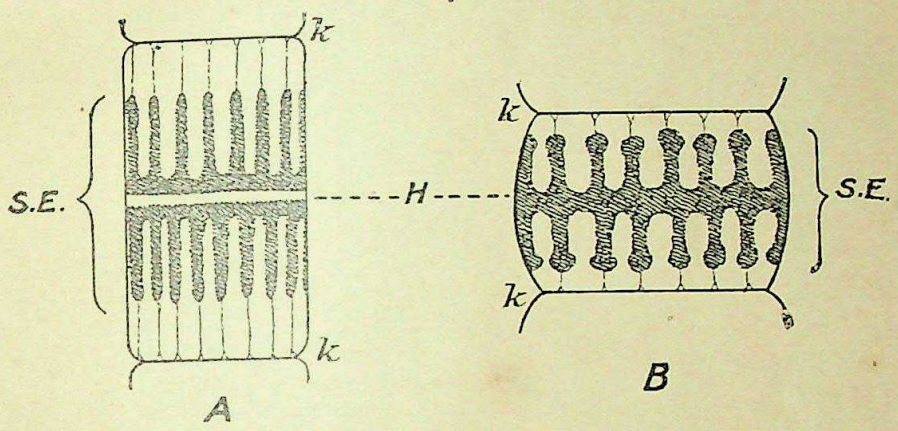

H. Line of Hensen. *k*, *k*. Membranes of Krause. S.E. Sarcous element.

When, on the contrary, the fibre is extended, this clear substance is driven out of the tubes and collects between the sarcous element and the membrane of Krause, and gives the appearance of the light part between these two structures; by this means it elongates and narrows the sarcomere.

Sharpey Schafer has shown that, if this view be correct, it harmonises the contraction of muscle with the amœboid action of protoplasm. In an amœboid cell there is, according to one view of the structure of protoplasm, a framework of spongioplasm, enclosing in its meshes a clear substance, hyaloplasm. Under stimulation the hyaloplasm passes into the pores of the spongioplasm; without stimulation it tends to pass out, as in the formation of pseudopodia. In muscle there is the same thing, viz. a framework of spongioplasm—the substance of the dim segment; and this encloses a clear hyaloplasm, the clear substance of the sarcomere. During contraction of the muscle—i.e. under stimulation—this clear substance passes into the pores of the spongioplasm; while during extension of the muscle—i.e. when there is no stimulation—it tends to pass out of the spongioplasm. In this way the contraction is brought about; under stimulation the protoplasmic material (the clear substance of the sarcomere) recedes into the sarcous element, causing the sarcomere to widen out and shorten. The contraction of the muscle is merely the sum total of this widening out and shortening of these bodies.

Vessels and nerves of striped muscle.—The *capillaries* of striped muscle are very abundant, and form a sort of rectangular network, the branches of which run longitudinally in the endomysium between the muscular fibres, and are joined at short intervals by transverse anastomosing branches. In the red muscles of the rabbit dilatations occur on the transverse branches of the capillary network. The

CC-0. In Public Domain. Gurukul Kangri Collection, Haridwar

Digitized by Arya Samaj Foundation Chennai and eGangotri

larger vascular channels, arteries and veins, are found only in the perimysium, between the muscular fasciculi. *Nerves* are profusely distributed to striped muscle. Their mode of termination is described in the chapter on Neurology. *Lymphatic vessels* do not occur in striped muscle, though they have been found in tendons and in the sheaths of the muscles.

The **unstriped, plain,** or **involuntary muscle** is found in the following situations—in the lower half of the œsophagus and the whole of the remainder of the gastro-intestinal tube; in the trachea and bronchi; in the gall-bladder and common bile-duct; in the large ducts of the salivary and pancreatic glands; in the pelvis and calyces of the kidney, the ureter, bladder, and urethra; in the female sexual organs—viz. the ovary, the uterine tubes, the uterus (enormously developed in pregnancy), the vagina, the broad ligaments, and the corpora cavernosa of the clitoris; in the male sexual organs—viz. the Dartos of the scrotum, the ductus deferentes and epididymes, the vesiculæ seminales, the prostate, and the corpora cavernosa of the penis and urethra; in the capsule and trabeculæ of the spleen; in the mucous membranes, forming the muscularis mucosæ; in the skin, forming the Arrectores pilorum, and also in the sweat-glands; in the mammary glands; in the arteries, veins, and lymphatics; in the iris and the ciliary muscle.

Fig. 47.—Muscle-fibres from the small intestine. (From Quain's Elements of Anatomy, vol. ii. pt. i., Microscopic Anatomy, by Sir Edward Sharpey Schafer.)

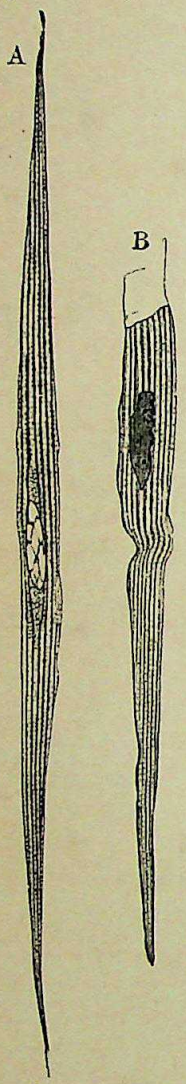

A. Complete cell. B. Broken cell showing delicate external layer.

Fig. 48.—Anastomosing muscular fibres of the heart seen in a longitudinal section. On the right the limits of the separate cells with their nuclei are exhibited somewhat diagrammatically. (Schweigger-Seidel.)

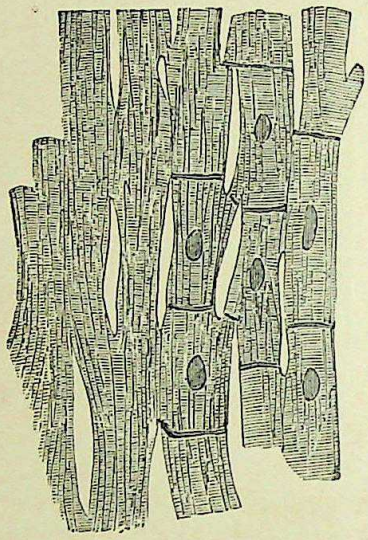

Unstriped or plain muscle is made up of spindle-shaped cells (fig. 47), collected into bundles and held together by a cement-substance. These bundles are further aggregated into larger fasciculi, or sheets, bound together by ordinary connective tissue.

The cells are elongated, spindle-shaped, and nucleated, and are of various sizes, averaging from 40μ to 80μ in length, and 6μ to 7μ in breadth. On transverse section they are more or less polyhedral in shape, from mutual pressure. Each presents a faint longitudinal striation and consists of an elastic cell-wall containing the contractile substance, and an oval or rod-like nucleus. A centriole lies close to the nucleus. The fibres are attached to one another by a certain amount of interstitial cement-substance which reduces nitrate of silver, but in some regions, e.g. the muscular coats of the intestines, the muscle-cells are also connected by 'bridges' similar to those which occur in the prickle-cells of the epidermis.

Sheets of smooth muscle frequently exhibit rhythmical contractions, which are more sluggish than the contractions of striped muscle, and in many cases travel

CC-0. In Public Domain. Gurukul Kangri Collection, Haridwar

Digitized by Arya Samaj Foundation Chennai and eGangotri

along the membrane in the form of waves. Such waves are well marked in the wall of the intestine. Contraction is often excited by a mechanical stimulus, as distension, for example, in the urinary bladder.

The **cardiac muscular tissue.**—The fibres of the heart differ very remarkably from those of other striped muscles. They are striated both transversely and longitudinally, but the striation, as compared with that of striped muscle, is faint and indistinct. The fibres are made up of quadrangular cells joined end to end so as to form a syncytium (fig. 48). Each cell contains a clear oval nucleus, situated near its centre. Many of the cells branch or divide, the subdivisions uniting with offsets from other cells, and thus producing an anastomosis of the fibres. The connective tissue between the bundles of fibres is much less than in ordinary striped muscle, and no sarcolemma has been proved to exist.

Purkinje's fibres (fig. 49).—Between the endocardium and the ordinary cardiac muscle are found, embedded in a small amount of connective tissue, peculiar fibres known as *Purkinje's fibres.* They are associated with the terminal distributions of the atrioventricular bundle. The fibres are very much larger in size than the cardiac cells and differ from them in several ways. In longitudinal section they are quadrilateral in shape, being about twice as long as they are broad. The central portion of each fibre contains one or more nuclei and is made up of granular protoplasm, with no indication of striation, while the peripheral portion is fibrillated and has transverse striations. The fibres are intimately connected with each other, possess no definite sarcolemma, and do not branch. They form a considerable portion of the moderator band in the heart of the sheep.

FIG. 49.—Purkinje's fibres from the sheep's heart. × 250.

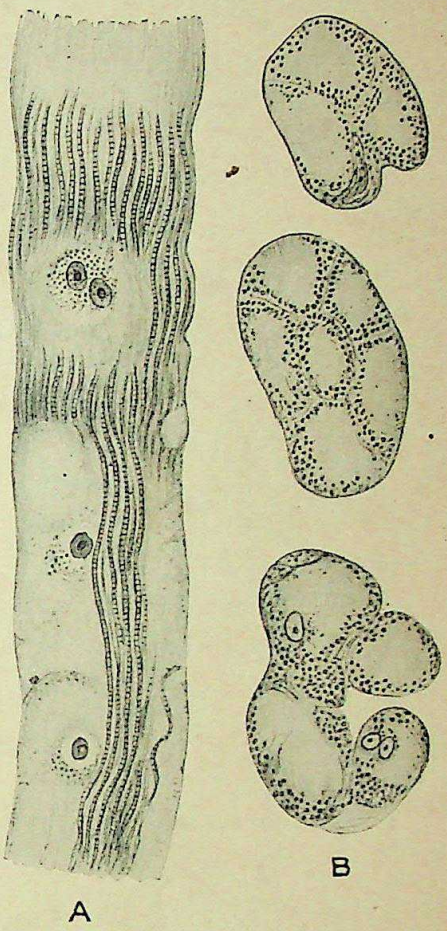

A. In longitudinal section.
B. In transverse section.

The **atrioventricular bundle** (see chapter on Angiology) is composed of cells which differ from ordinary cardiac muscle-cells in being more spindle-shaped. They are, moreover, more loosely arranged and have a richer vascular supply than the rest of the cardiac muscle.

Development of muscle-fibres.—Voluntary muscular fibres are developed from the mesoderm, the embryonic cells of which elongate, show multiplication of nuclei, and eventually become striated; the striation is first obvious at the side of the fibre, spreads around the circumference, and ultimately extends to the centre. The nuclei, at first situated centrally, gradually pass out to assume their final position immediately beneath the sarcolemma. In the case of involuntary muscle the mesodermal cell assumes a pointed shape at the extremities and becomes flattened, the nucleus also lengthening out to its permanent rod-like form.

NERVOUS TISSUE

The **nervous tissues** of the body comprise the brain, the medulla spinalis or spinal cord, the cerebral, spinal, and sympathetic nerves, and the ganglia connected with them.

The nervous tissues are composed of *nerve-cells* and their various processes, together with a supporting tissue called *neuroglia*, which, however, is found only in the brain and medulla spinalis. Certain long processes of the nerve-cells are of special importance, and it is convenient to consider them apart from the cells; they are known as *nerve-fibres.*

CC-0. In Public Domain. Gurukul Kangri Collection, Haridwar

Digitized by Arya Samaj Foundation Chennai and eGangotri

To the naked eye a difference is obvious between certain portions of the brain and medulla spinalis, viz. the *grey* substance, and the *white* substance. The grey substance is largely composed of nerve-cells, while the white substance contains only their long processes, the nerve-fibres. It is in the former that nervous impressions are received, stored, and transformed into efferent impulses, and by the latter that they are conducted. Hence the grey substance forms the essential constituent of all the ganglionic centres, both those in the isolated ganglia and those aggregated in the brain and medulla spinalis; while the white substance forms the bulk of the commissural portions of the nerve-centres and the peripheral nerves.

Neuroglia, the peculiar variety of connective tissue which binds together the true nervous constituents of the brain and medulla spinalis, consists of cells and fibres. Some of the cells (spider-cells) are stellate in shape, with ill-defined cell-bodies and their fine processes become neuroglia fibres, which extend radially and unbranched (fig. 50, B) among the nerve-cells and fibres which they aid in supporting.

FIG. 50.—Neuroglia-cells of the brain shown by Golgi's method. (After Andriezen.) (From Sharpey Schafer's Essentials of Histology.)

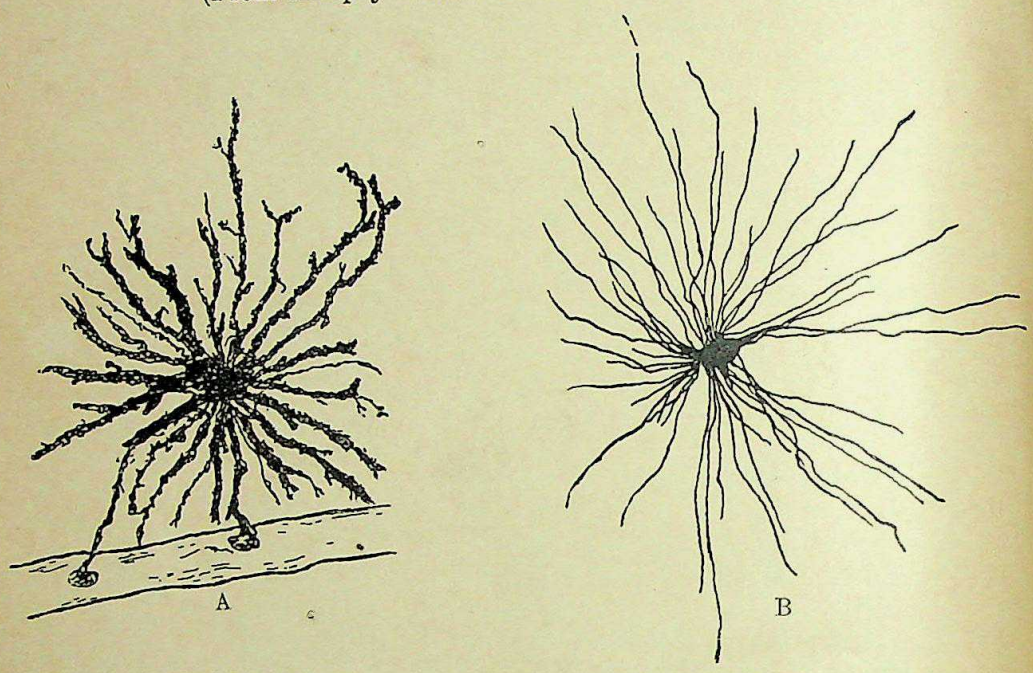

A. Arborescent cell with branched processes. B. Spider-cell with unbranched processes.

Other cells (arborescent cells) give off processes which branch repeatedly (fig. 50, A). Some of the fibres start from the epithelial cells lining the ventricles of the brain and central canal of the medulla spinalis, and pass through the nervous tissue branching repeatedly, to end in slight enlargements on the pia mater. Thus neuroglia is evidently a connective tissue in function, but it is not so in development; it is ectodermal in origin, whereas all other connective tissues are mesodermal.

Nerve-cells (fig. 51) are largely aggregated in the grey substance of the brain and medulla spinalis, but smaller collections of these cells also form the swellings, called *ganglia*, seen on many nerves. These latter are found chiefly upon the spinal and cerebral nerve-roots and in connexion with the sympathetic nerves.

Nerve-cells vary in shape and size, and have one or more processes. They may be divided for purposes of description into three groups according to the number of processes which they possess. (1) Unipolar cells are found in the spinal ganglia; the single process, after a short course, divides in a T-shaped manner (fig. 51). These cells are bipolar in embryonic life, but, as development proceeds the two processes approach one another and become fused for a short distance. In the spinal ganglia of fish the cells are bipolar throughout life. (2) Bipolar cells (fig. 51) are found, in the adult, in the retina, and in the ganglion spirale and ganglion vestibulare of the acoustic nerve. In some cases where two fibres are

CC-0.In Public Domain. Gurukul Kangri Collection, Haridwar

Digitized by Arya Samaj Foundation Chennai and eGangotri

apparently connected with a cell, one of the fibres is really derived from an adjoining nerve-cell and is passing to end in a ramification around a unipolar cell, or, again, it may be coiled spirally round the nerve-process which is issuing from the cell. (3) Multipolar cells are pyramidal or stellate in shape, and characterised by the

FIG. 51.—Various forms of nerve-cells.

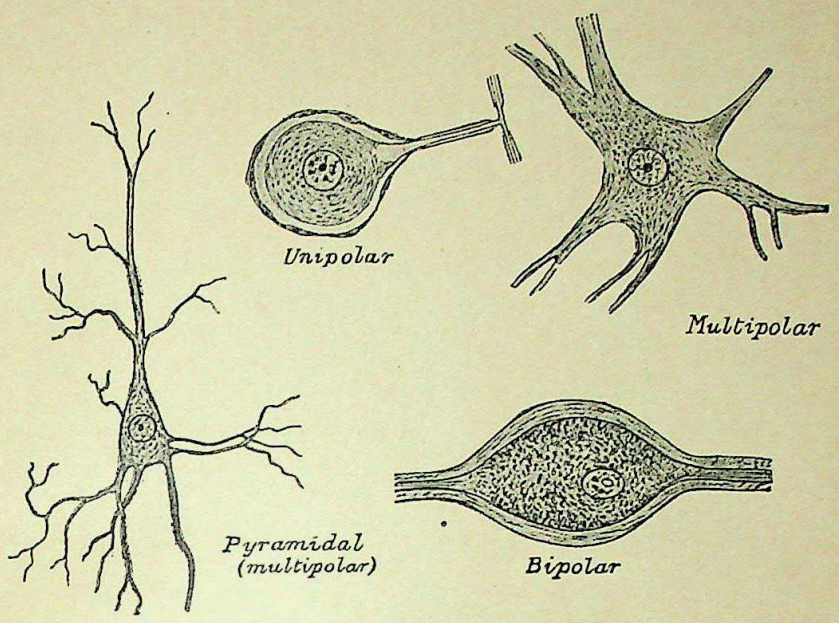

numerous processes which issue from them. The processes are of two kinds: one of them is termed the *axis-cylinder process* or *axon* because it becomes the axis-cylinder of a nerve-fibre (figs. 52, 53, 54). The others are termed the *protoplasmic processes* or *dendrons*; they begin to divide and subdivide as soon as they emerge from the cell, and finally end in minute twigs. The axons of certain multipolar

FIG. 52.—A motor nerve-cell from the anterior horn of the medulla spinalis of an ox, stained with methylene blue. ×500. The spindle-shaped Nissl's granules are shown. The dendrons and axon are broken off close to the cell.

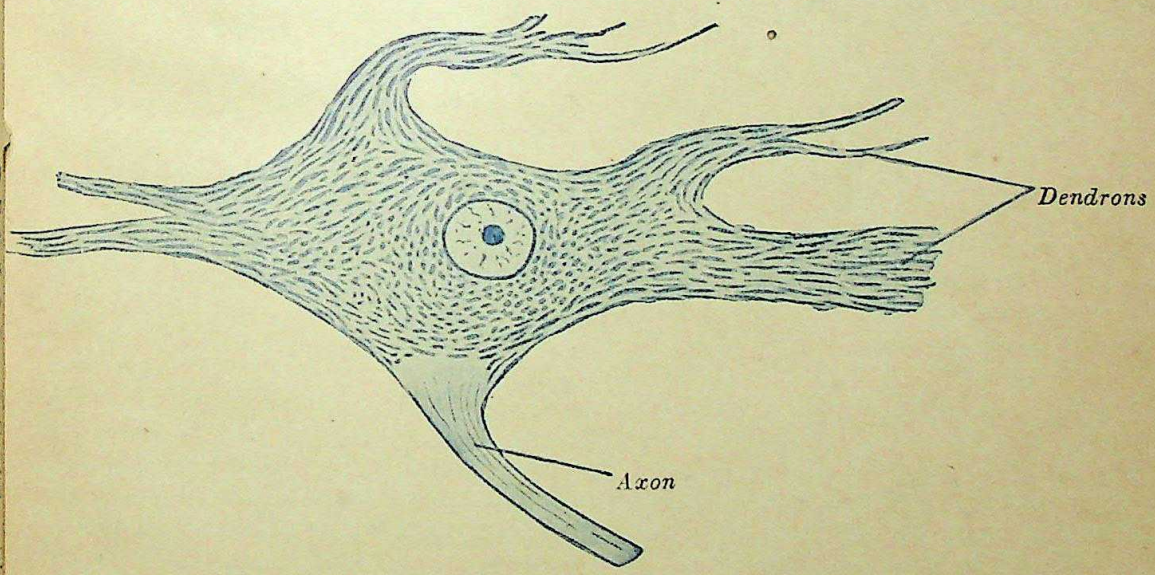

cells terminate by arborescence close to the cell-bodies; such cells were called by Golgi multipolar cells of the second type.

The body of the nerve-cell is known as the *cyton*. In fixed and stained preparations it consists of a finely fibrillated protoplasmic material in which there are occasionally patches of a deeper tint, caused by the aggregation of pigment-granules at the sides of the nuclei, as in the substantia nigra and locus cæruleus of the brain.

CC-0. In Public Domain. Gurukul Kangri Collection, Haridwar

Digitized by Arya Samaj Foundation Chennai and eGangotri

The protoplasm also contains peculiar angular masses of granules, which stain deeply with basic dyes such as methylene blue; these are known as *Nissl's spindles* (fig. 52). They extend into the dendritic processes but not into the axis-cylinder; the small clear area at the point of exit of the axon is termed the *cone of origin*. These bodies disappear (*chromatolysis*) during fatigue or after section of the nerve fibre connected with the cell. They are supposed to represent a store of nervous

FIG. 53.—A pyramidal cell from the cerebral cortex of a mouse. Golgi method. (After Ramón y Cajal.)

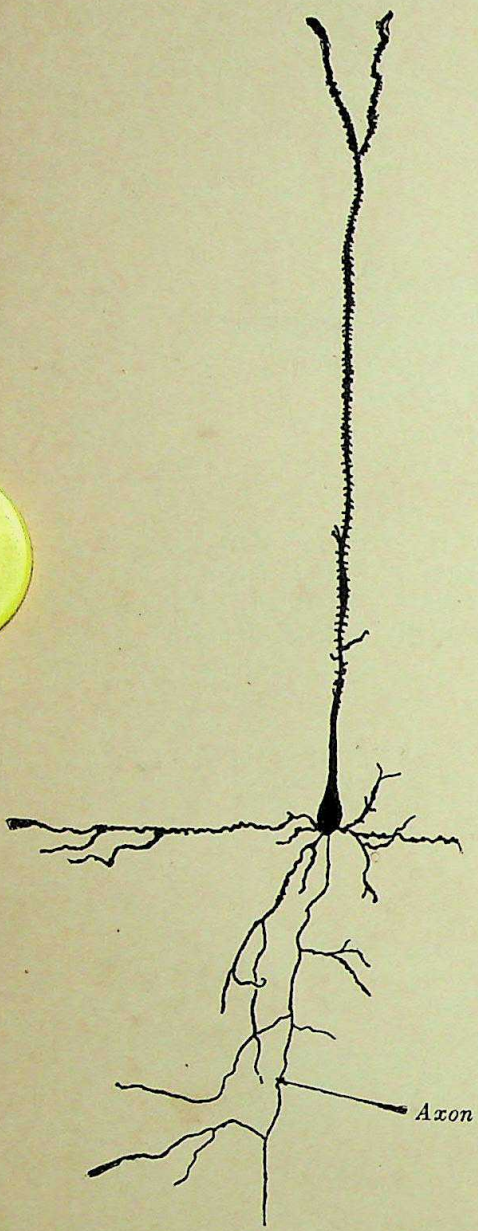

FIG. 54.—A cell of Purkinje from the cerebellum. Golgi method. (Ramón y Cajal.)

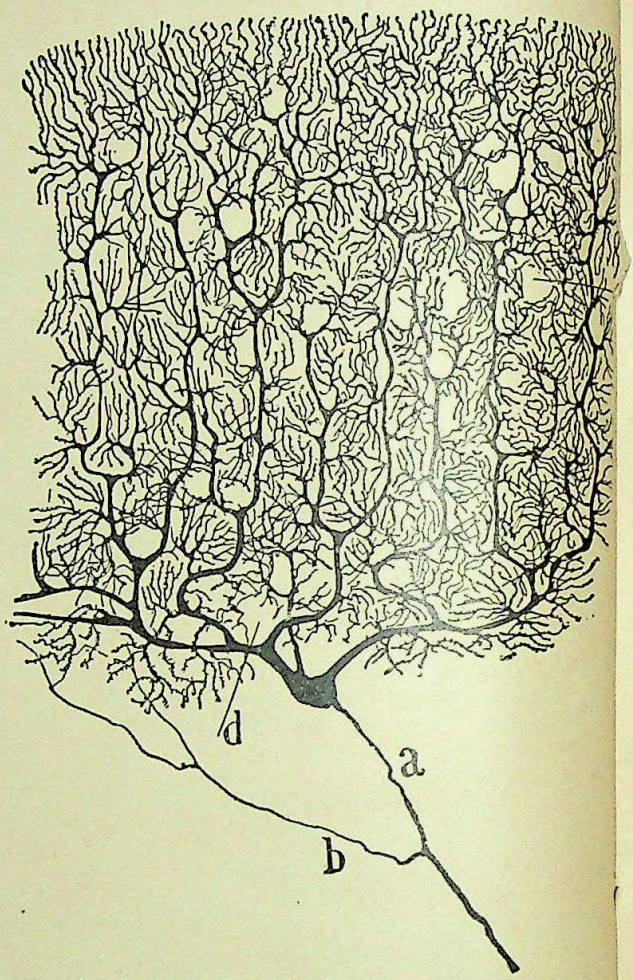

a. Axon. *b*. Collateral. *c* and *d*. Dendrons.

energy, and in various mental diseases are deficient or absent. The nucleus is, as a rule, a large, well-defined body, with a relatively small amount of chromatin, and contains a well-marked nucleolus.

In addition to the protoplasmic network described above, each nerve-cell may be shown to have delicate neurofibrils running through its substance (fig. 55); these fibrils are continuous with the fibrils of the axon, and are believed to convey nerve impulses. A *pericellular network* of fine branching fibres is a characteristic feature of many nerve-cells.

Mott and Marinesco have shown that, when living nerve-cells are examined by the dark ground illumination method, neither Nissl's bodies nor fibrils of any kind can be seen. The constancy of the occurrence of both these structures in fixed

CC-0. Panini Kanya Maha Vidyalaya Collection. Haridwar

Digitized by Arya Samaj Foundation Chennai and eGangotri

preparations, however, indicates that they represent something specific in the living cell.

Nerve-fibres are found universally in the peripheral nerves, and in the white substance of the brain and medulla spinalis. They are of two kinds—viz. *medullated* or *white* fibres, and *non-medullated* or *grey* fibres.

The *medullated fibres* form the white part of the brain and medulla spinalis, and also the greater part of every cerebral and spinal nerve, and give to these structures their opaque, white aspect. When perfectly fresh they appear to be homogeneous; but soon after removal from the body each fibre presents, when examined by transmitted light, a double outline or contour, as if consisting of two parts (fig. 56). The central portion is named the *axis-cylinder*; around this is a sheath of fatty

Fig. 55.—Nerve-cells of a kitten, showing neurofibrils. (Ramón y Cajal.)

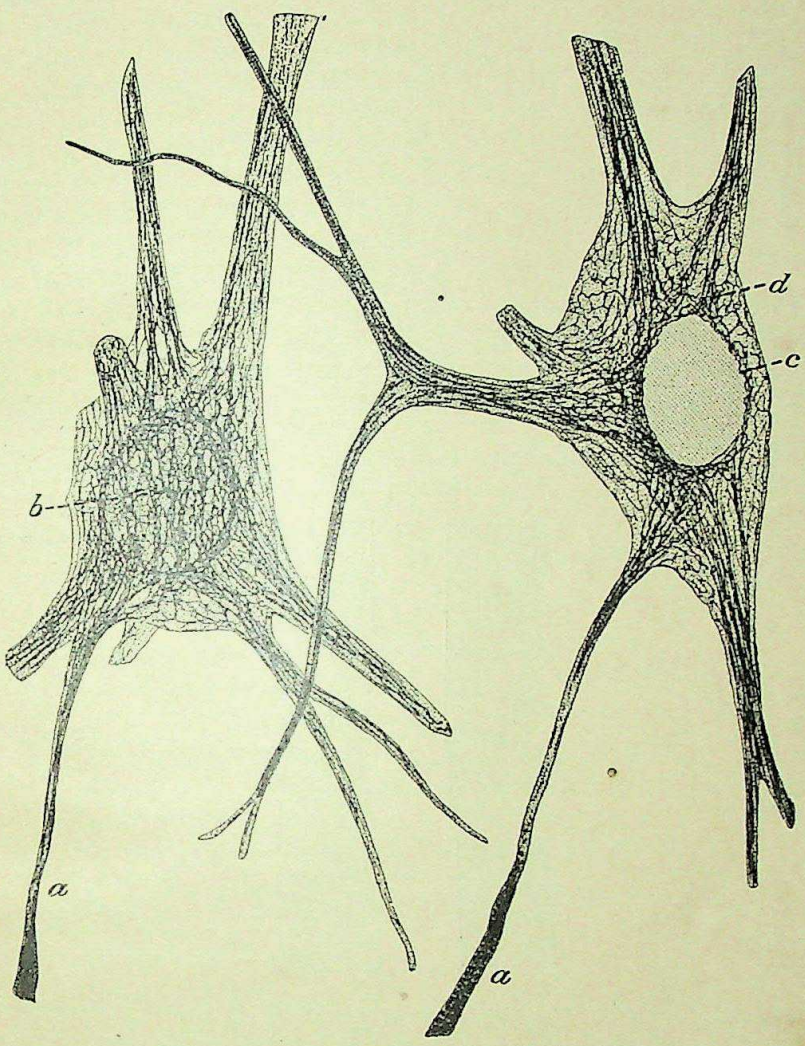

a. Axon. *b*. Cyton. *c*. Nucleus. *d*. Neurofibrils.

material, staining black with osmic acid, named the *white substance of Schwann* or *medullary sheath*, which gives to the fibre its double contour; and the whole is enclosed in a delicate membrane, the *neurolemma*, *primitive sheath*, or *nucleated sheath of Schwann* (fig. 57). Medullated nerve-fibres vary in diameter from 2μ to 16μ.

The *axis-cylinder* is the essential part of the nerve-fibre, and is always present; the medullary sheath and the neurolemma are occasionally absent, especially at the origin and termination of the nerve-fibre. The axis-cylinder undergoes no interruption from its origin in the nerve-centre to its termination, and must be regarded as a direct prolongation of a nerve-cell. Nerve-fibres in the white substance of the brain and medulla spinalis give off twigs known as *collaterals*. These arise from the main fibre at right angles to its course and run into the grey substance, where they terminate by arborisation. The axis-cylinder constitutes about one-half or one-third of the nerve-fibre, being greater in proportion in the fibres of the central organs than in those of the nerves. It is quite transparent, and is therefore

CC-0. In Public Domain. Gurukul Kangri Collection, Haridwar

Digitized by Arya Samaj Foundation Chennai and eGangotri

indistinguishable in a perfectly fresh and natural state of the nerve. It is made up of exceedingly fine fibrils (figs. 57 and 58), which stain darkly with gold chloride and at its termination may be seen to break up into these fibrils. The axis-cylinder is said by some to be enveloped in a special reticular sheath, which separates it from the medullary sheath, and is composed of a substance called *neurokeratin*. The more common opinion is that this network or reticulum is contained in the white substance of Schwann, and by some it is believed to be produced by the action of the reagents employed to show it.

FIG. 56.—Medullated nerve-fibres. × 350.

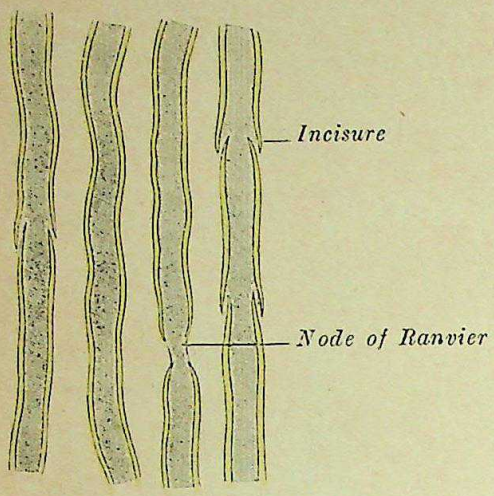

The *medullary sheath* or *white substance of Schwann* (fig. 57) is regarded as being a fatty material in a fluid state, which insulates and protects, or possibly supplies nutriment to, the essential part of the nerve—the axis-cylinder. As a general rule its thickness is proportional to the size of the axis-cylinder, and is such that it forms about half of the total area of the cross section of the fibre. Its continuity is interrupted at intervals of about 1 mm., giving to the fibre the appearance of constriction at these points; these are known as the *nodes of Ranvier* (figs. 56 and 57). The portion of nerve-fibre between two nodes is called an *internodal segment*. The neurolemma or primitive sheath is not interrupted at the nodes, but passes over them as a continuous membrane. Some

FIG. 57.—A diagram of longitudinal sections of medullated nerve-fibres. Osmic acid.

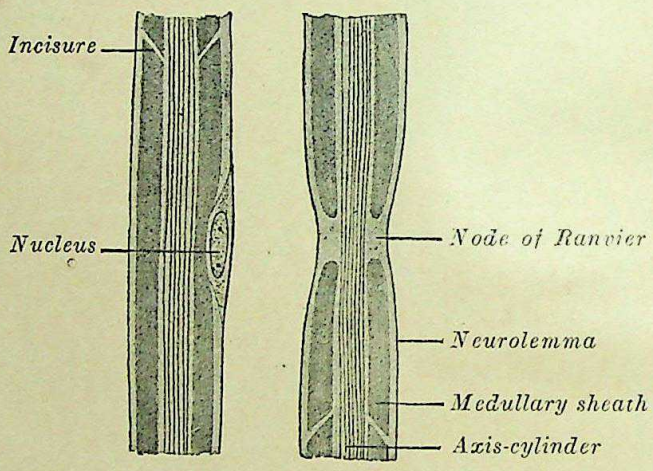

observers, however, believe that the neurolemma of one internodal segment is connected with that of the adjacent segment at the node by cement-substance. If the fibre be treated with silver nitrate the reagent penetrates the neurolemma at the nodes, and, on exposure to light, reduction takes place, giving rise to the appearance of black crosses, *Ranvier's crosses*, on the axis-cylinder. There may also be seen transverse lines beyond the nodes termed *Frommann's lines* (fig. 59); the significance of these is not understood. In addition to these interruptions, oblique clefts or *incisures* may be seen in the medullary sheath, subdividing it into irregular portions, which are termed *medullary segments*, or *segments of Lantermann* (figs. 56 and 57); there is reason to believe that these clefts are artificially produced in the preparation of the specimens. Medullated nerve-fibres, when examined in the fresh condition, frequently present a beaded or varicose appearance, due to

FIG. 58.—Transverse sections through medullated nerve-fibres. Osmic acid.

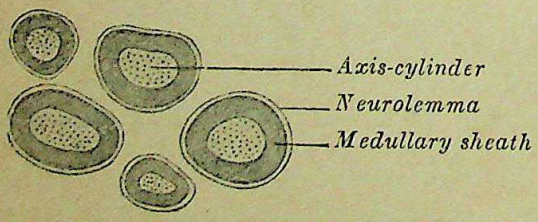

CC-0. In Public Domain. Gurukul Kangri Collection, Haridwar

Digitized by Arya Samaj Foundation Chennai and eGangotri

manipulation and pressure causing the oily matter to collect into drops; in consequence of the extreme delicacy of the primitive sheath even slight pressure will cause the transudation of the fatty matter, which collects as drops of oil outside the sheath.

The *neurolemma* or *primitive sheath* is a delicate, structureless membrane; here and there beneath it, and situated in depressions in the white substance of Schwann, are nuclei, each surrounded by a small amount of protoplasm. The nuclei are oval and somewhat flattened, and one is generally found in the middle of each internode. The primitive sheath is absent from the medullated fibres of the brain and medulla spinalis.

FIG. 59.—Medullated nerve-fibres stained with silver nitrate.

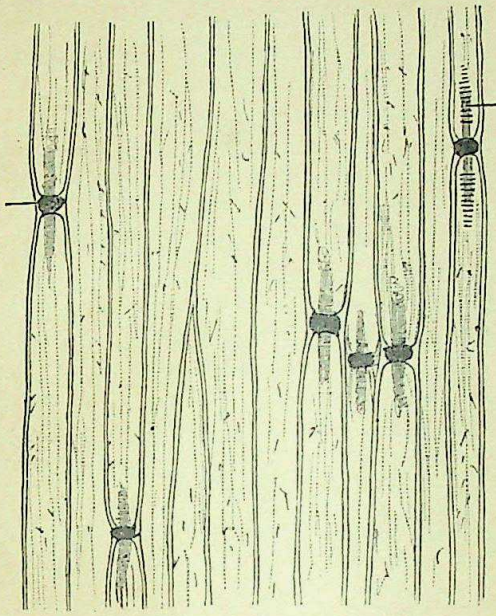

FIG. 60.—A small branch from the sympathetic trunk of a mammal.

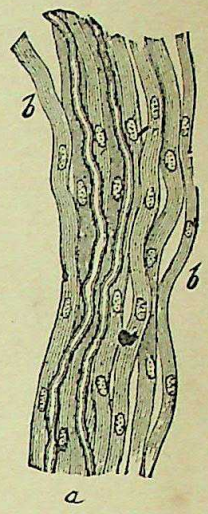

a. Two small medullated nerve-fibres among a number of non-medullated nerve-fibres, *b.*

Wallerian Degeneration.—When nerve-fibres are cut across, the central ends of the fibres degenerate as far as the first node of Ranvier; but the peripheral ends degenerate simultaneously throughout their whole length. The medullary sheath of each fibre becomes broken down, forming droplets of fatty substance, and the axon undergoes fragmentation. The nuclei of the primitive sheath proliferate, and finally absorption of the axons and fatty substance occurs. If the cut ends of the nerve be sutured together, regeneration of the nerve-fibres takes place by the downgrowth of axons from the central end of the nerve. At one time it was believed that the regeneration was peripheral in origin, but this has been disproved, the proliferated nuclei in the peripheral portions taking part merely in the formation of the so-called scaffolding along which the new axons pass.

Non-medullated fibres.—Most of the fibres of the sympathetic system, and some of the cerebrospinal, consist of the *grey* or *gelatinous* nerve-fibres—*fibres of Remak* (fig. 60). Each of these consists of an axis-cylinder to which nuclei are applied at intervals. These nuclei are believed to be in connexion with a delicate sheath corresponding with the neurolemma of the medullated nerve-fibre. In external appearance the non-medullated nerve-fibres are semitransparent and grey or yellowish-grey. The individual fibres vary in size, generally averaging about half the size of the medullated fibres.

CC-0. In Public Domain. Gurukul Kangri Collection, Haridwar

Digitized by Arya Samaj Foundation Chennai and eGangotri

EMBRYOLOGY

THE term **Embryology,** in its widest sense, comprises the various changes which take place during the growth of an animal from the egg to the adult condition; it is, however, usually restricted to the phenomena which occur before birth.

In vertebrate animals the development of a new being normally takes place when a female germ-cell or *ovum* has been fertilised by a male germ-cell or *spermatozoön*. The ovum is a nucleated cell, and the complicated changes by which the various tissues and organs of the body are formed from it, after it has been fertilised, are the result of two general processes, viz. *segmentation* and *differentiation* of cells. Thus, the fertilised ovum undergoes repeated segmentation into a number of cells which at first closely resemble one another, but are, sooner or later, differentiated into two groups: (1) *somatic cells*, the function of which is to build up the various tissues of the body; and (2) *germinal cells*, which are ultimately imbedded in the genital glands (ovaries and testes), and destined for the perpetuation of the species.

Having regard to the main purpose of this work, it is impossible, in the space available in this chapter, to describe or illustrate fully, all the changes which occur during the development of the human body. Only the principal facts are given, and the student is referred for further details to one or other of the text-books * on embryology.

THE OVUM

The ova are derived from the primitive germ-cells which are situated in the substance of the ovaries; each primitive germ-cell gives rise, by repeated divisions, to a number of smaller cells termed *oögonia* from which the *ova* or *primary oöcytes* are developed.

Human ova measure about 0·1 mm. in diameter, and are contained within the Graafian follicles of the ovaries †; as a rule each follicle contains one ovum, but sometimes two or more are present. By the enlargement and subsequent rupture of a follicle at the surface of the ovary, an ovum is liberated and enters the uterine tube through which it is conveyed to the cavity of the uterus. Unless it be fertilised it is discharged from the uterus, but if fertilisation takes place it is retained there and developed into a new being.

In appearance and structure the ovum (fig. 61) differs little from an ordinary cell (p. 1), but distinctive names are given to its several parts; thus, the cell-substance is known as the *yolk* or *oöplasm*, the nucleus as the *germinal vesicle*, and the nucleolus as the *germinal spot*. The ovum has a thick, transparent envelope named the *zona striata* or *zona pellucida*, and when the ovum is liberated from the Graafian follicle, several layers of cells, derived from those of the follicle, adhere to the outer surface of the zona striata, and collectively constitute the *corona radiata*.

The **yolk** comprises (1) *cytoplasm* similar to that of the ordinary animal cell (p. 1), and frequently termed the *formative yolk*; (2) *deuteroplasm* or *nutritive yolk*, which consists of numerous round granules of fatty and albuminoid substances imbedded in the cytoplasm. In the mammalian ovum the deuteroplasm is extremely small in amount, and nourishes the embryo in the early stages of its

* *Manual of Human Embryology*, Keibel and Mall; *Handbuch der vergleichenden und experimentellen Entwickelungslehre der Wirbeltiere*, Oskar Hertwig; *Human Embryology and Morphology*, Arthur Keith, 1921; *Traité d'Embryologie des vertébrés*, A. Brachet, 1921; *Vertebrate Embryology*, Jenkinson; *The Physiology of Reproduction*, Marshall.

† See description of the ovary under Splanchnology.

CC-0. In Public Domain. Gurukul Kangri Collection, Haridwar

Digitized by Arya Samaj Foundation Chennai and eGangotri

development only, whereas in the egg of the bird there is sufficient to supply the chick with nutriment throughout the whole period of incubation. The mode of distribution of the deuteroplasm within the egg varies in different animals; in some it is almost uniformly dispersed throughout the cytoplasm; in some it is centrally placed and surrounded by the cytoplasm; in others it is accumulated at the lower pole of the ovum, while the cytoplasm occupies the upper pole. A *centrosome* and *centriole* are present and lie in the immediate neighbourhood of the nucleus.

FIG. 61.—A human ovum examined fresh in the liquor folliculi. ×500. (Waldeyer.)

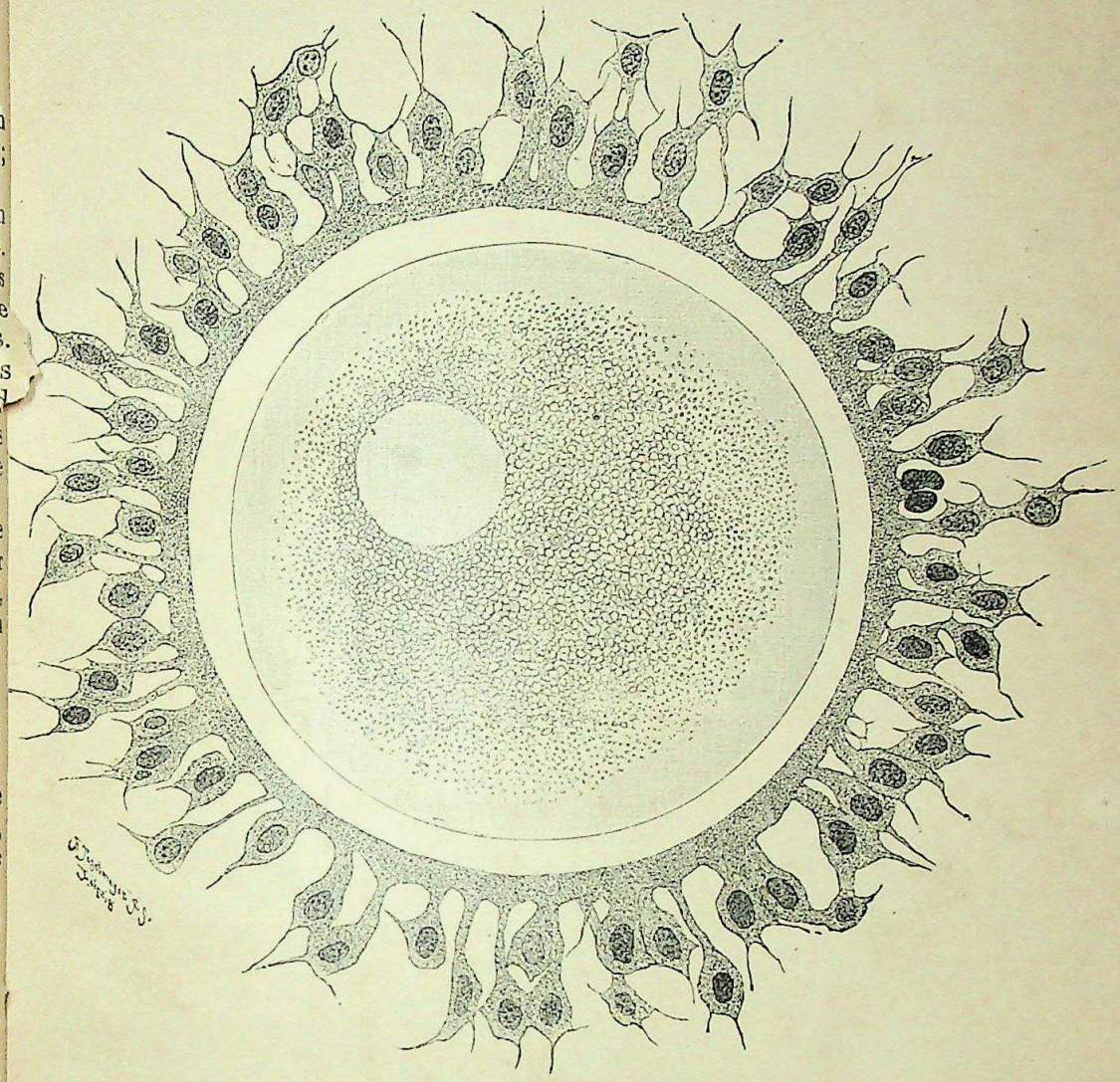

The zona pellucida is seen as a thick clear girdle surrounded by the cells of the corona radiata. The ovum shows a central granular deuteroplasmic area and a peripheral clear cytoplasmic layer, and encloses the germinal vesicle, in which the germinal spot is indistinctly seen.

The **nucleus** or **germinal vesicle** is a large spherical body which usually occupies an excentric position in the yolk. Its structure is that of an ordinary cell-nucleus, viz. it consists of a reticulum or karyomitome the meshes of which are filled with karyoplasm, while connected with, or imbedded in, the reticulum are a number of chromatin masses or chromosomes, which may present the appearance of a skein or may assume the form of rods or loops. The nucleus is enclosed by a delicate nuclear membrane, and contains in its interior a well-defined nucleolus or germinal spot.

THE COVERINGS OF THE OVUM

The **zona striata** or **zona pellucida** (fig. 61) is a thick membrane, which, under the higher powers of the microscope, is seen to be radially striated. Thomson* describes the zona pellucida as consisting of (*a*) an inner, homogeneous layer which

CC-0. In Public Domain. Gurukul Kangri Collection, Haridwar

* Professor Arthur Thomson, *Journal of Anatomy*, vol. liii. 1919.

Digitized by Arya Samaj Foundation Chennai and eGangotri

is derived from the ovum, and (*b*) an outer, fibrillar layer formed by the felting of the basal fibres of the innermost cells of the corona radiata. He is also of opinion that there is distinct evidence of a *vitelline membrane* within the zona pellucida.

The **corona radiata** (fig. 61) consists of two or three strata of cells which are derived from the cells of the Graafian follicle, and adhere to the outer surface of the zona striata when the ovum is set free from the follicle; the cells are radially arranged around the zona, those of the innermost layer being columnar in shape. The cells of the corona radiata soon disappear; in some animals they secrete, or are replaced by, a layer of protein, which may assist in protecting and nourishing the ovum.

The phenomena attending the discharge of the ova from the Graafian follicle are described with the anatomy of the ovaries.

THE MATURATION OF THE OVUM

Before an ovum or primary oöcyte can be fertilised it must undergo a process of *maturation* or *ripening* (fig. 62). This process consists of a heterotypical division of the ovum into two cells, followed by a homotypical division of the two cells into four. Three of the four cells are small, incapable of further development,

FIG. 62.—The formation of the polar bodies in Asterias glacialis. (Slightly modified from Hertwig.)

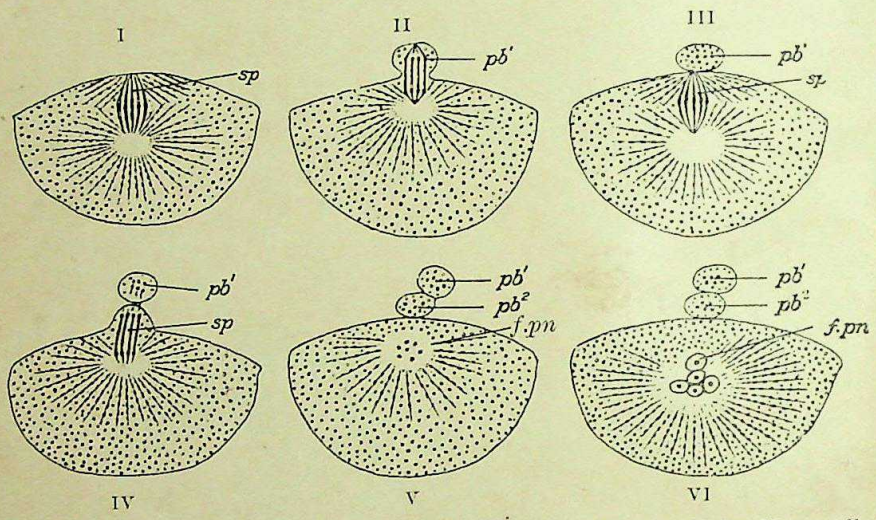

In fig. I the polar spindle (*sp*) has advanced to the surface of the egg. In fig. II a small elevation (pb^1) is formed which receives half of the spindle. In fig. III the elevation is constricted off, forming the first polar body (pb^1), and a second spindle is formed. In fig. IV is seen a second elevation which in fig. V has been constricted off as the second polar body (pb^2). Out of the remainder of the spindle (*f.pn* in fig. VI) the female pronucleus is developed.

and are named *polar bodies* or *polocytes*. The fourth cell is large; it is named the *mature ovum*, and is devoid of a centrosome. Its nucleus, as the result of the heterotypical division, contains only one-half of the number of chromosomes present in the nucleus of the primary oöcyte. The nucleus of the mature ovum is named the *female pronucleus*.

In most vertebrates the heterotypical division occurs before the ovum or primary oöcyte is liberated from the ovarian or Graafian follicle, and the homotypical division after a spermatozoön has penetrated the zona pellucida. Thomson * has submitted evidence to show that in man both polar bodies are extruded before the ovum is liberated from the Graafian follicle; in other words, the process of maturation is completed before the ovum has been subjected to the influence of a spermatozoon.

The process of maturation of the ovum has been carefully studied in the ova of some of the lower animals, to which the following description applies.

It was pointed out on page 2 that the number of chromosomes found in the nucleus is constant for all the cells in an animal of any given species, and that

CC-0. In Public Domain. Gurukul Kangri Collection, Haridwar

* *Loc. cit.*

Digitized by Arya Samaj Foundation Chennai and eGangotri

man the number is probably twenty-four.* This applies not only to the somatic cells but to the primitive ova and their descendants. For the purpose of illustrating the process of maturation a species may be taken in which the number of nuclear chromosomes is four (fig. 63). If an ovum from such be observed at the beginning of the maturation process, the usual achromatic spindle is seen lying close to and parallel with the surface of the ovum, with the four chromosomes arranged at its

FIG. 63.—A diagram showing the reduction in number of the chromosomes during the maturation of the ovum. The first division is heterotypical, the second homotypical.

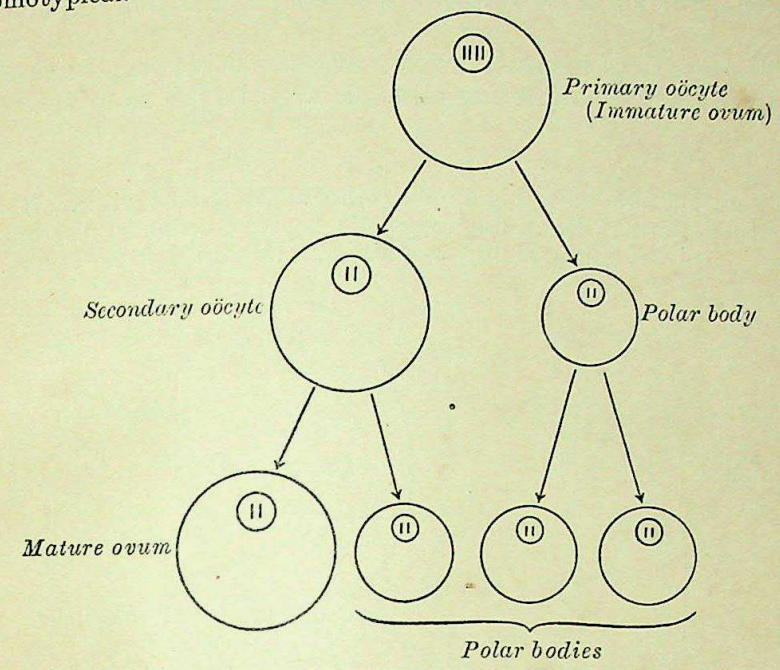

equator. The spindle then rotates so that its long axis is radial, and the first or heterotypical division takes place; two chromosomes pass to either end of the spindle, those at the periphery producing a surface elevation which is constricted off as the *first polar body*. The other two chromosomes are retained in the ovum, which is now termed a *secondary oöcyte*. Without passing through a resting stage the secondary oöcyte undergoes homotypical division, the two chromosomes each dividing into two, which travel to the ends of the spindle. A *second polar body* is segmented off, and the *mature ovum*, with two chromosomes gathered into a newly formed nucleus, remains. The first polar body frequently divides in a homotypical manner while the second is being formed, and as a final result four cells are produced, viz. the mature ovum and three polar bodies, each of which contains two chromosomes, i.e. one-half of the number present in the nuclei of the somatic cells of members of the same species.

THE SPERMATOZOÖN

The spermatozoa or male germ-cells are developed in the testes and are present in enormous numbers in the seminal fluid. Each consists of a small but greatly modified cell, and possesses a head, a neck, a connecting piece or body, and a tail (fig. 64).

The **head** is ovoid or elliptical, but flattened, so that when viewed in profile it is pear-shaped. Its anterior two-thirds are covered with a layer of modified protoplasm, named the *head-cap*, which ends anteriorly in a sharp edge. In some animals (e.g. the salamander), the head-cap is prolonged into a barbed spear-like process (*acrosome* or *perforator*), which probably facilitates the entrance of the spermatozoön into the ovum.

* H. von Winiwarter maintains that the number of chromosomes in the immature ovum is forty-eight, and in the primary spermatocyte, forty-seven.

CC-0. In Public Domain. Gurukul Kangri Collection, Haridwar

Digitized by Arya Samaj Foundation Chennai and eGangotri

The **neck** is less constricted in the human spermatozoön than in the spermatozoa of some of the lower animals. The *anterior centriole* is situated at the junction of the head and neck, and behind it is a band of homogeneous substance.

The **connecting piece** or **body** is rod-like, and is limited behind by a *terminal disc* or *ring*. The *posterior centriole* is placed at the junction of the body and neck and from it an *axial filament*, surrounded by a sheath, runs backwards through the body and tail. In the body the sheath of the axial filament is encircled by a *spiral thread*, around which is an envelope containing chondriosomes or mitochondrial granules, and termed the *mitochondrial sheath*.

The **tail** consists of the axial thread or filament, surrounded by a thin protoplasmic sheath ; the terminal portion or *end-piece* of the tail is composed of the axial filament only.

Krause gives the length of the human spermatozoön as between 52μ and 62μ, the head measuring 4μ to 5μ, the connecting piece 6μ, and the tail from 41μ to 52μ.

FIG. 64.—A human spermatozoa, highly magnified. A. Profile view. B. Surface view. (After Retzius.) C. A diagrammatic representation of the head, neck and connecting piece, more highly magnified. (Modified from Meves.)

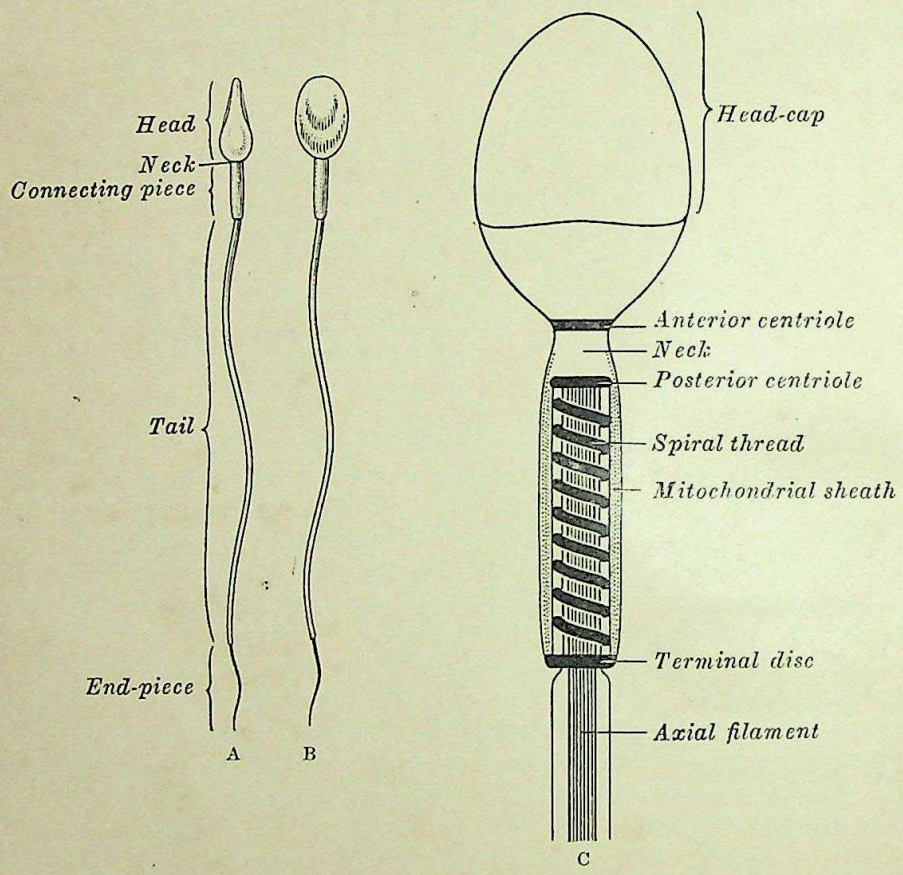

By virtue of their tails, which act as propellers, the spermatozoa are capable of free movement, and if placed in favourable surroundings (e.g. in the female passages) will retain their vitality and fertilising power for several days. In certain animals (e.g. bats) it has been proved that spermatozoa which have been retained in the female passages for several months are capable of fertilising ova.

The spermatozoa are developed from the primary germ-cells imbedded in the testes, and the stages of their development are very similar to those of the maturation of the ovum. The primary germ-cells undergo division and produce a number of cells termed *spermatogonia*, and from these the *primary spermatocytes* are derived. Each primary spermatocyte divides heterotypically into two *secondary spermatocytes*, in the nuclei of which the number of chromosomes is reduced by one-half and each secondary spermatocyte divides homotypically into two *spermatids* or young spermatozoa ; each primary spermatocyte therefore gives rise to four spermatozoa.

CC-0. In Public Domain. Gurukul Kangri Collection, Haridwar

Digitized by Arya Samaj Foundation Chennai and eGangotri

Interesting changes occur during the conversion of the spermatid into the spermatozoön (fig. 65). The two centrioles are at first tangential to the surface of the spermatid but soon assume a radial position so that one lies deeper than the other; the deeper one forms the anterior centriole of the neck. The axial

FIG. 65.—The transformation of a spermatid into a spermatozoön. Diagrammatic. (Modified from Meves.)

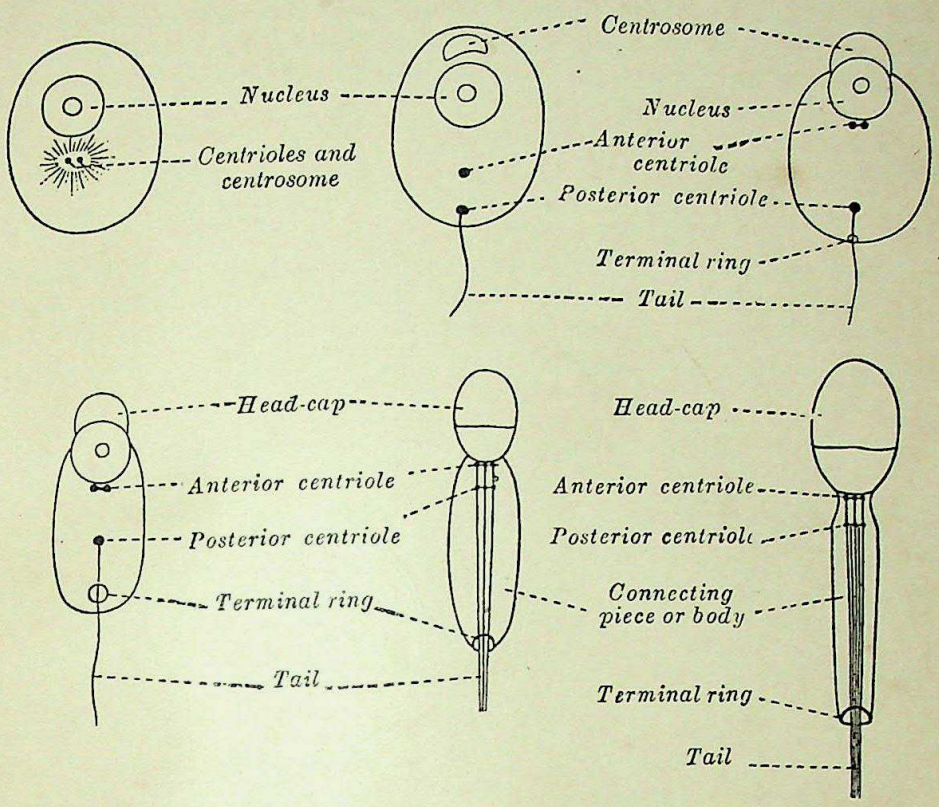

filament grows out from the superficial centriole, which divides into two parts; the anterior part forms the posterior centriole of the neck, and the posterior part, which is ring-like, migrates to the distal end of the connecting piece or body and there forms the terminal disc or ring, through which the axial filament passes.

FIG. 66.—A scheme showing the analogies in the process of maturation of the ovum and the development of the spermatids (young spermatozoa).

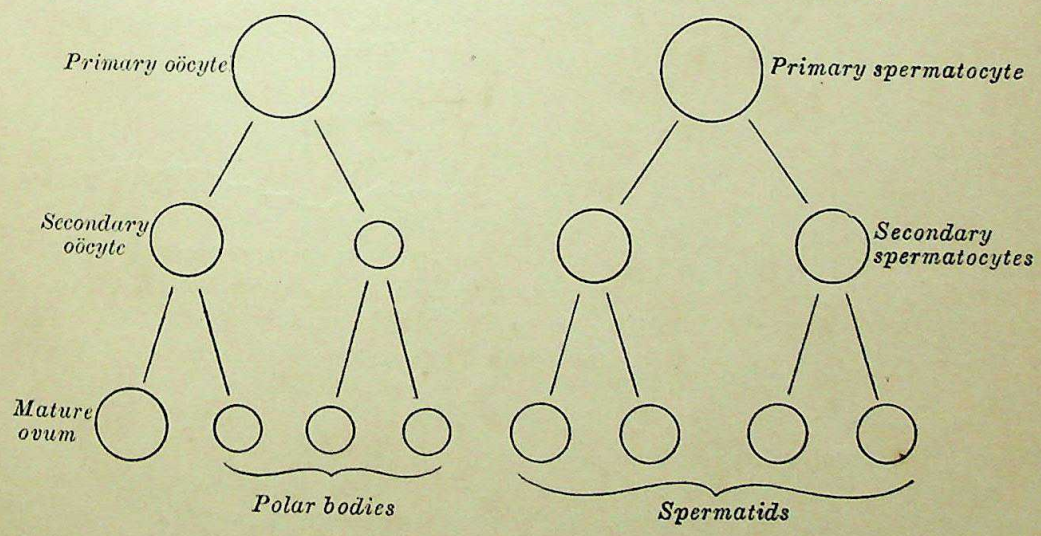

The nucleus of the spermatid forms the head of the spermatozoön, and the cytoplasm, the investing sheath of the body and tail. The centrosome probably moves away from the centrioles to the opposite side of the nucleus and is converted into the head-cap.

CC-0. In Public Domain. Gurukul Kangri Collection, Haridwar

Digitized by Arya Samaj Foundation Chennai and eGangotri

On comparing the development of the spermatozoön with the maturation of th ovum (fig. 66) it will be observed that the primary spermatocyte gives rise to tw secondary spermatocytes, and the primary oöcyte to the secondary oöcyte and th first polar body; the two secondary spermatocytes give origin to four spermatozo and the secondary oöcyte and first polar body to four cells, the mature ovum an three polar bodies. In the development of the spermatozoön, as in the maturatio of the ovum, there is a reduction of the nuclear chromosomes to one-half of tho present in the primary spermatocyte. But here the similarity ends, for it mu be noted that the four spermatozoa are of equal size, and each is capable of fertilisin a mature ovum, whereas the three polar bodies are much smaller than the matu ovum, incapable of further development, and may be regarded as abortive ova.

THE FERTILISATION OF THE OVUM

Fertilisation consists in the union of the spermatozoön with the mature ovu (fig. 67). Nothing is known regarding the fertilisation of the human ovum, but th various stages of the process have been studied in other mammals, and from th knowledge so obtained it is believed that fertilisation of the human ovum take

FIG. 67.—The process of fertilisation in the ovum of a mouse. (After Sobotta.)

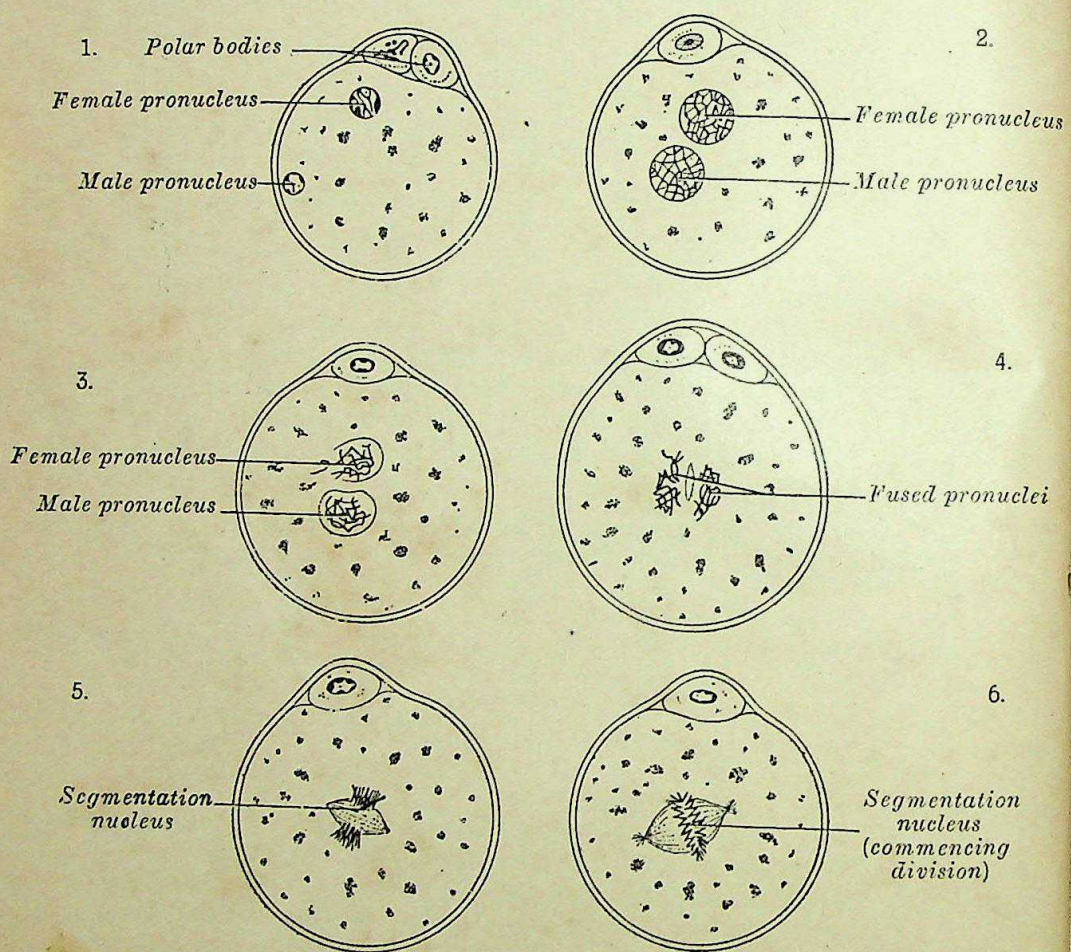

place in the lateral or ampullary part of the uterine tube. The fertilised ovum i then conveyed along the tube to the cavity of the uterus—a journey occupyin about seven or eight days; during the journey the ovum loses its corona radiat and zona striata, and undergoes segmentation. Having pierced the yolk, th spermatozoön loses its tail, while its head and connecting piece assume the form of a nucleus containing a cluster of chromosomes. This constitutes the *male pro nucleus*, and associated with it there are a centrosome and centriole. The mal pronucleus passes more deeply into the yolk, and the granules of the cytoplasm

CC-0. In Public Domain. Gurukul Kangri Collection, Haridwar

Digitized by Arya Samaj Foundation Chennai and eGangotri

surrounding it become radially arranged. The male and female pronuclei migrate towards each other, and, meeting near the centre of the yolk, fuse to form the *first segmentation nucleus* which thus contains both male and female chromatin; the former probably transmits the individualities of the paternal, the latter those of the maternal, ancestors to the future embryo. By the union of the male and female pronuclei the number of chromosomes is restored to that present in the nuclei of the somatic cells.

Applied Anatomy.—Sometimes the fertilised ovum is arrested in the uterine tube, and there undergoes development, giving rise to a *tubal pregnancy*; or it may fall into the abdominal cavity and produce an *abdominal pregnancy*. Occasionally the ovum is not expelled from the Graafian follicle when the latter ruptures, but is fertilised within the follicle and produces what is known as an *ovarian pregnancy*. Under normal conditions only one spermatozoön enters the yolk and takes part in the process of fertilisation. Occasionally a second spermatozoön may enter the yolk, thus giving rise to a condition of *polyspermy*; when this occurs the ovum usually develops in an abnormal manner and gives rise to a monstrosity.

FIG. 68.—The first stages of the segmentation of a mammalian ovum. Semidiagrammatic. (From a drawing by Allen Thomson.) (Quain's Elements of Anatomy.)

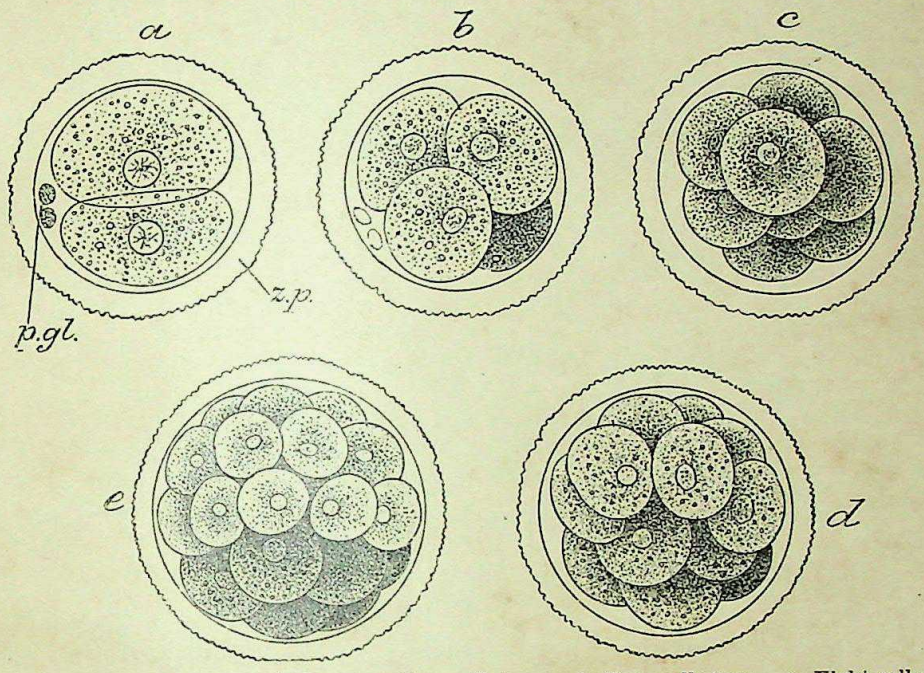

z.p. Zona striata. *p.gl.* Polar bodies. *a.* Two-cell stage. *b.* Four-cell stage. *c.* Eight-cell stage. *d, e.* Morula stage.

The **role of the chromosomes.***—According to recent researches the mature ovum contains within itself all the essentials for the formation of a new being, and in the lower forms is capable of producing such when stimulated by mechanical or chemical means. It is interesting to note that the sex of an animal so formed is male. The development of a female necessitates the presence of a spermatozoön containing an additional or specialised chromosome. Thus in some insects the primary oöcyte contains twenty-four chromosomes, and the primary spermatocyte, twenty-three. The mature ovum and the polar bodies each contain twelve chromosomes, while one-half of the spermatozoa contain twelve, and the other half, eleven. If a mature ovum be fertilised by a spermatozoön with eleven chromosomes, the resulting embryo is a male, but if it be fertilised by a spermatozoön with twelve chromosomes, a female embryo is produced. This, however, is not the only factor involved in the determination of sex. The theory advanced is that the chromosomes contain materials which chemically initiate and control the processes that lead to the development of the various tissues and their individual peculiarities. The establishment of a sex-difference is therefore, in the first instance, dependent on a specialised chromosome, but the development of the sexual features results from the presence of specialised chemical substances.

* Consult *The organism as a whole*, by Jacques Loeb, 1916.

CC-0. In Public Domain. Gurukul Kangri Collection, Haridwar

Digitized by Arya Samaj Foundation Chennai and eGangotri

THE SEGMENTATION OF THE FERTILISED OVUM

The early segmentation of the human ovum has not yet been seen, but from what is known to occur in other mammals it may be regarded as certain that the process starts immediately after fertilisation, i.e. while the ovum is in the uterine tube. The nucleus exhibits the usual mitotic changes, and these are succeeded by division of the fertilised ovum into two cells of nearly equal size.* The process

FIG. 69.—A section through the blastodermic vesicle of Vespertilio murinus. (After van Beneden.)

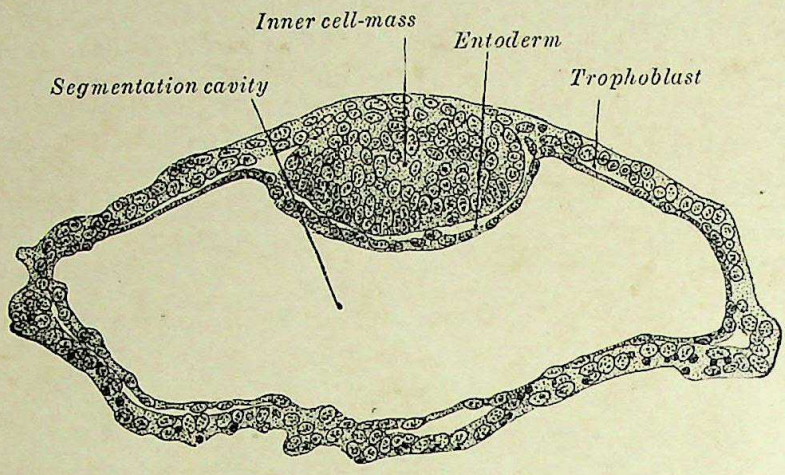

FIG. 70.—A section through the embryonic disc of Vespertilio murinus. (After van Beneden.)

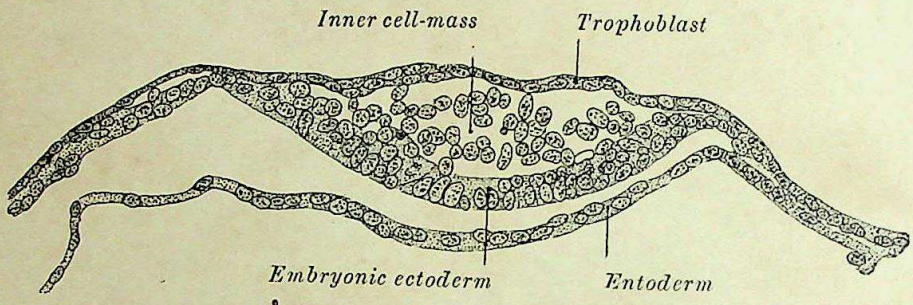

FIG. 71.—A section through the embryonic disc of Vespertilio murinus to show the formation of the amniotic cavity. (After van Beneden.)

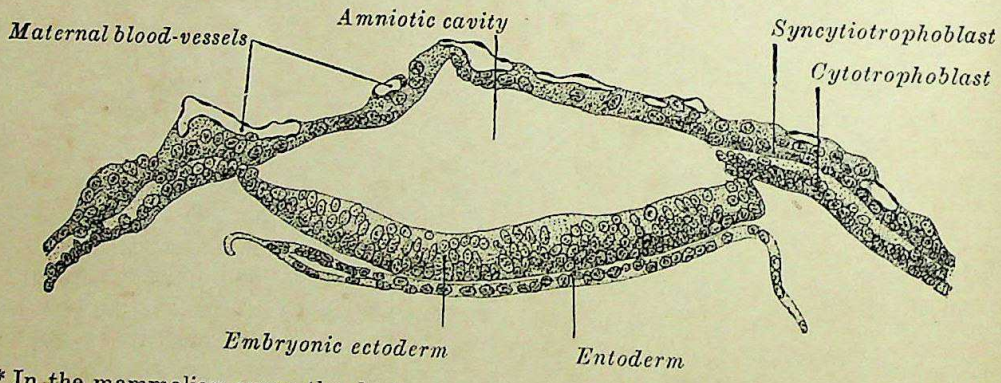

* In the mammalian ovum the deuteroplasm is small in amount and uniformly distributed throughout the cytoplasm; such an ovum undergoes *complete* division during the process of segmentation, and is therefore termed *holoblastic*. In the ova of birds, reptiles, and fishes, where the nutritive yolk forms by far the larger portion of the egg, the cleavage is limited to the formative yolk, and is therefore only *partial*; such ova are termed *meroblastic*. Again, it has been observed, in some of the lower animals, that the pronuclei do not fuse but merely lie in apposition. At the commencement of the segmentation process the chromosomes of the two pronuclei group themselves around the equator of the nuclear spindle and then divide; an equal number of male and female chromosomes travel to the opposite poles of the spindle, and thus the male and female pronuclei subscribe equal shares of chromatin to the nuclei of the two cells which result from the subdivision of the fertilised ovum.

CC-0. In Public Domain. Gurukul Kangri Collection, Haridwar

Digitized by Arya Samaj Foundation Chennai and eGangotri

is repeated again and again, so that the two cells are succeeded by four, eight, sixteen, thirty-two, and so on, with the result that a mass of cells is found within the zona striata, and to this mass the term *morula* is applied (fig. 68). The cells of the morula, at first closely aggregated, soon arrange themselves into (1) an outer or peripheral layer, the *trophoblast*, which takes no part in the formation of the embryo proper but is concerned in the formation of a protecting membrane, the chorion, from part of which a portion of the placenta is subsequently developed, and (2) an *inner cell-mass*, from a portion of which the embryo is developed. In most mammals fluid collects between the trophoblast and the greater part of the inner cell-mass, and thus the morula is converted into a vesicle which encloses the *segmentation cavity* (fig. 69). The inner cell-mass remains in contact, however, with the trophoblast at one pole of the ovum; this is named the *embryonic pole*, since it indicates the situation where the future embryo is developed. In the human ovum (figs. 72 to 74) there is no actual segmentation cavity but the inner and outer cell-masses are separated in part by delicate strands of mesoderm (magma réticulé or primitive mesoderm). Clefts appear in the magma réticulé, on either side of the developing inner cell-mass, and run together to form the *extra-embryonic cœlom* (fig. 74).

FIG. 72.—A diagram showing the first differentiation of the inner cell-mass.

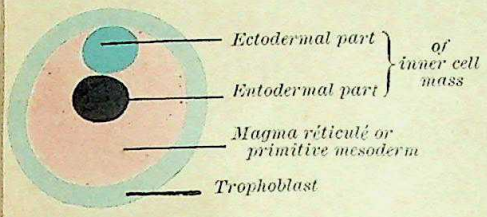

FIG. 73.—A diagram showing the early stages in the formation of the amnion and archenteron.

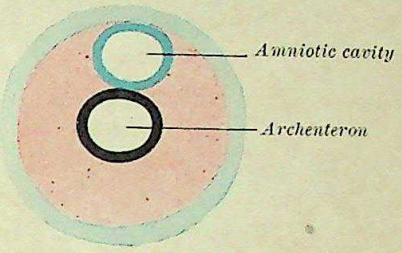

FIG. 74.—A diagram showing the commencing formation of the extra-embryonic cœlom.

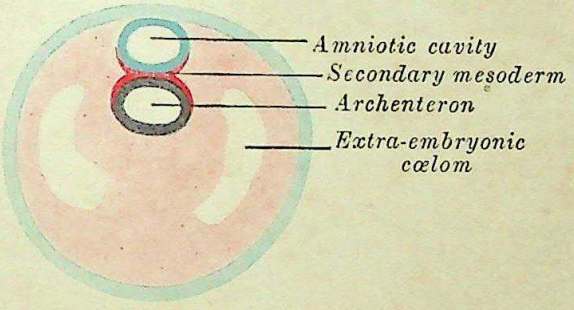

The trophoblast differentiates into two strata: an outer, the *syncytium* or *syncytiotrophoblast*, consisting of a layer of protoplasm studded with nuclei, but showing no evidence of subdivision into cells; and an inner, the *cytotrophoblast* or *layer of Langhans*, in which the cell-outlines are defined. As already stated, the trophoblast takes no share in the formation of the embryo proper; it forms the ectoderm of the chorion and plays an important part in the imbedding of the ovum in the uterine mucous membrane, and in the development of the placenta. The inner cell-mass divides into a dorsal, ectodermal, and a ventral, entodermal, part. Spaces appear between the cells of both parts and coalesce to form cavities; the cavity in the ectodermal part is named the *amniotic cavity*, that in the entodermal part, the *archenteron* (figs. 72, 73). The floor of the amniotic cavity is formed by the *embryonic disc* composed of a layer of prismatic cells, the *embryonic ectoderm*, which is in apposition with the *entoderm* of the archenteron (fig, 71).

The **formation of the mesoderm—the primitive streak.**—The development of the mesoderm has not been observed in the human ovum, seeing that it is already present in the youngest human ova that have been examined. From what has

CC-0. In Public Domain. Gurukul Kangri Collection, Haridwar

Digitized by Arya Samaj Foundation Chennai and eGangotri

been observed in other animals it may be concluded that the primitive streak is its principal source. The embryonic disc becomes oval and then pear-shaped. Near its narrow, caudal end an opaque streak, the *primitive streak* (fig. 75), makes its appearance and extends along the middle of the disc for a considerable part of its length; at the cephalic end of the streak there is a knob-like thickening of the ectoderm termed *Hensen's knot*. A shallow groove, the *primitive groove*, appears on the surface of the streak, and the cephalic end of this groove communicates with the archenteron through an aperture named the *blastopore*. The primitive streak is produced by a thickening of the axial part of the ectoderm, the cells of which multiply and blend with those of the subjacent entoderm (fig. 76, III, IV, V). From the primitive streak a third layer of cells, the *mesoderm*, extends between the ectoderm and entoderm.

The extension of the mesoderm takes place throughout the whole of the embryonic and extra-embryonic areas of the ovum, except in certain regions. One of these is seen at the cephalic end of the neural tube. Here the mesoderm grows forwards

FIG. 75.—An embryo of Hylobates concolor. Dorsal aspect, with the amnion laid open. (After Selenka.) (From Quain's Elements of Anatomy, vol. i., Embryology.)

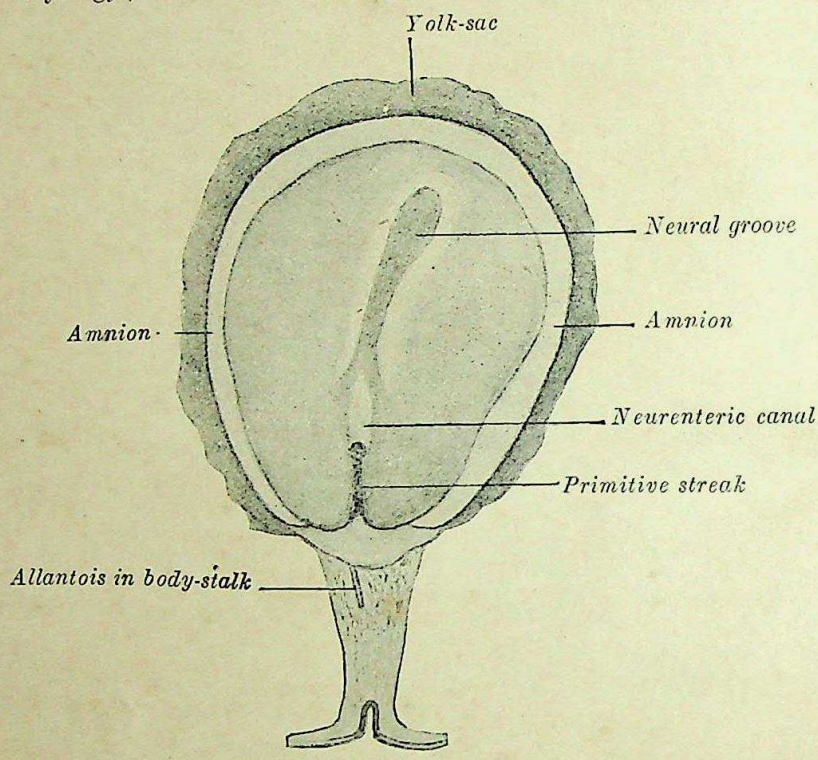

in the form of two crescentic masses, which meet in the middle line so as to enclose an area which is devoid of mesoderm. Over this area the ectoderm and entoderm are in contact with each other and constitute a thin membrane, the *buccopharyngeal membrane*, which forms a septum between the stomodœum or primitive mouth and the fore-gut or head-end of the primitive digestive tube. Where the lateral crescents of mesoderm meet in front of the buccopharyngeal membrane, the pericardium is afterwards developed, and this region is therefore designated the *pericardial area*. At the hind end of the embryo the ectoderm and entoderm are also in contact, and here they form the *cloacal membrane*.

The embryonic disc now consists of three layers, named from without inwards, ectoderm, mesoderm, and entoderm; each has distinctive characteristics and gives rise to certain tissues of the body.

The **ectoderm** consists of columnar cells, which are, however, somewhat flattened or cubical towards the margin of the embryonic disc. It forms the whole of the nervous system, the epidermis of the skin, the lining cells of the sebaceous, sudoriferous and mammary glands, the hairs and nails, the epithelium of the nose and adjacent air-sinuses, and that of the cheeks and roof of the mouth. From it

CC-0. In Public Domain. Gurukul Kangri Collection, Haridwar

Digitized by Arya Samaj Foundation Chennai and eGangotri

also are derived the anterior lobe of the hypophysis cerebri, the epithelium of the cornea, conjunctiva, and lacrimal glands, the neuro-epithelium of the sense-organs, and the enamel of the teeth.

FIG. 76.—A series of transverse sections through the embryonic disc of Tarsius. (After Hubrecht.) (From Quain's Elements of Anatomy, vol. i., Embryology.)

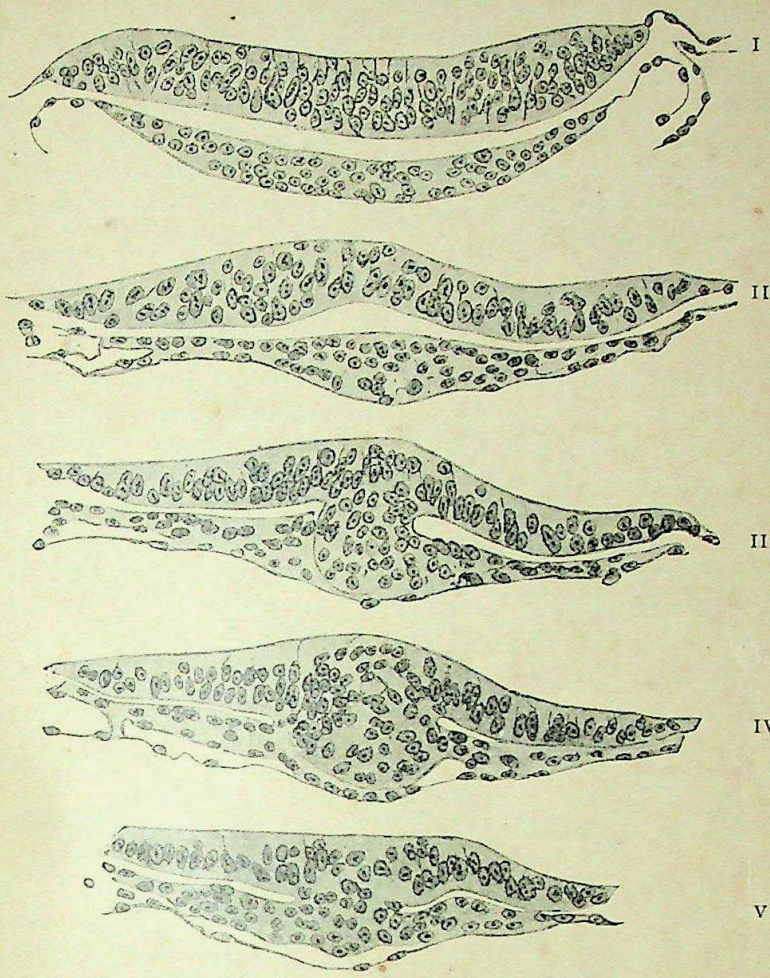

Section I passes through the disc, in front of Hensen's knot, and shows only the ectoderm and entoderm. Sections II, III, and IV pass through Hensen's knot, which is seen in V tapering away into the primitive streak. In III, IV, and V the mesoderm is seen springing from the keel-like thickening of the ectoderm, which in III and IV is observed to be continuous into the entoderm.

The **entoderm** consists at first of flattened cells, which subsequently become columnar. It forms the epithelial lining of the whole of the digestive tube excepting part of the mouth and pharynx and the terminal part of the rectum (which are lined by involutions of the ectoderm), the lining cells of all the glands which open into the digestive tube, including those of the liver and pancreas, the epithelium of the auditory tube and tympanic cavity, of the trachea, bronchi, and air-cells of the lungs, of the urinary bladder and part of the urethra, and that which lines the follicles of the thyreoid gland and thymus.

FIG. 77.—A diagram showing the extension of the mesoderm.

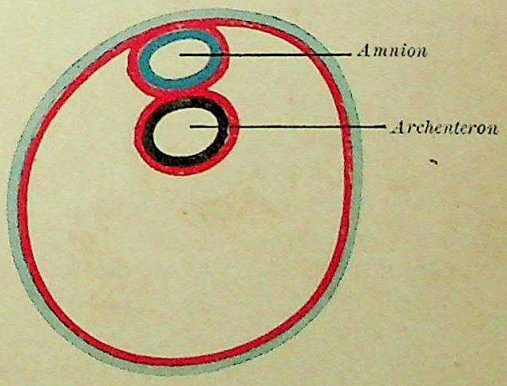

The **mesoderm** consists of loosely arranged branched cells surrounded by a considerable amount of intercellular fluid. From it the remaining tissues of the body are developed. The endothelial lining of the heart and blood-vessels and the blood-corpuscles are, however, regarded by some as being of entodermal origin.

As the mesoderm spreads between the ectoderm and entoderm it is separated for a time into lateral halves by the neural tube and notochord, presently to be

CC-0. In Public Domain. Gurukul Kangri Collection, Haridwar

Digitized by Arya Samaj Foundation Chennai and eGangotri

described. A longitudinal groove appears on the dorsal surface of either half and divides it into (*a*) the *paraxial mesoderm* which adjoins the neural tube and notochord, and is subsequently divided into the primitive segments, and (*b*) a lateral portion, the *lateral mesoderm*. The mesoderm in the floor of the longitudinal groove between the paraxial and the lateral mesoderm, is known as the *intermediate cell-mass;* the genito-urinary organs are developed in it, and for this reason it is sometimes named the *nephrogenic cord*. The lateral mesoderm splits into two layers, an outer or *somatic*, which adheres to the outer surface of the ectoderm of the amniotic vesicle, and extends on to the inner surface of the trophoblast now developing into the chorion; and an inner or *splanchnic*, which adheres to the entoderm, and with it forms the *splanchnopleure* (figs. 79, 82). The space between the two layers of the mesoderm is termed the *cœlom*. The intra-embryonic part of the cœlom forms the pericardial, pleural and peritoneal cavities; the extra-embryonic part is obliterated (p. 61).

THE NEURAL GROOVE AND TUBE

Anterior to the cephalic end of the primitive streak two longitudinal ridges, caused by a thickening and upfolding of the ectoderm, make their appearance, one on either side of the middle line (fig. 79). These are named the *neural folds*; they commence near the cephalic end of the embryonic disc, where they are continuous with each other, and gradually extend caudalwards, one on either side of the primitive streak. Between the neural folds is a shallow median groove, the *neural groove* (figs. 79, 80). This groove gradually deepens, and the edges of the folds meet and coalesce in the middle line and convert it into a closed tube, the *neural tube or canal* (fig. 82), the ectodermal wall of which forms the rudiment of the nervous

Fig. 78.—Two stages in the development of the neural crest in the human embryo. (Lenhossék.)

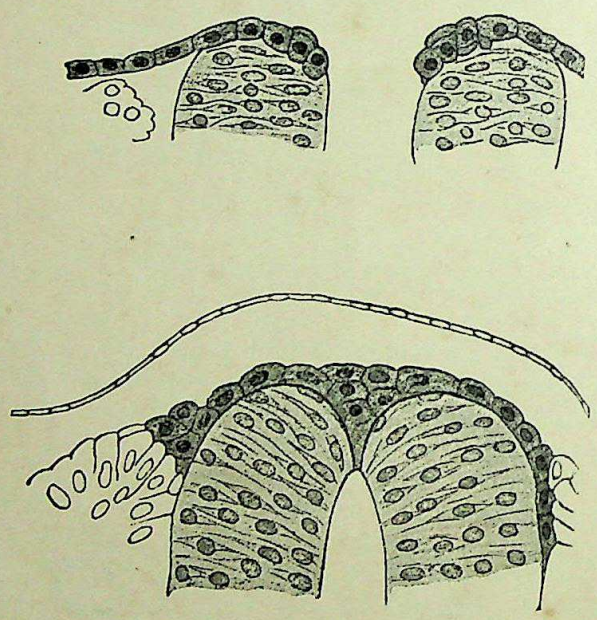

system. By the coalescence of the neural folds over the anterior end of the primitive streak, the blastopore no longer opens on the dorsal surface of the embryo but into the neural tube, and thus a transitory canal, the *neurenteric canal*, is established between the neural and primitive digestive tubes. Closure of the neural groove occurs first in the region of the hind-brain, and from there extends forwards and backwards; towards the end of the third week the anterior opening (*anterior neuropore*) of the tube closes, and forms a recess which is in contact, for a time, with the overlying ectoderm; about the same time the posterior opening or *posterior neuropore* is closed. Subsequently the paraxial mesoderm grows round the neural tube, and separates it from the overlying ectoderm.

Before the neural groove is closed a ridge of ectodermal cells appears along the margin of either neural fold; this is termed the *neural crest* or *ganglion-ridge* (fig. 78),

CC-0. In Public Domain. Gurukul Kangri Collection, Haridwar

Digitized by Arya Samaj Foundation Chennai and eGangotri

and from it the spinal and cerebral nerve-ganglia, the ganglia of the sympathetic nervous system, and the chromaffin bodies are developed.

The cephalic end of the neural groove exhibits several dilatations which, when the neural tube is closed, assume the form of three vesicles; these constitute the three primary cerebral vesicles, and correspond respectively to the future *prosencephalon* (fore-brain), *mesencephalon* (mid-brain), and *rhombencephalon* (hind-brain) (fig. 81). The walls of the vesicles are developed into the nervous tissue and neuroglia of the brain, and the cavities of the vesicles are modified to form the ventricles of the brain. The remainder of the neural tube forms the *medulla spinalis* or *spinal cord*; from its ectodermal wall the nervous and neuroglial elements are formed and its cavity persists as the central canal of the medulla spinalis.

FIG. 79.—A series of transverse sections through the embryo of a dog. (After Bonnet.) (From Quain's Elements of Anatomy, vol. i., Embryology.)

Section I is the most anterior. In V the neural plate is spread out nearly flat. The series shows the uprising of the neural folds to form the neural canal.

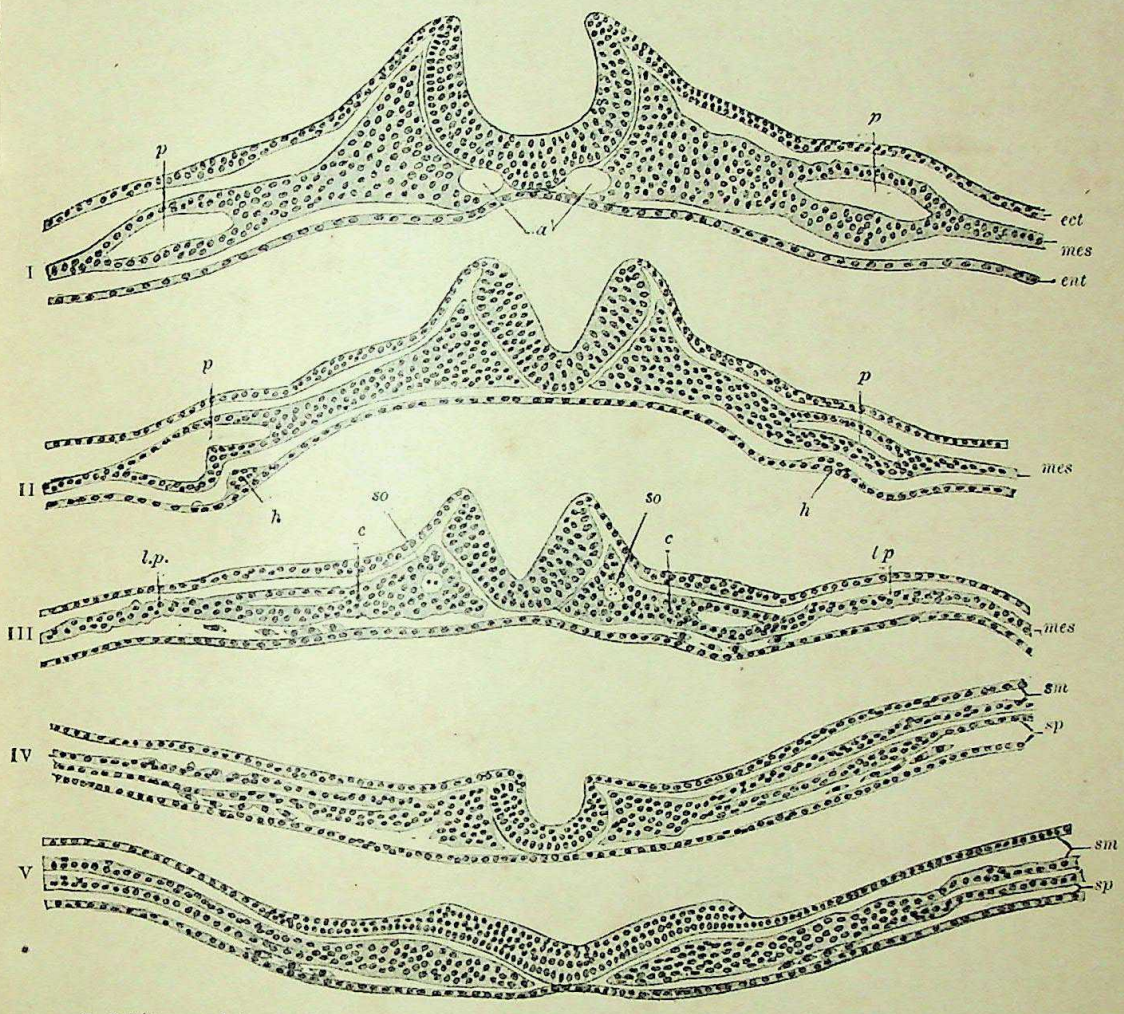

a, aortæ; *c*, intermediate cell-mass; *ect*, ectoderm; *ent*, entoderm; *h*, *h*, rudiments of endothelial heart-tubes. In III, IV, and V the scattered cells represented between the entoderm and splanchnic layer of mesoderm are the vasoformative cells which give origin in front, according to Bonnet, to the heart tubes *h*: *l.p.*, lateral plate still undivided in I, II, and III; in IV and V split into somatic (*sm*) and splanchnic (*sp*) layers of mesoderm; *mes*, mesoderm; *p*, pericardium; *so*, primitive segment.

THE NOTOCHORD

The **notochord** (fig. 82) constitutes the foundation of the axial skeleton, since around it the segments of the vertebral column are formed; its appearance synchronises with that of the neural tube. It grows forwards as a rod of cells (probably of mesodermal origin) from the cephalic end of the primitive streak, and is at first intimately connected with the entoderm underlying the neural groove. It soon separates from the entoderm, and the separation is later emphasised by the meso-

CC-0. In Public Domain. Gurukul Kangri Collection, Haridwar

Digitized by Arya Samaj Foundation Chennai and eGangotri

derm which grows medialwards and surrounds it. When fully formed the notochord extends throughout the length of the future vertebral column, and its cephalic end reaches as far as the anterior part of the mid-brain, where it ends in a hook-like extremity in the region of the future dorsum sellæ of the sphenoidal bone. From the mesoderm surrounding the neural tube and notochord, the skull, the vertebral column, and the membranes of the brain and medulla spinalis are developed.

THE PRIMITIVE SEGMENTS

Towards the end of the third week transverse segmentation of the paraxial mesoderm begins, and converts it into a series of well-defined, more or less cubical masses, the *primitive segments* (figs. 81, 82, 83), which extend from the occipital region of the skull along the entire length of the trunk on either side of the middle line. Each segment originally contains a central cavity (*myocœl*), but this is soon filled with angular and spindle-shaped cells.

The primitive segments lie immediately under the ectoderm on the lateral aspect of the neural tube and notochord, and are connected to the lateral mesoderm by the *intermediate cell-mass*. Those of the trunk are divisible into the following groups

FIG. 80.—A human embryo, 2 mm. in length. Dorsal aspect, with the amnion laid open. × 30. (After Graf Spee.)

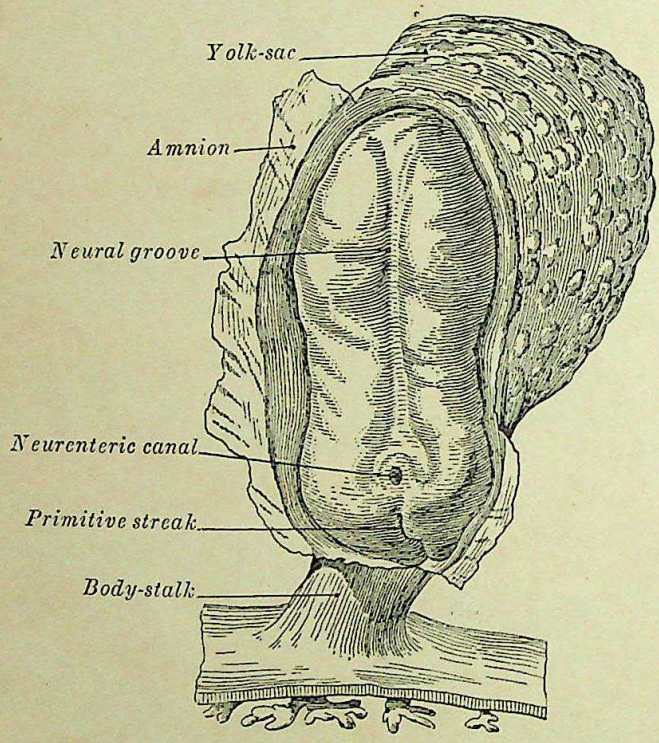

viz.: cervical 8, thoracic 12, lumbar 5, sacral 5, and coccygeal from 8 to 10. Those of the occipital region of the head are usually described as being four in number. In mammals primitive segments of the head can only be recognised in the occipital region, but a study of the lower vertebrates leads to the belief that they are present also in the anterior part of the head, and that altogether nine segments are represented in the head region.

THE FORMATION OF THE EMBRYO

The embryo increases rapidly in size, but the circumference of the embryonic disc, or line of meeting of the embryonic and amniotic parts of the ectoderm, is of relatively slow growth and gradually forms a constriction between the embryo and the greater part of the archenteron. By means of this constriction, which corresponds to the future umbilicus, the dorsal part of the archenteron is enclosed

CC-0. In Public Domain. Gurukul Kangri Collection, Haridwar

Digitized by Arya Samaj Foundation Chennai and eGangotri

within the embryo and constitutes the *primitive digestive tube*; the ventral part is left outside the embryo and constitutes the *yolk-sac*.

The embryo grows more rapidly in length than in width, and its cephalic and caudal ends bend in a ventral direction to form the *cephalic and caudal folds* respectively (figs. 89, 90). The cephalic fold is first formed, and the forward growth of

FIG. 81.—A chick embryo thirty-three hours old. Dorsal aspect. × 30. (From Duval's Atlas d'Embryologie.)

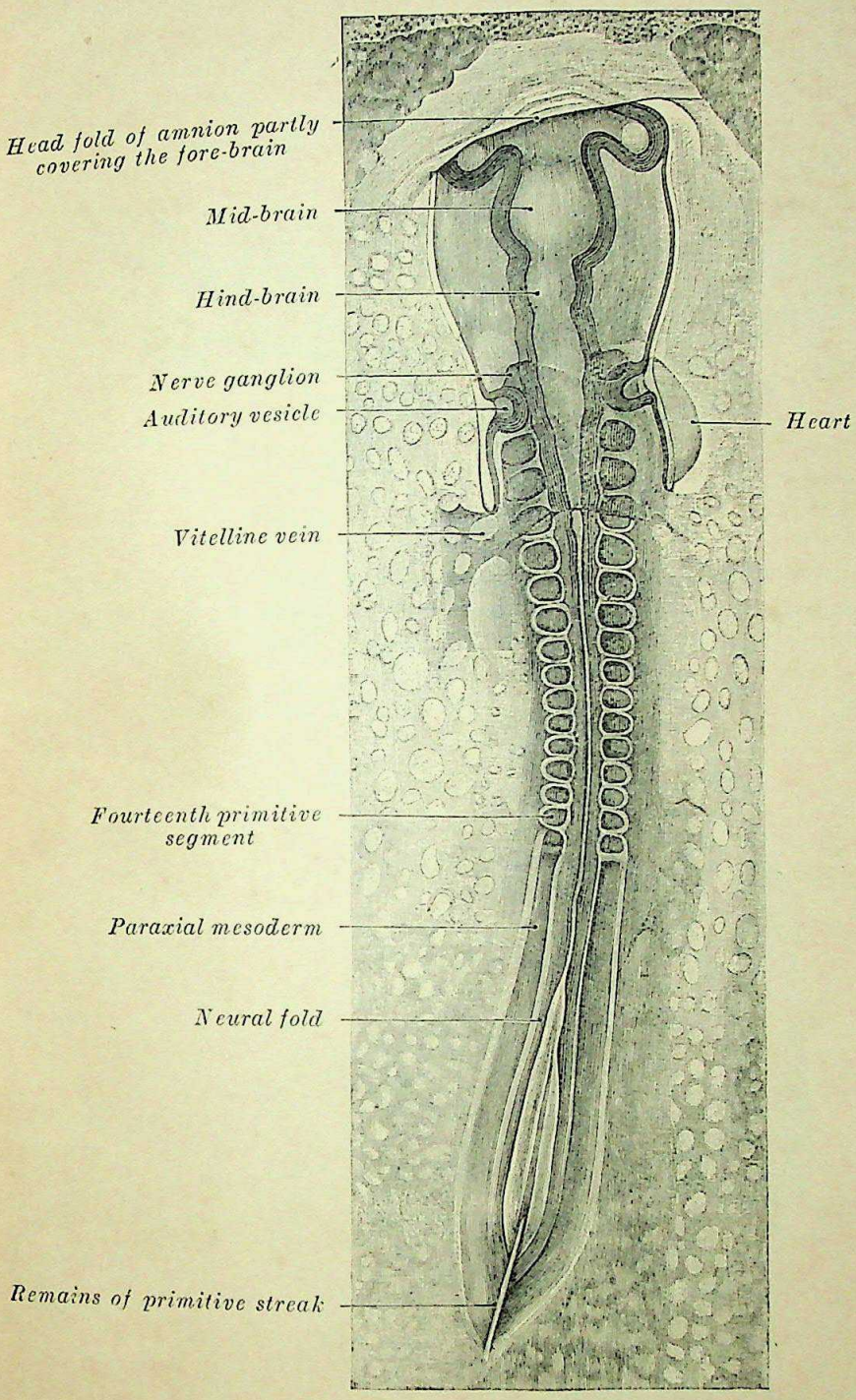

the head necessarily carries with it the posterior end of the pericardial area, so that this area and the buccopharyngeal membrane are folded under the head of the embryo. A diverticulum of the archenteron, named the *fore-gut*, is enclosed in the cephalic fold. The caudal end of the embryo is connected to the chorion by a band of mesoderm called the *body-stalk*, but with the continued growth of this end and the formation of the caudal fold the body-stalk assumes a ventral position; a diverticulum of the archenteron extends into the caudal fold and is termed the *hind-gut*. Between the fore-gut and the hind-gut there exists for a time a wide

CC10. In Public Domain. Gurukul Kangri Collection, Haridwar

Digitized by Arya Samaj Foundation Chennai and eGangotri

opening into the yolk-sac, but the relatively slow growth of the latter reduces it to a small pear-shaped sac (sometimes termed the *umbilical vesicle*), and the channel of communication is at the same time elongated to form a narrow tube called the *vitelline duct*.

THE YOLK-SAC

The **yolk-sac** (figs. 84, 85) is situated on the ventral aspect of the embryo; it is lined with entoderm, outside of which is a layer of mesoderm. It is filled with *vitelline*

FIG. 82.—A transverse section through a ferret embryo. (A. Robinson.)

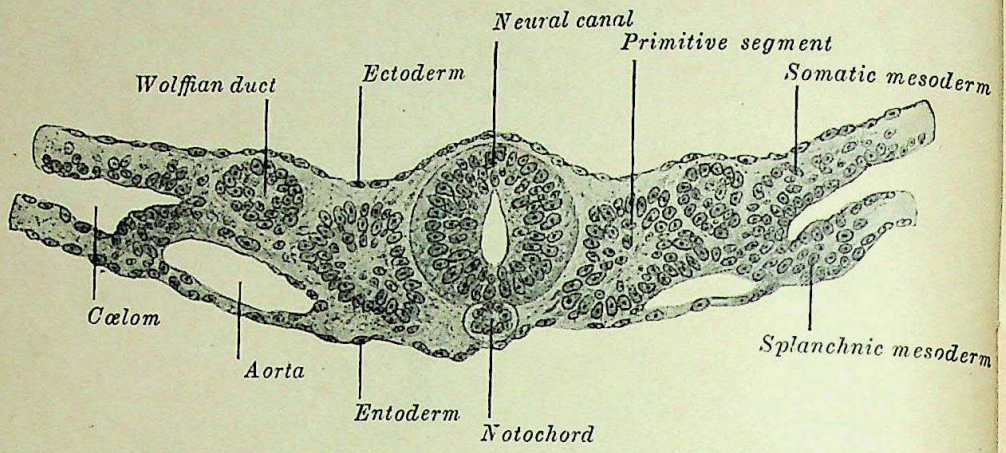

fluid, which is possibly utilised for the nourishment of the embryo during the earlier stages of its existence. Blood is conveyed to the wall of the sac by the ventral branches of the primitive aortæ, and, after circulating through a wide-meshed

FIG. 83.—A human embryo, 2·1 mm. long. Dorsal aspect. (From a model by Eternod.)

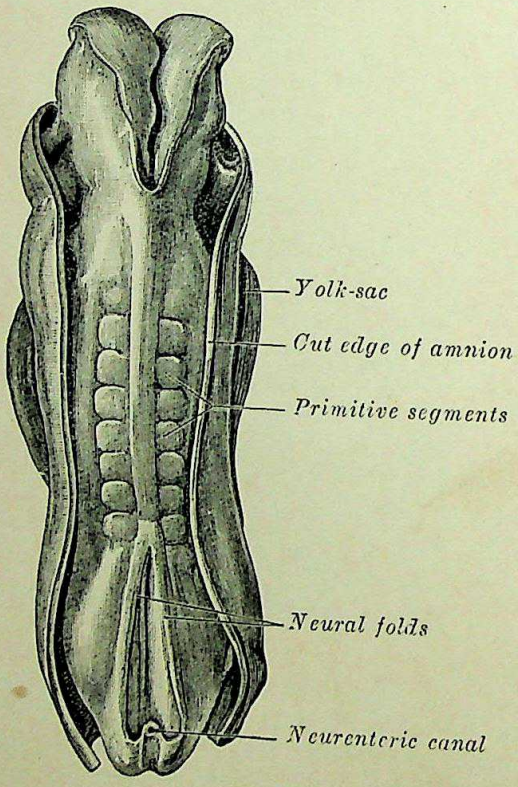

capillary plexus, is returned by the vitelline veins to the tubular heart of the embryo. By means of this circulation nutritive material is absorbed from the yolk-sac and conveyed to the embryo. At the end of the fourth week the yolk-sac presents the

CC-0. In Public Domain. Gurukul Kangri Collection, Haridwar

Digitized by Arya Samaj Foundation Chennai and eGangotri

appearance of a small pear-shaped vesicle (umbilical vesicle) opening into the digestive tube by a long narrow tube, the *vitelline duct*. The vitelline duct loses its attachment to the digestive tube, and as a rule undergoes complete obliteration during the seventh week, but in about two per cent. of cases its proximal part persists as a diverticulum (*Meckel's diverticulum*) from the small intestine, situated

FIG. 84.—A sagittal section through the embryo which is represented in fig. 80. (After Graf Spee.)

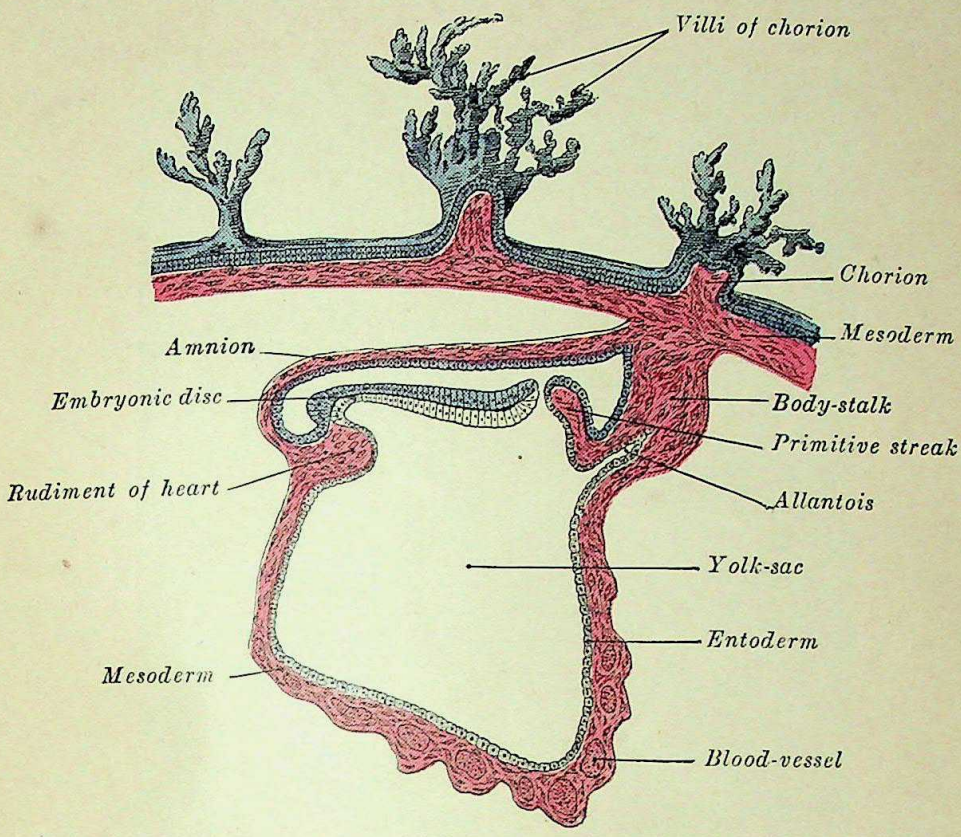

FIG. 85.—A human embryo of 2·6 mm. in length. Lateral aspect. (His.)

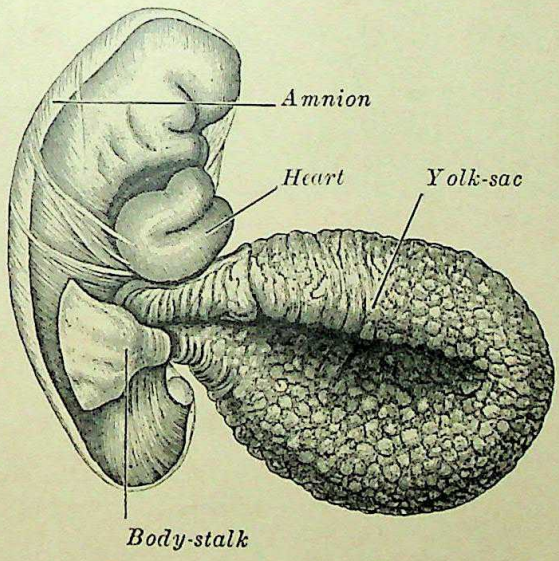

about one metre above the ileocolic junction, and sometimes attached by a fibrous cord to the abdominal wall at the umbilicus. A narrowing of the lumen of the ileum is occasionally found opposite the site of attachment of the duct.

The umbilical vesicle can be seen in the after-birth as a small somewhat oval-shaped body with a diameter of from 1 to 5 mm.; it is situated between the amnion and the chorion, and may lie on, or at a variable distance from, the placenta.

CC-0. In Public Domain. Gurukul Kangri Collection, Haridwar

Digitized by Arya Samaj Foundation Chennai and eGangotri

THE FŒTAL MEMBRANES AND THE PLACENTA

The **allantois** (figs. 84, 90, 93).—The allantois arises as a tubular diverticulum the posterior part of the archenteron; when the hind-gut is developed the allanto is carried backwards with it, and then opens from the cloaca or terminal part

FIG. 86.—A fœtus of about eight weeks, enclosed in the amnion. Magnified a little over 2 diameters. Drawn from stereoscopic photographs lent by Prof. A. Thomson, Oxford.

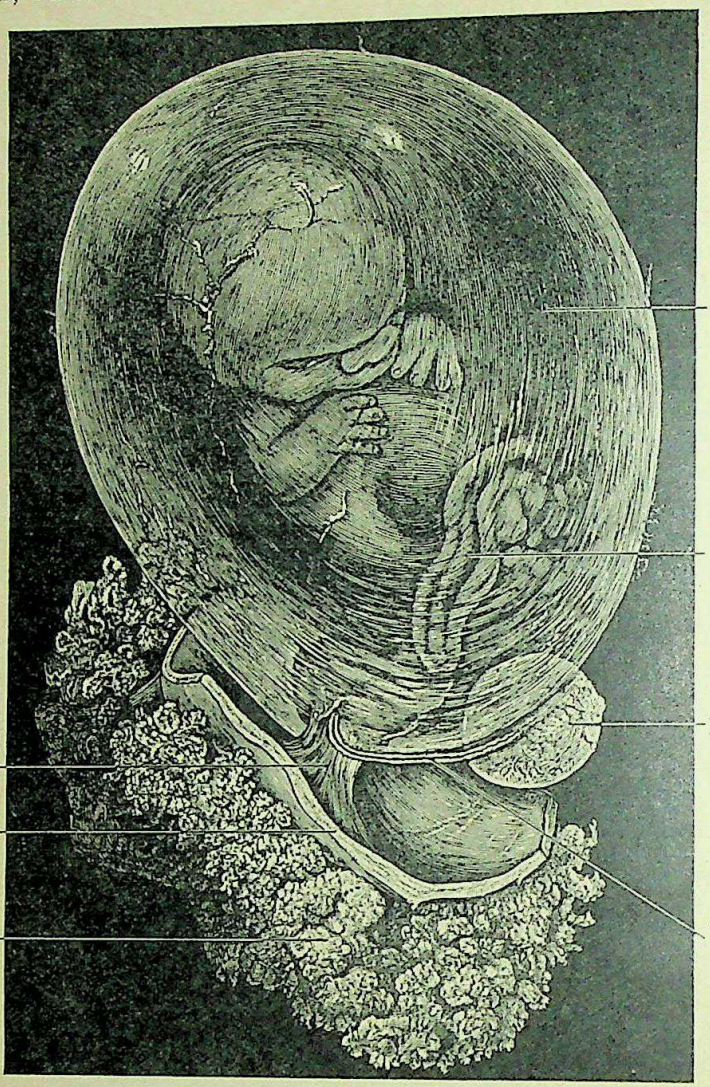

the hind-gut: it extends into the mesoderm of the body-stalk which connects th tail-end of the embryo with the chorion. The allantoic diverticulum is lined wit entoderm and covered with mesoderm, and in the latter are umbilical vessels.*

* In reptiles, birds, and many mammals the allantois expands into a vesicle which projec into the extra-embryonic cœlom. If its further development be traced in the bird, it is seen project to the right side of the embryo, and, gradually expanding, spreads over the dorsal surfa of the embryo as a flattened sac between the amnion and the serosa (p. 60*), and ultimate surrounds the yolk. Its outer wall becomes applied to, and fuses with, the serosa which li immediately inside the shell membrane. Blood is carried to the allantoic sac by the tw allantoic or umbilical arteries, which are continuous with the primitive aortæ, and after circ lating through the allantoic capillaries, is returned to the primitive heart by the two umbilic veins. In this way the allantoic circulation, which is of the utmost importance in connexi with the respiration and nutrition of the chick, is established. Oxygen is taken from, an carbonic acid is given up to the atmosphere through the egg-shell, and nutritive materials a at the same time absorbed by the blood from the yolk. With the formation of the amnion t embryo is, in most animals, entirely separated from the chorion, and is only again united the chorion when the allantoic mesoderm spreads over and becomes applied to its inner surfac but the human embryo, as was pointed out by His, is never wholly separated from the chori its tail-end being from the first connected with the chorion by means of a thick band of mesoder named the *body-stalk*.

CC-0. In Public Domain. Gurukul Kangri Collection, Haridwar

Digitized by Arya Samaj Foundation Chennai and eGangotri

FIG. 87.—A diagram showing the earliest observed stage of the human ovum.

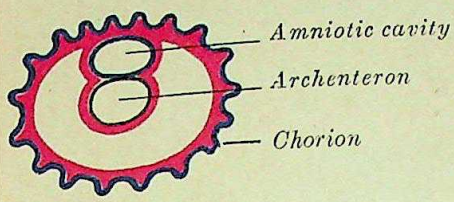

FIG. 88.—A diagram illustrating the early formation of the allantois, and the differentiation of the body-stalk.

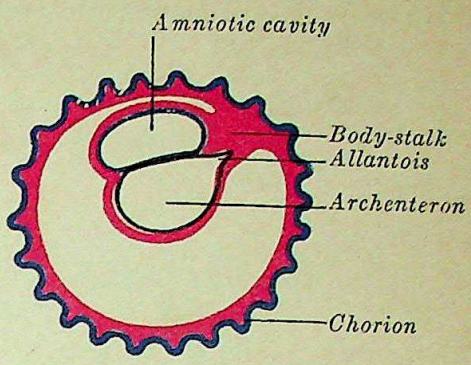

FIG. 89.—A diagram showing a later stage of the development of the allantois.

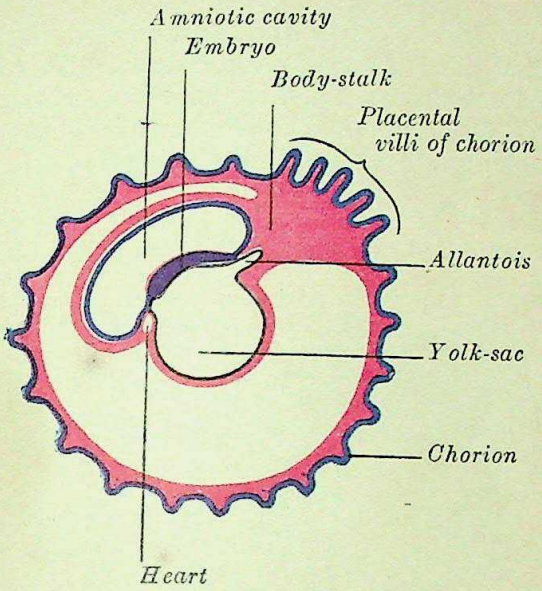

FIG. 90.—A diagram showing the expansion of the amnion, and the delimitation of the umbilicus.

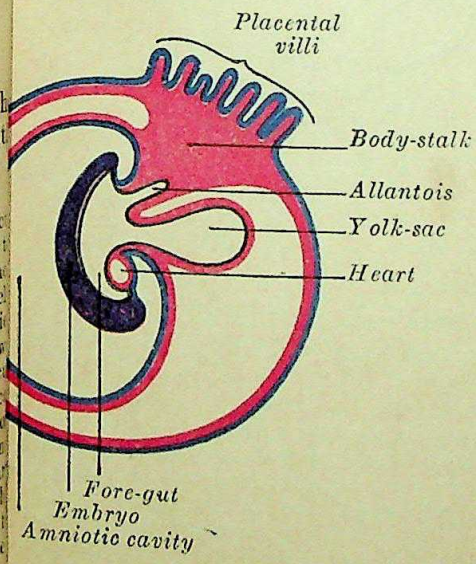

FIG. 91.—A diagram illustrating a later stage in the development of the umbilical cord.

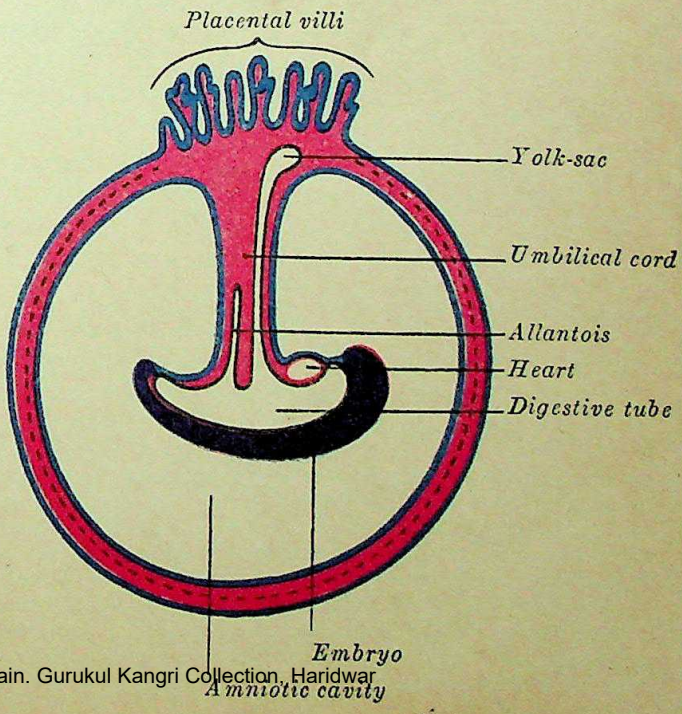

CC-0. In Public Domain. Gurukul Kangri Collection, Haridwar

Digitized by Arya Samaj Foundation Chennai and eGangotri

The **amnion** is a membranous sac which surrounds and protects the embryo; it is developed in reptiles, birds, and mammals, but not in amphibia or fishes.

In the human embryo the earliest stages of the formation of the amnion have not been observed; in the youngest embryo which has been studied the amnion was

FIG. 92.—A transverse section through the umbilical cord.

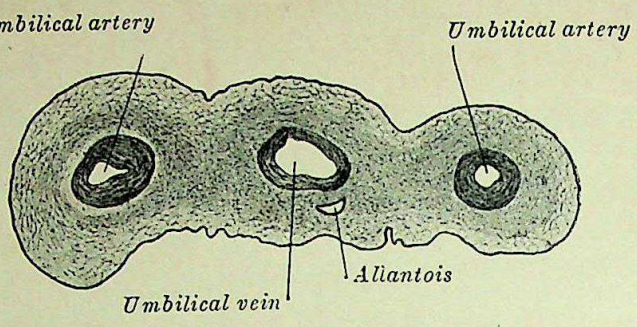

already present as a closed sac (figs. 87, 94), and, as indicated on page 49, appears as a cavity in the ectodermal part of the inner cell-mass. This cavity is roofed in by a stratum of flattened ectodermal cells, the *amniotic ectoderm*, and its floor consists of the prismatic ectoderm of the embryonic disc—the continuity between the roof and floor being established at the margin of the embryonic disc.

FIG. 93.—A human embryo, 1·3 mm. long. (From a model by Eternod.)

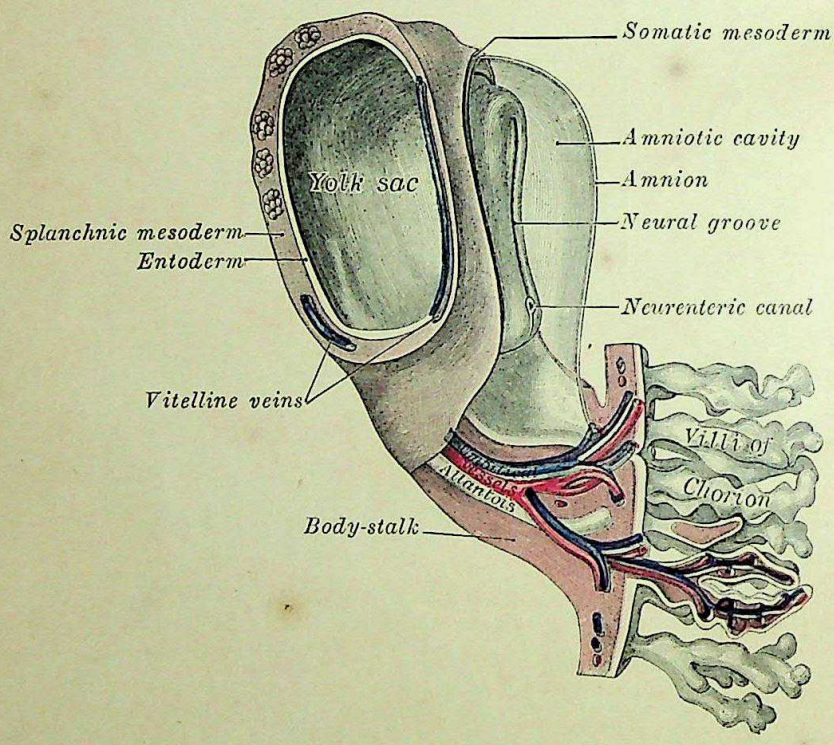

Outside the amniotic ectoderm is a thin layer of mesoderm, continuous with that of the somatopleure and connected by means of the body-stalk with the mesodermal lining of the chorion.*

* In reptiles, birds, and many mammals the amnion is developed as follows:—At the constriction where the primitive digestive tube of the embryo joins the yolk-sac, a reflection or upfolding of the somatopleure takes place. This, the *amniotic fold*, first makes its appearance at the cephalic end, and subsequently at the caudal end and sides of the embryo, and gradually rising more and more its different parts meet and fuse over the dorsal surface of the embryo, and enclose a cavity, the *amniotic cavity*. After the fusion of the edges of the amniotic fold, the two layers of the fold separate; the inner forms the *amnion*, the outer, the *false amnion* or *serosa*. The space between the amnion and the serosa constitutes the extra-embryonic cœlom, and for a time communicates with the embryonic cœlom.

CC-0. In Public Domain. Gurukul Kangri Collection, Haridwar

Digitized by Arya Samaj Foundation Chennai and eGangotri

Fluid, termed *liquor amnii*, appears within the amnion and increases steadily in amount, so that the sac gradually expands and encroaches on the cavity of the extra-embryonic cœlom; this expansion continues until the extra-embryonic cœlom is obliterated. The liquor amnii increases in quantity up to the sixth or seventh month of pregnancy, and then diminishes somewhat; at the end of pregnancy it amounts to about 1 litre. It allows of the free movements of the fœtus during the later stages of pregnancy, and also diminishes the risk to the fœtus of injury from without. It contains less than two per cent. of solids, consisting of urea and other extractives, inorganic salts, a small amount of protein, and frequently a trace of sugar.

FIG. 94.—A section through an ovum imbedded in the uterine decidua. Semidiagrammatic. (After Hubert Peters.)

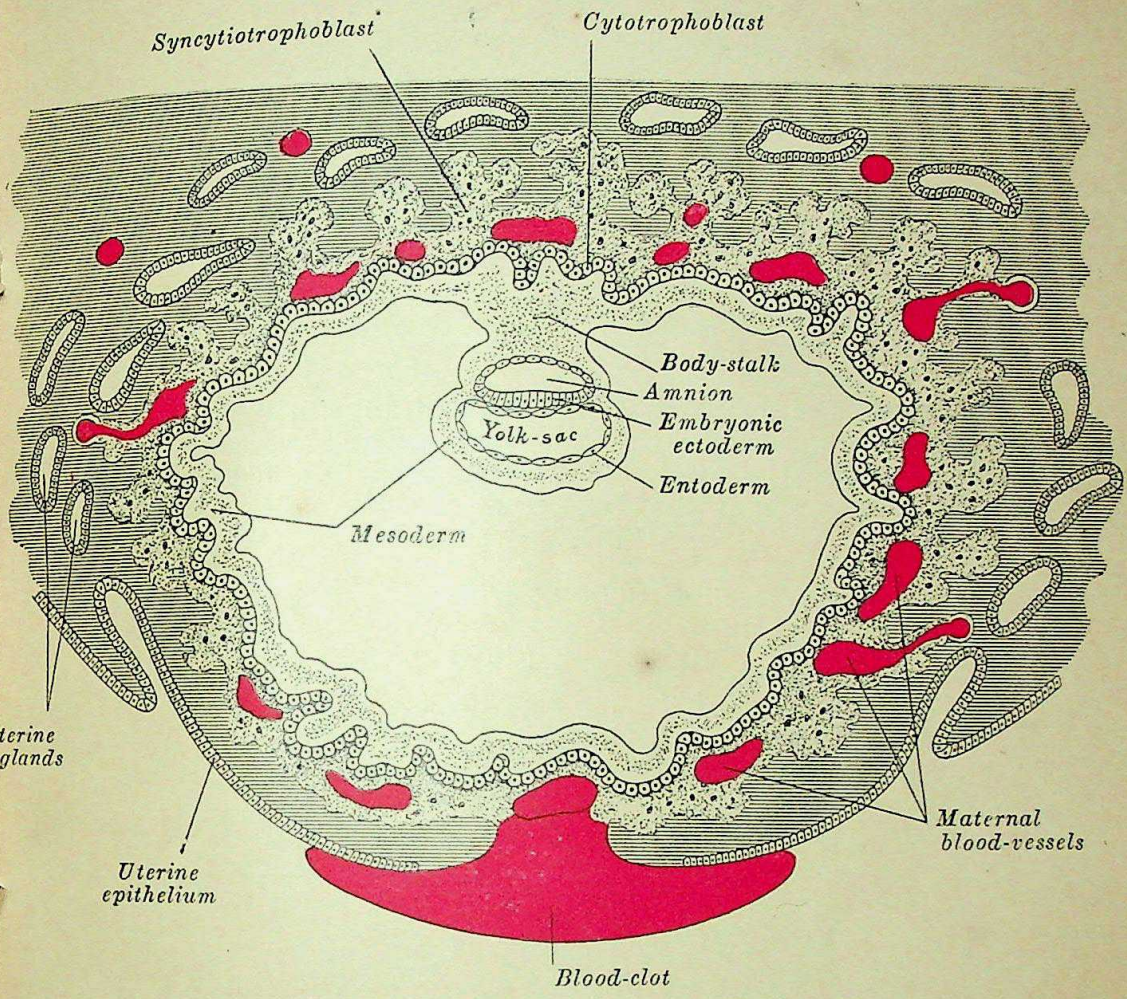

The **body-stalk** and the **umbilical cord**.—The body-stalk (figs. 84, 89, 90, 93) is a band of mesoderm which first connects the tail-end of the embryo with the chorion. Extending into the proximal part of it is the canal of the allantois, and running through it from the embryo to the chorion are the umbilical vessels. Its dorsal surface is covered with the amnion and its ventral surface is bounded by the extra-embryonic cœlom. As a result of the folding of the embryo and the distension of the amnion the body-stalk comes to lie on the ventral surface of the embryo, and its mesoderm approaches that of the yolk-sac and vitelline duct (fig. 90). As a consequence of the continued expansion of the amnion, the extra-embryonic cœlom is obliterated (figs. 90, 91), the vitelline duct is elongated, and the mesoderm of the amnion blends with that of the vitelline duct and body-stalk; by this fusion a solid cord, the *umbilical cord*, is formed (fig. 91) and connects the embryo to that portion of the chorion which will form the fœtal part of the placenta.

The umbilical cord (figs. 92, 100) is enveloped by the amniotic ectoderm and consists of a core of gelatinous tissue (*jelly of Wharton*) in which the umbilical vessels, the allantoic diverticulum, and the vitelline duct and vessels are imbedded. The allantoic diverticulum and the vitelline duct and vessels undergo obliteration

CC-0. In Public Domain. Gurukul Kangri Collection, Haridwar

Digitized by Arya Samaj Foundation Chennai and eGangotri

and atrophy, but traces of them may be seen up to the fourth month of pregnancy or later. The umbilical cord becomes spirally twisted, owing, it is believed, to the unequal growth of the two umbilical arteries; it also increases in length so that at the end of pregnancy it is about 50 cm. long.

FIG. 95.—Primary chorionic villi. Diagrammatic. (Modified from Bryce.)

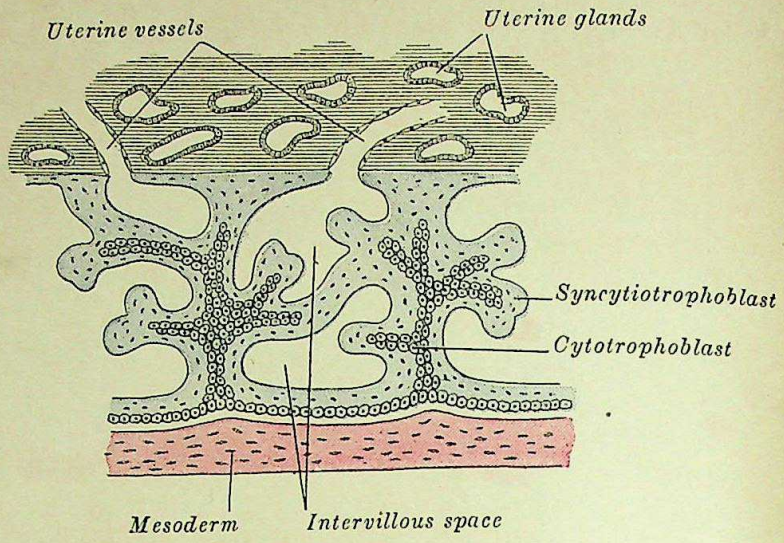

The **implantation or imbedding of the fertilised ovum in the uterine wall.**—As already stated (p. 46), fertilisation of the ovum is believed to occur in the lateral or ampullary end of the uterine tube, and is immediately followed by segmentation. The segmenting ovum is conveyed along the uterine tube to the cavity of the uterus.

FIG. 96.—Secondary chorionic villi. Diagrammatic. (Modified from Bryce.)

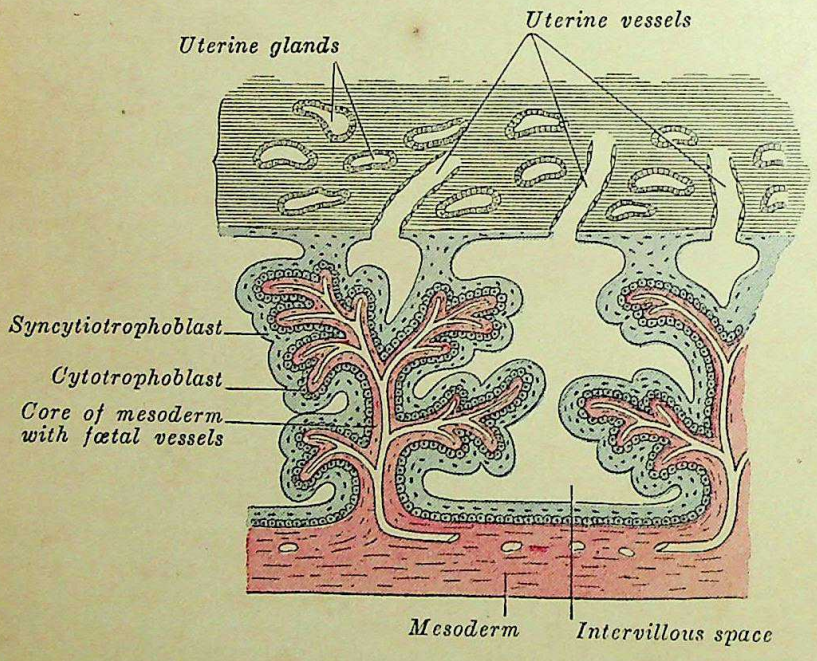

the journey occupying seven or eight days. By the time it reaches the uterus it possesses a well-developed trophoblast. The ovum adheres like a parasite to the uterine mucous membrane, destroys the epithelium over the area of contact, and excavates for itself a cavity in the mucous membrane in which it becomes imbedded. In an ovum described by Bryce and Teacher * the point of entrance of the ovum into

* Contribution to the study of the early development and imbedding of the human ovum, 1908.

CC-0. In Public Domain. Gurukul Kangri Collection, Haridwar

Digitized by Arya Samaj Foundation Chennai and eGangotri

the uterine mucous membrane was found to be closed by a mass of fibrin and leucocytes; in an ovum described by Peters * the opening was covered with a mushroom-shaped mass of fibrin and blood-clot (fig. 94), the narrow stalk of which plugged the aperture in the mucous membrane. Soon, however, all trace of the opening is lost, and the ovum is then completely surrounded by the uterine mucous membrane.

The structure actively concerned in excavating the uterine mucous membrane is the trophoblast. This increases rapidly in thickness, invades and digests the uterine tissues, destroys the epithelial cells of the uterine glands and the walls of the uterine (maternal) blood-vessels (fig. 94); at the same time there appear in the trophoblast numerous anastomosing spaces which are filled with maternal blood. These spaces expand to form what is ultimately known as the *intervillous space*, and the trophoblast is separated into a number of branching processes named the

FIG. 97.—A transverse section of a secondary chorionic villus.

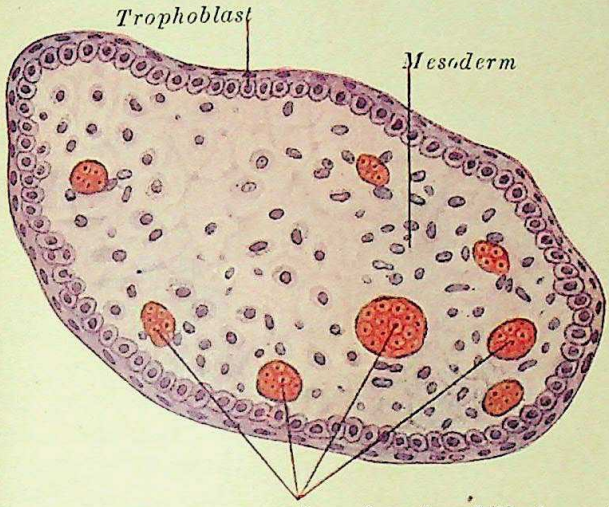

primary chorionic villi (fig. 95) which are bathed in the maternal blood. Cores of mesoderm, containing branches of the umbilical vessels, soon invade the primary chorionic villi and convert them into *secondary chorionic villi* (figs. 96, 97).

The decidua.—Before the fertilised ovum reaches the uterus, the mucous membrane of the body of the uterus undergoes important changes, and is then known as the *decidua*. The thickness and vascularity of the mucous membrane are greatly increased; its glands are elongated and open on its free surface by funnel-shaped orifices, while the deeper portions of the glands are tortuous and dilated into irregular spaces. The interglandular tissue is also increased in quantity, and is crowded with large round, oval, or polygonal cells, termed *decidual cells*. These changes are well advanced by the second month of pregnancy, when the mucous membrane consists of the following strata (fig. 98): (1) *stratum compactum*, next the free surface; in this the uterine glands are only slightly expanded, and are lined by columnar cells; (2) *stratum spongiosum*, where the uterine glands are greatly dilated and very tortuous, and are ultimately separated from one another by a small amount of interglandular tissue; for a time the cells lining the glands are cylindrical, but later they become flattened; (3) a thin *limiting or boundary layer*, next the uterine muscular fibres, containing the deepest parts of the uterine glands, which are not dilated, and are lined with cubical epithelium; it is from this epithelium that the epithelial lining of the uterus is regenerated after parturition.

After the ovum is imbedded distinctive names are applied to different portions of the decidua. The part which covers the ovum is named the *decidua capsularis*; the portion between the ovum and the uterine muscular wall is named the *decidua basalis* or *decidua placentalis*, since it is here that the placenta is subsequently developed; the part which lines the remainder of the body of the uterus is known as the *decidua vera* or *decidua parietalis* (fig. 99).

* *Die Einbettung des menschlichen Eies*, 1899.

CC-0. In Public Domain. Gurukul Kangri Collection, Haridwar

Digitized by Arya Samaj Foundation Chennai and eGangotri

Coincidently with the growth of the embryo, the decidua capsularis is thinne and distended (fig. 99) and the space between it and the decidua vera is gradual obliterated. By the beginning of the thi month of pregnancy the decidua capsula and decidua vera are in contact; by t fifth month of pregnancy the decidua ca sularis has practically disappeared, wh during the succeeding months the decid vera also atrophies, owing to the increas pressure. The glands of the stratum co pactum are obliterated, and their e thelium is lost; in the stratum spongiosu the glands are compressed and appear slit-like fissures, and their epithelium unde goes degeneration; in the limiting boundary layer, however, the glandul epithelium retains a cubical form.

FIG. 98.—Sections of the uterine mucous membrane; (A) of the non-pregnant uterus; (B) of the pregnant uterus. Diagrammatic. (Kundrat and Engelmann.)

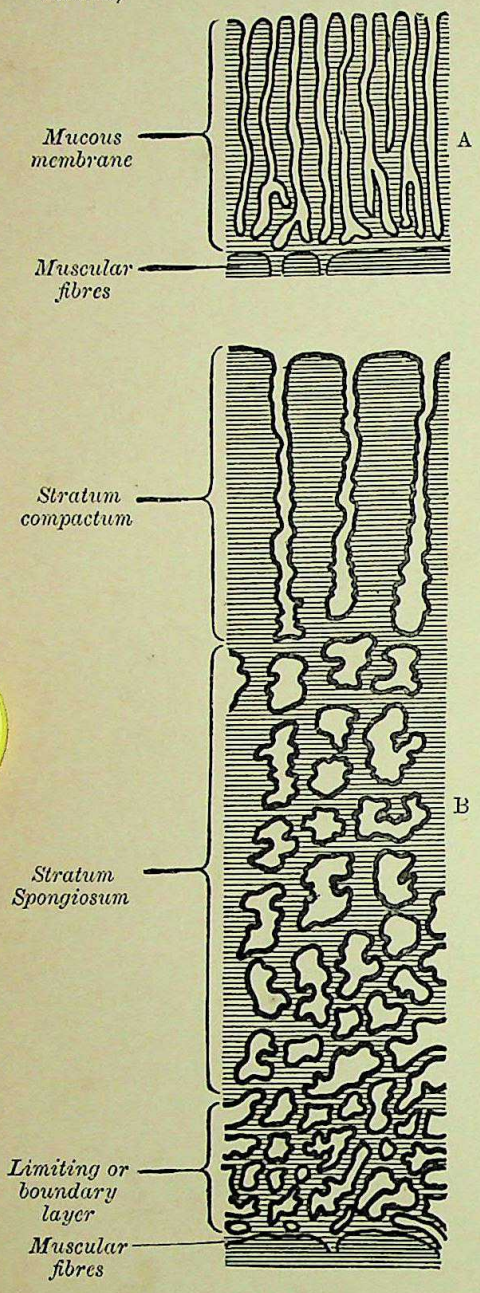

The **chorion** (figs. 89 to 93 and 95 to 9 consists of two layers: an outer of troph blast, and an inner of mesoderm. Th trophoblast consists of an internal layer, th *cytotrophoblast* or *layer of Langhans*, and a external layer, the *syncytiotrophoblast*. A stated (p. 63) the trophoblast undergo rapid proliferation and forms, on the su face of the chorion, numerous processes, th *primary chorionic villi* (fig. 95); these i crease in size and ramify, and the chorion mesoderm, carrying branches of the um bilical vessels, grows into them, and in th way they are converted into *seconda chorionic villi* (fig. 96). Blood is carrie from the embryo to the chorion by th umbilical arteries, and after circulatin through the capillaries of the chorionic vill is returned to the embryo by the umbilic veins. Until about the end of the secon month of pregnancy the entire chorion i covered by villi which are almost unifor in size, and project into the decidua placen talis and decidua capsularis (fig. 100). Wit the growth of the embryo and the expan sion of the amniotic cavity the decidu capsularis is thinned and compressed, th circulation through it is gradually cu off, and the villi of the corresponding par of the chorion atrophy and disappea This portion of the chorion becomes smoot (*chorion læve*); and, as it takes no shar in the formation of the placenta, is some times named the non-placental part of th chorion. On the other hand, the villi on that part of the chorion which is in conta with the decidua placentalis increase greatly in size and complexity, and hence th part is named the *chorion frondosum* (figs. 90, 91).

The **placenta** (figs. 100 to 102) connects the fœtus to the uterine wall, and is th organ by means of which the nutritive, respiratory, and excretory functions of th fœtus are carried on. It is composed of fœtal and maternal parts.

The *fœtal portion of the placenta* consists of the villi of the chorion frondosum which branches repeatedly, and increase enormously in size. The ends of some of the villi are anchored by columns of trophoblast to the walls of the intervillous space but the majority hang free in this space. All are bathed in maternal blood, which is conveyed to and from the intervillous space by the uterine vessels. Blood i carried from the embryo to the placental villi by the umbilical arteries, and returne

CC-0. In Public Domain. Gurukul Kangri Collection, Haridwar

Digitized by Arya Samaj Foundation Chennai and eGangotri

to the embryo by the umbilical veins. One or two branches of an artery enter each villus and there end in a capillary plexus which is drained by one or two tributaries of the veins. The vessels of the villi are surrounded by a thin layer of mesoderm which is covered with the two strata of the trophoblast, the cytotrophoblast or layer of Langhans being in contact with the mesoderm, and the syncytiotrophoblast in contact with the maternal blood (fig. 102); after the fifth month the two strata are replaced by a single layer of somewhat flattened cells.

Fig. 99.—Diagram showing the ovum imbedded in the uterine decidua.

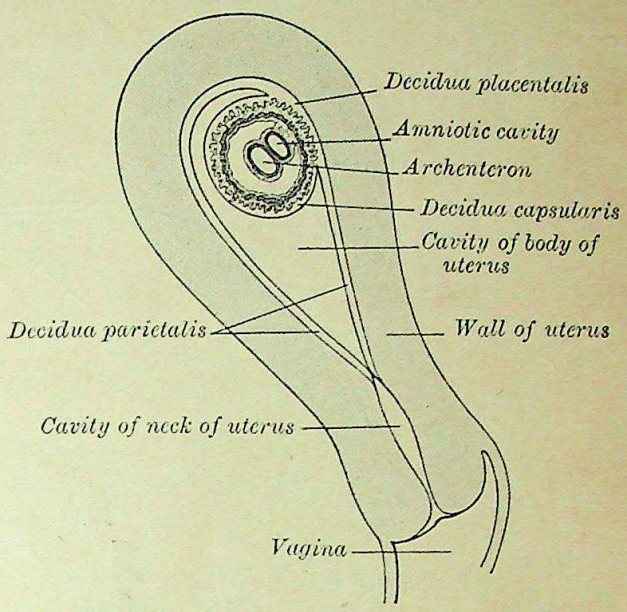

The *maternal portion of the placenta* is formed by the decidua placentalis containing the intervillous space. As already explained (p. 63), this space is produced by the enlargement and intercommunication of the spaces in the trophoblast; it is therefore lined throughout with syncytiotrophoblast. The formation of the intervillous space involves the disappearance of the greater portion of the stratum compactum, but the deeper part of this layer persists and is condensed to form what is known as the *basal plate*; this constitutes the outer wall of the intervillous space, and consists of a stroma containing decidual cells, portions of trophoblast and *fibrinoid substance*; the last appears to be derived in part from the trophoblast

Fig. 100.—A sectional plan of the gravid uterus in the third month. (Modified from Wagner.)

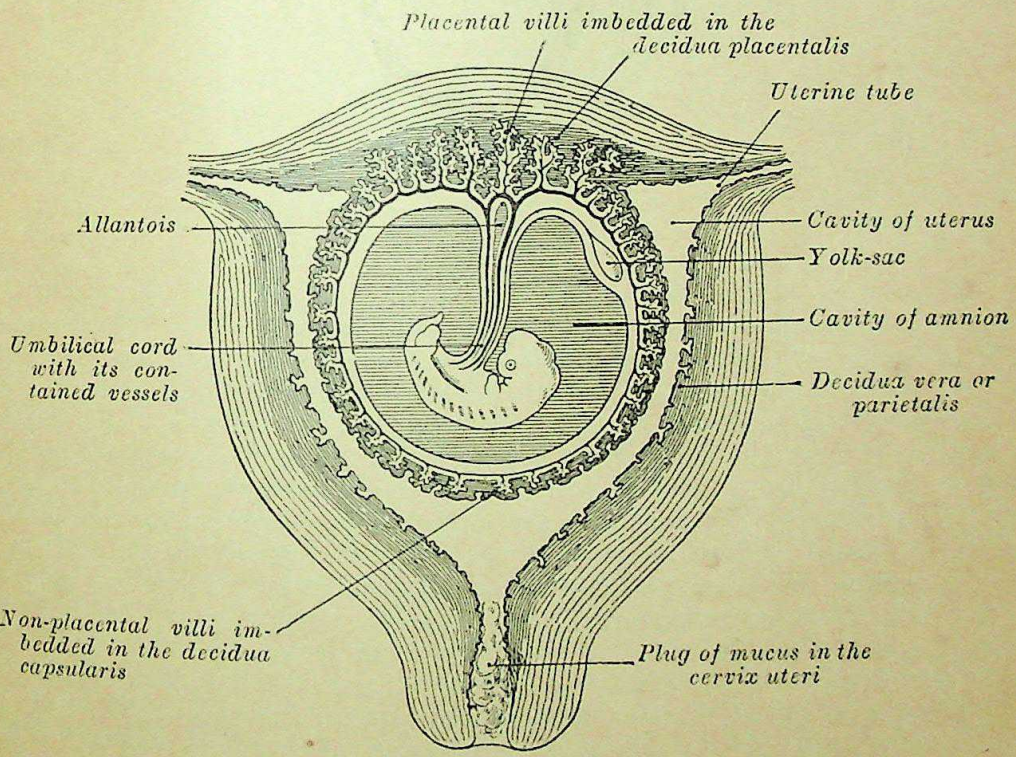

and in part from the maternal blood. Between the basal plate and the uterine muscular fibres are the stratum spongiosum and the limiting layer; through these and the basal plate the uterine arteries and veins pass to and from the intervillous space. Portions of the stratum compactum persist as pillars which project into

CC-0. In Public Domain. Gurukul Kangri Collection, Haridwar

Digitized by Arya Samaj Foundation Chennai and eGangotri

the intervillous space, but these pillars do not extend as far as the chorion, exce in the marginal part of the placenta; later they form the *placental septa* whi incompletely divide the placenta into lobes or *cotyledons*.

Maternal blood is conveyed to the intervillous space by branches of the uteri arteries and carried away by tributaries of the uterine veins (figs. 101, 102). Th vessels lose their muscular coats as they enter the basal plate, and in this plate cons of sinuous channels lined only with endothelium; these channels open into intervillous space, the arteries ending near the placental septa and the veins beginn near the centres of the cotyledons. The endothelial lining of the uterine vess ends where the vessels open into the intervillous space, the latter being lined throu out with syncytiotrophoblast. The circumferential part of the intervillous sp

Fig. 101.—A fœtus in utero, between the fifth and sixth months.

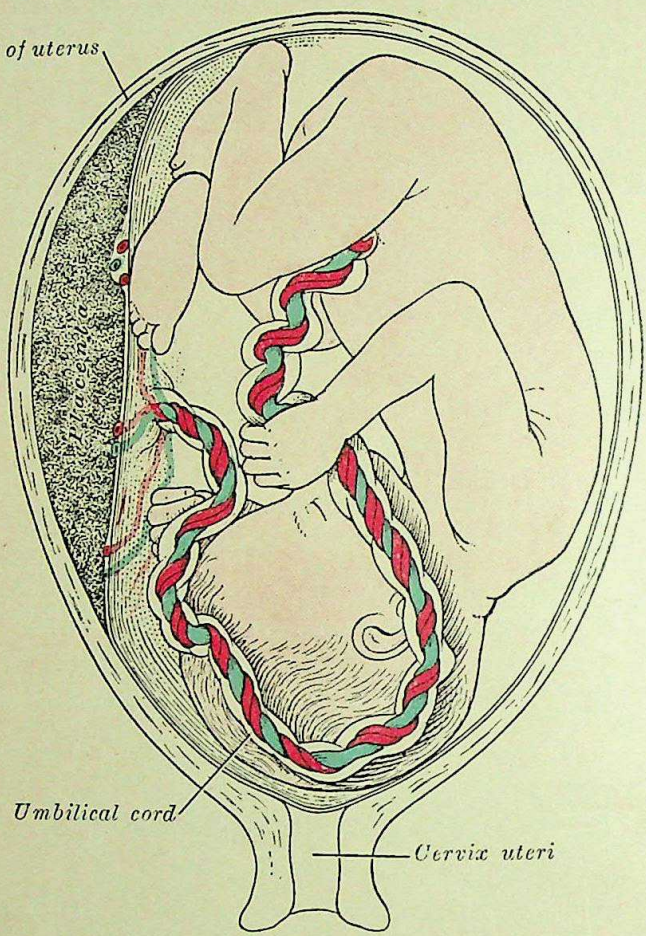

consists of an irregular channel named the *marginal sinus* (fig. 102); this sin partly encircles the placenta and communicates peripherally with the uterine vei and centrally with the intervillous space; clusters of placental villi project into it.

The fœtal and maternal blood-currents do not intermingle, being separat from each other by the delicate walls of the villi. Nevertheless, the fœtal blo is able to absorb, through the walls of the villi, oxygen and nutritive materials fro the maternal blood, and give up to the latter its waste products. The blood, purified, is carried back to the fœtus by the umbilical veins. It will thus be se that the placenta not only establishes a mechanical connexion between the moth and the fœtus, but subserves for the latter the purposes of nutrition, respiratio and excretion. That the placenta possesses certain selective powers is evidenc by the fact that glucose is more plentiful in the maternal than in the fœtal blood it is interesting to note also that the proportion of iron, lime and potash in the fœt is increased during the last months of pregnancy. Further, there is evidenc that the maternal leucocytes may migrate into the fœtal blood, since leucocyt are much more numerous in the blood of the umbilical vein than in that of t umbilical arteries.

Applied Anatomy.—The placenta is usually attached near the fundus uteri, and its si corresponds with that at which the ovum is imbedded. It may, however, occupy a low

CC-0. In Public Domain. Gurukul Kangri Collection, Haridwar

Digitized by Arya Samaj Foundation Chennai and eGangotri

level, and in very rare cases occludes the internal orifice of the uterus, thus giving rise to the condition known as *placenta prævia*.

The *separation of the placenta*.—After the child is born, the placenta and membranes (the latter consisting of the amnion, the chorion læve and the superficial part of the decidua parietalis) are separated from the uterine wall and expelled as the *after-birth*. The separation takes place along the plane of the stratum spongiosum (fig. 102), and necessarily causes rupture of the uterine vessels. The orifices of the torn vessels are, however, closed by the firm contraction and retraction of the uterine muscular fibres, and thus *post-partum hæmorrhage* is prevented. After the separation of the placenta and membranes a thin layer of the stratum spongiosum is left as a lining to the uterus, but this layer subsequently undergoes degeneration, and is cast off. The mucous membrane, the glands and the epithelial lining of the uterus are regenerated from the limiting or boundary layer of the decidua (p. 63).

The expelled placenta is a discoid mass which has a weight of about 500 gm., a diameter of from 15 cm. to 20 cm., and an average thickness of about 3 cm., but

Fig. 102.—A scheme of the placental circulation.

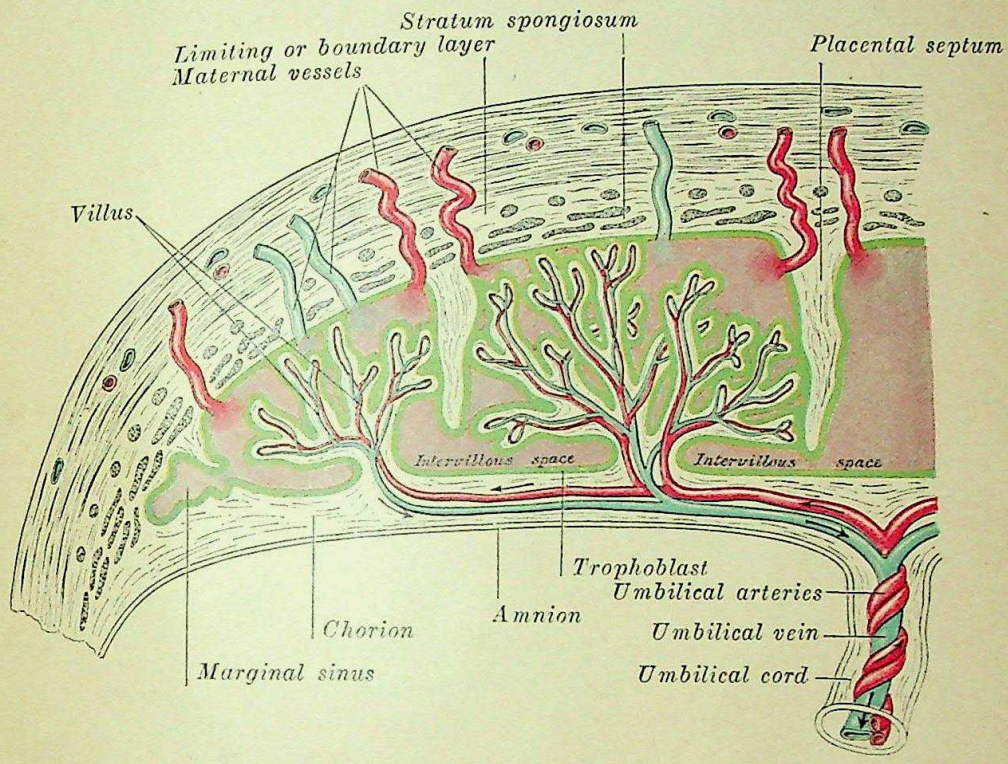

the thickness rapidly diminishes near the circumference of the placenta, which is continuous with the membranes. Its uterine or outer surface is divided by a series of fissures into lobules or *cotyledons* which are imperfectly separated from one another by the placental septa. Its fœtal or inner surface is smooth, and is closely invested by the amnion. When looked at through the amnion, the chorion presents a mottled appearance, consisting of grey, purple, or yellowish areas. The umbilical cord is usually attached near the centre of the placenta, but may be inserted at any point between the centre and the margin; in some cases it is inserted into the membranes, i.e. the *velamentous* insertion. From the site of the attachment of the cord the larger branches of the umbilical vessels radiate under the amnion, the veins being deeper and larger than the arteries. The remains of the vitelline duct and yolk-sac may be sometimes observed beneath the amnion, close to the cord, the former as an attenuated thread, the latter as a minute sac.

On section, the placenta presents a soft, spongy appearance, caused by the greatly branched villi; these are surrounded by a varying amount of maternal blood which gives the dark red colour to the placenta.

The further growth of the embryo will be best understood from a description of the principal facts relating to the development of the chief systems of which the body consists.

CC-0. In Public Domain. Gurukul Kangri Collection, Haridwar

Digitized by Arya Samaj Foundation Chennai and eGangotri

THE DEVELOPMENT OF THE PARIETES

The **skeleton** is of mesodermal origin, and may be divided into (1) th axial skeleton, viz. that of the vertebral column, skull, ribs, and sternu and (2) the appendicular skeleton, viz. that of the limbs.

The **vertebral column.**—The notochord (fig. 82) is a temporary structure a forms a central axis, around which the segments of the vertebral column a developed.* The notochord is derived from the cephalic end of the primiti streak, and, when fully formed, consists of a rod of cells, which lies on the vent aspect of the neural tube and reaches from the anterior end of the mid-brain the extremity of the tail. On either side of it is a column of paraxial mesode which becomes subdivid into a number of more less cubical segments, t *primitive segments* (figs. 8 83). These are separat from one another by *inte segmental septa* and a arranged symmetrically either side of the neura tube and notochord: t each primitive segment spinal nerve is distribute At first each segment co tains a central cavity, th *myocœl*, but this is soo filled with a core of angul and spindle-shaped cell The cells of each segme are differentiated into thr groups, which form respe tively the cutis-plate dermatome, the muscl plate or myotome, and th sclerotome (fig. 103). Th *cutis-plate* is placed on th lateral and dorsal aspec of the myocœl, and fro it the true skin of th corresponding segment derived; the *muscle-plat* is situated on the medi side of the cutis-plate, an furnishes the muscles the segment. The cells of the *sclerotome*, largely derived from those formin the core which fills the myocœl, lie next the notochord. Fusion of the individu sclerotomes in an anteroposterior direction soon takes place, and thus a co tinuous strand of cells, the *scleratogenous layer*, is formed along the ventr lateral aspect of the neural tube. The cells of this layer proliferate rapidly, an extending medialwards surround the notochord; at the same time they gro backwards on the lateral aspects of the neural tube and eventually surround and thus the notochord and neural tube are enveloped by a continuous shea of mesoderm (fig. 105, A), which is termed the *membranous vertebral column.* this mesoderm the original sclerotomes are still distinguishable, but each is no differentiated into two portions, an anterior, consisting of loosely arranged cells, an a posterior, of more condensed tissue (fig. 104, A and B). Between the two portio the rudiment of the intervertebral fibrocartilage is laid down (fig. 104, C). Cel from the posterior mass grow into the intervals between the myotomes (fig. 104, and C) of the corresponding and succeeding segments, and extend both dorsall

FIG. 103.—A transverse section of a human embryo of the third week, to show the differentiation of the primitive segment. (Kollmann.)

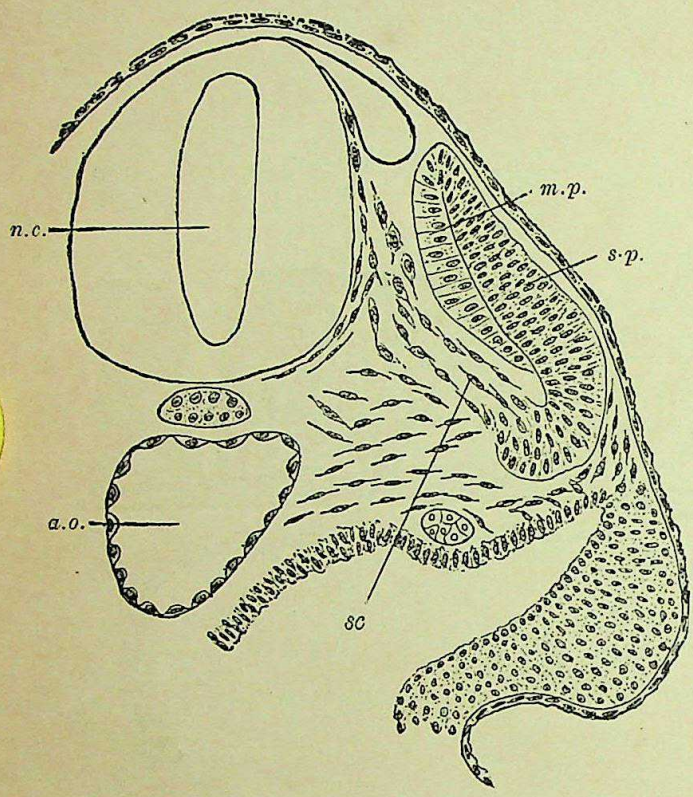

a.o, aorta; *m.p.*, muscle-plate; *n.c.*, neural canal; *sc.*, sclerotome; *s.p.*, cutis-plate.

* In *Amphioxus* the notochord persists and is the only representative of a skeleton in th animal.

CC-0. In Public Domain. Gurukul Kangri Collection, Haridwar

Digitized by Arya Samaj Foundation Chennai and eGangotri

and ventrally; the dorsal extensions surround the neural tube and represent the future vertebral arch, while the ventral extend into the body-wall as the costal processes. The hinder part of the posterior mass joins the anterior mass of the succeeding sclerotome to form the vertebral body. Each vertebral body is therefore

FIG. 104.—A scheme showing the manner in which each vertebral body is developed from portions of two adjacent segments.

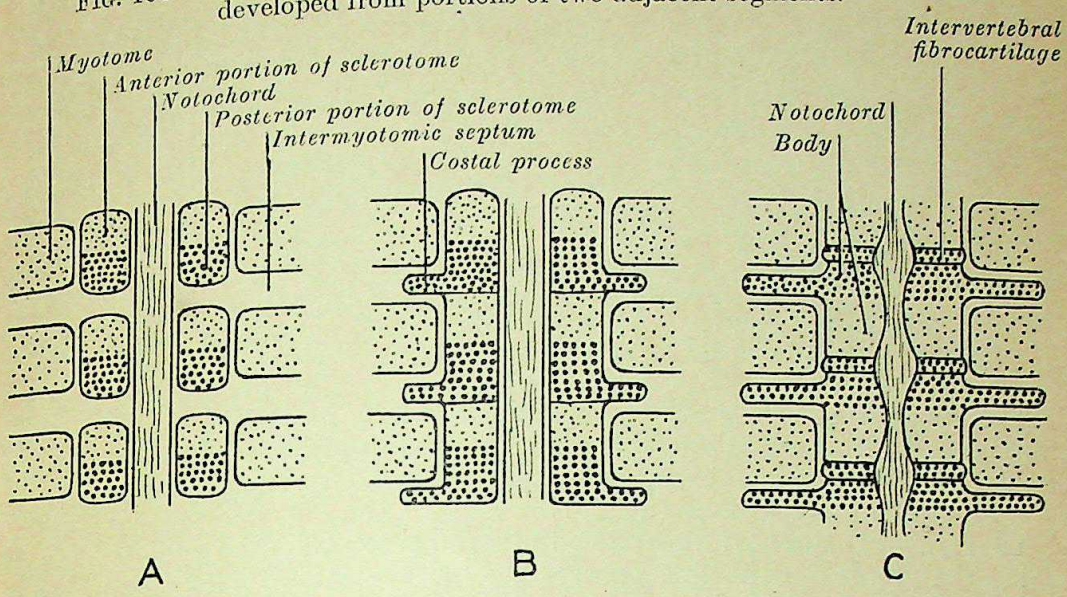

a composite of two segments, being formed from the posterior portion of one and the anterior part of that immediately behind it. The vertebral and costal arches are derivatives of the posterior part of the segment in front of the intersegmental septum with which they are associated.

This stage is succeeded by that of the *cartilaginous vertebral column*. In the fourth week cartilaginous centres make their appearance on either side of the notochord; these extend round the notochord and form the bodies of the cartilaginous vertebræ. A pair of cartilaginous foci appear in the lateral parts of each vertebral arch, and grow backwards on either side of the neural tube to form the cartilaginous vertebral arch, and a separate cartilaginous centre appears for each costal process. In the eighth week the cartilaginous vertebral arch fuses with the

FIG. 105.—Diagrams showing (A) the membranous and (B) the cartilaginous stages of a typical vertebra.

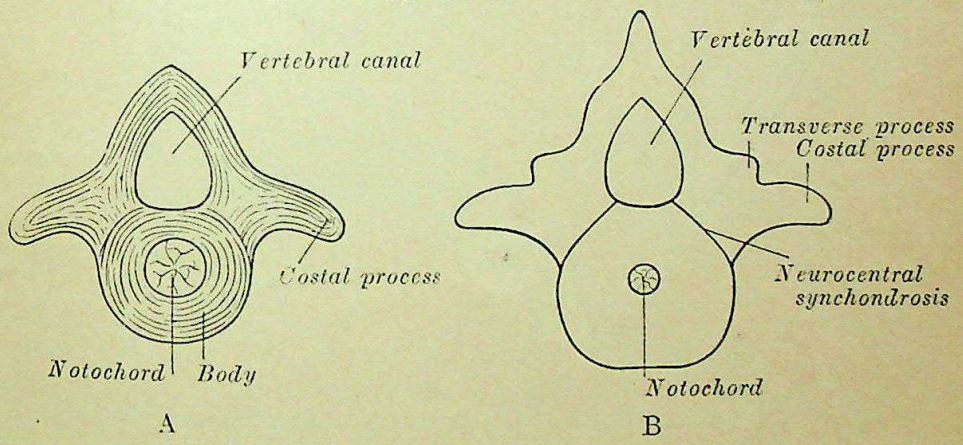

cartilaginous body, and in the fourth month the halves of the arch unite on the dorsal aspect of the neural tube (fig. 105, B); the spinous process is developed from the junction of the halves of the vertebral arch. The transverse processes grow out from the vertebral arch behind the costal processes.

In the upper cervical vertebræ a band of mesodermal tissue, named the *hypochordal bar* (fig. 106, A), connects the ventral ends of each vertebral arch across the ventral surface of the intervertebral fibrocartilage. In all except the atlas or first cervical vertebra this bar is transitory and fuses with the intervertebral fibro-

CC-0. In Public Domain. Gurukul Kangri Collection, Haridwar

Digitized by Arya Samaj Foundation Chennai and eGangotri

cartilage. In the atlas it persists, undergoes chondrification, and develops into th anterior arch of this bone, while the cartilage representing the body of the atla forms the dens or odontoid process which fuses with the body of the epistrophe or second cervical vertebra (fig. 106, B).

Fig. 106.—Diagrams showing the transformation of the hypochordal bar into the anterior arch of the atlas.

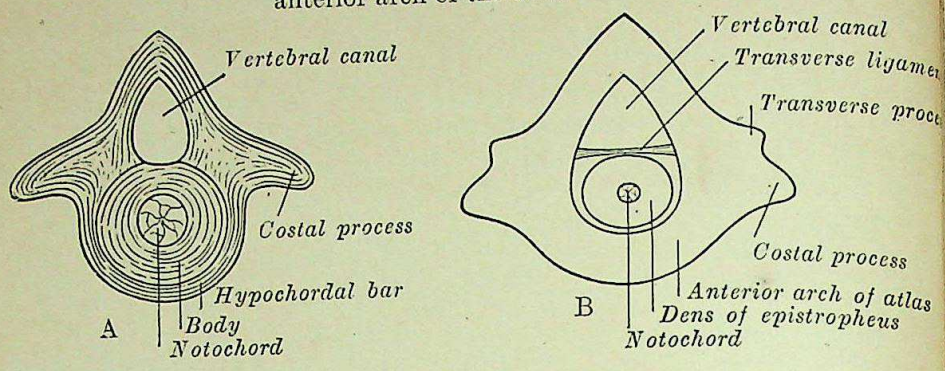

The portions of the notochord contained within the bodies of the vertebr atrophy, and ultimately disappear, while the portions in the centres of the inter vertebral fibrocartilages expand, and persist throughout life as the central *nucleu pulposus* of each fibrocartilage (fig. 107).

The **ribs.**—The ribs are formed from the costal processes of the primitive vertebr arches, the processes extending between the muscle-plates. In the *thoracic regi* of the vertebral column the costal processes grow lateralwards to form a seri of arches, the *primitive costal arches.* The transverse process grows out behi the vertebral end of the costal process, and is at first connected to this proce by mesoderm which is later differentiated to form the costotransverse ligament between the costal process and the tip of the transverse process the costotransver

Fig. 107.—A sagittal section through an intervertebral fibrocartilage and the adjacent parts of two vertebræ of the embryo of a sheep. (Kölliker.)

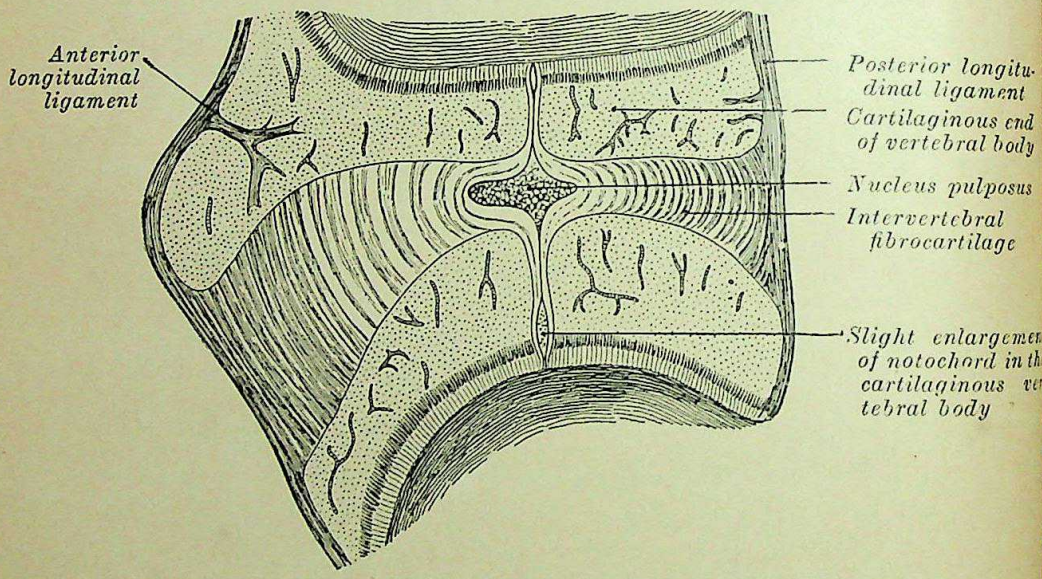

joint is formed by absorption, while the proximal end of the costal process becom separated from the vertebral arch by the development of the costocentral joi In the *cervical vertebræ* (fig. 108) the transverse process forms the posterior bounda of the foramen transversarium, while the costal process, corresponding to the he and neck of the rib, remains in continuity with the body of the vertebra, and for the anterolateral boundary of this foramen. The distal portions of the primiti costal arches remain undeveloped; occasionally, however, the costal processes of t seventh cervical vertebra undergo greater development, and by the formation costovertebral joints are separated off as cervical ribs. In the *lumbar region* the dist portions of the primitive costal arches fail; the proximal portions fuse with t

CC-0. In Public Domain. Gurukul Kangri Collection, Haridwar

Digitized by Arya Samaj Foundation Chennai and eGangotri

transverse processes to form the transverse processes of descriptive anatomy. Occasionally a pair of movable ribs is developed in connexion with the first lumbar vertebra. In the *sacral region* costal processes are developed only in connexion with the upper three or four vertebræ; the processes of adjacent segments fuse with one another to form the lateral parts of the sacrum. The *coccygeal vertebræ* are devoid of costal processes.

FIG. 108.—Diagrams showing the portions of the adult vertebræ derived respectively from the bodies, vertebral arches, and costal processes of the embryonic vertebræ.

The bodies of the vertebræ are represented in yellow, the vertebral arches in red, and the costal processes in blue.

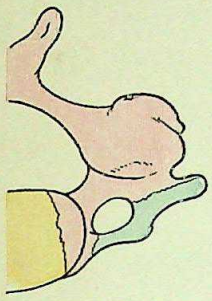

CERVICAL

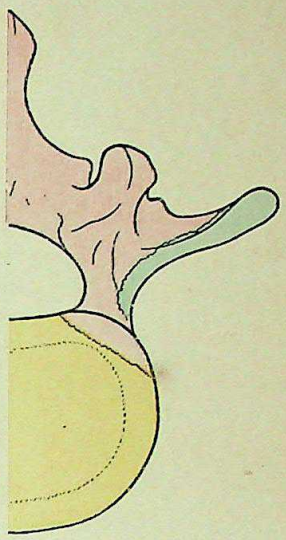

LUMBAR

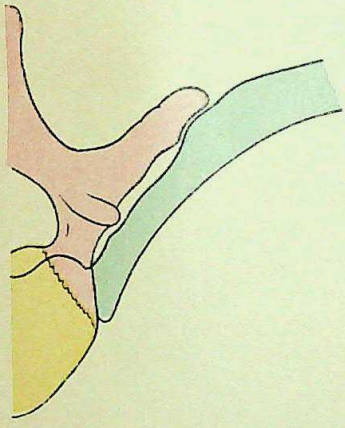

THORACIC

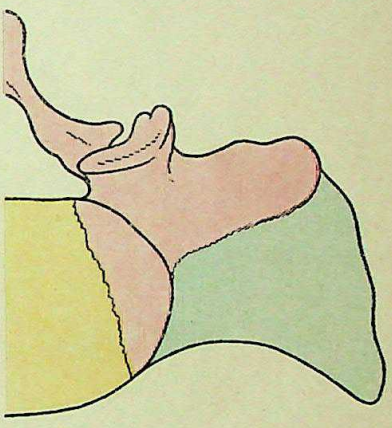

SACRAL

The **sternum.**—The ventral ends of the ribs become united to one another by a longitudinal bar termed the *sternal plate*, and opposite the first seven pairs of ribs these sternal plates fuse in the middle line to form the manubrium and body of the sternum. The xiphoid process is formed by a backward extension of the sternal plates.

The **skull.**—The bones of the cranium are developed from the mesoderm which invests the cerebral vesicles. At the end of the first and beginning of the second month of fœtal life this mesoderm increases in thickness and forms masses of blastema. These masses represent the earliest distinguishable elements of the skeleton of the head, and first become evident in the occipital region where they form a plate, the so-called *occipital plate*; in the middle of this plate the notochord runs sagitally. The occipital plate sends out on either side two processes which surround the hypoglossal nerve and form the hypoglossal canal.

The occipital plate is continued forwards as a thin blastemal layer on the dorsal aspect of the pharynx, and reaches the rudiment of the hypophysis. At the beginning of the second month it surrounds the duct of the hypophysis and extends between the nasal fossæ where it forms the basis of the ethmoidal bone and the nasal septum.

CC-0. In Public Domain. Gurukul Kangri Collection, Haridwar

Digitized by Arya Samaj Foundation Chennai and eGangotri

About the fifth week the two auditory vesicles become enclosed in blaste capsules, each of which is soon differentiated into a dorsolateral part envelo the semicircular canals, and a ven medial part surrounding the cochl at the upper boundary between th two parts the facial nerve lies i deep groove. The blastemal audit capsules fuse with the lateral proce of the occipital plate, leaving, h ever, a wide gap between each cap and the more median part of occipital plate; through this gap internal jugular vein, and the glos pharyngeal, vagus and accessory c bral nerves are transmitted.

FIG. 109.—A sagittal section through the cephalic end of the notochord. (Keibel.)

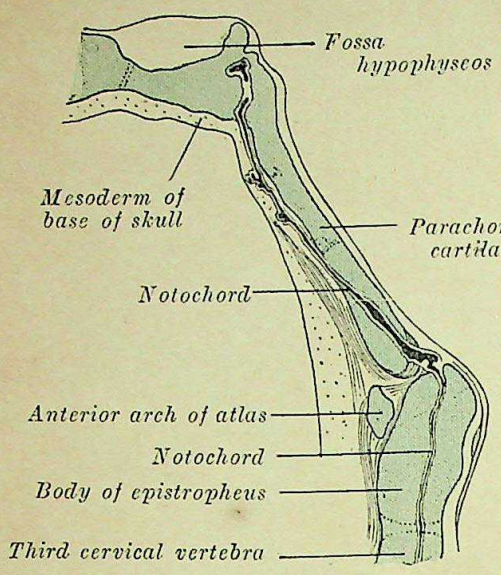

At this stage the blastema which s rounds the hypophysial duct and fo the rudiment of the post-sphenoi part of the body of the sphenoi bone, sends out a wing-like proc on either side, the future great wi (ala magna). More anteriorly, fro the central blastema which is form the interorbitonasal septu processes extend laterally and indic the sites of the small wings (a parvæ) of the sphenoidal bone, while condensations occur on either side of the na fossæ and blend above with the blastemal septum.

The first indications of the vault of the skull are seen about the thirtieth d and consist of blastemal plates which appear at the sides of the head and gradua extend into the upper wall where they blend with one another; they also ble with the blastema at the base of the cranium.

In the shark and dogfish this blastemal cranium undergoes complete chondrifi tion and forms the cartilaginous skull or chondrocranium of these animals. mammals the process of chondrification is limited to the base of the skull, includi a region dorsal to the foramen magnum and the auditory capsules. Chondrificati takes place primarily in two regions: (*a*) the anterior or *prechordal* part is developed front of the notochord and shows no regular division into primitive segments; (*b*) posterior or *chordal* part of the base of the skull is developed from the blastema wh surrounds the notochord, and exhibits traces of four primitive segments separat from one another by the roots of the hypoglossal nerve. (In the spring squirrel the is definite evidence that five primitive segments enter into the posterior part, as the are four separate roots of the hypoglossal nerves, and four hypoglossal canals.)

In mammals chondrification takes place primarily in three regions; (*a*) posteri in relation to the notochord; (*b*) intermediate, in relation to the hypophysis; a (*c*) anterior, between the orbital cavities and the nasal cavities. These parts may named *chordal*, *hypophysial*, and *interorbitonasal*; perhaps the last is identical with t trabeculæ cranii of the majority of vertebrates lower than mammals. It is uncert what the hypophysial part represents; when ossified it forms the postsphenoid.

* In man chondrification of the skull (figs. 110, 111, 112, 113) begins in the seco month of fœtal life, even before the blastemal stage is completed, and the first nu appear in the occipital plate, one on either side of the notochord, medial to hypoglossal canal. About the thirty-sixth day these two nuclei fuse anteriorly the dorsal surface of the notochord, and later they fuse posteriorly on its vent surface. Thus the notochord lies dorsal to the caudal part of the cartilagin occipital plate, then traverses the plate and lies ventral to it, and finally passes front of it and ends on the dorsal surface of the post-sphenoidal cartilage (fig. 10

The posterior part of the sphenoidal cartilage chondrifies from two centres, on either side of the developing hypophysis; these unite first behind and then front of the duct of the hypophysis, and in this way the craniopharyngeal can

* The following description is mainly based on the researches of Professor E. Fawcett. T reader is referred for further details to the *Journal of Anatomy and Physiology*, volumes xlv. and lii., and to the *Proceedings of the Anatomical Society of Great Britain and Ireland*, 1916.

CC-0. In Public Domain. Gurukul Kangri Collection, Haridwar

Digitized by Arya Samaj Foundation Chennai and eGangotri

through which the hypophysial diverticulum ascends into the skull, is formed; this canal is usually obliterated at the third month, but may remain open.

The central blastema in front of the hypophysis undergoes independent chondrification; it speedily joins with the posterior end of the chondrifying interorbitonasal septum, and from these are subsequently developed the presphenoidal part of the sphenoidal bone and the bony (ethmoidal) part of the nasal septum. All the above-mentioned parts ultimately fuse and form a continuous cartilaginous stem from the anterior edge of the foramen magnum to the anterior end of the nose.

The blastemal auditory capsule next undergoes chondrification, the portion surrounding the semicircular canals (canalicular portion) chondrifying before that enveloping the cochlea. A plate of cartilage (parietal plate) is connected to the

FIG. 110.—The chondocranium of a human embryo of a crown-rump length of 27 mm. Superior aspect. (From a model prepared by Prof. Edward Fawcett and Gwladys Ruth Llewelyn, B.Sc.)

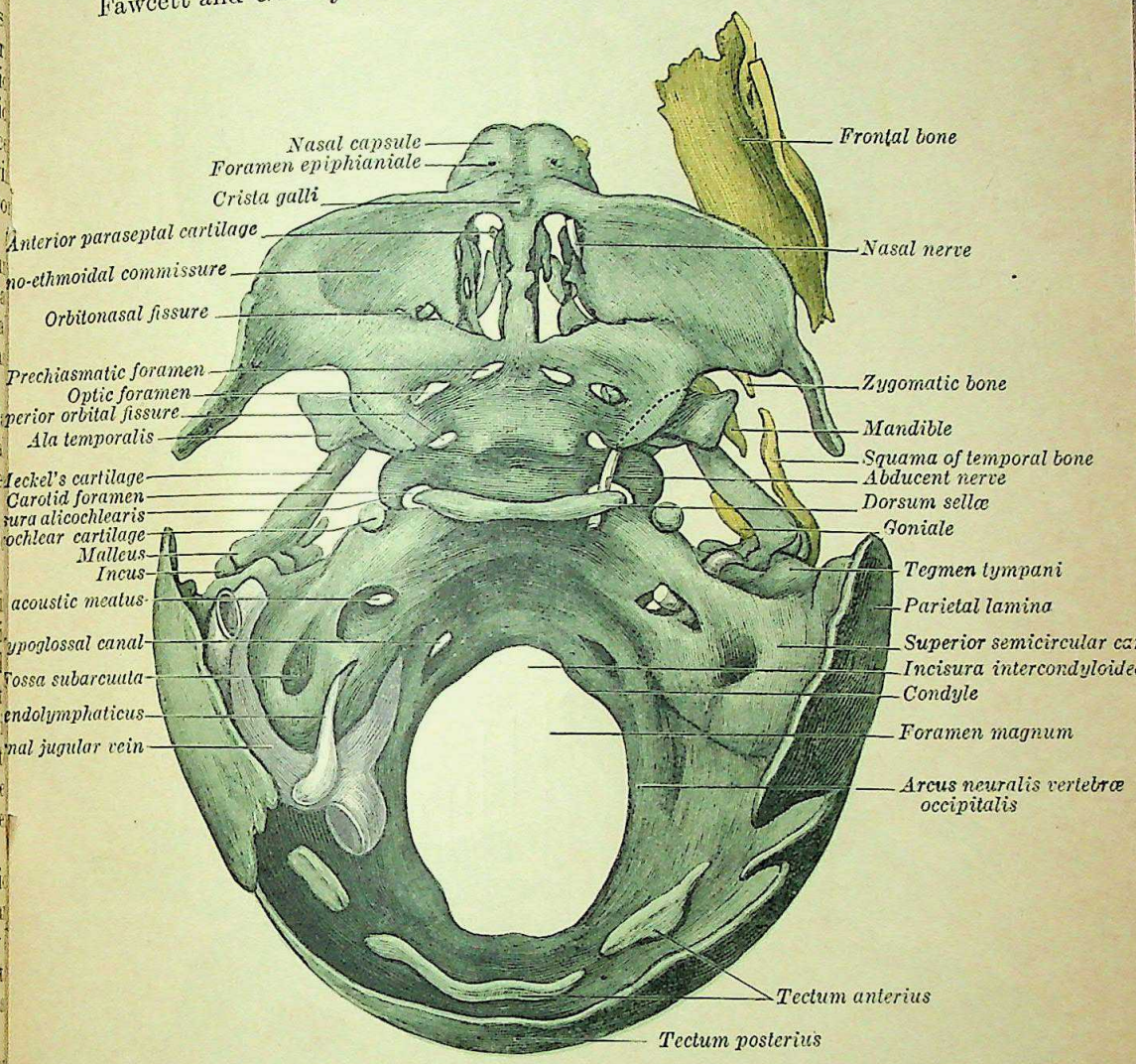

top of the canalicular part of each auditory capsule by means of a cartilaginous commissure. At the third month this plate forms a considerable part of the side-wall of the cranium, and is separated by only a small interval from the hinder end of the small wing of the sphenoidal bone. The distance between the two rapidly increases as age advances owing to the disappearance of the cartilage.

It is highly probable that the roof of the cranium in its typical human condition is formed by three tecta, which may be called the *tectum posterius*, *tectum intermedium*, and *tectum anterius*. The tectum posterius is broadest from above downwards, and when ossified forms the supra-occipital segment of the occipital bone. The tectum intermedium is very narrow and lies immediately in front of the tectum posterius; it soon disappears, and may not even form. The tectum anterius which stretches between the two parietal plates is a compound structure consisting of two lateral pieces, one on each side, and a median unpaired segment.

CC-0. In Public Domain. Gurukul Kangri Collection, Haridwar

Digitized by Arya Samaj Foundation Chennai and eGangotri

FIG. 111.—The chondrocranium shown in fig. 110. Inferior aspect.

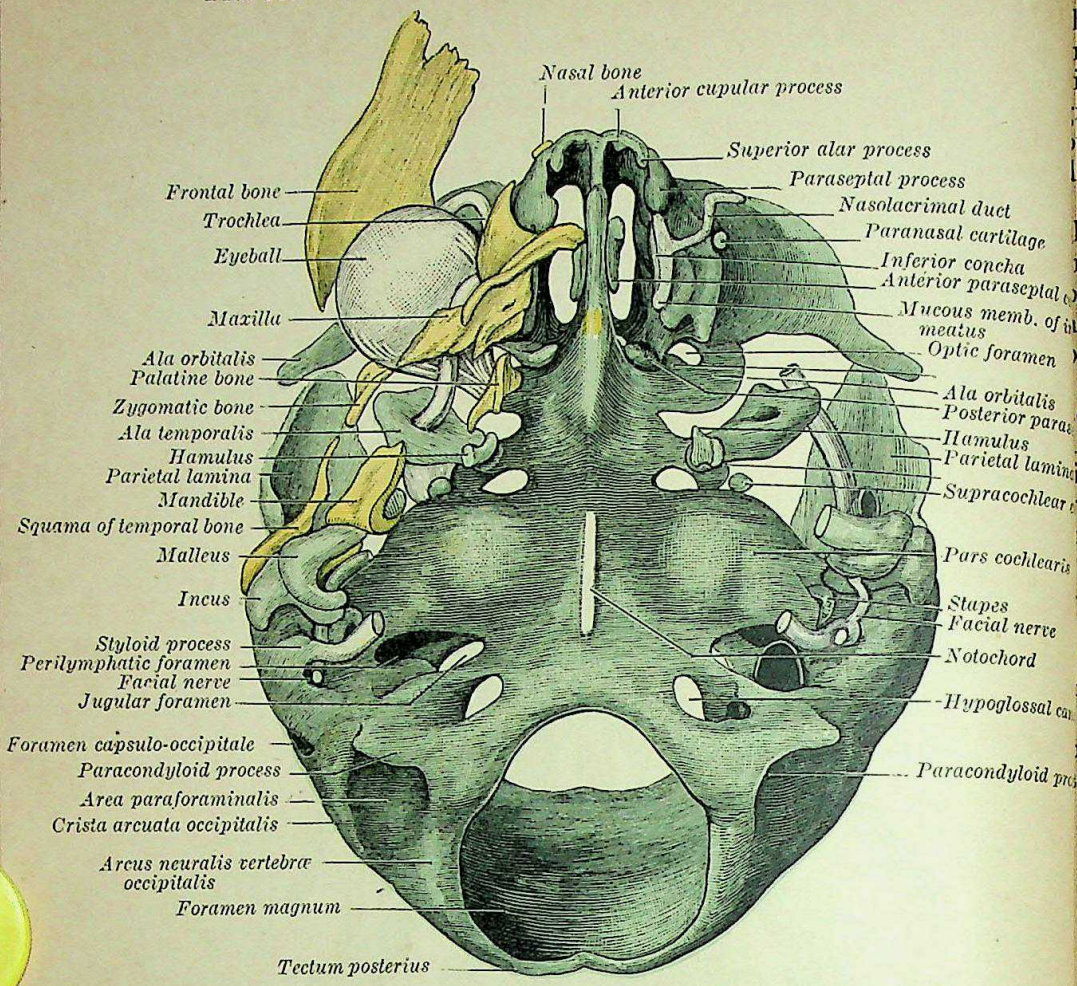

FIG. 112.—The chondrocranium shown in fig. 110. Lateral aspect.

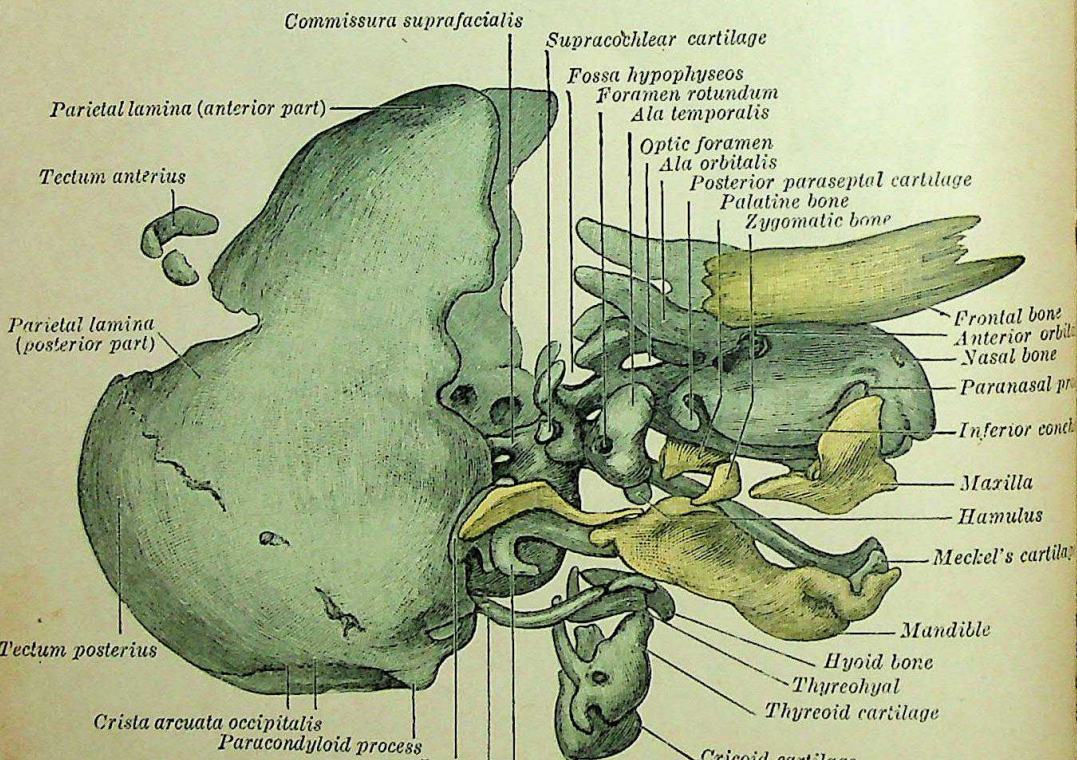

The great wings of the sphenoidal bone have separate cartilaginous nuclei these fuse with the post-sphenoidal cartilage which with two nuclei which conne

CC-0. In Public Domain. Gurukul Kangri Collection, Haridwar

Digitized by Arya Samaj Foundation Chennai and eGangotri

he post-sphenoidal cartilage and the corresponding great wing with the anterior nd of the cochlear capsule, lateral to the carotid artery. These nuclei form, on ither side, the alar process which later ossifies as the lingula. The cartilaginous reat wing is smaller than the small wing and only gives rise to the root of the terygoid process and to that part of the bone which surrounds the maxillary livision of the trigeminal nerve.

Between the great wing and the auditory capsule is a wide space which lodges he semilunar (Gasserian) ganglion and transmits the mandibular division of the rigeminal nerve and the middle meningeal artery. The backward growth of the alar rocess cuts off this space from the carotid canal, and at a later date the mandibular erve and middle meningeal artery are surrounded by membrane bone. The space etween the great and small wings forms the superior orbital (sphenoidal) fissure.

Chondrification of the small wing begins lateral to the optic nerve, and from this entre ingrowths extend in front of and behind the optic nerve and fuse with the inder part of the interorbitonasal septum and so form the optic foramen. Ossification of the small wing begins just lateral to the optic foramen, but does not extend ery far out; a considerable part of the cartilage disappears, and owing to this, the mall wing, in the bony condition, is much smaller than the great wing.

The *nasal capsule* is situated in front of the small wings, and is well developed y the third month; it consists of a central part, or septum, and two lateral parts.

The septum lies partly under the brain (subcerebral) and partly in front of the rain (precerebral); its lower margin is almost horizontal and is, for a time, free; s anterior border intervenes between the anterior nares (fenestræ narinæ).

The lateral parts of the capsule are primarily suspended from the precerebral part of the septum; later they are connected with the subcerebral part of the eptum by the lamina cribrosa of the ethmoidal bone. Each lateral part consists

FIG. 113.—The nasal capsule of a human embryo 65 mm. long. Ventral aspect. On the left side the floor of the capsule has been removed. (From a model by Professor Edward Fawcett.)

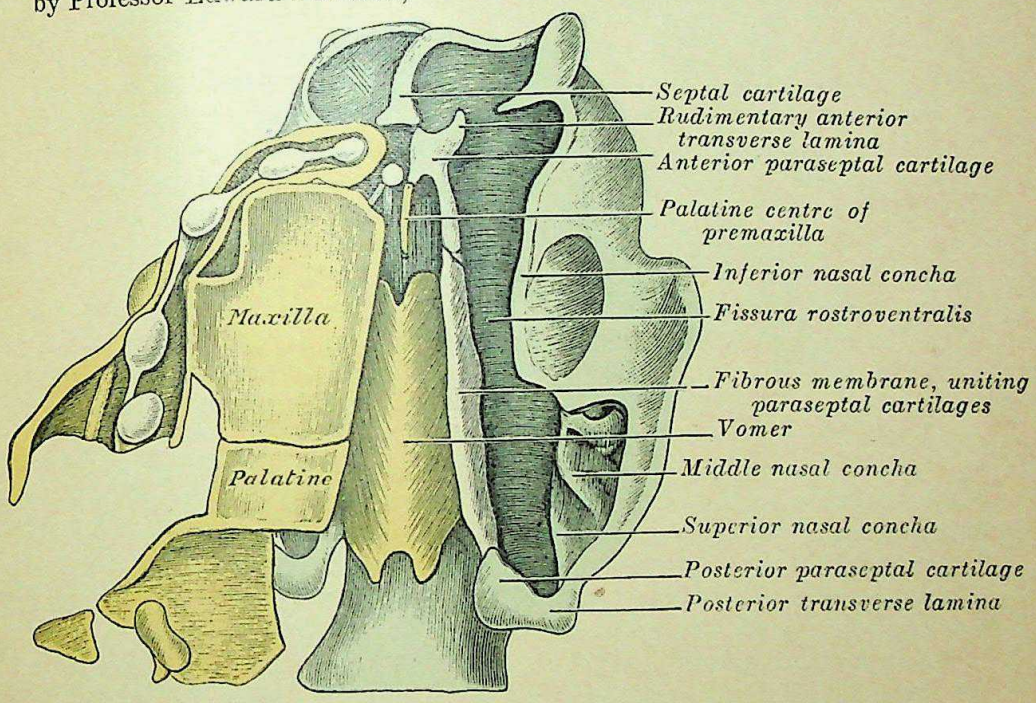

of an anterior, an intermediate and a posterior portion. The anterior and intermediate portions are separated externally by an anterolateral sulcus which corresponds internally with a semilunar crest; the lower end of this crest forms the uncinate process of the ethmoidal bone. The posterior and intermediate portions are separated by a faint postero-lateral sulcus which corresponds internally with the middle nasal concha. The lower edge of the lateral wall of the capsule is incurved to form the inferior nasal concha which, at the fifth month, becomes ossified and detached from the lateral wall of the capsule.

In man the floor of the cartilaginous nasal capsule is far from complete (fig. 113). In rodents and some marsupials it consists of an anterior and a posterior transverse

CC-0. In Public Domain. Gurukul Kangri Collection, Haridwar

Digitized by Arya Samaj Foundation Chennai and eGangotri

lamina connecting the lateral wall of the capsule with the septum; in front of anterior lamina is the fenestra narina. The anterior and posterior transverse lam are connected by a bar of cartilage which runs backwards alongside the sept and forms the *common paraseptal cartilage*; the anterior part of this cartilag bilaminar, and between the laminæ the organ of Jacobson is lodged; the poste part is small and cylindrical.

In man the greater part of the anterior transverse lamina is absent and thus fenestra narina is continuous with the fenestra basalis, the two forming the fiss rostroventralis. Further, only the anterior and posterior segments of the com paraseptal cartilage are developed in man; these parts are termed the anterior posterior paraseptal cartilages and are united to one another by fibrous membran

Part of the cartilaginous capsule is ossified to form the ethmoidal bone and inferior nasal conchæ, part remains cartilaginous as the septal and alar cartila of the nose, and part is replaced by membrane bones.

The ventral surface of the chondrocranium is indirectly connected with cartilages of the visceral arches, the fate of which is described below.

The bones of the vault of the skull are of membranous formation, and are term *dermal or covering bones*. They comprise the frontal and parietal bones, the up part of the squama occipita (interparietal bone), and squamæ and tympanic parts the temporal bones. During th course of growth cartilage a pears in the articular tuber (eminentia articularis) of temporal bone. Some of dermal or covering bones rem distinct throughout life (e parietal and frontal), while oth join with the bones of the ch drocranium (e.g. interparietal a squamæ of temporals).

FIG. 114.—A human embryo between eighteen and twenty-one days. Left lateral aspect. (His.)

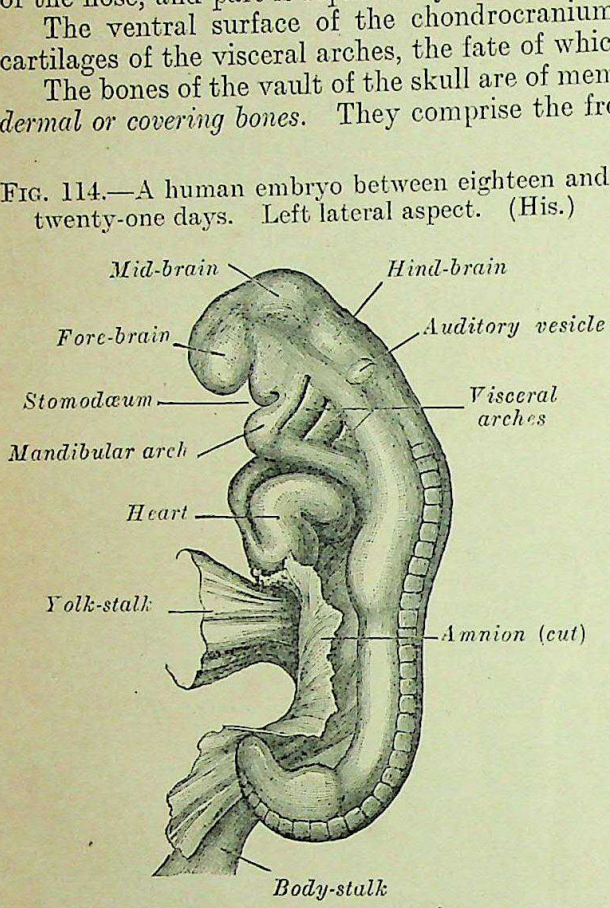

The **branchial or visceral arch and pharyngeal pouches.**—In t lateral walls of the anterior p of the fore-gut five *pharyng pouches* appear (figs. 115, 11 each of the upper four pouches prolonged into a dorsal and ventral diverticulum. Over the pouches corresponding indent tions of the ectoderm occ forming what are known as t *branchial or outer pharyng grooves*. The mesoderm which intervenes between the pouches and the grooves pressed aside for a time, and the ectoderm unites with the entoderm of the fore-g along the floors of the grooves to form thin *closing membranes* between the fore-g and the exterior; the mesoderm again penetrates between the entoderm and t ectoderm of these closing membranes. In gill-bearing animals the closing me branes disappear, and the grooves become the gill-clefts. Perforation does n occur in birds or mammals.

The branchial grooves separate a series of rounded bars or arches, the *branch or visceral arches* in which thickening and consolidation of the mesoderm take pla (figs. 114 to 116). The dorsal ends of these arches are attached to the sides of t head, while the ventral ends ultimately meet in the middle line of the neck. all, six arches make their appearance, but of these only the first four are visi externally. The first arch is termed the mandibular, and the second the hyoi the others have no distinctive names. In each arch the central part of the mesode consolidates and is then converted into a cartilaginous bar, consisting of right a left halves. Moreover, each arch is traversed by a nerve and by one of the primiti aortic arches.

The *mandibular arch* lies between the stomodæum or primitive mouth and t first branchial groove; from it are developed the lower lip, the mandible, the musc

CC-0. In Public Domain. Gurukul Kangri Collection, Haridwar

Digitized by Arya Samaj Foundation Chennai and eGangotri

of mastication, and the anterior part of the tongue. Its cartilaginous bar is formed by what are known as *Meckel's cartilages* (right and left) (fig. 117). The dorsal end of each cartilage is ossified to form two of the three bones of the middle ear, viz. the malleus and incus; the ventral ends of the two cartilages meet in the region of the symphysis menti, and become ossified and incorporated with that part of the mandible which lies below and inside the medial and lateral incisors (Low). The portion immediately below the malleus and incus is replaced by fibrous membrane which constitutes the sphenomandibular ligament, while the mandible is ossified in the connective tissue covering the remainder of the cartilage. From the dorsal ends of the mandibular arch a triangular process, the *maxillary process*, grows forwards on either side and forms the lower eyelid, the cheek, the lateral part of the upper lip, the zygomatic bone, and the greater part of the maxilla.

FIG. 115.—The head-end of a human embryo, about the end of the fourth week. Left lateral aspect. (From a model by Peter.)

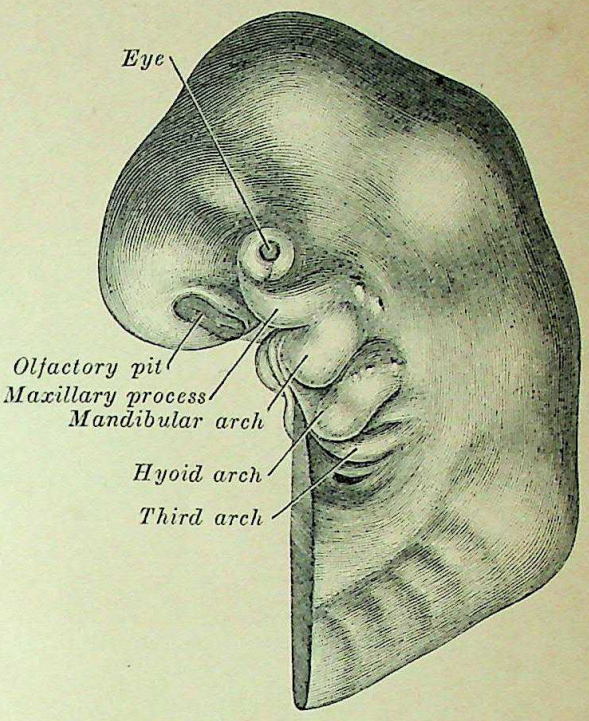

The second or *hyoid arch* assists in forming the side and front of the neck. From the dorsal end of its cartilaginous bar the third bone of the middle ear, viz. the stapes, is developed, and subsequently becomes attached to the auditory capsule. From the ventral part of the arch the styloid process, stylohyoid ligament, and lesser cornu of the hyoid bone are developed; the glossopalatine arch indicates the position of the hyoid arch. The cartilage of the *third arch* gives origin to the greater cornu of the hyoid bone, and the ventral ends of the second and third arches unite with those of the opposite side, and form a transverse band, from which the body of the hyoid bone and the posterior part of the tongue are developed. From the cartilage of the *fourth arch* the thyreoid cartilage is developed; from the cartilages of the *fifth arch* the cricoid cartilage is formed (Fawcett).*

FIG. 116.—The floor of the pharynx of the embryo shown in fig. 115.

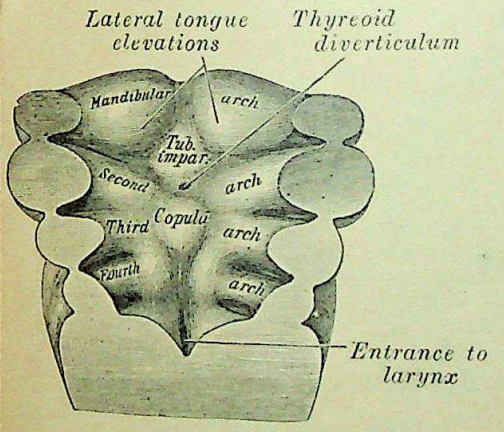

The mandibular and hyoid arches grow more rapidly than those behind them, with the result that the third and fourth arches recede from the surface and form the floor of a deep depression, the *sinus cervicalis*. The hyoid arch grows backwards and overlaps the sinus, the opening from which assumes the form of a narrow duct; this duct closes and converts the sinus into a vesicle which disappears before the end of the second month.

From the first branchial groove the concha of the auricula and the external acoustic meatus are developed, while around the groove there appear, on the mandibular and hyoid arches, several swellings from which the auricula or pinna is formed (p. 108). From the upper or dorsal parts of the first and second pharyngeal pouches the auditory tube and the tympanic cavity are developed (p. 107); the closing membrane between the mandibular and hyoid arches is invaded by mesoderm, and forms the tympanic membrane. No traces of the

* Professor Edward Fawcett (*Proceedings of the Anatomical Society of Great Britain and Ireland*, 1916).

CC-0. In Public Domain. Gurukul Kangri Collection, Haridwar

Digitized by Arya Samaj Foundation Chennai and eGangotri

second, third, or fourth branchial grooves persist. The dorsal angle of the sec pharyngeal pouch is named the *sinus tonsillaris*; in it the tonsil is developed, above the tonsil a trace of the sinus persists as the supratonsillar fossa.

FIG. 117.—The head and neck of a human embryo, eighteen weeks old, with Meckel's cartilage and the hyoid bar exposed. (After Kölliker.)

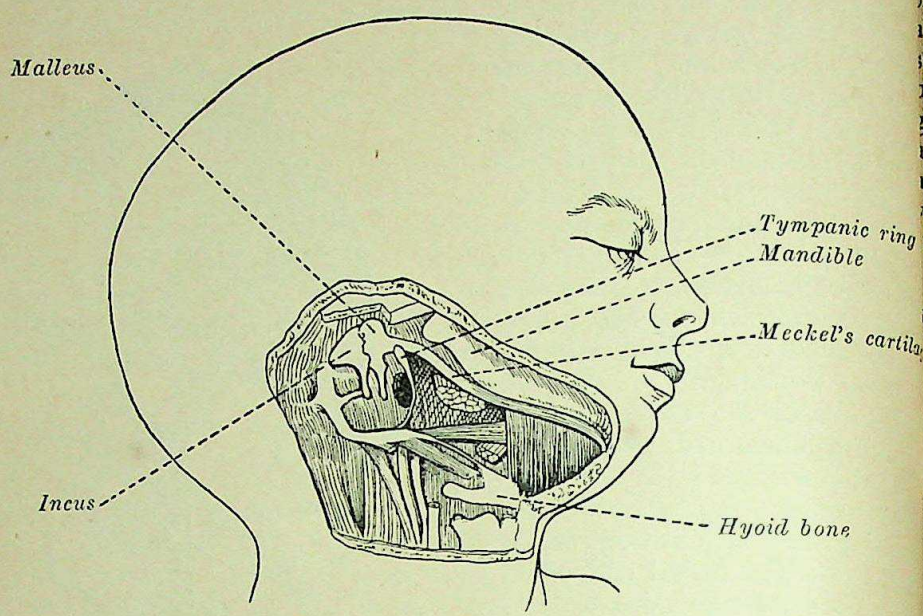

pharyngeal recess, or fossa of Rosenmüller, is by some regarded as a persistent par the second pharyngeal pouch, but it is probably developed as a secondary formati From the third pharyngeal pouch the thymus arises as an entodermal diverticul on either side, and from the fourth pouches small diverticula project and beco incorporated with the thymus, but in man they probably never form true thym tissue. The parathyreoids arise as diverticula from the third and fourth pouch From the fifth pouches the ultimobranchial bodies originate and are enveloped the lateral prolongations of the median thyreoid rudiment; they do not, howev form true thyreoid tissue, nor are any traces of them found in the human adult.

FIG. 118.—The head of a human embryo about twenty-nine days old. Ventral aspect. (From a model by His.)

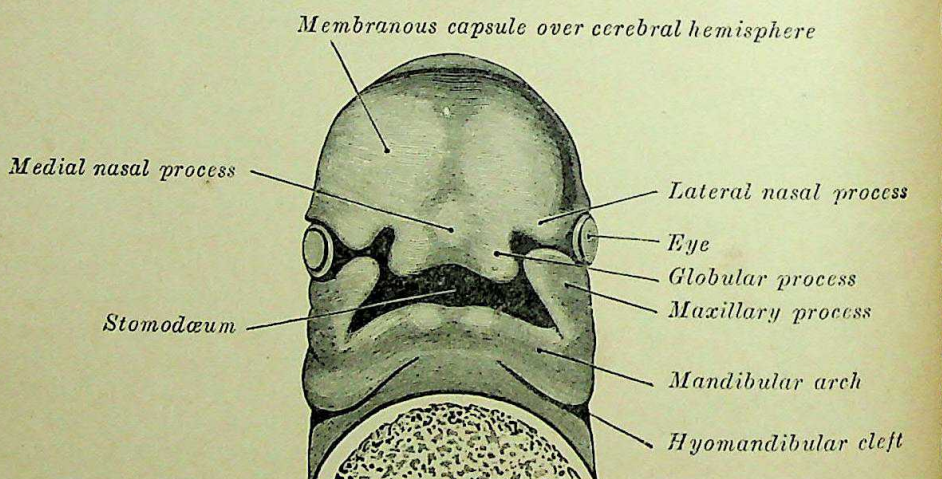

The **nose and face.**—During the fourth week two areas of thickened ectoderm, *olfactory plates*, appear immediately under the fore-brain in the anterior wall of stomodæum, one on either side of a region termed the *frontonasal process*. the upgrowth of the surrounding parts these areas are converted into the *olfact*

CC-0. In Public Domain. Gurukul Kangri Collection, Haridwar

Digitized by Arya Samaj Foundation Chennai and eGangotri

pits, which indent the frontonasal process and divide it into a *medial* and two *lateral nasal processes* (figs. 118, 119). The rounded lateral angles of the medial process are named the *globular processes* (His). From the ectodermal lining of the olfactory pits the epithelium of the nasal cavities is derived. The mesodermal plates which are represented on the surface by the globular processes are termed the *nasal laminæ*; these laminæ are at first some distance apart, but, gradually approaching, they ultimately fuse and form the nasal septum; the processes themselves meet in the middle line, and form the premaxillæ and the central part of the upper lip (fig. 122). The depressed part of the medial nasal process between the globular processes forms the lower part of the nasal septum or *columella*; while above this is seen a prominent angle, which becomes the future apex (figs. 118, 120), and still higher a flat area, the future bridge of the nose. The vomeronasal cartilage, which supports the rudimentary organ of Jacobson and is found in the nasal septum, just above the nasopalatine recess, is derived from the anterior part of the common

FIG. 119.—The head-end of a human embryo about thirty or thirty-one days old. Ventral aspect. (From a model by K. Peter.)

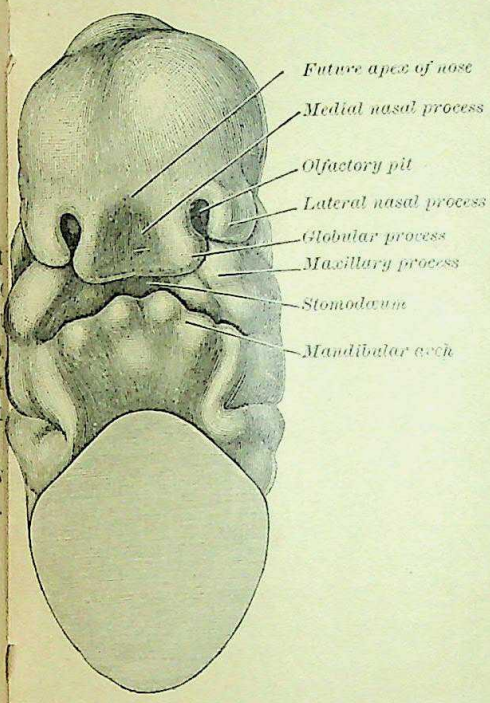

FIG. 120.—The same embryo as is shown in fig. 119, with the front wall of the pharynx removed.

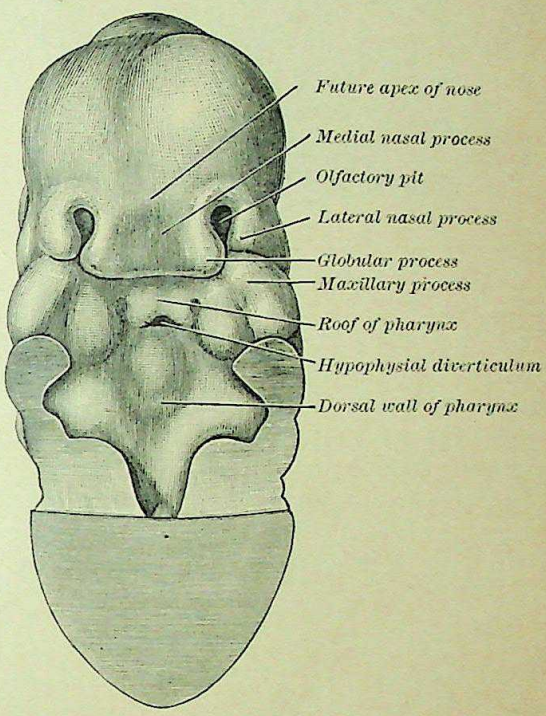

paraseptal cartilage (p. 76). The lateral nasal process forms the ala of the nose, and from the cartilage of this process the lamina cribrosa and labyrinth of the ethmoidal bone, the inferior nasal concha, the lesser alar cartilages, and the crus laterale of the greater alar cartilage are developed. The lacrimal and nasal bones, and the frontal process of the maxilla are ossified in the membrane covering the cartilage of the lateral nasal process. The maxillary process is separated for a time from the lateral nasal process by a groove, the *naso-optic furrow*, which extends from the furrow encircling the eyeball to the olfactory pit. The maxillary processes ultimately fuse with the lateral nasal and globular processes, and form the lateral parts of the upper lip and the posterior boundaries of the nares (figs. 121, 122). From the third to the fifth month the nares are filled by masses of epithelium, on the breaking down and disappearance of which the permanent openings are produced. By the fusion of the maxillary processes with the nasal and globular processes in the roof of the stomodæum the *primitive palate* (fig. 123) is formed, and the olfactory pits extend backwards above it. The posterior end of each pit is closed by an epithelial membrane, the *bucconasal membrane*, formed by the apposition of the nasal and stomodæal epithelium. About the fifth week the bucconasal membranes rupture and the *primitive choanæ* or openings between the olfactory pits and the stomodæum are established. The floor of the nasal cavity is completed by the development of a pair

CC-0. In Public Domain. Gurukul Kangri Collection, Haridwar

Digitized by Arya Samaj Foundation Chennai and eGangotri

of shelf-like *palatine processes* which appear about the sixth week and extend medi-wards from the maxillary processes (figs. 124, 125); the palatine processes coal-with each other and with the nasal septum in the middle line, and constitute the en-hard palate, except a small portion in front which is formed by the premaxillæ.

Fig. 121.—The face of a human embryo of about eight weeks, in which the nose and mouth are formed. (From a model by His.)

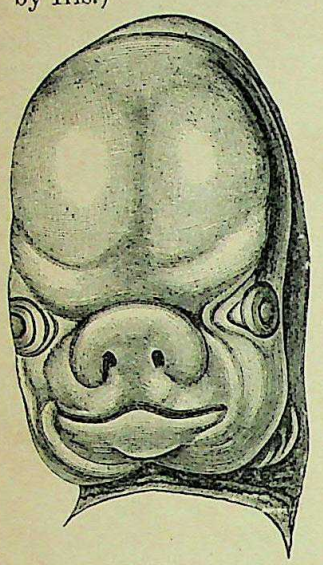

Fig. 122.—A diagram showing the parts of the a-face and neck which are related to the fronton-and maxillary processes and the branchial arches.

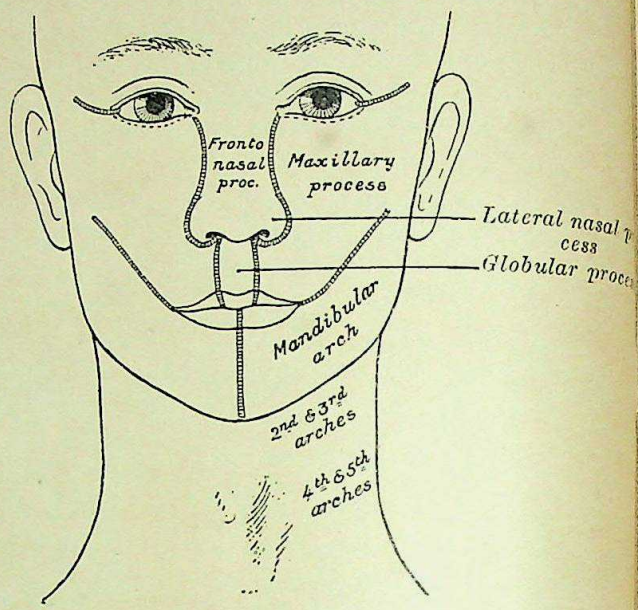

soft palate is formed by two secondary backward growths, one on either side, fr-the palatine processes; into these the palatine muscles extend, and the two p-ultimately join to form the soft palate and uvula. Two apertures persist fo-time between the palatine processes and the premaxillæ, and represent the perman-channels which in the lower animals connect the nose and mouth. The union-the parts which form the palate commences in front, the premaxillary and palat-processes joining in the eighth week of fœtal life, while the region of the fu-hard palate is completed by the ninth week, and that of the soft palate by-

Fig. 123.—The primitive palate of a human embryo about thirty-seven or thirty-eight days old. (From a model by K. Peter.)

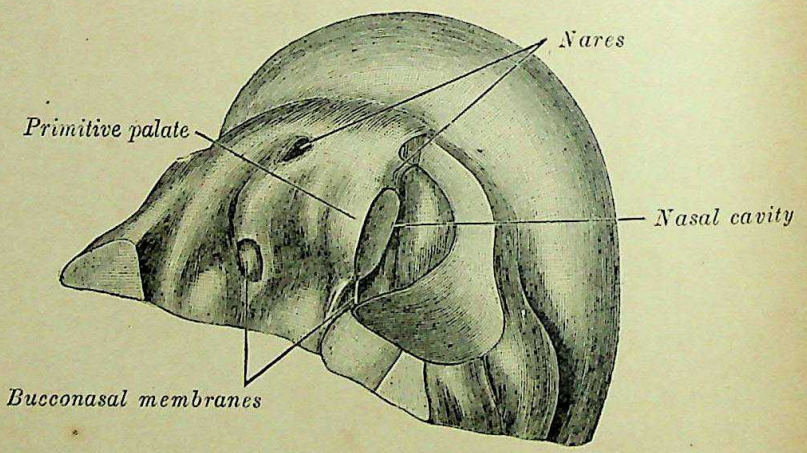

On the left side the lateral wall of the nasal cavity has been removed.

eleventh week. By the completion of the palate the *permanent choanæ* are form-and are situated a considerable distance behind the primitive choanæ. The n-cavity is divided by a cartilaginous septum, the anterior part of which persists as-septal cartilage of the nose, but the posterior and upper parts are replaced by-

CC-0. In Public Domain. Gurukul Kangri Collection, Haridwar

Digitized by Arya Samaj Foundation Chennai and eGangotri

omer and the lamina perpendicularis of the ethmoidal bone. On either side of he nasal septum, at its lower and anterior part, the ectoderm is invaginated to orm a diverticulum which extends backwards and upwards into the nasal septum nd is supported by a curved plate of cartilage. These diverticula form the

FIG. 124.—The roof of the mouth of a human embryo about two and a half months old, showing the mode of formation of the palate. (From a model by His.)

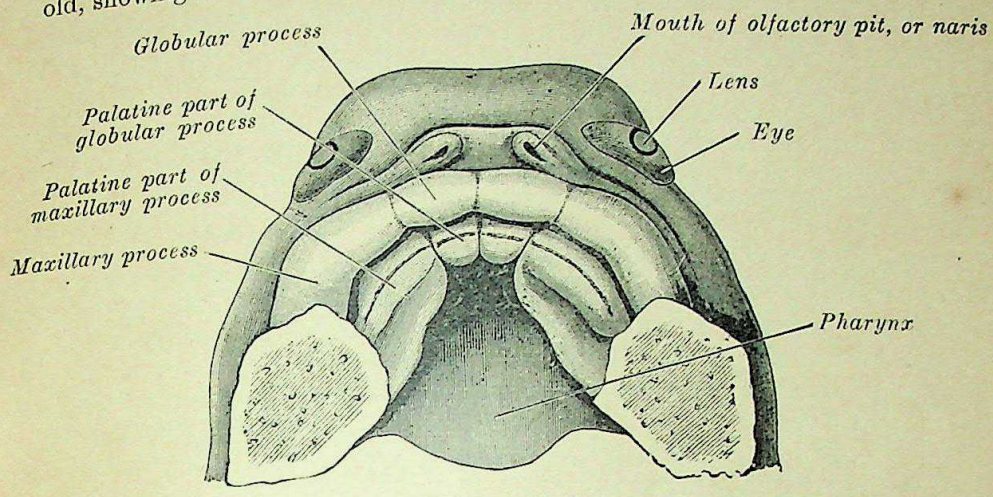

FIG. 125.—A frontal section through the nasal cavities of a human embryo 28 mm. long. (Kollmann.)

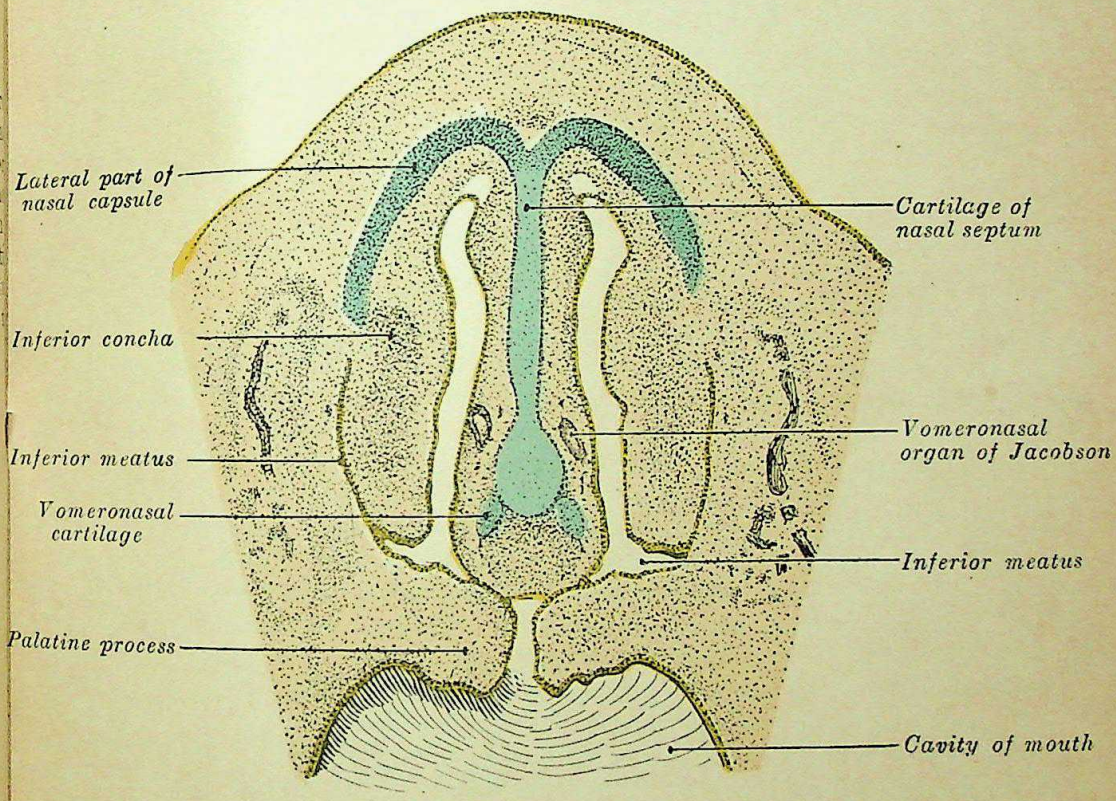

udiments of the *vomeronasal organs* of Jacobson, which open below, close to the unctions of the premaxillæ and maxillæ.*

* J. Ernest Frazer (Hunterian Lecture, *Lancet*, July 8, 1916) maintains that the increase in ize of the nasal cavities takes place in an upward and backward direction, and the septum is imply the part of the roof left undisturbed between the paired upgrowths. He also points ut that by the ninth week the primitive choanæ extend from the primitive palate to the top f the cavity of the mouth, and when the palatal folds meet they fuse with the lower two-hirds or three-fourths of the septum, while the upper one-fourth or so of the septum remains etween the upper parts of the openings which constitute the permanent choanæ.

CC-0. In Public Domain. Gurukul Kangri Collection, Haridwar

Digitized by Arya Samaj Foundation Chennai and eGangotri

Applied Anatomy.—Cleft palate is a common malformation. The cleft usually s posteriorly, and its most elementary form is a bifid uvula; or the cleft may extend thr the soft palate; or the posterior part of the hard palate may be involved as far forw as the incisive foramen. In the severest forms, the cleft passes between the inc bone or premaxilla and the rest of the maxilla, and extends through the alveolar pro between the lateral incisor and canine teeth. The palatine portion of the premaxilla con of a medial part corresponding to the medial incisor, and a lateral part to the lateral inc These two parts may fail to unite, and the cleft then runs between the central and la incisor teeth. The cleft may affect one or both sides; if the latter, the premaxilla frequently displaced forwards and remain united to the septum of the nose, the defici in the alveolus being complicated with a cleft in the lip (hare-lip). Where the alv is not implicated, the cleft is usually in the median line, but occasionally it is unila and in some cases bilateral. In those cases where the palatine processes fail to unite each other and with the nasal septum, the cleft of the palate is median; where one pala process unites with the nasal septum, the other failing to do so, the cleft in the pala unilateral. In some cases where the palatine processes fail to meet in the middle, the n septum may grow downwards between them and thus produce a bilateral cleft.

The **limbs.**—In the third week the limbs begin to make their appearance as s elevations or buds from a slight lateral ridge at either side of the trunk (fig. 1 Prolongations from several primitive segments extend into each bud, and ca with them the anterior divisions of the corresponding spinal nerves; the ner supplying the limbs indicate the number of primitive segments which contrib to their formation—the upper limb being derived from seven, viz. fourth cervi to second thoracic inclusive, and the lower limb from ten, viz. twelfth thoracic to fourth sacral inclusive. The axial part of the mesoderm of the limb-bud condenses and is converted into its cartilaginous skeleton, and by the ossification of this the bones of the limbs are formed. The limbs are at first directed backwards nearly parallel to the long axis of the trunk; by the sixth week their long axes are at right angles to that of the trunk, and the three chief divisions of each limb are marked off by furrows—arm, forearm, and hand in the upper limb; thigh, leg, and foot in the lower (fig. 127). The future *flexor* surface of the limb is directed ventrally; the *extensor* surface, dorsally; one border, the *pre-axial*, looks towards the cephalic end of the embryo, and the other, the *post-axial*, towards the caudal e The lateral epicondyle of the humerus, the radius, and the thumb lie along the p axial border of the upper limb; the medial epicondyle of the femur, the tibia, a the great toe along the corresponding border of the lower limb. The limbs n undergo a rotation or torsion through an angle of 90° around their long axes, rotation being effected almost entirely at the limb girdles. The rotation of upper limb is outwards and forwards; that of the lower limb is inwards and ba wards. As a consequence of this rotation the pre-axial (radial) border of the f limb is directed lateralwards, and the pre-axial (tibial) border of the hind-li medialwards; thus the flexor surface of the fore-limb is turned forwards, and t of the hind-limb backwards. The pre-axial part is derived from the ante primitive segments, the post-axial from the posterior primitive segments of limb-bud; and this explains, to a large extent, the innervation of the adult li the nerves of the more anterior segments being distributed along the pre-a (radial or tibial), and those of the more posterior segments along the post-a (ulnar or fibular) border of the limb.

Fig. 126.—A human embryo between thirty- and thirty-four days old. (His.)

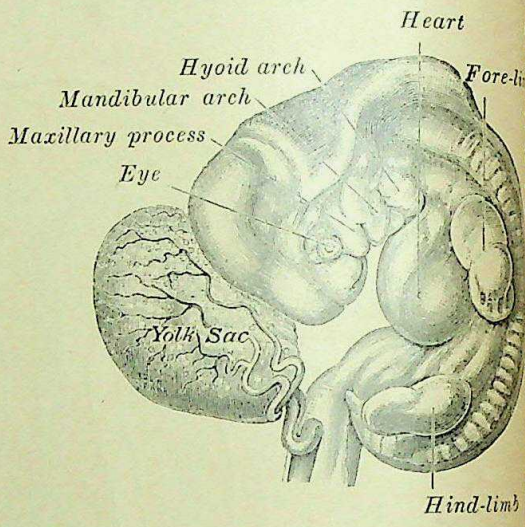

The **joints.**—The mesoderm from which the different parts of the skeleton formed at first shows no differentiation into masses corresponding with the in vidual bones; thus, continuous cores of mesoderm form the axes of the limb-bu

CC-0. In Public Domain. Gurukul Kangri Collection, Haridwar

Digitized by Arya Samaj Foundation Chennai and eGangotri

nd a continuous column of mesoderm the future vertebral column. The first ndications of the differentiation of the bones and joints are circumscribed conden- ations of the mesoderm; these condensed parts become chondrified and finally ssified to form the bones of the skeleton. The intervening non-condensed portions onsist at first of undifferentiated mesoderm, which may be converted into fibrous issue as in the case of the skull bones, a synarthrodial joint being the result; or it nay become partly cartilaginous, in which case an amphiarthrodial joint is formed; r it may become looser in texture, a cavity ultimately appearing in its midst, while he cells lining the sides of this avity form a synovial stratum, nd thus a diarthrodial joint s developed; in some diarth- odial joints portions of the mesoderm persist and form arti- ular discs.

The tissue surrounding the riginal mesodermal core forms ibrous sheaths for the developing ones (perichondrium and perios- eum) which are continued be- ween the ends of the bones ver the synovial strata as the ibrous capsules of the joints. These capsules are not of niform thickness, so that in hem may be recognised specially trengthened bands which are escribed as ligaments. This, owever, is not the only method f formation of ligaments. In ome cases by modification of, r derivations from, the tendons urrounding the joint, additional igamentous bands are provided o strengthen the articulations.

FIG. 127.—A human embryo about six weeks old. (His.)

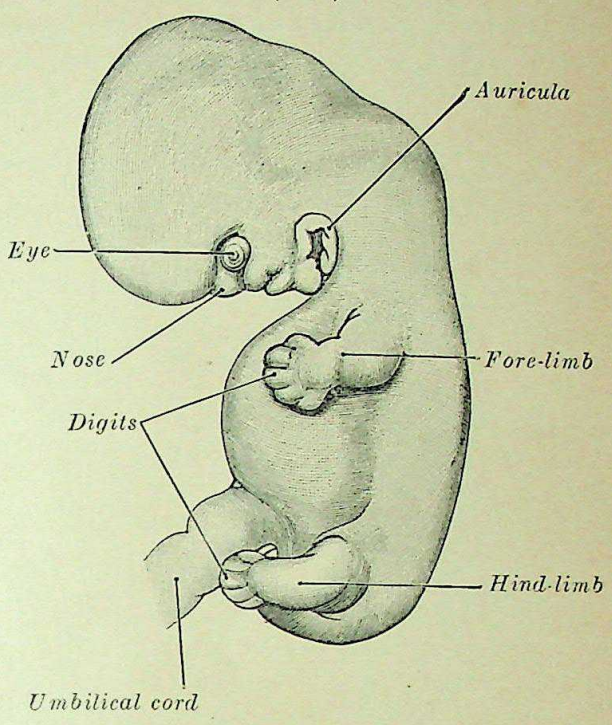

The **muscles.**—The voluntary muscles are developed from the myotomes of he primitive segments. Portions of the myotomes retain their position on the ides of the neural tube, where they may remain distinct from each other and form he short muscles of the vertebral column, or fuse with corresponding portions of eighbouring myotomes to form the Sacrospinales and their continuations. Other ortions of the myotomes extend into the trunk wall where again they may retain heir segmental condition, as in the Intercostales, or may fuse with adjacent egments to form the flat muscles of the abdominal wall. Finally, portions of the nyotomes wander into the limb-buds and there undergo fusions and alterations n form to produce the limb muscles. The original segmental character of the limb nuscles is therefore lost, but their segmental nerve supplies are retained. Some of he limb muscles expand and migrate secondarily towards the mid-dorsal line (e.g. rapezius and Latissimus dorsi) or towards the mid-ventral line (e.g. Pectoralis najor). Again, muscles may migrate in a cephalic direction (e.g. the facial muscles which are derived from the hyoid arch), or in a caudal direction (e.g. the Serratus nterior). In all cases they carry with them the segmental nerves of the myotomes rom which they are derived; one example of this will suffice, viz. the Serratus nterior, which is derived from the fifth, sixth, and seventh cervical segments as is ndicated by its nerves of supply. In man and the higher vertebrates many of the erivatives of the myotomes degenerate and are converted into aponeuroses (e.g. he galea aponeurotica, and the aponeuroses of the abdominal muscles) or ligaments e.g. the sacrotuberous ligament and the fibular collateral ligament of the knee).

The involuntary muscles are derived from the splanchnopleure mesoderm.

The **skin and its appendages.**—The epidermis, hairs, nails, sebaceous and udoriferous glands are developed from the ectoderm, the corium or true skin rom the mesoderm. The ectoderm at first consists of a single stratum of cells, ut by the fifth week two strata can be recognised, a superficial, named the *pitrichium*, consisting of flat nucleated cells readily, and a deep,

CC-0. In Public Domain. Gurukul Kangri Collection, Haridwar

Digitized by Arya Samaj Foundation Chennai and eGangotri

named the *stratum germinativum*, consisting at first of cubical, but later columnar, cells. By multiplication and differentiation of the cells of the stratum germinativum the different layers of the epidermis are developed. Towards the end of the third month the mesoderm condenses to form the corium, and at about the same time the subcutaneous areolar tissue is differentiated; in the fifth month the dermal papillæ begin to make their appearance. A considerable desquamation of the epidermis takes place; this desquamated epidermis, mixed with sebaceous secretion, constitutes the *vernix caseosa*, with which the skin is smeared during the last three months of fœtal life.

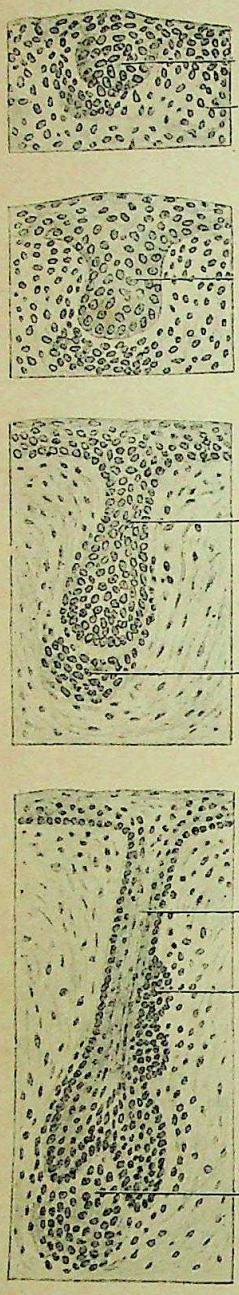

FIG. 128.—Successive stages in the development of a hair.

The *hairs* (fig. 128) originate as thickenings of the epidermis which grow obliquely downwards as solid buds into the corium, each bud consisting of an outer stratum of columnar cells and a core of polygonal cells. The deep end of each bud expands to form the hair-bulb, which is moulded over a papilla of condensed mesoderm. The cells of the hair-bulb proliferate and form a cone of cells, from which the scapus or shaft of the hair and its internal sheath are developed; the hairs gradually lengthen by growth at the hair-bulb, and ultimately project on the surface.

The *sebaceous glands* originate as lateral outgrowths from the sides of the hair-bulbs and, pushing their way into the mesoderm, divide into three or four oval or flask-shaped alveoli, the lining cells of which are derived from the stratum germinativum.

The rudiments of the *sudoriferous or sweat glands* make their appearance on the palms of the hands and soles of the feet in the fourth month, and closely resemble the rudiments of the hairs, each beginning as a solid downgrowth of the ectoderm. The ectodermal downgrowth lengthens, and its deeper part coils on itself and forms the body of the gland. A lumen is developed in the downgrowth about the seventh month of fœtal life, and opens on the surface by a duct which is lined with two layers of cells. In the secreting part of the gland the outer layer of cells is modified to form a stratum of smooth muscle-fibres which lies between the epithelium of the gland and the basement-membrane. Many sudoriferous glands arise as ectodermal downgrowths from the superficial portions of the hair-follicles, and later acquire independent openings on the surface of the skin.

The *mammary gland* may be looked upon as a collection of greatly modified sudoriferous glands; the epithelial lining of its ducts and alveoli is derived from the ectoderm, its supporting connective tissue from the mesoderm. On either side of the ventral surface of young embryos a thickened band of ectoderm, termed the *milk-ridge*, extends obliquely from the axilla to the inguinal region, and in some of the lower mammals mammæ are developed at intervals along this ridge. In man only one mamma, as a rule, is developed on either side of the middle line, but supernumerary glands or nipples are sometimes found above or below the fully developed gland.

The rudiment of the mamma appears as a thickening and subsequent downgrowth of the ectoderm; from this downgrowth fifteen or twenty solid cords branch off, each cord representing a future lactiferous tubule and lobe of the gland.

CC-0. In Public Domain. Gurukul Kangri Collection, Haridwar

Digitized by Arya Samaj Foundation Chennai and eGangotri

eep ends of the cords subdivide in the mesoderm and form the alveoli of the land. The region where the ectodermal thickening occurred is subsequently ised to form the nipple, and about the time of birth the tubules and alveoli ecome canalised. At the age of puberty, and in a greater degree towards the end f pregnancy, a marked enlargement of the gland, and a development of additional bules and alveoli, take place.*

The rudiments of the *nails* can be seen in embryos of about 4·5 cm. in length, nd appear as *primary nail-fields* of ectoderm on the dorsal surfaces of the terminal halanges of the digits. At the proximal end and sides of each nail-field the epiermis is invaginated to form the nail-folds, while the distal end, which will ltimately form the free end of the nail, is bounded by a shallow groove. The nail developed from the posterior nail-fold and consists of modified stratum lucidum. he stratum corneum covers the nail and forms the *eponychium*; this disappears om the surface of the nail, with the exception of a narrow fold which overlaps e proximal part of the lunule of the nail.

HE DEVELOPMENT OF THE NERVOUS SYSTEM AND SENSE-ORGANS

The nervous system is derived from the ectoderm and first appears as the neural oove on the dorsal aspect of the embryo (fig. 80). By the elevation and ultimate sion of the neural folds, the groove is converted into the neural tube (fig. 82). he anterior end of the tube expands to form the three primary brain-vesicles; e cavity of the tube is subsequently modified to form the ventricular cavities of he brain and the central canal of the medulla spinalis; from the wall the nervous lements and the neuroglia of the brain and medulla spinalis are developed.

The **medulla spinalis.**—At first the wall of the neural tube is composed of a ngle layer of columnar ectodermal cells. The lateral parts of the wall soon thicken, hile the dorsal and ventral parts remain thin, and are named the *roof-* and *floorlates* (figs. 129, 131). A transverse section of the tube at this stage presents an val outline and a slit-like lumen. The cells which constitute the wall of the tube roliferate rapidly, lose their cell-boundaries and form a syncytium consisting at rst of dense protoplasm with closely packed nuclei, but later opening out and orming a loose meshwork with the strands radiating from the central canal. hree layers of this syncytium may be defined—an internal or ependymal, an ntermediate or mantle, and an external or marginal (fig. 129). The *ependymal layer* ultimately converted into the ependyma of the central canal; the processes of s cells pass outwards towards the periphery of the medulla spinalis. The *marginal yer* is devoid of nuclei, and later forms the supporting framework for the white nniculi of the medulla spinalis. The *mantle layer* represents the future grey columns f the medulla spinalis; its cells are differentiated into two sets, viz. (*a*) *spongioasts* or young neuroglia-cells, and (*b*) *neuroblasts* or young nerve-cells (fig. 130). he spongioblasts are connected to another one by filaments of the syncytium; these, fibrils are developed, so that as the neuroglia cells become defined they khibit their characteristic mature appearance with multiple processes proceeding om each cell. The neuroblasts are large, round or oval, and first make their ppearance between the ependymal cells on the sides of the central canal. They ncrease rapidly in number, so that by the fourth week they form an almost conuous layer on either side of the central canal. No neuroblasts are found in he roof- or floor-plates; the roof-plate retains, in certain regions of the brain, its pithelial character; elsewhere, its cells become spongioblasts. The neuroblasts r young nerve-cells migrate from the sides of the central canal into the mantle yer, and at the same time become pear-shaped; the tapering part of the cell ndergoes still further elongation, and forms the axis-cylinder of the cell.

The lateral walls of the medulla spinalis increase in thickness, and the central nal widens out near its dorsal extremity, and assumes a somewhat lozenge-shaped ppearance. The widest part of the canal subdivides the lateral wall of the neural be into a *dorsal or alar*, and a *ventral or basal lamina* (fig. 131), a subdivision hich extends into the brain. The dorsal part of the canal is reduced to a mere t which is subsequently obliterated by the approximation and fusion of its walls; e ventral part persists as the central canal of the adult medulla spinalis. The

* Consult, 'The mammary apparatus of the Marsupialia,' by Ernst Bresslau. 1920.

CC-0. In Public Domain. Gurukul Kangri Collection, Haridwar

Digitized by Arya Samaj Foundation Chennai and eGangotri

caudal end of the canal exhibits a conical expansion which is known as the *terminal ventricle*.

The ventral part of the mantle layer increases in thickness, and on cross-section appears as a triangular patch between the marginal and ependymal layers. This thickening is the rudiment of the anterior column of grey substance, and contains many motor neuroblasts, the axis-cylinders of which pass out through the marginal layer and form the anterior roots of the spinal nerves (fig. 129). Dart and Shellshear * are of opinion that the motor neuroblasts originate in the myotomes, and migrate into the wall of the neural tube. The thickening of the mantle layer gradually extends in a dorsal direction, and forms the posterior column of grey substance. In the thoracic and upper lumbar regions a lateral or intermediate column of grey substance is differentiated. The axons of the cells of this column form the splanchnic efferent nerves; they emerge in the anterior nerve-roots, and pass through the white rami communicantes to the ganglia of the sympathetic

FIG. 129.—A transverse section through the medulla spinalis of a human embryo four weeks old. (His.)

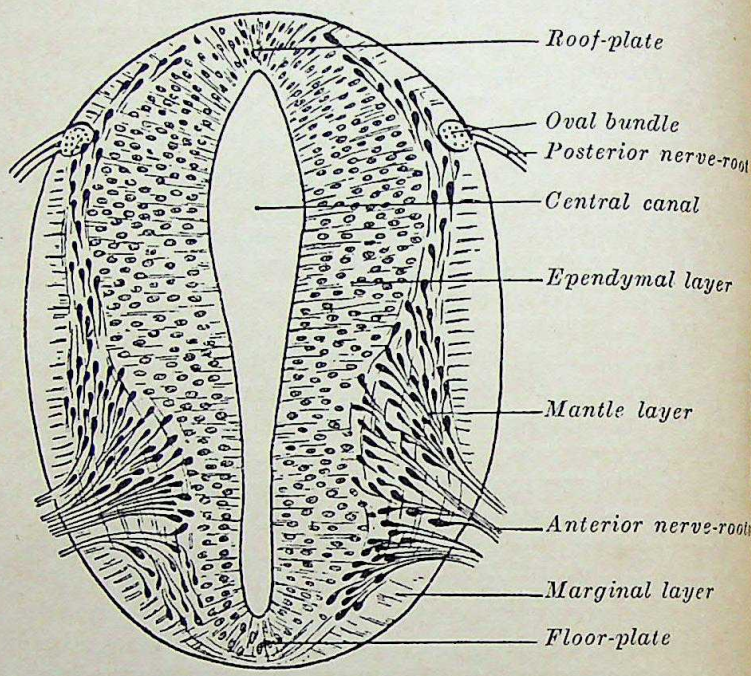

trunk. The axons of many of the neuroblasts in the alar lamina run forward, cross in the floor-plate to the opposite side of the medulla spinalis, and form the rudiment of the anterior white commissure.

About the end of the fourth week nerve-fibres appear in the marginal layer. The first to develop are the short intersegmental fibres from the neuroblasts in the mantle zone, and the fibres of the posterior roots of the spinal nerves which pass into the medulla spinalis from the cells of the spinal ganglia. By the sixth week the fibres of the posterior roots of the spinal nerves form a well-defined *oval bundle* in the peripheral part of the alar lamina; this bundle increases in size, and spreads towards the middle line forms the rudiment of the posterior funiculus. The long intersegmental fibres begin to appear about the third month, and the cerebrospinal fibres about the fifth month. All nerve-fibres are at first destitute of medullary sheaths, and different groups of fibres receive their sheaths at different times, e.g. the anterior and posterior nerve-roots are medullated about the fifth month, the cerebrospinal fibres after the ninth month.

By the growth of the anterior columns of grey substance, and by the increase in size of the anterior funiculi, an anterior furrow is formed between the lateral halves of the medulla spinalis; this gradually deepens to form the anterior median fissure (fig. 131, B). The mode of formation of the posterior septum is somewhat uncertain. It is probably produced by the growing together of the walls of the posterior part of the central canal and by the development from its ependyma

* Raymond A. Dart and Joseph L. Shellshear, *Journal of Anatomy*, vol. lvi. January 192

CC-0. In Public Domain. Gurukul Kangri Collection, Haridwar

Digitized by Arya Samaj Foundation Chennai and eGangotri

ells of a septum of fibrillated tissue which separates the future funiculi graciles. he cervical and lumbar enlargements appear simultaneously with the development f the limb-buds.

FIG. 130.—A transverse section through the medulla spinalis of a human embryo at the beginning of the fourth week. (After His.) The left edge of the figure corresponds to the lining of the central canal.

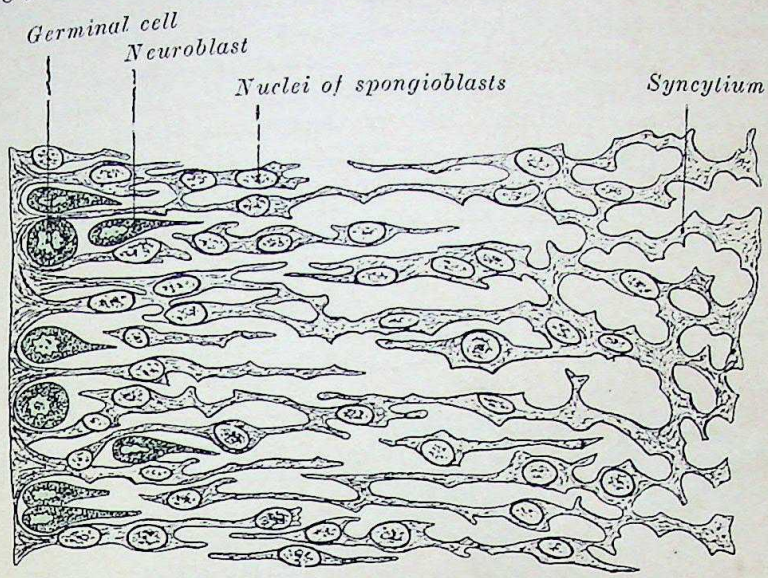

In early fœtal life the medulla spinalis occupies the entire length of the vertebral anal, and the spinal nerves pass outwards at right angles. When the embryo has ttained a length of 30 mm. the vertebral column begins to grow farther caudalvards than the medulla spinalis, and the latter gradually assumes a higher position within the vertebral canal, the principal part of this upward migration occurring luring the first half of fœtal life. By the twenty-fifth week of fœtal life the terminal entricle of the medulla spinalis (p. 86) has ascended from the level of the second

FIG. 131.—Transverse sections through the medullæ spinales of human embryos. A, about four and a half weeks old. B, about three months old. (His.)

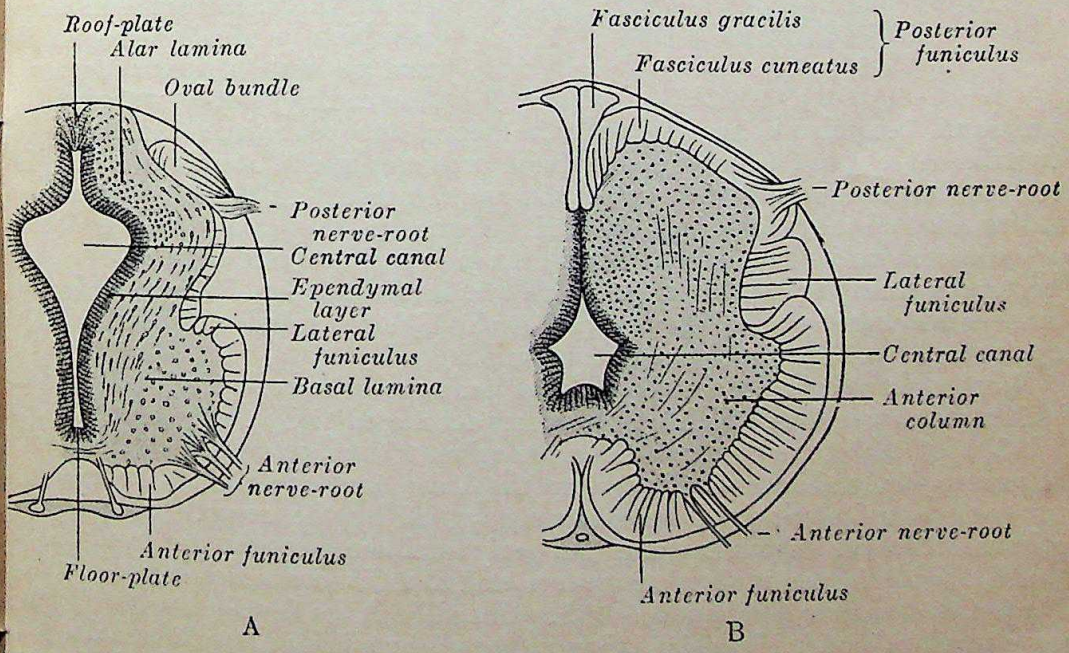

occygeal vertebra to that of the third lumbar vertebra, or a distance of nine gments, and there remain but two segments before the adult position is reached treeter *). A delicate filament, the *filum terminale*, extends from the lower end

* George L. Streeter, Contrib. to Embryol. No. 25, 1919.

CC-0.In Public Domain. Gurukul Kangri Collection, Haridwar

Digitized by Arya Samaj Foundation Chennai and eGangotri

of the medulla spinalis as far as the first piece of the coccyx, and represents part of the fœtal medulla spinalis which is caudal to the second coccygeal segm and has become converted into a fibrous strand. This strand, like the sacral n roots, elongates in adaptation to the ascending displacement of the medulla spi

The spinal nerves.—Each spinal nerve is attached to the medulla spinal an anterior and a posterior root.

The fibres of the anterior or motor roots are formed by the axons of the n blasts which lie in the ventral part of the mantle layer; these axons grow through the overlying marginal layer into the myotomes of the primitive segm and are ultimately aggregated to form the anterior nerve-roots (fig. 129).

The fibres of the posterior roots are developed from the cells of the spinal ga Before the neural groove is closed to form the neural tube a ridge of ectode cells, the *ganglion-ridge* or *neural crest* (fig. 132), appears along the prominent ma of each neural fold. When the folds meet in the middle line the two ganglion-ri fuse and form a wedge-shaped area along the line of closure of the tube. cells of this area proliferate rapidly opposite the primitive segments to form a s of oval-shaped masses which their connexions with the ne tube and then migrate for a sh distance in a lateral and ven direction. From the ventral p of each mass a small portion detached to form a sympath ganglion, while the remainde converted into a spinal gangl These spinal ganglia are arran symmetrically on the two side the neural tube and, except in region of the tail, are equal number to the primitive segme The cells of the ganglia, like cells of the mantle layer, are two kinds, viz. spongioblasts neuroblasts. The spongioblast velop into the neuroglial cells of ganglia. The neuroblasts, at round or oval in shape, soon ass the form of spindles the extrem of which gradually elongate central and peripheral proces The central processes grow med wards and, becoming connected with the neural tube, constitute the fibres of posterior nerve-roots, while the peripheral processes grow lateralwards to mi with the fibres of the anterior root in the spinal nerve. As development proc the original bipolar form of the cells changes; the two processes bec approximated until they ultimately arise from a single stem in a T-shaped man The bipolar form is retained in the retina and in the ganglia of the acoustic ne Some recent observers hold, however, that the T-form is derived from the bra ing of a single process which grows out from the cell.

Fig. 132. Two stages in the development of the neural crest in the human embryo. (Lenhossék.)

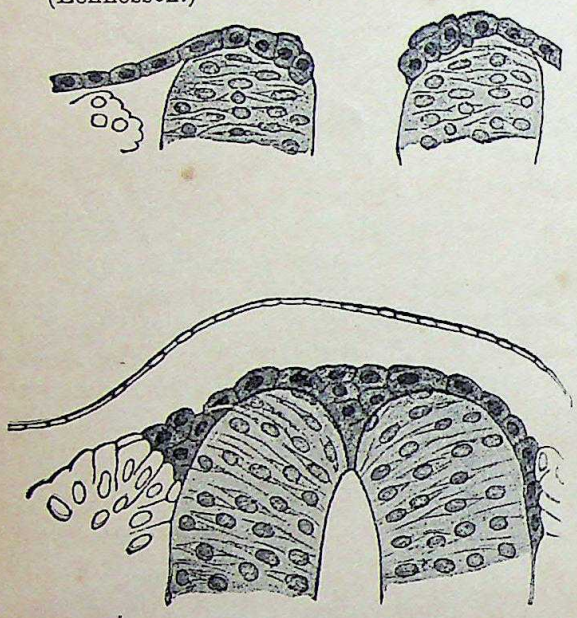

Many embryologists maintain (1) that each motor nerve-cell gives origin single motor nerve-fibre which later becomes connected to its own special myot and (2) that each sensory nerve-cell gives origin to two processes, a central w grows into the medulla spinalis or into the brain, and a peripheral which p outwards to unite with the sense-organ supplied by the nerve. It is, howe probable that the myotomes and the peripheral sense-organs are from the connected with the central nervous system, and that this connexion is never lost. *Lepidosiren paradoxa*, Graham Kerr * has traced back the development of the m nerve-trunk to a period in which it is represented by a bridge of soft granular p plasm connecting the medulla spinalis and myotome at a stage when these struct are in close apposition. As the myotome is pushed outwards it remains conne with the medulla spinalis by the ever-lengthening strand of nerve, which soon lose granular protoplasmic character and assumes a fibrillated appearance. A sin

* J. Graham Kerr, "Transactions of the Royal Society of Edinburgh," vol. xli. part i. 1903-4.

CC-0. In Public Domain. Gurukul Kangri Collection, Haridwar

Digitized by Arya Samaj Foundation Chennai and eGangotri

ndition probably exists regarding the development of sensory nerve-fibres, for meron and Milligan * have shown that in early embryonic life the cell-elements of e sense-epithelium of the auditory vesicle are connected with those of the hind-rain by a continuous tract of nucleated protoplasm (syncytium) which is never

FIG. 133.—A human embryo 10·2 mm. long, showing the peripheral nerves. (After a reconstruction by His.) (From Quain's Elements of Anatomy, vol. i., Embryology.)

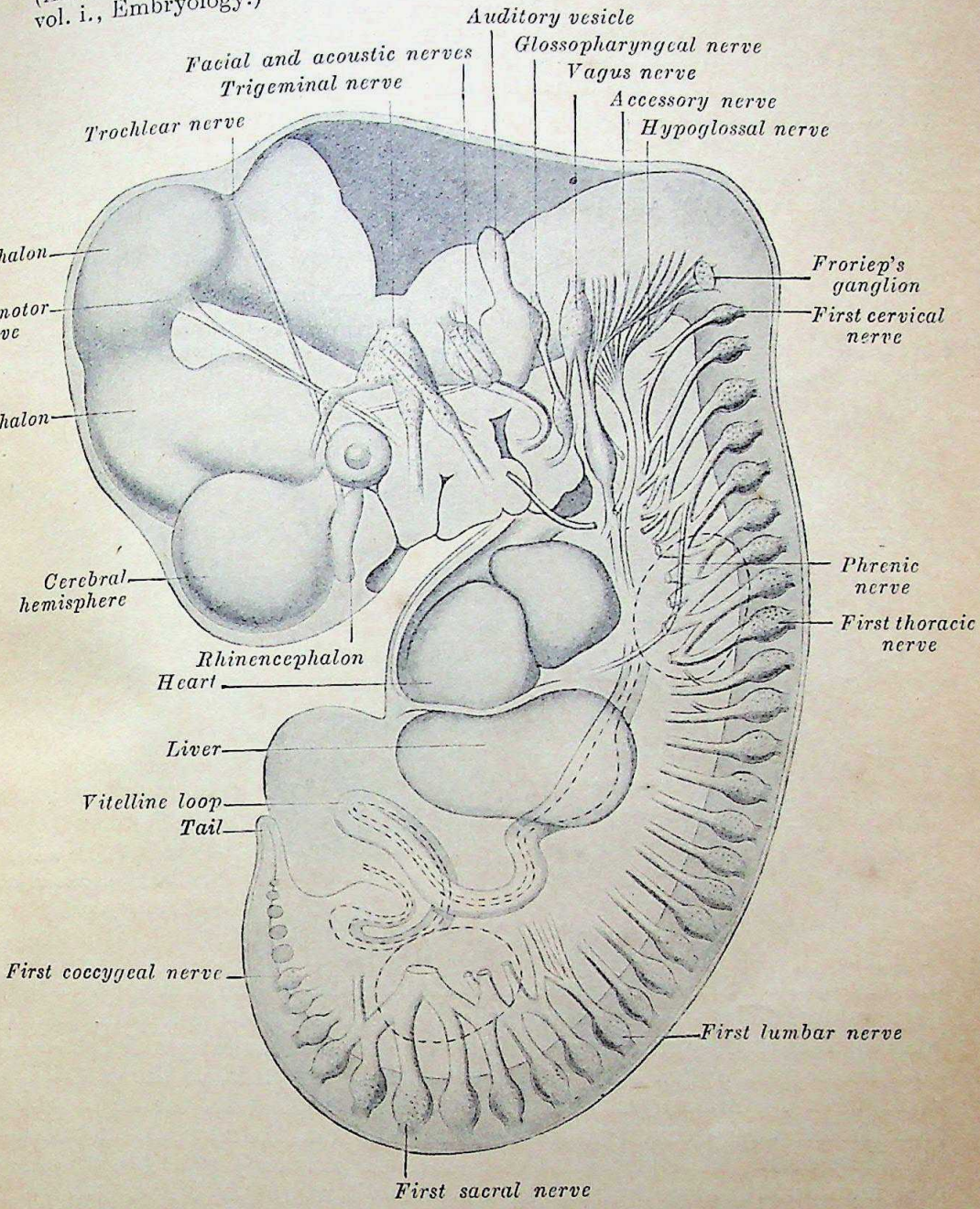

The abducent nerve is not labelled, but is seen passing forwards to the eye under the mandibular and maxillary nerves.

vered. This syncytium, at first undifferentiated, becomes fibrillated longitudinally form a continuous tract of nerve-fibres (the future auditory nerve) uniting the nse-epithelium of the auditory organ with the hind-brain.

The anterior and posterior nerve-roots join immediately beyond the spinal nglion to form the *spinal nerve* (fig. 133), which then divides into anterior, posterior, d visceral divisions. The anterior and posterior divisions proceed directly to their eas of distribution without further association with ganglion-cells. The visceral

* 'The development of the auditory nerve in vertebrates,' *Journal of Anatomy and hysiology*, vol. xliv.

CC-0. In Public Domain. Gurukul Kangri Collection, Haridwar

Digitized by Arya Samaj Foundation Chennai and eGangotri

divisions are distributed to the thoracic, abdominal and tripelvic viscera, to which they pass through the sympathetic trunk, and many of the fibres of divisions form arborisations around the ganglion-cells of this trunk. Vi divisions are not given off from all the spinal nerves; they form two groups (*a*) *thoracicolumbar*, from the thoracic and the first and second lumbar ne and (*b*) *sacral*, from the second, third and fourth sacral nerves.

The **brain** is developed from the cephalic end of the neural tube, which early period expands into the three primary cerebral vesicles (fig. 81). The marked off from each other by constrictions, and are named the *rhombencep* or *hind-brain*, the *mesencephalon* or *mid-brain*, and the *prosencephalon* or *fore-br* the first being continuous with the medulla spinalis. As the result of the un growth of its different parts three flexures appear in the brain; two of these fle are concave ventrally and are associated with corresponding flexures of the The first appears in the region of the mid-brain, and is named the *ventral ce flexure* (figs. 134, 139); the fore-brain bends in a ventral direction around the an end of the notochord and fore-gut until its floor lies almost parallel with th

Fig. 134.—A diagram to illustrate the alar and basal laminæ of the brain vesicles. (His.)

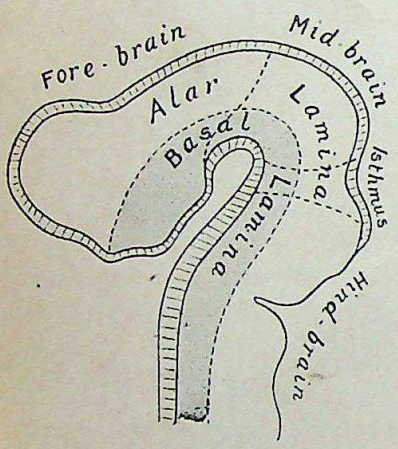

Fig. 135.—A transverse section through medulla oblongata of a human embryo. × (From Kollmann's Entwickelungsgeschic

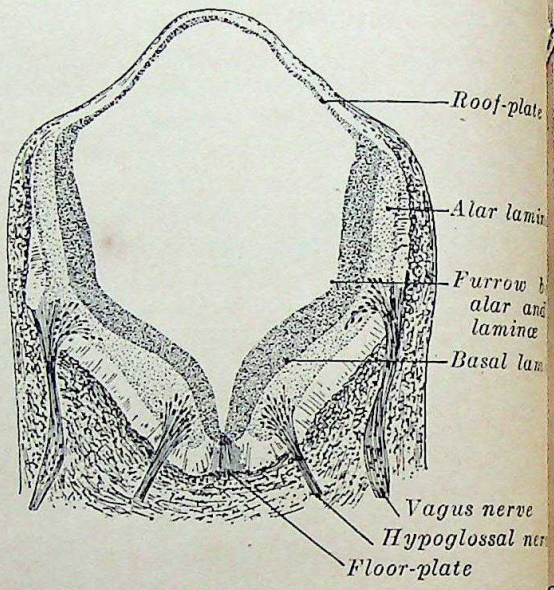

the hind-brain. The mid-brain is for a time the most prominent part of the b since its dorsal surface corresponds with the convexity of the flexure. The sec bend appears at the junction of the hind-brain and medulla spinalis, and is ter the *cervical flexure* (fig. 138). It increases from the third to the end of the week, when the hind-brain forms nearly a right angle with the medulla spin after the fifth week erection of the head takes place and the cervical flexure dimin and disappears. The third bend is named the *pontine flexure* (fig. 140), bec it is found in the region of the future pons (Varolii). It differs from the two in that (*a*) its convexity is forwards, and (*b*) it does not affect the head.

The lateral walls of the brain-tube, like those of the medulla spinalis, are div by internal furrows into dorsal or alar and ventral or basal laminæ (figs. 134, 1

The **rhombencephalon** or **hind-brain**.—The cavity of the hind-brain bec the fourth ventricle. By the time the ventral cephalic flexure appears the h brain exceeds in length the combined lengths of the other two brain vesi Anteriorly it exhibits a constriction, the *isthmus rhombencephali* (fig. 134, Isthm which is best seen when the brain is viewed from the dorsal aspect. From isthmus the brachia conjunctiva of the cerebellum and the anterior medu velum are formed. The rest of the hind-brain consists of two parts, an up the *metencephalon*, and a lower, the *myelencephalon*. The cerebellum is develo by a thickening of the roof, and the pons by a thickening of the floor and la walls of the metencephalon. The floor and lateral walls of the myelencep

CC-0. In Public Domain. Gurukul Kangri Collection, Haridwar

Digitized by Arya Samaj Foundation Chennai and eGangotri

thickened to form the medulla oblongata; its roof remains thin, and, retaining a great extent its epithelial nature, is expanded in a lateral direction. Later, by growth and backward extension of the cerebellum, the roof is folded inwards wards the cavity of the fourth ventricle; it assists in completing the dorsal ll of this cavity, and is also invaginated to form the ependymal covering of chorioid plexuses of the ventricle. Above it is continuous with the posterior dullary velum; below, with the obex and ligulæ.

The development of the *medulla oblongata*, though resembling that of the medulla nalis, exhibits one or two interesting modifications. At an early stage the elencephalon consists of two lateral walls, connected across the middle line floor- and roof-plates (figs. 135, 136). Each lateral wall consists of an alar d a basal lamina, separated by an internal furrow, the remains of which are resented in the adult brain by the sulcus limitans of the rhomboid fossa. e contained cavity is more or less triangular in section, the base being formed the thin and greatly expanded roof-plate, the upper part of which ultimately ms the posterior medullary velum. Pear-shaped neuroblasts are developed in

FIG. 136.—A transverse section through the medulla oblongata of a human embryo. (After His.)

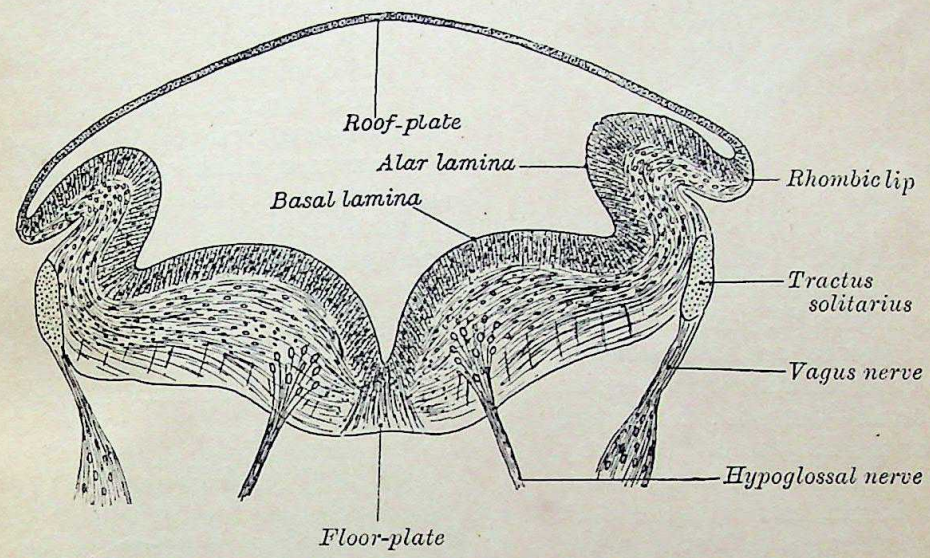

e alar and basal laminæ, and their narrow stalks are elongated to form the axis-linders of the nerve-fibres. Opposite the furrow or boundary between the alar d basal laminæ a bundle of nerve-fibres attaches itself to the outer surface of alar lamina. This is named the *tractus solitarius* (fig. 136), and is formed by sensory fibres of the glossopharyngeal and vagus nerves. It is the homologue the *oval bundle* seen in the medulla spinalis (p. 86), and, like it, is developed an ingrowth of fibres from the ganglia of the neural crest. At first it is applied the outer surface of the alar lamina, but is soon buried by the growth over it the neighbouring parts. By the fifth week the dorsal part of the alar lamina nds in a lateral direction along its entire length to form what is termed the *mbic lip* (figs. 136, 140). Within a few days this lip adheres to, and unites with, e outer surface of the main part of the alar lamina, and so covers in the tractus itarius and also the spinal root of the trigeminal nerve.

Neuroblasts accumulate in the mantle layer; those in the basal lamina corre-ond with the cells in the anterior grey column of the medulla spinalis, and, like em, give origin to motor nerve-fibres; in the medulla oblongata the neuroblasts e arranged in groups or nuclei, instead of forming a continuous column as in the dulla spinalis. From the alar lamina and its rhombic lip, neuroblasts migrate o the basal lamina, where some are aggregated to form the olivary nuclei, while ny send their axis-cylinders through the floor-plate to the opposite side, and s constitute the rudiment of the raphe of the medulla oblongata. By means of s thickening of the ventral portion, the motor nuclei are buried deeply in the erior, and in the adult are found close to the rhomboid fossa. This is still

CC-0. In Public Domain. Gurukul Kangri Collection, Haridwar

Digitized by Arya Samaj Foundation Chennai and eGangotri

further accentuated: (a) by the development of the pyramids of the m oblongata, which are formed about the fourth month by the downgrowth cerebrospinal fasciculi; and the fibres which pass to and the cerebellum.

Fig. 137.—The hind-brain of a human embryo about three months old. Viewed from behind and partly from the right side. (From a model by His.)

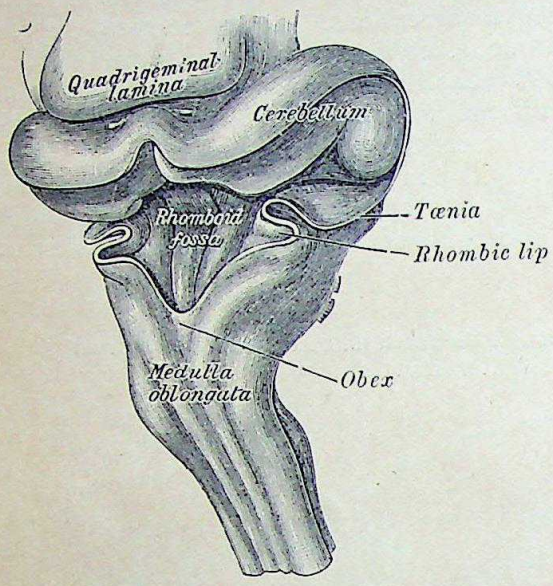

The *pons* is developed fr ventrolateral wall of the m cephalon by a process simi that which has been describ the ventrolateral wall of the m oblongata.

The *cerebellum* is develop the roof of the anterior part hind-brain (figs. 137 to 142), alar laminæ of this part incre thickness and form two lateral which fuse in the middle lin produce a thick lamina which the upper part of the cavity hind-brain vesicle; this lamina stitutes the rudiment of the bellum, the outer surface of is originally smooth and co The flocculus and nodule are veloped from the rhombic lip, are recognisable as separate po before any of the other cere lobules. The fissures of the cerebellum appear first in the vermis and floc region, and traces of them are found during the third month; the fissur the cerebellar hemispheres do not appear till the fifth month. The primitive fissures are not developed in the order of their relative size in the adult—thus the horizontal sulcus at the fifth month is merely a shallow groove. The more important of the early fissures are: (a) the *fissura prima* between the developing culmen and clivus, and (b) the *fissura secunda* between the future pyramid and uvula. The groove produced by the bending over of the rhombic lip is here known as the *floccular fissure*; when the two lateral walls fuse, the right and left floccular fissures join in the middle line, and their central part becomes the *postnodular fissure*.

Fig. 138.—The brain of a human embryo four and a half weeks old. Right aspect. (From a model by His.)

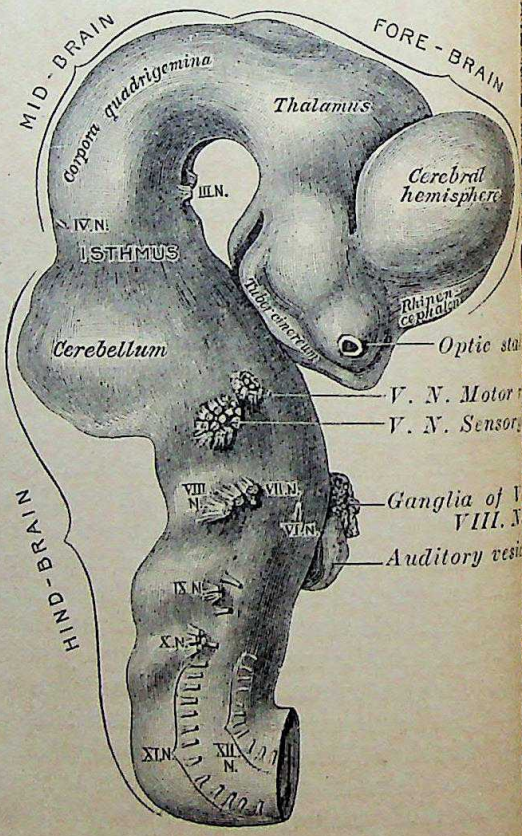

On the ventricular surface of the cerebellar lamina a transverse furrow, the *incisura fastigii*, appears and then deepens to form the tent-like recess of the roof of the fourth ventricle. The rudiment of the cerebellum at first projects in a dorsal direction; but, by the backward growth of the cerebrum, it is folded downwards, and somewhat flattened, and the thin roof-plate of the fourth ventricle, originally continuous with the posterior border of the cerebellum, is projected inwards tow the cavity of the ventricle.

CC-0. In Public Domain. Gurukul Kangri Collection, Haridwar

Digitized by Arya Samaj Foundation Chennai and eGangotri

After the seventh month of fœtal life the cerebellum increases very rapidly in e.*

The **mesencephalon** or **mid-brain** (figs. 138 to 142) exists for a time as a thin-lled cavity of some size, and is separated by slight constrictions from the isthmus mbencephali and the fore-brain. Its cavity becomes relatively reduced in meter, and forms the cerebral aqueduct of the adult brain. The basal laminæ the mid-brain increase in thickness to form the cerebral peduncles, which are first of small size, but rapidly enlarge after the fourth month. Many of the uroblasts of these laminæ are uped in relation to the sides and or of the cerebral aqueduct, and nstitute the nuclei of the oculo-tor and trochlear nerves, and of mesencephalic root of the tri-minal nerve; others are aggre-ed to form the red nuclei. By a ilar thickening process the alar inæ are developed into the adrigeminal lamina. The dorsal t of the wall expands, and for ime presents an internal median row and a corresponding external ge; these, however, disappear, the latter is replaced by a ove. Subsequently two oblique rows extend medialwards and ckwards, and the thickened nina is thus subdivided into the perior and inferior colliculi.

Fig. 139.—The brain of a human embryo, about four and a half weeks old. (From a model by His.)

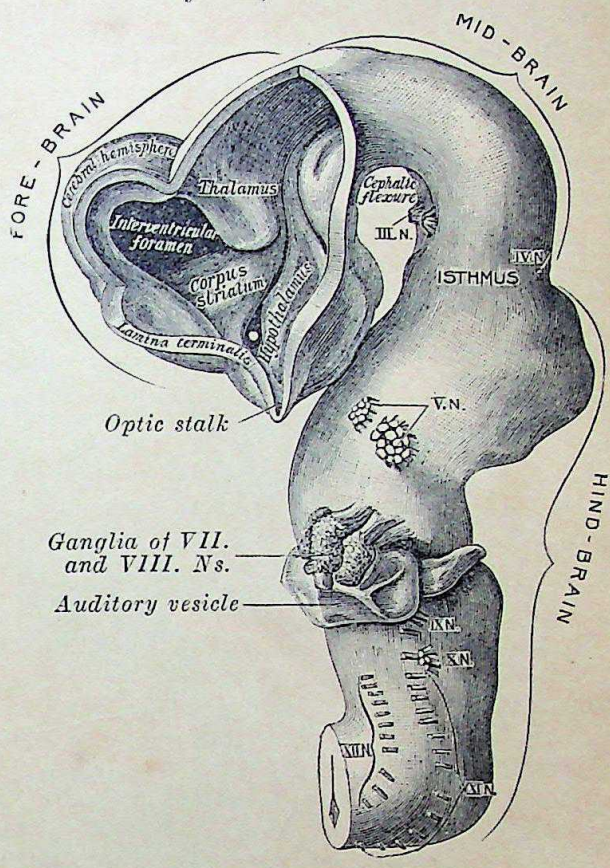

The **prosencephalon** or **fore-ain.**—A transverse section through e early fore-brain shows the me parts as are displayed in nilar sections of the medulla inalis and medulla oblongata, . a pair of thick lateral walls nnected by thin floor- and roof-ates. Moreover, each lateral wall divided into a dorsal or alar and entral or basal lamina separated ernally by a furrow termed the *cus of Monro.* This sulcus ends anteriorly at the medial end of the optic stalk, l in the adult brain is retained as a slight groove extending backwards from the erventricular foramen to the cerebral aqueduct.

At a very early period—in some animals before the closure of the cranial part of neural tube—two lateral diverticula, the *optic vesicles*, appear, one on either side the fore-brain; for a time they communicate with the cavity of the fore-brain by atively wide openings. The distal parts of the vesicles expand, while the proximal rts are reduced to tubular stalks, the *optic stalks*; their further development iven on pp. 101 to 104. The fore-brain then grows forwards, and from the alar inæ of this front portion the cerebral hemispheres originate as diverticula which idly expand to form two large pouches, one on either side. The cavities of se diverticula are the rudiments of the lateral ventricles; they communicate h the median part of the fore-brain cavity by relatively wide openings which imately form the interventricular foramen (foramen of Monro). The median tion of the wall of the fore-brain vesicle consists of a thin lamina, the *lamina minalis* (figs. 142, 145), which stretches from the interventricular foramen to recess at the base of the optic stalk. The anterior part of the fore-brain, includ-the rudiments of the cerebral hemispheres, is named the *telencephalon*, and the terior portion the *diencephalon*; both contribute to the formation of the third tricle.

* Halbert L. Dunn, *Proceedings of the American Association of Anatomists, Anatomical Record*, 21, No. 1, p. 55.

CC-0. In Public Domain. Gurukul Kangri Collection, Haridwar

Digitized by Arya Samaj Foundation Chennai and eGangotri

The *diencephalon*.—From the alar lamina of the diencephalon, the thal metathalamus, and epithalamus are developed. The *thalamus* (figs. 138 t arises as a thickening which involves the anterior two-thirds of the alar lamina two thalami are visible, for a time, on the surface of the brain, but are subseq hidden by the cerebral hemispheres which grow backwards over them. The t extend medialwards and gradually narrow the interval between them into a s cavity which forms the greater part of the third ventricle; their medial su adhere, in part, to each other, and the *intermediate mass* of the ventricle is dev across the area of contact. The *metathalamus* comprises the medial and geniculate bodies which originate as slight outward bulgings of the alar la In the adult the lateral geniculate body appears as an eminence on the latera of the posterior end of the thalamus, while the medial lies under cover of the pu

FIG. 140.—The brain of a human embryo, about five weeks old. Right later aspect; the roof of the hind-brain has been removed. (From a model b His.)

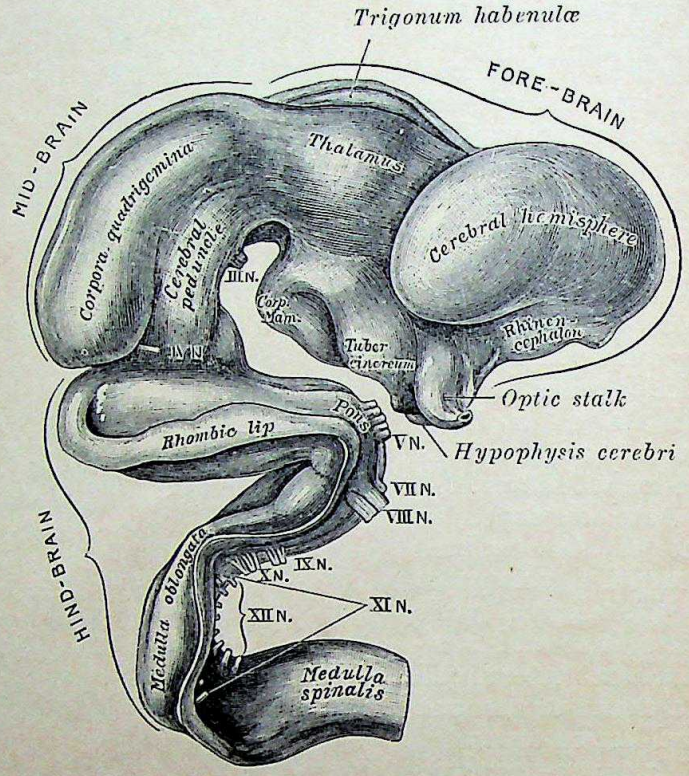

of the thalamus. The *epithalamus* includes the pineal body, the posterior missure, and the trigonum habenulæ. The pineal body arises as a bilateral eva tion of the roof-plate immediately in front of the mid-brain; only the left po of this evagination persists in vertebrates, and it becomes solid with the exce of its proximal part, which forms the recessus pinealis. The pineal body co essentially of (*a*) a distal part representing a rudimentary eye, and (*b*) a pro part which is glandular in nature; only this latter portion is represented in The posterior commissure is formed by the ingrowth of fibres into the depr behind and below the pineal evagination, and the trigonum habenulæ is deve in front of the pineal recess.

From the basal laminæ of the diencephalon the *pars mamillaris hypoth* is developed; this comprises the corpora mamillaria and the posterior part tuber cinereum. The corpora mamillaria arise as a single thickening, whi divided by a median furrow during the third month.

The roof-plate of the diencephalon, in front of the pineal body, remains thi epithelial in character, and is subsequently invaginated by the chorioid ple of the third ventricle.

The *telencephalon* consists of a median portion and two lateral divert The median portion forms the anterior part of the cavity of the third vent and is closed below and in front by the lamina terminalis. The lateral divert consist of outward pouchings of the alar lamina; the cavities represent the f

CC-0. In Public Domain. Gurukul Kangri Collection, Haridwar

Digitized by Arya Samaj Foundation Chennai and eGangotri

ral ventricles, and their walls the nervous matter of the cerebral hemispheres. roof-plate of the telencephalon remains thin, and is continuous in front with lamina terminalis, and behind with the roof-plate of the diencephalon. In basal laminæ and floor-plate the *pars optica hypothalami* is developed; this prises the anterior part of the tuber cinereum, the infundibulum and posterior e of the hypophysis, and the optic chiasma. The anterior part of the tuber ereum is derived from the posterior part of the floor of the telencephalon; the undibulum and posterior lobe of the hypophysis arise as a downward diverticulum m the floor. The most dependent part of the diverticulum becomes solid and ms the posterior lobe of the hypophysis; the anterior lobe of the hypophysis leveloped from a diverticulum of the ectodermal lining of the stomodæum (p. 135). e optic chiasma is formed by the meeting and partial decussation of the optic ves, which subsequently grow backwards as the optic tracts and end in the ncephalon.

FIG. 141.—The brain of a human embryo about five weeks old. Medial aspect of right half. The roof of the hind-brain has been removed. (From a model by His.)

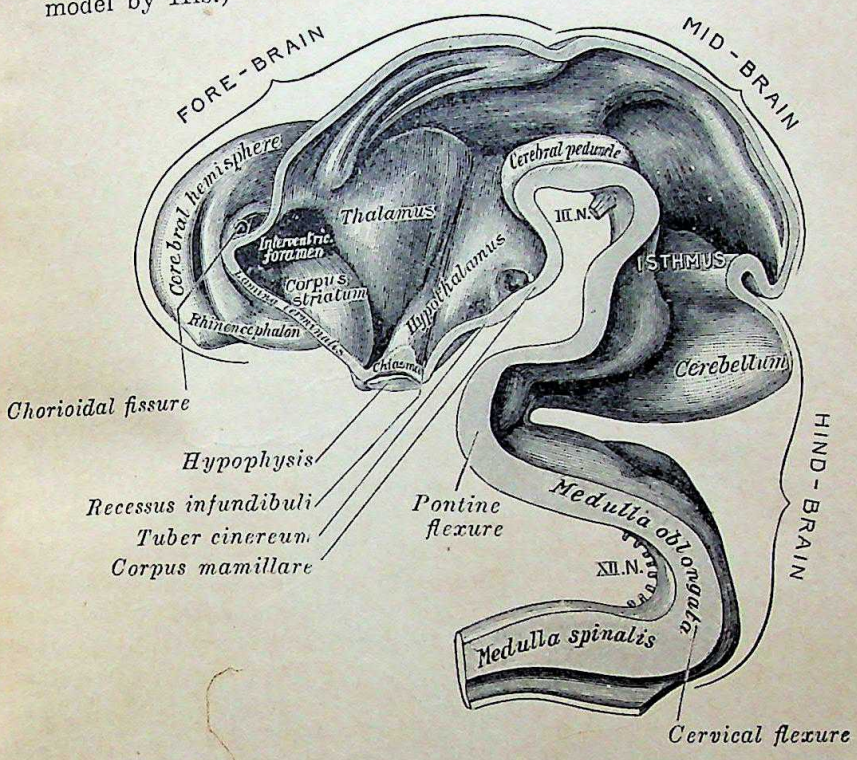

The *cerebral hemispheres* arise as diverticula of the alar laminæ of the telen- halon (figs. 138 to 142); they increase rapidly in size and ultimately overlap structures developed from the mid- and hind-brains. This great expansion he hemispheres is a characteristic feature of the brains of mammals, and attains maximum development in the brain of man. G. Elliot Smith divides each ebral hemisphere into three fundamental parts, viz. the rhinencephalon, the pus striatum, and the neopallium.

The *rhinencephalon* (figs. 140 to 143) represents the oldest part of the telen- halon, and forms almost the whole of the hemisphere in fishes, amphibians, and tiles. In man it is feebly developed in comparison with the rest of the hemi- ere, and comprises the following parts, viz. the olfactory lobe (consisting of the ctory tract and bulb, and the trigonum olfactorium), the anterior perforated stance, the septum pellucidum, the subcallosal, supracallosal, and dentate gyri, fornix, the hippocampus, and the uncus. The rhinencephalon appears as a gitudinal elevation, with a corresponding internal groove, on the under surface he hemisphere close to the lamina terminalis; it is separated from the lateral ace of the hemisphere by a furrow, the *external rhinal fissure*, and is continuous nd with that part of the hemisphere which will ultimately form the anterior end he temporal lobe. The elevation is divided by a groove into an anterior and sterior part. The anterior grows forward as a hollow stalk, the lumen of which

CC-0. In Public Domain. Gurukul Kangri Collection, Haridwar

Digitized by Arya Samaj Foundation Chennai and eGangotri

is continuous with the anterior part of the lateral ventricle. During the month the stalk becomes solid and forms the rudiment of the olfactory bulb tract; a strand of gelatinous tissue in the interior of the bulb indicates the p of the original cavity. From the posterior part the anterior perforated sub and the pyriform lobe are developed; at the beginning of the fourth mon latter forms a curved elevation continuous behind with the medial surface temporal lobe, and consisting, from before backwards, of the gyrus olfa lateralis, gyrus ambiens, and gyrus semilunaris, parts which in the adult are represented by the lateral root of the olfactory tract and the uncus position and connexions of the remaining portions of the rhinencephalon are de with the anatomy of the brain.

The *corpus striatum* (figs. 139, 141) appears in the fourth week as a tria thickening of the floor of the telencephalon between the optic recess and the

FIG. 142.—The brain of a human embryo, about three months old. Medi aspect of right half. (From a model by His.)

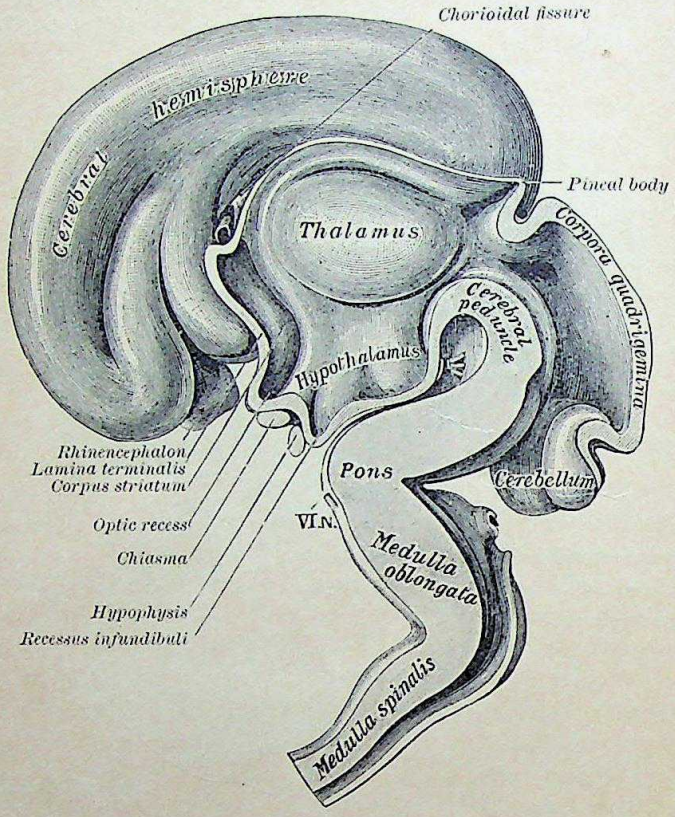

ventricular foramen, and continuous behind with the thalamic part of the cephalon. It increases in size, and by the second month forms a swelling i floor of the future lateral ventricle; this swelling reaches as far as the pos end of the primitive hemisphere, and when this part of the hemisphere backwards and downwards to form the temporal lobe, the posterior part corpus striatum is carried into the roof of the inferior horn of the ventricle, it is seen as the tail of the caudate nucleus in the adult brain. During the and fifth months the corpus striatum becomes incompletely subdivided b fibres of the internal capsule into two masses, an inner, the caudate nucleu an outer, the lentiform nucleus. In front, the corpus striatum is continuous the anterior perforated substance; laterally it is confluent for a time with portion of the wall of the vesicle which is developed into the insula, but this tinuity is subsequently interrupted by the fibres of the external capsule.

The *neopallium* (fig. 144) forms the remaining, and by far the greater of the cerebral hemisphere. It consists, at an early stage, of a relatively more or less hemispherical cavity—the primitive lateral ventricle—enclos a thin wall from which the cortex of the hemisphere is developed. The expands in all directions, but more especially upwards and backwards, so th the third month the hemispheres cover the diencephalon, by the sixth they o the mid-brain, and by the eighth the hind-brain.

CC-0. In Public Domain. Gurukul Kangri Collection, Haridwar

Digitized by Arya Samaj Foundation Chennai and eGangotri

The lamina terminalis unites the two hemispheres but does not share in their pansion, and thus the hemispheres are separated by a cleft, the forerunner of e longitudinal fissure, and this cleft is occupied by a septum of mesodermal tissue ich constitutes the primitive falx cerebri. Coincidently with the expansion of e vesicle, its cavity is drawn out into three prolongations which represent the ns of the future lateral ventricle; the hinder end of the vesicle is carried down- rds and forwards, and forms the inferior horn; the posterior horn is produced mewhat later, in association with the backward growth of the occipital lobe of the misphere. The roof-plate of the primitive fore-brain remains thin and of an ithelial character; it is invaginated into the lateral ventricle along the medial ll of the hemisphere. This invagination constitutes the chorioidal fissure, and tends from the interventricular foramen to the posterior end of the vesicle. esodermal tissue, continuous with that of the pia mater, and carrying blood-vessels th it, spreads between the two layers of the invaginated fold and forms the

FIG. 143.—The brain of an embryo at the beginning of the fourth month. Inferior aspect. (Kollmann.)

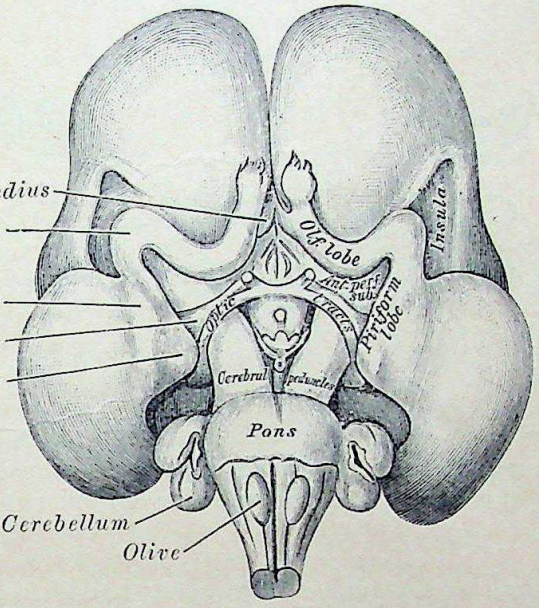

diment of the tela chorioidea; the margins of the tela become highly vascular and rm the chorioid plexuses which for some months almost completely fill the ntricular cavities; the tela at the same time invaginates the epithelial roof of e diencephalon, and there forms the chorioid plexuses of the third ventricle. By e downward and forward growth of the posterior end of the vesicle to form the mporal lobe the chorioidal fissure finally reaches from the interventricular foramen the extremity of the inferior horn of the ventricle.

Parallel with but above and in front of the chorioidal fissure the medial wall of e cerebral vesicle becomes folded and gives rise to a shallow fissure, the *hippo-mpal fissure*, on the medial surface, and to a corresponding bulging, the *hippo-mpus*, on the medial wall of the ventricular cavity.* The grey or ganglionic vering of the wall of the vesicle ends at the inferior margin of the fissure in a ickened edge; beneath this the marginal or reticular layer (future white sub-ance) is exposed, and its lower thinned edge is continuous with the epithelial vagination covering the chorioid plexus (fig. 144). As a result of the later wnward and forward growth of the temporal lobe the hippocampal fissure and e parts associated with it extend from the interventricular foramen to the end the inferior horn of the ventricle. The thickened edge of grey substance comes the gyrus dentatus, the fasciola cinerea and the supra- and sub-callosal ri, while the free edge of the white substance forms the fimbria hippocampi and e body and crus of the fornix. The corpus callosum is developed within the

* Consult an article on the development of the fissura hippocampi by Marion Hines, *Journal Comparative Neurology*, vol. 34, No. 1, February 1922.

CC-0. In Public Domain. Gurukul Kangri Collection, Haridwar

Digitized by Arya Samaj Foundation Chennai and eGangotri

arch of the hippocampal fissure, and the upper part of the fissure forms, in adult brain, the callosal fissure on the medial surface of the hemisphere.

FIG. 144.—A coronal section through the brain to show the relations of the neopallium. Diagrammatic. (After His.) (From Quain's Elements of Anatomy, vol. i., Embryology.)

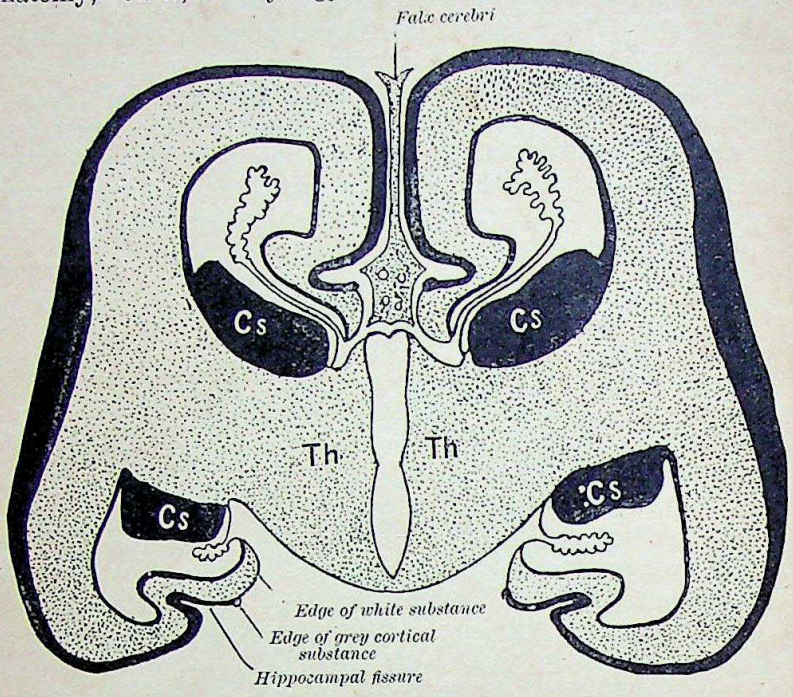

Cs. Corpus striatum. Th. Thalamus.

The commissures (fig. 145).—The development of the posterior commis has already been referred to (p. 94). The great commissures of the hemispheres, the corpus callosum, the fornix, and the anterior commissure, arise from the lam

FIG. 145.—The brain of a human embryo, four months old. Medial aspect of left half. (Marchand.)

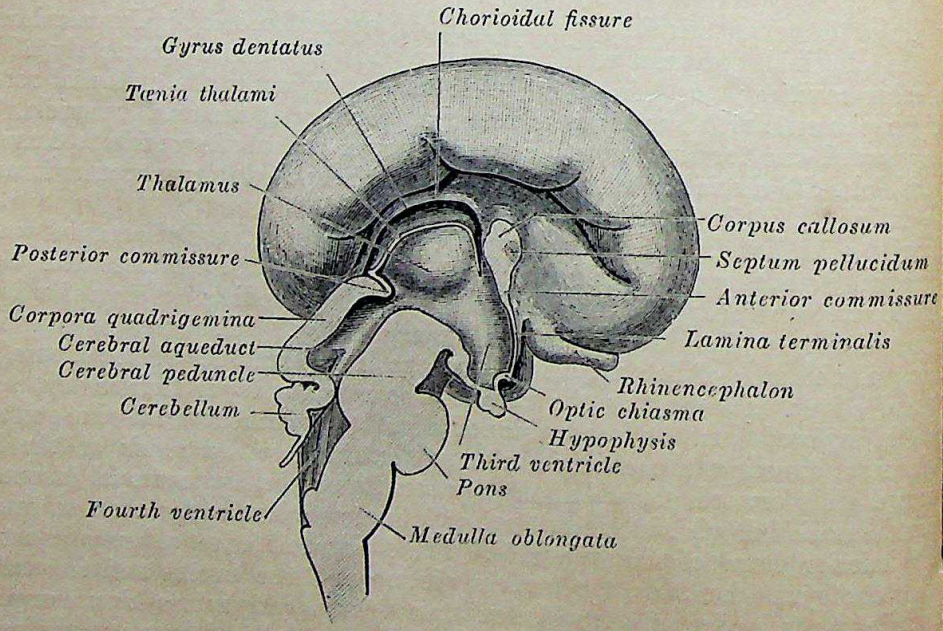

terminalis. About the fourth month a small thickening appears in this lam immediately in front of the interventricular foramen. The lower part of

CC-0. In Public Domain. Gurukul Kangri Collection, Haridwar

Digitized by Arya Samaj Foundation Chennai and eGangotri

ickening is soon separated, and nerve-fibres appear in it to form the anterior mmissure. The upper part continues to grow with the hemispheres, and is vaded by two sets of fibres. Transverse fibres, extending between the hemiheres, pass into its dorsal part, which is now differentiated as the corpus callosum. to the ventral part longitudinal fibres from the hippocampus pass to the lamina rminalis, and through that structure to the corpora mamillaria; these fibres nstitute the fornix. The *paraterminal bodies*, or portions of the rhinencephalon mediately in front of the lamina terminalis, are stretched to form the subcallosal rus and the laminæ of the septum pellucidum.

The *fissures or sulci*.—Until the fifth month the surface of the cerebral hemiere is almost smooth. Between the sixth and seventh months the cortex inses rapidly in volume and becomes folded, and the surface is thus raised into a mber of elevations or convolutions, separated by fissures or sulci; the chief of se are well developed by the seventh month. The *lateral cerebral, or Sylvian, sure* differs from the others in its mode of development. About the third month depression, the *Sylvian fossa*, appears on the lateral surface of the hemisphere 146); this fossa corresponds with the position of the corpus striatum, and its

FIG. 146.—The right cerebral hemisphere of a human embryo, about five months old. Lateral aspect.

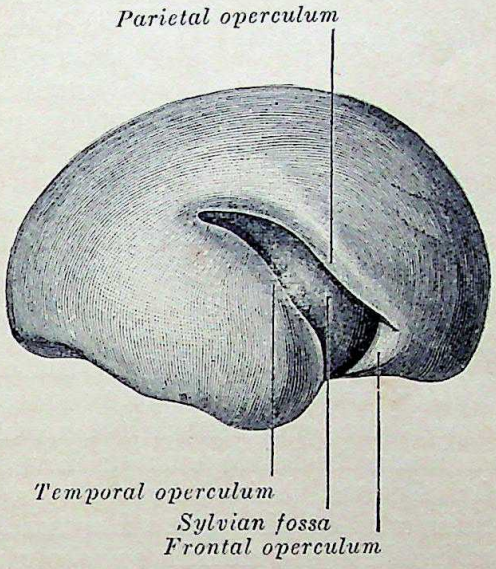

oor is moulded to form the cortex of the insula. The intimate connexion which xists between the deep surface of the cortex of the insula and the corpus striatum revents the insular part of the hemisphere wall from expanding at the same rate s the portions which surround it, with the result that the latter grow over and cover he insula, and constitute the temporal, parietal, frontal, and orbital opercula of he adult brain. The frontal and orbital opercula are the last to form, but by the nd of the first year after birth the insula is completely submerged by the approximation of the opercula. The fissures separating the opposed margins of the opercula onstitute the composite lateral cerebral fissure.

If a section across the wall of the hemisphere about the sixth week be examined icroscopically it is seen to consist of a thin marginal or reticular layer, a thick pendymal layer, and a thin intervening mantle layer. Neuroblasts from the pendymal and mantle layers migrate into the deep part of the marginal layer and orm the cells of the cerebral cortex. By the sixth month the middle cell-lamina as attained one-half, and the inner cell-lamina three-fourths of their adult thickess; the outer cell-lamina is the last to develop and its thickness varies with the tellectual capacity of the individual. The nerve-fibres which form the underlying hite substance of the hemispheres consist at first of outgrowths from the cells of he corpora striata and thalami; the fibres from the cells of the cortex are added ter. Medullation of these fibres begins about the time of birth and continues ntil puberty.

CC-0. In Public Domain. Gurukul Kangri Collection, Haridwar

Digitized by Arya Samaj Foundation Chennai and eGangotri

A summary of the parts derived from the cerebral vesicles is given in the foll table :—

Rhombencephalon or hind-brain	1. Myelencephalon	Medulla oblongata. Lower part of fourth ventric
	2. Metencephalon	Pons. Cerebellum. Intermediate part of fourth ventricle.
	3. Isthmus rhombencephali	Anterior medullary velum. Brachia conjunctiva cerebell Upper part of fourth ventric
Mesencephalon or mid-brain . . .		Cerebral peduncles. Lamina quadrigemina. Cerebral aqueduct.
Prosencephalon or fore-brain	1. Diencephalon	Thalamus. Metathalamus. Epithalamus. Pars mamillaris hypothalami Posterior part of third ventricle.
	2. Telencephalon	Anterior part of third ventricle. Pars optica hypothalami. Cerebral hemispheres. Lateral ventricles. Interventricular foramen.

The **cerebral nerves.**—With the exception of the olfactory, optic, and acc nerves, which will be specially considered, the cerebral nerves are developed similar manner to the spinal nerves (p. 88). The sensory or afferent fibres o trigeminal, facial, glossopharyngeal and vagus nerves are partly derived from cells of the ganglion-rudiments of the neural crest and partly from the cel certain thickened patches of the ectoderm (*placodes*), which are developed a upper ends of the branchial grooves. The central processes of these cells form roots of the nerves, the peripheral processes their fibres of distribution (fig. It has been seen, in considering the development of the medulla oblongata (p. that the *tractus solitarius* (fig. 148), derived from the ingrowing fibres from cells of the ganglion-rudiments of the glossopharyngeal and vagus nerve the homologue of the *oval bundle* in the medulla spinalis which has its origin in posterior nerve-roots. The motor nerves arise from the neuroblasts situated in basal laminæ of the mid- and hind-brain. While, however, the spinal motor ne roots arise in one series from the basal lamina, the cerebral motor nerves grouped into two sets, according as they spring from the medial or lateral p of the basal lamina. To the former set belong the oculomotor, trochlear, abduc and hypoglossal nerves; to the latter, the accessory nerve, and the motor f of the trigeminal, facial, glossopharyngeal, and vagus nerves (figs. 147, 148).

The **sympathetic system.**—The ganglion-cells of the *sympathetic system* derived from the segmented masses of the cells of the neural crests, which mig along the sides of the neural tube to form the spinal ganglia; certain cells de themselves from the ventral margins of these masses and move towards the s of the aorta, where some of them are grouped to form the ganglia of the sym thetic trunks, while others undergo a further migration and form the gangli the prevertebral and visceral plexuses. The ciliary, sphenopalatine, otic, and maxillary ganglia are probably formed by groups of cells which have migr from that part of the neural crest which gives rise to the semilunar ganglion.

The **chromaffin organs.**—The tissue from which the sympathetic ganglia formed is at first a syncytium of cells termed sympathochromaffin cells, but two varieties of cells, small and large, are differentiated from it; the small (sympathoblasts) are transformed into the sympathetic nerve-cells, the l become chromaffin cells, and, separating from the others, accumulate to f the chromaffin organs. In the gangliated trunk of the sympathetic the chrom bodies are situated in depressions in the ganglia. In connexion with certain

CC-0. In Public Domain. Gurukul Kangri Collection, Haridwar

Digitized by Arya Samaj Foundation Chennai and eGangotri

t all, of the secondary plexuses of the sympathetic system chromaffin organs found; the largest members of this series are the *aortic bodies*, which lie along sides of the abdominal aorta between the superior mesenteric and common c arteries; to this group ong also the *carotid glomera* rotid bodies). After birth the romaffin organs degenerate and n no longer be isolated by gross section, but chromaffin tissue n be recognised with the icroscope in the sites originally cupied by them.

FIG. 147.—A transverse section through the medulla oblongata of a human embryo. × 32. (From Kollmann's Entwickelungsgeschichte.)

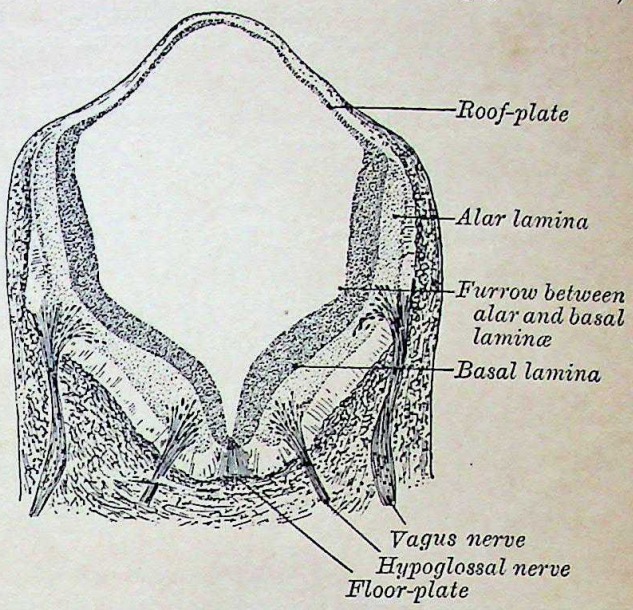

The **suprarenal glands.**—Each prarenal gland consists of a rtical portion derived from e cœlomic epithelium and a edullary portion originally com- sed of sympathochromaffin sue. The cortical portion is t recognisable about the be- ning of the fourth week as a es of buds from the cœlomic s at the root of the mesen- y. Later it is completely parated from the cœlomic epi- elium and forms a suprarenal lge projecting into the cœlom tween the mesonephros and the root of the mesentery. Into this cortical portion lls from the neighbouring masses of sympathochromaffin tissue migrate along the e of its central vein to form the medullary portion of the gland.

The **nose.**—The development of the nose has already been considered (pp. 78 81).

The *olfactory nerves* are developed from the cells of that part of the ectoderm hich lines the olfactory pits; these cells undergo proliferation and give rise to hat are termed the *olfactory cells* of the nose. The axons of these cells grow into e overlying olfactory bulb and form the olfactory nerves.

FIG. 148.—A transverse section through the medulla oblongata of a human embryo. (After His.)

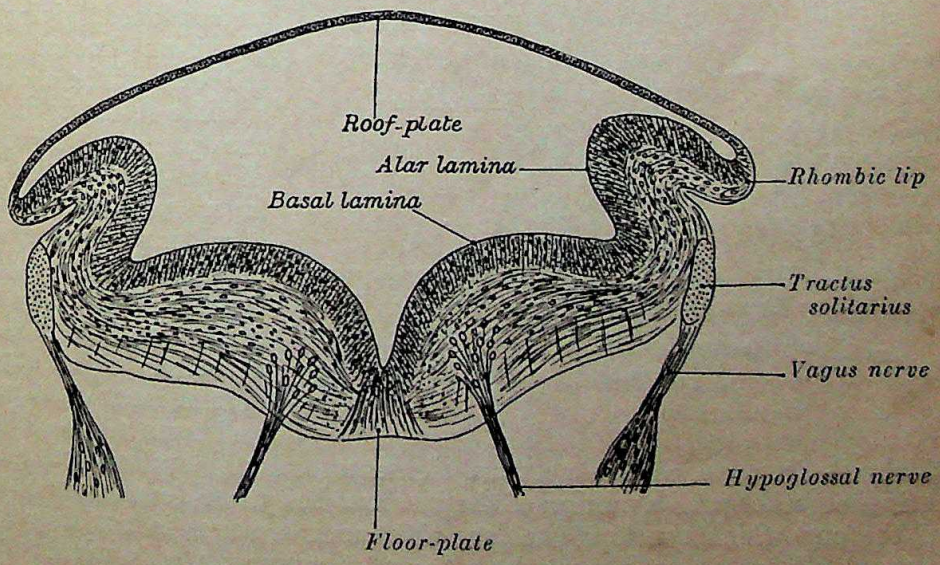

The **eyes.**—The rudiments of the eyes appear as a pair of hollow diverticula from e lateral aspects of the fore-brain. These diverticula are visible before the osure of the anterior neuropore; after its closure they are known as the *optic sicles*. They project towards the sides of the head, and the distal part of each

CC-0. In Public Domain. Gurukul Kangri Collection, Haridwar

Digitized by Arya Samaj Foundation Chennai and eGangotri

expands to form the *optic bulb*, while the proximal part remains narrow and constitutes the *optic stalk* (figs. 149, 150). A small area of ectoderm overlying the optic bulb becomes thickened, and ultimately separated as the *lens-vesicle*, the rudiment of the crystalline lens. The outer wall of the optic bulb increases in thickness and undergoes invagination so that the bulb is converted into a cup,

FIG. 149.—A transverse section through the head of a chick, about forty-eight hours old. (From Duval's Atlas d'Embryologie.)

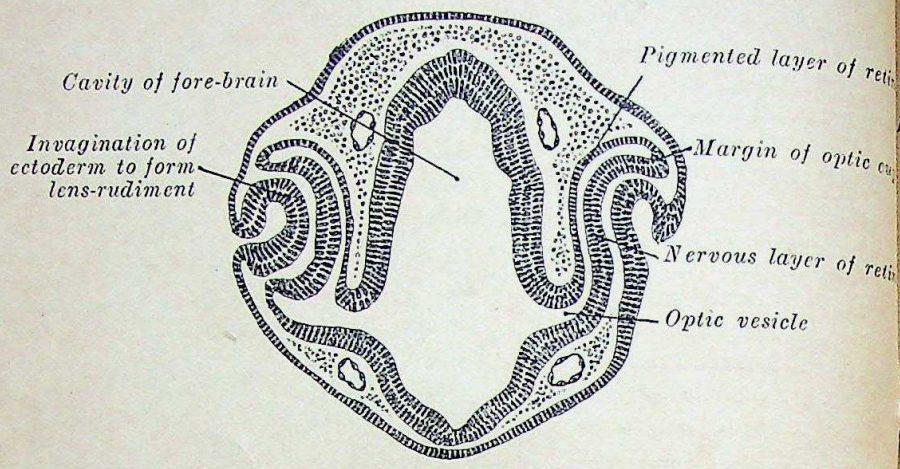

optic cup, consisting of two strata of cells (fig. 150). These two strata are continuous with each other at the cup-margin, which ultimately overlaps the front of the lens and reaches as far forward as the future aperture of the pupil. The invagination is not limited to the outer wall of the bulb, but involves also its postero-inferior surface and extends in the form of a groove for some distance along the optic stalk and thus, for a time, a gap or fissure, the *chorioidal fissure*, exists in the lower part of the cup (fig. 151). Through the groove and fissure the mesoderm extends into the optic stalk and cup, and in this mesoderm an artery is developed; during the seventh week the groove and fissure close, and the artery becomes the central artery of the retina. Sometimes the chorioidal fissure persists, and when this occurs the chorioid and iris in the region of the fissure remain undeveloped, giving rise to a condition known as *congenital coloboma* of the chorioid or iris.

FIG. 150.—A transverse section through the head of a chick embryo, about fifty-two hours old. (From Duval's Atlas d'Embryologie.)

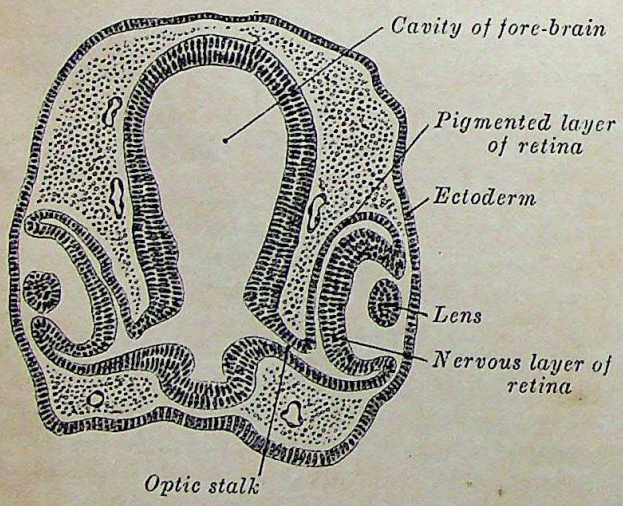

The retina is developed from the optic cup. The outer stratum of the cup persists as a single layer of cells which assume a columnar shape, acquire pigment, and form the pigmented layer of the retina, the pigment first appearing in the cells at the edge of the cup. The cells of the inner stratum proliferate and form a layer of considerable thickness from which the nervous elements and the sustentacular fibres of the retina, together with a portion of the vitreous body, are developed. In the portion of the cup which overlaps the lens the inner stratum is not differentiated into nervous elements, but persists as a layer of columnar cells which, together with the corresponding part of the pigmented layer, form the *pars ciliaris* and *iridica retinæ*.

The cells of the inner or retinal layer of the optic cup differentiate into spongioblasts and germinal cells, and the latter by their subdivisions give rise to neuroblasts.

CC-0. In Public Domain. Gurukul Kangri Collection, Haridwar

Digitized by Arya Samaj Foundation Chennai and eGangotri

spongioblasts the sustentacular fibres of Müller, the outer and inner limiting membranes, and the ground-work of the molecular layers of the retina, are formed. The neuroblasts become arranged to form the ganglionic and nuclear layers. The layer

FIG. 151.—The optic cup and the chorioidal fissure of a human embryo, about four weeks old. Ventral aspect. (Kollmann.)

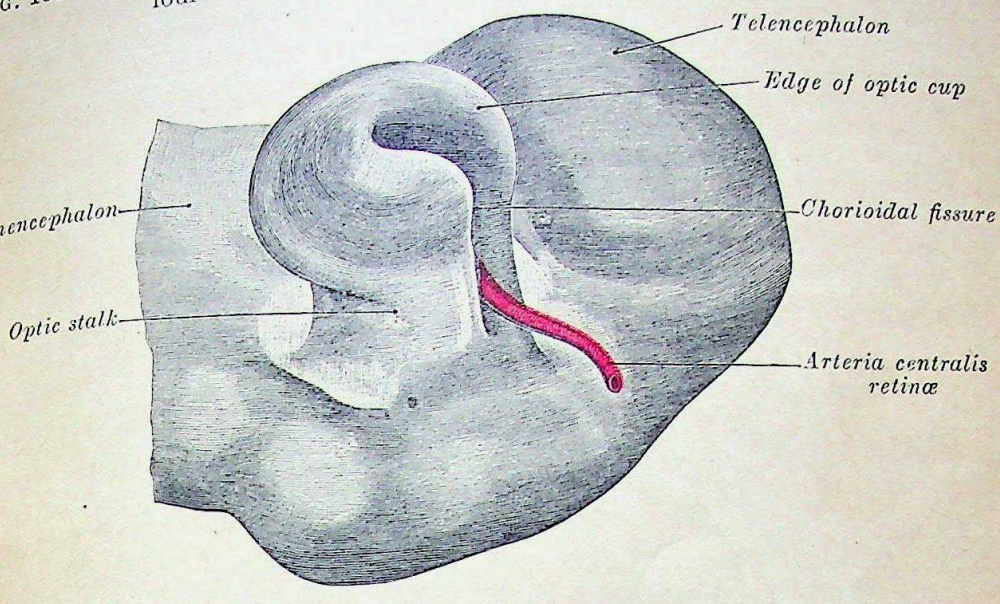

of rods and cones is first developed in the central part of the optic cup, and from there gradually extends towards the cup margin. All the layers of the retina are completed by the eighth month of fœtal life.

FIG. 152.—A section through the eye of a rabbit embryo, about eighteen days old. × 30. (Kölliker.)

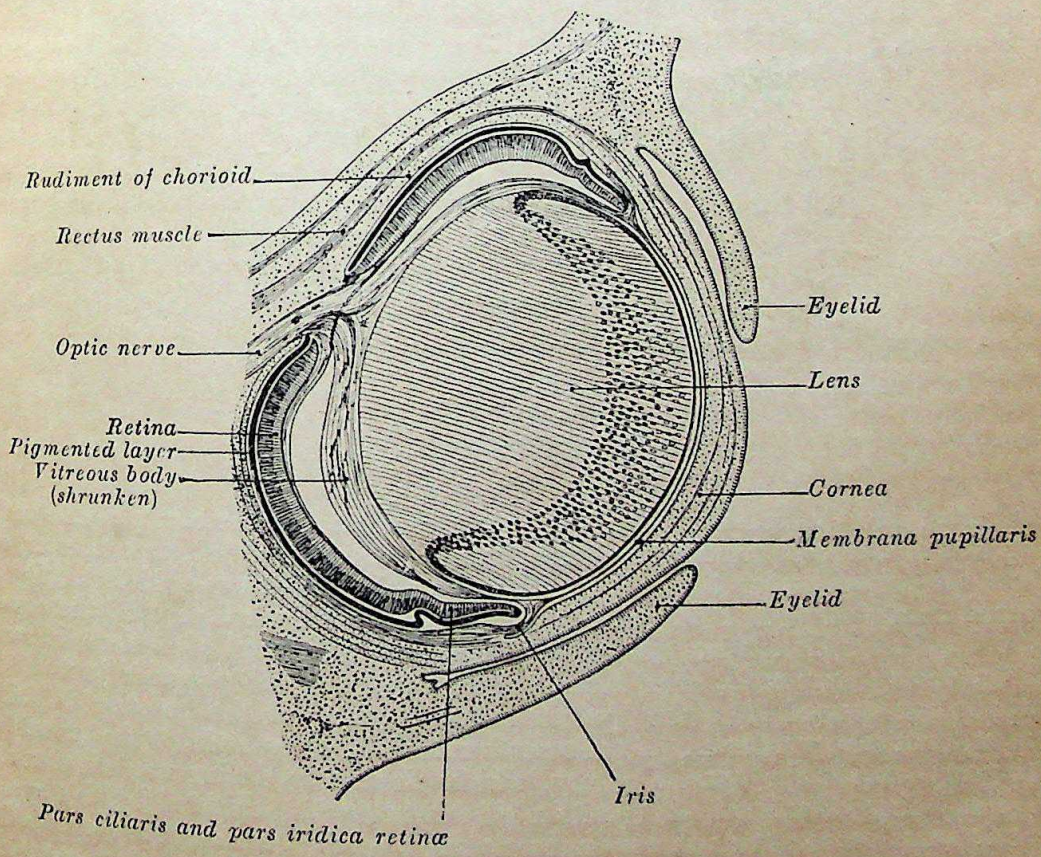

The optic stalk is converted into the optic nerve by the obliteration of its cavity and the growth of nerve-fibres into it. Most of these fibres are centripetal, and

CC-0. In Public Domain. Gurukul Kangri Collection, Haridwar

Digitized by Arya Samaj Foundation Chennai and eGangotri

are the axons of the nerve-cells of the ganglionic layer of the retina, but a fe centrifugal and are derived from nerve-cells in the brain. The fibres of the nerve receive their medullary sheaths about the tenth week after birth. The chiasma is formed by the meeting and partial decussation of the fibres of the optic nerves. Behind the chiasma the fibres are continued backwards as the tracts to the thalami and mesencephalon.

The crystalline lens is developed from the lens-vesicle, which recedes the margin of the cup, and becomes separated from the overlying ectoder mesoderm. The cells forming the posterior wall of the vesicle lengthen an

Fig. 153.—A sagittal section through the eye of a human embryo, about six weeks old. (Kollmann.)

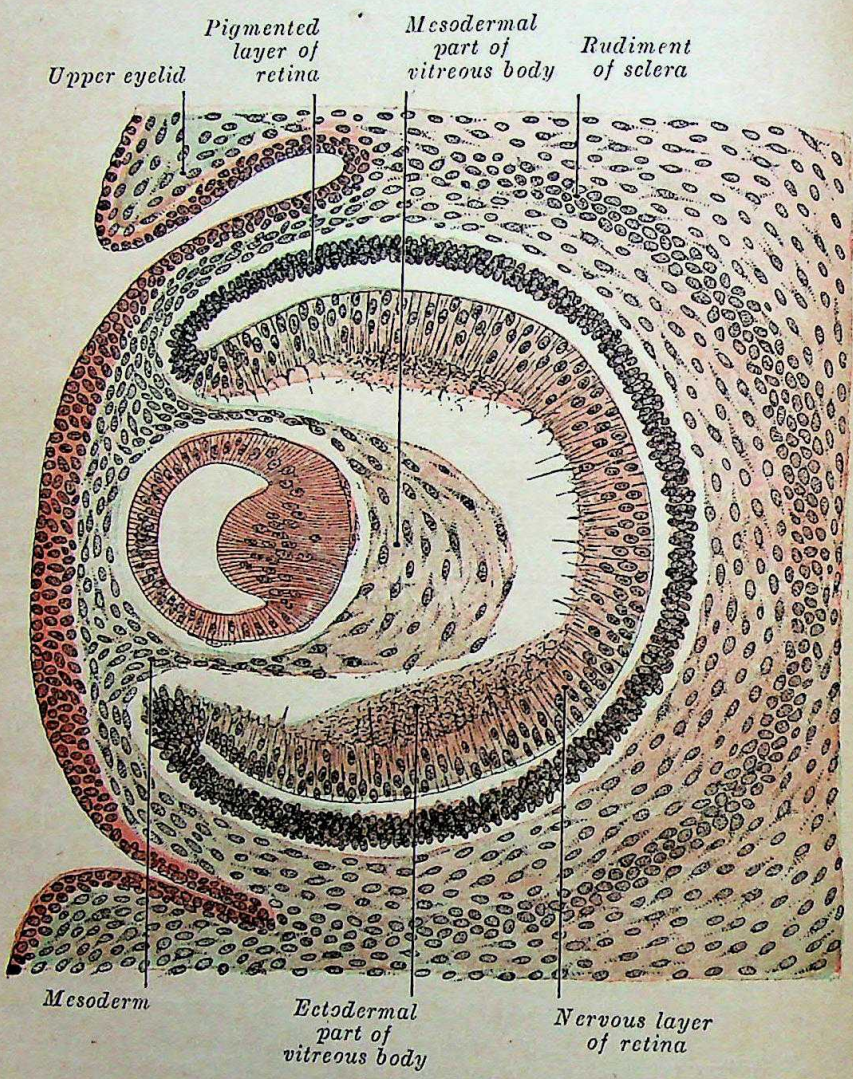

converted into the lens-fibres, which grow forward and fill the cavity of the ves (fig. 152). The cells forming the anterior wall retain their cellular character, a form the epithelium on the anterior surface of the fully developed lens. By second month the lens is invested by a vascular mesodermal capsule, the *caps vasculosa lentis*, the anterior part of which, covering the front of the lens, is nam the *pupillary membrane*; the blood-vessels supplying the posterior part of t capsule are derived from the hyaloid artery; those for the anterior part fr the anterior ciliary arteries. By the sixth month all the vessels of the capsule atrophied except the hyaloid artery, which disappears during the ninth mon of fœtal life; after birth the position of this artery is indicated by the hyal canal, which reaches from the optic disc to the posterior surface of the lens. W the loss of its blood-vessels the capsula vasculosa lentis disappears, but sometim the pupillary membrane persists at birth, giving rise to the condition term *congenital atresia of the pupil.*

CC-0. In Public Domain. Gurukul Kangri Collection, Haridwar

Digitized by Arya Samaj Foundation Chennai and eGangotri

The vitreous body is developed between the lens and the optic cup. The lens-diment and the optic vesicle are at first in contact with each other, but after the osure of the lens-vesicle and the formation of the optic cup the former is withdrawn om the retinal layer of the cup; the two, however, remain connected by a network delicate protoplasmic processes. This network, derived partly from the cells the lens and partly from those of the retinal layer of the cup, constitutes the rimitive vitreous body (figs. 153, 154). At first these protoplasmic processes spring om the whole of the retinal layer of the cup, but later are limited to the ciliary egion, where by a process of condensation they appear to form the zonula ciliaris. he mesoderm which enters the cup through the chorioidal fissure and around he equator of the lens becomes intimately united with this reticular tissue, and ontributes to form the vitreous body, which is therefore derived partly from the ctoderm and partly from the mesoderm.

FIG. 154.—A section through the developing eye of a trout. (Szily.)

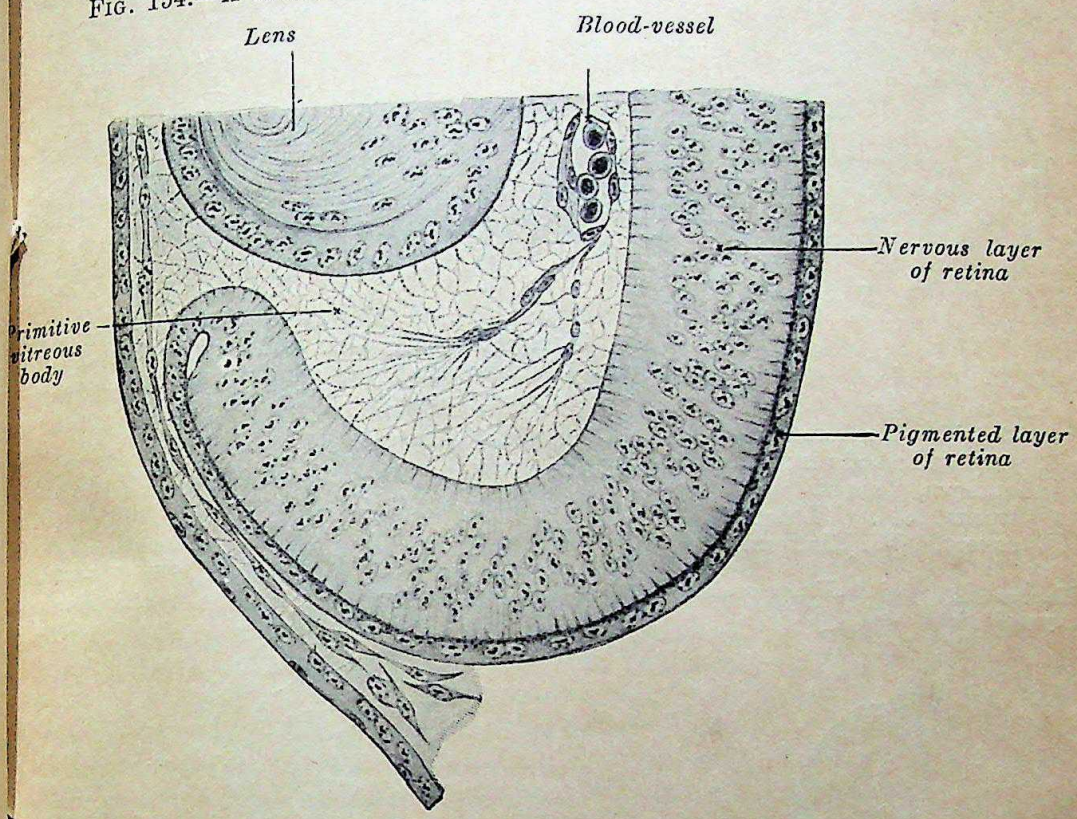

The aqueous chamber of the eye appears as a cleft in that part of the mesoderm hich intervenes between the lens and the ectoderm. The layer of mesoderm in ront of the cleft forms the substantia propria of the cornea, that behind the cleft he stroma of the iris and the pupillary membrane. The fibres of the Ciliaris muscle re derived from the mesoderm, but those of the Sphincter and Dilatator pupillæ re of ectodermal origin, being developed from the cells of the pupillary part of the ptic cup.

The sclera and chorioid are derived from the mesoderm surrounding the optic cup.

The eyelids are formed as small cutaneous folds (fig. 152). About the middle f the third month their edges come together and unite in front of the cornea; they emain united until about the end of the sixth month.

The epithelium of the alveoli and ducts of the lacrimal gland arise as a series f tubular buds from the ectoderm of the superior conjunctival fornix; these buds re arranged in two groups, one forming the superior or orbital, and the other the nferior or palpebral, part of the gland. The lacrimal sac and nasolacrimal duct esult from a thickening of the ectoderm in the *naso-optic furrow* between the lateral asal and maxillary processes (p. 79). This thickening forms a solid cord of cells hich sinks into the mesoderm; during the third month the central cells of the ord break down, and a lumen, the naso-lacrimal duct, is established. The lacrimal ucts or canaliculi arise as buds from the upper part of the cord of cells and econdarily establish openings (puncta lacrimalia) on the margins of the lids; the

CC-0. In Public Domain. Gurukul Kangri Collection, Haridwar

Digitized by Arya Samaj Foundation Chennai and eGangotri

inferior duct cuts off a small part of the lower eyelid to form the caruncula lacri (Ask). The epithelium of the cornea and conjunctiva is of ectodermal orig are also the eyelashes and the lining cells of the tarsal and other glands which on the margins of the eyelids.

The ears.—The rudiments of the internal ears appear shortly after those o eyes, as two patches of thickened, surface ectoderm, the *auditory plates*, ov region of the hind-brain. Each auditory plate is invaginated and converted the *auditory pit* (fig. 155). The mouth of the pit is then closed, and a v the *auditory vesicle* or *otocyst*, is formed (fig. 156); from it the epithelial

FIG. 155.—A section through the hind-brain and auditory pits of a human embryo, about twelve days old. (Kollmann.)

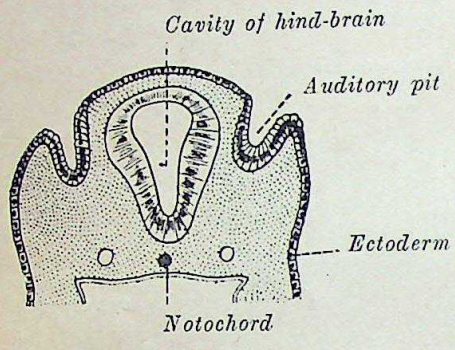

FIG. 156.—A section through t hind-brain and auditory vesicl of an embryo more advanc than that of fig. 155. (Aft His.)

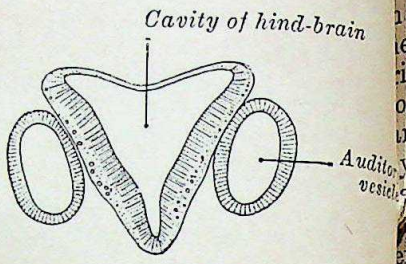

FIG. 157.—The left auditory vesicle of a human embryo, about four weeks old. Lateral aspect. (W. His, jun.)

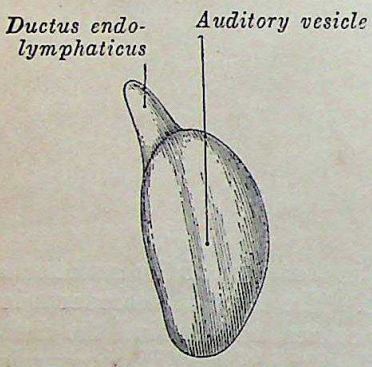

FIG. 158.—The left auditory vesicle of a human embryo, about five weeks old. Lateral aspect. (W. His, jun.)

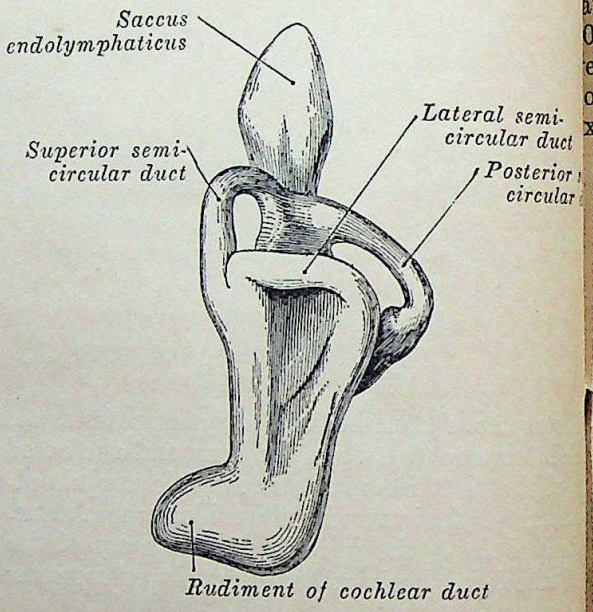

of the membranous labyrinth is derived. The vesicle assumes a flask-shape, the neck of the flask is obliterated (fig. 157). From the vesicle certain diverti are given off which form the various parts of the membranous labyrinth. from the middle part forms the ductus and saccus endolymphaticus. A second, f the anterior end, elongates, and forms the coiled tube of the cochlear duct, proximal or vestibular extremity of which is subsequently constricted to f the canalis reuniens. Three others appear as disc-like evaginations on the sur of the vesicle; the central parts of the walls of the discs coalesce and disap while the peripheral portions of the discs persist to form the semicircular duc the superior duct is the first, and the lateral the last, to be completed (fig. 1 The central part of the vesicle represents the membranous vestibule, and is s divided by a constriction into a smaller ventral part, the saccule, and a lar dorsal and posterior part, the utricle (fig. 159). This subdivision is effected a fold which extends deeply into the proximal part of the ductus endolymphatic

CC-0. In Public Domain. Gurukul Kangri Collection, Haridwar

Digitized by Arya Samaj Foundation Chennai and eGangotri

th the result that the utricle and saccule ultimately communicate with each her by means of a Y-shaped canal. The saccule opens into the cochlear duct, rough the canalis reuniens; the semicircular ducts communicate with the utricle. The mesoderm surrounding the various parts of the epithelial labyrinth is nverted into a cartilaginous ear-capsule, and this is finally ossified to form the ny labyrinth. The portion of the psule which envelopes the semi- rcular canals chondrifies before hat which surrounds the cochlea. or a time the cartilaginous capsule incomplete, and the cochlear, estibular, and genicular ganglia are tuated in the gap between its nalicular and cochlear parts. hese ganglia are soon covered by outgrowth of cartilage and at e same time the facial nerve is idged by a growth of cartilage om the cochlear to the canalicular rts of the capsule. In the em- yonic connective tissue between e cartilaginous capsule and the thelial wall of the labyrinth the erilymphatic spaces are developed. treeter* states that the rudiment the vestibular perilymphatic pace, or *periotic cistern* as he iggests this space should be named, an be seen in an embryo of from 0 to 40 mm. in length, in the reticulum between the saccule and the fenestra estibuli. The scala tympani is next developed, and begins opposite the fenestra ochleæ; the scala vestibuli is the last to appear. The two scalæ gradually xtend along either side of the ductus cochlearis and when they reach its tip, an opening which represents the helicotrema, is developed between them. The modiolus and the osseous spiral lamina of the cochlea are not preformed in cartilage but are ossified directly from connective tissue.

FIG. 159.—The left membranous labyrinth of a human embryo, 30 mm. long. (From a model by W. His, jun.)

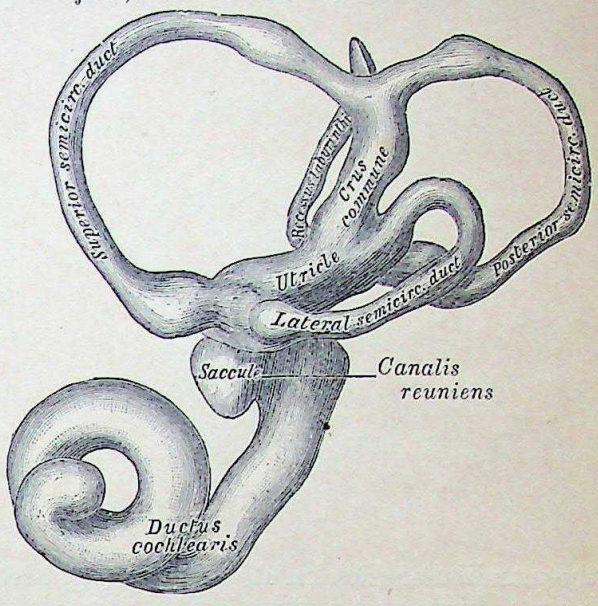

FIG. 160.—The tubercles from which the different parts of the auricula are developed. (His.)

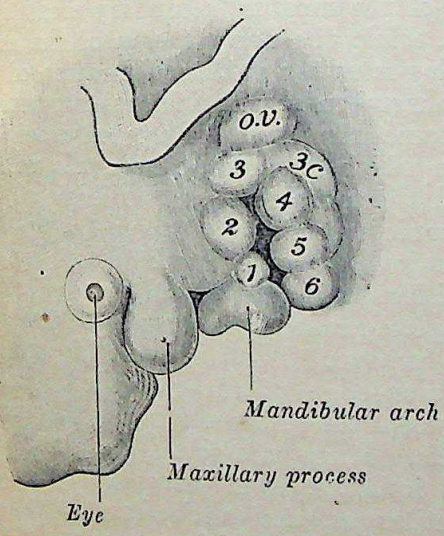

2. Tubercles on mandibular arch. 3. Tubercle above groove. 3, c. Prolongation of 3 downwards. 4, 5, 6. Tubercles on hyoid arch. *o.v.* Auditory vesicle.

The auditory tube and tympanic cavity were formerly regarded as being derived from the first pharyngeal pouch, but Frazer† has recently pointed out that they are developed from a recess, the *tubotympanic recess*, between the first and third visceral arches, the floor of the recess consisting of the first and second arches and the first and second pharyngeal pouches. By the forward growth of the third arch the inner part of the recess is narrowed to form the tubal region, and the inner part of the second arch is excluded from this portion of the floor. The outer part of the recess is subsequently developed into the tympanic cavity, and the floor of this part forms the outer wall of the tympanic cavity up to about the level of the chorda ympani nerve. From this it will be seen that the outer wall of the tympanic avity has both first and second arch elements in it, the share taken by the rst arch being limited to the part in front of the handle of the malleus. The

* George L. Streeter, *American Journal of Anatomy*, vol. xxi.

† J. Ernest Frazer, *Journal of Anatomy and Physiology*, vol. xlviii.

CC-0. In Public Domain. Gurukul Kangri Collection, Haridwar

Digitized by Arya Samaj Foundation Chennai and eGangotri

area of the second arch includes the outer wall behind this, and turns on t back wall to take in the tympanohyal region.' During the sixth or seventh m the tympanic antrum appears as an upward and backward expansion o tympanic cavity.

The opinion generally held as to the development of the ossicles o middle ear is that the *incus* and *malleus* are derived from the dorsal e

FIG. 161.—The left auriculæ of human embryos, estimated to be thirty-fi and thirty-eight days old respectively. (After His.)

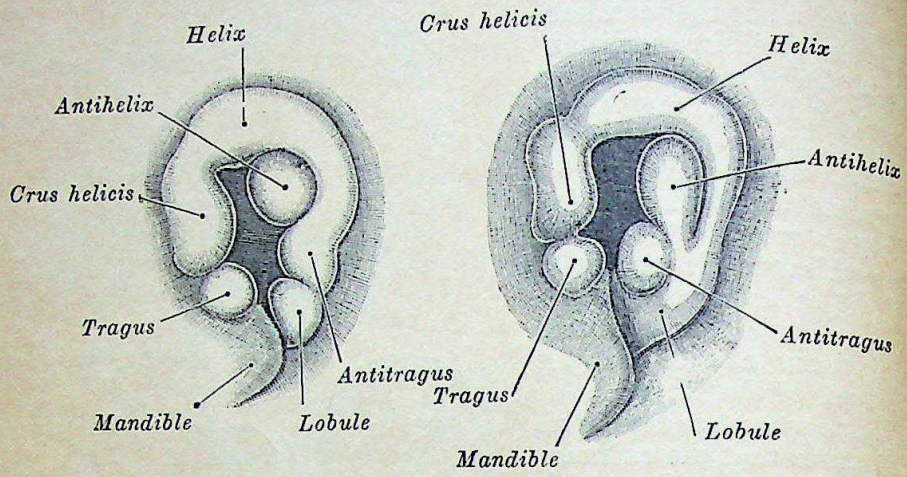

the mandibular (Meckel's) cartilage (fig. 116), the incus representing the qua bone of birds and reptiles. The *stapes* is developed from the dorsal end o cartilage of the second or hyoid arch, and first appears as a ring (annulus stap encircling a small vessel, the stapedial artery, which subsequently undergoes atro

The external acoustic meatus is developed from the first branchial or pharyngeal groove. The lower part of this groove extends inwards as a fu shaped tube (primary meatus) from which the cartilaginous portion and a s part of the roof of the osseous portion of the meatus are developed. From lower part of the funnel-shaped tube a solid epidermal plug extends downw and inwards along the floor of the tubotympanic recess; by the breaking dow the central cells of this plug the inner part of the meatus (secondary meatu produced, while the deepest cells of the e dermal plug form the epidermal stratum o tympanic membrane. The fibrous stratu the tympanic membrane is formed from mesoderm which extends between the m plate and the entoderm of the floor o tubotympanic recess.

FIG. 162.—The auricula in a more advanced stage of development than those represented in fig. 161.

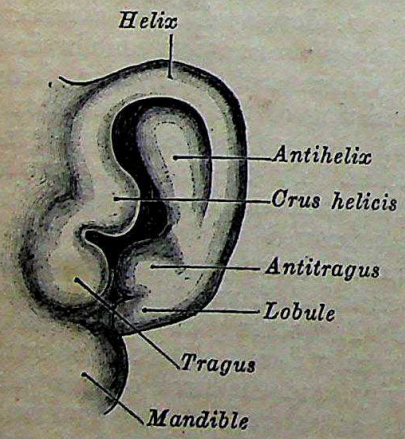

The auricula or pinna is developed by gradual differentiation of six tubercles (fig. which appear around the margin of the branchial groove. Two tubercles appear the posterior edge of the mandibular a these represent the rudiments of the tragus crus helicis. Three are found on the h arch, and indicate, from below upwards, lobule, antitragus, and antihelix. One a dorsal to the first branchial groove, and g downwards behind the antitragus and antihe from it and its downward prolongation helix is developed (figs. 161, 162). S observers, however, maintain that the lowest tubercle on the hyoid arch beco the antitragus, and that the lobule is developed later as an independent forma The rudiment of the *acoustic nerve* appears about the end of the third wee the acoustic ganglion which is closely applied to the cephalic edge of auditory vesicle; the cells of this ganglion are probably derived from the ectod

CC-0. In Public Domain. Gurukul Kangri Collection, Haridwar

Digitized by Arya Samaj Foundation Chennai and eGangotri

the auditory vesicle. The acoustic ganglion divides into the vestibular ganglion d the spiral ganglion of the cochlea; their nerve-cells are bipolar, each sending proximal fibre into the neural tube, and a distal fibre to the epithelial cells of e auditory vesicle.

THE DEVELOPMENT OF THE VASCULAR SYSTEM

The blood-corpuscles and the blood-vessels first make their appearance between e entoderm and the mesoderm in three regions, viz.: (*a*) on the surface of the lk-sac, (*b*) in the body-stalk, and (*c*) in the chorion.* The cells become arranged to solid strands or cords, which llectively form what His termed e *angioblast*. These strands join form a close-meshed network, e *area vasculosa*, which covers the tire yolk-sac. The peripheral ls of the strands become flat-ed and joined to each other their edges to form the endo-elium of the walls of the primi-e blood-vessels. Fluid collects thin the strands and converts em into tubes, and the more ntrally situated cells of the strands are thus pushed to the sides of the vessels d appear as masses of loosely-arranged cells projecting towards the lumen of e tube. These masses are termed *blood-islands* (figs. 163, 164); their cells are tached to form the primary blood-corpuscles (mesamœboids of Minot). The rliest blood-vessels, therefore, are formed at several separate centres; from e walls of these vessels buds grow out, become vascularised and converted into w vessels, and join with those of neighbouring areas to form a close meshwork. ang † maintains that in the ferret embryo there is evidence to show that the gins of the blood-corpuscles and the endothelium of the blood-vessels are separate and distinct—the blood-corpuscles arising from the entoderm, and the vascular endothelium from the mesoderm; the blood-corpuscles are engulfed by the endothelium of the growing vessels and in this way enter their lumina. His was of opinion that the vessels within the embryo were developed as extensions of this network, but probably they arise independently. Most observers agree that, after the aortæ have appeared, no other dependent vessels are laid down, i.e. all new vessels are derived from pre-isting ones.

FIG. 163.—A section through the vascular area to show the differentiation of the primitive vascular cells. Diagrammatic.

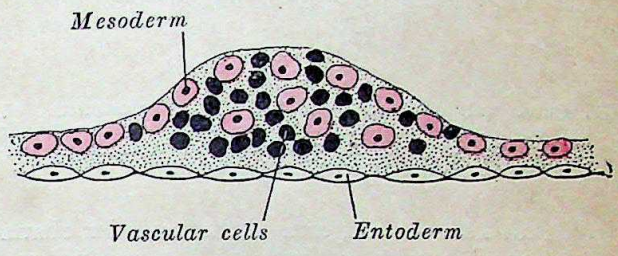

FIG. 164.—A section through a developing blood-vessel. Diagrammatic.

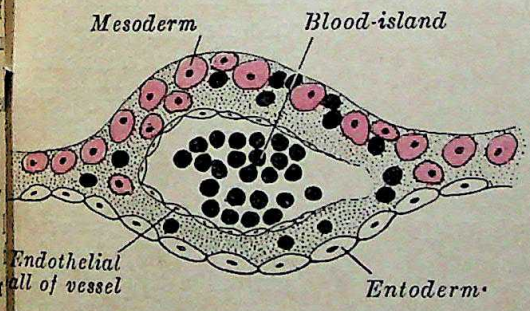

The red and the colourless corpuscles of the blood are derived from the *mesamœ-ds*. The earliest blood-corpuscles are thus all nucleated; they are also capable subdivision and of executing amœboid movements. Some mesamœboids acquire louring matter (hæmoglobin); their nuclei disintegrate and are extruded, and e non-nucleated red corpuscles or erythrocytes result. Other mesamœboids ain their nuclei; some remain in the blood as the leucocytes; others wander t into the tissues, particularly into the liver, the lymphoid tissues, and the arrow of the bones, where they form specialised collections from which the rpuscles of the blood are regenerated. From the mesamœboids five chief forms

* Consult an article "On the earliest blood-vessels in Man" by J. L. Bremer in the *Anatomical cord*, vol. viii. Feb. 1914.

† Chung-Ching Wang, *Journal of Anatomy*, vol. lii. parts 1 and 2.

CC-0. In Public Domain. Gurukul Kangri Collection, Haridwar

Digitized by Arya Samaj Foundation Chennai and eGangotri

are derived: (1) erythrocytes, (2) lymphocytes, (3) finely granular or neu leucocytes, (4) coarsely granular or eosinophil leucocytes, (5) degenerati basiphil leucocytes (p

Fig. 165.—A transverse section through the region of the heart of a rabbit embryo, nine days old. × 80. (Kölliker.)

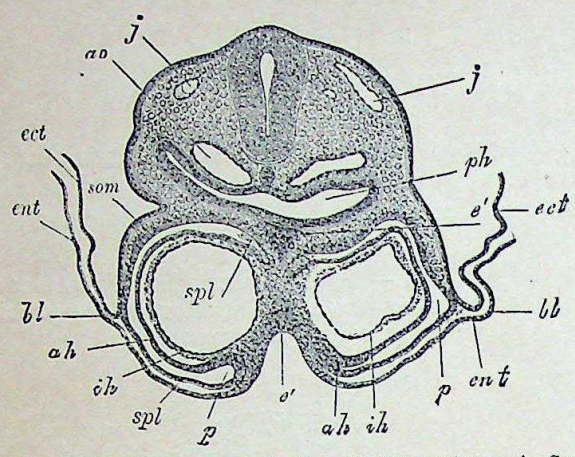

ah. Outer wall of heart. *ao.* Aorta. *bl.* Proamnion. *e'.* Septum between heart-tubes. *ect.* Ectoderm. *ent.* Entoderm. *ih.* Endothelial lining of heart. *j, j.* Jugular veins. *p.* Pericardium. *ph.* Pharynx. *som.* Somatopleure. *spl.* Splanchnopleure.

Fig. 166.—A diagram of the vascular channels in a human embryo of the second week. (After Eternod.) (From Quain's Elements of Anatomy, vol. i., Embryology.)

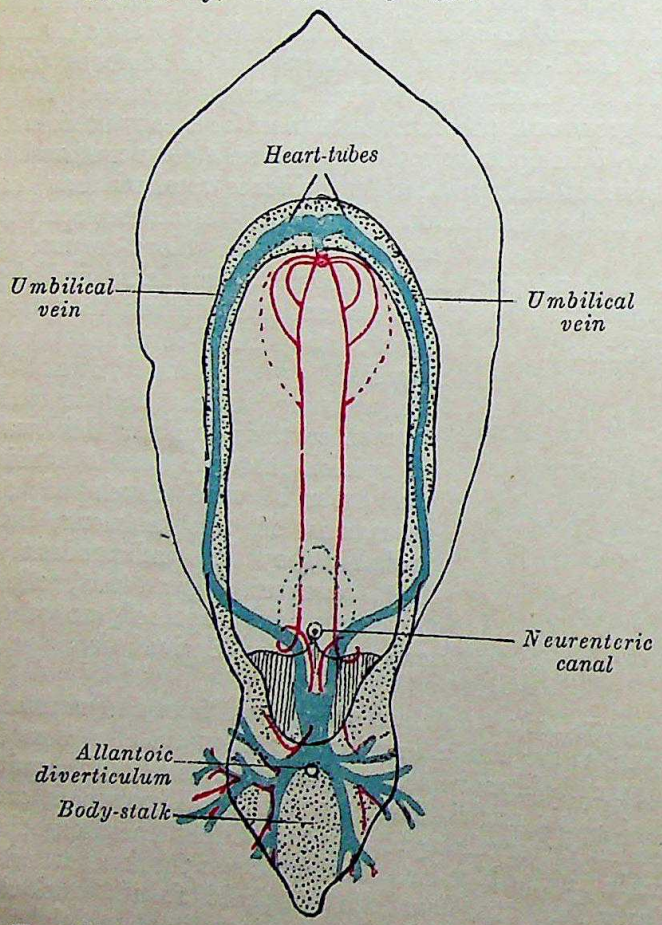

The red lines are the dorsal aortæ continued into the umbilical arteries. The red dotted lines are the ventral aortæ, and the blue dotted lines the vitelline veins.

Minot describes stages in the develop the red blood-corpus (*a*) *the ichthyoid* blo containing granular and representing the nent blood-cells of fish the *sauroid blood-cel* rived from but small the former; they rep the permanent blood- reptiles, and their contain a dense netw chromatin which stain deeply; (*c*) the *blood-p* or early red blood-corp which are at first sp in shape; they are non- ated and found onl mammals.

The earliest stage the development of human heart and b vessels have not yet seen, but it may be sumed that they are lar to those occurrin other mammals. As al stated (p. 109), b vessels are first deve in the wall of the yolk and in the body-stalk chorion, and it is st matter of doubt wh the blood-vessels w the embryo arise as ex sions from those of yolk-sac (His), or are veloped from vascular *in situ*, and subsequ establish connexions w those of extra-embry origin.

The first rudimen the heart appears in form of a pair of tub vessels (primitive ao which are developed i a mass of cells in splanchnopleure of pericardial area (fig. These two vessels backwards, one on e side of the notochord, pass into the body- along which they carried as the umb arteries to the chorion

By the forward gr and flexure of the head the pericardial area and the anterior portions of the prim aortæ are folded under the head and come to lie on the ventral aspect of the fore-

CC-0. In Public Domain. Gurukul Kangri Collection, Haridwar

Digitized by Arya Samaj Foundation Chennai and eGangotri

and each vessel now consists of a ventral part, a dorsal part, united by an arch; these three parts are named respectively the ventral aorta, the dorsal aorta, and the first aortic arch. The first aortic arches pass through the mandibular arches,

FIG. 167.—A human embryo, about fourteen days old, with yolk-sac. (After His.)

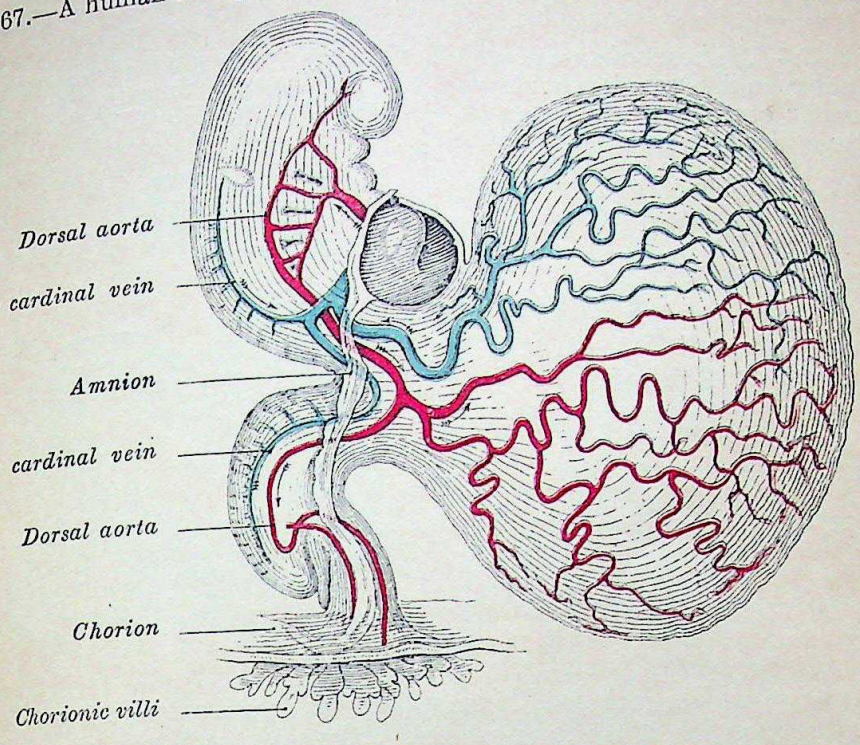

and behind them five additional pairs subsequently develop, so that altogether six pairs of aortic arches are formed.

In the pericardial region the two primitive aortæ, which from the first lie close together, come into contact and the partition between them disappears, and thus a single tubular heart is formed (fig. 168); from the cephalic end of the heart the ventral aortæ arise and into its caudal end the umbilical and vitelline veins pour their contents.

FIG. 168.—The head of a chick embryo, about thirty-eight hours old. Ventral aspect. × 26. (From Duval's Atlas d'Embryologie.)

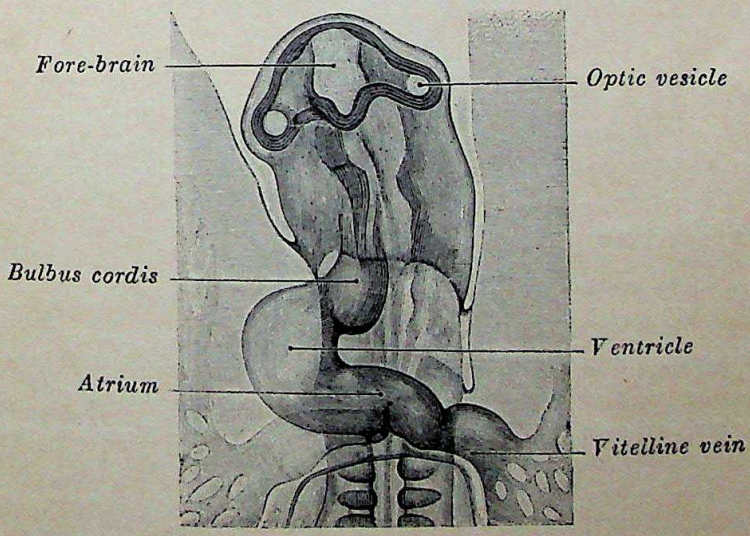

Eternod * described the circulation in a human embryo which measured 1·3 mm. in length and was devoid of mesodermal somites (fig. 166). The rudiment of the heart was situated immediately below the fore-gut and consisted of a short stem.

* *Anat. Anzeiger*, Bd. xv. 1899.

CC-0. In Public Domain. Gurukul Kangri Collection, Haridwar

Digitized by Arya Samaj Foundation Chennai and eGangotri

It gave off two vessels, the primitive aortæ, which ran backwards, one on side of the rudiment of the notochord, and then passed into the body-stalk, which they were carried to the villi of the chorion. From the chorionic vi blood was returned by a pair of umbilical veins which united in the body-st form a single vein (vena umbilicalis impar); on reaching the embryo thi

Fig. 169.—The heart of an early embryo, to illustrate its simple tubular condition. (From an Ecker-Ziegler model.)

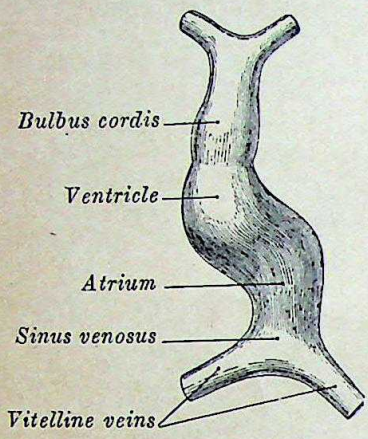

Fig. 170.—The heart of a human embryo, about fourteen days old. (From a model by His.)

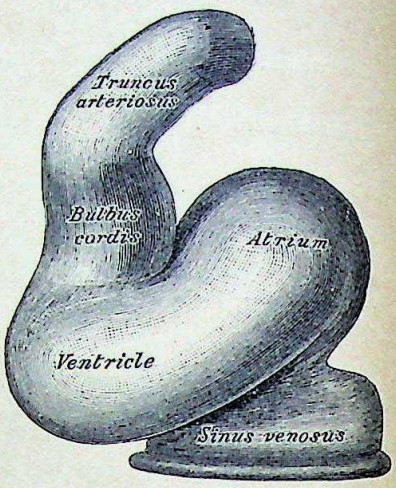

divided into two which encircled the mouth of the yolk-sac and opened into heart. At the junction of the yolk-sac and body-stalk each vein was joined transitory vitelline vein from the vascular plexus of the yolk-sac. The transi vitelline veins are replaced by the true vitelline veins which return the blood the yolk-sac, and enter the embryo through the anterior wall of the umbi orifice (figs. 167, 168). They then traverse the septum transversum, a ban mesoderm which lies between the pericardium and the yolk-sac; in this sep each vitelline vein unites with the corresponding umbilical vein to form the *com*

Fig. 171.—The heart of a human embryo, about fifteen days old. (From a reconstruction by His.)

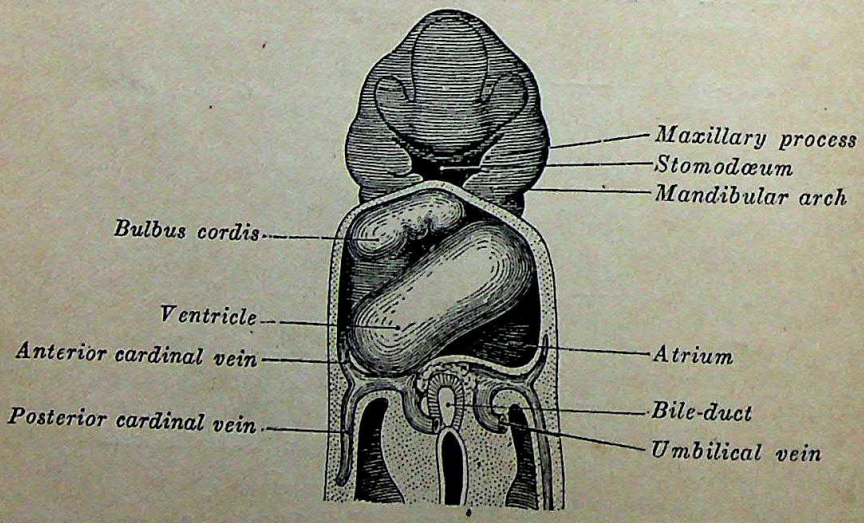

vitello-umbilical vein which opens into the caudal end (sinus venosus) of the tub heart. The vitello-umbilical veins are soon joined by a pair of anterior cardi (primitive jugular) veins from the head, and a little later each anterior cardinal v is joined by a posterior cardinal vein from the trunk and limbs, and the short tru (duct of Cuvier) formed by the union of these two veins opens into the correspondi

CC-0. In Public Domain. Gurukul Kangri Collection, Haridwar

Digitized by Arya Samaj Foundation Chennai and eGangotri

llo-umbilical vein. The sinus venosus expands in a transverse direction and rporates the adjoining parts of the vitello-umbilical veins which come to form right and left horns of the sinus; into the horns of the sinus the three venous nks, viz. the vitelline vein, the umbilical vein and the duct of Cuvier, open. The r is developed in the septum transversum, and in the course of its development vitelline and umbilical veins undergo important transformations which will be plained later (p. 124).

With the atrophy of the yolk-sac the vitelline circulation diminishes and ultitely ceases, and an increasing amount of blood is carried through the umbilical eries to the villi of the chorion. Subsequently, as the non-placental chorionic li atrophy, their vessels disappear; and then the umbilical arteries convey the ole of the blood from the embryo to the placenta, whence it is returned to the bryo by the umbilical veins.

FIG. 172.—The heart of a human embryo, about thirty-five days old. Dorsal aspect. (From a model by His.)

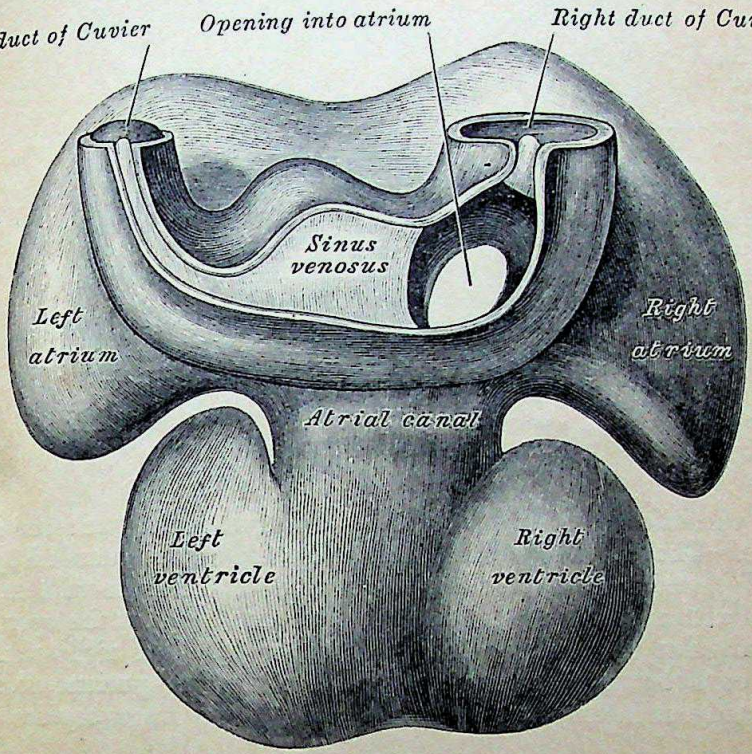

The **further development of the heart.**—The simple tubular heart, already deibed (p. 111), elongates and bends so as to form an S-shaped loop, the anterior part nvex ventrally and to the right, and the posterior, dorsally and to the left (fig. 170). e intermediate portion arches transversely from left to right, and then turns rply forward into the anterior part of the loop. Slight constrictions make their pearance in the tube and divide it from behind forwards into five parts, viz.: the *sinus venosus*; (2) the *atrium*; (3) the *ventricle*; (4) the *bulbus cordis*, and the *truncus arteriosus* (fig. 170). The constriction between the atrium and ntricle constitutes the *atrial canal* (fig. 172), and indicates the site of the future rioventricular valves.

The sinus venosus is situated in the septum transversum behind the atrium, d opens into the latter by a median aperture. The sinus is at first placed transrsely but soon assumes an oblique position and a crescentic shape (fig. 172); right half or horn increases in size more rapidly than its left, and the sinus opens o the right portion of the atrium. The right horn of the sinus is ultimately orporated with and forms a part of the right atrium, the line of union between and the auricula being indicated in the interior of the adult atrium by a vertical st, the *crista terminalis* of His. The left horn, which ultimately receives only left duct of Cuvier, persists as the coronary sinus (fig. 172). The vitelline and bilical veins are later replaced by a single vessel, the inferior vena cava, and the

CC-0. In Public Domain. Gurukul Kangri Collection, Haridwar

Digitized by Arya Samaj Foundation Chennai and eGangotri

three veins (inferior vena cava and right and left ducts of Cuvier) open in dorsal part of the atrium by a common slit-like aperture (fig. 173). The upp of this aperture represents the opening of the permanent superior vena ca

FIG. 173.—The heart of a human embryo, about thirty days old. The inter of the dorsal half. (From a model by His.)

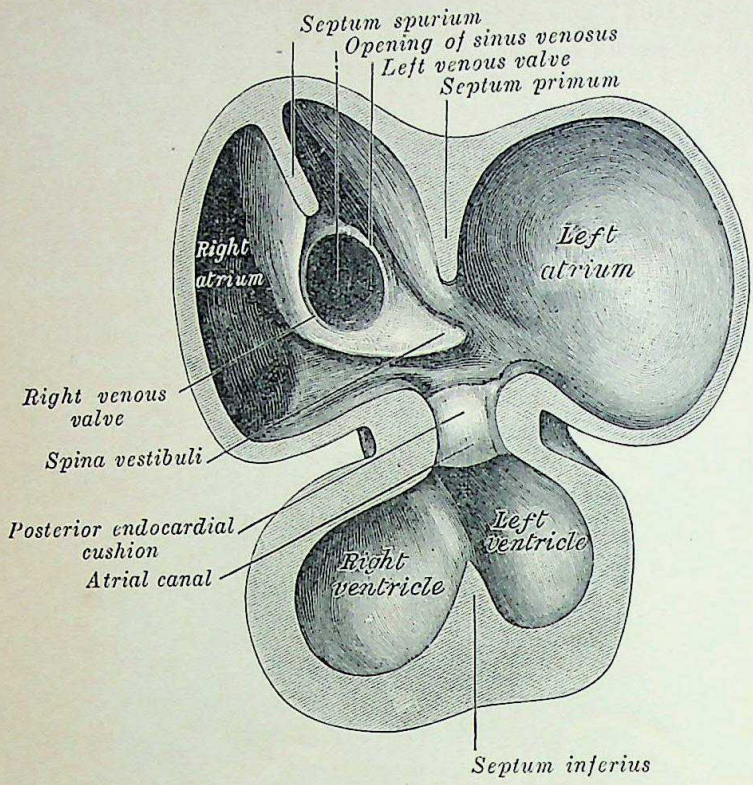

lower that of the inferior vena cava, and the intermediate part the orifice coronary sinus. The slit-like aperture lies obliquely, and is guarded by two the *right* and *left venous valves*; above the opening these unite with each othe are continuous with a fold named the *septum spurium*; below the opening the to form a triangular thickening—the *spina vestibuli*. The right venous va retained; its cephalic portion, together with the septum spurium, forms the terminalis already mentioned. A small septum, the *sinus septum*, grows

FIG. 174.—A heart showing the expansion of the atria. (From an Ecker-Ziegler model.)

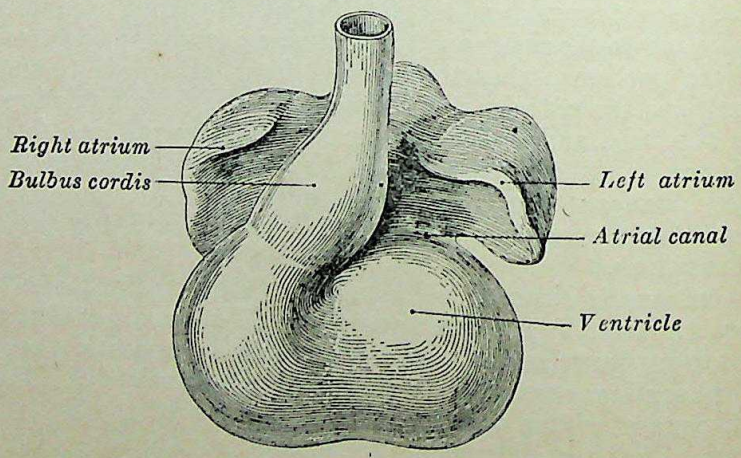

the posterior wall of the sinus venosus to fuse with the right venous valve divide its caudal portion into two parts—an upper, the valve of the inferior cava, and a lower, the valve of the coronary sinus. The upper and middle

CC-0. In Public Domain. Gurukul Kangri Collection, Haridwar

Digitized by Arya Samaj Foundation Chennai and eGangotri

the left venous valve disappear; the lower one-third is continued into the spina stibuli, and later fuses with the septum secundum of the atria and takes part the formation of the limbus fossæ ovalis.

The atrial canal is at first a short straight tube connecting the atrial with the ntricular portion of the heart, but its growth being relatively slow, it is gradually erlapped by the atria and ventricles so that its position on the surface of the art is indicated only by an annular constriction (fig. 174). Its lumen is reduced a transverse slit, and two thickenings, or *endocardial cushions* (fig. 173), appear, e on its dorsal, and the other on its ventral wall. These endocardial cushions oject into the atrial canal, and, meeting in the middle line, unite to form the *ptum intermedium*, which divides the canal into two channels, the future right d left atrioventricular orifices.

Fig. 175.—The heart of a human embryo, about thirty-five days old. The interior of the dorsal half. (From a model by His.)

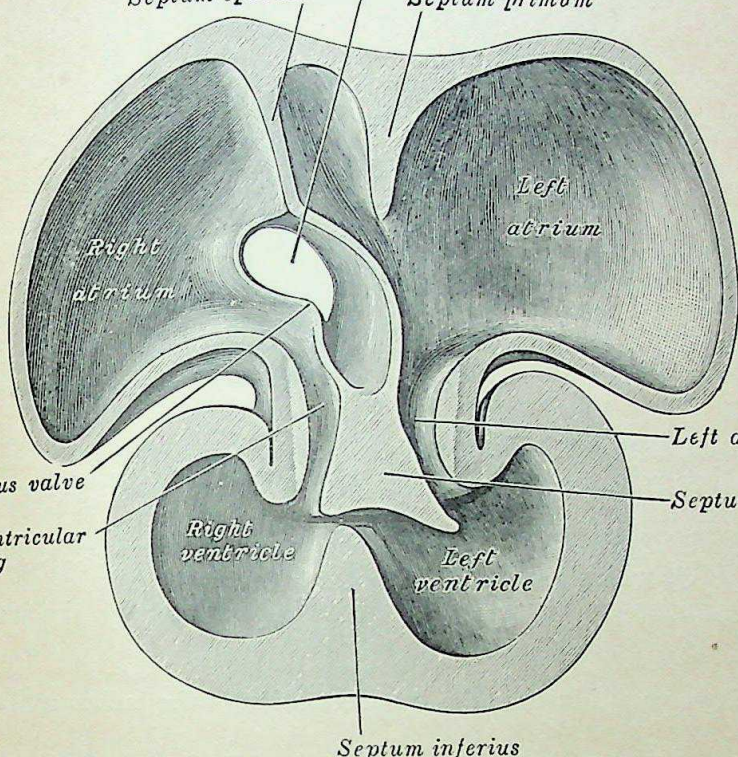

The atrium grows rapidly, and by its lateral expansion partially encircles the lbus cordis. The latter thus comes to lie in a groove which is the first indication the ultimate division of the atrium into right and left chambers, the division ing effected by a septum, the *septum primum* (figs. 173, 175), which grows from e dorsal to the ventral wall of the cavity. For a time the atria communicate ith each other by an opening, the ostium primum of Born, in front of the free argin of the septum primum. This opening is closed by the union of the septum imum with the septum intermedium, but before this closure occurs a new opening developed in the dorsal part of the septum primum; this new opening is known the foramen ovale (ostium secundum of Born) and persists until birth. A escentic septum, the *septum secundum* (fig. 176), grows from the upper and dorsal all of the atrium immediately to the right of the septum primum and foramen vale. The horns of this crescentic septum fuse with the ventral part of the septum imum, and the intervening free part of the septum secundum overlaps the foramen vale and septum primum; the dorsal part of the latter septum acts as a flap-like lve which allows the blood to flow from the right into the left atrium, but not an opposite direction. After birth, the free edge of the septum secundum blends ith the septum primum and the foramen ovale is closed; sometimes the fusion incomplete and the upper part of the foramen remains patent.

CC-0. In Public Domain. Gurukul Kangri Collection, Haridwar

Digitized by Arya Samaj Foundation Chennai and eGangotri

Issuing from either lung is a pair of pulmonary veins which unite to f single vein, and these in turn join with one another to form a common trunk opens into the left atrium. Subsequently the common trunk and the two

FIG. 176.—The heart of a human embryo, about thirty-five days old. Open on right side. (From a model by His.)

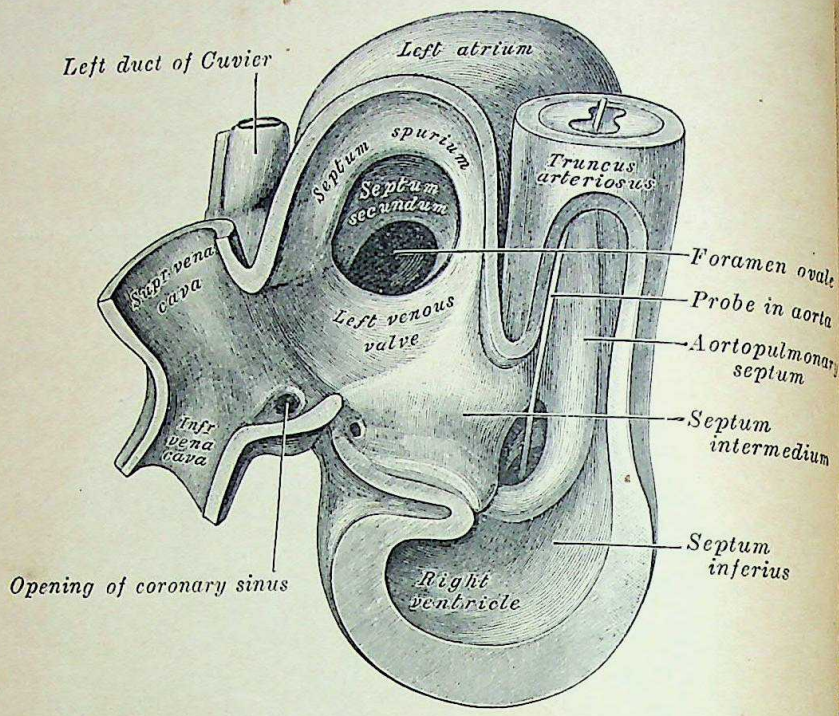

forming it expand and form the vestibule or greater part of the left atrium expansion reaching as far as the orifices of the four veins which thus open separ into the adult left atrium.

The ventricle is divided by a septum, the *septum inferius* or *ventricular se* (figs. 173, 175, 176), which grows upwards from the lower part of the ventricl position on the surface of the heart being indicated later by the interventri

FIG. 177.—Diagrams to illustrate the transformation of the bulbus cordis. (Keit

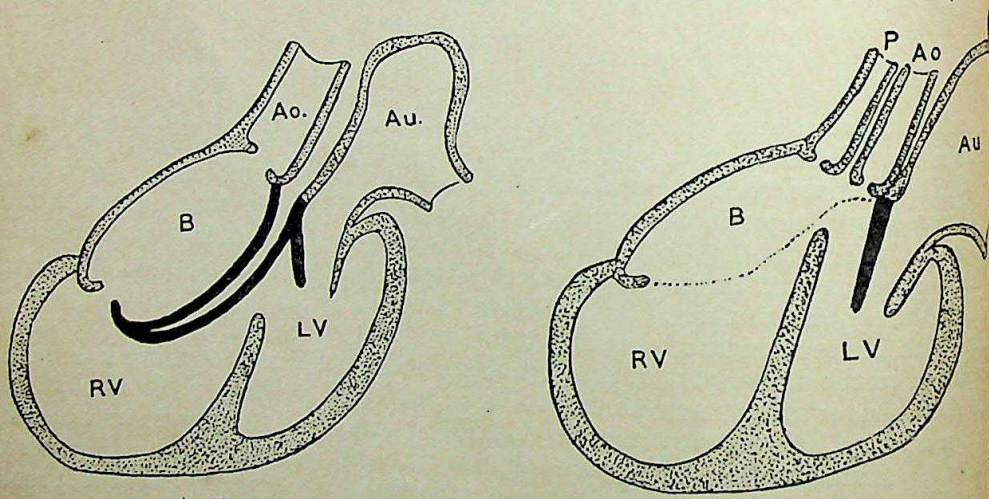

Ao. Truncus arteriosus. *Au.* Atrium. *B.* Bulbus cordis. *LV.* Left ventricle. *P.* Pulmonary artery. *RV.* Right ventricle.

sulcus. Its dorsal part increases more rapidly than its ventral portion, and f with the dorsal endocardial cushion. Above its ventral portion there exists f time an interventricular foramen (fig. 176).

CC-0. In Public Domain. Gurukul Kangri Collection, Haridwar

Digitized by Arya Samaj Foundation Chennai and eGangotri

When the heart assumes its S-shape the bulbus cordis lies in front of and ventral to the ventricle. The adjacent walls of the bulbus cordis and ventricle approximate and fuse, and the fused portion projects as a ridge, the *bulboventricular ridge*, between the bulbus cordis and the ventricle; the narrow passage which

FIG. 178.—A diagram showing the relations at an early stage between the atrioventricular opening and ventricles, the cavity of the bulbus cordis, and the bulboventricular ridge. The endocardial cushions at the distal end of the bulb are shown in a more differentiated state than they really exhibit at this stage. (J. Ernest Frazer.)

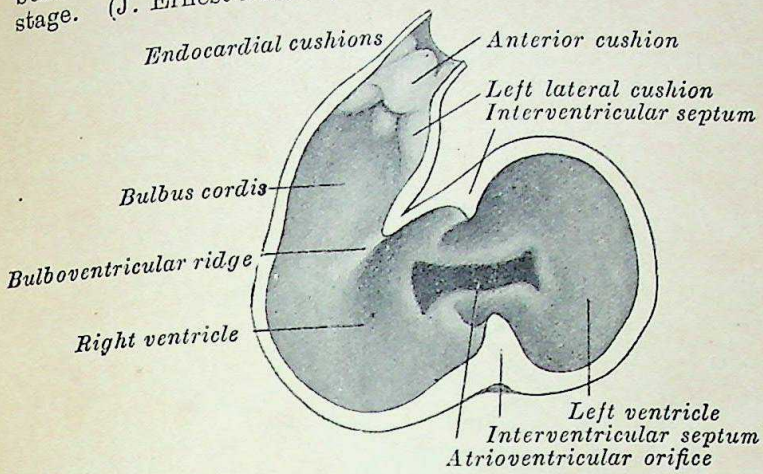

nnects these cavities is placed at the right of the atrioventricular orifice (fig. 178). he bulboventricular ridge soon disappears, and the opening from the ventricle into e bulbus cordis is widened, and lies over the right half of the atrioventricular pening (fig. 179). By the upgrowth of the ventricular septum the bulbus cordis in great measure separated from the left ventricle, but remains an integral part the right ventricle, of which it forms the infundibulum (fig. 177).

The truncus arteriosus and bulbus cordis are divided by a septum which makes s appearance in three portions. (1) Two ridge-like thickenings project into the men of the distal part of the truncus arteriosus; these increase in size and ultiately meet and fuse to form the *aortopulmonary septum* (fig. 176), which takes a

FIG. 179.—A diagram to show the intermediate stages of the aortic and pulmonary channels. (J. Ernest Frazer.)

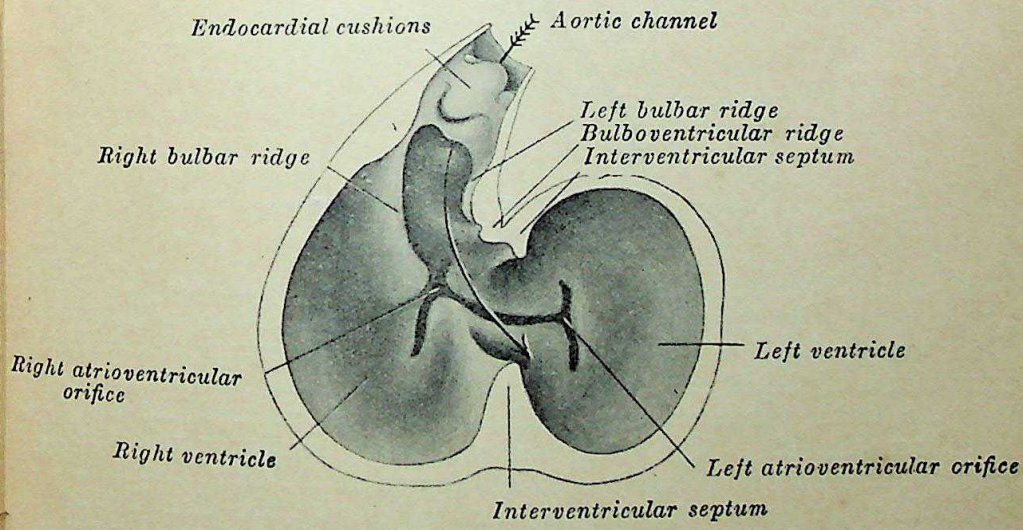

piral course towards the proximal end of the truncus arteriosus. It divides the uncus arteriosus into the aorta and the pulmonary artery. (2) Four endocardial ushions, anterior, posterior, right and left, appear at the distal end of the bulbus ordis (fig. 178). The right and left cushions meet and fuse to form the *distal bulbar*

CC-0. In Public Domain. Gurukul Kangri Collection, Haridwar

Digitized by Arya Samaj Foundation Chennai and eGangotri

septum which is joined by the aortopulmonary septum. (5) Two endocardial the *right and left bulbar ridges*, develop in the bulbus cordis (fig. 179) and unite the *proximal bulbar septum* which is continuous above with the distal septum. Its lower edge fuses with the ventricular septum and brings the ventricle into communication with the pulmonary artery, and through the with the sixth pair of aortic arches; while the left ventricle is brought in tinuity with the aorta, which communicates with the remaining aortic The completed ventricular septum consists of a lower, muscular, and an membranous, part; the former is developed from the septum inferius, the from the bulbar septum.

FIG. 180.—A human embryo estimated to be twenty or twenty-one days o Right lateral aspect. (After His.)

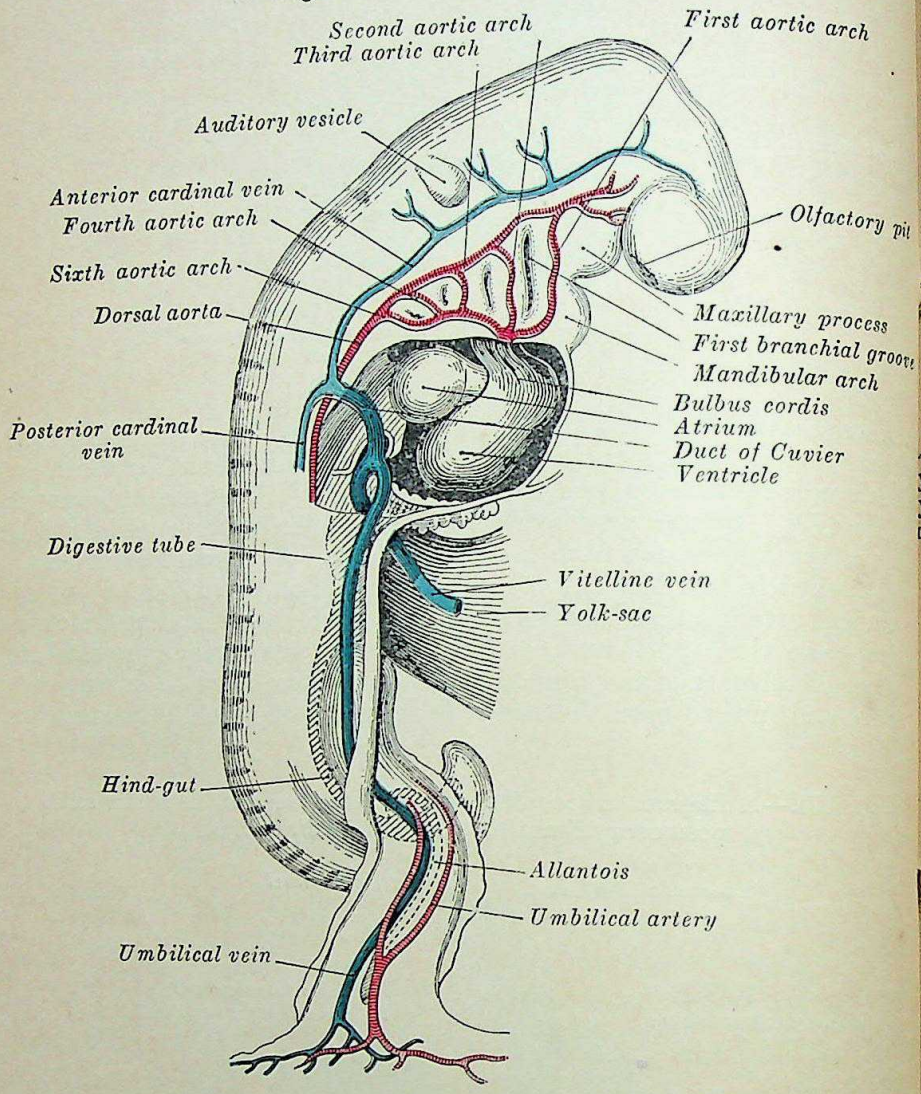

The valves of the heart.—The atrioventricular valves are developed in relati the atrial canal. By the upward expansion of the bases of the ventricles the becomes invaginated into the ventricular cavities. The invaginated margin the rudiments of the lateral cusps of the atrioventricular valves; the med septal cusps of the valves are developed as downward prolongations of the se intermedium (fig. 181). The aortic and pulmonary semilunar valves are fo from the four endocardial cushions which appear at the distal end of the b cordis. When the aortopulmonary septum unites with the distal bulbar se the lateral endocardial cushions are each divided into two, thus giving rise thickenings—the rudiments of the semilunar valves—three at the aortic and at the pulmonary orifice.

Applied Anatomy.—In rare cases portions of the various cardiac septa may develop, or some of the endocardial cushions may fuse in an abnormal manner giving

CC-0. In Public Domain. Gurukul Kangri Collection, Haridwar

Digitized by Arya Samaj Foundation Chennai and eGangotri

various forms of congenital heart disease. Thus, the ventricular septum may fail almost irely, and a heart with but one ventricle results; more commonly the failure is only tial, leaving a patent septum ventriculorum. Various degrees of patency of the foramen

FIG. 181.—Section of a fœtal heart. (His.)

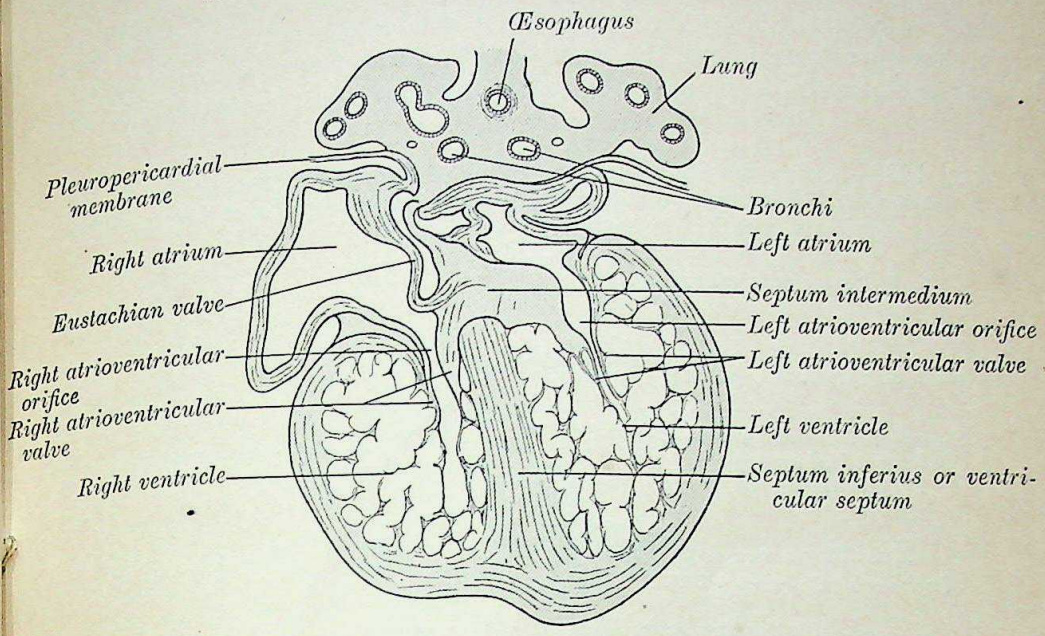

le have also been noted. Stenosis (narrowing) of the aortic and pulmonary orifices y possibly be related to defective development of the bulbus cordis; sometimes there y be only two cusps in the aortic or pulmonary valves. Complete atresia (non-perfora-n) of the pulmonary orifice is a very rare anomaly.

FIG. 182.—A scheme of the aortic arches and their transformations. (Modified from Kollmann.)

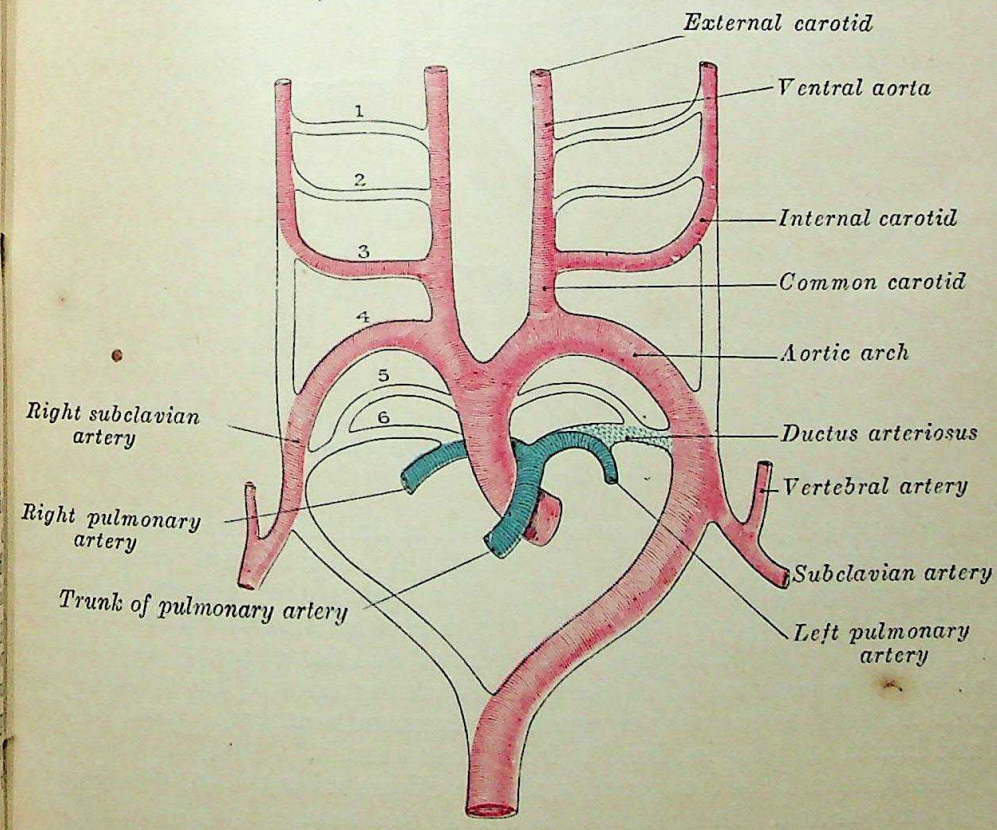

The **further development of the arteries.**—Recent observations show that none the main vessels of the adult arise as single trunks in the embryo. At the site of

CC-0. In Public Domain. Gurukul Kangri Collection, Haridwar

Digitized by Arya Samaj Foundation Chennai and eGangotri

each vessel a capillary network forms, and by the enlargement of definite p this network the larger arteries and veins are developed. The branches main arteries are not always simple modifications of the vessels of the ca network, but may arise as new outgrowths from the enlarged stem.

It has been seen (p. 111) that each primitive aorta consists of a vent a dorsal part which are continuous through the first aortic arch. The dorsa at first run backwards separately on either side of the notochord, but in th week they fuse from about the level of the fourth thoracic to that of the lumbar segment to form a single trunk, the descending aorta. The first

FIG. 183.—A diagram showing the origins of the main branches of the caro arteries. (Founded on Tandler by T. H. Bryce.) (From Quain's Eleme of Anatomy, vol. i., Embryology.)

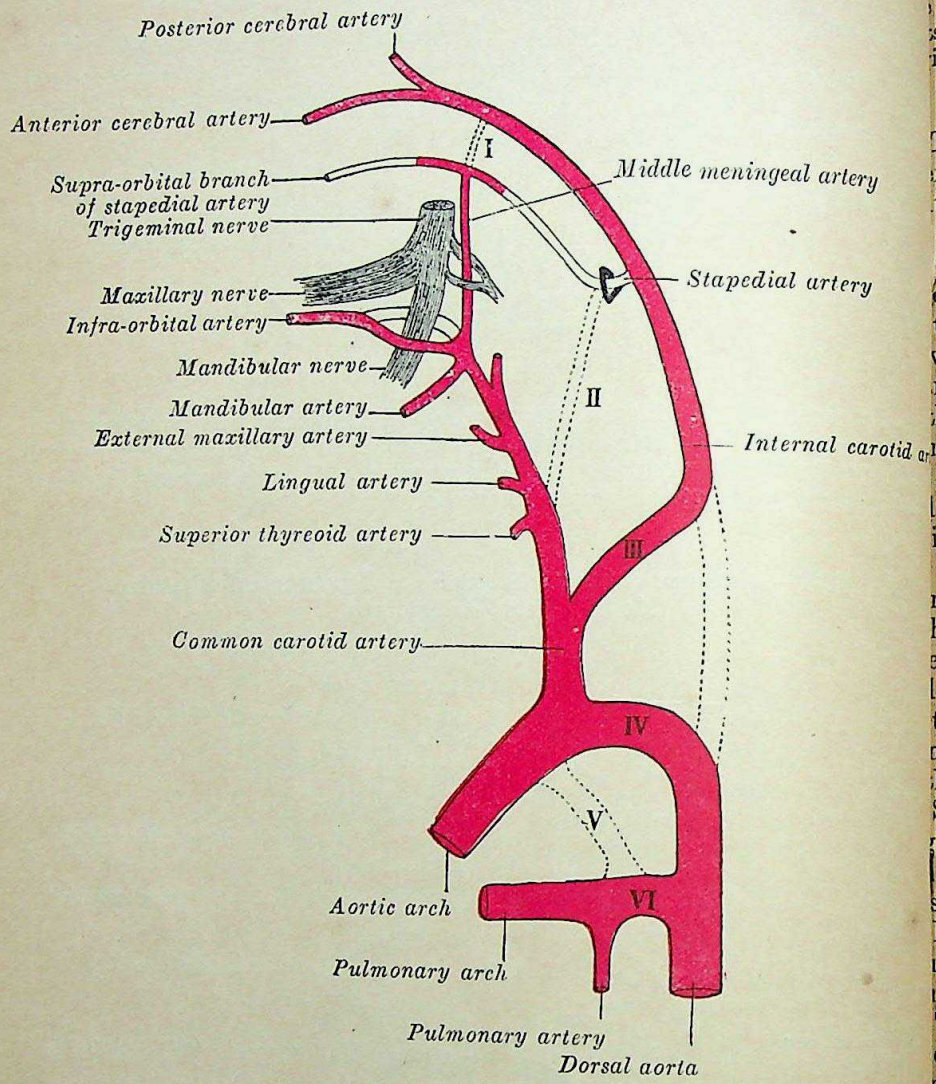

arches run through the mandibular arches, and behind them five additional pai developed within the corresponding visceral arches; so that, in all, six pairs of arches are formed (figs. 180, 182). The fifth arches are very transitory v connecting the truncus arteriosus with the dorsal ends of the sixth arches. first and second arches pass between the ventral and dorsal aortæ, while the arise at first by a common stem from the truncus arteriosus, but end separat the dorsal aortæ. As the neck elongates, the ventral aortæ are drawn out, an third and fourth arches arise directly from these vessels.

In fishes the aortic arches persist and give off branches to the gills, in whic blood is oxygenated. In mammals some of the arteries remain as perm structures, while others disappear or are obliterated (fig. 182).

The ventral aortæ.—These persist on both sides. The right ventral aorta f as far as the fourth aortic arch, the innominate artery, and beyond that arc

CC-0. In Public Domain. Gurukul Kangri Collection, Haridwar

Digitized by Arya Samaj Foundation Chennai and eGangotri

t common and external carotid arteries. The left gives rise to (*a*) the portion he aortic arch between the origins of the innominate and left common carotid ries; (*b*) the left common and external carotid arteries.

The aortic arches.—The first and second arches disappear, but the dorsal end he second gives origin to the stapedial artery (fig. 183), a vessel which atrophies nan but persists in some mammals (e.g. the rat).

The stapedial artery passes through the ring of the stapes and divides into supra-ital, infra-orbital, and mandibular branches which follow the three divisions of the eminal nerve. The infra-orbital and mandibular branches arise from a common n, the terminal part of which anastomoses with the external carotid. On the teration of the stapedial artery this anastomosis enlarges and forms the internal illary artery, and the branches of the stapedial artery are now branches of this vessel. common stem of the infra-orbital and mandibular branches passes between the two s of the auriculotemporal nerve and becomes the middle meningeal artery; the inal supra-orbital branch of the stapedial artery is represented by the orbital twigs of middle meningeal artery.

The third aortic arch constitutes the commencement of the internal carotid ry, and is therefore named the *carotid arch*. The fourth right arch forms the t subclavian as far as the origin of its internal mammary branch, while the fourth arch constitutes the arch of the aorta between the origin of the left common tid artery and the termination of the ductus arteriosus. The fifth arch dis-ears on both sides. The sixth right arch disappears; the sixth left arch gives the pulmonary arteries and forms the ductus arteriosus; this duct remains vious during fœtal life, but is obliterated a few days after birth and forms the mentum arteriosum of the adult. His showed that in the early embryo the h arch on either side gives a branch to the corresponding lung, but later both monary arteries take origin from the left arch.

The dorsal aortæ.—In front of the third aortic arches the dorsal aortæ persist form the continuations of the internal carotid arteries; these arteries pass to the in, and each divides into an anterior and a posterior branch, the former giving off ophthalmic artery and the anterior and middle cerebral arteries, while the latter ns back and joins the cerebral part of the vertebral artery. Behind the third h the right dorsal aorta disappears as far as the point where the two dorsal aortæ e to form the descending aorta. The part of the left dorsal aorta between the third fourth arches disappears, while the remainder persists to form the descending t of the arch of the aorta. A constriction, the *aortic isthmus*, is sometimes n in the aorta between the origin of the left subclavian artery and the attachment he ductus arteriosus.

Sometimes the right subclavian artery arises from the aortic arch distal to the in of the left subclavian and passes upwards and to the right behind the trachea œsophagus. This condition may be explained by the persistence of the right sal aorta and the obliteration of the fourth right arch.

In birds the fourth right arch forms the arch of the aorta; in reptiles the rth arch persists on both sides and gives rise to the double aortic arch in these mals.

The heart originally lies on the ventral aspect of the pharynx, immediately dal to the stomodæum (fig. 180); with the elongation of the neck and the develop-nt of the lungs it recedes within the thorax, and, as a consequence, the anterior tral aortæ are drawn out and the original position of the fourth and fifth arches reatly modified. Thus, on the right side the fourth arch recedes to the root of neck, while on the left side it is withdrawn within the thorax. The recurrent ves originally pass to the larynx under the sixth pair of arches, and are therefore led backwards with the descent of these structures, so that in the adult the left ve hooks round the ligamentum arteriosum; owing to the disappearance of the h and the sixth right arches the right nerve hooks round that immediately above m, i.e. the commencement of the subclavian artery.

The primitive dorsal aortæ give off ventral, dorsal, and lateral groups of mental arteries.

The *ventral* segmental arteries, the first to be developed, are originally paired sels, but, after the fusion of the dorsal aortæ, appear as unpaired trunks; they distributed to the primitive digestive tube and to the wall of the yolk-sac. ee of them persist and constitute the coeliac, superior mesenteric, and inferior

CC-0. In Public Domain. Gurukul Kangri Collection, Haridwar

Digitized by Arya Samaj Foundation Chennai and eGangotri

mesenteric arteries of the adult. As the viscera supplied by these three descend into the abdomen, the vessels at the same time wander in a caudal di thus, the origin of the cœliac artery is transferred from the level of the cervical to that of the twelfth thoracic segment, the superior mesente

FIG. 184.—A diagram to illustrate the general development of the arteries of lower limb. The letter P indicates the position of the Popliteus; T of the Tibialis posterior; and H that of the Flexor hallucis lon (H. D. Senior.)

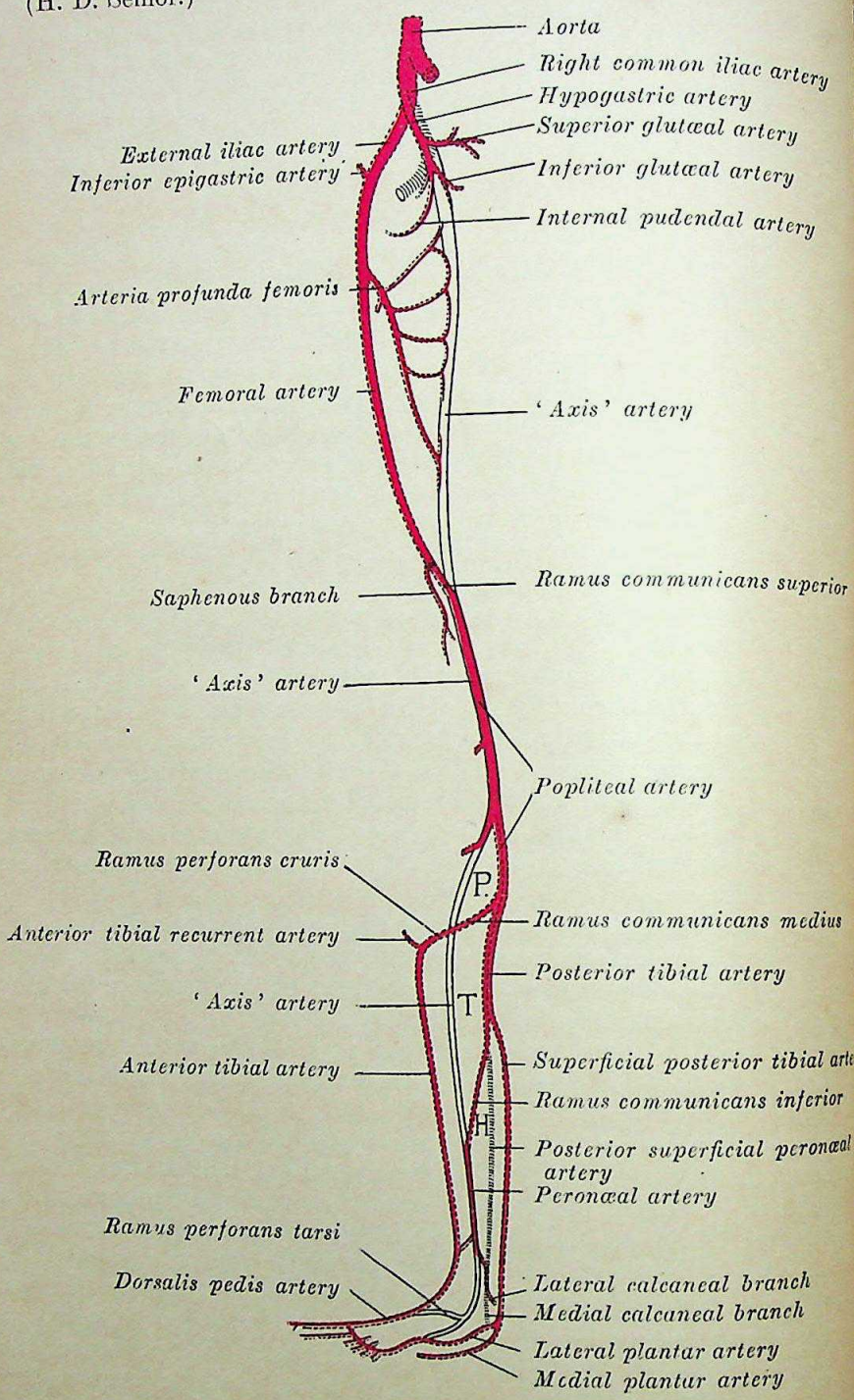

the second thoracic to the first lumbar segment, and the inferior mesenter the twelfth thoracic to the third lumbar segment.

The *dorsal* segmental arteries are at first distributed to the neural tu later give off parietal branches to the body-wall; these parietal branches p the thoracic and lumbar regions as the intercostal and lumbar arteries. Fr seventh pair the entire left subclavian artery, the greater part of the right sub artery, and the proximal part of the vertebral artery are derived; the ma

CC-0. In Public Domain. Gurukul Kangri Collection, Haridwar

Digitized by Arya Samaj Foundation Chennai and eGangotri

he cervical portion of the vertebral artery is developed from a longitudinal stomosis between the first seven dorsal segmental arteries. The second dorsal mental arteries run alongside the hypoglossal nerves to the brain and are named hypoglossal arteries. Each sends forwards a branch which forms the cerebral t of the vertebral artery and anastomoses with the posterior branch of the internal otid artery; the cerebral portions of the two vertebrals unite on the ventral face of the pons to form the basilar artery. The hypoglossal arteries atrophy, d then the cervical and cerebral parts of the vertebrals are connected by means the first pair of segmental arteries.

The *lateral* segmental arteries supply, on either side, the mesonephros or Wolffian ly and give branches to the testis (or ovary) and the suprarenal glands. One ticular (or ovarian) artery and three suprarenal arteries persist on either side. e inferior phrenic artery arises as a branch from the first, and the renal artery a branch from the third suprarenal artery. Additional renal arteries are frently present and may be looked on as branches of persistent lateral segmental eries.

The arteries of the limbs.—Several small arteries pass from the dorsal aorta into upper limb-bud, and form in it a free capillary anastomosis. Only one of these eries persists to form the arterial stem (subclavian artery) and the origin of this sistent vessel is transferred from the dorsal aorta to the seventh segmental ery. The subclavian artery is prolonged into the limb under the names of axillary and brachial arteries, and these together constitute the arterial stem the upper arm; the continuation of this stem in the forearm is represented by volar interosseous artery. A branch which accompanies the median nerve soon reases in size and forms the main vessel (median artery) of the forearm, while volar interosseous diminishes. Later the radial and ulnar arteries are developed as nches of the brachial part of the stem and coincidently with their enlargement median artery dwindles; occasionally it persists as a vessel of some size and ompanies the median nerve into the palm of the hand.

Senior has recently worked out the development of the arteries of the lower limb, d the following description is based on his observations.*

The primary arterial trunk (fig. 184) or 'axis' artery of the lower limb arises from e dorsal root of the umbilical artery, and courses along the dorsal surface of the igh, knee and leg; below the knee it lies between the tibia and the Popliteus uscle, and in the leg between the crural interosseous membrane and the Tibialis sterior muscle. It ends distally in a rete plantare, and gives off a perforating tery (ramus perforans tarsi) which traverses the sinus tarsi and forms a rete rsale. The femoral artery passes along the ventral surface of the thigh, and opens a new channel to the lower limb. It arises from a plexus of capillaries which is nnected proximally with the femoral branches of the external iliac artery, and stally with the ramus communicans superior of the axis artery. At the proximal rgin of the Popliteus the axis artery gives off two vessels, viz.: the posterior perficial tibial, and the posterior superficial peroneal arteries, and at the distal rgin of the same muscle it supplies a perforating branch (ramus perforans cruris) the front of the leg. A middle and an inferior communicating artery pass from the perficial peroneal to the axis artery, the former at the distal border of the Popliteus, d the latter at the distal border of the Tibialis posterior.

The femoral artery gradually increases in size, and coincidently with this increase most the whole of the axis artery, proximal to the ramus communicans superior sappears; the root of the axis artery, however, persists as the inferior glutæal tery. Two other segments of the distal part of the axis artery are maintained; e, just beyond the ramus communicans superior, which forms the proximal part the popliteal artery, the other, near the ankle, which forms a part of the peroneal tery.

The proximal portions of the posterior superficial tibial and posterior superficial roneal arteries fuse and form (*a*) the distal part of the popliteal artery, and (*b*) the st part of the posterior tibial artery, i.e. as far as the point where it gives off the roneal artery. The posterior superficial tibial artery ends in the medial plantar tery, and is largely retained to form the greater part of the posterior tibial artery. he posterior superficial peroneal artery ends in the lateral plantar artery, but e latter vessel is subsequently transferred to the posterior tibial artery. The

* H. D. Senior, *American Journal of Anatomy*, vol. xxv. 1919, and *Anatomical Record*, l. xvii. 1920.

CC-0. In Public Domain. Gurukul Kangri Collection, Haridwar

Digitized by Arya Samaj Foundation Chennai and eGangotri

part of the posterior superficial peroneal artery just distal to its fusion w posterior superficial tibial forms the proximal part of the peroneal arte remainder of the latter vessel consisting of (*a*) the ramus communicans i (*b*) a short persistent part of the axis artery, and (*c*) the distal portion of the p superficial peroneal artery and its lateral calcaneal branch. The anterio artery is derived from (*a*) the ramus communicans medius, (*b*) a short sectio axis artery, (*c*) the ramus perforans cruris and its continuation to the ankle tibialis anterior pars distalis). The arteries which are distributed on the of the foot are derived from the rete dorsale, while the plantar arch and its branches originate from the rete plantare.

The **further development of the veins.**—The principal veins of the embryo divided into two groups, visceral and parietal.

Fig. 185.—The liver, and the veins in connexion therewith, of a human embry twenty-four or twenty-five days old. Ventral aspect. (After His.)

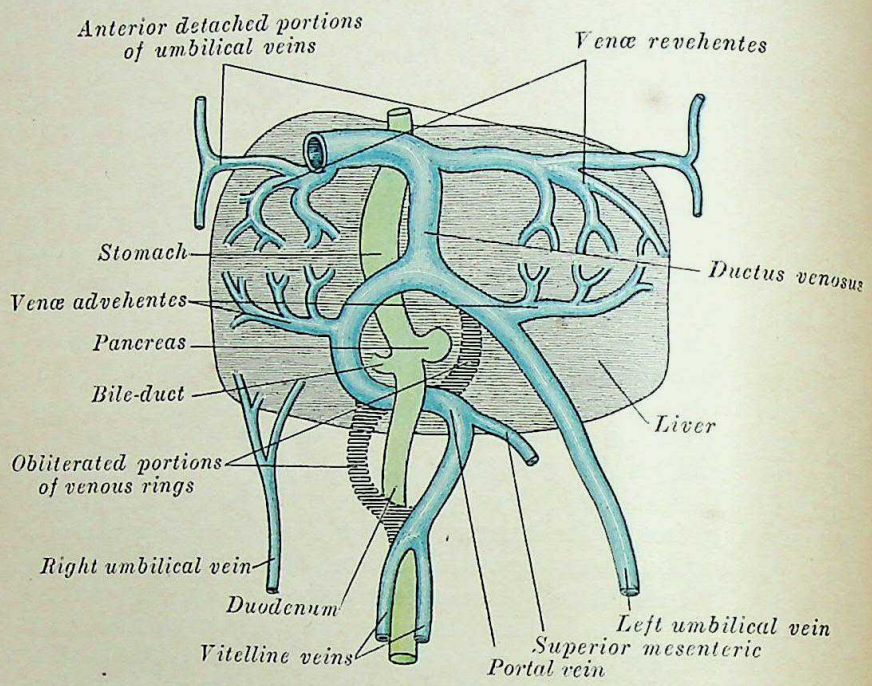

The visceral veins are the two vitelline veins bringing the blood from the yo and the two umbilical veins returning the blood from the placenta; these veins open close together into the sinus venosus.

The vitelline veins run upwards at first in front, and subsequently on side, of the digestive tube. They unite on the ventral surface of the tube beyond this are connected to one another by two anastomotic branches, one dorsal and the other on the ventral aspect of the duodenal portion of the inte which is thus encircled by two venous rings forming the figure 8 (fig. 185): the middle or dorsal anastomosis the superior mesenteric vein opens. The po of the veins above the upper ring become connected with a plexus of small cap like vessels termed *sinusoids* which form in the developing liver. The v conveying the blood to this plexus are named the *venæ advehentes*, and becom branches of the portal vein; while the vessels draining the plexus into the venosus are termed the *venæ revehentes*, and form the future hepatic veins (figs 186). After a time the left vena revehens no longer communicates directly the sinus venosus, but opens into the upper part of the right vena revehens hepatic vein). The persistent part of the upper venous ring, above the open the superior mesenteric vein, forms the trunk of the portal vein.

The two umbilical veins fuse to form a single trunk, the *vena umbilicalis* in the umbilical cord; this trunk divides within the embryo into the right an umbilical veins which pass forwards to the sinus venosus in the side walls o body. Like the vitelline veins, the direct connexion of the umbilical veins the sinus venosus becomes interrupted by the developing liver, and the whole

CC-0. In Public Domain. Gurukul Kangri Collection, Haridwar

Digitized by Arya Samaj Foundation Chennai and eGangotri

od from the yolk-sac and placenta passes through the substance of the liver before eaches the heart. The right umbilical and right vitelline veins shrivel and ppear; the left umbilical, on the other hand, enlarges and opens into the upper ous ring of the vitelline veins; with the atrophy of the yolk-sac the left vitelline n shrivels and disappears. Finally, a direct branch named the *ductus venosus* stablished between the upper venous ring and the right hepatic vein; the ductus osus enlarges rapidly and forms a wide channel through which most of the od, returned from the placenta, is carried direct to the heart without passing ough the liver. A small part of the blood from the placenta is, however, conveyed

FIG. 186.—A human embryo with the heart and anterior body wall removed to show the sinus venosus and its tributaries. (After His.)

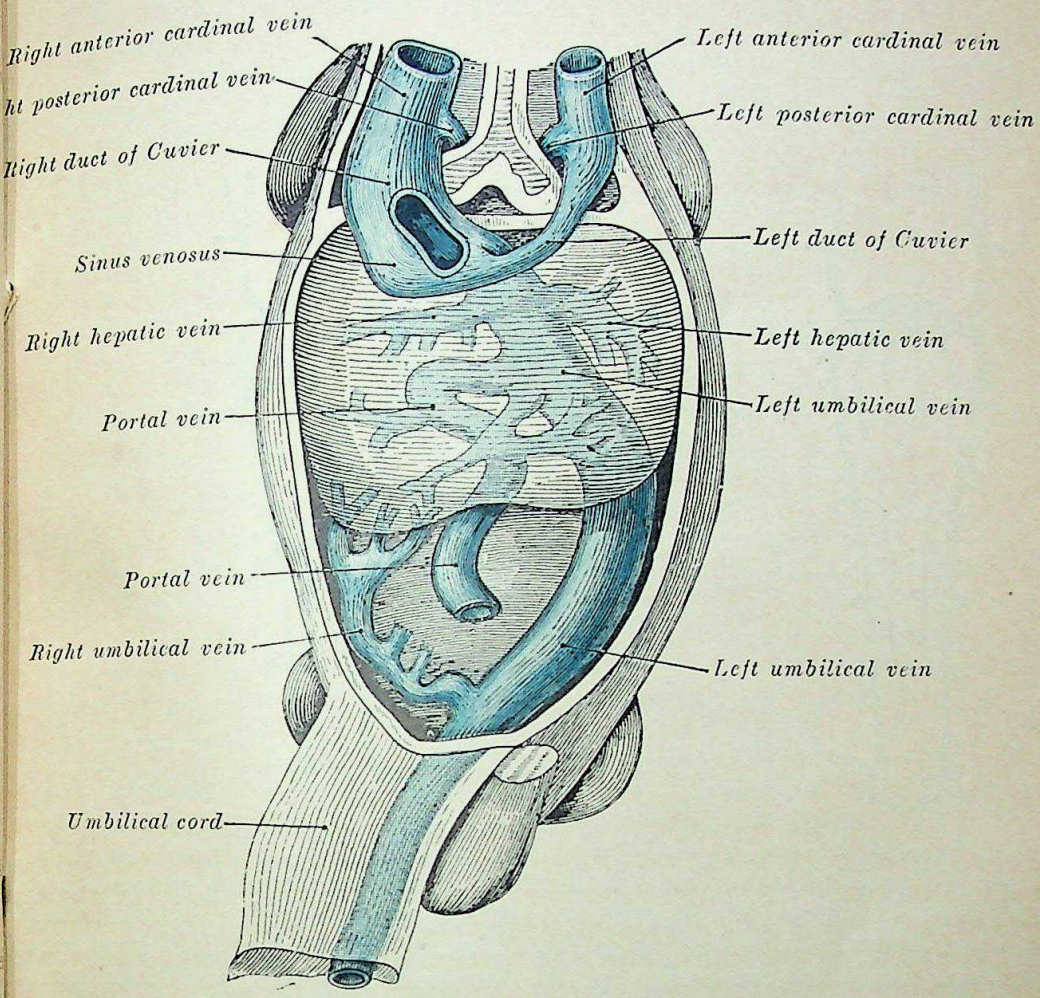

m the left umbilical vein to the liver through the left vena advehens. The t umbilical vein and the ductus venosus are obliterated after birth, and form pectively the ligamentum teres and ligamentum venosum of the liver.

The parietal veins.—A pair of short transverse veins, named the *ducts of Cuvier*, en, one on either side, into the sinus venosus. Each of these ducts receives an cending and a descending vein. The ascending veins return the blood from the rieties of the trunk and from the Wolffian bodies, and are called *posterior cardinal* ins. The descending veins return the blood from the head, and are called the *terior cardinal* (primitive jugular) veins (fig. 187). The blood from the lower limbs collected by the right and left iliac and hypogastric veins, which, in the earlier ges of development, open into the corresponding right and left posterior cardinal ins; later, a transverse branch (the left common iliac vein) is developed between e lower parts of the posterior cardinal veins (fig. 189), and through this the blood carried into the right posterior cardinal vein. The portion of the left posterior rdinal vein below the left renal vein atrophies and disappears up to the point entrance of the left testicular vein; the portion above the left renal vein persists

CC-0. In Public Domain. Gurukul Kangri Collection, Haridwar

Digitized by Arya Samaj Foundation Chennai and eGangotri

as the hemiazygos and accessory hemiazygos veins and the lower portion
left superior intercostal vein. The right posterior cardinal vein, which now
the blood from both lower extremities, forms a large venous trunk along the
abdominal wall; up to the level of the renal veins it forms the lower part
inferior vena cava. Above the level of the renal veins the right posterior
vein persists as the azygos vein and receives the right intercostal veins,
hemiazygos and accessory hemiazygos veins are brought into commu
with it by the development of transverse branches in front of the vertebral
(figs. 189, 190).

The inferior vena cava.—The development of the inferior vena cava is as
with the formation of two veins, the *subcardinal veins* (figs. 187, 188). Th
along the medial surfaces of the Wolffian bodies parallel to the posterior
veins; they communicate with the posterior cardinal veins above and bel

FIG. 187.—A scheme of the arrangement of the parietal veins.

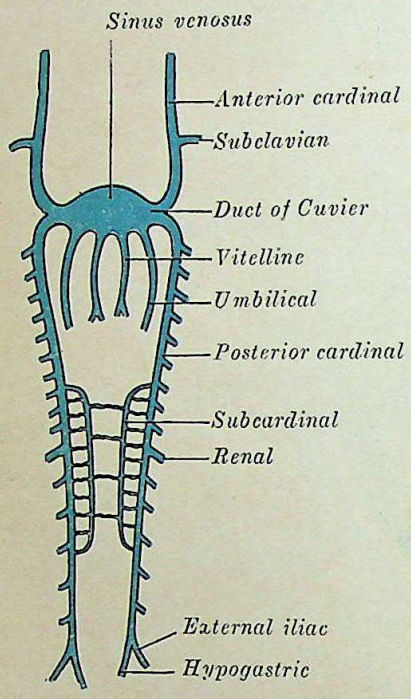

FIG. 188.—A scheme showing early stages of the developm of the inferior vena cava.

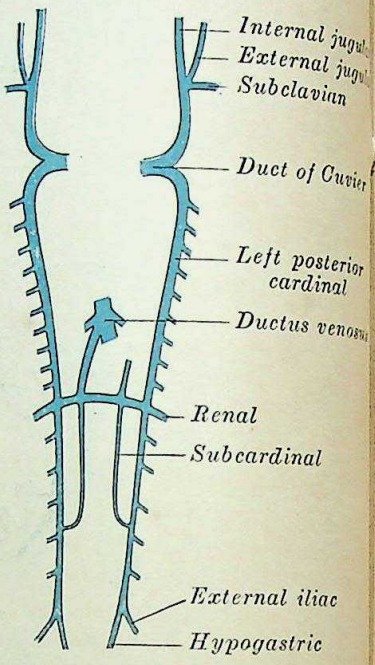

also by a series of transverse branches. The two subcardinals are for a tim
nected with each other in front of the aorta by cross branches, but these dis
and are replaced by a single transverse channel (intersubcardinal anastomo
the level where the renal veins join the posterior cardinals, and at the sam
a cross communication is established on either side between the posterior ca
and subcardinal (fig. 188). The portion of the right subcardinal behind this
communication disappears, while that in front (i.e. the prerenal part) be
connected by means of a channel with the proximal part of the right hepatic
and this channel rapidly enlarges and receives the blood from the postrenal
the right posterior cardinal through the cross communication referred to.
manner a single trunk, the *inferior vena cava* (fig. 190), is formed, and cons
the proximal part of the right hepatic vein, the new channel just describe
prerenal part of the right subcardinal vein, the postrenal part of the right po
cardinal vein, and the cross branch connecting it with the right subcardinal
The left subcardinal disappears, except the part immediately in front of the
vein, which is retained as the left suprarenal vein. The testicular (or ovarian
opens into the postrenal part of the corresponding posterior cardinal vein.
portion of the right posterior cardinal, as already explained, forms the lowe
of the inferior vena cava, so that the right testicular opens directly into that
The postrenal segment of the left posterior cardinal disappears, with the exce
of the portion between the testicular and renal veins, which is retained a
terminal part of the left testicular vein.

CC-0. In Public Domain. Gurukul Kangri Collection, Haridwar

Digitized by Arya Samaj Foundation Chennai and eGangotri

Huntington and McClure * contend (1) that the right posterior cardinal vein takes no e in the development of the postrenal segment of the inferior vena cava, and (2) that rms only the cranial end of the azygos vein.

They state that a *supracardinal system of veins*, consisting of a bilateral and originally metrical venous channel, is developed dorsomedial to the posterior cardinal veins dorsolateral to the aorta. Frequent anastomoses occur between the posterior cardinal supracardinal veins, but only a single anastomosis, at about the level of the inter- ardinal anastomosis, is retained on each side of the body; this anastomosis permits d, collected by the supracardinal veins in the lumbar region, to reach the heart by of the prerenal division of the inferior vena cava. The formation of this anastomosis blishes the presence of a circumaortic venous ring, named the *renal collar*. The acardinal veins unite (*a*) caudally with the posterior cardinal veins at the level where

FIG. 189.—A diagram showing the development of the main cross branches between the cardinal veins.

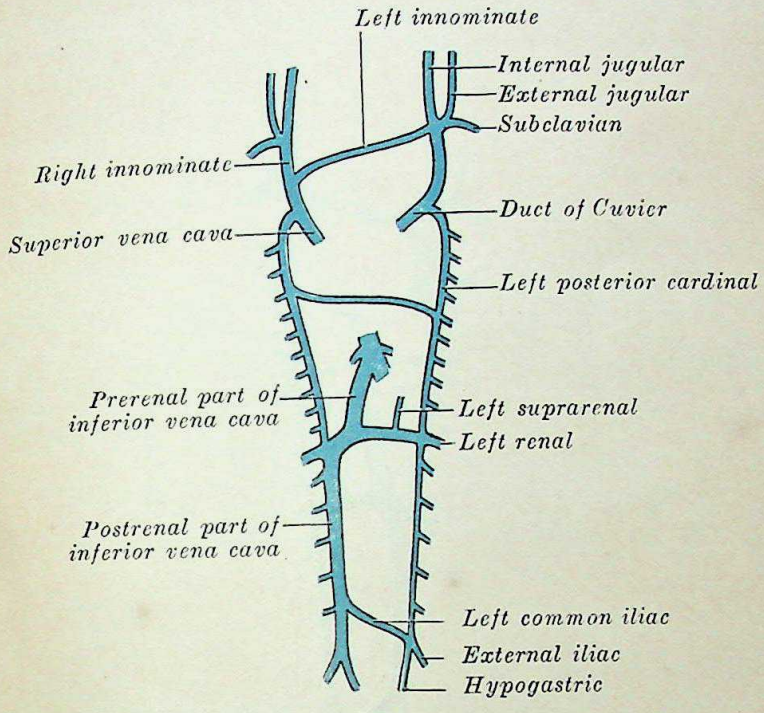

latter receive the internal iliac and hypogastric veins, and (*b*) cranially at the level he renal collar, and thus there is established for a time a venous ring through which ureter passes.

he supracardinal veins soon separate into a cranial or azygos, and a caudal or lumbar, of veins, and the bilaterally symmetrical plan of the latter is replaced by an asymmetri- one which is initiated by a reduction, followed by a complete atrophy, of the left half he renal collar; the right half of this collar persists and elongates to form a part of postrenal segment of the inferior vena cava. The caudal half of the left supracardinal is drawn into and fuses with the vein of the right side, and from these fused veins the dal part of the postrenal segment of the inferior vena cava is formed.

The history of the development of the azygos veins in the cat shows "that they are ived chiefly from the supracardinals, and that in the adult cat only the proximal end the right azygos near the duct of Cuvier is derived from the posterior cardinal n."

In consequence of the atrophy of the Wolffian bodies the posterior cardinal veins inish in size; the anterior cardinal veins, on the other hand, become enlarged, ing to the rapid development of the head and brain. They are further augmented receiving the veins (*subclavian*) from the upper extremities, and so come to form chief veins of the ducts of Cuvier; these ducts gradually assume an almost tical position in consequence of the descent of the heart into the thorax. The ht and left ducts of Cuvier are originally of the same diameter, and are frequently med the *right and left superior venæ cavæ*. By the development of a transverse nch (the *left innominate vein*) between the two anterior cardinal veins, the blood

* G. S. Huntington and C. F. W. McClure, *Anatomical Record*, vol. xx. December 1920.

CC-0. In Public Domain. Gurukul Kangri Collection, Haridwar

Digitized by Arya Samaj Foundation Chennai and eGangotri

is carried across from the left to the right and becomes cardinal (figs. 189, 19
portion of the right anterior cardinal vein between the left innominate
azygos vein forms the upper part of the superior vena cava of the adult;
part of the latter vessel (i.e. below the entrance of the azygos vein) is form
right duct of Cuvier. Below the origin of the transverse branch the left
cardinal vein and left duct of Cuvier atrophy, the former constituting t
part of the left superior intercostal vein, while the latter is represented
ligament of the left vena cava (vestigial fold of Marshall) and the oblique
the left atrium (oblique vein of Marshall) (fig. 190). The oblique vein of
atrium passes downwards across the back of the left atrium to open into the
sinus, which, as already indicated, represents the persistent left horn of
venosus. Right and left superior venæ cavæ are present in some animals,
occasionally found in the adult human being.

FIG. 190.—A diagram showing the completion of the development of th
parietal veins.

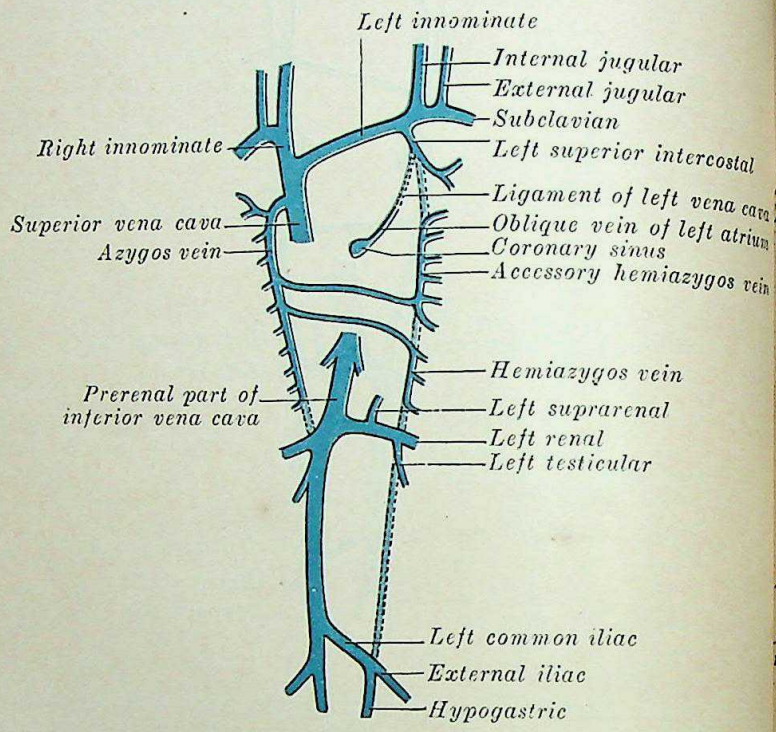

The venous sinuses of the dura mater. The following description is based
given by Streeter.*

The primary blood-vessels of the head consist of a close-meshed capillary
which is drained by anastomosing loops into a pair of veins, named the *primo*
veins. Each primary head vein (fig. 191 *A*) begins on the diencephalon, and
along the side of the brain running medial to the semilunar ganglion and latera
auditory vesicle; on reaching the vagus nerve it turns sharply downwards and
into the duct of Cuvier. The part of the vein which is caudal to the vagus
the anterior cardinal vein, the cephalic portion of which forms the internal
vein. At a later stage the greater part of the original capillary plexus assu
form of three secondary plexuses—anterior, middle and posterior (fig. 191,
the middle and posterior plexuses each open by a single vein into the primar
vein. Some tributaries from the ventral part of the head also enter this vei
most important of these are the channels from the eye-region, and these
become the ophthalmic veins.

The development of the cranium and the brain membranes introduces
changes: the three main secondary plexuses are largely retained in associati
the dura mater, while superficial portions are split off to drain the surface of th
and deeper portions are specialized for the drainage of the brain-stem. Th

* George L. Streeter, *American Journal of Anatomy*, vol. xviii. 1915.

CC-0. In Public Domain. Gurukul Kangri Collection, Haridwar

Digitized by Arya Samaj Foundation Chennai and eGangotri

FIG. 191.—Profile drawings showing the development of the venous sinuses of the dura mater in human embryos from 4 mm. to birth. Their adaptation to the growth and changes in the form of the brain should be noted. A. Embryo of 4 mm.; B. Embryo of 14 mm.; C. Embryo of 18 mm.; D. Embryo of 21 mm.; E. Embryo of 35 mm.; F. Embryo of 50 mm. crown-rump length; G. Embryo of 80 mm. crown-rump length; H. At birth. (George L. Streeter.)

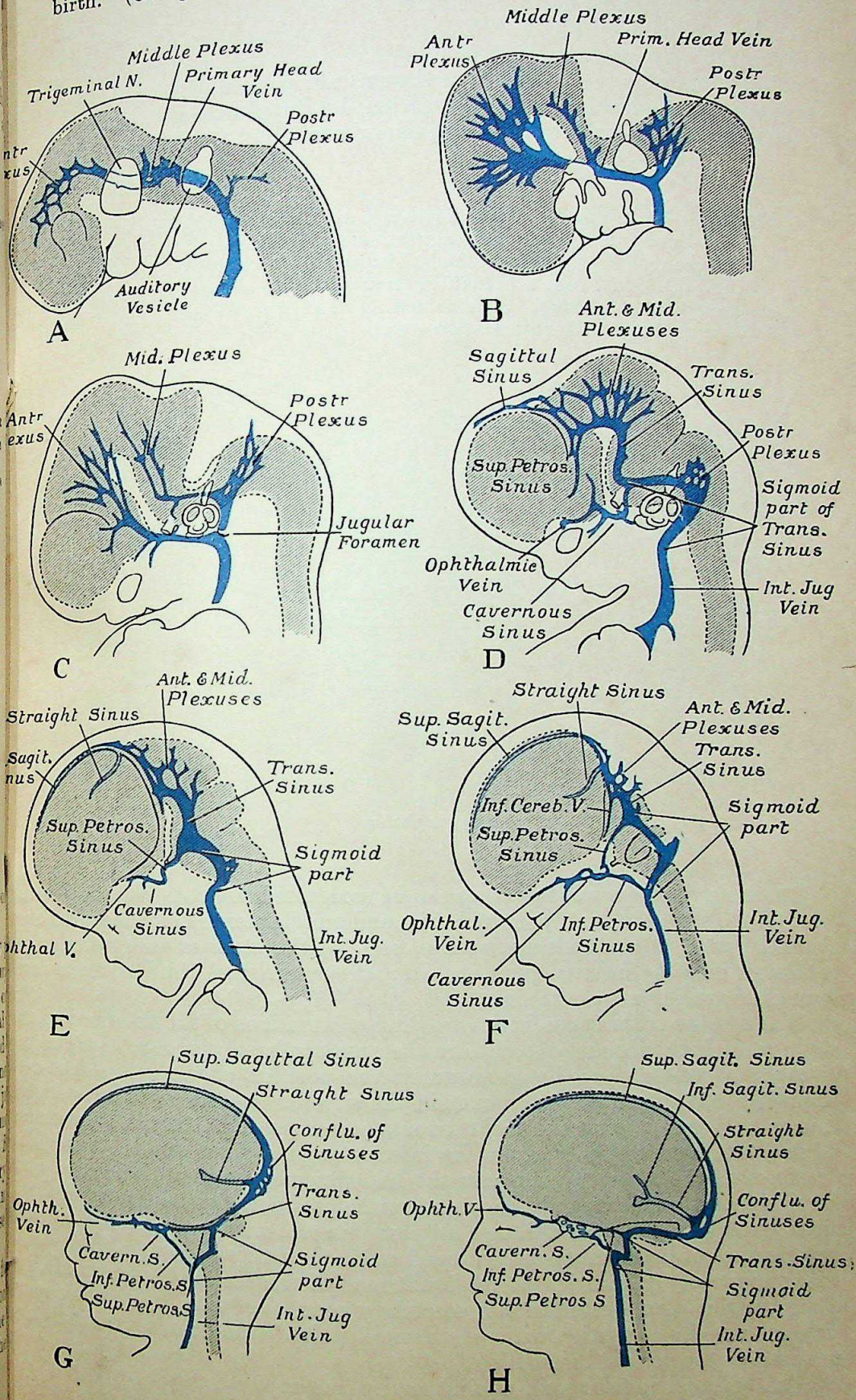

CC-0. In Public Domain. Gurukul Kangri Collection, Haridwar

Digitized by Arya Samaj Foundation Chennai and eGangotri

series of modifications is largely due to the increase in the size of the inte
An anastomosing channel between the middle and posterior plexuses form
dorsal aspect of the auditory vesicle, and the anterior and middle plexuses u
one another (fig. 191, *C*, *D*). A single large vein which is the commencem
transverse sinus drains the anterior and middle plexuses into the new anas
channel (fig. 191, *D*). The posterior part of the primary head vein, i.e.
connected with the internal jugular vein, disappears, but the anterior portio
region of the trigeminal nerve, is retained as the cavernous sinus, and into
ophthalmic veins open (fig. 191, *D*, *E*). The original stem of the middle
between the new anastomosing channel and the primary head vein, u
atrophy, but later is re-established as the superior petrosal sinus (fig. 191, *E*
The inferior petrosal sinus is a new formation, developed from a small plexus
the cavernous sinus and the internal jugular vein (fig. 191, *F*, *G*).

FIG. 192.—Three stages in the formation of the sagittal plexus, showing conversion into the superior sagittal sinus. Draining into it from below the channel from the chorioidal plexuses which becomes the straight si (fig. B.). A. From a human embryo 13·8 mm. long; B. From a hum embryo 20 mm. long; C. is a drawing of an injected and cleared specim 54 mm. long. (George L. Streeter.)

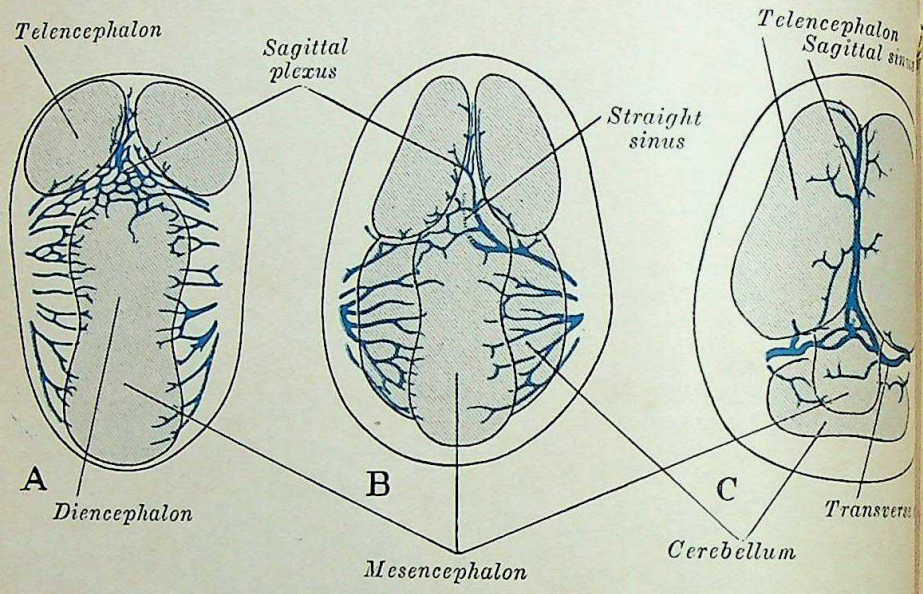

The transverse sinus at this stage can be recognized as a composite vessel from (1) the stem of the conjoined anterior and middle plexuses, (2) the anasto channel dorsal to the auditory vesicle, and (3) the stem of the posterior continued into the internal jugular vein; the second and third portions t form the sigmoid part of the sinus.

Between the growing cerebral hemispheres extensions of the anterior and plexuses of both sides meet and form the *sagittal plexus* (fig. 192, *A*, *B*), a of capillary veins which hangs down in the position of the future falx Along the dorsal margin of this curtain the superior sagittal sinus is evolv this sinus usually joins the right transverse sinus (fig. 192, *B*, *C*); al ventral free edge of the curtain the inferior sagittal sinus and the straig are formed, the latter passing into the left transverse sinus. When the hemispheres grow backwards they carry with them the sagittal sinus; the sinus extends backwards through a plexus in the tentorium cerebelli, transference of both sinuses is continued until they arrive at their adult with their point of junction at the confluence of the sinuses (torcular He The posterior plexus establishes a secondary connexion with the confluence sinuses, loses its connexion with the sigmoid part of the transverse sinus, retained as the occipital sinus.

The external jugular vein at first drains the region behind the ear (p auricular) and enters the anterior cardinal; a lateral tributary. A group o

CC-0. In Public Domain. Gurukul Kangri Collection, Haridwar

Digitized by Arya Samaj Foundation Chennai and eGangotri

m the face and lingual region converge to form a common vein, the linguofacial,* ch also terminates in the anterior cardinal vein. Later, cross communications elop between the external jugular and the linguofacial, with the result that the terior group of facial veins is transferred to the external jugular. The cephalic n is, for a time, a tributary of the external jugular vein, but is later diverted into axillary vein.

In early fœtal life the heart is placed directly under the head and is relatively large size. Later it assumes its position in the thorax, but lies at first in the idle line; towards the end of pregnancy it gradually becomes oblique in direction. atrial portion is at first larger than the ventricular part, and the two atria municate freely through the foramen ovale. In consequence of the communica-, through the ductus arteriosus, between the pulmonary artery and the aorta, contents of the right ventricle are mainly carried into the latter vessel instead

FIG. 193.—A scheme showing the relative positions of the primary lymph-sacs. (Based on the description given by Florence Sabin.)

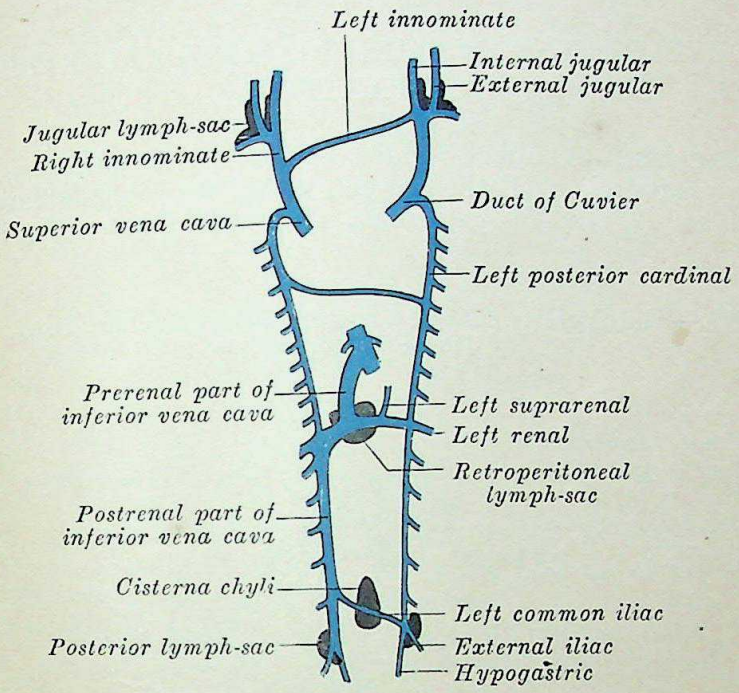

to the lungs, and hence the wall of the right ventricle is as thick as that of the . At the end of fœtal life, however, the left ventricle is thicker than the right, difference which becomes more and more emphasised after birth.

The fœtal circulation and the changes which take place in the circulation after th are described in the section on Angiology.

The **lymphatic vessels.**—The lymphatic system begins as a series of sacs † at e points of junction of certain of the embryonic veins. These lymph-sacs are veloped by the confluence of numerous venous capillaries, which at first lose eir connexions with the venous system, but subsequently, on the formation of e sacs, regain them. The lymphatic system is therefore developmentally an shoot of the venous system, and the lining walls of its vessels are always dothelial.

In the human embryo the lymph-sacs from which the lymphatic vessels are rived are six in number; two paired, the jugular and the posterior lymph-sacs; e two unpaired, the retroperitoneal and the cisterna chyli. In lower mammals additional pair, the subclavian, is present, but in the human embryo these are erely extensions of the jugular sacs.

The position of the sacs is as follows (fig. 193): (1) the jugular, the first to appear, the junction of the subclavian vein with the anterior cardinal; (2) the posterior,

* Lewis, *American Journal of Anatomy*, vol. ix. 1909.

† F. Sabin, *American Journal of Anatomy*, vol. ix. 1909.

CC-0. In Public Domain. Gurukul Kangri Collection, Haridwar

Digitized by Arya Samaj Foundation Chennai and eGangotri

at the junction of the iliac vein with the posterior cardinal; (3) the retroper
in the root of the mesentery near the suprarenal glands; (4) the cisterna
opposite the third and fourth lumbar vertebræ. From the lymph-sacs th
phatic vessels bud out along fixed lines corresponding more or less close
the course of the embryonic blood-vessels. In the body-wall and in the
the intestine,* the deeper plexuses are the first to be developed; by co
growth of these, the vessels in the superficial layers are gradually formed
thoracic duct is probably formed from anastomosing outgrowths from the
sac and cisterna chyli. At its connexion with the cisterna chyli it is at first
but the vessels soon join.

All the lymph-sacs except the cisterna chyli are, at a later stage, divided
slender connective tissue bridges and transformed into groups of lymph-
The lower portion of the cisterna chyli is similarly converted, but its upper
remains as the adult cisterna.

THE DEVELOPMENT OF THE DIGESTIVE AND RESPIRATORY APPARATUS

The **digestive tube.**—As already indicated (p. 55), the primitive digestive
consists of two parts, viz.: (1) the *fore-gut*, within the cephalic flexure, and
to the heart; and (2) the *hind-gut*, within the caudal flexure (fig. 194). Be

FIG. 194.—The digestive tube of a human embryo 2·5 mm. long. (Peter Thompson.)

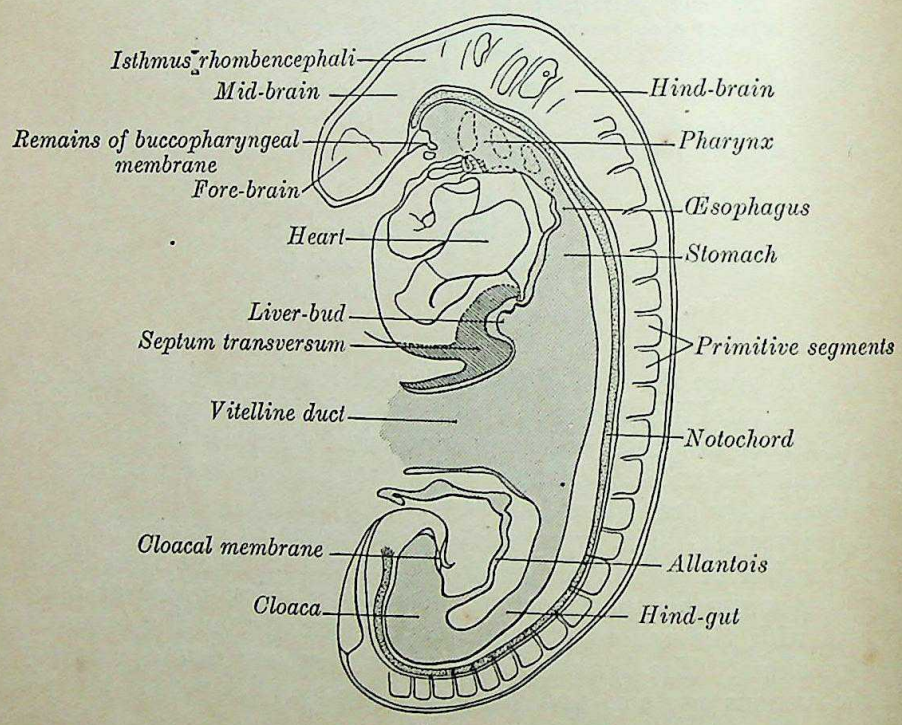

these is the wide opening of the yolk-sac, which is gradually narrowed and re
to a small foramen leading into the vitelline duct. At first the fore-gut and hi
end blindly; the anterior end of the fore-gut is closed by the buccophar
membrane; the hind-gut ends in the cloaca, which is similarly closed b
cloacal membrane.

The **mouth** is developed partly from the stomodæum, and partly from th
of the anterior portion of the fore-gut. By the growth of the head-end

* Heuer, *American Journal of Anatomy*, vol. ix. 1909

CC-0. In Public Domain. Gurukul Kangri Collection, Haridwar

Digitized by Arya Samaj Foundation Chennai and eGangotri

bryo, and the formation of the cephalic flexure, the pericardial area and the copharyngeal membrane come to lie on the ventral surface of the embryo. th the further expansion of the brain, and the forward bulging of the pericardium, buccopharyngeal membrane is pressed between these two promices. This depression constitutes *stomodæum* (fig. 195). It is lined h ectoderm, and is separated from anterior end of the fore-gut by the copharyngeal membrane, which is med by the apposition of the modæal ectoderm with the fore- entoderm; at the end of the d week the membrane disappears, a communication is established ween the mouth and the future rynx. No trace of the membrane ound in the adult; and the comnication just mentioned must not confused with the permanent mus faucium. The lips, teeth, gums are formed from the walls he stomodæum, but the tongue is eloped in the floor of the mouth pharynx.

FIG. 195.—The head-end of a human embryo about thirty to thirty-one days old. Ventral aspect. (From a model by K. Peter.)

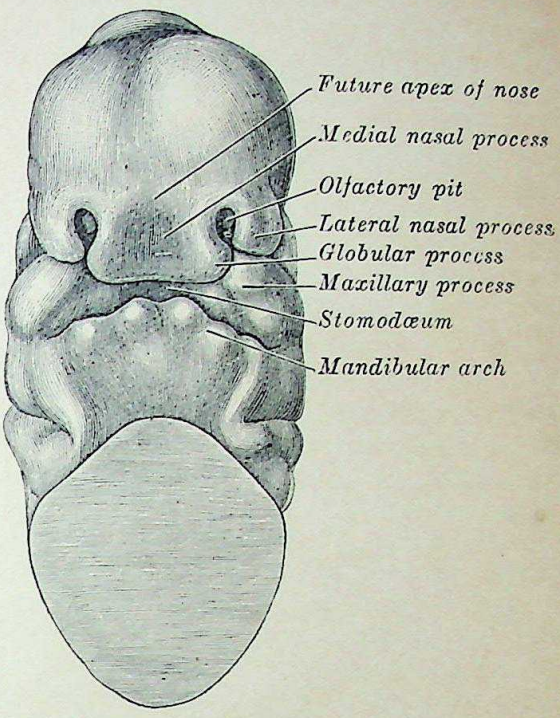

The visceral arches grow in a tral direction and lie between the modæum and the pericardium; h the completion of the mandiar arch and the formation of the xillary processes, the mouth umes the appearance of a pentaal orifice, bounded in front by the frontonasal process, behind by the mandibular h, and laterally by the maxillary processes (fig. 195). With the inward growth fusion of the palatine processes (figs. 124, 125), the stomodæum is divided into upper nasal and a lower buccal part. Along the free margins of the processes nding the mouth cavity a shallow groove appears; this is termed the *primary al groove*, and from the bottom of it a downgrowth of ectoderm into the underlying oderm takes place. Owing to the degeneration of the central cells of this

196.—The floor of the pharynx of human embryo about twenty-six ys old. (From a model by . Peter.)

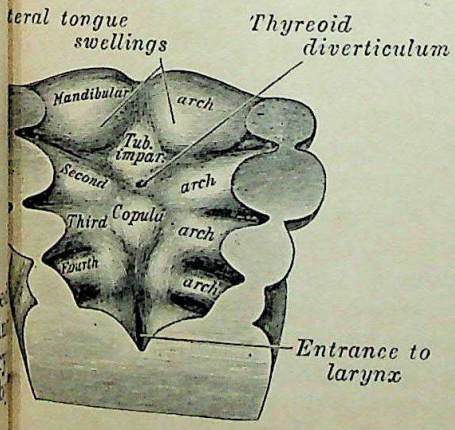

FIG. 197.—The floor of the pharynx of a human embryo about the end of the fourth week. (From a model by K. Peter.)

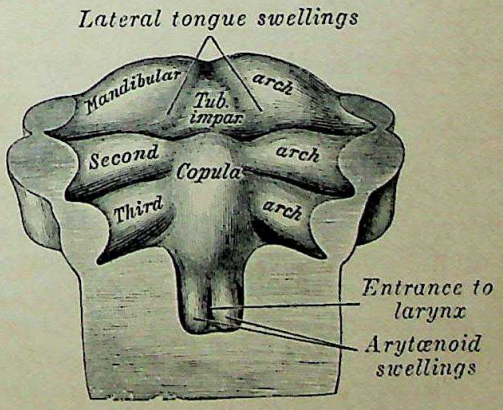

dermal downgrowth the groove is deepened and a *secondary labial groove* is ed, and separates the lips and cheeks from the alveolar processes of the maxillæ mandible.

CC-0. In Public Domain. Gurukul Kangri Collection, Haridwar

Digitized by Arya Samaj Foundation Chennai and eGangotri

The **salivary glands** arise as buds from the epithelial lining of the mou parotid appears during the fourth week in the angle between the maxillary and the mandibular arc submaxillary appears in t week, and the sublingual the ninth week, in the between the tongue and t dibular arch.

Fig. 198.—The floor of the pharynx of a human embryo, about thirty days old. (From a model by K. Peter.)

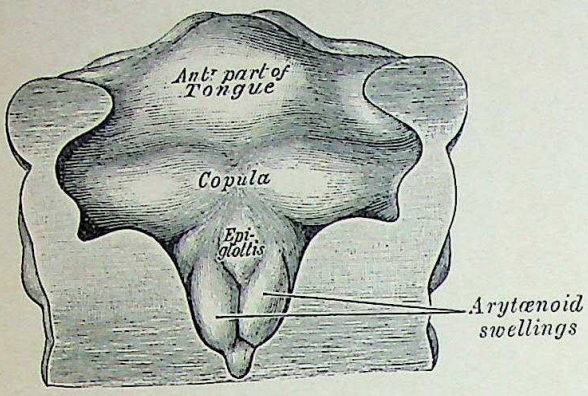

The **tongue** (figs. 196 consists of an anterior or and a posterior or pharyng During the third week appears, immediately bel ventral ends of the ha the mandibular arch, a swelling named the tu *impar*, which was descri His as forming the whole buccal part of the tongue. recent researches have that this part of the tongue is mainly, if not entirely, developed from of lateral lingual swellings which arise from the inner surface of the bular arch and meet in the middle line. The tuberculum impar is said t the central part of the tongue immediately in front of the foramen cæcu Hammar insists that it is purely a transitory structure and forms no part adult tongue. From the ventral ends of the fourth arch there arises a seco larger elevation, in the centre of which is a median groove or furrow. This ele named by His the *furcula*, is at first separated from the tuberculum impa depression, but later by a ridge, the *copula*, formed by the forward grow fusion of the ventral ends of the second and third arches. The poste pharyngeal part of the tongue is developed from the copula, which extends forwards in the form of a **V**, so as to embrace between its two limbs the buccal part of the tongue. At the apex of the **V** a pit-like invagination occurs, to form the thyreoid gland, and this depression is represented in the adult by the *foramen cæcum* of the tongue. In the adult the union of the anterior and posterior parts of the tongue is marked by the **V**-shaped *sulcus terminalis*, the apex of which is at the foramen cæcum, while the two limbs run lateralwards and forwards parallel to but a little behind the papillæ vallatæ.

Fig. 199.—A scheme showing the d ment of the branchial epithelial (Modified from Kohn.)

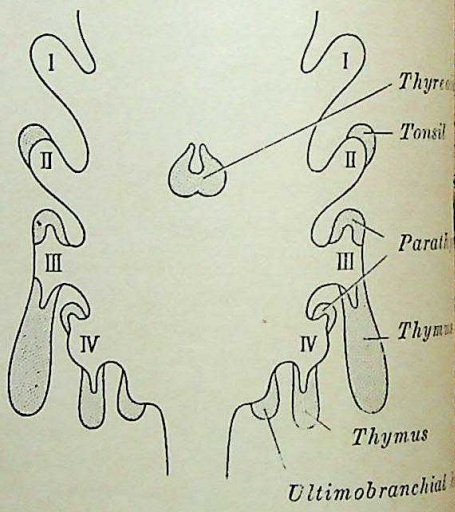

I. II, III, IV. Pharyngeal pouches.

The **thyreoid gland** is developed from a median diverticulum, which appears about the fourth week on the summit of the tuberculum impar, but later is found in the furrow immediately behind the tuberculum (fig. 196). It grows downwards and backwards as a tubular duct bifurcates and subsequently divides into a series of cellular cords, from wh isthmus and lateral lobes of the thyreoid gland are developed. As already (p. 78), the ultimobranchial bodies from the fifth pharyngeal pouches are em by the lateral lobes of the thyreoid gland, but they undergo atrophy and form true thyreoid tissue. The connexion of the diverticulum with the pha termed the *thyreoglossal duct*; by the second month the duct is obliterat upper end being represented by the foramen cæcum of the tongue, and its by the pyramidal lobe of the thyreoid gland.

The **palatine tonsils** are developed from the parts of the second phar

CC-0. In Public Domain. Gurukul Kangri Collection, Haridwar

Digitized by Arya Samaj Foundation Chennai and eGangotri

ches which lie between the tongue and the soft palate. The entoderm lining e pouches grows in the form of a number of solid buds into the surrounding oderm. These buds are excavated by the degeneration and shedding of their ral cells, and by this means the tonsillar crypts are formed. Lymphoid cells mulate around the pts, and are grouped form the lymphoid cles. The supraton- r fossa is a remnant he second pharyngeal ch.

The **thymus** appears he form of two flask- ped entodermal diver- la, which arise, one either side, from the d pharyngeal pouch 199), and extend alwards and back- ds into the surround- mesoderm in front of ventral aortæ. Here meet and are sub- ently joined by con- ive tissue, but there ever any fusion of the mus tissue proper. pharyngeal opening each diverticulum is obliterated, but the k persists for some e as a cellular cord. further proliferation the cells lining the erticulum, buds of s are formed, which ome surrounded and ated by the invading oderm. In the latter, nerous lymphoid cells e their appearance, are aggregated to n lymphoid follicles. se lymphoid cells are bably derivatives of entodermal cells ch lined the original rticula and their sub- sions. Additional portions of thymus tissue are sometimes developed from fourth branchial pouches. The thymus begins to atrophy about the age of erty.

FIG. 200.—Sagittal sections of the heads of early embryos of the rabbit. Magnified. (From Mihalkovics.)

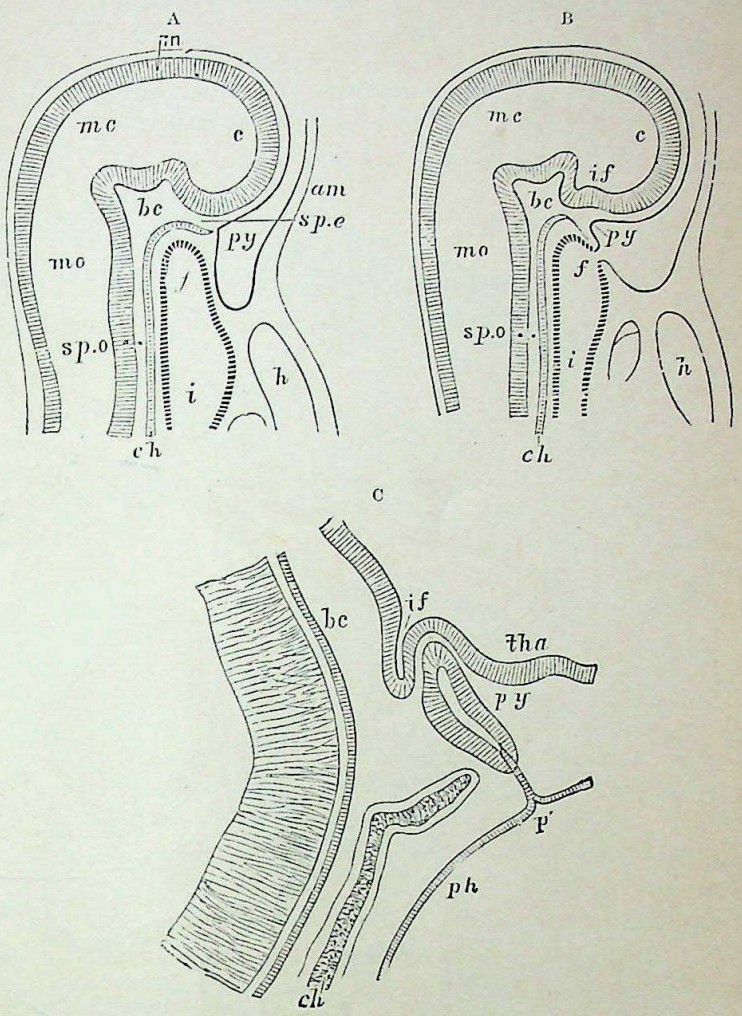

A. From an embryo of 5 mm. long. B. From an embryo of 6 mm. long. C. Vertical section of the anterior end of the notochord and hypophysis, etc., from an embryo 16 mm. long. In A the buccopharyngeal membrane is still present. In B it is in the process of disappearing, and the stomodæum now communicates with the primitive pharynx. *am.* Amnion. *c.* Fore-brain. *ch.* Notochord. *f.* Anterior extremity of fore-gut, *i.* *h.* Heart. *if.* Infundibulum. *m.* Wall of brain cavity. *mc.* Mid-brain. *mo.* Hind-brain. *p.* Original position of hypophysial diverticulum, *py.* *ph.* Pharynx. *sp.e.* Spheno-ethmoidal, *bc.* Central, and *sp.o.* Spheno-occipital parts of basis cranii. *tha.* Thalamus.

The two pairs of **parathyreoid bodies** are developed as outgrowths from the third fourth pharyngeal pouches (fig. 199); the diverticula from the third pouches, g attached to the stalks of the thymus, are drawn to a lower level than those n the fourth pouches, and consequently the inferior pair of parathyreoids is ved from the third, and the superior pair from the fourth, pharyngeal pouches. Two diverticula arise from the fifth pharyngeal pouches and form what are ed the *ultimobranchial bodies* (fig. 199); the latter fuse with the thyreoid gland, do not form true thyreoid tissue.

The **hypophysis cerebri** consists of an anterior and a posterior lobe; the former derived from the ectoderm of the stomodæum, the latter from the floor of fore-brain. Previous to the rupture of the buccopharyngeal membrane a ch-like diverticulum of the ectodermal lining of the roof of the stomodæum

CC-0. In Public Domain. Gurukul Kangri Collection, Haridwar

Digitized by Arya Samaj Foundation Chennai and eGangotri

appears. This diverticulum (*pouch of Rathke*) (Fig. 200) is the rudime
anterior lobe of the hypophysis; it extends upwards in front of the cep
of the notochord and in front of the buccopharyngeal membrane, and
contact with the under surface of the fore-brain. It is then constricted o
a closed vesicle, but remains for a time connected to the ectoderm of the st
by a solid cord of cells. Masses of epithelial cells form on either side and in
wall of the vesicle, and by the growth of a stroma from the mesoderm bet
masses the development of the anterior lobe of the hypophysis is comp

FIG. 201.—A human embryo of 7 mm. greatest length. Left lateral aspe
(From a reconstruction by P. Thompson.)

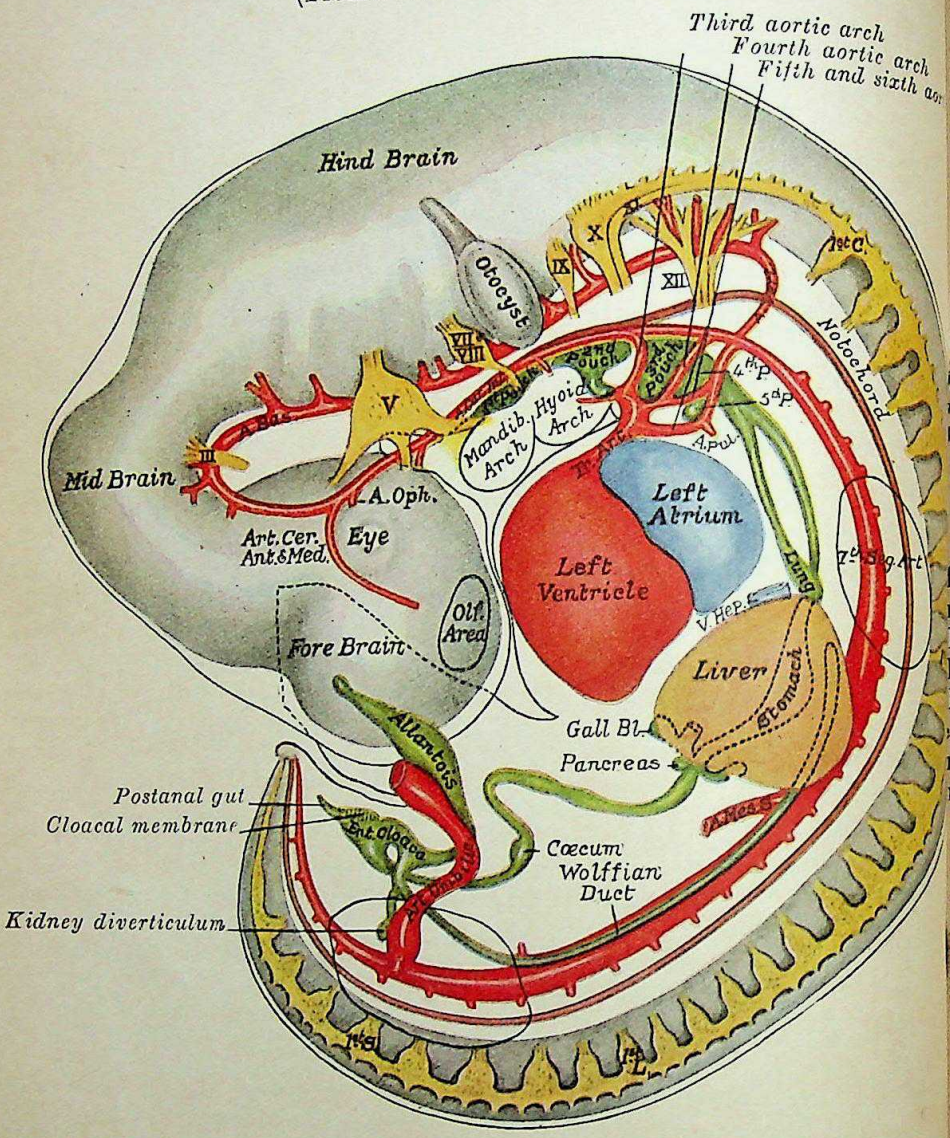

canal (*craniopharyngeal canal*) sometimes runs from the anterior part of t
hypophyseos of the sphenoidal bone to the under surface of the skull, an
the original position of Rathke's pouch; while at the junction of the septu
nose with the palate traces of the stomodæal end of the pouch are occa
present (Frazer). The stomodæal part of the hypophysis becomes applie
anterolateral aspect of a downwardly directed diverticulum from the base of
brain (p. 95). This diverticulum constitutes the future infundibulum of t
of the third ventricle, and its inferior extremity is modified to form the p
lobe of the hypophysis. In some of the lower animals the posterior lobe
nerve-cells and nerve-fibres, but in man and the higher vertebrates t
replaced by connective tissue.

A small entodermal diverticulum, termed *Seessel's pouch*, projects tow
brain from the anterior end of the foregut, close to the buccopharyngeal me
In some marsupials this pouch forms a part of the hypophysis (pituitary bo

CC-0. In Public Domain. Gurukul Kangri Collection, Haridwar

Digitized by Arya Samaj Foundation Chennai and eGangotri

The further development of the digestive tube. The upper part of the fore-gut tes to form the pharynx (fig. 194) in the lateral walls of which the branchial es are developed (p. 76); the succeeding part remains tubular, and is elongated

FIG. 202.—Front views of two successive stages in the development of the digestive tube. (His.)

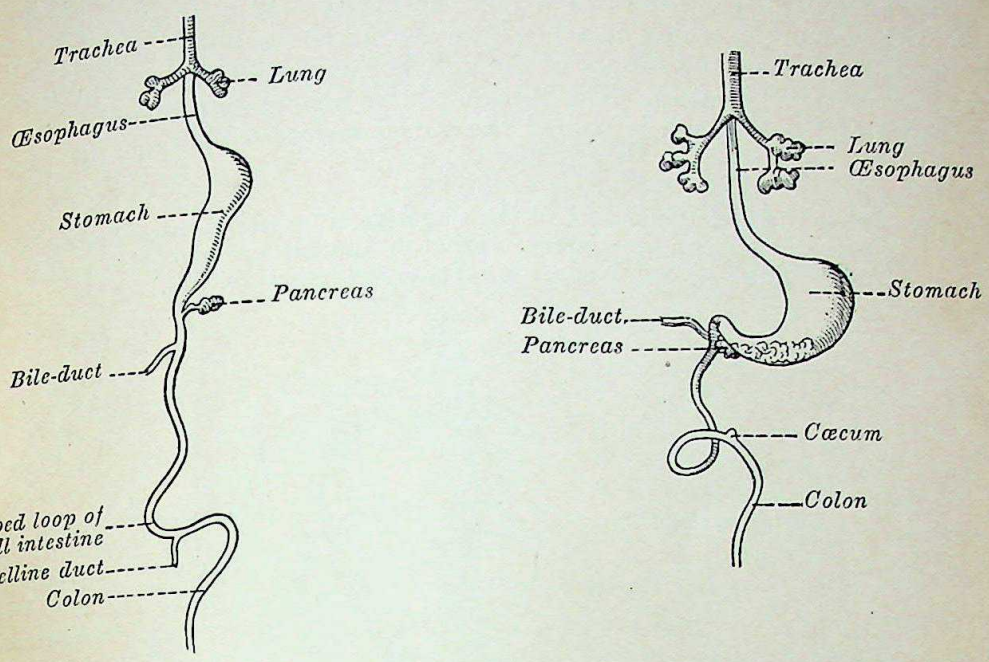

form the œsophagus. About the fourth week a fusiform dilatation, the future mach, makes its appearance (fig. 201), and beyond this the gut opens into the k-sac; this opening is at first wide, but is gradually narrowed into a tubular lk, the *yolk-stalk* or *vitelline duct*. Between the stomach and the mouth of the k-sac the liver diverticulum appears. From the stomach to the rectum alimentary canal is attached to the notochord by a band of mesoderm, m which the common mesentery of the gut is subsequently developed. The mach has an additional attachment to the anterior abdominal wall as far as

FIG. 203.—The primitive mesentery of a human embryo, six weeks old. Half-schematic. (Kollmann.)

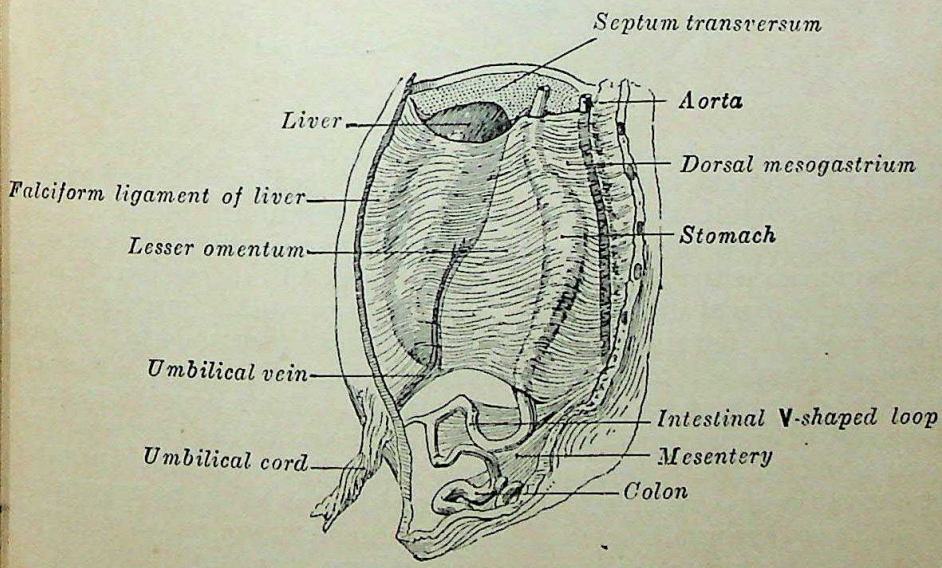

umbilicus by the septum transversum. The cephalic portion of the septum nsversum takes part in the formation of the Diaphragm, while the caudal tion into which the liver grows forms the *ventral mesogastrium* (fig. 203). The

CC-0. In Public Domain. Gurukul Kangri Collection, Haridwar

Digitized by Arya Samaj Foundation Chennai and eGangotri

stomach undergoes a further dilatation, and its two curvatures can be reco
(fig. 202), the greater directed towards the vertebral column and the lesser to
the anterior wall of the abdomen, while its two surfaces look to the right an
respectively. Distal to the stomach the gut undergoes great elongation, and
a V-shaped loop which projects downwards and forwards; from the bend or
of the loop the vitelline duct opens (fig. 203). For a time a large part of the
extends beyond the abdominal cavity into the umbilical cord, but by the e
the third month it is withdrawn within the cavity. With the lengthening
tube, the mesoderm, which attaches it to the future vertebral column and
the blood vessels for the supply of the gut, is thinned and drawn out to for
posterior common mesentery. The portion of this mesentery attached to the g
curvature of the stomach is named the *dorsal mesogastrium*, and the part

FIG. 204.—The abdominal part of the digestive tube and its attachment to th
posterior common mesentery. From a human embryo, six weeks ol
(After Toldt.) (From Kollmann's Entwickelungsgeschichte.)

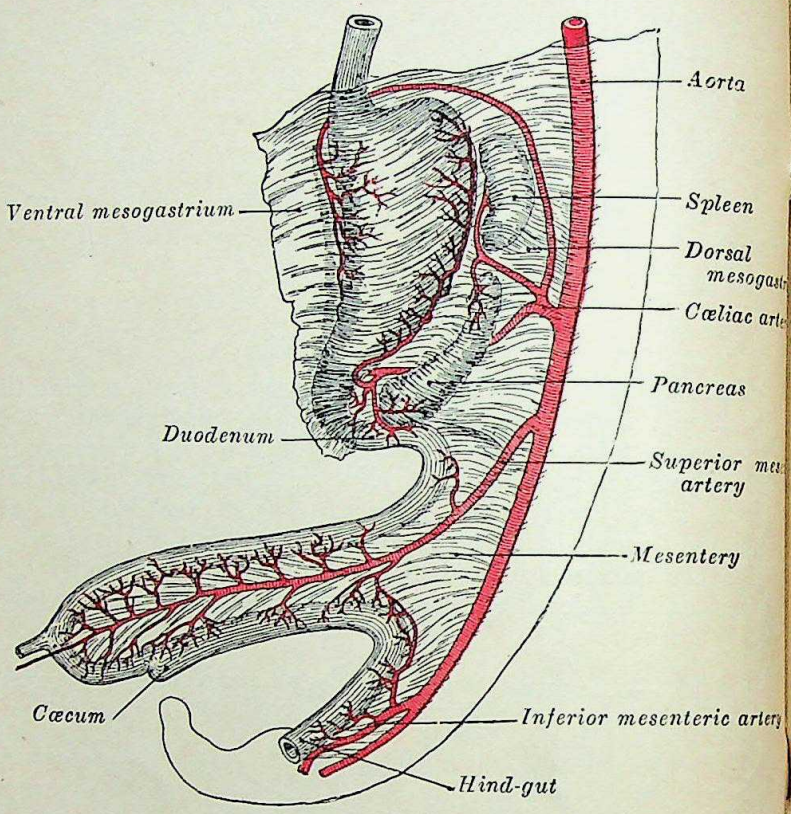

suspends the intestine is termed the *mesentery* (fig. 204). About the sixth
a diverticulum of the gut appears just behind the opening of the vitelline
and is differentiated into the future cæcum and vermiform process. The
of the loop on the distal side of the cæcal diverticulum increases in diameter
forms the future ascending and transverse portions of the large intestine.
the fifth month the cæcal diverticulum has a uniform calibre, but from this
onwards its distal part remains rudimentary and forms the vermiform process,
its proximal part expands to form the cæcum. Further changes are mean
taking place in the shape and position of the stomach. The fundus is developed
localised outgrowth or diverticulum from the cardiac end of the greater curvat
Lewis† points out that in a 16 mm. embryo a canal (gastric canal) passes
the lesser curvature of the stomach from the œsophagus to the pars pylorica,
that in a 44·3 mm. embryo this canal is more distinct than in the earlier st
and reaches from the antrum cardiacum to the incisura angularis.

* A. Keith and F. Wood Jones, *Proceedings of the Anatomical Society of Great Britai Ireland*, November 1901.

† F. T. Lewis, *American Journal of Anatomy*, vol. xiii. 1912.

CC-0. In Public Domain. Gurukul Kangri Collection, Haridwar

Digitized by Arya Samaj Foundation Chennai and eGangotri

The dorsal part or greater curvature of the stomach, to which the dorsal mesogastrium is attached, grows much more rapidly than its ventral part or lesser curvature, to which the ventral mesogastrium is fixed. The dorsal mesogastrium expands rapidly, and the greater curvature is carried downwards and to the left, and the right surface of the stomach is now directed backwards, and the left surface forwards (fig. 206)—a change in position which explains why the left vagus nerve is found on the front, and the right vagus on the back of the

FIG. 205.—The trunk of a human embryo 17 mm. long. (After a reconstruction by Mall.) (From Quain's Elements of Anatomy, vol. i., Embryology.)

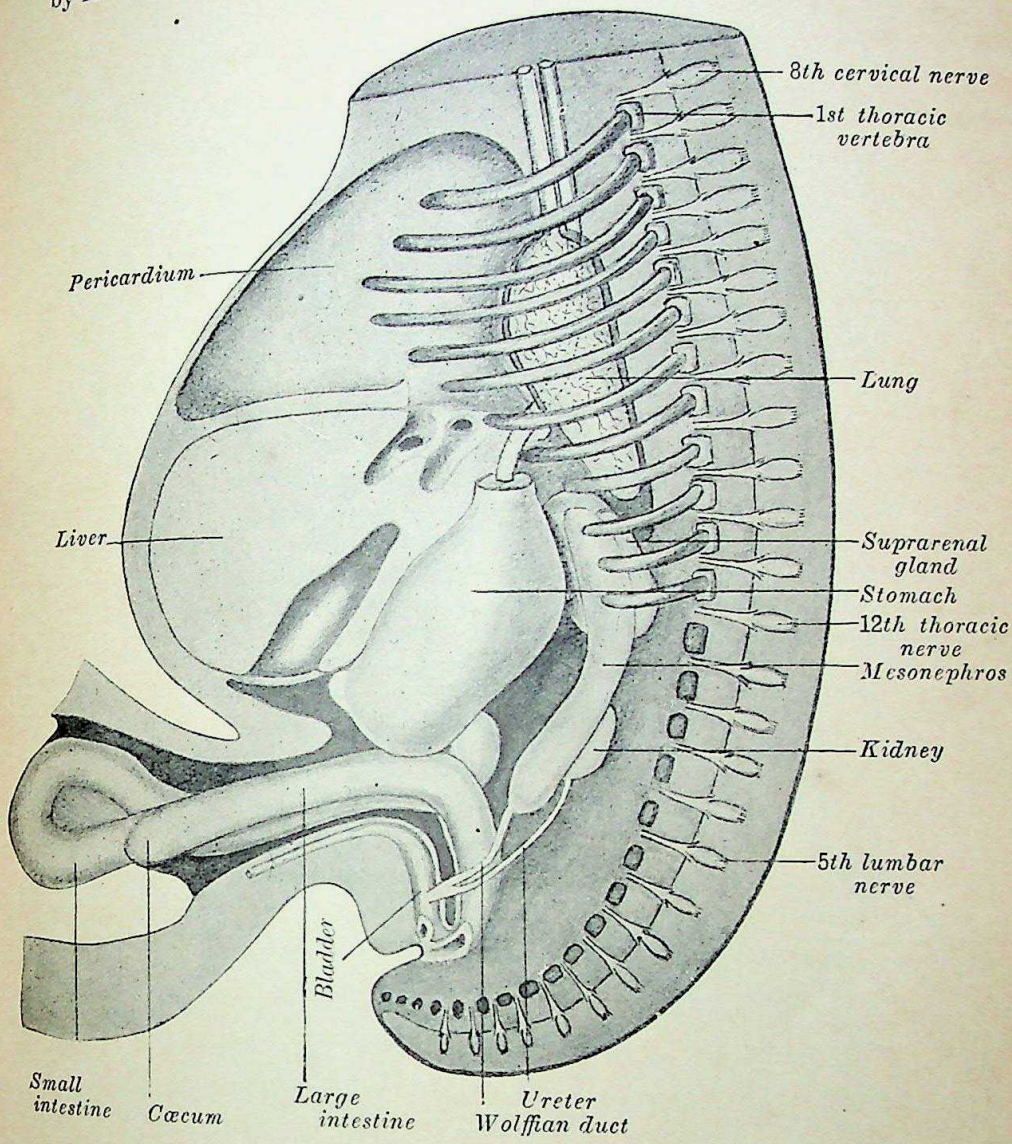

stomach. The dorsal mesogastrium attached to the greater curvature follows its alterations in position, and hence it is greatly elongated and drawn to the left and ventralwards, and, as in the case of the stomach, the right surfaces of both the dorsal and ventral mesogastria are now directed backwards, and the left forwards. In this way a pouch, the *bursa omentalis*, is formed behind the stomach, and this increases in size as the digestive tube undergoes further development; the entrance to the pouch constitutes the future *epiploic foramen* (foramen of Winslow).

The duodenum is developed from that part of the tube which immediately succeeds the stomach; it undergoes little elongation, being more or less fixed in position by the liver and pancreas, which arise as diverticula from it; for a time its lumen is occluded by an epithelial plug. The duodenum is at first suspended by a mesentery, and projects forwards in the form of a loop; but the loop and its mesentery are subsequently displaced by the transverse colon, so that the right surface of the duodenal mesentery is directed backwards, and, adhering to the

CC-0. In Public Domain. Gurukul Kangri Collection, Haridwar

Digitized by Arya Samaj Foundation Chennai and eGangotri

parietal peritoneum, is lost. The remainder of the digestive tube elo greatly, and is thrown into coils, and this elongation demands a correspo

FIG. 206.—Diagrams to illustrate two stages in the development of the digestive t and its mesentery. The arrow indicates the entrance to the bursa omentalis.

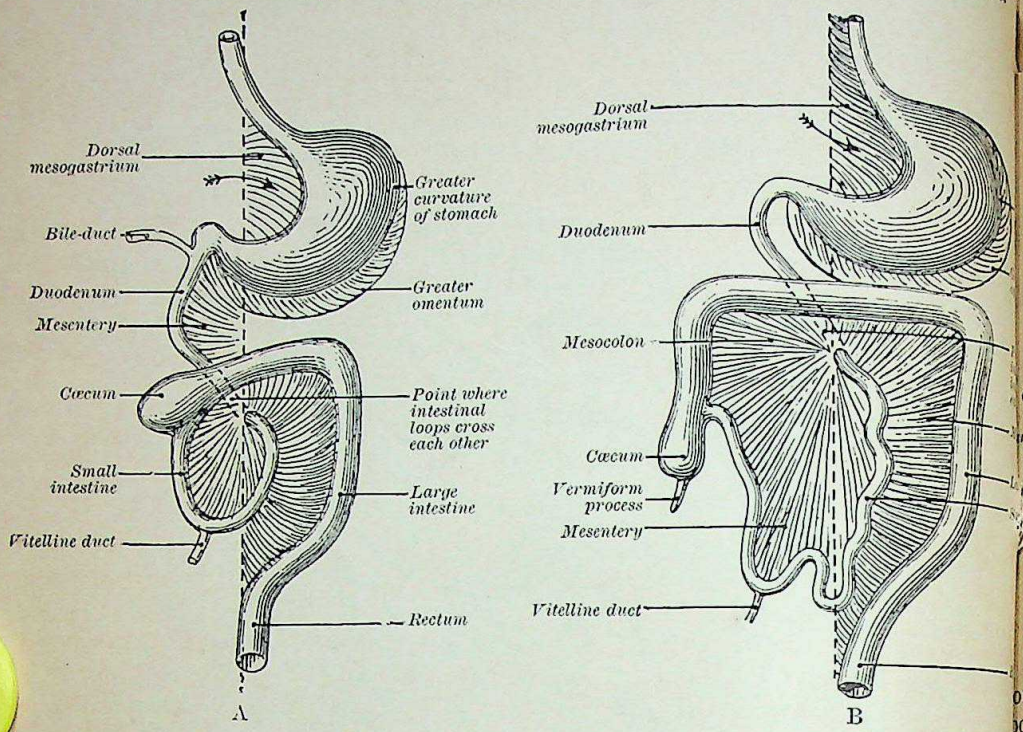

FIG. 207.—The final disposition of the intestines and their vascular relations. (Jonnesco.)

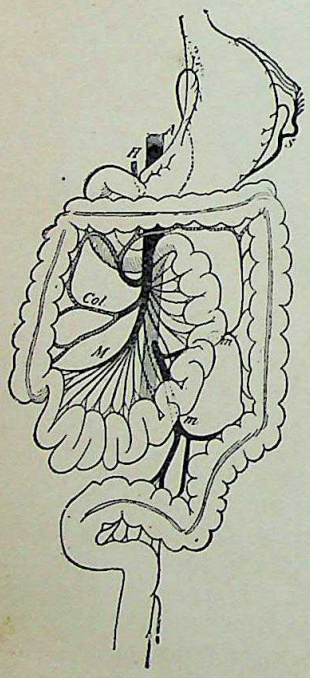

A, Aorta. *H*. Hepatic artery. *M*, *Col*. Branches of superior mesenteric artery. *m*, *m'*. Branches of inferior mesenteric artery. *S*. Lienal artery.

FIG. 208.—A schematic figure of the bursa omen &c. From a human embryo, eight weeks (Kollmann.)

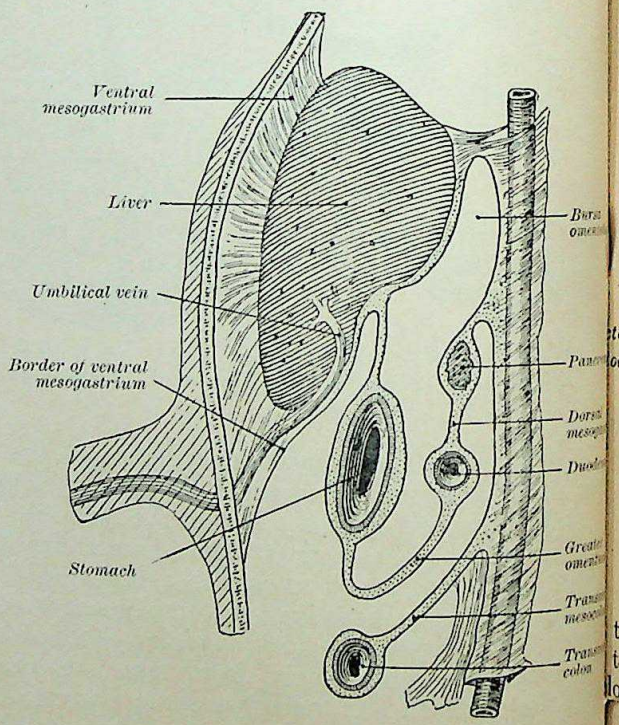

increase in the width of the intestinal attachment of the mesentery, wh becomes folded.

CC-0. In Public Domain. Gurukul Kangri Collection, Haridwar

Digitized by Arya Samaj Foundation Chennai and eGangotri

At this stage the small and large intestines are attached to the vertebral column by a common mesentery, the coils of the small intestine falling to the right of the middle line, while the large intestine lies on the left side.*

FIG. 209.—Diagrams to illustrate the development of the greater omentum and the transverse mesocolon.

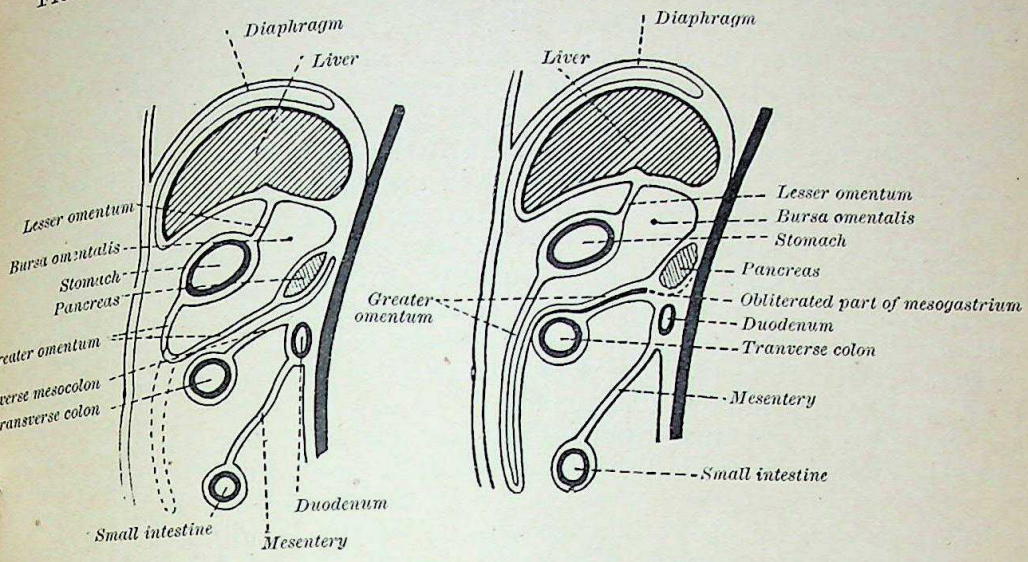

The gut is now rotated upon itself, so that the large intestine is carried over in front of the small intestine, and the cæcum is placed immediately below the liver; about the sixth month the cæcum descends into the right iliac fossa, and the large intestine forms an arch consisting of the ascending, transverse, and descending portions of the colon—the transverse portion crossing in front of the duodenum and lying just below the greater curvature of the stomach; within this arch the coils

FIG. 210.—The tail-end of a human embryo, fifteen to eighteen days old. (From a model by Keibel.)

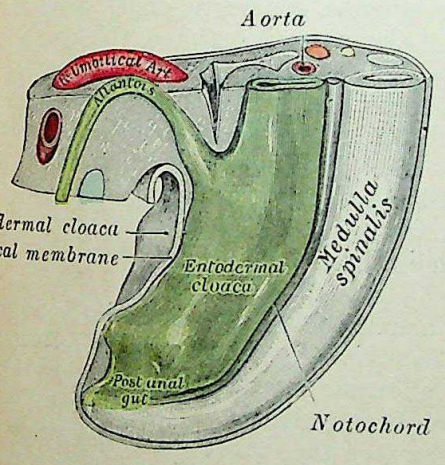

FIG. 211.—The cloaca of a human embryo, twenty-five to twenty-seven days old. (From a model by Keibel.)

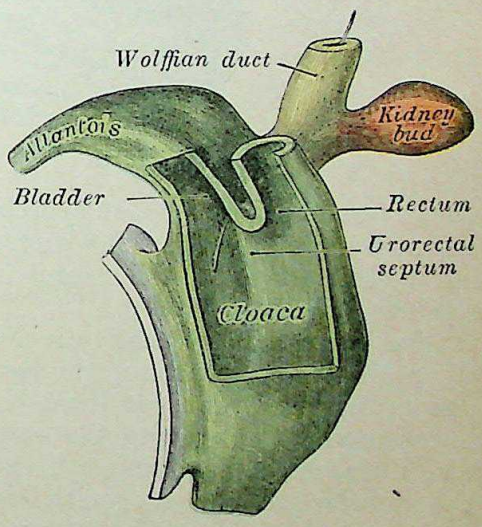

the small intestine are disposed (fig. 207). Sometimes the downward progress of the cæcum is arrested, so that in the adult it may be found lying immediately below the liver instead of in the right iliac region.†

* Sometimes this condition persists throughout life, and the duodenum lies entirely on the right side of the median plane, where it is continued into the jejunum; in such cases the arteries to the small intestine (jejunal and ileal) arise from the right instead of the left side of the superior mesenteric artery.

† See article by J. Ernest Frazer and R. H. Robbins 'On the factors concerned in causing rotation of the intestine in man,' *Journal of Anatomy and Physiology*, vol. L.

CC-0. In Public Domain. Gurukul Kangri Collection, Haridwar

Digitized by Arya Samaj Foundation Chennai and eGangotri

Further changes take place in the bursa omentalis and in the common mese and give rise to the peritoneal relations seen in the adult. The bursa ome which at first reaches only as far as the greater curvature of the stomach, ex downwards in front of the transverse colon and the coils of the small inte to form the greater omentum (fig. 208). Before the pleuroperitoneal op is closed, the bursa omentalis sends a diverticulum upwards on either side o œsophagus; the left diverticulum soon disappears, but the right is constrict and forms the *bursa infracardiaca* which may persist in the adult as a small sac within the thorax on the right side of the lower end of the œsophagus. The an layer of the transverse mesocolon is at first distinct from the posterior layer o greater omentum, but the two layers blend, and then the greater omentum be attached to the transverse colon (fig. 209). The mesenteries of the ascending descending parts of the colon disappear in the majority of cases, while that o small intestine assumes the oblique attachment characteristic of its adult cond

The lesser omentum is formed, as indicated above, by a thinning of the derm (*ventral mesogastrium*) which attaches the stomach and duodenum t anterior abdominal wall. By the subsequent growth of the liver this leaf of derm is divided into two parts, viz. the lesser omentum between the stomach liver, and the falciform and coronary ligaments between the liver and the abdo wall and Diaphragm (figs. 203, 208).

The **rectum and anal canal.**—The hind-gut is at first prolonged backw into the body-stalk as the tube of the allantois; but, with the growth and fle of the tail-end of the embryo, body-stalk, with its contained alla tube, is carried forwards to the ve aspect of the body, and consequ a bend is formed at the junctio the hind-gut and allantois. This dilates to form a pouch, which stitutes the *entodermal cloaca*; its dorsal part the hind-gut opens from its ventral part the alla passes into the body-stalk. later stage the Wolffian and Müll ducts open into the ventral porti the cloaca. The cloaca is, for a shut off from the exterior by *cloacal membrane* which is forme the apposition of a thick ectode and a thin entodermal layer, reaches at first as far forwards a future umbilicus. Behind the um cus, however, the mesoderm s quently extends to form the symphysis pubis and the lower part of the abdo wall. By the growth of the surrounding tissues the cloacal membrane com lie at the bottom of a depression, which is lined by ectoderm and named *ectodermal cloaca* (fig. 210)

Fig. 212.—The tail-end of a human embryo, eight and a half to nine weeks old. (From a model by Keibel.)

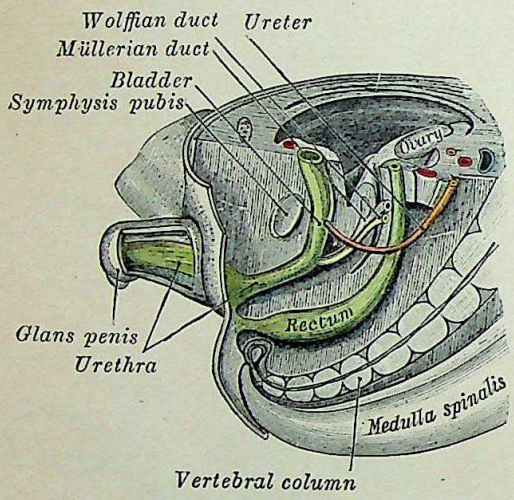

The entodermal cloaca is divided into a narrow dorsal and a wide ventral by means of a partition, the *urorectal septum* (fig. 211). This septum g downwards from the ridge separating the allantoic from the cloacal opening o intestine and, fusing with the cloacal membrane, divides the latter into an and a urogenital membrane. The dorsal part of the cloaca forms the rectum the anterior part the urogenital sinus and bladder. For a time a communic named the *cloacal duct* exists between the two parts of the cloaca below the uror septum; this duct occasionally persists as a passage between the rectum an bladder or urethra. By the upgrowth of the surrounding parts the anal p the cloacal membrane comes to lie at the bottom of a depression, the *proctod* or *anal pit*. On the absorption and disappearance of this membrane the re communicates with the anal canal (fig. 212). A small part of the hind-gut pr backwards beyond the anal membrane; it is named the *post-anal gut* (fig. and usually becomes obliterated and disappears.*

* Consult in this connexion: 'A contribution to the morphology of the human uro tract,' by D. Berry Hart, *Journal of Anatomy and Physiology*, vol. xxxv.

CC-0. In Public Domain. Gurukul Kangri Collection, Haridwar

Digitized by Arya Samaj Foundation Chennai and eGangotri

The **liver** arises as a diverticulum from the ventral surface of the fore-gut at e point where the latter joins the yolk-sac (fig. 213). This diverticulum is lined th entoderm, and grows upwards and forwards into the septum transversum which a mass of mesoderm between the vitelline duct and the pericardial cavity; the

FIG. 213.—The liver with the septum transversum. Human embryo. (After a model and figure by His.)

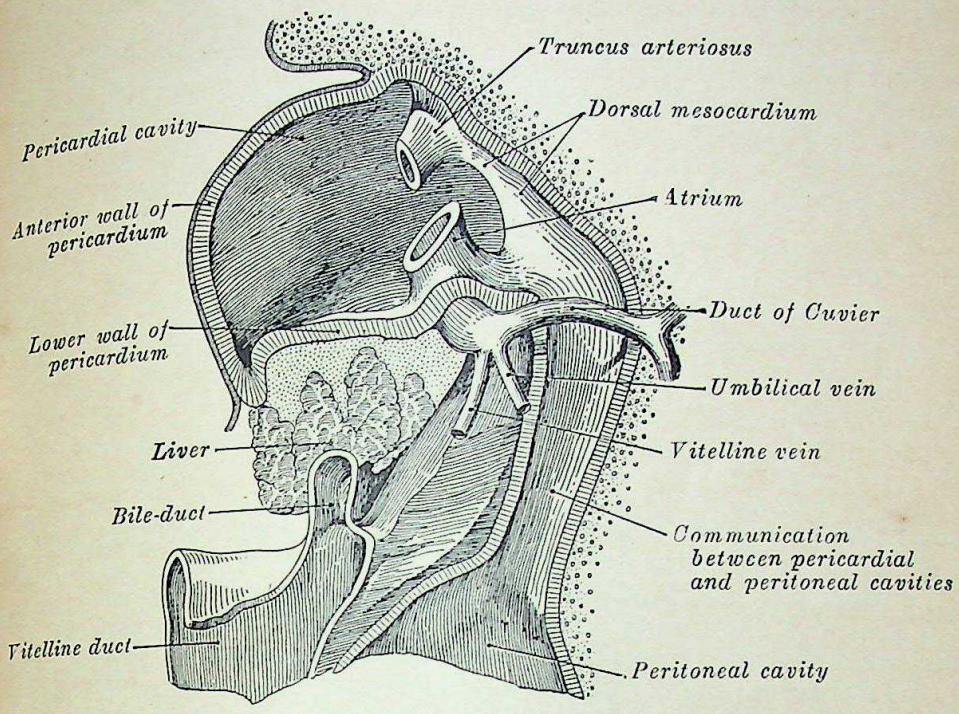

verticulum gives off two solid buds of cells which represent the right and the t lobes of the liver. The solid buds of cells grow into columns or cylinders, termed e *hepatic cylinders*, which branch and anastomose to form a close meshwork. is network invades the vitelline and umbilical veins, and breaks them up into eries of capillary-like vessels termed *sinusoids* (Minot), which ramify in the meshes the cellular network. By the continued growth and ramification of the hepatic linders the mass of the liver is gradually formed. The original diverticulum from e duodenum forms the bile-duct, and from this the cystic duct and gall-bladder

IG. 214.—The pancreas of a human embryo, five weeks old. (Kollmann.)

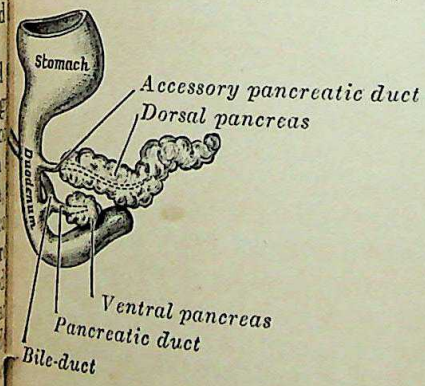

FIG. 215.—The pancreas of a human embryo, at the end of the sixth week. (Kollmann.)

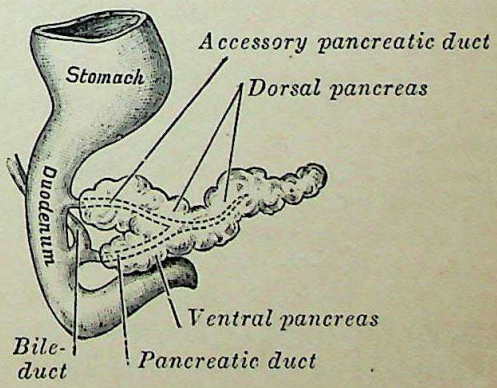

se as a solid outgrowth which later acquires a lumen. The opening of the bile-ct is at first in the ventral wall of the duodenum; later, owing to the rotation the gut the opening is carried to the left and then dorsalwards to the position occupies in the adult.

CC-0. In Public Domain. Gurukul Kangri Collection, Haridwar

Digitized by Arya Samaj Foundation Chennai and eGangotri

As the liver undergoes enlargement, both it and the ventral mesoga are gradually differentiated from the septum transversum; and from the surface of the latter the liver projects downwards into the abdominal cavity the growth of the liver the ventral mesogastrium is divided into two parts, of the anterior forms the falciform and coronary ligaments and the poster lesser omentum. About the third month the liver almost fills the abd cavity, and its left lobe is nearly as large as its right. From this period the r development of the liver is less active, more especially that of the left lobe,

FIG. 216.—A schematic and enlarged transverse section through the body of human embryo, in the region of the mesogastrium. At the beginning the third month. (Modified from Toldt.)

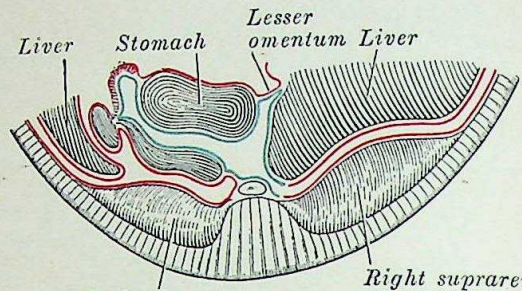

actually undergoes some degeneration and becomes smaller than the right; b to the end of fœtal life the liver remains relatively larger than in the adult.

The **pancreas** (figs. 214, 215).—The pancreas is developed in two parts, a and a ventral. The former arises as a diverticulum from the dorsal wall duodenum a short distance above the hepatic diverticulum, and, growing up and backwards into the dorsal mesogastrium, forms the whole of the body a of the pancreas and a part of the head and uncinate process. The ventra appears in the form of a diverticulum from the primitive bile-duct at the spot the latter opens into the duodenum; from the ventral pancreas the rem of the head and uncinate process of the pancreas are developed. The duct dorsal part (accessory pancreatic duct) therefore opens directly into the duod while that of the ventral part (pancreatic duct) opens with the bile-duct.

FIG. 217.—A schematic and enlarged transverse section through the same regio as in fig. 216, at end of the third month. (Modified from Toldt.)

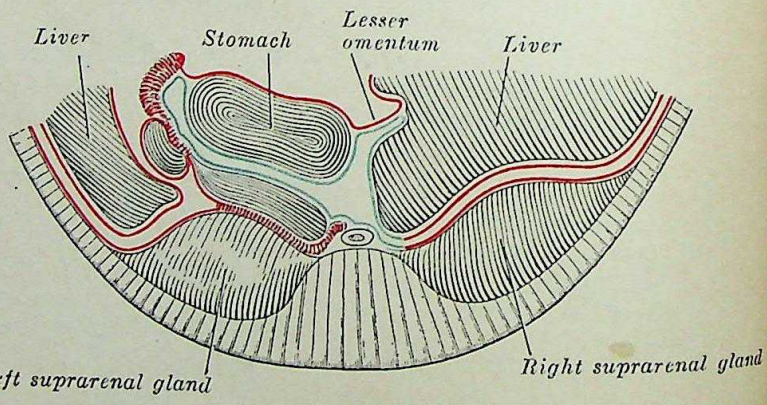

the sixth week the two parts of the pancreas meet and fuse, and a communic is established between their ducts. After this has occurred the terminal p the accessory duct, i.e. the part between the duodenum and the point of me of the two ducts, undergoes little or no enlargement, while the duct of the ve part increases in size and forms the main duct of the gland. The opening accessory duct into the duodenum is sometimes obliterated, and even wh remains patent it is probable that the whole of the pancreatic secretion is conv through the pancreatic duct.

CC-0. In Public Domain. Gurukul Kangri Collection, Haridwar

Digitized by Arya Samaj Foundation Chennai and eGangotri

At first the pancreas is directed upwards and backwards between the two layers the dorsal mesogastrium, which give to it a complete peritoneal investment, d its surfaces look to the right and left. With the change in the position of e stomach the dorsal mesogastrium is drawn downwards and to the left, and the ht side of the pancreas is directed backwards, and the left forwards (fig. 216). e right surface becomes applied to the posterior abdominal wall, and the ritoneum which covers it undergoes absorption (fig. 217); and thus, in the adult, e gland lies behind the peritoneal cavity.

The **spleen** (fig. 204).—Although the spleen belongs to the group of ductless nds, its development may be conveniently referred to here. It appears about e fifth week as a localised thickening of the mesoderm in the dorsal mesogastrium ove the tail of the pancreas. With the change in position of the stomach the leen is carried to the left, and comes to lie behind the stomach and in contact th the left kidney. The part of the dorsal mesogastrium which intervened tween the spleen and the greater curvature of the stomach forms the gastrosplenic ament (gastrosplenic omentum).

FIG. 218.—The head and neck of a human embryo thirty-two days old. Ventral aspect. The floor of the mouth and the ventral wall of the pharynx have been removed. (His.)

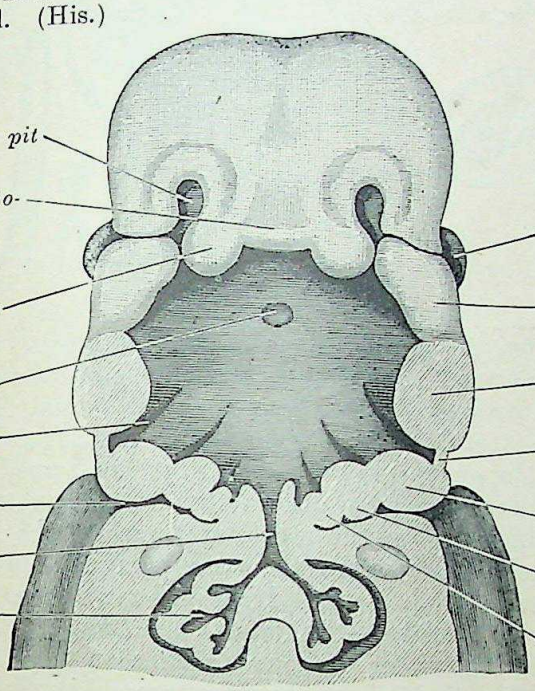

The **respiratory organs.**—The rudiment of the respiratory organs appears in e fourth week as a median *laryngotracheal groove* in the ventral wall of the harynx. The groove deepens and its lips fuse to form a septum which grows om below upwards and converts the groove into a tube, the *laryngotracheal tube* g. 218), the cephalic end of which opens into the pharynx by a slit-like aperture rmed by the persistent anterior part of the groove. The tube is lined with ntoderm, and from this the epithelial lining of the respiratory tract is developed. he cephalic part of the tube forms the larynx, and its next succeeding part the rachea, while from its caudal end two lateral outgrowths, the right and left *lung-ds*, arise, and from the mesoderm surrounding them the connective tissue of the ronchi and lungs are developed.

The first rudiment of the larynx consists of two *arytænoid swellings*, which ppear, one on either side of the cephalic end of the laryngotracheal groove, nd are continuous in front of the groove with a transverse ridge (*furcula* His) which lies between the ventral ends of the fourth branchial arches nd from which the epiglottis is subsequently developed (figs. 197, 198). After e separation of the trachea from the œsophagus, the arytænoid swellings me into contact with one another and with the back of the epiglottis, and the trance to the larynx assumes the form of a T-shaped cleft, the margins of the cleft here to one another and the laryngeal centre Kangri Collection, Haridwar occluded. The

CC-0. In Public Domain. Gurukul Kangri Collection, Haridwar

Digitized by Arya Samaj Foundation Chennai and eGangotri

arytænoid swellings are differentiated into the arytænoid and corniculate car and the folds joining them to the epiglottis form the aryepiglottic folds in the cuneiform cartilages are developed as derivatives of the epiglottis. The th cartilage is developed from the ventral ends of the cartilages of the four fifth branchial arches; it appears as two lateral plates, each chondrified fro centres and united in the midventral line by membrane in which an add centre of chondrification develops. The cricoid cartilage arises from two c ginous centres, which soon unite ventrally and gradually extend and ulti fuse on the dorsal aspect of the tube.*

According to Frazer,† who has made an important investigation on the de ment of the larynx, the glottis or space between the vocal folds is the pr opening of the larynx. During the second and third months a lateral mass (a noid swelling), derived from the fourth and fifth arches, grows forward on eith

Fig. 219.—The lung-buds from a human embryo, about four weeks old, showing commencing lobulation. (His.)

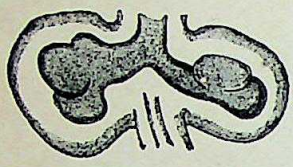

Fig 220.—The lungs of a human emb more advanced in development. (His.

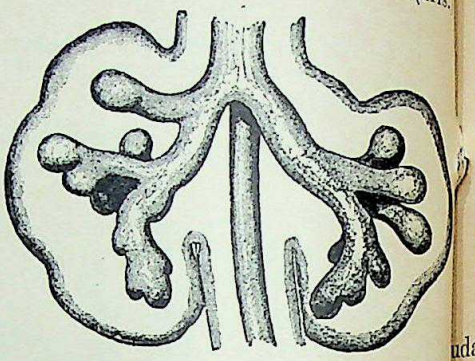

of the primary opening, and from these masses the lateral walls of the ves of the larynx are developed. A third elevation or 'central mass' is formed b the second and third arches. These three masses bound the secondary op of the larynx. In the lateral masses the arytænoid cartilages and aryepiglottic are developed; from the central mass the epiglottis is formed.

The right and left lung-buds grow out posterior to the ducts of Cuvier, and into lobules, three appearing on the right, and two on the left, lung-bud; subdivisions are the early indications of the corresponding lobes of the lungs (figs 220). The buds undergo further subdivision and ramification, and ultimatel in minute expanded extremities—the infundibula of the lung. After the month the air-sacs begin to make their appearance on the infundibula in the of minute pouches. The pulmonary arteries are derived from the sixth a arches. During the course of their development the lungs migrate in a c direction, so that by the time of birth the bifurcation of the trachea is opp the fourth thoracic vertebra. As the lungs grow they project into the pl passages or parts of the cœlom which will ultimately form the pleural sacs, an splanchnic mesoderm enveloping the lung rudiment expands on the growing and is converted into the pulmonary pleura.

THE DEVELOPMENT OF THE BODY-CAVITIES

In the human embryo described by Peters the mesoderm outside the embr disc is split into two layers enclosing the extra-embryonic part of the cœlom. appear in the embryonic part of the mesoderm, and fuse to form the intra-embr part of the cœlom. At first the two parts of the cœlom are separated from another, but later they become continuous around the orifice of the future umbi on the closure of which the continuity is again lost. The intra-embryonic p the cœlom forms the pericardial, pleural and peritoneal cavities; the e

* E. Fawcett, *loc. cit.*

† J. Ernest Frazer, *Journal of Anatomy and Physiology*, vol. xliv.

CC-0. In Public Domain. Gurukul Kangri Collection, Haridwar

Digitized by Arya Samaj Foundation Chennai and eGangotri

bryonic part is obliterated by the expansion of the amnion, and the consequent ion of the amniotic with the chorionic mesoderm (figs. 90, 91). From the peri- dial (cephalic) part of the cœlom two canals or passages (pleural passages) extend

FIG. 221.—A transverse segment through the upper part of the cœlom of a human embryo about four weeks old. (Kollmann.)

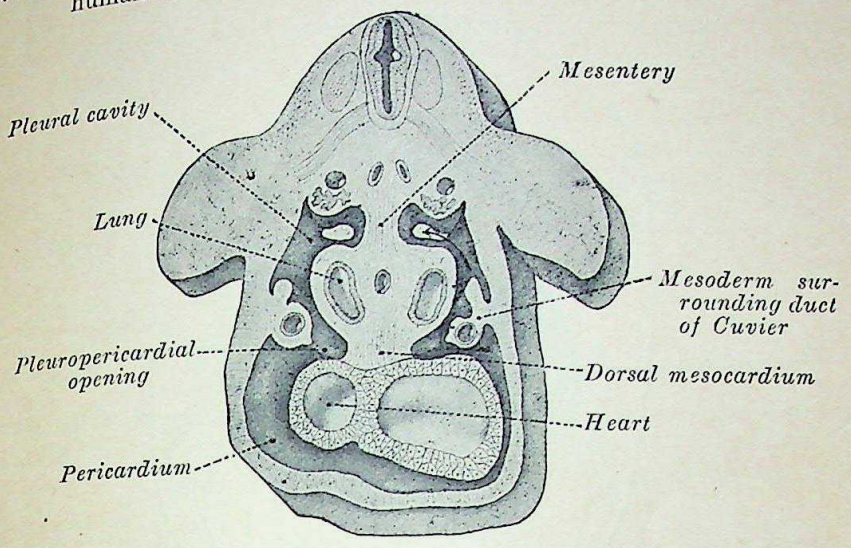

The upper arrow is in the pleuroperitoneal, the lower in the pleuropericardial opening.

ndalwards and open into the peritoneal part of the cœlom (fig. 221). These pleural ssages ultimately form the pleural cavities. Between the pleural passages is a ass of mesoderm continuous ventrally with that in which the umbilical veins are ssing to the sinus venosus. A septum of mesoderm thus extends across the body the embryo. It is attached in front to the body-wall between the pericardium d umbilicus; behind to the body-wall at the level of the second cervical segment;

FIG. 222.—The upper part of the cœlom of a human embryo of 6·8 mm. long. Dorsal aspect. (From a model by Piper.)

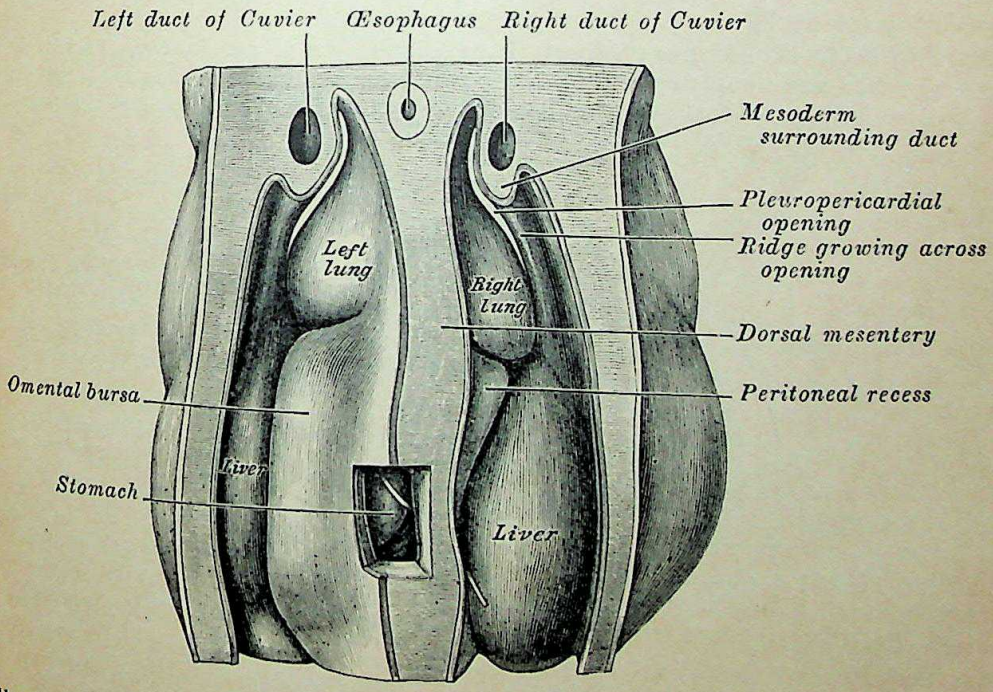

erally it is deficient where the pericardial and peritoneal cavities communicate rough the pleural passages; in the middle line it is perforated by the fore-gut. is partition is termed the *septum transversum*, and is at first a bulky plate of

CC-0. In Public Domain. Gurukul Kangri Collection, Haridwar

Digitized by Arya Samaj Foundation Chennai and eGangotri

tissue; within it the liver is developed, and from it the principal part Diaphragm is formed. As development proceeds the dorsal end of the septum versum is carried gradually caudalwards, and when it reaches the fourth

FIG. 223.—A diagram of a transverse section through a rabbit embryo. (After Keith.)

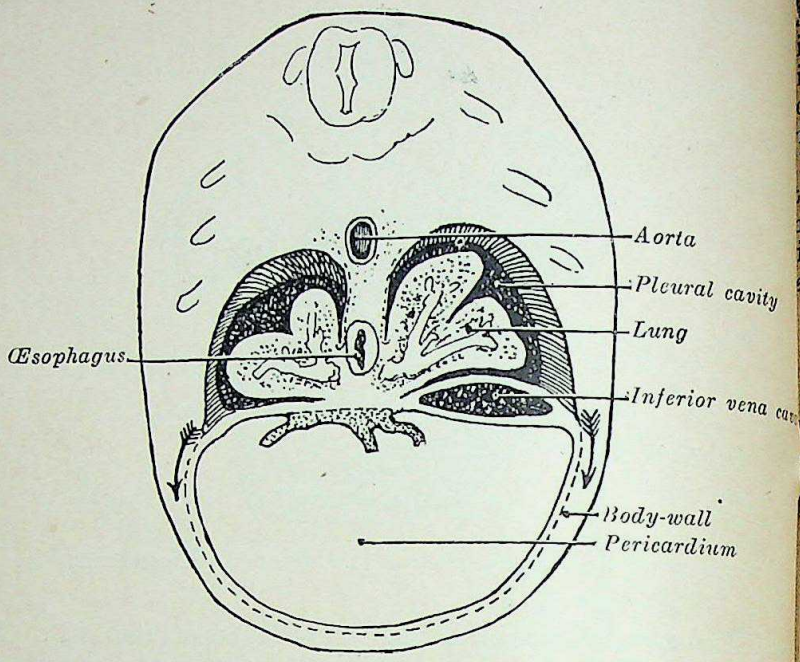

segment muscular tissue and the phrenic nerve grow into it. It continues to however, until it reaches the position of the adult Diaphragm on the bodies upper lumbar vertebræ.

The lung-buds meanwhile grow out from the caudal end of the laryngotr tube (p. 145) into the pleural passages and distend these passages to form the cavities (fig. 223). Those parts of the lungs which grow in an upward or ce direction pass on the lateral sides of the ducts of Cuvier, and gradually push

FIG. 224.—The thoracic aspect of the Diaphragm of a new-born child in whic the communication between the peritoneum and pleura has not been clos on the left side; the position of the opening is marked on the right side b the spinocostal hiatus. (After Keith.)

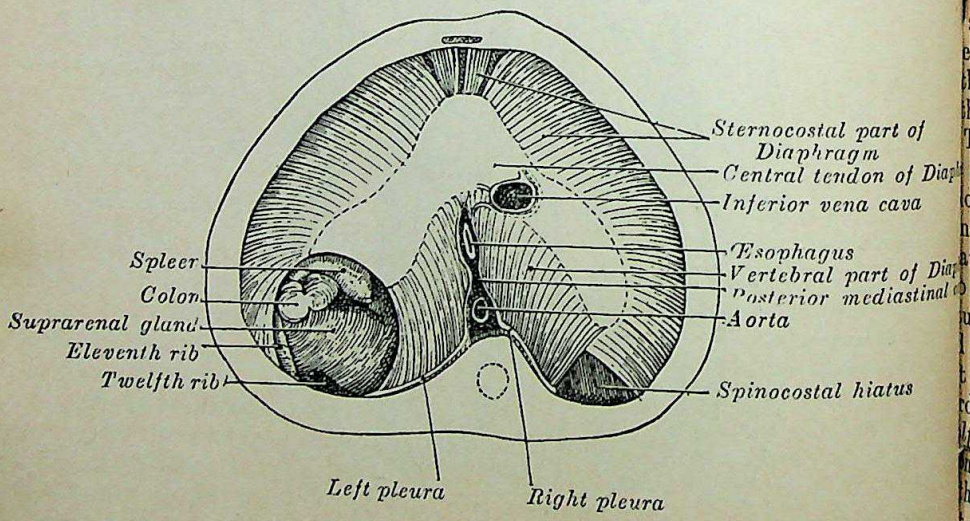

ducts and the mesoderm in which they lie against the pleuropericardial open with the result that the latter are soon reduced to mere slits (fig. 222). Owi the descent of the dorsal end of the septum transversum and the lung buds come

CC-0. In Public Domain. Gurukul Kangri Collection, Haridwar

Digitized by Arya Samaj Foundation Chennai and eGangotri

ve the septum, and thus pleural and peritoneal portions of the cœlom (still, rever, in communication with one another) may be recognised.

The ultimate separation of the pericardial, pleural, and peritoneal cavities from another is effected by the growth of a ridge of tissue (*pulmonary ridge* of Mall) either side from the mesoderm surrounding the duct of Cuvier (figs. 221, 222). front or cephalic part of this ridge (pleuropericardial membrane) grows across obliterates the pleuropericardial opening; the hinder or caudal part (pleuro-itoneal membrane) grows across the pleuroperitoneal opening. The pleuro-itoneal openings may remain patent; fig. 224 represents a persistent left opening, ough which the spleen and left suprarenal body projected into the left pleural ity.

With the continued growth of the lungs the pleural cavities are pushed forwards he body-wall towards the ventral median line, thus separating the pericardium n the lateral thoracic walls (fig. 223). The further development of the peritoneal ity has been described with the development of the digestive tube (p. 137 eq.).

THE DEVELOPMENT OF THE UROGENITAL ORGANS

The urinary and generative organs are developed from the intermediate cell-mass h is situated between the primitive segments and the lateral plates of mesoderm. permanent organs of the adult are preceded by a set of embryonic structures

FIG. 225.—A transverse section through a ferret embryo. (A. Robinson.)

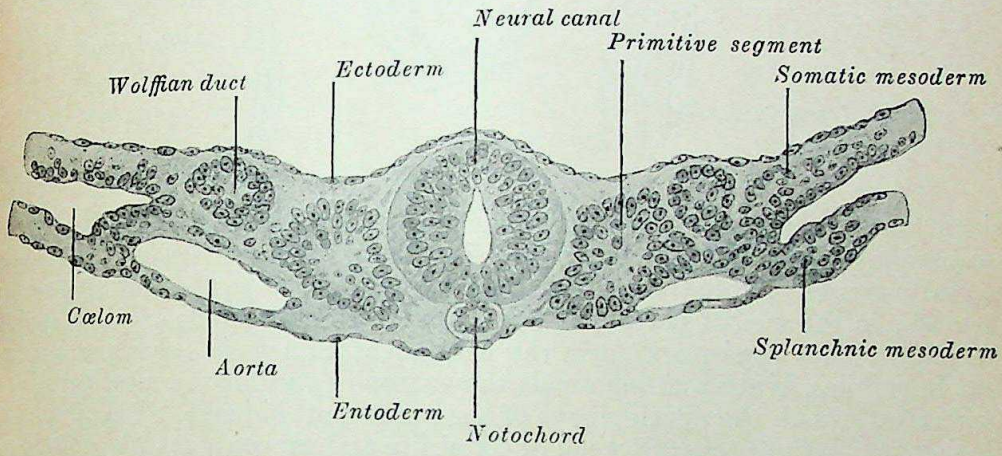

ither side; these consist of the pronephros, the mesonephros, the metanephros, the Wolffian and Müllerian ducts. The pronephros disappears very early; structural elements of the mesonephros mostly degenerate, but in their place eveloped the genital gland, in association with which the Wolffian duct remains he duct of the male genital gland, the Müllerian as that of the female; some he tubules of the metanephros form part of the permanent kidney.

The **pronephros and the Wolffian duct.**—In the intermediate cell-mass of lower thoracic and upper cervical segments short evaginations from the om grow dorsalwards into each segment. The evaginations form a series of nsverse tubules each of which communicates by means of a funnel-shaped ated opening with the cœlomic cavity, and in the course of each duct a glomerulus is developed. Secondary glomeruli are formed, and the complete group con-utes the *pronephros*. The tubules of the pronephros undergo rapid atrophy disappear. A solid rod of cells forms in the mesoderm of the lateral cell-mass, under the ectoderm and overlying the pronephros. This rod grows caudal-rds to reach the ventral part of the cloaca, and becoming canalised, forms the *lffian duct* (fig. 225). In lower vertebrates its head-end acts as a duct for the nephros and is termed the *pronephric duct*, but in man this function is in abeyance he pronephros is a rudimentary and very transitory structure, the proximal part undergoing atrophy while the distal part is still in process of formation.

The **mesonephros, Müllerian duct, and genital gland.**—On the medial side of Wolffian duct, and extending from the sixth cervical to the third lumbar

CC-0. In Public Domain. Gurukul Kangri Collection, Haridwar

Digitized by Arya Samaj Foundation Chennai and eGangotri

segment, the *Wolffian tubules* (fig. 226) are developed. Each tubule first ap a solid mass of cells, which later becomes hollowed in the centre; one en towards and finally opens into the Wolffian duct, the other dilates and is inva by a tuft of capillary blood-vessels to form a glomerulus. The tubules coll constitute the *mesonephros or Wolffian body* (figs. 201, 205, 227). By the

FIG. 226.—A section through the urogenital fold of a chick embryo, four days old. (Waldeyer.)

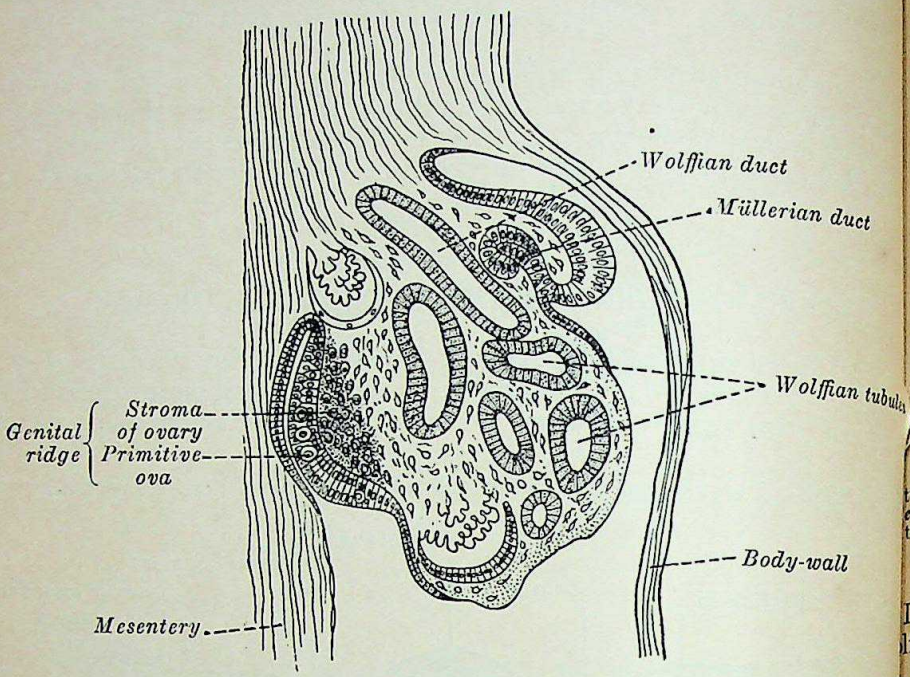

sixth week this body forms an elongated spindle-shaped structure, term *urogenital fold* (fig. 226), which projects into the cœlomic cavity on either side dorsal mesentery, from the septum transversum in front to the fifth lumbar s behind; in the medial parts of these folds the genital glands are developed Wolffian bodies persist and form the permanent kidneys in fishes and ampl but in reptiles, birds, and mammals they atrophy and for the most part dis coincidently with the development of the permanent kidneys. The atrophy during the sixth or seventh week of fœtal life and proceeds rapidly, so that beginning of the fifth month only the ducts and a few of the tubules remain.

FIG. 227.—The left Wolffian body before any distinction of sex has appeared. Anterior aspect. Enlarged. (From Farre, after Kobelt.)

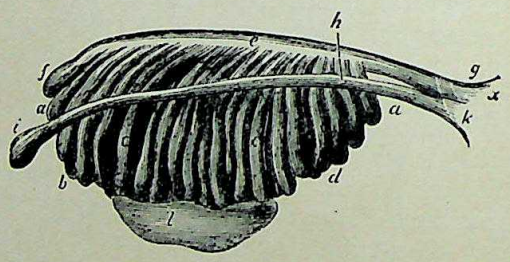

a, a, b, c, d. Tubular structure of the Wolffian body. *e.* Wolffian duct. *f.* Its upper extre *g.* Its termination in *x*, the urogenital sinus. *h.* Müllerian duct. *i.* Its upper, funnel-shaped extre *k.* Its lower end, terminating in the urogenital sinus. *l.* Genital gland. *x.* Urogenital sinus.

In the male the Wolffian duct persists, and forms the tube of the epidi the ductus deferens, and the ejaculatory duct; during the third month the s vesicle arises as a lateral diverticulum from the hinder end of the duct. A part of the head end of the mesonephros atrophies and disappears; of the rem the anterior tubules form the efferent ducts of the testis; while the posterior t

CC-0. In Public Domain. Gurukul Kangri Collection, Haridwar

Digitized by Arya Samaj Foundation Chennai and eGangotri

represented by the ductuli aberrantes, and by the paradidymis which is some-
es found in front of the spermatic cord above the head of the epididymis
230, C).

FIG. 228.—The broad ligament of an adult, showing the epoöphoron. (From Farre, after Kobelt.)

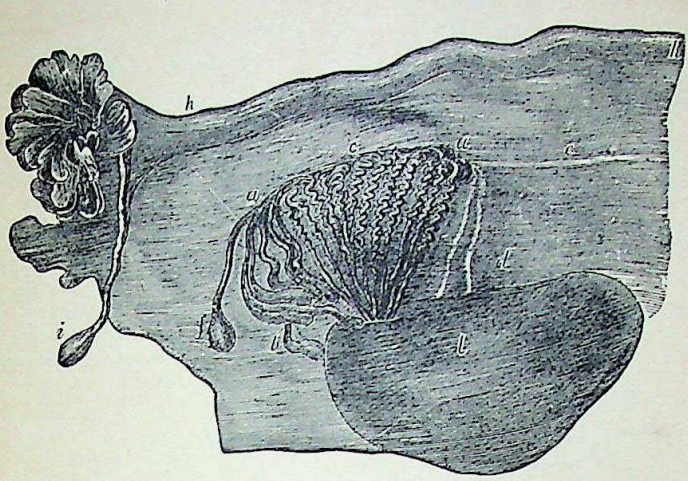

a, a. Epoöphoron formed from the upper part of the Wolffian body. *b.* Remains of the uppermost tubes, sometimes forming appendices. *c.* Middle set of tubes. *d.* Some lower atrophied tubes. *e.* Atrophied remains of the Wolffian duct. *f.* Terminal bulb or hydatid. *h.* Uterine tube, originally the proximal part of the Müllerian duct. *i.* Appendix attached to the extremity. *l.* Ovary.

In the female the Wolffian bodies and ducts atrophy. The remains of the lffian tubules are represented by the epoöphoron or organ of Rosenmüller, and paroöphoron, two small collections of rudimentary, blind tubules which are ated in the mesosalpinx (fig. 228).

e lower part of the Wolffian duct ppears, while the upper part persists he longitudinal duct of the epoöphoron uct of Gärtner * (fig. 230, B).

The **Müllerian ducts.**—Shortly after formation of the Wolffian ducts a ond pair of ducts is developed; these named the *Müllerian ducts*. Each es on the lateral aspect of the corre-nding Wolffian duct as a tubular gination of the cells lining the cœlom 226). The orifice of the invagination ains patent, and undergoes enlarge-nt and modification to form the ominal ostium of the uterine tube. e ducts pass backwards, and run at t lateral to the Wolffian ducts; to-rds the posterior end of the embryo y cross to the medial side of the lffian ducts, and run side by side ween and dorsal to them—the four ducts forming the *genital cord* (fig. 229). e Müllerian ducts end on the *Müllerian eminence*, an epithelial elevation in the tral part of the cloaca between the orifices of the Wolffian ducts; at a later e they open into the cloaca in this situation.

FIG. 229.—The urogenital sinus of a female human embryo, eight and a half to nine weeks old. (From a model by Keibel.)

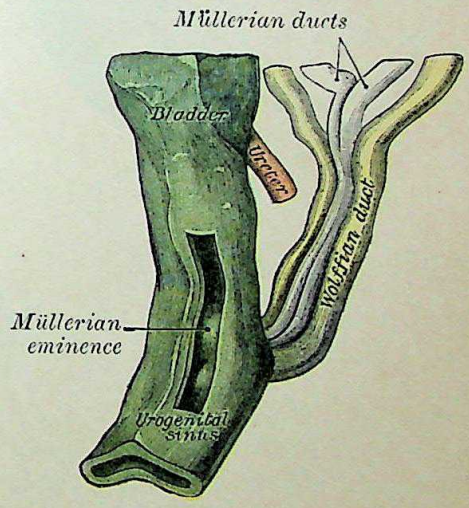

* Berry Hart (*op. cit.*) has described the Wolffian ducts as ending at the site of the future en in bulbous enlargements, which he has named the *Wolffian bulbs*; and states that the en is formed by these bulbs, 'aided by a special involution from below of the cells lining urogenital sinus.' He further believes that 'the lower third of the vagina is due to the escence of the upper portion of the urogenital sinus and the lower ends of the Wolffian s,' and that 'the epithelial lining of the vagina is derived from the Wolffian bulbs.' He regards the colliculus seminalis of the male urethra as being formed from the lower part he Wolffian ducts.

CC-0. In Public Domain. Gurukul Kangri Collection, Haridwar

Digitized by Arya Samaj Foundation Chennai and eGangotri

A

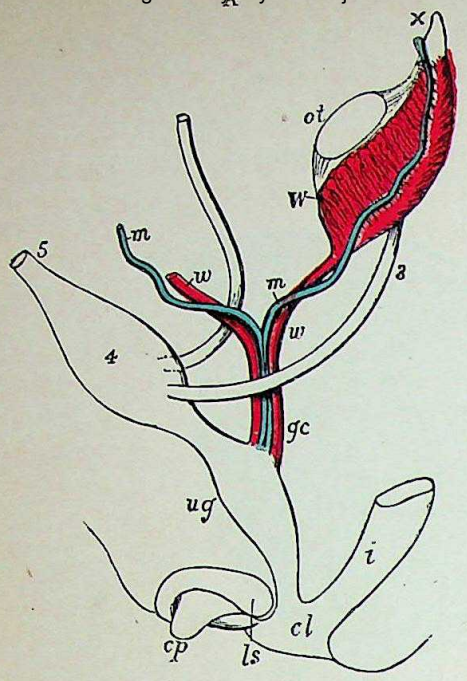

B

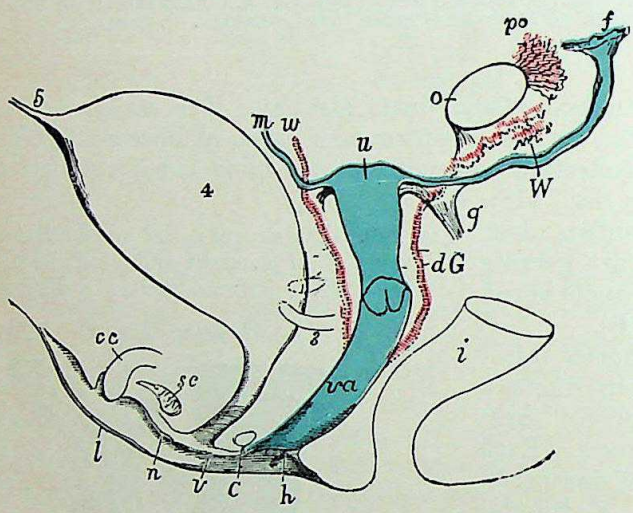

C

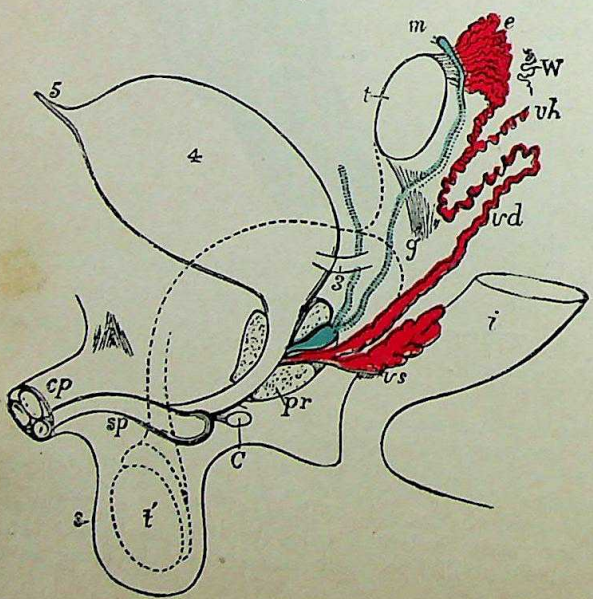

FIG. 230.—Diagrams to show development of the male and fe generative organs from a com type. (Allen Thomson.)

A.—A diagram of the primitive urogenital the embryo previous to sexual distin

3. Ureter. 4. Urinary bladder. 5. *cl.* Cloaca. *cp.* Elevation which bec clitoris (or the penis). *i.* Lower part of tine. *gc.* Genital cord. *ls.* Fold of in from which the scrotum or the labia m formed. *m, m.* Right and left Müller uniting and running with the Wolffian d the genital cord. *ot.* The genital ridge fr the ovary or the testis is formed. urogenitalis. *W.* Left Wolffian body. *w,* and left Wolffian ducts.

B.—A diagram of the fe of sexual organs.

C. Greater vestibular gla immediately above it the *cc.* Corpus cavernosum clitori Remains of the left Wolffia persisting as the left duct o ner, represented by dotted that of the right side is ma *f.* Abdominal opening of t uterine tube. *g.* Round li corresponding to the gubern *h.* Situation of the hymen. part of the intestine. *l.* L majus. *n.* Labium minus. ovary. *po.* Epoöphoron. Corpus cavernosum urethr Uterus. *m.* Right uterine *v.* Vulva. *va.* Vagina. *W.* tered remains of Wolffian forming the paroöphoron.

C.—A diagram of the male type o organs.

C. Bulbo-urethral gland of one s Corpora cavernosa penis cut short. epididymis. *g.* Gubernaculum. part of the intestine. *m.* Müller the upper part of which remains appendix testis (hydatid of Morga lower part, represented by a dot descending to the prostatic utri stitutes the occasionally existing the utricle. *pr.* Prostate. *s.* *sp.* Corpus cavernosum urethræ. in the place of its original f *t'*, together with the dotted lines indicates the direction in which th and epididymis descend from the into the scrotum. *vd.* Ductus *vh.* Ductulus aberrans. *vs.* Vesic nalis. *W.* Scattered remains Wolffian body.

CC-0. In Public Domain. Gurukul Kangri Collection, Haridwar

Digitized by Arya Samaj Foundation Chennai and eGangotri

In the male the Müllerian ducts atrophy, but traces of their anterior ends are resented by the appendices of the testes (hydatids of Morgagni), while their minal fused portions form the utricle which opens into the floor of the prostatic tion of the urethra (fig. 230, C).

In the female the Müllerian ducts persist and undergo further development. e portions of the ducts which lie in the genital cord fuse to form the uterus: e parts which are proximal to this cord remain separate, and each forms the responding uterine tube—the abdominal ostium of which is developed from the terior extremity of the original tubular invagination from the cœlom (fig. 230, B). e fusion of the distal parts of the Müllerian ducts begins in the third month, d the septum formed by their fused medial walls disappears from behind forwards, d thus the cavity of the uterus is produced. In some animals, and occasionally he human subject, the septum persists, giving rise to a bicornuate uterus. About fifth month an annular constriction marks the position of the neck of the uterus, d after the sixth month the lls of the uterus begin to thicken. e vagina is formed from two d extensions from the ends of Müllerian ducts; these grow first as solid cords which push r way towards the urogenital um. The ends fuse with one ther, and by the breaking wn of the central cells the cavity the vagina results, and this ity opens on the exterior through e urogenital septum; a portion the septum remains to form the men.

FIG. 231.—A transverse section through a human embryo, eight and a half to nine weeks old. (From a model by Keibel.)

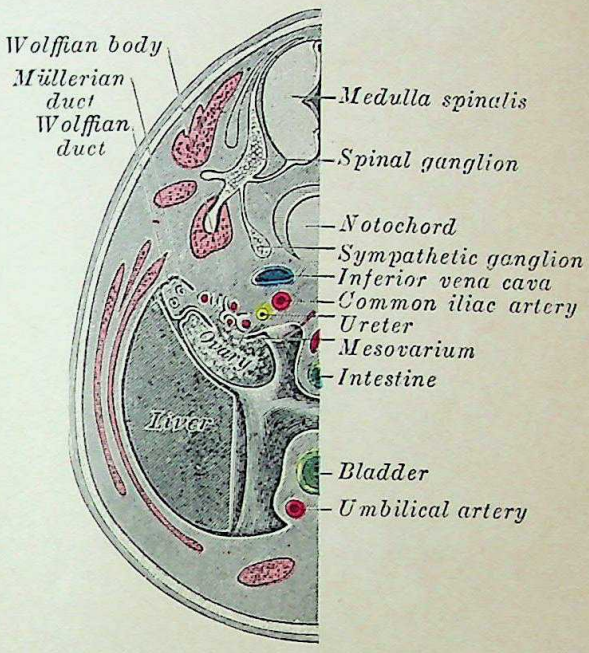

The **genital glands**.—The first pearance of the genital gland is entially the same in the two kes, and consists of a thickening the epithelial layer which lines e cœlomic cavity on the medial e of the urogenital fold (fig. 226). e thick plate of epithelium *nital epithelium*) extends deeply, d, pushing the mesoderm before forms a distinct projection, med the *genital ridge* (fig. 226). From the latter the testis in the male and the ry in the female are developed. At first the mesonephros and genital ridge suspended by a common mesentery, but as the embryo grows the genital ridge gradually pinched off from the mesonephros, with which it is at first continuous, ough it still remains connected to the remnant of this body by a fold of itoneum, the *mesorchium* (*or mesovarium*) (fig. 231). The distinction of sex in e genital ridge is perceptible about the seventh week.

In a 10 mm. embryo the genital gland reaches from about the sixth to the elfth thoracic segment. It subsequently extends as far as the second sacral gment, but simultaneously with this caudal extension the cranial three-fourths the gland undergo degeneration.

The **ovary**, formed from the genital ridge, is at first a group of cells derived m the genital epithelium; later the group is differentiated into a central mass d a layer of surface epithelium (fig. 232). Between the cells of the surface ithelium a number of larger cells, the *primitive ova*, are found, and these are rried into the subjacent stroma by bud-like ingrowths (*genital cords*) of the surface ithelium (fig. 233). The surface epithelium ultimately forms the permanent thelial covering of this organ; it loses its connexion with the central mass of lls, and a tunica albuginea develops between them. The ova are chiefly derived m the cells of the central mass; these cells are separated from one another by irregularly arranged growth of connective tissue; each ovum assumes a covering connective tissue (follicle) cells, and in this way the rudiments of the ovarian licles are formed (fig. 233).

CC-0. In Public Domain. Gurukul Kangri Collection, Haridwar

Digitized by Arya Samaj Foundation Chennai and eGangotri

It was formerly supposed that the primitive germ-cells were derived fro cœlomic epithelium covering the genital ridge, but it has been shown that, in the vertebrates at least, they are probably formed during the later stages of cell-cle They can be distinguished from the somatic cells by the large size of their bodi nuclei, and by their cytoplasm which is only faintly granular and has no affini ordinary stains, but assumes a brownish colour when treated by osmic acid. primitive germ-cells migrate first into the root of the mesentery and from there in cœlomic epithelium covering the genital ridge. A considerable number apparently reach their proper destination, since 'vagrant germ-cells are found in all sorts of but more particularly on the mesentery.'* Some of these may possibly find the into the germinal ridge; some probably undergo atrophy, while others may persi become the seat of dermoid tumours.

The **testis** is developed in much the same way as the ovary. Like the ov its earliest stages it consists of a central mass of epithelial cells covered by a

FIG. 232.—A longitudinal section of the ovary of a cat embryo, 9·4 cm. long. Sche (After Coert, from Hertwig's Handbuch der Entwickelungslehre.)

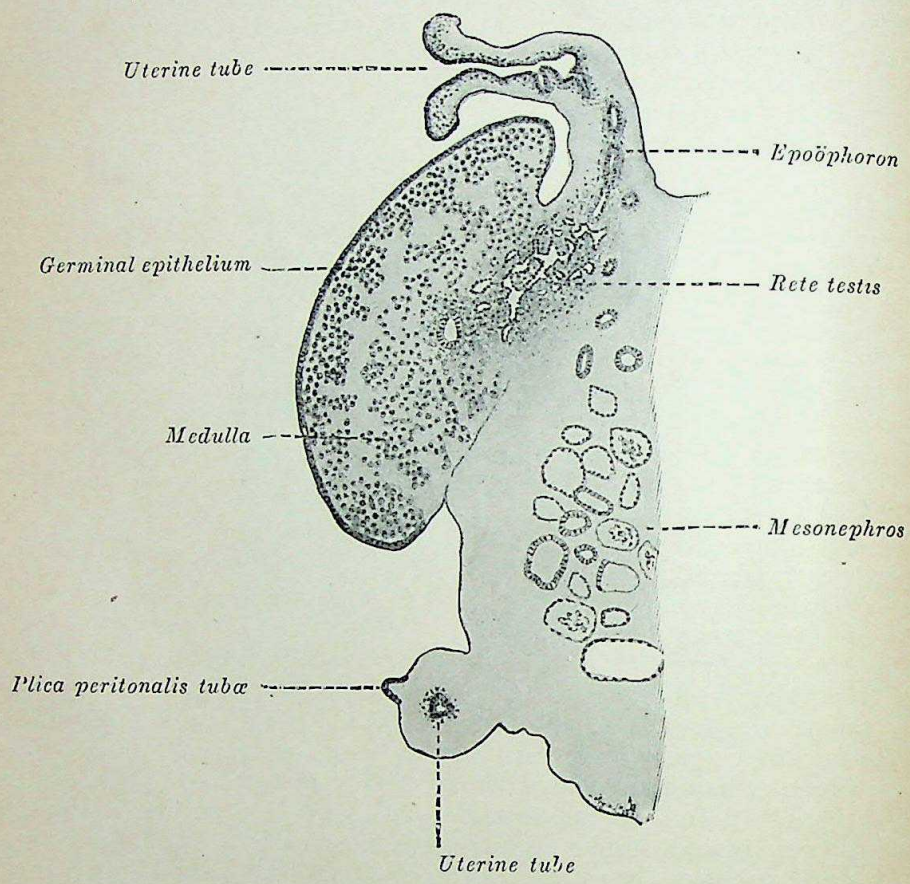

epithelium. In the central mass a series of epithelial cords (testis-cords) a (fig. 234); simultaneously the peripheral part of the central mass is converted a tunica albuginea which intervenes between the testis-cords and the su epithelium and excludes the latter from any part in the formation of the tiss the testis. The thin inner ends of the testis-cords converge towards the f hilum and there unite in a network which ultimately becomes the rete testis. the outer parts of the testis-cords the seminiferous tubules are developed. between them connective tissue septa extend. The tubules of the rete testis be connected with outgrowths from the Wolffian body, which, as already mentio form the efferent ducts of the testis.

The descent of the testes.—The testes at an early period of fœtal life, are pl in the posterior part of the abdominal cavity, and each is attached to the m nephros by a peritoneal fold, named the *mesorchium*. From the front of mesonephros a fold of peritoneum, termed the *inguinal fold*, grows forwards to and fuse with a peritoneal fold, named the *inguinal crest*, which grows backw

* Beard, *Journal of Anatomy and Physiology*, vol. xxxviii.

CC-0. In Public Domain. Gurukul Kangri Collection, Haridwar

Digitized by Arya Samaj Foundation Chennai and eGangotri

in the anterolateral abdominal wall. The testis thus acquires an indirect nexion with the anterior abdominal wall; and at the same time a portion of peritoneal cavity lateral to these fused folds is marked off as the future saccus

FIG. 233.—A section through the ovary of a new-born child. (Waldeyer.)

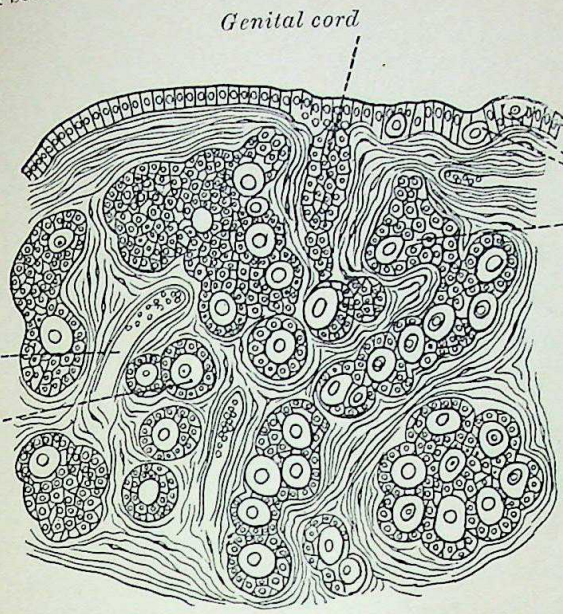

ginalis. In the inguinal crest a peculiar structure, the *gubernaculum testis*, akes its appearance. This is at first a slender band, extending from that part the skin which afterwards forms the scrotum, through the inguinal canal to the dy and epididymis of the testis. As development advances, the peritoneum closing the gubernaculum forms two folds, one above the testis and the other low it. The one above the stis is the *plica vascularis*, and ntains ultimately the testicular ssels. The one below, the *plica bernatrix*, contains the lower part the gubernaculum and ends at e abdominal inguinal ring in a e of peritoneum, the *saccus inalis*, which protrudes down inguinal canal. By the fifth nth the upper part of the guber- culum has disappeared, while e lower part has become a thick rd, and consists of a central re of unstriped muscle-fibres, d outside this of a firm layer striped elements, connected with e abdominal wall; as the scrotum velops, the main portion of the wer end of the gubernaculum is rried, with the skin to which it attached, to the bottom of this uch. The saccus vaginalis projects self downwards into the inguinal el, and emerges at the subcu- eous inguinal ring, pushing before a part of the Obliquus internus and the aponeurosis of the Obliquus externus, ich form respectively the Cremaster muscle and the intercrural fascia. It forms gradually elongating pouch, which eventually reaches the bottom of the scrotum, d behind this pouch the gubernaculum lies. The testis, being attached by the

FIG. 234.—A section through a genital cord of the testis of a human embryo 3·5 cm. long. (Felix and Bühler.)

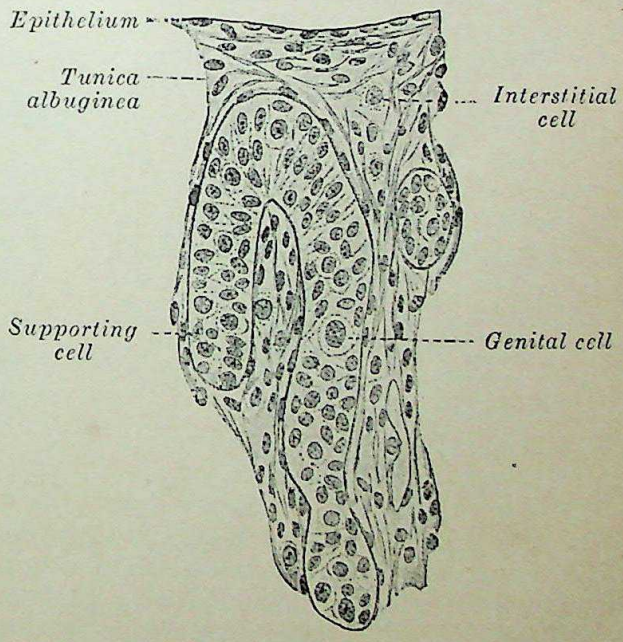

CC-0. In Public Domain. Gurukul Kangri Collection, Haridwar

Digitized by Arya Samaj Foundation Chennai and eGangotri

gubernaculum to the bottom of the scrotum, passes first into the inguin and eventually into the scrotum, invaginating the saccus vaginalis from It seems certain also that the gubernacular cord becomes shortened as devel proceeds, and this assists in causing the testis to reach the bottom of the s By the end of the eighth month the testis has reached the scrotum, and th part of the saccus vaginalis is converted into a narrow canal which is obl a short time after birth, and this o tion extends gradually downwa within a short distance of the The lower part of the saccus va is thus entirely cut off from the peritoneal cavity and constitut parietal portion of the *tunica vag*

FIG. 235.—The tail-end of a human embryo, twenty-five to twenty-nine days old. (From a model by Keibel.)

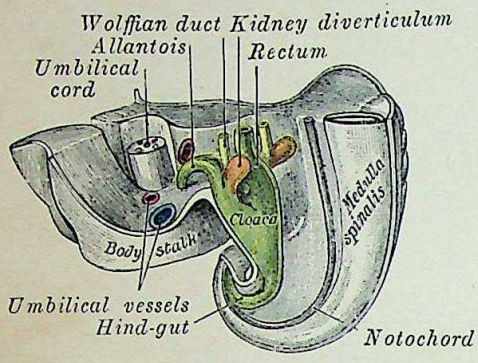

Descent of the ovaries.—In the there is also a gubernaculum, effects a considerable change position of the ovary, though extensive as that of the testis gubernaculum in the female contact with the fundus of the and contracts adhesions to this The part of the gubernaculum be the ovary and the uterus becomes t ment of the ovary, the part betwe uterus and the labium majus the round ligament of the uterus; a pouch o toneum analogous to the saccus vaginalis in the male accompanies it alo inguinal canal; it is called the *canal of Nuck.*

Applied Anatomy.—Sometimes the testes are retained within the abdomen or i canal, constituting what is known as cryptorchismus. In the female, in rare ca gubernaculum fails to contract adhesions to the uterus, and then the ovary d through the inguinal canal into the labium majus, and its position resembles tha testis.

The **metanephros and the permanent kidney.**—The rudiments of the perm kidneys make their appearance about the end of the first or the beginning second month. Each kidney has a twofold origin, part arising from the metanephros, and part as a diverticulum from the hind-end of the Wolffian duct close to where the latter opens into the cloaca (figs. 235, 236). The metanephros arises in the intermediate cell-mass, caudal to the mesonephros which it resembles in structure. The diverticulum from the Wolffian duct grows dorsalwards and cranialwards along the posterior abdominal wall, where its blind extremity expands and subsequently divides into several buds, which form the rudiments of the pelvis and calyces of the kidney; the collecting tubules are developed by continued growth and subdivision of the buds. The proximal portion o diverticulum becomes the ureter. The secretory tubules are developed fro metanephros, which is moulded over the growing end of the diverticulum the Wolffian duct. The tubules of the metanephros, unlike those of the prone and mesonephros, do not open into the Wolffian duct. One end of each t expands to form a glomerulus, while the remainder rapidly elongates to form convoluted tubule, the loop of Henle, and the junctional tubule; the last and establishes communication with one of the collecting tubules which are d from the ultimate ramifications of the diverticulum from the Wolffian duct.

FIG. 236.—The tail-end of a hum embryo, thirty-two to thirty-th days old. (From a model Keibel.)

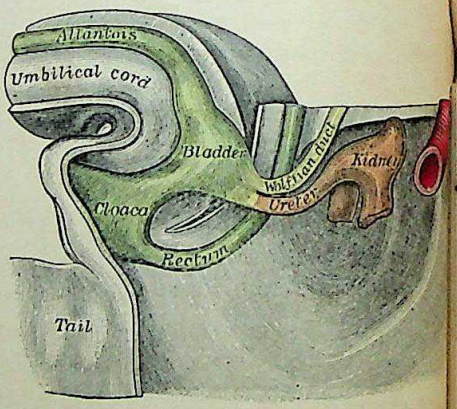

CC-0. In Public Domain. Gurukul Kangri Collection, Haridwar

Digitized by Arya Samaj Foundation Chennai and eGangotri

oderm around the tubules is condensed to form the connective tissue of the ey. The ureters open at first into the hind-end of the Wolffian ducts; but r the sixth week they open independently into the part of the cloaca which nately becomes the bladder.

237, 238).

he secretory tubules of the ey are arranged into pyramidal ses or lobules, the bases of ch are at the surface of the ey, while their apices constitute renal papillæ. The lobulated dition of the kidneys exists for e time after birth and traces of ay be found in the adult. The eys of the ox and many other nals remain lobulated throughout

Fig. 237.—The tail-end of a human embryo, eight and a half to nine weeks old. (From a model by Keibel.)

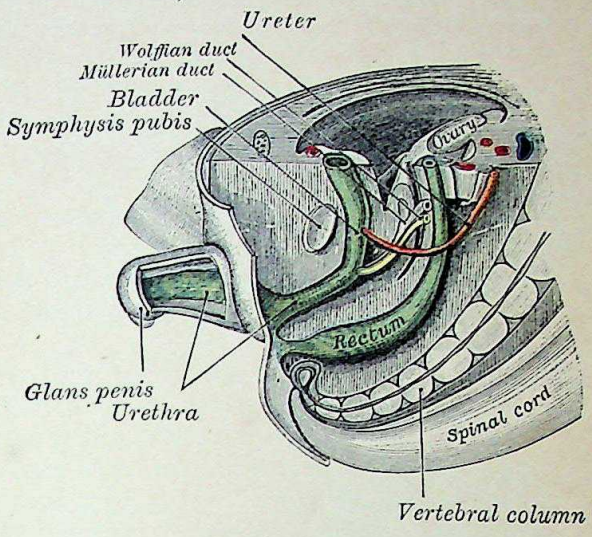

he **urinary bladder** is formed ly from the entodermal cloaca partly from the ends of the fian ducts. After the separation rectum from the dorsal part e cloaca (p. 142), the ventral of the latter becomes subdivided three portions: (1) a dorsal *co-urethral portion*, continuous the allantois—into this portion the Wolffian ducts open; (2) an intermediate row channel, the *pelvic portion*; and (3) a ventral broad *phallic portion*, closed rnally by the urogenital membrane (fig. 238). The second and third parts ther constitute the *urogenital sinus*. The vesico-urethral portion incorporates hind-ends of the Wolffian ducts and the associated ends of the renal diverticula, these give rise to the trigone of the bladder and part of the prostatic urethra. remainder of the vesico-urethral portion forms the body of the bladder and part he prostatic urethra; its apex is prolonged to the umbilicus as a narrow canal, ch later is obliterated and becomes the medial umbilical ligament (urachus).

Fig. 238.—The primitive kidney and the bladder, from a reconstruction. (After Schreiner.) (From Quain's Elements of Anatomy, vol. i., Embryology.)

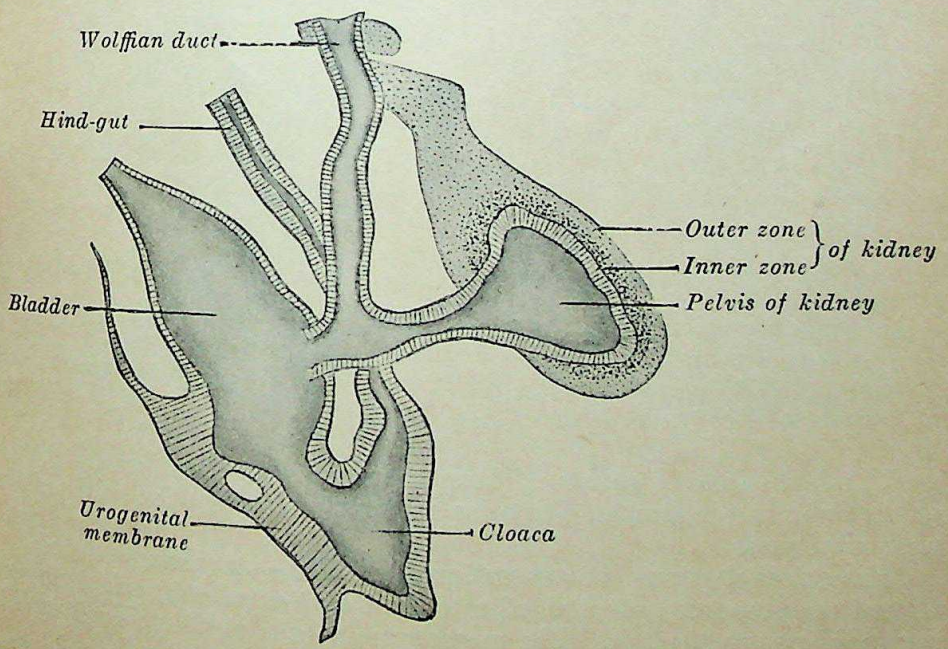

he **prostate** originally consists of two separate portions, each of which arises series of buds from the epithelial lining of the urogenital sinus and vesico-hral part of the cloaca, between the third and fourth months. These buds

CC-0. In Public Domain. Gurukul Kangri Collection, Haridwar

Digitized by Arya Samaj Foundation Chennai and eGangotri

become tubular, and form the glandular substance of the two lobes which ul meet and fuse behind the urethra and also extend on to its ventral aspe isthmus or middle lobe is formed as an extension of the lateral lobes betw common ejaculatory ducts and the bladder. In the female the urethral which open into the para-urethral ducts (Skene's ducts) are believed to homologues of the prostatic glands.

FIG. 239.—Stages in the development of the external sexual organs in the m and female. (From the Ecker-Ziegler models.)

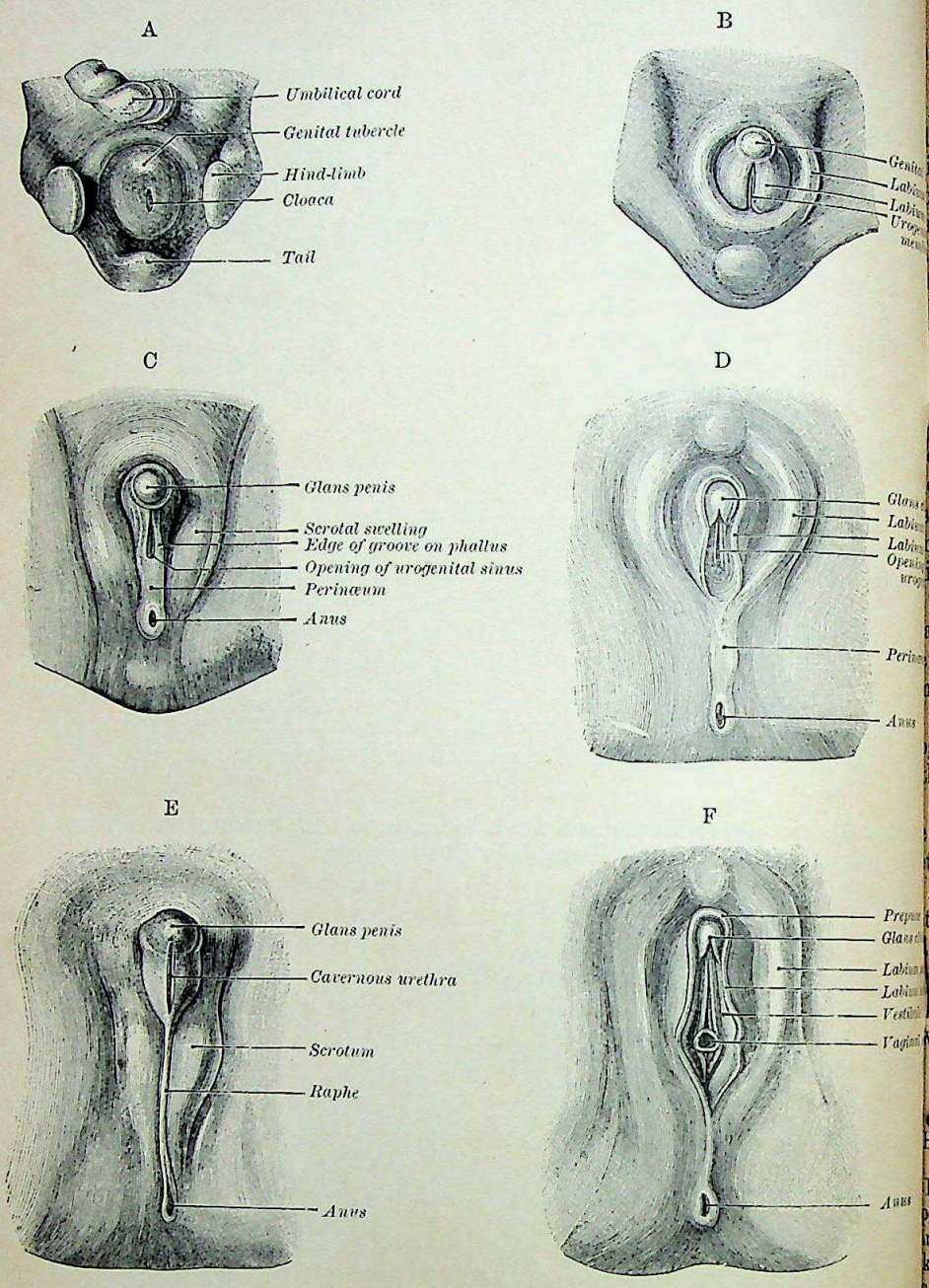

The *bulbo-urethral glands of Cowper* in the male, and *greater vestibular of Bartholin* in the female, also arise as diverticula from the epithelial lining urogenital sinus.

The **external organs of generation** (fig. 239).—As already stated (p. 14 cloacal membrane, composed of ectoderm and entoderm, originally reache the umbilicus to the tail. The mesoderm extends to the midventral line fo distance behind the umbilicus, and forms the lower part of the abdominal it ends below in a prominent swelling, the *cloacal tubercle*. Behind this t the urogenital part of the cloacal membrane separates the ingrowing sh mesoderm.

CC-0. In Public Domain. Gurukul Kangri Collection, Haridwar

Digitized by Arya Samaj Foundation Chennai and eGangotri

The first rudiment of the penis (or clitoris) is a structure termed the *phallus*; it is ved from the phallic portion of the cloaca which has extended on to the end and s of the under surface of the cloacal tubercle. The terminal part of the phallus, esenting the future glans penis, becomes solid; the remainder, which is hollow, is erted into a longitudinal groove by the absorption of the urogenital membrane. *In the female* a deep groove forms around the phallus and separates it from the of the cloacal tubercle, which is now termed the *genital tubercle*. The sides of genital tubercle grow backwards as the *genital swellings*, which ultimately form labia majora; the tubercle itself becomes the mons pubis. The labia minora e by the continued growth of the lips of the groove on the under surface of phallus; the remainder of the phallus forms the clitoris.

In the male the early stages are similar, but the pelvic portion of the cloaca ergoes much greater development, pushing before it the phallic portion. The ital swellings extend round between the pelvic portion and the anus, and form rotal area; during the changes associated with the descent of the testes this is drawn out to form the scrotal sacs. The penis is developed from the phallus. n the female, the urogenital membrane undergoes absorption, forming a channel the under surface of the phallus; this channel extends only as far forwards he corona glandis.

The corpora cavernosa of the penis (or clitoris) and of the urethra arise from esodermal tissue in the phallus; they are at first dense structures, but later ar spaces appear in them, and they gradually become cavernous.

The *prepuce* is formed by the growth of a solid plate of ectoderm into the erficial part of the phallus; on coronal section this plate presents the shape of orseshoe. By the breaking down of its more centrally situated cells the plate plit into two lamellæ, and a cutaneous fold, the prepuce, is liberated which ns a hood over the glans. 'Adherent prepuce is not an adhesion really, but ndered central desquamation' (Berry Hart, *op. cit.*).

The **urethra.**—As described above, in both sexes the phallic portion of the aca extends on to the under surface of the cloacal tubercle as far forwards as apex. At the apex the walls of the phallic portion come together and fuse, the en is obliterated, and a solid plate, the *urethral plate*, is formed. The remainder the phallic portion is for a time tubular, and then, by the absorption of the genital membrane, it establishes a communication with the exterior; this opening he *primitive urogenital ostium*, and extends forwards to the corona glandis.

In the female this condition is largely retained; the portion of the groove on clitoris broadens out while the body of the latter enlarges, and thus the adult thral opening is situated behind the base of the clitoris.

In the male, by the greater growth of the pelvic portion of the cloaca a longer thra is formed, and the primitive ostium is carried forwards with the phallus, it still ends at the corona glandis. Later the groove closes from behind forwards. nwhile the urethral plate of the glans breaks down centrally to form a median ve continuous with the primitive ostium. This groove also closes from behind wards, so that the external urethral opening is shifted forwards to the end of glans penis.

HE FORM OF THE EMBRYO AT DIFFERENT STAGES OF ITS GROWTH.

During the first week the ovum is in the uterine tube. Having been fertilised in the per part of the tube, it passes slowly along the tube—undergoing segmentation meanwhile nd ultimately reaches the uterus. Peters * described a specimen, the age of which he koned as from three to four days, but which was probably about fourteen days.† It s embedded in the decidua on the posterior wall of the uterus and enveloped by a decidua sularis, the central part of which, however, consisted merely of a layer of fibrin. The m was in the form of a sac, the outer wall of which consisted of a layer of trophoblast; de this was a thin layer of mesoderm composed of round, oval, and spindle-shaped s. Numerous villous processes—some consisting of trophoblast only, others possessing re of mesoderm—projected from the surface of the ovum into the surrounding decidua. de this sac the rudiment of the embryo was found in the form of a patch of ectoderm, ered by a small but completely closed amnion. It possessed a minute archenteron

* Hubert Peters, *Die Einbettung des menschlichen Eies*, 1899.

† Bryce and Teacher (*Early Development and Imbedding of the Human Ovum*, 1908) describe ovum, the age of which they estimate at 13 to 14 days; they are of opinion that the age of ers' ovum has been greatly understated, and should be reckoned as from 13½ to 14½ days.

CC-0. In Public Domain. Gurukul Kangri Collection, Haridwar

Digitized by Arya Samaj Foundation Chennai and eGangotri

and was surrounded by mesoderm, which was connected by a band to the lining the trophoblast (fig. 94).

By the third week the cephalic and caudal folds of the embryo are evident; groove is partly closed, and six or seven pairs of primitive segments are present

FIG. 240.—A human embryo, 2·6 mm. long. (His.)

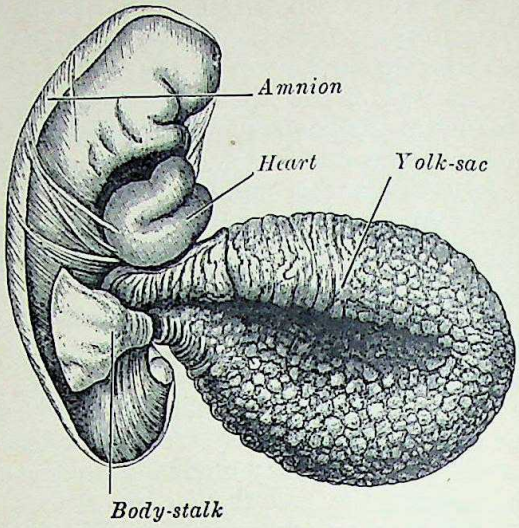

In the fourth week the embryo is about 2·5 mm. long, and thirty pairs of segments are differentiated. The brain-vesicles and the rudiment of the auditor are visible (figs. 240, 241).

In the fifth week the embryo is markedly curved on itself; the stomodœum branchial grooves are developed; the lens-rudiment is separated from the ecto forms a closed vesicle; the rudiments of the limb-buds and of the Wolffian b visible. The crown-rump length of the embryo—i.e. the length from the verte head to the lowest part of the breech—is about 5 mm.

FIG. 241.—A human embryo, 4·2 mm. long. (His.)

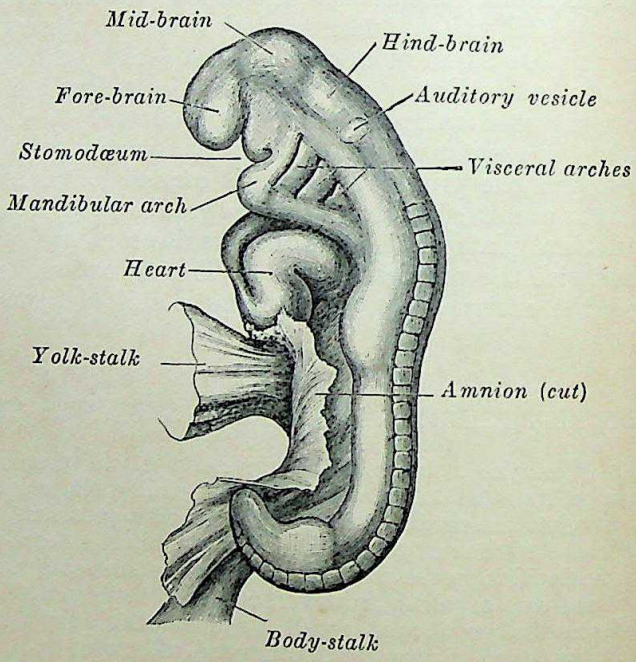

By the sixth week the third and fourth branchial arches have receded from the and form the floor of the sinus cervicalis which is covered in front by the hyoid arch medial and lateral nasal processes are separated by the olfactory pits; the globular pr are approaching one another; the maxillary processes are growing forward to fuse w lateral nasal and globular processes. The three segments of each limb-bud can be reco —the development of the fore-limb being always in advance of that of the hind Towards the end of this month the rudiments of the fingers and toes are evident, a crown-rump length is about 11 mm.

CC-0. In Public Domain. Gurukul Kangri Collection, Haridwar

Digitized by Arya Samaj Foundation Chennai and eGangotri

In the seventh and eighth weeks the flexure of the head is gradually reduced and the k is somewhat lengthened. The upper lip is completed and the nostrils are directed wards; the palate is not completely developed. The eyelids are present in the shape olds above and below the eye, and the different parts of the auricula are distinguishable. the end of the eighth week the crown-rump length of the fœtus is about 25 mm.

FIG. 242.—A human embryo, about 10 mm. long. (His.)

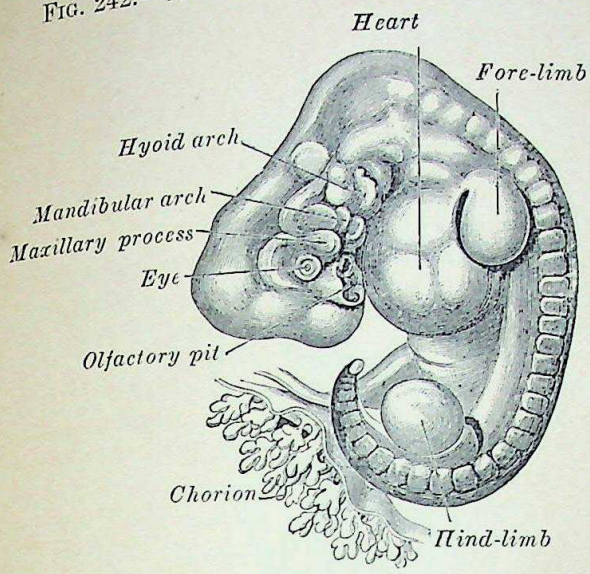

In the third month the head is extended and the neck is lengthened. The eyelids meet d fuse, remaining closed until the end of the sixth month. The limbs are well developed d nails appear on the digits. The external generative organs are so far differentiated t it is possible to distinguish the sex. By the end of this month the crown-rump length the fœtus is about 10 cm.

In the fourth month the loop of gut which projected into the umbilical cord is withdrawn thin the fœtus. The hairs begin to make their appearance. By the end of the fourth nth the crown-rump length of the fœtus is about 14 cm., and the total length—i.e. luding the legs—about 22 cm.

FIG. 243.—A human embryo, about 11 mm. long. (His.)

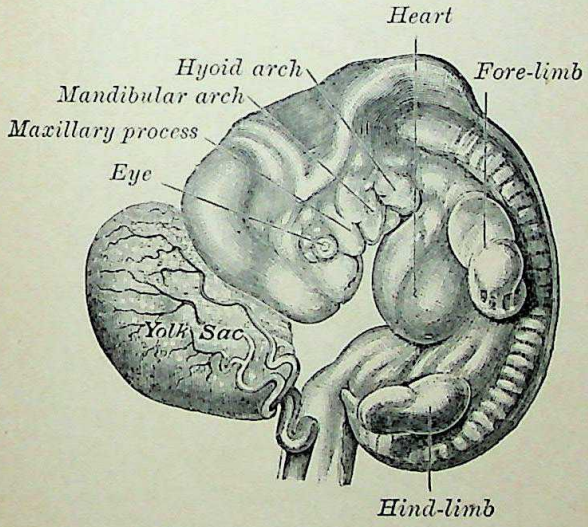

During the fifth month the first movements of the fœtus are usually observed. The uption of hair on the head commences, and the vernix caseosa begins to be deposited. the end of this month the total length of the fœtus is nearly 30 cm.

In the sixth month the body is covered by fine hairs (*lanugo*) and the deposit of vernix eosa is considerable. The papillæ of the skin are developed and the free borders of the ils project from the corium of the dermis. From vertex to heels, the total length of the tus at the end of this month is about 33 cm. The weight is about 1 kilogram.

In the seventh month the pupillary membrane atrophies and the eyelids are open. e testis descends with the vaginal sac of the peritoneum. From vertex to heels the total gth at the end of the seventh month is about 40 cm. The weight is about 1·5 kilograms.

CC-0. In Public Domain. Gurukul Kangri Collection, Haridwar

Digitized by Arya Samaj Foundation Chennai and eGangotri

During the eighth month the skin is entirely coated with vernix caseosa, and th begins to disappear. Subcutaneous fat has been developed to a considerable ext the fœtus presents a plump appearance. The total length, *i.e.* from head to heel end of the eighth month is about 45 cm., and the weight varies between 2 and 2·5 kil

FIG. 244.—A human embryo, about 15·5 mm. long. (His.)

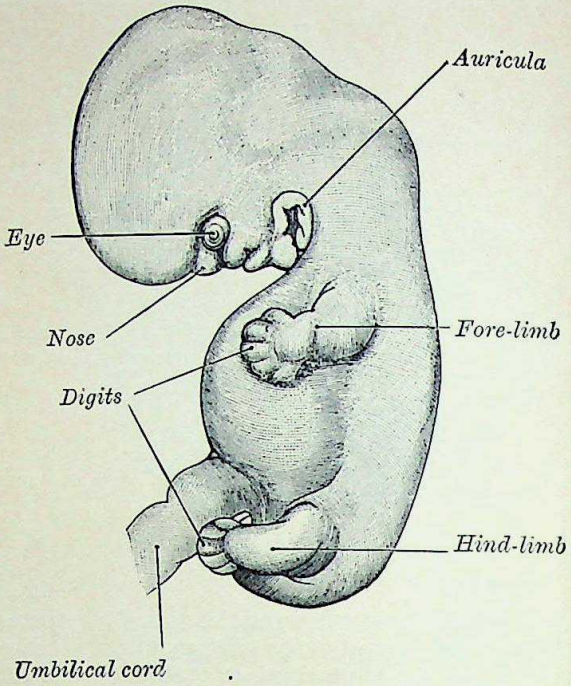

FIG. 245.—A human embryo, about 23 mm. long. (His.)

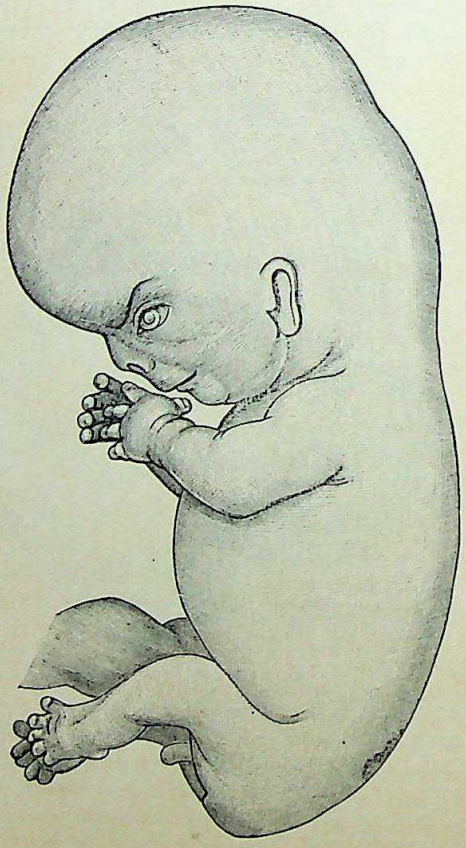

At the end of the ninth month the lanugo has largely disappeared from the t The umbilicus is almost in the middle of the body and the testes are in the scrotum. fœtus weighs from 3 to 3·5 kilograms, and measures from head to heels about 50 cm.

CC-0. In Public Domain. Gurukul Kangri Collection, Haridwar

Digitized by Arya Samaj Foundation Chennai and eGangotri

OSTEOLOGY

HE general framework of the body is built up mainly of a series of bones, supplemented in certain regions by pieces of cartilage; this bony and ilaginous framework constitutes the *skeleton*.

In comparative anatomy the term skeleton has a wider application, since ome of the lower animals hard, protecting and supporting structures are 'oped in association with the integumentary system. In such animals keleton consists of an internal or deep skeleton, the *endoskeleton*, and an rnal or superficial, the *exoskeleton*. In the human subject the oxeskeleton ery rudimentary, its only important representatives being the nails and enamel of the teeth, and therefore, in human anatomy, the term skeleton is fined to the endoskeleton; this is divisible into an *axial* part, which includes bones of the head and trunk, and an *appendicular* part, which comprises se of the extremities or limbs. The minute structure and the physical perties of bone are described on pages 17 to 25.

In the skeleton of the adult there are 206 bones, grouped as follows:

Axial Skeleton	Vertebral column	26	
	Skull	22	
	Hyoid bone	1	
	Ribs and sternum	25	
		—	74
Appendicular Skeleton	Upper extremities	64	
	Lower extremities	62	
		—	126
	Auditory ossicles		6
	Total		206

Bones are divisible into four classes: *long*, *short*, *flat*, and *irregular*.

The **long bones** are found in the limbs, where they form levers; each sists of a body or shaft and two ends. The *body* or *shaft* is tubular, h a central cavity termed the *medullary cavity*; the wall consists of dense, npact substance of considerable thickness in the middle part of the body the bone, but becoming thinner towards the ends; projecting into the dullary cavity is some spongy substance, scanty in the middle of the body the bone, but plentiful towards the ends. The *ends* are usually expanded, purposes of articulation and muscular attachment; they consist of spongy stance covered by thin compact bone, and are usually developed from or more secondary or *epiphysial* centres of ossification. The medullary rity and the spaces in the spongy substance are filled with marrow (*medulla ium*).

The **short bones**.—Where a part of the skeleton is intended for strength d compactness combined with limited movement, it is constructed of a mber of short bones, as in the *carpus* and *tarsus*. These bones consist of spongy stance surrounded by a thin crust of compact bone.

The **flat bones**.—Where the principal requirement of the skeleton is to tect delicate structures or provide broad surfaces for muscular attachment, bones are expanded into plates, as in the skull and the scapulæ, and are nposed of two thin layers of compact bone separated by a variable quantity

CC-0. In Public Domain. Gurukul Kangri Collection, Haridwar

Digitized by Arya Samaj Foundation Chennai and eGangotri

of spongy substance. In the cranial bones, the layers of compact b familiarly known as the *tables* of the skull; the outer table is thick and the inner thin, dense, and brittle. The intervening spongy substance the *diploë*, and this, in certain regions of the skull, undergoes absorpti spaces filled with air (*air-sinuses*) are left between the two tables of the

The **irregular bones**, from their peculiar form, cannot be groupe the preceding heads. They consist of spongy substance enclosed w thin layer of compact bone.

Surface of bones.—On the surfaces of the bones there are eminen depressions, either articular or non-articular. Examples of *articular em* are the heads of the humerus and femur; and of *articular depressions* the cavity of the scapula, and the acetabulum of the hip-bone. *Non-a eminences* are designated according to their form. Thus, a broad, uneven elevation is called a *tuberosity*, *trochanter*, *protuberance*, or *proc* small, rough prominence, a *tubercle*; a sharp, slender, pointed eminence, a a narrow, rough elevation of some length, a *ridge*, *crest*, or *line*. *Non-a depressions* are also of variable form, and are described as *fossæ*, *pits*, *depr grooves*, *furrows*, *fissures*, *notches*, &c.

THE VERTEBRAL COLUMN (COLUMNA VERTEBRALIS)

The **vertebral column** (fig. 277) is a flexuous and flexible column, of a series of bones called *vertebræ*, which are united to one another by vertebral fibrocartilages. The bones are thirty-three in number, a grouped under the names *cervical*, *thoracic*, *lumbar*, *sacral*, and *co* according to the regions they occupy; there are seven cervical ve twelve thoracic, five lumbar, five sacral, and four coccygeal.

The cervical, thoracic, and lumbar vertebræ are separate bones thro life, and are therefore known as *movable* vertebræ; the sacral and co vertebræ, on the other hand, are termed *fixed* vertebræ, because th united in the adult to form two bones, viz. the *sacrum* and *coccyx*, respectively by the fused sacral and coccygeal vertebræ.

The General Characteristics of a Vertebra

With the exception of the first and second cervical, the movable ve have certain common characteristics which are best studied by exa one from the middle of the thoracic region.

A typical **vertebra** (fig. 246) consists of two principal parts, an a the *body*, and a posterior, the *vertebral arch*; these enclose a forame *vertebral foramen*.

In the articulated vertebral column the bodies form a pillar for the su of the head and trunk, and the vertebral foramina constitute a canal in the medulla spinalis or spinal cord is lodged and protected. Between pair of vertebræ are two *intervertebral foramina*, one on either side, transmission of the spinal nerves and vessels.

The **body** of a vertebra is more or less cylindrical in shape; its and lower surfaces are flattened and rough, and give attachment to the vertebral fibrocartilages, and each presents a rim around its circumf In front, it is convex from side to side and concave from above down behind, it is slightly concave from side to side and flat from above down On its anterior surface are a few small apertures for the passage of n vessels; on its posterior surface is a large, irregular aperture (occasi more than one) for the exit of the basivertebral veins from the body vertebra.

The **vertebral arch** consists of a pair of *pedicles* or *roots* and a p *laminæ*; it supports seven *processes*, viz. four *articular*, two *transverse* a *spinous*.

The *pedicles* or *roots of the vertebral arches*, are two short, thick proc which project backwards from the body, at the junctions of its latera

CC-0. In Public Domain. Gurukul Kangri Collection, Haridwar

Digitized by Arya Samaj Foundation Chennai and eGangotri

erior surfaces. The concavities above and below the pedicles are named *vertebral notches*; and when the vertebræ are articulated with one another, notches of contiguous pairs form the *intervertebral foramina*, already rred to.

The *laminæ* are two broad plates directed backwards and medialwards m the pedicles. They fuse in the middle line posteriorly, and so complete

FIG. 246.—A typical thoracic vertebra. Superior aspect.

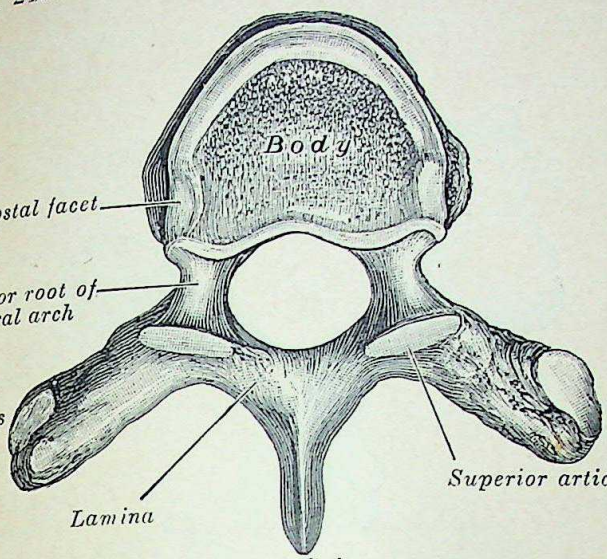

posterior boundary of the vertebral foramen. Their upper borders and lower parts of their anterior surfaces are rough for the attachment of the menta flava.

The *spinous process* is directed backwards and downwards from the junction he laminæ, and serves for the attachment of muscles and ligaments.

The *articular processes*, two superior and two inferior, spring from the ctions of the pedicles and laminæ. The superior processes project upwards, l their articular surfaces are directed more or less backwards; the inferior ject downwards, and their articular surfaces look more or less forwards.

The *transverse processes* project lateralwards from the junctions of the icles and laminæ; y serve for the attach- t of muscles and ments.

tructure of a vertebra 247).—The body of a ebra is composed of gy substance covered a thin coating of com- bone; the latter is orated by numerous ces for the passage of sels; the interior of the y is traversed by one or large canals, for the ption of veins, which verge towards the large rture on the posterior surface of the body. The vertebral arch and the processes ecting from it have thick coverings of compact substance.

FIG. 247.—A sagittal section through a lumbar vertebra.

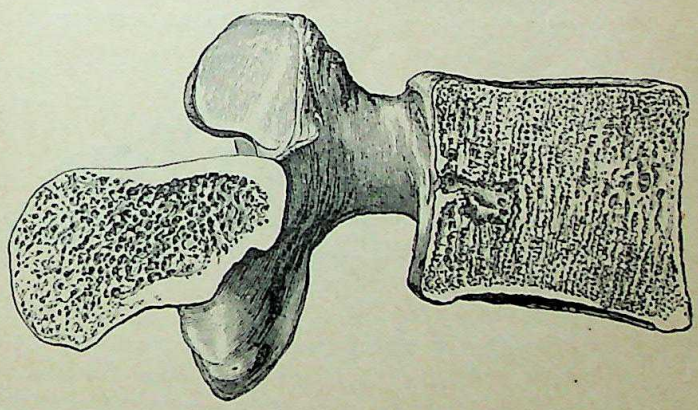

THE CERVICAL VERTEBRÆ (VERTEBRÆ CERVICALES)

The cervical vertebræ (figs. 248, 249), seven in number, are the smallest he movable vertebræ, and can be readily distinguished from the thoracic or bar vertebræ by the presence of a foramen in each transverse process.

CC-0. In Public Domain. Gurukul Kangri Collection, Haridwar

Digitized by Arya Samaj Foundation Chennai and eGangotri

The first, second, and seventh cervical vertebræ present exceptional f but the following characteristics are common to the remaining four.

The *body* is small, and broader from side to side than from before bac The anterior and posterior surfaces are flattened and of equal depth, anterior surface is placed on a lower level than the posterior, and its border is prolonged downwards, so as to overlap the upper and front pa succeeding vertebra. The superior surface is concave transversely, and

FIG. 248.—A typical cervical vertebra. Superior aspect.

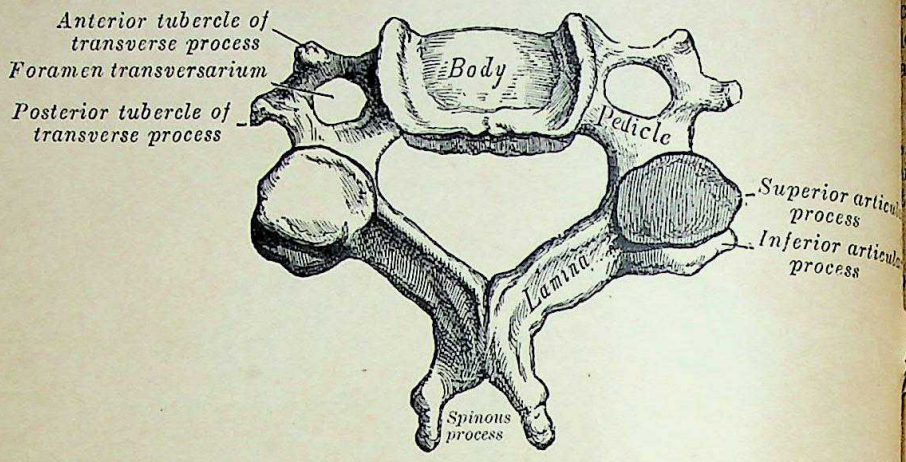

upwardly projecting lip on either side; the inferior surface is saddle-s being concave from before backwards, convex from side to side, and p laterally shallow concavities which receive the projecting lips of the sub vertebra. The *pedicles* are directed lateralwards and backwards; th attached to the body midway between its upper and lower borders, and th the superior and inferior vertebral notches are of equal depth; the su notch is, however, the narrower. The *laminæ* are narrow, and are thinner than below; the *vertebral foramen* is large, and of triangular form *spinous process* is short and bifid, and its terminal tubercles are often of u size. The *superior and inferior articular processes* of either side are fused t an articular pillar, which projects lateralwards from the junction of the p and lamina. The articular facets are flat and of an oval form; the su

FIG. 249.—A typical cervical vertebra. Left lateral aspect.

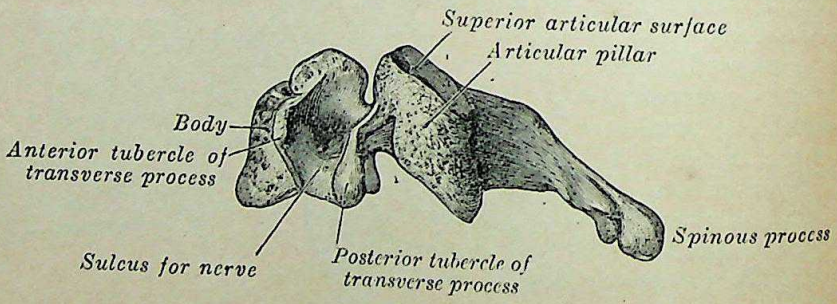

facets look backwards, upwards, and slightly medialwards; the inferior for downwards, and slightly lateralwards. In the third and fourth ver the lateral surfaces of the articular pillars are grooved for the acco dation of the medial branches of the posterior divisions of the corres ing cervical nerves.* The *transverse processes* are each pierced by *foramen transversarium*, which, in the upper six vertebræ, gives pass the vertebral artery and vein and a plexus of sympathetic nerves.

* F. Wood Jones, *Journal of Anatomy and Physiology*, vol. xlvi., 1911.

CC-0. In Public Domain. Gurukul Kangri Collection, Haridwar

Digitized by Arya Samaj Foundation Chennai and eGangotri

ocess consists of an anterior and a posterior part. The anterior portion is homologue of the rib in the thoracic region, and is therefore named the *ral process*; it arises from the side of the body, is directed lateralwards in nt of the foramen, and ends in a tubercle, the *tuberculum anterius*. The terior part, the true transverse process, springs from the vertebral arch hind the foramen transversarium, and is directed forwards and lateralwards; ends in a flattened vertical tubercle, the *tuberculum posterius*. Lateral to e foramen transversarium the anterior and posterior tubercles are united by curved bar of bone, the groove or sulcus on the upper surface of which commodates the anterior division of the corresponding spinal nerve. This cus is deeper, wider, and more downwardly directed in the fifth and sixth n in the third and fourth vertebræ.*

Chassaignac pointed out that the common carotid artery can be compressed against anterior tubercle of the transverse process of the sixth cervical vertebra; this tubercle refore is named the *tuberculum caroticum* or *Chassaignac's tubercle*. It also contutes an important guide to the vertebral artery.

The **first cervical vertebra** (fig. 250) is named the **atlas** because it ports the globe of the head. Its chief peculiarity is that it has no body, and

FIG. 250.—The first cervical vertebra, or atlas. Superior aspect.

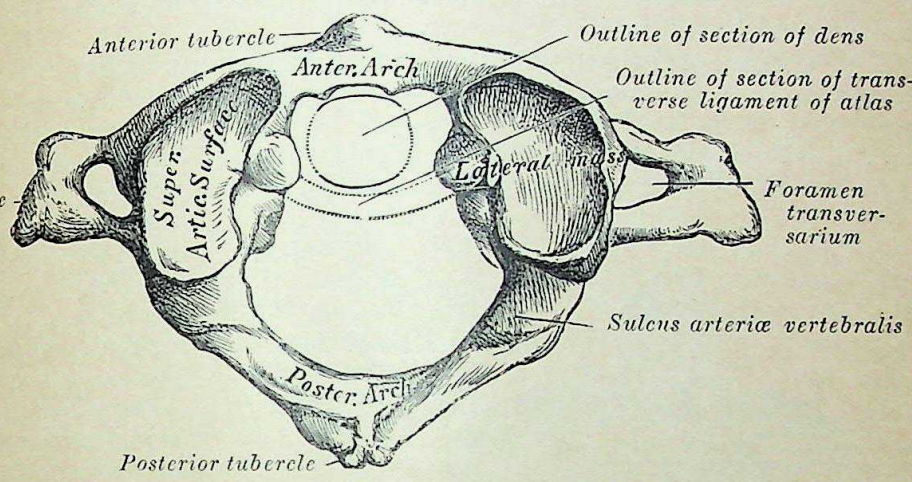

s is due to the fact that the body of the atlas has fused with that of the second vical vertebra. It has no spinous process but is ring-like, and consists of an erior and a posterior arch and two lateral masses. The *anterior arch* forms ut one-fifth of the ring: its front surface is convex, and at its centre is the *erior tubercle* for the attachment of parts of the Longus colli muscles; steriorly it is concave, and marked by a smooth, oval or circular facet (fovea ntis), for articulation with the anterior surface of the dens or odontoid process the epistropheus or axis. The upper and lower borders respectively give achment to the anterior atlanto-occipital membrane and the anterior atlanto-istropheal ligament; the former connects the atlas with the occipital bone, the ter the atlas with the epistropheus. The *posterior arch* forms about two-fifths the ring: at the centre of its posterior surface is the *posterior tubercle*, which the rudiment of a spinous process and gives origin to the Recti capitis steriores minores. The small size of this process prevents it from interfering th the movements between the atlas and the skull. The upper edge of the ntral part of the posterior arch is rounded and affords attachment to the sterior atlanto-occipital membrane, while immediately behind the superior icular process of each lateral mass is a groove, the *sulcus arteriæ vertebralis*, metimes converted into a foramen by a bony spiculum which arches backwards m the posterior end of the superior articular process. This sulcus lodges

* The *costal element* of a cervical vertebra not only includes the portion which springs from side of the body, but the anterior and posterior tubercles and the bar of bone which connects se tubercles (fig. 108).

CC-0. In Public Domain. Gurukul Kangri Collection, Haridwar

Digitized by Arya Samaj Foundation Chennai and eGangotri

the vertebral artery which, after ascending through the foramen in the tra process of the atlas, winds round the lateral mass in a direction bac and medialwards; it also lodges the suboccipital or first spinal nerv the under surface of the posterior arch, behind the inferior articular are the two shallow vertebral notches. The lower border of the po arch gives attachment to the posterior atlanto-epistropheal ligament.

The *lateral masses* support the weight of the head; each contributes one-fifth of the ring, and carries two articular facets, a superior and an i The superior articular facets are large, oval, and concave; they ap each other in front, but diverge behind; they are directed upwards, u wards, and a little backwards, and form cups for the reception of the co of the occipital bone, and are admirably adapted to the nodding move of the head; occasionally they are constricted near their centres. Just the medial margin of each superior facet is a small tubercle, for the attac of the transverse ligament of the atlas; this ligament divides the ring atlas into two unequal parts—the anterior, smaller part receiving the or odontoid process of the epistropheus, the posterior transmitting the m spinalis and its membranes. The inferior articular facets, nearly ci in form, are flattened or slightly concave; they are directed downward medialwards, and articulate with the superior facets of the epistrop The *transverse processes* are long and project lateralwards and downw from the lateral masses; the anterior and posterior tubercles of each pr are fused into one mass. The foramen transversarium is large and is di upwards and backwards.

The **second cervical vertebra** or **epistropheus** (axis) (figs. 251, forms the pivot upon which the atlas, carrying the head, rotates. The characteristic of this is the strong tooth process, the *dens*, projects perpendic from the upper surf the body. The *bo* deeper in front behind. On its an surface is a median r separating two d sions for the attach of portions of the L colli muscles. Its in surface is concave before backwards convex from side to The *dens* (odontoid cess), conical in shap about 1·5 cm. long, exhibits a slight cons tion, or neck, wher joins the body. O anterior surface is oval or nearly cir facet for articulation

FIG. 251.—The second cervical vertebra, or epistropheus. Posterosuperior aspect.

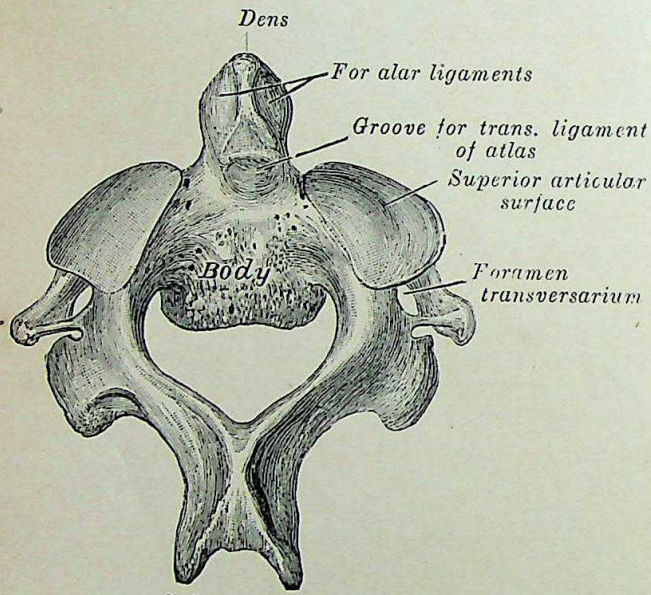

that on the posterior surface of the anterior arch of the atlas. On the ba the neck, and frequently extending on to its lateral surfaces, is a shallow gr for the transverse ligament of the atlas, which retains the dens in position. apex is pointed, and gives attachment to the ligamentum apicis dentis; b the apex, the process is somewhat enlarged and presents on either side a r impression for the attachment of the alar ligaments which connect the to the occipital bone. The internal structure of the dens is more compact that of the body. The *pedicles* are broad and strong, especially in front, w they fuse with the sides of the body and the base of the dens. They are co above by the superior articular surfaces. The *laminæ* are thick and str and the *vertebral foramen* is large, but smaller than that of the atlas. *transverse processes* are very small; each ends in a single tubercle a

CC-0. In Public Domain. Gurukul Kangri Collection, Haridwar

Digitized by Arya Samaj Foundation Chennai and eGangotri

forated by the foramen transversarium which is directed upwards and lateral-
ds. The *superior articular surfaces* are circular, slightly convex, directed
wards and a little lateralwards, and are supported on the body, pedicles, and
sverse processes; the *inferior* have the same direction as those of the typical
ical vertebræ. The *superior vertebral notches* are very shallow, and lie

FIG. 252.—The second cervical vertebra, or epistropheus. Right lateral aspect.

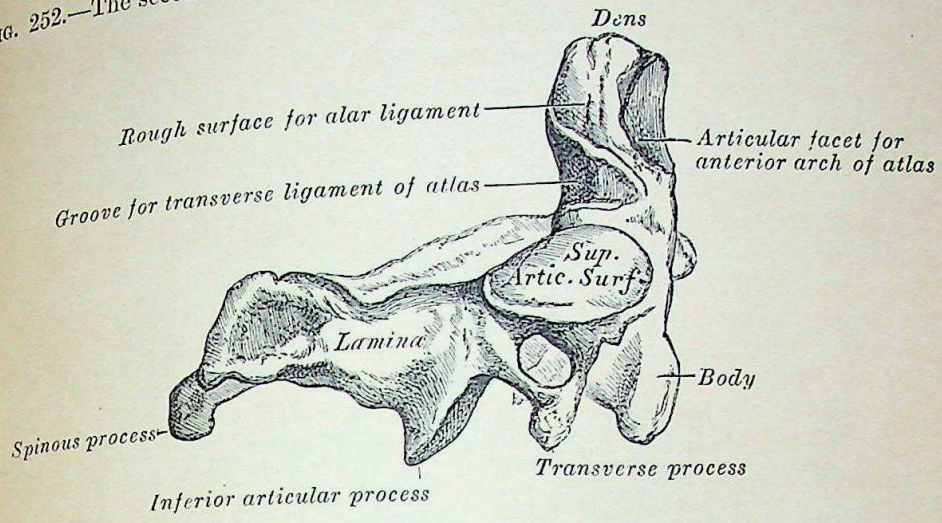

ind the articular processes; the *inferior* are in front of the articular processes,
in the typical cervical vertebræ. The *spinous process* is large and very
ong; it is deeply channelled on its under surface, and has a bifid, tuberculated
remity.

The **seventh cervical vertebra** (fig. 253).—This vertebra is named the
ebra prominens because of its long and prominent spinous process. This
cess is thick, and nearly horizontal in direction; it is not bifurcated, but
s in a tubercle to which the lower end of the ligamentum nuchæ is attached.

e *transverse processes* are
considerable size, and
ir posterior roots are
ge and prominent; the
erior roots are usually
ll and faintly marked,
occasionally they exist
separate bones, which
nd lateralwards and
wards, and are known
cervical ribs. The upper
face of each transverse
cess has usually a shal-
y sulcus for the seventh
vical nerve, and the
remity of the process
dom presents more than
race of division. The
perior articular facets
k almost directly back-
rds. The foramen trans-
sarium is generally
aller than that in the
er cervical vertebræ;
ely it is double, some-
es it is absent. On the
side it occasionally gives passage to the vertebral artery; sometimes the
tebral vein traverses it on both sides; but as a rule the artery and vein pass
front of the transverse process.

FIG. 253.—The seventh cervical vertebra. Superior aspect.

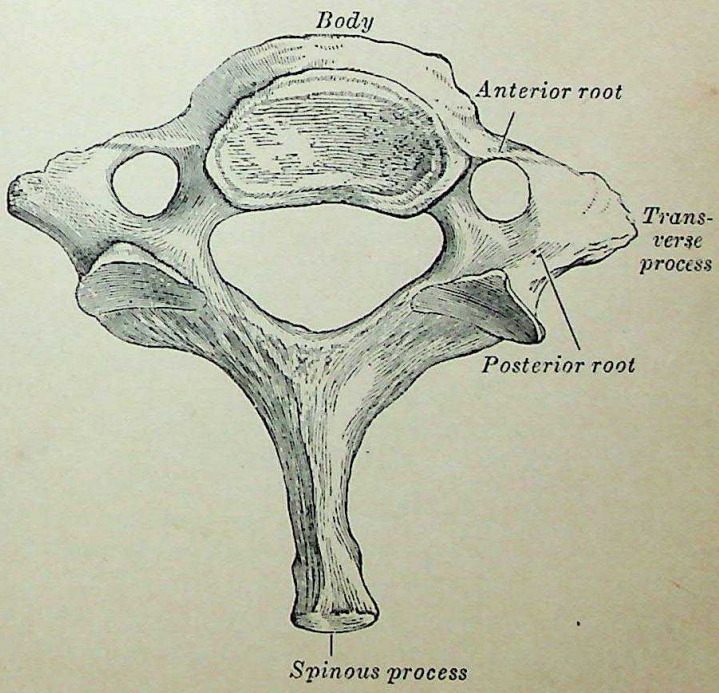

CC-0. In Public Domain. Gurukul Kangri Collection, Haridwar

Digitized by Arya Samaj Foundation Chennai and eGangotri

The Thoracic Vertebræ (Vertebræ Thoracales)

The **thoracic vertebræ** (fig. 254), twelve in number, increase succ in size from above downwards. All are distinguished by the presence o on the sides of the bodies, and all but the two lowest by facets on the tr processes; the former articulate with the heads of the ribs, the latter tubercles of the ribs.

The *first*, *ninth*, *tenth*, *eleventh*, and *twelfth* thoracic vertebræ present peculiarities, and must be specially considered (fig. 255).

In a typical vertebra from the middle of the thoracic region the heart-shaped, and its anteroposterior and transverse diameters are equal. It is slightly thicker behind than in front, flat above and below, from side to side in front, deeply concave behind, and slightly con laterally and in front. On either side are two costal facets, a superi

Fig. 254.—A typical thoracic vertebra. Right lateral aspect.

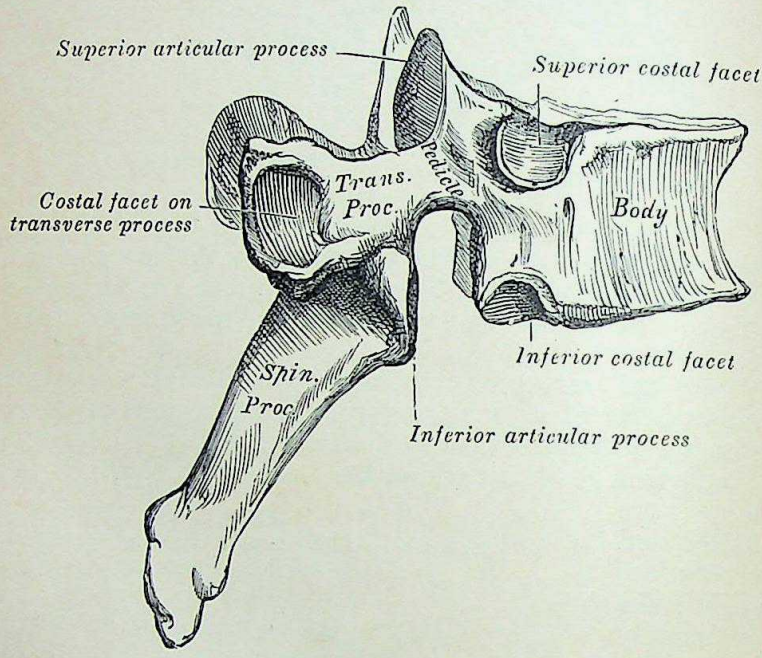

larger, near the root of the pedicle, and an inferior in front of the in vertebral notch; in the articulated vertebral column these facets form the intervertebral fibrocartilages, oval surfaces for the reception of the of the ribs. The *pedicles* are directed backwards and slightly upwards the inferior vertebral notches are of large size, and deeper than those cervical or lumbar vertebræ. The *laminæ* are broad and thick, and ov those of subjacent vertebræ like tiles on a roof. The *vertebral foramen* is sm than that of a cervical or lumbar vertebra, and is of a circular form. *spinous process* is long, triangular on coronal section, directed obliquely wards, and ends in a tuberculated extremity. The spinous processes ov from the fifth to the eighth, but are less oblique in direction above and these levels.* The *superior articular processes* are thin plates of bone proj upwards from the junctions of the pedicles and laminæ; their articular are almost flat, and are directed backwards and a little lateralwards and up The *inferior articular processes* are fused to a considerable extent wit laminæ, and project but slightly beyond the lower borders of the la their facets are directed forwards and a little medialwards and down

* In quadrupeds the majority of the spinous processes of the thoracic vertebræ upwards and backwards, while those of the lumbar region are directed upwards and for The change in inclination is effected in one of the lower thoracic vertebræ, the spine of points almost directly upwards. This vertebra is known as the *anticlinal*, and in m representative is the eleventh thoracic.

CC-0. In Public Domain. Gurukul Kangri Collection, Haridwar

Digitized by Arya Samaj Foundation Chennai and eGangotri

e *transverse processes* arise from the arch behind the superior articular pro-
sses and pedicles; they are thick, strong, and of considerable length, directed
liquely backwards and lateralwards, and each ends in a clubbed extremity,
the front of which is a small costal facet, for articulation with the tubercle
a rib. In the upper six thoracic vertebræ the costal facets are concave,

FIG. 255.—The first, ninth, tenth, eleventh and twelfth thoracic vertebræ. Right lateral aspect.

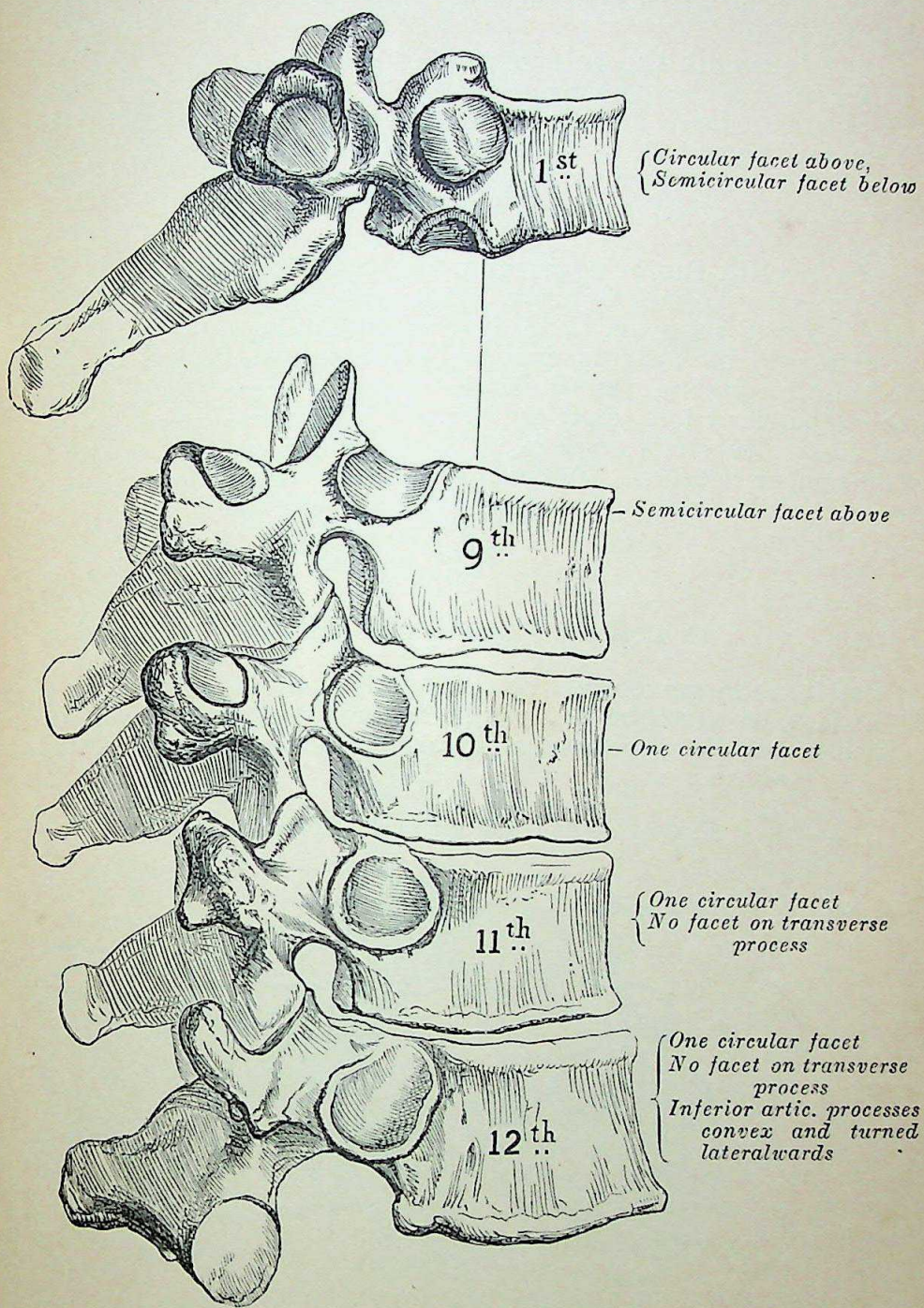

d are placed on the anterior surfaces of the transverse processes; in the
rtebræ from the seventh to the tenth inclusive the costal facets are flat and
aced on the upper surfaces of the transverse processes.

The **first thoracic vertebra** (fig. 255) has on either side of the upper part
the body a complete facet for the head of the first rib, and at the lower part
the body a small facet for the upper half of the head of the second rib. The
dy resembles that of the seventh cervical vertebra, being broad transversely,

CC-0. In Public Domain. Gurukul Kangri Collection, Haridwar

Digitized by Arya Samaj Foundation Chennai and eGangotri

while its upper surface is concave in the same direction, and lipped on side. The *superior articular surfaces* are directed upwards and back the *spinous process* is thick, long, and almost horizontal. The *tra processes* are long, and the superior vertebral notches are deeper than of the other thoracic vertebræ.

The **ninth thoracic vertebra** (fig. 255) may have no inferior costal but in some cases these are present.

The **tenth thoracic vertebra** (fig. 255) has usually a complete costal placed partly on the lateral surface of the pedicle, for the head of the ten but the facet for the head of this rib is sometimes completed by the body ninth vertebra.

In the **eleventh thoracic vertebra** (fig. 255) the *body* approaches in and size those of the lumbar vertebræ. The facets for the heads of the el pair of ribs are large, and placed chiefly on the pedicles, which are thick stronger in this and the next vertebra than in other parts of the thoracic r The *spinous process* is short, and nearly horizontal in direction. The *tra processes* are very short, tuberculated at their extremities, and have no facets.

The **twelfth thoracic vertebra** (fig. 255) has the same general ch teristics as the eleventh, but may be distinguished from it by its inferior art surfaces which are convex and directed lateralwards like those of the lum vertebræ; by the body, laminæ, and spinous process, which resemble tho the lumbar vertebræ; and by each transverse process being a short irre knob subdivided into superior, inferior, and lateral tubercles; the su and inferior tubercles correspond to the mamillary and accessory pro of the lumbar vertebræ. Traces of similar tubercles are found on the tran processes of the tenth and eleventh thoracic vertebræ.

The Lumbar Vertebræ (Vertebræ Lumbales)

The **lumbar vertebræ** (figs. 256, 257), five in number, are the l of the movable vertebræ, and can be distinguished by the absence of for in their transverse processes, and of costal facets on the sides of the bodi

Fig. 256.—A lumbar vertebra. Right lateral aspect.

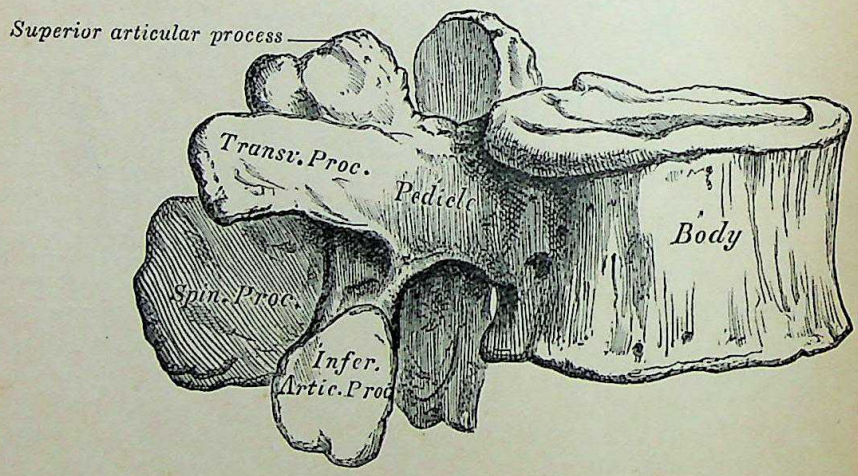

The *body* is large, wider from side to side than from before backwards a little thicker in front than behind. It is flattened above and below, con behind, and constricted in front and at the sides. The *pedicles* are strong directed backwards from the upper part of the body; consequently, the inf vertebral notches are of considerable depth. The *laminæ* are broad, sh and strong; the *vertebral foramen* is triangular, larger than in the thoracic smaller than in the cervical region. The *spinous process* projects al

CC-0. In Public Domain. Gurukul Kangri Collection, Haridwar

Digitized by Arya Samaj Foundation Chennai and eGangotri

rizontally backwards; it is somewhat quadrilateral in outline, with bulging sterior and inferior borders. The *superior and inferior articular processes*

FIG. 257.—A lumbar vertebra. Posterosuperior aspect.

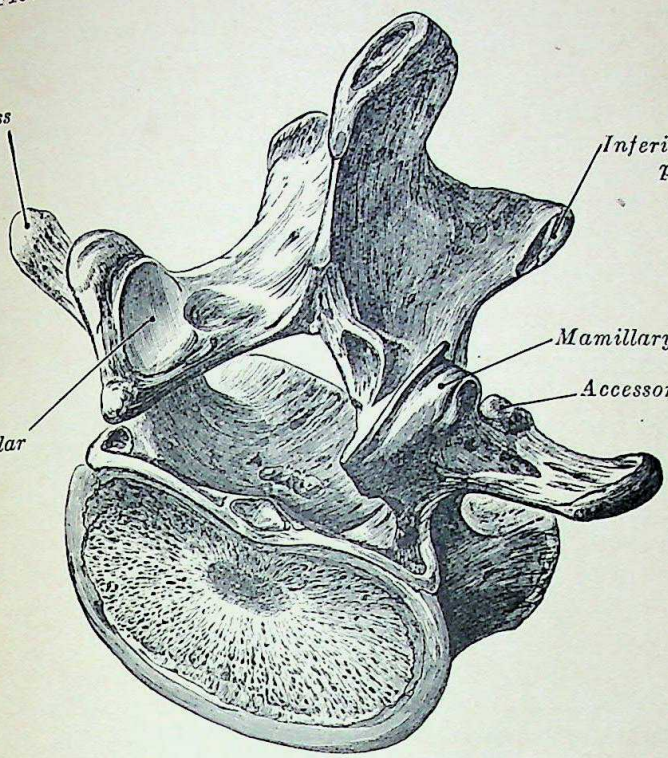

FIG. 258.—The fifth lumbar vertebra. Superior aspect.

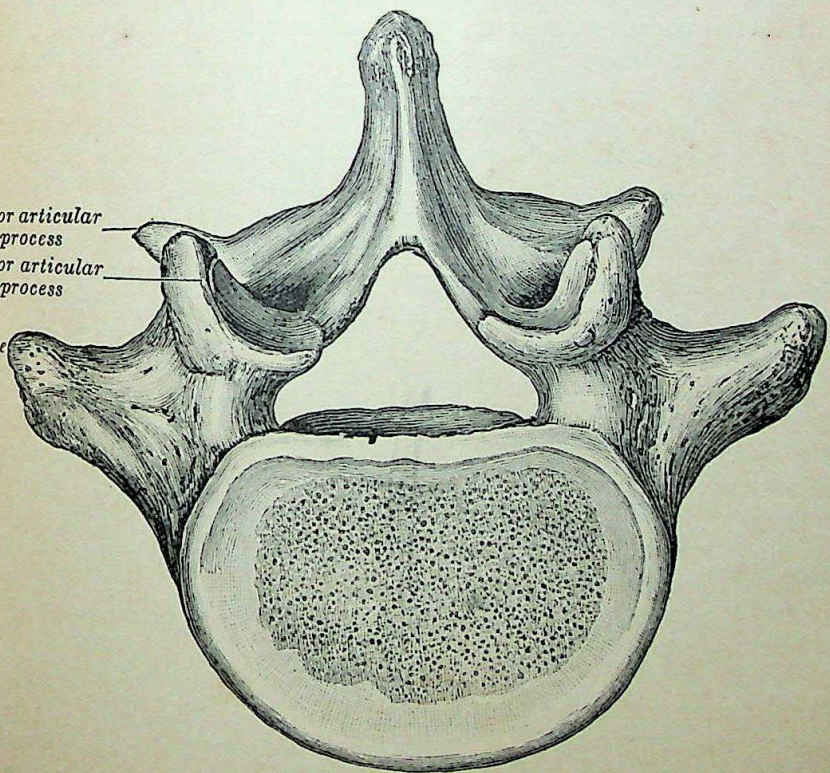

oject respectively upwards and downwards from the junctions of the pedicles d laminæ. The facets on the superior processes are concave, and look

CC-0. In Public Domain. Gurukul Kangri Collection, Haridwar

Digitized by Arya Samaj Foundation Chennai and eGangotri

backwards and medialwards; those on the lumbar convex, and are d
forwards and lateralwards. The inferior articular processes are closer t
than the superior, and, in the articulated vertebral column, are embra
the superior processes of the subjacent vertebra. The *transverse proce*
situated in front of the articular processes instead of behind them as
thoracic vertebræ, and are homologous with the ribs. Those of the uppe
vertebræ arise from the junctions of the pedicles and laminæ, and ar
slender, and horizontally directed; those of the lower two vertebræ
a little upwards, and spring from the pedicles and posterior parts of the
The transverse process of the first lumbar vertebra is sometimes dev
as a separate piece which may remain ununited with the rest of the
thus forming a lumbar rib. Of the tubercles noticed in connexion wi
transverse processes of the lower thoracic vertebræ, the *superior* is com
in the lumbar region with the posterior part of the superior articular p
and is named the *mamillary process;* the *inferior* is situated at the po
part of the base of the transverse process, and is called the *accessory p*
(fig. 257).*

The **fifth lumbar vertebra** (fig. 258) is characterised by its body
considerably deeper in front than behind, a condition which accords wi
prominence of the sacrovertebral articulation; by the small size of its sp
process; by the wide interval between the inferior articular processes;
by the thickness of its transverse processes, which spring from the bod
well as from the pedicles.

The Sacrum (Os Sacrum)

The **sacrum** is a large, wedge-shaped bone formed by the fusion of th
sacral vertebræ. It is situated at the upper and posterior part of the
cavity, where it is inserted like a wedge between the two hip-bones
base projects upwards and forwards to articulate with the fifth lumbar ve
and form with it the prominent *sacrovertebral angle*; its apex articulates
the coccyx. The bone is placed very obliquely and is curved longitud
with a dorsal convexity, so that its central part is projected upward
backwards to give increased capacity to the cavity of the lesser pelvis.
sides of the wedge are somewhat sinuous in outline since the third sacral ve
is rather wider than the second. The sacrum has a pelvic, a dorsal, and
lateral surfaces, a base, an apex, and a central canal.

The *pelvic surface* of the sacrum (fig. 259) is concave from above down
and slightly so from side to side. It is crossed transversely by four ridges,
correspond in position with the original planes of separation between th
segments of the bone: the portions separated by the ridges are the bodies
sacral vertebræ. The body of the first vertebra is of large size, and in
resembles that of a lumbar vertebra; the succeeding ones diminish from
downwards, are flattened from before backwards, and curved to accomm
themselves to the form of the sacrum, being concave in front, and co
behind. On either side, at the ends of the ridges are the four *anterior*
foramina, somewhat rounded in form, diminishing successively in size
above downwards, and directed lateralwards and forwards: they open
the sacral canal and give exit to the anterior divisions of the sacral ne
and entrance to the lateral sacral arteries. On either side of these fora
are the *lateral parts* of the sacrum, each consisting of five separate segm
at an early period of life; in the adult, these are blended with the bodies
with each other. Each lateral part is traversed by four broad, shallow gro
for the anterior divisions of the sacral nerves; the grooves are separ
from one another by prominent ridges which give origin to the Piriformis.

In a medial sagittal section of the sacrum (fig. 263) the central par
the bodies of the sacral vertebræ are seen to be separated by intervals w

* The mamillary and accessory processes 'are merely muscular processes which, repre
and conjoined in the thoracic region, become separated in the lumbar region by the p
of the internal branch of the posterior division of the lower thoracic and lumbar nerves be
them.' (Wood Jones, *Journal of Anatomy and Physiology*, vol. lvii., p. 118.)

CC-0. In Public Domain. Gurukul Kangri Collection, Haridwar

Digitized by Arya Samaj Foundation Chennai and eGangotri

the recent state, are filled by the intervertebral fibrocartilages. In some cimens the union is more complete between the lower than between the er segments.

The *dorsal surface* of the sacrum (fig. 260) is convex, and is narrower than pelvic surface. In the middle line is the *median sacral crest*, surmounted the rudimentary spinous processes of the upper three or four sacral vertebræ. either side of this crest is the *sacral groove*, which gives origin to the tifidus, the floor of the groove being formed by the united laminæ of the tebræ. The laminæ of the fifth sacral vertebra, and sometimes those of fourth, fail to meet behind, and thus a deficiency (*hiatus sacralis*) occurs in posterior wall of the sacral canal. Lateral to either sacral groove is a linear

FIG. 259.—The sacrum. Pelvic aspect.

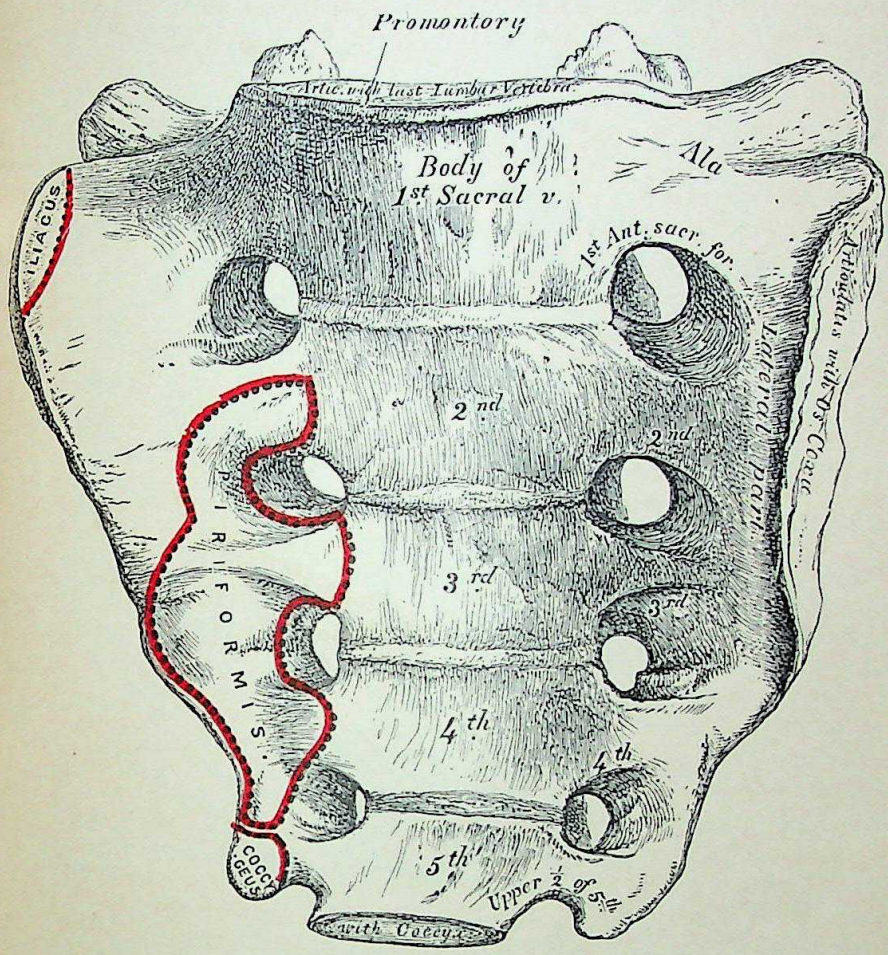

es of tubercles produced by the fusion of the articular processes, which ether form the indistinct *sacral articular crests*. The articular processes of first sacral vertebra are large, and their facets are oval or circular in shape, concave from side to side; they look backwards and medialwards, and iculate with the facets on the inferior processes of the fifth lumbar vertebra. e tubercles which represent the inferior articular processes of the fifth sacral tebra are prolonged downwards as rounded processes, which are named *sacral cornua*, and are connected to the cornua of the coccyx. Lateral the sacral articular crests are the four *posterior sacral foramina*; they transmit posterior divisions of the sacral nerves, and are smaller in size and less ular in form than the anterior foramina. Lateral to the posterior sacral mina are the *lateral sacral crests*, formed by the fused transverse processes the sacral vertebræ. The transverse tubercles of the first sacral vertebra large and very distinct; they and the transverse tubercles of the second tebra, give attachment to the short posterior sacro-iliac ligaments; those of third vertebra give attachment to the long posterior sacro-iliac ligaments; those of the fourth and fifth to the sacrotuberous ligaments.

CC-0. In Public Domain. Gurukul Kangri Collection, Haridwar

Digitized by Arya Samaj Foundation Chennai and eGangotri

The *lateral surfaces* of the sacrum (fig. 260) are broad above, and below. On the broad upper part of each is an ear-shaped surface, the *surface*, for articulation with the ilium, and behind this is a rough *sacral tuberosity*, on which are three deep impressions, for the att of the interosseous sacro-iliac ligament; the thin, lower part gives att to the sacrotuberous and sacrospinous ligaments, to some fibres of the maximus behind, and of the Coccygeus in front. It ends below in a p called the *inferior lateral angle*; the notch on the medial side of th is converted into a foramen by the transverse process of the first piec coccyx, and transmits the anterior division of the fifth sacral nerve.

Fig. 260.—The sacrum. Dorsal aspect.

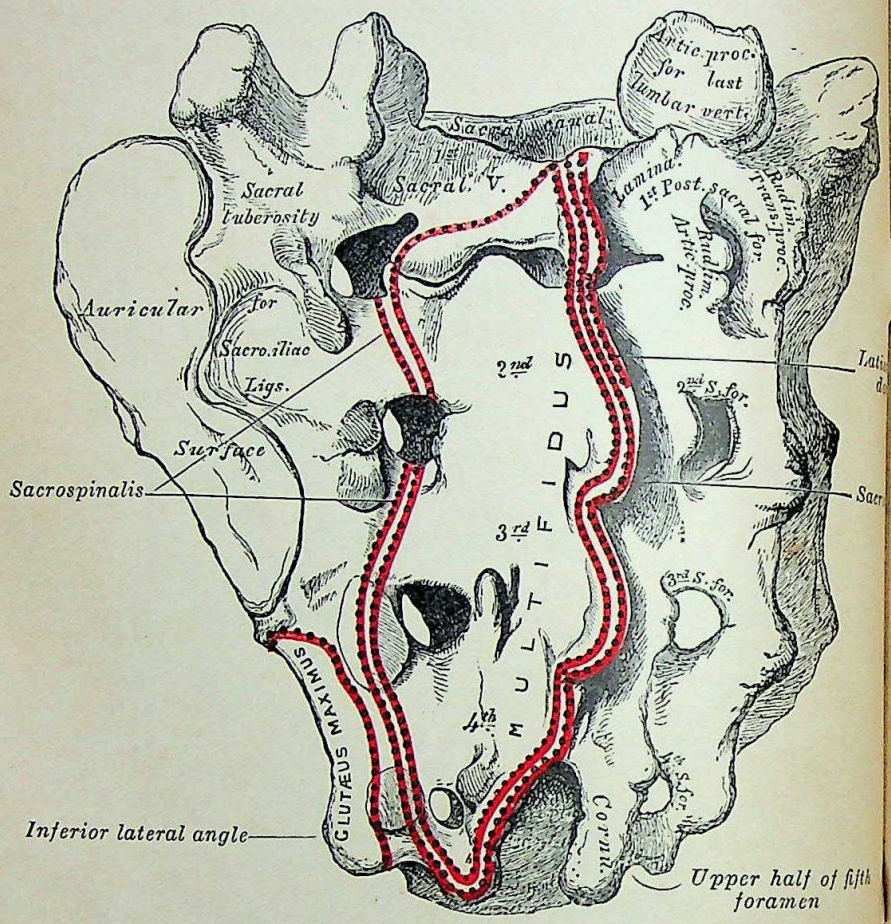

The *base* of the sacrum (fig. 262) is transversely expanded, and is dir upwards and forwards. In its central part is the large oval upper surf the body of the first sacral vertebra, which is connected with the under s of the body of the last lumbar vertebra by an intervertebral fibrocart the anterior projecting edge of the body is named the *promontory*. Behi body is the superior orifice of the sacral canal, triangular in shape and com posteriorly by the arch of the first sacral vertebra. On either side of the is a large triangular plate called the *ala sacralis*. The upper surface of t is slightly concave from side to side, and convex from before backward in the articulated pelvis is continuous with the iliac fossa. The po one-third of the ala represents the transverse process, and the anterior two- the costal process of the first sacral vertebra. The superior articular pro are attached to the body of the first sacral vertebra and to the alæ by thick pedicles; they are oval, concave, directed backwards and medial like the superior articular processes of the lumbar vertebræ. On the surface of either pedicle is a vertebral notch, which forms the lower p the foramen between the last lumbar and first sacral vertebræ.

The *apex* of the sacrum, directed downwards, is truncated and an oval facet for articulation with the coccyx.

CC-0. In Public Domain. Gurukul Kangri Collection, Haridwar

Digitized by Arya Samaj Foundation Chennai and eGangotri

FIG. 261.—The sacrum and coccyx. Right lateral aspect.

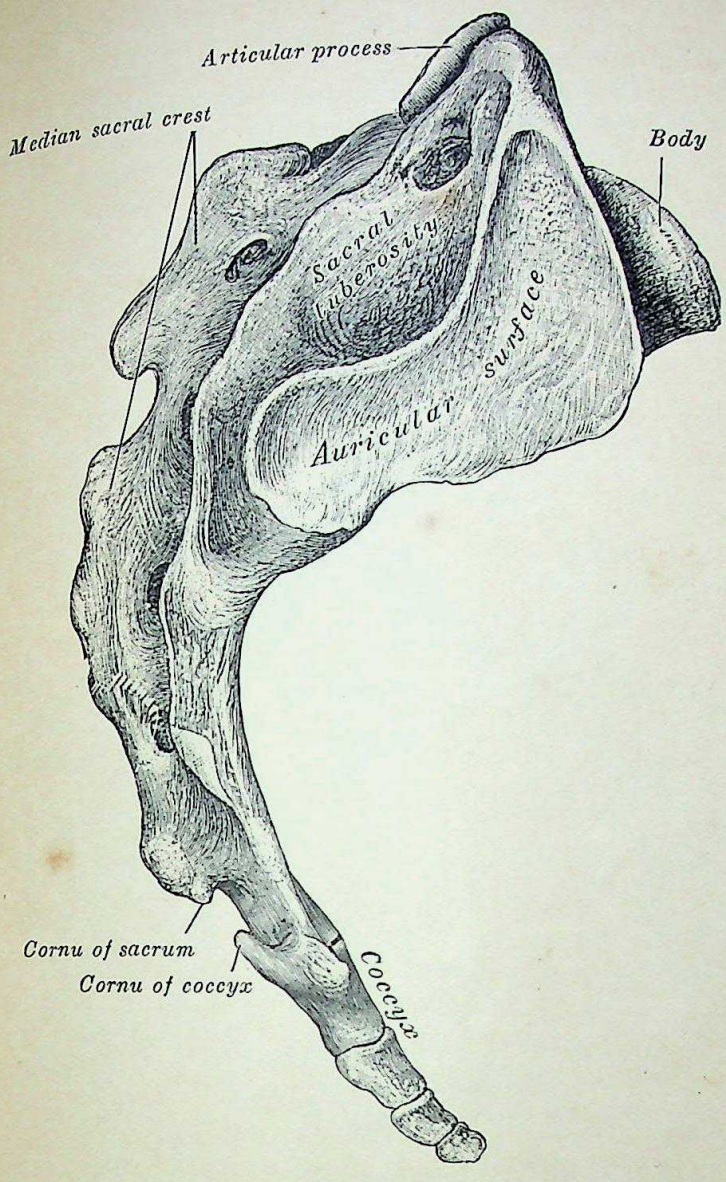

FIG. 262.—The sacrum. Superior aspect.

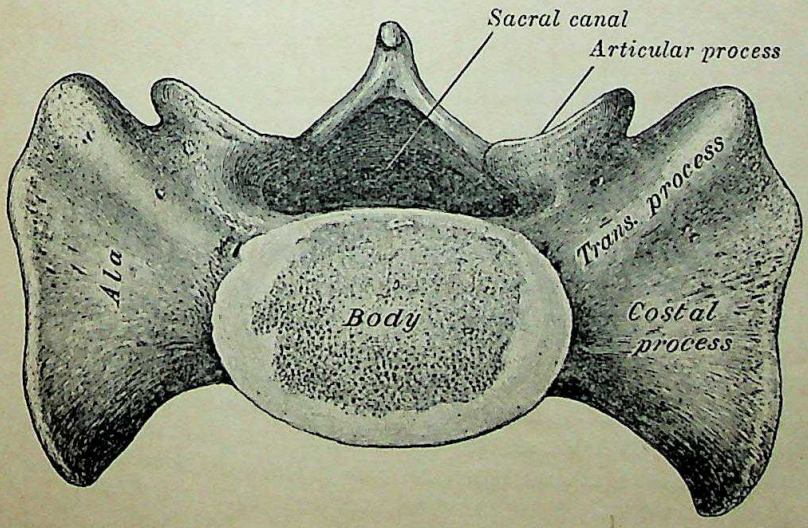

CC-0. In Public Domain. Gurukul Kangri Collection, Haridwar

Digitized by Arya Samaj Foundation Chennai and eGangotri

The *sacral canal* (fig. 263) lodges the sacral nerves and runs thro greater part of the length of the bone; above, it is a closed canal, tri in cross section; below, its posterior wall is incomplete, owing to th development of the laminæ and spinous processes. Its walls are per by the anterior and posterior sacral foramina through which the emerge.

Differences in the sacrum of the male and female.—In the the sacrum is shorter and wider than in the male; the upper part of th is flattened, and the lower part curved abruptly forwards. In the m

Fig. 263.—A median sagittal section through the sacrum.

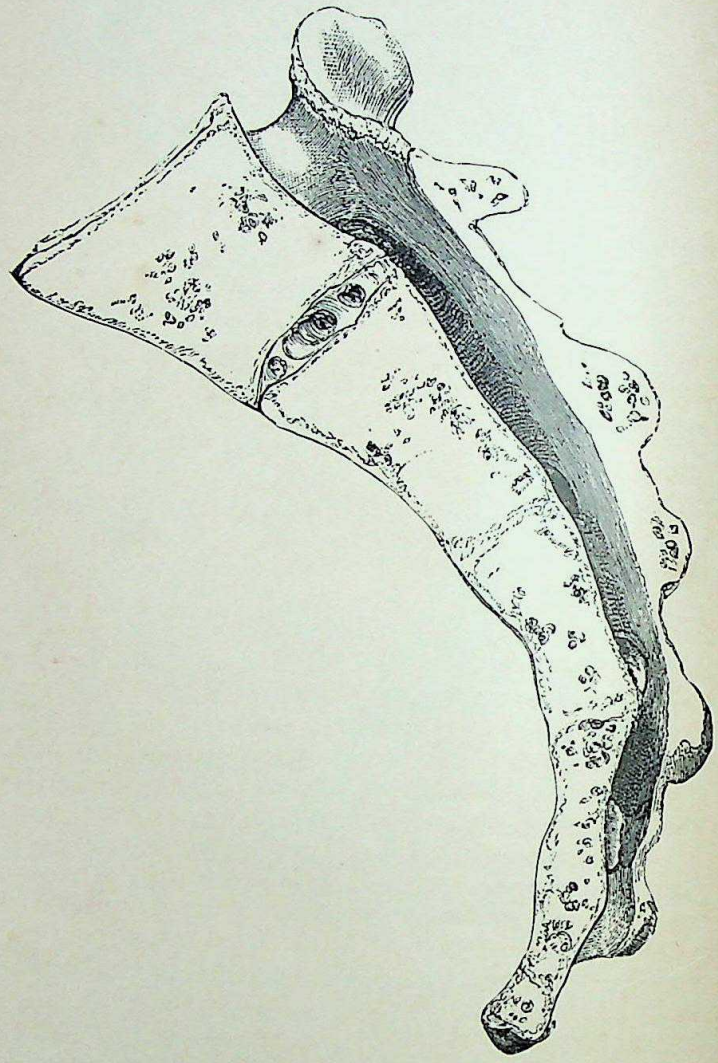

curvature is more evenly distributed over the whole length of the bone the female the bone is directed more obliquely backwards than in the m this increases the size of the pelvic cavity and renders the sacrovertebral more prominent. In the female the auricular surface for articulation the ilium is shorter than that in the male, extending along the sides o first and second sacral vertebræ only; in the male it is continued down t middle or lower limit of the third vertebra.

Structure.—The sacrum consists of spongy substance enveloped by a thin of compact bone.

Variations.—The curvature of the sacrum varies considerably in dif specimens of the same sex. In some cases the bone consists of six vertebr others of four. The transverse process of the first sacral segment may n joined to the rest of the ala on one or both sides, and a considerable part o posterior wall of the sacral canal may be wanting, in consequence of the imp development of the laminæ and spinous processes.

CC-0. In Public Domain. Gurukul Kangri Collection, Haridwar

Digitized by Arya Samaj Foundation Chennai and eGangotri

THE COCCYX (OS COCCYGIS)

he **coccyx** (figs. 264, 265) is a small, triangular bone consisting usually of rudimentary vertebræ, but the number may be increased to five or reduced ce; it forms a pointed apex for the sacral wedge.

he *first coccygeal vertebra* is the largest and often exists as a separate piece. he upper surface of its central part or body, is an oval facet for articulation the apex of the sacrum. Two processes, named *coccygeal cornua*, project rds from the posterolateral parts of the body; they are the homologues e pedicles and superior articular processes of the movable vertebræ. They d to articulate with the sacral cornua, and, on either side, form part e margin of the intervertebral foramen for the fifth sacral nerve. A entary transverse process projects lateralwards and slightly upwards either side of the body. It is flattened from before backwards, and ascends to articulate with the inferior lateral angle of the sacrum, thus leting the foramen for the passage of the anterior division of the fifth l nerve; the posterior division of this nerve descends on the back of the verse process.

64.—The coccyx. Anterior aspect.

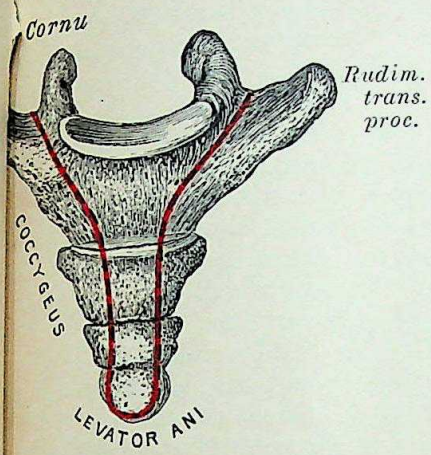

FIG. 265.—The coccyx. Posterior aspect.

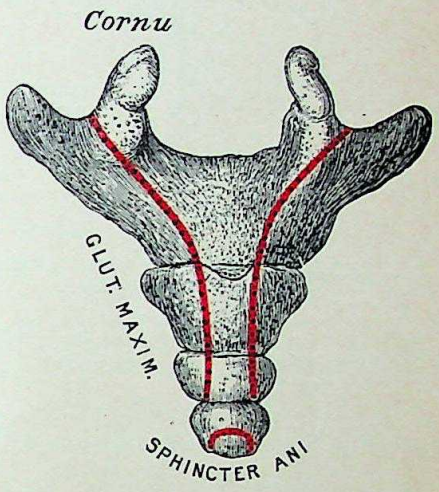

he *second*, *third*, and *fourth coccygeal vertebræ* diminish successively in size, are usually fused with one another. The second shows traces of transverse esses and pedicles; the third and fourth represent only rudimentary ebral bodies, and are mere nodules of bone.

he filum terminale of the medulla spinalis is attached to the posterior ce of the first segment. The Glutæus maximus arises from the posterior aces of the first three segments, and the Sphincter ani externus from the The Coccygei and Levatores ani are attached to the thin lateral edges, to the adjoining parts of the anterior surface of the bone.

The ossification of the vertebral column.—Each typical vertebra is ossified from e primary centres (fig. 266), two for the vertebral arch, and one for the body.* fication of the vertebral arches begins in the upper cervical vertebræ about the nth or eighth week of fœtal life, and gradually extends down the column. The res first appear in the situations where the transverse processes afterwards ect, and spread backwards to the spinous process, forwards into the pedicles, lateralwards into the transverse processes. Ossification of the bodies begins he lower thoracic vertebræ about the eighth week of fœtal life, and subsequently nds upwards and downwards along the column. The centre for the body does give rise to the whole of the body of the adult vertebra, the posterolateral portions which are ossified from the centres for the vertebral arch. The body of a ebra during the first few years of life shows, therefore, two synchondroses *rocentral synchondroses*) traversing it along the planes of junction of these three res (fig. 267). In the thoracic region the costal facets on the bodies lie behind neurocentral synchondroses. At birth a vertebra consists of three pieces, viz. the y and the halves of the vertebral arch. During the first year the halves of the

* The body is occasionally ossified from two lateral centres which sometimes fail to unite.

CC-0. In Public Domain. Gurukul Kangri Collection, Haridwar

Digitized by Arya Samaj Foundation Chennai and eGangotri

arch unite behind, union taking place first in the lumbar region and then upwards through the thoracic and cervical regions. In the upper cervical the bodies unite with about the third year, lower lumbar vertebr is not completed until year. Until puberty, and under surfaces of and the ends of the and spinous processes laginous, but about the year five secondary ce pear, one for the tip transverse process, one end of the spinous pro two annular epiphysial the circumferential par upper and lower surface body (figs. 267, 268). T articular facets arise as sions of the annular ep discs (Dixon).* These sec centres fuse with the rest bone about the age of five years. In the bifid of the cervical vertebr are two secondary centr

Exceptions to this ossification occur in th second, and seventh vertebræ, and in the vertebræ.

The **atlas,** or first vertebra, is usually ossif three centres (fig. 269 appears in either later about the seventh week life, and gradually exten the posterior arch, wh two unite between the th fourth years, either dire through the medium of rate centre. At birth, t terior arch consists of car in this a separate centre about the end of the firs and unites with the lateral between the sixth and years—the lines of uni tending across the anter tions of the superior ar facets. Occasionally the arch is formed by the extension and ultimate the centres for the masses; sometimes it is from two laterally placed

The **epistropheus,** or cervical vertebra, is ossifie five primary and two sec centres (fig. 270). The ve arch is ossified from two p

Fig. 266.—The ossification of a typical vertebra.

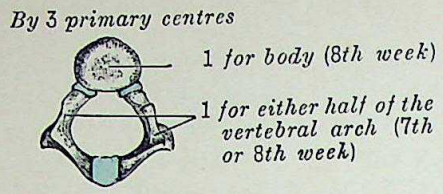

Fig. 267.

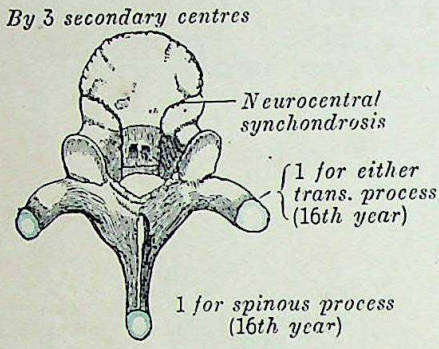

Fig. 268.

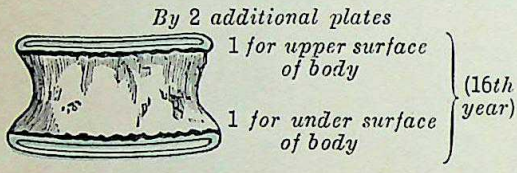

Exceptional cases

Fig. 269.—The ossification of the atlas.

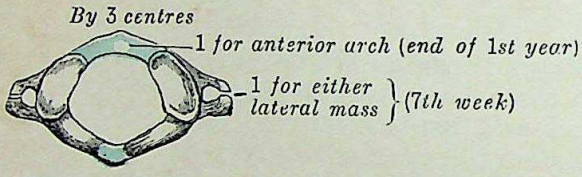

Fig. 270.—The ossification of the epistropheus.

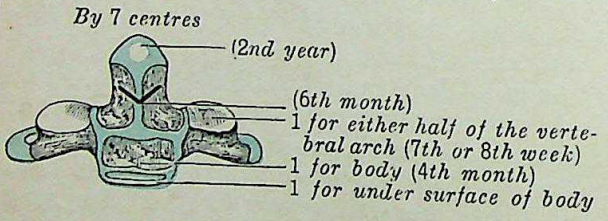

Fig. 271.—The ossification of a lumbar vertebra.

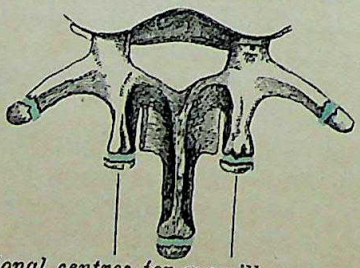

* A. Francis Dixon, *Journal of Anatomy*, vol. lv., October 1920.

CC-0. In Public Domain. Gurukul Kangri Collection, Haridwar

Digitized by Arya Samaj Foundation Chennai and eGangotri

es, and the body from one, as in a typical vertebra; the centres for the arch r about the seventh or eighth week of fœtal life, the centre for the body about fourth or fifth month. The dens or oid process represents the body of the and is chiefly ossified from two later- laced centres; these appear about the month of fœtal life, and join before to form a conical mass, deeply cleft e. A wedge-shaped piece of cartilage he cleft and forms the summit of the ss; in this cartilage a centre appears t the second year and unites with the mass of the dens about the twelfth year. base of the dens is separated from the of the epistropheus by a cartilaginous the circumference of which ossifies, but entre remains cartilaginous until ad- d age; in this cartilaginous disc, ents of the lower epiphysial lamella of plas and the upper epiphysial lamella epistropheus may sometimes be found. dition to these centres there is one for n epiphysial plate on the under surface e body of the bone.

he **seventh cervical vertebra.**—The l processes of this vertebra are usually ed from separate centres which appear t the sixth month of fœtal life, and the body and transverse processes een the fifth and sixth years. As dy stated (p. 169), the costal processes persist as separate pieces, and grow lwards and forwards, to constitute ical ribs.

Separate ossific centres have also been d in the costal processes of the fourth, and sixth cervical vertebræ.

The **lumbar vertebræ** (fig. 271) have each additional centres, for the mamillary esses.

he **sacrum** (figs. 272 to 275).—Each i vertebra is ossified from three primary es, one for the body and two for the ebral arch. Two epiphysial plates are ed for each body, one for the upper and other for the lower surface.

The anterior portions of the lateral parts he sacrum have six additional (costal) es, two for each of the first three verte- ; these appear above and lateral to the erior sacral foramina (figs. 272, 273).

Two epiphysial plates are developed on er lateral surface of the sacrum (figs. 274,); one for the auricular surface, and ther for the thin edge of bone below surface.

FIG. 272.—The ossification of the sacrum and coccyx.

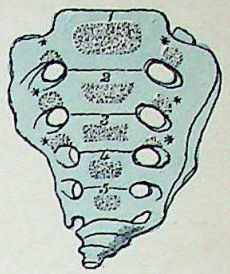

FIG. 273.

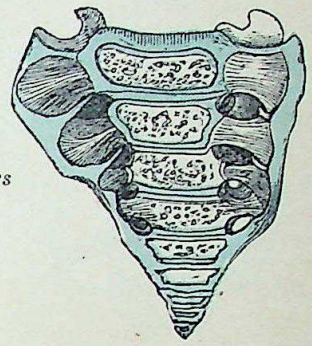

FIG. 274.

The two epiphysial plates for each lateral surface are marked by asterisks.

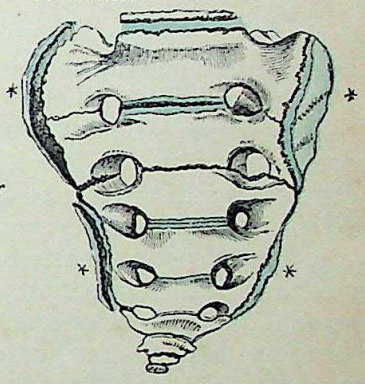

FIG. 275.—The base of the sacrum of an adolescent.

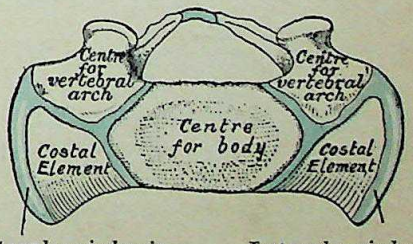

The ends of the spinous processes of the upper three sacral vertebræ are some- s developed from separate epiphyses, and Fawcett* has pointed out that a ber of epiphyses are present in the sacrum at the eighteenth year (fig. 276). se are distributed as follows: One for each of the two mamillary processes of first sacral vertebra; twelve, six on either side, in connexion with the costal esses (two each—an anterior and a posterior—for the first and second, and

* E. Fawcett, *Anatomischer Anzeiger*, Bd. xxx., 1907.

CC-0 In Public Domain. Gurukul Kangri Collection, Haridwar

Digitized by Arya Samaj Foundation Chennai and eGangotri

one each—an anterior—for the third and fourth vertebræ; and eight, four side, for the transverse processes, one each for the first, third, fourth He is also of opinion (1) that the auricular facets on the lateral surfaces of th are in the main formed by the development and fusion of the costal epiphy first and second sacral vertebræ, and (2) that the lower part of each lateral formed by the extension and union of the costal epiphyses of the third a with the epiphyses of the transverse processes of the fourth and fifth, sacral

The periods of ossification of the sacrum.—The centres for the bodi first, second and third sacral vertebræ appear towards the end of the thir and those for the bodies of th and fifth vertebræ between and eighth months of fo The centres for the vertebr appear about the fifth mon those for the costal proc the lateral parts of the bone the sixth and eighth months life. In the lower vertel arches fuse with the bodies second year; in the first fusion does not occur until th or sixth year. About the si year the epiphysial plates upper and under surfaces bodies are formed; and betw eighteenth and twentieth year for the lateral surfaces of th make their appearance. Duri life, the bodies of the sacral are separated from each o intervertebral fibrocartilages, b the eighteenth year the bodie two lower vertebræ become united by bone, and the process of bon gradually extends upwards, with the result that between the twenty-f thirtieth years of life all the vertebræ are united (fig. 263).

Fig. 276.—The epiphyses of the costal and transverse processes of the sacrum at the eighteenth year. (E. Fawcett.)

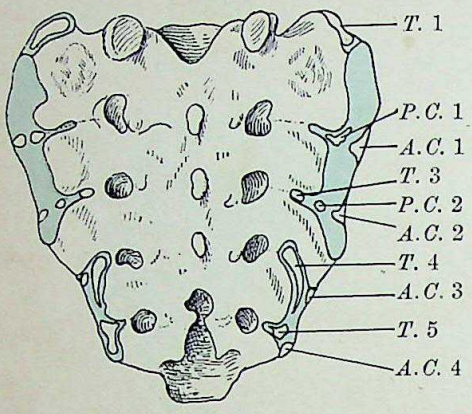

A.C. 1, 2, 3, 4, Anterior epiphyses for first, second, third and fourth costal processes. *P.C.* 1, 2, Posterior epiphyses for first and second costal processes. *T.* 1, 3, 4, 5, Epiphyses for the first, third, fourth and fifth transverse processes.

The **coccyx.**—Each segment of the coccyx is ossified from one centr centres appear in the following order: in the first segment between the f fourth years; in the second between the fifth and tenth years; in the third the tenth and fifteenth years; in the fourth between the fourteenth and tw years. A secondary centre for each coccygeal cornu, and a pair of epiphysi for each of the rudimentary bodies have been described. As age advan segments unite with one another, the union between the first and secon frequently delayed until after the age of twenty-five or thirty years. A period of life, especially in females, the coccyx often fuses with the sacrum.

The Vertebral Column as a Whole

The **vertebral column** is situated in the median line. at the p part of the trunk. Its average length in the male is about 71 cm.; the cervical part measures 12·5 cm., the thoracic 28 cm., the lumbar and the sacrum and coccyx 12·5 cm. The average length of the female v column is about 61 cm.

The curves of the vertebral column.—Viewed laterally (fig. 277), the v column presents cervical, thoracic, lumbar, and pelvic curves. The and pelvic curves are termed primary curves, because they alone are during fœtal life. The cervical and lumbar curves are secondary or co tory, and are developed after birth, the cervical curve when the child to hold up its head (at three or four months), and to sit upright (abo months), the lumbar at twelve or eighteen months when the child b walk. The *cervical* curve is convex forwards, and is the least marked four; it begins at the atlas, and ends at the middle of the second vertebra. The *thoracic* curve is concave forwards, and extends fr

CC-0. In Public Domain. Gurukul Kangri Collection, Haridwar

Digitized by Arya Samaj Foundation Chennai and eGangotri

dle of the second to the middle of twelfth thoracic vertebra. The *bar* curve is convex anteriorly is more pronounced in the female in the male; it reaches from the dle of the last thoracic vertebra he sacrovertebral angle, and the vexity of the lower three segments reater than that of the upper two. *pelvic* curve extends from the overtebral articulation to the of the coccyx; its concavity is cted downwards and forwards.

In the upper part of the thoracic on of the vertebral column e is a slight *lateral* curvature, its convexity directed towards right side in right-handed per-

Some regard this curve as due to the greater use and ularity of the right arm, and in ort of this explanation it has found that in left-handed viduals the convexity of the e is directed towards the left

Others regard it as being uced by the aortic arch and er part of the descending thoracic a—a view which is supported the fact that in cases where the era are transposed and the a is consequently on the right the convexity of the curve is cted to the left.

The *anterior surface* of the verte- column.—When viewed from ront, the width of the bodies of vertebræ is seen to increase n the second cervical to the first acic; there is then a slight inution in the next three verte- ; below this there is again a ual and progressive increase in h as low as the sacrovertebral e. From this level there is a d diminution, to the apex of the yx.

The *posterior surface* of the ebral column presents in the ian line the spinous processes. the cervical region (with the ption of the second and seventh ebræ) these are short and hori- tal, with bifid ends. In the upper of the thoracic region they are cted obliquely downwards; in middle part they are long and ost vertical; in the lower part he thoracic region and in the bar region they are nearly hori- tal. They are separated by con- rable intervals in the cervical lumbar regions, but are closely

FIG. 277.—The vertebral column. Left lateral aspect.

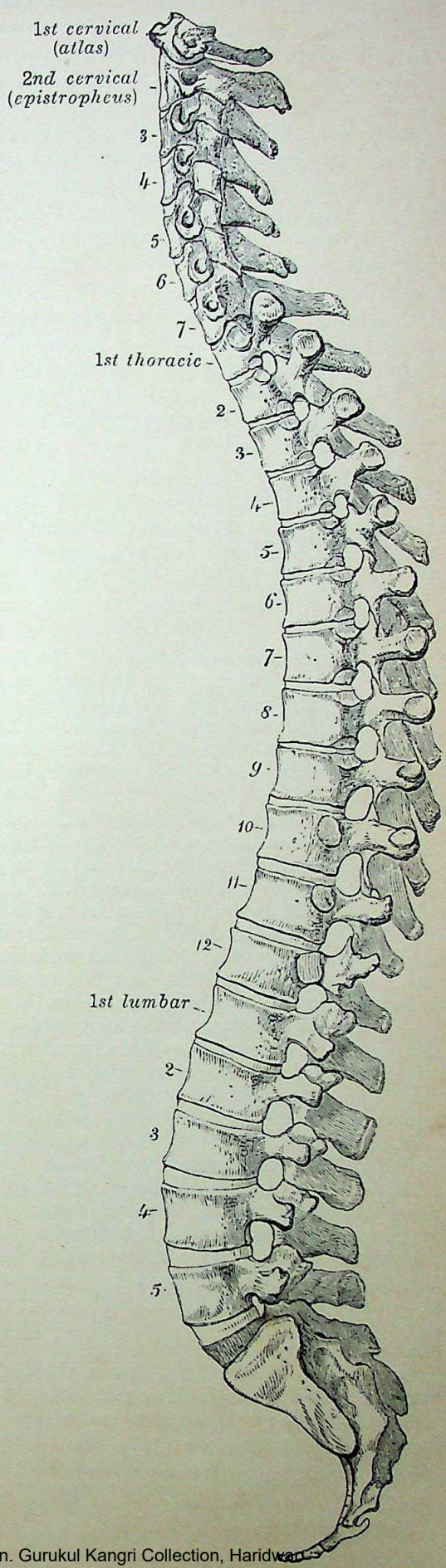

CC-0. In Public Domain. Gurukul Kangri Collection, Haridwar

Digitized by Arya Samaj Foundation Chennai and eGangotri

approximated in the middle of the thoracic region. Occasionally a process may deviate from the median line—a fact to be remembered in as irregularities of this sort are attendant also on fractures or displ of the vertebral column. At the sides of the spinous processes *vertebral grooves* which lodge the deep muscles of the back. In the and lumbar regions these grooves are shallow and are formed by the of the vertebræ; in the thoracic region they are deep and wide, formed by the laminæ and transverse processes. Lateral to the grooves are the articular processes, and still more lateral the transve cesses. In the thoracic region, the transverse processes stand backwar plane considerably behind that of the same processes in the cervical and regions. In the cervical region, the transverse processes are placed of the articular processes, lateral to the pedicles, and between the interv foramina. In the thoracic region they are behind the pedicles, interv foramina, and articular processes. In the lumbar region they are in the articular processes, but behind the intervertebral foramina.

The *lateral surfaces* of the vertebral column are separated from the surface by the articular processes in the cervical and lumbar regions, the transverse processes in the thoracic region. In front are the sides bodies of the vertebræ, marked in the thoracic region by the facets for a tion with the heads of the ribs. Between the pedicles are the interver foramina, oval in shape, smallest in the cervical and upper part of the th regions, and gradually increasing in size to the last lumbar; these fo transmit the spinal nerves and vessels.

The *vertebral canal* follows the curves of the column; it is large and tri in the cervical and lumbar regions, where movement is free, but sm circular in the thoracic region, where motion is more limited.

Applied Anatomy.—Occasionally the coalescence of the laminæ is not comple consequently a cleft is left in the arches of the vertebræ, through which a prot the spinal membranes (dura mater and arachnoid), and generally of the medulla and pia mater, takes place, constituting the malformation known as *spina bifi* condition is most common in the lumbosacral region, but it may occur in the or cervical region, or the arches throughout the whole length of the canal may incomplete.

Although there is only a very limited amount of movement between any t tiguous vertebræ, there is a considerable range of movement in the vertebral colu whole. The intervertebral fibrocartilages act as buffers between the different s and counteract or neutralize the effect of jars or shocks which may be applied column; for example, dropping from a height on to the feet rarely causes conc the brain or spinal medulla. The security of the column is also provided for by its tion in curves, enabling it to bend without breaking. The vertebræ are so firmly to one another that violence applied to the column is more likely to produce fr dislocation than a tearing of ligaments.

Fracture-dislocations of the vertebral column are more frequently caused by than by direct violence. When produced by indirect violence, the upper seg driven forwards on the lower, and the spinal medulla is compressed between the the vertebra immediately below, and the arch of the vertebra immediately ab injury. Since the spinal medulla ends at the level of the upper border of the lumbar vertebra it follows that partial dislocations, or gunshot wounds, below th are less serious than those above it.

The normal position of the vertebral column may be altered either by the form new curvatures or by an increase of some of the normal ones. In many cases, no rapidly growing adolescents, the deformity results from weakness of the supporting which are unable to keep the vertebræ firmly applied to one another, and altera the disposition of the column are produced by the weight of the body. In later persistent use of faulty positions (e.g. in shoemakers, tailors, etc.) or the carrying of suspended from the trunk (e.g. in hawkers) may distort the vertebral column. I cases the changes in the curvatures may be the result of diseases of the vertebræ ligaments (e.g. tuberculosis, rheumatism, etc.). Sometimes the deviations result m cally from the effects of disease in other parts (e.g. in cases of shortening of one hip-joint disease, or in cases of adhesions in the thorax from an old empyema). in the curvatures of the vertebral column are multiple since secondary (compe curves form to restore the balance of the body.

The chief forms of abnormal curvatures are scoliosis, kyphosis and lordosis. In the column is bent to one side, and this is accompanied by a rotation of the vertebral round a vertical axis. In *kyphosis* the thoracic curve is increased, while in *lord* deformity is an exaggeration of the lumbar curve.

CC-0. In Public Domain. Gurukul Kangri Collection, Haridwar

Digitized by Arya Samaj Foundation Chennai and eGangotri

aminectomy.—The operation of laminectomy is performed in cases of pressure on edulla spinalis, where the continuity of the nerve-tracts has not been completely yed. It consists of cutting down on and removing the laminæ and spinous pro- in the affected region, so as to relieve the medulla spinalis from pressure; but it less in cases of complete destruction of this structure. Laminectomy is chiefly med (i) for fracture-dislocation; (ii) for localised pressure in cases of spinal caries, ject here being to remove the laminæ against which the medulla spinalis is pressed e inflammatory mass, and (iii) for the removal of tumours growing inside the bral canal and compressing the medulla spinalis. If such cases be taken early, very actory results are obtained.

e subarachnoid cavity ends at the level of the lower border of the second sacral bra; the lower part of the sacrum may therefore be removed to expose growths or urs of the rectum without opening into this cavity.

The Sternum

e **sternum** (figs. 278 to 280) is a long flat bone, forming the middle on of the anterior wall of the thorax. Its average length is about 17 cm., s rather greater in the male than in the female. Its upper end supports lavicles, and its margins articulate with the cartilages of the first seven of ribs. It consists of three parts, named from above downwards, the *rium*, the *body*, and the *xiphoid process*; in early life the body consists r segments or *sternebræ*. In its natural position the inclination of the is oblique from above, downwards and forwards. It is slightly convex ont, and concave behind; it is broad above, narrow at the junction of manubrium with the body, below which it gradually widens as far as the of the articulations of the cartilages of the fifth ribs, and then narrows kly to its lower extremity.

e **manubrium sterni** is of a somewhat triangular form, broad and thick e, narrow below at its junction with the body. Its *anterior surface*, convex side to side, concave from above downwards, is smooth, and affords hment on either side to the sternal origins of the Pectoralis major and ocleidomastoideus. Its *posterior surface*, concave and smooth, gives n on either side to the Sternohyoideus and Sternothyreoideus. The *rior border* is thick, and presents at its centre the *jugular notch*; on either of this notch is an oval articular surface, directed upwards, backwards, and lwards, for articulation with the sternal end of the clavicle. The *inferior r*, oval and rough, is covered in the recent state with a thin layer of lage, for articulation with the upper end of the body. The *lateral borders* ach marked above by a depression for the reception of the first costal lage, and below by a small articular facet, which, with a similar one on pper angle of the body, forms a notch for the sternal end of the costal ge of the second rib. Between the depression for the first costal cartilage the facet for the second is a narrow, curved edge, which slopes from above wards and medialwards.

e **body** of the sternum, longer, narrower, and thinner than the manubrium, ns its greatest breadth close to the lower end. Its *anterior surface*, nearly is directed forwards and upwards, and is marked by three transverse s opposite the third, fourth, and fifth articular depressions.* It affords hment on either side to the sternal origin of the Pectoralis major. A *al foramen*, of varying size and form, is occasionally seen at the junction e third and fourth pieces of the body. The *posterior surface*, slightly ave, is also marked by three transverse lines, less distinct, however, than e on the anterior surface; from its lower part, on either side, the Transversus acis takes origin. The *upper end* is oval and articulates with the manu- n, the junction of the two forming the *sternal angle* (*angulus Ludovici* †). *lower end* is narrow, and articulates with the xiphoid process. Each *l border* (fig. 280), at its superior angle, has a small facet, which with a

Paterson (*The Human Sternum*, 1904) found that these ridges were absent in 26·7 per cent.; ridge existed opposite the third costal cartilage in 69 per cent.; opposite the fourth in cent.; and opposite the fifth in 4 per cent.

Named after the French surgeon Antoine Louis, 1723-1792. The Latin term *angulus ici* is not infrequently mistranslated into English as 'the angle of Ludwig.'

CC-0. In Public Domain. Gurukul Kangri Collection, Haridwar

Digitized by Arya Samaj Foundation Chennai and eGangotri

similar one on the manubrium, forms a notch for the reception of the end of the cartilage of the second rib; below this are four angular facets to receive the sternal ends of the cartilages of the third, fourth, fifth, and sixth ribs; the inferior angle has a small facet, which, with a similar one on the xiphoid process, forms a notch for the reception of the cartilage of the

FIG. 278.—The sternum and costal cartilages. Anterior aspect.

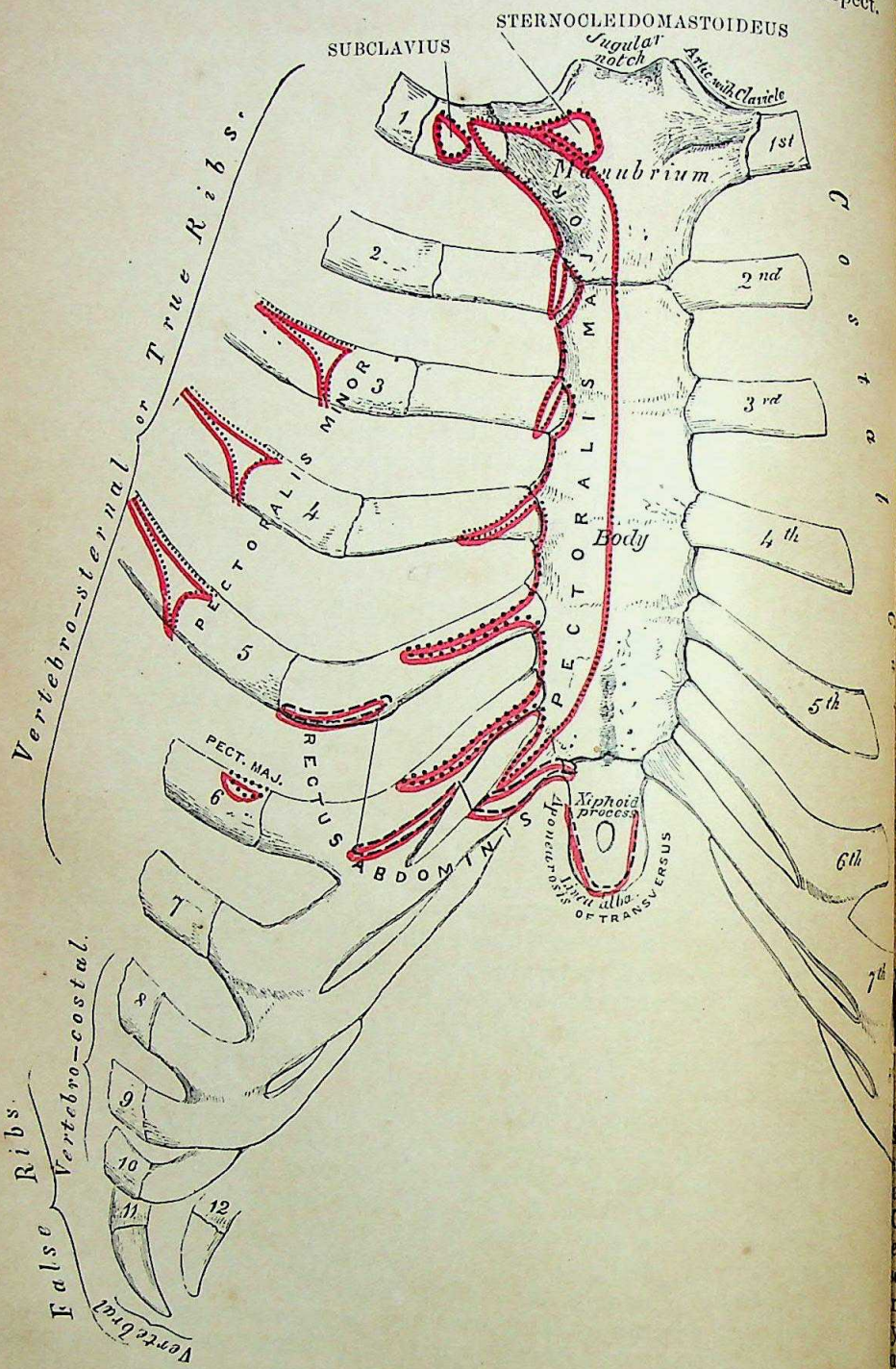

rib. These articular depressions are separated by a series of curved which diminish in length from above downwards, and correspond to the ends of the intercostal spaces.

It will be observed that most of the cartilages of the true ribs articulate sternum at the lines of junction of its primitive component segments; this is well many of the lower animals, where the parts of the bone remain ununited long in man.

CC-0. In Public Domain. Gurukul Kangri Collection, Haridwar

Digitized by Arya Samaj Foundation Chennai and eGangotri

The **xiphoid process** is the smallest piece of the sternum; it is thin and gated, cartilaginous in youth, but more or less ossified at its upper part be adult. Its *anterior surface* affords attachment on either side to the rior costoxiphoid ligament and a small part of the Rectus abdominis; its rior *surface*, to the posterior costoxiphoid ligaments and to some of the s of the Diaphragm and Transversus thoracis; its *lateral borders*, to the euroses of the abdominal muscles. Above, it articulates with the lower of the body of the bone, and on the front of each superior angle is a facet part of the cartilage of the seventh rib; the linea alba is attached to its ted lower end.

The xiphoid process varies greatly; it may be broad and thin, pointed, perforated, curved, or deflected to one or other side.

279.—The sternum. Posterior aspect.

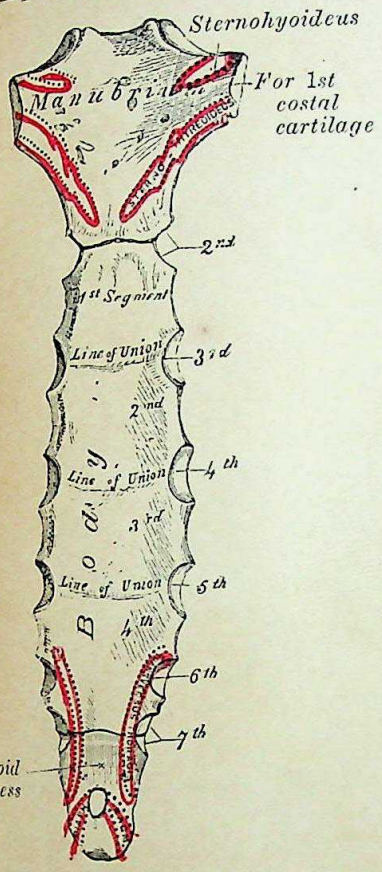

FIG. 280.—The sternum. Lateral aspect.

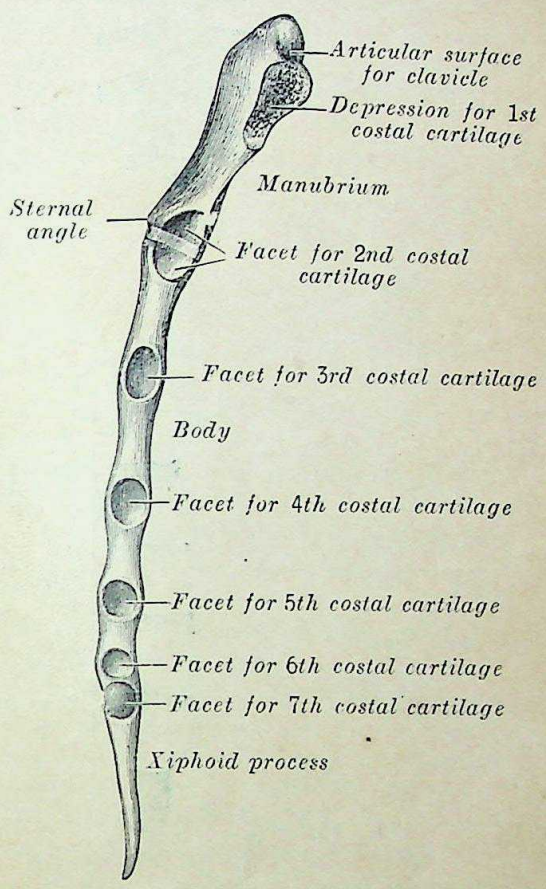

Structure.—The sternum is composed of highly vascular spongy substance red by a layer of compact bone which is thickest on the manubrium between articular facets for the clavicles.

Ossification.—The sternum originally consists of two cartilaginous *sternal es*, one on either side of the median plane. Opposite the first seven pairs of ribs e plates fuse with one another in the middle line to form the cartilaginous num, which is ossified from six centres: one for the manubrium, four for the y, and one for the xiphoid process (fig. 281). These centres appear in the rvals between the articular depressions for the costal cartilages, in the following r: in the manubrium and first piece of the body, during the sixth month of fœtal in the second and third pieces of the body, during the seventh month of fœtal in the fourth piece, shortly before birth; and in the xiphoid process, in the third or much later.* Two small episternal centres sometimes appear, one on either of the jugular notch; they are probably vestiges of the episternal bone of the otremata and lizards. The manubrium may have two, three, or more centres;

Paterson (*op. cit.*) found the fourth or lowest centre for the body present only in 26·9 per of cases.

CC-0. In Public Domain. Gurukul Kangri Collection, Haridwar

Digitized by Arya Samaj Foundation Chennai and eGangotri

when two are present, one is generally situated above the other, the up the larger. The first segment of the body has seldom more than one cen the second, third, and fourth segments are often ossified from two lateral centres, and if these fail to join, the foramen or fissure which is occasion in this part of the bone results. Union between the centres of the bod about puberty, and proceeds from below upwards (fig. 282); by the age of five they are all united. The xiphoid process usually fuses with the bo

Fig. 281.—The ossification of the sternum.

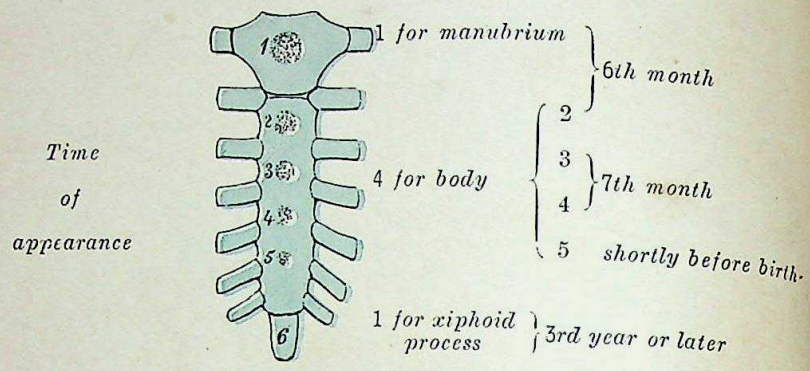

Fig. 282.

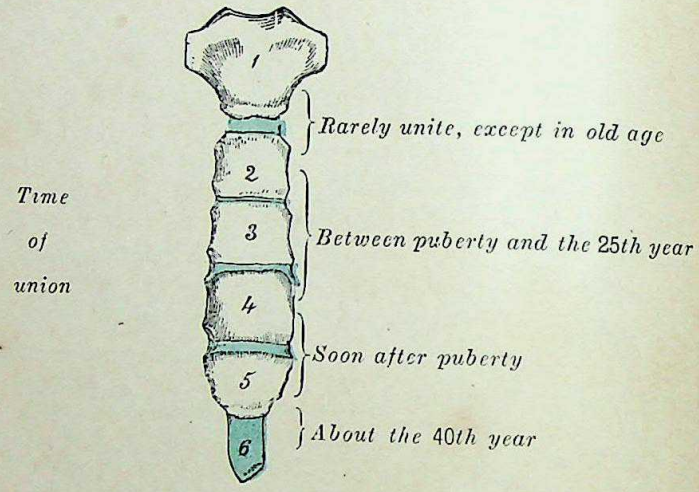

the age of forty years, but may remain ununited in old age. In advanc the manubrium is occasionally joined to the body by bone, but when this only the peripheral part of the intervening cartilage is converted into bon central part remains unossified.

The Ribs (Costæ)

The **ribs** are elastic arches of bone, which are connected behind wi vertebral column, and form a large part of the skeleton of the thorax. are twelve in number on either side; but this number may be increa the development of a cervical or a lumbar rib, or may be reduced to The first seven are connected in front, through the intervention of the cartilages, with the sternum (fig. 278); they are called *true* ribs (costæ The remaining five are *false* ribs (costæ spuriæ); of these the cartilages eighth, ninth and tenth are each joined to the cartilage of the rib immed

* Sometimes the eighth rib cartilage articulates with the sternum; this condition more frequently on the right than on the left side.

CC-0. In Public Domain. Gurukul Kangri Collection, Haridwar

Digitized by Arya Samaj Foundation Chennai and eGangotri

(vertebrochondral ribs); the eleventh and twelfth are free at their anterior and are termed *floating* or *vertebral* ribs.

FIG. 283.—A central rib of the left side. Inferior aspect.

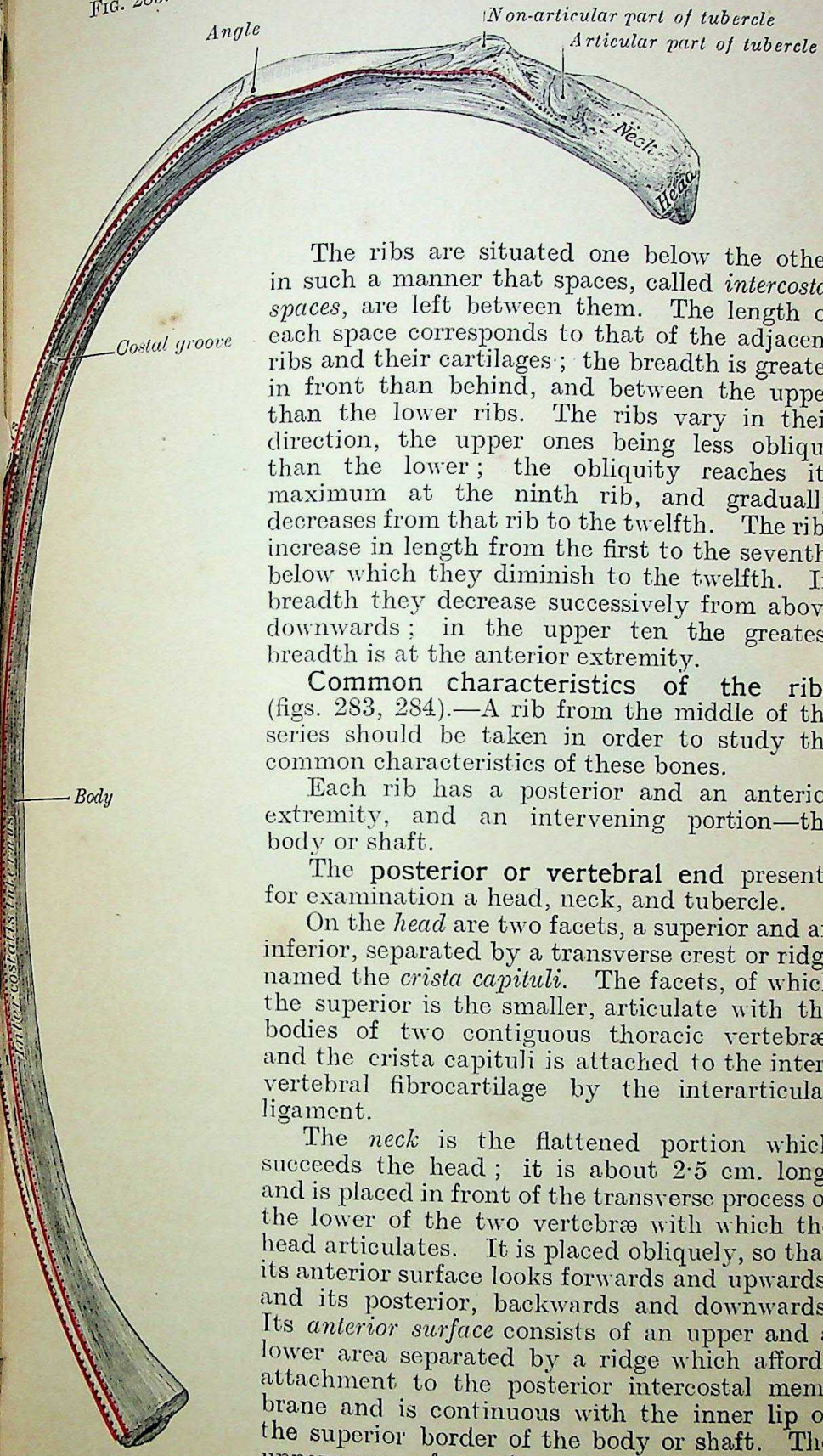

The ribs are situated one below the other in such a manner that spaces, called *intercostal spaces*, are left between them. The length of each space corresponds to that of the adjacent ribs and their cartilages; the breadth is greater in front than behind, and between the upper than the lower ribs. The ribs vary in their direction, the upper ones being less oblique than the lower; the obliquity reaches its maximum at the ninth rib, and gradually decreases from that rib to the twelfth. The ribs increase in length from the first to the seventh, below which they diminish to the twelfth. In breadth they decrease successively from above downwards; in the upper ten the greatest breadth is at the anterior extremity.

Common characteristics of the ribs (figs. 283, 284).—A rib from the middle of the series should be taken in order to study the common characteristics of these bones.

Each rib has a posterior and an anterior extremity, and an intervening portion—the body or shaft.

The **posterior or vertebral end** presents for examination a head, neck, and tubercle.

On the *head* are two facets, a superior and an inferior, separated by a transverse crest or ridge named the *crista capituli*. The facets, of which the superior is the smaller, articulate with the bodies of two contiguous thoracic vertebræ, and the crista capituli is attached to the intervertebral fibrocartilage by the interarticular ligament.

The *neck* is the flattened portion which succeeds the head; it is about 2·5 cm. long, and is placed in front of the transverse process of the lower of the two vertebræ with which the head articulates. It is placed obliquely, so that its anterior surface looks forwards and upwards, and its posterior, backwards and downwards. Its *anterior surface* consists of an upper and a lower area separated by a ridge which affords attachment to the posterior intercostal membrane and is continuous with the inner lip of the superior border of the body or shaft. The upper area, of varying size and more or less triangular in shape, is separated from the erior intercostal membrane by some fatty tissue; the lower is smooth and red by the costal pleura. Its *posterior surface* is rough for the attachment

CC-0. In Public Domain. Gurukul Kangri Collection, Haridwar

Digitized by Arya Samaj Foundation Chennai and eGangotri

of the ligament of the neck of the rib, and perforated by numerous fo
On its *superior border* is a rough crest, the *crista colli costæ*, for the atte
of the anterior costotransverse ligament; from this crest a line can be t
into the outer lip of the superior border of the body or shaft. Its
border, more or less rounded, gives attachment to the posterior inte
membrane and is continuous with the superior border of the costal gro

On the posterior surface of the rib, at the junction of the neck an
and nearer the lower than the upper border, is the *tubercle*; it is more pro
in the upper than in the lower ribs, and consists of an articular and
articular portion. The *articular portion*, the lower and more medial, has
oval surface for articulation with the end of the transverse process of th
of the two vertebræ to which the head is connected. The *non-articular*
is a rough elevation, and affords attachment to the ligament of the tub

The **body** or **shaft** is thin and flat, with an external and an internal s
and a superior and an inferior border. The *external surface* is convex,
and marked, a little in front of the tubercle, by a rough line directed
wards and lateralwards; this gives attachment to one of the tendons of t

Fig. 284.—A central rib of the left side. Posterior aspect.

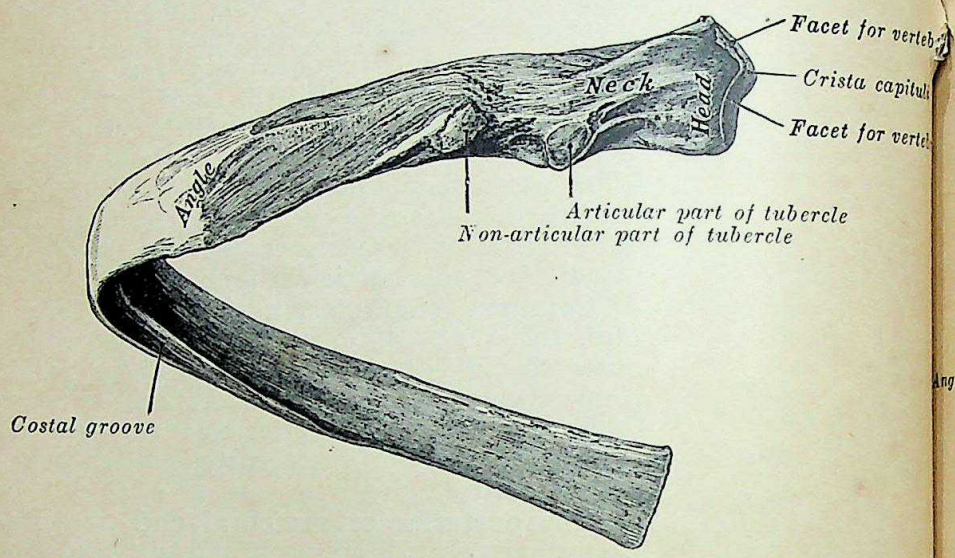

costalis, and is called the *angle*. At this line the bone is bent in two dire
and at the same time twisted on its long axis. This may be demons
by laying a rib with its lower border in contact with a flat horizontal s
The portion behind the angle is then seen to be inclined medialward
upwards from the long axis of the body of the rib, while as the result
twisting, the external surface of the part behind the angle looks down
and that in front of the angle slightly upwards. The distance betwe
angle and the tubercle is progressively greater from the second to the
ribs. Between the angle and the tubercle the external surface is ro
rough, and irregular, and serves for the attachment of a slip of the Longi
dorsi. Near the sternal end of the external surface is an indistinct
line, the *anterior angle*. The *internal surface* is concave, smooth, d
a little upwards behind the angle, a little downwards in front of it,
marked by a ridge which commences at the lower edge of the head; thi
is prominent as far as the angle, but is lost at the junction of the a
with the middle one-third of the bone. Between the ridge and the inferior
is the *costal groove*, for the intercostal vessels and nerve; within the
are seen the orifices of numerous small foramina for nutrient vessels,
traverse the shaft obliquely from before backwards. At the posteri
of the bone the costal groove occupies the inferior border, but just in f
the angle the groove is deep and broad, and is placed on the internal surface
upper edge of the groove serves for the attachment of an Intercostalis int
and is continuous behind with the inferior border of the neck; the i

CC-0. In Public Domain. Gurukul Kangri Collection, Haridwar

Digitized by Arya Samaj Foundation Chennai and eGangotri

of the groove constitutes the *inferior border* of the rib, and gives attach- to an Intercostalis externus. The *superior border* of the rib, thick and ded, is marked by an external and an internal lip, more distinct behind in front; the former gives attachment to an Intercostalis externus, the to an Intercostalis internus.

the **anterior or sternal end** is an oval, cup-shaped depression, into the lateral end of the costal cartilage is received.

he first, second, tenth, eleventh, and twelfth ribs present certain variations, equire special consideration.

he **first rib** (fig. 285) is the most curved and usually the shortest of the it is broad and flat, its surfaces looking upwards and downwards, and orders inwards and outwards. The *head* is small, rounded, and has only gle, nearly circular, articular facet, which articulates with the upper of the side of the body of the first thoracic vertebra. The *neck* is

Fig. 285.—The first and second ribs. Superior aspect.

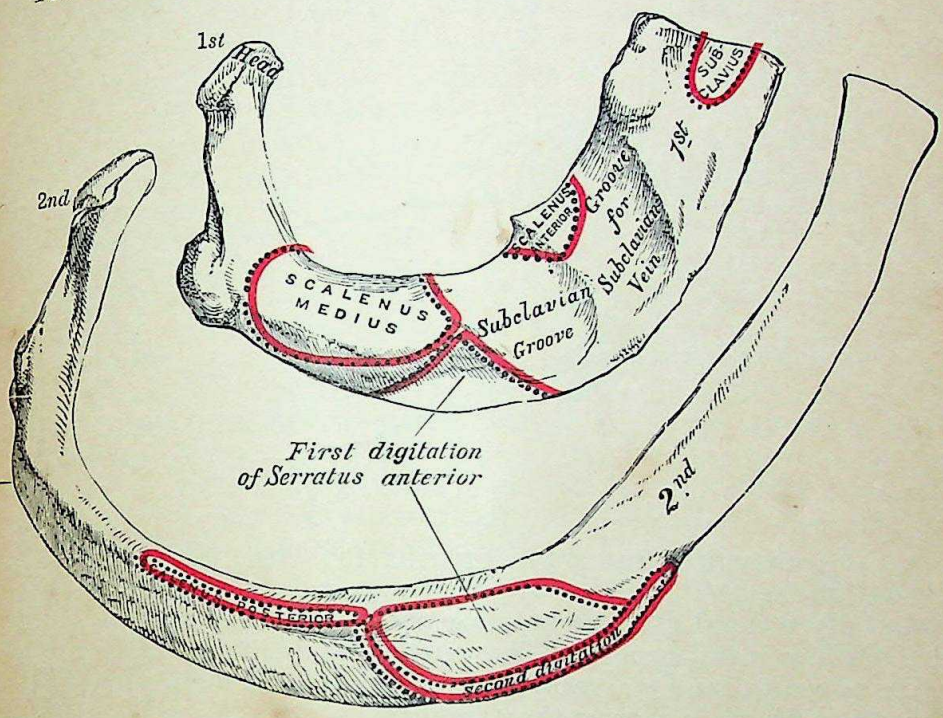

hat rounded. The *tubercle*, thick and prominent, is directed upwards backwards; on its medial part is an oval facet for articulation with the verse process of the first thoracic vertebra. At the tubercle the rib is so that the head of the bone is directed slightly downwards. There is gle. The *upper surface* of the body is marked by two shallow grooves, ated from one another by a slight ridge which ends at the inner border of b in the *scalene tubercle*. The tubercle gives the attachment of the Scalenus ior; the groove in front of it supports the subclavian vein, that behind e subclavian artery and the lowest trunk of the brachial plexus.* The ce in front of the anterior groove gives origin to the Subclavius muscle, attachment to the costoclavicular ligament; behind the posterior groove rough area for the attachment of the Scalenus medius. The *under sur-* is smooth, and destitute of a costal groove. The *outer border* is convex, behind, but thin in front. Immediately behind the subclavian groove es origin to the upper part of the first digitation of the Serratus anterior. *nner border* is concave and thin, and marked near its centre by the e tubercle. The *anterior end* is larger and thicker than that of any of her ribs.

he **second rib** (fig. 285) is about twice the length of the first, but has ilar curvature. The non-articular portion of the *tubercle* is often small.

*See article by Wood Jones, *Anat. Anzeiger*, Bd. xxxvi, 1910.

CC-0. In Public Domain. Gurukul Kangri Collection, Haridwar

Digitized by Arya Samaj Foundation Chennai and eGangotri

The *angle* is slight, and situated close to the tubercle. The *body* is no so that both ends of it touch any plane surface upon which the rib may but at the tubercle there is an upward convexity, similar to, but sma that found in the first rib. The *external surface* of the body is convex, upwards and a little outwards; near its middle is a rough eminenc origin of the lower part of the first and the whole of the second of the Serratus anterior; behind and above this the Scalenus po inserted. The *internal surface*, smooth and concave, is directed do and a little inwards; on its posterior part there is a short costal groo

The **tenth rib** (fig. 286) has only a single articular facet on its head

FIG. 286.—The tenth, eleventh and twelfth ribs. Posterior aspect.

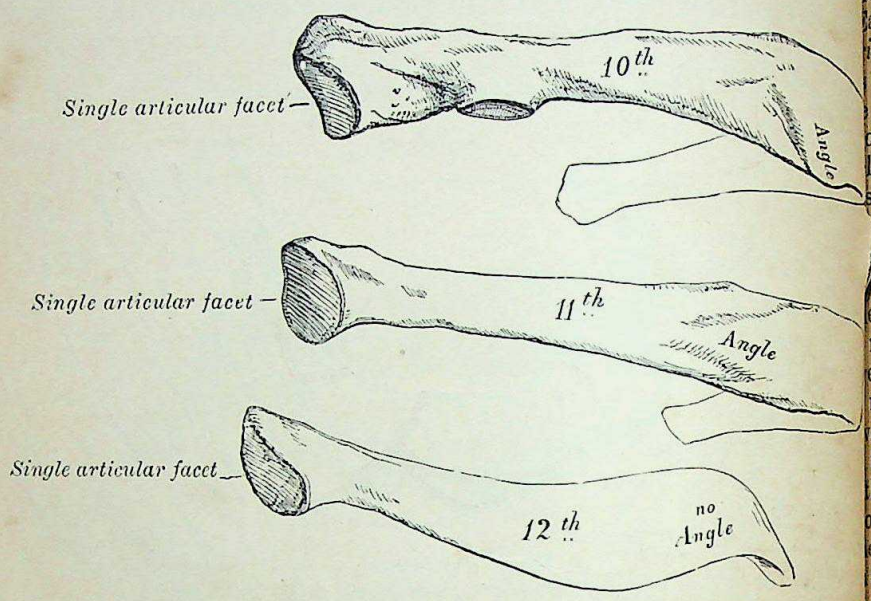

The **eleventh and twelfth ribs** (fig. 286) have each a single facet on the head, which is of rather large size; they have no necks or t and are pointed at their anterior ends. The eleventh has a slight a a shallow costal groove. The twelfth has neither; it is much shor the eleventh, and its vertebral end is directed slightly upwards. S the twelfth rib is shorter than the first.

Structure.—The ribs consist of highly vascular spongy substance en a thin layer of compact bone.

Ossification.—Each rib, with the exception of the first and the last two, is from four centres; a primary centre for the body, and three secondary cen for the head and one each for the articular and non-articular parts of the t The primary centre appears near the angle, towards the end of the secon of fœtal life, and is seen first in the sixth and seventh ribs. The secondar for the head and tubercle appear between the sixteenth and twentiet and unite with the body about the twenty-fifth year. The first rib h centres, viz.: a primary one for the body, a secondary centre for the h one for the tubercle. The eleventh and twelfth ribs, being destitute of t have each only two centres.

THE COSTAL CARTILAGES

The **costal cartilages** (fig. 278) are bars of hyaline cartilage which forwards from the anterior ends of the ribs and contribute very mate the elasticity of the walls of the thorax. The first seven pairs are co

* E. Fawcett states that 'in all probability there is usually no epiphysis on the no part of the tuberosity below the sixth or seventh rib' (*Journal of Anatomy and P* vol. xlv.).

CC-0. In Public Domain. Gurukul Kangri Collection, Haridwar

Digitized by Arya Samaj Foundation Chennai and eGangotri

the sternum; the eighth, ninth, and tenth are each articulated with the r border of the cartilage immediately above; the last two have pointed emities which end in the wall of the abdomen. The costal cartilages vary eir length, breadth, and direction. They increase in length from the first e seventh, then gradually decrease to the twelfth. They diminish in th from the first to the last, and so also do the intervals between them. are broad at their attachments to the ribs, and taper towards their medial emities, with the exception of the first and second which are of the same fth throughout, and the sixth, seventh, and eighth which are enlarged e their margins are in contact. The first cartilage descends a little, the d is horizontal, the third ascends slightly, while the others are angular, wing the course of the ribs for a short distance, and then ascending to the um or preceding cartilage.

ach costal cartilage has two surfaces, two borders, and two ends. The *ior surface* is convex, and looks forwards and upwards: that of the first attachment to the costoclavicular ligament and the Subclavius muscle; of the first six or seven at their medial ends, to the Pectoralis major. others are covered by, and give partial attachment to, some of the flat les of the abdomen. The *posterior surface* is concave, and directed back- s and downwards; that of the first gives attachment to the Sternothyreoi- those of the second to the sixth inclusive to the Transversus thoracis, e six inferior ones to the Transversus abdominis and the Diaphragm. *perior border* is concave, and the *inferior* convex; they afford attachment e Intercostales interni. The inferior borders of the sixth, seventh, eighth, ninth cartilages present heel-like projections at the points of greatest exity; a similar heel-like projection occurs on the lower border of the right cartilage in 72 per cent. and on the fifth left cartilage in 50 per cent. rcett). On these projections are oblong facets which articulate respectively facets on slight projections from the superior borders of the sixth, seventh, h, ninth, and tenth cartilages. The *lateral end* of each cartilage is con- ous with the osseous tissue of the rib to which it belongs. The *medial end* e first is continuous with the sternum: the medial ends of the six succeeding are rounded and articulate with shallow concavities on the lateral margins e sternum. The medial ends of the eighth, ninth, and tenth costal cartilages pointed, and each is connected with the cartilage immediately above. Those e eleventh and twelfth are pointed and free.

n old age the costal cartilages are prone to undergo superficial ossification.

THE THORAX

e skeleton of the **thorax**, or **chest** (fig. 287), is an osseocartilaginous which contains and protects the principal organs of respiration and lation. It is conical in shape, narrow above and broad below, flattened before backwards, and longer behind than in front. It is reniform on ontal section on account of the forward projection of the vertebral es.

Boundaries.—*Posteriorly* it is formed by the twelve thoracic vertebræ the posterior parts of the ribs. On either side of the vertebral column is ep groove in consequence of the lateral and backward direction which ribs take from their vertebral extremities to their angles. *Anteriorly* it is ed by the sternum and costal cartilages, and this surface is flattened or tly convex. *Laterally* it is convex, and is formed by the ribs. The ribs costal cartilages are separated from each other by the intercostal spaces, en in number, which are occupied by the Intercostal muscles and mem- nes.

e *upper opening* of the thorax is reniform in shape; its anteroposterior eter is about 5 cm., its transverse about 10 cm. It slopes downwards forwards, and is bounded by the first thoracic vertebra behind, the superior er of the manubrium sterni in front, and the first rib on either side. The *opening* is bounded by the twelfth thoracic vertebra behind, by the

CC-0. In Public Domain. Gurukul Kangri Collection, Haridwar

Digitized by Arya Samaj Foundation Chennai and eGangotri

eleventh and twelfth ribs at the sides, and in front by the cartilages of the tenth, ninth, eighth, and seventh ribs, which ascend on either side to form an angle, the *subcostal angle*, into the apex of which the xiphoid process projects. The lower opening is wider transversely than from before backwards, and slopes obliquely downwards and backwards; it is closed by the Diaphragm, which forms the floor of the thorax.

FIG. 287.—The skeleton of the thorax. Anterior aspect.

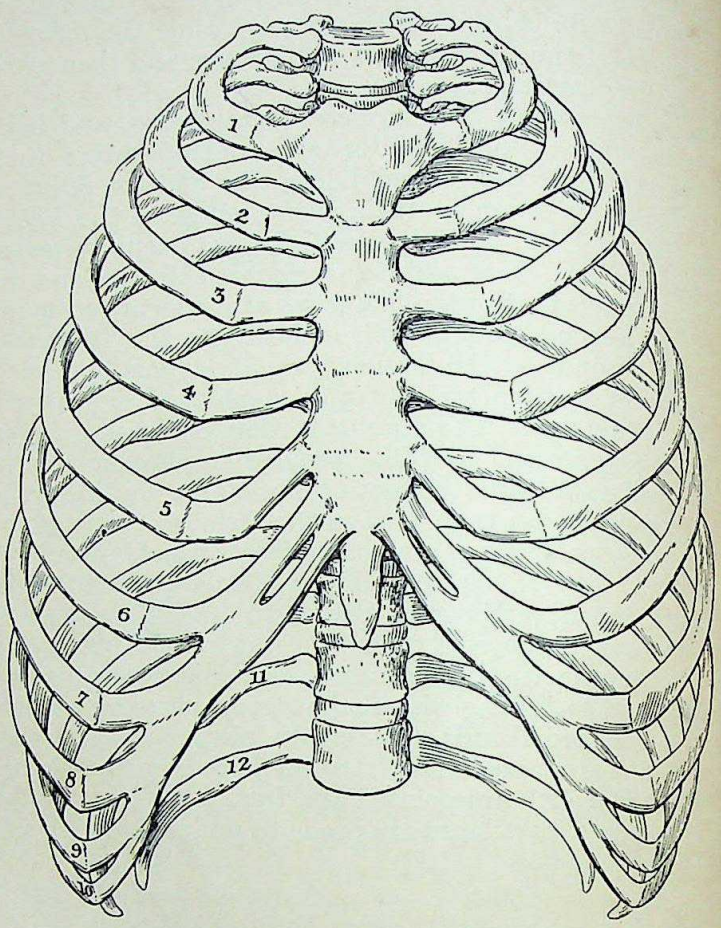

The thorax of the female differs from that of the male as follows: 1. Its capacity is less. 2. The sternum is shorter. 3. The upper margin of the sternum is on a level with the lower part of the body of the third dorsal vertebra, whereas in the male it is on a level with the lower part of the body of the second. 4. The upper ribs are more movable, and so allow a greater expansion of the upper part of the thorax.

Applied Anatomy.—Fracture of the sternum is by no means common, owing, no doubt, to the elasticity of the ribs and their cartilages, which support it like springs. The fracture usually occurs in the upper half of the body. Dislocation of the body from the manubrium may take place, and is sometimes described as a fracture.

The ribs are frequently broken, though from their connexions and shape they are fitted to withstand great force, yielding under the injury and recovering themselves like springs. The middle ribs are the most liable to fracture. The first, and to a less extent the second, being protected by the clavicle, are rarely fractured; and the eleventh and twelfth on account of their loose and floating condition enjoy a like immunity. The injury generally occurs from indirect violence from forcible compression of the chest when the bone then gives way at its weakest part, i.e. just in front of the angle. But the ribs may also be broken by direct violence, in which case the bone is driven inwards at the point struck. Fracture of the ribs is frequently complicated with some injury to the viscera contained within the thorax or upper part of the abdominal cavity; this is more likely to occur in fractures from direct violence.

Fracture of the costal cartilages, or separation of the cartilages from the ribs, is

CC-0. In Public Domain. Gurukul Kangri Collection, Haridwar

Digitized by Arya Samaj Foundation Chennai and eGangotri

e place, though they are compared by injuries. In workmen the pressure of tools y displace the xiphoid process inwards.

The ribs are frequently the seat of tuberculous disease, with the formation of a chronic cess in the chest-wall. This may not immediately overlie the carious portion of rib, as pus is often directed a considerable distance along the costal groove before appearing ath the integument.

Resection of a portion of a rib is often required in order to give efficient drainage to an yema; this is referred to in the description of the respiratory organs.

Cervical ribs derived from the seventh cervical vetebra (page 169) are of not infrequent urrence, and are important clinically because they may give rise to nervous or vascular ptoms. The cervical rib may be a mere epiphysis articulating only with the trans- e process of the vertebra, but more commonly it consists of a defined head, neck and ercle, with or without a body. It extends lateralwards, or forwards and lateralwards, the posterior triangle of the neck, where it may terminate in a free end or may join first thoracic rib, the first costal cartilage, or the sternum.* It varies much in shape, direction, and mobility. If it reach far enough forwards, its relations are similar to e of the first thoracic rib; part of the brachial plexus and the subclavian artery and cross over it, and are apt to suffer compression in so doing. Pressure on the artery obstruct the circulation so much that arterial thrombosis results, causing gangrene he finger-tips. Pressure on the nerves is commoner, and affects the eighth cervical first thoracic nerves, causing paralysis of the muscles they supply, and neuralgic pains, hic changes and paræsthesia in the area of skin to which they are distributed: no lopupillary changes are to be found. If these symptoms be severe, removal of the rib much of it as causes pressure on the vessels and nerves is called for. The operation free from difficulty, and has been followed by paralysis of the muscles and by sub- n aneurysm, due to injuries inflicted in the course of the operation.

The *thorax* is frequently found to be altered in shape in certain diseases.

In *rickets*, the ends of the ribs, where they join the costal cartilages, become enlarged, ing rise to the so-called 'rickety rosary,' which in mild cases is only found on the internal face of the thorax. Lateral to these enlargements the softened ribs sink in, so as to sent a groove passing downwards and lateralwards on either side of the sternum. The s affected are the second to the eighth, the lower ones being prevented from falling in the presence of the liver, stomach, and spleen; and when the abdomen is distended, t often is in rickets, the lower ribs may be pushed outwards, causing a transverse groove arrison's sulcus) just above the costal arch. The sternum is forced forwards by the nding of the ribs, and the anteroposterior diameter of the thorax is increased; this formity, often asymmetrical, is known as *pigeon breast*. In many instances it is associated children with obstruction in the upper air-passages, due to enlarged tonsils or adenoid wths. In some rickety children or adults, and also in others who give no history or ther evidence of having had rickets, an opposite condition obtains. The lower part of sternum and often the xiphoid process as well are deeply depressed backwards, pro- ing an oval hollow in the lower sternal and upper epigastric regions; this is known 'funnel-breast.' The *phthisical chest* is often long and narrow, with great obliquity of ribs and projection of the scapulæ. In *pulmonary emphysema* the chest is enlarged in its diameters, and presents on section an almost circular outline. It has received the me of the 'barrel-shaped chest.' In severe cases of *lateral curvature of the vertebral column* thorax becomes much distorted. In consequence of the rotation of the bodies of the ebræ which takes place in this disease, the ribs opposite the convexity of the dorsal e become extremely convex behind, being thrown out and bulging, and at the same e flattened in front, so that the two ends of the same rib are almost parallel. Coinci- tly with this the ribs on the opposite side, on the concavity of the curve, are sunk and pressed behind, and bulging and convex in front.

More or less shrinkage of one side of the thorax is often seen as a consequence of hesive pleurisy, in which the pulmonary and parietal pleuræ adhere closely to one other and the lung becomes collapsed and fibrosed. If this process be at all complete, eat deformity of the chest results, the ribs on the affected side falling in, together with literation of the intercostal spaces; the contents of the mediastinal cavity are pulled er towards the affected side, and the other lung becomes emphysematous compensa- ily. The vertebral column becomes scoliotic, with the concavity of the curve towards affected side.

THE SKULL

The skull is supported on the top of the vertebral column, and is of an oid shape, wider behind than in front. It is composed of a series of flattened irregular bones which, with the exception of the mandible, are immovably nted together. It is divisible into: (1) the *cranium*, which consists of

* W. Thorburn, *The Med. Chronicle*, Manchester, 4th series, xiv. 1907.

CC-0. In Public Domain. Gurukul Kangri Collection, Haridwar

Digitized by Arya Samaj Foundation Chennai and eGangotri

fifteen bones, and (2) the skeleton of the face, which consists of s follows :

Skull, 22 bones	*Cranium*, 15 bones	Occipital. Sphenoidal. Two Temporals. Two Parietals. Frontal. Ethmoidal. Two Inferior Nasal C Two Lacrimals. Two Nasals. Vomer.
	Face, 7 bones	Two Maxillæ. Two Palatines. Two Zygomatics. Mandible.

The hyoid bone, situated at the root of the tongue and attached to t of the skull by ligaments, is described in this section.

THE CRANIAL BONES (OSSA CRANII)

The Occipital Bone (Os Occipitale)

The **occipital bone** (figs. 288, 289), situated at the posterior and i part of the cranium, is trapezoid in shape and concave forwards. It is by a large oval aperture, the *foramen magnum*, through which the cranial communicates with the vertebral canal. The expanded plate abov behind this foramen is named the *squama* ; the thick, somewhat quadri piece in front of it is called the *basilar part* ; whilst on either side of it *lateral portion.*

The **squama** of the occipital bone, situated above and behind the fo magnum, is curved from above downwards and from side to side.

The *external surface* of the squama is convex and presents midway be the summit of the bone and the foramen magnum a prominence, the e *occipital protuberance.* Extending lateralwards from this on either sid two curved lines, one a little above the other. The upper line, often f marked, is named the *highest nuchal line* (linea nuchæ suprema), and to galea aponeurotica (epicranial aponeurosis) is attached. The lower l termed the *superior nuchal line.* The part of the external surface abo highest nuchal lines is named the *planum occipitale* ; it is smooth, and co with the Occipitalis muscle. The part below the highest nuchal line is te the *planum nuchale*, and is rough and irregular for the attachment of s muscles. From the external occipital protuberance a ridge, the *median line*, often faintly marked, descends to the foramen magnum, and a attachment to the ligamentum nuchæ ; running lateralwards from the m of this line on either side is the *inferior nuchal line.* Several muscles (fig are attached to the outer surface of the squama, thus : the superior n line gives origin to the Occipitalis and Trapezius, and insertion to the S cleidomastoideus and Splenius capitis ; into the surface between the su and inferior nuchal lines the Semispinalis capitis and the Obliquus c superior are inserted ; the inferior nuchal line and the area below it r the insertions of the Recti capitis posteriores major and minor. The po atlanto-occipital membrane is attached around the posterolateral part o foramen magnum, just outside the margin of the foramen.

The *internal surface* of the squama is deeply concave and divided into fossæ by a *cruciate eminence*, one limb of which is in the median sagittal the other transverse. The upper two fossæ are triangular, and lodg posterior parts of the occipital lobes of the cerebrum ; the lower tw quadrilateral and support the hemispheres of the cerebellum. At the

CC-0. In Public Domain. Gurukul Kangri Collection, Haridwar

Digitized by Arya Samaj Foundation Chennai and eGangotri

intersection of the limbs of the cruciate eminence is the *internal occipital tuberance.* The upper division of the sagittal limb of the cruciate eminence s from this protuberance to the superior angle of the bone, and on one side t (generally the right) is a wide groove, the *sagittal sulcus,* which lodges hinder part of the superior sagittal sinus; to the margins of this sulcus the erior part of the falx cerebri is attached. The lower division of the sagittal b of the cruciate eminence is prominent, and is named the *internal occipital* ; it gives attachment to the falx cerebelli, and bifurcates near the foramen gnum; in the attached margin of this falx is the occipital sinus, which is metimes duplicated. At the lower part of the internal occipital crest, a ll depression is sometimes distinguishable; it is termed the *vermian fossa,*

FIG. 288.—The occipital bone. External aspect.

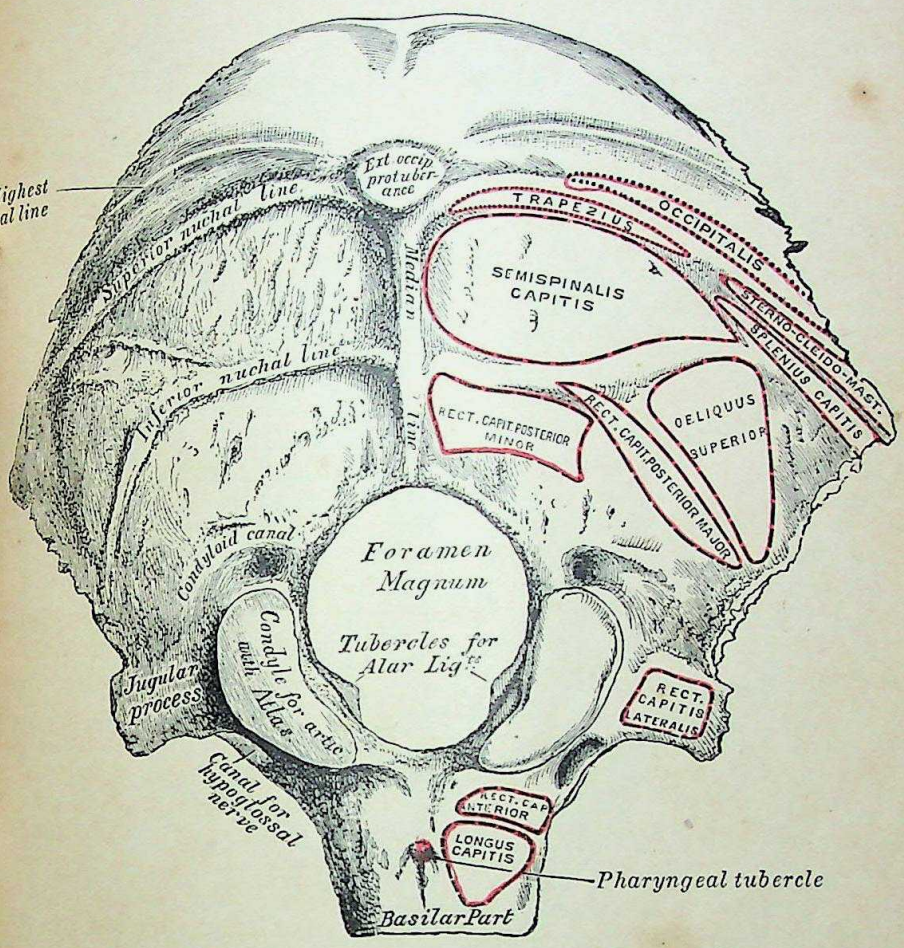

ce it is occupied by part of the vermis of the cerebellum. The right and left ts of the transverse limb of the cruciate eminence are each marked by a nsverse sulcus, which extends lateralwards from the internal occipital pro- berance; these sulci accommodate the transverse sinuses, and their margins e attachment to the tentorium cerebelli. The right transverse sulcus is ually larger than the left, and continuous with the sagittal sulcus; but the may be larger than the right, or the two may be almost equal in size. e angle of union of the superior sagittal and transverse sinuses is named the *fluence of the sinuses* or *torcular Herophili,** and its position is indicated a depression on one or other side of the protuberance.

The *superior angle* of the squama articulates with the occipital angles of parietal bones, and, in the fœtal skull, corresponds in position with the *pital fonticulus* (posterior fontanelle). The *lateral angles* are at the ends he transverse sulci; each is received into the interval between the mastoid gle of the parietal bone and the mastoid part of the temporal bone. The

* The columns of blood coming in different directions were supposed to be pressed together this point (*torcular*, a wine-press).

CC-0. In Public Domain. Gurukul Kangri Collection, Haridwar

Digitized by Arya Samaj Foundation Chennai and eGangotri

lambdoid or superior borders extend from the superior to the lateral
they are serrated for articulation with the occipital borders of the parietal
and form by this union the lambdoid suture. The *mastoid or inferior*
extend from the lateral angles to the jugular processes; each articulat
the mastoid process of the corresponding temporal bone.

The **basilar part** of the occipital bone extends forwards and
from the foramen magnum, and presents *in front* a more or less quad
surface. In the young skull this surface is rough and uneven, and i

FIG. 289.—The occipital bone. Internal aspect.

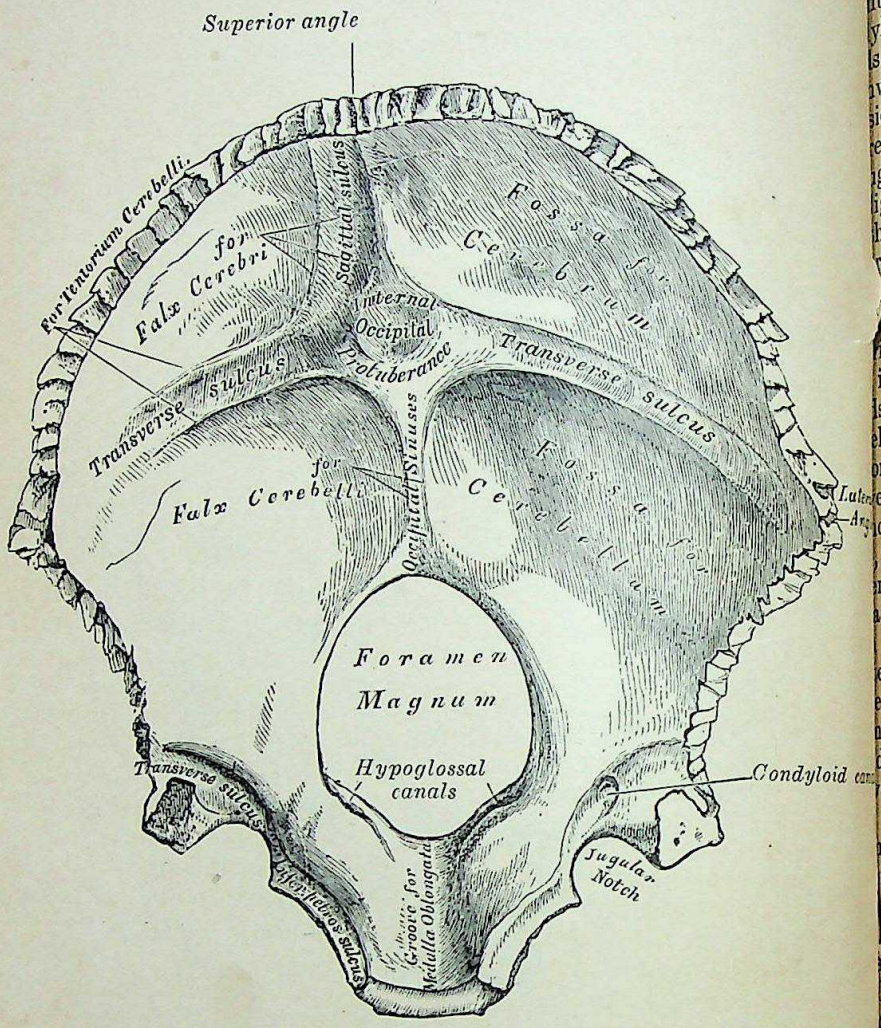

to the body of the sphenoidal bone by a plate of cartilage. By the tw
fifth year this plate of cartilage has undergone ossification, and the occi
and sphenoidal bones are fused.

On the *inferior surface* of the basilar part, about 1 cm. in front of the for
magnum, is the *pharyngeal tubercle* which gives attachment to the fibrous
of the pharynx. On either side of the middle line the Longus capitis
Rectus capitis anterior are inserted, and immediately in front of the for
magnum the anterior atlanto-occipital membrane is attached.

The *superior surface* of the basilar part consists of a broad, shallow gr
which inclines upwards and forwards from the anterior border of the for
magnum; it supports the medulla oblongata and the lower part of the p
and near the margin of the foramen gives attachment to the membrana tec
On the lateral margins of this surface are the *inferior petrosal sulci* for
inferior petrosal sinuses, and below each of these sulci the lateral marg
the basilar part is rough for articulation with the petrous part of the tem
bone.

CC-0. In Public Domain. Gurukul Kangri Collection, Haridwar

Digitized by Arya Samaj Foundation Chennai and eGangotri

The lateral parts of the occipital bone are situated at the sides of the men magnum; on their *inferior surfaces* are two oval processes, the *occipital yles*, for articulation with the superior facets of the atlas or first cervical bra. The condyles are oval or reniform in shape, with their long axes ng forwards and medialwards, so their anterior ends are closer her than their posterior, and oach on the basilar portion of the ; the posterior ends extend back e level of the middle of the foramen num. The articular surfaces of the yles are convex from before back- s and from side to side; they look wards and lateralwards, and are sionally constricted near their es. On the medial side of either is gh impression or tubercle for the igament. Above the anterior part her condyle is the *hypoglossal canal* rior condyloid foramen); this begins on the cranial surface of one a short distance above the ior part of the foramen magnum, is directed lateralwards and for- s. It may be partially or com- ly divided into two by a spicule one; it gives exit to the hypoglossal e, and entrance to a meningeal ch of the ascending pharyngeal artery. Behind either condyle is a depres- the *condyloid fossa*, which receives the posterior margin of the corresponding rior facet of the atlas when the head is bent backwards; the floor of this is sometimes perforated by the *condyloid canal*, through which an emissary passes from the transverse sinus. Extending lateralwards from the erior half of the condyle is the *jugular process*, a quadrilateral plate of e, indented in front by the *jugular notch* which, in the articulated skull, s the posterior part of the jugular foramen. The jugular notch is sometimes ded into two by a bony spicule, the *intrajugular process*, which projects ards and lateralwards. The under surface of the jugular process is rough, gives attachment to the Rectus capitis lateralis; from this surface an ence, the *paramastoid process*, sometimes projects downwards, and may f sufficient length to articulate with the transverse process of the atlas. rally the jugular process presents a rough quadrilateral or triangular which is joined to the jugular surface of the temporal bone by a plate rtilage; after the age of twenty-five this plate tends to ossify.

Fig. 290.—The occipital bone at birth. External aspect.

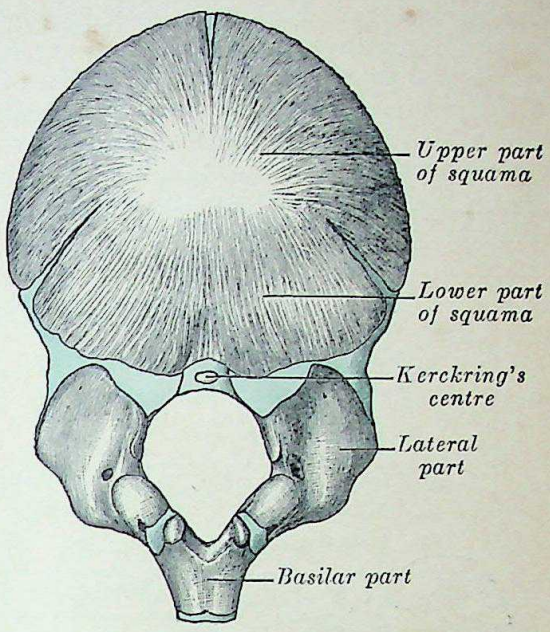

On the *superior surface* of the lateral part is an oval eminence, the *tuberculum lare*, which overlies the hypoglossal canal; behind this tubercle is a shallow ow for the glossopharyngeal, vagus, and accessory nerves. On the superior ace of the jugular process is a deep groove which curves medialwards and ards around an upwardly directed hook-shaped process, and ends at the lar notch. This groove lodges the terminal part of the transverse sinus, close to the medial margin of the groove, the condyloid canal opens.

The *foramen magnum* is a large oval aperture with its long diameter in median sagittal plane. The foramen is wider behind than in front, where it croached upon by the occipital condyles. It transmits the medulla oblon- and its membranes, the spinal portions of the accessory nerves, the vertebral ries, the anterior and posterior spinal arteries, the membrana tectoria, the alar ligaments.

Structure.—The occipital, like the other cranial bones, consists of two compact llæ, called the *outer and inner tables*, between which is the spongy substance *ploë*; the bone is thick at the ridges, protuberances and condyles, and at the rior portion of the basilar part; in the lower parts of the inferior fossæ it is thin, transparent, and destitute of diploë.

Ossification (fig. 290).—The part of the squama above the highest nuchal line

CC-0. In Public Domain. Gurukul Kangri Collection, Haridwar

Digitized by Arya Samaj Foundation Chennai and eGangotri

is developed in membrane, and is ossified from two centres,* one app either side of the middle line about the second month of fœtal life; th the squama may remain separate throughout life, and is then known as *parietal bone.* The rest of the occipital bone is developed in cartilage. T part of the squama is ossified from two centres, which appear about the seve of fœtal life and soon unite to form a single piece. Union of the upper portions of the squama takes place in the third month of fœtal life. An centre appears in the posterior margin of the foramen magnum about the week (Kerckring); it unites with the rest of the squama before birth. the lateral parts ossifies from a single centre which appears during the eig of fœtal life. The basilar portion is ossified from one centre,* which appe the sixth week of fœtal life. About the fourth year the squama unites lateral portions, and about the sixth year the bone consists of a single piece. the eighteenth and twenty-fifth years the occipital and sphenoidal bones unit a single bone.

The Sphenoidal Bone (Os Sphenoidale)

The **sphenoidal body** (figs. 291 to 293) is situated at the base of th in front of the temporal bones and the basilar part of the occipit

Fig. 291.—The sphenoidal bone. Superior aspect.

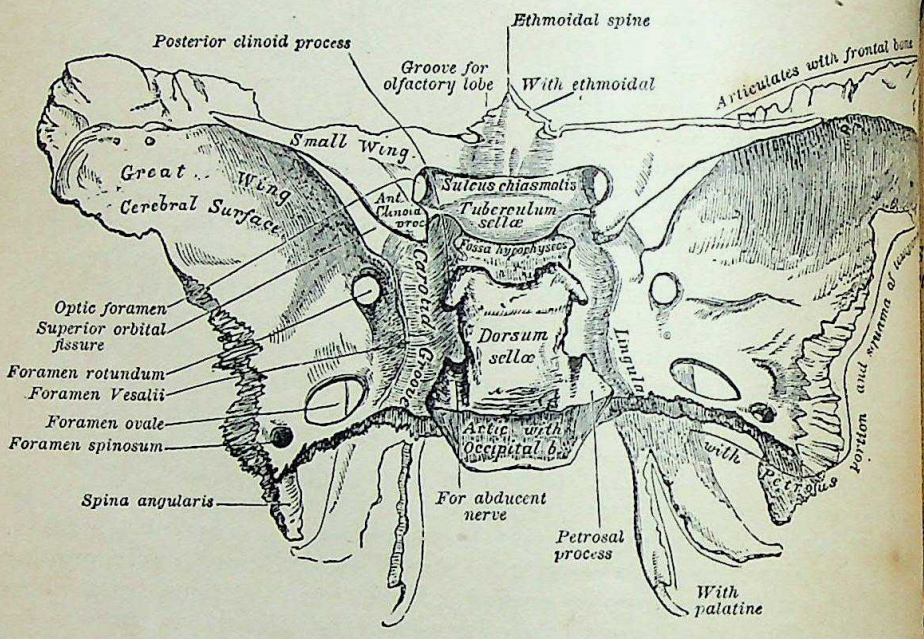

It somewhat resembles a bat with wings extended, and consists of a portion or body, two great and two small wings extending lateralwards fro sides of the body, and two pterygoid processes which are directed down from the adjoining parts of the body and great wings.

The **body** of the sphenoidal bone, more or less cubical in shape, co two large cavities, the *sphenoidal air-sinuses*, separated from each other septum.

The *cerebral or superior surface* of the body (fig. 291) presents in fro *ethmoidal spine*, for articulation with the lamina cribrosa of the eth bone; behind this is a smooth surface, which is faintly grooved on eith of the middle line for the olfactory tracts of the brain. The superior s is bounded behind by a ridge, which forms the anterior border of a tran groove, the *sulcus chiasmatis* (optic groove); this sulcus ends on either s the *optic foramen.* Posterior to the sulcus is a more or less oval elev the *tuberculum sellæ*; and behind this is a deep depression, the *sella t* the deepest part of which lodges the hypophysis cerebri and is known a *fossa hypophyseos.* The anterior boundary of the sella turcica is com

* Mall, *American Journal of Anatomy*, vol. v. 1906.

CC-0. In Public Domain. Gurukul Kangri Collection, Haridwar

Digitized by Arya Samaj Foundation Chennai and eGangotri

erally by two small eminences, called the *middle clinoid processes*, whilst the terior boundary is formed by a square plate of bone, the *dorsum sellæ*; superior angles of this plate end in two tubercles, the *posterior clinoid cesses*, which vary considerably in form and size, and give attachment to lateral borders of the tentorium cerebelli. On either side of the dorsum e is a notch for the passage of the abducent nerve, and below this notch sharp process, the *petrosal process*, which articulates with the apex of the rous portion of the temporal bone. Behind the dorsum sellæ is a shallow pression, which slopes obliquely backwards, and is continuous with the llow groove on the superior surface of the basilar portion of the occipital ne; it supports the upper part of the pons.

The *lateral surfaces* of the body are united with the great wings and with medial pterygoid laminæ. Above the attachment of each wing is a broad ove, the *carotid sulcus*, curved somewhat like the italic letter *f*; it lodges

FIG. 292.—The sphenoidal bone. Posterior aspect.

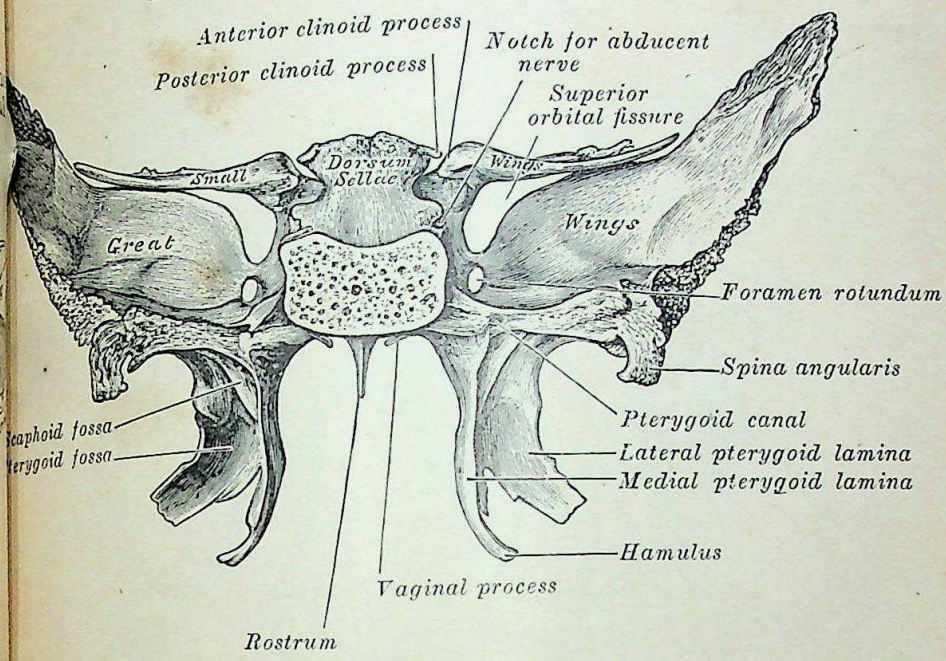

internal carotid artery and the cavernous sinus. The carotid sulcus is pest at its posterior end where it is overhung by the petrosal process, and ted laterally by a sharp margin called the *lingula*; the latter is continued ckwards to overlie the posterior opening of the pterygoid canal.

The *posterior surface* of the body, quadrilateral in form (fig. 292), is joined, ing infancy and adolescence, to the basilar part of the occipital bone by late of cartilage which ossifies between the eighteenth and twenty-fifth years.

The *anterior surface* of the body (fig. 293) presents, in the middle line, a angular crest, the *sphenoidal crest*, which forms a small part of the septum the nose. The anterior border of this crest articulates with the lamina pendicularis of the ethmoidal bone; the lower border, with the vomer. either side of the crest is an opening leading into the corresponding *sphenoidal -sinus*.* The sphenoidal air-sinuses are two large, irregular cavities in body of the bone, separated from one another by a bony septum, which is mmonly bent to one or the other side. They vary considerably in form and e,† are seldom symmetrical, and are often partially subdivided by bony

* It may be stated here that the name 'sinus' is applied to two kinds of spaces associated the skull, viz.: (*a*) 'blood-sinuses' which produce grooves on the inner surfaces of some he bones, and (*b*) 'air-sinuses' which are cavities within some of the bones.

† Logan Turner (*The Accessory Sinuses of the Nose*, 1901) gives the following measurements an adult sphenoidal sinus of average size: height, 2 cm.; breadth, 1·8 cm.; anteroposterior th, 2·1 cm. Onodi (*The Accessory Sinuses of the Nose in Children*, 1911) states that in the -born infant their height is 4 mm. and their width 2 mm., while at the eighth year of life ir height is from 8 to 12 mm., and their width 11 mm.

G.A.

CC-0. In Public Domain. Gurukul Kangri Collection, Haridwar

Digitized by Arya Samaj Foundation Chennai and eGangotri

laminæ. A lateral recess may extend from one or other sinus into th wing and lingula ;* the sinuses occasionally reach into the basilar the occipital bone nearly as far as the foramen magnum. In the art skull they are closed, in front and below, by the *sphenoidal conchæ* only a round opening being left in the anterior wall of each sinus b it communicates with the spheno-ethmoidal recess at the upper and l part of the nasal cavity, and occasionally with the posterior ethmoidal air Each half of the anterior surface of the body of the sphenoidal bone of two parts : (*a*) an upper and lateral depressed area which completes labyrinth of the ethmoidal bone, the posterior ethmoidal air-sinuses ; it margin articulates with the lamina papyracea of the ethmoidal bone and with the orbital process of the palatine bone below ; (*b*) a lower and smooth, triangular area which forms the posterior part of the roof of th near its superior angle is the round orifice leading from the sphenoidal s

FIG. 293.—The sphenoidal bone. Antero-inferior aspect.

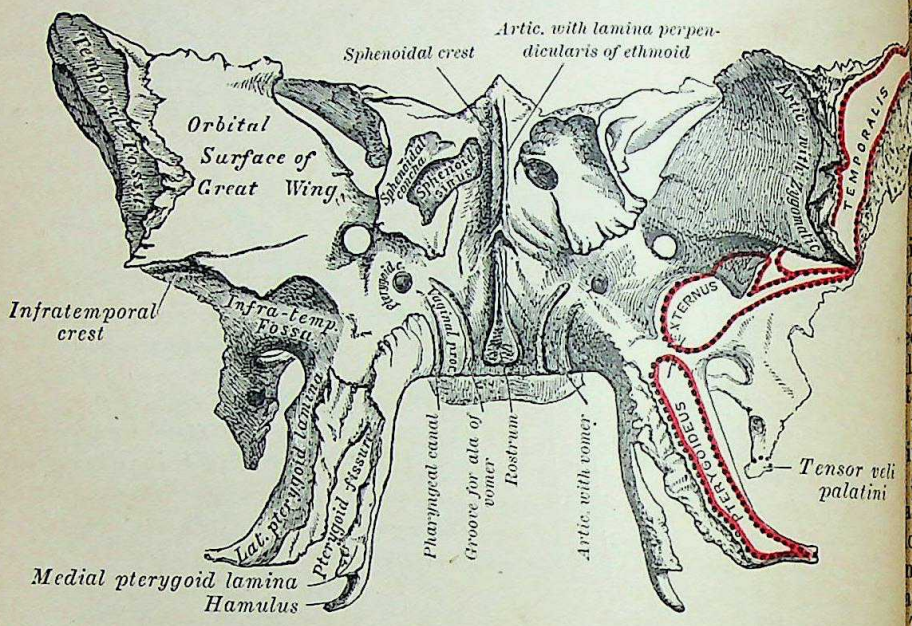

The *inferior surface* of the body (fig. 293) presents, in the middle triangular spine, the *sphenoidal rostrum*, which, in the articulated skull, into a deep fissure between the anterior parts of the alæ of the vomer. posterior, triangular parts of the sphenoidal conchæ extend backwards sides of the rostrum, and articulate with the alæ of the vomer. On eith of the posterior part of the rostrum, and immediately behind the ar the sphenoidal concha, is a projecting lamina, the *vaginal process*, di medialwards from the base of the medial pterygoid lamina, with wh will be described.

The **great wings** (alæ magnæ) of the sphenoidal bone are two stron cesses, which curve upwards and lateralwards from the sides of the body. posterior part of each is triangular and fits into the angle between the p portion and the squama of the temporal bone ; projecting downwards the apex of this triangular portion is a pointed process named the *spina ang* on the medial side of which there is usually a groove, directed downward forwards, for the chorda tympani nerve.† To the spina angularis are att the sphenomandibular ligament and a part of the Tensor veli palatini.

* V. Z. Cope (*Journal of Anatomy and Physiology*, vol. li. part ii.) found a well-marked recess in 72 out of 292 sinuses examined, and pointed out that the hypophysis, the anter of the internal carotid artery, the optic and maxillary nerves, and the nerve of the pt canal may give rise to elevations in the walls of the sinuses.

† R. Clements Lucas, *Proceedings of the Anatomical Society of Great Britain and I* November, 1894.

CC-0. In Public Domain. Gurukul Kangri Collection, Haridwar

Digitized by Arya Samaj Foundation Chennai and eGangotri

The *cerebral or superior surface* of the great wing (fig. 291) forms part of floor of the middle fossa of the skull; it is deeply concave and presents ressions corresponding with the convolutions of the anterior part of the poral lobe of the brain. At its anteromedial part is a circular aperture, *foramen rotundum*, for the passage of the maxillary nerve. Behind and al to this foramen is the *foramen ovale*, for the transmission of the mandi- r nerve, the accessory meningeal artery, and sometimes the lesser superficial osal nerve.* Medial to the foramen ovale, a small aperture, the *foramen alii*, is often seen; when present it opens below at the lateral side of the hoid fossa, and transmits a small vein from the cavernous sinus. In the erior angle, near to but in front of the spina angularis, is a short canal, *foramen spinosum*, which transmits the middle meningeal artery and the rus spinosus.

The *lateral surface* of the great wing (fig. 293) is convex from above down- ds, and is divided by a transverse ridge, the *infratemporal crest*, into an er or temporal and a lower or infratemporal surface. The *temporal surface*, ave from before backwards, forms a portion of the temporal fossa, and s origin to a part of the Temporalis. The *infratemporal surface* is concave directed downwards; it forms a part of the infratemporal fossa, and, ther with the infratemporal crest, gives origin to the upper head of the tgoideus externus. It is pierced by the foramen ovale and foramen um, and at its posterior part is the spina angularis. Medial to the anterior mity of the infratemporal crest is a triangular process which serves to ase the attachment of the Pterygoideus externus. A ridge runs downwards medialwards from this triangular process to the front of the lateral pterygoid ina; it forms the anterior limit of the infratemporal surface, and, in the culated skull, the posterior boundary of the pterygomaxillary fissure.

The *orbital surface* of the great wing (fig. 293), quadrilateral in shape, is cted forwards and medialwards and forms the posterior part of the lateral l of the orbit. Its upper serrated edge articulates with the orbital plate the frontal bone; its lateral serrated margin with the zygomatic bone. inferior smooth border forms the posterolateral boundary of the inferior ital fissure. Its medial sharp margin constitutes the lower boundary of superior orbital fissure; projecting from near the centre of this margin is a ll tubercle which gives an attachment to part of the Rectus lateralis oculi. ow the medial end of the superior orbital fissure is a grooved surface, which ms the posterior wall of the pterygopalatine fossa, and is pierced by the men rotundum.

The margin of the great wing (fig. 291).—The portion of the margin of the at wing which extends from the body to the spina angularis is irregular. medial half forms the anterior boundary of the *foramen lacerum*, and presents posterior aperture of the pterygoid canal for the passage of the corresponding e and artery. Its lateral half articulates, by means of a synchondrosis, the petrous portion of the temporal bone, and between the two bones, he under surface of the skull, is a furrow, the *sulcus tubæ*, for the lodgment he cartilaginous part of the auditory tube. Extending forwards from the a angularis is the *squamosal margin*, a concave, serrated edge, bevelled he expense of the inner surface below, and of the outer surface above, for culation with the temporal squama. The tip of the great wing, or *parietal le*, is bevelled at the expense of the inner surface, and articulates with the enoidal angle of the parietal bone. Medial to this is a triangular rough a, for articulation with the frontal bone; the medial angle of this area is tinuous with the sharp edge which forms the lower boundary of the superior ital fissure, and the anterior angle with the serrated margin for articulation h the zygomatic bone.

The **small wings** (alæ parvæ) of the sphenoidal bone are two triangular tes, which project lateralwards from the upper and anterior parts of the body, end in sharp points (figs. 291, 292). The *cerebral surface* of each is smooth, supports a small part of the frontal lobe of the brain. The *inferior surface* ms the posterior part of the roof of the orbit, and the upper boundary of *superior orbital fissure*; it overhangs the anterior part of the middle fossa

* The lesser superficial petrosal nerve sometimes passes through a special canal (*canaliculus minatus* of Arnold) on the medial side of the foramen spinosum.

CC-0. In Public Domain. Gurukul Kangri Collection, Haridwar

Digitized by Arya Samaj Foundation Chennai and eGangotri

of the skull. The superior orbital fissure is triangular in shape, and l
the cranial cavity into that of the orbit; it is bounded medially by
of the sphenoidal bone; above, by the small wing; below, by the
margin of the orbital surface of the great wing; and is completed
between the great and small wings, by the frontal bone. It transmits
orbital cavity the oculomotor, trochlear, and abducent nerves, the three
of the ophthalmic division of the trigeminal nerve, and some filaments
the cavernous plexus of the sympathetic; and from the orbital ca
recurrent meningeal branch of the lacrimal artery, and the ophthalmic
The *frontal or anterior border* of the small wing is serrated for articulation
the posterior edge of the orbital plate of the frontal bone. The *posterior*
is smooth and projects into the lateral cerebral fissure; the medial end
border forms the *anterior clinoid process* which gives attachment to the
end of the free border of the tentorium cerebelli. The anterior and
clinoid processes are sometimes united by a spicule of bone, and w
occurs the end of the groove for the internal carotid artery is converted
foramen (*caroticoclinoid foramen*). The small wing is connected to th
by two roots, the upper thin and flat, the lower thick and triangular;
these is the *optic foramen*, for the transmission of the optic nerve and oph
artery to the orbital cavity.

The **pterygoid processes** of the sphenoidal bone (figs. 292, 293), on
either side, descend perpendicularly from the regions where the body and
wings unite. Each process consists of a medial and a lateral lamina, the
parts of which are fused anteriorly; a shallow groove, the *pterygo*
sulcus, descends on the front of the line of fusion, and forms, in the arti
skull, the posterior wall of the pterygopalatine canal. The laminæ are se
below by an angular cleft, the *pterygoid fissure*, the rough margins o
articulate with the pyramidal process of the palatine bone. The two
diverge behind, and between them is the wedge-shaped *pterygoid fossa*
contains the Pterygoideus internus and Tensor veli palatini. Abo
fossa is a small, oval, shallow depression, the *scaphoid fossa*, which
origin to part of the Tensor veli palatini. The anterior surface
pterygoid process is broad and triangular near its root, where it
the posterior wall of the pterygopalatine fossa; on it is the anterior orifice
pterygoid canal.

The *lateral lamina* of the pterygoid process is broad, thin, and e
its *lateral surface* forms part of the medial wall of the infratemporal fossa
gives origin to the lower head of the Pterygoideus externus; its *medial*
forms the lateral wall of the pterygoid fossa, and gives origin to the great
of the Pterygoideus internus. The lower part of its *anterior border* arti
with the palatine bone; its *posterior border* is free.

The *medial lamina* of the pterygoid process is narrower and longer th
lateral; its lower extremity curves lateralwards into a hook-like p
the *pterygoid hamulus*, around which the tendon of the Tensor veli p
glides. The *lateral surface* of this lamina forms the medial wall of the pte
fossa, and the Tensor veli palatini lies against it; the *medial surface* cons
the lateral boundary of the choana or posterior aperture of the corresp
nasal cavity. Superiorly the medial lamina is prolonged on to the
surface of the body as a thin plate, named the *vaginal process*, which arti
anteriorly with the sphenoidal process of the palatine bone and mediall
the ala of the vomer. On the under surface of the vaginal process is a
which is converted into a canal by the sphenoidal process of the palatine
this canal transmits the pharyngeal branch of the internal maxillary
and the pharyngeal nerve from the sphenopalatine ganglion. The po
margin of the medial lamina gives attachment in its entire length
pharyngobasilar fascia (pharyngeal aponeurosis), and from the lower one
of this margin the Constrictor pharyngis superior takes origin. At the
end of this margin is a small pyramidal process named the *pterygoid t*
immediately above which is the posterior opening of the pterygoid
Projecting backwards from near the middle of the margin is an angular p
the *processus tubarius*, which supports the pharyngeal end of the au
tube. The anterior margin of the lamina articulates with the posterior
of the vertical part of the palatine bone.

CC-0. In Public Domain. Gurukul Kangri Collection, Haridwar

Digitized by Arya Samaj Foundation Chennai and eGangotri

The sphenoidal conchæ (fig. 293) are two thin, curved plates, situated at anterior and lower parts of the body of the sphenoidal bone; the upper, cave surface of each forms the anterior wall and a part of the floor of corresponding sphenoidal air-sinus. The sphenoidal conchæ are usually e or less destroyed in the process of disarticulating the skull, but when *in situ*, each consists of an anterior, vertical, quadrilateral part and a erior, horizontal, triangular part. The anterior, vertical portion consists (*a*) an upper and lateral, depressed area which completes the posterior noidal air-sinuses and articulates below with the orbital process of the atine bone: and (*b*) a lower and medial area, smooth and triangular, which ms part of the roof of the nasal cavity, and is perforated near its superior le by a round opening through which the sphenoidal air-sinus com- nicates with the spheno-ethmoidal recess of the nasal cavity. The anterior, tical portions of the two bones meet in the middle line, and are protruded rwards as the sphenoidal crest. The horizontal triangular portion of concha forms a part the roof of the nasal ity, and completes the enopalatine foramen; its tial margin articulates the rostrum of the hoidal bone, and with ala of the vomer; its x, directed backwards, medial to and above the inal process of the medial rygoid lamina, and arti- ates with the posterior t of the ala of the vomer.

FIG. 294.—The sphenoidal bone at birth. Posterior aspect.

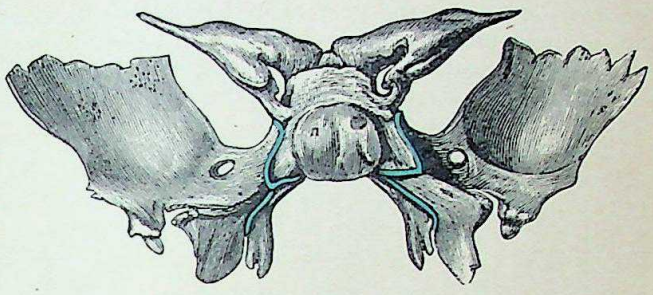

small piece of the sphenoidal concha sometimes appears in the medial wall the orbit, between the lamina papyracea of the ethmoidal bone in front, the bital plate of the palatine bone below, and the frontal bone above.

Ossification.—Until the seventh or eighth month of fœtal life the body of the henoidal bone consists of two parts—viz. one in front of the tuberculum sellæ, e *presphenoidal part*, with which the small wings are continuous; the other mprising the sella turcica and dorsum sellæ, the *postsphenoidal part*, with which e great wings, and pterygoid processes are associated. A considerable part of e bone is ossified in cartilage. There are six centres for the presphenoidal and ht for the postsphenoidal part.

Presphenoidal part. About the ninth week of fœtal life a centre of ossification pears for each of the small wings, just lateral to the optic foramen; shortly rwards two centres appear in the presphenoidal part of the body. The sphenoidal chæ are each developed from a centre which makes its appearance about the h month*; at birth they consist of small triangular laminæ; about the third r they become hollowed out and cone-shaped; about the fourth year they e with the labyrinths of the ethmoidal bone, and between the ninth and twelfth ars with the sphenoidal bone.

Postsphenoidal part.—The first centres of ossification are those for the great ngs. One appears below the foramen rotundum in the cartilage which forms e base of each wing about the eighth week. The following portions of the great ng are ossified in membrane, viz.: the parts surrounding the foramen ovale d foramen spinosum, the orbital plate, and the part found in the temporal fossa.† bout the fourth month, two centres appear in the postsphenoidal part of the dy, one on either side of the sella turcica, and fuse about the middle of fœtal e. Each medial pterygoid lamina (with the exception of its hamulus) is ossified membrane, and its centre probably appears about the ninth or tenth week; e hamulus is chondrified during the third month, and almost at once begins ossify.‡ The medial and lateral pterygoid laminæ join about the sixth month. bout the fourth month a centre appears for each lingula and speedily joins the st of the bone.

* According to Cleland, each sphenoidal concha is ossified from four centres.

† E. Fawcett, *Journal of Anatomy and Physiology*, vol. xliv. 1910.

‡ E. Fawcett, *Anatomischer Anzeiger*, March 1905.

CC-0. In Public Domain. Gurukul Kangri Collection, Haridwar

Digitized by Arya Samaj Foundation Chennai and eGangotri

The presphenoidal and the postsphenoidal parts of the body fuse at eighth month of fœtal life, and at birth the bone is in three pieces (fig. 294): consisting of the body and small wings, and two lateral, each comprising a and pterygoid process. In the first year after birth the great wings and and the small wings extend medialwards above the anterior part of the meet to form an elevated smooth surface, termed the *jugum sphenoidale*. twenty-fifth year the sphenoidal and occipital bones are completely fused. anterior part of the fossa hypophyseos there are occasionally seen the the *canalis craniopharyngeus*, through which, in early fœtal life, the diverticulum of the buccal ectoderm is transmitted (p. 135).

Traces of the sphenoidal air-sinuses are seen as early as the third month life, but they do not attain their full size until after puberty.

Certain parts of the sphenoidal bone are connected by ligaments which ossify. The more important of these ligaments are: the *pterygospinous*, between the spina angularis and the upper part of the lateral pterygoid lamina *colli*); the *interclinoid*, joining the anterior to the posterior clinoid process; *caroticoclinoid*, connecting the anterior to the middle clinoid process.

Applied Anatomy.—Premature ossification or synostosis of the suture between and postsphenoidal parts (which normally begins to join at the eighth month) sphenobasilar suture produces a characteristic physiognomy. This is best seen in and consists in an abnormal depression of the bridge of the nose; it is a featu observed in dwarfs.

Tumours and cysts of the hypophysis are removed by gaining access to the fo physeos, either from below through the nose and the spenoidal air-sinuses, or fro by raising the brain from the anterior fossa of the cranial cavity.

The Temporal Bones (Ossa Temporalia)

The **temporal bones** are situated at the sides and base of the skull. consists of five parts, viz. the *squama*, the *mastoid*, *petrous*, and *tympanic* and the *styloid process*.

The **squama** of the temporal bone forms the anterior and upper parts bone, and is scale-like, thin and translucent. Its *temporal or external* (fig. 295) is smooth and slightly convex; it forms part of the tempora and gives origin to the Temporalis muscle; on its hinder part, abo opening of the external acoustic meatus, is a vertical groove for the temporal artery. A curved line, the *temporal line* or *supramastoid crest*, backwards and upwards, across its posterior part; it serves for the attac of the temporal fascia, and limits the origin of the Temporalis muscle. boundary between the squama and the mastoid portion of the bone lies 1·5 cm. below the temporal line, and is frequently indicated by traces original squamosomastoid suture; the external surface of this lower p the squama is convex, and from its anterior part the Auricularis posterior origin. Between the anterior end of the temporal line and the posterosu sector of the opening of the external acoustic meatus is an angular depre the *suprameatal triangle* of Macewen; through this triangle an instru may be pushed into the tympanic antrum.

Projecting from the lower part of the squama is a long, arched proce *zygomatic process*. The posterior part of this process is triangular in and springs from a broad base; it is directed lateralwards, and its faces are superior and inferior. The process is then twisted inwards runs forwards, and the surfaces of this anterior portion are therefore and lateral. The superior surface of the posterior part is concave continuous with the temporal surface of the squama; the inferior surf bounded by two roots, a *posterior* and an *anterior*, which converge as approach the anterior part of the process. At the meeting point of the roots is a small tubercle for the attachment of the temporomandibular ment. The posterior root is prolonged forwards from the surface of the sq immediately above the opening of the external acoustic meatus; its border is continuous behind with the temporal line. The anterior root almost horizontally from the side of the squama; its inferior surface, from before backwards, is smooth for articulation with the articular disc

CC-0. In Public Domain. Gurukul Kangri Collection, Haridwar

Digitized by Arya Samaj Foundation Chennai and eGangotri

ndibular joint, and the whole root presents the form of a short semi-
indrical bar, termed the *articular tubercle* (eminentia articularis). The
icular tubercle forms the anterior boundary of the mandibular fossa.
The anterior part of the zygomatic process is thin and flat. The superior
der, long and thin, gives attachment to the temporal fascia; the inferior,
t and arched, gives origin to some fibres of the Masseter. The lateral
ace is convex and subcutaneous; the medial is concave, and gives origin
part of the Masseter. The anterior end is deeply serrated and cut obliquely
the expense of the lower border; it articulates with the temporal process of
zygomatic bone. In front of the articular tubercle is a small triangular
which forms a part of the infratemporal fossa, and is separated from the

FIG. 295.—The left temporal bone. External aspect.

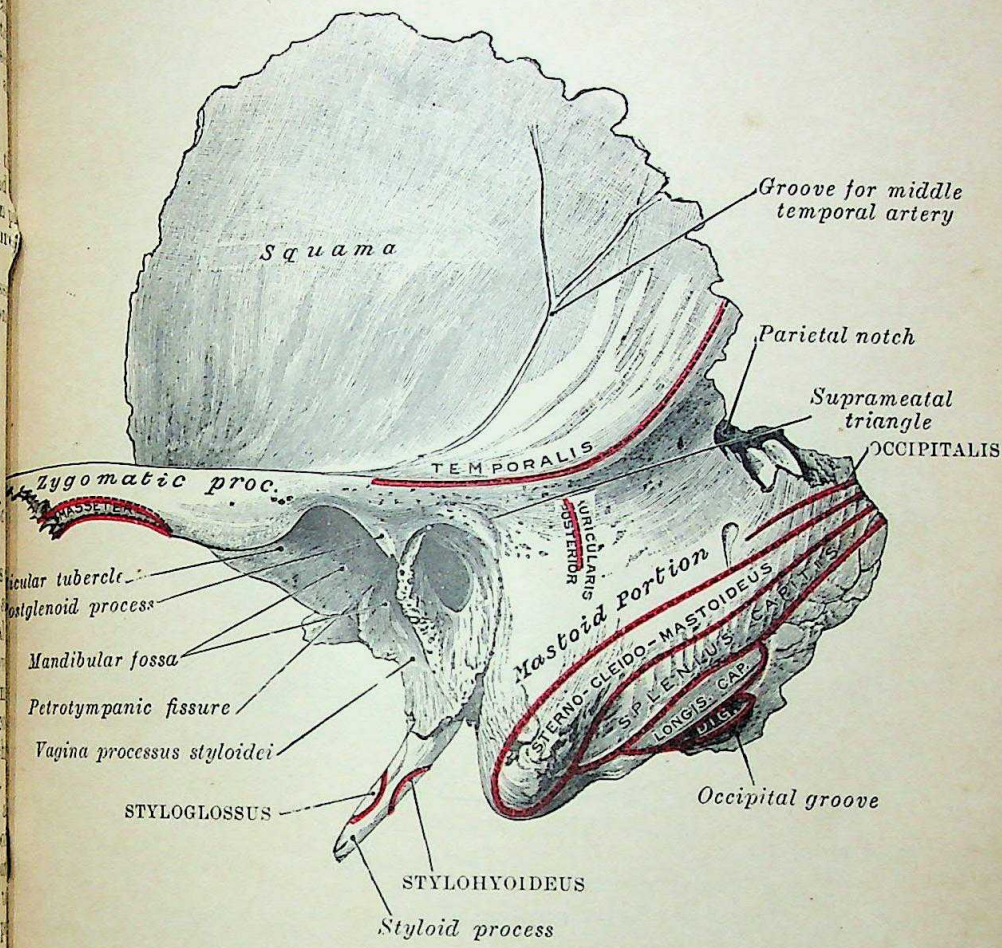

er surface of the squama by a ridge; this ridge is continuous behind with the
erior root of the zygomatic process, and in front, in the articulated skull,
h the infratemporal crest on the great wing of the sphenoidal bone. The
ndibular fossa (glenoid fossa) is bounded in front by the articular tubercle;
consists of an anterior, articular portion, formed by the squama, and a
terior non-articular portion, formed by the tympanic part of the
mporal bone. The articular portion, smooth, oval and deeply concave,
culates with the articular disc of the mandibular joint; the non-articular
tion sometimes lodges a small part of the parotid gland. A small, some-
at conical, eminence, the *postglenoid tubercle*, separates the lateral part
the articular portion from the anterior margin of the tympanic part of the
e, and is the representative of a prominent tubercle which, in some mammals,
ends behind the condyle of the mandible, and prevents its backward
placement; the postglenoid tubercle is sometimes described as the third
of the zygomatic process. The medial part of the articular portion of
mandibular fossa is separated from the tympanic part of the bone by the
er edge of a plate which projects downwards from the tegmen tympani

CC-0. In Public Domain. Gurukul Kangri Collection, Haridwar

Digitized by Arya Samaj Foundation Chennai and eGangotri

of the petrous part of the bone; between this plate and the tympani the *petrotympanic fissure* (Glaserian fissure). This fissure leads into the ear or tympanic cavity; it lodges the anterior process of the malle transmits the anterior tympanic branch of the internal maxillary arter medial end of the fissure is known as the *canal of Huguier*; it trans chorda tympani nerve.

The *cerebral or internal surface* of the squama (fig. 296) is concave; it depressions corresponding to the convolutions of the temporal lobe of th and grooves for the branches of the middle meningeal vessels; its lower is united to the anterior surface of the petrous portion by the *petrosq* suture, traces of which are frequently seen in the adult bone.

FIG. 296.—The left temporal bone. Internal aspect.

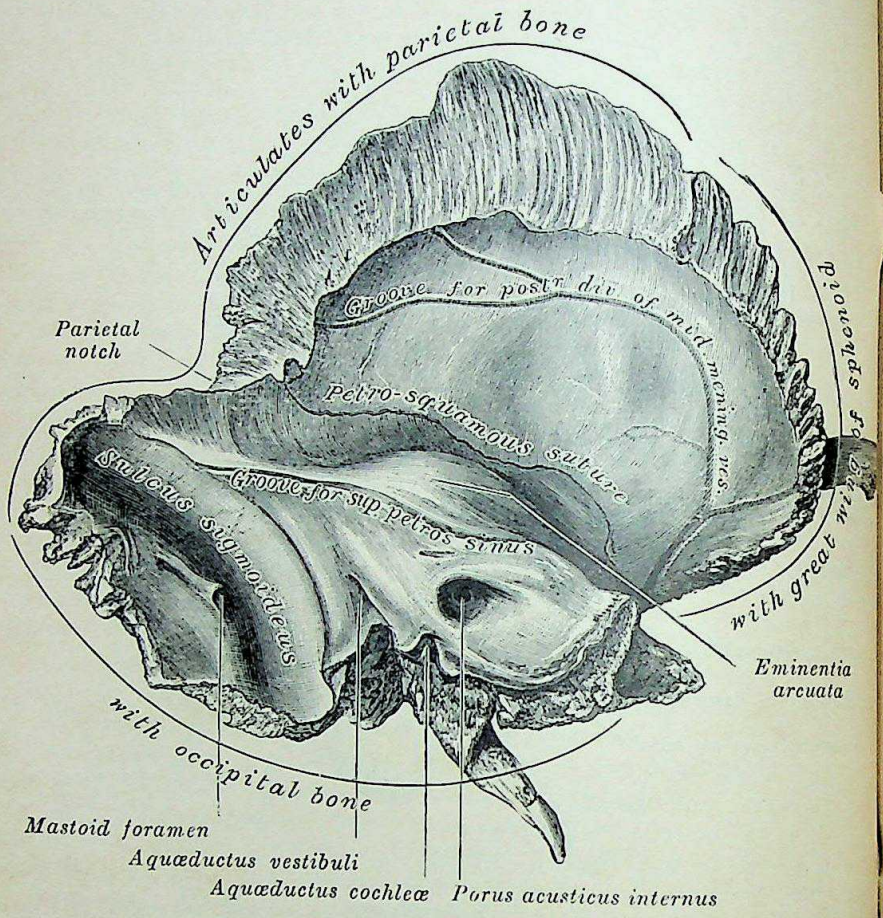

The *parietal or superior border* is thin, bevelled at the expense of the in surface, and overlaps the squamous border of the parietal bone, forming it the squamosal suture. Posteriorly, the superior border forms an the *parietal notch*, with the mastoid portion of the bone. The *sphenoi antero-inferior border*, thin above and thick below, articulates with the wing of the sphenoidal bone; its upper part is bevelled at the expense inner, its lower at the expense of the outer, surface.

The **mastoid portion** of the temporal bone forms the posterior p the bone. Its *outer surface* (fig. 295) is rough, and gives attachment t Occipitalis, and Auricularis posterior. It is frequently perforated near t terior border by the *mastoid foramen* which transmits a vein from the tran sinus, and a small branch of the occipital artery to the dura mater; the p and size of this foramen are very variable; it may be situated in the oc bone, or in the suture between the temporal and the occipital bones. mastoid portion is continued below into a conical projection, the *mastoid p* the size and form of which vary somewhat; it is larger in the male th the female. This process serves for the attachment of the Sterno

CC-0. In Public Domain. Gurukul Kangri Collection, Haridwar

Digitized by Arya Samaj Foundation Chennai and eGangotri

stoideus, Splenius capitis, and Longissimus capitis; on the medial side is a p groove, the *mastoid notch* (digastric fossa), for the attachment of the terior belly of the Digastricus; medial to this notch is a shallow furrow, *occipital groove*, which lodges the occipital artery.

On the *inner surface* of the mastoid portion (fig. 296) there is a deep, ved groove, the *sulcus sigmoideus*, which lodges part of the transverse sinus; this sulcus is the opening of the mastoid foramen. The sulcus sigmoideus is arated from the innermost of the mastoid air-sinuses by a thin lamina of e which may be partly deficient.

The *superior border* of the mastoid portion is thick and serrated for arti- ation with the mastoid angle of the parietal bone. The *posterior border*, o serrated, articulates with the inferior border of the occipital bone between

FIG. 297.—A coronal section through the right temporal bone. Anterior aspect.

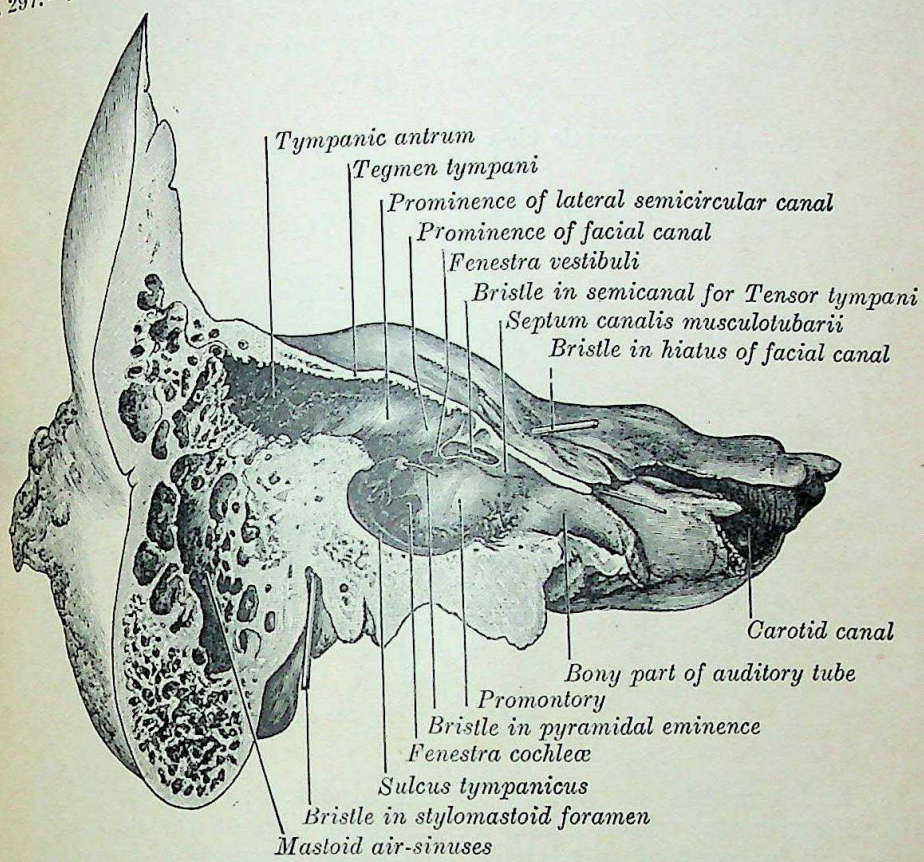

lateral angle and jugular process. Anteriorly the mastoid portion is fused h the descending process of the squama above; below it enters into the mation of the posterior wall of the tympanic cavity.

A section of the mastoid process (fig. 297) exhibits a number of spaces, *mastoid air-sinuses*, which vary greatly in size and number. At the upper d front part of the process they are large and irregular, but towards the er part they diminish in size, while those at the apex of the process are quently quite small; occasionally they are entirely absent, and the mastoid then solid throughout. In addition to the mastoid air-sinuses a large egular air-sinus, the *tympanic antrum* (mastoid antrum) is situated in e upper and front part of the process; it is lined with a prolongation of e mucous membrane of the tympanic cavity. It is bounded above by a thin te of bone, the *tegmen tympani*, which separates it from the middle fossa the base of the skull; laterally by the part of the squama which lies below e supramastoid crest; on its medial wall is the lateral semicircular canal the internal ear. Below and behind, the tympanic antrum communicates h the mastoid air-sinuses; in front it opens into that portion of the mpanic cavity which is known as the *attic* or *epitympanic recess*. The mpanic antrum is a cavity of some considerable size at the time of birth;

CC-0. In Public Domain. Gurukul Kangri Collection, Haridwar

Digitized by Arya Samaj Foundation Chennai and eGangotri

the mastoid air sinuses originate as diverticula from the antrum, a to appear at or before birth; by the fifth year they are of consider but their development is not completed until puberty.

The **petrous portion** or **pyramid** of the temporal bone is wedged the sphenoidal and occipital bones at the base of the skull (figs. 3 It is directed medialwards, forwards, and a little upwards, and has an apex, three surfaces, and three angles (margins). The essential the organs of hearing and equilibrium are placed within it.

The *base* is fused with the squama and the mastoid portion.

The *apex*, rough and uneven, is received into the angular interval the posterior border of the great wing of the sphenoidal bone and the part of the occipital bone; it is pierced by the anterior or internal orifi carotid canal, and forms the posterolateral boundary of the foramen lac

The *anterior surface* forms the posterior part of the middle fossa skull, and is continuous with the inner surface of the squama, to whi united by the *petrosquamosal suture*, remains of which are distinct a late period of life. It is marked by depressions for the convolutions

FIG. 298.—A diagrammatic view of the lateral end of the right internal acou meatus. (Testut.)

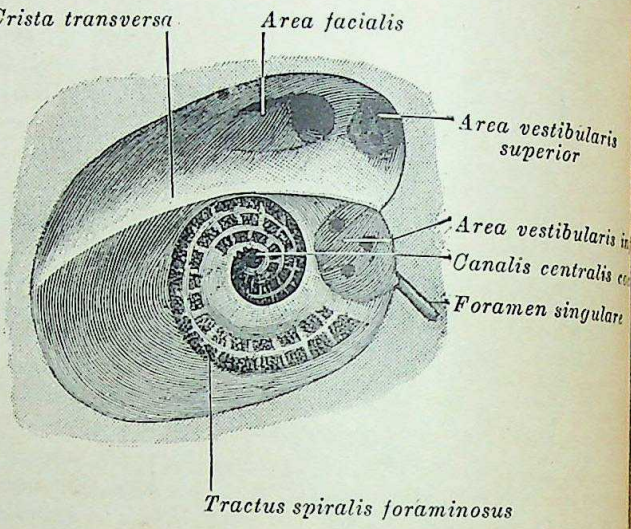

brain, and presents six points for examination: (1) near the centre *eminentia arcuata*, which indicates the situation of the superior semic canal; (2) in front of and lateral to this eminence is a depressed area forms the roof of the tympanic cavity and consists of a thin plate of known as the *tegmen tympani*; a thin scale of this descends betwee squama and the tympanic plate, and forms the anterior boundary of the tympanic fissure, and the greater part of the lateral wall of the sem for the Tensor tympani muscle; (3) a shallow groove, sometimes d leads backwards and lateralwards to an oblique opening, the *hiatus of the canal*, for the passage of the greater superficial petrosal nerve and the p branch of the middle meningeal artery; (4) lateral to the hiatus th occasionally a smaller opening for the passage of the lesser superficial p nerve; (5) near the apex of the bone is the end of the carotid canal, the an wall of which is deficient; (6) above this canal is the shallow *trigeminal imp* for the reception of the semilunar ganglion of the trigeminal nerve.

The *posterior surface* (fig. 296) forms the anterior part of the posterior of the skull, and is continuous with the inner surface of the mastoid p Near the centre of this surface is an orifice of varying size, the *porus ac internus* leading into the *internal acoustic meatus*, a canal, about 1 cm. in le which runs lateralwards. It transmits the facial and acoustic nerves an internal auditory branch of the basilar artery. The lateral end of the int acoustic meatus is separated from the internal ear by a vertical plate, is divided by a horizontal crest, the *crista transversa*, into two unequal pe

CC-0. In Public Domain. Gurukul Kangri Collection, Haridwar

Digitized by Arya Samaj Foundation Chennai and eGangotri

298). Below the posterior part of the crista transversa, and situated e *area vestibularis inferior* are several small openings for the transmission e nerves to the saccule; below and behind this area is the *foramen singulare*, h gives passage to the nerve to the posterior semicircular duct. Below nterior part of the crista transversa is the *tractus spiralis foraminosus*, sting of a number of small spirally arranged openings, which encircle *analis centralis cochleæ*; these openings together with the canalis centralis leæ transmit the nerves to the cochlea. The portion above the crista sversa displays behind, the *area vestibularis superior*, pierced by a series nall openings for the passage of the nerves to the utricle and the superior lateral semicircular ducts, and, in front, the *area facialis*, with one large ing which is the commencement of the *canalis facialis* (aquæductus Fallopii)

FIG. 299.—The left temporal bone. Inferior aspect.

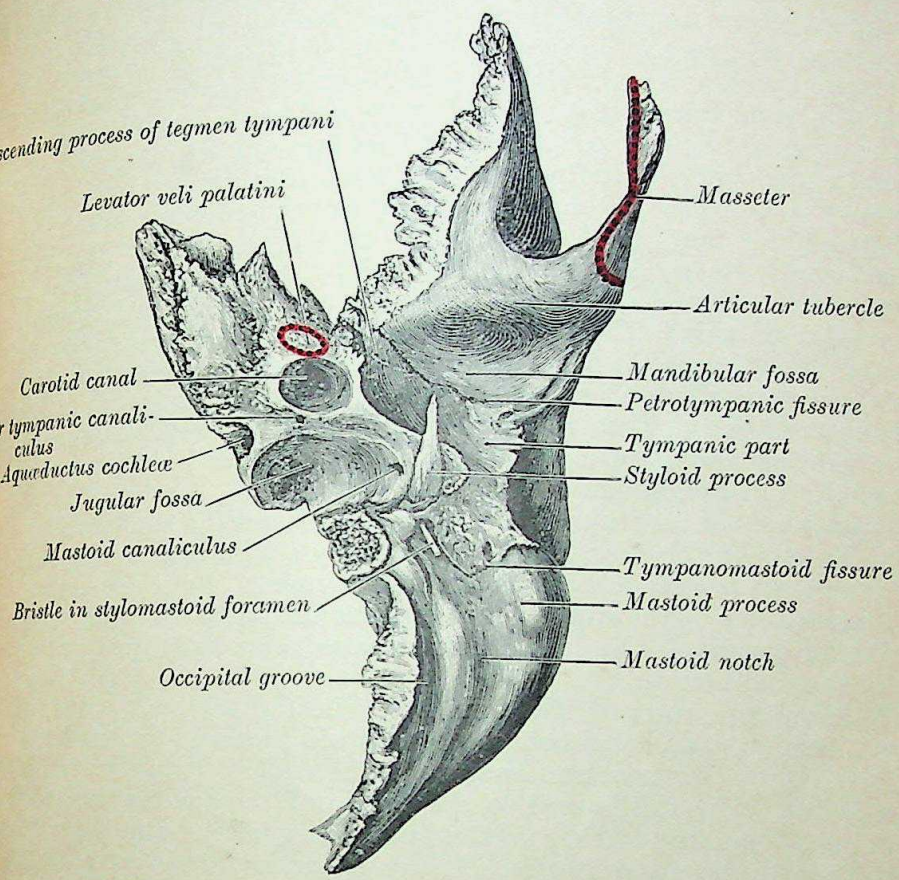

transmits the facial nerve. Behind the porus acusticus internus is a small almost hidden by a thin plate of bone, leading to a canal, the *aquæductus buli*, which contains the ductus endolymphaticus together with a small artery vein. Above and between these two openings is an irregular depression h lodges a process of the dura mater and transmits a small vein; in the infant depression is represented by a large fossa, the *fossa subarcuata*, which extends wards as a short, blind tunnel under the superior semicircular canal.

The *inferior surface* (fig. 299), rough and irregular, forms part of the rnal surface of the base of the skull. It presents the following parts for mination: (1) near the apex is a quadrilateral rough surface, which serves ly for the attachment of the Levator veli palatini and the cartilaginous por- of the auditory tube, and partly for connexion with the basilar part of the pital bone through the intervention of some dense fibrous tissue; (2) behind is a large, nearly circular aperture, the inferior opening of the *carotid canal*; canal runs at first vertically, and then, making a bend, is directed hori- ally forwards and medialwards; it transmits into the cranium the internal tid artery, and the carotid plexus of nerves; (3) behind this opening is a

CC-0. In Public Domain. Gurukul Kangri Collection, Haridwar

Digitized by Arya Samaj Foundation Chennai and eGangotri

deep depression, the *jugular fossa*, of variable depth and size in differe
it lodges the bulb of the internal jugular vein ; (4) in front of the me
of the jugular fossa and directly below the porus acusticus internus is a t
depression ; at the apex of this depression is a small opening, the a
cochleæ, which lodges a tubular prolongation of the dura mater, and t
a vein from the cochlea to join the internal jugular vein ; (5) in the b
dividing the carotid canal from the jugular fossa is the small *inferior*
canaliculus for the passage of the tympanic branch of the glossoph
nerve (nerve of Jacobson) ; (6) in the lateral part of the jugular fo
mastoid canaliculus for the entrance of the auricular branch of the vag
(nerve of Arnold) ; (7) behind the jugular fossa is the *jugular surface*,
quadrilateral area covered with cartilage in the recent state, and art
with the jugular process of the occipital bone ; (8) extending late
from the carotid canal is the sharp lower border of the tympanic pa
bone ; the lateral part of this border splits to ensheath the root of the
process and is therefore named the *vagina processus styloidei* (vaginal p
(9) emerging from its sheath is the *styloid process*, which is about 2·5
length, and is directed downwards and forwards ; (10) between the
and mastoid processes is the *stylomastoid foramen* ; this foramen is the en
facial canal, and transmits the facial nerve and stylomastoid artery.

The *superior angle* (superior margin), the longest, is grooved for the s
petrosal sinus, and gives attachment to the tentorium cerebelli ; at its
extremity is a shallow notch, in which the trigeminal nerve lies. The p
angle (posterior margin) is intermediate in length between the super
the anterior. Its medial part is marked by a sulcus, which forms,
corresponding sulcus on the occipital bone, the channel for the inferior
sinus. Behind this is the *jugular fossa* which, with the jugular notch
occipital bone, forms the jugular foramen ; an eminence occasionally
from the centre of the fossa, and divides the foramen into two. The
angle (anterior margin) is divided into two parts—a lateral, joined to the
at the *petrosquamosal* suture ; a medial, free, for articulation with th
wing of the sphenoidal bone.

At the angle of junction of the petrous part and the squama are tw
placed one above the other, and separated by a thin plate of bone, the
canalis musculotubarii (processus cochleariformis). Both canals lead i
tympanic cavity ; the upper (semicanalis m. tensoris tympani) tr
the Tensor tympani, the lower (semicanalis tubæ auditivæ) forms th
part of the auditory tube.

The **tympanic part** of the temporal bone (fig. 299) is a curved pla
below the squama and in front of the mastoid process. Internally, it
with the petrous portion, and appears in the angle between it and the s
where it lies below and lateral to the orifice of the auditory tube. B
fuses with the squama and the mastoid process, and forms the anterior bo
of the tympanomastoid fissure. Its *posterior surface* is concave, and
the anterior wall, the floor, and a part of the posterior wall of the bony e
acoustic meatus ; at the medial end of this surface is a narrow furr
tympanic sulcus, for the attachment of the circumference of the ty
membrane. Its *anterior surface*, quadrilateral and slightly concave, con
the posterior wall of the mandibular fossa, and is sometimes in conta
a part of the parotid gland. Its *lateral border*, free and rough, forms
part of the margin of the *porus acusticus externus*, and gives attachment
cartilaginous part of the external acoustic meatus, The lateral part
upper border is fused with the back of the postglenoid process ; its med
forms the posterior boundary of the petrotympanic fissure. The *lower b*
sharp ; its lateral part splits to enclose the root of the styloid process
therefore named the vagina processus styloidei (vaginal process). The
portion of the tympanic part of the temporal bone is thin, and in
siderable percentage of skulls is perforated by the *foramen of Huschke*.

The *external acoustic meatus*, about 16 mm. long, is directed inwar
slightly forwards and downwards, and the floor of the meatus is convex up
In sagittal section the meatus is oval or elliptical in shape with the lo
directed downwards and slightly backwards. Its anterior wall and flo
the lower part of its posterior wall are formed by the tympanic part

CC-0. In Public Domain. Gurukul Kangri Collection, Haridwar

Digitized by Arya Samaj Foundation Chennai and eGangotri

e; the roof and the upper part of the posterior wall by the squama. Its r end is closed, in the recent state, by the tympanic membrane; its r end (*porus acusticus externus*) is bounded above by the posterior root he zygomatic process, below which a small spine, the *suprameatal spine*, metimes seen at the upper and posterior part of the orifice.

The styloid process of the temporal bone, slender, pointed, and averaging rt 2·5 cm. in length, projects downwards and forwards, from the under ace of the temporal bone. Its proximal part (tympanohyal) is surrounded by heath (vagina processus styloidei), while its distal part (stylohyal) gives chment to the stylohyoid and stylomandibular ligaments, and to the oglossus, Stylohyoideus and Stylopharyngeus muscles.

Structure.—The structure of the squama is like that of the other cranial bones: mastoid portion is spongy, and the petrous portion dense and hard.

Ossification.—The temporal bone is ossified from eight centres (exclusive of e for the internal ear and the tympanic ossicles)—viz. one each for the squama the tympanic part, four for the petrous and mastoid parts, and two for the

FIG. 300.—The three principal parts of the right temporal bone at birth.

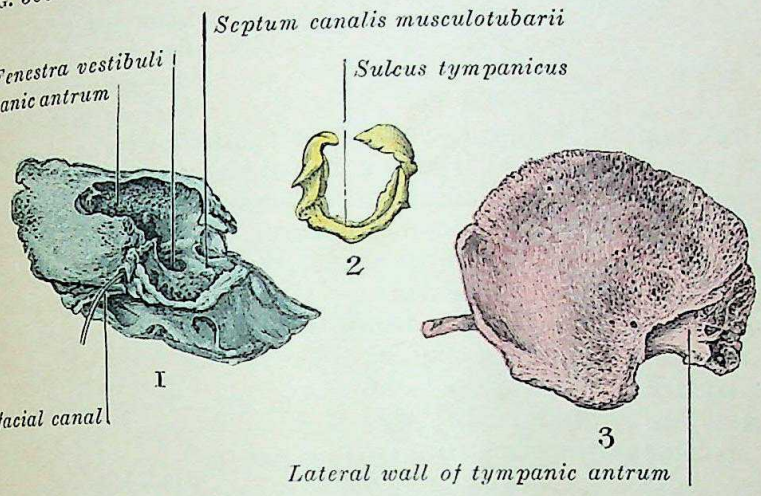

xternal aspect of petromastoid part. 2. Internal aspect of tympanic ring. 3. Internal aspect of squama.

oid process. Just before the close of fœtal life the bone consists of three principal ts, viz.: the squama, the petromastoid part, and the tympanic ring (fig. 300). *squama* is ossified in membrane from a single centre which appears near the of the zygomatic process about the seventh or eighth week of fœtal life. The *mastoid* part is developed from four centres, which make their appearance he cartilaginous ear-capsule (p. 107) about the fifth or sixth month of fœtal life. e (pro-otic) appears in the neighbourhood of the eminentia arcuata, spreads in t of and above the internal acoustic meatus and extends to the apex of the bone; overs part of the cochlea, vestibule, superior semicircular canal, and medial wall he tympanic cavity. A second (opisthotic) appears at the promontory on the dial wall of the tympanic cavity and surrounds the fenestra cochleæ; it forms floor of the tympanic cavity and vestibule, surrounds the carotid canal, invests lateral and lower parts of the cochlea, and spreads medially below the internal ustic meatus. A third (pterotic) roofs in the tympanic cavity and antrum; while fourth (epiotic) appears near the posterior semicircular canal and extends to m the mastoid process (Vrolik). The *tympanic ring* is an incomplete circle concavity of which is grooved by the tympanic sulcus, for the attachment of circumference of the tympanic membrane.* The tympanic ring expands to m the tympanic part of the bone, and is ossified in membrane from a single re which appears about the third month. The *styloid process* is developed m the cranial end of the cartilage of the second branchial or hyoid arch (p. 77)

* Two crests, the *superior and inferior tympanic crests*, run obliquely downwards and forwards ss the anterior part of the inner surface of the tympanic ring. Between them is an obliquely ected furrow, the *sulcus malleolaris*, which lodges the anterior process of the malleus, the erior tympanic artery and the chorda tympani nerve.

CC-0. In Public Domain. Gurukul Kangri Collection, Haridwar

Digitized by Arya Samaj Foundation Chennai and eGangotri

by two centres: one for the proximal part of the process, the tympanohyal before birth; the other, for the distal part of the process, the stylohyal, appear until aft The tympanic rin with the squama before birth; the mastoid part a squama join dur first year, and th panohyal portion styloid process al same time (figs. 3 The stylohyal do unite with the res bone until after and in some skull at all.

Fig. 301.—The temporal bone at birth. External aspect.

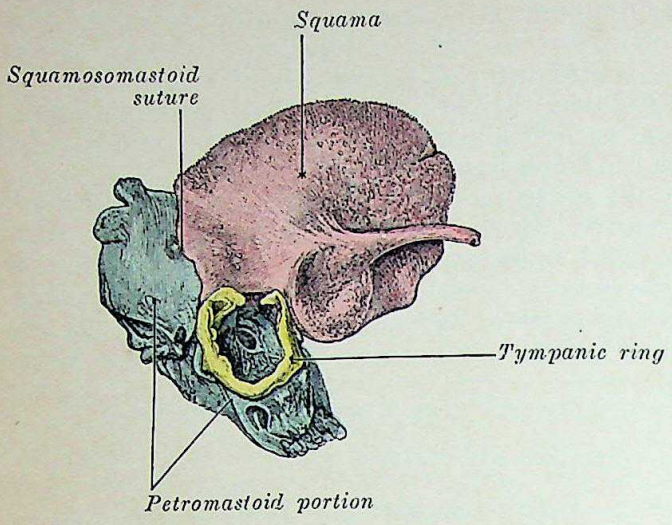

The chief sub changes in the te bone apart from inc size are: (1) The tym ring grows lateralward backwards to form th panic part of the bone. This extension does not, however, take place at a rate all round the circumference of the ring, but occurs most rapidly on its a and posterior portions, and these outgrowths meet and blend, and thus, for there exists in the floor of the meatus a foramen, the *foramen of Huschk* foramen is usually closed about the fifth year, but may persist througho (2) The mandibular fossa is at first extremely shallow, and looks more later than downwards; it becomes deeper and is ultimately directed downward change in direction is accounted for as follows. The part of the squama which forms the fossa lies at first below the level of the zygomatic process and is nearly vertical, but in consequence of the subsequent increase in the width of the base of the skull this part of the squama comes to be directed horizontally inwards, and its surfaces therefore upwards and downwards; the attached portion of the zygomatic process also becomes everted and projects like a shelf at right angles to the squama. (3) The mastoid portion is at first flat, and the stylomastoid foramen and rudimentary styloid process lie immediately behind the tympanic ring. With the development of the mastoid air-sinuses the lateral part of the mastoid portion grows downwards and forwards to form the mastoid process, and the styloid process and stylomastoid foramen come to lie on the under surface of the bone. The descent of the stylomastoid foramen is nece accompanied by a corresponding increase in the length of the canal for the nerve. (4) The downward and forward growth of the mastoid process also forward the tympanic part of the bone, so that the portion of the latter which the original floor of the external acoustic meatus and contained the fora Huschke ultimately constitutes the anterior wall of the meatus. (5) The subarcuata on the posterior surface of the petrous portion is gradually fill almost obliterated.

Fig. 302.—The temporal bone Internal aspect.

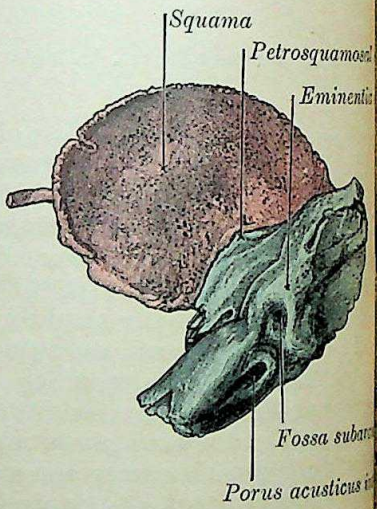

Applied Anatomy.—The external acoustic meatus is relatively as long in the in the adult, but in the child the canal is cartilaginous, whereas in the adult th

CC-0. In Public Domain. Gurukul Kangri Collection, Haridwar

Digitized by Arya Samaj Foundation Chennai and eGangotri

thirds of it are osseous. When it is necessary to open the tympanum for suppuration, approached through the tympanic antrum. In the child only a thin scale of bone es to be removed from the suprameatal triangle to open into the tympanic antrum.

The Parietal Bones (Ossa Parietalia)

The **parietal bones** form, by their union, the sides and the roof of the um. Each bone is irregularly quadrilateral in shape, and has two surfaces, borders, and four angles.

Fig. 303.—The left parietal bone. External aspect.

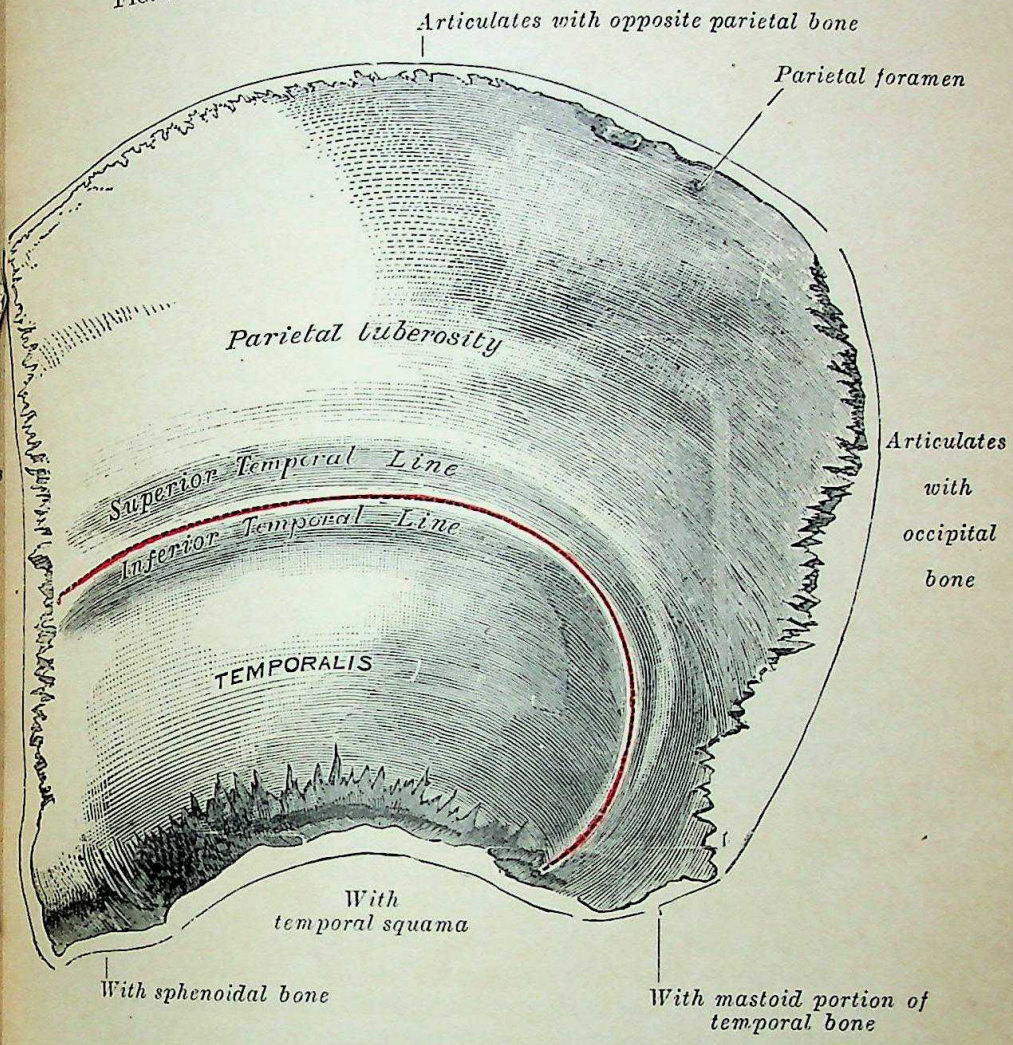

The *parietal* or *external surface* (fig. 303) is convex, smooth, and marked the centre by an eminence, the *parietal tuberosity or eminence.* Crossing middle of the bone in an arched direction are two curved lines, the *superior inferior temporal lines*; the former gives attachment to the temporal a, and the latter indicates the upper limit of the origin of the Temporalis. part of the bone above these lines is covered, in the recent condition, with galea aponeurotica; that below the lines forms a part of the temporal . At the posterior part and close to the upper or sagittal border is the *etal foramen*, which transmits a vein from the superior sagittal sinus, and times a small branch of the occipital artery; the foramen is not constantly nt, and its size varies considerably.

The *cerebral or internal surface* (fig. 304) is concave; it presents depressions sponding to the cerebral convolutions, and numerous furrows for the fications of the middle meningeal vessels *; these furrows run upwards

* Consult articles by F. Wood Jones, *Journal of Anatomy and Physiology*, vol. xlvi., and en, *Journal of Anatomy and Physiology*, vol. xlviii.

CC-0. In Public Domain. Gurukul Kangri Collection, Haridwar

Digitized by Arya Samaj Foundation Chennai and eGangotri

and backwards from the sphenoidal angle, and from the central and part of the squamous border. Along the upper or sagittal border is groove, which, with that on the opposite parietal bone, forms the *sagi* for the superior sagittal sinus; to the edges of this sulcus the falx attached. Near the sulcus are several depressions, best marked in of old persons, for the arachnoideal granulations (glandulæ Pacchioni

The *sagittal border*, the longest and thickest, is dentated; it with the corresponding border of the opposite parietal bone, to form t suture. The *squamous border* is divided into three parts: of these, the short, thin and pointed, is bevelled at the expense of the external sur

Fig. 304.—The left parietal bone. Internal aspect.

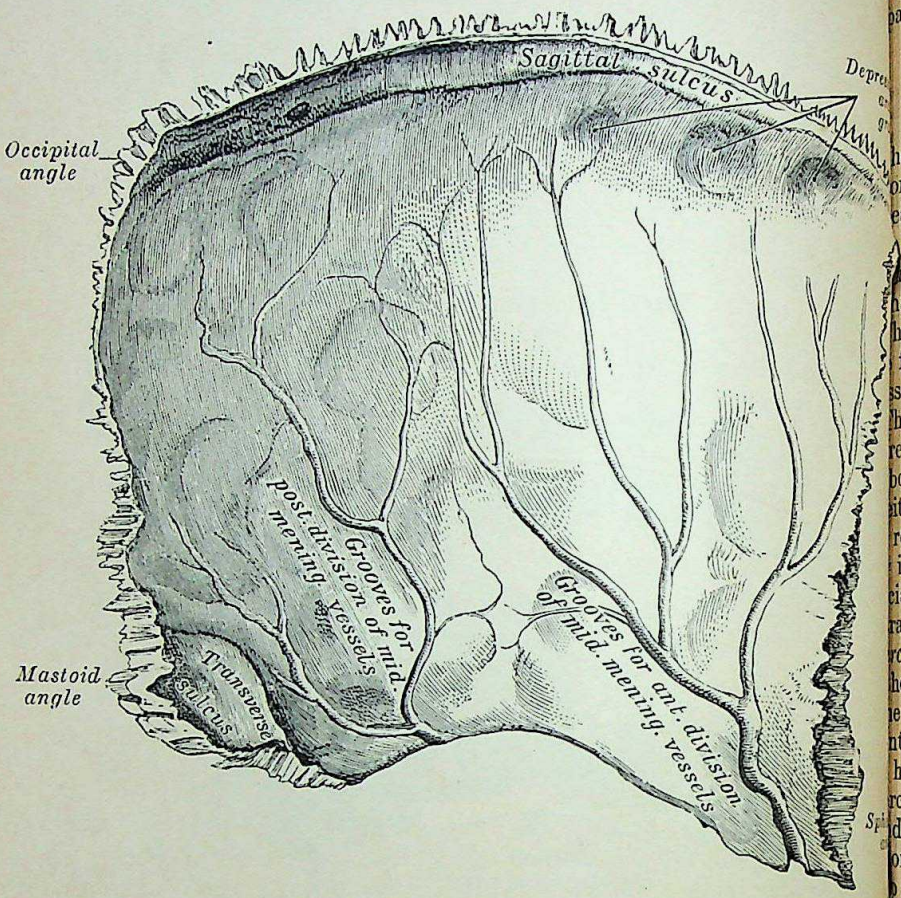

overlapped by the tip of the great wing of the sphenoidal bone; the portion is arched, bevelled at the expense of the external surface, and ove by the squama of the temporal bone; the posterior part, short, th serrated, articulates with the mastoid portion of the temporal bon *frontal border* is deeply serrated, and bevelled at the expense of the surface above and of the internal below; it articulates with the front forming one-half of the coronal suture. The *occipital border*, deeply d articulates with the occipital bone, forming one-half of the lambdoid s

The *frontal angle* is almost a right angle, and corresponds with the or point of meeting of the sagittal and coronal sutures. The *sphenoid* thin and acute, is received into the interval between the frontal bone great wing of the sphenoidal bone. Its internal surface is marked b groove, sometimes a canal, for the anterior divisions of the middle m vessels. In some skulls the frontal bone articulates with the squam temporal bone, and the parietal bone then fails to reach the great the sphenoidal bone. The *occipital angle* is rounded and corresponds *lambda* or point of meeting of the sagittal and lambdoid sutures. The *angle* is blunt, and articulates with the occipital bone and with the portion of the temporal bone, the meeting point of the three bones being

CC-0. In Public Domain. Gurukul Kangri Collection, Haridwar

Digitized by Arya Samaj Foundation Chennai and eGangotri

asterion. On the internal surface of this angle is a broad, shallow groove h lodges a small part of the transverse sinus.

t birth there are unossified or membranous intervals in the skull at the s of the parietal bones; they are named fonticuli (fontanelles) and are ribed on pp. 267, 268.

ssification.—The parietal bone is ossified in membrane from two centres, n appear one above the other at the parietal tuberosity about the seventh of fœtal life. These centres unite early, and ossification gradually extends radial manner towards the margins of the bone; the angles are consequently parts last formed, and it is here that the fonticuli are found. At birth the oral lines are situated low down; they only reach their permanent position the eruption of the molar teeth. Occasionally the parietal bone is divided into parts, upper and lower, by an anteroposterior suture.

The Frontal Bone (Os Frontale)

he **frontal bone** resembles a cockle-shell in form, and consists of two ons—a vertical part, the *squama*, corresponding with the region of the ead; and a horizontal or *orbital part*, which enters into the formation roofs of the orbital and nasal cavities.

e **squama** of the frontal bone has two surfaces, an external and an nal.

he *external surface* of the squama (fig. 305) is convex and divided into a frontal and two small temporal surfaces by lines which arch backwards s the lateral parts of the bone.

he *frontal surface* usually exhibits, in the lower part of the middle line, remains of the *frontal or metopic suture*; in infancy this suture divides bone into two, a condition which persists in about 9 per cent. of skulls. ither side of the middle line, about 3 cm. above the supra-orbital margin, rounded elevation, the *frontal tuberosity or eminence.* These tuberosities in size in different individuals, are occasionally unsymmetrical, and are cially prominent in young skulls. Below the frontal tuberosities, and rated from them by a shallow groove, are two curved elevations, the *rciliary arches*, the medial parts of which are prominent, and joined to one her by a smooth elevation named the *glabella.* These arches are larger e male than in the female, and their degree of prominence depends to some nt on the size of the frontal air-sinuses; prominent superciliary arches however, occasionally associated with small air-sinuses. Beneath the rciliary arches are the curved *supra-orbital margins*, which form the upper daries of the bases of the orbits, and separate the squama from the orbital on of the bone. The lateral two-thirds of each supra-orbital margin is p; the medial one-third is rounded. At the junction of these two parts is *upra-orbital notch or foramen* which transmits the supra-orbital vessels and e. Medial to this notch, and present in about 50 per cent. of skulls, is small *frontal notch or foramen.* The supra-orbital margin ends laterally e *zygomatic process*, which is strong and prominent, and articulates with zygomatic bone. Curving upwards and backwards from this process is a which soon divides into the *superior and inferior temporal lines.*

he portion of the squama which projects downwards between the supra- al margins is named the *nasal part.* It presents an uneven interval, the *l notch*, which articulates on either side of the middle line with the nasal , and lateral to this with the frontal process of the maxilla and with the mal bone. From the centre of the notch the *nasal process* projects down- ds and forwards beneath the nasal bones and frontal processes of the maxillæ, supports the bridge of the nose. The nasal process ends below in a sharp *al spine*, and on either side of this is a small grooved surface which forms a of the roof of the corresponding nasal cavity. The frontal spine forms t of the septum of the nose; in front it articulates with the crest of the nasal s, behind with the lamina perpendicularis of the ethmoidal bone (fig. 322). he *temporal surface*, below and behind the temporal lines, forms the anterior of the temporal fossa, and gives origin to a part of the Temporalis le.

CC-0. In Public Domain. Gurukul Kangri Collection, Haridwar

Digitized by Arya Samaj Foundation Chennai and eGangotri

The *cerebral or internal surface* (fig. 306) of the squama is concave; upper part of the middle line is a vertical groove, the *sagittal sulcus*, t of which unite below to form the *frontal crest*; the sulcus lodges the part of the superior sagittal sinus, while to its margins and to the fro the anterior part of the falx cerebri is attached. The crest ends below in notch which is converted into the *foramen cæcum* by articulation ethmoidal bone. The foramen cæcum varies in size in different skull often pervious; when this is so, it transmits a vein from the nose to the sagittal sinus. On either side of the middle line are depressions

Fig. 305.—The frontal bone. External aspect.

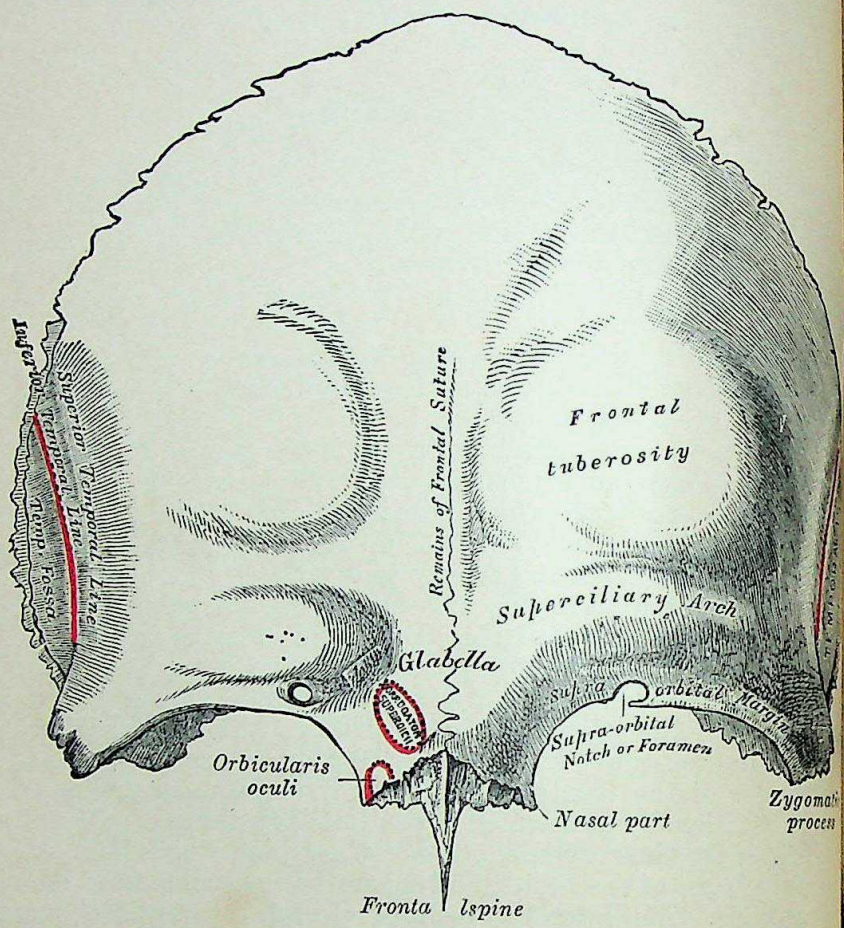

convolutions of the brain, and minute furrows for the anterior bran the middle meningeal vessels. Several small, irregular fossæ may b on either side of the sagittal sulcus, for the reception of arach granulations.

The *border of the squama* is thick, strongly serrated, bevelled expense of the cerebral surface above, where it rests upon the parietal and at the expense of the temporal surface on either side, where it the lateral pressure of the parietal bones; it is continued below triangular, rough surface, for articulation with the great wing of the sp bone.

The **orbital part** of the frontal bone consists of two thin triangular *plates*, which form the vaults of the orbits, and are separated from one by a wide gap, the *ethmoidal notch*.

The *orbital surface* (fig. 306) of each orbital plate is smooth and conc presents, laterally, under cover of the zygomatic process, a shallow dep the *lacrimal fossa*, for the lacrimal gland; below and behind the med of the supra-orbital margin, about midway between the supra-orbital and the frontolacrimal suture, is a small depression or spine, the *fovea t trochlearis*, for the attachment of the fibrocartilaginous pulley of the O oculi superior. The *cerebral surface* is convex and marked by dep

CC-0. In Public Domain. Gurukul Kangri Collection, Haridwar

Digitized by Arya Samaj Foundation Chennai and eGangotri

ponding to the convolutions on the inferior surface of the frontal lobe brain, and by faint grooves for the meningeal branches of the ethmoidal s.

e *ethmoidal notch* (incisura ethmoidalis) (fig. 306) separates the two orbital ; it is quadrilateral, and filled, in the articulated skull, by the lamina a of the ethmoidal bone. On the margins of the notch are portions eral air-sinuses which complete the ethmoidal air-sinuses when the idal bone is in position. Two transverse grooves cross each margin of the ; they are converted into the *anterior and posterior ethmoidal canals* by

Fig. 306.—The frontal bone. Internal and inferior aspects.

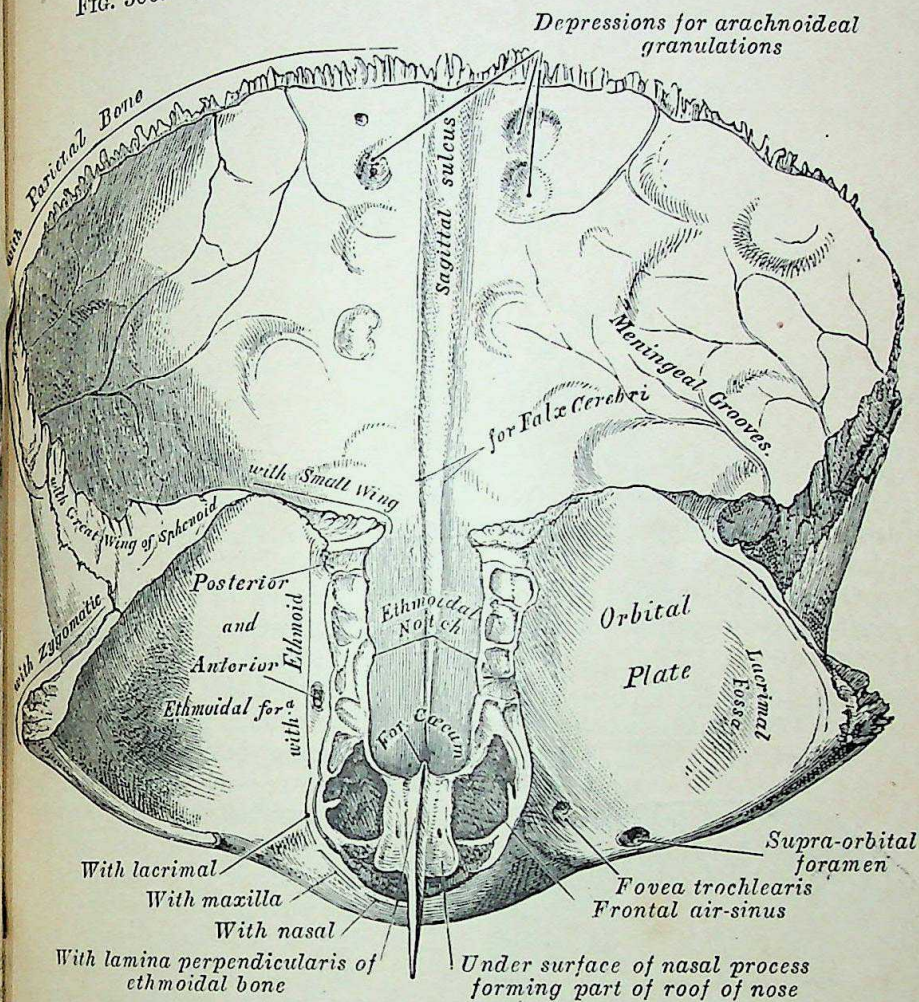

thmoidal bone, and open on the medial wall of the orbit ; they transmit nterior and posterior ethmoidal nerves and vessels.

front of the ethmoidal notch, and lateral to the frontal spine, are the ngs of the *frontal air-sinuses* (fig. 307). These air-sinuses are two irregular ies, which extend backwards, upwards, and lateralwards for a variable nce between the tables of the frontal bone ; they are separated from one her by a thin bony septum, which is often deflected to one or other side of median plane, with the result that the sinuses are seldom symmetrical. mentary at birth, the frontal air-sinuses are usually fairly well-developed een the seventh and eighth years, but only reach their full size after rty. They vary in size in different persons, and are larger in men than men.* Occasionally they extend backwards in the roofs of the orbit

ogan Turner (*op. cit.*) gives the following measurements for an adult sinus of average size : 3·16 cm. ; breadth, 2·58 cm. ; depth from before backwards, 1·8 cm. Onodi (*op. cit.*) that in infants of from one to twelve months the height of the frontal sinus varies from m. to 8 mm., and its width from 2 mm. to 6 mm., and that in the eighth year of life the is from 14 mm. to 17 mm., and the width from 7 mm. to 9 mm.

CC-0. In Public Domain. Gurukul Kangri Collection, Haridwar

Digitized by Arya Samaj Foundation Chennai and eGangotri

cavities as far as the optic foramen. Each communicates with the meatus of the corresponding nasal cavity by means of a passage, the *frontonasal duct.*

FIG. 307.—Frontal air-sinuses. Anterior aspect. The left sinus is larger than the right and the septum between them is obliquely placed.

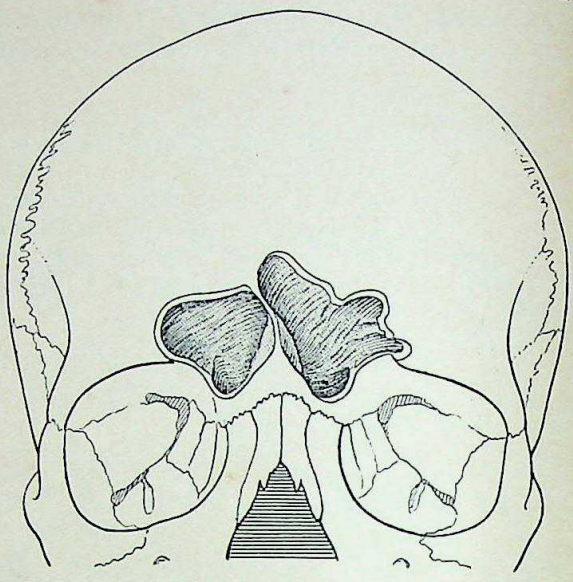

The *posterior borders of the orbital plates* are thin and serrated, and articulate with the small wings of the sphenoidal bone; the lateral part of each appears in the middle fossa of the skull between the great and small wings of the sphenoidal bone.

Structure.—The squama and the zygomatic process of the frontal bone are thick and consist of spongy substance contained between two compact laminæ; the spongy substance is absent in the parts occupied by the frontal air-sinuses. The orbital part, composed entirely of compact bone, is thin and translucent in its posterior two-thirds.

FIG. 308.—The frontal bone at birth. External aspect.

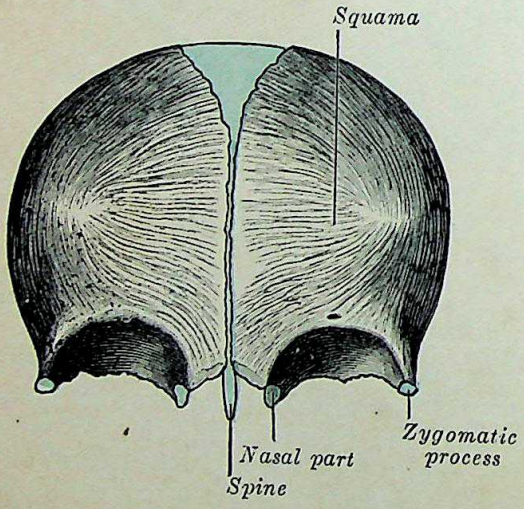

Ossification.—(fig. 308) The frontal bone is ossified in membrane from two primary centres which appear about the seventh or eighth week of fœtal life, one above each superciliary margin. From each of these centres ossification extends upwards into the corresponding half of the frontal bone and backwards to form the orbital plate. The frontal spine is ossified from two secondary centres, one on either side of the middle line. These secondary centres also appear in the orbital parts and zygomatic processes. At birth the bone consists of two halves separated by the frontal suture. The union of the pieces begins in the second year, and the frontal suture is obliterated, except at its lower part, by the eighth year.

THE ETHMOIDAL BONE (OS ETHMOIDALE)

The **ethmoidal bone** is cubical in shape, and exceedingly light. It is situated at the anterior part of the base of the cranium, and assists in forming the medial walls of the orbital cavities and the roofs and lateral walls of the

CC-0. In Public Domain. Gurukul Kangri Collection, Haridwar

Digitized by Arya Samaj Foundation Chennai and eGangotri

cavities. It consists of four parts: a horizontal, perforated plate named mina cribrosa, a lamina perpendicularis, and two labyrinths or lateral s.

e **lamina cribrosa** of the ethmoidal bone (fig. 309) occupies the idal notch of the frontal bone and forms a part of the roofs of the nasal s. Projecting upwards from the median line of this lamina is a thick, h, triangular process, the *crista galli*, so called from its resemblance to 's comb. Its posterior border, long, thin, and curved, gives attachment falx cerebri. Its anterior border, short and thick, articulates with the l bone by two small projecting *alar processes* which complete the foramen n. Its sides are smooth, and sometimes bulging owing to the presence nall air-sinus in the interior. On either side of the crista galli, the lamina sa is narrow and depressed; it supports the olfactory bulb and is per- d by foramina for the passage of the olfactory nerves. The foramina middle part are small and transmit the nerves to the mucous membrane roof of the nasal cavity; those in the medial and lateral parts are larger former transmit the nerves to the mucous membrane on the upper part nasal septum, the latter erves to the mucous rane on the superior oncha. At the front the lamina cribrosa, her side of the crista s a small fissure which upied by a process of mater. Lateral to this is a foramen which its the anterior eth- l nerve to the nasal ; from this foramen ove runs backwards to nterior ethmoidal fora-

FIG. 309.—The ethmoidal bone. Superior aspect.

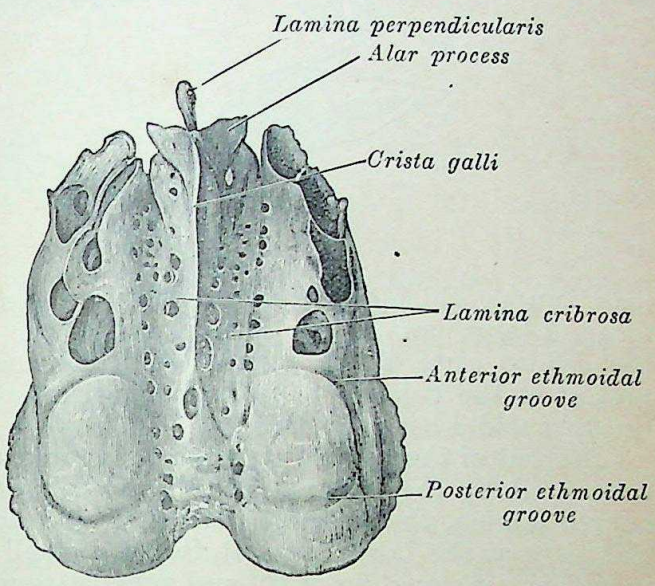

e **lamina perpendicu-** of the ethmoidal bone 310, 311), thin, flat, and hat quadrilateral in descends from the under e of the lamina cribrosa, orms the upper part of asal septum; it is generally deflected a little to one or other side. The *r border* articulates with the spine of the frontal bone and the crest of asal bones. The *posterior border* articulates with the sphenoidal crest and with the vomer below. The *superior border* is attached to the a cribrosa. The *inferior border* is thick, and serves for the attachment e cartilage of the septum of the nose. The surfaces of the lamina are h, except above, where numerous grooves and canals are seen; these rom the medial foramina in the lamina cribrosa and lodge filaments olfactory nerves.

ch **labyrinth** or **lateral mass** of the ethmoidal bone consists of a er of thin-walled *ethmoidal air-sinuses*, arranged in three groups, *anterior*, e, and *posterior*, and interposed between two vertical plates of bone; the l plate forms part of the medial wall of the orbit, the medial plate, part e lateral wall of the nasal cavity.* In the disarticulated bone many of ethmoidal air-sinuses are opened into, but in the articulated skull they are where closed, except at their apertures of communication with the nasal y. The *upper surface* of the labyrinth (fig. 309) presents a number of uses, the walls of which are completed, in the articulated skull, by the of the ethmoidal notch of the frontal bone. Crossing this surface are rooves which are converted into the *anterior and posterior ethmoidal canals*

me anatomists divide the ethmoidal air-sinuses into two groups, an *anterior*, comprising which open into the middle meatus, and a *posterior*, those which open into the superior of the nose.

CC-0. In Public Domain. Gurukul Kangri Collection, Haridwar

Digitized by Arya Samaj Foundation Chennai and eGangotri

by articulation with the frontal bone. On the *posterior surface* labyrinth (fig. 311) are large air-sinuses the walls of which are compl sphenoidal concha and the orbital process of the palatine bone. *surface* (fig. 312) consists of a thin, smooth, oblong plate, the *lamina*

FIG. 310.—The lamina perpendicularis of the ethmoidal bone. Right la aspect. Shown by removing the right labyrinth.

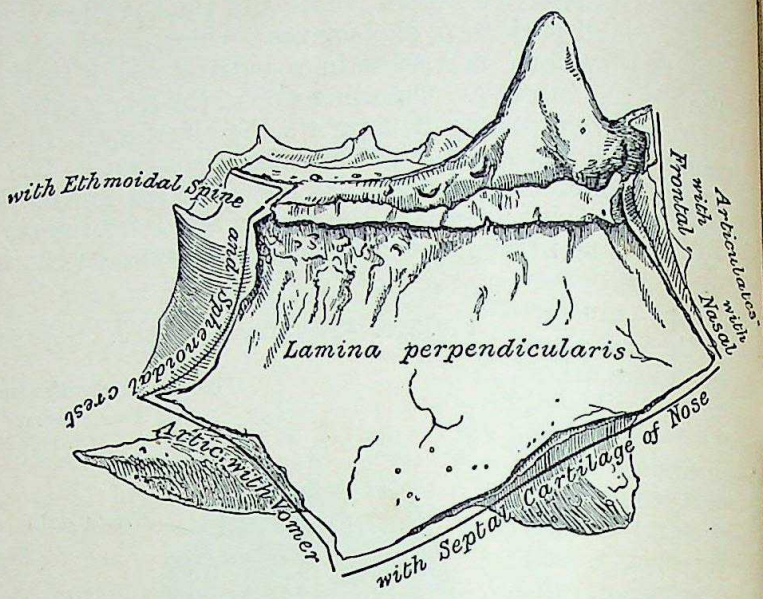

(os planum), which covers the middle and posterior ethmoidal air-si forms a large part of the medial wall of the orbit; it articulates a the orbital plate of the frontal bone, below with the maxilla and t process of the palatine bone, in front with the lacrimal bone, and be the sphenoidal bone (fig. 328).

In front of the lamina papyracea are some air-sinuses, the walls of completed by the lacrimal bone and the frontal process of the ma curved lamina, the *uncinate process*, projects downwards and backw this part of the labyrinth; it forms a small part of the medial wa maxillary air-sinus (fig. 328), and articulates with the ethmoidal proc inferior nasal concha.

FIG. 311.—The ethmoidal bone. Posterior aspect.

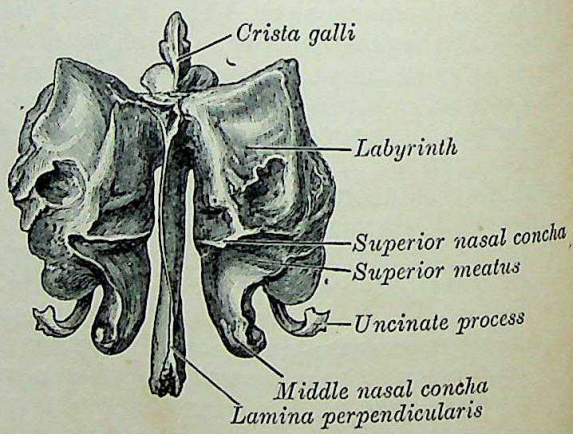

The *medial surface* of the labyrinth (fig. 313) forms part of the late of the corresponding nasal cavity; it consists of a thin lamella, which from the under surface of the lamina cribrosa, and ends in a free, co portion, the *middle nasal concha*. The upper part of the medial s

CC-0. In Public Domain. Gurukul Kangri Collection, Haridwar

Digitized by Arya Samaj Foundation Chennai and eGangotri

ked by numerous grooves, directed nearly vertically downwards from the ina cribrosa; they lodge branches of the olfactory nerves, which are distri- d to the mucous membrane covering the superior nasal concha. The

Fig. 312.—The ethmoidal bone. Right lateral aspect.

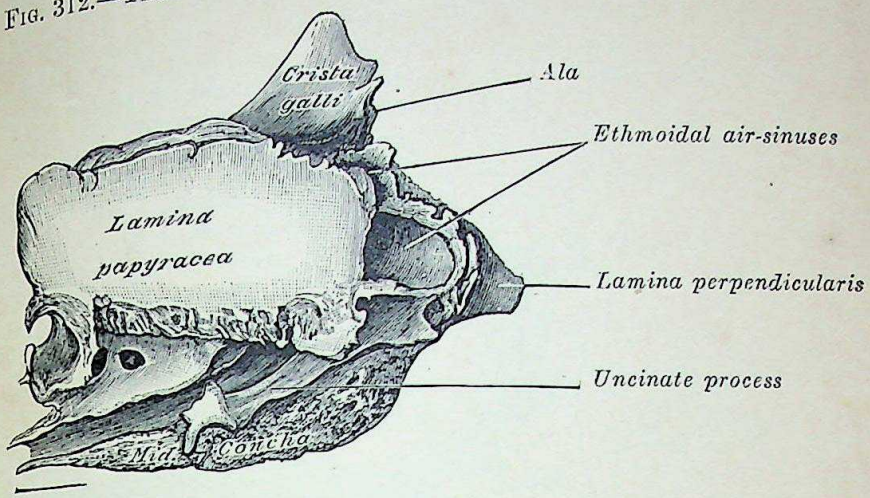

rior part of the medial surface is subdivided by a narrow, oblique fissure, *superior meatus* of the nose, which is bounded above by a thin, curved e, the *superior nasal concha*; the posterior ethmoidal air-sinuses open this meatus. Below and in front of the superior meatus, is the convex face of the middle nasal concha; it extends along the whole length of the

Fig. 313.—The lateral wall of the right nasal cavity, showing the ethmoidal bone (coloured red) and the inferior nasal concha (coloured blue) in position.

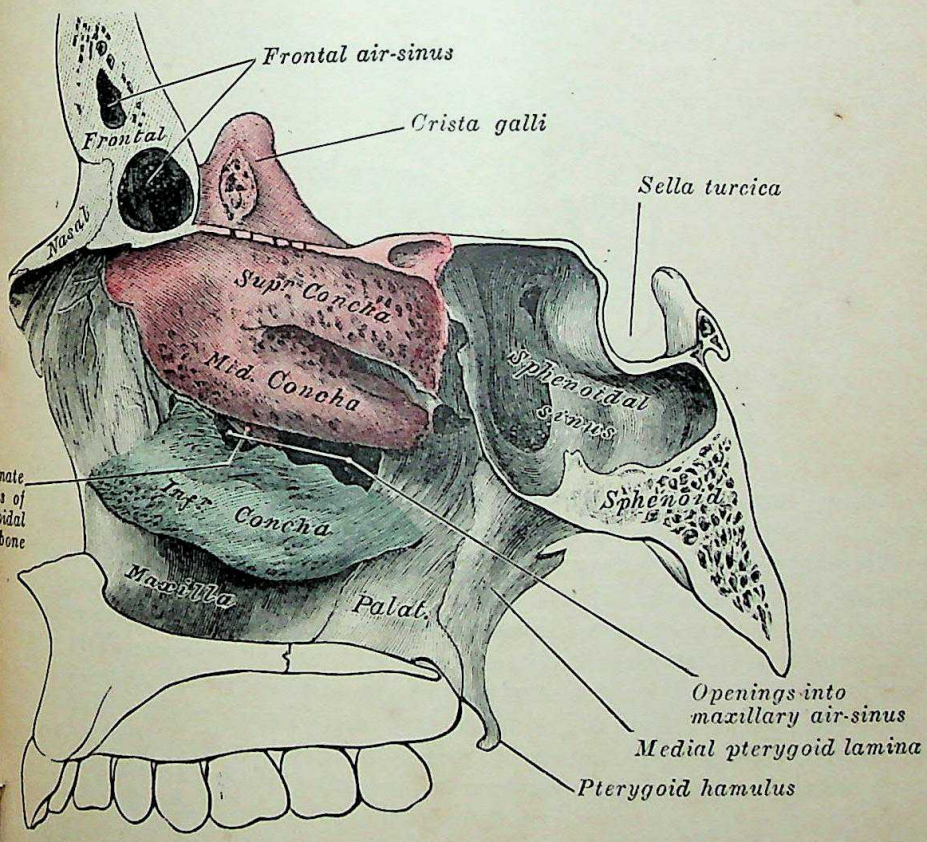

dial surface of the labyrinth. Its lower margin is free and thick, while its eral surface is concave, and assists in forming the *middle meatus* of the nose. middle ethmoidal air-sinuses produce a rounded swelling named the

CC-0. In Public Domain. Gurukul Kangri Collection, Haridwar

Digitized by Arya Samaj Foundation Chennai and eGangotri

bulla ethmoidalis, on the lateral wall of the middle meatus (fig. 314). bulla, or immediately above it, these air-sinuses open into the m curved passage, named the *infundibulum*, extends upwards and forw the middle meatus; it communicates with the anterior ethmoidal ai and in rather more than 50 per cent. of skulls is continued upwards as th nasal duct into the frontal air-sinus.

Fig. 314.—The lateral wall of the right nasal cavity, with parts of the m and inferior nasal conchæ removed.

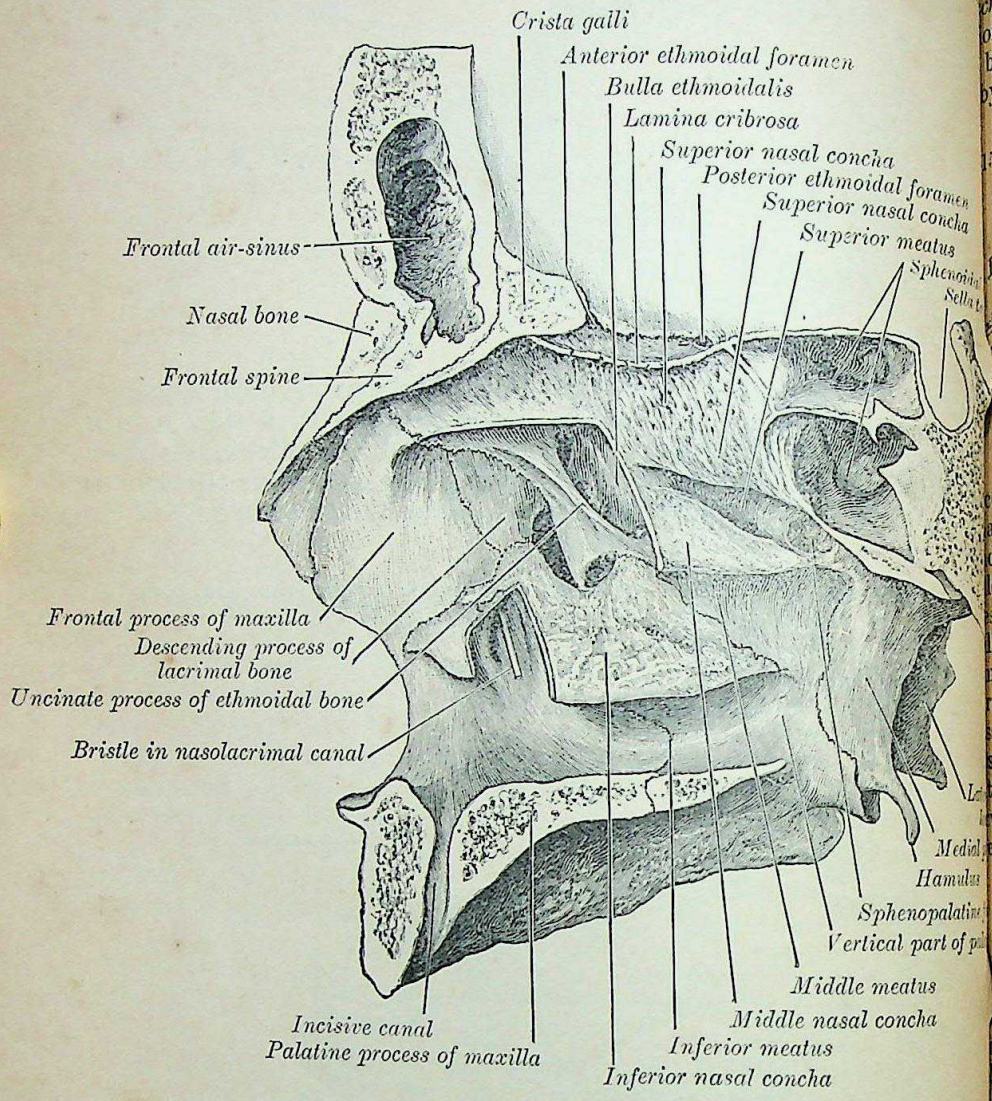

Ossification.—The ethmoidal bone is ossified in the cartilaginous nasal from three centres; one for the lamina perpendicularis, and one for each lab

The centre for each labyrinth appears in the region of the lamina p between the fourth and fifth months of fœtal life, and extends into the c At birth, the bone consists of the two labyrinths, which are small and ill-dev During the first year after birth, the lamina perpendicularis and crista gal to ossify from a single centre, and are joined to the labyrinths about the be of the second year. The lamina cribrosa is ossified partly from the lamina p cularis and partly from the labyrinths. The ethmoidal cells begin to during fœtal life, and in the new-born infant have the form of narrow pouch

The Inferior Nasal Conchæ (Conchæ Nasales Inferiores)

The **inferior nasal conchæ** are curved laminæ which extend horiz along the lateral walls of the nasal cavities (fig. 313). Each bone h surfaces, two borders, and two ends

CC-0. In Public Domain. Gurukul Kangri Collection, Haridwar

Digitized by Arya Samaj Foundation Chennai and eGangotri

e *medial surface* (fig. 315) is convex, perforated by numerous apertures, raversed by longitudinal grooves for the lodgment of vessels. The *lateral* e is concave (fig. 316), and forms part of the inferior meatus of the nasal . The *superior border* is thin and irregular, and may be divided into three ns: of these, the anterior articulates with the crista conchalis of the la, and the posterior with the crista conchalis of the palatine bone. The e portion presents three processes, which vary in size and form. Of these, *crimal process* is small and pointed and is situated at the junction of the or one-fourth with the posterior three-fourths of the bone: it articu- by its apex, with the descending process of the lacrimal bone (fig. 314), by its margins, with the edges of the nasolacrimal groove on the medial

15.—The right inferior nasal concha. Medial aspect.

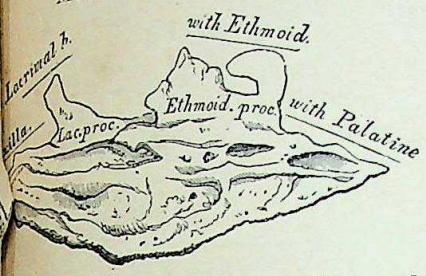

FIG. 316.—The right inferior nasal concha. Lateral aspect.

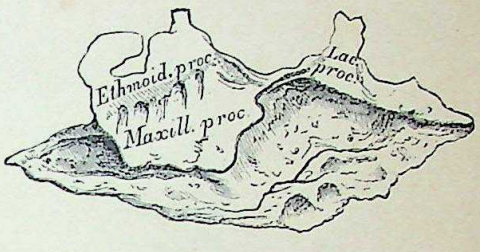

e of the body of the maxilla, and thus assists in forming the canal for asolacrimal duct. Behind this process a thin plate, the *ethmoidal process*, ds to join the uncinate process of the ethmoid (fig. 314). From the e part of the superior border a thin lamella, the *maxillary process*, s downwards and lateralwards; it articulates with the maxilla and the llary process of the palatine bone, and forms a part of the medial wall of maxillary sinus (fig. 328). The *inferior border* is free, thick, and spongy ructure, more especially in the middle of the bone. Both *ends* are more s pointed, the posterior being the more tapered.

ssification.—The inferior nasal concha is ossified from one centre; this appears the fifth month of fœtal life in the maxilloturbinal cartilage which is the ved lower border of the lateral wall of the nasal capsule. It is detached from emainder of the nasal capsule during ossification.

THE LACRIMAL BONES (OSSA LACRIMALIA)

e **lacrimal bones**, the smallest and most fragile of the cranial bones, are ed at the front parts of the medial walls of the orbits (figs. 319, 328). Each mal bone has two surfaces and four borders.

lateral or orbital surface (fig. 317) is divided by a cal ridge, the *posterior lacrimal crest*. In front its crest is a vertical groove, the *lacrimal groove*. anterior border of this groove articulates with posterior border of the frontal process of the lla to complete the *lacrimal fossa* for the lodge- of the lacrimal sac. The medial wall of the mal groove is prolonged downwards under the e of the *descending process*. This process assists rming the bony canal for the nasolacrimal by articulating with the lips of the sulcus malis of the maxilla, and with the lacrimal ess of the inferior nasal concha. The portion d the crest is smooth, and forms a part of the al wall of the orbit. The crest, with a part of rbital surface immediately posterior to it, gives n to the lacrimal part of the Orbicularis oculi. crest ends below in a small hook, the *lacrimal hamulus*, which articulates the lacrimal tubercle of the maxilla and completes the upper orifice of the

FIG. 317.—The left lacrimal bone. Lateral aspect. (Enlarged.)

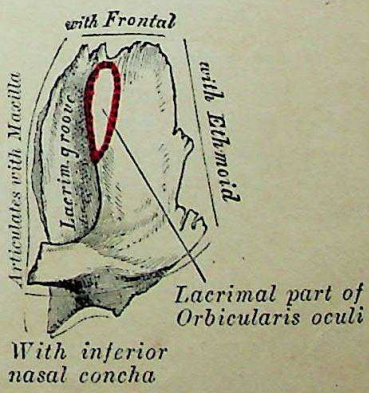

CC-0. In Public Domain. Gurukul Kangri Collection, Haridwar

Digitized by Arya Samaj Foundation Chennai and eGangotri

bony canal for the nasolacrimal duct ; the lacrimal hamulus somet as a separate piece, and is then called the *lesser lacrimal bone*. On th *nasal surface* is a vertical furrow, corresponding to the posterior lac on the lateral surface. The area in front of this furrow forms p middle meatus of the nose ; that behind the furrow articulates wi moidal bone, and completes some of the anterior ethmoidal air-sin *anterior border* of the lacrimal bone articulates with the frontal pro maxilla ; the *posterior border* with the lamina papyracea of the bone ; the *superior border* with the frontal bone. The posterior p *inferior border* articulates with the orbital plate of the maxilla.

FIG. 318.—A sketch showing how the medial wall of the nasolacrimal c completed by the articulation of the descending process of the lacrim with the lacrimal process of the inferior nasal concha. (After Whitna

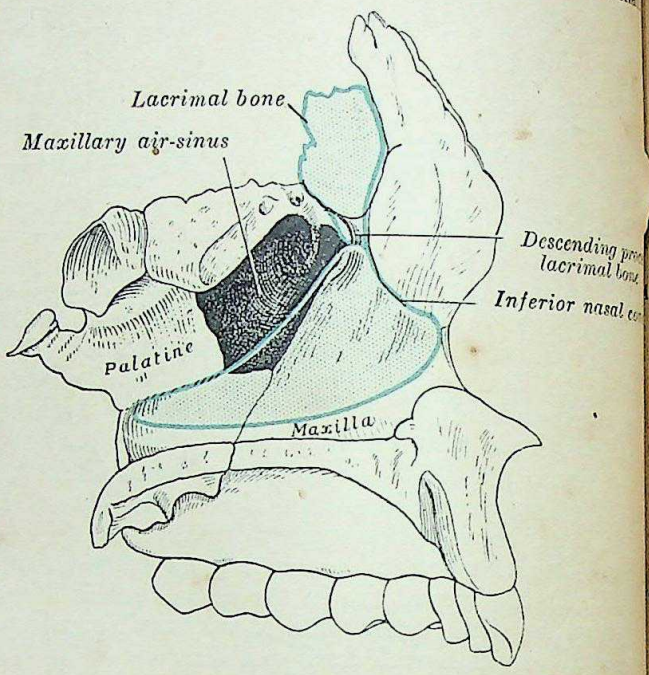

Ossification.—The lacrimal bone is ossified from one centre, which about the twelfth week of fœtal life in the membrane covering the car nasal capsule.

THE NASAL BONES (OSSA NASALIA)

The **nasal bones** are two small oblong bones, varying in size and different individuals ; they are placed side by side between the frontal p of the maxillæ, and form, by their junction, 'the bridge' of the nose (f 356).

Each nasal bone has two surfaces and four borders. The *external* (fig. 320) is concavo-convex from above downwards, and convex from side ; it is covered by the Procerus and Compressor naris, and is pe near its centre by a foramen, for the transmission of a small vein. The *surface* (fig. 321) is concave from side to side, and is traversed from abo wards by a groove, the *ethmoidal sulcus*, which lodges the anterior et nerve. The *superior border*, thick and serrated, articulates with the nas of the frontal bone. The *inferior border*, thin and notched, gives att to the lateral cartilage of the nose. The *lateral border* articulates w frontal process of the maxilla. The *medial border*, thicker above than articulates with the opposite nasal bone, and is prolonged behind into a crest which forms a small part of the septum of the nose, and articulate above downwards, with the frontal spine, the lamina perpendicular ethmoidal bone, and the cartilage of the septum of the nose.

CC-0. In Public Domain. Gurukul Kangri Collection, Haridwar

Digitized by Arya Samaj Foundation Chennai and eGangotri

Ossification.—The nasal bone is ossified from one centre, which appears at the beginning of the third month of fœtal life in the membrane overlying the anterior part of the cartilaginous nasal capsule.

FIG. 319.—The articulation of the nasal and lacrimal bones with the maxilla. Left lateral aspect.

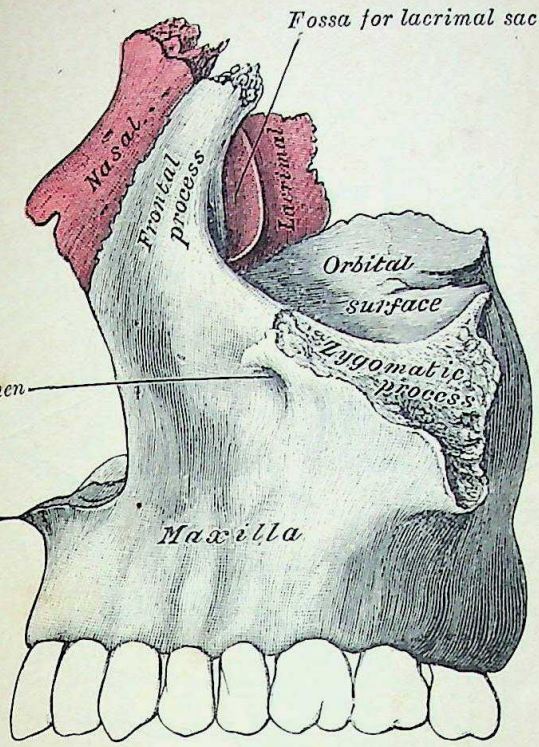

FIG. 320.—The right nasal bone. External aspect.

FIG. 321.—The right nasal bone. Internal aspect.

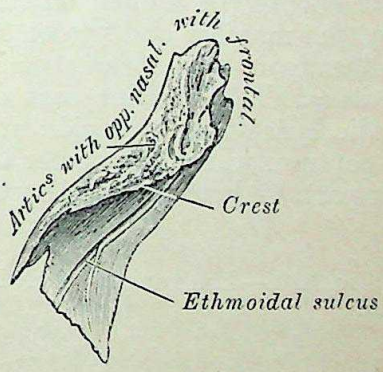

THE VOMER

The **vomer** is thin, somewhat quadrilateral in shape, and forms the hinder and lower part of the septum of the nose (fig. 322); it has two surfaces and four borders. Each *surface* (fig. 323) is marked by small furrows for blood-vessels, and is traversed by the *nasopalatine groove* which runs obliquely downwards and forwards, and lodges the corresponding nasopalatine nerve and vessels. The *superior border*, the thickest, presents a deep furrow, bounded on either side by a projecting ala; the furrow receives the rostrum of the sphenoidal bone; the alæ articulate with the sphenoidal conchæ, the sphenoidal processes of the palatine bones and the vaginal processes of the medial pterygoid laminæ of the sphenoidal bone. The *inferior border* articulates with the nasal crest formed by the maxillæ and palatine bones. The *anterior border* is the longest;

CC-0. In Public Domain. Gurukul Kangri Collection, Haridwar

Digitized by Arya Samaj Foundation Chennai and eGangotri

its upper half articulates with the lamina perpendicularis of the eth bone, its lower is cleft for the reception of the inferior margin of the car the septum of the nose. The *posterior border* is free, concave, and separ

FIG. 322.—The median wall of the left nasal cavity, showing the vomer in

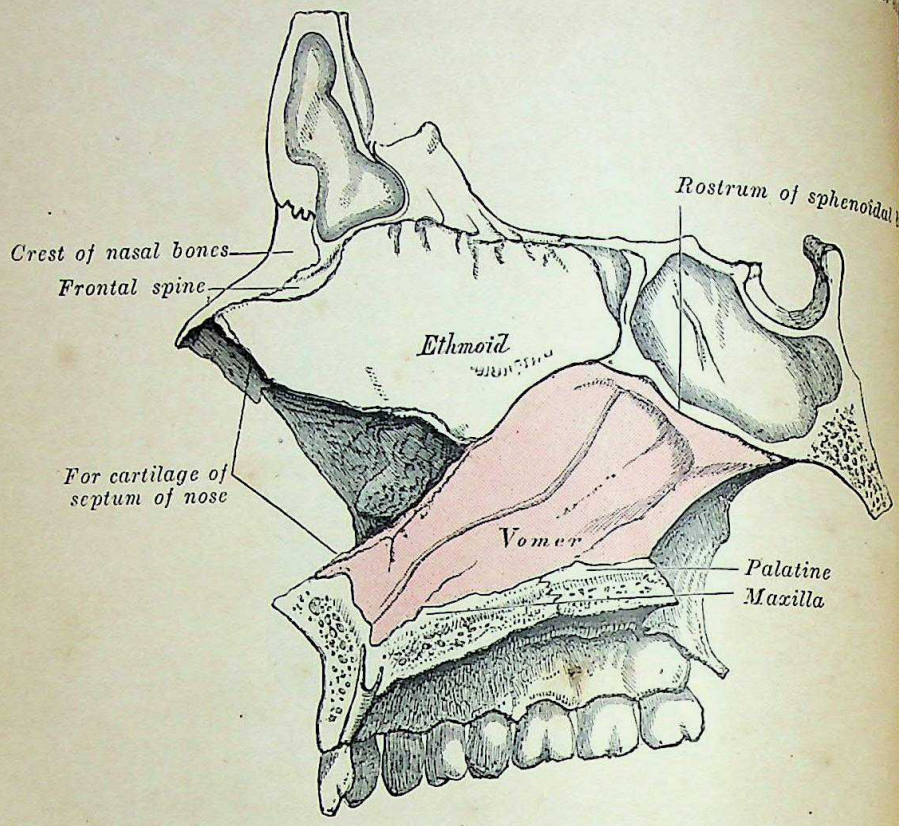

choanæ or posterior nasal apertures ; it is thick and bifid above, thin belo anterior end of the vomer articulates with the posterior margin of the crest of the maxillæ and projects downwards between the incisive cana

Ossification.—At an early period the septum of the nose consists of of cartilage. The superior part of this cartilage is ossified to form the perpendicularis of the ethmoid ; its antero-inferior portion persists as the of the septum, whilst the vomer is ossified in the membrane covering its inferior part. About the eighth week of fœtal life two centres of ossification

FIG. 323.—The vomer. Left lateral aspect.

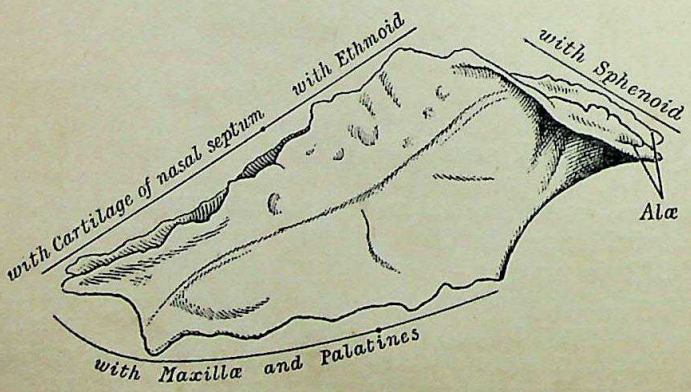

FIG. 324.—The of an infant

either side of the middle line, appear in this part of the membrane, medial little behind the paraseptal cartilages (p. 76). About the third month these unite below the cartilage, and thus a deep groove is formed (fig. 324) in w

CC-0. Panini Kanya Maha Vidyalaya Collection. Haridwar

Digitized by Arya Samaj Foundation Chennai and eGangotri

lage of the septum of the nose is lodged. As growth proceeds, the union of bony lamellæ extends upwards and forwards, and at the same time the inter-ng plate of cartilage undergoes absorption. By the age of puberty the lamellæ almost completely united, but evidence of the bilaminar origin of the bone is in the everted alæ of its upper border and the groove on its anterior border. to a certain stage the vomer is entirely derived from membrane, but 'it mes added to by the ossification of the hinder end of the anterior paraseptal lage.'* From this part of the ossified anterior paraseptal cartilage a plate of descends by the side of the primary part of the vomer, and fuses with it. vomeronasal cartilage of Jacobson is the persistent part of the anterior septal cartilage.*

THE SUTURAL BONES (OSSA SUTURARUM)

n addition to the usual centres of ossification of the cranial bones, others may occur e course of the sutures, giving rise to irregular, isolated, *sutural or Wormian* † *bones* 325). They occur most frequently in the course of the lambdoid suture, but are ionally seen at the fonticuli, especially the posterior. One, the *pterion ossicle*, some-exists between the sphenoidal angle of the parietal bone and the great wing of the oidal bone. They have a tendency to be more or less symmetrical on the two sides skull, and vary much in size. Their number is generally limited to two or three; ore than a hundred have been found in the skull of a hydrocephalic subject.

Fig. 325.—A sketch showing sutural bones in the lambdoid and sagittal sutures.

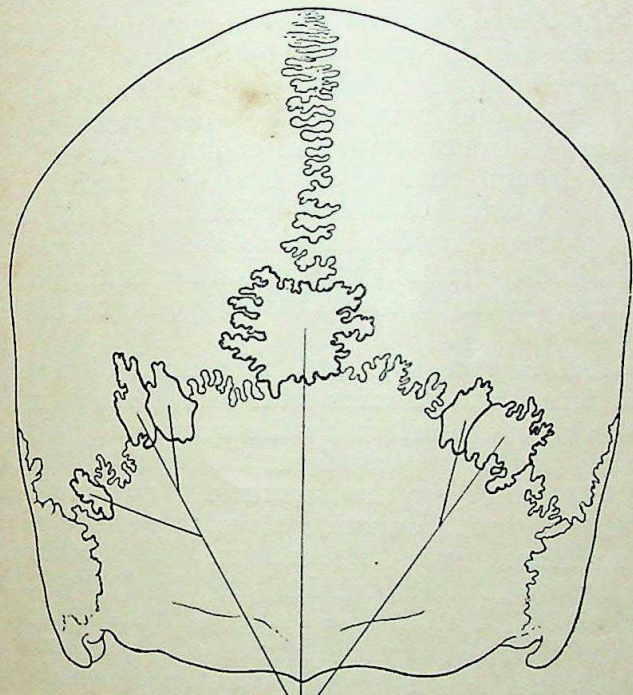

Sutural bones

pplied Anatomy.—An arrest in the ossifying process may give rise to deficiencies, gaps, ssures in the cranium, which are of importance from a medico-legal point of view, hey are liable to be mistaken for fractures. The fissures generally extend from the gins towards the centre of a bone, but the gaps may be found in the middle as well as he edges. In course of time they may become filled with thin laminæ of bone. In e instances, however, the gaps are due to absorption of bone already formed. This pecially so when they appear in the centre of a bone such as the parietal, the ossification ich has already been described as occurring in a regular manner radiating from two es. The condition is most commonly seen in very badly nourished children affected congenital syphilis, and is called *craniotabes*.

E. Fawcett, *Journal of Anatomy and Physiology*, vol. xlv.

Ole Worm, Professor of Anatomy at Copenhagen, 1624-1639, was erroneously supposed ave given the first detailed description of these bones.

CC-0. In Public Domain. Gurukul Kangri Collection, Haridwar

Digitized by Arya Samaj Foundation Chennai and eGangotri

THE FACIAL BONES (OSSA FACIEI)

The Maxillæ

The **maxillæ** are the largest bones of the face, excepting the mand form, by their union, the whole of the upper jaw (fig. 356). Each completing the roof of the mouth, the floor and lateral wall of the nose floor of the orbit; it also enters into the formation of the infra and pterygopalatine fossæ, and the inferior orbital and pterygo fissures.

Each **maxilla** consists of a body and four processes—zygomatic, alveolar, and palatine.

The **body** of the maxilla is somewhat pyramidal in shape. It surfaces,—anterior, infratemporal, orbital, and nasal—and encloses cavity, the **maxillary** air-sinus or antrum of Highmore.

The *anterior surface* (fig. 326) is directed forwards and lateralwar its lower part is a series of eminences (juga alveolaria) corresponding positions of the roots of the upper teeth. Just above those of the inciso is a depression, the *incisive fossa*, which gives origin to the Depressor se the alveolar border below the fossa a slip of the Orbicularis oris is at above and lateral to the fossa, the Nasalis arises. Lateral to the incisi is a larger and deeper depression, the *canine fossa*; it is separated f incisive fossa by the *canine eminence*, which corresponds to the socke canine tooth; the fossa gives origin to the Caninus. Above the cani is the *infra-orbital foramen*, the end of the infra-orbital canal; it tr the infra-orbital vessels and nerve. Above the foramen is a sharp marking the junction of the anterior and orbital surfaces. This bord a small part of the circumference of the base of the orbit, and gives o the orbital head of the Quadratus labii superioris. Medially, the anterior is limited by a deep concavity, the *nasal notch*; the margin of the not attachment to the Dilatator naris posterior, and ends below in a pointed which with the corresponding process of the opposite maxilla forms the *nasal spine.*

The *infratemporal surface* (fig. 326) is convex, directed backwar lateralwards, and forms the anterior wall of the infratemporal fossa separated from the anterior surface by the zygomatic process and by which runs upwards to that process from the socket of the first molar It is pierced near its centre by the apertures of two or three *alveolar* which transmit the posterior superior alveolar vessels and nerves. lower part of this surface is a round eminence, the *maxillary tuberosity* is rough for articulation with the pyramidal process of the palatine bone (fi it gives origin to a few fibres of the Pterygoideus internus, and in som articulates with the lateral pterygoid lamina of the sphenoidal bone. this is a smooth surface, which forms the anterior boundary of the p palatine fossa, and is grooved for the maxillary nerve; the groove nerve is directed lateralwards and slightly upwards, and is continuo the infra-orbital groove on the orbital surface.

The *orbital surface* (fig. 326) is smooth and triangular, and forms the part of the floor of the orbit. Its *medial border* presents anteriorly a the *lacrimal notch*, behind which it articulates from before backwards w lacrimal bone, the lamina papyracea of the ethmoidal bone, and the process of the palatine bone (fig. 328). Its *posterior border* is smoo rounded; it forms the lateral part of the lower margin of the inferior fissure, and its central part is notched by the commencement of the orbital groove. The *anterior border* forms a small part of the circum of the base of the orbit, and is continuous medially with the anterior l crest on the frontal process (p. 232). The *infra-orbital groove*, for the of the infra-orbital vessels and nerve, begins at the middle of the p border, where it is continuous with the groove near the upper edge of the

CC-0. In Public Domain. Gurukul Kangri Collection, Haridwar

Digitized by Arya Samaj Foundation Chennai and eGangotri

poral surface; it passes forwards and ends in the *infra-orbital canal*, which
s on the anterior surface of the bone just below the margin of the orbit.
he medial and front part of the orbital surface, and lateral to the lacrimal
ve, is a small depression, which gives origin to the Obliquus oculi inferior.
The *nasal surface* (fig. 327) presents in its upper and posterior part a large,
ular opening leading into the maxillary air-sinus. At the upper border
his aperture are some broken air-sinuses, which, in the articulated skull, are
ed by the ethmoidal and lacrimal bones. Below the opening into the
illary air-sinus is a smooth concave surface which forms part of the inferior
tus of the nasal cavity, and behind it is a rough surface for articulation
the vertical part of the palatine bone; this rough surface is traversed
groove, which begins near the middle of the posterior border, runs obliquely
nwards and forwards, and is converted into the *pterygopalatine canal* by
vertical part of the palatine bone and the pterygoid process of the sphenoidal

FIG. 326.—The left maxilla. Lateral aspect.

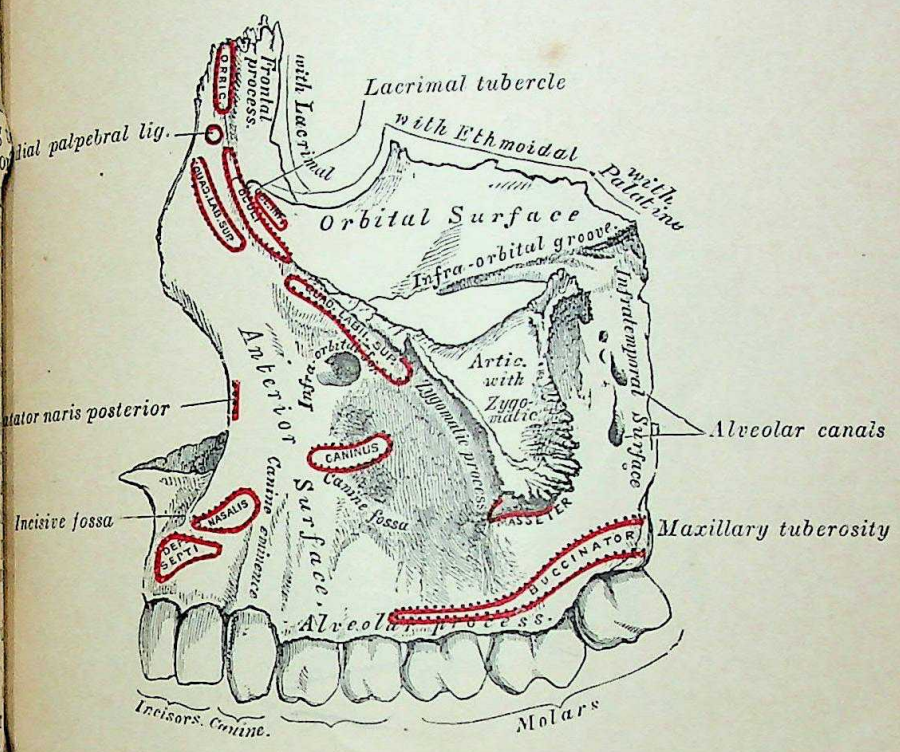

e. In front of the opening of the maxillary air-sinus is a deep groove, the
us lacrimalis, which constitutes about two-thirds of the circumference of the
olacrimal canal, the remaining one-third being formed by the descending
cess of the lacrimal bone and the lacrimal process of the inferior nasal
cha (fig. 318); this canal opens into the inferior meatus of the nose
314) and transmits the nasolacrimal duct. More anteriorly is an oblique
ge, the *crista conchalis*, for articulation with the inferior nasal concha. The
llow concavity below this ridge forms part of the inferior meatus of the
se, and the surface above the ridge part of the atrium of the middle meatus.
The **maxillary air-sinus** (*antrum of Highmore*) is a large pyramidal cavity
hin the body of the maxilla. Its walls are thin, and correspond to the
al, orbital, anterior, and infratemporal surfaces of the body of the bone.
apex, directed lateralwards, is formed by the zygomatic process; its *base*,
nasal wall, directed medialwards, is formed by the lateral wall of the nose,
presents, in the disarticulated bone, a large, irregular aperture communicat-
with the nasal cavity. In the articulated skull this aperture is much
uced in size by the following bones: the uncinate process of the ethmoidal
ne and the descending process of the lacrimal bone above, the maxillary
cess of the inferior nasal concha below, and the vertical part of the pala-
e bone behind (figs. 314, 328). The maxillary air-sinus communicates with

CC-0. In Public Domain. Gurukul Kangri Collection, Haridwar

Digitized by Arya Samaj Foundation Chennai and eGangotri

the middle meatus of the nose, generally by two small apertures, one
is usually closed, in the recent state, by mucous membrane. On the
wall are the *alveolar canals*, transmitting the posterior superior alveol
and nerves to the molar teeth; these canals occasionally project
into the maxillary air-sinus. The *floor* is formed by the alveolar p
the maxilla, and its lowest part is usually about 1·25 cm. below the
the floor of the nasal cavity. In a large proportion of cases radiat
of varying sizes spring from the floor of the sinus in the intervals
adjacent teeth; in some cases the floor is perforated by the fangs of
teeth.* The infra-orbital canal usually projects into the sinus a
marked ridge extending from the *roof* to the *anterior wall*. The siz
cavity varies in different skulls, and even on the two sides of the sam

FIG. 327.—The left maxilla. Medial aspect.

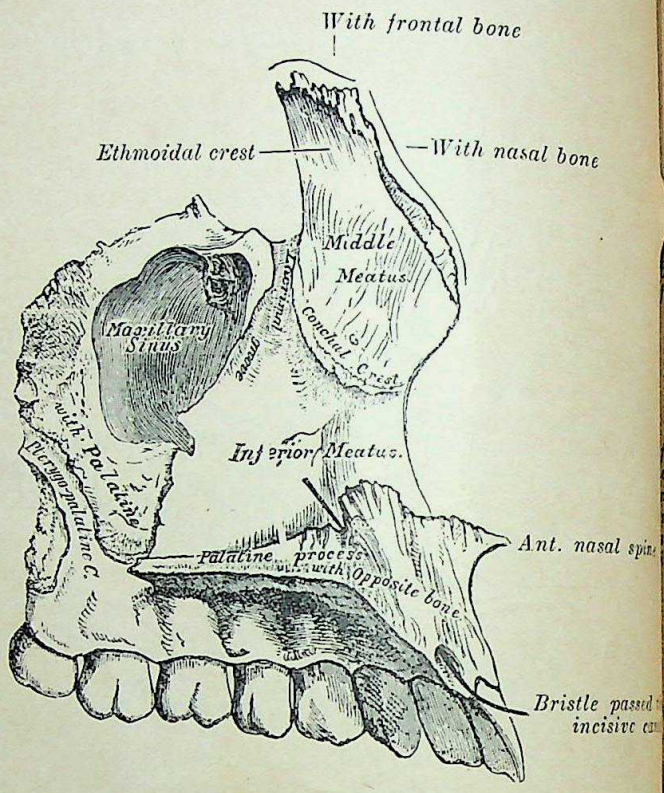

Applied Anatomy.—The extreme thinness of the walls of this cavity affords an
tion of the fact that a tumour growing from the maxillary air-sinus and encroachi
the adjacent parts may push up the floor of the orbit, and displace the eyeba
project into the nose; may protrude forwards on to the cheek; or may make
backwards into the infratemporal fossa, or downwards into the mouth.

The **zygomatic process** of the maxilla is a rough triangular emi
situated at the angle of separation of the anterior, infratemporal, and
surfaces. In front it forms part of the anterior surface of the body
bone; *behind*, it is concave, and continuous with the infratemporal s
above, it is rough and serrated for articulation with the zygomatic bone:
it presents a prominent arched border which separates the anterior fr
infratemporal surface.

The **frontal process** of the maxilla projects upwards and backwards b
the nasal and lacrimal bones (figs. 328, 353). Its *lateral surface* is divid
two parts by a vertical crest, the *anterior lacrimal crest*, which gives atta

* The number of teeth whose roots are in relation with the floor of the maxillary s
is variable. The sinus may extend so as to be in relation to all the teeth of the true maxil
the canine to the third molar.—(Salter.)

† Logan Turner (*op. cit.*) gives the following measurements for an adult sinus of avera
vertical height opposite first molar tooth, 3·5 cm.; transverse breadth, 2·5 cm.; and
posterior depth, 3·2 cm.

CC-0. In Public Domain. Gurukul Kangri Collection, Haridwar

Digitized by Arya Samaj Foundation Chennai and eGangotri

he medial palpebral ligament, and is continuous below with the infra-orbital rin. At the junction of the crest with the orbital surface is a small tubercle, *lacrimal tubercle*, which serves as a guide to the position of the lacrimal The part in front of the anterior lacrimal crest is smooth, and merges w with the anterior surface of the body; it gives attachment to a portion e Orbicularis oculi, and to the angular head of the Quadratus labii superioris. part behind the anterior lacrimal crest is hollowed into a groove which ontinuous inferiorly with the sulcus lacrimalis on the nasal surface of the e, and posteriorly, in the articulated skull, with the lacrimal groove on lacrimal bone, the two grooves forming the *lacrimal fossa* for the lodgement he lacrimal sac.

FIG. 328.—The left maxillary air-sinus. Opened from the lateral side.

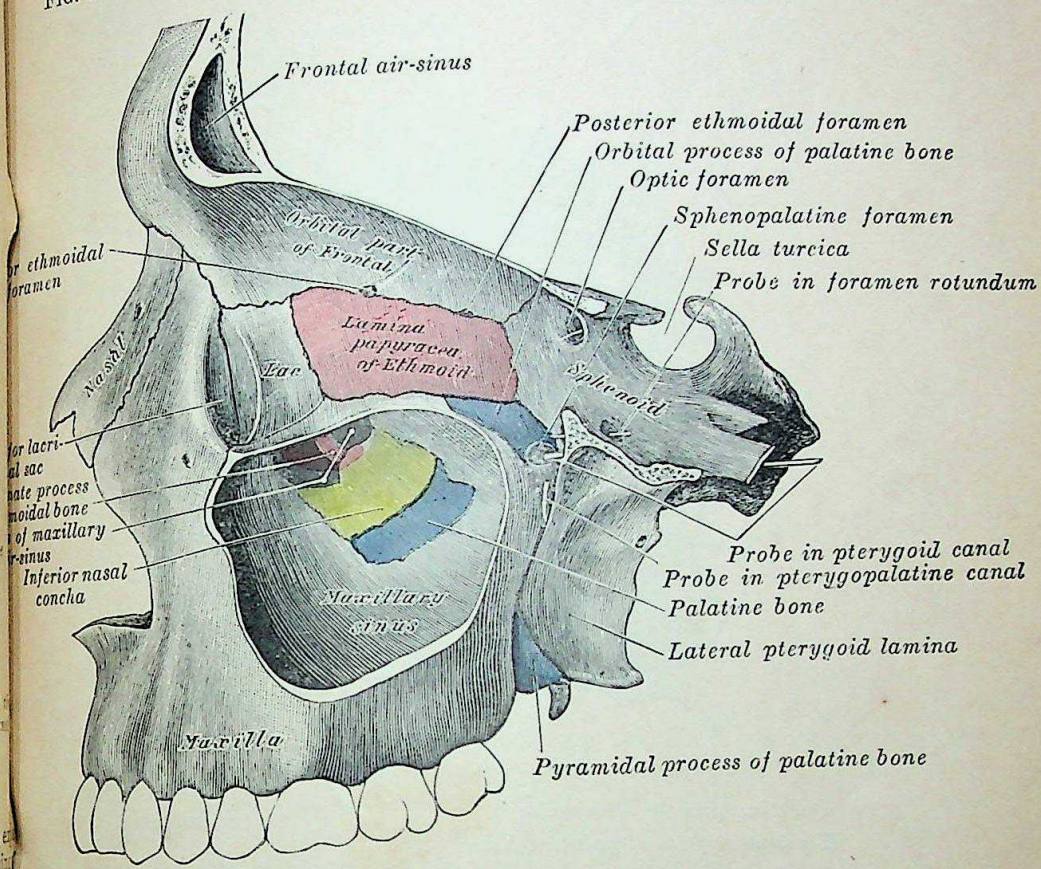

The *medial surface* of the frontal process forms a portion of the lateral wall he nasal cavity. A rough, uneven area at its upper part articulates with ethmoidal bone and closes in the anterior ethmoidal air-sinuses. Below rough area is an oblique ridge, the *crista ethmoidalis*, the posterior part which articulates with the middle nasal concha, while the anterior part ermed the *agger nasi*; the crista ethmoidalis forms the upper limit of the nm of the middle meatus of the nose. The *upper end* of the frontal process culates with the nasal notch of the frontal bone, the *anterior border* with nasal bone, and the *posterior border* with the lacrimal bone.

The **alveolar process** of the maxilla, thick and arched, is broader behind n in front, and excavated into cavities or alveoli for the reception of the ts of the teeth. These cavities are eight in number, and vary in size and th according to the teeth they contain. That for the canine tooth is the gest; those for the molars are the widest, and are subdivided into three or cavities by septa; those for the incisors and the second bicuspid are gle; that for the first bicuspid is sometimes divided into two. The Buccinator es from the outer surface of this process, as far forward as the first molar th. When the maxillæ are articulated with each other, their alveolar cesses together form the *alveolar arch*.

CC-0. In Public Domain. Gurukul Kangri Collection, Haridwar

Digitized by Arya Samaj Foundation Chennai and eGangotri

The **palatine process** of the maxilla, thick and strong, is horiz projects medialwards from the nasal surface of the bone. It forms a co part of the floor of the nose and the roof of the mouth, and is much front than behind. Its *inferior surface* (fig. 329), concave, rough and forms, with the palatine process of the opposite bone, the anterior thre of the hard palate. It is perforated by numerous foramina for the the nutrient vessels, and presents depressions for the lodgement of the glands; it is channelled at the posterior part of its lateral border grooves which lodge the descending palatine vessels, and the anterior nerve. When the two maxillæ are articulated, a funnel-shaped ope *incisive foramen*, is seen in the middle line, immediately behind the inci

Fig. 329.—The bony palate and the alveolar arch. Inferior aspect.

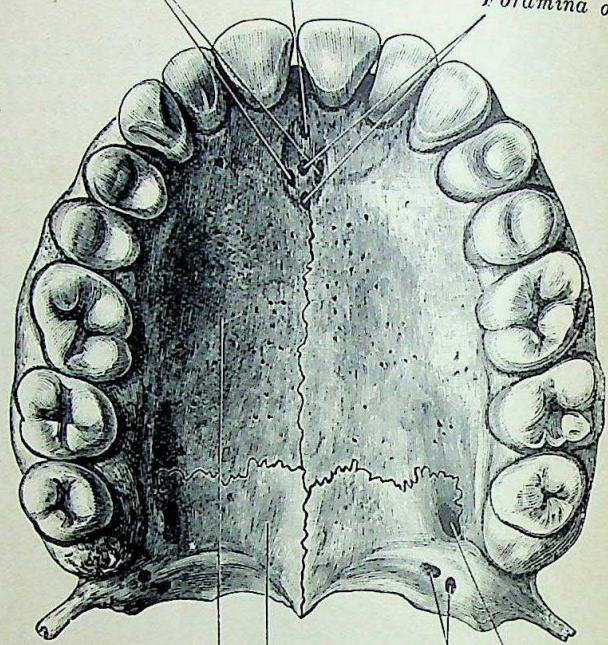

In this opening the orifices of two lateral canals are visible; they are the *incisive canals* or *foramina of Stensen*; each leads upwards into the sponding nasal cavity and transmits the terminal branch of the greater p artery and the nasopalatine nerve. Occasionally there are two add apertures in the middle line; they are termed the *foramina of Scarp* when present transmit the nasopalatine nerves, the left passing throu anterior, and the right through the posterior foramen. On the under of the palatine process, a delicate suture, well seen in young skulls, may times be noticed extending lateralwards and forwards from the incisive fo to the interval between the lateral incisor and the canine teeth. The part in front of this suture constitutes the *premaxilla* or *os incisivum*, in most vertebrates forms an independent bone; it includes the whole th of the alveolus, the corresponding part of the floor of the nose and the a nasal spine, and contains the sockets of the incisor teeth. The *upper* of the palatine process is concave from side to side, smooth, and form greater part of the floor of the nasal cavity; close to the anterior part medial margin is the upper orifice of the incisive canal. The *lateral* of the process is fused with the rest of the bone. The *medial border*, in front than behind, is raised into a ridge, the *nasal crest*, which, wi

CC-0. In Public Domain. Gurukul Kangri Collection, Haridwar

Digitized by Arya Samaj Foundation Chennai and eGangotri

responding ridge of the opposite bone, forms a groove for the reception of vomer. The front part of this ridge rises to a considerable height, and is ed the *incisor crest* (fig. 327); it is prolonged forwards into a sharp pro- which, with the similar process of the opposite bone, forms the *anterior l spine*. The *posterior border* is serrated for articulation with the hori- al part of the palatine bone.

Ossification.—The maxilla is mainly developed in membrane. Mall* and cett† have shown that it is ossified from two centres, one for the maxilla proper one for the premaxilla. These centres appear at the end of the sixth week of l life, that for the maxilla proper commencing above the canine tooth-germ;

FIG. 330.—The right maxilla at birth. Lateral aspect.

FIG. 331.—The right maxilla at birth. Inferior aspect.

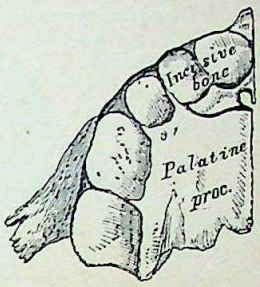

FIG. 332.—The right maxilla at birth. Medial aspect.

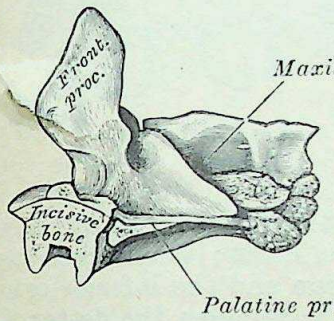

y unite at the end of the second or early in the third month, but the suture ween them (fig. 331) may persist on the palate until nearly middle life; the frontal ess of the bone is developed from both centres. The ossifying maxilla invades incorporates the paranasal process of the cartilaginous nasal capsule, a condition ch may account for the small islands of cartilage which are sometimes found in ossifying maxilla. The maxillary air-sinus appears as a shallow groove (fig. 332) the nasal surface of the bone about the fourth month of fœtal life, but does not ch its full size until after the second dentition. The infra-orbital vessels and ve lie for a time in an open groove in the floor of the orbit; the anterior part his groove is converted into the infra-orbital canal by a lamina of bone which ws from the lateral side of the groove.

CHANGES PRODUCED IN THE MAXILLA BY AGE

At birth the transverse and anteroposterior diameters of the maxilla are each greater n the vertical. The frontal process is well-marked, but the body of the bone consists of e more than the alveolar process, the tooth-sockets reaching almost to the floor of the it. The maxillary air-sinus is seen as a furrow on the lateral wall of the nose. In the lt the vertical diameter is the greatest, owing to the development of the alveolar pro- and the increase in size of the air-sinus. In old age, the bone reverts in some ure to the infantile condition: its height is diminished, and after the loss of the h the alveolar process is absorbed, and the lower part of the bone contracted and ced in thickness.

* *American Journal of Anatomy*, vol. v. 1906.
† *Journal of Anatomy and Physiology*, vol. xlv. 1911.

CC-0. In Public Domain. Gurukul Kangri Collection, Haridwar

Digitized by Arya Samaj Foundation Chennai and eGangotri

The Palatine Bones (Ossa Palatina)

The **palatine bones** are situated at the posterior part of the nasal between the maxillæ and the pterygoid processes of the sphenoidal bone (

Fig. 333.—The articulation of the left palatine bone with the left maxilla.

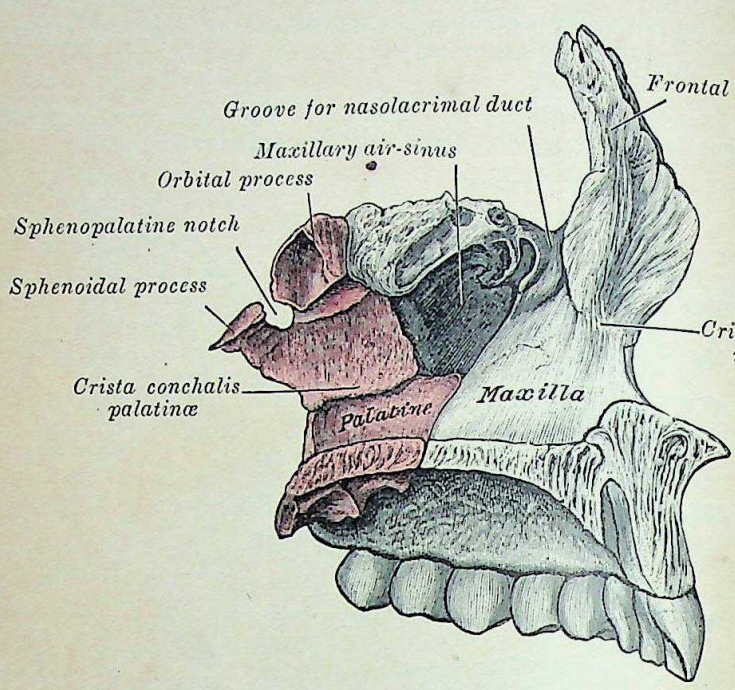

Each assists in forming the floor and lateral wall of the nasal cavity, t of the mouth, and the floor of the orbit; it enters into the formation pterygopalatine and pterygoid fossæ and the inferior orbital fissure.

The palatine bone somewhat resembles the letter L, and consist horizontal and a vertical part, and three outstanding processes—a pyramidal process, which is directed backwards, lateralwards, and down from the junction of the horizontal and vertical parts, and the orbit sphenoidal processes, which surmount the vertical part, and are sep by a deep notch, the sphenopalatine notch.

The **horizontal part** of the palatine bone (figs. 334, 335) is quadrilater has two surfaces and four borders. The *nasal surface*, concave from s side, forms the posterior part of the floor of the nasal cavity. The p *surface* forms, with the corresponding surface of the opposite bone, the po one-fourth of the hard palate; near its posterior margin is a curved The *posterior border* is thin and concave; to it, and to the palatine surface forwards as the curved ridge just mentioned, the expanded tendon of the veli palatini is attached. The medial end of the posterior border is p and, when united with that of the opposite bone, forms a projecting p the *posterior nasal spine*, for the attachment of the Musculus uvulæ *anterior border* is serrated, and articulates with the palatine process of the m The *lateral border* is united with the inferior border of the vertical part, grooved by the lower end of the pterygopalatine sulcus. The *medial* thick and serrated, articulates with the corresponding border of the o bone, and the opposed borders form a crest which articulates with the p part of the lower edge of the vomer, and is continuous anteriorly w nasal crest of the maxillæ.

The **vertical part** of the palatine bone (figs. 334, 335), thin and oblong form, has two surfaces and four borders.

The *nasal surface* exhibits at its lower part a broad, shallow dep which forms part of the inferior meatus of the nasal cavity. Immed

CC-0. In Public Domain. Gurukul Kangri Collection, Haridwar

Digitized by Arya Samaj Foundation Chennai and eGangotri

ve this is a horizontal ridge, the *crista conchalis*, for articulation with the rior nasal concha; still higher is a second broad, shallow depression, which ns part of the middle meatus, and is limited above by the *crista ethmoidalis*,

FIG. 334.—The left palatine bone. Medial aspect. (Enlarged.)

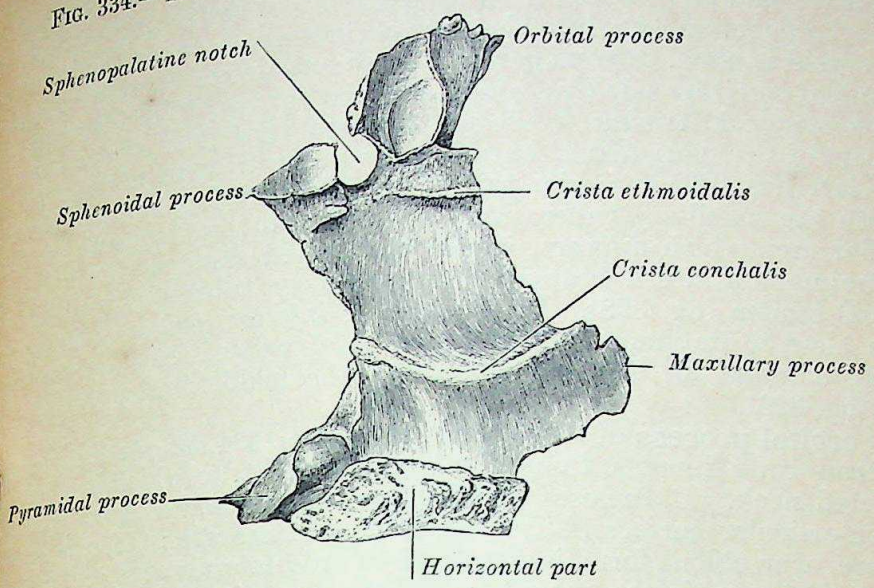

articulation with the middle nasal concha. Above the crista ethmoidalis narrow, horizontal groove, which forms part of the superior meatus.

The *maxillary surface* is rough and irregular throughout the greater part s extent, for articulation with the nasal surface of the maxilla; its upper posterior part is smooth and forms the medial wall of the pterygopalatine a; its front portion is also smooth and forms the posterior part of the ial wall of the maxillary air-sinus (fig. 328). On the posterior part of the illary surface is a deep vertical groove, the *pterygopalatine sulcus*, which the articulated skull is converted the *pterygopalatine canal* by the illa and the pterygoid process of sphenoidal bone; this canal trans- s the descending palatine vessels, the palatine nerves.

The *anterior border* is thin and gular; at the level of the crista chalis is a pointed projecting na, the *maxillary process*, which rected forwards below and behind maxillary process of the inferior l concha with which it articu- s and assists in forming the ial wall of the maxillary air- s (fig. 328). The *posterior border* 335) is serrated for articulation the medial pterygoid lamina of sphenoidal bone. This border is tinuous above with the sphenoidal cess; it expands below into the amidal process. The *superior* r supports the orbital process ront and the sphenoidal process nd. These processes are separ- d by the *sphenopalatine notch*, which is converted into the *sphenopalatine men* by the under surface of the body of the sphenoidal bone. In the culated skull this foramen leads from the pterygopalatine fossa into the

FIG. 335.—The left palatine bone. Posterior aspect. (Enlarged.)

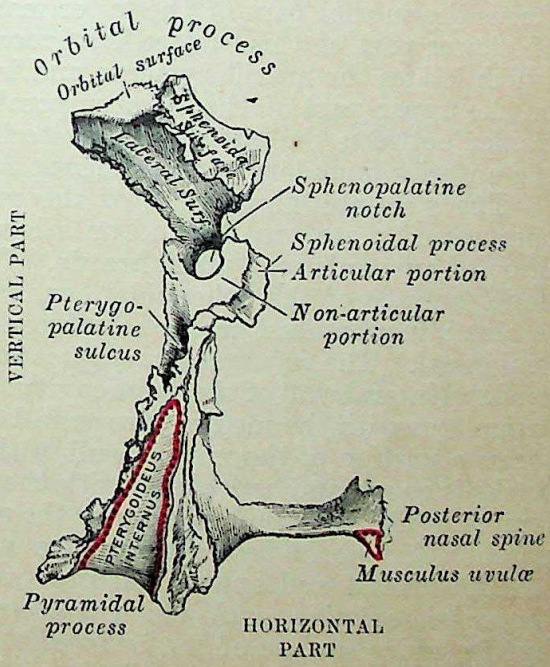

CC-0. In Public Domain. Gurukul Kangri Collection, Haridwar

Digitized by Arya Samaj Foundation Chennai and eGangotri

posterior part of the superior meatus of the nose, and transmits the palatine vessels and the posterior superior nasal nerves. The *infer* is fused with the lateral border of the horizontal part, and in the pyramidal process is grooved by the lower end of the pteryg sulcus.

The **pyramidal process** (tuberosity) of the palatine bone projects ba lateralwards, and downwards from the junction of the horizontal and parts of the bone, and fits into the angular interval between the lower the pterygoid laminæ. On its *posterior surface* is a smooth, grooved, tr area, limited on either side by a rough articular furrow. The furrows a with the pterygoid laminæ, while the grooved triangular area comp lower part of the pterygoid fossa and gives origin to some fibres of th goideus internus. The anterior part of the *lateral surface* is rough for tion with the maxillary tuberosity; the posterior part consists of a triangular area which appears, in the articulated skull, at the lower the infratemporal fossa between the maxillary tuberosity and the pterygoid lamina (fig. 328). In the *base* or *inferior surface* of the py process, close to its union with the horizontal part of the bone, are th *palatine foramina* for the transmission of the middle and posterior nerves (fig. 329).

The **orbital process** of the palatine bone (figs. 334, 335) is directed up and lateralwards from the front of the vertical part, to which it is joine constricted neck. It encloses an air-sinus, and presents three articu two non-articular surfaces. The articular surfaces are: (1) the *ant maxillary*, of an oblong form, is directed forwards, lateralwards, and dow and articulates with the maxilla; (2) the *posterior* or *sphenoidal*, backwards, upwards, and medialwards, presents the opening of the ai which usually communicates with the sphenoidal air-sinus; the ma the opening articulate with the sphenoidal concha; (3) the *medial* or *eth* directed medialwards and forwards, articulates with the labyrinth ethmoidal bone. In some cases, the air-sinus opens on this surface an communicates with the posterior ethmoidal air-sinuses; more rarely i on the ethmoidal and sphenoidal surfaces, and then communicates w posterior ethmoidal air-sinuses, and the sphenoidal air-sinus. The non-a surfaces are: (1) the *superior* or *orbital*, triangular in shape, is directed u and lateralwards, and forms the posterior part of the floor of the orbi (2) the *lateral*, of an oblong form, is directed towards the pterygop fossa, and is separated from the orbital surface by a rounded border forms the medial part of the lower margin of the inferior orbital fissu the lower part of this surface is a groove, directed lateralwards and up which lodges the maxillary nerve and is continuous with the transverse on the upper part of the infratemporal surface of the maxilla (p. 230) border between the lateral and posterior surfaces is prolonged downw the anterior boundary of the sphenopalatine notch.

The **sphenoidal process** of the palatine bone (figs. 334, 335) is a compressed plate, smaller and on a lower level than the orbital process directed upwards and medialwards. Its *superior surface* articulates wi under surface of the sphenoidal concha and the root of the medial pte lamina; it presents a groove which contributes to the formation of the p geal canal. The *inferomedial surface* is concave, and forms a small part roof and lateral wall of the nasal cavity. The posterior part of the *lateral* articulates with the medial pterygoid lamina; the anterior part is smoo forms a portion of the medial wall of the pterygopalatine fossa. The p *border* is rough and articulates with the vaginal process of the medial pte lamina. The *anterior border* forms the posterior boundary of the sphenop notch. The *medial border* articulates with the ala of the vomer.

The orbital and sphenoidal processes are separated from one anot the *sphenopalatine notch* which is converted into the sphenopalatine fo by the under surface of the body of the sphenoidal bone; sometimes th processes are united by a spicule of bone which converts the notch i foramen.

Ossification.—The palatine bone is ossified in membrane from one centre, appears during the eighth week of fœtal life in the vertical part of the

CC-0. In Public Domain. Gurukul Kangri Collection, Haridwar

Digitized by Arya Samaj Foundation Chennai and eGangotri

n this point ossification spreads upwards into the orbital and sphenoidal pro-
es, medialwards into the horizontal part, and downwards into the pyramidal
ess.
At the time of birth the height of the vertical part is about equal to the transverse
h of the horizontal part, whereas in the adult it measures nearly twice as much.

The Zygomatic Bones (Ossa Zygomatica)

The **zygomatic or malar bones** are situated at the upper and lateral parts
he face. Each forms the prominence of the cheek, part of the lateral wall
floor of the orbit, and parts of the temporal and infratemporal fossæ
336).
The zygomatic bone is quadrangular in shape and has two surfaces, four
ers, and four processes.

Fig. 336.—The left zygomatic bone *in situ*.

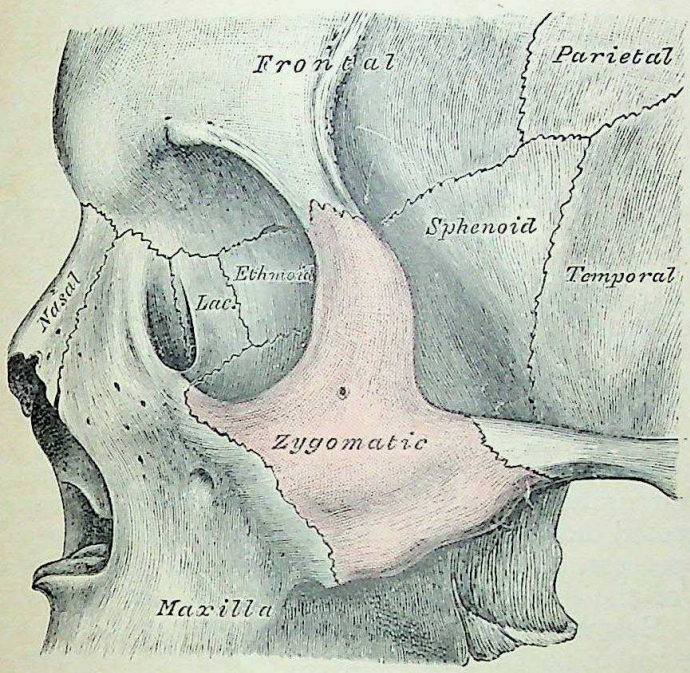

The *malar surface* (figs. 336, 337), directed lateralwards and forwards, is
vex and is perforated near its orbital border by the *zygomaticofacial foramen*
the passage of the zygomaticofacial nerve and vessels; below this foramen
slight elevation, which gives origin to the Zygomaticus. The *temporal*
face (fig. 338), directed medialwards and backwards, is concave, presenting
eriorly a rough, triangular area, for articulation with the maxilla, and
eriorly a smooth, concave surface, the upper part of which forms the
erior boundary of the temporal fossa, the lower, a part of the infratemporal
a. Near the posterior edge of the rough triangular area is the *zygomatico-*
poral foramen for the transmission of the zygomaticotemporal nerve.
The *anterosuperior or orbital border* is smooth, concave, and forms a con-
erable part of the circumference of the base of the orbit. The *antero-inferior*
maxillary border is rough, and articulates with the maxilla; near the orbital
rgin it gives origin to the zygomatic head of the Quadratus labii superioris.
e *posterosuperior or temporal border*, curved like an italic letter *f*, is continuous
re with the temporal line on the frontal bone, and below with the upper
der of the zygomatic arch; the temporal fascia is attached to it. The
ntero-inferior or zygomatic border affords attachment by its rough edge to
Masseter.
The *frontosphenoidal process* is thick and serrated, and articulates with the
omatic process of the frontal bone. On its orbital surface, just within the

CC-0. In Public Domain. Gurukul Kangri Collection, Haridwar

Digitized by Arya Samaj Foundation Chennai and eGangotri

orbital margin and about 11 mm. below the zygomaticofrontal su tubercle of varying size and form, but present in 95 per cent. o (Whitnall).*

The *orbital process* is a thick, strong plate, projecting backwa medialwards from the orbital margin. Its *orbital surface*, smooth and forms a part of the floor and lateral wall of the orbit. On it are seen the orifices of two canals, the *zygomatico-orbital foramina*; one canals opens on the temporal surface, the other on the malar surfac bone; the former transmits the zygomaticotemporal, the latter the zyg facial nerve. Its *temporal surface*, smooth and convex, forms part

FIG. 337.—The left zygomatic bone. Lateral aspect.

FIG. 338.—The left zygomatic Medial aspect.

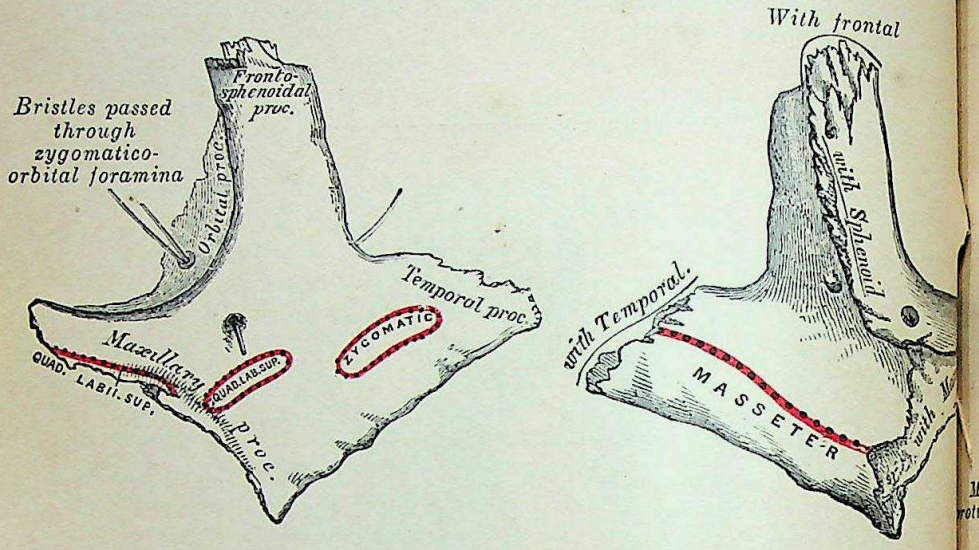

temporal and infratemporal fossæ. Its *anterior margin*, smooth and ro is part of the circumference of the base of the orbit. Its *superior* rough, and directed horizontally, articulates with the frontal bone the zygomatic process. Its *posterior margin* is serrated for articulatio the great wing of the sphenoidal bone above, and the orbital surface maxilla below. Between these two serrated portions there is usually a concave, non-articular part which forms the anterior boundary of the orbital fissure. This non-articular part is sometimes absent, and the fis then completed by the junction of the maxilla and the sphenoidal bone, the interposition of a small sutural bone in the angular interval between

The *infra-orbital process* is pointed and articulates with the maxilla, the infra-orbital foramen.

The *temporal process* is directed backwards and ends in an oblique, s margin which articulates with the zygomatic process of the temporal bo

Ossification.—The zygomatic bone is ossified from one centre which about the eighth week of fœtal life. The bone is sometimes divided by a ho suture into an upper larger, and a lower smaller division.

THE MANDIBLE (MANDIBULA)

The **mandible**, the largest and strongest bone of the face, consis curved, horizontal portion, the *body*, from the ends of which two perpen portions, the *rami*, project upwards.

* S. E. Whitnall, *The Anatomy of the Human Orbit*, 1921.—The structures attache tubercle are: (1) the "check ligament" of the Rectus lateralis; (2) part of the ap of the Levator palpebræ superioris; (3) the suspensory ligament of the eyeball; and lateral palpebral ligament.

CC-0. In Public Domain. Gurukul Kangri Collection, Haridwar

Digitized by Arya Samaj Foundation Chennai and eGangotri

The body of the mandible is curved somewhat like a horseshoe, and has two faces and two borders. The *external surface* (fig. 339) is marked in the upper t of the median line by a faint ridge, indicating the *symphysis* or junction of two pieces of which the bone is composed at an early period of life. This e divides below and encloses a triangular eminence, the *mental protuberance*, base of which is depressed in the centre but raised on either side to form *mental tubercle*. On either side of the ridge, just below the incisor teeth, he *incisive fossa*, which gives origin to the Mentalis and to a small portion he Orbicularis oris. Below the second premolar tooth, and about midway ween the upper and lower borders of the body, is the *mental foramen*, for

FIG. 339.—The left half of the mandible. Lateral aspect.

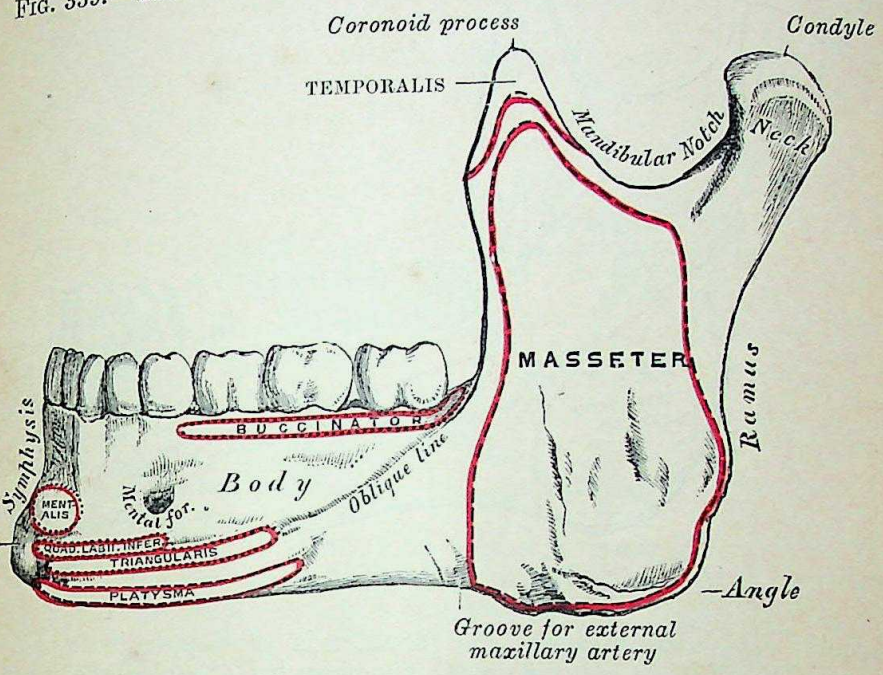

exit of the mental vessels and nerve. Running backwards and upwards m the mental tubercle is a faint ridge, the *oblique line*, which is continuous h the anterior border of the ramus; the Quadratus labii inferioris and angularis are attached to it, and the Platysma below it.

The *internal surface* (fig. 340) is concave from side to side. Near the lower of the symphysis is a pair of laterally placed spines, termed the *mental nes*, which give origin to the Genioglossi. Immediately below these is a ond pair of spines, or more frequently a median ridge or impression, for the gins of the Geniohyoidei. In some bones the mental spines are fused to form ingle eminence; in others they are absent, and their position is indicated rely by an irregularity of the surface. Above the mental spines a median amen and furrow are sometimes present; they mark the line of union of the ves of the bone. Below the mental spines, on either side of the middle line, an oval depression, the *digastric fossa*, for the attachment of the anterior ly of the Digastricus. Extending upwards and backwards on either side from e lower part of the symphysis to a point behind the last molar tooth is the *lohyoid line* which gives origin to the Mylohyoideus; the posterior part this line, near the alveolar margin, gives attachment to a small part of the nstrictor pharyngis superior, and to the pterygomandibular raphe. Above e anterior part of this line is a smooth triangular area against which the blingual gland rests, and below the posterior part, an oval fossa for a part he submaxillary gland.

The *alveolar part* or upper portion of the body is hollowed into sixteenities or alveoli, for the reception of the roots of the teeth; these cavities y in depth and size, and are single or subdivided by septa, according to teeth which they contain. From the external surface of the alveolar part Buccinator takes origin as far forwards as the first molar tooth. The

CC-0.In Public Domain. Gurukul Kangri Collection, Haridwar

Digitized by Arya Samaj Foundation Chennai and eGangotri

inferior border or *base* of the mandible is rounded, and is thicker in fr behind: at the point where it is continuous with the lower border of th a shallow groove, for the external maxillary artery, may be present.

The **ramus** of the mandible is quadrilateral in shape, and has two four borders, and two processes. The *lateral surface* (fig. 339) is marked by oblique ridges at its lower part; it gives attachment th nearly the whole of its extent to the Masseter. The *medial surface* presents about its centre the *mandibular foramen*, which transmits the

Fig. 340.—The left half of the mandible. Medial aspect.

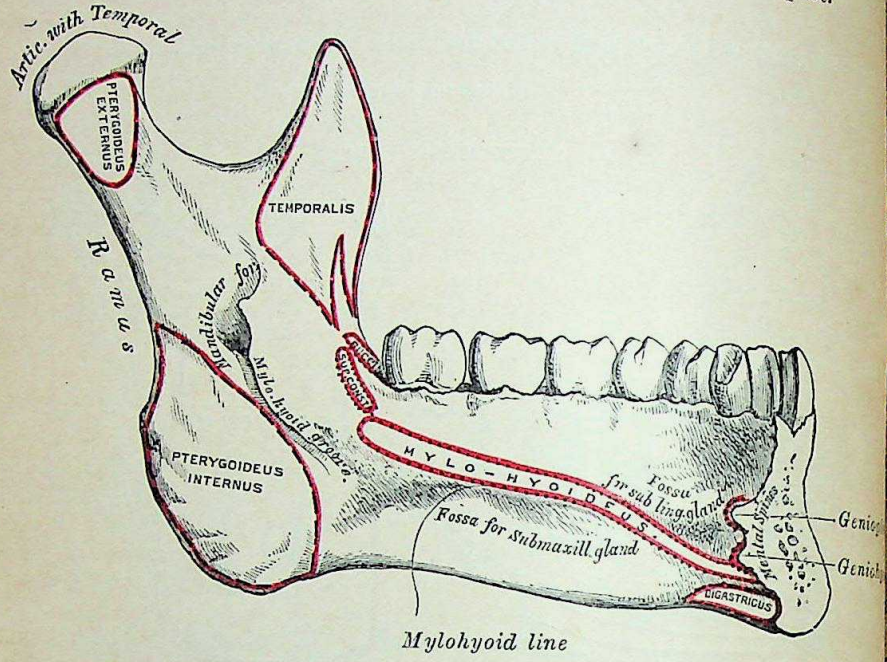

alveolar vessels and nerve. The foramen is overlapped in front by a tri process, the *lingula mandibulæ*, to the margins of which the sphenoman ligament is attached. Behind the lingula is a notch from which the my *groove* runs obliquely downwards and forwards; this groove lodges the hyoid vessels and nerve. Behind the groove is a rough surface for the in of the Pterygoideus internus. Into the anterosuperior part of the surface a portion of the Temporalis is inserted. The *lower border* of the is thick, straight, and continuous with the inferior border of the body bone. At its junction with the posterior border is the *angle* of the ma which may be either inverted or everted, and is marked by rough, oblique on either surface, for the insertion of the Masseter laterally, and the Pterg internus medially; the stylomandibular ligament is attached to the between these muscles. The *border*, thin above and thick is continuous with the oblique The *posterior border*, thick, and rounded, is covered b parotid gland. The *upper* is surmounted by two pro the *coronoid* in front and th *dyloid* behind; these are sep by a deep concavity, the *bular notch*, which transmi masseteric nerve and vessels.

Fig. 341.—The right half of the mandible of a human embryo 24 mm. long. Lateral aspect. (From a model by Low.)

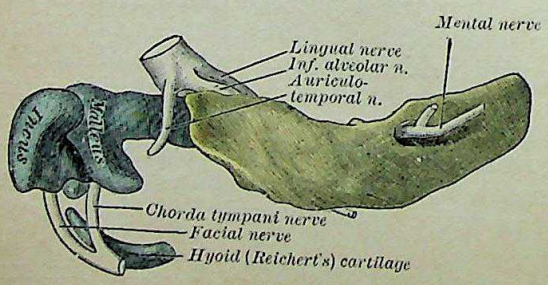

The *coronoid process* of mandible is a thin, tria eminence, which is flattened side to side. Its *anterior border* is convex and is continuous below wi anterior border of the ramus; its *posterior border* is concave and form anterior boundary of the mandibular notch. Its *lateral surface* is smoot

CC-0. In Public Domain. Gurukul Kangri Collection, Haridwar

Digitized by Arya Samaj Foundation Chennai and eGangotri

rds insertion to the Masseter and Temporalis. Its *medial surface* gives rtion to the Temporalis, and presents a ridge which begins near the apex he process and runs downwards and forwards to the medial side of the molar tooth. Between this ridge and the anterior border is a grooved gular area, the upper part of which gives attachment to the Temporalis, lower part to some fibres of the Buccinator.

The *condyloid process* of the mandible is thicker than the coronoid process, consists of two portions; the condyle, and the constricted neck which orts it. The *condyle* articulates with the articular disc of the temporo-dibular joint; it is convex from before backwards and from side to side, its articular surface extends lower on the posterior than on the anterior ace. The long axis of the condyle is directed medialwards and slightly wards, and if prolonged to the middle line will meet that of the opposite yle near the anterior gin of the foramen num. At the lateral emity of the con- is a small tubercle the attachment of mandibular liga- The *neck* is ened from before kwards, and strength- d by ridges which end from the sides the lateral part of front of the condyle. posterior surface is vex; on its anterior surface is a depression, the *pterygoid fovea*, for the chment of the Pterygoideus externus.

FIG. 342.—The right half of the mandible of a human embryo 24 mm. long. Medial aspect. (From a model by Low.)

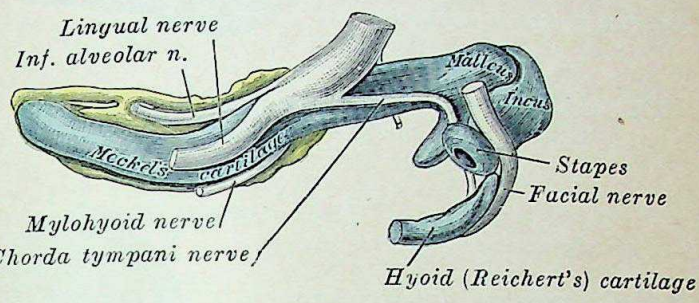

The *mandibular canal* runs from the mandibular foramen obliquely down- rds and forwards in the ramus, and then horizontally forwards in the body eath the alveoli, with which it communicates by small openings. It contains inferior alveolar vessels and nerve, from which branches enter the roots of teeth. Between the roots of the first and second premolar teeth the ndibular canal divides into the *mental* and *incisive canals*; the mental al runs upwards, backwards and lateralwards and ends at the mental men; the incisive canal is continued forward below the incisor teeth.

Ossification.—The mandible is ossified in the fibrous membrane covering the er surfaces of Meckel's cartilages. These two cartilages, a right and a left, the cartilaginous bar of the mandibular arch (p. 76). Their dorsal or cranial are connected with the cartilaginous ear-capsules, and their ventral ends joined to one another by mesodermal tissue. They run forwards immediately ow the mandibular condyles and then, bending downwards, lie in a groove near lower border of the bone; in front of the canine teeth they incline upwards he symphysis. From the proximal end of each cartilage the malleus and incus, of the three ossicles of the middle ear, are developed; the next succeeding tion, as far as the lingula of the mandible, is replaced by fibrous tissue which ns the sphenomandibular ligament. Between the lingula and the canine tooth cartilage disappears, whilst the portion of it below and behind the incisor th is ossified and incorporated with this part of the mandible.

Ossification takes place in the membrane covering the outer surfaces of Meckel's tilages (figs. 341 to 344), and each half of the bone is formed from one centre* ich appears, near the mental foramen, about the sixth week of fœtal life. By tenth week the portion of Meckel's cartilage which lies below and behind the isor teeth is surrounded and invaded by the membrane-bone. Somewhat later, essory pieces of cartilage make their appearance—viz. a wedge-shaped piece in condyloid process and extending downwards through the ramus; a small patch g the anterior border of the coronoid process; and smaller nodules in the front t of both alveolar walls and along the front of the lower border of the bone.

* A. Low, *Proceedings of the Anatomical and Anthropological Society of the University of Aberdeen*, 5, and *Journal of Anatomy and Physiology*, vol. xliv., and E. Fawcett, *Journal of the American dical Association*, September 3, 1905.

CC-0. In Public Domain. Gurukul Kangri Collection, Haridwar

Digitized by Arya Samaj Foundation Chennai and eGangotri

These accessory nodules of cartilage possess no separate ossific centres, b invaded by the surrounding membrane-bone and undergo absorption. Th alveolar border, formerly described as arising from a separate *splenial* ce

FIG. 343.—The right half of the mandible of a human embryo 95 mm. long. I aspect. (The nuclei of cartilage are stippled.) (From a model by Low.)

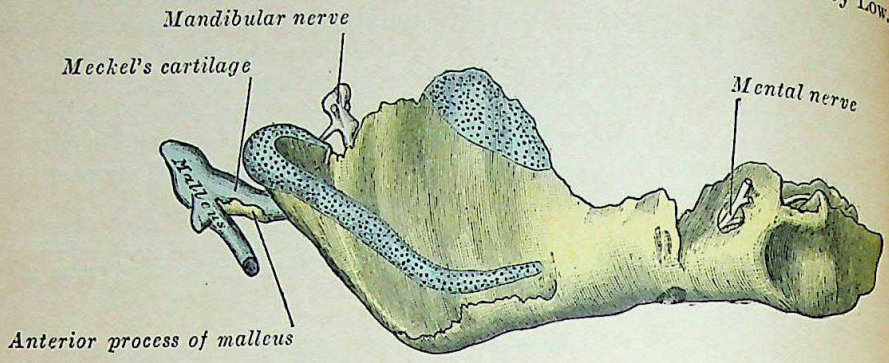

FIG. 344.—The right half of the mandible of a human embryo 95 mm. long. Me aspect. (The nuclei of cartilage are stippled.) (From a model by Low.)

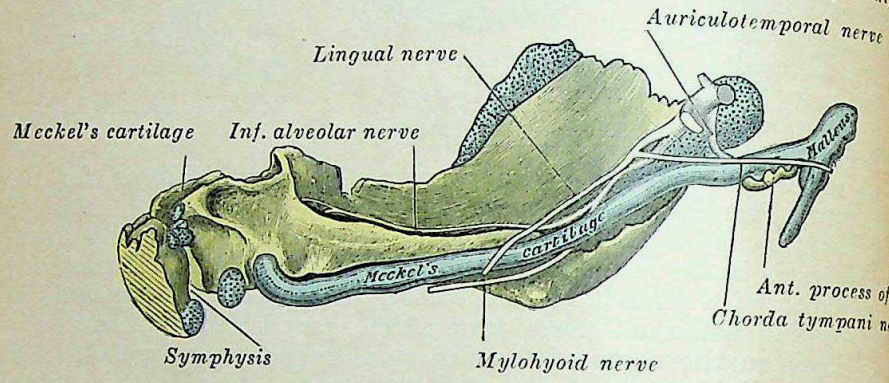

formed in the human mandible by an ingrowth from the main mass of the At birth the bone consists of two parts, united by a fibrous symphysis, in ossification takes place during the first year.

THE CHANGES PRODUCED IN THE MANDIBLE BY AGE

At birth (fig. 345) the body of the bone is a mere shell, containing on either sid sockets of the deciduous teeth, imperfectly partitioned off from one another. mandibular canal runs near the lower border of the bone, and the mental foramen beneath the socket of the first deciduous molar tooth. The angle is obtuse (175°), an condyloid portion is nearly in line with the body. The coronoid process is relat large, and projects above the level of the condyle.

After birth (fig. 346) the two segments of the bone become joined at the sym from below upwards, in the first year; but a trace of separation may be visible beginning of the second year, near the alveolar margin. The body elongates, but especially behind the mental foramen to provide space for the three additional developed in this part. The depth of the body increases by growth of the alveolar of the bone, to afford room for the roots of the teeth, and by thickening of the alveolar portion. After the second dentition, the mandibular canal is situated just the level of the mylohyoid line, and the mental foramen occupies the position usual in the adult. By the fourth year the angle is reduced to about 140°.

In the adult (fig. 347) the alveolar and subalveolar portions of the body are of equal depth. The mental foramen opens midway between the upper and lower borde the bone, and the mandibular canal runs nearly parallel with the mylohyoid line. ramus is almost vertical in direction, the angle measuring from 110° to 120°.

In old age (fig. 348) the bone is reduced in size, for with the loss of the teeth alveolar process is absorbed, and, consequently, the mandibular canal and the m foramen are close to the alveolar border. The ramus is oblique in direction, the measures about 140°, and the neck of the condyle is more or less bent backwards.

CC-0. In Public Domain. Gurukul Kangri Collection, Haridwar

Digitized by Arya Samaj Foundation Chennai and eGangotri

THE MANDIBLE AT DIFFERENT PERIODS OF LIFE. LEFT LATERAL ASPECT.

FIG. 345.—At birth.

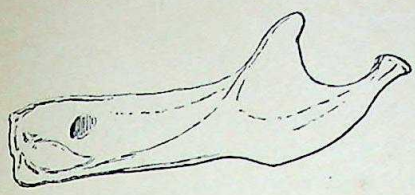

FIG. 346.—In childhood.

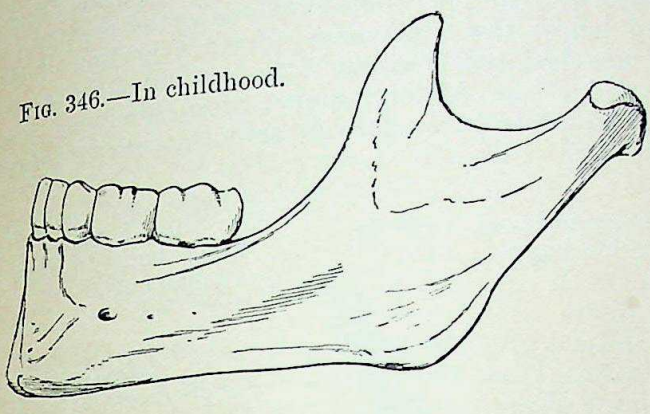

FIG. 347.—In the adult.

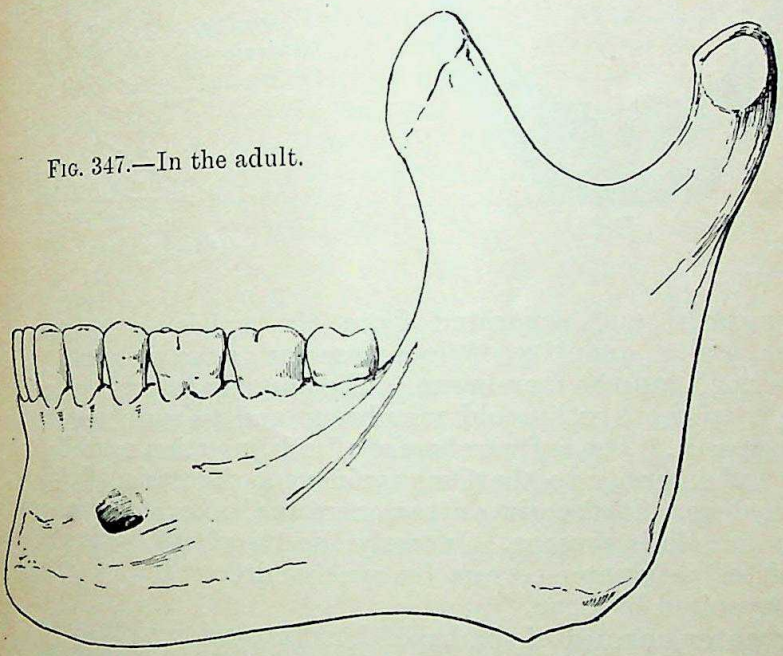

FIG. 348.—In old age.

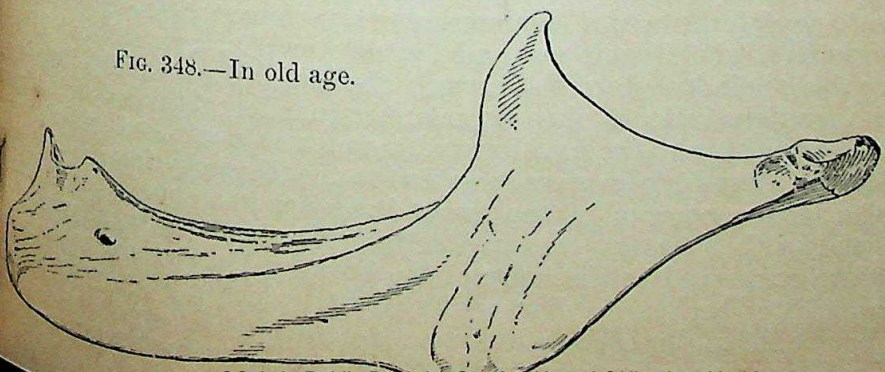

CC-0. In Public Domain. Gurukul Kangri Collection, Haridwar

Digitized by Arya Samaj Foundation Chennai and eGangotri

The Hyoid Bone (Os Hyoideum)

The **hyoid bone** (fig. 349) is U-shaped, and is suspended from the the styloid processes of the temporal bones by the stylohyoid ligame consists of a body, two greater and two lesser cornua.

The **body** or central part of the hyoid bone is of a quadrilateral fo *anterior surface* is convex and directed forwards and upwards. Its up is crossed by a well-marked ridge which has a slight downward co and in many cases a vertical median ridge divides the body into lateral The portion of the vertical ridge above the transverse line is present in a r of specimens, but that below the transverse line is rarely seen. The surface gives insertion to the Geniohyoideus in the greater part of its both above and below the transverse ridge; a portion of the origin Hyoglossus notches the lateral margin of the Geniohyoideus attachment. the transverse ridge the Mylohyoideus, Sternohyoideus, and Omoh are inserted. The *posterior surface* is smooth, concave, directed bac

Fig. 349.—The hyoid bone. Antero-superior aspect.

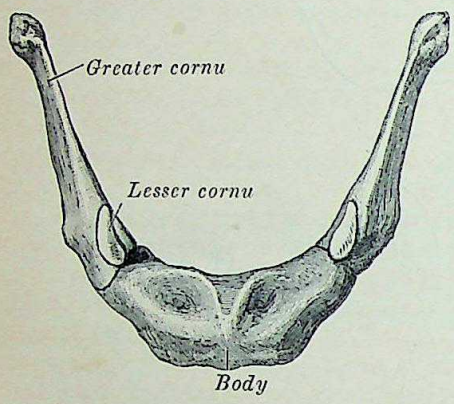

Fig. 350.—A sketch of left half of hyoid bone to show the musc attachments.

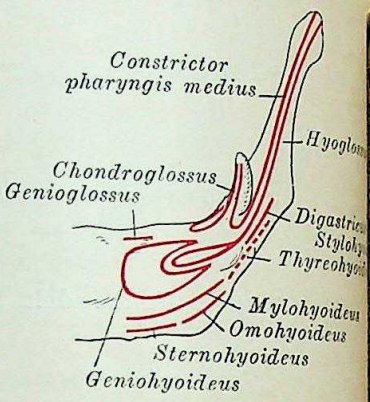

and downwards, and separated from the epiglottis by the hyoth membrane and a quantity of loose areolar tissue; a bursa interven tween the bone and the membrane. The *superior border* is rounded, and attachment to the hyothyreoid membrane and to some aponeurotic fi the Genioglossus. The *inferior border* affords insertion medially to the S hyoideus and laterally to the Omohyoideus and occasionally a portion o Thyreohyoideus. It also gives attachment to the Levator glandulæ thyre when this muscle is present. In early life the *lateral borders* of the bo connected to the greater cornua by synchondroses, but after middle lif are usually united by bone.

The **greater cornua** of the hyoid bone project backwards from the borders of the body; they are flattened from above downwards and di in size from before backwards. Each cornua ends posteriorly in a tube which the lateral hyothyreoid ligament is fixed. The *upper surface* is close to its lateral border, for muscular attachments: the largest of the the origins of the Hyoglossus and Constrictor pharyngis medius which along the whole length of the cornu; the Digastricus and Stylohyoideu small insertions in front of these, near the junction of the body with the To the *medial border* the hyothyreoid membrane is attached, while the an half of the *lateral border* gives insertion to the Thyreohyoideus.

The **lesser cornua** of the hyoid bone are two small, conical emin attached by their bases at the angles of junction of the body and greater co They are connected to the body of the bone by fibrous tissue and occasio to the greater cornua by diarthrodial joints, which usually persist throu life, but occasionally become ankylosed.

The lesser cornua are situated in the line of the transverse ridge on the

CC-0. In Public Domain. Gurukul Kangri Collection, Haridwar

Digitized by Arya Samaj Foundation Chennai and eGangotri

appear to be morphological continuations of it. The apex of each cornu attachment to the stylohyoid ligament †; the Chondroglossus rises from medial side of the base.

Ossification.—The hyoid bone is developed from the cartilages of the second third branchial or visceral arches—the lesser cornua from the second, the er cornua from the third, and the body from the fused ventral ends of both s (p. 77). It is ossified from six centres: two for the body, and one for each n. Ossification commences in the greater cornua towards the end of fœtal in the body before or shortly after birth, and in the lesser cornua during the or second year, or later.

THE EXTERIOR OF THE SKULL

he skull as a whole may be viewed from above (norma verticalis), from w (norma basalis), from the side (norma lateralis), from behind (norma vitalis), or from the front (norma frontalis).

Norma Verticalis

When viewed from above, the outline of the skull varies greatly in different imens; in some it is more or less oval, in others more nearly circular. The face is traversed by three sutures, viz.: (1) the coronal, nearly transverse in ction, between the frontal and parietal bones; (2) the sagittal, in the dian plane, between the parietal bones, and deeply serrated in its anterior thirds; and (3) the upper part of the lambdoid, between the occipital and etal bones. The point of junction of the sagittal and coronal sutures med the bregma, that of the sagittal and lambdoid sutures, the lambda; indicate respectively the positions of the anterior and posterior fonticuli e fœtal skull. On either side of the sagittal suture are the parietal tubero- or eminence and the parietal foramen—the latter, however, is frequently nt on one or both sides. The skull is often somewhat flattened in the hbourhood of the parietal foramina, and the term obelion is applied to that t of the sagittal suture which is on a level with the foramina. At the t of the skull are the frontal tuberosities or eminences; below these are superciliary arches, joined to one another by the elevation of the glabella. ediately above the glabella the remains of the frontal suture may be seen; ancy this suture divides the frontal bone into two parts, a condition which is in about 9 per cent. of skulls. Passing backwards and upwards from zygomatic processes of the frontal bone are the temporal lines, which mark upper limits of the temporal fossæ. The zygomatic arches may or may not een projecting beyond the anterior portions of these lines.

Norma Basalis (Basis Cranii Externa) (figs. 351, 352)

The external surface of the base of the skull, exclusive of the mandible, is nded in front by the incisor teeth in the maxillæ; behind, by the superior al lines of the occipital bone; and laterally by the alveolar arch, the lower der of the zygomatic bone, the zygomatic arch and an imaginary line drawn n this arch to the mastoid process of the temporal bone and the superior al line of the occipital bone. The anterior part or hard palate projects w the level of the rest of the surface, and is bounded in front and laterally by alveolar arch containing the sixteen teeth of the maxillæ (fig. 329). Immedi- behind the incisor teeth is the incisive foramen. In this foramen are ateral apertures, the openings of the incisive canals (foramina of Stensen); of these leads upwards into the corresponding nasal cavity and transmits

* F. G. Parsons, *Journal of Anatomy and Physiology*, vol. xliii.

† These ligaments may undergo partial ossification.

CC-0. In Public Domain. Gurukul Kangri Collection, Haridwar

Digitized by Arya Samaj Foundation Chennai and eGangotri

the terminal branches of the greater palatine vessels and the nasopalatine
Occasionally there are two additional apertures (foramina of Scarpa)
middle line; when these foramina are present the nasopalatine nerve
through them instead of through the foramina of Stensen, the left

FIG. 351.—The external surface of the left half of the base of the skull. (Norma basalis.)

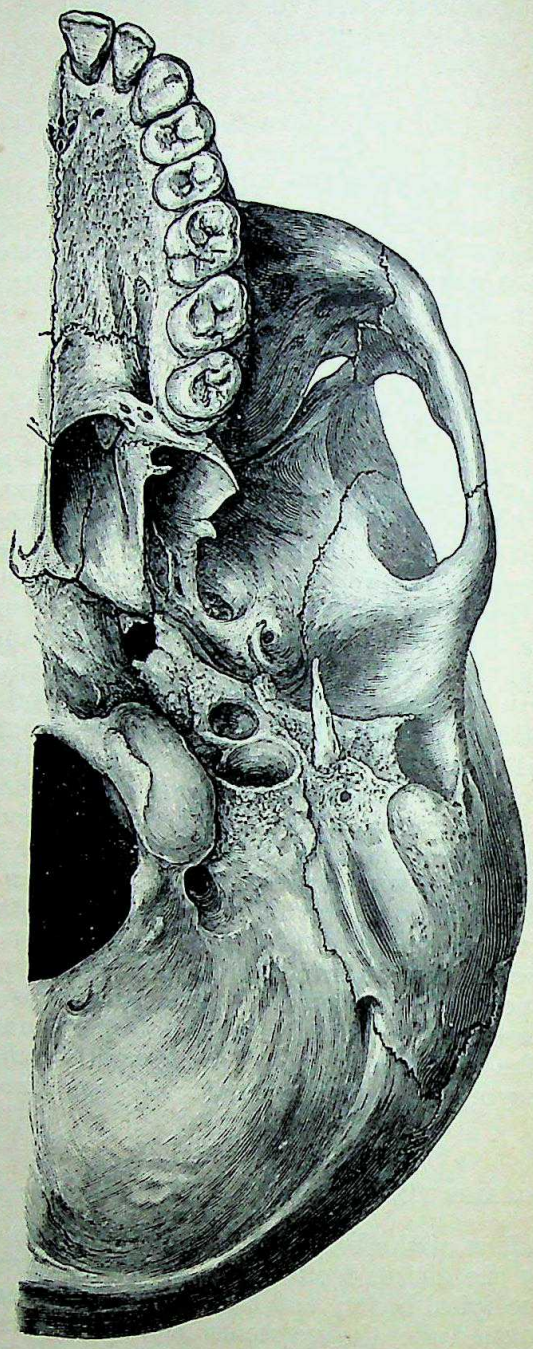

being usually transmitted through the anterior, and the right through
posterior foramen. The vault of the hard palate is concave, uneven, perfo
by numerous foramina, and marked by depressions for the palatine gla
its posterior part is traversed by a cruciate suture formed by the junction of
four bones of which it is composed. In the young skull a suture may be pre
extending on either side from the incisive foramen to the interval betwee
lateral incisor and canine teeth, and marking off in front of it the os inci
or premaxillary bone. At either posterior angle of the hard palate

CC-0. In Public Domain. Gurukul Kangri Collection, Haridwar

Digitized by Arya Samaj Foundation Chennai and eGangotri

er palatine foramen, for the transmission of the greater palatine vessels he anterior palatine nerve; and running forwards and medialwards from oramen are two grooves, for the same vessels and nerve. Behind the er palatine foramen is the pyramidal process of the palatine bone, per-

FIG. 352.—Key to fig. 351.

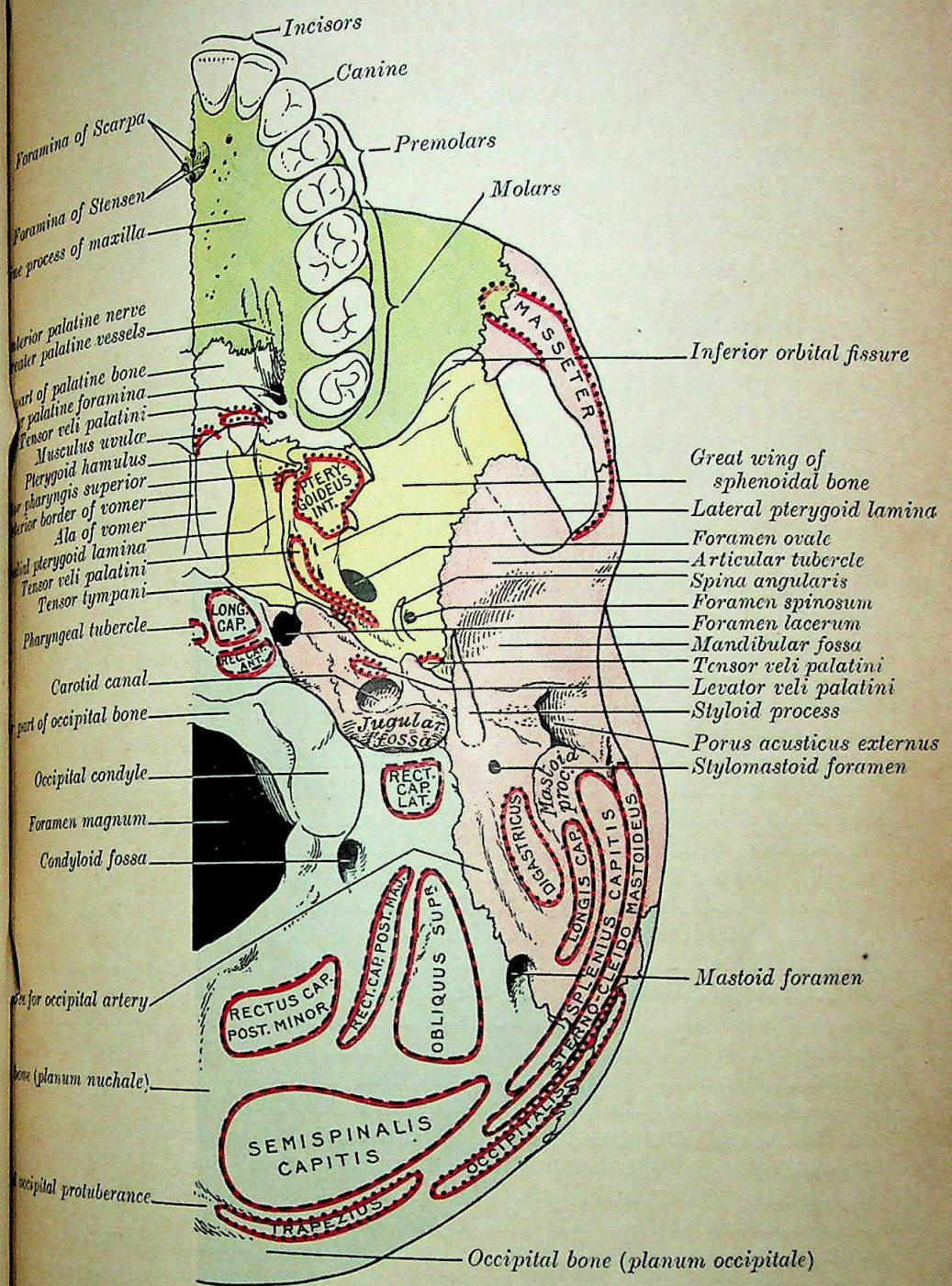

ted by two or three lesser palatine foramina, and marked by a curved e which is continued on the horizontal part of the bone, and gives attach- to part of the aponeurosis of the Tensor veli palatini. Projecting back- from the middle of the posterior border of the hard palate is the posterior spine, from which the Musculus uvulæ takes origin.

Behind and above the hard palate are the choanæ, each measuring about cm. vertically and 1·25 cm. transversely. They are separated from one her by the vomer and each is bounded above by the body of the sphenoidal

CC-0. In Public Domain. Gurukul Kangri Collection, Haridwar

Digitized by Arya Samaj Foundation Chennai and eGangotri

bone and the vaginal process of the medial pterygoid lamina, below horizontal part of the palatine bone, and laterally by the medial pl lamina. At the superior border of the vomer are the expanded al bone, which receive between them the rostrum of the sphenoidal b articulate laterally with the sphenoidal processes of the palatine bone vaginal processes of the medial pterygoid laminæ. Below the vaginal are the pharyngeal canals. The medial pterygoid lamina is long and lateral to its upper part is the scaphoid fossa, for the origin of the Te palatini; this muscle descends in contact with the medial surface of the and its tendon turns round the hamulus at the lower end of the lam the upper end of the medial pterygoid lamina is the pterygoid tuber immediately above this tubercle, the posterior end of the pterygoi The lateral pterygoid lamina is broad; its lateral surface forms the boundary of the infratemporal fossa, and gives origin to the lower hea Pterygoideus externus. Its medial surface forms the lateral wall of th goid fossa, and gives origin to the greater part of the Pterygoideus inte

Behind the choanæ are the posterior part of the body of the sphenoi and the basilar portion of the occipital bone; near the centre of the the pharyngeal tubercle for the attachment of the fibrous raphe of the p and on either side of the middle line are depressions for the inser the Longus capitis and Rectus capitis anterior. Behind the upper end lateral pterygoid lamina is the foramen ovale, for the transmission mandibular nerve, the accessory meningeal artery, and sometimes th superficial petrosal nerve; behind the foramen ovale are the foramen sp and the spina angularis of the sphenoidal bone; the former transm middle meningeal artery and the nervus spinosus, the latter gives atta to the sphenomandibular ligament and to a part of the Tensor veli p Lateral to the spina angularis is the mandibular fossa, divided into tw by the petrotympanic fissure; the anterior portion of the fossa, c smooth and bounded in front by the articular tubercle, articulates w articular disc of the mandibular joint; the posterior portion, bounded by the tympanic part of the temporal bone, is sometimes occupied by of the parotid gland. Emerging from the vagina processus styloide tympanic part of the temporal bone is the styloid process; and bet upper end of this process is the stylomastoid foramen, for the exit of th nerve, and entrance of the stylomastoid artery. Lateral to the stylo foramen, between the tympanic part and the mastoid process, is the ty mastoid fissure, which gives exit to the auricular branch of the vagu Medial to the mastoid process is the mastoid notch (digastric fossa) posterior belly of the Digastricus, and medial to the mastoid notch, the for the occipital artery. At the base of the medial pterygoid lamina foramen lacerum, bounded anteriorly by the great wing of the sphenoid posteriorly and laterally by the apex of the petrous portion of the te bone, and medially by the body of the sphenoidal bone and the basilar of the occipital bone; it presents in front, the posterior orifice of the pt canal; behind, the superior aperture of the carotid canal. In the recen the lower part of the foramen lacerum is filled up by a fibrocartilaginous on the upper surface of which the internal carotid artery rests. Betw petrous part of the temporal bone and the great wing of the sphenoid is the sulcus tubæ auditivæ. This sulcus, directed lateralwards and back lodges and gives attachment to the cartilaginous part of the auditory and is continuous behind with the semicanalis tubæ auditivæ in the te bone. In the floor of this sulcus is the petrosphenoidal fissure, occup the recent condition, by a plate of cartilage. Behind this fissure is the surface of the petrous portion of the temporal bone, presenting, near its a quadrilateral rough surface, part of which gives origin to the Levat palatini; lateral and posterior to this surface is the inferior orifice of the canal, and medial to this orifice, the depression leading to the aqua cochleæ. Behind the inferior orifice of the carotid canal is the jugular fo formed in front and laterally by the petrous portion of the temporal behind and medially by the occipital bone; it is generally larger on th than on the left side of the skull. The anterior part of the jugular fo transmits the inferior petrosal sinus; the intermediate, the glossopharyn

CC-0. In Public Domain. Gurukul Kangri Collection, Haridwar

Digitized by Arya Samaj Foundation Chennai and eGangotri

and accessory nerves; the posterior, the transverse sinus and some ngeal branches from the occipital and ascending pharyngeal arteries. On dge of bone between the inferior orifice of the carotid canal and the jugular en is the inferior tympanic canaliculus for the passage of the tympanic h of the glossopharyngeal nerve, and in the lateral part of the jugular en, near the root of the styloid process, is the mastoid canaliculus for the ge of the auricular branch of the vagus nerve. Running from the jugular en to the foramen lacerum is the petro-occipital fissure, occupied, in the t state, by a plate of cartilage. Behind the basilar portion of the occipital is the foramen magnum which transmits the medulla oblongata and its branes, the spinal parts of the accessory nerves, the vertebral arteries, nterior and posterior spinal arteries, and the ligaments connecting the ital bone with the epistropheus or axis vertebra. Lateral to the anterior of the foramen magnum are the occipital condyles for articulation with las vertebra; the medial side of each condyle is rough for the attachment e alar ligament. Lateral to the condyle is the jugular process of the ital bone, which gives attachment to the Rectus capitis lateralis. In front e condyle is the hypoglossal canal for the passage of the hypoglossal and a meningeal artery. Behind the condyle is the condyloid fossa, t is sometimes perforated by the condyloid canal for the transmission of n from the transverse sinus. Behind the foramen magnum is the n nuchal line, ending above at the external occipital protuberance; on side are the superior and inferior nuchal lines, which, with the surfaces ne between them, are rough for the attachment of the muscles enumerated 196.

Norma Lateralis (fig. 353)

When viewed from the side the skull is seen to consist of the cranium above behind, and the face below and in front. The cranium is somewhat ovoid hape, but its contour varies in different cases, and depends largely on the th and height of the skull and on the degree of prominence of the superciliary es and frontal tuberosities. Entering into its formation are the frontal, etal, occipital, temporal, and sphenoidal bones. These bones are joined e another by the coronal, sphenofrontal, sphenoparietal, sphenosquamosal, mosal, parietomastoid and lambdoid sutures. The sphenoparietal suture es in length in different skulls, and is absent in those cases where the tal bone articulates with the temporal squama; the posterior end of the enoparietal suture is named the pterion. The squamosal suture arches wards from the pterion and connects the temporal squama with the lower er of the parietal bone; it is continuous behind with the short, nearly ontal parietomastoid suture which unites the mastoid process of the ral bone with the mastoid angle of the parietal bone. Extending across cranium are the coronal and lambdoid sutures; the former connects the tal and parietal bones; the latter, the occipital and parietal bones. The bdoid suture is continuous below with the occipitomastoid suture between occipital bone and the mastoid portion of the temporal bone; in or near latter suture is the mastoid foramen which transmits an emissary vein. Immediately above the orbital margin is the superciliary arch, and, at a er level, the frontal tuberosity. Near the centre of the parietal bone is parietal tuberosity. Posteriorly is the external occipital protuberance, n which the superior nuchal line may be followed to the mastoid process. temporal lines arch across the side of the cranium and mark the upper it of the temporal fossa.

The *temporal fossa* is bounded above and behind by the temporal lines, ich extend from the zygomatic process of the frontal bone upwards and wards across the frontal and parietal bones, and then curve downwards forwards to the temporal bone to become continuous with the supra- oid crest and the posterior root of the zygomatic arch. The temporal a is bounded in front by the frontal and zygomatic bones; opening on latter is the zygomaticotemporal foramen. Laterally the fossa is limited the zygomatic arch; below, it is separated from the infratemporal fossa the infratemporal crest on the great wing of the sphenoidal bone, and by a

CC-0. In Public Domain. Gurukul Kangri Collection, Haridwar

Digitized by Arya Samaj Foundation Chennai and eGangotri

ridge which runs backwards from this crest across the temporal squa
anterior root of the zygomatic process. The floor of the fossa, deepl
in front, is formed by the zygomatic, frontal, parietal, sphenoidal, and
bones. It is traversed by vascular furrows: one, usually well mar
upwards above the opening of the external acoustic meatus, and l
middle temporal artery. Two others, frequently indistinct, may be
on the anterior part of the floor, and are for the anterior and poste
temporal arteries. The temporal fossa contains the Temporalis mu
its vessels and nerves, together with the zygomaticotemporal nerve.

Fig. 353.—The skull. Lateral aspect. (Norma lateralis.)

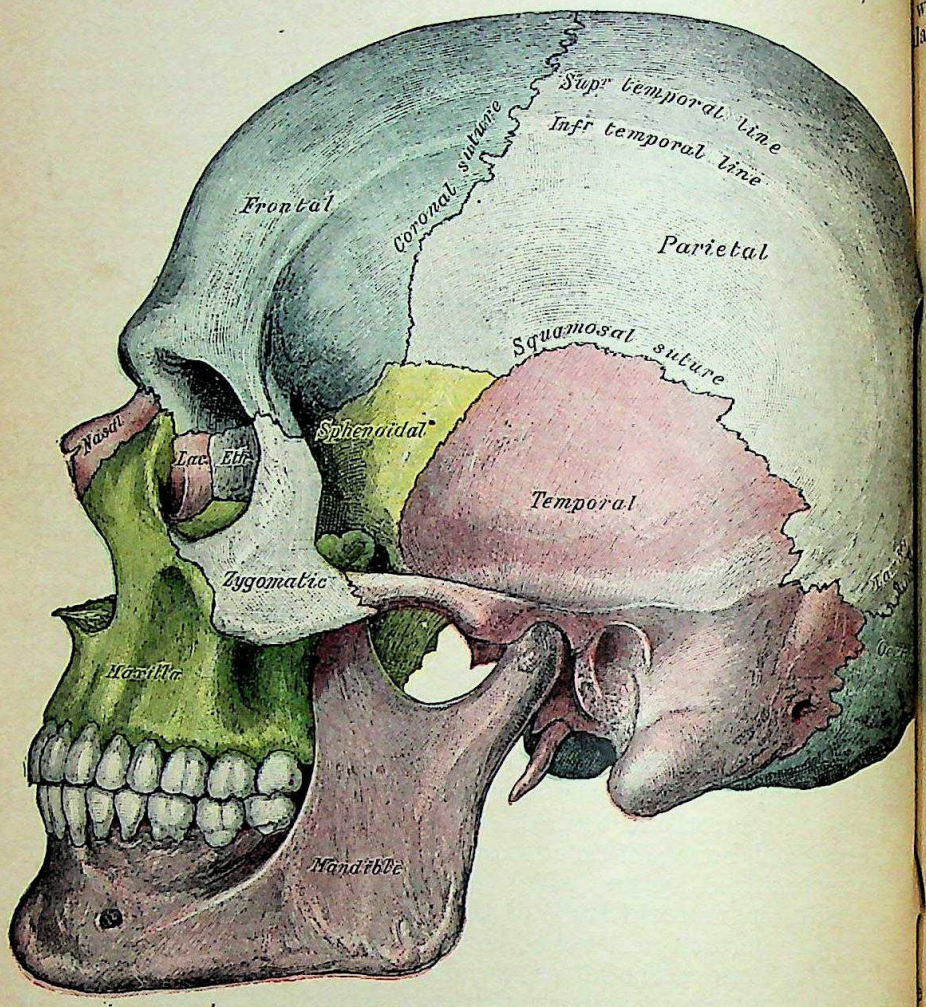

The *zygomatic arch* is formed by the union of the zygomatic process temporal bone with the temporal process of the zygomatic bone; the of the Temporalis descends on the medial side of the arch to gain ins into the coronoid process of the mandible. The zygomatic process temporal bone arises by two roots, an anterior, directed inwards in fr the mandibular fossa, where it expands to form the articular tubercle. posterior which runs backwards above the opening of the external a meatus and is continuous with the temporal line. The upper border zygomatic arch gives attachment to the temporal fascia; the lower and medial surface of the arch give origin to the Masseter.

Below the posterior root of the zygomatic arch is the porus ac externus, to the circumference of which the cartilaginous segment external acoustic meatus is attached. The small triangular area be the supramastoid crest and the posterosuperior part of the porus acu externus is termed the suprameatal triangle, and on the anterior bor this triangle, the suprameatal spine is sometimes seen. Between the tym

CC-0. In Public Domain. Gurukul Kangri Collection, Haridwar

Digitized by Arya Samaj Foundation Chennai and eGangotri

nd the articular tubercle is the mandibular fossa; behind the fossa yloid process extends downwards and forwards for a variable distance; es attachment to the Styloglossus, Stylohyoideus, and Stylopharyngeus es, and to the stylohyoid and stylomandibular ligaments. Projecting wards behind the porus acusticus externus is the mastoid process, to the surface of which the Sternoc leidomastoideus, Splenius capitis, and ssimus capitis are attached.

e *infratemporal fossa* (fig. 351) is an irregularly shaped space, situated l to the zygomatic arch and the coronoid process of the mandible. It nded in front by the infratemporal surface of the maxilla, and by a which ascends from the socket of the first molar tooth; behind, by the lar tubercle of the temporal bone and the spina angularis of the sphenoidal

Fig. 354.—The left infratemporal fossa.

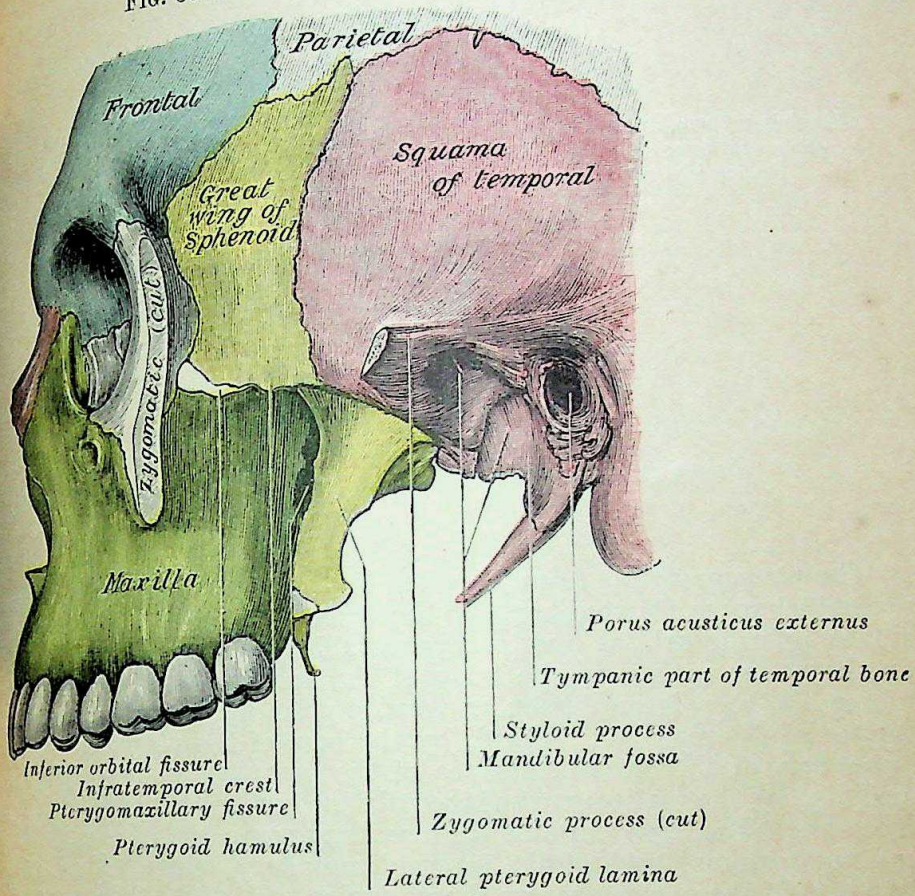

; above, by the great wing of the sphenoidal bone below the infratemporal , and a small triangular part of the temporal squama in front of the arti- r tubercle; below, by the alveolar border of the maxilla; medially, by ateral pterygoid lamina. It contains the lower part of the Temporalis, Pterygoidei internus et externus, the internal maxillary vessels, and the dibular and maxillary nerves. The foramen ovale and foramen spinosum on its roof, and the alveolar canals, on its anterior wall. At the upper medial part of the fossa are two fissures, which meet at a right angle, the zontal limb being the inferior orbital fissure, and the vertical limb the ygomaxillary fissure.

The *inferior orbital fissure* (sphenomaxillary fissure), nearly horizontal in ction, opens into the lateral and posterior part of the orbit. It is bounded by the lower border of the orbital surface of the great wing of the noidal bone; below, by the lateral border of the orbital surface of the illa and the orbital process of the palatine bone; laterally, by a small part e zygomatic bone *; medially, it joins at right angles with the pterygo-

* In from 35 to 40 per cent. of skulls the maxilla and the sphenoidal bone articulate with ther at the lateral end of this fissure, and exclude the zygomatic bone from it.

CC-0. In Public Domain. Gurukul Kangri Collection, Haridwar

Digitized by Arya Samaj Foundation Chennai and eGangotri

maxillary fissure. Through the inferior orbital fissure the orbit com- with the infratemporal and pterygopalatine fossæ; the fissure tran- maxillary nerve and its zygomatic (temporomalar) branch, the infr- vessels, the orbital branches of the sphenopalatine ganglion, and ve- connect the inferior ophthalmic vein with the pterygoid venous plex-

The *pterygomaxillary fissure* is vertical, and descends at right an- the medial end of the inferior orbital fissure; it is a triangular interva- by the divergence of the maxilla from the pterygoid process of the sp- bone. It connects the infratemporal fossa with the pterygopalatine f- transmits the terminal part of the internal maxillary artery.

Fig. 355.—A section showing the posterior wall of the pterygopalatine fossa.

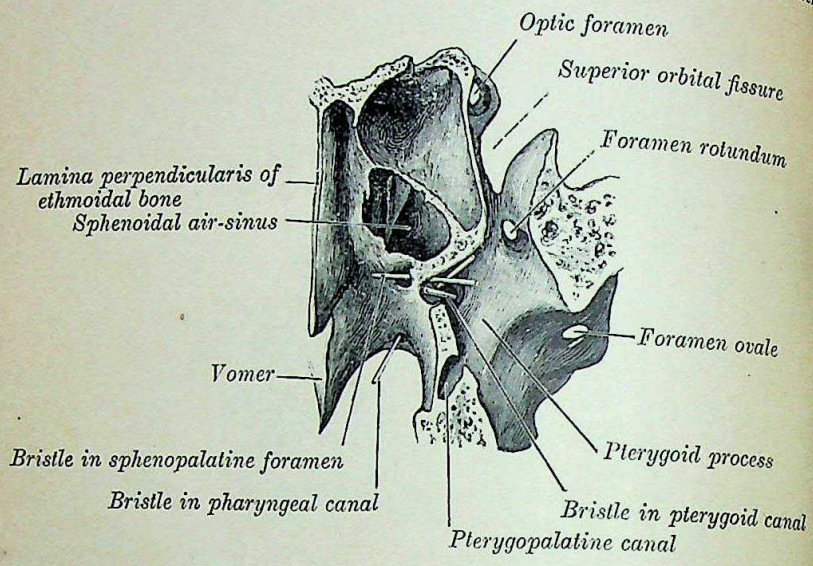

The *pterygopalatine fossa* (sphenomaxillary fossa) (figs. 355, 360) is a pyramidal space situated beneath the apex of the orbit at the angle of j- of the inferior orbital and pterygomaxillary fissures. It is bounded by the under surface of the body of the sphenoidal bone and by the process of the palatine bone; in front, by the upper part of the infrat- surface of the maxilla; behind, by the base of the pterygoid process a- lower part of the anterior surface of the great wing of the sphenoid- medially, by the vertical part of the palatine bone with its orbital and sph- processes. The fossa contains the maxillary nerve, the sphenopalatine gan- and the terminal part of the internal maxillary artery. Five foramin- into it. Of these, three are on the posterior wall, viz.: the foramen rotu- the pterygoid canal, and the pharyngeal canal, in this order downwar- medialwards; on the medial wall is the sphenopalatine foramen; b- the superior orifice of the pterygopalatine canal.

Norma Occipitalis

When viewed from behind, the cranium presents a more or less c- outline. In the upper portion of the middle line is the posterior part sagittal suture connecting the parietal bones; extending downward- lateralwards from the posterior end of this suture is the deeply serrated lam- suture joining the occipital and parietal bones, and continuous below w- parietomastoid and occipitomastoid sutures; the lambdoid suture fre- contains one or more sutural bones (fig. 325). Near the middle of the o- squama is the external occipital protuberance or inion, and, extending l- wards from it, the superior nuchal lines, and above these the faintly m- highest nuchal lines. The surface of the occipital bone above the inio- highest nuchal lines is named the planum occipitale, and is covered b- Occipitalis muscle; the surface below is termed the planum nuchale,

CC-0. In Public Domain. Gurukul Kangri Collection, Haridwar

Digitized by Arya Samaj Foundation Chennai and eGangotri

d by the medial nuchal line which runs downwards and forwards from on to the foramen magnum; this line gives attachment to the ligamentum The muscles attached to the planum nuchale are enumerated on Below and in front are the mastoid processes, convex laterally and d medially by the mastoid notches. In or near the occipitomastoid is the mastoid foramen for the passage of the mastoid emissary vein.

Norma Frontalis (fig. 356)

hen viewed from the front, the skull exhibits a somewhat oval outline, d above by the frontal bone, below by the body of the mandible, and lly by the zygomatic bones and the mandibular rami. The upper part,

Fig. 356.—The skull. Anterior aspect. (Norma frontalis.)

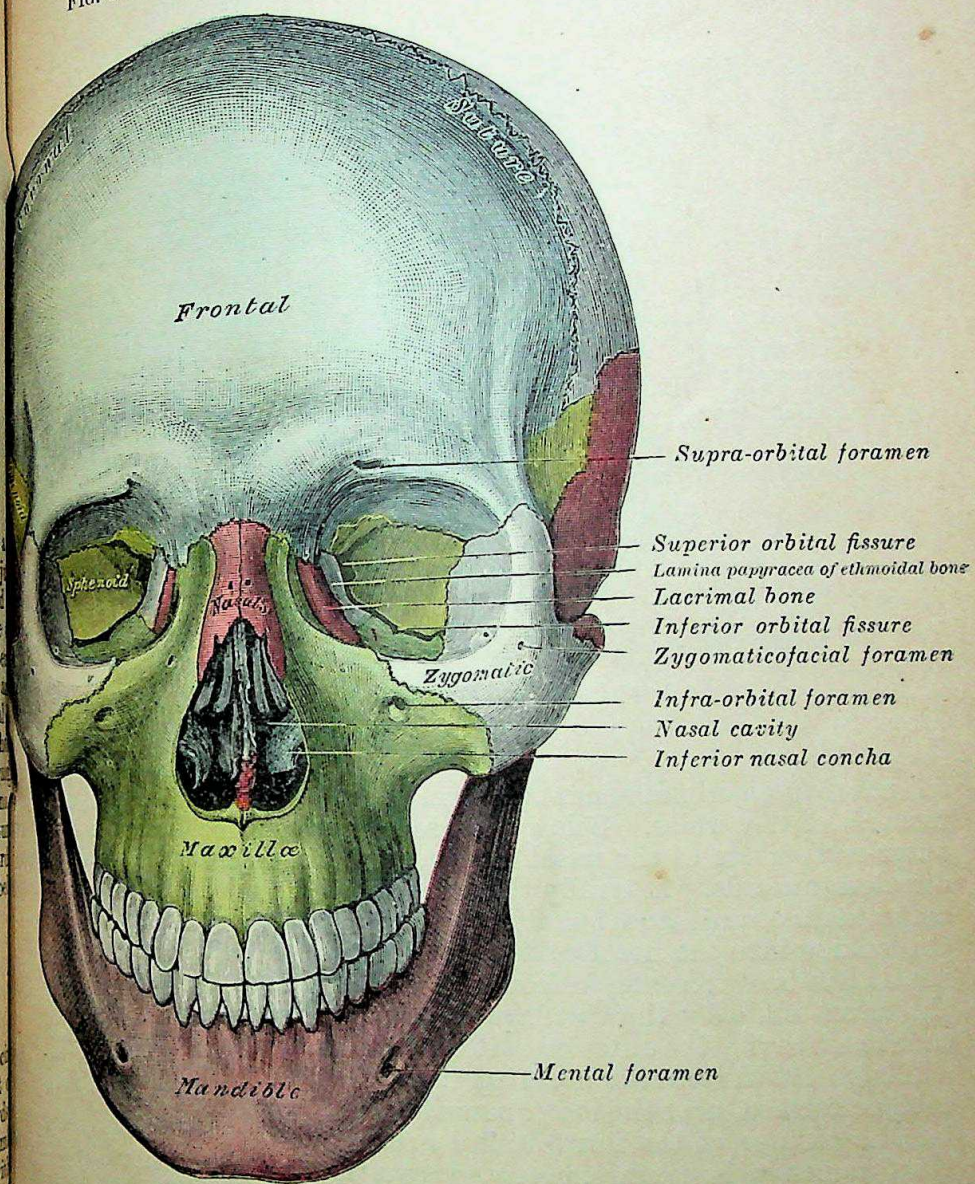

d by the frontal squama, is smooth and convex. The lower part, made the bones of the face, is irregular; it is excavated laterally by the orbital ies, and presents in the middle the anterior nasal aperture leading to the l cavities, and below this the transverse slit between the upper and lower al arcades. The frontal tuberosities stand out more or less prominently, beneath these are the superciliary arches, the medial ends of which are

CC-0. In Public Domain. Gurukul Kangri Collection, Haridwar

Digitized by Arya Samaj Foundation Chennai and eGangotri

joined to one another by the glabella. On and above the glabella a the frontal suture sometimes persists; beneath the glabella is the fr suture, below and behind which are the frontomaxillary and fronto sutures. Below each superciliary arch is the upper part of the circum the base of the orbit, thin and prominent in its lateral two-thirds, in its medial one-third, and displaying at the junction of these two po supra-orbital notch or foramen for the supra-orbital nerve and vess supra-orbital margin ends laterally in the zygomatic process, from w temporal lines extend upwards and backwards. Below the frontona is the bridge of the nose, convex from side to side, concavo-convex fr downwards, and formed by the two nasal bones which are supported in th line by the nasal spine of the frontal bone and the lamina perpe of the ethmoidal bone. The frontal processes of the maxillæ ascend

FIG. 357.—The right orbital cavity. Anterior aspect.

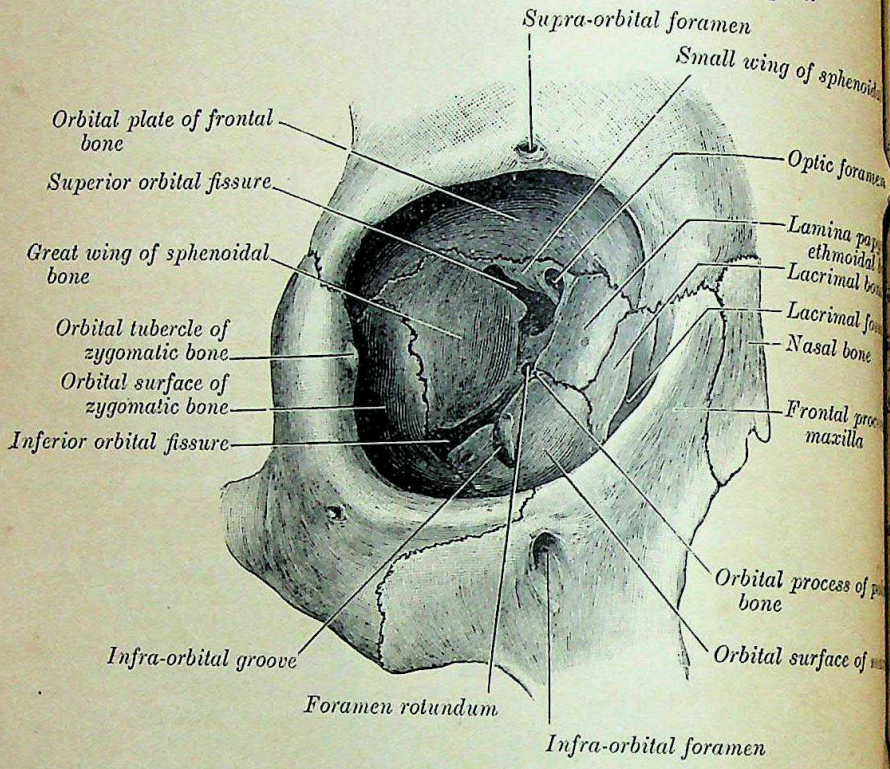

the nasal and lacrimal bones and form the lower and medial parts of the c ferences of the orbits. Below the nasal bones and between the maxillæ anterior aperture of the nasal cavity, pyriform in shape, with the nar directed upwards. Laterally this aperture is bounded by sharp margins curve medialwards and forwards below, and end in the anterior nasal On looking into the nasal cavity, the bony septum between the right a nasal chambers presents, in front, a large triangular deficiency; this is f the recent state by the cartilage of the nasal septum; on the lateral w each nasal cavity the anterior part of the inferior nasal concha is visible. and lateral to the anterior nasal aperture are the anterior surfaces of the m each perforated, near the lower margin of the orbit, by the infra-orbital fo for the passage of the infra-orbital nerve and vessels. Below and med this foramen is the canine eminence separating the incisive from the canine Beneath these fossæ are the alveolar processes of the maxillæ containing th of the upper teeth; the front upper teeth overlap the corresponding teeth. The zygomatic bone on either side forms the prominence of the and the anterior part of the zygomatic arch, and assists in forming the lowe lateral portion of the orbital cavity. It articulates medially with the m behind with the zygomatic process of the temporal bone, and the great of the sphenoidal bone, and above with the zygomatic process of the f bone; it is perforated by the zygomatic foramen for the passage

CC-0. In Public Domain. Gurukul Kangri Collection, Haridwar

Digitized by Arya Samaj Foundation Chennai and eGangotri

naticofacial nerve. On the upper part of the body of the mandible is
ian ridge, indicating the position of the symphysis or junction of the two
of which the bone is composed at an early period of life; this ridge
s below to enclose the mental protuberance, the lateral angles of which
med the mental tubercles. Below the incisor teeth is the incisive fossa;
h the second premolar tooth is the mental foramen which transmits the
l nerve and vessels. The oblique line ascends from the mental tubercle
continuous behind with the anterior border of the ramus. The posterior
of the ramus runs downwards and forwards from the condyle to the
which is more or less everted.

58.—A horizontal section through the nasal and orbital cavities. Superior aspect.

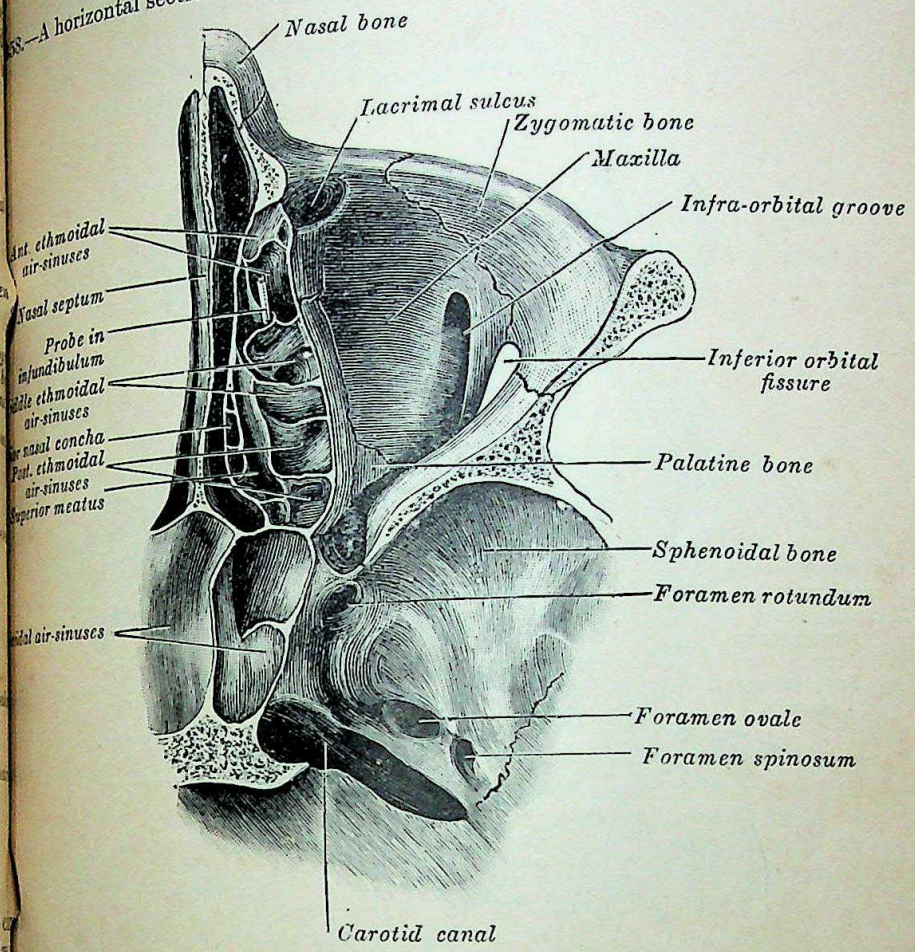

e orbits (figs. 356 to 360) are two pear-shaped cavities, situated at
nction of the cranium with the face, their bases being directed forwards
teralwards, and their apices backwards and medialwards, so that the
xes of the cavities, if continued backwards, would meet over the body
sphenoidal bone. Each orbit has a roof, a floor, a medial and a lateral
a base, and an apex.

e *roof* of the orbit is thin, triangular, and concave, and is directed down-
and slightly forwards. It separates the orbital from the cranial cavity,
s anteromedial part is double owing to the extension into it of the frontal
ns, and sometimes also the ethmoidal air-sinuses. It is formed in front
e orbital plate of the frontal bone, and behind by the small wing of the
oidal bone, which is pierced by the optic foramen. It presents, just within
e of the orbit and about midway between the supra-orbital notch and
ntolacrimal suture, a small depression or spine, the fovea vel spina
aris, for the attachment of the fibrocartilaginous pulley of the Obliquus
superior; on its anterolateral part is the lacrimal fossa for the lacrimal
; posteriorly is the suture between the frontal bone and the small wing
sphenoidal bone.

CC-0. In Public Domain. Gurukul Kangri Collection, Haridwar

Digitized by Arya Samaj Foundation Chennai and eGangotri

The *floor* of the orbit (fig. 358) looks upwards and lateralwards, a shortest of the four walls; it separates the orbital cavity from the air-sinus. Triangular in shape, it is formed chiefly by the orbital surf maxilla; in front and laterally, by the orbital process of the zygoma behind and medially, to a small extent, by the orbital process of the bone. At its medial angle is the upper opening of the nasolacrim immediately to the lateral side of which is a small depression on th surface of the maxilla for the origin of the Obliquus oculi inferior. lateral part of the floor is the suture between the maxilla and the z bone, and at its posterior part the suture between the maxilla and th process of the palatine bone. Running forwards near the middle of is the infra-orbital groove, ending anteriorly in the infra-orbital c transmitting the infra-orbital nerve and vessels.

FIG. 359.—The medial wall of the left orbit.

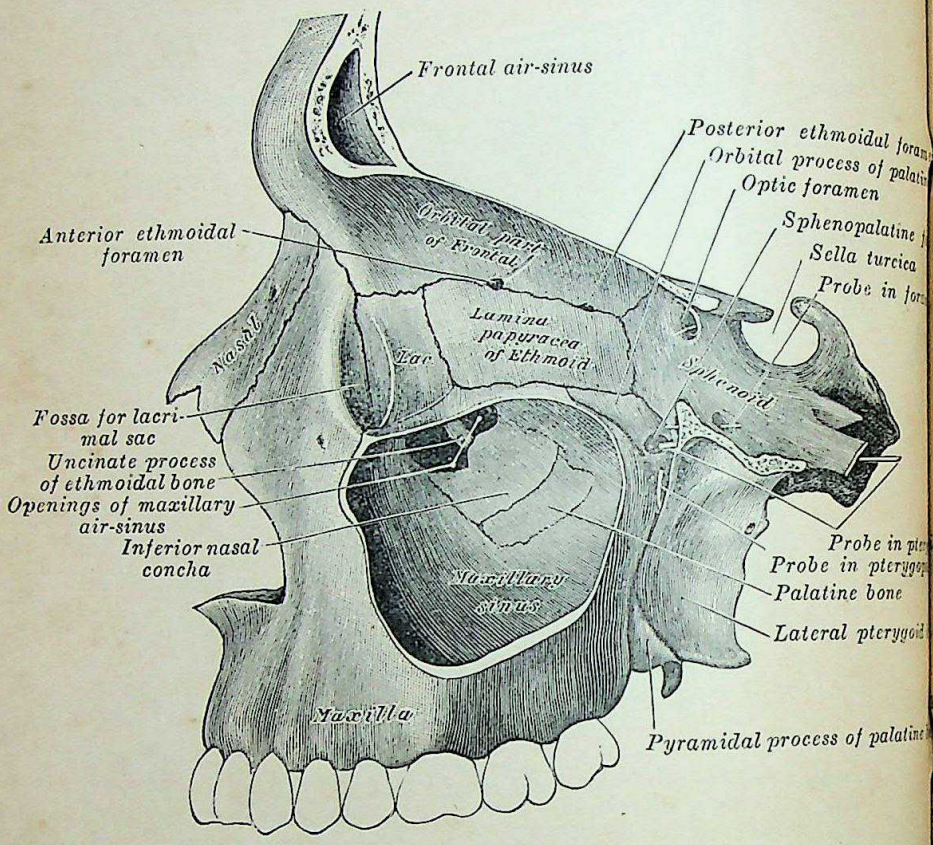

The *medial wall* of the orbit (fig. 359) is nearly vertical. It is ve and separates the orbital cavity from the ethmoidal air-sinuses, and fr anterior part of the sphenoidal air-sinus. It is formed from before ba by the frontal process of the maxilla behind the anterior lacrimal cr lacrimal bone and the small part of the frontal bone directly above lamina papyracea of the ethmoidal bone, and a small portion of the the sphenoidal bone in front of the optic foramen; sometimes the sp concha forms a small part of this wall (p. 205). It exhibits three vertical viz. the lacrimomaxillary, lacrimo-ethmoidal, and spheno-ethmoidal. I is seen the lacrimal fossa, which lodges the lacrimal sac, and behind th is the posterior lacrimal crest, from which the lacrimal part of the Orb oculi arises. At the junction of the medial wall and the roof are the maxillary, frontolacrimal, fronto-ethmoidal, and frontosphenoidal sutur the fronto-ethmoidal suture are the anterior and posterior ethmoidal fo for the transmission of the corresponding ethmoidal nerves and vessels.

The *lateral wall* of the orbit (fig. 360), directed medialwards and fo is formed by the orbital surface of the zygomatic bone and the orbital

CC-0. In Public Domain. Gurukul Kangri Collection, Haridwar

Digitized by Arya Samaj Foundation Chennai and eGangotri

e great wing of the sphenoidal bone; these are united by the spheno-
matic suture which terminates below at the anterior end of the inferior
l fissure. On the orbital process of the zygomatic bone are the orbital
le (Whitnall) and the orifices of one or two canals, which transmit the
hes of the zygomatic nerve. Between the posterior parts of the roof and
teral wall is the superior orbital fissure. Through this fissure the oculo-
, trochlear, and abducent nerves, the three branches of the ophthalmic
and some filaments from the cavernous plexus of the sympathetic enter
bital cavity. The ophthalmic veins and the recurrent meningeal branch
lacrimal artery leave the orbit through this fissure. The lateral wall and
oor of the orbit are separated posteriorly by the inferior orbital fissure,
transmits the maxillary nerve and its zygomatic (temporomalar) branch,

FIG. 360.—The lateral wall of the right orbit.

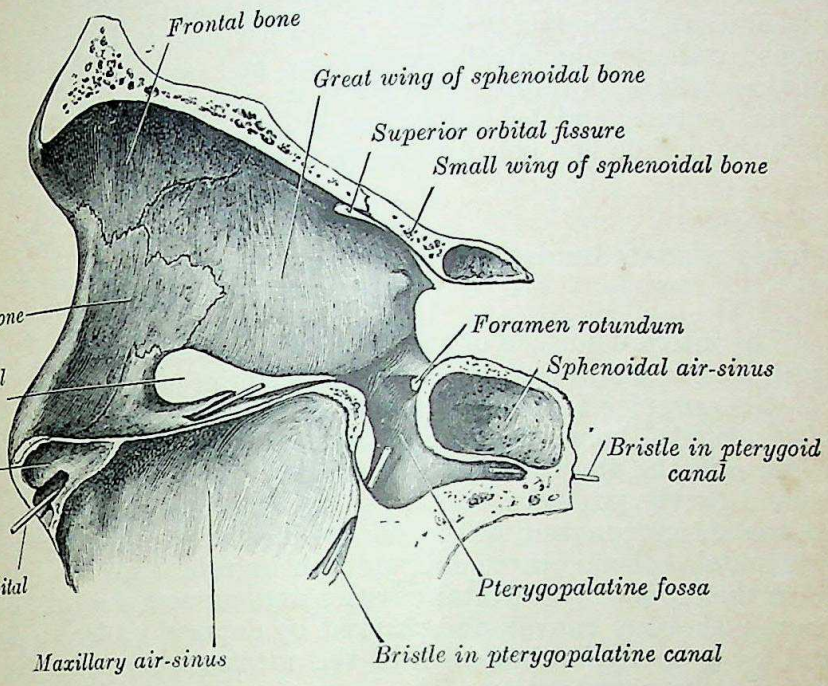

fra-orbital vessels, the orbital branches of the sphenopalatine ganglion,
ins which connect the inferior ophthalmic vein with the pterygoid venous

e *base* of the orbit (fig. 357), more or less quadrangular in shape, is formed
by the supra-orbital arch of the frontal bone, in which is the supra-orbital
or foramen for the passage of the supra-orbital vessels and nerve; below
e zygomatic bone and the maxilla, united by the zygomaticomaxillary
; laterally by the zygomatic bone and the zygomatic process of the
l bone joined by the zygomaticofrontal suture; medially by the frontal
and the frontal process of the maxilla united by the frontomaxillary
. Owing to the overhang of the orbital walls in front the base of the
is somewhat constricted, and the greatest circumference of the cavity is
1 cm. behind the orbital margin.
e *apex* of the orbit corresponds to the optic foramen,* a short canal
h which the optic nerve and ophthalmic artery enter the orbital cavity.
henoidal air-sinus is on the medial side of the foramen.

centre of the bar of bone between the optic foramen and the superior orbital fissure is
s described as the apex of the orbit.

CC-0. In Public Domain. Gurukul Kangri Collection, Haridwar

Digitized by Arya Samaj Foundation Chennai and eGangotri

THE INTERIOR OF THE SKULL

In order to study the interior of the skull, the skull-cap should be by a saw-cut carried round the cranium about the level of the frontal and the upper limits of the squamosal sutures, cutting the occipital bo above its external protuberance.

The Internal Surface of the Skull-cap

On the concave internal surface of the skull-cap are depressions convolutions of the cerebrum, and numerous furrows for the branch meningeal vessels. In the middle line is the sagittal sulcus, narrow and broad behind; it lodges the superior sagittal sinus, and its marg attachment to the falx cerebri. On either side of the sulcus are sever sions for the arachnoideal granulations, and, at its posterior part, the of the parietal foramina when these are present. It is crossed in fro coronal suture, and behind by the lambdoid suture, whilst the sagitt is in the middle line between the parietal bones.

The Internal Surface of the Base of the Skull (Basis Cranii I (figs. 361, 362)

The internal surface of the base of the skull, or floor of the crani is divided into anterior, middle, and posterior cranial fossæ.

The **anterior fossa.**—The floor of this fossa is formed by the orbi of the frontal bone, the lamina cribrosa of the ethmoidal bone, and wings and the anterior part of the body of the sphenoidal bone; it behind by the posterior borders of the small wings of the sphenoidal by the anterior margin of the sulcus chiasmatis. It is traversed by th ethmoidal, spheno-ethmoidal and sphenofrontal sutures. Its lateral form the roofs of the orbital cavities and support the frontal lobes of brum; they are convex and marked by depressions for the brain conv and by grooves for branches of the meningeal vessels. The central of the floor corresponds with the roof of the nasal cavity, and is depressed on either side of the crista galli. It presents, in the med from before backwards, the commencement of the frontal crest for th ment of the falx cerebri; the foramen cæcum which frequently opens nasal cavity and transmits a small vein from that cavity to the superior sinus; the crista galli, the free margin of which affords attachment anterior end of the falx cerebri. On either side of the crista galli is the groove formed by the lamina cribrosa of the ethmoidal bone, which the olfactory bulb and is perforated by foramina for the transmissio olfactory nerves; at the front part of the lamina cribrosa is the fora the anterior ethmoidal nerve. Lateral to the olfactory groove are the openings of the anterior and posterior ethmoidal foramina; the situated about the middle of the lateral margin of the olfactory groove, t the anterior ethmoidal nerve and vessels; the nerve runs in a groo the lateral edge of the lamina cribrosa to the foramen above mention posterior ethmoidal foramen opens at the posterior part of this marg cover of a projecting lamina of the sphenoidal bone, and transmits the ethmoidal nerve and vessels. The anterior margin of the sulcus ch runs lateralwards to the upper margins of the optic foramina.

The **middle fossa.**—This fossa is deeper than the anterior, and is the middle, and wide at the sides of the skull. It is bounded in front posterior margins of the small wings of the sphenoidal bone, the anterior processes, and the ridge forming the anterior margin of the sulcus chi behind, by the dorsum sellæ of the sphenoidal bone and the superior (superior margins) of the petrous portions of the temporal bones; late

CC-0. In Public Domain. Gurukul Kangri Collection, Haridwar

Digitized by Arya Samaj Foundation Chennai and eGangotri

emporal squamæ, the sphenoidal angles of the parietal bones, and the wings of the sphenoidal bone. It is traversed by the squamosal, spheno-al, sphenosquamosal, and sphenopetrosal sutures.

he middle part of the fossa presents, in front, the sulcus chiasmatis and culum sellæ; the sulcus ends on either side at the optic foramen, which mits the optic nerve and ophthalmic artery to the orbital cavity. The or clinoid process is directed backwards and medialwards behind the foramen and gives attachment to the anterior end of the free border e tentorium cerebelli. Behind the tuberculum sellæ is the sella turcica, eepest part of which lodges the hypophysis and is named the fossa hypo-os. At the lateral angles of the anterior wall of the sella turcica are iddle clinoid processes. The sella turcica is bounded posteriorly by the m sellæ, the upper angles of which are surmounted by the posterior d processes; these afford attachment to the lateral borders of the tentorium lli, and a little below each process the side of the dorsum sellæ is notched e passage of the abducent nerve. Lateral to the sella turcica is the d sulcus, which begins behind at the foramen lacerum, and ends on the l side of the anterior clinoid process, where it is sometimes converted into men (caroticoclinoid) by the union of the anterior and middle clinoid pro-; the posterior part of the sulcus is bounded anterolaterally by the The carotid sulcus lodges the cavernous sinus, the internal carotid and the plexus of sympathetic nerves surrounding the latter.

e lateral parts of the middle fossa are deep, and support the temporal of the brain. They are marked by depressions for the brain convolutions, re traversed by furrows for the anterior and posterior branches of the e meningeal vessels. These furrows begin by the bifurcation of a groove commences at the foramen spinosum and runs for about 2 cm. forwards ateralwards on the temporal squama; the anterior furrow is directed rds and upwards to the sphenoidal angle of the parietal bone, where it is times converted into a bony canal; the posterior furrow arches backwards s the upper part of the temporal squama and passes on to the parietal near the middle of its lower border. In the anterior part of the fossa e superior orbital fissure, bounded above by the small wing, below by the wing and medially by the body, of the sphenoidal bone; it is usually ted laterally by the orbital plate of the frontal bone. It transmits to the l cavity the oculomotor, trochlear, and abducent nerves, the three ches of the ophthalmic nerve, and some filaments from the cavernous s of the sympathetic; and from the orbital cavity the recurrent meningeal h of the lacrimal artery, and the ophthalmic veins. Behind the medial f the superior orbital fissure is the foramen rotundum, for the exit of the lary nerve. Posterior and lateral to the foramen rotundum is the foramen which transmits the mandibular nerve, the accessory meningeal artery, e lesser superficial petrosal nerve.* Medial to the foramen ovale is the men Vesalii which varies in size, and is often absent; when present, it opens at the lateral side of the scaphoid fossa, and transmits a small vein. Lateral e foramen ovale is the foramen spinosum, for the passage of the nervus sus and the middle meningeal artery. Medial and posterior to the foramen is the foramen lacerum; in the recent state the lower part of this foramen d by a fibrocartilaginous plate, on the upper surface of which rests the al carotid artery surrounded by a plexus of sympathetic nerves; the of the pterygoid canal, and a meningeal branch from the ascending ngeal artery, pierce the fibrocartilaginous plate. On the anterior surface e petrous portion of the temporal bone is the eminentia arcuata caused e upward projection of the superior semicircular canal; in front of this, epressed area forming the roof of the tympanic cavity, and the groove ng to the hiatus of the facial canal for the transmission of the greater cial petrosal nerve and the petrosal branch of the middle meningeal lateral to this groove, the smaller groove for the passage of the lesser cial petrosal nerve; and, near the apex of the bone, the depression for milunar ganglion, and the internal orifice of the carotid canal.

e posterior fossa.—The posterior fossa, the largest and deepest, is formed e dorsum sellæ of the sphenoidal bone, the basilar and lateral parts of the

* See footnote, p. 203.

CC-0. In Public Domain. Gurukul Kangri Collection, Haridwar

Digitized by Arya Samaj Foundation Chennai and eGangotri

occipital bone, the petrous and mastoid portions of the temporal b
mastoid angles of the parietal bones, and the lower part of the squa
talis; it lodges the cerebellum, pons, and medulla oblongata, and b
by the petro-occipital, occipitomastoid, and parietomastoid sutur

FIG. 361.—The internal surface of the left half of the base of the skull. (Basis cranii interna.)

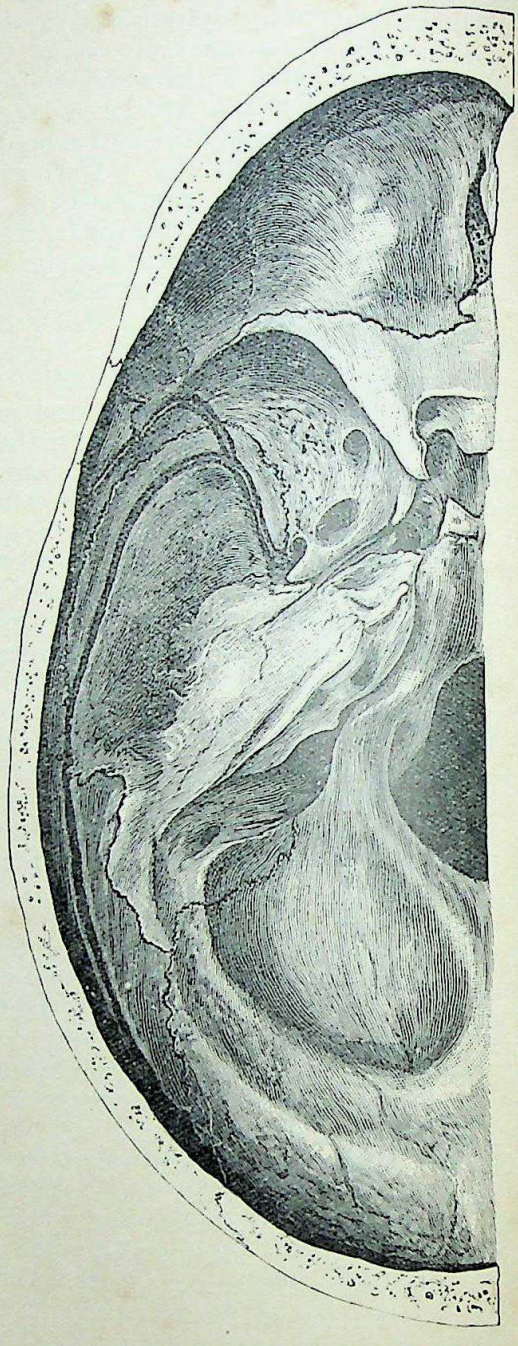

separated from the middle fossa in and near the median line by the dorsum
of the sphenoidal bone, and on either side by the superior angle (s
margin) of the petrous portion of the temporal bone. This angle gives
ment to the tentorium cerebelli, is grooved for the superior petrosal sin
is notched at its medial end for the trigeminal nerve. The posterior
limited behind by the transverse sulci of the occipital bone. In its centr
foramen magnum, and on either side of this foramen is a rough tube
the attachment of the alar ligaments; a little above this tubercle

CC-0. In Public Domain. Gurukul Kangri Collection, Haridwar

Digitized by Arya Samaj Foundation Chennai and eGangotri

glossal canal which transmits the hypoglossal nerve and a meningeal branch the ascending pharyngeal artery. In front of the foramen magnum the r portion of the occipital bone and the posterior part of the body of the oidal bone form a grooved sloping surface which supports the medulla

FIG. 362.—Key to fig. 361.

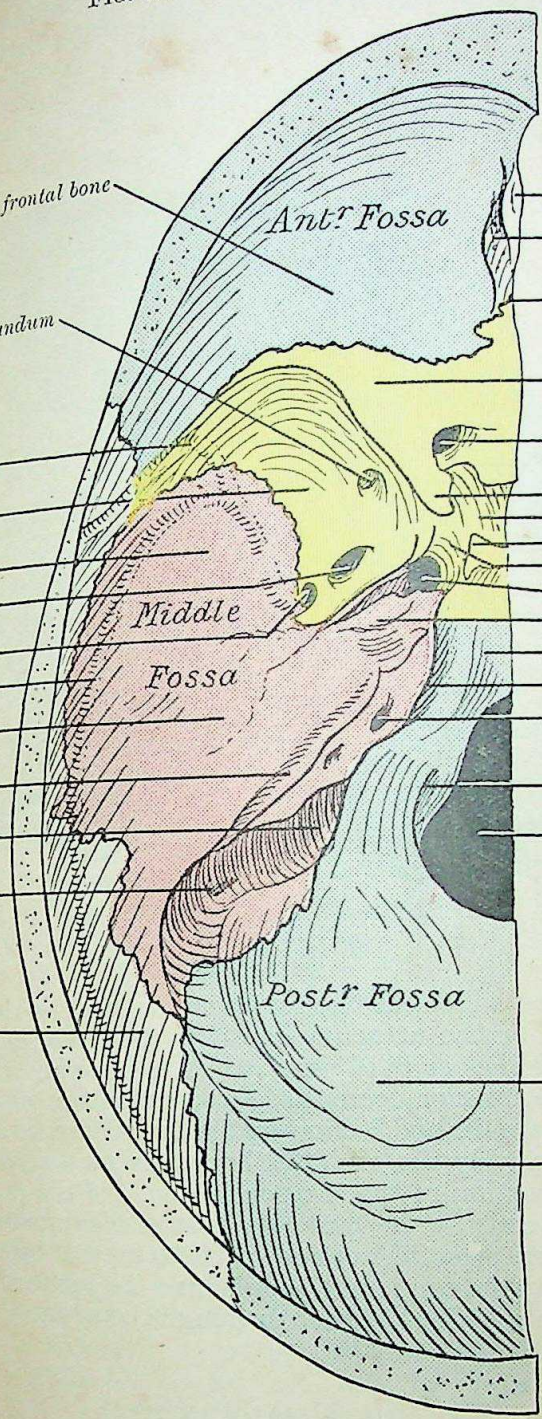

gata and pons; in the young skull these bones are joined by a synchon-s. This grooved surface is separated on either side from the petrous n of the temporal bone by the petro-occipital fissure, which is occupied recent state by a plate of cartilage; the fissure is continuous behind with gular foramen, and its margins are grooved for the inferior petrosal sinus. jugular foramen is situated between the lateral part of the occipital bone the petrous part of the temporal bone. The anterior portion of this foramen mits the inferior petrosal sinus; the posterior portion, the transverse sinus

CC-0. In Public Domain. Gurukul Kangri Collection, Haridwar

Digitized by Arya Samaj Foundation Chennai and eGangotri

and some meningeal branches from the occipital and ascending p
arteries; and the intermediate portion, the glossopharyngeal, va
accessory nerves. Above the jugular foramen is the opening of the
acoustic meatus, for the facial and acoustic nerves and the internal
artery; posterior and lateral to this opening is the slit leading to the aq
vestibuli which lodges the ductus endolymphaticus. Near the super
(margin) of the petrous portion, is a small depression, the remain
fossa subarcuata, which lodges a process of the dura mater and tran

FIG. 363.—A sagittal section through the skull.

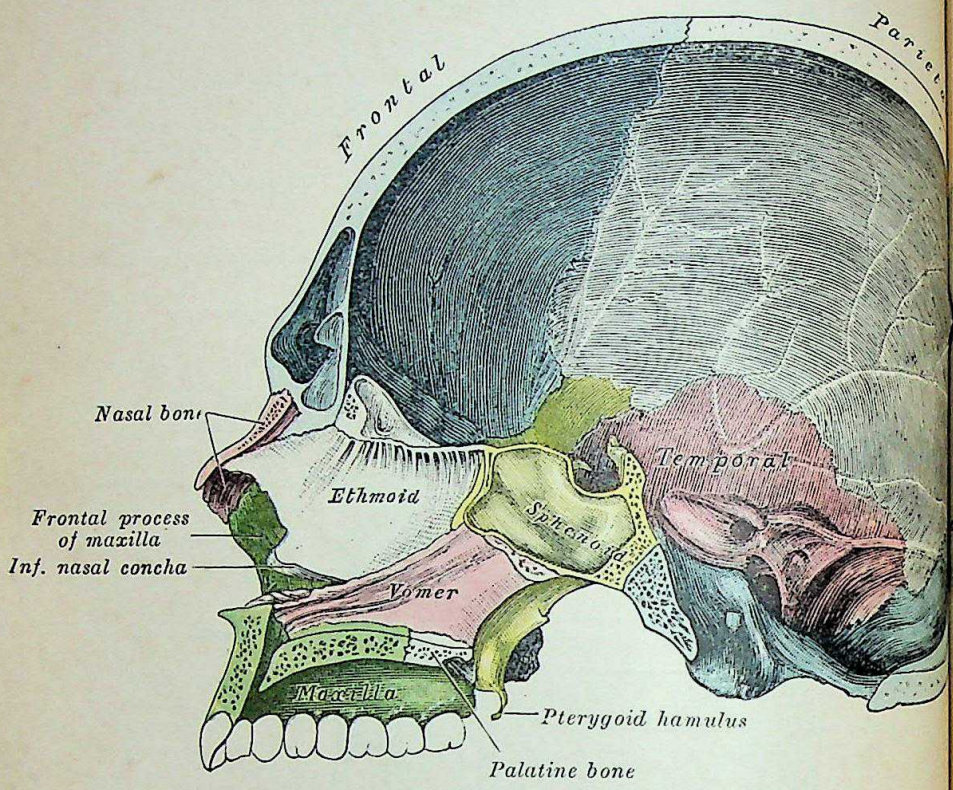

or more small veins. Behind the foramen magnum is the internal c
crest which serves for the attachment of the falx cerebelli; in the a
margin of this falx is the occipital sinus, which is sometimes duplicated.
to the crest are the inferior occipital fossæ, which support the hemisp
the cerebellum and are limited behind by the transverse sulci. Each tra
sinus grooves successively the occipital bone, the mastoid angle of the p
bone, the mastoid portion of the temporal bone, and the jugular process
occipital bone, and ends at the posterior part of the jugular foramen.
the sinus grooves the mastoid portion of the temporal bone, the orifice
mastoid foramen may be seen; and, just behind the jugular foramen, the
loid canal may open into it; neither opening is constant.

THE NASAL CAVITIES

The **nasal cavities** are two irregular spaces, situated one on eith
of the middle line of the face, extending from the base of the cranium
roof of the mouth, and separated from each other by a thin vertical s
They open on the face through the pear-shaped anterior nasal apertu
their posterior openings, or choanæ, communicate, in the recent state
the nasal part of the pharynx. They are narrower above than below,
the middle than at their anterior or posterior openings: their depth is g
in the middle. They communicate with the frontal, ethmoidal, sphe
and maxillary air-sinuses.

CC-0. In Public Domain. Gurukul Kangri Collection, Haridwar

Digitized by Arya Samaj Foundation Chennai and eGangotri

ch nasal cavity has a roof, a floor, and a medial and a lateral wall.

he *roof* (figs. 365, 366) is horizontal in its central part, but slopes down- in front and behind; it is formed in front by the nasal bone and the l spine; in the middle, by the lamina cribrosa of the ethmoidal bone; ehind, by the body of the sphenoidal bone, the sphenoidal concha, the the vomer and the sphenoidal process of the palatine bone. In the lamina sa are the foramina for the olfactory nerves, and in front of these is the en for the anterior ethmoidal nerve; in the posterior part of the roof opening into the sphenoidal air-sinus.

Fig. 364.—The medial wall of the left nasal cavity.

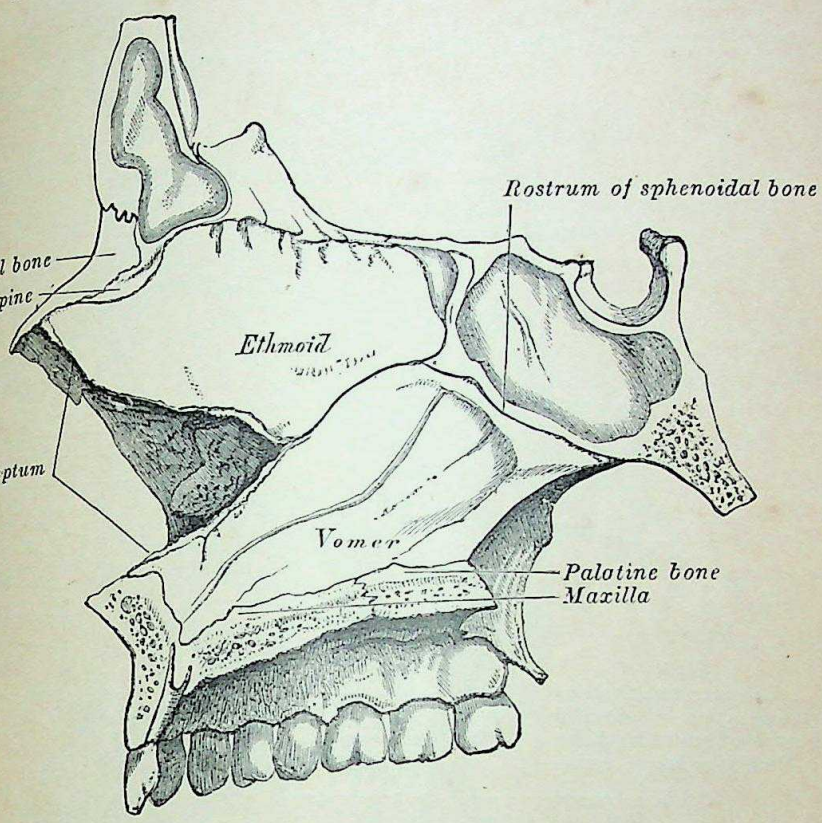

e *floor*, flattened from before backwards and concave from side to side, rmed by the palatine process of the maxilla and the horizontal part of the ine bone; near its anteromedial angle is the opening of the incisive

he *medial wall*, or *septum nasi* (fig. 364), is frequently deflected to one her side, more often to the left than to the right. It is formed, in front, by rest of the nasal bones and the frontal spine; in the middle, by the lamina endicularis of the ethmoidal bone; behind, by the vomer and by the um of the sphenoidal bone; below, by the crest of the maxillæ and palatine s. In front is a large, triangular notch which is filled by the cartilage of eptum; behind, is the free edge of the vomer. The septum nasi is marked rrows for vessels and nerves, and the vomer is grooved for the nasopalatine e also.

he *lateral wall* (figs. 365, 366) is formed, in front, by the nasal bone, the frontal ss of the maxilla, and the lacrimal bone; in the middle, by the ethmoidal the maxilla, and the inferior nasal concha; behind, by the vertical part palatine bone, and the medial pterygoid lamina of the sphenoidal bone. his wall are three irregular, anteroposterior passages, termed the superior, le, and inferior meatuses of the nose. The *superior meatus*, the smallest of hree, is between the superior and middle nasal conchæ; the spheno- ine foramen opens into it behind, and the posterior ethmoidal air-sinuses

CC-0. In Public Domain. Gurukul Kangri Collection, Haridwar

Digitized by Arya Samaj Foundation Chennai and eGangotri

in front. Above and behind the superior concha is a triangular de
named the spheno-ethmoidal recess into which the sphenoidal air-sinu
The *middle meatus* is between the middle and inferior conchæ, and
from the anterior to the posterior end of the latter. The lateral wa
meatus can be satisfactorily studied only after the removal of the middl
On it is a curved fissure, the hiatus semilunaris, limited below by the
the uncinate process of the ethmoidal bone, and above by an elevatio
the bulla ethmoidalis; the middle ethmoidal air-sinuses are contained
this bulla, and open on, or near to it. Through the hiatus semilu
meatus opens into a curved passage termed the infundibulum; the
bulum communicates in front with the anterior ethmoidal air-sinuses
rather more than fifty per cent. of skulls is continuous above with the
nasal duct which opens into the frontal air-sinus; when this contin

FIG. 365.—The roof, floor, and lateral wall of the left nasal cavity.

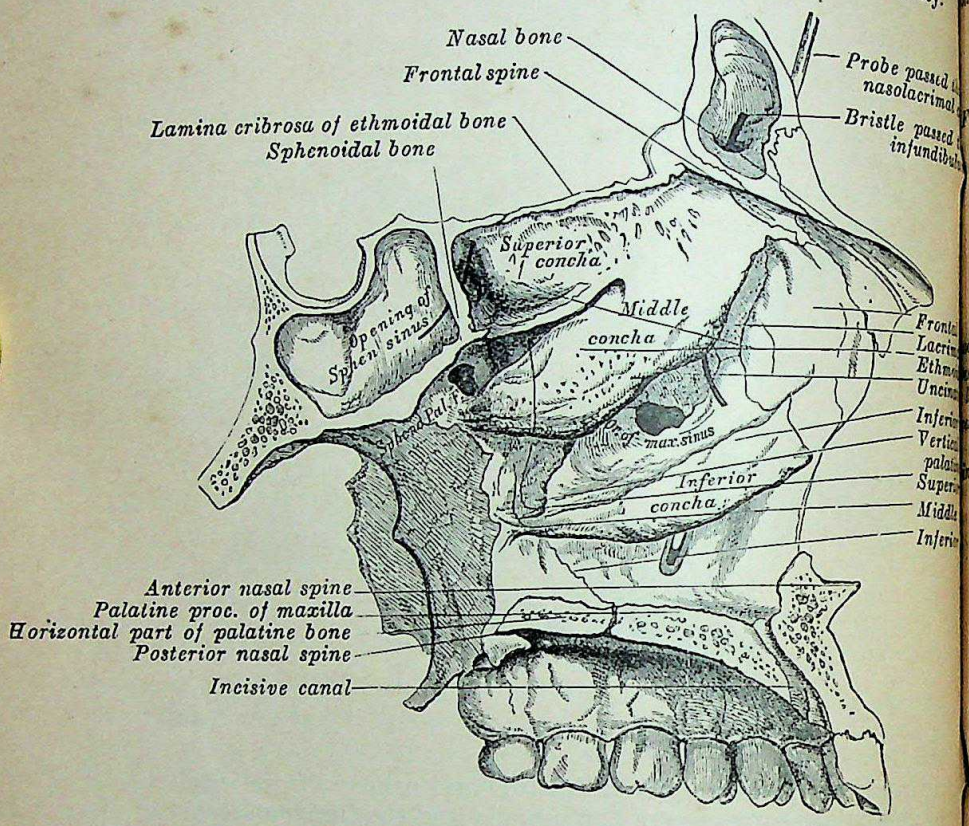

through the fusion of the bulla ethmoidalis with the uncinate process
ethmoidal bone, the frontonasal duct opens directly into the anterior
the middle meatus. Below the bulla ethmoidalis and hidden by the u
process of the ethmoidal bone is the ostium maxillare or opening
maxillary air-sinus; an accessory opening from this air-sinus is fre
present above the posterior part of the inferior nasal concha. The
meatus, the largest of the three, is the space between the inferior con
the floor of the nasal cavity. It extends almost the entire length of the
wall of the nose, is broader in front than behind, and presents anteri
lower orifice of the nasolacrimal canal.

The *apertura piriformis*, or *anterior nasal aperture* (fig. 356), is b
above by the inferior borders of the nasal bones; laterally by the thi
margins which separate the anterior from the nasal surfaces of the m
and below by the same margins, where they curve medialwards to jo
other at the anterior nasal spine. In the recent state it is much co
by the lateral and alar cartilages of the nose.

The *choanæ* or *posterior nasal apertures* are separated from one and
the posterior border of the vomer; each is bounded above by the ala

CC-0. In Public Domain. Gurukul Kangri Collection, Haridwar

Digitized by Arya Samaj Foundation Chennai and eGangotri

and the vaginal process of the medial pterygoid lamina; below, by the rior border of the horizontal part of the palatine bone; laterally, by edial pterygoid lamina.

FIG. 366.—The lateral wall of the right nasal cavity, with parts of the middle and inferior nasal conchæ removed.

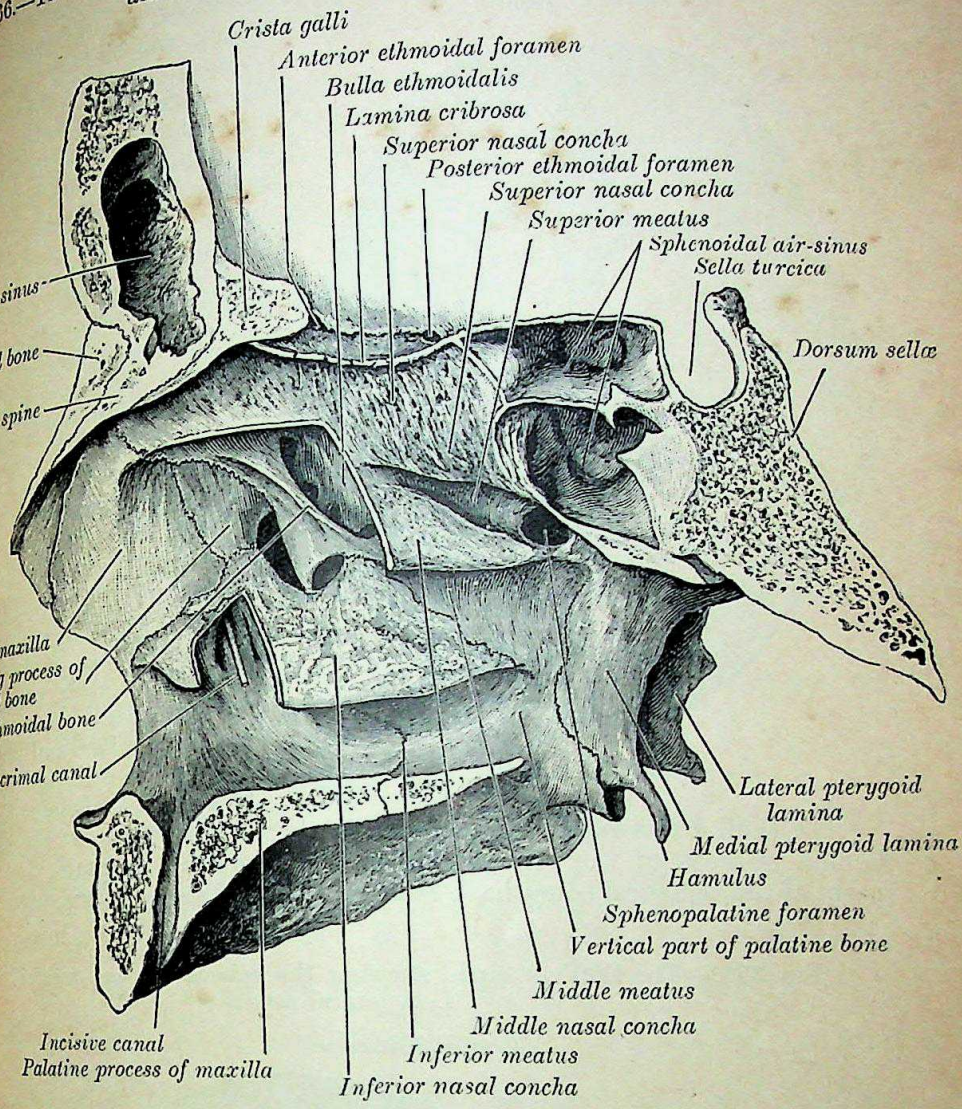

THE DIFFERENCES IN THE SKULL DUE TO AGE

t birth the skull is large in proportion to the other parts of the skeleton, but se is short and narrow in proportion to the vault; the facial portion is small quals only about one-eighth of the bulk of the cranium as compared with lf in the adult. The frontal and parietal tuberosities or eminences are promi- and when the skull is viewed from above it presents a pentagonal outline its greatest width at the parietal tuberosities (fig. 367); on the other hand, abella, superciliary arches, and mastoid processes are not developed. Ossi- on of the skull bones is not completed, and many of them—e.g. the occipital, rals, sphenoidal, frontal, and mandible—consist of more than one piece. ified membranous intervals, termed fonticuli (fontanelles), are seen at the of the parietal bones; these fonticuli are six in number; two, the frontal cipital, are situated in the middle line, and two, the sphenoidal and mastoid, er side.

e *frontal or anterior fonticulus* (fig. 367) is the largest, and is placed at the on of the sagittal, coronal, and frontal sutures; it is lozenge-shaped, and res about 4 cm. in its anteroposterior and 2·5 cm. in its transverse diameter. *ccipital or posterior fonticulus* (fig. 367) is triangular in form and is situated

CC-0. In Public Domain. Gurukul Kangri Collection, Haridwar

Digitized by Arya Samaj Foundation Chennai and eGangotri

at the junction of the sagittal and lambdoid sutures. The *sphenoidal* and *fonticuli* (fig. 368) are small, irregular in shape, and correspond respectively the sphenoidal and mastoid angles of the parietal bones. An additional is sometimes seen in the suture at the region of the

Fig. 367.—The skull at birth, showing the frontal and occipital fonticuli. Superior aspect.

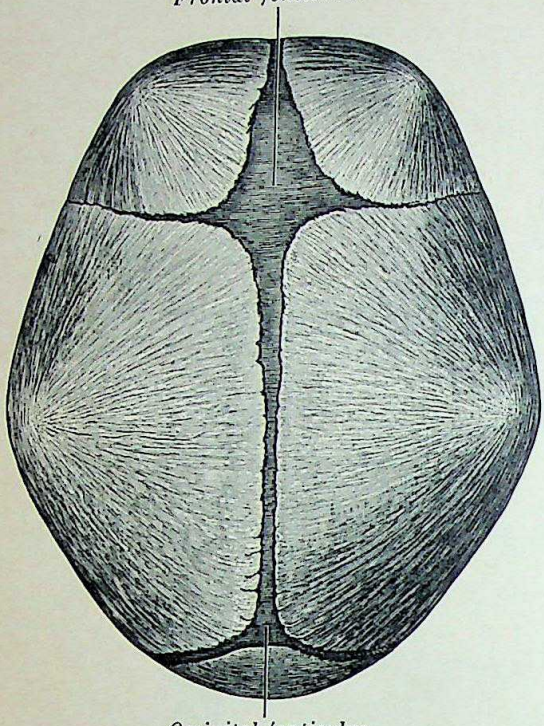

The fonticuli are usually the growth and extension of which surround them, but they are the sites of separate of ossification which deve sutural bones. The occi sphenoidal fonticuli are o within two or three mont birth; the mastoid fonti usually closed about the en first year, and the frontal fo about the middle of the seco

The smallness of the face is mainly accounted for by mentary condition of the and maxillæ, the non-erup the teeth, and the small size maxillary air-sinuses and cavities. At birth the nasal lie almost entirely betwe orbits, and the lower borde anterior nasal aperture is little below the level of the floor. With the eruption deciduous teeth there is an ment of the face and jaws, a changes are still more mark the second dentition.

The skull grows rapidly from birth to the seventh year; at the latter lamina cribrosa of the ethmoidal bone, the foramen magnum, and the parts of the temporal bones have reached their full size, and the orbital cav

Fig. 368.—The skull at birth, showing the sphenoidal and mastoid fonti Left lateral aspect.

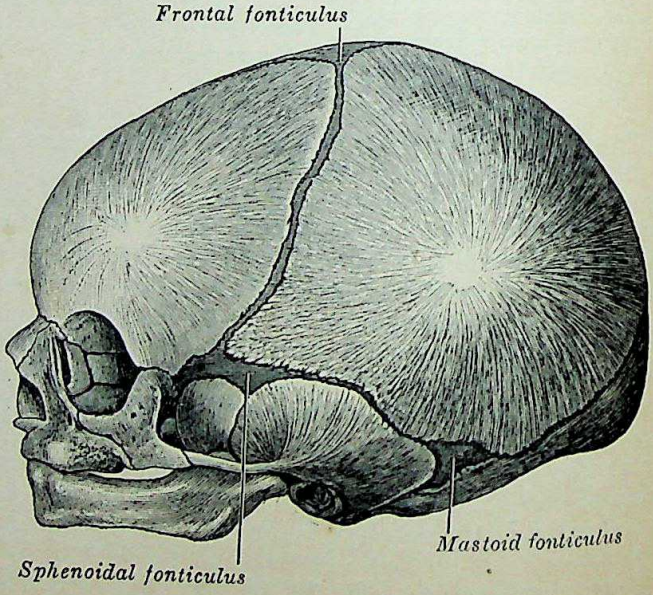

only a little smaller than those of the adult. Growth is slow from the year until the approach of puberty, when a second period of increased

CC-0. In Public Domain. Gurukul Kangri Collection, Haridwar

Digitized by Arya Samaj Foundation Chennai and eGangotri

rs: this results in an enlargement in all directions, but especially in the frontal facial regions, where it is associated with the development of the air-sinuses. bliteration of the sutures of the vault of the skull takes place as age nces. It may commence between the ages of thirty and forty on the inner ce, and about ten years later on the outer surface of the skull, but the times hich the sutures are closed are subject to great variations. Obliteration usually s first in the lower part of the coronal suture, next in the posterior part of the al suture, and then in the lambdoid suture.

In old age the skull generally becomes thinner and lighter, but in a small portion of cases it increases in thickness and weight. The most striking feature e senile skull is the diminution in the size of the mandible and maxillæ consequent on the loss of the teeth and the absorption of the alveolar processes. This sociated with a marked reduction in the vertical measurement of the face with an alteration in the angles of the mandible.

The Sex Differences in the Skull

ntil the age of puberty there is little difference between the skull of the female hat of the male. The skull of an adult female is as a rule lighter and smaller, s capacity is about 10 per cent. less, than that of the male. Its walls are r and its muscular ridges less marked; the glabella, superciliary arches, and id processes are less prominent, and the corresponding air-sinuses are small dimentary. The upper margin of the orbit is sharp, the forehead vertical, rontal and parietal tuberosities prominent, and the vault somewhat flattened. ontour of the face is rounder, the facial bones are smoother, and the mandible maxillæ and their contained teeth smaller. Speaking generally, more of infantile characteristics are retained in the skull of the adult female than in of the adult male. A well-marked male or female skull can easily be recognised ch, but in some skulls the respective characteristics are so indistinct that the rmination of the sex may be difficult or impossible.*

Craniology

kulls vary in size and shape, and the term craniology is applied to the study of these tions.

he *capacity* of the cranial cavity constitutes a good index of the size of the brain h it contained, and is most conveniently arrived at by filling the cavity with shot and uring the contents in a graduated vessel. Skulls may be classified according to their acities as follows:

Microcephalic, with a capacity of less than 1350 c.cm.—e.g. those of native ralians and Andaman Islanders.

Mesocephalic, with a capacity of from 1350 c.cm. to 1450 c.cm.—e.g. those of n negroes and Chinese.

Megacephalic, with a capacity of over 1450 c.cm.—e.g. those of Europeans, nese and Eskimos.

n comparing the shape of one skull with that of another it is necessary to adopt some ite position in which the skulls should be placed during the process of examination. should be so placed that a line carried through the lower margin of the orbit and r margin of the opening of the external acoustic meatus is in the horizontal plane. normæ of one skull can then be compared with those of another, and the differences ontour and surface-form noted. Further, it is necessary that the various linear asurements used to determine the shape of the skull should be made between definite easily localised points on its surface. The principal points may be divided into two ps: (1) those in the median plane, and (2) those on either side of it (fig. 369).

The **points in the median plane** are the:

Pogonion. The most prominent point of the chin.

Alveolar point or *prosthion*. The central point of the anterior margin of the upper olar arch.

Rhinthion. The tip of the anterior nasal spine.

Rhinnasal point. The middle of the lower border of the anterior nasal aperture, at the of the anterior nasal spine.

Nasion. The most prominent point of the internasal suture.

Bregma. The central point of the frontonasal suture.

Glabella. The point in the middle line at the level of the superciliary arches.

* Some additional differences between the male and female skull are given by Professor F. G. ...as and Mrs. Lucas Keene, *Journal of Anatomy*, vol. liv, 1919.

CC-0. In Public Domain. Gurukul Kangri Collection, Haridwar

Digitized by Arya Samaj Foundation Chennai and eGangotri

Ophryon. The point in the middle line of the forehead at the level where the lines most nearly approach each other.

Bregma. The meeting point of the coronal and sagittal sutures.

Obelion. A point in the sagittal suture on a level with the parietal foramina.

Lambda. The point of junction of the sagittal and lambdoid sutures.

Occipital point. The point in the middle line of the occipital bone farthest from the glabella.

Inion. The external occipital protuberance.

Opisthion. The mid-point of the posterior margin of the foramen magnum.

Basion. The mid-point of the anterior margin of the foramen magnum.

FIG. 369.—An outline of the left side of the skull.

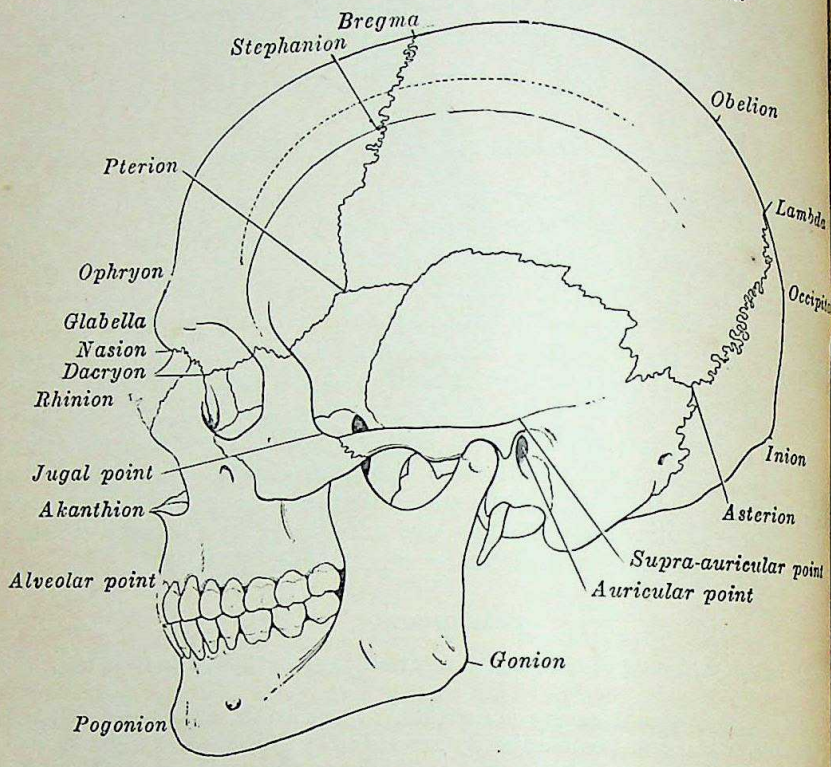

The **points on either side of the median plane** are the:

Gonion. The outer margin of the angle of the mandible.

Jugal point. The angle between the temporal border of the zygomatic bone and the upper border of the zygomatic arch.

Dacryon. The point of union of the anterosuperior angle of the lacrimal with the frontal bone and the frontal process of the maxilla.

Pterion. The point where the great wing of the sphenoidal bone joins the squamous angle of the parietal.

Stephanion. The point where the temporal line intersects the coronal suture.

Auricular point. The centre of the orifice of the external acoustic meatus.

Supra-auricular point. A point on the posterior root of the zygomatic arch in the middle of the orifice of the external acoustic meatus.

Asterion. The point of meeting of the lambdoid, masto-occipital, and masto-parietal sutures.

The *horizontal circumference* of the cranium is measured in a plane passing through the glabella in front, and the occipital point behind; it averages about 50 cm. in the female and 52·5 cm. in the male.

The *occipitofrontal or longitudinal arc* is measured from the nasion over the vertex line of the vertex to the opisthion, while the *basinasal length* is the distance between the basion and the nasion. These two measurements, plus the anteroposterior diameter of the foramen magnum, represent the *vertical circumference* of the cranium.

The *length* is measured from the glabella to the occipital point, while the *breadth* or greatest transverse diameter is usually found a little above and behind the opening of the external acoustic meatus. The proportion of breadth to length $\frac{\text{breadth}}{\text{length}}$ is termed the *cephalic index* or *index of breadth.*

The *height* is measured from the basion to the bregma, and the proportion of height to length $\frac{\text{height} \times 100}{\text{length}}$ constitutes the *vertical or height index.*

CC-0. In Public Domain. Gurukul Kangri Collection, Haridwar

Digitized by Arya Samaj Foundation Chennai and eGangotri

studying the face the principal points to be noticed are the proportion of its length breadth, the shape of the orbits and of the anterior nasal aperture, and the degree of tion of the jaws.

e *length of the face* is measured from the nasion to the lower margin of the man- or, if the mandible be wanting, to the alveolar point; its *width* is the distance en the zygomatic arches. By comparing the length with the width of the face, may be divided into two groups; *dolichofacial* (long-faced) and *brachyfacial* -faced).

e *orbital index* signifies the proportion which the orbital height bears to the orbital thus:

$$\frac{\text{orbital height} \times 100}{\text{orbital width}}$$

e *nasal index* expresses the proportion which the width of the anterior nasal ure bears to the height of the nose, the latter being measured from the nasion to the sal point, thus:

$$\frac{\text{nasal width} \times 100}{\text{nasal height}}$$

e degree of projection of the jaws is determined by the *gnathic or alveolar index*, represents the proportion between the basi-alveolar and basinasal lengths, thus:

$$\frac{\text{basi-alveolar length} \times 100}{\text{basinasal length}}$$

e *dental index* is arrived at by comparing the *dental length* (i.e. the distance en the anterior surface of the first premolar and the posterior surface of the third tooth of the maxilla) with the basinasal length, thus:

$$\frac{\text{dental length} \times 100}{\text{basinasal length}}$$

e following table, modified from that given by Duckworth,* illustrates how some of indices may be utilised in the classification of skulls:

Index.	Classification.	Nomenclature.	Examples.
Cephalic .	Below 75 . . .	Dolichocephalic .	Kaffirs and Native Australians
	Between 75 and 80 .	Mesaticephalic .	Europeans and Chinese
	Above 80 . . .	Brachycephalic .	Mongolians and Andamans
Orbital .	Below 84 . . .	Microseme . .	Tasmanians and Native Australians
	Between 84 and 89 .	Mesoseme . .	Europeans
	Above 89 . . .	Megaseme . .	Chinese and Polynesians
Nasal . .	Below 48 . . .	Leptorhine . .	Europeans
	Between 48 and 53 .	Mesorhine . .	Japanese and Chinese
	Above 53 . . .	Platyrhine . .	Negroes and Native Australians
Gnathic .	Below 98 . . .	Orthognathous .	Europeans
	Between 98 and 103 .	Mesognathous .	Chinese and Japanese
	Above 103 . . .	Prognathous .	Native Australians

plied Anatomy.—Occasionally a protrusion of the brain or its membranes may take through one of the sutures, owing to non-closure. When the protrusion consists of branes only, and is filled with cerebrospinal fluid, it is called a *meningocele*; when it ts of brain as well as membranes, it is termed an *encephalocele*. These malforma- are usually found in the middle line, and most frequently at the back of the head, trusion taking place between the centres of ossification of the occipital squama 200.) They generally occur through the upper part of the vertical fissure, which last to close, but not uncommonly through the lower part, when the foramen m may be incomplete. More rarely these protrusions are met with in other ions, as in the sagittal, lambdoid, and other sutures, or through abnormal gaps at des or base of the skull.

* W. L. H. Duckworth, *Morphology and Anthropology*, Cambridge University Press.

CC-0. In Public Domain. Gurukul Kangri Collection, Haridwar

Digitized by Arya Samaj Foundation Chennai and eGangotri

The chief function of the skull is to protect the brain, and therefore those
the skull which are most exposed to external violence are thicker than those
shielded from injury by overlying muscles. Thus, the skull-cap is thick
whereas the temporal squamæ, being protected by the Temporales muscles
inferior occipital fossæ, being shielded by the muscles at the back of the neck,
fragile. Fracture of the skull is further prevented by its elasticity, its roun
and its construction of a number of secondary elastic arches, each made up
bone. The manner in which vibrations are transmitted through the bones of
also of importance as regards its protective mechanism, at all events as far as
concerned. In the vault, the bones being of a fairly equal thickness and den
tions are transmitted in a uniform manner in all directions, but in the base, ow
varying thickness and density of the bones, this is not so; and therefore in this
there are special buttresses which serve to carry the vibrations in certain defi
tions. At the front of the skull, on either side, is the ridge which separates th
from the middle fossa of the base; and behind, the ridge or buttress which sep
middle from the posterior fossa; and if any violence is applied to the vault, the
would be carried along these buttresses to the sella turcica, where they meet. Th
been termed the 'centre of resistance,' and here there is a special protective m
to guard the brain. The subarachnoid cavity at the base of the brain is dilated
cerebrospinal fluid which fills it acts as a water-cushion to shield the brain fro
In like manner, when violence is applied to the base of the skull, as in falls upo
the vibrations are carried backwards through the occipital crest, and forwards
the basilar part of the occipital and body of the sphenoidal bone to the vau
skull.

Fractures of the skull are best considered as affecting either the vault or
Fractures of the vault generally involve the whole thickness of the bone; but s
the inner table alone is fractured, and portions of it driven inwards. In fractu
skull, and especially in punctured fractures, the inner table is more splintered
minuted than the outer, and this is due to several causes. It is thinner and mo
the force of the violence as it passes inwards becomes broken up and is more d
the time it reaches the inner table; the bone being in the form of an arch bends
and spreads out, and thus presses the particles together on the convex surface of
i.e. the outer table, and forces them asunder on the concave surface or inner ta
lastly, there is nothing firm under the inner table to support it and oppose the forc
tures of the vault may be either simple, or starred and comminuted, and the
may be depressed or elevated. Cases of fracture with elevation of the fractures
are uncommon, and can only be produced by direct wound. In comminuted
a portion of the skull is broken into several pieces, the lines of fracture radiatin
centre where the chief impact of the blow was felt; if the fracture is also dep
fissure circumscribes the radiating lines, enclosing a portion of the skull. If
is circular it is termed a 'pond' fracture, and has probably been caused by a roun
ment, as a life-preserver or hammer; if elliptical in shape it is termed a 'gutter'
and owes its shape to the instrument which has produced it, as a poker. Fractu
outer table alone may occur in the region of the frontal air-sinuses where the t
are completely separated.

Fractures of the base of the skull may be produced by *indirect* or *direct* violen

I. In cases of the former class the violence is applied to the vertex or some p
cranial convexity, as when a person falls from a height on to his head and a fr
the base results. The mechanism of this form of fracture is explained, (*a*) by
of a fissure from the vertex to the base, or (*b*) by compression causing bursting
place at a weak point in the base.

II. Direct violence may be applied to the base of the skull in several differe
by the impact of the vertebral column against the condyles of the occipital bon
on the buttocks or feet; by the condyle of the mandible being driven against th
bular fossa, in blows or falls on the chin; by the thrusting of a pointed in
through the orbit or nose; by gunshot wounds through the mouth; and by a fall
on the back of the head.

In the majority of cases the fracture is compound. The most common place
ture of the base to occur is through the middle fossa, and here the fissure usually
fairly definite course. Starting from the point struck, which is generally some
the neighbourhood of the parietal eminence, it runs downwards through the par
the temporal squama and across the petrous portion, frequently traversing and in
the internal acoustic meatus, to the foramen lacerum. From this it may pass a
body of the sphenoidal bone, through the sella turcica, to the foramen lacerum of
side, and may indeed travel round the whole cranium so as completely to sep
anterior from the posterior part. The course of the fracture explains the sym
which fracture in this region may give rise: thus if the fissure pass across the
acoustic meatus injury to the facial and acoustic nerves may result, with co
facial paralysis and deafness; if the fissure extends through the semicircular can
ness will be complained of, especially on turning the head sideways; or the tub
longation of the arachnoid around the nerves in the meatus may be torn and the
of the escape of the cerebro-spinal fluid should there be a communication bet

CC-0.In Public Domain. Gurukul Kangri Collection, Haridwar

Digitized by Arya Samaj Foundation Chennai and eGangotri

al ear and the tympanic cavity together with rupture of the tympanic membrane, frequently the case: again, if the fissure pass across the sella turcica, and the mucoeum covering the under surface of the body of the sphenoidal bone is torn, blood nd its way into the pharynx and be swallowed, and after a time vomiting of blood sult. Fractures of the anterior fossa, involving the bones forming the roof of the and nasal cavity, are generally the result of blows on the forehead; but fracture lamina cribrosa of the ethmoid may be a complication of fracture of the nasal bone. the fracture implicates the roof of the orbit, the blood finds its way into this cavity, avelling forwards, appears as a subconjunctival ecchymosis. If the roof of the nasal be fractured, the blood escapes from the nose. In rare cases there may be also of cerebrospinal fluid from the nose should the dura mater and arachnoid have orn. In fractures of the posterior fossa, extravasation of blood may appear at the f the neck, beneath the muscles attached to the superior nuchal line of the occipital

formities of the skull.—General enlargement of the skull, producing characteristic nities of various types, occurs in certain rare diseases such as ostitis deformans, egaly, and leontiasis ossea; it also is present in the much commoner disorders, rickets rdrocephalus. In rickety cases the skull becomes enlarged from the formation of cal outgrowths of soft tissue on the outer side of the skull. These deposits are very blood-vessels, and occur between the ridges of the cranial bones and their centres fication, and are symmetrically arranged—often about the anterior fontanelle; s *nodes*, which are local thickenings of the diplöe or of the outer table are often ted with rickets, especially when congenital syphilis coexists. The anterior fonitself, instead of closing about the middle of the second year, remains patent until rd or even the sixth year. The general shape of the skull alters. The forehead is nd square, with prominent frontal eminences, and the head tends to be cubical or haped; the enlargement of the head in rickets appears to be greater than it really ause the development of the facial bones is retarded. The base of the nose may r sunken, from retarded development of the basis cranii. In congenital hydrolus, or enlargement of the head due to the presence of excess of fluid in the ventricles e brain, the cranium becomes globular, and its bones are thin and often widely ated.

e bones of the face are sometimes fractured as the result of direct violence. Those commonly broken are the nasal bones and the mandible; the latter is by far the frequently fractured of all the facial bones. Fracture of the *nasal bone* is for the part transverse, and takes place about 1·25 cm. from the free margin. The broken n may be displaced backwards or more generally to one side by the force which ced the lesion. The *zygomatic bone* is probably never broken alone—that is to say, ut fracture of some of the other bones of the face. The *zygomatic arch* is occasionfractured, and when this occurs as a result of direct violence the fragments may be ced inwards. Fractures of the *maxilla* may vary much in degree, from the chipping a portion of the alveolar arch to an extensive comminution of the whole bone from violence, as the kick of a horse. The most common situation for a fracture of the dle is in the neighbourhood of the canine tooth, as at this spot the bone is weakened e deep socket for the root of this tooth; it is next most frequently fractured at the ; then at the symphysis; and finally the neck of the condyle or the coronoid process e broken. Occasionally a double fracture may occur, one in either half of the bone. actures are usually compound, from laceration of the mucous membrane covering ms. Displacement readily occurs and is difficult to rectify; it results in inequality e line of the teeth and is commonly due to the muscles attached in the region of the ysis dragging this portion downwards.

the operation of excision of the maxilla, the central incisor tooth having been cted the incision is begun just below the medial canthus of the eye and passes along de of the nose round the ala and down the middle line of the upper lip into the h. A second incision is made from the commencement of the first along the lower er of the orbit as far as the prominence of the zygomatic bone. The flap thus formed ected, so as to expose the bone. The periosteum attached along the lower margin of rbit is now to be incised, and the periosteum covering the floor of the orbit is raised the bone, for in all cases it is essential that this fibrous layer should not be removed. outh is now widely opened with a gag, and the mucous membrane covering the hard e incised down to the bone in the middle line, and the soft palate separated from the The surgeon having first separated the ala of the nose from its bony attachment. eds to divide the connexions of the maxilla with the other bones of the face. They the junction with the zygomatic bone, the line of section being carried into the or orbital fissure; (2) the frontal process of the maxilla; a small portion of its upper ity, connected with the nasal bone in front, the lacrimal bone behind, and the bone above, being left; (3) the connexion with the opposite maxilla and with the e, are broken through. The bone is now firmly grasped and the remaining attachs of the orbital plate with the ethmoid, and of the back of the bone with the palatine roken through. Occasionally the orbital plate can be saved, and this should always me if possible, as it prevents lowering of the eyeball and consequent double vision. rizontal saw-cut should then be made just below the infra-orbital foramen.

CC-0. In Public Domain. Gurukul Kangri Collection, Haridwar.

Digitized by Arya Samaj Foundation Chennai and eGangotri

THE EXTREMITIES

The extremities or limbs are four in number: a *superior pair*, mainly to prehension; and an *inferior pair*, intended for support motion. Both pairs are constructed after a common type, but certain differences are observed between them.

The bones by which the upper and lower limbs are attached to constitute respectively the shoulder- and pelvic girdles. The *shoul* or *girdle of the superior extremities* is formed by the scapulæ and clavi is imperfect in front and behind. In front, however, it is complete upper end of the sternum, with which the medial ends of the clavicles a Behind, it is widely imperfect, the scapulæ being connected to the muscles only. The *pelvic girdle* or *girdle of the inferior extremities* is by the hip-bones which articulate with each other in front at the sy pubis. It is imperfect behind, but the gap is filled by the upper par sacrum. The pelvic girdle, with the sacrum, is a complete ring, mas comparatively rigid, in marked contrast to the lightness and mobility shoulder-girdle.

THE BONES OF THE SUPERIOR EXTREMITY

The Scapula

The **scapula** or shoulder-blade is a flat, triangular bone, with two three processes, three borders, and three angles. On the lateral a shallow concavity, the *glenoid cavity*, for articulation with the head humerus.

The *costal surface* (fig. 370) presents a broad cavity, the *subscapul* the medial two-thirds of which are marked by several oblique ridges lateralwards and upwards. The ridges give attachment to the te intersections, and the surfaces between them to the fleshy fibres, Subscapularis; the lateral one-third of the fossa is smooth and in cont this muscle. The fossa is separated from the vertebral border by triangular areas at the medial and inferior angles of the bone, and in the between the angles by a narrow ridge; these triangular areas and the inte narrow ridge afford attachment to the Serratus anterior. At the up of the fossa the bone is bent on itself along a line corresponding w attached margin of the spine.

The *dorsal surface* (fig. 371) is arched from above downwards, and divided into two fossæ by a projecting plate of bone, the *spine*; the above the spine is called the supraspinatous fossa, and that below it th spinatous fossa. The *supraspinatous fossa* is concave and smooth; its two-thirds give origin to the Supraspinatus. The *infraspinatous fossa* is larger than the preceding; towards its vertebral margin a shallow co is present at its upper part; the central part is convex, while that n axillary border is deeply grooved. From the medial two-thirds of th the Infraspinatus takes origin; the lateral one-third is in contact wi muscle. From the lower part of the glenoid cavity an elevated ridge runs wards and backwards and reaches the vertebral border, about 2·5 cm. the inferior angle; it gives attachment to a fibrous septum which separa Infraspinatus from the Teres major and Teres minor. The upper p the surface between the ridge and the axillary border is narrow; it gives to the Teres minor, and is crossed by a shallow groove for the passage scapular circumflex vessels. The lower part of the surface is sou triangular, and gives origin to the Teres major. The two parts are sep by an oblique line which runs downwards and backwards from the a border; a fibrous septum is attached to this oblique line, and separa Teres major from the Teres minor. The upper portion of the Lat dorsi glides over the Teres major, and frequently derives a few fibres of from the inferior angle of the bone.

CC-0. In Public Domain. Gurukul Kangri Collection, Haridwar

Digitized by Arya Samaj Foundation Chennai and eGangotri

he *spine* is a triangular plate, which crosses obliquely the medial four-fifths upper part of the dorsal surface of the scapula, and separates the supra- the infraspinatous fossa. It begins at the vertebral border in a smooth, ular area over which the tendon of insertion of the lower part of the zius glides, and, gradually becoming more elevated, ends in the acromion,

FIG. 370.—The left scapula. Costal aspect.

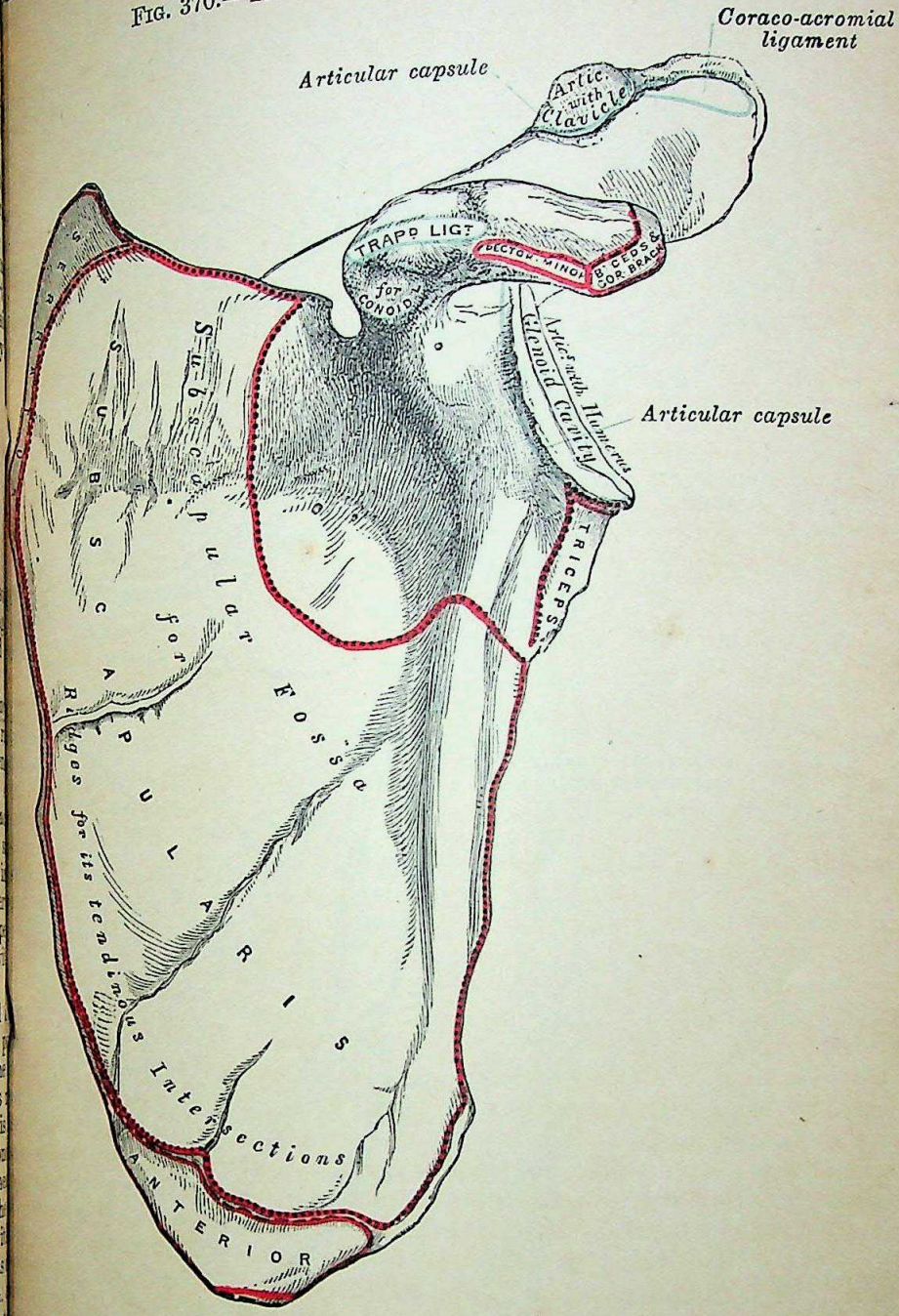

h overhangs the glenoid cavity. It is flat from above downwards, and pex is directed towards the vertebral border. It has two surfaces and e borders. Its *superior surface* forms a part of the supraspinatous fossa, gives origin to a portion of the Supraspinatus. Its *inferior surface* forms f the infraspinatous fossa, gives origin to a portion of the Infraspinatus, resents near its centre the orifice of a nutrient canal. The *anterior border* ached to the dorsal surface of the scapula. The *posterior border*, or *crest e spine*, is broad, with a superior and an inferior lip, and an intervening surface. The Trapezius is attached to the lateral three-fourths of the rior lip, and a rough tubercle is generally seen on the medial portion of

CC-0. In Public Domain. Gurukul Kangri Collection, Haridwar

Digitized by Arya Samaj Foundation Chennai and eGangotri

the lip for the tendon of insertion of the lower part of this muscle; the l
is attached to the whole length of the inferior lip; the area betwee
is subcutaneous and partly covered by the tendinous fibres of these
The *lateral border or base of the spine* is thick and slightly concave;
tinuous above with the under surface of the acromion, below with the

FIG. 371.—The left scapula. Dorsal aspect.

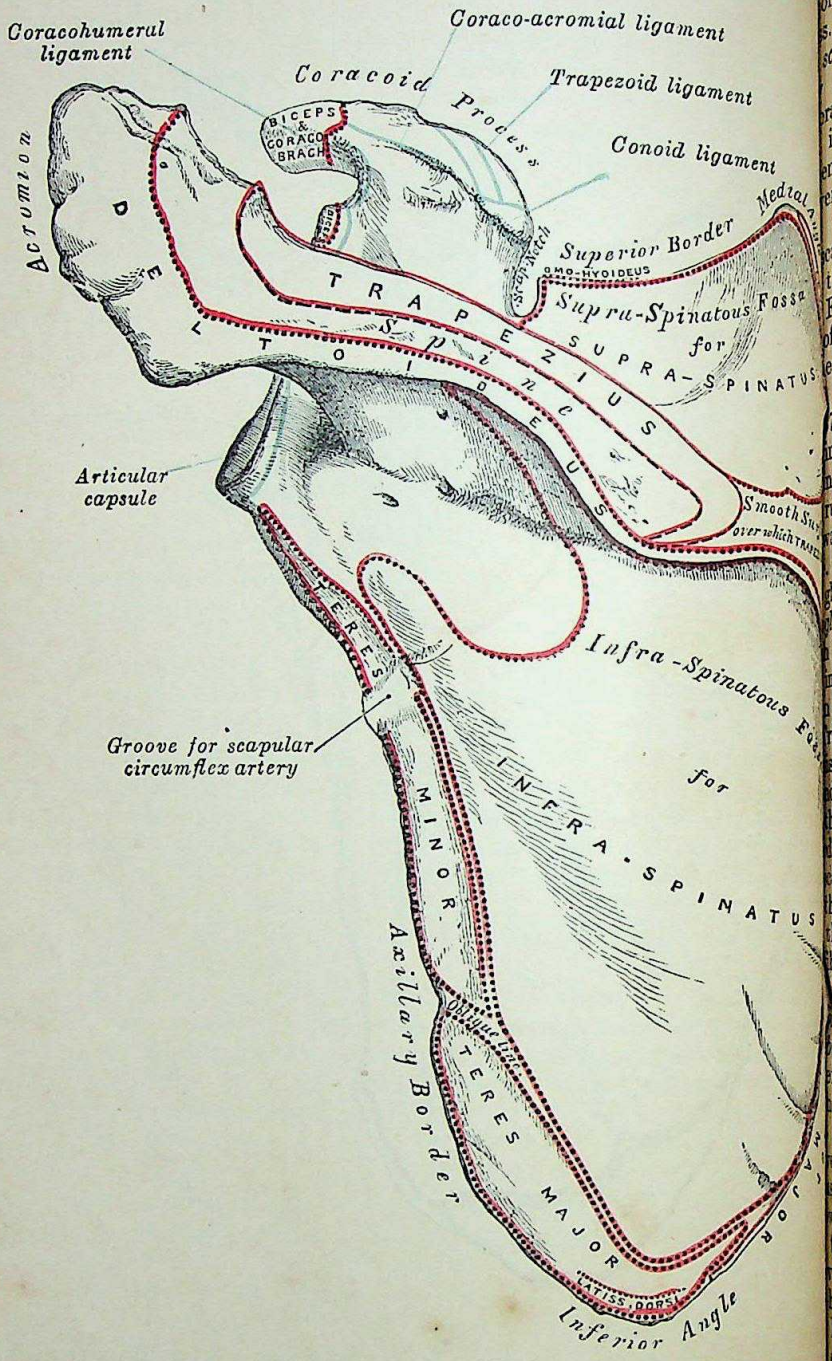

surface of the neck of the scapula. It forms the medial boundary of the *scapular notch*, which connects the supra- and infraspinatous fossæ.

The *acromion* is a large triangular or oblong process which proj first lateralwards from the spine, and then curves forwards and upw as to overhang the glenoid cavity. Its *superior surface*, directed u and slightly backwards and lateralwards, is subcutaneous. Its *inferior* is smooth and concave. Its *lateral border* is thick and irregular, an are three or four tubercles for the tendinous origins of the Deltoide

CC-0. In Public Domain. Gurukul Kangri Collection, Haridwar

Digitized by Arya Samaj Foundation Chennai and eGangotri

y border, shorter than the lateral, is concave; it gives attachment to a *n of the Trapezius*, and presents near its anterior extremity a small, oval *o for articulation* with the acromial end of the clavicle. Its *apex*, which *ponds* with the point of meeting of the lateral and medial borders in *is thin*, and to it the coraco-acromial ligament is attached.

the three borders of the scapula, the *superior* is the shortest and thinnest; *oncave*, and extends from the medial angle to the base of the coracoid *s*. At its lateral part *scapular notch*, formed by the base of *racoid process*. This is converted into a *en* by the superior *erse* scapular liga- and transmits the *scapular nerve*; some- the ligament is ossi- From the adjacent of the superior bor- *e* Omohyoideus takes The *axillary border* 72) is the thickest; *ns* above at the lower *n* of the glenoid cavity, *runs* downwards and *ards* to the inferior Immediately below *glenoid* cavity is the *glenoid tuberosity*, a impression about 2·5 *n* length, which gives *t* to the long head of *riceps brachii*; in front *s* a longitudinal groove *ds* as far as the lower *hird* of this border, and *s* origin to part of the *apularis*. The inferior *hird* is thin and serves *he* attachment of a *bres* of the Teres major *d*, and of the Sub- *aris* in front. The *ral border* is the longest *xtends* from the medial *e* inferior angle; it is so that the portion *e* the spine forms an *se* angle with the part *v*. It gives insertion *he* Levator scapulæ *e* the triangular surface *e* apex of the spine, to Rhomboideus minor on *dge* of that surface, and to the Rhomboideus major below it; the last *le* is usually attached by means of a fibrous arch, connected above to the *r* part of the triangular surface at the apex of the spine, and below to the *part* of the vertebral border.

FIG. 372.—The left scapula. Lateral aspect.

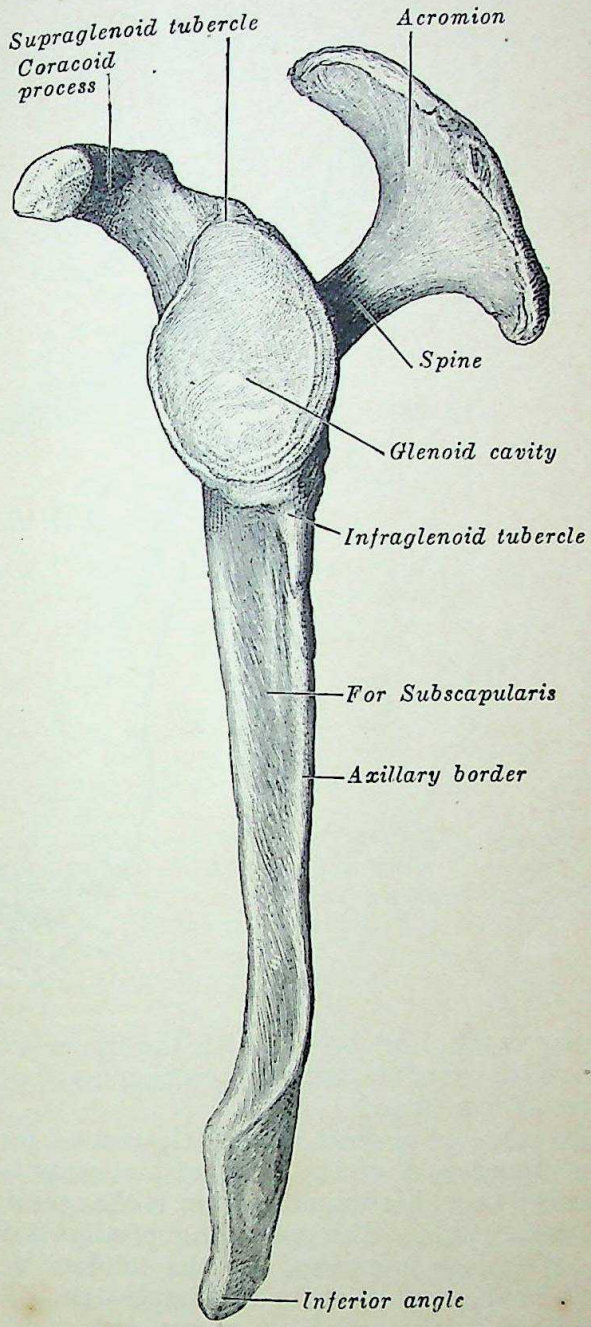

f the three *angles*, the *medial*, at the junction of the superior and vertebral *rs*, is thin and smooth; it gives attachment to a few fibres of the Levator *ulæ*. The *inferior angle*, thick and rough, is formed by the union of the *ebral* and axillary borders; its dorsal surface gives origin to the Teres *or* and frequently to a few fibres of the Latissimus dorsi. The *lateral*

CC-0. In Public Domain. Gurukul Kangri Collection, Haridwar

Digitized by Arya Samaj Foundation Chennai and eGangotri

angle is the thickest part of the bone, and is sometimes called the h
scapula. It supports the coracoid process, and on its lateral surface is
pyriform, articular surface, the *glenoid cavity* (fig. 372). This ca
lateralwards and forwards and articulates with the head of the hum
broader below than above and its vertical diameter is the longe
margin is attached a fibrocartilaginous lip, the glenoidal labrum, whi
the cavity. At its apex is a small elevation, the *supraglenoid tuber*
which the long head of the Biceps brachii takes origin.

The *neck* of the scapula (collum scapulæ) is the somewhat constr
between the body and the head of the bone. Above, it correspond

FIG. 373.—A plan of the ossification of the scapula. From seven cen

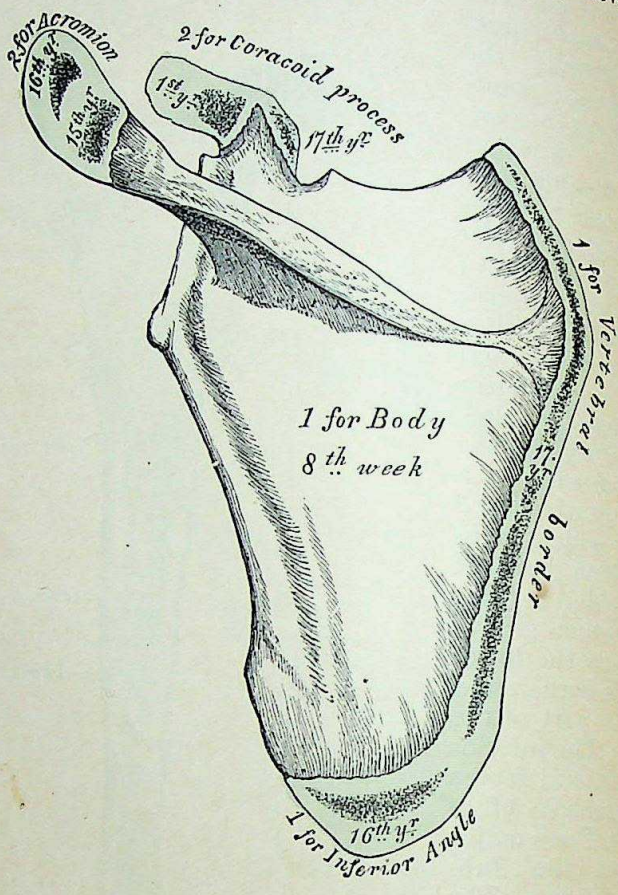

scapular notch, and below, with the upper end of the infraglenoid tub
On the surfaces of the bone its position may be indicated by lines drawn
the points mentioned.

The *coracoid process* is a thick curved process attached by a bro
to the upper part of the head of the scapula; it runs at first upwa
forwards; then, becoming smaller, it changes its direction, and projects
and lateralwards. The ascending portion is flat from before backwa
anterior surface is crossed by the tendon of the Subscapularis, its p
surface by the tendon of the Supraspinatus. The horizontal portion is
from above downwards; its upper surface is convex and irregular, an
attachment to the Pectoralis minor; its under surface is smooth; its
and lateral borders are rough, the former giving attachment to the Pe
minor, and the latter to the coraco-acromial ligament; the conjoined
of origin of the Coracobrachialis and short head of the Biceps brac
the coracoclavicular fascia are attached to the apex of the coracoid p
On the angle of junction of the ascending and horizontal portions of the co
process is a rough impression for the attachment of the conoid ligamen
running from this impression obliquely forwards and lateralwards, on
upper surface of the horizontal portion, is an elevated ridge for the atta
of the trapezoid ligament.

CC-0. In Public Domain. Gurukul Kangri Collection, Haridwar

Digitized by Arya Samaj Foundation Chennai and eGangotri

ructure.—The head, processes, and thickened parts of the scapula contain y substance; the rest consists of a thin layer of compact bone. The central f the supraspinatous fossa and the greater part of the infraspinatous fossa are occasionally the bone is wanting in these situations, the gaps being filled rous tissue.

sification (fig. 373).—The scapula is ossified from seven or more centres: r the body, two for the coracoid process, two for the acromion, one for the ral border, and one for the inferior angle.

e centre for the body appears in the eighth week of fœtal life, and spreads m an irregular quadrilateral plate of bone, immediately behind the glenoid . This plate forms the chief part of the bone, and the spine grows up from rsal surface about the third month. At birth, the glenoid cavity, coracoid s, acromion, vertebral border, and inferior angle are cartilaginous. In the ear of life, ossification begins in the middle of the coracoid process, and this s joins the rest of the bone about the fifteenth year. Between the fourteenth wentieth years, ossification of the remaining parts usually takes place in the ing order; first, in the root of the coracoid process; second, near the of the acromion; third, in the inferior angle and contiguous part of rtebral border; fourth, near the extremity of the acromion; fifth, in the ral border. The base of the acromion is formed by an extension from ne; the rest of the acromion is ossified from two centres which unite, and oin the extension from the spine. The upper one-third of the glenoid is ossified from a subcoracoid centre, which appears between the tenth eventh, and joins between the sixteenth and the eighteenth, years. Further, physial plate appears for the lower part of the glenoid cavity, while the tip of racoid process frequently presents a separate centre. These various epiphyses ined to the bone by the twenty-fifth year.

plied Anatomy.—Fractures of the body of the scapula are rare, owing to the ity of the bone, the thick layers of muscles by which it is encased, and the elasticity ribs on which it rests. The most frequent course of a fracture is from the scapular to the infraglenoid tuberosity, and it derives its principal interest from its simula- f a subglenoid dislocation of the humerus. The diagnosis can be made by noting teration in the position of the coracoid process. The acromion is more frequently n than any other part of the bone, and fibrous union is very liable to follow. Failure y union between the acromion and spine sometimes occurs and may simulate a re; and the junction of these two parts may be then effected by fibrous tissue, or imperfect articulation.

e presence of 'winged scapulæ' (scapulæ alatæ) described in thin persons of feeble lar development in whom the lower angles of the scapulæ project unduly, is due to abnormal roundness of the thoracic wall, and partly to weakness and flaccidity Latissimus dorsi and Serratus anterior. The shoulders are held low in these subjects, e clavicles slope downwards and forwards, carrying with them the scapulæ, which the posterior wall of the chest and so tend to project from it.

The Clavicle (Clavicula)

e clavicle or collar-bone (figs. 374, 375) articulates medially with the brium sterni, and laterally with the acromion of the scapula.* It is a bone, and is placed nearly horizontally at the upper and anterior part of horax. It is bent somewhat like the italic letter *f*, presenting a double ature, with a convexity forwards at the sternal end and a concavity forwards e acromial end. Its lateral one-third is flattened, whilst its medial two- s are cylindrical or prismoid in form.

e lateral one-third of the clavicle has two surfaces, an upper and a lower, two borders, an anterior and a posterior. The *upper surface* is flat and d; it affords attachment to the Deltoideus in front, and the Trapezius d; between these a small portion of the surface is subcutaneous. The

e clavicle acts especially as a fulcrum to enable the muscles to give lateral motion to . It is accordingly absent in those animals whose fore-limbs are used only for progression, present for the most part in animals whose anterior extremities are clawed and used for sion, though in some of them—as, for instance, in a large number of the carnivora—a rudimentary bone suspended among the muscles, and not articulating with either the a or the sternum.

CC-0. In Public Domain. Gurukul Kangri Collection, Haridwar

Digitized by Arya Samaj Foundation Chennai and eGangotri

lower surface is flat; at its posterior border, near the junction with the two-thirds of the bone, is a rough eminence, the *coracoid tuberosity* tubercle); this overlies the coracoid process of the scapula, and gives ment to the conoid ligament. From this tuberosity, the *oblique or ridge* runs forwards and lateralwards, and affords attachment to the ligament. The *anterior border* is concave, thin, and rough, and gives a portion of the Deltoideus; at its medial part there is frequently a the *deltoid tubercle*. The *posterior border*, convex, rough, and thicker anterior, gives insertion to a part of the Trapezius.

The **medial two-thirds** of the clavicle constitute the prismoid portion bone, which is marked by three borders, separating three surfaces. The *border* is continuous with the anterior border of the flat portion. Its lat is smooth, and corresponds to the interval between the attachment

Fig. 374.—The left clavicle. Superior aspect.

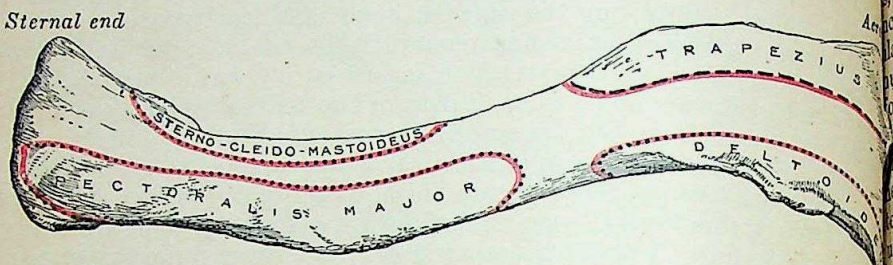

Fig. 375.—The left clavicle. Inferior aspect.

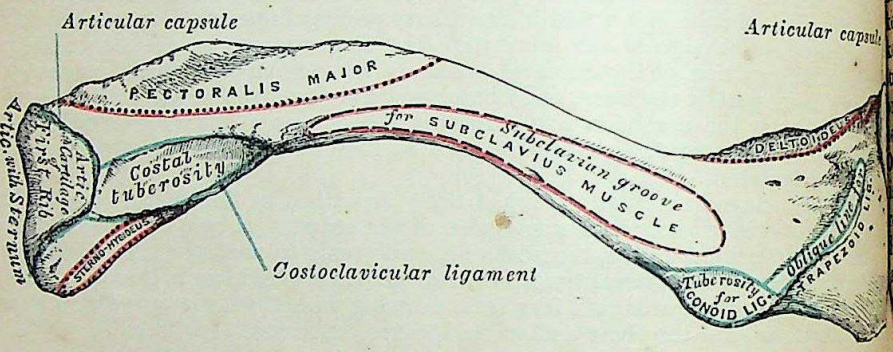

Pectoralis major and Deltoideus; its medial part forms the lower bo of an elliptical surface for the attachment of the clavicular portion Pectoralis major. The *superior border* is continuous with the posterior of the flat portion, and separates the anterior from the posterior surface. S and rounded laterally, it becomes rough towards the medial one-third attachment of the Sternocleidomastoideus, and ends at the upper a the sternal extremity. The *subclavian or posterior border* separates the p from the inferior surface, and extends from the coracoid tuberosity costal tuberosity; it forms the posterior boundary of the groove for th clavius, and gives attachment to a layer of cervical fascia which co the Omohyoideus. The *anterior surface* is between the superior and a borders. Its lateral part looks upwards, and is continuous with the s surface of the flattened portion; it is smooth, convex, and nearly subcut being covered only by the Platysma. Its medial part is divided by a subcutaneous region into two areas; a lower, elliptical in form, and di forwards, for the attachment of the Pectoralis major; and an upper, attachment of the clavicular part of the Sternocleidomastoideus. The p *or cervical surface* is smooth, and looks backwards towards the root of th It is limited, above, by the superior border; below, by the subclavian

CC-0. In Public Domain. Gurukul Kangri Collection, Haridwar

Digitized by Arya Samaj Foundation Chennai and eGangotri

ally, by the margin of the sternal extremity; and laterally, by the coracoid rosity. It is in relation with the transverse scapular vessels, and, at the tion of the curves of the bone, with the brachial plexus of nerves and ubclavian vessels. Near the sternal end, this surface gives attachment to of the Sternohyoideus; and near the middle of this surface is a foramen he transmission of a nutrient artery which runs lateralwards into the A second nutrient artery may enter this, or the inferior, surface. The or or *subclavian surface* is between the anterior and subclavian borders. narrow medially, but increases in width laterally, and is continuous with ower surface of the lateral one-third. On its medial part is a rough area, stal *tuberosity* (rhomboid impression), rather more than 2 cm. in length, e attachment of the costoclavicular ligament. The rest of this surface is ed, and gives insertion to the Subclavius muscle; the coracoclavicular splits to enclose the muscle and is attached to the margins of the groove. he sternal end of the clavicle is triangular in form, and is directed medial- s, and a little downwards and forwards. On it is an articular facet which ncave from before backwards, and convex from above downwards; it lates with the articular disc of the sternoclavicular joint. This facet is ued on to the anterior and inferior sufaces of the bone as a small semi-oval for articulation with the cartilage of the first rib. The circumference of icular surface is rough for the attachment of ligaments; the upper angle narrow rough area below it give attachment to the articular disc.

e acromial end of the clavicle presents a small, flattened, oval surface ed slightly downwards, for articulation with the acromion of the scapula. upper margin of the facet is rough for the attachment of the acromio- ular ligament.

n the female, the clavicle is shorter,* thinner, less curved, and smoother in the male. In the female the acromial end is a little below the level of ternal end; in the male it is on a level with, or slightly higher than, the al end. In persons who perform hard manual labour the clavicle is er and more curved, and its ridges for muscular attachment are better ed.

ructure.—The clavicle consists of spongy substance, enveloped by a layer mpact bone which is much thicker in the intermediate part than at the ends e bone.

ssification.—The clavicle begins to ossify before any other bone in the body, s ossified from three centres. The body of the bone is ossified from two primary es, † a medial and a lateral, which appear between the fifth and sixth weeks of life, and fuse about the forty-fifth day; a secondary centre for the sternal ppears about the eighteenth or twentieth year, and unites with the body bone about the twenty-fifth year.

14 mm. embryo the future clavicle is represented by a band of mesoderm which s from the acromion of the scapula to the tip of the first rib, and is continuous with ment of the sternum. In this band a medial and a lateral mass of 'precartilage' eloped, and in the adjacent ends of these masses the two centres for the body of one appear and soon fuse with each other. The sternal and acromial ends of the inous masses are converted into cartilage and into this the ossification of the of the bone extends.

plied Anatomy.—The clavicle is very frequently fractured, since it is much exposed ence, and is the only bony connexion between the upper limb and the trunk, acting buttress to keep the point of the shoulder away from the thorax. It is, moreover, , and is very superficial. The most common cause is indirect violence, as the of force applied to the hand or shoulder, and the bone then gives way at the junction lateral with its intermediate third, that is to say, at the junction of the two curves, is its weakest part. The fracture is generally oblique, and the displacement of the fragment is downwards, forwards, and medialwards. The deformity is mainly due weight of the arm acting upon the fragment when the buttress-like action of the gone, assisted by the muscles which pass from the thorax to the upper extremity.

G. Parsons (*Journal of Anatomy and Physiology*, vol. li.) gives the following as the average of the clavicle in the male and female: male, left, 154 mm., right, 152 mm.; female, 3 mm., right, 138 mm.

ll, *American Journal of Anatomy*, vol. v., 1906; Fawcett, *Journal of Anatomy and ology*, vol. xlvii.; Hanson, *Anatomical Record*, vol. xix. (number 6), 1920.

CC-0. In Public Domain. Gurukul Kangri Collection, Haridwar

Digitized by Arya Samaj Foundation Chennai and eGangotri

The medial fragment, as a rule, is little displaced. The main vessels of the
and the great nerve-cords of the brachial plexus lie beneath the bone on the
are liable to be wounded, especially in fracture from direct violence, when the
blow drives the broken ends inwards. Fortunately the Subclavius intervenes
these structures and the clavicle, and often protects them from injury.

The clavicle is occasionally the seat of sarcomatous tumours, rendering the
of excision of the entire bone necessary. This is an operation of considerable
and danger. It is best performed by exposing the bone freely, disarticulating
acromial end, and turning it forwards. The removal of the lateral part is comp
easy, but resection of the medial part is fraught with difficulty, the main da
the risk of wounding the great veins which are in relation with its deep surface.

Great deformity of the clavicle may be met with in rickets, the natural cur
the bone being exaggerated until it takes an S shape, and 'green-stick' frac
uncommonly seen associated therewith.

The Humerus

The **humerus** (figs. 377, 378), the longest and largest bone of th
limb, is divisible into a body or shaft, and two ends.

The **upper end** consists of the *head* and the *greater* and *lesser tuberc*

The **head** of the humerus (fig. 376), nearly hemispherical in
directed upwards, medialwards, and a little backwards; it articulat

Fig. 376.—The upper end of the left humerus. Superior aspect.

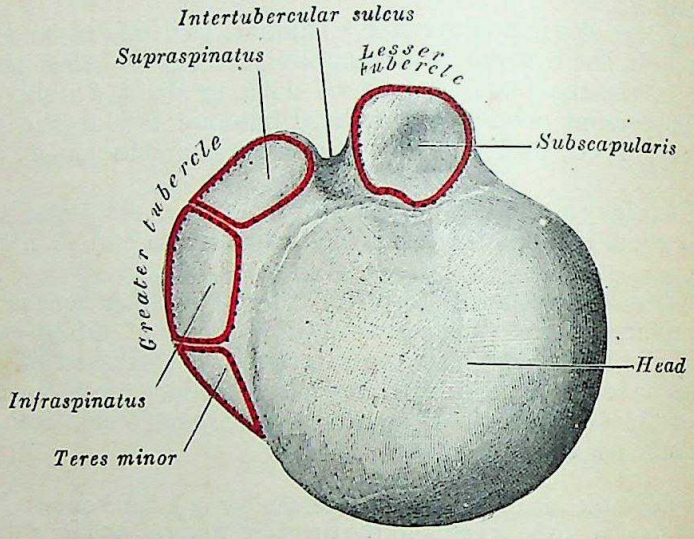

the glenoid cavity of the scapula. The circumference of its articular
is slightly constricted, and is termed the *anatomical neck*, in contradis
to a constriction below the tubercles, which is called the *surgical neck* be
is frequently the seat of fracture.

The *anatomical neck* forms an obtuse angle with the body and is best
in the lower half of its circumference; in the upper half it is represent
narrow groove separating the head from the tubercles. It affords atta
to the articular capsule of the shoulder-joint, and is perforated by fo
for the transmission of blood-vessels.

The *greater tubercle* is lateral to the head and lesser tubercle. Its
surface is convex and marked by three impressions; the highest of thes
insertion to the Supraspinatus; the middle, to the Infraspinatus; the
and the bone for about 2·5 cm. distal to it, to the Teres minor. The
surface of the greater tubercle is convex, rough, and continuous with the
surface of the body.

The *lesser tubercle*, more prominent than the greater, is situated in
and is directed forwards and medialwards. On its upper and front pa
impression for the insertion of the tendon of the Subscapularis.

CC-0. In Public Domain. Gurukul Kangri Collection, Haridwar

Digitized by Arya Samaj Foundation Chennai and eGangotri

etween the tubercles is the
ubercular sulcus (bicipital
re), which lodges the long
on of the Biceps brachii,
units a branch of the
or humeral circumflex
y to the shoulder-joint,
gives insertion to the
n of the Latissimus dorsi.
ulcus diminishes in depth
wards, and, near the
ion of the upper with the
le one-third of the bone,
ntinuous with the antero-
al surface. The lips of
ulcus are called the *crests*
greater and lesser tubercles
tal ridges), and form the
parts of the anterior and
l borders of the body of
ne.

e body or shaft of the
rus is almost cylindrical
e, but prismoid and flat-
d below; it has three
ers and three surfaces.
The *anterior border* runs
the front of the greater
rcle above to the coronoid
below, and separates
anteromedial from the
rolateral surface. Its upper
the crest of the greater
rcle, serves for the inser-
of the tendon of the Pecto-
major; its middle part
s the anterior boundary
he deltoid tuberosity; its
r part is smooth and
ded, and affords attach-
to the Brachialis.

e *lateral border* runs from
ck of the greater tubercle
he lateral epicondyle, and
rates the anterolateral from
posterior surface. Its
r half, which is indistinctly
ed, gives insertion to the
r part of the Teres minor,
origin to the lateral head
the Triceps brachii; its
le part is traversed by a
w oblique depression, the
a *nervi radialis* (musculo-
l groove). Its lower part
s a prominent rough
gin, the *lateral supracondy-*
le, which is curved for-
, and gives attachment
e lateral intermuscular
m. The proximal two-
s of this ridge give origin
the Brachioradialis; the

FIG. 377.—The left humerus. Anterior aspect.

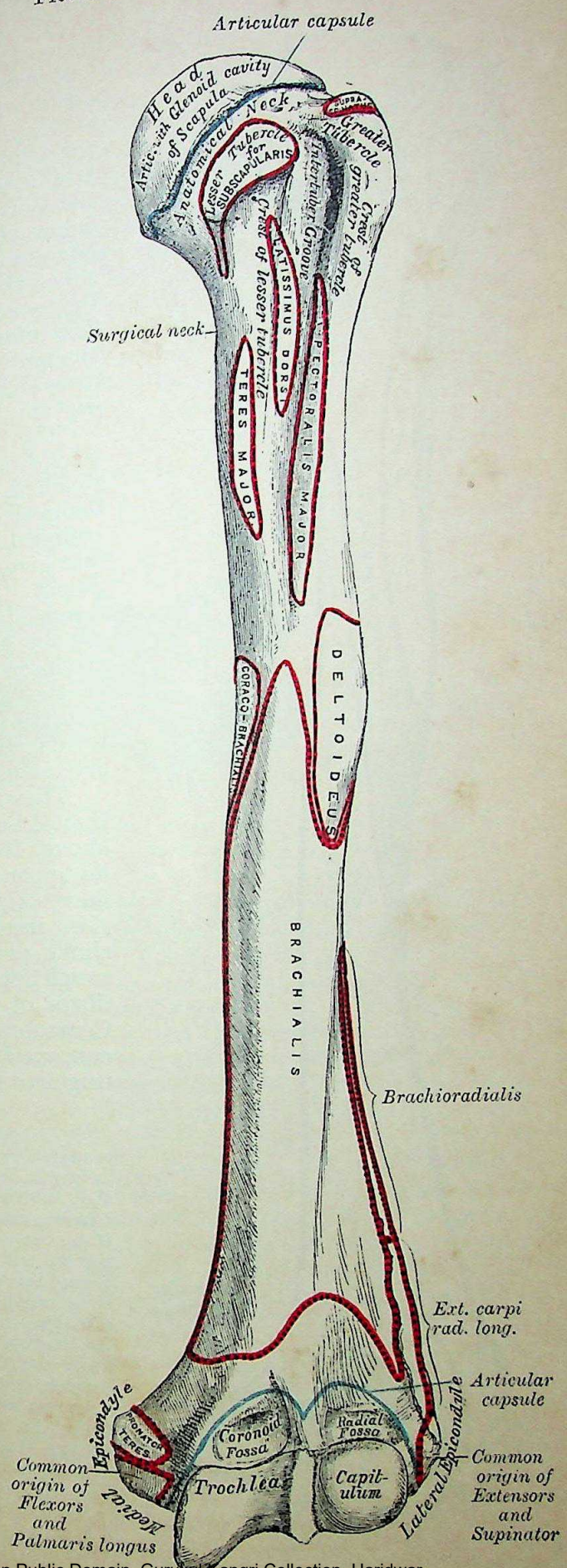

CC-0. In Public Domain. Gurukul Kangri Collection, Haridwar

Digitized by Arya Samaj Foundation Chennai and eGangotri

FIG. 378.—The left humerus. Posterior aspect.

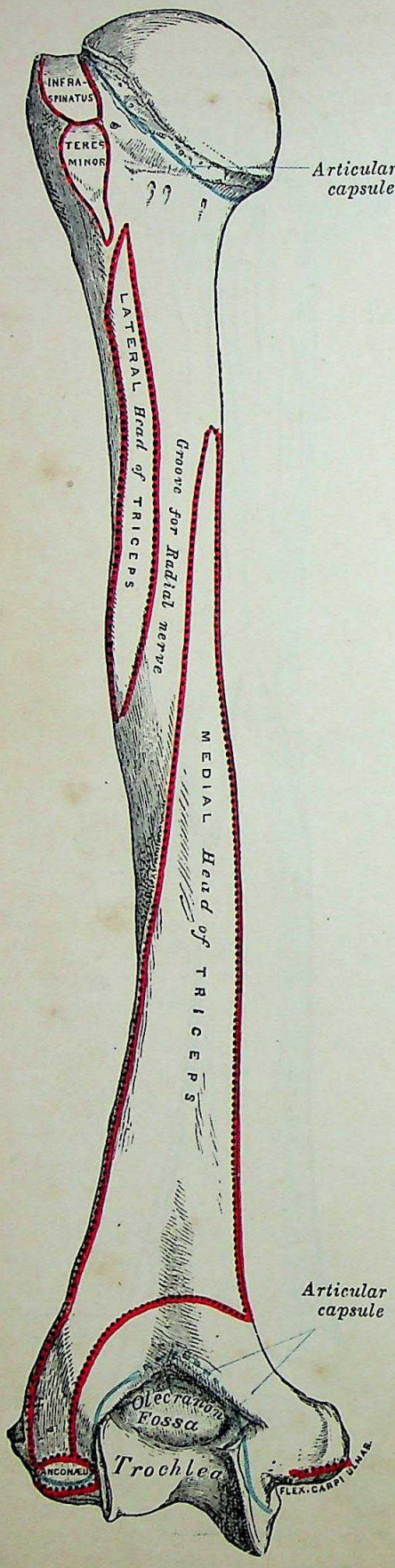

distal one-third, to the Exte radialis longus.

The *medial border* extends lesser tubercle to the medial and separates the anteromedial posterior surface. Its upper part of the lesser tubercle, gives in the tendon of the Teres major. middle is a slight impression for tion of the Coracobrachialis, below this the nutrient canal bone, and is directed downward times there is a second nutrient the commencement of the radi The inferior one-third of this lo the *medial supracondylar ridge* w attachment to the medial inter septum, and is prominent below.

The *anterolateral surface* is lateralwards above, where it is rounded, and covered by the De forwards and lateralwards below, is slightly concave from above do and gives origin to part of the B About the middle of this surf rough elevation, triangular in sh the apex below, the *deltoid tube* the insertion of the Deltoideus; b is the sulcus nervi radialis, w directed from behind, forwards, a wards, and transmits the radial n arteria profunda brachii.

The *anteromedial surface*, less than the anterolateral, is directed above, forwards and medialwards its upper part, which is narrow, f floor of the intertubercular sul gives insertion to the tendon of th simus dorsi; its middle part is rough for the attachment of som fibres of the tendon of insertion Coracobrachialis; its lower part is concave from above downwards, a origin to the Brachialis.*

* A hook-shaped process of bone, th *condylar process*, varying from 2 mm. to in length, is not infrequently found projec the anteromedial surface of the body humerus, about 5 cm. above the medial e It is curved downwards and forwards, pointed end is connected to the medial bo above the epicondyle, by a fibrous ban gives origin to a portion of the Pronat through the arch completed by this fibr the median nerve and brachial artery p these structures deviate from their usu Sometimes the nerve alone is transmitted it, or the nerve may be accompanied by artery, in cases of high division of the artery. A groove is usually found behind cess, in which the nerve and artery are This arch is the homologue of the supra foramen found in many animals, and probab in them to protect the nerve and artery fr pression during the contraction of the m this region.

CC-0. In Public Domain. Gurukul Kangri Collection, Haridwar

Digitized by Arya Samaj Foundation Chennai and eGangotri

e *posterior surface* appears somewhat twisted, so that its upper part ted a little medialwards, its lower part backwards. Nearly the whole surface is covered by the lateral and medial heads of the Triceps brachii, mer arising above, the latter below the radial sulcus.

e lower end of the humerus is flattened from before backwards, and slightly forwards; it ends in a broad, articular surface which is divided o parts by a smooth ridge. Projecting on either side, at a higher level he articular surface, are the lateral and medial epicondyles. The *articular* (fig. 379) is curved slightly forwards, and its medial extremity is lower the lateral. The lateral portion of this surface is a smooth, rounded ce, named the *capitulum* of the humerus; it articulates with the cup- depression on the head of the radius, and is limited to the front and lower the bone. On the medial side of the capitulum is a shallow groove, in the medial margin of the head of the radius is received; above the art of the capitulum is a small depression, the *radial fossa*, which receives erior border of the head of the radius, when the forearm is flexed. The portion of the articular surface is named the *trochlea* or pulley; it ates with the semilunar notch of the ulna. Its central part consists of

FIG. 379.—The lower end of the left humerus. Inferior aspect.

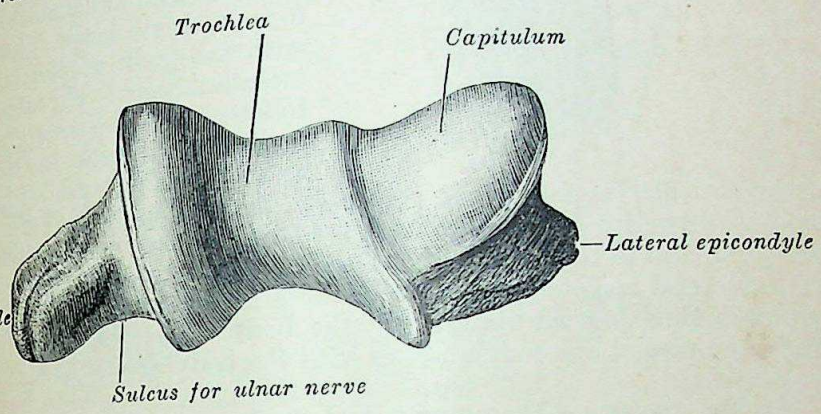

groove which winds spirally from before backwards and lateralwards the lower end of the bone; the groove is deeper behind where it expands ppy the whole width of the trochlea. The medial margin of the trochlea minent, and forms about two-thirds of a circle, and the adjacent portion articular surface is convex from side to side on the front and lower the bone; on the posterior surface the convexity disappears. The l margin of the trochlea is rounded in front and below, where it is separated the capitulum by the groove which receives the margin of the head of the s; posteriorly the margin is sharp and prominent. Above the trochlea, nt, is a depression, the *coronoid fossa*, which receives the coronoid process ulna when the forearm is flexed, and above the trochlea, behind, is a triangular depression, the *olecranon fossa*, in which the summit of the non is received when the forearm is extended. These fossæ are separated one another by a thin lamina of bone, which is sometimes perforated e *supratrochlear foramen*; they are lined in the recent state by the rial stratum, and their margins afford attachment to the fibrous stratum, e articular capsule of the elbow-joint. The *lateral epicondyle* is small and culated, and curved a little forwards; it gives attachment to the radial eral ligament of the elbow-joint and to a tendon common to the origin of upinator and some of the extensor muscles of the forearm. The *medial* dyle, larger and more prominent than the lateral, is directed a little ards; it gives attachment to the ulnar collateral ligament of the elbow- to the Pronator teres, and to a common tendon of origin of some of the muscles of the forearm; the ulnar nerve and posterior ulnar recurrent run in a groove (*sulcus nervi ulnaris*) on the back of this epicondyle. upracondylar ridges end at the epicondyles.

CC-0. In Public Domain. Gurukul Kangri Collection, Haridwar

Digitized by Arya Samaj Foundation Chennai and eGangotri

Structure. The ends of the humerus consist of spongy substance, co a thin layer of compact bone (fig. 380); the body is composed of a compact bone, thicker at the c towards the extremities, and medullary canal extends throu length.

FIG. 380.—A longitudinal section through the head of the left humerus.

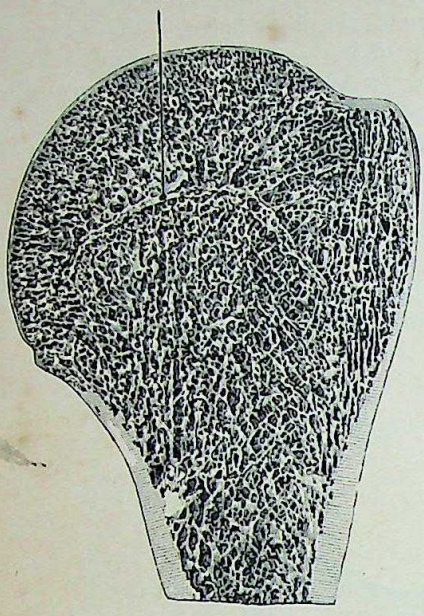

Ossification (figs. 381, 382).—T erus is ossified from eight centre each of the following parts: the head, the greater tubercle, the lesse the capitulum and lateral part of lea, the medial part of the trochle for either epicondyle. The centr body appears near the middle in t week of fœtal life, and gradually towards the ends, which at birth laginous. During the first year, occ before birth, ossification begins in during the third year in the tubercle, and during the fifth in th tubercle. By the sixth year the for the head and tubercles have form a single large epiphysis, whi with the body of the humerus al twentieth year. The lower end is o follows. At the end of the seco ossification begins in the capitul extends medialwards to form the c of the articular surface; the centre for the medial part of the trochlea about the twelfth year. Ossification begins in the medial epicondyle a fifth year, and in the lateral about the thirteenth or fourteenth year. Th for the lateral epicondyle fuses with those for the trochlea and capitulum. epiphysis thus formed unites with the body about the sixteenth or sev year; the medial epicondyle unites with the body about the eighteenth ye

Applied Anatomy.—The upper end of the humerus, though the first to ossi last to join the body, and the length of the bone is mainly due to growth from t epiphysial plate. Hence, in cases of amputation through the arm in young sub humerus continues to grow considerably, and the lower end of the bone, which ately after the operation was covered with a thick cushion of soft tissue, begins to thinning the soft parts and rendering the stump conical. This may necessi removal of about 5 cm. of the bone, and even after this operation a recurrenc conical stump may take place. The region of the upper epiphysis is a common the growth of tumours, both innocent and malignant.

The upper one-third of the humerus is best exposed through an incision al anterior border of the Deltoideus; the middle one-third by continuing this incision wards through the middle of the Brachialis between the parts of the muscle sup the musculocutaneous and radial nerves; the lower one-third by an incision al lateral epicondylar ridge.

Fractures of the humerus are common. This bone is probably more frequent tured by muscular action than any other long bone; it is usually the body of th just below the insertion of the Deltoideus, which is thus broken, and the accid been known to happen from throwing a stone or a hand-grenade. Fracture anatomical neck is a very rare accident. Fracture of the surgical neck of the bon uncommon; impaction may occur, or the upper end of the lower fragment may placed into the axilla and damage the vessels or nerves. The fracture simulates dis of the shoulder-joint, but can be distinguished by the fact that the head of the bone in its normal position and the greater tubercle still forms the most prominent poi shoulder. Separation of the upper epiphysis sometimes occurs in the young subj is marked by a characteristic deformity, the upper end of the diaphysis projecting at at the front of the joint a short distance below the coracoid process. In fractures upper end of the humerus, extension with the arm in the abducted position is ne so that should ankylosis take place the mobility of the scapula may be brought u use. In fractures of the body of the humerus the lesion may take place at any but appears to be more common in the lower than the upper part of the bone. Th of interest in connexion with these fractures are: (1) that the radial nerve may be as it lies in the groove on the bone, or may become involved in the callus w

CC-0. In Public Domain. Gurukul Kangri Collection, Haridwar

Digitized by Arya Samaj Foundation Chennai and eGangotri

ently thrown out; and (2) the frequency of non-union, which is believed to be more in the humerus than in any other bone. The non-union is in some measure due difficulty in fixing the bone, since the upper end articulates with the movable and the body lies by the chest-wall which moves with each respiration. Again, s attached to the entire circumference of the bone and is liable to get between the ts, should there be any overlapping of the latter. The axillary (circumflex) nerve

381.—A plan of the ossification of the humerus.

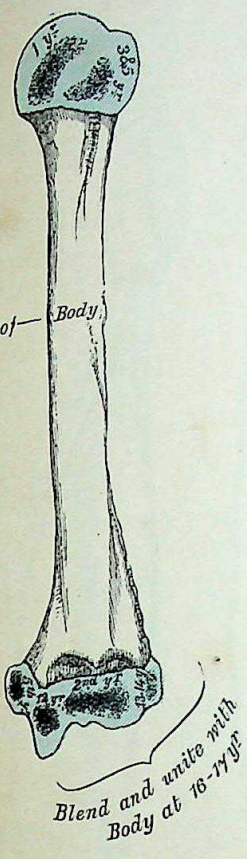

FIG. 382.—The epiphysial lines of the left humerus in a young adult. Anterior aspect.

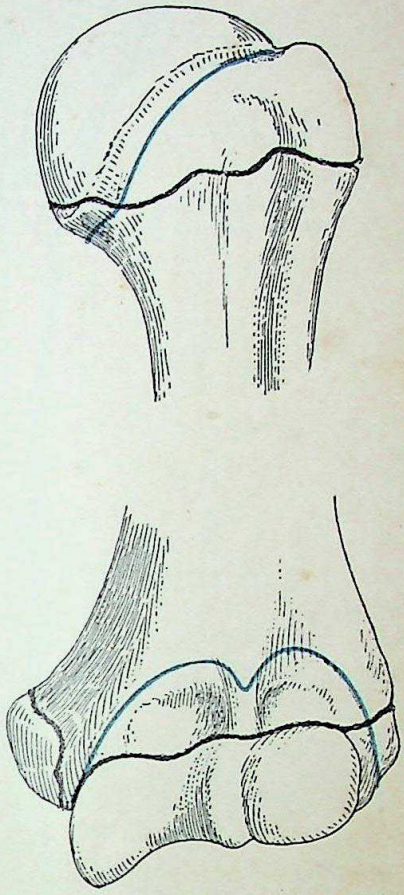

The lines of attachment of the articular capsules are in blue.

injured by fractures of the upper end of the bone and the ulnar nerve by fracture medial epicondyle. In fractures of the lower end it is important to distinguish those that involve the elbow-joint and those that do not; the former are always as they may lead to impairment of the utility of the limb; they include the ed fracture and oblique fractures which involve the articular surface. Those which involve the joint are the transverse fracture above the epicondyles, and the so-called bear fracture, where the tip of the medial epicondyle is broken off, generally by violence.

THE RADIUS

e radius (figs. 383 and 384) is situated on the lateral side of the forearm. a long bone, prismoid in form and slightly curved longitudinally. Its end is small, and forms only a small part of the elbow-joint; its lower s large, and forms a large part of the wrist-joint.

e upper end of the radius consists of a head, neck, and tuberosity. The disc-shaped, and on its proximal surface is a shallow cup for articulation he capitulum of the humerus. The circumference of the head is smooth; road medially where it articulates with the radial notch of the ulna, and w in the rest of its extent which is embraced by the annular ligament. ead is supported on a round, smooth, and constricted *neck*. Below the

CC-0. In Public Domain. Gurukul Kangri Collection, Haridwar

Digitized by Arya Samaj Foundation Chennai and eGangotri

FIG. 383.—The bones of the left forearm. Volar aspect.

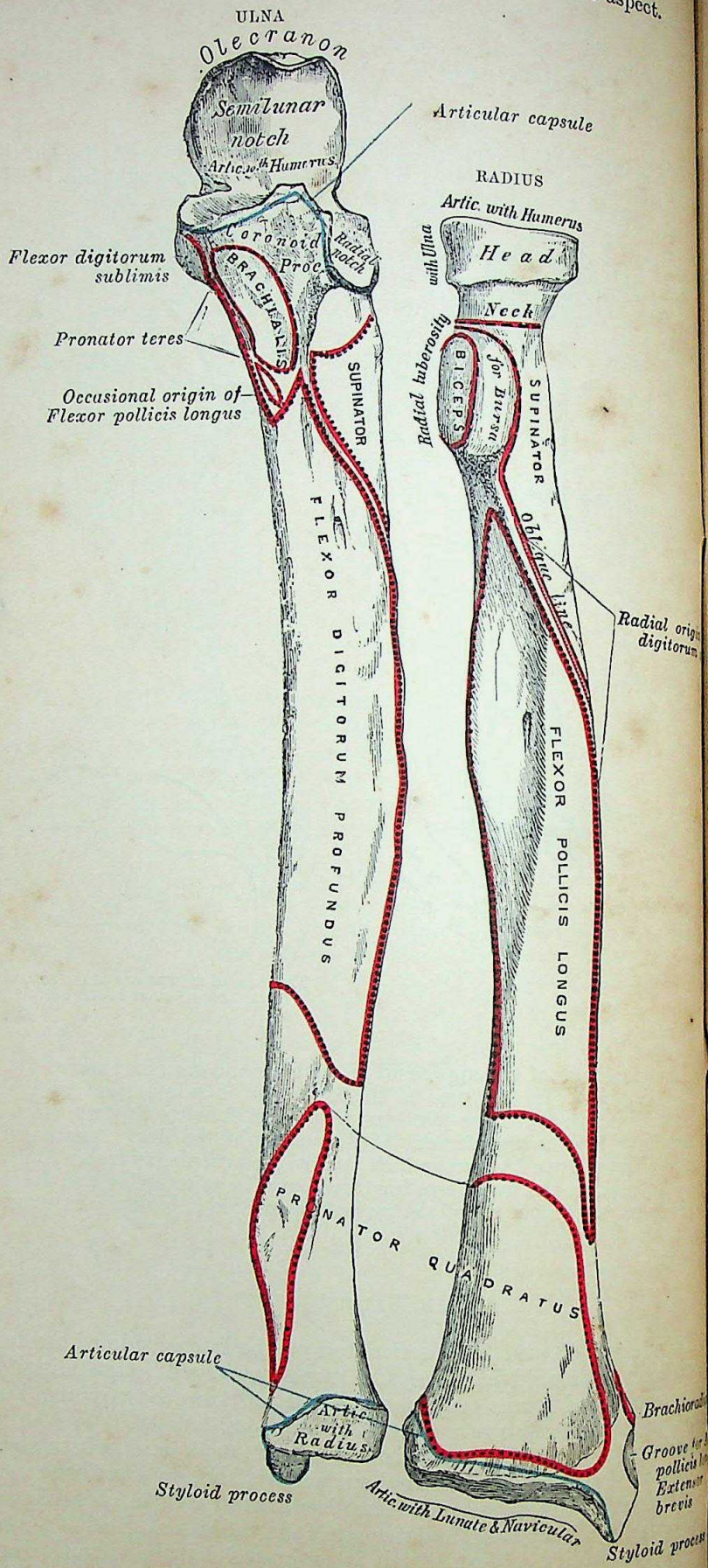

CC-0. In Public Domain. Gurukul Kangri Collection, Haridwar

Digitized by Arya Samaj Foundation Chennai and eGangotri

FIG. 384.—The bones of the left forearm. Dorsal aspect.

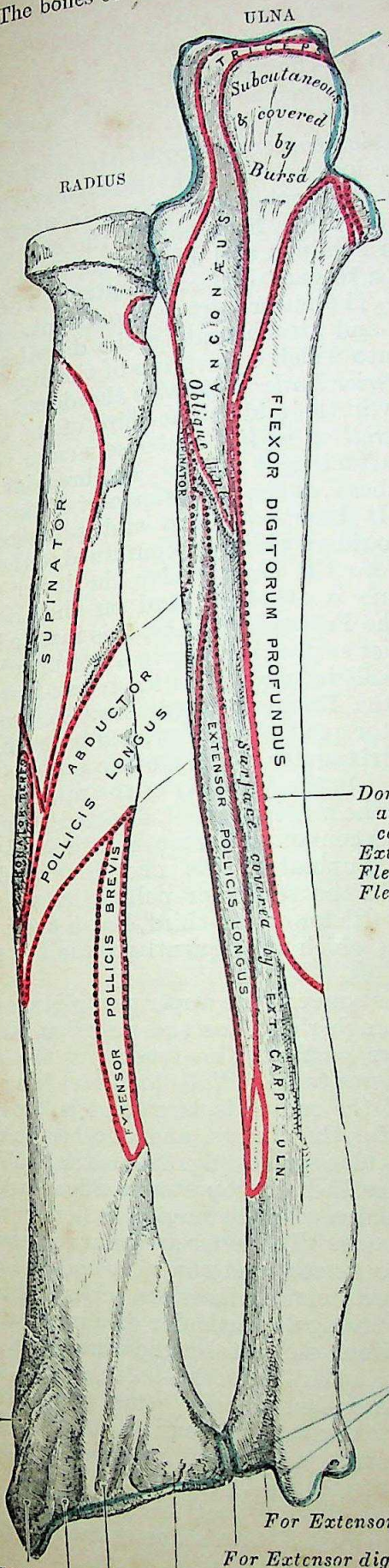

CC-0. In Public Domain. Gurukul Kangri Collection, Haridwar

Digitized by Arya Samaj Foundation Chennai and eGangotri

medial part of the neck is an eminence, the *radial tuberosity*, the a
which is divided into a dorsal rough portion for the insertion of th
of the Biceps brachii, and a volar smooth portion on which a bursa is i
between the tendon and the bone.

The **body** or **shaft** of the radius is prismoid in form, narrower at
below, and slightly curved, so as to be convex laterally. It has thre
and three surfaces.

The *volar or anterior border* separates the volar from the lateral
and extends from the lower part of the tuberosity above, to the ante
of the base of the styloid process below. Its upper part is promin
from its oblique direction has been named the *oblique line*; it gives
the Flexor digitorum sublimis and Flexor pollicis longus; the surfa
the line gives insertion to part of the Supinator. The middle part of t
border is indistinct. The lower part is prominent, and gives insertio
Pronator quadratus, and attachment to the dorsal carpal ligament;
in a small tubercle, into which the tendon of the Brachioradialis is ins

The *dorsal or posterior border* separates the dorsal from the lateral
it is well-marked only in the middle one-third of the bone.

The *interosseous crest* or *medial border* separates the volar from th
surface, and gives attachment to the antibrachial interosseous me
(fig. 388); it begins above, at the posterior part of the tuberosity, and i
part is indistinct. It becomes sharp and prominent as it descen
divides below into two ridges which are continued to the volar and dorsal
of the ulnar notch; to the dorsal ridge the lower part of the anti
interosseous membrane is attached, and on the triangular surface
the ridges a part of the Pronator quadratus is inserted.

The *volar or anterior surface* is concave in its upper three-fourths, a
origin to the Flexor pollicis longus; its lower one-fourth is broad and
affords insertion to the Pronator quadratus. A prominent ridge li
insertion of the Pronator quadratus below, and between this ridge and th
articular surface is a triangular rough surface for the attachment of th
radiocarpal ligament. At the junction of the upper with the middle o
of the volar surface is the nutrient canal, directed obliquely upwards.

The *dorsal surface* is convex and smooth in the upper one-third of its
and covered by the Supinator. Its middle one-third, broad and
concave, gives origin to the Abductor pollicis longus above, and the E
pollicis brevis below. Its lower one-third, broad and convex, is covered
tendons of the muscles which subsequently run in the grooves on the lo
of the bone.

The *lateral surface* is convex; its upper part gives insertion to the Sup
near its centre is a rough ridge, for the insertion of the Pronator te
contact with its lower part are the tendon of the Brachioradialis a
tendons of the Extensores carpi radialis longus et brevis.

The **lower end** of the radius is large and is provided with two ar
surfaces—one below, for the carpus, and another at the medial side,
ulna. The carpal articular surface (fig. 389) is triangular, concave, smoo
divided by a slightly-marked anteroposterior ridge into two parts. The
triangular part, articulates with the navicular bone; the medial, quadr
part, with the lunate bone. The ulnar articular surface is called the *ulna*
(sigmoid cavity); it is narrow and concave, and articulates with the
the ulna. These two articular surfaces are separated by a prominent r
which the base of the triangular articular disc is attached; this disc se
the radiocarpal joint from the distal radio-ulnar joint. The lower end
bone has three non-articular surfaces—volar, dorsal, and lateral. Th
surface, rough and irregular, affords attachment to the volar radi
ligament. The *dorsal surface* is convex; it affords attachment to the
radiocarpal ligament, and is marked by three grooves. Enumerate
the lateral side, the first groove is broad, but shallow, and subdivided
faint vertical ridge; the lateral part transmits the tendon of the Ex
carpi radialis longus, the medial, the tendon of the Extensor carpi radialis
The second groove, deep and narrow, is bounded laterally by a sharp
it runs obliquely downwards and lateralwards, and transmits the ten
the Extensor pollicis longus. The third groove is broad, for the passage

CC-0. In Public Domain. Gurukul Kangri Collection, Haridwar

Digitized by Arya Samaj Foundation Chennai and eGangotri

ns of the Extensor indicis proprius and Extensor digitorum communis. ateral part of the lower end of the radius is prolonged downwards as a conical projection, the *styloid process*, the base of which gives attach- to the tendon of the Brachioradialis, the apex to the radial collateral ent of the wrist-joint. On the lateral surface of the styloid process there hallow groove, directed downwards and forwards, and separated from the surface by a sharp border; the tendon of the Abductor pollicis longus the anterior part, and the tendon of the Extensor pollicis longus in the rior part, of this groove.

385.—A plan of the ossification of e radius. From three centres.

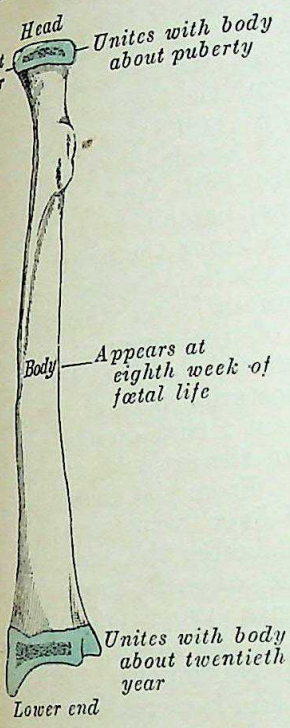

FIG. 386.—The epiphysial lines of the left radius in a young adult. Volar aspect.

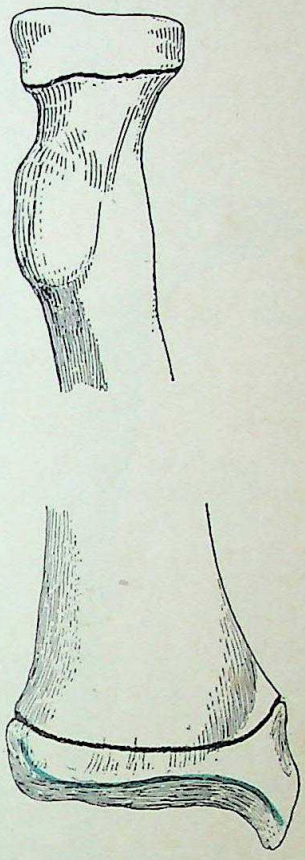

The line of attachment of the articular capsule of the wrist-joint is in blue.

ructure.—The structure of the radius is like that of the other long bones.

ssification (figs. 385, 386).—The radius is ossified from three centres: one for ody, and one for either end. That for the body appears near the middle, e eighth week of fœtal life. About the close of the second year, ossification s in the lower end; and at the fifth year, in the upper end. The upper epi- s fuses with the body at the age of seventeen or eighteen years, the lower the age of twenty. An additional centre sometimes appears in the radial ssity about the fourteenth or fifteenth year.

THE ULNA

e ulna (figs. 383 and 384) is placed at the medial side of the forearm, el with the radius. The upper end is thick and strong, and forms a part of the elbow-joint; the body or shaft diminishes in size from above wards; the lower end is small, and is excluded from the wrist-joint by interposition of a triangular articular disc.

CC-0. In Public Domain. Gurukul Kangri Collection, Haridwar

Digitized by Arya Samaj Foundation Chennai and eGangotri

On the upper end of the ulna (fig. 387) are two curved proc olecranon and the coronoid process; and two concave articular the semilunar and radial notches.

The *olecranon* is a thick, curved eminence, on the upper and d of the ulna. It is bent forwards at the summit so as to present a p beak which is received into the p fossa of the humerus when the f extended. Its *base* is contracted joins the body, and is the r part of the upper end of the u *dorsal surface*, directed back triangular, smooth, subcutane is covered by a bursa. Its *surface*, of quadrilateral form, is behind by a rough impression insertion of the Triceps brachii front, close to the margin, by groove for the attachment of par articular capsule of the elbo between the groove for the a capsule and the impression Triceps brachii is a smooth are is separated from the tendon Triceps brachii by a bursa. *surface* forms the upper part of lunar notch. On its *borders* are continuous with that on the part of the superior surface; the medial border gives attach the posterior part of the ulnar c ligament; that on the lateral b part of the articular capsule of th joint. From the medial border a the Flexor carpi ulnaris arises lateral border the Anconæus is att

Fig. 387.—The upper part of the left ulna. Lateral aspect.

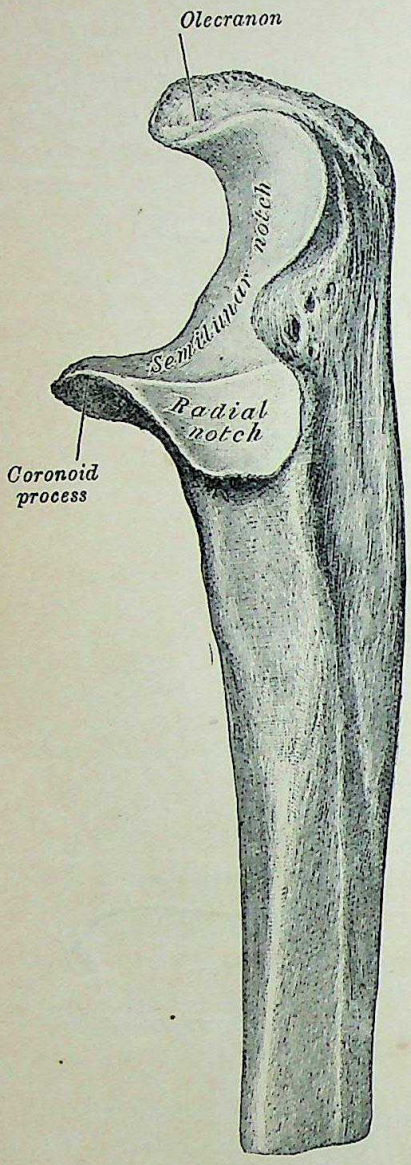

The *coronoid process* is a p eminence projecting forwards fr front of the upper end of the u *base* is continuous with the body bone, and is of considerable streng *apex*, pointed and curved slightly u is received into the coronoid fossa humerus when the forearm is flexe *upper surface* forms the lower part semilunar notch. Its *antero-inferio* is concave, and marked by a rou pression for the insertion of the Bra this impression extends on to the part of the body of the ulna. At the junction of this surface with the the body is a rough eminence, the *ulnar tuberosity*, which gives inserti part of the Brachialis; to the lateral border of this tuberosity the oblig is attached. On the *lateral surface* of the coronoid process is a narrow, articular depression, the *radial notch*. The *medial surface* of the proce superiorly in a prominent, free margin which gives attachment to the ulnar collateral ligament. At the front part of this surface is a eminence for the origin of a small part of the Flexor digitorum sublimis; the eminence is a depression for part of the origin of the Flexor dig profundus; descending from the eminence is a ridge which gives ori the ulnar head of the Pronator teres. Frequently a fasciculus of the pollicis longus arises by a tendinous slip from the lower part of the co process.

The *semilunar notch* (greater sigmoid cavity) (fig. 387), for articulati the trochlea of the humerus, is a large depression, formed by the olecra

CC-0. In Public Domain. Gurukul Kangri Collection, Haridwar

Digitized by Arya Samaj Foundation Chennai and eGangotri

coronoid process. It is concave from above downwards and its deepest is constricted and sometimes crossed by a groove; it is divided into a al and a lateral portion by a smooth ridge running from the beak of olecranon to the apex of the coronoid process. The medial portion is larger, and is slightly concave transversely; the lateral is convex above, ly concave below.

The *radial notch* (lesser sigmoid cavity) (fig. 387) is an oblong, articular ssion on the lateral side of the coronoid process, for the reception of the nferential articular surface of the head of the radius. It is concave from e backwards, and its volar and dorsal margins serve for the attachment of annular ligament.

The body or shaft of the ulna, at its upper part, is prismoid in form, and d, with its convexity directed dorsalwards and lateralwards; its central part smoid and straight; its lower part is rounded and bent a little lateralwards body tapers gradually from above downwards, and has three borders and surfaces.

The *volar or anterior border* separates the volar from the medial surface; gins above at the prominent medial angle of the coronoid process, and below in front of the styloid process. Its upper part, well defined, and iddle portion, smooth and rounded, give origin to the Flexor digitorum dus; its lower part forms minent ridge for the origin e Pronator quadratus.

The *dorsal border* is subneous, and separates the al from the dorsal surface; gins above at the apex of triangular area on the um of the olecranon, runs st downwards and lateralls, and ends below at back of the styloid process.

Its upper three-fourths well marked and give chment to an aponeurosis which affords a common origin to the Flexor ulnaris, the Extensor carpi ulnaris, and the Flexor digitorum profundus; wer one-fourth is smooth and rounded.

Fig. 388.—A transverse section through the left radius and ulna, showing the attachment of the antibrachial interosseous membrane. Superior aspect.

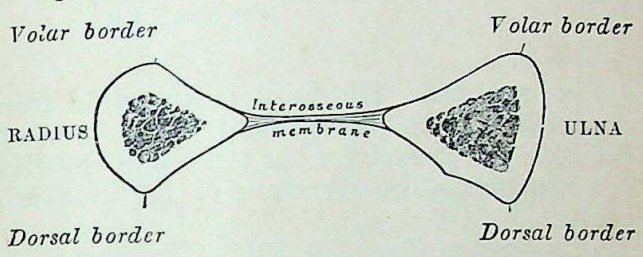

The *interosseous crest* or *lateral border* separates the volar from the dorsal ce and gives attachment to the antibrachial interosseous membrane 388); it begins above by the union of two lines, which converge from the of the radial notch and form the sides of a triangular area for the origin rt of the Supinator. The crest ends below at the head of the ulna; its r part is sharp and prominent, its lower, smooth and rounded.

The *volar surface* is broader above than below; its upper three-fourths are ave and give origin to the Flexor digitorum profundus; its lower one-fourth vered by the Pronator quadratus and is separated from the rest of the ce by a ridge which is directed obliquely downwards and medialwards, marks the extent of origin of the Pronator quadratus. At the junction of upper with the middle one-third of the volar surface is the nutrient canal, ted obliquely upwards.

The *dorsal surface*, directed dorsalwards and lateralwards, is broad above; ex and somewhat narrower in the middle; narrow and rounded below. its upper part is an oblique ridge which runs downwards from the dorsal of the radial notch to the dorsal border; the upper part of the ridge affords chment to the Supinator, and the triangular surface above the ridge gives rtion to the Anconæus. Below this ridge the dorsal surface is subdivided *perpendicular line*, into a medial and a lateral portion: the medial part is h, and covered by the Extensor carpi ulnaris; the lateral part gives s from above downwards to the Abductor pollicis longus, the Extensor cis longus, and the Extensor indicis proprius.

The *medial surface* is broad and concave above, narrow and convex below. upper three-fourths give origin to the Flexor digitorum profundus; its er one-fourth is subcutaneous.

CC-0. In Public Domain. Gurukul Kangri Collection, Haridwar

Digitized by Arya Samaj Foundation Chennai and eGangotri

The lower end of the ulna is small, and has two eminences; the and larger is termed the head of the ulna; the medial, narrower projecting, the styloid process. On the *head* is an articular surface; part of this surface, of a semilunar form (fig. 389), is directed do and comes into contact with the upper surface of the triangular arti which separates the ulna from the radiocarpal joint; the remaining directed lateralwards, is narrow and convex, and is received ulnar notch of the radius. The *styloid process* projects from the me dorsal part of the bone; it descends a little lower than the head, rounded apex affords attachment to the ulnar collateral liga

Fig. 389.—The lower ends of the left radius and ulna. Inferior aspect.

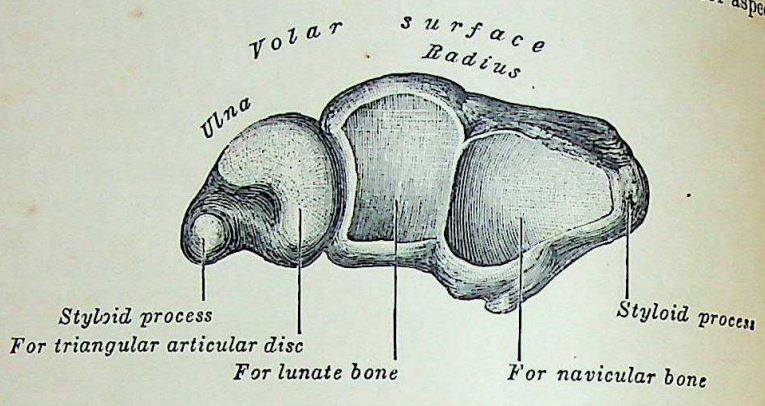

the wrist-joint. The head is separated from the styloid process, belo depression for the attachment of the apex of the triangular articular di behind by a groove for the tendon of the Extensor carpi ulnaris.

Structure.—The structure of the ulna is similar to that of the oth bones.

Ossification (figs. 390, 391).—The ulna is ossified from three centres: for the body, the lower end, and the top of the olecranon. Ossificatio near the middle of the body, about the eighth week of fœtal life, and soon through its greater part. About the fourth year, the centre for the lo appears in the middle of the head, and extends into the styloid process. the tenth year, a centre appears in the olecranon and forms a thin scale top of this process, the chief part of the process being formed by an upward ex of the body; sometimes the upper part of the olecranon is ossified from two The upper epiphysis joins the body about the sixteenth, the lower about the tw year.

Applied Anatomy.—When indirect force is applied to the forearm the radius gives way, though both bones may suffer. Fractures from indirect force genera place somewhere about the middle of the bones, while those from direct violen occur at any part, but are most frequent in the lower half of the bones. The fract usually transverse, but may be more or less oblique. A point of interest in co with these fractures is the tendency for the two bones to unite across the inter membrane; the limb should therefore be put up in a position midway between sup and pronation, which is not only the most comfortable position, but also separ bones most widely from each other. Anterior and posterior splints are applied cases, and should be rather wider than the limb, so as to prevent any side pres the bones.

The special fractures of the ulna are: (1) Fracture of the olecranon, which is caused by direct violence, by falls on the elbow with the forearm flexed, but occas by muscular action in sudden contraction of the Triceps brachii; the most comm of this fracture is at the constricted portion where the olecranon joins the body bone, and the fracture is usually transverse; but any part may be broken, and eve shell may be torn off. Fractures from direct violence are occasionally comminu the fibrous structures around the process are not torn, the displacement is slight wise the olecranon may be drawn up for a very considerable distance. (2) Fractur coronoid process may occur as a complication of dislocation backwards of the bones forearm, but it is doubtful if it ever takes place as an uncomplicated injury. (3 tures of the body of the ulna may occur at any point, but usually take place at co

CC-0. In Public Domain. Gurukul Kangri Collection, Haridwar

Digitized by Arya Samaj Foundation Chennai and eGangotri

the middle of the bone. They are generally the result of direct violence, but may as a complication of dislocation of the radius. (4) The styloid process may be d off by direct violence.
e ulna may be exposed in its whole length by an incision along its dorsal border.

FIG. 391.—The epiphysial lines of the left ulna in a young adult. Lateral aspect.

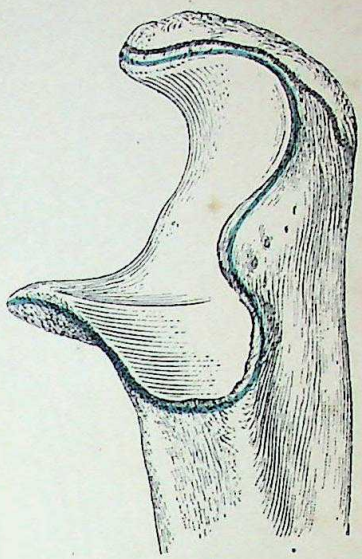

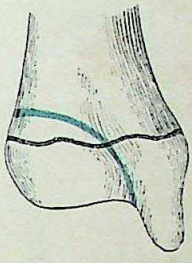

The lines of attachment of the articular capsules are in blue.

0.—A plan of the ossification of the ulna. From three centres.

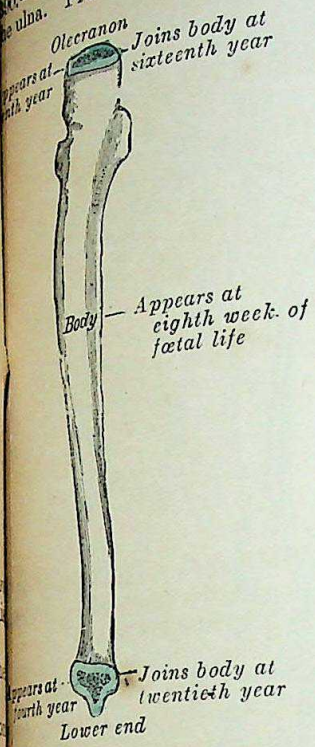

ctures of the radius may consist of: (1) Fracture of the head of the bone; this for ost part takes place in conjunction with some other lesion, but may occur as an plicated injury. (2) Fracture of the neck also may occur, but is usually compli- with other injury. (3) Fractures of the body of the radius are very common, and e place at any part of the bone. In fracture of the upper one-third of the body— s to say, above the insertion of the Pronator teres—the displacement is very great. pper fragment is strongly supinated by the Biceps and Supinator, and flexed by the s; while the lower fragment is pronated and drawn towards the ulna by the two ors. If such a fracture be put up in the ordinary position, midway between ation and pronation, the bone will unite with the upper fragment in a position of ation, and the lower one in the mid-position, and thus considerable impairment movement of supination will result; the limb should therefore be put up with the m supinated. (4) The most important fracture of the radius is that of the lower (Colles's fracture). The fracture is transverse, and generally takes place about m. from the lower end. It is caused by falls on the palm of the hand, and is ry of advanced life, occurring more frequently in the female than in the male. In quence of the manner in which the fracture is caused, the upper fragment is driven e lower, and impaction commonly is the result; excess of violence may, however, pact, the lower fragment being split into two or more pieces, so that no fixation r. Separation of the lower epiphysis of the radius may take place in the young. injury and Colles's fracture may be distinguished from other injuries in this neigh- d—especially dislocation of the wrist, with which they are liable to be confounded bserving the relative positions of the styloid processes of the ulna and radius. In tural conditions of parts, with the arm hanging by the side, the styloid process of dius is on a lower level than that of the ulna. After fracture or separation of the ns the styloid process of the radius is on the same level as, or on a higher level that of the ulna, whereas it would be unaltered in position in dislocation. Reduc- n the case of Colles's fracture is usually easily effected by traction on the hand, the

CC-0. In Public Domain. Gurukul Kangri Collection, Haridwar

Digitized by Arya Samaj Foundation Chennai and eGangotri

FIG. 392.—The bones of the left hand. Volar aspect.

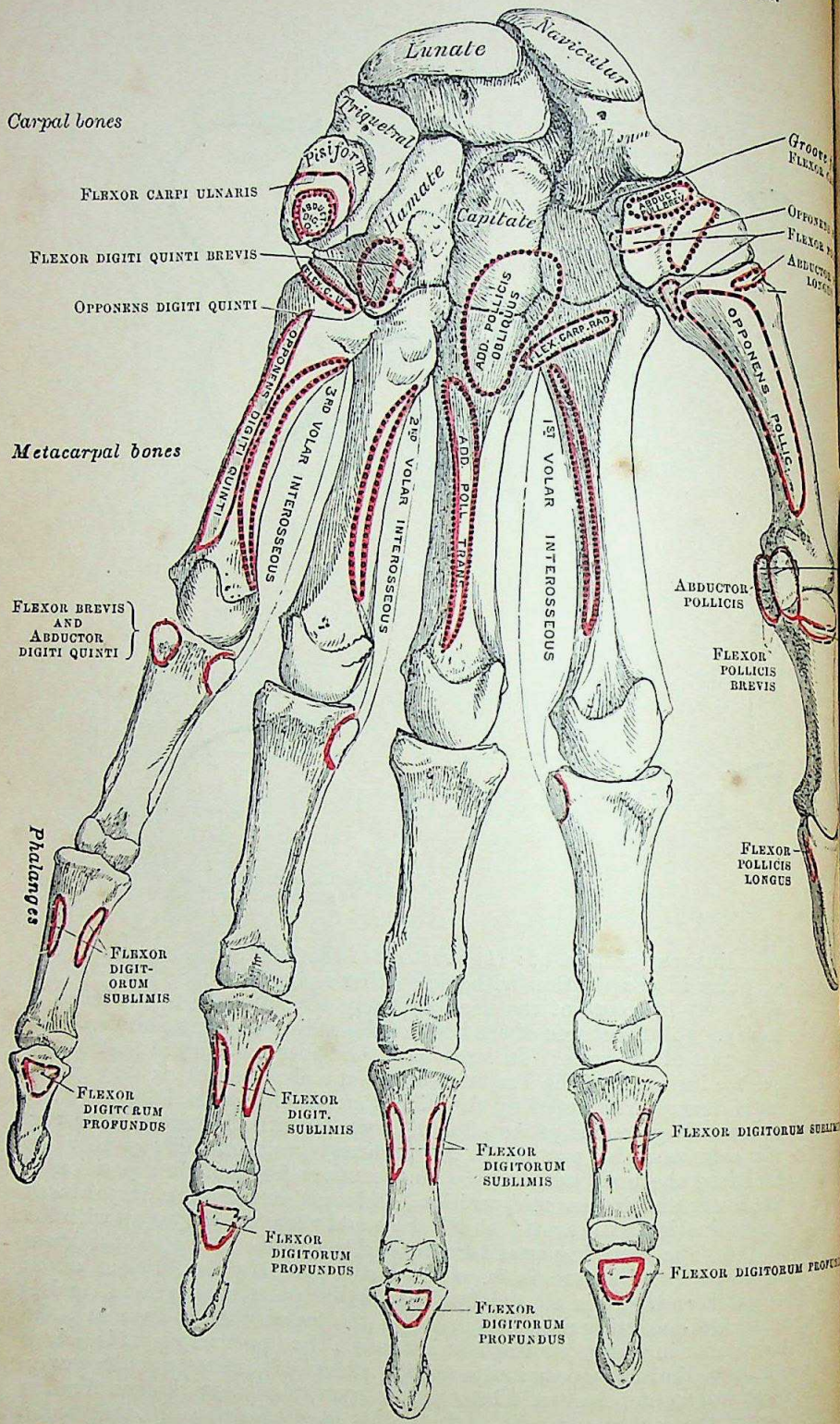

CC-0. In Public Domain. Gurukul Kangri Collection, Haridwar

Digitized by Arya Samaj Foundation Chennai and eGangotri

FIG. 393.—The bones of the left hand. Dorsal aspect.

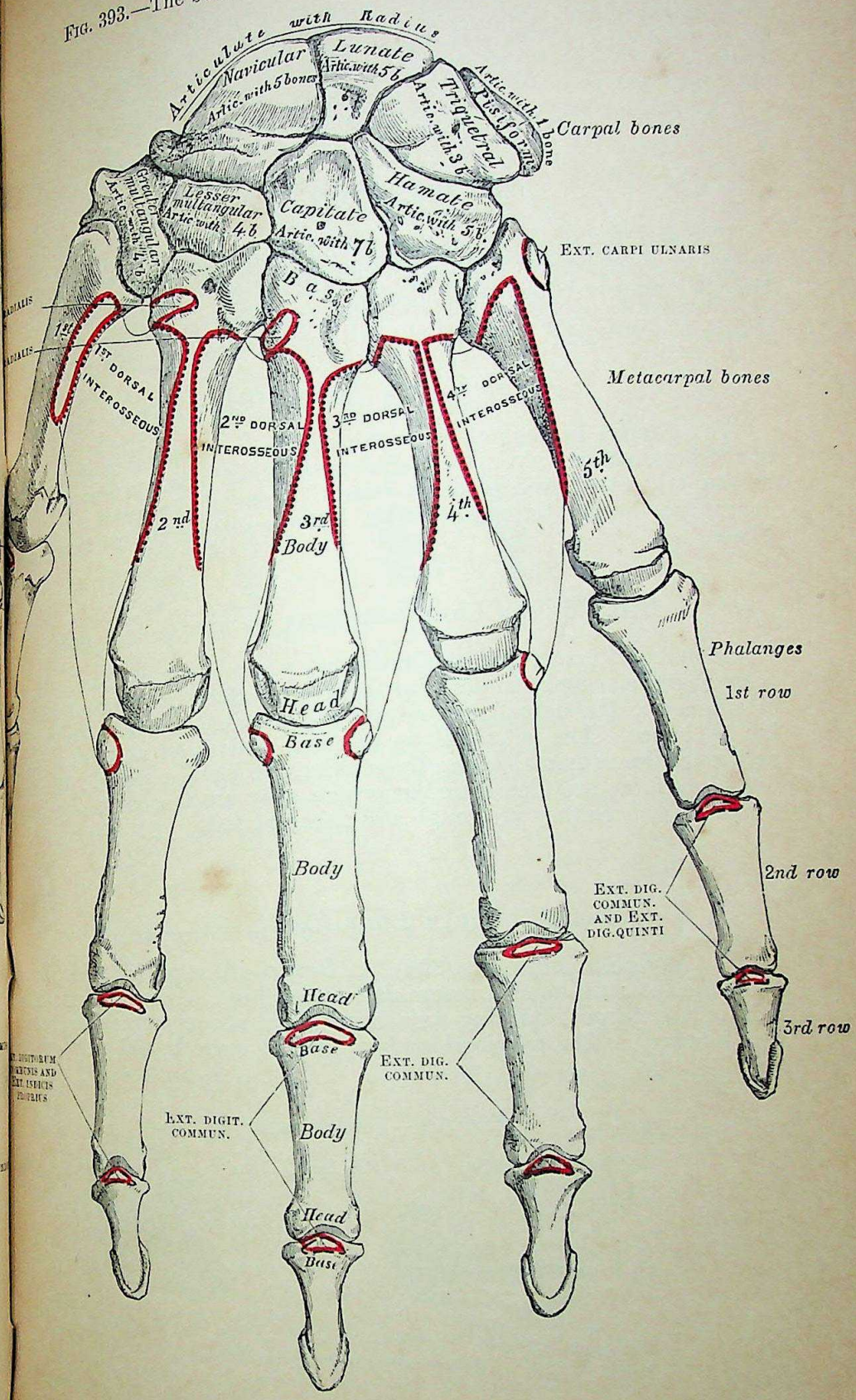

CC-0. In Public Domain. Gurukul Kangri Collection, Haridwar

Digitized by Arya Samaj Foundation Chennai and eGangotri

limb being subsequently splinted with the hand deflected towards the ulnar side. plete reduction is most important in this fracture, since any imperfection leads ment of mobility and function.

The upper one-third of the radius is exposed through an incision along the margin of the Brachioradialis, and then along the oblique line of the Radius. The containing the deep branch (posterior interosseous branch) of the radial nerve is lateralwards, and the Flexores digitorum sublimis et profundus medialwards bone.

THE SKELETON OF THE HAND

The skeleton of the hand (figs. 392, 393) consists of three segments: carpal or wrist bones ; (2) the metacarpal bones or bones of the palm; the phalanges or bones of the digits.

The Carpal Bones (Ossa Carpi)

The carpal bones, eight in number, are arranged in two rows. of the proximal row, from the radial to the ulnar side, are named the na lunate, triquetral, and pisiform bones ; those of the distal row, in th order, are the greater multangular, lesser multangular, capitate, and bones.

The Common Characteristics of the Carpal Bones

Each bone (excepting the pisiform) presents six surfaces. Of th *volar or anterior* and the *dorsal or posterior surfaces* are rough, for liga attachment ; the dorsal surfaces are the broader, except in the navic lunate bones. The *proximal or superior*, and *distal or inferior surf* articular, the proximal generally convex, the distal concave ; the *med lateral surfaces* are also articular where they are in contact with co bones, elsewhere they are rough and tuberculated.

The Navicular Bone (Os Naviculare Manus)

The navicular bone (fig. 394), the largest of the proximal row, has re its name from its fancied resemblance to a boat. It is situated at the side of the carpus, its long axis being from above downwards, lateral and forwards. The *proximal surface*, convex, smooth, and of triangular

Fig. 394.—The left navicular bone.

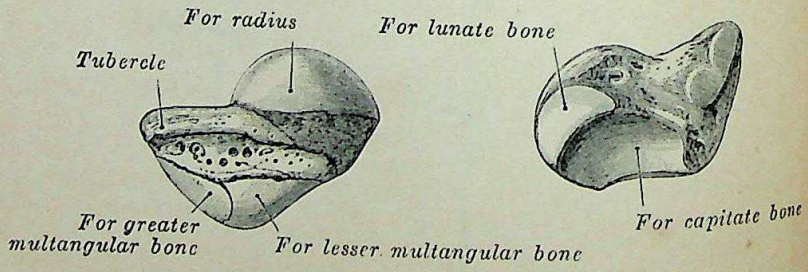

articulates with the lower end of the radius. The *distal surface*, di downwards and backwards, is also smooth, convex, and triangular divided by an indistinct ridge into a lateral part which articulates w greater multangular bone, and a medial with the lesser multangular

CC-0. In Public Domain. Gurukul Kangri Collection, Haridwar

Digitized by Arya Samaj Foundation Chennai and eGangotri

he *dorsal surface* is a narrow, rough groove which serves for the attachment ments. The *volar surface* is concave above, but elevated at its lower lateral part into a rounded *tubercle*, which is directed forwards and gives hment to the transverse carpal ligament and sometimes to a few fibres e Abductor pollicis brevis. The *lateral surface*, rough and narrow, gives hment to the radial collateral ligament of the wrist. On the *medial ce* are two articular facets; of these, the proximal is flat and crescentic hape, and articulates with the lunate bone; the distal is concave, and s with the lunate bone a concavity for the head of the capitate bone.

The Lunate Bone (Os Lunatum)

he lunate or semilunar bone (fig. 395), distinguished by its deep con- y and crescentic outline, is situated in the centre of the proximal row e carpus, between the navicular and triquetral bones. The *proximal ce*, convex and smooth, articulates with the radius. The *distal surface* is

Fig. 395.—The left lunate bone.

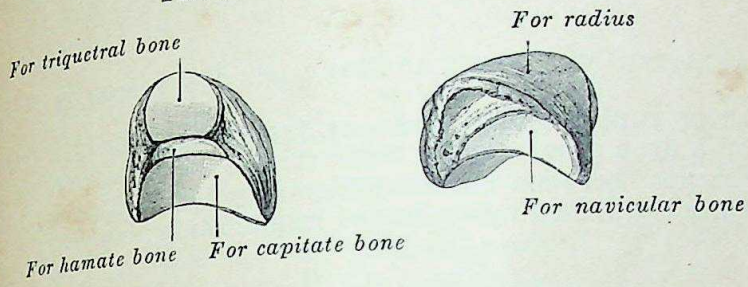

ly concave from before backwards; it articulates with the head of the tate bone by a large lateral facet, and with the hamate bone by a narrow, ial one. The *dorsal* and *volar surfaces* are rough, for the attachment of ments, the dorsal being the smaller. On the *lateral surface* is a semilunar for articulation with the navicular bone, and on the *medial surface* a rilateral facet for the triquetral bone.

The Triquetral Bone (Os Triquetrum)

he triquetral or cuneiform bone (fig. 396) may be distinguished by its midal shape, and by an oval, isolated facet for articulation with the pisiform

Fig. 396.—The left triquetral bone.

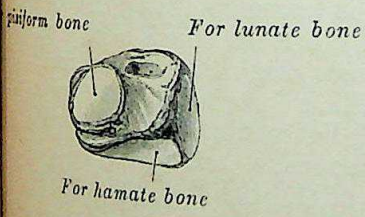

Fig. 397.—The left pisiform bone.

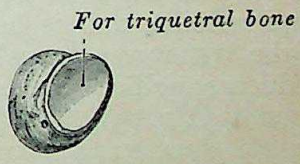

ne. It is situated at the ulnar side of the proximal row of the carpal bones its long axis from above downwards and medialwards. The *proximal ce* presents a medial rough non-articular portion, and a lateral convex oth portion which articulates with the triangular articular disc of the wrist. *distal surface*, directed lateralwards, is concave, sinuously curved, and oth for articulation with the hamate bone. The *dorsal surface* is rough the attachment of ligaments. The *volar surface* displays, on its medial part, oval facet for articulation with the pisiform bone; its lateral part is rough

CC-0. In Public Domain. Gurukul Kangri Collection, Haridwar

Digitized by Arya Samaj Foundation Chennai and eGangotri

for ligamentous attachment. The *lateral surface*, or base of the pyr marked by a flat, quadrilateral facet for articulation with the lunat The *medial surface*, or summit of the pyramid, is pointed and gives att to the ulnar collateral ligament of the wrist.

The Pisiform Bone (Os Pisiforme)

The **pisiform bone** (fig. 397) is situated in front of the triquetral bo may be known by its small size, and by its presenting a single, oval f articulation with that bone. This facet is on the *dorsal surface* of th and its long axis is directed distalwards and lateralwards. The *volar* is round and rough, and gives attachment to the Flexor carpi ulnari *medial surface* gives attachment to the Abductor digiti quinti and the carpal ligament; the pisometacarpal ligament is attached to the dis of this surface. On the volar and lateral surfaces is an oblique line o the distal part of which gives attachment to the volar carpal ligament distal part of the bone projects beyond the articular surface and p a tubercle for the attachment of the pisohamate ligament.*

The Greater Multangular Bone (Os Multangulum Majus)

The **greater multangular bone or trapezium** (fig. 398) may b tinguished by a deep groove on its volar surface. It is situated at the side of the carpus, between the navicular and first metacarpal bones *proximal surface* is directed upwards and medialwards; medially it is

Fig. 398.—The left greater multangular bone.

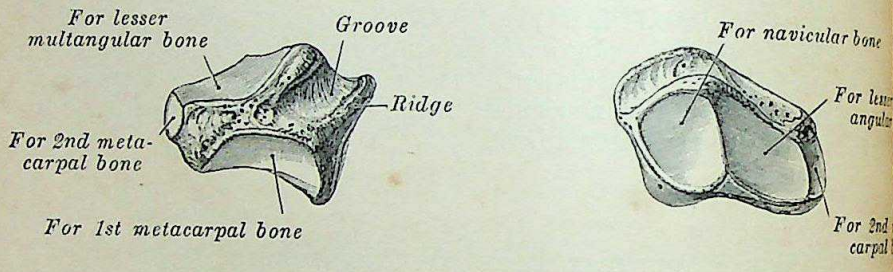

and articulates with the navicular bone; laterally it is rough and conti with the lateral surface. The *distal surface* is oval, concave from side to convex from before backwards, so as to form a saddle-shaped surfac articulation with the base of the first metacarpal bone The *dorsal* is rough. The *volar surface* is narrow and rough. At its upper part is a groove, running from above downwards; it transmits the tendon of the carpi radialis, and is bounded laterally by a ridge which affords attac to the transverse carpal ligament, and gives origin to the Opponens p Abductor pollicis brevis, and Flexor pollicis brevis. The *lateral surf* broad and rough for the attachment of ligaments. On the *medial* are two facets; a proximal, large and concave, articulates with the multangular bone; a distal, small and oval, with the base of the metacarpal bone.

The Lesser Multangular Bone (Os Multangulum Minus)

The **lesser multangular or trapezoid bone** (fig. 399) is the smallest in the distal row. It may be known by its wedge-shaped form, the thick of the wedge constituting the dorsal surface; and by its having four art

* R. H. Robbins, *Journal of Anatomy and Physiology*, vol. li.

CC-0. In Public Domain. Gurukul Kangri Collection, Haridwar

Digitized by Arya Samaj Foundation Chennai and eGangotri

s separated by sharp edges. The *proximal surface*, smaller, quadrilateral, slightly concave, articulates with the navicular bone. The large *distal* ce articulates with the proximal end of the second metacarpal bone; convex from side to side, concave from before backwards. The *dorsal*

Fig. 399.—The left lesser multangular bone.

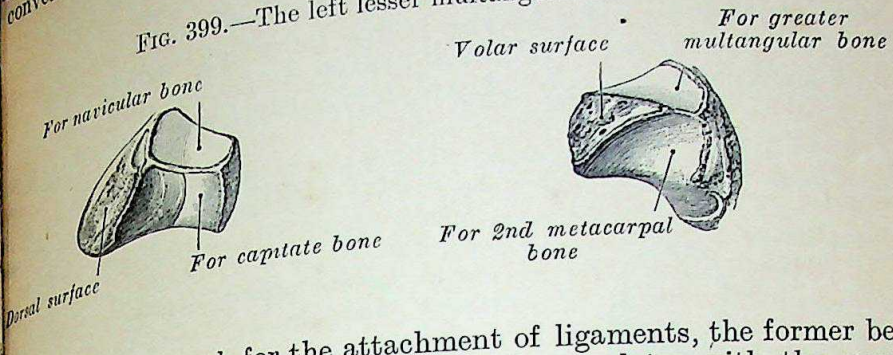

olar surfaces are rough for the attachment of ligaments, the former being larger. The *lateral surface* is convex, and articulates with the greater angular bone. The *medial surface* is concave and smooth in front, for ulation with the capitate bone; rough behind, for the attachment of an sseous ligament.

The Capitate Bone (Os Capitatum)

The capitate bone or os magnum (fig. 400) is the largest of the carpal bones, occupies the centre of the wrist. It presents a rounded proximal portion, head, which is received into the concavity formed by the navicular and te bones; a constricted portion, the neck; and a distal part, the body.

Fig. 400.—The left capitate bone.

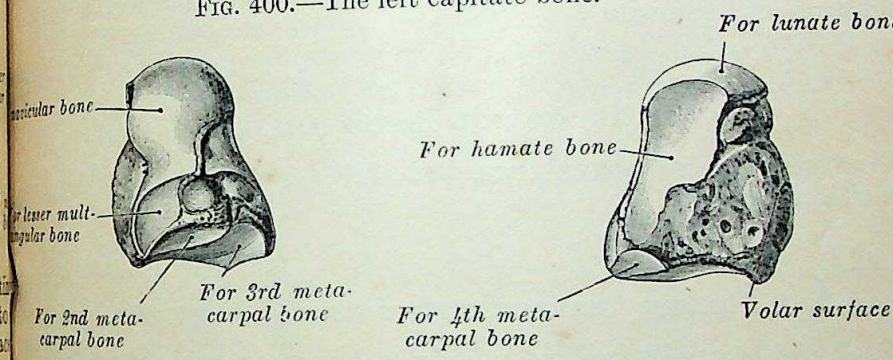

proximal surface is round, smooth, and articulates with the lunate bone. *distal surface* is divided by two ridges into three facets, for articulation with second, third, and fourth metacarpal bones, that for the third being the gest. The *dorsal surface* is broad and rough. The *volar surface* is narrow, jecting and rough; it gives attachment to ligaments and to the oblique t of the Adductor pollicis. The *lateral surface* articulates, by a small facet its volar distal angle, with the lesser multangular bone; dorsal to this facet is ugh depression for the attachment of an interosseous ligament. Proximal this is a deep, rough groove, forming part of the neck, and serving for the achment of ligaments; it is bounded proximally by a smooth, convex face, for articulation with the navicular bone. The *medial surface* articulates the hamate bone by a smooth, oblong facet which occupies the dorsal proximal parts of this surface; its volar part is rough for the attachment interosseous ligament.

CC-0. In Public Domain. Gurukul Kangri Collection, Haridwar

Digitized by Arya Samaj Foundation Chennai and eGangotri

The Hamate Bone (Os Hamatum)

The **hamate or unciform bone** (fig. 401) may be readily dist by its wedge-shaped form, and the hook-like process which projects volar surface. It is situated at the medial and distal part of t with its base directed distally, and its apex proximally and latera *proximal surface* or apex of the wedge is convex, smooth, and a with the lunate bone. The *distal surface* articulates with the fo fifth metacarpal bones, by concave facets which are separated by

Fig. 401.—The left hamate bone.

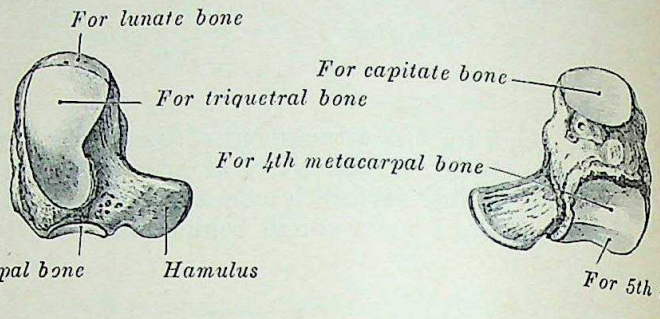

ridge. The *dorsal surface* is triangular, and rough for ligaments. F distal and medial part of the *volar surface* a curved, hook-like proc *hamulus*, is directed forwards and lateralwards. This process gives atta by its apex, to the transverse carpal ligament and the Flexor carpi by its medial surface to the Flexor brevis and Opponens digiti qui lateral side is grooved for the passage of the flexor tendons into the the hand. The *medial surface* articulates with the triquetral bone oblong, obliquely-cut facet. The proximal and dorsal parts of the *lateral* articulate with the capitate bone; the rest of the surface is rough attachment of ligaments.

The Metacarpal Bones (Ossa Metacarpi)

The **metacarpal bones** (figs. 392, 393), five in number, are enu from the lateral side.

The Common Characteristics of the Metacarpal Bones

Each metacarpal bone has a body, a base or proximal end, and a h distal end.

The **body** of each bone is prismoid in form, and curved, so as to be c longitudinally behind, concave in front. It has three surfaces: medial, l and dorsal. The *medial* and *lateral surfaces* are concave, for the attac of the Interossei, and separated from one another by a prominent volar The *dorsal surface* presents in its distal two-thirds a smooth, triangular, fl area which is covered, in the recent state, by the tendons of the extensor m This surface is bounded by two lines, which commence in small tu situated at the sides of the head, and converge and meet some distance the centre of the bone to form a ridge which is continued to the base. ridge separates two sloping surfaces for the attachment of the Inte dorsales. To the tubercles at the head are attached the collateral liga of the metacarpophalangeal joints.

The **base** is of a cuboidal form, and broader behind than in front: it arti with one or more of the carpal bones, and with the contiguous meta bones; its *dorsal* and *volar surfaces* are rough, for the attachment of ligam

The **head** presents an oblong surface markedly convex from before wards, less so transversely; it articulates with the proximal phalan

CC-0. In Public Domain. Gurukul Kangri Collection, Haridwar

Digitized by Arya Samaj Foundation Chennai and eGangotri

broader, and extends farther proximalwards on the dorsal surface, and its transverse diameter is the shorter. On either side of the base is a deep depression, and behind this a tubercle for the attachment of one of the collateral ligaments of the metacarpophalangeal joint. The *dorsal surface*, broad and flat, supports the extensor tendons; the *volar surface* is grooved for the flexor tendons, and marked on either side by an articular surface continuous with the terminal articular surface.

The Characteristics of the Individual Metacarpal Bones

The **first metacarpal bone** (fig. 402), shorter and stouter than the others, differs from the second, and its volar surface is directed medialwards. The shaft is flattened and broad on its dorsal surface, but does not present the ridge which is found on the other metacarpal bones; its volar surface is concave from above downwards. The Opponens pollicis is inserted into its radial border; the lateral head of the first Interosseus dorsalis arises from its ulnar border. The *base* presents a concavoconvex surface, for articulation with the greater multangular bone; it has facets on its sides, but on its lateral side is a tubercle for the insertion of the Abductor pollicis longus. The *head* is less convex than the heads of the other metacarpal bones, and broader from side to side than from before backwards. On its volar surface are two tubular eminences, of which the lateral is the larger; on these surfaces sesamoid bones

Fig. 402.—The first left metacarpal bone.

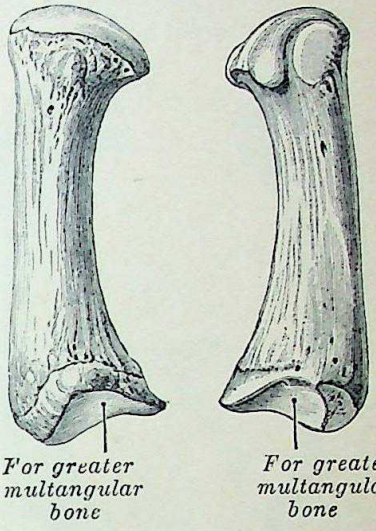

The **second metacarpal bone** (fig. 403) is the longest, and its base the largest, of the four remaining bones. Its *base* is deeply grooved, and medial to the groove is a prominent ridge. The base presents four articular facets: three on the proximal, and one on the medial surface. Of the facets

Fig. 403.—The second left metacarpal bone.

Fig. 404.—The third left metacarpal bone.

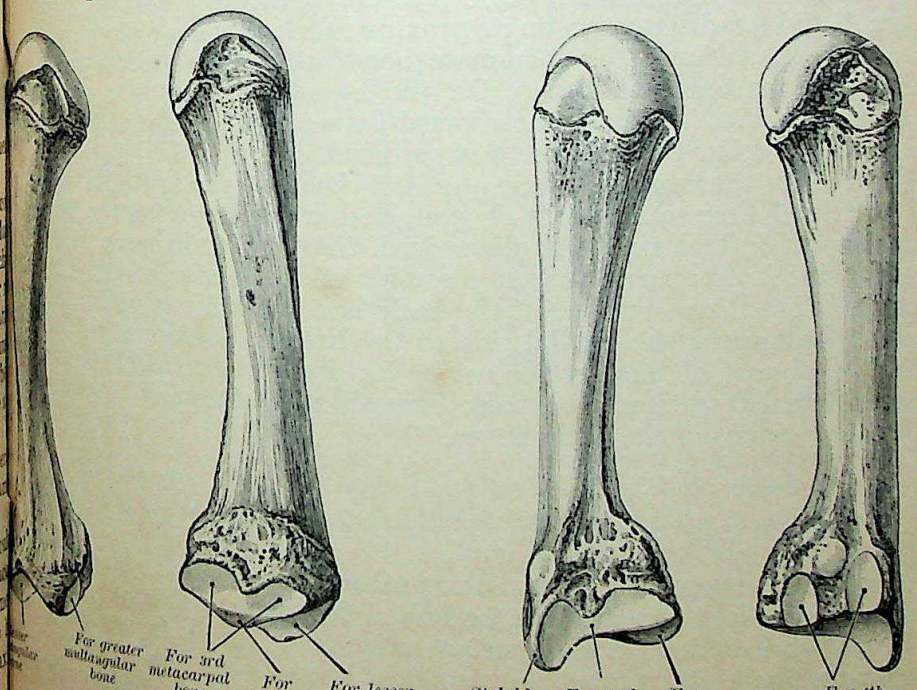

CC-0. In Public Domain. Gurukul Kangri Collection, Haridwar

Digitized by Arya Samaj Foundation Chennai and eGangotri

on the proximal surface, the intermediate is the largest and is concave
to side, convex from before backwards, for articulation with the la
angular bone; the lateral is small, flat and oval for articulation with t
multangular bone; the medial, on the summit of the ridge, is long a
for articulation with the capitate bone. The facet on the medial side
with the third metacarpal bone. The Extensor carpi radialis longus
on the lateral part of the dorsal surface, and the Flexor carpi radi
volar surface, of the base.

The **third metacarpal bone** (fig. 404) is a little smaller than th
On the lateral side of the dorsal part of its *base* is a pyramidal emi
styloid process; immediately distal to this is a rough surface for the at
of the Extensor carpi radialis brevis. The proximal articular facet i
dorsally, and articulates with the capitate bone. On the lateral
smooth, concave facet for articulation with the second metacarpal b
on the medial side two small oval facets for the fourth metacarpal b

Fig. 405.—The fourth left metacarpal bone.

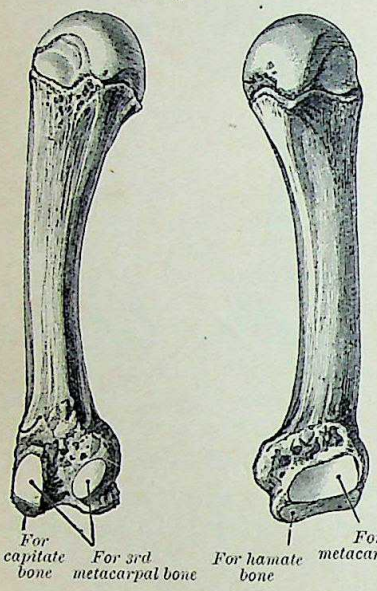

Fig. 406.—The fifth le carpal bone.

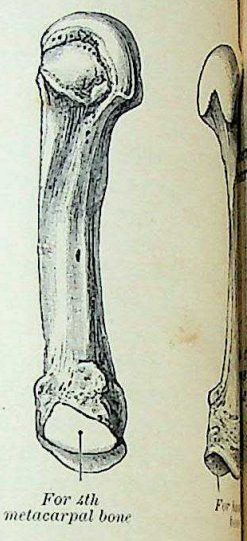

The **fourth metacarpal bone** (fig. 405) is shorter than the third.
is small and quadrilateral; on its proximal surface are two facets, a large
one for articulation with the hamate bone, and a small one at the dorsa
angle for the capitate bone. On the lateral side are two oval face
articulation with the third metacarpal bone; and on the medial side, a
concave facet, for the fifth metacarpal bone.

The **fifth metacarpal bone** (fig. 406) has two facets on its *base*; t
its proximal surface is saddle-shaped, and articulates with the hamate
that on the lateral side articulates with the fourth metacarpal bone
medial side is a tubercle for the insertion of the tendon of the Extens
ulnaris. The dorsal surface of the body is divided by an oblique ridge,
extends from near the medial side of the base to the lateral side of the
The lateral part of this surface serves for the attachment of the fourth
osseus dorsalis; the medial part, smooth and triangular, is covered
extensor tendons of the little finger.

The Phalanges of the Hand (Phalanges Digitorum Manus)

The **phalanges** are fourteen in number, three for each finger, and t
the thumb. Each consists of a body and two ends. The *body* tapers t
its distal end, and its dorsal surface is convex; its volar surface is c
longitudinally, and flat from side to side; its sides are marked by rough
which give attachment to the fibrous sheaths of the flexor tendons.

CC-0. In Public Domain. Gurukul Kangri Collection, Haridwar

Digitized by Arya Samaj Foundation Chennai and eGangotri

ual ends of the bones of the first row present oval, concave articular ces, broader from side to side than from before backwards. On the nal end of each of the bones of the second and third rows are two con- ies separated by a median ridge. The *distal ends* are smaller than the nal, and each terminates in two condyles separated by a shallow groove; rticular surface extends farther on the volar than on the dorsal surface, a tion best marked in the bones of the first row.

he *ungual phalanges* are convex on their dorsal, and flat on their volar ces; they are recognised by their small size, and by a rough, elevated e of a horseshoe form on the volar surface of the distal end of each, which s to support the sensitive pulp of the finger.

The Ossification of the Bones of the Hand

he **carpal bones** are each ossified from a single centre, and ossification proceeds following order (fig. 407): in the capitate and hamate bones, during the ear; in the triquetral bone, during the third year; in the lunate and greater

Fig. 407.—A plan of the ossification of the bones of the hand.

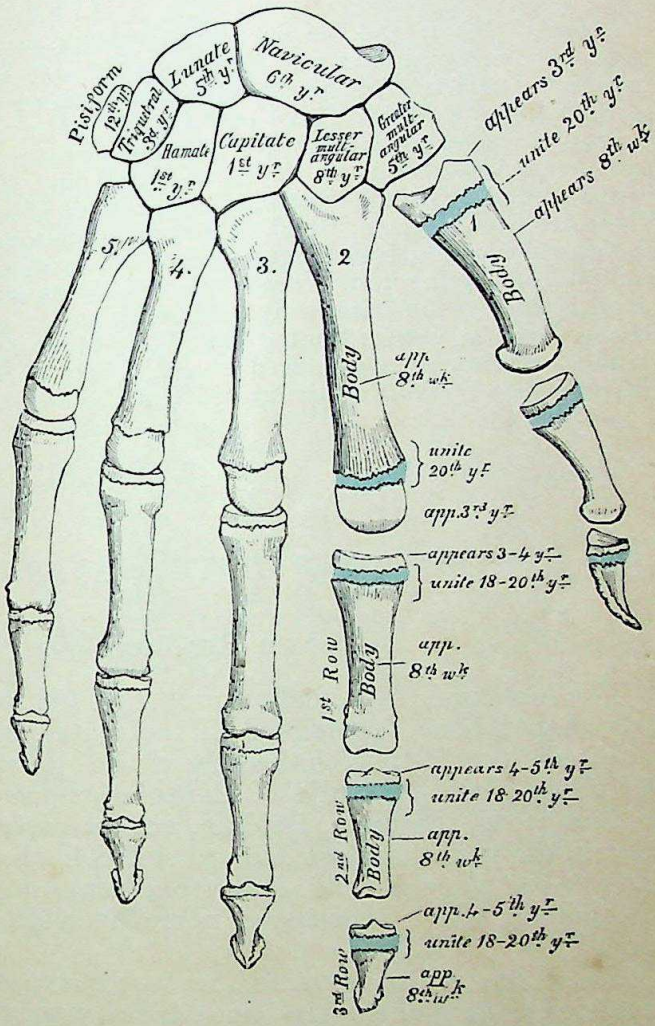

CARPAL BONES
entre for each bone:
rtilaginous at birth

METACARPAL BONES
entres for each bone:
for body
for head

PHALANGES
entres for each bone:
for body
for proximal end

angular bones, during the fifth year; in the navicular bone, during the sixth r; in the lesser multangular bone, during the eighth year; and in the pisiform about the twelfth year.

ccasionally an additional bone, the *os centrale*, is found between the navicular, multangular, and capitate bones. During the second month of fœtal life represented by a small cartilaginous nodule, which usually fuses with the laginous navicular. Sometimes the styloid process of the third metacarpal e is detached and forms an additional ossicle.

CC-0. In Public Domain. Gurukul Kangri Collection, Haridwar

Digitized by Arya Samaj Foundation Chennai and eGangotri

The **metacarpal bones** are each ossified from two centres; a primary for the body, and a secondary or epiphysial centre for the base or proximal the first and for the head or distal end of each of the other four.* The first carpal bone is therefore ossified in the same manner as the phalanges, and has led some anatomists to regard the thumb as being made up of three phalanges and not of a metacarpal bone and two phalanges. Ossification begins in the of the body about the eighth or ninth week of fœtal life, the centres for the and third metacarpal bones being the first, and that for the first metacarpal the last, to appear. About the third year the base of the first metacarpal and the heads of the other metacarpal bones, begin to ossify; they unite with bodies about the twentieth year.

The **phalanges** are each ossified from two centres; a primary centre body, and a secondary or epiphysial centre for the proximal extremity. Ossification begins in the body about the eighth week of fœtal life. The epiphyses for the of the first row of phalanges appear between the third and fourth years, and for the second and third rows of phalanges a year later. All unite with the between the eighteenth and twentieth years.

In the ungual phalanges the centres for the bodies appear at the distal of the phalanges, instead of at the middle of the bodies, as in the other phalanges. Moreover, of all the bones of the hand, the ungual phalanges are the last ossify.

Applied Anatomy.—The use of X-rays has shown that the carpal bones are frequently fractured than was formerly supposed. When a single bone is broken usually the navicular or the capitate (more frequently the former) and the fracture at right angles to the long axis of the bone. There are two diseases of the metacarpal bones and phalanges which require special mention on account of their frequency. One is tuberculous dactylitis, consisting of a deposit of tuberculous matter in the medullary canal, expansion of the bone, with subsequent caseation and suppuration. The other is chondroma, which is perhaps more commonly found in connexion with metacarpal bones and phalanges than with any other bones. The tumours are multiple, and spring from beneath the periosteum about the epiphysial plate. In arthritis small symmetrical bony outgrowths known as "Heberden's nodes," often on the dorsal aspects of the terminal joints of the fingers, with radial deflection of terminal phalanges in advanced cases. These nodes are usually painless, but inconvenience by limiting the mobility of the finger-tips.

THE BONES OF THE INFERIOR EXTREMITY

The Hip-Bone (Os Coxæ)

The **hip-bone** (os innominatum) (figs. 408, 409) is a large, flattened, irregularly shaped bone, constricted in the centre and expanded above and below. It articulates in front with the bone of the opposite side, and the two bones form the pelvic girdle or girdle of the inferior extremity. The hip-bone consists of three parts, the ilium, ischium, and os pubis, which are distinct from one other in the young subject, but are united in the adult; the union of the three parts takes place in and close to a large cup-shaped articular cavity, the acetabulum, which is situated near the middle of the outer surface of the bone.

The **ilium** (os ilii) so named because it supports the flank, is the broad, expanded portion of the hip-bone which extends upwards from the acetabulum. It is divisible into two parts, the body and the ala, which are separated on the internal surface of the bone by a curved line, the *arcuate line*, and on the external surface by the upper part of the margin of the acetabulum.

The **body** of the ilium forms rather less than two-fifths of the acetabulum. Its *external surface* is partly articular, partly non-articular; the articular

* Allen Thomson (*Journal of Anatomy and Physiology*, vol. iii. 1869) pointed out that the first metacarpal bone is often developed from three centres; that is to say, there is a second centre for the distal end, forming a distinct epiphysis visible at the age of seven or eight. He also stated that there are traces of a proximal epiphysis in the second metacarpal bone.

CC-0. In Public Domain. Gurukul Kangri Collection, Haridwar

Digitized by Arya Samaj Foundation Chennai and eGangotri

ment forms part of the lunate surface of the acetabulum, the non-articular
ion contributes to the acetabular fossa. The *internal surface* of the body
part of the wall of the lesser pelvis; it gives origin to some fibres of the
rator internus, and is continuous below with the pelvic surfaces of the
um and os pubis.

FIG. 408.—The right hip-bone. External surface.

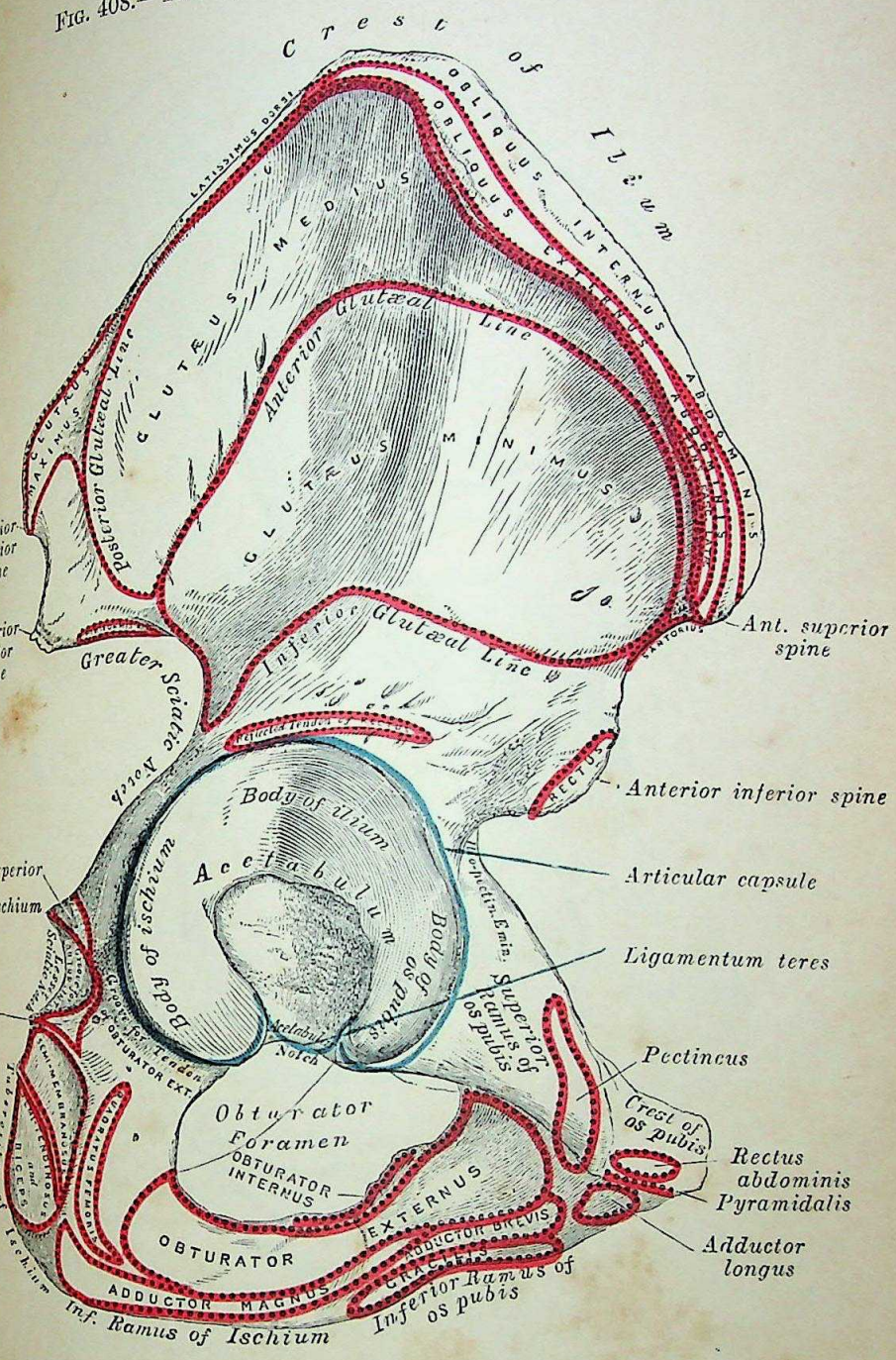

The ala of the ilium, the large expanded portion, bounds the greater pelvis
ally. It has an external and an internal surface, a crest, and an anterior
a posterior border. The *external surface*, or *dorsum* (fig. 408), is directed
wards and lateralwards behind, and lateralwards and downwards in front.
smooth, convex in front, concave behind, and is bounded above by the
below by the upper border of the acetabulum, and in front and behind
anterior and posterior borders. This surface is crossed by the posterior,
rior, and inferior glutæal lines. The *posterior glutæal line* (superior curved
the shortest of the three, begins above at the crest, about 5 cm. in front
posterior extremity, and ends below at the upper part of the greater

CC-0. In Public Domain. Gurukul Kangri Collection, Haridwar

Digitized by Arya Samaj Foundation Chennai and eGangotri

sciatic notch; its upper part is well marked, but its lower part is i and frequently absent. Behind this line is a narrow, semilunar sur upper part of which is rough and gives origin to a portion of the maximus; the lower part is smooth, and has no muscular fibres at it. The *anterior glutæal line* (middle curved line), the longest of t

Fig. 409.—The right hip-bone. Internal surface.

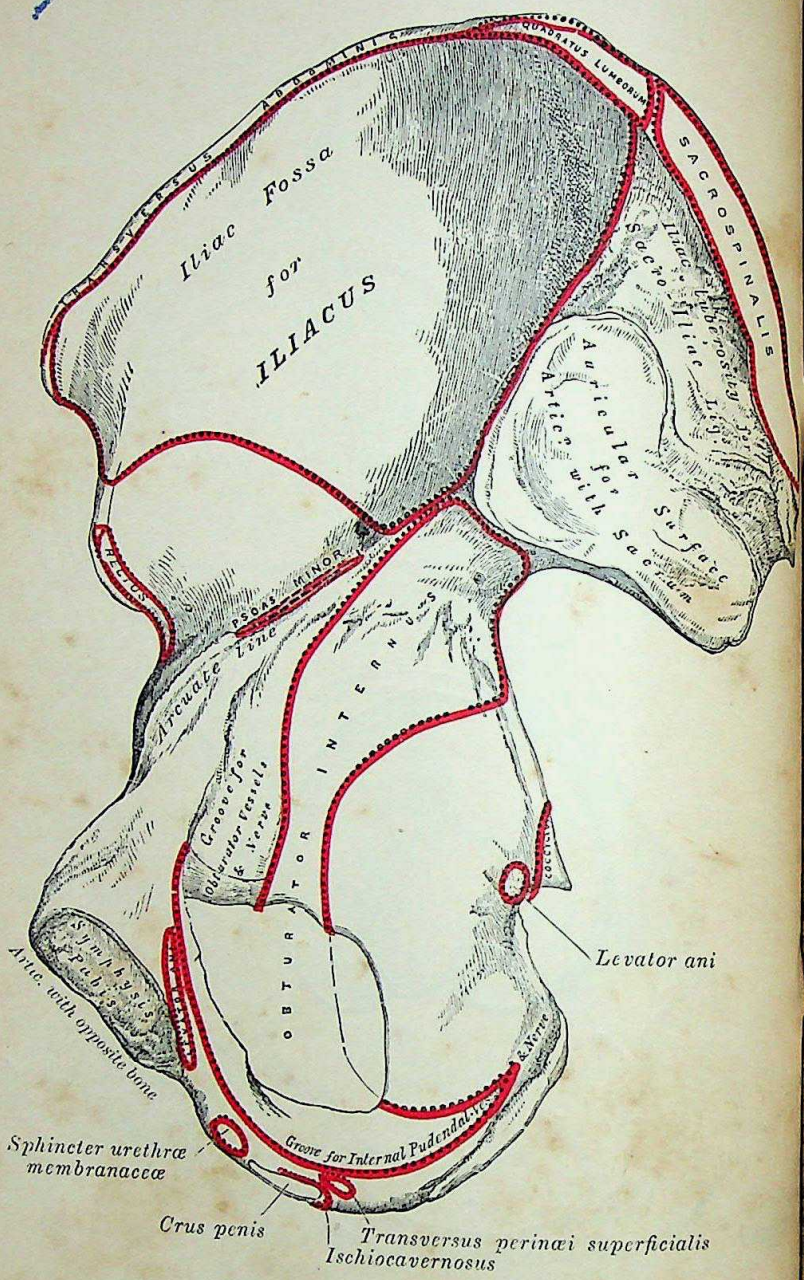

begins near the crest, about 4 cm. behind its anterior extremity, and, c backwards and downwards, ends at the upper part of the greater sciatic n a nutrient foramen is often seen near the middle of this line. The s between the crest and the anterior and posterior glutæal lines, gives to the Glutæus medius. The *inferior glutæal line* (inferior curved line), least distinct, begins in front at the notch on the anterior border, and, c backwards and downwards, ends near the middle of the greater sciatic n the Glutæus minimus takes origin between the anterior and inferior glutæal Immediately above the acetabulum is a rough shallow groove from whic reflected tendon of the Rectus femoris takes origin.

CC-0. In Public Domain. Gurukul Kangri Collection, Haridwar

Digitized by Arya Samaj Foundation Chennai and eGangotri

e *internal surface* (fig. 409) of the ala is bounded above by the crest; by the arcuate line; in front and behind by the anterior and posterior rs. The tendon of the Psoas minor is inserted into the arcuate line. nterior part of the internal surface, smooth and concave, is termed the ossa; it gives origin to the Iliacus, and is perforated posteriorly by a nt canal. Behind the iliac fossa is a rough surface, divided into a superior an inferior portion. The inferior portion or *auricular surface*, so called its resemblance in shape to the auricula or pinna, articulates with a r surface on the side of the sacrum. The superior portion, known as the *tuberosity*, is elevated and rough, for the attachment of the short posterior liac ligament; it is continuous above and behind with the inner lip e iliac crest, and here it gives origin to the Sacrospinalis. Below and nt of the auricular surface is the *pre-auricular sulcus*, more commonly nt and better marked in the female than in the male; the pelvic portion anterior sacro-iliac ligament is attached to this sulcus.

e *crest* of the ilium is convex in its general outline but is sinuously curved, concave inwards in front, and outwards behind. It is thinner at the than at the extremities, and it ends in the anterior and posterior superior pines. The surface of the crest is divided into an external and an internal d an intermediate line; there is a prominent tubercle on the external ut 5 cm. behind the anterior superior iliac spine. To the external lip tached, from before backwards, the Tensor fasciæ latæ, Obliquus us abdominis, and Latissimus dorsi, and along its whole length the hata; to the intermediate line the Obliquus internus abdominis; to ternal lip, the Transversus abdominis, Quadratus lumborum, Sacro-s, Iliacus, and the fascia iliaca.

e *anterior border* of the ala presents two projections, separated by a notch. per projection, at the junction of the crest and anterior border, is called *nferior superior iliac spine*; its outer border gives attachment to the fascia and the Tensor fasciæ latæ; its inner border, to the Iliacus; its extremity attachment to the inguinal ligament, and origin to the Sartorius. Beneath me is a notch from which the Sartorius takes origin and across which teral femoral cutaneous nerve passes. Below the notch is the *anterior r iliac spine* which gives attachment to the straight tendon of the Rectus s and to the iliofemoral ligament of the hip-joint. Medial to the anterior r iliac spine is a broad, shallow groove, over which the Iliacus descends the thigh. This groove is bounded medially by the *iliopectineal eminence*, marks the union of the ilium and the os pubis.

e *posterior border* of the ala, shorter than the anterior, also presents two ctions, the *posterior superior* and *posterior inferior iliac spines*, separated otch. The former serves for the attachment of the long posterior sacro-ment; the latter corresponds with the posterior end of the auricular . Below the posterior inferior spine is a deep notch, the *greater sciatic*

e ischium (os ischii) forms the lowest part of the hip-bone. It is divisible body and a superior and an inferior ramus.

e body of the ischium enters into and constitutes a little more than ths of the acetabulum. Its *external surface* forms a part of the lunate e of the acetabulum and a portion of the acetabular fossa. Its *internal* e is a part of the wall of the lesser pelvis, and gives origin to some fibres e Obturator internus. Its *posterior surface* is convex, and covered by riformis muscle. Its *antero-inferior border* is thin, and forms a part e boundary of the obturator foramen; it ends above at the acetabular e. Its *lateral border* forms the posterior part of the rim of the acetabulum; e *medial border* a pointed triangular eminence, the *ischial spine*, extends rds and medialwards. The external surface of this spine gives attach-o the Gemellus superior; its internal surface to the Coccygeus, Levator d the pelvic fascia; its pointed extremity to the sacrospinous ligament. e spine is the *greater sciatic notch*, converted into a foramen by the inous ligament; this foramen transmits from the pelvis the Piriformis e, the superior and inferior glutæal vessels and nerves, the sciatic and or femoral cutaneous nerves, the internal pudendal vessels and pudendal

CC-0. In Public Domain. Gurukul Kangri Collection, Haridwar

Digitized by Arya Samaj Foundation Chennai and eGangotri

nerve, and the nerves to the Obturator internus and Quadratus fem
these, the superior glutæal vessels and nerve emerge above the Pirifo
other structures below it. Below the spine is the *lesser sciatic not*
converted into a foramen by the sacrotuberous and sacrospinous li
and transmits the tendon of the Obturator internus, the nerve which
that muscle, and the internal pudendal vessels and pudendal nerve.

The superior ramus of the ischium projects downwards and be
from the body and has three surfaces: external, internal, and posteri
external surface is quadrilateral in shape, and on its upper part is a
which lodges the tendon of the Obturator externus. Below, it is co
with the external surface of the inferior ramus; in front, it is limited
posterior margin of the obturator foramen; behind, a prominent
separates it from the posterior surface. In front of the latter ma
external surface gives origin to the Quadratus femoris, and to some
fibres of the Obturator externus; its lower part gives origin to a p
the Adductor magnus. The *internal surface* forms a part of the bony w
lesser pelvis. In front it is limited by the posterior margin of the o
foramen. Below and behind, it is bounded by a sharp ridge whic
attachment to the falciform process of the sacrotuberous ligament
anteriorly it gives origin to the Transversus perinæi superficialis a
Ischiocavernosus.

The *posterior surface* of the superior ramus forms a large swelli
tuberosity of the ischium, which consists of two portions: a lower, ro
angular part, and an upper, smoother, quadrilateral portion. Th
triangular portion is subdivided by a prominent longitudinal ridge i
parts; the lateral part gives attachment to the Adductor magnus, the
to the sacrotuberous ligament. The upper, quadrilateral portion is sub
into two areas by an oblique ridge which runs downwards and latera
from the upper and lateral area the Semimembranosus arises; from th
and medial area, the Semitendinosus and the long head of the Biceps fe

The inferior ramus is the thin, flattened part of the ischium, which
forwards from the superior ramus, and joins the inferior ramus of the os
the junction being indicated on the external surface by a raised li
external surface is uneven for the origin of the Obturator externus an
of the fibres of the Adductor magnus; its *internal surface* forms part
anterior wall of the pelvis and gives attachment to the Sphincter u
membranaceæ. The *lower border* of the inferior ramus is thick, rough, a
everted. It forms part of the outlet of the pelvis, and presents two
ridges and an intervening space. The ridges are continuous with simil
on the inferior ramus of the os pubis; to the outer is attached the dee
of the superficial perinæal fascia (fascia of Colles), and to the inner the
fascia of the urogenital diaphragm. When traced backwards these two
join; from the space just in front of their junction the Transversus p
superficialis takes origin, and in front of this the Ischiocavernosus a
crus penis vel clitoridis are attached. The *upper border* of the inferior
is thin, and forms part of the medial margin of the obturator foramen.

The os pubis, the anterior part of the hip-bone, is divisible into a
and a superior and an inferior ramus.

The body of the os pubis forms one-fifth of the acetabulum, contr
by its *external surface* both to the lunate surface and to the acetabular
Its *internal surface* enters into the formation of the wall of the lesser
Its *anterior surface* is marked by a rough eminence, the *iliopectineal em*
which indicates the junction of the ilium with the os pubis.

The superior ramus of the os pubis extends from the body to the m
plane, where it articulates with the superior ramus of the opposite os
It is conveniently described in two portions, viz. a medial flattened part
narrow lateral prismoid portion.

The *medial portion* of the superior ramus, formerly described as the
of the os pubis, is somewhat quadrilateral in shape, and has two surfaces
three borders. The *external surface* is directed downwards and lateral
and serves for the origin of various muscles. The Adductor longus
from the anterior and medial angle, immediately below the crest;
posteriorly, the Obturator externus, the Adductor brevis, and the upper

CC-0. In Public Domain. Gurukul Kangri Collection, Haridwar

Digitized by Arya Samaj Foundation Chennai and eGangotri

Gracilis take origin. The *internal surface*, convex from above downwards, ve from side to side, is smooth, and forms part of the anterior wall of esser pelvis. It gives origin to parts of the Levator ani and Obturator us, and attachment to the puboprostatic ligaments and to a few muscular prolonged from the bladder. On the *upper border* is a prominent tubercle, *bic tubercle* (pubic spine) which projects forwards and gives attachment inguinal ligament (Poupart's ligament). Passing upwards and lateral- from the pubic tubercle is a well-defined ridge, the *pecten pubis*, which a part of the brim of the lesser pelvis; to it are attached a portion of inguinal falx (conjoined tendon of Obliquus internus and Transversus), ligament (Gimbernat's ligament), and the reflected inguinal ligament ular fascia). Medial to the pubic tubercle is the *pubic crest*, which ds from the tubercle to the medial border of the bone; it affords attach- to the inguinal falx, and to the Rectus abdominis and Pyramidalis. oint of junction of the crest with the medial border of the bone is called *ngle*; a part of the superior crus of the subcutaneous inguinal ring is ed to it. The *medial border* is articular; it is oval, and is marked by or nine transverse ridges, or a series of nipple-like processes arranged s; they serve for the attachment of a thin layer of cartilage, which d to that of the opposite pubic bone by the interpubic fibrocartilaginous The *lateral border* presents a sharp margin, the *obturator crest*, which part of the circumference of the obturator foramen and affords attachment obturator membrane.

e *lateral portion* of the superior ramus has an internal and an external e, separated by the pecten pubis. The *internal surface* constitutes a part e anterior boundary of the lesser pelvis, and affords origin to some fibres Obturator internus. The *external surface* consists of an anterosuperior postero-inferior part, separated by a prominent ridge which extends the anterior margin of the acetabular notch to the pubic tubercle. The superior part, triangular in form, is limited above by the *iliopectineal ne* (p. 309), and is covered by the Pectineus. The postero-inferior also triangular in form, is directed towards the obturator foramen; on it is d, deep groove, the *obturator groove*, for the lodgment of the obturator s and nerve.

e **inferior ramus** of the os pubis is thin and flattened. It passes lateral- s and backwards from the medial part of the superior ramus, narrows ceedes and joins with the inferior ramus of the ischium below the obturator n. Its *external surface*, directed forwards and downwards, is rough e origin of the following muscles, viz.—the Gracilis along its medial r, a portion of the Obturator externus near the obturator foramen, and en these two muscles, the Adductores brevis et magnus, the former e more medial. The *internal surface*, directed backwards and upwards, th, and gives origin to the Obturator internus, and, close to the medial r, to the Sphincter urethræ membranaceæ. The *medial border* is thick, , and everted. It presents two ridges, separated by an intervening . The ridges extend downwards, and are continuous with similar ridges e inferior ramus of the ischium (p. 310); to the external is attached the cial perinæal fascia (fascia of Colles), and to the internal the inferior of the urogenital diaphragm. The *lateral border* is thin and sharp, part of the circumference of the obturator foramen, and gives attach- to the obturator membrane.

e **acetabulum** of the hip-bone (fig. 408) is a deep, cup-shaped, hemi- al depression, which looks downwards, lateralwards, and forwards. It is d above by the ilium, medially by the os pubis, posteriorly and below by the m; a little less than two-fifths is contributed by the ilium, a little more two-fifths by the ischium, and one-fifth by the os pubis. It is surrounded prominent, uneven rim, which is thick and strong above, and serves attachment of the glenoidal labrum (cotyloid ligament), which contracts fice of the acetabulum, and deepens the surface for articulation. It ts below, a deep notch, the *acetabular notch*, which is continuous with ly circular non-articular depression, the *acetabular fossa*, at the bottom e cavity; this fossa is perforated by apertures for vessels, and lodges a of fat. The notch is converted into a foramen by the transverse acetabular

CC-0. In Public Domain. Gurukul Kangri Collection, Haridwar

Digitized by Arya Samaj Foundation Chennai and eGangotri

ligament, and through the foramen nutrient vessels and nerves enter the
the margins of the notch serve for the attachment of the ligamentum
The rest of the acetabulum consists of a horse-shoe shaped articular
the *lunate surface*, for articulation with the head of the femur.

The **obturator foramen** of the hip-bone is an aperture between the
and os pubis. In the male it is large and of an oval form, its longest
slanting obliquely from before backwards; in the female it is small
more triangular. It is bounded by a thin, uneven margin, to which the ob
membrane is attached, and it presents, superiorly, a deep groove, the
groove, which runs downwards and medialwards from the pelvis. This
is converted into a canal by a ligamentous band, which consists of a sp
part of the obturator membrane, and is attached to two tubercles:

FIG. 410.—A plan of the ossification of the hip-bone.

By eight centres { *Three primary, for the ilium, ischium, and os pubis.*
Five secondary.

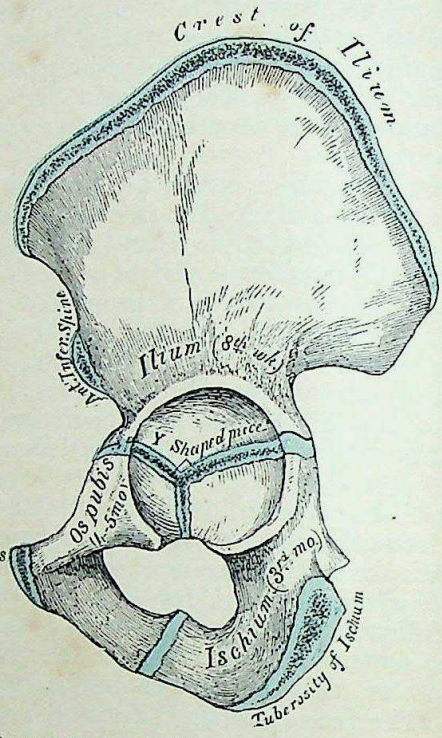

The three primary centres unite through the Y-shaped piece about puberty.
Secondary centres appear about puberty, and unite about 25th year.

posterior obturator tubercle, just below the acetabular notch; the other
anterior obturator tubercle, on the obturator crest (p. 311) of the superior
of the os pubis. Through the canal the obturator vessels and nerve pa
of the pelvis.

Structure.—The thicker parts of the hip-bone consist of spongy sub
enclosed between two layers of compact bone; the thinner parts, as at the
of the acetabulum and centre of the iliac fossa, are usually semitransparent
composed entirely of compact bone.

Ossification (fig. 410).—The hip-bone is ossified from eight centres: three pri
one each for the ilium, ischium, and os pubis; and five secondary, one each f
crest of the ilium, the anterior inferior iliac spine (said to occur more freq
in the male than in the female), the tuberosity of the ischium, the pubic sym
(more frequent in the female than in the male), and one or more for the Y-sh
piece at the bottom of the acetabulum. The centres appear in the following o
in the ilium, immediately above the greater sciatic notch, about the eighth or
week of fœtal life; in the superior ramus of the ischium, about the third m
in the superior ramus of the os pubis, between the fourth and fifth months
birth, the iliac crest, the greater part of the acetabulum, the ischial tube

CC-0. In Public Domain. Gurukul Kangri Collection, Haridwar

Digitized by Arya Samaj Foundation Chennai and eGangotri

e inferior rami of the ischium and os pubis are cartilaginous. By the seventh
th year, the inferior rami of the os pubis and ischium are almost completely
d by bone. The three primary centres extend their growth into the bottom
e acetabulum, where they are separated from each other by a Y-shaped
n of cartilage which begins to ossify by two or more centres in the twelfth
One of these centres, the *os acetabuli*, forms the pubic part of the acetabulum
ses with the main parts of the bone about puberty. The ilium and ischium
become joined, and lastly the os pubis and ischium, through the intervention
Y-shaped portion. At about the age of puberty, ossification takes place in
of the remaining portions, and they join with the rest of the bone between the
eth and twenty-fifth years. Separate centres are frequently found for the
le, crest and angle of the os pubis, and the spine of the ischium.

The Pelvis

e pelvis, so called from its resemblance to a basin, is a massive bony
interposed between the movable segments of the vertebral column which
ports, and the lower limbs upon which it rests; it is composed of the

ig. 411.—The diameters of the superior aperture of the lesser pelvis (female).

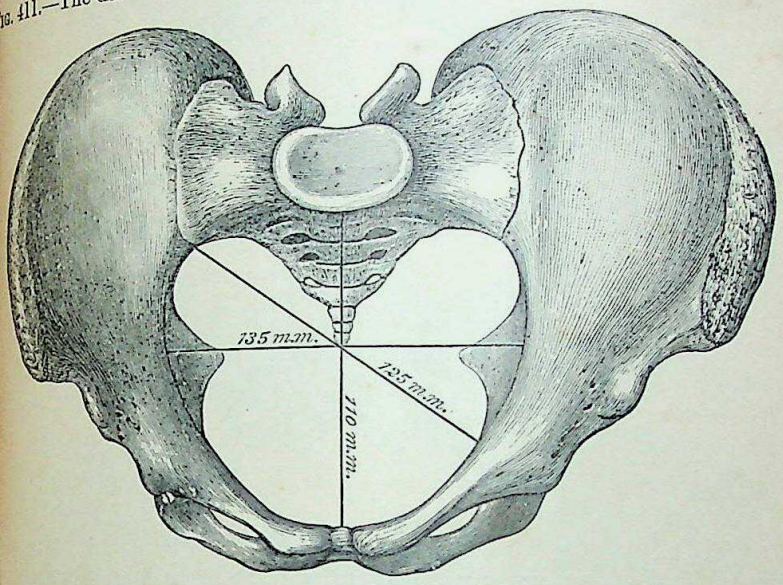

ip-bones laterally and in front, and the sacrum and coccyx behind. It
vided into the greater and the lesser pelvis by an oblique plane passing
h the prominence of the sacrum behind, the arcuate line and pecten
laterally, and the upper margin of the symphysis pubis in front. The
nference of this plane is termed the *pelvic brim*.

he greater pelvis (pelvis major), the expanded portion of the cavity
e and in front of the pelvic brim, is formed on either side by the ilium
posteriorly by the base of the sacrum.

he lesser pelvis (pelvis minor) is that part of the pelvic cavity which lies
and behind the pelvic brim. Its bony walls are more complete than
of the greater pelvis. It possesses an inlet bounded by the superior
nference, an outlet bounded by the inferior circumference, and a
y.

he *superior circumference* forms the brim of the pelvis, the included space
called the *superior aperture* or *inlet* (fig. 411). The superior aperture
ewhat heart-shaped, obtusely pointed in front, and encroached upon
d by the forward projection of the promontory of the sacrum. It has
principal diameters: anteroposterior, transverse, and oblique. The
posterior or conjugate diameter extends from the sacrovertebral angle
the symphysis pubis; its average measurement is about 110 mm. in the

CC-0. In Public Domain. Gurukul Kangri Collection, Haridwar

Digitized by Arya Samaj Foundation Chennai and eGangotri

female. The *transverse diameter* extends from the middle of the brim side to the same point on the opposite side; its average measurement 135 mm. in the female. The *oblique diameter* extends from the iliac eminence to the opposite sacro-iliac articulation; its average measure is about 125 mm. in the female.

The *cavity* of the lesser pelvis is a short curved canal, considerably behind than in front. It is bounded in front and below by the pubic and symphysis; above and behind, by the pelvic surfaces of the sacrum coccyx; laterally by a smooth, quadrangular area of bone, formed inner surfaces of the body and superior ramus of the ischium and of of the ilium. It contains, in the recent subject, the sigmoid (pelvic rectum, urinary bladder, and some of the organs of generation. The is placed at the back of the pelvis, in the curve of the sacrum and the urinary bladder is in front, behind the pubic symphysis. In the the uterus and vagina lie between the rectum and the urinary bladder.

The *lower circumference* of the pelvis is very irregular; the space by it is named the *inferior aperture* or *outlet* (fig. 412), and is bounded

FIG. 412.—The diameters of the inferior aperture of the lessser pelvis (female)

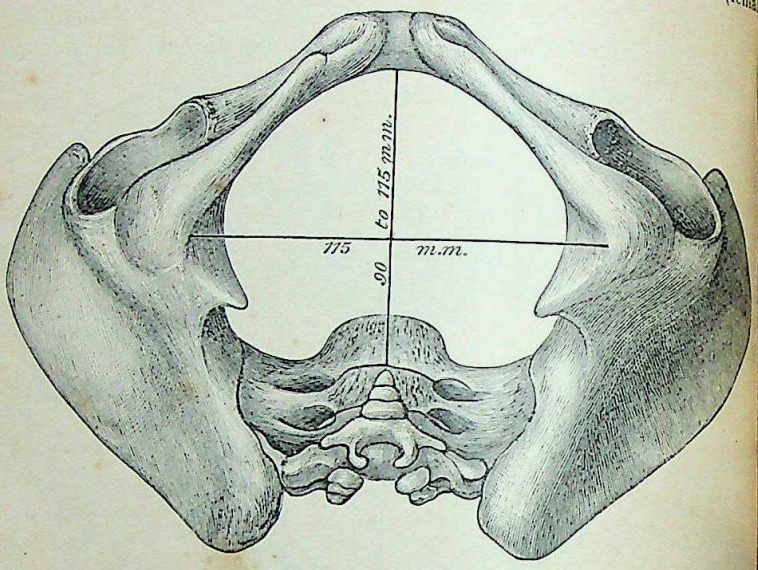

by the apex of the coccyx, and laterally by the ischial tuberosities. eminences are separated by three notches: one in front, the *pubic arch*, by the convergence of the inferior rami of the ischium and os pubis on side. The other notches, one on either side, are formed by the sacrum coccyx behind, the ischium in front, and the ilium above: they are called *sciatic notches*; in the natural state they are converted into foramina by sacrotuberous and sacrospinous ligaments. When these ligaments have preserved, the inferior aperture of the pelvis is lozenge-shaped, and is bounded in front, by the arcuate pubic ligament and the inferior rami of the ossa pubis ischia; laterally, by the ischial tuberosities; behind, by the sacrotuberous ligaments and the tip of the coccyx.

The *anteroposterior diameter* of the inferior aperture of the pelvis extends from the apex of the coccyx to the lower part of the pubic symphysis measurement is from 90 to 115 mm. in the female. It varies with the of the coccyx, and is capable of increase or diminution, on account of mobility of that bone. The *transverse diameter*, measured between the posterior parts of the ischial tuberosities, is about 115 mm. in the female.*

Axes (fig. 413).—The axis of the superior aperture, *i.e.* a line at right angles to the plane of the superior aperture through its centre, is directed downwards

* The measurements of the pelvis given above are fairly accurate, but different figures given by various authors, no doubt mainly due to differences in the physique and stature of population from whom the measurements have been taken.

CC-0. In Public Domain. Gurukul Kangri Collection, Haridwar

Digitized by Arya Samaj Foundation Chennai and eGangotri

ackwards, and if the line be prolonged it passes through the umbilicus above he middle of the coccyx below. The axis of the inferior aperture is directed wards and slightly backwards; if prolonged upwards it touches the f the sacrum. The axis of the cavity—i.e. an axis at right angles to a of planes between and including of the superior and inferior res—is curved like the cavity this curve is parallel to that of rum and coccyx.

Fig. 413.—A median sagittal section through the pelvis.

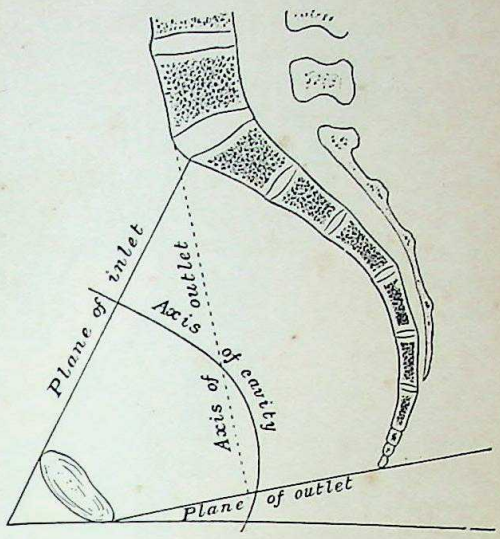

sition of the pelvis (fig. 413).—erect posture, the pelvis is placed ly with regard to the trunk: the of the superior aperture forms the horizontal plane an angle of 50° to 60°, and that of the inferior re one of about 15°. The pelvic e of the symphysis pubis looks ds and backwards, the concavity sacrum and coccyx downwards orwards. The position of the in the erect posture may be ed by holding it so that the r superior iliac spines and the of the top of the symphysis pubis the same vertical plane.

ferences between the male emale pelves (figs. 414, 415, 416, 417).—The female pelvis is distinguished that of the male by its bones being more delicate and its depth less. The pelvis is less massive, and its muscular impressions are not so marked. are larger, their posterior borders are more rounded and less vertical. anterior iliac spines more widely separated; hence the greater lateral ance of the hips. The superior aperture of the lesser pelvis is larger in the

Fig. 414.—The female pelvis. Anterior aspect.

From a specimen in the museum of the Royal College of Surgeons of England.

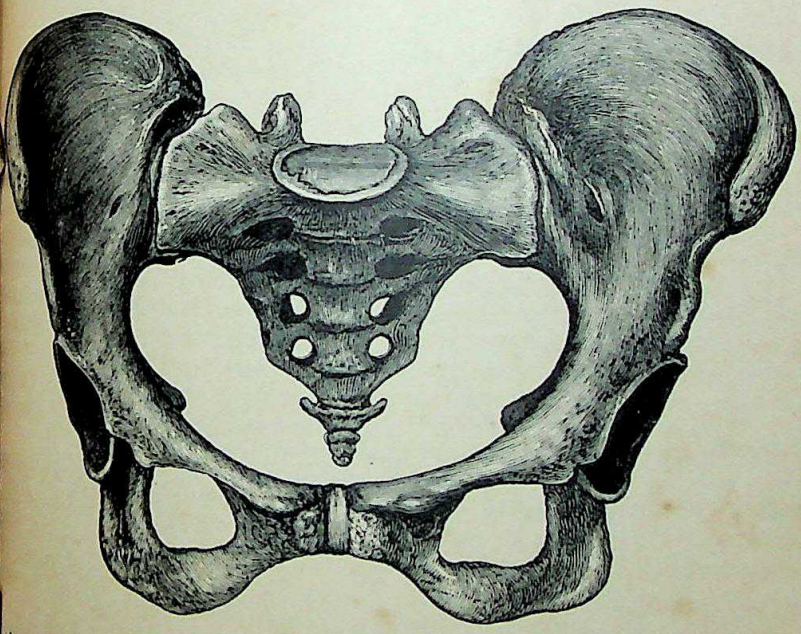

than in the male; it is more nearly circular, and its obliquity is greater. vity is shallower and wider; the sacrum is shorter, wider, and its upper s less curved; the obturator foramina are triangular in shape and are e in size than in the male. The inferior aperture is larger, and the coccyx nsurvable. The pre-auricular sulci are more commonly present and better

CC-0. In Public Domain. Gurukul Kangri Collection, Haridwar

Digitized by Arya Samaj Foundation Chennai and eGangotri

marked. The sciatic notches are wider and shallower, and the spines ischia project less inwards. The acetabula are wider apart, smaller more distinctly forwards.* The ischial tuberosities are also wider

FIG. 415.—The male pelvis. Anterior aspect.

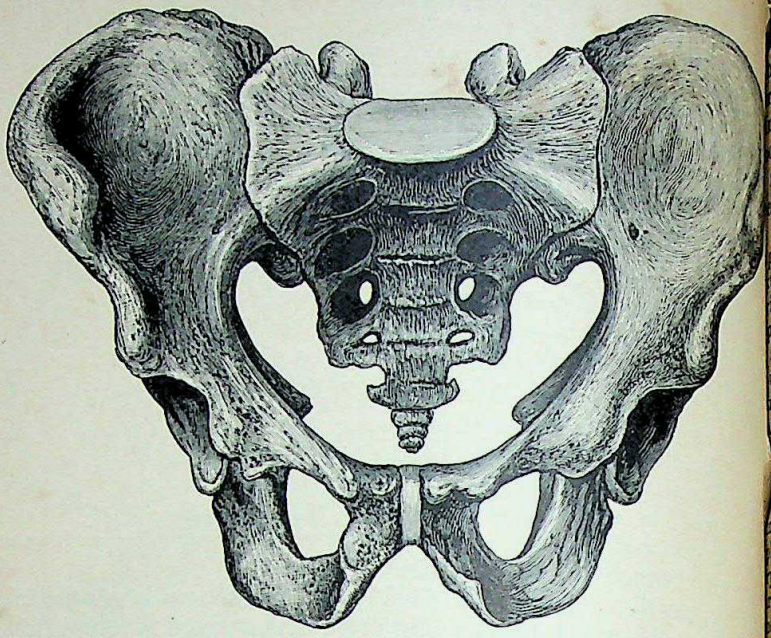

and are more everted. The depth of the pubic symphysis is less, pubic arch is wider and more rounded than in the male, where it is rather than an arch. The auricular surfaces for articulation with the usually involve only two vertebræ, whereas in the male they extend and a half or three vertebræ.

FIG. 417.—Profile view of male p

FIG. 416.—Profile view of female pelvis.

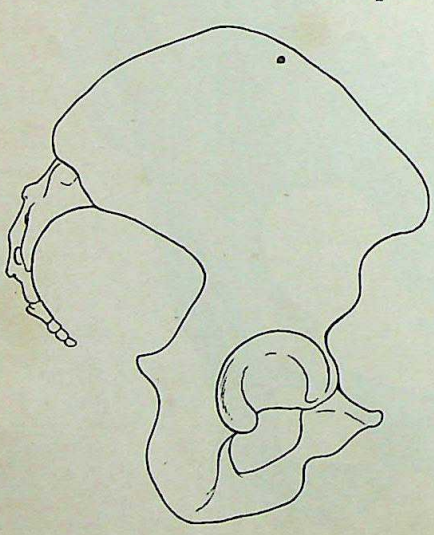

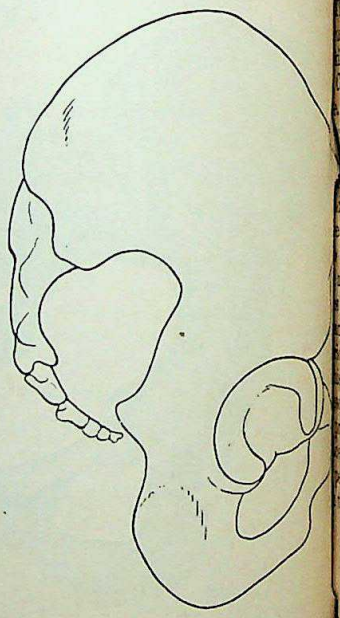

The size of the pelvis varies not only in the two sexes, but also in di members of the same sex, and does not appear to be greatly influen the height of the individual. Women of short stature, as a rule, have

* Derry, *Journal of Anatomy and Physiology*, vol xliii.

CC-0. In Public Domain. Gurukul Kangri Collection, Haridwar

Digitized by Arya Samaj Foundation Chennai and eGangotri

Occasionally the pelvis is contracted in all its dimensions, and its meters may be as much as 12·5 mm. less than the average, and this even ell-formed women of average height. The principal divergences, however, ound at the superior aperture, and affect the relation of the anteroposterior e transverse diameter. Thus the superior aperture may be elliptical in a transverse or an anteroposterior direction, the transverse diameter e former, and the anteroposterior in the latter, greatly exceeding the diameters; in other instances it is almost circular.

In the *fœtus*, and for several years after birth, the pelvis is small in portion to that of the adult, and the projection of the sacrovertebral angle marked. The characteristic differences between the male and female s are distinctly indicated as early as the fourth month of fœtal life.

Applied Anatomy.—There is arrest of development in the bones of the pelvis in cases troversion of the bladder; the anterior part of the pelvic girdle is deficient, the or rami of the pubic bones are imperfectly developed, and the symphysis is absent. pubic bones are separated to the extent of from two to four inches, the superior shortened and directed forwards, and the obturator foramina diminished in size, ved, and turned outwards. The iliac bones are straightened out more than normal. transverse curve of the sacrum is flattened out or even convex, and the vertical curve ightened.*

ctures of the pelvis are divided into those of the greater and those of the lesser Fractures of the greater pelvis vary in extent; a small portion of the crest may ken, or one of the spinous processes may be torn off, or the bone may be extensively inuted. This latter accident is the result of some crushing violence, and may be ociated with fracture of the lesser pelvis. These cases may be accompanied by y to the intestine or to the iliac vessels. A fracture of the lesser pelvis generally s through the superior ramus of the os pubis and the inferior ramus of the ischium, ses are the weakest parts of the bony ring, and may be caused either by crushing ce applied in an anteroposterior direction, when the fracture occurs from direct or by compression laterally, when the acetabula are pressed together and the bone way in the same place from indirect violence. Sometimes both sides of the pelvis ctured, and it is in these cases that the contained viscera are likely to be injured: rethra, the bladder, the rectum, the small intestines, the vagina, and even the uterus, e been lacerated by displaced fragments. Fractures of the acetabulum are occa- y met with: either a portion of the rim may be broken off, or a fracture may take through the bottom of the cavity, and the head of the femur be driven into the pelvic Separation of the Y-shaped cartilage at the bottom of the acetabulum may also in the young subject, splitting the bone into its three portions.

he coccyx is not infrequently displaced forwards to nearly a right angle with the m by a kick or by a fall backwards. The condition is attended with great pain in ing and on making any expiratory effort, such as coughing, defæcation, etc., because coccygei and Levatores ani which form the pelvic diaphragm are attached to this Such injuries often give rise to severe persistent pain, which is exceedingly table and difficult of cure. The condition is known as *coccygodynia*, and for its emoval of the coccyx has been practised.

pelvic bones often undergo important deformity in *rickets*, the effects of which in lt woman may seriously interfere with child-bearing. The deformity is due mainly weight of the trunk, which presses on the sacrovertebral angle and greatly increases that the anteroposterior diameter of the pelvis is diminished, and may measure as s 40 mm., the entrance into the pelvis becoming reniform. In other cases all the pelvic yield, and a general diminution in all the diameters of the pelvis results, the pelvic e becoming triangular or asymmetrical. If the pubic symphysis be forced forwards, ckety pelvis may even come to resemble closely the deformed pelvis of *osteomalacia*; s disease the weight of the trunk causes an increase in the sacrovertebral angle, and ing of the anteroposterior diameter of the superior aperture, and at the same time ssure of the heads of the femora on the acetabula causes these cavities, with the ent bone, to be pushed upwards and backwards, so that the oblique diameters of ris are also diminished, and the cavity of the pelvis assumes a triradiate shape, the symphysis pubis pushed forwards.

THE FEMUR

e femur (figs. 419 and 420), the longest and strongest bone in the skeleton, ndrical in the greater part of its extent. In the erect posture it is placed ely, being separated above from the bone of the opposite limb by an val which corresponds to the breadth of the pelvis, but inclines gradually

* Wood. Heath's *Dictionary of Practical Surgery*.

CC-0. In Public Domain. Gurukul Kangri Collection, Haridwar

Digitized by Arya Samaj Foundation Chennai and eGangotri

downwards and medialwards, so as to bring the knee-joint near the gravity of the body. The degree of this inclination varies in different and is greater in the female than in the male, on account of the greater of the pelvis. The femur has a body and two ends.

The **upper end** of the femur (fig. 418) comprises a head, a neck, and a lesser trochanter.

The *head* forms rather more than a hemisphere; it articulates acetabulum of the hip-bone, and is directed upwards, medialwards little forwards. Its surface is smooth, except at an ovoid depression, *capitis femoris*, which is situated a little below and behind the centre of and gives attachment to the ligamentum teres of the hip-joint.

Fig. 418.—The upper extremity of the right femur. From behind and al

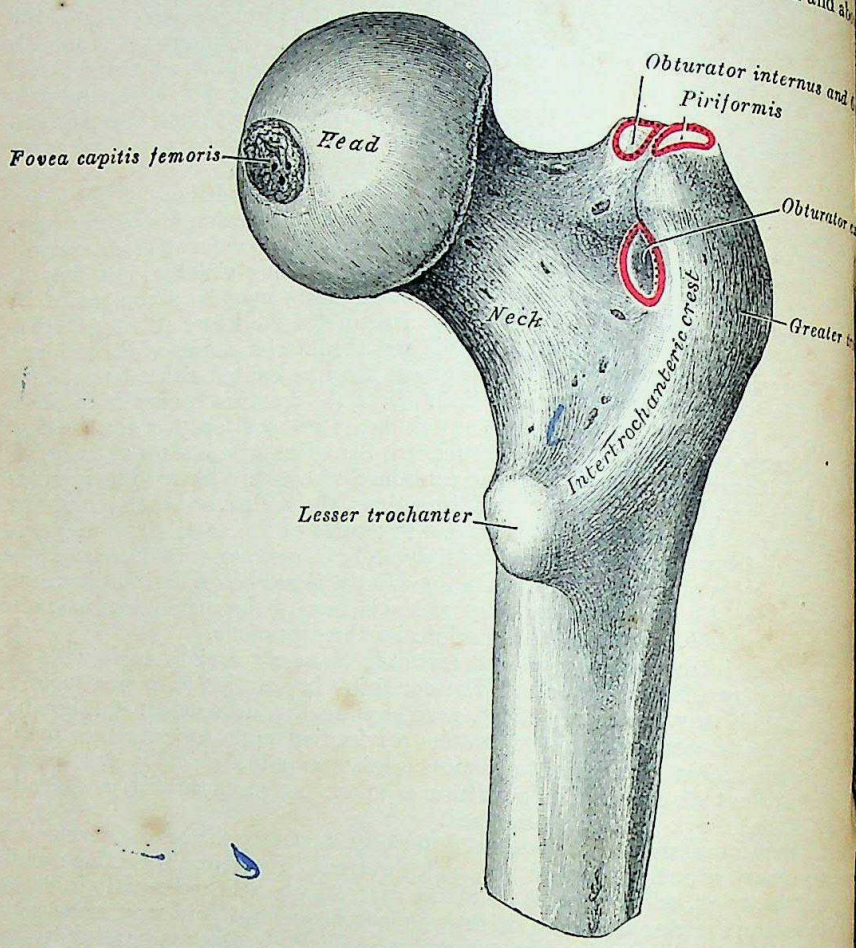

The *neck* of the femur is flattened anteroposteriorly; it connects th with the body, and forms with the latter an angle of about 125°. Th decreases during the period of growth, but after full growth has been a it does not usually undergo any change; in the female, in consequence greater width of the pelvis, it is less than in the male. In addition to pro upwards and medialwards from the body of the femur, the neck p somewhat forwards; the amount of this forward projection is ext variable, but on an average is from 12° to 14°.

The neck is contracted in the middle, and broader laterally than me The vertical diameter of the lateral half is increased by the obliquity lower edge, which slopes downwards to join the body at the level of the trochanter; the medial half is smaller, and of a more cylindrical shape. *anterior surface* of the neck is perforated by numerous foramina for v Along the upper part, and encroaching on the line of junction of this with the head is a shallow, rough groove, best marked in elderly subjects groove lodges the orbicular fibres of the capsule of the hip-joint. The p

CC-0. In Public Domain. Gurukul Kangri Collection, Haridwar

Digitized by Arya Samaj Foundation Chennai and eGangotri

Fig. 419.—The right femur. Anterior aspect.

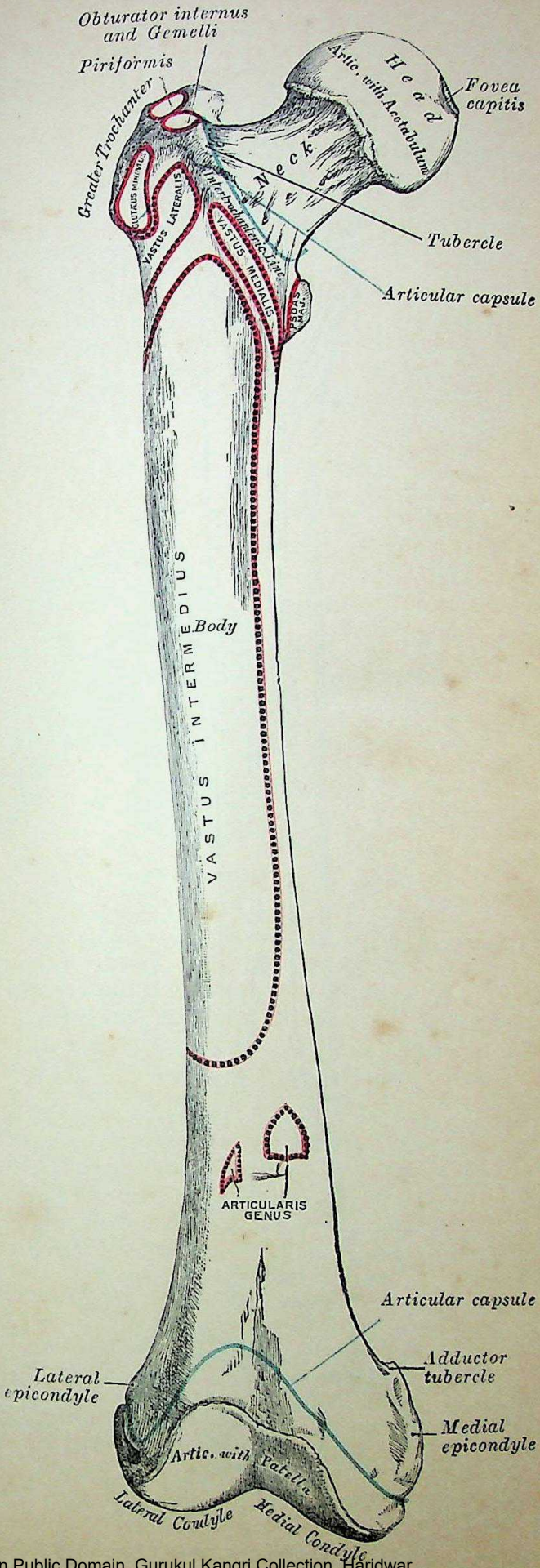

CC-0. In Public Domain. Gurukul Kangri Collection, Haridwar

Digitized by Arya Samaj Foundation Chennai and eGangotri

FIG. 420.—The right femur. Posterior aspect.

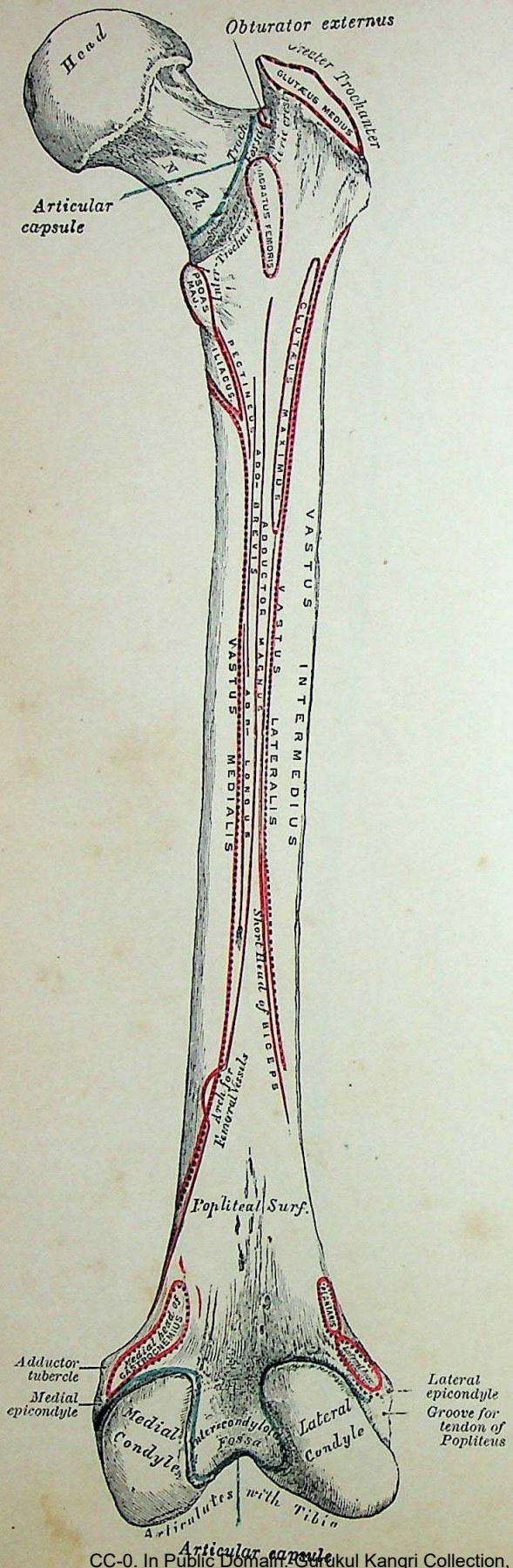

posterior surface is qu
in shape. The tend
Glutæus minimus i
to a prominent ridg
lateral part of this s
is separated from t
part by a synovial b
posterior border is a
rounded edge, whic
the back of the tr
fossa, and forms t
part of the intertr
crest.

The *lesser trocha*
femur is a conical
which projects from
at its junction with
and posterior part of
From it three borders
two of these are dire
wards — a *medial* co
with the lower borde
neck; a *lateral* with
trochanteric crest;
or *inferior* is contin
the middle division of
aspera. The *summit*
trochanter is rough,
insertion to the tend
Psoas major.

A prominence, of
size, occurs at the
of the upper part of
of the neck with the
trochanter, and is ca
tubercle of the femur.
downwards and med
from it is the *intertr*
line; this line winds
round the medial sid
body of the bone, in
the lesser trochanter,
about 5 cm. below this
in the linea aspera. I
half is rough, and
attachment to the late
of the iliofemoral lig
the hip-joint; to its lo
which is less promin
medial part of the il
ligament and the pubo
ligament are attached.
posterior surface a p
ridge, the *intertrochant*
runs obliquely downw
medialwards from the
of the greater troch
the lesser trochanter; it
half forms the posterio
of the greater trocha
slight ridge, the *linea g*
is sometimes seen com
about the middle of th

CC-0. In Public Domain. Gurukul Kangri Collection, Haridwar

Digitized by Arya Samaj Foundation Chennai and eGangotri

running vertically downwards for about 5 cm. along the triangular surface between the lateral and intermediate ridges of the linea aspera; it gives attachment to the Quadratus femoris and a few fibres of the Adductor magnus; as a rule, there is merely a slight thickening about the middle of the intertrochanteric crest, marking the attachment of the upper part of the Quadratus femoris.

The **body or shaft** of the femur, almost cylindrical in form, is a little broader above than in the centre, broadest and somewhat flattened from before backwards below. It is slightly arched, so as to be concave behind, where it is strengthened by a prominent longitudinal crest, the *linea aspera*. It has three borders and three surfaces. Of the borders, one, the linea aspera, is posterior, one is medial, and the other, lateral.

The *linea aspera* (fig. 420) is a longitudinal crest, on the middle third of the shaft; it has a medial and a lateral lip, and a narrow, rough, intermediate ridge. Three ridges, lateral, intermediate and medial, run upwards from the linea aspera. The lateral ridge is very rough, and ascends to the base of the greater trochanter; it is termed the *glutæal tuberosity*, and gives insertion to the tendon of the Glutæus maximus; its upper part is often elongated into a raised crest, on which a rounded tubercle, the *third trochanter*, is occasionally developed. The intermediate ridge or *pectineal line* is continued to the base of the lesser trochanter and gives insertion to the Pectineus. The medial ridge or *spiral line* is continuous with the intertrochanteric line. The lips of the linea aspera diverge below and are prolonged as two epicondylar ridges to form the sides of a triangular area named the *popliteal surface*. The lateral epicondylar ridge is the more prominent, and descends to the lateral condyle. The medial epicondylar ridge is indistinct above where it is crossed by the femoral artery; it ends below, at the medial epicondyle, in the *adductor tubercle*, which affords insertion to the tendon of the Adductor magnus. In about 80 per cent. of specimens a rounded tubercle is present on the lower part of the popliteal surface, just above the medial condyle; to this tubercle the upper part of the medial head of the Gastrocnemius is attached.*

Fig. 421.—The lower end of the right femur. Inferior aspect.

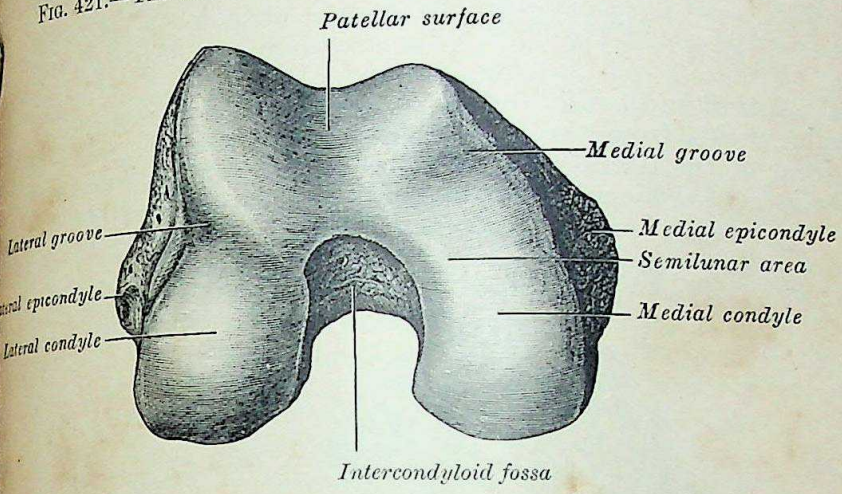

From the medial lip of the linea aspera and its prolongations above and below, the Vastus medialis arises; and from the lateral lip and its upward prolongation, the Vastus lateralis takes origin. The Adductor magnus is inserted into the linea aspera, and to its lateral prolongation above, and its medial prolongation below. Between the Vastus lateralis and the Adductor magnus the Glutæus maximus is inserted above, and the short head of the Adductor femoris takes origin below. Between the Adductor magnus and the Vastus medialis four muscles are inserted: the Iliacus and the Pectineus above, the Adductor brevis and the Adductor longus below. Near the middle

* G. Parsons, *Journal of Anatomy and Physiology*, vol. xlviii., and J. S. B. Stopford, *Journal of Anatomy and Physiology*, vol. xlix.

CC-0. In Public Domain. Gurukul Kangri Collection, Haridwar

Digitized by Arya Samaj Foundation Chennai and eGangotri

of the linea aspera is the orifice of the canal for the nutrient artery, directed obliquely upwards.

FIG. 422.—The lower end of the right femur. Lateral aspect.

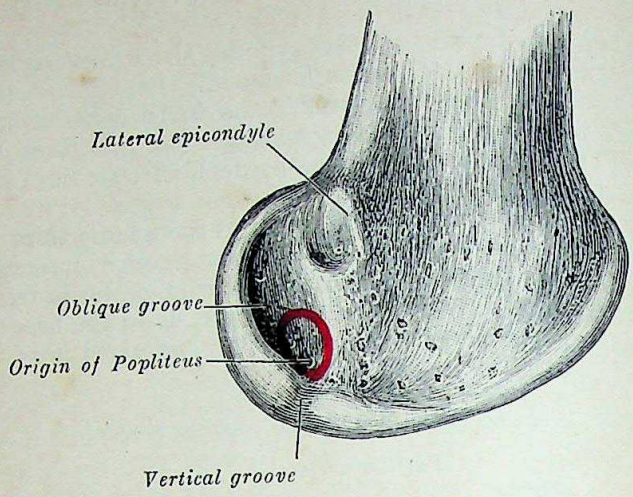

The *lateral* and *medial borders* of the femur are only slightly mark lateral extends from the antero-inferior angle of the greater troch the front of the lateral condyle; the medial from the intertrochant at the level of the lesser trochanter, to the front of the medial condyle.

FIG. 423.—A longitudinal section through the head and neck of the femur

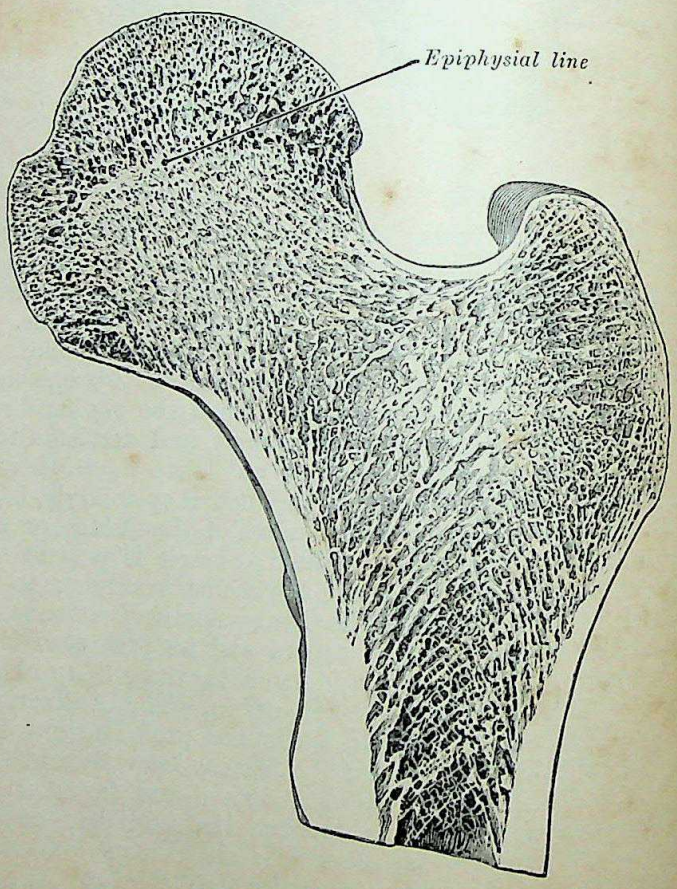

The *anterior surface* of the femur is between the lateral and medial b it is smooth, convex, broader above and below than in the middle. The

CC-0. In Public Domain. Gurukul Kangri Collection, Haridwar

Digitized by Arya Samaj Foundation Chennai and eGangotri

rmedius arises from its upper three-fourths, and from the upper part of its r one-fourth the Articularis genus takes origin. The *lateral surface* is ween the lateral border and the linea aspera; it is continuous above with lateral surface of the greater trochanter, below with that of the lateral ycle: the Vastus intermedius arises from its upper three-fourths. The *dial surface* is between the medial border and the linea aspera; it is continuous ve with the lower border of the neck, below with the medial side of the dial condyle; it is covered by the Vastus medialis.

The lower end of the femur (figs. 421, 422) is larger than the upper, and sists of two oblong eminences, known as the *condyles*; in front, these are but tly prominent, and are separated by a smooth shallow articular depression d the *patellar surface*; behind, they project considerably, and are separated deep notch, the *intercondyloid fossa*. The *lateral condyle* is the more pro nt anteriorly, and is the broader both in its anteroposterior and transverse meters. The *medial condyle* projects to a lower level than the lateral, when femur is held with its body perpendicular; when, however, the bone is s natural oblique position the lower surfaces of the two condyles lie in the horizontal plane. The condyles are not quite parallel with one another; long axis of the lateral is almost directly anteroposterior, but that of the l runs backwards and medialwards. Their opposed surfaces are small, and concave, and form the walls of the intercondyloid fossa; this fossa ted above by a ridge, the *intercondyloid line*, and below by the central of the posterior margin of the patellar surface. The posterior cruciate ment of the knee-joint is attached to the lower and front part of the medial of the fossa, and the anterior cruciate ligament to the upper and posterior of its lateral wall. Each condyle is surmounted by an elevation, the ndyle. The *medial epicondyle* is a large convex eminence to which the tibial teral ligament of the knee-joint is attached. At its upper part is the ctor tubercle, already referred to, and behind it is a rough impression which s origin to a large part of the medial head of the Gastrocnemius. The *lateral ndyle* (fig. 422), smaller and less prominent than the medial, gives attach- t to the fibular collateral ligament of the knee-joint. Directly below it is a ll depression from which a deep, oblique groove curves upwards and back- s to the posterior end of the condyle. This groove is separated from the ular surface of the condyle by a rounded across the anterior part of which a vertical, low groove descends from the depression. the recent state these grooves are covered cartilage. The Popliteus arises from the ression below the epicondyle; its tendon lies oblique groove when the knee is acutely and in the vertical groove when the knee tended. Above and behind the lateral epi- yle is an area for the origin of the lateral of the Gastrocnemius, above and medial to h the Plantaris arises.

FIG. 424.—A scheme showing the disposition of the principal cancellous lamellæ in the upper end of the femur.

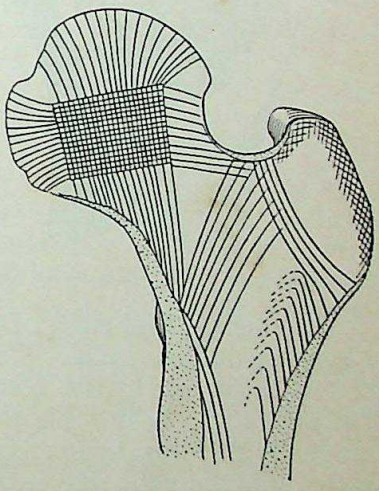

The *articular surface* of the lower end of the r occupies the anterior, inferior, and erior surfaces of the condyles. Its front articulates with the patella, and is named *patellar surface*; it presents a median ve between two convexities, the lateral of h is broader, more prominent, and ascends er than the medial. The lower and erior parts of the articular surface con- te the *tibial surfaces* for articulation with rresponding condyles of the tibia and the l of the knee-joint. The tibial surfaces are separated from one another intercondyloid fossa, and from the patellar surface by two faint grooves extend obliquely across the condyles. The lateral groove is the better ed; it runs lateralwards and slightly forwards from the front part of the ondyloid fossa, and expands to form a triangular depression which rests the anterior portion of the lateral meniscus when the knee-joint is fully

CC-0. In Public Domain. Gurukul Kangri Collection, Haridwar

Digitized by Arya Samaj Foundation Chennai and eGangotri

extended. The medial groove is less distinct than the lateral, and ex
on the medial part of the condyle; it receives the anterior edge of the
meniscus when the knee-joint is extended. Where this groove ceases
the patellar surface is continued backwards on the medial condyle a
lunar area adjoining the anterior part of the intercondyloid fossa; this
area articulates with the medial vertical facet of the patella in forced
the knee-joint. The tibial surfaces of the condyles are convex from sid
and from before backwards. Each presents a double curve, its posterior
being an arc of a circle, its anterior, part of a cycloid.*

FIG. 425.—An oblique section through the upper end of the left femur showing the calcar femorale.

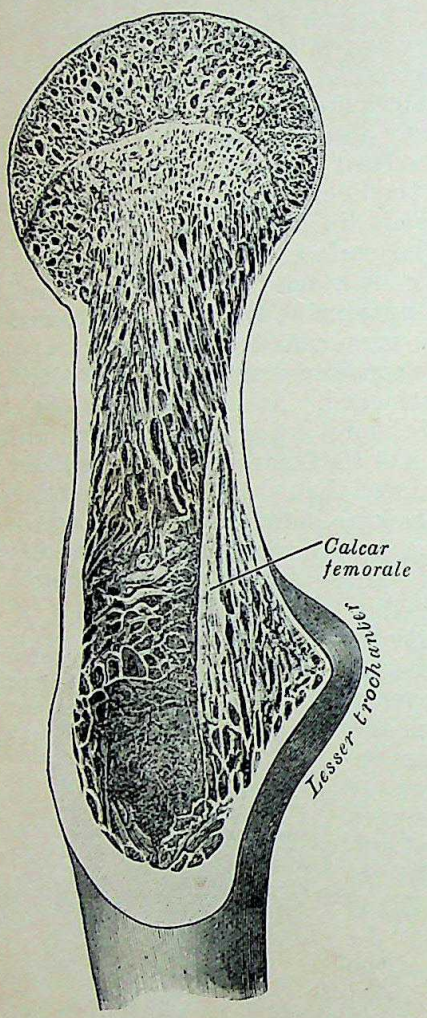

FIG. 426.—A plan of the ossificatio
femur. From five centres.

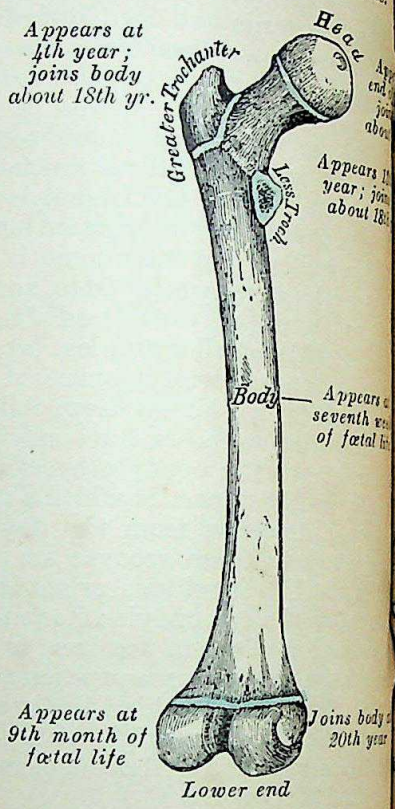

Structure.—The body of the femur is a cylinder of compact bone, hollo
a large medullary canal. The wall of the cylinder is thick in the middle
of the body, where the bone is narrowest and the medullary canal best
but above and below this the wall becomes thinner, while the medullary
gradually filled up by spongy substance, so that the upper and lower end
body, and the articular extremities more especially, consist of spongy sub
invested by a thin compact layer.

The cancelli in the ends of the femur are disposed along the lines of greates
sure and tension. In the upper end (figs. 423, 424) the chief lamellæ are
in the following manner. A series of bony planes at right angles to the
surface of the head converge to a central dense wedge; this wedge is

* A *cycloid* is a curve traced by a point in the circumference of a wheel when the
rolled along in a straight line.

CC-0. In Public Domain. Gurukul Kangri Collection, Haridwar

Digitized by Arya Samaj Foundation Chennai and eGangotri.

rong lamellæ which extend to the sides of the neck and are specially marked its upper and lower borders. Any force therefore applied to the head of emur is transmitted directly to the central wedge and thence to the junction e neck with the body. This junction is specially strengthened by a series se lamellæ which extend from the lesser trochanter to the lateral end of the or border of the neck; this arrangement will obviously oppose considerable ance to either tensile or shearing force. A smaller bar stretching across unction of the greater trochanter with the neck and body resists the shearing of the muscles attached to this prominence. These two bars, one at the ion of body and neck, the other at the junction of body and greater trochanter, the upper layers of a series of arches which extend across between the sides

427.—The epiphysial lines of the femur in a young adult. Anterior aspect.

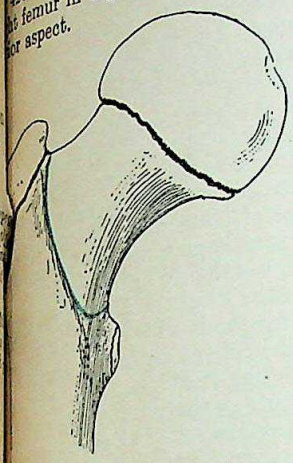

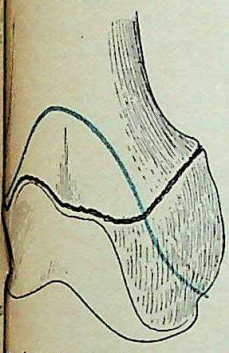

es of attachment of the articular capsules are in blue.

FIG. 428.—The epiphysial lines of the right femur in a young adult. Posterior aspect.

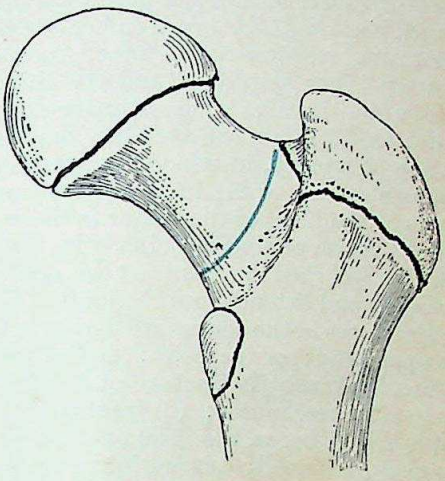

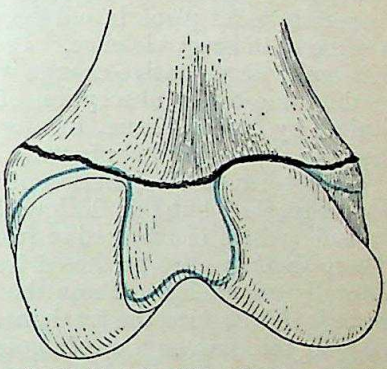

The lines of attachment of the articular capsules are in blue.

e body and transmit to the body forces applied to the upper end of the bone. e spongy substance of the neck is a thin vertical plate of bone, the *calcar* rale (fig. 425), which springs from the compact wall of the body in the region of linea aspera. Medially it is attached to the inner surface of the posterior wall e neck of the bone; laterally it continues the plane of the posterior wall of ck into the greater trochanter, where it shades off into the general spongy ance. It is thus situated in a plane anterior to the intertrochanteric crest to the base of the lesser trochanter.

n the lower end, the cancelli spring on all sides from the inner surface of the ler, and descend in a direction perpendicular to the articular surface, the ll being strongest and having a more accurately perpendicular course above ndyles. In addition to this, there are horizontal planes of cancellous tissue, at the spongy substance in this situation is mapped out into a series of cubical artments.

ssification (figs. 426, 427, 428).—The femur is ossified from five centres: one for the body, head, greater trochanter, lesser trochanter, and lower end

CC-0. In Public Domain. Gurukul Kangri Collection, Haridwar

Digitized by Arya Samaj Foundation Chennai and eGangotri

Except the clavicle, it is the first of the long bones to show traces of os
Ossification begins in the middle of the body in the seventh week of fœtal
extends upwards and downwards. The secondary centres appear as
in the lower end, during the ninth month of fœtal life (from this centre the
and epicondyles are formed); in the head at the end of the first year; in the
trochanter during the fourth year; and in the lesser trochanter between
teenth and fourteenth years. The epiphyses, derived from the secondary
fuse independently with the body after puberty; the lesser trochanter
then the greater, then the head, and, lastly, the lower end which is
until the twentieth year.

Applied Anatomy.—The lower end of the femur is the only epiphysis in which
tion has commenced at the time of birth. The presence of this centre of ossifi
therefore, a proof, in a new-born child found dead, that the child has arrived at
period of uterogestation, and is always relied upon in medico-legal investigation
position of the epiphysial plate should be carefully noted. It is on a level
adductor tubercle, and the epiphysis does not, therefore, form the whole of the
covered portion of the lower end of the bone. It is essential to bear this point in
performing excision of the knee, since growth in length of the femur takes place
from the lower epiphysis, and any interference with the epiphysial cartilage in
child would involve such ultimate shortening of the limb, from want of growth
render the limb almost useless. Separation of the lower epiphysis may take place
the age of twenty, at which time it becomes completely joined to the body of the
but, as a matter of fact, few cases occur after the age of sixteen or seventeen.
physis of the head of the femur is the seat of origin, in a large number of cases,
culous disease of the hip-joint. In the majority of cases the disease begins in the
vascular and growing tissue at the end of the body in the neighbourhood of the
cartilage, and extends into the joint. The epiphysis for the head is entirely intra

Fractures of the femur are divided, like those of the other long bones, into fra
the upper end; of the body; and of the lower end. The fractures of the upper
be classified into (1) fracture of the neck; (2) fracture at the junction of the
the greater trochanter; (3) fracture of the greater trochanter; and (4) separation
epiphysis, either of the head or of the greater trochanter. The first of these, fra
the neck, is usually termed *intracapsular* fracture, but this is scarcely a correct
tion, as, owing to the attachment of the articular capsule, the fracture is partly
and partly without the capsule when the fracture occurs at the lower part of the
generally takes place in old people, principally women, and usually from a very
degree of indirect violence. Probably the main cause of its occurrence in old
the senile degenerative change which takes place in the bone. Merkel believes
mainly due to the absorption of the calcar femorale. As a rule the fragments
united by fibrous tissue, but frequently no union takes place, and the opposed
become smooth and eburnated.

Fractures at the junction of the neck with the greater trochanter are usually
extracapsular, but this designation is also incorrect, as the fracture is partly within
capsule, which is attached in front to the intertrochanteric line below the line of
These fractures are produced by direct violence to the greater trochanter, as from
laterally on the hip. From the manner in which the accident is caused the neck
bone is driven into the trochanter, where it may remain impacted or the trochanter
be split into two or more fragments, disimpaction resulting.

Fractures of the body may occur at any part, but the most usual situation is at
the centre of the bone. Fractures of the upper third of the body are almost always
result of indirect violence, while those of the lower third are the result, for the most
direct violence. Fractures of the body are generally oblique, but they may be transverse
longitudinal, or spiral. The transverse fracture occurs most frequently in children
fractures of the lower end of the femur include transverse fracture above the condyles
the most common; and this may be complicated by a vertical fracture between
condyles, constituting the T-shaped fracture. In these cases the popliteal artery
danger of being wounded. Oblique fracture separating either the medial or
condyle, and a longitudinal incomplete fracture between the condyles, may also
place.

When there is a possibility of a fracture of the femur resulting in shortening
bone, treatment should be carried out in the abducted position, so that the tilting
pelvis to counteract the abduction may produce lengthening. The replacement of fra
of the lower one-third is facilitated by flexing the knee and so relaxing the gastrocnemius
and the hamstrings.

The femur is exposed, with least injury to the vascular and nervous supply
muscles, through an incision in the line of the lateral intermuscular septum.

The femur and the other long bones of the leg are frequently the seat of
osteomyelitis in children. This is no doubt due to their greater exposure to
which is often the exciting cause of this disease. Necrosis of portions of the dia

CC-0. In Public Domain. Gurukul Kangri Collection, Haridwar

Digitized by Arya Samaj Foundation Chennai and eGangotri

ently ensue, especially in the region of the popliteal space and of the femur, and the se may continue for years, great trouble being experienced with discharging sinuses periodically close and reopen to allow of the exit of pieces of dead bone.

umours are not infrequently found growing from the femur: the most common being sarcoma, which may grow either from the periosteum or from the medullary within the interior of the bone, and exostosis, which commonly originates in the bourhood of the epiphysial cartilage of the lower end. The region of the lower ysial line is by far the commonest seat for all these tumours, and it should be noted he lower epiphysis has the longest period of active growth, and that these tumours y appear towards the end of the period of active growth of the bone.

The Tibia

he tibia (figs. 430, 431) is situated at the medial side of the leg, and, ding the femur, is the longest bone of the skeleton. It is prismoid in expanded above, where it enters into the formation of the knee-joint, cted in the lower one-third, and again enlarged, but to a lesser extent, . It has a body and two ends.

Fig. 429.—The upper surface of the right tibia.

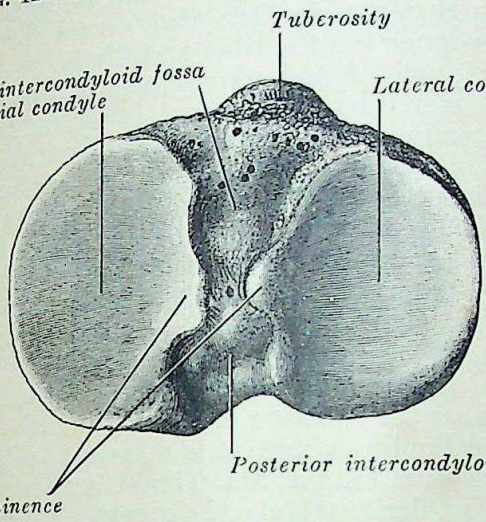

he upper end of the tibia (fig. 429) is expanded into two eminences, the *l and lateral condyles*, the superior surfaces of which form the medial and l articular surfaces. The medial articular surface, oval in shape, is y concave from side to side, and from before backwards; the lateral, y circular, is concave from side to side, but slightly convex from before wards, especially at its posterior part where it is prolonged on to the erior surface for a short distance. The central portions of the medial and al articular surfaces articulate with the condyles of the femur, while their teral portions support the menisci of the knee-joint, which here intervene ween the tibia and the femoral condyles. Between the articular surfaces, nearer the posterior than the anterior part of the bone, is the *intercondyloid* nence (tibial spine), surmounted by two prominent tubercles, on the sides hich the articular surfaces are prolonged; in front of and behind the rcondyloid eminence are rough depressions, the *anterior and posterior rcondyloid fossæ*, for the attachment of the cruciate ligaments and the isci of the knee-joint. The anterior surfaces of the condyles are continuous one another, forming a large, triangular, somewhat flattened area; this area orated by foramina for vessels, and ends below in an oblong elevation, the sity of the tibia, which gives attachment to the ligamentum patellæ; a intervenes between the deep surface of the ligament and the part of the immediately above the tuberosity. The *medial condyle* is grooved eriorly, for the insertion of the tendon of the Semimembranosus; its medial ace, convex, rough and prominent, gives attachment to the posterior part the tibial collateral ligament of the knee-joint. The *lateral condyle* presents

CC-0. In Public Domain. Gurukul Kangri Collection, Haridwar

Digitized by Arya Samaj Foundation Chennai and eGangotri

posteriorly a flat, nearly circular articular facet directed downwards, wards, and lateralwards, for articulation with the head of the fibula. It surface is convex, rough and prominent in front: on it is an eminence, on a level with the articular facet for the fibula, for the attachment iliotibial tract or band of the fascia lata. Just below this eminence a the tendon of the Biceps femoris is inserted, and a small part of the digitorum longus takes origin.

The **body or shaft** of the tibia has three crests or margins, and three

The *anterior crest* or *shin*, the most prominent, begins above at the tu and ends below at the anterior margin of the medial malleolus. It is and prominent in its upper two-thirds, but smooth and rounded below; attachment to the deep fascia of the leg.

The *medial margin* is smooth and rounded above and below, b prominent in the centre; it begins at the posterior part of the medial and ends at the posterior border of the medial malleolus; its upper p attachment to the tibial collateral ligament of the knee-joint to the of about 5 cm., and insertion to some fibres of the Popliteus; from its one-third some fibres of the Soleus and Flexor digitorum longus take orig

The *interosseous crest* gives attachment to the crural interosseous me (fig. 434), and is most distinct in the middle one-third of the bone; it above in front of the fibular articular facet, and bifurcates below to form sides of a triangular rough depression, the *fibular notch*, for the attachment interosseous ligament connecting the tibia and fibula.

The *medial surface* is smooth and convex, and is broader above than Its upper one-third is covered by an aponeurosis derived from the tendo Sartorius, and by the tendons of the Gracilis and Semitendinosus; all th inserted into this part of the bone. The rest of the surface is subcutan

The *lateral surface* is narrower than the medial; on its upper two-th shallow groove for the origin of the Tibialis anterior; its lower one- smooth, convex, curves gradually forwards to the anterior aspect of th and is covered by the tendons of the Tibialis anterior, Extensor hallucis and Extensor digitorum longus, arranged in this order from the medial

At the upper part of the *posterior surface* (fig. 431) is a prominent the *popliteal line*, which descends obliquely from the fibular articul to the medial border, near the junction of the upper with the middle one- the fascia covering the Popliteus muscle is attached to this line, and p the Soleus, Flexor digitorum longus, and Tibialis posterior take origin Above the line is a triangular area, into the greater part of which the Po is inserted; immediately below the line is the orifice of the nutrient canal is large and directed obliquely downwards. The middle one-third posterior surface is divided into two areas by a vertical ridge which be the popliteal line and is usually well marked above, but indistinct below medial and broader area gives origin to the Flexor digitorum longus, the and narrower to a part of the Tibialis posterior. The lower part of the po surface is smooth and covered by the Tibialis posterior, Flexor dig longus, and Flexor hallucis longus.

The **lower end** of the tibia is prolonged downwards on its medial sid strong process, the *medial malleolus*. The *inferior articular surface* is lateral, and articulates with the talus. It is broader in front than b concave from before backwards, and near the middle is traversed in this di by a slight elevation. It is continuous with the articular surface on the side of the medial malleolus. The *anterior surface* is smooth and ro above, and covered by the tendons of the Extensor muscles; at its margin is a furrow for the attachment of the articular capsule of the ankle The lateral part of the *posterior surface* is traversed by a shallow groove, di obliquely downwards and medialwards, in which the tendon of the hallucis longus lies. On the *lateral surface* is a triangular rough depr the *fibular notch*, for the attachment of the interosseous ligament conne the tibia with the fibula; in the recent state, the lower border of this is occasionally covered with cartilage, and articulates with the fibula fibular notch is bounded by two prominent borders, continuous above w interosseous crest; their lower parts afford attachment to the anterior posterior ligaments of the lateral malleolus.

CC-0. In Public Domain. Gurukul Kangri Collection, Haridwar

Digitized by Arya Samaj Foundation Chennai and eGangotri



FIG. 431.—The bones of the right leg. Posterior aspect.

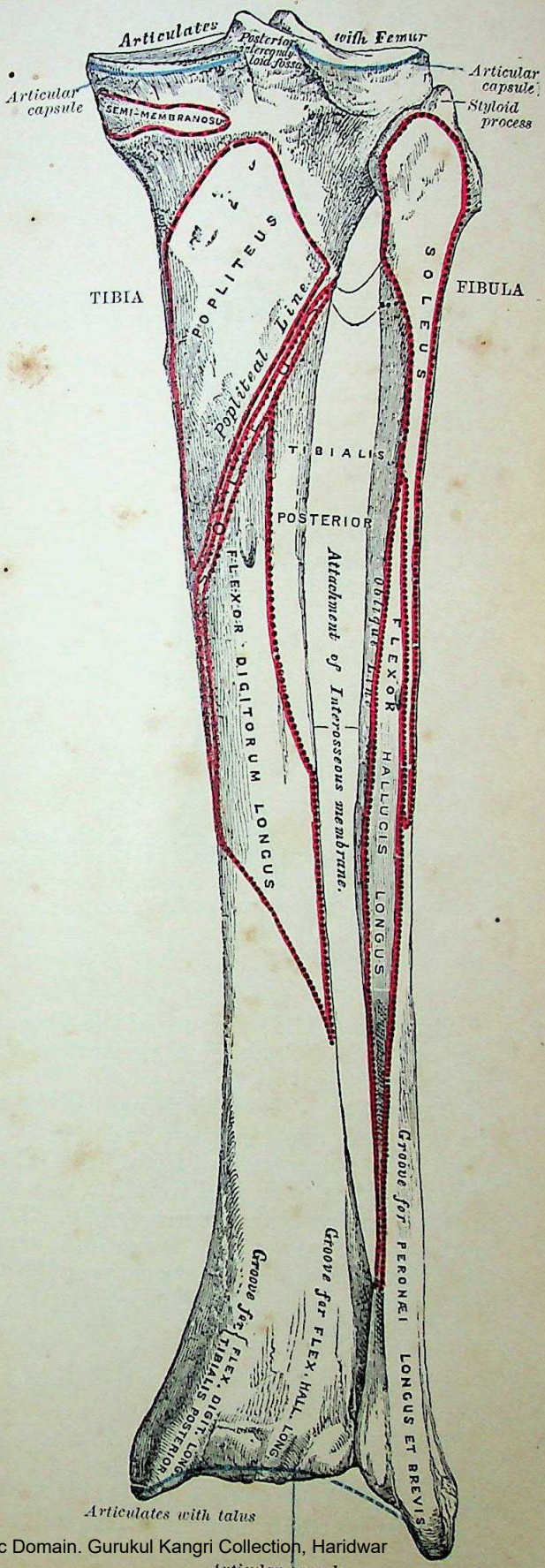

CC-0. In Public Domain. Gurukul Kangri Collection, Haridwar

Digitized by Arya Samaj Foundation Chennai and eGangotri

The *medial malleolus* is a strong pyramidal process, flattened fro side. Its *medial surface* is convex and subcutaneous; its *lateral or surface*, smooth and slightly concave, articulates with the talus; its *border* is rough, for the attachment of the anterior fibres of the deltoid of the ankle-joint: on its *posterior border* is a broad groove, the *malleo* directed obliquely downwards and medialwards, and occasionally do lodges the tendons of the Tibialis posterior and Flexor digitorum long *lower border* of the malleolus is marked posteriorly by a depressio attachment of the deltoid ligament of the ankle-joint.

Fig. 432.—A plan of the ossification of the tibia. From three centres.

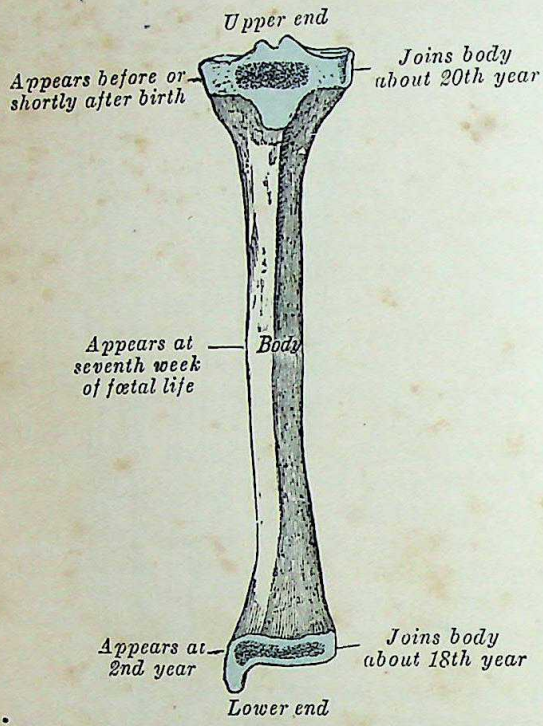

Fig. 433.—The epiphysial l right tibia and fibula i adult. Anterior aspect.

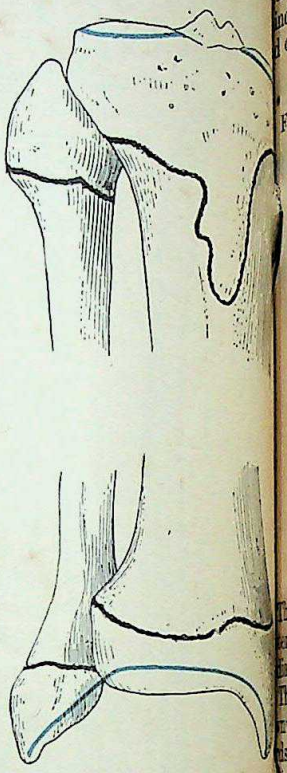

The lines of attachment of the capsules are in blue.

Structure.—The structure of the tibia is like that of the other long bon compact wall of the body is thickest at the junction of the middle with t one-third of the bone.

Ossification.—The tibia is ossified from three centres (figs. 432, 433) the body and one for either end. Ossification begins in the middle of t about the seventh week of fœtal life. The centre for the upper end appe or shortly after birth, and from it a thin tongue-shaped process extends d in front, to form the tuberosity (fig. 433); the centre for the lower en in the second year. The lower end joins the body about the eighteen the upper about the twentieth year. Two additional centres occasion one for the tongue-shaped process which forms the tuberosity, and on medial malleolus.

The Fibula

The **fibula** (figs. 430, 431) is placed on the lateral side of the tibia connected to it above and below. In proportion to its length it is slender of all the long bones. Its upper end articulates with th of the lateral condyle of the tibia, below the level of the knee-joint. T inclines a little forwards so that its lower end or lateral malleolus is on

CC-0. In Public Domain. Gurukul Kangri Collection, Haridwar

Digitized by Arya Samaj Foundation Chennai and eGangotri

erior to that of the upper end; it projects below the tibia, and forms the
ral part of the ankle-joint.

The upper end or head of the fibula is of an irregular quadrate form, and
a flattened articular surface, directed upwards, forwards, and medialwards,
rticulation with the lateral condyle of the tibia. On its lateral side is
ick and rough prominence, continued behind into a pointed eminence,
per or *styloid process*, which projects upwards from the posterior part of the
d. The upper and lateral parts of this prominence give attachment to the
ion of the Biceps femoris and to the fibular collateral ligament of the knee-
t, the ligament dividing the tendon into two parts. The remaining part
he head is rough, for the attachment of muscles and ligaments; in front
tubercle for the origin of the highest fibres of the Peronæus longus, and a
ce for the attachment of the anterior ligament of the head of the bone;
nd, is another tubercle for the attachment of the posterior ligament of the
d of the fibula, and a few fibres of the Soleus.

FIG. 434.—A transverse section through the right tibia and fibula, showing the attachment of the crural interosseous membrane.

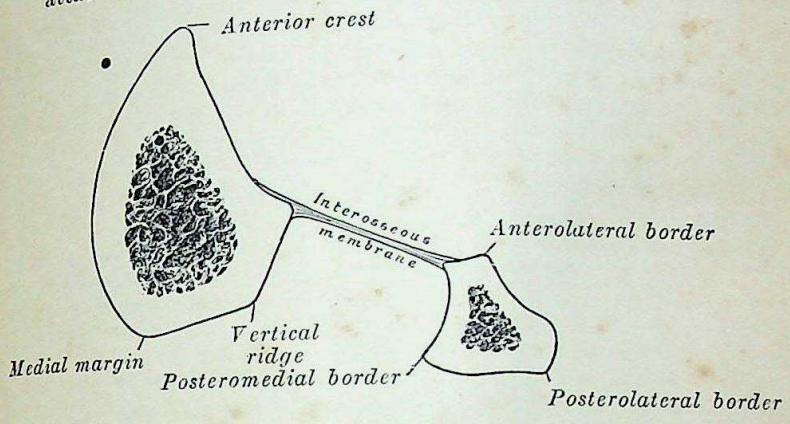

The body or shaft of the fibula has four borders—anterolateral, anteromedial, rolateral, and posteromedial; and four surfaces—anterior, posterior, rial, and lateral.

The *anterolateral border* begins above in front of the head, runs vertically rwards to a little below the middle of the bone, and then curving lateral-ds, divides to form the sides of a triangular subcutaneous surface which is nued on to the lateral malleolus. This border gives attachment to the or fibular intermuscular septum which separates the extensor muscles e front of the leg from the Peronæus longus and Peronæus brevis on the ral side

The *anteromedial border*, or *interosseous crest*, is on the medial side of the rolateral border; it runs close to and nearly parallel with the upper one-l of this border, but diverges from its lower two-thirds. It begins above below the head of the bone, and is sometimes quite indistinct for about m.; it ends at the apex of a rough triangular surface which is situated e the articular facet of the lateral malleolus. It serves for the attachment e crural interosseous membrane (fig. 434) which separates the extensor es in front from the flexor muscles behind.

The *posterolateral border* is prominent; it begins above at the styloid ess of the head and ends below in the posterior border of the lateral eolus. It is directed lateralwards above, backwards in the middle of its se, backwards and a little medialwards below, and gives attachment to osterior fibular intermuscular septum which separates the Peronæi on the l side from the Soleus and Flexor hallucis longus behind.

The *posteromedial border*, sometimes called the *oblique line*, begins above e medial side of the head and ends by joining the interosseous crest at lower part of the bone; it is well marked and prominent in its upper and dle parts. It gives attachment to an aponeurosis which separates the tis posterior from the Soleus and Flexor hallucis longus.

CC-0. In Public Domain. Gurukul Kangri Collection, Haridwar

Digitized by Arya Samaj Foundation Chennai and eGangotri

The *anterior surface* is the interval between the anterolateral and medial borders. It is narrow and flat in the upper one-third of its broader and grooved longitudinally in its lower one-third; it serves origin of the Extensor digitorum longus, Extensor hallucis longus, and Pe tertius.

The *posterior surface* is between the posterolateral and poster borders; it is continuous below with the triangular area above the surface of the lateral malleolus, and is directed backwards above, and wards below. Its upper one-third is rough for the origin of the Sole lower part, triangular in shape, is connected to the tibia by a strong inter ligament; the intervening part gives origin to a portion of the Flexor longus. Near the middle of this surface is the orifice of the nutrien which is directed downwards.

FIG. 435.—The lower end of the right fibula. Medial aspect.

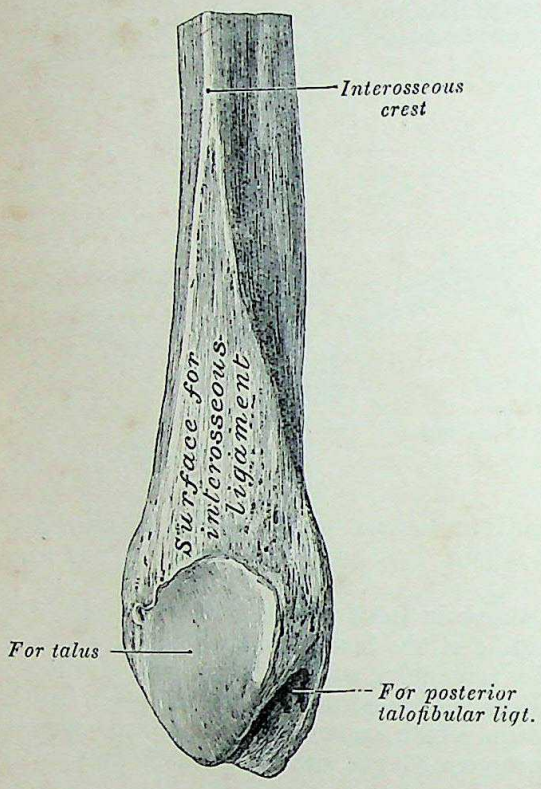

FIG. 436.—A plan of the of the fibula. From three

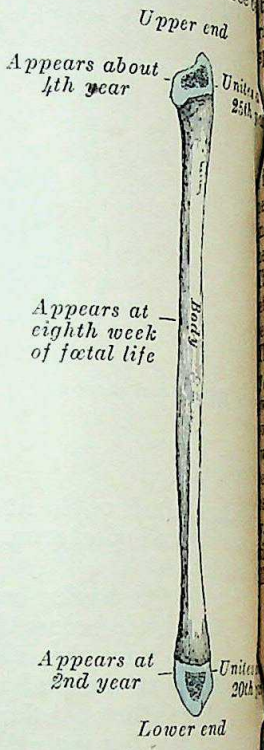

The *medial surface*, between the anteromedial and posteromedial b gives origin to part of the Tibialis posterior.

The *lateral surface*, between the anterolateral and posterolateral b is broad and often deeply grooved. It is directed lateralwards in its two-thirds, and backwards in its lower one-third, where it is continuo the posterior border of the lateral malleolus. The upper part of this gives origin to the Peronæi longus et brevis; the lower part is covered tendons of these muscles.

The **lower end** of the fibula, or *lateral malleolus*, is of a pyramidal and somewhat flattened from side to side; it descends to a lower level the medial malleolus. The *lateral surface* is convex, and continuous w triangular, subcutaneous surface on the lateral side of the body of the The *medial surface* (fig. 435) presents in front a smooth triangular s convex from above downwards, which articulates with the lateral side talus. Behind and distal to the articular surface is a rough depression attachment of the posterior talofibular ligament. The *anterior border* is and rough, and marked below by a depression for the attachment of the talofibular ligament. The *posterior border* is broad, and presents a s

CC-0. In Public Domain. Panini Kanya Maha Vidyalaya Collection.

Digitized by Arya Samaj Foundation Chennai and eGangotri

cal groove which is traversed by the tendons of the Peronæi longus et is. The *summit* is rounded, and gives attachment to the calcaneofibular ment.

Ossification.—The fibula is ossified from three centres (fig. 436): one for the and one for either end. Ossification begins in the body about the eighth of fœtal life, in the lower end during the second year, and in the upper about fourth year. The lower epiphysis, the first to ossify, unites with the body at the twentieth year; the upper about the twenty-fifth year.

Applied Anatomy.—In fractures of the bones of the leg, both bones are generally red, but either bone may be broken separately, the fibula more frequently than the When fracture occurs from indirect force, the break in the tibia is at the junction e middle with the lower one-third, or weakest part of the bone, while the fracture of bula is usually at a rather higher level. These fractures present great variety, both ards their direction and condition. They may be oblique, transverse, longitudinal, ral. When oblique, they are for the most part the result of indirect violence, and rection of the fracture is downwards, forwards, and medialwards in many cases, but e downwards and lateralwards, or downwards and backwards. When transverse, ture is often at the upper part of the bone, and is the result of direct violence. piral fracture of the tibia generally starts as a vertical fissure, involving the ankle- and is associated with fracture of the fibula higher up. It is the result of torsion, rsting of the body while the foot is fixed.

ctures of the tibia alone are almost always the result of direct violence, except the malleolus is broken off by twists of the foot. Fractures of the fibula alone may from indirect or direct force, those of the lower end being usually the result of the t, and those higher up being caused by a direct blow on the part; the common neal nerve, where it winds round the neck of the fibula, may be injured at the time e fracture, or subsequently by ill-applied splints.

he tibia is the bone which is most commonly and most extensively distorted in ts. It bends at the junction of the middle and lower third, its weakest part, and ers a curve forwards with generally some lateral displacement.

he tibia is more often the seat of acute infective necrosis than any other bone in the s, and with the formation of the sequestrum a large amount of new bony material is n out by the periosteum. The sequence of events in this disease can be very closely ved in the case of the tibia, and it is not uncommon to find a patient from whom hole diaphysis of the tibia has been removed, going about with a new bone entirely eriosteal formation. Chronic bone abscess is more frequently met with in the llous tissue of the head or lower end of the tibia than in any other bone in the . These abscesses are very chronic, and in most cases the result of tuberculous s, although they are sometimes due to the organisms of suppuration or even the us typhosus.

The Patella

e patella (figs. 437, 438), the largest of the sesamoid bones, is situated s of the knee-joint in the tendon of the Quadriceps femoris. It is d triangular, and has an anterior and a posterior surface, three borders, n apex.

Fig. 437.—The right patella. Anterior aspect.

Fig. 438.—The right patella. Posterior aspect.

The *anterior surface* rvex, perforated by ures for the passage rient vessels, and ed by numerous longitudinal striæ. separated from the by a bursa and is ed, in the recent by an expansion the tendon of the riceps femoris; this ion is continuous with the super- fibres of the ligamentum patellæ. The *posterior surface* presents above oth, oval, articular area, divided into two facets by a vertical ridge; ridge corresponds to the groove on the patellar surface of the femur, and facets to the medial and lateral parts of the same surface; the lateral is the broader and deeper. Below the articular surface is a rough,

CC-0. In Public Domain. Gurukul Kangri Collection, Haridwar

Digitized by Arya Samaj Foundation Chennai and eGangotri

convex, non-articular area, the lower part of which gives attachme ligamentum patellæ.

The *base* or *superior border* is thick, and sloped from behind, do and forwards: it gives attachment, except near its posterior margin portion of the Quadriceps femoris which is derived from the Rectus fe Vastus intermedius. The *medial and lateral borders* are thinner and below: they give attachment to those portions of the Quadriceps which are derived from the Vasti medialis et lateralis. Near the of the superior and lateral borders is a small shallow circular depre which a part of the tendon of the Vastus lateralis is inserted.

The *apex* is pointed, and gives attachment to the ligamentum pate

Structure.—The patella consists of a nearly uniform dense spongy covered by a thin compact lamina. The cancelli immediately beneath th surface are arranged parallel with it. In the rest of the bone they rad the articular surface towards the other parts of the bone.

Ossification.—The patella is ossified from a single centre, which usual its appearance in the second or third year, but may be delayed until the si Ossification is completed about the age of puberty.

Applied Anatomy.—Fractures of the patella are of frequent occurrence. most often produced by muscular action—that is to say, by violent contracti Quadriceps femoris while the limb is in a position of semiflexion, so that th snapped across the condyles of the femur and the fracture is transverse. Fract patella is also produced by direct violence, such as falls on the knee, and here th is usually stellate and the bone comminuted. In fractures by muscular action th and lateral retinacular fibres of the articular capsule of the knee-joint are separation of the fragments takes place. When the fracture is caused by direct these retinacular fibres are not torn, and the fragments remain in contact. In by muscular action the fibrous expansion of the Quadriceps femoris which passe front of the patella to the ligamentum patellæ is torn from the front of the lower and falls as a veil over the fracture-surface of the upper fragment. Owing condition just described, (2) the displacement of the fragments, and (3) the di maintaining the latter in apposition, union takes place by fibrous tissue w subsequently stretch, producing wide separation of the fragments and perma ness. Really satisfactory results after this fracture are generally only to be ob opening the joint, removing the overhanging aponeurosis, and wiring the together.

If the fracture involve only the lower and non-articular part of the bone, anatomical possibility for such to take place without injury to the synovial str without involving the cavity of the knee-joint.

THE SKELETON OF THE FOOT

The skeleton of the foot (figs. 439, 440) consists of three segment tarsal bones, the metatarsal bones, and the phalanges or bones of the di

The Tarsal Bones (Ossa Tarsi)

The **tarsal bones** are seven in number: viz. the talus, calcaneus, na first, second, and third cuneiforms, and the cuboid.

The Talus (figs. 441 to 444)

The **talus** (astragalus), the second largest of the tarsal bones, the tibia and rests on the calcaneus; it articulates on either side corresponding malleolus, and in front with the navicular bone. It of a head, neck, body, and trochlea.

The **head** of the talus is directed forwards and medialwards. Its *or navicular surface* is oval and convex, with its long axis running do and medialwards; it articulates with the concavity of the navicula

CC-0. In Public Domain. Gurukul Kangri Collection, Haridwar

Digitized by Arya Samaj Foundation Chennai and eGangotri

FIG. 439.—The bones of the right foot. Dorsal aspect.

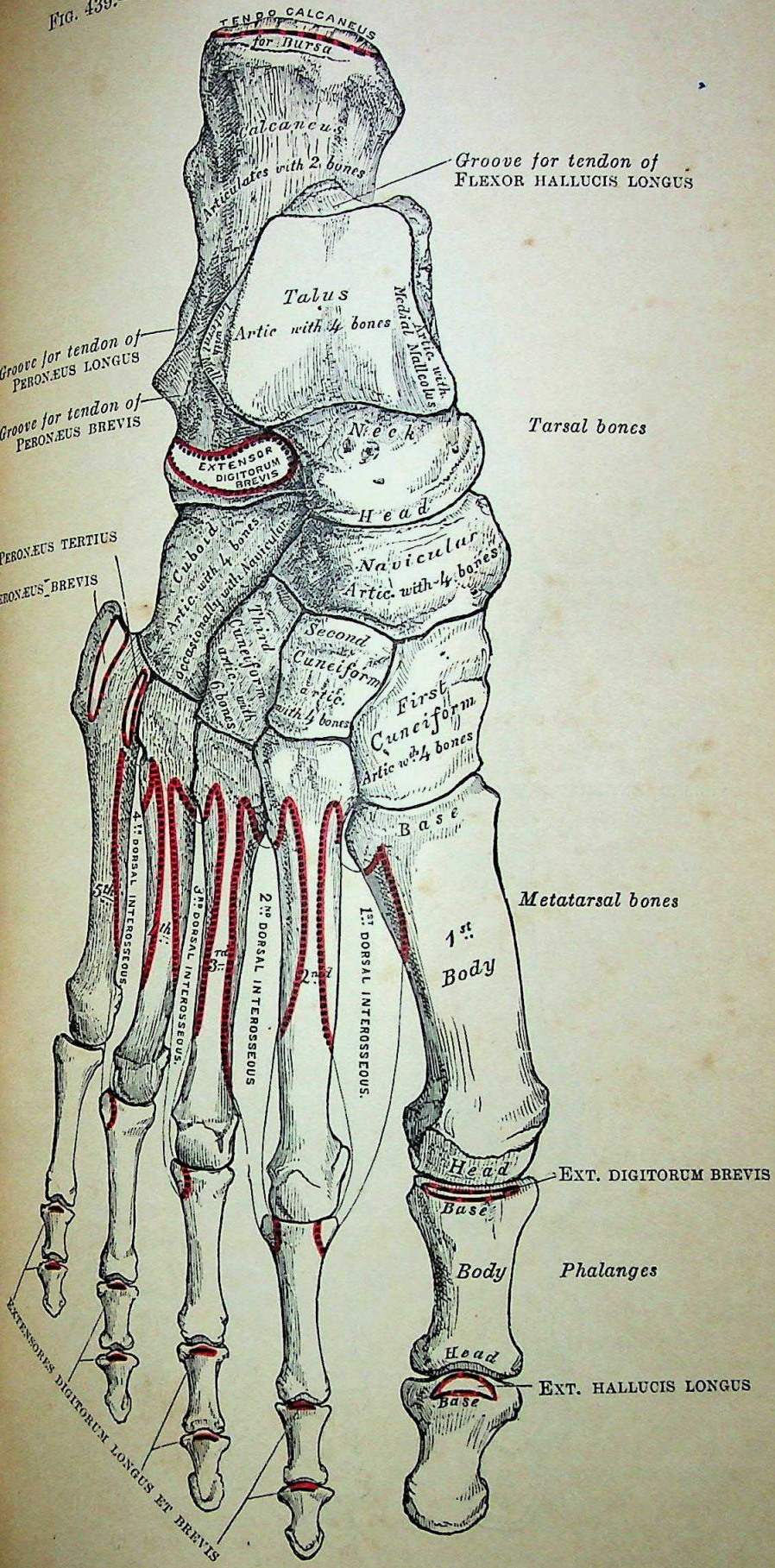

CC-0. In Public Domain. Gurukul Kangri Collection, Haridwar

Digitized by Arya Samaj Foundation Chennai and eGangotri

FIG. 440.—The bones of the right foot. Plantar aspect.

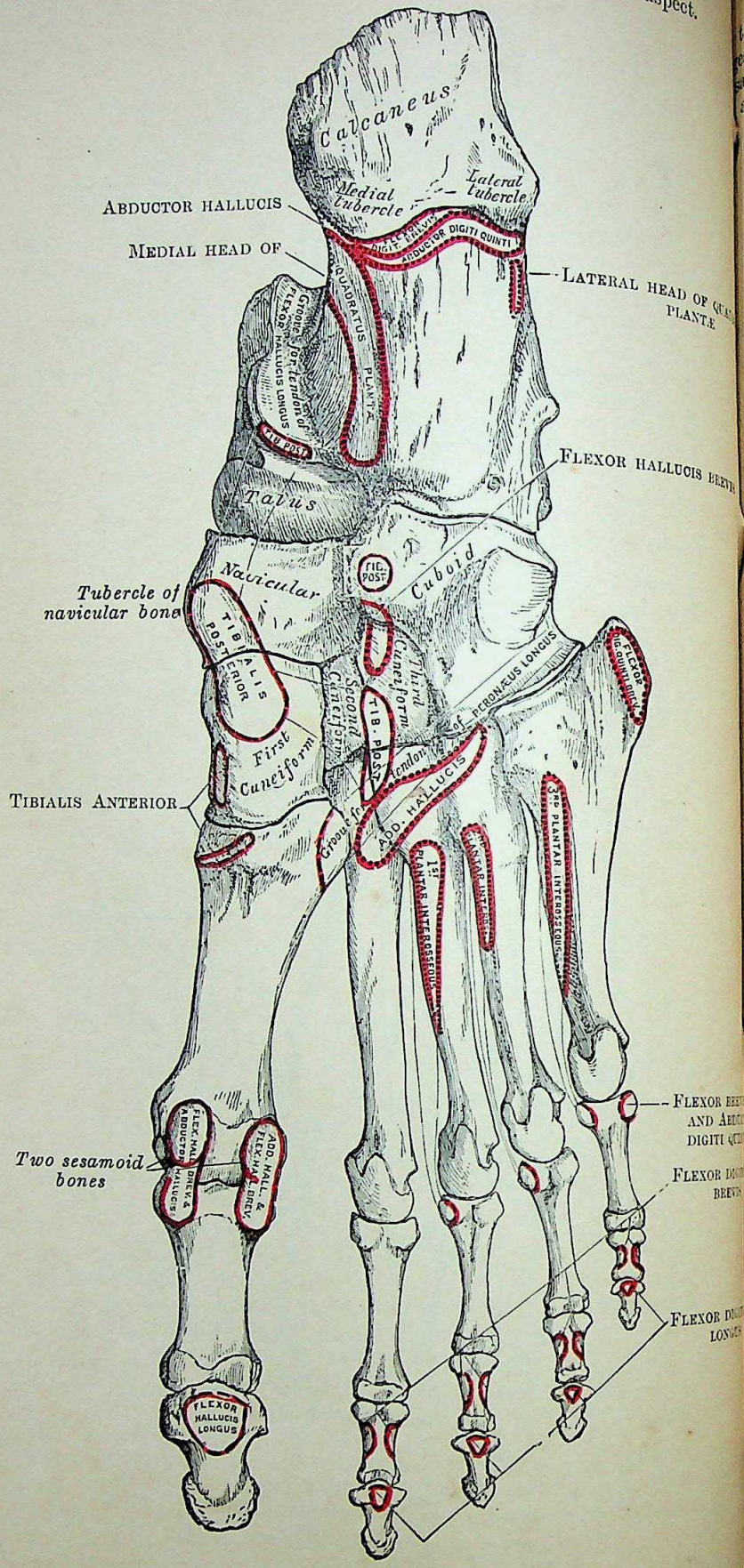

CC-0. In Public Domain. Gurukul Kangri Collection, Haridwar

Digitized by Arya Samaj Foundation Chennai and eGangotri

the *plantar surface* of the head are three articular areas (fig. 442). The rest and hindmost, termed the *middle calcaneal surface*, articulates with the al surface of the sustentaculum tali. Anterior and lateral to this surface, as a rule continuous with it, is the *anterior calcaneal surface*, quadrilateral

FIG. 441.—The left talus. Dorsal aspect.

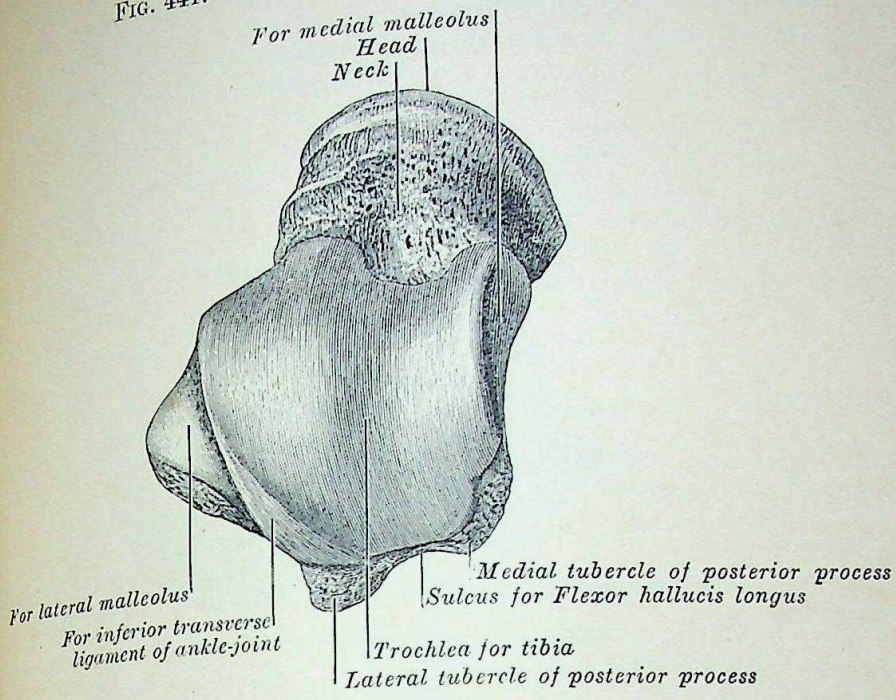

FIG. 442.—The left talus. Plantar aspect.

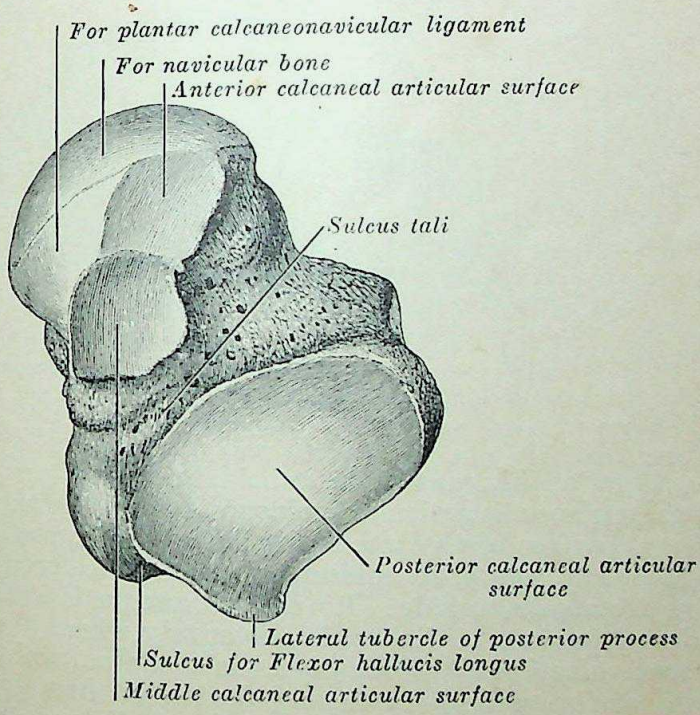

egularly oval in shape, for articulation with the anterior part of the dorsal ce of the calcaneus. Sometimes the anterior and middle calcaneal articular ces are wholly or partly discontinuous. Medial to the anterior calcaneal ce is a triangular, convex area, which extends on to the medial side of the d; it rests on the inferior calcaneonavicular ligament and on the anterior of the deltoid ligament of the ankle-joint.

CC-0. In Public Domain. Gurukul Kangri Collection, Haridwar

Digitized by Arya Samaj Foundation Chennai and eGangotri

The **neck** of the talus is the constricted part connecting the head body. Its *dorsal and medial surfaces* are rough and perforated by t for vessels. The dorsal surface gives attachment to the talonavicular li and a depression on it, immediately in front of the trochlea, receives the edge of the lower end of the tibia when the foot is flexed at the ank The *lateral surface* is narrow, concave, and continuous with the *plantar* which consists of the *sulcus tali*, a deep groove, wide in front and narrow and directed forwards and lateralwards ; in the articulated foot the sul overlies the sulcus calcanei and the two sulci form the *sinus tarsi*, a which is filled, in the recent condition, with the interosseous talo ligament.

Fig. 443.—The left talus. Medial aspect.

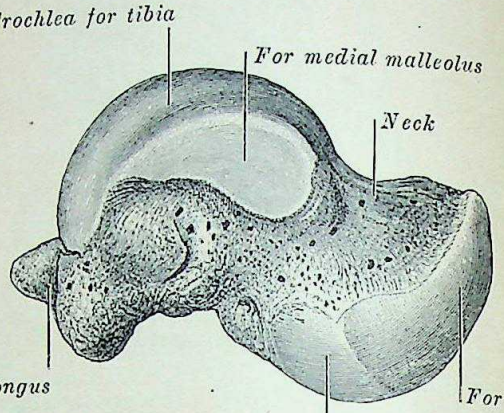

Fig. 444.—The left talus. Lateral aspect.

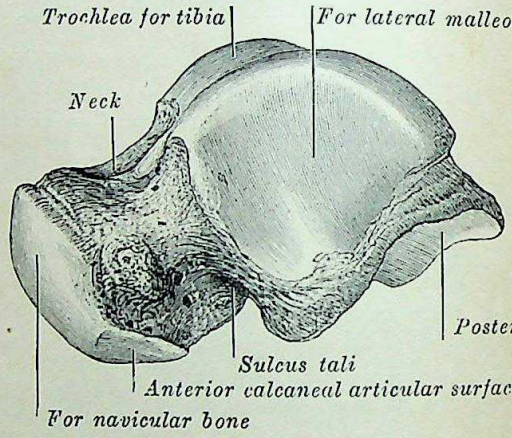

The **body** of the talus is the cuboidal posterior part of the bone, an its dorsal surface the articular eminence termed the *trochlea* projects (fig The dorsal surface of the trochlea articulates with the lower end of the it is broader in front than behind, convex from before backwards, and concave from side to side. Its medial margin is straight, but its la curved and inclines medialwards posteriorly where it usually expands small triangular facet * which comes into contact with the inferior tra ligament of the ankle-joint during flexion of that articulation. The surface of the trochlea articulates with the medial malleolus : it is pear-sh with the blunt end directed forward (fig. 443). Below this surface is a depressed area on the body of the bone for the attachment of the deep p the deltoid ligament of the ankle-joint. The lateral surface of the t articulates with the lateral malleolus ; it is concave vertically, and tria in outline with its apex downwards (fig. 444). Below the apex, the b

* E. Fawcett, *Edinburgh Medical Journal*, 1895.

CC-0. In Public Domain. Gurukul Kangri Collection, Haridwar

Digitized by Arya Samaj Foundation Chennai and eGangotri

lus projects as a rough, triangular eminence, named the *lateral process*; the lateral talocalcaneal ligament is attached. In front of the articular ce for the lateral malleolus is a rough impression for the anterior talo-ar ligament, while below and behind it is a groove in which a part of posterior talofibular ligament is implanted.

n the *plantar surface* of the body (fig. 442) is the *posterior calcaneal surface*, h is large in size and oval in form for articulation with the dorsal surface e calcaneus. It is limited in front by the sulcus tali and is deeply concave e direction of its long axis, which runs forwards and lateralwards at an e of about 45° with the median plane.*

The *posterior surface* of the body is small, and projects backwards as the rior *process*; it is traversed in a direction downwards and medialwards sulcus for the tendon of the Flexor hallucis longus (fig. 441). On either of this sulcus is a tubercle. That on the lateral side is the more pro-nt and gives attachment to the main part of the posterior talofibular ent; it is sometimes detached from the rest of the bone, and is then n as the *os trigonum*. To the smaller medial tubercle the medial calcaneal ligament is attached.

The Calcaneus (figs. 445 to 448)

The calcaneus (os calcis) is the largest of the tarsal bones. It is situated at lower and posterior part of the foot, and forms a strong lever for the cles of the calf. It is irregularly cuboidal in shape, having its long axis ted forwards and lateralwards.

445.—The left calcaneus. Dorsal aspect.

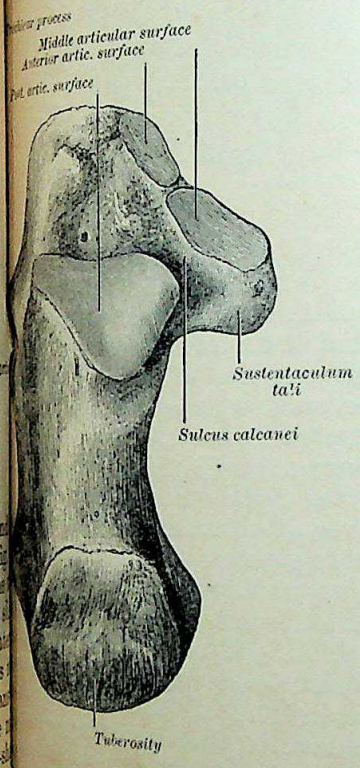

Fig. 446.—The left calcaneus. Plantar aspect.

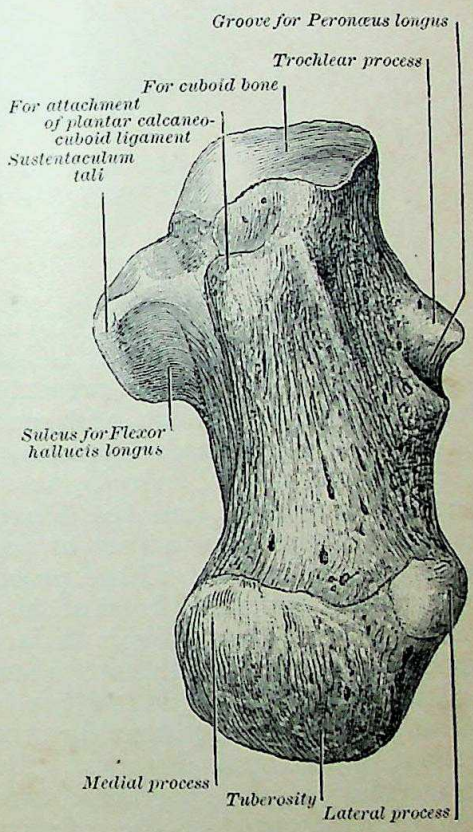

The *dorsal surface* (fig. 445) consists of a posterior non-articular and an rior articular part. The former varies in length in different individuals, onvex from side to side, concave from before backwards, and supports a

* R. B. S. Sewell (*Journal of Anatomy and Physiology*, vol. xxxviii.) pointed out that in about per cent. of bones a small triangular facet, continuous with the posterior calcaneal facet, is ent at the junction of the lateral surface of the body with the posterior wall of the sulcus tali.

CC-0. In Public Domain. Gurukul Kangri Collection, Haridwar

Digitized by Arya Samaj Foundation Chennai and eGangotri

mass of fat placed in front of the tendo calcaneus. In front of this a *posterior articular surface*, a large, usually somewhat oval-shaped fac looks upwards and forwards; it is convex from behind forwards, and a with the posterior calcaneal facet on the plantar surface of the tal bounded anteriorly by a deep depression which is continued back medialwards in the form of a groove, the *sulcus calcanei*; in the a foot this sulcus lies below the sulcus tali, and the two sulci form a t sinus tarsi, already referred to (p. 338). In front and medial to th is an elongated facet, concave from behind forwards, and with diameter directed forwards and lateralwards. This facet is frequently into two parts: of these, the posterior and larger is termed the *middle surface*; it is supported on a projecting process of bone, the *sustenac* and articulates with the middle calcaneal facet on the plantar surfa talus; the anterior and lesser, termed the *anterior articular surface*, on the front part of the body, and articulates with the anterior calcan on the plantar surface of the talus. The dorsal surface, anterior and to the facets, is rough for the attachment of ligaments and for the the Extensor digitorum brevis.

FIG. 447.—The left calcaneus. Lateral aspect.

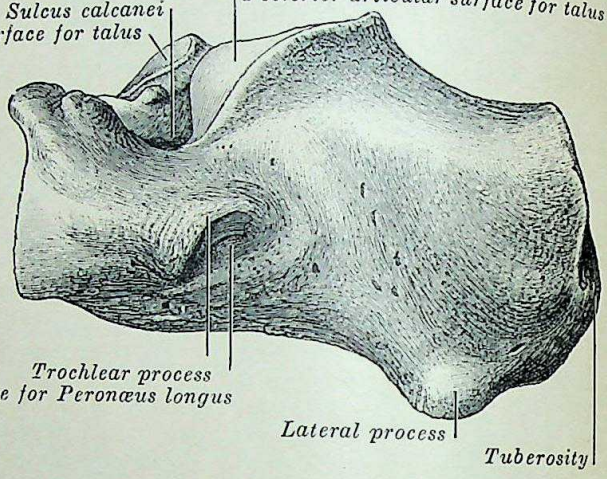

The *plantar surface* (fig. 446) is uneven, wider behind than in fro convex from side to side; it is bounded posteriorly by the lower part calcaneal tuberosity, which presents a medial and a lateral process; the *process*, small, prominent, and rounded, gives origin to part of the Ab digiti quinti; the *medial process*, broader and larger, gives attachme its prominent medial margin, to the Abductor hallucis, and in front plantar aponeurosis and the Flexor digitorum brevis; from the dep between the processes a part of the Abductor digiti quinti takes origin rough surface in front of the processes gives attachment to the long p ligament and the lateral head of the Quadratus plantæ; to a prominent tu near the anterior part of this surface and to a transverse groove in front tubercle, the plantar calcaneocuboid ligament is attached.

The *lateral surface* (fig. 447) is broad behind, and narrow in front, fl almost subcutaneous; near its centre is a small tubercle, for the attac of the calcaneofibular ligament. Below and in front of this tubercle is a the *trochlear process* (peronæal tubercle), which is often indistinctly m It gives attachment to the inferior peronæal retinaculum, and separates grooves; the superior groove transmits the tendon of the Peronæus lo the inferior, that of the Peronæus longus.

The *medial surface* (fig. 448) is directed obliquely downwards and for and is deeply concave; above the anterior part of the concavity is a sh projection, the *sustentaculum tali*. The dorsal surface of the sustentaculu is concave, and articulates with the middle calcaneal articular surface talus; its plantar surface is grooved for the tendon of the Flexor h

CC-0. In Public Domain. Gurukul Kangri Collection, Haridwar

Digitized by Arya Samaj Foundation Chennai and eGangotri

is; the narrow, medial surface is overlaid by the tendon of the Flexor orum longus, and is grooved near its upper margin for the attachment part of the deltoid ligament of the ankle-joint. The anterior margin of the ntaculum tali gives attachment to the plantar calcaneonavicular ligament. he *anterior extremity* or articular surface for the cuboid bone is of a somewhat gular form. It is concave from above downwards and lateralwards, and ex in a direction at right angles to this. Its medial border gives attachment e plantar calcaneonavicular ligament.

FIG. 448.—The left calcaneus. Medial aspect.

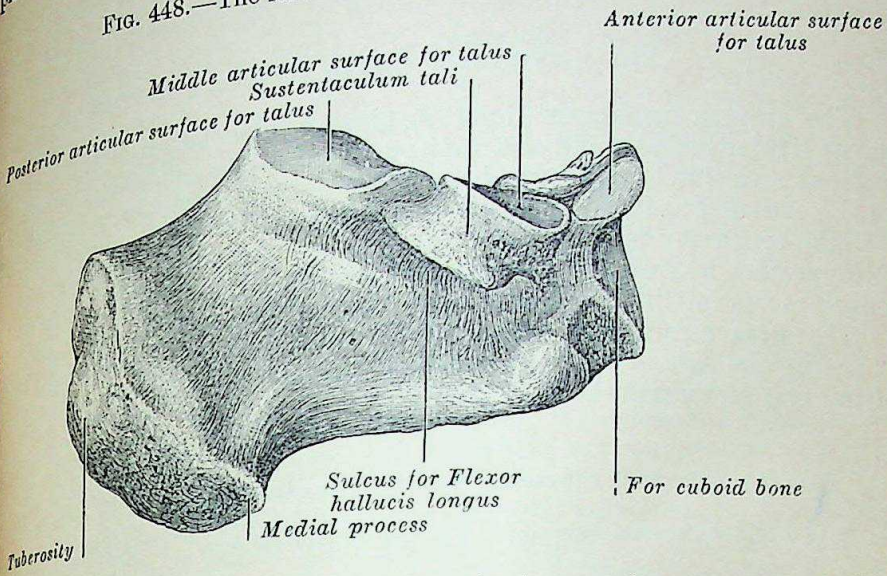

The *posterior extremity* or *calcaneal tuberosity* is prominent, convex, wider n than above, and divisible into three areas. The lowest of these areas is h, and covered by the fatty and fibrous tissue of the heel; the middle, rough, gives insertion to the tendo calcaneus and Plantaris; while the est is smooth, and is covered by a bursa which intervenes between this part e tuberosity and the tendo calcaneus. The plantar surface of this tuberosity ays the medial and lateral processes already described (p. 340).

THE NAVICULAR BONE (OS NAVICULARE PEDIS)

The navicular bone (fig. 449) is situated at the medial side of the tarsus, en the talus behind and the cuneiform bones in front.

The *anterior surface* is convex from side to side, and subdivided by two s into three facets, for articulation with the three cuneiform bones. The

FIG. 449.—The left navicular bone. A. Anterior aspect. B. Posterior aspect.

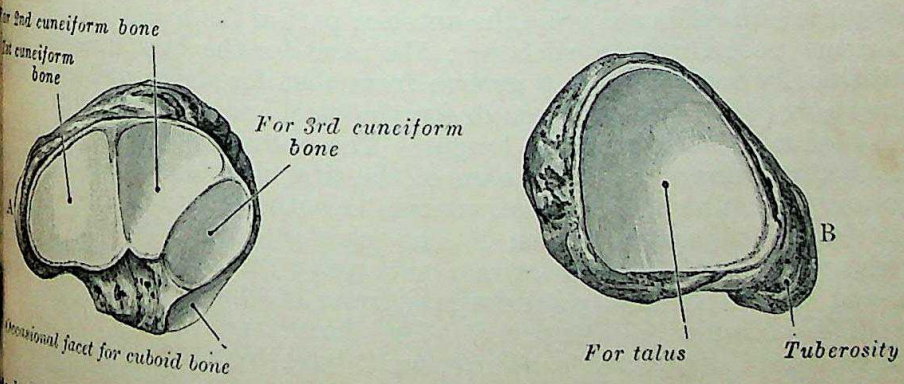

erior surface, oval and concave, articulates with the anterior surface of the d of the talus. The *dorsal surface* is convex from side to side, and rough

CC-0. In Public Domain. Gurukul Kangri Collection, Haridwar

Digitized by Arya Samaj Foundation Chennai and eGangotri

for the attachment of ligaments. The *plantar surface*, irregularly displays on its lateral part a downward projection of varying size, the *process*, to which a portion of the plantar calcaneonavicular ligament is The *medial surface* consists of a rounded *tuberosity*, the lower part gives insertion to a large part of the tendon of the Tibialis posterior. the tuberosity and the plantar process is a groove for the lodgment of the tendon of the Tibialis posterior. The *lateral surface* is rough and for the attachment of ligaments, and frequently presents a facet for ar with the cuboid bone.

The Cuneiform Bones (Ossa Cuneiformia)

The **cuneiform bones** (fig. 439), three wedge-shaped bones, artic the navicular bone behind and with the first, second, and third metatar in front; the first cuneiform bone is the largest, and the second the In the articulated foot the posterior surfaces of the three cuneiform be a slight concavity for the navicular, but the anterior portions of the third project in front of the anterior surface of the second, and form a deep recess in which the base of the second metatarsal bone is lodged.

The **first cuneiform bone** (os cuneiforme primum) (fig. 450) is at the medial side of the foot, between the navicular bone behind and of the first metatarsal bone in front.

Fig. 450.—The first left cuneiform bone. A. Medial aspect. B. Lateral as

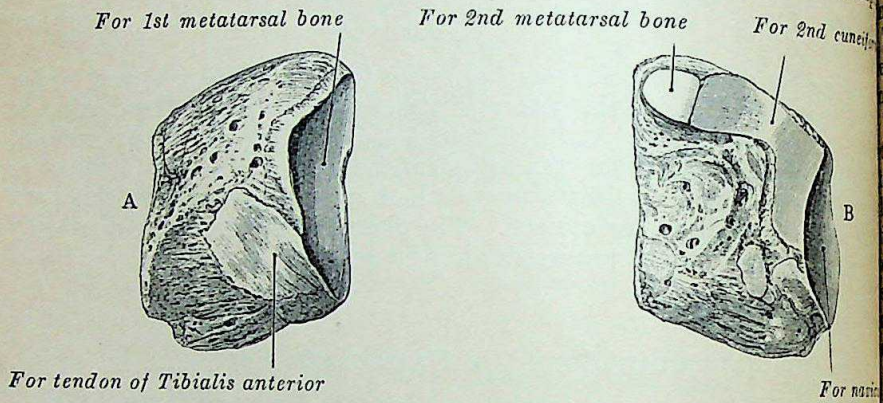

The *medial surface* is subcutaneous, broad and quadrilateral; at its plantar angle is a smooth oval impression, into which a part of the ten the Tibialis anterior is inserted. The *lateral surface* is concave; al superior and posterior borders is a narrow L-shaped articular surface, the limb and posterior part of the horizontal limb of which articulate w second cuneiform bone, while the anterior part of the horizontal limb art with the second metatarsal bone; the facet for the second metatarsal occasionally separated by a groove from that for the second cuneiform The rest of this surface is rough for the attachment of ligaments and the tendon of the Peronæus longus. The *anterior surface*, large and shaped, articulates with the base of the first metatarsal bone. The *surface*, triangular and concave, articulates with the medial facet on the surface of the navicular bone. The *plantar surface* forms the base wedge; at its posterior part is a tuberosity for the insertion of part tendon of the Tibialis posterior; in front of this a part of the ten the Tibialis anterior is inserted. The *dorsal surface* is the thin end wedge, and is directed upwards and lateralwards; it is rough f attachment of ligaments.

The **second cuneiform bone** (os cuneiforme secundum) (fig. 451), regular wedge-like form, is situated between the first and third cu bones.

CC-0. In Public Domain. Gurukul Kangri Collection, Haridwar

Digitized by Arya Samaj Foundation Chennai and eGangotri

The *anterior surface*, triangular in form, articulates with the base of the and metatarsal bone. The *posterior surface*, also triangular, articulates the intermediate facet on the anterior surface of the navicular bone. the *medial surface* is an L-shaped facet, running along the superior and erior borders, for articulation with the first cuneiform bone; the rest the surface is rough for the attachment of ligaments. The *lateral surface* ents posteriorly a vertical facet for articulation with the third cuneiform The *dorsal surface* or base of the wedge is quadrilateral and rough

FIG. 451.—The second left cuneiform bone.

A. Anteromedial aspect. B. Posterolateral aspect.

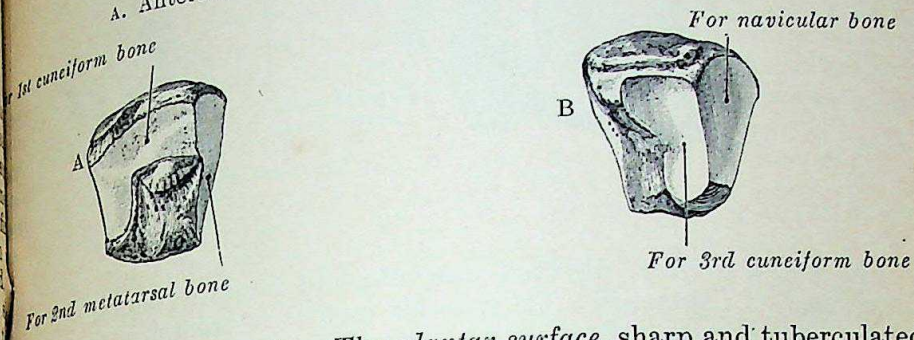

the attachment of ligaments. The *plantar surface*, sharp and tuberculated, also rough for the attachment of ligaments, and for the insertion of a slip the tendon of the Tibialis posterior.

The third **cuneiform bone** (os cuneiforme tertium) (fig. 452) has its base ted upwards; it is placed between the second cuneiform and cuboid es.

The *anterior surface*, triangular in form, articulates with the base of the third tarsal bone. The *posterior surface* articulates with the lateral facet on the erior surface of the navicular bone, and is rough below for the attachment ligamentous fibres. The *medial surface* presents an anterior and a posterior ular facet: the anterior, sometimes divided into two, articulates with the eral side of the base of the second metatarsal bone; the posterior skirts the erior border, and articulates with the second cuneiform bone; the inter- ing rough area gives attachment to an interosseous ligament. The *lateral* ce also presents two articular facets; the anterior one, situated at the

FIG. 452.—The third left cuneiform bone. A. Anterolateral aspect. B. Posteromedial aspect.

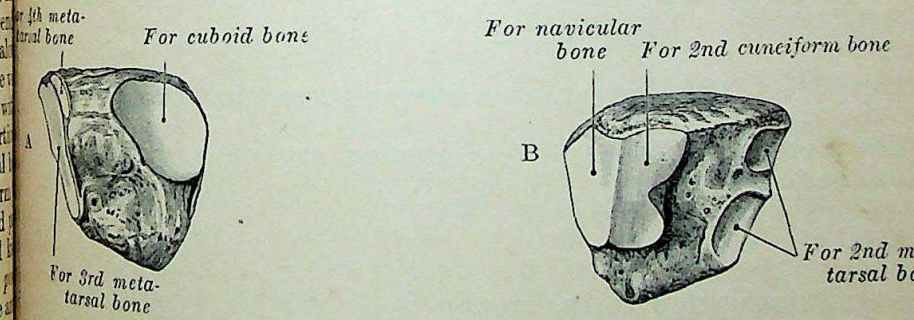

erior angle of the bone, is small and semi-oval in shape, and articulates with medial side of the base of the fourth metatarsal bone; the posterior and er one is triangular or oval, and articulates with the cuboid bone; the rvening, rough, non-articular area serves for the attachment of an inter- eous ligament. The *dorsal surface* or base of the wedge is of an oblong ro, its posterolateral angle being prolonged backwards. The *plantar surface* narrow and rounded, and serves for the attachment of ligaments and parts the tendons of the Tibialis posterior and Flexor hallucis brevis.

CC-0. In Public Domain. Gurukul Kangri Collection, Haridwar

Digitized by Arya Samaj Foundation Chennai and eGangotri

The Cuboid Bone (Os Cuboideum)

The **cuboid bone** (fig. 453) is placed on the lateral side of the foot of the calcaneus, and behind the fourth and fifth metatarsal bones.

Fig. 453.—The left cuboid bone. A. Anteromedial aspect. B. Posterolateral

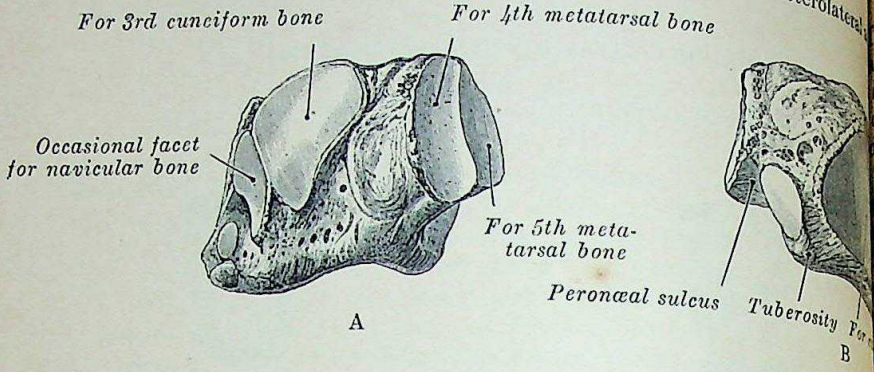

The *dorsal surface*, directed upwards and lateralwards, is rough attachment of ligaments. The *plantar surface* is crossed in front by groove, the *peronæal sulcus*, which runs obliquely forwards and medi it lodges the tendon of the Peronæus longus, and is bounded behind prominent ridge, to which the long plantar ligament is attached. T ends laterally in the *tuberosity*, the lateral part of which carries an oval on this facet the sesamoid bone or cartilage which is frequently found tendon of the Peronæus longus glides. Behind the peronæal sulcus th is rough, for the attachment of the plantar calcaneocuboid ligament, a few of the Flexor hallucis brevis, and a fasciculus from the tendon of the posterior. On the *lateral surface* is a deep notch which marks the com ment of the peronæal sulcus. The *posterior surface* is smooth, triangul concavoconvex, for articulation with the anterior surface of the calcaneu plantar, medial angle projects backwards as a process which underl supports the anterior end of the calcaneus. The *anterior surface* is divi a vertical ridge into two facets ; the medial, quadrilateral in form, arti with the fourth metatarsal bone ; the lateral, triangular, with the fifth *medial surface* is irregularly quadrilateral, and at its middle and dors is a smooth oval facet, for articulation with the third cuneiform bone; this a small facet for articulation with the navicular bone is frequently pr the rest of this surface is rough for the attachment of interosseous ligame

The Metatarsal Bones (Ossa Metatarsi)

The **metatarsal bones**, five in number, are enumerated from the side of the foot.

The Common Characteristics of the Metatarsal Bones

Each metatarsal bone has a body, a base or proximal end, and a h distal end.

The **body** of each bone is prismoid in form ; it tapers gradually from th to the head, and is slightly convex longitudinally on its dorsal surface.

The **base** articulates with the tarsus, and with the contiguous meta bones.

The **head** articulates with the proximal phalanx by a convex arti surface which extends farther backwards on the plantar than on the d surface ; the plantar extension ends on either side on the summit of a s

CC-0. In Public Domain. Gurukul Kangri Collection, Haridwar

Digitized by Arya Samaj Foundation Chennai and eGangotri

ular eminence. The sides of the head are flattened and on each is a ession surmounted by a tubercle for the attachment of one of the collateral ments of the metatarsophalangeal joint.

The Characteristics of the Individual Metatarsal Bones

The first metatarsal bone (fig. 454) is the shortest and thickest of the tarsal bones. The *body* is strong, and of well-marked prismoid form. *base* has, as a rule, no articular facets on its sides, but there is occasionally on the lateral side for articulation with the second metatarsal bone. Its nal articular surface, of large size and kidney-shaped, articulates with the cuneiform bone; its circumference is grooved, for the tarsometatarsal ents, and medially gives insertion to a part of the tendon of the Tibialis tor; its plantar angle presents a rough, oval prominence for the insertion e tendon of the Peronæus longus. The *head* is large; on its plantar ce is a median elevation separating two grooved facets on which sesamoid s glide.

54.—The first left metatarsal bone.

Fig. 455.—The second left metatarsal bone.

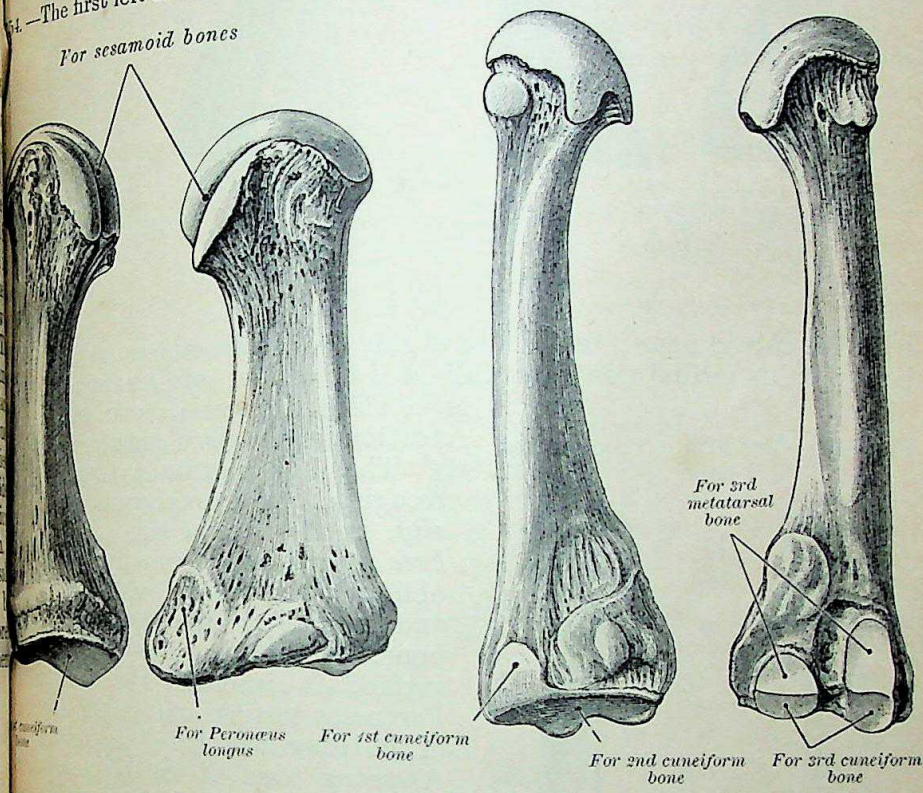

The second metatarsal bone (fig. 455) is the longest of the metatarsal s. On its wedge-shaped *base* are four articular facets: one on its proximal ce, of a triangular form, for articulation with the second cuneiform bone; at the upper part of its medial surface, for articulation with the first iform bone; and two on its lateral surface, an upper and lower, separated rough non-articular interval. Each of these lateral articular surfaces is ded by a vertical ridge; the two anterior facets articulate with the third tarsal bone; the two posterior (sometimes continuous) with the third iform bone. A fifth facet is occasionally present for articulation with the metatarsal bone; it is oval in shape, and is situated on the medial side e base, distal to the facet for the first cuneiform bone.

The third metatarsal bone (fig. 456) has a triangular *base* which articu- proximally with the third cuneiform bone; medially it articulates by two s with the second metatarsal bone; and laterally, by a single facet situated e dorsal angle, with the fourth metatarsal bone.

CC-0. In Public Domain. Gurukul Kangri Collection, Haridwar

Digitized by Arya Samaj Foundation Chennai and eGangotri

The **fourth metatarsal bone** (fig. 457) is smaller than the third proximal surface of its *base* is an oblique quadrilateral facet for an

Fig. 456.—The third left metatarsal bone.

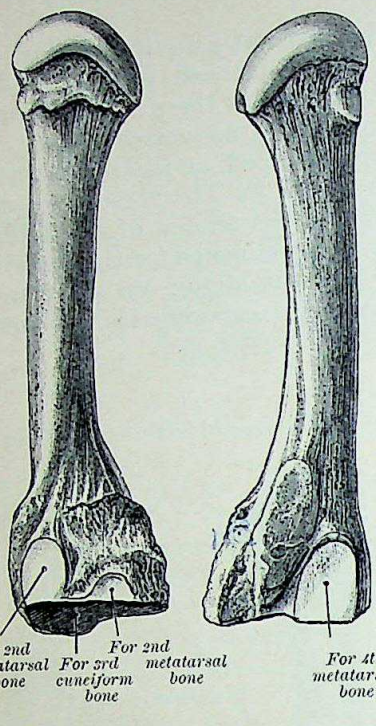

Fig. 457.—The fourth left meta

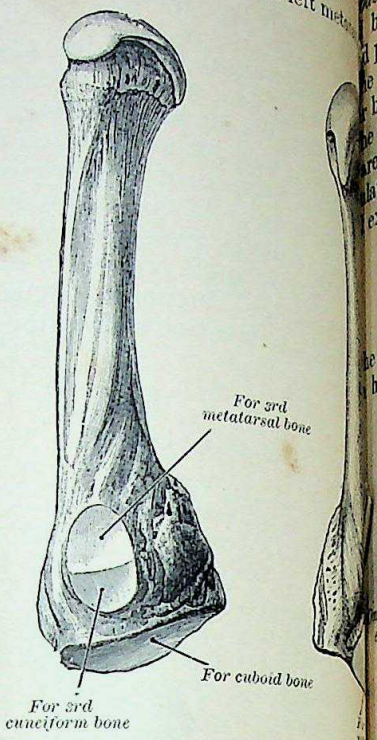

with the cuboid bone; on its lateral side a single facet, for the fifth me bone; on its medial side a facet divided by a ridge into an anterior po the third metatarsal bone, and a p portion for the third cuneiform bone.

Fig. 458.—The fifth left metatarsal bone.

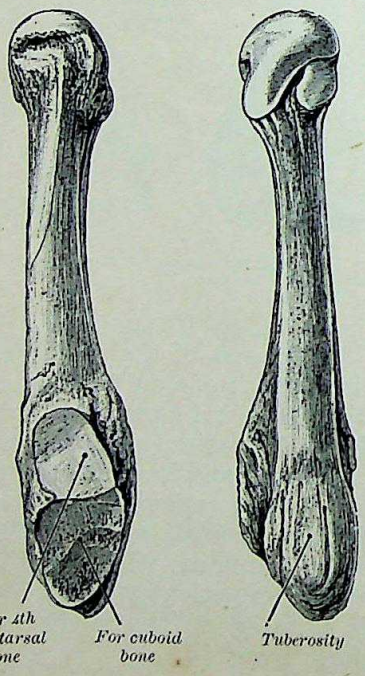

The **fifth metatarsal bone** (fig recognised by a rough eminence, th *sity*, on the lateral side of its base *base* articulates proximally, by a tri obliquely cut surface, with the cuboi and medially, with the fourth me bone. On the medial part of its surface is inserted the tendon Peronæus tertius, and on the dorsal of the tuberosity that of the Peronæus A strong band of the plantar apo connects the projecting part of the tu with the lateral process of the tube the calcaneus. The plantar surface base is grooved for the tendon of the tor digiti quinti, and gives origin Flexor digiti quinti brevis.

The Phalanges of the Foot (Phal Digitorum Pedis)

The **phalanges** of the foot co in number and general arrangeme those of the hand; there are two in the great toe, and three in each of th toes. They are, however, much smaller, and their bodies, especially the bones of the first row, are compressed from side to side.

CC-0. In Public Domain. Gurukul Kangri Collection, Haridwar

Digitized by Arya Samaj Foundation Chennai and eGangotri

he phalanges of the **first row** closely resemble those of the hand. The of each is compressed from side to side, convex above, concave below. ase is concave for articulation with the head of the corresponding meta- bone, and on the *head* is a trochlear surface for articulation with the phalanx.

he phalanges of the **second row** are remarkably small and short, but broader than those of the first row.

he **ungual phalanges** resemble those of the fingers; but they are smaller, re flattened from above downwards; each presents a broad base for lation with the corresponding bone of the second row, and an expanded extremity for the support of the nail and the end of the toe.

Ossification of the Bones of the Foot (fig. 459)

he **tarsal bones** are each ossified from a single centre, excepting the calcaneus has an epiphysis for its tuberosity. The centres make their appearance as

Fig. 459.—A plan of the ossification of the bones of the foot.

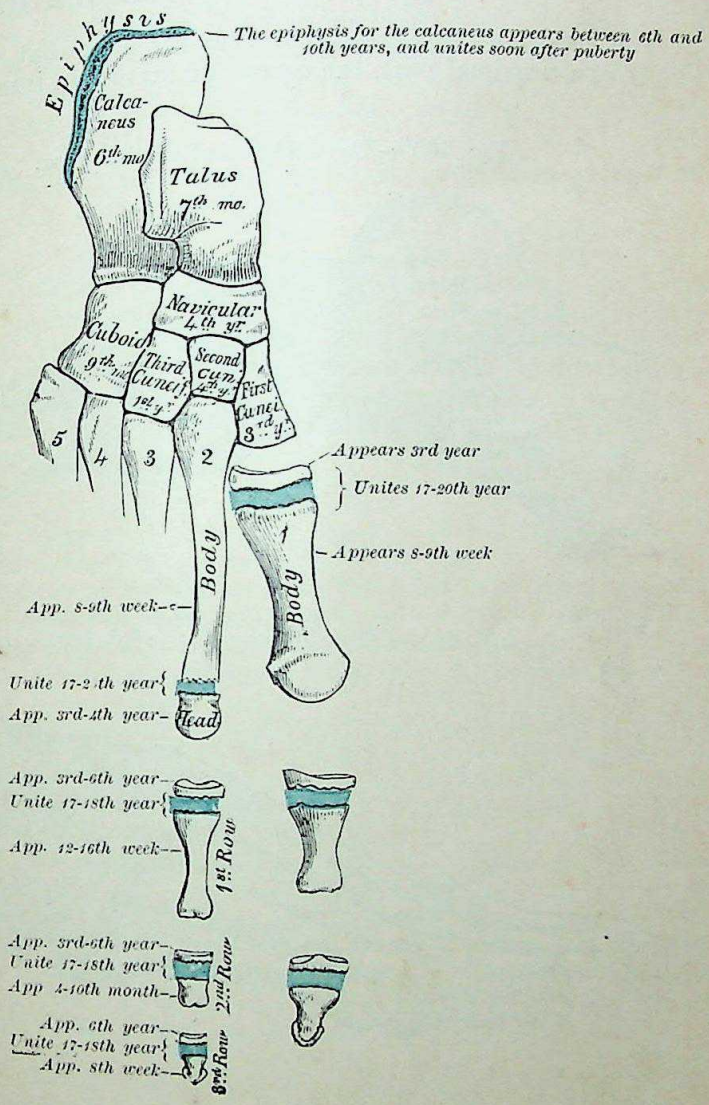

s: in the calcaneus, at the sixth month of fœtal life; in the talus, about the h month; in the cuboid, at the ninth month; in the third cuneiform, during st year; in the first cuneiform, during the third year; in the second cuneiform navicular, during the fourth year. The epiphysis for the tuberosity of the neus begins to ossify between the sixth and tenth years, and unites with the of the bone soon after puberty. The lateral tubercle of the posterior process

CC-0. In Public Domain. Gurukul Kangri Collection, Haridwar

Digitized by Arya Samaj Foundation Chennai and eGangotri

of the talus is sometimes ossified from an independent centre, and ma separate from the rest of the bone, when it is named the *os trigonum*.

The **metatarsal bones** are each ossified from two centres: a primary for the body, and a secondary or epiphysial centre for the base or proximal e first, and for the head or distal end of each of the other four.* Ossifica in the middle of the body about the eighth or ninth week of fœtal life. The for the base of the first metatarsal appears about the third year; those heads of the other metatarsals between the third and fourth years; all the bodies between the seventeenth and twentieth years. An epiphy quently present on the tuberosity of the base of the fifth metatarsal bone (fi

The **phalanges** are each ossified from two centres: a primary one for and an epiphysis for the base. The primary centres for the ungual appear about the eighth week of fœtal life; those for the first phalanges the twelfth and sixteenth weeks, and those for the second phalanges sixteenth week (that for the second phalanx of the fifth toe does not usua until after birth). The epiphysial centres appear between the third years, and unite with the bodies about the seventeenth or eighteenth year

Comparison of the Bones of the Hand and Foot

The hand and foot are constructed on somewhat similar principles, sisting of a proximal part, the carpus or tarsus, an intermediate portion,

Fig. 460.—The skeleton of the left foot. Medial aspect.

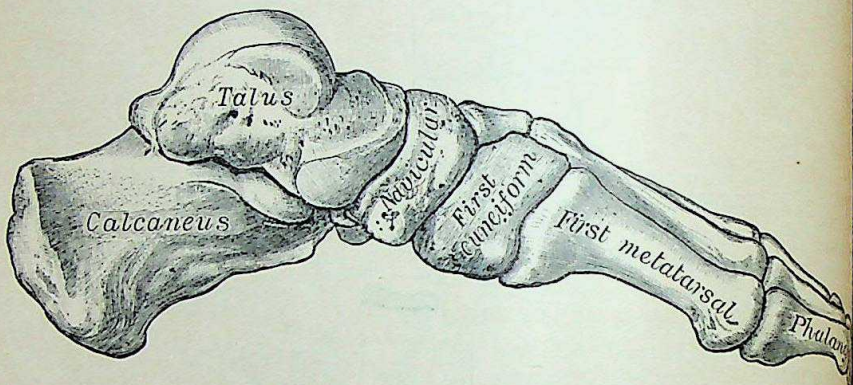

Fig. 461.—The skeleton of the left foot. Lateral aspect.

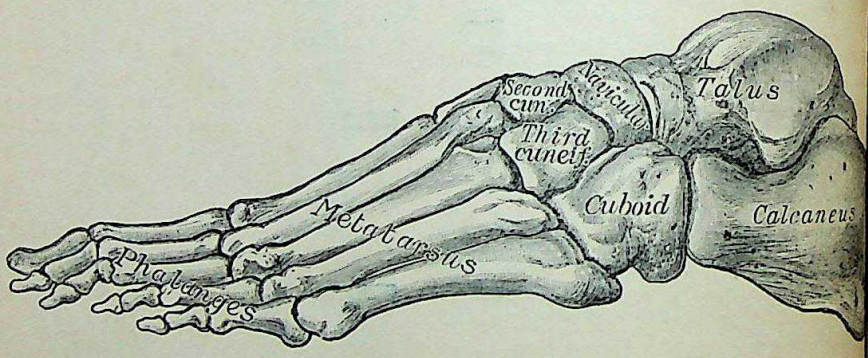

carpus or metatarsus, and a distal portion, the phalanges. The proxi consists of a series of more or less cubical bones which allow a slight a gliding on one another and are chiefly concerned in distributing forces tra to or from the bones of the arm or leg. The intermediate part is made up o

* As in the first metacarpal bone (see footnote, page 306), so in the first metatarsal often a second epiphysis for the head.

† C. Thurstan Holland, *Journal of Anatomy*, vol. lv., 1921.

CC-0. In Public Domain. Gurukul Kangri Collection, Haridwar

Digitized by Arya Samaj Foundation Chennai and eGangotri

ble long bones which assist the carpus or tarsus in distributing forces and give greater breadth for the reception of such forces. The separation of the dual bones from one another allows of the attachments of the interosseous les and protects the dorsipalmar and dorsiplantar vascular anastomoses. distal portion is the most movable, and its separate elements enjoy a varied of movements, the chief of which are flexion and extension.

The functions of the hand and foot are, however, very different, and the general arity between them is greatly modified to meet these requirements. Thus the forms a firm basis of support for the body in the erect posture, and is therefore solidly built, and its component parts are less movable on each other than of the hand. In the case of the phalanges the difference is readily noticeable; of the foot are smaller and their movements more limited than those of the

Very much more marked is the difference between the metacarpal bone of umb and the metatarsal bone of the great toe. The metacarpal bone of the b is constructed to permit of great mobility; it is directed at an acute angle that of the index finger, and is capable of a considerable range of movement articulation with the carpus. The metatarsal bone of the great toe assists in orting the weight of the body, is constructed with great solidity, lies parallel the other metatarsals, and has a very limited degree of mobility. The carpus ll in proportion to the rest of the hand, is placed in line with the forearm, and a transverse arch, the concavity of which constitutes a bed for the flexor s. The tarsus forms a considerable part of the foot, and is placed at right s to the leg, a position which is almost peculiar to man, and has relation to his posture. In order to allow of their supporting the weight of the body with least expenditure of material the tarsus and metatarsus are constructed in es of arches (figs. 460, 461), the disposition of which will be considered the articulations of the foot have been described.

plied Anatomy.—Considering the injuries to which the foot is subjected, it is sur- g how seldom the tarsal bones are fractured. This is no doubt due to the fact that rsus is composed of a number of bones, articulated by a considerable extent of e, and joined together by very strong ligaments which serve to break the force of ce applied to this part of the body. When fracture does occur, these bones being sed for the most part of a soft cancellous structure, covered only by a thin shell of act tissue, are often extensively comminuted, especially as most of the fractures are ced by direct violence; and, as there is only a very scanty amount of soft parts over ces, the fractures are very often compound, and amputation is often necessary.

hen fracture occurs in the anterior group of tarsal bones, it is almost invariably the t of direct violence; but fractures of the posterior group—that is, of the calcaneus lus—are usually produced by falls from a height on to the feet.

club-foot (talipes), especially in congenital cases, the bones of the tarsus become d in shape and size, and displaced from their proper positions. This is principally e in congenital talipes equinovarus, in which the head of the talus becomes twisted ophied, and a similar condition may be present in the other bones, more especially vicular.

e tarsal bones are peculiarly liable to become the seat of tuberculous caries following atively trivial injuries. Caries of the calcaneus or talus may remain limited to e bone for a long period, but when one of the other bones is affected, the remainder ily become involved, since the disease spreads through the large and complicated al stratum which is more or less common to these bones.

mputation of the foot is often required either for injury or disease. The principal ations are as follows: (1) Syme's: amputation at the ankle-joint by a heel-flap, emoval of the malleoli and sometimes a thin slice from the lower end of the tibia. rgoff's: amputation of the whole of the tarsal bones (except the posterior part of lcaneus), and a thin slice from the tibia and fibula including the two malleoli. The surface of the calcaneus is then turned up and united to the cut surface of the tibia. bastragalar: amputation of the foot below the talus through the joint between it the calcaneus.

the bones of the tarsus occasionally require removal individually. This is especially ne with the talus for tuberculous disease limited to that bone; or the talus may e excision in cases of subastragalar dislocation, or in cases of inveterate talipes. boid has been removed for the same reason.

e metatarsal bones, and especially that of the great toe, are frequently diseased, in tuberculous subjects or in patients with perforating ulcer of the foot.

CC-0. In Public Domain. Gurukul Kangri Collection, Haridwar

Digitized by Arya Samaj Foundation Chennai and eGangotri

THE SESAMOID BONES *

The **sesamoid bones** are small more or less rounded masses of bone in certain tendons and usually related to joint-surfaces. Their probably are to modify pressure, to diminish friction, and occasionally the direction of the pull of a muscle. That they are not developed certain physical requirements in the adult is evidenced by the fact are present as cartilaginous nodules in the fœtus, and in greater than in the adult. They must be regarded as integral parts of the phylogenetically inherited.† Physical necessities probably come into selecting and in regulating the degree of development of the origi laginous nodules.

Sesamoid bones are invested by the fibrous tissue of the tendon on the surfaces in contact with the parts over which they glide, w present smooth articular facets.

In the upper extremity the sesamoid bones of the joints are fo on the palmar surface of the hand. Two, of which the medial is th are present at the metacarpophalangeal joint of the thumb; one is fo present in the corresponding joint of the index finger, and one (or the same joint of the little finger. Sesamoid bones are found occasi the metacarpophalangeal joints of the middle and ring fingers, at t phalangeal joint of the thumb, and at the distal interphalangeal joi index finger.

In the lower extremity the largest sesamoid bone of the joints is th developed in the tendon of the Quadriceps femoris. On the plant of the foot, two, of which the medial is the larger, are always prese metatarsophalangeal joint of the great toe; one sometimes at th tarsophalangeal joints of the second and fifth toes, one occasionall corresponding joints of the third and fourth toes, and one at the interp joint of the great toe.

Sesamoid bones apart from joints are seldom found in the tendo upper limb; one is sometimes seen in the tendon of the Biceps brachi the radial tuberosity. They are, however, present in several of the of the lower limb—viz. one in the tendon of the Peronæus longus, glides on the cuboid bone; one, appearing late in life, in the tendon of th anterior, opposite the smooth facet of the first cuneiform bone; o tendon of the Tibialis posterior, opposite the medial side of the hea talus; one in the lateral head of the Gastrocnemius, behind the latera of the femur; and one in the tendon of the Psoas major, where it gli the os pubis. Sesamoid bones are found occasionally in the tendo wind round the medial and lateral malleoli, and one is sometimes p the tendon of the Glutæus maximus where it passes over the greater tro of the femur.

* Consult an article by A. H. Bizarro, *Journal of Anatomy*, vol. lv., 1921.
† Thilenius, *Morpholog. Arbeiten*, v., 1896.

CC-0. In Public Domain. Gurukul Kangri Collection, Haridwar

Digitized by Arya Samaj Foundation Chennai and eGangotri

SYNDESMOLOGY

bones of the skeleton are connected to one another at different parts their surfaces, and such connexions are termed *joints* or *articulations*. the joints are *immovable*, as in the articulations of the cranium, the ed margins of the bones are nearly in contact, being separated merely thin layer of fibrous membrane, named the *sutural ligament*; in certain ns at the base of the skull this fibrous membrane is replaced by a layer rtilage. Where *slight movement* combined with great strength is required, pposed osseous surfaces are united by tough and elastic *fibrocartilages*, as e joints between the vertebral bodies, and in the interpubic articulation. e *freely movable* joints the opposed surfaces are completely separated one another; the parts of the bones forming the articulations are expanded reater convenience of mutual connexion, and are covered with *hyaline lar cartilage*, while the joints are enveloped by *articular capsules*, and are lly strengthened by strong fibrous bands called *ligaments*.

In long bones the ends are the parts which form the articulations; they omewhat enlarged, and consist of spongy substance with a thin coating mpact substance. In the flat bones the articulations usually take place e edges, and in the short bones at various parts of their surfaces. The of compact bone which forms the joint surface, and to which the articular lage is attached, is called the *articular lamella*; its lacunæ are large, but ntains no Haversian canals or canaliculi. The vessels of the spongy nce approach the articular lamella but do not perforate it; this lamella equently denser and firmer than ordinary bone.

The **articular cartilage** which covers the articular surfaces of bones, the **fibrocartilage** which enters into the structure of some of the joints, described in the section on Histology (pp. 14 to 17).

The **ligaments** are composed mainly of parallel or closely interlaced bundles *hite fibrous tissue*, and present a silvery appearance. They are pliant flexible, so as to allow perfect freedom of movement, but strong, tough, and tensible, so as not to yield readily to applied force. Some ligaments consist ly of *yellow elastic tissue*, as the ligamenta flava which connect together laminæ of adjacent vertebræ, and the ligamentum nuchæ in the lower nals. In these cases the elasticity of the ligament is intended to act as stitute for muscular power.

The **articular capsules** form complete envelopes for the freely movable s. Each capsule consists of two strata—an external (stratum fibrosum) posed of white fibrous tissue, and an internal (stratum synoviale) which metimes described separately as the synovial membrane of the joint.

The *stratum fibrosum* is attached to the circumferences of the articular of the bones entering into the joint, and thus entirely surrounds the ulation.

The *stratum synoviale* invests the inner surface of the stratum fibrosum, ollected over any tendons passing through the joint cavity, and ceases the margins of the articular cartilages. It is composed of a thin, delicate,

CC-0. In Public Domain. Gurukul Kangri Collection, Haridwar

Digitized by Arya Samaj Foundation Chennai and eGangotri

connective tissue, and is covered on its free surface with a layer of end
In some joints it is thrown into folds which pass across the cavity
knee-joint; in others there are flattened folds, subdivided at their
into fringe-like processes which contain convoluted vessels. Th
generally project near the margin of the cartilage, and lie flat upon
The endothelium of the stratum synoviale secretes a small quantity
lubricating fluid, termed *synovia*.

Closely related in structure and function to the synovial stratu
articular capsule, and therefore conveniently described in this sec
the vaginæ mucosæ of tendons and the bursæ mucosæ.

Vaginæ mucosæ (mucous sheaths) serve to facilitate the gliding of
in fibro-osseous canals, e.g. the tendons of the flexor and extensor
of the fingers and toes as they pass through canals in or near the
foot. Each sheath has the form of an elongated closed sac which
wall of the canal, and is reflected upon the surface of the enclosed
tendons.

Bursæ mucosæ are interposed between surfaces which glide upon ea
They consist of closed sacs containing a minute quantity of clear vis
and may be grouped, according to their situations, under the head
cutaneous, *submuscular*, *subfascial*, and *subtendinous*.

A CLASSIFICATION OF THE JOINTS

Joints are divided into three classes: *synarthroses* or immovable
arthroses or slightly movable, and *diarthroses* or freely movable joints.

1. Synarthroses. (Immovable Articulations)

Synarthroses are articulations in which the surfaces of the b
fastened together by intervening connective tissue or hyaline cartil
in which there is no appreciable motion, as in the joints between the
the cranium. There are three varieties of synarthrosis: sutura, go
and synchondrosis.

Sutura is an articulation met with only in the skull, where the
of the bones articulate with one another (fig. 462). The margins of th
are not in direct contact, being separated by a thin layer of fibrous
continuous externally with the pericranium, internally with the dura m

Fig. 462.—A section through the sagittal suture.

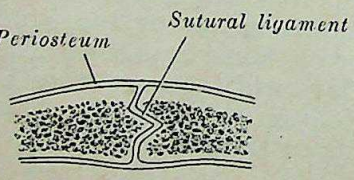

Fig. 463.—A section through the sphenoidal synchondrosis of an

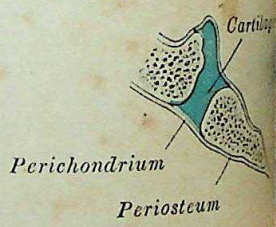

When the bony margins are connected by a series of interlocking
like processes, the articulation is named *sutura serrata*, as in the
suture. When the articulation is formed by one bone overlapping
as in the suture between the temporal and parietal bones, it is termed
squamosa; where there is simple apposition of contiguous rough surf
between the palatine processes of the maxillæ, or between the horizont
of the palatine bones, it is named *sutura palatina*.

CC-0. In Public Domain. Gurukul Kangri Collection, Haridwar

Digitized by Arya Samaj Foundation Chennai and eGangotri

Gomphosis is articulation by the insertion of a conical process into a socket; seen in the articulations of the roots of the teeth with the alveoli of the dible and maxillæ.

Synchondrosis.—Where the connecting medium is cartilage the joint is d a synchondrosis (fig. 463); this is a temporary form of joint, for the lage is ultimately converted into bone. Such joints are found between epiphyses and bodies of long bones, between the occipital and sphenoidal s at and for some years after birth, and between the petrous portions of emporal bones and the jugular process of the occipital bone.

2. Amphiarthroses. (Slightly Movable Articulations)

In these articulations the contiguous bony surfaces are either united by an osseous ligament, as in the inferior tibiofibular articulation, or are covered articular cartilage and connected by broad flattened discs of fibrocartilage, more or less complex structure, as in the articulations between the bodies e vertebræ. The first form is termed a **syndesmosis**, the second a **physis** (fig. 464).

3. Diarthroses. (Freely Movable Articulations)

This class includes the majority of the joints. In a diarthrodial joint contiguous bony surfaces are covered with articular cartilage, and con- ed by an articular capsule and ligaments (fig. 465).

Fig. 464.—A section through a symphysis. Diagrammatic.

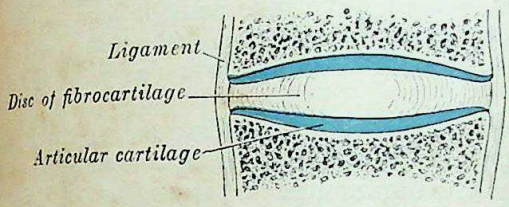

465.—A section through a simple rodial joint. Diagrammatic.

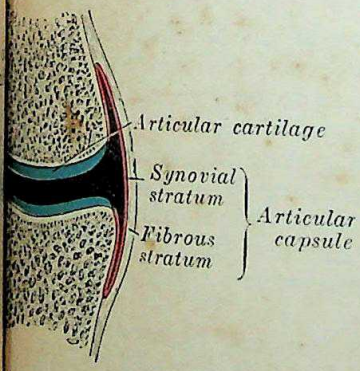

Fig. 466.—A section through a diarthrodial joint with an articular disc. Diagrammatic.

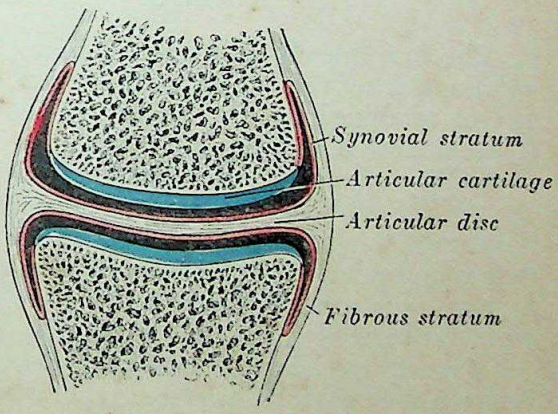

oint may be completely divided by an *articular disc* (fig. 466), or incom- by *menisci* (fig. 521); the periphery of such structures is continuous with ibrous stratum of the articular capsule while their free surfaces are covered the synovial stratum.

Diarthrodial joints are classified according to the kind of motion permitted them. There are two varieties in which the movement is uni-axial; that

CC-0. In Public Domain. Gurukul Kangri Collection, Haridwar

Digitized by Arya Samaj Foundation Chennai and eGangotri

is to say, all movements take place around one axis. In one, the or *hinge-joint*, this axis is, practically speaking, transverse; in the *articulatio trochoidea* or *pivot-joint*, it is longitudinal. There are two where the movement is bi-axial; these are the *articulatio ellipsoidea* or *joint* and the *articulatio sellaris* or *saddle-joint*. There is one form movement is poly-axial, the *articulatio sphæroidea* or *enarthrosis* (*ball-* *joint*); and finally there is the *arthrodia* or *gliding joint*.

Ginglymus or hinge-joint.—In this form the articular surfaces are to each other in such a manner as to permit motion only in one pla articular surfaces are connected together by strong collateral ligamen form their chief bond of union. The best examples of ginglymus interphalangeal joints, and the joint between the humerus and ulna.

Trochoid articulation or pivot-joint.—Where the movement is to rotation, the joint is formed by a pivot turning within a ring, or a ring on a pivot, the ring being formed partly of bone, partly of ligam the proximal radio-ulnar articulation, the ring is formed by the radi of the ulna and the annular ligament; here, the head of the radius within the ring. In the articulation of the dens of the epistropheus atlas, the ring is formed in front by the anterior arch, and behind transverse ligament, of the atlas; here, the ring rotates round the dens.

Condyloid articulation.—In this form of joint, an ovoid convex surface, or condyle, is received into an elliptical concavity in such a as to permit of flexion, extension, adduction, abduction, and circum but no axial rotation. The radiocarpal joint is an example of this articulation.

Saddle-articulation.—In this variety the opposing surfaces are cally concavoconvex, and the movements are the same as in the p form. The best example of the saddle-articulation is the carpom joint of the thumb.

Enarthrosis is a joint in which the distal bone is capable of motion an indefinite number of axes, which have one common centre. It is by the reception of a globular head into a cup-like cavity, hence th 'ball-and-socket.' Examples of this form of articulation are found hip- and shoulder-joints.

Arthrodia is a joint which admits of only gliding movement; it is by the apposition of plane, or nearly plane, surfaces, the amount of m such joints being limited by the ligaments or osseous processes sur the articulations. It is the form present in the joints between the processes of the vertebræ, and in most of the carpal and tarsal joints.

The Kinds of Movement permitted in Joints

The movements permitted in joints may be divided into four kinds: and angular movements, circumduction, and rotation. Frequently these or less combined in the various joints, so as to produce an infinite vari it is seldom that only one kind of motion is found in any particular joint.

Gliding movement is the simplest kind of motion that can take place in one surface gliding over another without any angular or rotatory movem is common to all movable joints; but in some, as in most of the articulation carpus and tarsus, it is the only motion permitted. This movement is not to plane surfaces, but may take place between any two contiguous surf whatever form.

Angular movement occurs only between the long bones, and by it th between the two bones is increased or diminished. It may take place: (1) f and backwards, constituting flexion and extension; or (2) towards and f median plane of the body, or, in the case of the fingers or toes, from the line of the hand or foot, constituting adduction and abduction. The ginglymoid or hinge-joints admit of flexion and extension only. Abduction adduction, combined with flexion and extension, are met with in the more joints.

Circumduction is that form of motion which takes place between the h bone and its articular cavity, when the bone is made to circumscribe a conical

CC-0. In Public Domain. Gurukul Kangri Collection, Haridwar

Digitized by Arya Samaj Foundation Chennai and eGangotri

base of the cone is described by the distal end of the bone, the apex is in the ular cavity; this kind of motion is best seen in the shoulder- and hip-joints.

Rotation is a form of movement in which a bone moves round a longitudinal : the axis of rotation may lie in a separate bone, as in the case of the pivot ed by the dens of the epistropheus around which the atlas turns; or a bone rotate around its own longitudinal axis, as in the rotation of the humerus he shoulder-joint; or the axis of rotation may not be quite parallel to the long of the bone, as in the movement of the radius on the ulna during pronation supination of the hand, where it is represented by a line connecting the centre he head of the radius with the centre of the head of the ulna.

Applied Anatomy.—W. W. Keen points out how important it is 'that the surgeon uld remember the ligamentous action of muscles in making passive motion—for ance, at the wrist after Colles's fracture. If the fingers be extended, the wrist can be d to a right angle. If, however, they be first flexed as in "making a fist," flexion he wrist is quickly limited to from forty to fifty degrees in different persons, and is painful beyond that point. Hence passive motion here should be made with the ers extended. In the leg, when flexing the hip, the knee should be flexed.'

THE MANDIBULAR JOINT

The bony parts entering into the formation of the mandibular (temporo-ndibular) joint are: above, the articular tubercle and the anterior portion the mandibular fossa of the temporal bone; below, the condyle of the ndible. An articular disc divides the joint into an upper and a lower cavity. ligaments of the joint are the following:

The articular capsule.	Sphenomandibular.
Temporomandibular.	Stylomandibular.

Fig. 467.—The left mandibular joint. Lateral aspect.

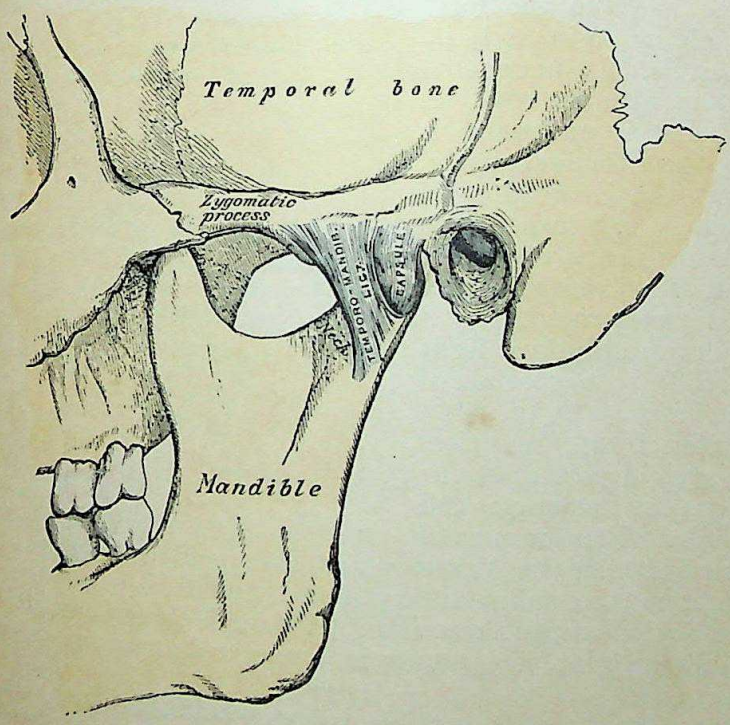

The articular capsule is a thin, loose envelope, attached, above, to the mference of the mandibular fossa and the articular tubercle; below, the neck of the mandible. The synovial stratum of the articular capsule ntinued over the upper and lower surfaces of the articular disc.

CC-0. In Public Domain. Gurukul Kangri Collection, Haridwar

Digitized by Arya Samaj Foundation Chennai and eGangotri

The **temporomandibular ligament** (external lateral ligament) consists of two short, narrow fasciculi, one in front of the other, attached to the lateral surface of the zygomatic process of the temporal bone and to the tubercle on its lower border; to the lateral surface and posterior border of the neck of the mandible. It is shorter above than below, and its fibres are directed obliquely downwards and backwards.

Fig. 468.—The left mandibular joint. Medial aspect.

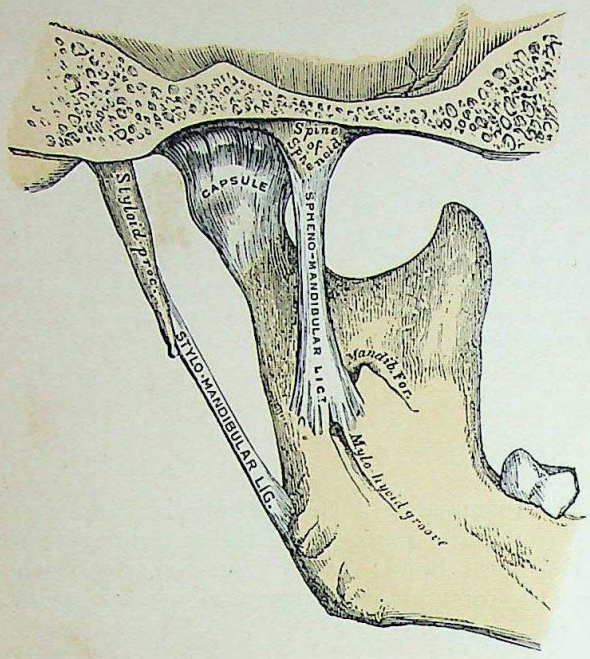

The **sphenomandibular ligament** (fig. 468) is a thin band which is attached above to the spina angularis of the sphenoidal bone, becoming broader as it descends, is fixed to the lingula of the mandibular foramen. Its lateral surface is in relation above, with the Pterygoideus externus; lower down it is separated from the neck of the condyle by the internal maxillary vessels; still lower the inferior alveolar artery and nerve and a lobule of parotid gland lie between it and the ramus of the mandible. Its medial surface is in relation with the Pterygoideus internus.

The **articular disc** (fig. 469) is a thin, oval plate, placed between the condyle of the mandible and the mandibular fossa; it divides the joint into two cavities. Its upper surface is concavoconvex from before backwards to accommodate itself to the form of the mandibular fossa and the articular tubercle. Its under surface, in contact with the condyle, is concave. Its circumference is connected to the articular capsule, and in front to the tendon of the Pterygoideus externus. It is thicker at its periphery, especially behind, than at its centre, where it is sometimes perforated.

Fig. 469.—A sagittal section through the mandibular joint.

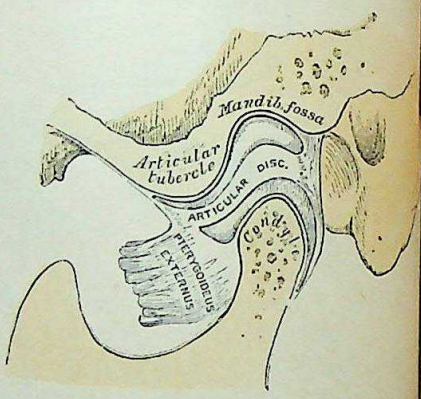

The **stylomandibular ligament** (fig. 468) is a specialised band of the fascia colli (p. 448), which stretches from the apical part of the styloid process of the temporal bone to the angle and posterior border of the ramus of the mandible between the Masseter and Pterygoideus internus. It separates the parotid from the submaxillary gland, and from its deep surface fibres of the Styloglossus take origin. Although classed among the ligaments of the mandibular joint, it can only be considered as accessory to it.

* J. Cameron (*Journal of Anatomy and Physiology*, vol. xlix.) points out that the crura of this ligament 'enters the inner extremity of the Glaserian fissure and whilst doing so is attached to the spine of the sphenoid by its inner edge.' He suggests that the attachment to the spina angularis of the sphenoidal bone is purely adventitious, and that the morphological attachment is in reality to the lips of the fissure and also within the tympanic cavity, where a considerable proportion of the fibres are directly continuous with the fibres of the membrana tympani. This intratympanic portion is usually described as the anterior ligament of the malleus. It forms a prominent band in a seven months' fœtus, and at this time appears to be independent of the sphenoidal bone.

CC-0. In Public Domain. Gurukul Kangri Collection, Haridwar

Digitized by Arya Samaj Foundation Chennai and eGangotri

The *nerves* of the mandibular joint are derived from the auriculotemporal and masseteric branches of the mandibular nerve, the *arteries* from the superficial temporal branch of the external carotid artery, and from the internal maxillary artery.

Movements.—The mandible may be depressed and elevated, or carried forwards and backwards; a slight amount of side-to-side movement is also permitted. When the mouth is opened the body of the mandible is depressed, and the condyles and articular discs are pulled forwards on to the articular tubercles; in shutting the mouth the reverse action takes place. When the mandible is carried horizontally forwards, as in protruding the lower incisor teeth in front of the upper, the discs and the condyles glide forwards on the mandibular fossæ and articular tubercles. The grinding or chewing movement is produced by one condyle, with its disc, gliding alternately forwards and backwards, while the other condyle moves simultaneously in the opposite directions; at the same time the condyle undergoes a vertical rotation on the disc. One condyle advances and rotates, while the other recedes and rotates.

Muscles producing the movements:

Depression.—Digastrici, Mylohyoidei, Geniohyoidei and Pterygoidei externi.
Elevation.—Masseteres, Temporales and Pterygoidei interni.
Protrusion.—Pterygoidei interni et externi (both sides).
Retraction.—Temporales (posterior fibres).
Lateral movement.—Pterygoidei interni et externi (one side).

Applied Anatomy.—The mandible can be dislocated only in one direction—viz. forwards. When the mouth is open, the condyle is situated on the articular tubercle, and any sudden violence, or even a sudden muscular spasm, as during a convulsive yawn, may displace the condyle forwards into the infratemporal fossa. The displacement may be unilateral or bilateral. Reduction is accomplished by depressing the jaw with the thumbs placed on the last molar teeth, and at the same time elevating the chin. The downward pressure overcomes the spasm of the Masseter, Temporalis, and Pterygoideus internus, and elevation of the chin throws the condyle backwards; the above-mentioned muscles then draw the condyle back into its normal position.

In close relation to the condyle of the mandible are the external acoustic meatus and the tympanic cavity; any force, therefore, applied to the bone is liable to be attended with damage to these parts, or inflammation in the joint may extend to them. On the other hand inflammation of the tympanic cavity may involve the articulation and cause obstruction, thus leading to ankylosis of the joint.

THE ARTICULATIONS OF THE VERTEBRAL COLUMN

The vertebræ from the third cervical to the first sacral inclusive are articulated to one another by: (1) a series of amphiarthrodial joints between the vertebral bodies; and (2) a series of diarthrodial joints between the vertebral arches.

I. The Articulations of the Vertebral Bodies

The amphiarthrodial articulations between the bodies of the vertebra allow only slight movement between adjoining bones, but when this slight movement takes place in a considerable length of the vertebral column, the total range of movement is great. The vertebral bodies are united by anterior and posterior longitudinal ligaments, and by intervertebral fibrocartilages.

The anterior longitudinal ligament (fig. 470) is a strong band of fibres, which extends along the anterior surfaces of the bodies of the vertebræ. It is broader below than above, thicker and narrower in the thoracic than in the cervical and lumbar regions, and somewhat thicker and narrower opposite the bodies of the vertebræ than opposite the intervertebral fibrocartilages. It is attached above, to the pharyngeal tubercle of the occipital bone, and since it extends to the anterior tubercle of the atlas, then to the front of the body of the epistropheus, and is continued down as far as the upper

CC-0. In Public Domain. Gurukul Kangri Collection, Haridwar

Digitized by Arya Samaj Foundation Chennai and eGangotri

part of the front of the sacrum. It consists of dense longitudinal fibre are intimately adherent to the intervertebral fibrocartilages and the pr margins of the vertebræ, but not to the middle parts of the vertebral bo the latter situation the ligament is thick and fills up the concavitie anterior surfaces, and makes the front of the vertebral column mo It is composed of several layers of fibres, of which the most superficial longest and extend between four or five vertebræ. The intermedia extend between two or three vertebræ, while the deepest reach from one to the next. At the sides of the bodies the ligament consists of a fe fibres which connect adjacent vertebræ.

The **posterior longitudinal ligament** (figs. 470, 471) is situated the vertebral canal on the posterior surfaces of the bodies of the v Above, it is attached to the body of the epistropheus, and is thence co

FIG. 470.—A median sagittal section through a portion of the lumbar region the vertebral column.

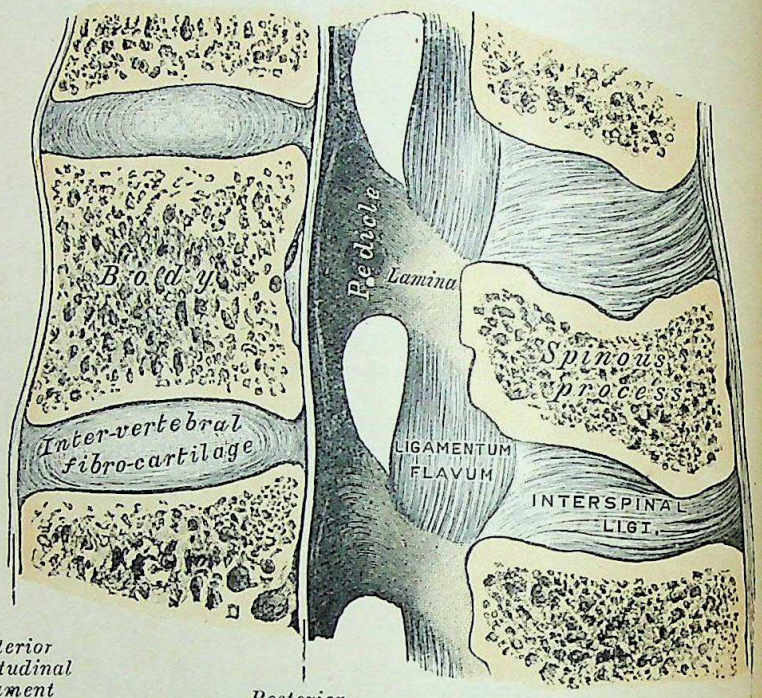

downwards to the sacrum; its upper end is intimately connected wi membrana tectoria which appears to be a continuation of it. It is b above than below, and thicker in the thoracic than in the cervical and l regions. In the situation of the intervertebral fibrocartilages and con margins of the vertebræ, where the ligament is more intimately adheren broad, and in the thoracic and lumbar regions presents a series of den with intervening concave margins; but it is narrow and thick over the c of the bodies, from which it is separated by the basivertebral veins. ligament is composed of smooth, shining fibres, denser and more co than those of the anterior ligament, and consists of superficial layers occ the interval between three or four vertebræ, and deeper layers which c between adjacent vertebræ.

The **intervertebral fibrocartilages** (figs. 470, 471) are interposed be the adjacent surfaces of the bodies of the vertebræ, from the epistro to the sacrum, and form the chief bonds of connexion between the vert Their shape corresponds with that of the bodies between which they are p Their thickness varies in different regions of the column, and in different of the same column; they are thicker in front than behind in the co

CC-0. In Public Domain. Gurukul Kangri Collection, Haridwar

Digitized by Arya Samaj Foundation Chennai and eGangotri

lumbar regions, and thus contribute to the anterior convexities of these s of the column; while they are of nearly uniform thickness in the thoracic on, the anterior concavity this part of the column almost entirely due to shape of the vertebral es. They are adherent, by surfaces, to thin layers of line cartilage which cover upper and under surfaces he bodies of the vertebræ; e lower cervical vertebræ, over, small joints with ular capsules are occa- ally present between the r surfaces of the bodies the margins of the fibro- lages on either side. The vertebral fibrocartilages closely connected to the or and posterior longi- al ligaments; in the acic region they are ed laterally, by means of interarticular ligaments, the heads of those ribs ch articulate with two ebræ. The interverte- fibrocartilages constitute ut one-fourth of the length he vertebral column, ex- ive of the first two verte- ; but this amount is not ally distributed between various bones, the cervical lumbar portions having, in proportion to their length, a much greater ont than the thoracic region, with the result that these parts possess ter pliancy and freedom of movement.

Fig. 471.—The posterior longitudinal ligament of the vertebræ, in the lumbar region.

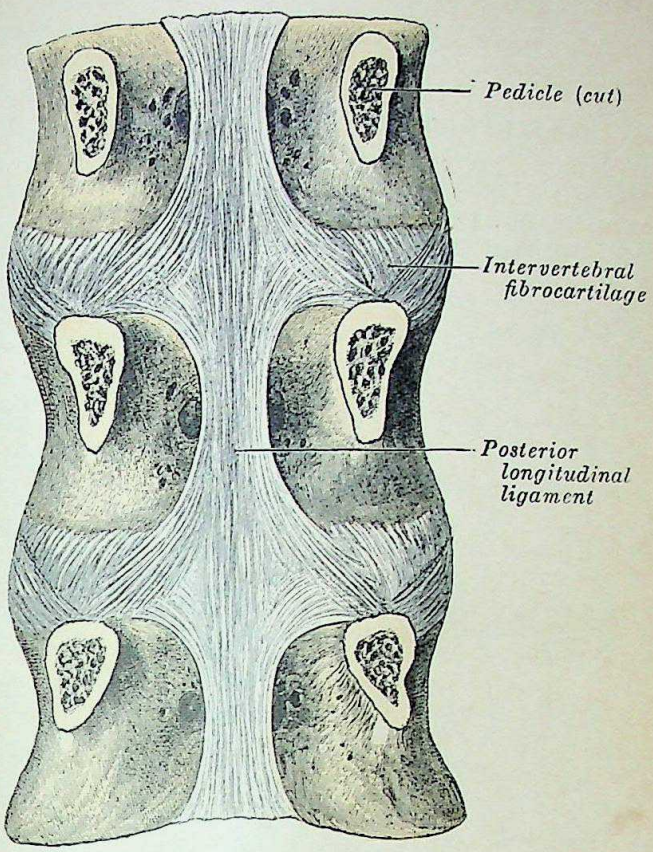

ructure of the intervertebral fibrocartilages.—Each is composed, at its circumfer- of laminæ of fibrous tissue and fibrocartilage, forming the *annulus fibrosus*; and, centre, of a soft, pulpy, highly elastic substance, of a yellowish colour, which pro- considerably above the surrounding level when the disc is divided horizontally. pulpy substance (*nucleus pulposus*), especially well developed in the lumbar region, ains the remains of the notochord. The laminæ are arranged concentrically; the rmost consist of ordinary fibrous tissue, the others of white fibrocartilage. The inæ are not quite vertical in their direction, those near the circumference being ed outwards and closely approximated; while those nearest the centre curve in the osite direction, and are somewhat more widely separated. The fibres composing laminæ are directed, for the most part, obliquely from above downwards, the fibres jacent laminæ passing in opposite directions and varying in every layer: so that bres of one layer are directed across those of another, like the limbs of the letter X. laminar arrangement exists in about the outer half of each fibrocartilage. The substance presents no such arrangement, and consists of a fine fibrous matrix, aining angular cells united to form a reticular structure.

plied Anatomy.—When an aneurysm presses on the vertebral column, the vertebral s are often deeply eroded by it, while the intervertebral fibrocartilages remain . The fibrocartilages are the first to be destroyed, however, in tuberculosis of ertebral column, where, as not infrequently happens, the disease begins in a fibro- ge, and spreads thence to the bodies of the two adjoining vertebræ.

CC-0. In Public Domain. Gurukul Kangri Collection, Haridwar

Digitized by Arya Samaj Foundation Chennai and eGangotri

2. The Articulations of the Vertebral Arches

The joints between the articular processes of the vertebræ belo arthrodial variety and are enveloped by articular capsules; the lamin and transverse processes are connected by the following ligaments:

Ligamenta flava. Ligamentum nuchæ.
Supraspinal. Interspinal.
Intertransverse.

The **articular capsules** are thin and loose, and are attached to th of the articular processes of adjacent vertebræ; they are longer a in the cervical than in the thoracic and lumbar regions.

The **ligamenta flava** (figs. 470, 472) connect the laminæ of adjacent and are best seen from the interior of the vertebral canal. Their att

Fig. 472.—The ligamenta flava of the lumbar region. Anterior aspect.

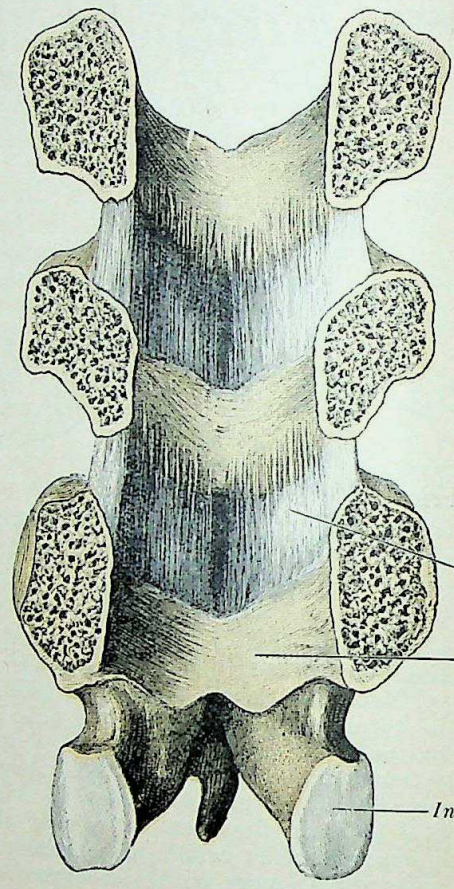

extend from the articular capsules to the regions where the laminæ fuse the spinous processes; here their posterior margins come into contact to a certain extent united, small intervals being left for the passage of The ligamenta flava consist of yellow elastic tissue, the fibres of which perpendicular in direction, are attached to the anterior surface of the above, some distance from its inferior margin, and to the posterior and upper margin of the lamina below. The ligaments are thin, bu and long in the cervical region; they are thicker in the thoracic reg thickest in the lumbar region. Their elasticity helps to preserve the posture, and to assist the vertebral column in resuming it after flexion.

The **supraspinal ligament** (fig. 470) is a strong fibrous cord, which co together the apices of the spinous processes from the seventh cervical to the sacrum; fibrocartilage is developed in the ligament at its p attachment to the tips of the spinous processes. It is thicker and

CC-0. In Public Domain. Gurukul Kangri Collection, Haridwar

Digitized by Arya Samaj Foundation Chennai and eGangotri

the lumbar than in the thoracic region, and intimately blended in both
ations with the neighbouring fascia. The most superficial fibres of this
ment extend over three or four vertebræ; those more deeply seated pass
een two or three vertebræ; while the deepest connect the spinous processes
eighbouring vertebræ. Between the spinous processes it is continuous
the interspinal ligaments. Between the spinous process of the seventh
ical vertebra and the external occipital protuberance its place is taken by
ligamentum nuchæ.

The **ligamentum nuchæ** is a fibrous membrane, which, in the neck, is
ologous with the supraspinal ligament of the thoracic and lumbar vertebræ.
xtends from the external protuberance and median nuchal line of the
cipital bone to the spinous process of the seventh cervical vertebra. From
nterior border a fibrous lamina is given off, which is attached to the posterior
rcle of the atlas, and to the spinous processes of the cervical vertebræ, and
s a septum between the muscles of the two sides of the neck. In man it is
representative of an important elastic ligament, which, in some of the
r animals, serves to sustain the weight of the head.

The **interspinal ligaments** (fig. 470), thin and membranous, connect
ining spinous processes, and their attachments extend from the root to
pex of each process. They meet the ligamenta flava in front and the
spinal ligament behind. They are narrow and elongated in the thoracic
n; broader, thicker, and quadrilateral in form in the lumbar region; and
slightly developed in the neck.

The **intertransverse ligaments** are interposed between the transverse
esses. In the cervical region they consist of a few irregular, scattered
s; in the thoracic region they are rounded cords intimately connected
the deep muscles of the back; in the lumbar region they are thin and
branous.

3. The Sacrococcygeal Symphysis

This articulation is an amphiarthrodial joint, between the apex of the
rum and the base of the coccyx, the bones being united by anterior,
erior and lateral sacrococcygeal ligaments, and by a disc of fibrocartilage.

The anterior **sacrococcygeal ligament** (fig. 501) consists of a few irregular
s, which descend from the anterior surface of the sacrum to the front of the
yx, blending with the periosteum.

The posterior **sacrococcygeal ligament** is a flat band, which arises from
margin of the lower orifice of the sacral canal, and descends to be inserted
the posterior surface of the coccyx. This ligament completes the lower
of the sacral canal, and is divisible into a short *deep* and a longer *super-*
part.

A lateral **sacrococcygeal ligament** exists on either side and connects
transverse process of the coccyx to the inferior lateral angle of the sacrum;
mpletes the foramen for the fifth sacral nerve.

A thin disc of **fibrocartilage** is interposed between the contiguous surfaces
he sacrum and coccyx; it is somewhat thicker in front and behind than
he sides. Occasionally the coccyx is freely movable on the sacrum; in
cases an articular capsule lined with a synovial stratum is present.

The different segments of the coccyx are connected together by the
nsion downwards of the anterior and posterior sacrococcygeal ligaments,
annular discs of fibrocartilage being interposed between the segments.
the adult male, all the pieces become ossified together at a comparatively
y period; but in the female, this does not commonly occur until a later
od of life. At a more advanced age the joint between the sacrum and
yx is obliterated.

ackward and forward movements take place between the sacrum and
yx; their extent increases during pregnancy.

Movements.—The movements permitted in the vertebral column are: flexion,
ension, lateral movement, circumduction, and rotation.

In *flexion*, or movement forwards, the anterior longitudinal ligament is relaxed
the anterior parts of the intervertebral fibrocartilages are compressed; while
posterior longitudinal ligament, the ligamenta flava, and the interspinal and

CC-0. In Public Domain. Gurukul Kangri Collection, Haridwar

Digitized by Arya Samaj Foundation Chennai and eGangotri

supraspinal ligaments are stretched, as well as the posterior fibres of the vertebral fibrocartilages. The interspaces between the laminæ are widened, the inferior articular processes glide upwards upon the superior articular processes of the subjacent vertebræ. Flexion is the most extensive of all the movements of the vertebral column, and is freest in the lumbar region.

In *extension*, or movement backwards, an exactly opposite disposition of the parts takes place. This movement is limited by the anterior longitudinal ligament and by the approximation of the spinous processes. It is freest in the cervical region.

In *lateral movements*, the sides of the intervertebral fibrocartilages are compressed, the extent of motion being limited by the resistance offered by the supraspinal ligaments. Lateral movements may take place in any part of the column, but are freest in the cervical and lumbar regions.

Circumduction is very limited, and is merely a succession of the preceding movements.

Rotation is produced by the twisting of the intervertebral fibrocartilages, which, although only slight between any two vertebræ, allows of a considerable extent of movement when it takes place in the whole length of the column, the front of the upper part of the column being turned to one or other side. This movement, which is to a slight extent in the cervical region, is freer in the upper part of the cervical region, and absent in the lumbar region.

The extent and variety of the movements are influenced by the shape and direction of the articular surfaces. In the *cervical* region the upward inclination of the superior articular surfaces allows of free flexion and extension. Extension can be carried farther than flexion; at the upper end of the region it is limited by the locking of the posterior edges of the superior atlantal facets in the condyloid fossæ of the occipital bone; at the lower end it is limited by a mechanism in which the inferior articular processes of the seventh cervical vertebra slip into a space behind and below the superior articular processes of the first thoracic. Flexion is arrested just beyond the point where the cervical convexity is straightened, and movement is checked by the apposition of the projecting lower lips of the bodies of the vertebræ with the shelving surfaces on the bodies of the subjacent vertebræ. Lateral flexion and rotation are free in the cervical region, and are always combined, the upward and medial inclinations of the superior articular surfaces limiting rotatory movement during lateral flexion. In the *thoracic* region, notably in the upper part, all the movements are limited in order to reduce interference with respiration to a minimum. The almost complete absence of an upward inclination of the superior articular surfaces prohibits any marked flexion, while extension is checked by the contact of the inferior articular margins with the laminæ and the contact of the spinous processes with one another. Rotation is free in the thoracic region: the superior articular processes are segments of a cylinder whose axis is in the mid-ventral line of the vertebral bodies. The direction of the articular facets would allow of free lateral flexion, but this movement is considerably limited in the upper part of the region by the resistance of the ribs and sternum. In the *lumbar* region flexion and extension are free. The inferior articular facets are not in close apposition with the superior facets of the subjacent vertebræ, and on this account a considerable amount of lateral flexion is permitted. For the same reason a slight amount of rotation can be carried out, but this is so soon checked by the interlocking of the articular surfaces that it is negligible.

Muscles producing the movements.—The vertebral column may be moved either by (*a*) muscles attached to it and acting directly on it, or by (*b*) muscles attached to other bones and acting indirectly on the column.

a. Muscles acting *directly* on the vertebral column.

Flexion.—Longus colli, Scaleni, Quadratus lumborum, Psoas major, Psoas minor.

Extension.—Interspinales, Multifidus, Spinales, Semispinales dorsi et cervicis, Iliocostalis cervicis, Longissimi dorsi et cervicis and Splenius cervicis.

Lateral flexion.—Intertransversarii, Multifidus, Iliocostalis cervicis, Longissimi cervicis, Splenius cervicis, Levatores costarum, Longus colli, Scaleni, Quadratus lumborum and Psoas major.

Rotation.—Rotatores, Multifidus, Splenius cervicis, Semispinales dorsi et cervicis, Levatores costarum and Longus colli.

CC-0. In Public Domain. Gurukul Kangri Collection, Haridwar

Digitized by Arya Samaj Foundation Chennai and eGangotri

b. Muscles acting *indirectly* on the vertebral column.

Flexion.—Sternocleidomastoideus, Longus capitis and the abdominal muscles.

Extension.—Splenius capitis, Semispinalis capitis, Iliocostales lumborum et dorsi, and Longissimi dorsi et capitis.

Lateral flexion and rotation.—Sternocleidomastoideus, Obliqui abdominis, Iliocostales lumborum et dorsi, and Longissimi dorsi et capitis.

4. The Articulation of the Atlas with the Epistropheus

The articulation of the atlas with the epistropheus is of a complicated ure and comprises three joints. There is a pivot-joint between the dens he epistropheus and the ring formed by the anterior arch and the transverse

Fig. 473.—The anterior atlanto-occipital membrane.

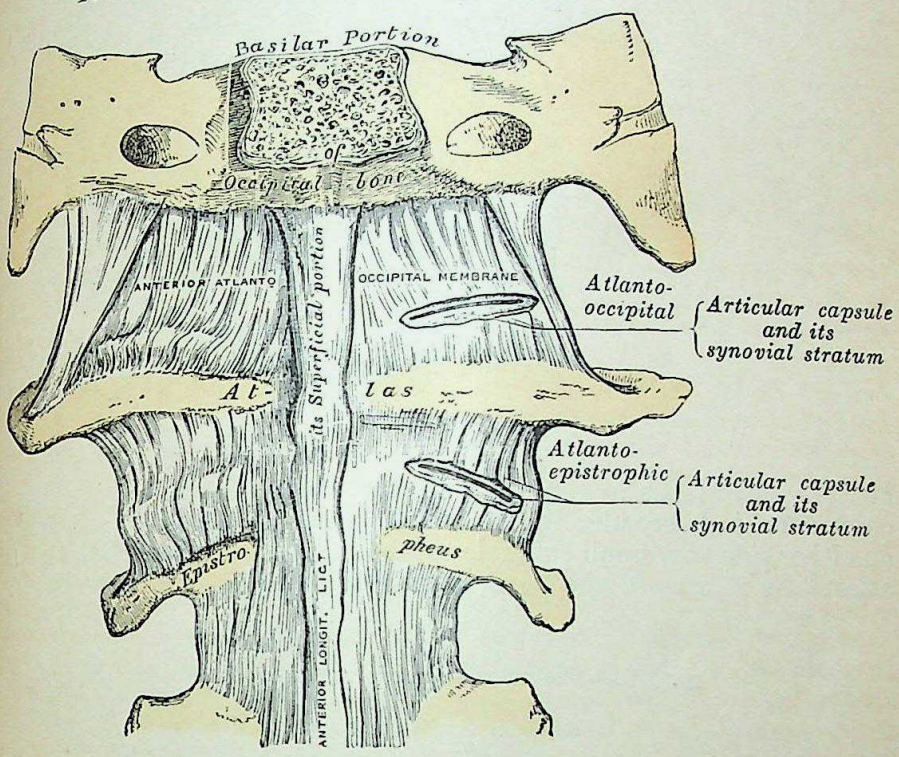

ment of the atlas (fig. 475), and a pair of arthrodial or gliding joints between articular surfaces of the two bones. The bones are connected by two cular capsules and by the transverse ligament of the atlas.

The articular capsules are thin and loose, and surround the joints between articular surfaces. Each is strengthened at its posterior and medial part an *accessory ligament*, which is attached below to the body of the epistro- us near the base of the dens, and above to the lateral mass of the atlas near transverse ligament.

In front, the two vertebræ are connected by a continuation of the anterior gitudinal ligament (fig. 473). In this position it is a strong membrane, d, above, to the lower border of the anterior arch of the atlas, and below, to front of the body of the epistropheus. It is strengthened in the middle by a rounded cord, which connects the tubercle on the anterior arch of the to the body of the epistropheus.

Behind, the atlas and epistropheus are joined by a broad, thin membrane 473) attached, above, to the lower border of the posterior arch of the atlas, ow, to the upper edges of the laminæ of the epistropheus; it is in series h the ligamenta flava.

CC-0. In Public Domain. Gurukul Kangri Collection, Haridwar

Digitized by Arya Samaj Foundation Chennai and eGangotri

The transverse ligament of the atlas (figs. 475 to 477) is a strong band, which arches across the ring of the atlas, and retains the

Fig. 474.—The posterior atlanto-occipital membrane.

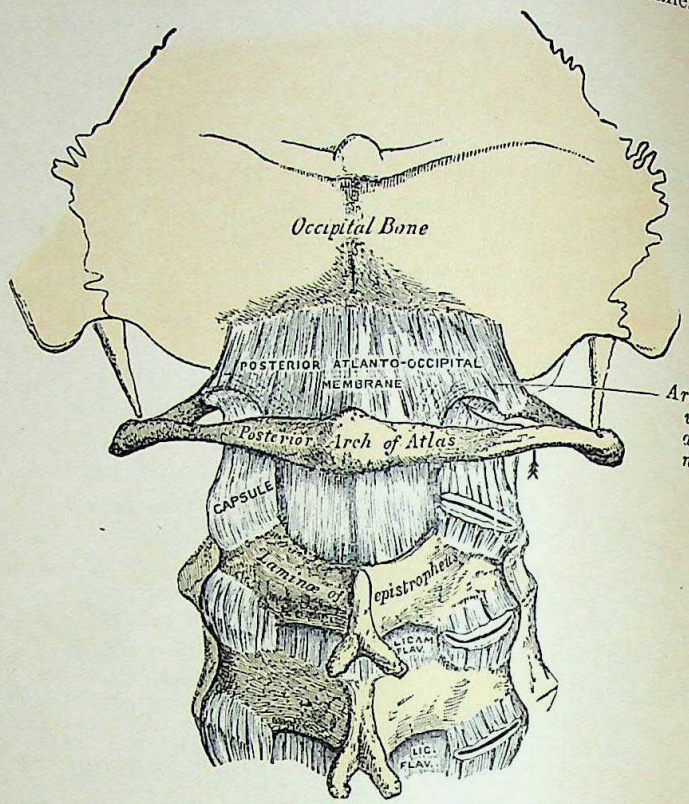

of the epistropheus in contact with the anterior arch. It is concave in convex behind, broader in the middle than at the ends, and firmly on either side to a small tubercle on the medial surface of the lateral mass atlas. As it crosses the dens, a small fasciculus (*crus superius*) is pr

Fig. 475.—The atlas vertebra, with the transverse ligament.

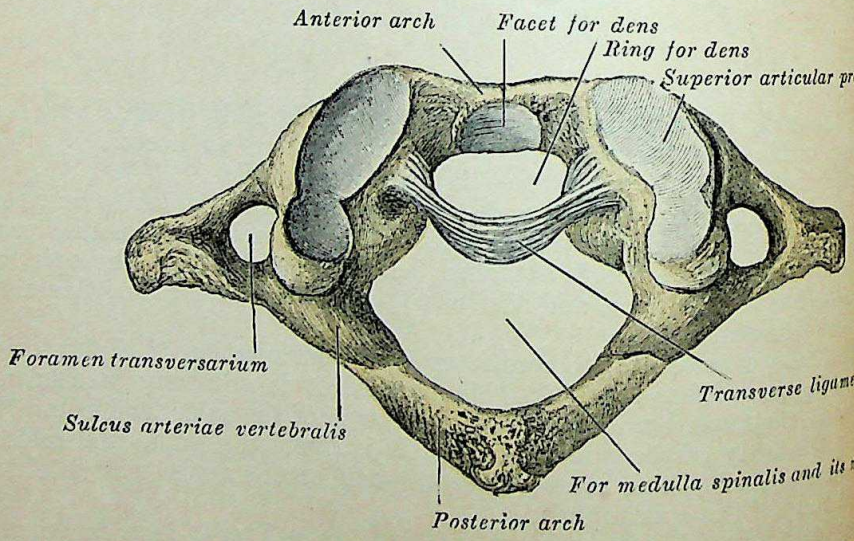

upwards, and another (*crus inferius*) downwards, from the superficial or pos fibres of the ligament. The *crus superius* is attached to the upper surface

CC-0. In Public Domain. Gurukul Kangri Collection, Haridwar

Digitized by Arya Samaj Foundation Chennai and eGangotri

FIG. 476.—The membrana tectoria, and the transverse and alar ligaments. The crus superius of the transverse ligament is drawn to one side.

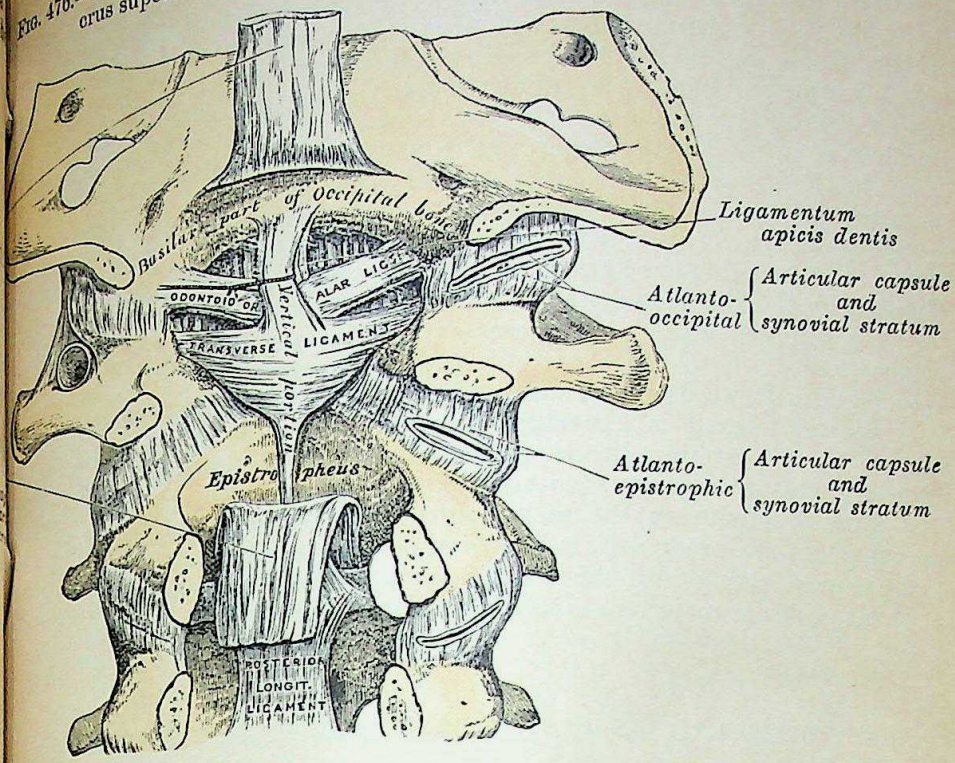

FIG. 477.—A median sagittal section through the occipital bone and first three cervical vertebræ.

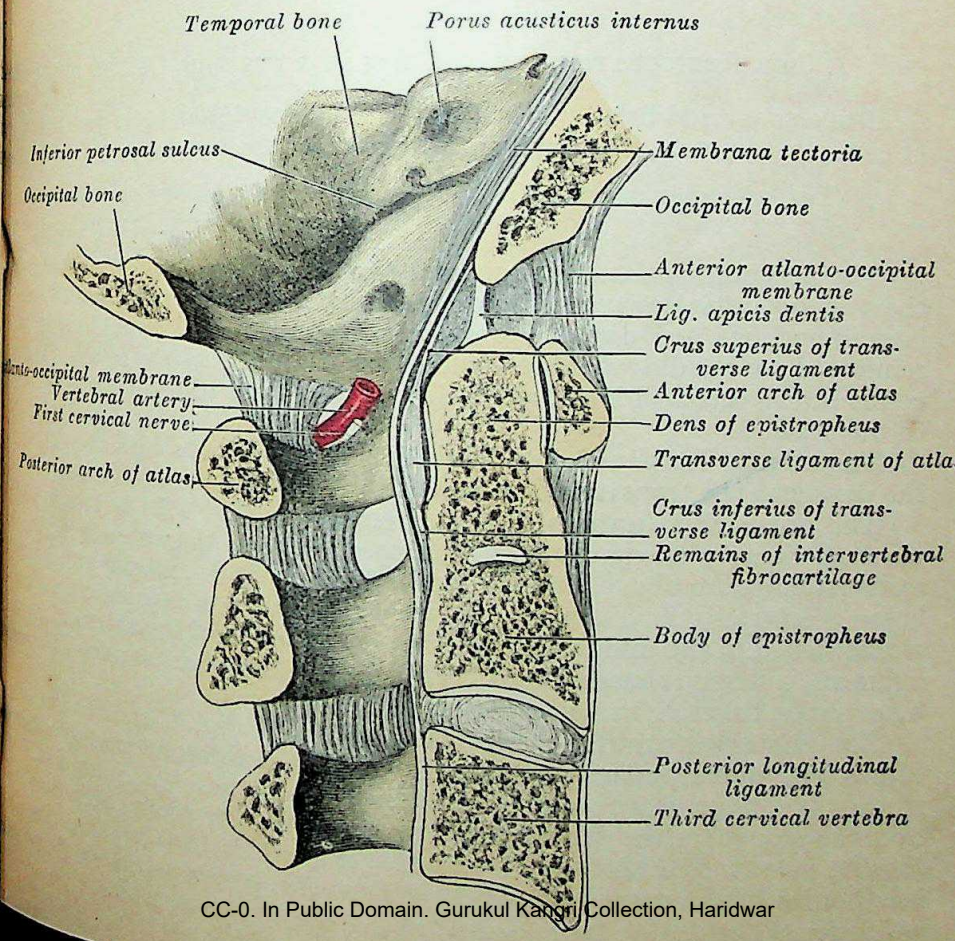

CC-0. In Public Domain. Gurukul Kangri Collection, Haridwar

Digitized by Arya Samaj Foundation Chennai and eGangotri
basilar part of the occipital bone between the ligamentum apicis de the membrana tectoria; the crus inferius is attached to the posterior of the body of the epistropheus; hence the whole ligament is na *ligamentum cruciatum atlantis.* The transverse ligament divides the ri atlas into two unequal parts: of these, the posterior and larger surro medulla spinalis and its membranes and the spinal parts of the accessory the anterior and smaller contains the dens. The neck of the dens is co where it is embraced posteriorly by the transverse ligament, so that this suffices to retain the process in position after all the others have been di

The joint-cavity between the dens and the transverse ligament continuous with those of the atlanto-occipital articulations.

Movements.—This articulation with its three joints allows the rotatio atlas (and, with it, the skull) upon the epistropheus, the extent of rotati limited by the alar ligaments (p. 367).

The opposed articular surfaces of the atlas and epistropheus are not cally curved; both are convex in their long axes. When, therefore, th facet glides forwards on the lower it also descends; the fibres of the capsule are relaxed in a vertical direction, and will then permit of mo in an anteroposterior direction. By this means a shorter capsule suffi the strength of the joint is materially increased.

Muscles producing the movements.—The principal muscles by which movements are produced are the Sternocleidomastoideus and Semispinalis of one side, acting with the Longus capitis, Splenius, Longissimus capitis capitis posterior major, and Obliquus capitis inferior of the other side.

THE ARTICULATIONS OF THE VERTEBRAL COLUMN WITH THE CRA

The ligaments connecting the vertebral column with the cranium divided into two sets; those uniting the atlas with the occipital bo those connecting the epistropheus with the occipital bone.

1. The Articulation of the Atlas with the Occipital Bon

The articulation between the atlas and the occipital bone consists of of condyloid joints. The ligaments connecting the bones are:

Two articular capsules.	Anterior and posterior atlanto-occipital membranes.

The **articular capsules** surround the condyles of the occipital bo the superior articular processes of the atlas: they are thin and loose. lateral portions are directed obliquely upwards and medialwards, a reinforced by bundles of fibres, which are attached above to the jugul cesses of the occipital bone, and below to the bases of the transverse pr of the atlas.

The atlanto-occipital joints frequently communicate with the joint b the dens and the transverse ligament of the atlas.

The **anterior atlanto-occipital membrane** (fig. 473) is broad, an posed of densely woven fibres which pass between the anterior margin foramen magnum above, and the upper border of the anterior arch of th below; laterally, it is continuous with the articular capsules; in front strengthened in the middle line by the continuation of the anterior longi ligament, a strong, rounded cord, which connects the basilar part of the o bone to the tubercle on the anterior arch of the atlas.

The **posterior atlanto-occipital membrane** (fig. 474), broad but th connected, above, to the posterior margin of the foramen magnum; bel the upper border of the posterior arch of the atlas. On either side it o over the groove for the vertebral artery, and with this groove bounds an o for the entrance of the artery and the exit of the first cervical nerve free border of the membrane, arching over the artery and nerve, is som ossified.

CC-0. In Public Domain. Gurukul Kangri Collection, Haridwar

Digitized by Arya Samaj Foundation Chennai and eGangotri

Movements.—The movements permitted in this joint are (*a*) flexion and extension, which give rise to the ordinary forward and backward nodding of the head, (*b*) slight lateral motion to one or other side.

Muscles producing the movements:

Flexion.—Longus capitis and Rectus capitis anterior.

Extension.—Recti capitis posteriores major et minor, Obliquus superior, Semispinalis capitis, Splenius capitis, Sternocleidomastoideus and Trapezius (upper fibres).

Lateral flexion.—Rectus capitis lateralis, Semispinalis capitis, Splenius capitis, Sternocleidomastoideus and Trapezius (upper fibres).

2. The Ligaments connecting the Epistropheus with the Occipital Bone

Membrana tectoria. Two alar. Ligamentum apicis dentis.

The **membrana tectoria** (occipito-axial ligament) (figs. 476, 477) is situated within the vertebral canal. It is a broad, strong band, which covers the dens with its ligaments, and appears to be a prolongation upwards of the posterior longitudinal ligament of the vertebral column. It is fixed, below, to the posterior surface of the body of the epistropheus, and, expanding as it ascends, is attached above to the upper surface of the basilar part of the occipital bone, in front of the foramen magnum, blending with the cranial dura mater.

The **alar ligaments** (odontoid ligaments) (fig. 476) are two strong, rounded cords, which arise one on either side of the upper part of the dens, and passing obliquely upwards and lateralwards, are inserted into rough impressions on the medial sides of the condyles of the occipital bone. The alar ligaments limit rotation of the cranium and therefore receive the name of *check ligaments*.

Between the alar ligaments is the **ligamentum apicis dentis** (fig. 477) which extends from the tip of the dens to the anterior margin of the foramen magnum, being intimately blended with the deep portion of the anterior atlanto-occipital membrane and with the superior crus of the transverse ligament of the atlas. It is regarded as a rudimentary intervertebral fibrocartilage, and traces of the notochord may persist in it.

In addition to the ligaments which unite the atlas and epistropheus to the skull, it must be remembered that the ligamentum nuchæ (p. 361) connects the cervical vertebræ with the cranium.

Applied Anatomy.—The ligaments of the vertebral column are so strong, and the joints so interlocked by the arrangement of their articulating processes, that dislocation is very uncommon, and, except in the upper part of the neck, rarely occurs unless accompanied by fracture. Dislocation of the occipital bone from the atlas has been recorded in one or two cases; but dislocation of the atlas from the epistropheus, with rupture of the transverse ligament of the atlas, is much more common; it is the mode in which death is produced in many cases of execution by hanging. Hanging may however produce a fracture through the epistropheus, or a separation through the fibrocartilage between the epistropheus and the third cervical vertebra. Below the third cervical vertebra, dislocation without fracture occasionally takes place.

THE COSTOVERTEBRAL ARTICULATIONS

The articulations of the ribs with the vertebral column may be divided into two sets, one connecting the heads of the ribs with the bodies of the vertebræ, the other uniting the necks and tubercles of the ribs with the transverse processes.

1. The Articulations of the Heads of the Ribs (fig. 478)

These articulations, sometimes named the *costocentral*, constitute a series of arthrodial joints. They are formed by the articulation of the heads of the thoracic ribs with the facets on the contiguous margins of the bodies of the thoracic vertebræ and with the intervertebral fibrocartilages between them; the first,

CC-0. In Public Domain. Gurukul Kangri Collection, Haridwar

Digitized by Arya Samaj Foundation Chennai and eGangotri

tenth, eleventh, and twelfth ribs each articulate with a single vertebra, the ligaments of the joints are :

The articular capsules. Radiate.
Interarticular.

In the articulations of the heads of the ribs from the second to the tenth, inclusive, two articular capsules are present, since each of these joints is divided by an interarticular ligament. The **articular capsules** connect the heads of the ribs with the circumferences of the articular cavities formed by the intervertebral fibrocartilages and the adjacent vertebræ. Some of the upper fibres pass through the intervertebral foramen to the back of the intervertebral fibrocartilage, while the posterior fibres are continuous with the ligament of the neck of the rib.

FIG. 478.—The costovertebral articulations. Right antero-lateral aspect.

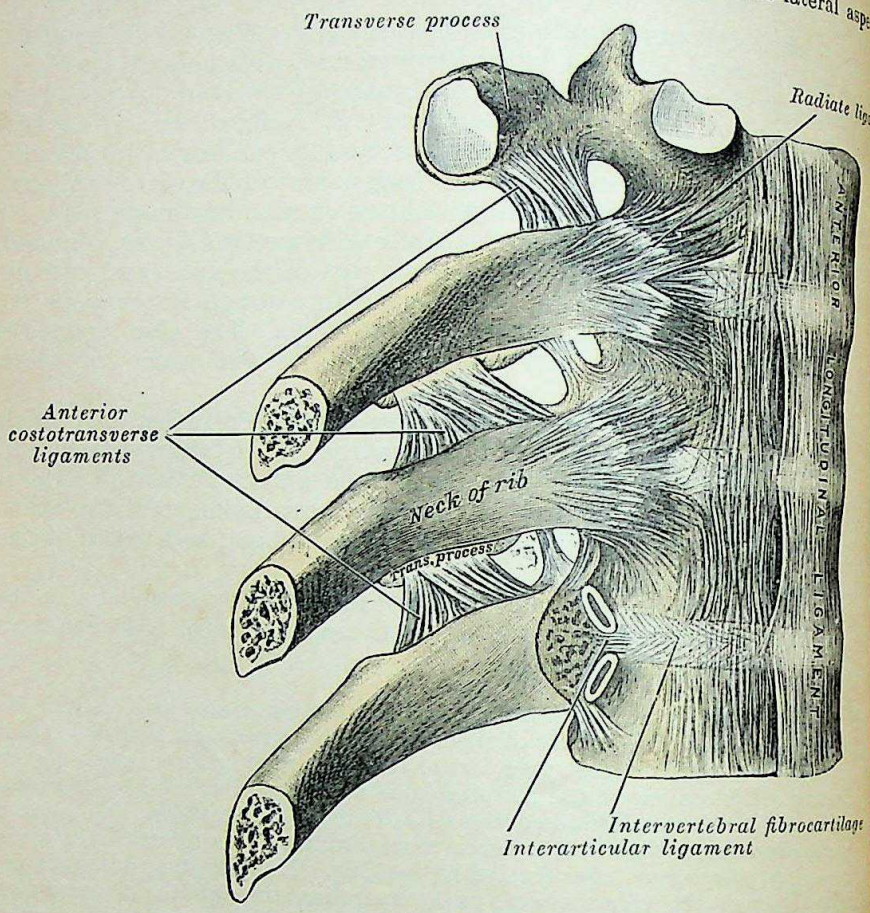

The **radiate ligament** (stellate ligament) connects the anterior part of the head of each rib with the sides of the bodies of two vertebræ, and the intervertebral fibrocartilage between them. It is attached to the anterior part of the head of the rib, just beyond the articular surface. The superior fibres are short and are connected with the body of the vertebra above ; the inferior fibres descend to the body of the vertebra below ; the middle fibres, the smallest and least distinct, are horizontal and attached to the intervertebral fibrocartilage.

In the articulation of the first rib, the radiate ligament is attached to the body of the last cervical vertebra, as well as to that of the first thoracic. In the articulations of the tenth, eleventh, and twelfth ribs, each of which articulates with a single vertebra, the radiate ligament is connected to the vertebra with which the rib articulates, and also to the vertebra immediately above.

The **interarticular ligament** is situated in the interior of the joint, and consists of a short band of fibres, flattened from above downwards, attached laterally to the crest separating the two articular facets on the head of the rib, and medially to the intervertebral fibrocartilage ; it divides the

CC-0. In Public Domain. Gurukul Kangri Collection, Haridwar

Digitized by Arya Samaj Foundation Chennai and eGangotri

two cavities and its upper and lower surfaces are covered with the synovial ta of the articular capsules. In the joints of the first, tenth, eleventh, and lfth ribs, interarticular ligaments do not exist; consequently, there is but cavity in each of these articulations. The interarticular ligament is the logue of the *ligamentum conjugale* which is present in some mammals, and s the heads of opposite ribs across the back of the intervertebral fibro-ilage.

2. The Costotransverse Articulations (fig. 479)

The articular portion of the tubercle of a rib forms an arthrodial joint with transverse process of the lower of the two vertebræ to which the head of rib is fixed. In the eleventh and twelfth ribs this articulation is wanting. The ligaments of the joint are:

The articular capsule.
Anterior and posterior costotransverse.
Ligament of the neck of the rib.
Ligament of the tubercle of the rib.

The **articular capsule** is a thin membrane attached to the circumference e articular surfaces, and lined with a synovial stratum.

Fig. 479.—The costotransverse articulations. Superior aspect.

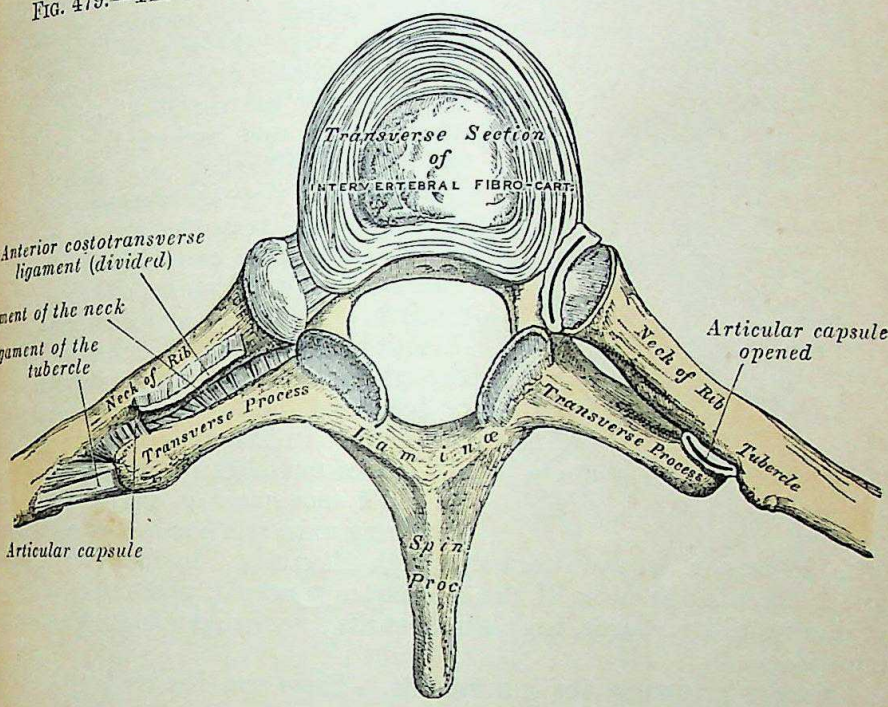

The **anterior costotransverse ligament** is attached below to the crest the upper border of the neck of the rib, and passes obliquely upwards and lwards to the lower border of the transverse process immediately above. The first rib has no anterior costotransverse ligament. The neck of the fth rib is connected to the base of the transverse process of the first lumbar ebra by a band of fibres, named the *lumbocostal ligament*; it is in series the anterior costotransverse ligaments.

The **posterior costotransverse ligament** is a feeble band which is ched below to the neck of the rib, behind and medial to the anterior transverse ligament; it passes upwards and medialwards to the base of transverse process and the lateral border of the inferior articular process of vertebra above.

The **ligament of the neck of the rib** (interosseous costotransverse ment) consists of short but strong fibres, connecting the rough surface the back of the neck of the rib with the anterior surface of the adjacent verse process. A rudimentary ligament may be present at the eleventh twelfth ribs.

CC-0. In Public Domain. Gurukul Kangri Collection, Haridwar

Digitized by Arya Samaj Foundation Chennai and eGangotri

The **ligament of the tubercle of the rib** is a short, thick fasciculus, which passes obliquely from the apex of the transverse p the rough non-articular portion of the tubercle of the rib. The l attached to the upper ribs ascend from the transverse processes, shorter and more oblique than those at the lower ribs, which descend slightly.

FIG. 480.—A section through the costotransverse joints from the third to the ninth inclusive. Contrast the concave facets on the upper with the flattened facets on the lower transverse processes.

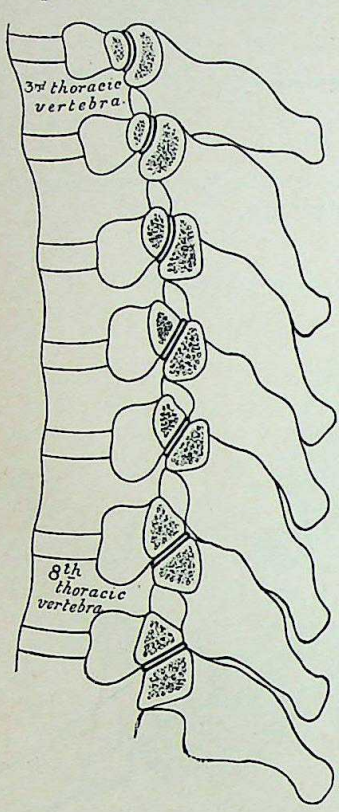

Movements.—The heads of the rib closely connected to the bodies of the by the radiate and interarticular ligam only slight gliding movements of the surfaces on one another can take place. the strong ligaments binding the necks and of the ribs to the transverse processes movements of the costotransverse slight gliding, the nature of which is de by the shape and direction of the artic faces (fig. 480). The articular surfaces tubercles of the upper six ribs are oval and convex from above downwards; into corresponding concavities on the surfaces of the transverse processes, upward and downward movements of the are associated with rotation of the rib its long axis. On the seventh, eight and tenth ribs the articular surfaces on the are flat, and are directed obliquely do medialwards, and backwards. The surfa which they articulate are placed on th margins of the transverse processes; therefore, the tubercles are drawn up at the same time carried backwards and wards. The two joints, costocentral a transverse, move simultaneously and in t directions, the total effect being that the the rib moves as if on a single joint, of w costocentral and costotransverse articulati the ends. In the upper six ribs the neck rib moves but slightly upwards and dow its chief movement is one of rotation r own long axis, rotation backwards being a with depression, rotation forwards with elevation. In the seventh, eight and tenth ribs the neck of the rib moves upwards, backwards, and medi or downwards, forwards, and lateralwards; very slight rotation accompan movements.

Muscles producing the movements.—These are discussed with the mu of respiration (p. 468).

THE STERNOCOSTAL ARTICULATIONS (fig. 481)

The cartilages of the true ribs, with the exception of the first, ar with the sternum by arthrodial joints. The cartilage of the first rib is d united with the sternum, and the joint between this rib and the ster a synchondrosis.

The ligaments of the arthrodial joints are :

The articular capsules.	Interarticular sternocostal.
Radiate sternocostal.	Costoxiphoid.

The **articular capsules** surround the joints between the sternu the cartilages of the ribs from the second to the seventh inclusive. Th very thin, intimately blended with the radiate sternocostal ligamen strengthened at the upper and lower parts of the articulations by a few which connect the cartilages to the side of the sternum.

CC-0. In Public Domain. Gurukul Kangri Collection, Haridwar

Digitized by Arya Samaj Foundation Chennai and eGangotri

The radiate sternocostal ligaments are broad, thin membranous bands h radiate from the front and back of the sternal ends of the cartilages e true ribs to the anterior and posterior surfaces of the sternum. Their ficial fibres intermingle with the fibres of the ligaments above and below with those of the opposite side, and on the front of the sternum with

ig. 481.—The sternocostal and interchondral articulations. Anterior aspect.

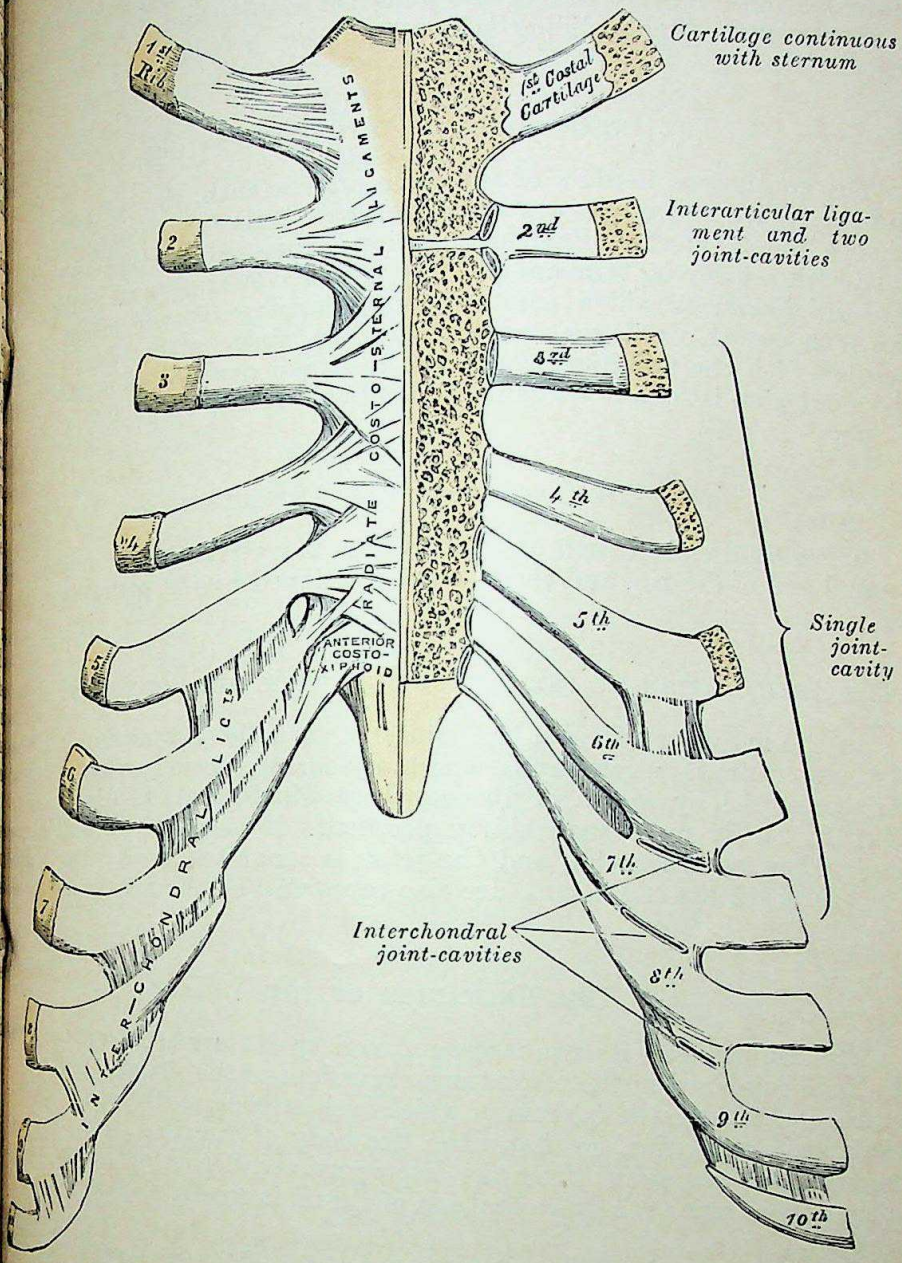

tendinous fibres of origin of the Pectoralis major, forming a thick fibrous mbrane (*membrana sterni*) which envelops the bone, and is more distinct s lower than at its upper part.

The interarticular sternocostal ligaments are found constantly only een the second costal cartilages and the sternum. The cartilage of the *rib* is connected with the sternum by means of an interarticular ligament, ched laterally to the cartilage of the rib, and medially to the fibrocartilage h unites the manubrium and body of the sternum. Occasionally the tilage of the *third rib* is connected with the first and second pieces of the body

CC-0. In Public Domain. Gurukul Kangri Collection, Haridwar

Digitized by Arya Samaj Foundation Chennai and eGangotri

of the sternum by an interarticular ligament. Still more rarely, si
ments are found in the other four joints of the series. In the lowe
interarticular ligament sometimes obliterates the joint-cavity, so as t
the articulation into an amphiarthrosis. After middle life the articula
lose their polish, become roughened, and the synovial strata appar
appear. In old age, the cartilages of most of the ribs become contin
the sternum, and the joint-cavities are consequently obliterated.

The **costoxiphoid ligaments** connect the anterior and posterior
of the seventh costal cartilage, and sometimes those of the sixth, to
and back of the xiphoid process. They vary in length and breadth in
subjects; those on the back of the joint are less distinct than those in

Movements.—Slight gliding movements are permitted in the st
articulations.

The Interchondral Articulations (fig. 481)

The contiguous borders of the sixth and seventh, the seventh and
and the eighth and ninth, costal cartilages articulate with each other
smooth, oblong facets. Each articulation is enclosed in a thin *articular*
lined with a synovial stratum and strengthened laterally and medially
chondral ligaments which pass from one cartilage to the other. So
the fifth costal cartilages, more rarely the ninth, articulate by the
borders with the adjoining cartilages by small oval facets; more fr
the connexion is by a few ligamentous fibres.

The Costochondral Articulations

The lateral end of each costal cartilage is received into a depressi
sternal end of the rib, and the two are enveloped by the periosteum.

The Articulation of the Manubrium with the Body of the St

In the majority of cases the joint between the manubrium and th
of the sternum is a symphysis, the bony surfaces being coated with c
and connected by a disc of fibrocartilage which tends to ossify in a
life. In rather more than thirty per cent. of cases the central par
disc undergoes absorption and the joint is converted into a diarthro
The two segments of the bone are also connected by the membrana ster

The Mechanism of the Thorax

Each rib possesses its own range and variety of movements, but the mo
of all are combined in the respiratory excursions of the thorax. Each rib
regarded as a lever, the fulcrum of which is situated immediately outside th
transverse articulation, so that when the body of the rib is elevated the
depressed and *vice versa*; from the disproportion in length of the arms of th
a slight movement at the vertebral end of the rib is greatly magnified at the
extremity.

The anterior ends of the ribs lie on a lower plane than the posterior
therefore the body of the rib is elevated the anterior extremity is also thrust u
Again, the middle of the body of the rib lies in a plane below that passing thro
two extremities, so that when the body is elevated relatively to its ends
the same time carried outwards from the median plane of the thorax; furth
rib forms the segment of a curve which is greater than that of the rib imm
above. Therefore the elevation of a rib increases the transverse diameter
thorax in the plane to which it is raised. The modifications of the rib mo
at their vertebral ends have already been described (p. 370). Further m
tions result from the attachments of their anterior extremities, and it is con
therefore to consider separately the movements of the ribs of the three g
vertebrosternal, vertebrochondral, and vertebral.

CC-0. In Public Domain. Gurukul Kangri Collection, Haridwar

Digitized by Arya Samaj Foundation Chennai and eGangotri

ertebrosternal ribs (figs. 482, 483).—The first rib differs from the others of this n in that its attachment to the sternum is a rigid one; this is counterbalanced ne extent by the fact ts head possesses no ticular ligament, and refore more movable. first pair of ribs with manubrium sterni as a single piece, the or portion being ele- by rotatory move- s at the vertebral mities. In normal respiration the move- of this arc is practi- *nil*; when it does the anterior part is and carried for- increasing the an- terior and trans- diameters of this of the chest. The ment of the second also slight in normal ation, as its anterior mity is fixed to the brium, and prevented fore from moving rds. The sternocos- rticulation, however, s the middle of the body of the rib to be drawn up, and in this way ransverse thoracic diameter is increased. Elevation of the third, fourth, fifth,

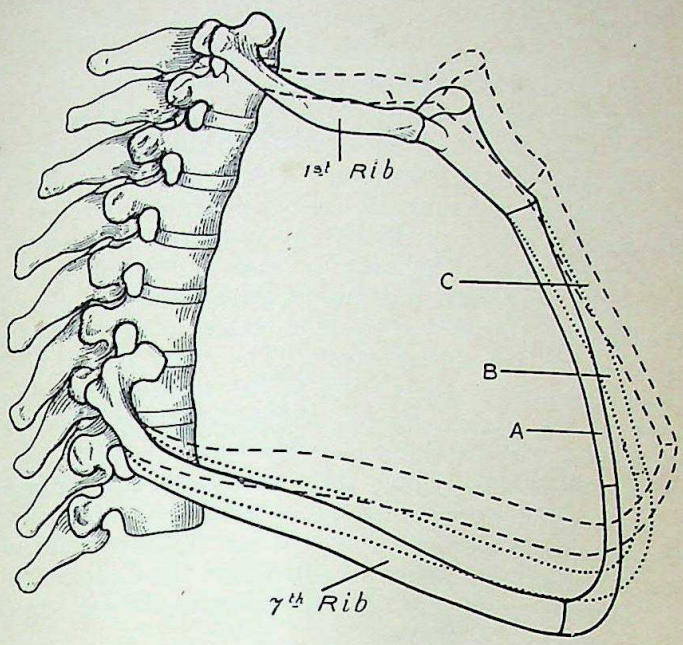

FIG. 482.—A lateral view of the first and the seventh ribs in position, showing the movements of the sternum and ribs in, A, ordinary expiration; B, quiet inspiration; C, deep inspiration.

3.—A diagram showing the axis movement (AB and CD) of a ebrosternal rib. The interrupted s indicate the position of the rib spiration.



FIG. 484.—A diagram showing the axes of movement (AB) of a vertebrochondral rib. The interrupted lines indicate the position of the rib in inspiration.

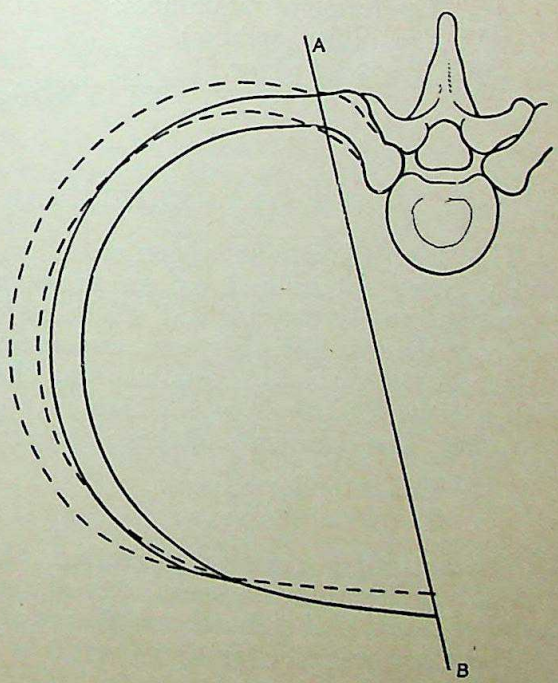

ixth ribs raises and thrusts forwards their anterior extremities, the greater of the movement being effected by the rotation of the rib-neck backwards.

CC-0. In Public Domain. Gurukul Kangri Collection, Haridwar

Digitized by Arya Samaj Foundation Chennai and eGangotri

The thrust of the anterior extremities carries forwards and upwards the sternum, which moves on the joint between it and the manubrium; the anteroposterior thoracic diameter is increased. This movement is soon arrested, and the elevating force is then expended in raising the body of the rib and everting its lower border; at the same time the chondral angle is opened out. By these latter movements a considerable in the transverse diameter of the thorax is effected.

Vertebrochondral ribs (fig. 484).—The seventh rib is included with the as it conforms more closely to their type. While the movements of these in enlarging the thorax for respiratory purposes, they are also concerned in the upper abdominal space for viscera displaced by the action of the D The costal cartilages articulate with one another, so that each pushes up it, the final thrust being directed to pushing forwards and upwards the of the body of the sternum. The amount of elevation of the anterior is limited on account of the very slight rotation of the rib-neck. El the shaft is accompanied by an outward and backward movement; the movement everts the anterior end of the rib and opens up the subcost while the backward movement pulls back the anterior extremity and co the forward thrust due to its elevation; this latter is most noticeable in ribs, which are the shortest. The total result is a considerable increa transverse and a diminution in the median anteroposterior diameter of part of the abdomen; at the same time, however, the lateral anter diameters of the abdomen are increased.

Vertebral ribs.—Since these ribs have free anterior extremities and central articulations with no interarticular ligaments, they are capable movements in all directions. When the other ribs are elevated these are and fixed to form points of action for the Diaphragm.

Muscles producing the movements.—These are discussed with the of respiration (p. 468).

THE ARTICULATIONS OF THE UPPER EXTREMITY

The articulations of the upper extremity comprise the following:

I. The sternoclavicular.
II. The acromioclavicular.
III. The humeral (shoulder).
IV. The cubital (elbow).
V. The radio-ulnar.
VI. The radiocarpal (wr
VII. The intercarpal.
VIII. The carpometacarp
IX. The intermetacarp
X. The metacarpophal
XI. The digital.

I. THE STERNOCLAVICULAR ARTICULATION (fig. 485)

The sternoclavicular articulation is a double arthrodial joint, the cavity being subdivided by an articular disc. The parts entering formation are the sternal end of the clavicle, the lateral part of the border of the manubrium sterni, and the cartilage of the first rib. The surface of the clavicle is much larger than that of the sternum, and is with a layer of cartilage,* which is considerably thicker than that sternum. The ligaments of this joint are:

The articular capsule.
Sternoclavicular.
Interclavicular.
Costoclavicular.

The **articular capsule** surrounds the articulation; in front and it is of considerable thickness, but above, and especially below, it is partakes more of the character of areolar than of true fibrous tissue.

The **sternoclavicular ligament** is a broad band, covering the anterior face of the articulation; it is attached above to the upper and front part

* According to Bruch, the sternal end of the clavicle is covered by a tissue which is rather than cartilaginous in structure.

CC-0. In Public Domain. Gurukul Kangri Collection, Haridwar

Digitized by Arya Samaj Foundation Chennai and eGangotri

nal end of the clavicle, and, passing obliquely downwards and medialwards, ttached below to the front of the upper part of the manubrium sterni.

The **interclavicular ligament** is continuous above with the fascia colli e cervical fascia); it passes from the upper part of the sternal end of clavicle to that of the other, and is also attached to the upper margin e manubrium sterni.

The **costoclavicular ligament** (rhomboid ligament) is short, flat, strong, rhomboid in form. Attached below to the upper surface of the cartilage e first rib, it ascends backwards and lateralwards, and is fixed above to costal tuberosity on the under surface of the clavicle.

FIG. 485.—The sternoclavicular articulations. Anterior aspect.

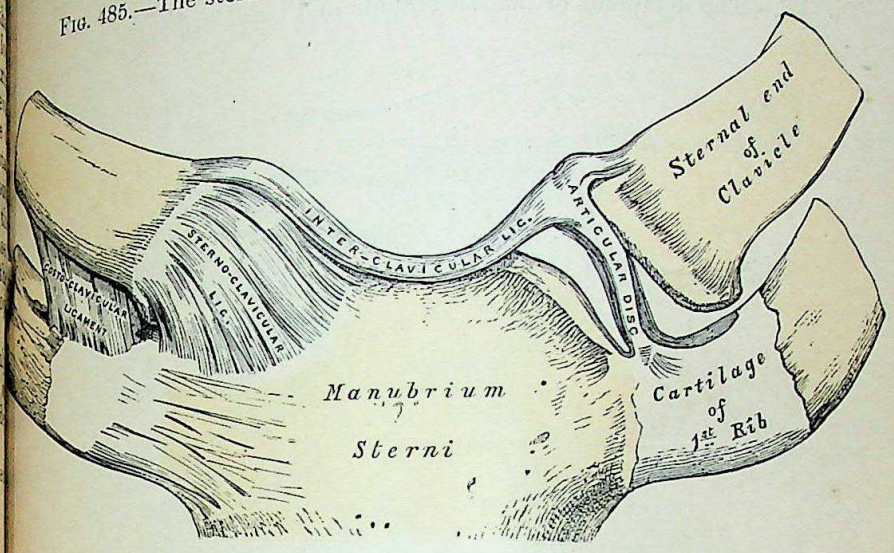

The **articular disc** is flat and nearly circular, and is interposed between the ulating surfaces of the sternum and clavicle. It is attached, above to upper and posterior border of the articular surface of the clavicle; below e cartilage of the first rib, near its junction with the sternum; and by rest of its circumference to the articular capsule. It is thicker at the mference than at the centre, and divides the joint into two cavities; each surfaces is clothed with a synovial stratum.

The *arteries* supplying the joint are derived from the internal mammary ansverse scapular arteries; the *nerves*, from the anterior supraclavicular s.

Movements.—This articulation admits of a limited amount of movement in nearly direction—upwards, downwards, backwards, forwards, as well as circum- on. When these movements take place in the joint, the clavicle in its motion s the scapula with it, this bone gliding on the outer surface of the chest. This therefore forms the centre from which all movements of the supporting arch e shoulder originate, and is the only point of articulation of the shoulder-girdle the trunk. The movements attendant on elevation and depression of the der take place between the clavicle and the articular disc. When the shoulder ved forwards and backwards, the clavicle, with the articular disc, rolls to and n the articular surface of the sternum. Elevation of the shoulder is limited rally by the costoclavicular ligament; depression, by the interclavicular ent and articular disc.

plied Anatomy.—The strength of this joint depends upon its ligaments, and lly on the articular disc. It is owing to these, and to the fact that the force of the usually transmitted along the long axis of the clavicle, that dislocation rarely , and that the clavicle is broken rather than displaced. Dislocation may be either is, backwards or upwards. Should the clavicle be displaced backwards it may pressure on the trachea and great vessels of the neck. The chief point worthy of as regards the construction of the joint, in connexion with dislocation, is the fact owing to the shape of the articular surfaces, and the strength of the joint mainly ing upon the ligaments, the displacement when reduced is very liable to recur.

CC-0. In Public Domain. Gurukul Kangri Collection, Haridwar

Digitized by Arya Samaj Foundation Chennai and eGangotri

II. THE ACROMIOCLAVICULAR ARTICULATION

The acromioclavicular articulation (fig. 486) is an arthrodial joint between the acromial end of the clavicle and the medial margin of the acromion of the scapula. Its ligaments are :

The articular capsule.
Acromioclavicular.
Coracoclavicular { Trapezoid and Conoid.

The **articular capsule** completely surrounds the articular margins, and is strengthened above by the acromioclavicular ligament.

FIG. 486.—The ligaments of the left scapula and shoulder-joint. Anterior aspect.

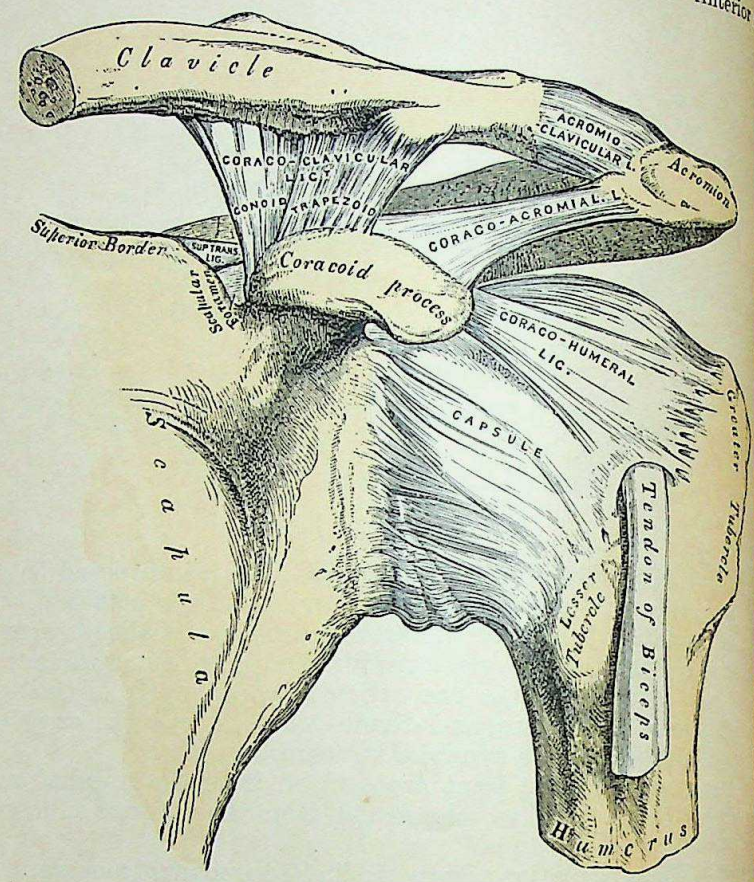

The **acromioclavicular ligament** is a quadrilateral band, covering the superior part of the articulation, and extending between the upper surface of the acromial end of the clavicle and the adjoining part of the upper surface of the acromion ; it is composed of parallel fibres, which interlace with the aponeuroses of the Trapezius and Deltoideus.

An **articular disc** is sometimes found in this joint ; when present it generally occupies the upper part of the articulation, and only partially separates the articular surfaces. More rarely, it completely divides the joint into two cavities.

The **coracoclavicular ligament** (fig. 486) connects the clavicle with the coracoid process of the scapula. It does not properly belong to the acromioclavicular articulation, but is usually described with it since it forms the efficient means of retaining the clavicle in contact with the acromion. It consists of two parts, viz. the *trapezoid* and *conoid ligaments*, which are separated by a bursa.

The *trapezoid ligament*, the anterior and lateral fasciculus, is broad and quadrilateral. It is attached, below, to the upper surface of the coracoid process ; above, to the oblique ridge on the under surface of the clavicle.

CC-0. In Public Domain. Gurukul Kangri Collection, Haridwar

Digitized by Arya Samaj Foundation Chennai and eGangotri

anterior border is free, its posterior is joined with the conoid ligament, two forming, by their junction, an angle projecting backwards.

The *conoid ligament*, the posterior and medial fasciculus, is a dense band of s, conical in form, with its base directed upwards. Its apex is attached rough impression at the junction of the ascending and horizontal portions e coracoid process, medial to the trapezoid ligament; its base is fixed e coracoid tuberosity on the under surface of the clavicle, and to a line ceding medialwards from it for 1·25 cm.

The *arteries* supplying the joint are derived from the transverse scapular thoraco-acromial arteries; the *nerve* is a branch of the suprascapular e.

Movements.—The movements of this articulation are of two kinds: (1) a gliding on of the articular end of the clavicle on the acromion; (2) rotation of the ula forwards and backwards upon the clavicle. The extent of this rotation is ed by the two portions of the coracoclavicular ligament, the trapezoid limiting ion forwards, and the conoid backwards.

The acromioclavicular joint has important functions in the movements of the r extremity. Humphry * pointed out that if there had been no joint between lavicle and scapula, the circular movement of the scapula on the ribs (as in ing the shoulders backwards or forwards) would have been attended with ter alteration in the direction of the shoulder than is consistent with the se of the arm in such positions, and it would have been impossible to give w straight forwards with the full force of the arm: that is to say, with the ined force of the scapula, arm, and forearm. 'This joint,' as he happily ' is so adjusted as to enable either bone to turn in a hinge-like manner upon a al axis drawn through the other, and it permits the surfaces of the scapula, the baskets in a roundabout swing, to look the same way in every position, or y so.' Again, when the whole arch formed by the clavicle and scapula rises falls (in elevation or depression of the shoulder), the joint between these two s enables the scapula still to maintain its lower part in contact with the ribs.

plied Anatomy.—The acromioclavicular joint owes its security mainly to the coclavicular ligament. Owing to the slanting shape of the articular surfaces of this dislocation generally occurs upwards; that is to say, the acromial end of the clavicle placed above the acromion of the scapula. The displacement is often incomplete, ccount of the strong coracoclavicular ligaments, which remain untorn. The same ility exists, as in the sternoclavicular dislocation, in maintaining the end of the bone sition after reduction.

THE LIGAMENTS OF THE SCAPULA

he ligaments of the scapula (fig. 486) are the coraco-acromial, and the rior and inferior transverse.

The **coraco-acromial ligament** is a strong triangular band, extending een the coracoid process and the acromion. Its apex is attached to the e of the acromion just in front of the articular surface for the clavicle; its base to the whole length of the lateral border of the coracoid process. ligament, together with the coracoid process and the acromion, forms an for the protection of the head of the humerus. It sometimes consists o strong marginal bands and a thinner intervening portion, the two bands attached respectively to the apex and the base of the coracoid process, joining together at the acromion.

When the Pectoralis minor is inserted, as it is occasionally, into the ule of the shoulder-joint instead of into the coracoid process, the tendon e muscle passes between the two bands of the coraco-acromial ligament.

The **superior transverse ligament** (suprascapular ligament) converts the lar notch into a foramen, and is sometimes ossified. It is a thin and sciculus, narrower at the middle than at the extremities, which are attached e base of the coracoid process and the medial end of the scapular notch tively. The suprascapular nerve runs through the foramen; the trans- e scapular vessels cross over the ligament.

* *A Treatise on the Human Skeleton.*

CC-0. In Public Domain. Gurukul Kangri Collection, Haridwar

Digitized by Arya Samaj Foundation Chennai and eGangotri

The **inferior transverse ligament** (spinoglenoid ligament) is a membranous band, stretching from the lateral border of the spine of the scapula to the margin of the glenoid cavity. It forms an arch under which the transverse scapular vessels and suprascapular nerve enter the infraspinous fossa. It is frequently absent.

III. THE HUMERAL ARTICULATION OR SHOULDER-JOINT

The shoulder-joint (figs. 486 to 489) is an enarthrodial or ball-and-socket joint. The bones entering into its formation are the hemispherical head of the humerus and the shallow glenoid cavity of the scapula, a construction which allows of very considerable movement, while the joint itself is protected by

FIG. 487.—A section through the shoulder-joint.

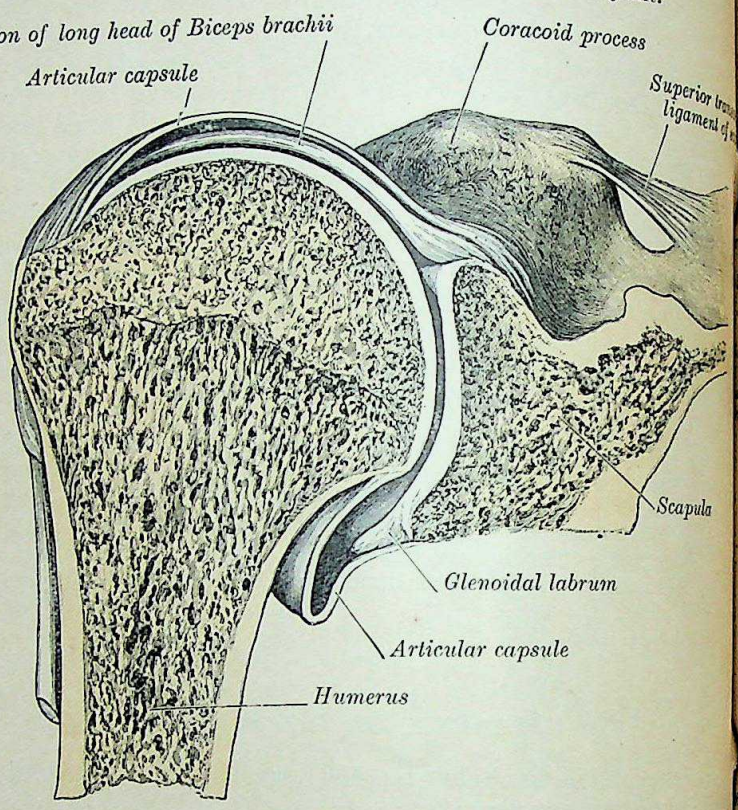

displacement, by the muscles which surround it. The joint is also protected above by an arch, formed by the coracoid process, the acromion, and the coraco-acromial ligament. The articular cartilage on the head of the humerus is thicker at the centre than at the circumference, the reverse being true with the articular cartilage of the glenoid cavity. The ligaments of articulation are :

The articular capsule.	The glenoidal labrum.
Coracohumeral.	Transverse humeral.

The **articular capsule** (figs. 486 to 488) envelops the joint, and is attached above, to the circumference of the glenoid cavity beyond the glenoidal labrum; below, to the anatomical neck of the humerus, approaching nearer to the articular cartilage at the upper than at the lower part of the neck. It is lax above and below than elsewhere, and is so remarkably loose and lax that the bones may be separated from each other for a distance of 2 or 3 cm. This evident provision for the great freedom of movement which is permitted by this articulation. It is strengthened, above, by the Supraspinatus; in front, by the long head of the Triceps brachii ; behind, by the tendons of the Infraspinatus and Teres minor; and in front, by the tendon of the Subscapularis.

CC-0. In Public Domain. Gurukul Kangri Collection, Haridwar

Digitized by Arya Samaj Foundation Chennai and eGangotri

are usually three openings in the capsule. One anteriorly, below the oid process, establishes a communication between the joint and a bursa th the tendon of the Subscapularis; another, between the tubercles of the us, gives passage to the long tendon of the Biceps brachii; the third, is not constant, is at the posterior part, between the joint and a bursal nder the tendon of the Infraspinatus.

hree supplemental bands (fig. 489) which are named the *glenohumeral onds*, strengthen the capsule. These are best seen by opening the posterior of the capsule of the joint and removing the head of the humerus. At scapular ends they are all attached to the upper part of the medial margin

ig. 488.—The articular capsule of the right shoulder-joint (distended). Anterior aspect. (From a specimen prepared by J. C. B. Grant.)

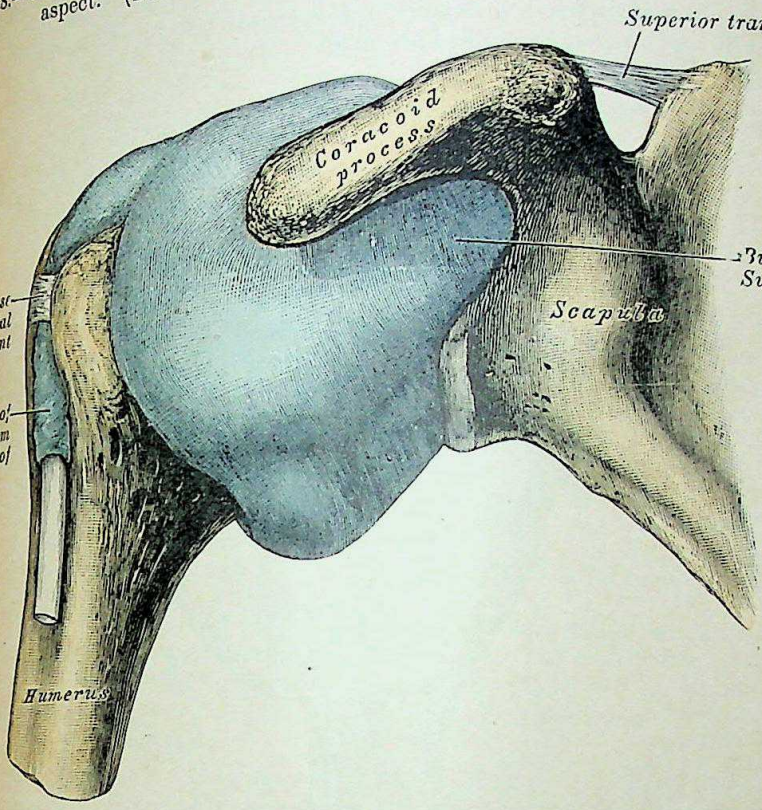

glenoid cavity and are intimately connected with the glenoidal labrum. superior band passes along the medial edge of the tendon of Biceps brachii attached to a small depression above the lesser tubercle of the humerus; middle band reaches the lower part of the lesser tubercle; the inferior band ds to the lower part of the anatomical neck of the humerus. In addition se, the capsule is strengthened in front by two bands, one derived from endon of the Pectoralis major, the other from the tendon of the Teres r.

he *synovial stratum* is reflected from the margin of the glenoid cavity over enoidal labrum; it is then continued over the inner surface of the capsule, overs the lower part and sides of the anatomical neck of the humerus as the articular cartilage on the head of the bone. The tendon of the long of the Biceps brachii passes through the fibrous stratum of the capsule s enclosed in a tubular sheath of the synovial stratum, which is reflected it from the summit of the glenoid cavity and is continued round the into the intertubercular sulcus as far as the surgical neck of the humerus 88).

he **coracohumeral ligament** is a broad band which strengthens the part of the capsule. It arises from the lateral border of the root of racoid process, and passes obliquely downwards and lateralwards to the of the greater tubercle of the humerus, blending with the tendon of

CC-0. In Public Domain. Gurukul Kangri Collection, Haridwar

Digitized by Arya Samaj Foundation Chennai and eGangotri

the Supraspinatus. The hinder and lower border of the ligament to the capsule; its anterior and upper border is free, and overlaps the lesser to the greater tubercle of the humerus; it converts the inter sulcus into a canal, and its attachment is always limited to that the bone which lies above the epiphysial line.

The **glenoidal labrum** (glenoid ligament) (fig. 489) is a fibrocartilage attached round the margin of the glenoid cavity. It is triangular the base being fixed to the circumference of the cavity, while the is thin and sharp. It is continuous above with the tendon of the of the Biceps brachii, which gives off two fasciculi to blend with tissue of the labrum. It deepens the articular cavity, and protects of the bone. Its attachment to the margin of the glenoid cavity is deficient in parts; the deficiency occurs most commonly at the upper part of the medial margin, and a small fringe of the synovial occasionally protrudes through the gap.

Fig. 489.—Interior of shoulder-joint. Lateral aspect.

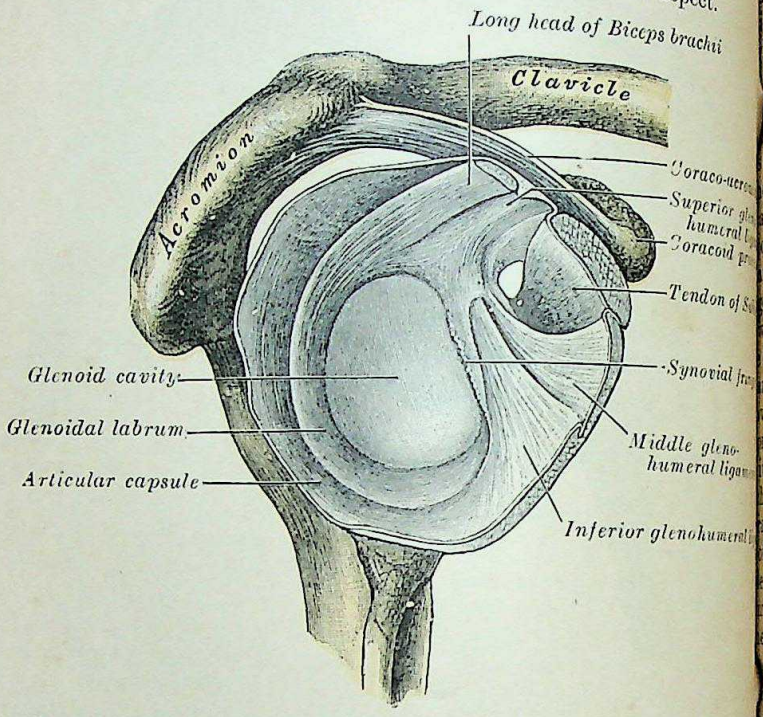

Bursæ.—The bursæ in the neighbourhood of the shoulder-joint are the (1) one is constantly found between the tendon of the Subscapularis and capsule: it communicates with the synovial cavity through an open front of the capsule; (2) one is sometimes found between the tendon of spinatus and the capsule; it occasionally opens into the joint; (3) a exists between the under surface of the Deltoideus and the capsule, but communicate with the joint: this bursa is prolonged under the acro coraco-acromial ligament, and intervenes between these structures and the (4) a large one is situated on the summit of the acromion; (5) one is found between the coracoid process and the capsule; (6) one exists be Coracobrachialis; (7) one lies between the Teres major and the long he Triceps brachii; (8) one is placed in front of, and another behind, the the Latissimus dorsi.

The *muscles* in relation with the joint are, above, the Supraspinatus the long head of the Triceps brachii; in front, the Subscapularis; be Infraspinatus and Teres minor; within, the tendon of the long head of brachii. The Deltoideus covers the articulation in front, behind, and

The *arteries* supplying the joint are derived from the anterior and humeral circumflex, and transverse scapular arteries; the *nerves*, from the (circumflex) and suprascapular nerves.

CC-0. In Public Domain. Gurukul Kangri Collection, Haridwar

Digitized by Arya Samaj Foundation Chennai and eGangotri

ovements.—The shoulder-joint is capable of flexion, extension, abduction, ion, circumduction, and rotation.

e most striking peculiarities in this joint are: 1. The large size of the head humerus in comparison with the depth of the glenoid cavity, even though the s supplemented by the glenoidal labrum. 2. The looseness of the capsule joint. 3. The intimate connexion of the capsule with the muscles attached tubercles of the humerus. 4. The peculiar relation of the tendon of the long f the Biceps brachii to the joint.

is in consequence of the relative sizes of the two articular surfaces, and the ess of the articular capsule, that the joint enjoys such free movement in all ons. When these movements of the arm are arrested in the shoulder-joint contact of the bony surfaces, and by the tension of the fibres of the capsule er with that of the muscles acting as accessory ligaments, the arm can be considerably farther by the movements of the scapula, involving, of motion at the sternoclavicular and acromioclavicular joints. These joints erefore to be regarded as accessory to the shoulder-joint (pp. 374 to 377). xtent of the scapular movements is very considerable, especially in extreme on of the arm, a movement best accomplished when the arm is thrown hat forwards and outwards, because the margin of the head of the humerus o means a true circle; the greatest diameter of the head is from the ercular groove, downwards, medialwards, and backwards, and the greatest n of the arm can be obtained by rolling its articular surface in the direction measurement.

e looseness of the capsule is so great that the arm will fall 2 or 3 cm. from pula when the muscles are dissected from the capsule, and an opening made o counteract the atmospheric pressure. The movements of the joint, there- re not regulated by the capsule so much as by the surrounding muscles, an ement which 'renders the movements of the joint much more easy than ould otherwise have been, and permits a swinging, pendulum-like vibration limb when the muscles are at rest' (Humphry). The fact, also, that in all ry positions of the joint the capsule is not put on the stretch, enables the arm e freely in all directions. Extreme movements are checked by the tension opriate portions of the capsule, as well as by the interlocking of the bones. t is said that 'abduction is checked by the contact of the great tuberosity e upper edge of the glenoid cavity; adduction by the tension of the coraco- al ligament' (Beaunis and Bouchard). Cleland * maintains that the limita- t movement at the shoulder-joint are due to the structure of the joint itself, enoidal labrum fitting, in different positions of the elevated arm, into the ical neck of the humerus.

e scapula is capable of being moved upwards and downwards, and forwards kwards, and, by a combination of these movements, circumducted on the he chest. The mobility of the scapula is very considerable, and greatly he movements of the arm at the shoulder-joint. Thus, in raising the arm e side, the Deltoideus and Supraspinatus can only lift it to a right angle e trunk, the further elevation of the limb being effected by the Trapezius ratus anterior moving the scapula on the wall of the chest. This mobility ecial importance in ankylosis of the shoulder-joint, the movements of the compensating to a very great extent for the immobility of the joint.

kart † has pointed out that in abducting the arm and raising it above the he scapula rotates throughout the whole movement with the exception of space at the beginning and at the end; that the humerus moves on the not only while passing from the hanging to the horizontal position, but travelling upwards as it approaches the vertical above; that the clavicle not only during the second half of the movement but in the first as well, to a less extent—i.e. the scapula and clavicle are concerned in the first stage as in the second; and that the humerus is partly involved in the second as chiefly in the first.

peculiar relations of the tendon of the long head of the Biceps brachii to lder-joint appear to subserve various purposes. In the first place, by its on with both the shoulder and elbow the muscle harmonises the action two joints, and acts as an elastic ligament during all the movements

* *Journal of Anatomy and Physiology*, vol. xxiii.

† *Journal of Anatomy and Physiology*, vol. xviii.

CC-0. In Public Domain. Gurukul Kangri Collection, Haridwar

Digitized by Arya Samaj Foundation Chennai and eGangotri

which occur at these articulations. It strengthens the upper part of the joint, and prevents the head of the humerus from being pressed up against the acromion when the Deltoideus contracts; it thus fixes the head of the humerus as the centre of motion in the glenoid cavity. By its passage along the bicipital sulcus it assists in steadying the head of the humerus in the various movements of the arm. When the arm is raised from the side the Biceps brachii, the Supraspinatus and the Infraspinatus in rotating the head of the humerus in the glenoid cavity. It also holds the head of the bone firmly in contact with the glenoid cavity, and prevents it slipping over the lower edge, and also from being pulled by the action of the Latissimus dorsi and Pectoralis major, as in climbing, and many other movements.

Muscles producing the movements.—The muscles moving the shoulder-joint are divided into: (*a*) those acting on the shoulder-girdle, and (*b*) those acting on the shoulder-joint.

(*a*) **Muscles acting on the shoulder-girdle.**—The chief effect of these muscles is to displace the point of the shoulder, either by pulling directly on the shoulder-girdle or by rotating the scapula. The terms elevation, depression, etc., therefore refer to the point of the shoulder.

Elevation.—Trapezius, Levator scapulæ, Serratus anterior.
Depression.—Pectoralis minor, Rhomboideus major, Subclavius.
Forward movement.—Pectoralis minor, Serratus anterior, Subclavius.
Backward movement.—Trapezius, Levator scapulæ, Rhomboidei.

(*b*) **Muscles acting on the shoulder-joint.**

Flexion.—Subscapularis, Deltoideus (anterior part), Pectoralis major (clavicular head), Coracobrachialis, Biceps brachii.
Extension.—Infraspinatus, Teres minor, Teres major, Latissimus dorsi, Triceps brachii (long head).
Abduction.—Supraspinatus, Deltoideus.
Adduction.—Subscapularis, Infraspinatus, Teres minor, Pectoralis major, Latissimus dorsi, Teres major, Coracobrachialis, Biceps brachii, Triceps brachii.
Rotation inwards.—Subscapularis, Pectoralis major, Latissimus dorsi, Teres major.
Rotation outwards.—Infraspinatus, Teres minor, Deltoideus (posterior).

Applied Anatomy.—Owing to the construction of the shoulder-joint and the kind of movement which it enjoys, as well as in consequence of its exposed situation, it is more frequently dislocated than any other joint. Dislocation occurs when the arm is forced, and when, therefore, the head of the humerus presses against the lower and front part of the capsule, which is the thinnest and least supported part of the ligament. The rupture of the capsule almost invariably takes place in this situation, and through it the head of the bone escapes, so that the dislocation in most instances is primarily subglenoid. The head of the bone does not usually remain in this situation, between the tendons of Subscapularis and the Triceps brachii, but generally assumes some other position, which varies according to the direction and amount of force producing the dislocation and the relative strength of the muscles in front of and behind the joint. As the muscles in the back are stronger than those in front, and especially since the long head of the Triceps brachii prevents the bone from passing backwards, dislocation forwards is much more common. The most frequent position which the head of the humerus ultimately assumes is on the front of the neck of the scapula, beneath the coracoid process, and hence is subcoracoid. Occasionally, in consequence of a greater amount of force being brought to bear on the limb, the head is driven farther medialwards, and rests on the upper part of the front of the chest, beneath the clavicle (subclavicular). Sometimes it remains in the position in which it was primarily displaced, resting on the axillary border of the scapula (subglenoid), and rarely it passes backwards and remains in the infraspinous fossa, beneath the spine (subspinous). If, after the dislocation has been reduced, motion of the arm is prevented, the dislocation cannot recur.

Synovitis is attended with effusion into the joint, and when this occurs the joint is evenly distended, and the contour of the joint rounded. Special projections occur at the sites of the openings in the capsule. Thus a swelling may appear just medial to the lesser tubercle, from effusion into the bursa beneath the Subscapularis; or a swelling which is sometimes bilobed may be seen in the interval between the Teres minor and Pectoralis major, from effusion into the diverticulum which runs down the tubercular groove with the tendon of the Biceps brachii. The effusion into the joint cavity can be best ascertained by examination from the axilla, where a soft fluctuating swelling may be felt. In cases of septic synovitis, where

CC-0. In Public Domain. Gurukul Kangri Collection, Haridwar

Digitized by Arya Samaj Foundation Chennai and eGangotri

ed, the opening should be made in front, over the most prominent point of the ng. After the pus has been evacuated a counter-opening should be made behind, so nsure efficient drainage. In making this counter-opening care should be taken not re the axillary nerve, which here lies in contact with the joint-capsule.

e bursa under the Deltoideus may be distended with fluid; this condition may be en for effusion into the joint.

cision of the shoulder-joint may be required in cases of arthritis (especially the ulous form) which have gone on to destruction of the articulation; in compound tions and fractures, particularly those arising from gunshot injuries, in which has been extensive injury to the head of the bone; in some cases of old unreduced ation, where there is much pain. The operation is best performed by making an n from the middle of the coraco-acromial ligament down the arm for about 7 or , this will expose the intertubercular groove containing the tendon of the Biceps , which should be hooked out of the way. The articular capsule is freely opened, a muscles attached to the greater and lesser tubercles of the humerus are stripped th the capsule, without dividing their attachments to the latter. The head of the an then be thrust out of the wound and sawn off; or divided with a narrow saw and subsequently removed. The section should be made, if possible, just below icular surface, so as to leave the bone as long as possible.

hen the shoulder-joint is ankylosed, the loss of movement in the joint is partly nsated for by increased mobility of the scapula. In treating conditions of the er-joint likely to lead to ankylosis the humerus should be kept in the position it s when the palm of the hand is placed on the back of the neck, *i.e.* abducted, rotated inwards, and flexed anteriorly, so as to make full use of this compensating y of the scapula.

IV. THE CUBITAL ARTICULATION OR ELBOW-JOINT

e elbow-joint includes three articulations :—(1) *humero-ulnar*, between rochlea of the humerus and the semilunar notch of the ulna, (2) *humero-* between the capitulum of the humerus and the fovea on the head of dius, and (3) *proximal radio-ulnar*, where the circumference of the radial is retained in the circle formed by the annular ligament and the radial of the ulna (see p. 387). All three are included in a common articular le.

e humero-ulnar and humeroradial articulations together form a ginglymus ge-joint, the ligaments of which are :

The articular capsule.	Ulnar collateral.	Radial collateral.

e **articular capsule** (figs. 492 to 494).—The anterior part of the articular le is a broad and thin fibrous layer. It is attached, above, to the front of dial epicondyle and to the front of the humerus immediately above the l and radial fossæ ; below, to the anterior surface of the coronoid process ulna and to the annular ligament (p. 387), being continuous on either with the collateral ligaments. Its superficial fibres pass obliquely from edial epicondyle of the humerus to the annular ligament. The middle vertical in direction, pass from the upper part of the coronoid depression come partly blended with the preceding, but are inserted mainly into the or surface of the coronoid process. The deep or transverse set intersects at right angles. It is in relation, in front, with the Brachialis, except at st lateral part.

e posterior part of the articular capsule is thin and membranous, and s of transverse and oblique fibres. Above, it is attached to the humerus diately behind the capitulum and close to the medial margin of the lea, to the margins of the olecranon fossa, and to the back of the lateral ndyle some little distance from the trochlea. Below, it is fixed to the and lateral margins of the olecranon, to the posterior part of the annular nt, and to the ulna behind the radial notch. The transverse fibres a strong fasciculus which bridges the olecranon fossa ; under cover of and a pouch of the synovial stratum and a pad of fat are displaced e upper part of the fossa when the joint is extended. In the fat are a attered fibrous bundles which pass from the deep surface of the transverse to the upper part of the fossa. It is in relation, behind, with the tendon e Triceps brachii and the Anconæus.

CC-0. In Public Domain. Gurukul Kangri Collection, Haridwar

Digitized by Arya Samaj Foundation Chennai and eGangotri

The *synovial stratum* (figs. 490, 491) is very extensive. It ex the margin of the articular surface of the humerus, and lines the radial and olecranon fossæ on that bone; it is reflected over the d of the capsule and lines the deep surface of the annular ligament. into the joint-cavity between the radius and ulna is a crescentic synovial stratum, suggesting the division of the joint into two humeroradial, the other the humero-ulnar.

Fig. 490.—The articular capsule of the left elbow-joint (distended). Anterior aspect. (From a specimen prepared by J. C. B. Grant.)

Fig. 491.—The articular ca left elbow-joint (distended). aspect of the specimen rep fig. 490.

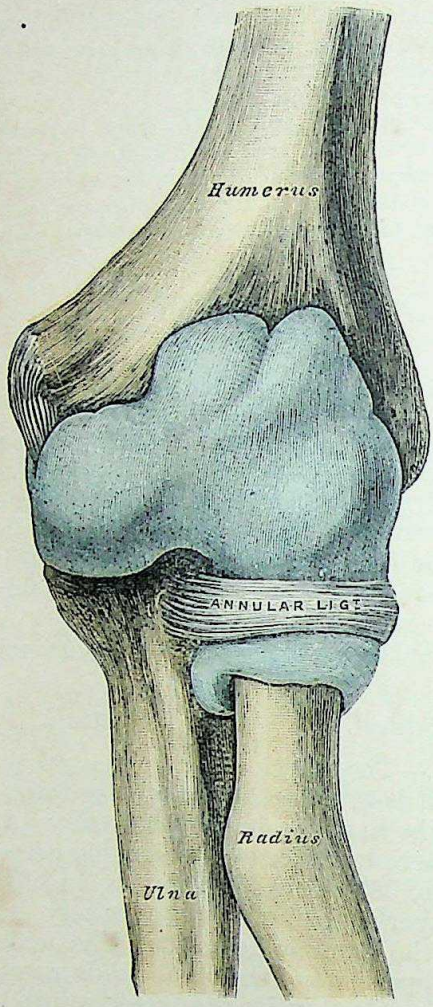

Between the fibrous and the synovial strata of the articular ca three masses of fat. The largest, over the olecranon fossa, is press fossa by the Triceps brachii during flexion; the second, over the coron and the third, over the radial fossa, are pressed by the Brachialis i respective fossæ during extension.

The **ulnar collateral ligament** (internal lateral ligament) (fig. 4 thick triangular band consisting of two portions, an anterior and a p united by a thinner intermediate portion. The *anterior portion*, obliquely forwards, is attached, above, by its apex, to the front p medial epicondyle of the humerus; and, below, by its broad base, to margin of the coronoid process. The *posterior portion*, also of triang is attached, above, by its apex, to the lower and back part of the epicondyle; below, to the medial margin of the olecranon. Betwe two bands a few intermediate fibres descend from the medial epicond *oblique band*, which stretches between the olecranon and coronoid p

CC-0. In Public Domain. Gurukul Kangri Collection, Haridwar

Digitized by Arya Samaj Foundation Chennai and eGangotri

converts the depression on the medial margin of the semilunar notch into framen, through which the intra-articular pad of fat is continuous with extra-articular fat on the medial side of the joint. The ulnar collateral ment is in relation with the Triceps brachii and Flexor carpi ulnaris and ulnar nerve, and gives origin to part of the Flexor digitorum sublimis.

FIG. 492.—A sagittal section through the left elbow-joint.

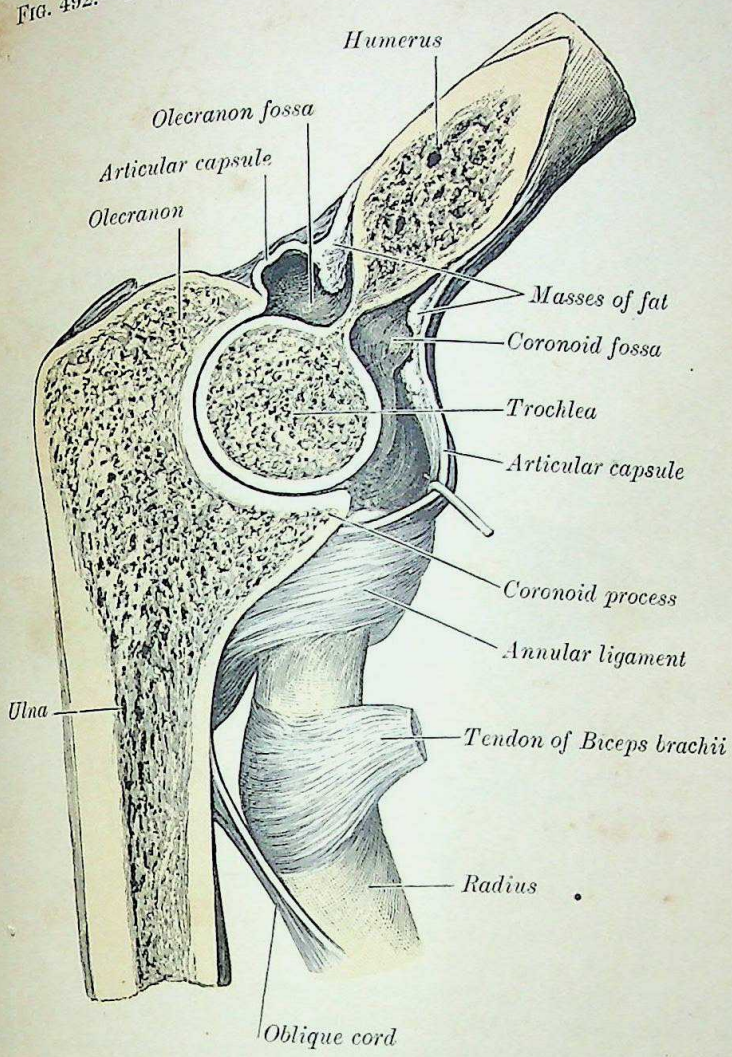

he radial collateral ligament (external lateral ligament) (fig. 494), a short narrow fibrous band, less distinct than the ulnar collateral, is attached, e, to the lower part of the lateral epicondyle of the humerus, and below e annular ligament, while some of its most posterior fibres pass over that ent to be inserted into the lateral margin of the ulna. It is intimately ed with the origins of the Supinator and Extensor carpi radialis brevis.

muscles in relation with the joint are, in front, the Brachialis; behind, the s brachii and Anconæus; laterally, the Supinator, and the common tendon gin of the extensor muscles; medially, the common tendon of origin of the muscles, and the Flexor carpi ulnaris.

arteries supplying the joint are derived from the anastomosis between the ia and the superior and inferior ulnar collateral branches of the brachial with the anterior, posterior, and interosseous recurrent branches of the rtery, and the recurrent branch of the radial artery. These vessels form tomotic network around the joint.

nerves of the joint consist of a twig from the ulnar nerve, as the latter between the medial condyle and the olecranon; a filament from the branch nsculocutaneous nerve to the Brachialis, and two from the median nerve.

movements at the elbow-joint are described on p. 388.

CC-0. In Public Domain. Gurukul Kangri Collection, Haridwar

Digitized by Arya Samaj Foundation Chennai and eGangotri

FIG. 493.—The left elbow-joint. Medial aspect.

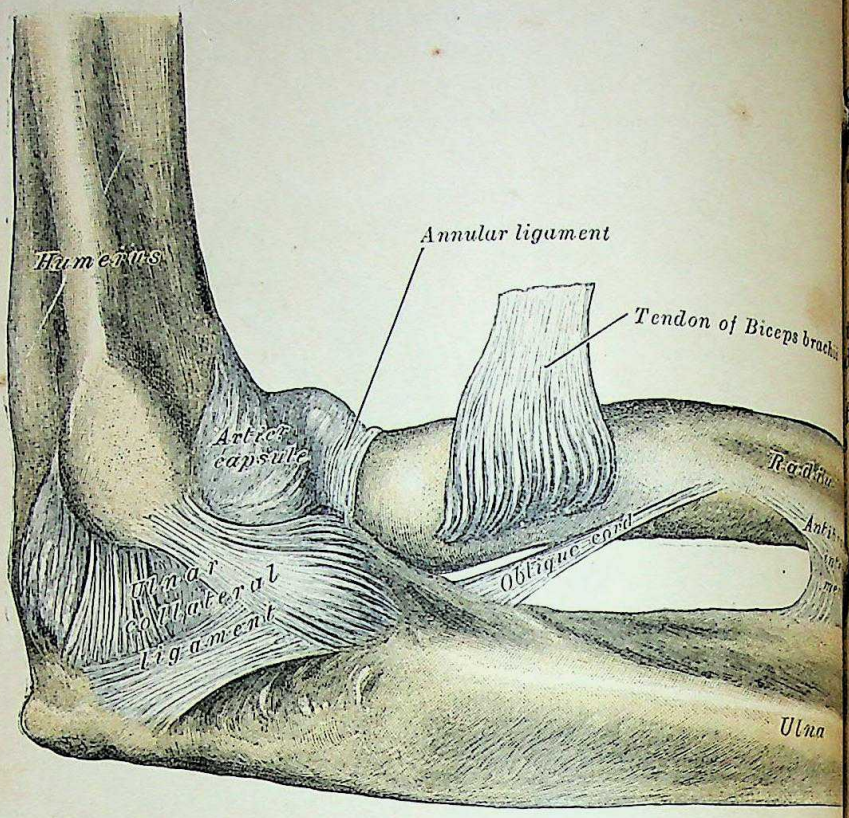

FIG. 494.—The left elbow-joint. Lateral aspect.

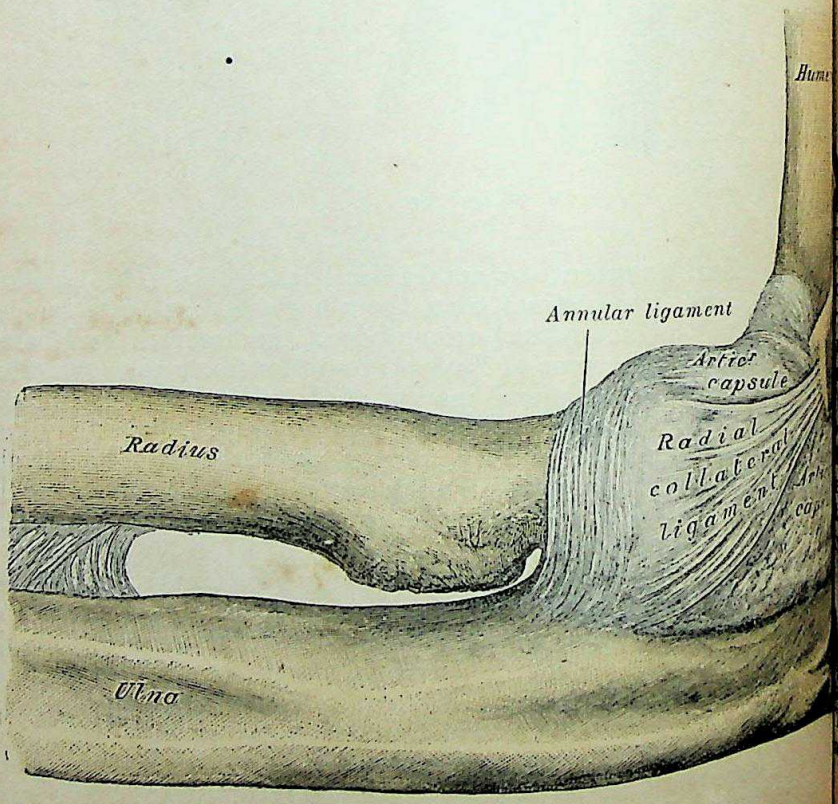

CC-0. In Public Domain. Gurukul Kangri Collection, Haridwar

Digitized by Arya Samaj Foundation Chennai and eGangotri

V. THE RADIO-ULNAR ARTICULATIONS

The articulation of the radius with the ulna is effected by ligaments which nect together the extremities and also the bodies of these bones. The aments may, consequently, be subdivided into three sets: 1, those of the ximal radio-ulnar articulation; 2, the middle radio-ulnar ligaments; those of the distal radio-ulnar articulation.

1. The Proximal Radio-ulnar Articulation

This articulation forms a trochoid or pivot-joint between the circumference the head of the radius and the ring formed by the radial notch of the ulna the annular ligament.

The **annular ligament** (orbicular ligament) (fig. 495) is a strong band fibres, which encircles the head of the radius, and retains it in contact with radial notch of the ulna. It forms about four-fifths of the osseofibrous

Fig. 495.—The annular ligament of the left radius. Superior aspect. The head of the radius has been sawn off and the bone dislodged from the ligament.

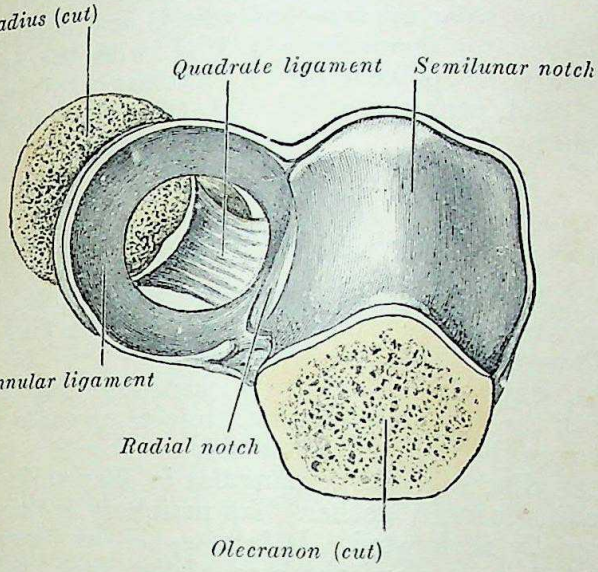

and is attached to the anterior and posterior margins of the radial notch; of its lower fibres are continued round below the notch and form at this a complete fibrous ring. Its upper border blends with the radial collateral ment and the anterior and posterior parts of the articular capsule of the r-joint, while from its lower border a thin loose membrane passes to be ched to the neck of the radius. A thickened band which extends from the ior border of the annular ligament below the radial notch to the neck of adius is known as the *quadrate ligament*. The *superficial surface* of the ular ligament is strengthened by the radial collateral ligament of the elbow, affords origin to part of the Supinator. Its *deep surface* is lined with a vial stratum which is continuous with that of the elbow-joint.

Movements.—The movements allowed in this articulation are limited to rotatory ements of the head of the radius within the ring formed by the annular ligament e radial notch of the ulna; rotation forwards being called *pronation*; rotation wards, *supination*.

2. The Middle Radio-ulnar Union

e bodies of the radius and ulna are connected by the oblique cord and tibrachial interosseous membrane.

e oblique cord (fig. 493) is a small, flattened band, extending from the l side of the tubercle of the ulna at the base of the coronoid process to

CC-0. In Public Domain. Gurukul Kangri Collection, Haridwar

Digitized by Arya Samaj Foundation Chennai and eGangotri

the radius a little below the radial tuberosity and its fibres run at right a
those of the interosseous membrane. It is sometimes wanting.

The **antibrachial interosseous membrane** is a broad and thin sh
fibres of which slant obliquely downwards and medialwards from the
osseous crest of the radius to that of the ulna; the lower part of the ma
is attached to the posterior of the two lines into which the interosseo
of the radius divides. Two or three bands are occasionally found on the
surface of this membrane; their fibres descend obliquely from the ulna t
the radius, i.e. at right angles to the other fibres. The membrane is d
above, commencing about 2 or 3 cm. below the tuberosity of the rad
broader in the middle than at either end; and presents an oval ape
little above its lower margin, for the passage of the volar interosseous
to the back of the forearm. Between its upper border and the oblic
is a gap, through which the dorsal interosseous vessels pass. The me
connects the bones, and increases the extent of surface for the attach
the deep muscles of the forearm. It also transmits to the ulna and
to the humerus any force acting upwards through the hand and rad
is relaxed in complete pronation or supination, and is tense when the
midway between the prone and supine positions. *In front*, the memb
in relation, in its upper three-fourths, with the Flexor pollicis longus
radial side, and with the Flexor digitorum profundus on the ulnar side; b
these muscles are the volar interosseous vessels and nerve; in its low
fourth with the Pronator quadratus; *behind*, with the Supinator, Ab
pollicis longus, Extensor pollicis brevis, Extensor pollicis longus, E
indicis proprius; and, near the wrist, with the volar interosseous arte
dorsal interosseous nerve.

3. The Distal Radio-ulnar Articulation

This is a pivot-joint formed between the head of the ulna and th
notch of the lower end of the radius; the surfaces are enclosed in an a
capsule and held together by an articular disc.

The **articular capsule** is slightly thickened in front and behind;
it is lax, and with the synovial stratum, projects upwards as a pouch (
sacciformis) between the radius and the ulna.

The **articular disc** (fig. 498), triangular in shape, binds the lower
the ulna and radius firmly together. Its periphery is thicker than its
which is occasionally perforated. It is attached by its apex to a dep
between the styloid process and the head of the ulna; and by its base
is thin, to the prominent edge which separates the ulnar notch from the
articular surface of the radius. Its margins are united to the ligaments
wrist-joint. Its *proximal surface*, smooth and concave, articulates w
head of the ulna. Its *distal surface*, also smooth and concave, forms a
the radiocarpal joint and articulates with the medial part of the lunate
when the hand is adducted it articulates with the triquetral bone. B
its surfaces is clothed with a synovial stratum: the proximal, with that
distal radio-ulnar articulation; the distal, with that of the radiocarpal

Movements.—The movements of the three joints within the elbow s
studied together. The combination of the movements of flexion and exte
the forearm with those of pronation and supination of the hand, which is
by the two being performed at the same joint, is essential to the accurac
various minute movements of the hand.

The portion of the joint between the ulna and humerus is a simple hin
and allows of movements of flexion and extension only, but owing to the
of the trochlea of the humerus, this movement does not take place in the
posterior plane of the body of the humerus. When the forearm is exten
supinated, the axes of the arm and forearm are not in the same line; the arm
an obtuse angle with the forearm, the hand and forearm being directed
wards. During flexion, however, the forearm and the hand tend to appro
middle line of the body, and thus enable the hand to be easily carried to
The accurate adaptation of the trochlea of the humerus, with its promin
depressions, to the semilunar notch of the ulna, prevents any lateral mov

CC-0. In Public Domain. Gurukul Kangri Collection, Haridwar

Digitized by Arya Samaj Foundation Chennai and eGangotri

The joint between the head of the radius and the capitulum of the humerus is arthrodial joint. The bony surfaces would of themselves constitute an enarthrosis and allow of movement in all directions, were it not for the annular ligament, which the head of the radius is bound to the radial notch of the ulna, and which prevents any lateral separation of the two bones. It is to the same ligament that the head of the radius owes its security from dislocation, which would otherwise tend to occur, from the shallowness of the cup-like surface on the head of the radius. In fact, but for this ligament, the tendon of the Biceps brachii would be liable to pull the head of the radius out of the joint. The head of the radius is not in complete contact with the capitulum of the humerus in all positions of the joint. The capitulum occupies only the anterior and inferior surfaces of the lower end of the humerus, so that in complete extension a part of the radial head can be easily felt projecting at the back of the articulation. In full flexion the movement of the radial head is hampered by the compression of the surrounding soft parts, and that the freest rotatory movement of the radius on the humerus (pronation and supination) takes place in semiflexion, in which position the two articular surfaces are in most intimate contact. Flexion and extension of the elbow-joint are limited by the tension of the structures on the front and back of the joint; the limitation of flexion is also aided by the soft structures of the arm and forearm coming into contact.

In any position of flexion or extension, the radius, carrying the hand with it, is rotated in the proximal radio-ulnar joint. The hand is directly articulated with the lower surface of the radius only, and the ulnar notch on the lower end of the radius travels round the lower end of the ulna. The latter bone is excluded from the wrist-joint by the articular disc. Thus, rotation of the head of the radius about an axis passing through the centre of the capitulum of the humerus imparts similar movement to the hand through a very considerable arc.

The movements in the distal radio-ulnar articulation consist of rotation of the lower end of the radius round an axis which passes through the centre of the head of the ulna. When the radius rotates forwards, *pronation* of the forearm and hand is the result; and when backwards, *supination*. It will thus be seen that in pronation and supination the radius describes the segment of a cone, the axis of which extends from the centre of the head of the radius to the middle of the head of the ulna. In this movement the head of the ulna is not stationary, but describes a curve in a direction opposite to that taken by the head of the radius. This, however, is not to be regarded as a rotation of the ulna—the curve which the head of the bone describes is due to a combined anteroposterior and rotatory movement taking place at the elbow-joint.

Muscles producing the movements.—These muscles may be grouped as (*a*) those acting on the humero-ulnar and humeroradial joints, and (*b*) those acting on the radio-ulnar joints.

(*a*) **Muscles acting on the humero-ulnar and humeroradial joints :**
Flexion.—Brachialis, Brachioradialis, Biceps brachii, Pronator teres.
Extension.—Triceps brachii, Anconæus.

(*b*) **Muscles acting on the radio-ulnar joints :**
Pronation.—Pronator teres, Pronator quadratus.
Supination.—Supinator, Biceps brachii.

Applied Anatomy.—From the breadth of the elbow-joint, and the manner in which the articular surfaces are interlocked, and also on account of the strong collateral ligaments and the support which the joint derives from the mass of muscles attached to the condyles of the humerus, lateral displacement of the bones is very uncommon; whereas anteroposterior dislocation, on account of the shortness of the anteroposterior diameter, thickness of the anterior and posterior parts of the articular capsule, and the want of support of muscles, occurs much more frequently. Dislocation backwards takes place when the forearm is in a position of extension, and forwards when in a position of flexion. In the extended position, the coronoid process is not locked into the coronoid fossa, but loosely prevents displacement forwards. On the other hand, during flexion, the coronoid process is in the coronoid fossa, and prevents dislocation backwards, while the olecranon, having left the olecranon fossa, is not so efficient in preventing a forward displacement. For the production of lateral dislocation it is necessary that the force should be applied laterally and that either the humerus or the bones of the forearm should be fixed. This is probably the chief reason why this dislocation is so rare; when it does occur it is generally incomplete. Dislocation of the elbow-joint is common in children.

CC-0. In Public Domain. Gurukul Kangri Collection, Haridwar

Digitized by Arya Samaj Foundation Chennai and eGangotri

In lesions of this joint it is often difficult to ascertain the exact nature of the ... by x-ray examination.

The elbow-joint is occasionally the seat of acute synovitis. The joint ... becomes distended with fluid, the bulging showing itself principally around th... in consequence of the laxness of the articular capsule. Again, there is often ... just above the head of the radius, in the line of the radiohumeral joint, or the ... may assume a fusiform appearance. There is not generally much swelling ... of the joint, though sometimes deep-seated fulness beneath the Brachialis ... When suppuration occurs the abscess usually points at one or other border of ... brachii; occasionally the pus discharges itself in front, near the insertion of the ... In cases of suppurative synovitis, incisions should be made into the joint on ... of the olecranon, care being taken to avoid wounding the ulnar nerve on the ...

The most useful position in which to have the elbow-joint ankylosed is ge... acute angle, but there are certain occupations, such as those that necessitate ... barrow, when the limb is more useful with the joint ankylosed at an obtuse ang... both elbow-joints are ankylosed it is important that one should be at an acute ... the other at an obtuse angle.

Excision of the elbow is principally required for one of three conditions—... culous arthritis, injury and its results, and faulty ankylosis—but may be ne... some other rarer conditions, such as disorganising arthritis after pyæmia and ... dislocations. The operation is best performed by a vertical incision down the ... joint; a straight incision is made about 10 cm. long, the mid-point of which is ... with and a little to the medial side of the tip of the olecranon. This incision ... down to the bone, through the substance of the Triceps brachii. The operator ... the soft parts with his thumb-nail, separates them from the bone with the ... knife. In doing this there are two structures which he should carefully avoid ... nerve, which as it courses down between the medial epicondyle and the olec... parallel with, but on the medial side of, the incision; and the prolongat... Triceps brachii into the deep fascia of the forearm over the Anconæus. After ... bones and dividing the collateral and posterior ligaments, the forearm should ... flexed and the ends of the bones turned out and sawn off. The turning out of ... the bones is rendered easier by first cutting off the olecranon with a pair of ... forceps. The section of the humerus should be through the base of the epicon... of the ulna and radius should be just below the level of the radial notch of the ... the neck of the radius. The synovial stratum which extends on to the neck of ... must be thoroughly removed when diseased. It is most important to ... continuity of the Triceps brachii with the deep fascia of the forearm, so as to ... power of extension in the new joint.

Dislocation of the head of the radius alone is a not uncommon accident, ... most frequently in young persons from falls on the hand when the forearm is ... and supinated, the head of the bone being displaced forward. It is attended ... of the annular ligament. Occasionally a peculiar injury, which is suppose... subluxation, occurs in young children. It is believed that the head of the ... displaced downwards in the annular ligament, the upper border of which becom... over the head of the radius, between it and the capitulum of the humerus; the ... of the head of the radius in the child predisposes to this injury. The forearm ... fixed in a position of semiflexion, midway between supination and pronation, ... pain is complained of upon any attempt to move the joint. The synovial strat... proximal radio-ulnar joint is directly continuous with that of the elbow-joint, ... fore, any septic or tuberculous disease which affects the latter also involves th... joint. The proximal radio-ulnar joint is always removed in an excision of the ... disease (see preceding paragraph); for conditions other than disease excision of ... end of the humerus, without the removal of any part of the radius or ulna.

VI. THE RADIOCARPAL ARTICULATION OR WRIST-JOINT

The radiocarpal articulation or wrist-joint (figs. 496, 497) is a ... articulation. The parts forming it are the distal end of the radius ... surface of the articular disc above; and the navicular, lunate, and ... bones below. The articular surface of the radius and the distal surf... articular disc form together a transversely elliptical concave surf... *receiving cavity*. The proximal articular surfaces of the navicular, lun... triquetral bones form a smooth convex surface, the *condyle*, which is ... into the concavity. The joint is surrounded by an articular capsule ... *synovial stratum* of the capsule is usually distinct from that of the dist... ulnar joint and from that of the carpal joints; the *fibrous stratum* is stren... by the following ligaments:

Volar and dorsal radiocarpal. Ulnar and radial collater...

CC-0. In Public Domain. Gurukul Kangri Collection, Haridwar

Digitized by Arya Samaj Foundation Chennai and eGangotri

The volar radiocarpal ligament (fig. 496) is a membranous band, ched above to the anterior margin of the distal end of the radius, to its id process, and to the front of the distal end of the ulna; its fibres pass wards and medialwards to be attached to the volar surfaces of the navi- lunate, and triquetral bones, some being continued to the capitate bone.

FIG. 496.—The ligaments of the left wrist and metacarpus. Volar aspect.

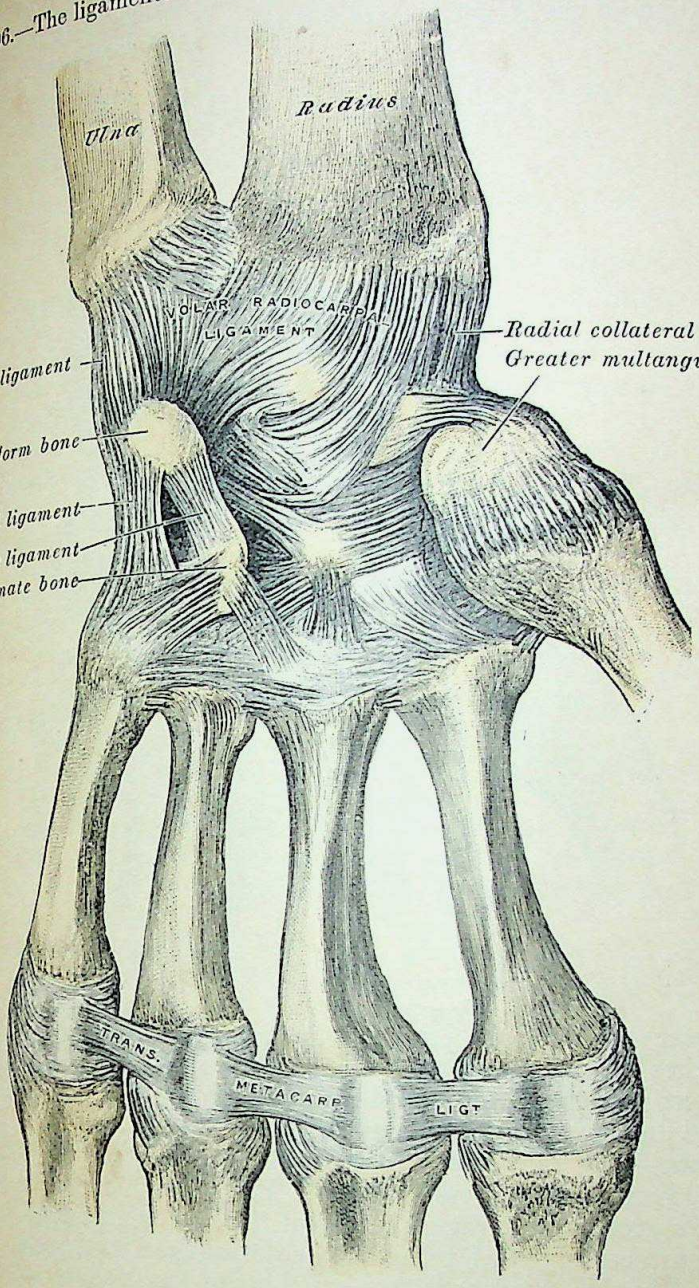

addition to this broad membrane, there is a rounded fasciculus, superficial the rest, which reaches from the base of the styloid process of the ulna to lunate and triquetral bones. The ligament is perforated by apertures for the sage of vessels, and is in relation, in front, with the tendons of the Flexor orum profundus and Flexor pollicis longus; behind, it is closely adherent to anterior border of the articular disc of the distal radio-ulnar articulation.

The dorsal radiocarpal ligament (fig. 497), less thick and strong than volar, is attached, above, to the posterior border of the distal end of the us; its fibres are directed obliquely downwards and medialwards, and are d, below, to the dorsal surfaces of the navicular, lunate, and triquetral es, being continuous with those of the dorsal intercarpal ligaments. It is relation, behind, with the extensor tendons of the fingers; in front, it ended with the articular disc of the distal radio-ulnar articulation.

CC-0. In Public Domain. Gurukul Kangri Collection, Haridwar

Digitized by Arya Samaj Foundation Chennai and eGangotri

The **ulnar collateral ligament** (internal lateral ligament) (figs. is attached to the end of the styloid process of the ulna; it divides fasciculi, one of which is fixed to the medial side of the triquetral other to the pisiform bone.

The **radial collateral ligament** (external lateral ligament) (figs. extends from the tip of the styloid process of the radius to the radial navicular bone, some of its fibres being prolonged to the greater mu bone. It is in relation with the radial artery, which separates the from the tendons of the Abductor pollicis longus and Extensor pollicis

FIG. 497.—The ligaments of the left wrist. Dorsal aspect.

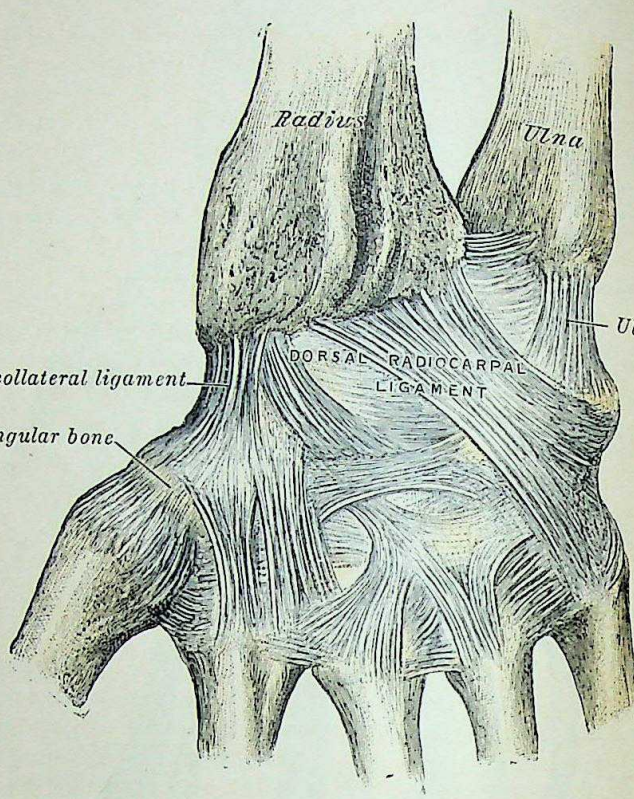

The *arteries* supplying the joint are the volar interosseous, the volar and carpal branches of the radial and ulnar, the volar and dorsal metacarpal some recurrent branches from the deep volar arch. The *nerves* are derived the volar and dorsal interosseous nerves.

Movements.—The movements permitted in this joint are flexion, ext abduction, adduction, and circumduction. Flexion and extension are the mo and of these a greater amount of extension than of flexion is permitted, sin articulating surfaces extend farther on the dorsal than on the volar surfaces carpal bones. In this movement the carpal bones rotate on a transverse axis between the tips of the styloid processes of the radius and ulna. Adduc ulnar flexion, and abduction or radial flexion are also permitted. The for considerably greater in extent than the latter on account of the shortness styloid process of the ulna, abduction being soon limited by the contact of the process of the radius with the greater multangular bone. In this movem carpus revolves upon an anteroposterior axis drawn through the centre of the Finally, circumduction is permitted by the combined and consecutive move of adduction, extension, abduction, and flexion. No rotation is possible, b effect of rotation is obtained by the pronation and supination of the radius ulna.

* H. M. Johnston (*Journal of Anatomy and Physiology*, vol. xli.) maintains that in u radial flexion only slight lateral movement occurs at the radiocarpal joint, and that in c flexion and extension of the hand there is a small degree of ulnar flexion at the radiocarpal

CC-0. In Public Domain. Gurukul Kangri Collection, Haridwar

Digitized by Arya Samaj Foundation Chennai and eGangotri

VII. THE INTERCARPAL ARTICULATIONS

These articulations may be subdivided into three sets: (1) those of the imal row of carpal bones; (2) those of the distal row of carpal bones; (3) those of the two rows with each other.

1. The Articulations of the Proximal Row of Carpal Bones

These are arthrodial joints. The navicular, lunate, and triquetral are nected by dorsal, volar, and interosseous ligaments.

The **dorsal and volar ligaments**, two of each, are placed transversely ween the bones of the first row; they connect the navicular and lunate es, and the lunate and triquetral bones. The volar ligaments are weaker n the dorsal.

The **interosseous ligaments** (fig. 498) are two narrow bundles, one con- ting the lunate and navicular bones, the other the lunate and triquetral es. They are on a level with the proximal surfaces of these bones, and n part of the convex articular surface of the radiocarpal joint.

The ligaments of the pisiform bone are: an articular capsule, and the piso- te and pisometacarpal ligaments.

The **articular capsule** is thin and connects the pisiform to the triquetral. synovial stratum is distinct from that of the other carpal joints.

The **pisohamate ligament** connects the pisiform and hamate bones, and **pisometacarpal ligament** joins the pisiform bone to the base of the fifth tacarpal bone (fig. 496). These two ligaments are, in reality, prolonga- s of the tendon of the Flexor carpi ulnaris.

2. The Articulations of the Distal Row of Carpal Bones

These also are arthrodial joints; the bones are connected by dorsal, volar, interosseous ligaments.

The **dorsal and volar ligaments**, each three in number, extend transversely n one bone to another; one connects the greater and lesser multangular es, a second the lesser multangular and capitate bones, and a third the tate and hamate bones.

The three **interosseous ligaments** are much thicker than those of the imal row; one unites the capitate and hamate bones, a second the capitate lesser multangular bones, and a third the greater and lesser multangular s. The first is the strongest; the third is sometimes wanting.

3. The Articulations of the Two Rows of Carpal Bones with each other

The joint between the navicular, lunate, and triquetral bones on the one d, and the second row of carpal bones on the other, is named the *mid-carpal* t, and is made up of three portions: in the centre the head of the capitate e and the superior surface of the hamate bone articulate with the deep -shaped cavity formed by the navicular and lunate bones, and constitute rt of ball-and-socket joint; on the radial side the greater and lesser tangular bones articulate with the navicular bone, and on the ulnar side the te bone articulates with the triquetral bone, forming gliding joints.

The ligaments are: dorsal, volar, ulnar, and radial collateral.

The **dorsal and volar ligaments** consist of short, irregular bundles passing ween the bones of the first and second rows. On the volar surface the fibres ating from the head of the capitate bone to the surrounding bones form the *mentum carpi radiatum*.

The **collateral ligaments** are very short: one is placed on the radial, the er on the ulnar side of the carpus: the former, the stronger and more inct, connects the navicular and greater multangular bones, the latter the

CC-0. In Public Domain. Gurukul Kangri Collection, Haridwar

Digitized by Arya Samaj Foundation Chennai and eGangotri

triquetral and hamate bones; they are continuous with the collateral l of the wrist-joint. In addition to these ligaments, a slender interosse sometimes connects the capitate and navicular bones.

The **synovial stratum of the carpus** is very extensive (fig. 4 bounds a cavity of very irregular shape. The proximal part of t intervenes between the distal surfaces of the navicular, lunate, and t bones and the proximal surfaces of the bones of the second row. It s prolongations upwards—between the navicular and lunate bones, and the lunate and triquetral bones—and three downwards between t

FIG. 498.—A vertical section through the articulations at the right wri showing the synovial cavities.

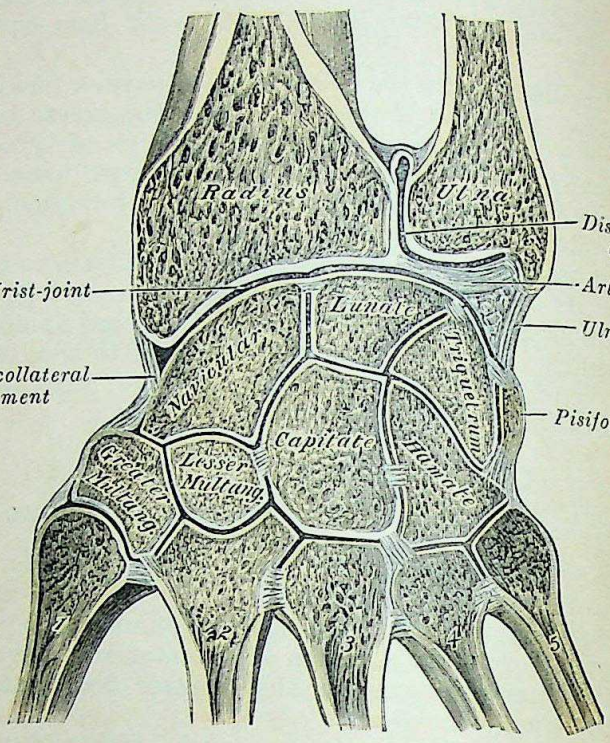

bones of the second row. The prolongation between the greater and multangular bones, or that between the lesser multangular and capitate is, owing to the absence of the interosseous ligament, often continuous the cavity of the carpometacarpal joints, sometimes of the second, fourth, and fifth metacarpal bones, sometimes of the second and third In the latter condition the joint between the hamate bone and the and fifth metacarpal bones has a separate synovial stratum. The sy cavities of these joints are prolonged for a short distance between the of the metacarpal bones. There is a separate synovial stratum betwe pisiform and triquetral bones.

Movements.—The chief movements permitted in the mid-carpal joint are and extension, flexion being freer than extension. A very slight amount of r is also permitted, the head of the capitate bone rotating round a vertic drawn through its own centre.

Muscles producing the movements:

Flexion.—Flexor carpi radialis, Flexor carpi ulnaris, Palmaris longus, F digitorum sublimis et profundus, Flexor pollicis longus.

Extension.—Extensores carpi radiales longus et brevis, Extensor carpi u Extensor digitorum communis, Extensores pollicis longus et b Extensor indicis proprius, Extensor digiti quinti proprius.

Adduction.—Flexor carpi ulnaris, Extensor carpi ulnaris.

Abduction.—Abductor pollicis longus, Extensores pollicis longus et b Extensor carpi radialis longus.

CC-0. In Public Domain. Gurukul Kangri Collection, Haridwar

Digitized by Arya Samaj Foundation Chennai and eGangotri

pplied Anatomy.—The radiocarpal joint is rarely dislocated, its strength depending upon the numerous strong tendons which surround the articulation. Its security ther provided for by the number of small bones of which the carpus is made up, and are united by very strong ligaments. The slight movements which take place n the several bones serve to break the jars that result from falls or blows on the Dislocation backwards, which is the more common, simulates to a considerable Colles' fracture of the radius, and is liable to be mistaken for it. The differential is can be easily made by observing the relative positions of the styloid processes radius and the ulna. In the natural condition when the arm hangs by the side, radius is on a lower level, i.e. nearer the ground, than that of yloid process of the radius is not disturbed in dislocation. In Colles' fracture, the lna, and this relationship is on the same level as, or even on a higher level than, that d process of the radius is on the same level as, or even on a higher level than, that e ulna. A fracture of the lower end of the radius may be caused by a 'back-fire' rking a motor-car, and is named a chauffeur's fracture; there is usually little dis- ement and the fracture can only be detected by *x*-ray examination.

e radiocarpal joint is occasionally the seat of acute synovitis. When the joint y is distended with fluid, the swelling is greatest on the dorsal aspect of the wrist, r a general fulness, with some bulging between the tendons.

e grasp of the hand is strongest when the radiocarpal joint is hyperextended; the therefore, should be kept in this position during the treatment of any disease or injury to lead to ankylosis of the joint.

VIII. THE CARPOMETACARPAL ARTICULATIONS

1. The Carpometacarpal Articulation of the Thumb

This is a joint of reciprocal reception between the first metacarpal and r multangular bones; it enjoys great freedom of movement on account e configuration of its articular surfaces, which are saddle-shaped. The is surrounded by an **articular capsule** which is thick but loose, and s from the circumference of the base of the metacarpal bone to the rough bounding the articular surface of the greater multangular bone; it is est laterally and dorsally. A synovial stratum lines the capsule and te distinct from that of the other carpometacarpal joints (fig. 498).

ovements.—In this articulation the movements permitted are flexion, exten- bduction, adduction, circumduction, and opposition. It is by the movement position that the tip of the thumb is brought into contact with the volar surfaces slightly flexed fingers. This movement is effected through the medium of ll sloping facet on the anterior lip of the saddle-shaped articular surface of reater multangular bone. The flexor muscles pull the corresponding part articular surface of the metacarpal bone on to this facet, and the movement of tion is then carried out by the opponens and adductor muscles.

scles producing the movements:

Flexion.—Opponens pollicis, Flexores pollicis longus et brevis.

Extension.—Extensores pollicis longus et brevis.

Adduction.—Adductor pollicis, Opponens pollicis, Flexor pollicis brevis.

Abduction.—Abductor pollicis brevis, Extensores pollicis longus et brevis.

The Articulations of the Second, Third, Fourth, and Fifth Metacarpal Bones with the Carpus

he joints between the carpus and the second, third, fourth, and fifth meta- al bones are arthrodial. The bones are united by **articular capsules**, thened by dorsal, volar, and interosseous ligaments.

he **dorsal ligaments**, the strongest and most distinct, connect the carpal metacarpal bones on their dorsal surfaces. The second metacarpal bone s two fasciculi, one each from the greater and lesser multangular bones; hird metacarpal receives two, one each from the lesser multangular and te bones; the fourth two, one each from the capitate and hamate bones; h receives a single fasciculus from the hamate bone, and this is continuous a similar ligament on the volar surface, forming an incomplete fibrous ble.

he **volar ligaments** have a somewhat similar arrangement, with the tion of those of the third metacarpal bone, which are three in number: a

CC-0. In Public Domain. Gurukul Kangri Collection, Haridwar

Digitized by Arya Samaj Foundation Chennai and eGangotri
lateral one from the greater multangular bone, situated superficial sheath of the tendon of the Flexor carpi radialis; an intermediate the capitate bone; and a medial one from the hamate bone.

The **interosseous ligaments** consist of short, thick fibres, and to one part of the carpometacarpal articulation; they connect the inferior margins of the capitate and hamate bones with the adjacent of the third and fourth metacarpal bones.

The **synovial stratum** of the articular capsules is a continuation of the intercarpal joints. Occasionally, the joint between the hamate the fourth and fifth metacarpal bones has a separate synovial stratum.

Movements.—The movements permitted in the carpometacarpal of the fingers are limited to slight gliding of the articular surfaces upon the extent of which varies in the different joints. The metacarpal little finger is the most movable, then that of the ring-finger; the metacarpal of the index and middle fingers are almost immovable.

IX. THE INTERMETACARPAL ARTICULATIONS

The bases of the second, third, fourth, and fifth metacarpal bones with one another by small surfaces covered with cartilage, and are together by dorsal, volar, and interosseous ligaments.

The **dorsal and volar ligaments** pass transversely from one another on the dorsal and volar surfaces. The **interosseous ligaments** nect the contiguous surfaces of the bones, just distal to their collateral facets.

The **synovial stratum** of these joints is continuous with the carpometacarpal articulations.

The **transverse metacarpal ligament** (fig. 496) is a narrow fibrous which connects the volar surfaces of the heads of the second, third and fifth metacarpal bones. It is blended with the accessory volar (glenoid ligaments) of the metacarpophalangeal articulations. Its volar is grooved where the flexor tendons pass over it; the tendons of the pass behind the ligament.

X. THE METACARPOPHALANGEAL ARTICULATIONS

These articulations (figs. 499, 500) are of the condyloid kind, formed reception of the rounded heads of the metacarpal bones into shallow on the proximal ends of the first phalanges, with the exception of the thumb, which presents more of the characteristics of a ginglymoid joint joint has an accessory volar and two collateral ligaments.

The **accessory volar ligaments** (*glenoid ligaments* of Cruveilhier) thick, dense, fibrocartilaginous structures, placed upon the volar surface the joints in the intervals between the collateral ligaments, to which are connected; they are loosely united to the metacarpal bones, but firmly attached to the bases of the first phalanges. Their volar surface intimately blended with the transverse metacarpal ligament, and grooved the flexor tendons, the fibrous sheaths of which are connected to the of the grooves. Their deep surfaces form parts of the articular facets heads of the metacarpal bones.

The **collateral ligaments** are strong, rounded cords, placed on the of the joints; each is attached by one extremity to the posterior and adjacent depression on the side of the head of the metacarpal bone by the other to the side of the base of the phalanx.

The dorsal surfaces of these joints are covered with the expansion extensor tendons, together with some loose areolar tissue which the deep surfaces of the tendons to the bones.*

* Consult an article on 'The nerve supply of the interphalangeal and metacarpo joints,' by J. S. B. Stopford, *Journal of Anatomy*, vol. lvi, 1921.

CC-0. In Public Domain. Gurukul Kangri Collection, Haridwar

Digitized by Arya Samaj Foundation Chennai and eGangotri

ovements.—The movements which occur in these joints are flexion, extension, ction, abduction, and circumduction; the movements of abduction and ction are very limited, and cannot be performed when the fingers are flexed.

ig.—The metacarpophalangeal digital articulations. Volar ect.

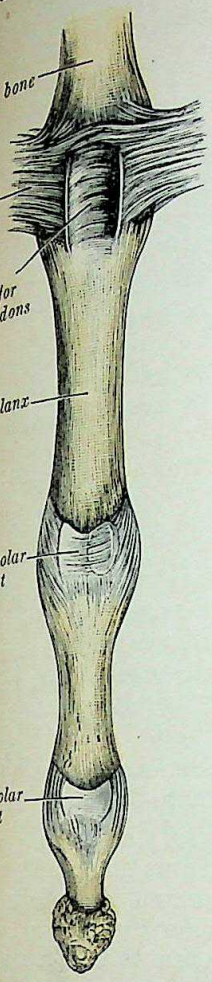

FIG. 500.—The metacarpophalangeal and digital articulations. Medial aspect.

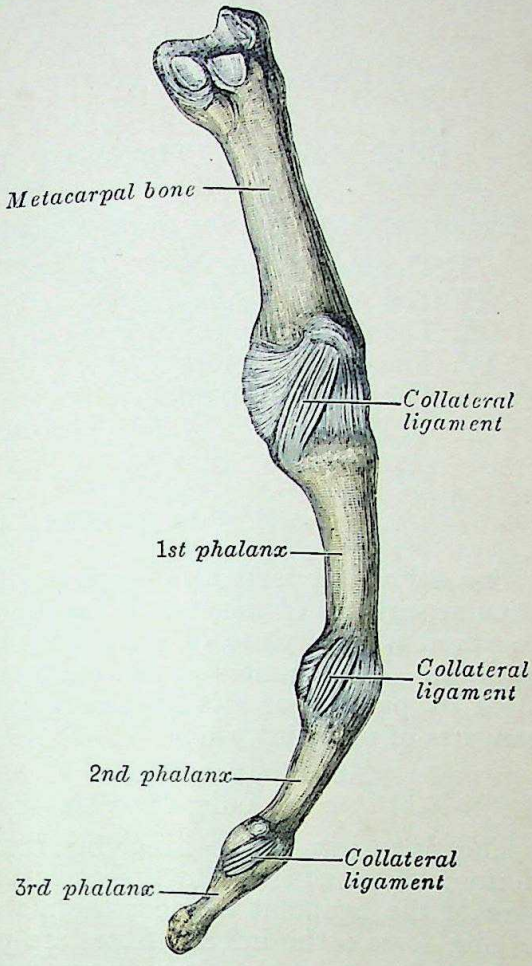

scles producing the movements :

Flexion.—Flexores digitorum sublimis et profundus, Lumbricales, Interossei dorsales et volares, Flexores pollicis longus et brevis, Flexor digiti quinti brevis.

Extension.—Extensor digitorum communis, Extensores pollicis longus et brevis, Extensor indicis proprius, Extensor digiti quinti proprius.

Adduction.—Interossei volares, Adductor pollicis, long flexors of fingers and thumb.

Abduction.—Interossei dorsales, Abductor pollicis brevis, Abductor digiti quinti, long extensors of fingers.

XI. THE DIGITAL ARTICULATIONS (figs. 499, 500)

he digital or interphalangeal articulations are hinge-joints; each has a volar two collateral ligaments. The arrangement of these ligaments is similar to in the metacarpophalangeal articulations. The extensor tendons supply aces of dorsal ligaments.

ovements.—The only movements permitted in the interphalangeal joints are n and extension; these movements are more extensive between the first and d phalanges than between the second and third. The amount of flexion is considerable, but extension is limited by the accessory volar ligaments.

CC-0. In Public Domain. Gurukul Kangri Collection, Haridwar

Digitized by Arya Samaj Foundation Chennai and eGangotri

Muscles producing the movements :

Flexion.—Flexores digitorum sublimis et profundus, Flexor pollicis longus et brevis.

Extension.—Lumbricales, Interossei dorsales et volares, Extensores.

Applied Anatomy.—Division of the extensor tendons opens the interphalan... These joints would be frequently sprained were it not that the metacarpophalan... are condyloid articulations, allowing of abduction and adduction, and dimin... effects of force applied to the sides of the fingers.

THE ARTICULATIONS OF THE LOWER EXTREMITY

The articulations of the lower extremity comprise the following:

I. The sacro-iliac.
II. The pubic symphysis.
III. The coxal (hip).
IV. The knee.
V. The tibiofibular.
VI. The talocrural (ankle).
VII. The intertarsal.
VIII. The tarsometatarsal.
IX. The intermetatarsal.
X. The metatarsophalangeal.
XI. The digital.

I. THE SACRO-ILIAC ARTICULATION

The sacro-iliac articulation is a diarthrodial joint, formed betw... auricular surfaces of the sacrum and ilium. The articular surface of ea... is covered with a plate of cartilage which is thicker on the sacrum ... the ilium. These plates are in close contact with each other, and ar... united by patches of soft fibrocartilage, and by fine interosseous fibre... ligaments of the joint are :

Anterior sacro-iliac. Interosseous sacro-iliac.
Long and short posterior sacro-iliac.

The **anterior sacro-iliac ligament** (fig. 501) covers the anter... inferior surfaces of the joint and consists of numerous thin bands. The ... fibres of the ligament connect the ala of the sacrum to the adjoining ... the iliac fossa ; the inferior fibres are placed below the arcuate line, an... the lateral parts of the three upper sacral vertebræ to the pre-auricular ... and adjacent part of the ilium.

The **interosseous sacro-iliac ligament** is very strong, and form... chief bond of union between the two bones. It fills the irregular spa... mediately above and behind the joint-cavity (figs. 504, 505) and is cove... the posterior sacro-iliac ligaments. It consists of bundles of short fibre... connect the iliac and sacral tuberosities.

The **long posterior sacro-iliac ligament** is oblique in direction ... connects the third transverse tubercle of the sacrum to the posterior s... iliac spine.

The **short posterior sacro-iliac ligament** (fig. 502) is nearly hor... in direction, and passes from the posterior superior iliac spine to the fi... second transverse tubercles of the sacrum.

The ilium is connected to the fifth lumbar vertebra by the *iliolumb... ment*, and the sacrum to the ischium by the *sacrotuberous and sacro... ligaments.*

The **iliolumbar ligament** (fig. 501) is attached above to the lower an... part of the transverse process of the fifth lumbar vertebra, and occas... has an additional, weak attachment to the transverse process of the ... It radiates as it passes lateralwards and is attached by two main ba... the pelvis. The lower band runs to the ala of the ilium and the base ... sacrum, blending with the anterior sacro-iliac ligament ; the upper is att... to the crest of the ilium immediately in front of the sacro-iliac arti... and is continuous above with the lumbodorsal fascia.

CC-0. In Public Domain. Gurukul Kangri Collection, Haridwar

Digitized by Arya Samaj Foundation Chennai and eGangotri

The **sacrotuberous ligament** (great sacrosciatic ligament) (figs. 501, 502) placed at the lower and posterior part of the pelvis. It is attached by a d base to the posterior iliac spines, to the third, fourth, and fifth trans- e tubercles of the sacrum, and to the lateral margin of the lower part of acrum and upper part of the coccyx. Its fibres run obliquely downwards lateralwards, and converge to form a thick, narrow band; this band widens below and is fixed to the medial margin of the ischial tuberosity, and is tinued along the inferior ramus of the ischium under the name of the *falci- process*, the free concave edge of which gives attachment to the fascia of

Fig. 501.—The articulations of the right side of the pelvis. Anterosuperior aspect.

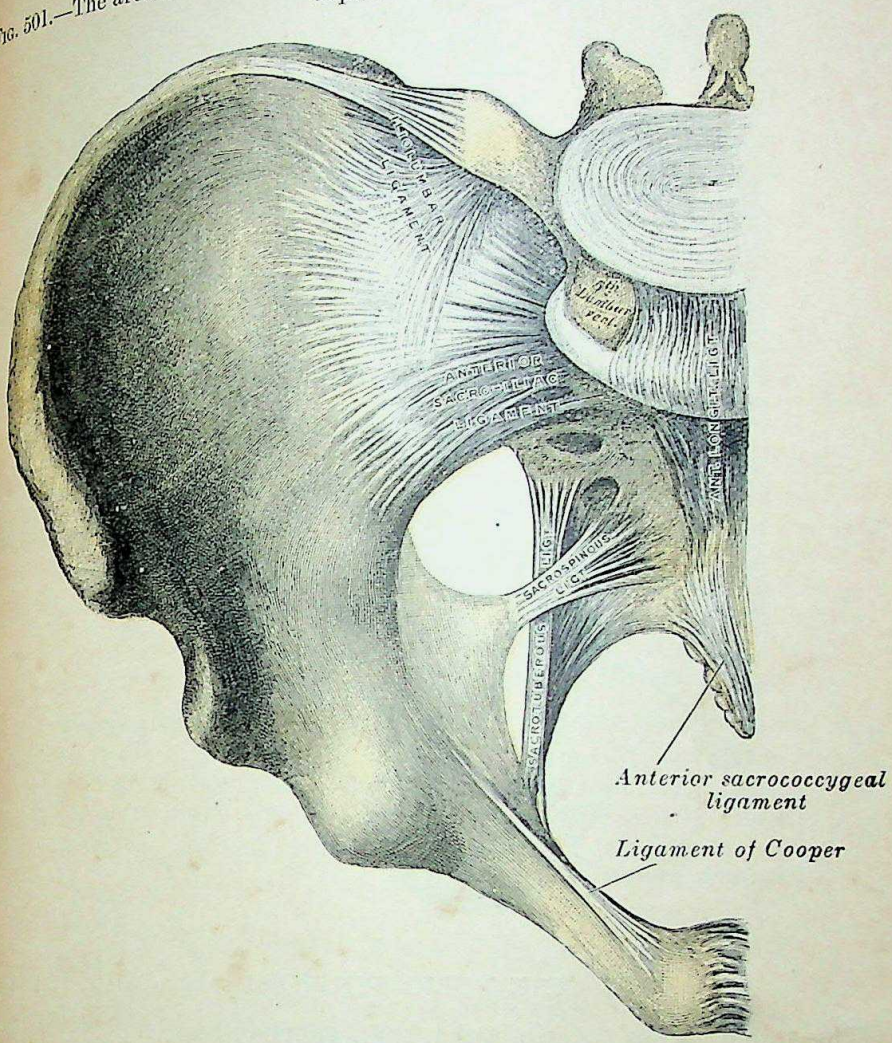

Obturator internus. Some of the superficial fibres of the lower part of the ment are continued into the tendon of origin of the long head of the Biceps oris.

The **sacrospinous ligament** (small sacrosciatic ligament) (fig. 501) is thin, triangular in form; it is attached by its apex to the spine of the ischium, medially, by its broad base, to the lateral margins of the sacrum and cyx, in front of the sacrotuberous ligament, with which its fibres are ntermingled. It is in relation in front with the Coccygeus muscle, to which is closely connected, and of which it may represent a degenerated part.

These two ligaments convert the sciatic notches into foramina. The *greater sciatic* men is bounded, in front and above, by the greater sciatic notch; behind, by the tuberous ligament; and below, by the sacrospinous ligament and the spine of the um. It is partially filled up, in the recent state, by the Piriformis muscle which ges from the pelvis through it. Above this muscle, the superior glutæal vessels and e pass out of the pelvis; and below it, the inferior glutæal vessels and nerve, the rnal pudendal vessels and nerve, the sciatic and the posterior femoral cutaneous nerves,

CC-0. In Public Domain. Gurukul Kangri Collection, Haridwar

Digitized by Arya Samaj Foundation Chennai and eGangotri

and the nerves to the Obturator internus and Quadratus femoris make their the pelvis. The *lesser sciatic foramen* is bounded, in front, by the superior ra ischium; above, by the spine of the ischium and sacrospinous ligament; bel sacrotuberous ligament. It transmits the tendon of the Obturator internus, th this muscle, and the internal pudendal vessels and nerve.

FIG. 502.—The articulations of the right side of the pelvis. Posterior asp

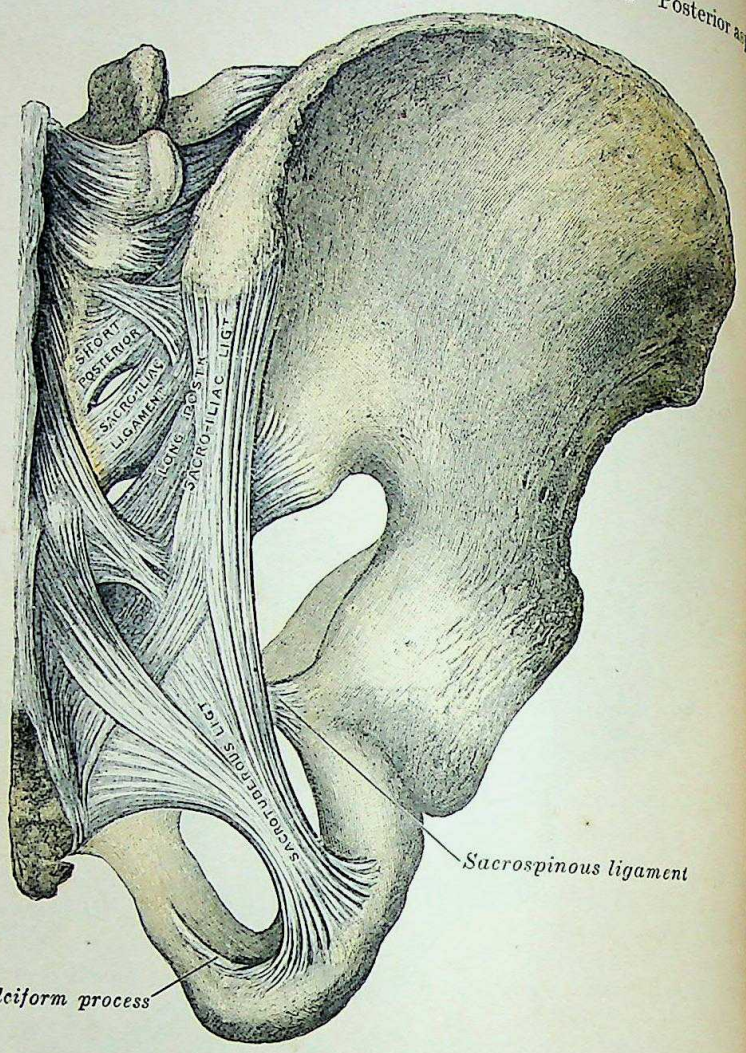

II. THE PUBIC SYMPHYSIS (fig. 503)

The pubic bones are united to one another by a superior and an a pubic ligament, and by an interpubic fibrocartilaginous lamina.

The **superior pubic ligament** connects the pubic bones superiorly extends as far as the pubic tubercles

The **arcuate pubic ligament** (inferior or subpubic ligament) is a triangular arch of fibres, connecting the two pubic bones below, and formi upper boundary of the pubic arch. Above, it is blended with the inter fibrocartilaginous lamina; laterally, it is attached to the inferior rami o pubic bones; its base is free, and is separated from the fascia of the urog diaphragm by an opening through which the deep dorsal vein of the (or clitoris) enters the pelvis.

The **interpubic fibrocartilaginous lamina** connects the opposed surfa the pubic bones. Each of these surfaces is covered with a thin layer of hy cartilage firmly joined to the bone by a series of nipple-like processes accurately fit into corresponding depressions on the osseous surface. T opposed cartilaginous surfaces are connected by a lamina of fibrocart which varies in thickness in different subjects. It often contains a c in its interior, probably formed by the softening and absorption of the

CC-0. In Public Domain. Gurukul Kangri Collection, Haridwar

Digitized by Arya Samaj Foundation Chennai and eGangotri

lage, since it rarely appears before the tenth year of life and is not lined a synovial stratum. This cavity is usually limited to the upper and back of the joint; it occasionally reaches the front, and may extend the entire h of the cartilage. It may be easily demonstrated when present by

FIG. 503.—A coronal section through the pubic symphysis. Anterior aspect.

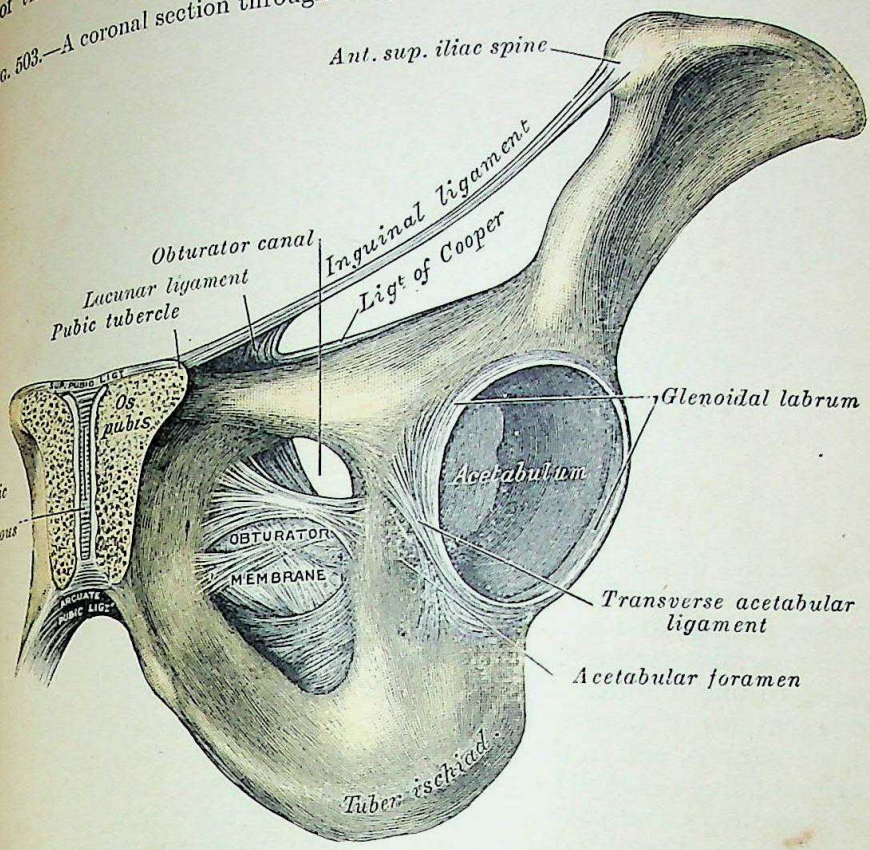

ing a coronal section of the symphysis pubis near its posterior surface 503). In front, the lamina is strengthened by several superimposed layers fibres, which pass obliquely from one bone to the other, decussating and ing an interlacement with the fibres of the aponeuroses of the Obliqui rni and the medial tendons of origin of the Recti abdominis.

The Mechanism of the Pelvis

he pelvic girdle supports and protects the contained viscera and affords surfaces e attachments of the muscles of the trunk and lower limb. Its most important nical function, however, is to transmit the weight of the trunk and upper to the lower extremities.

t may be divided into two arches by a vertical plane passing through the aceta- cavities; the posterior of these arches is the one chiefly concerned in the n of transmitting the weight of the trunk. Its essential parts are the upper sacral vertebræ and two strong pillars of bone running from the sacro-iliac ulations to the acetabular cavities. For the reception and diffusion of the ht each acetabular cavity is strengthened by two additional bars running rds the os pubis and the ischium. In order to lessen concussion in rapid changes ribution of the weight, joints (sacro-iliac articulations) are interposed between crum and the iliac bones; an accessory joint (symphysis pubis) exists in the e of the anterior arch. The sacrum forms the summit of the posterior arch; eight transmitted falls on it at the lumbosacral articulation and, theoretically, component in each of two directions. One component of the force is expended ving the sacrum downwards and backwards between the iliac bones, while ther thrusts the upper end of the sacrum downwards and forwards towards elvic cavity.

CC-0. In Public Domain. Gurukul Kangri Collection, Haridwar

Digitized by Arya Samaj Foundation Chennai and eGangotri

The movements of the sacrum are regulated by its form. Viewed as it presents the shape of a wedge with its base upwards and forwards. component of the force is therefore acting against the resistance of the its tendency to separate the iliac bones is resisted by the sacro-iliac and ligaments and by the ligaments of the symphysis pubis.

FIG. 504.—A coronal section through the anterior sacral segment.

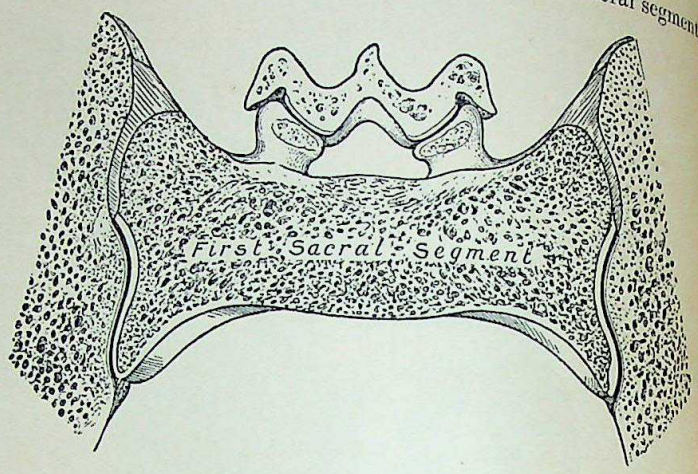

If a series of coronal sections be made through the sacro-iliac joints, found possible to divide the articular portion of the sacrum into three anterior, middle, and posterior. In the *anterior segment* (fig. 504), which the first sacral vertebra, the articular surfaces show slight sinuosities and parallel to one another. In the *middle segment* (fig. 505) the width bet dorsal margins of the sacral articular surfaces is greater than that bet ventral margins, and in the centre of each surface there is a concavity in a corresponding convexity of the iliac articular surface fits, forming an int mechanism. In the *posterior segment* (fig. 506) the ventral width of the is greater than the dorsal, and the articular surfaces are only slightly con

FIG. 505.—A coronal section through the middle sacral segment.

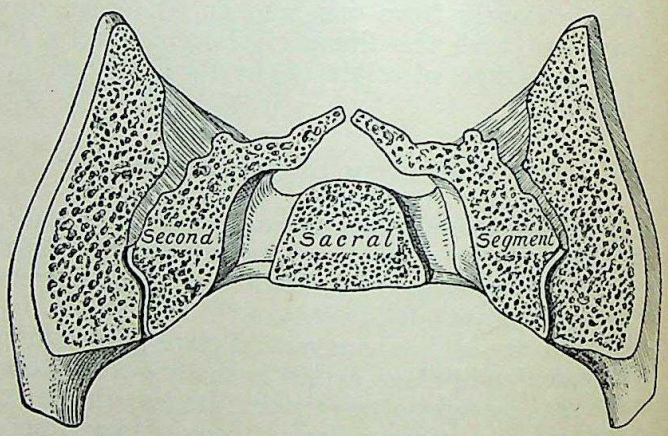

Dislocation downwards and forwards of the sacrum by the second co of the force applied to it is prevented therefore by the middle segme interposes the resistance of its wedge-shape and that of the interlocking m on its surfaces; a rotatory movement, however, is produced by which the segment is tilted downwards and the posterior upwards: the axis of this passes through the dorsal part of the middle segment. The movement anterior segment is slightly limited by its wedge-form, but chiefly by the and interosseous sacro-iliac ligaments; that of the posterior segment is ch a slight extent by its wedge-form, but the chief limiting factors are the tuberous and sacrospinous ligaments. In all these movements the effect

CC-0. In Public Domain. Gurukul Kangri Collection, Haridwar

Digitized by Arya Samaj Foundation Chennai and eGangotri

-iliac and iliolumbar ligaments and the ligaments of the symphysis pubis in ting the separation of the iliac bones must be recognised.

During pregnancy the pelvic s and ligaments are relaxed, capable therefore of more sive movements. When the s is being expelled the force plied to the front of the um. Upward dislocation is ented by the interlocking anism of the middle segment. the fœtal head passes the rior segment the latter is ed upwards, enlarging the posterior diameter of the e inlet; when the head es the posterior segment also is pressed upwards against the resistance of its wedge, the movement only g possible by the laxity of the joints and the stretching of the sacrotuberous sacrospinous ligaments.

Fig. 506.—A coronal section through the posterior sacral segment.

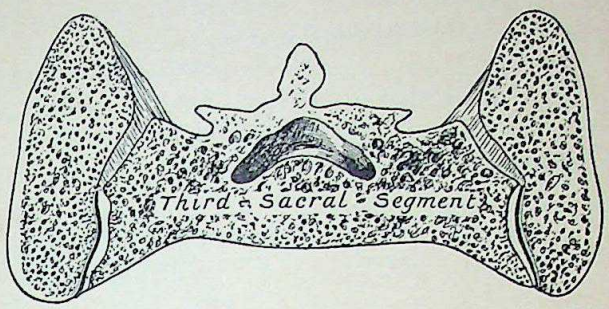

III. THE COXAL ARTICULATION OR HIP-JOINT

The hip-joint is an enarthrodial or ball-and-socket articulation, formed the reception of the head of the femur into the cup-shaped cavity of the

Fig. 507.—A section through the hip-joint.

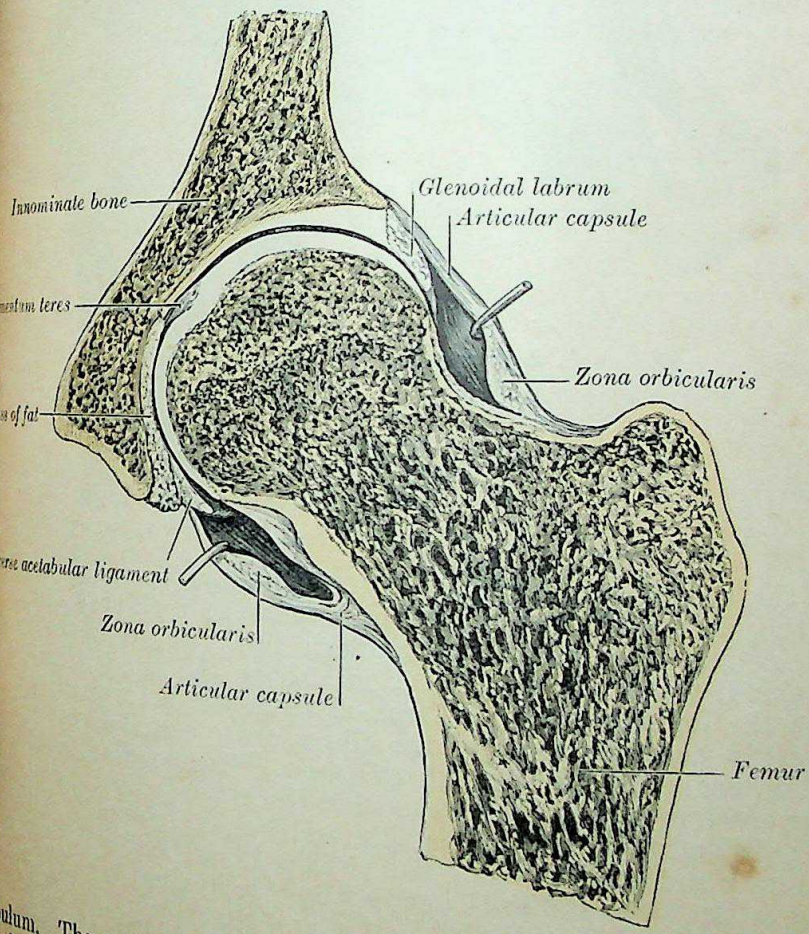

abulum. The articular cartilage on the head of the femur, thicker at the re than at the circumference, covers the entire surface with the exception the fovea capitis femoris, to which the ligamentum teres is attached; that

CC-0. In Public Domain. Gurukul Kangri Collection, Haridwar

Digitized by Arya Samaj Foundation Chennai and eGangotri

on the acetabulum forms an incomplete ring, the lunate surface. W
lunate surface there is a circular depression devoid of cartilage, occ
the recent state by a mass of fat covered with the synovial strata
articular capsule. The ligaments of the joint are :

The articular capsule.	Pubocapsular.
Iliofemoral.	Ligamentum teres femoris
Ischiocapsular.	The glenoidal labrum.

Transverse acetabular.

The **articular capsule** (figs. 507, 508) is strong and dense. Abo
attached to the margin of the acetabulum, 5 or 6 mm. beyond the g
labrum; in front, it is attached to the outer margin of the labru

FIG. 508.—The articular capsule of the right hip-joint (distended). Poste
aspect. (From a specimen prepared by J. C. B. Grant.)

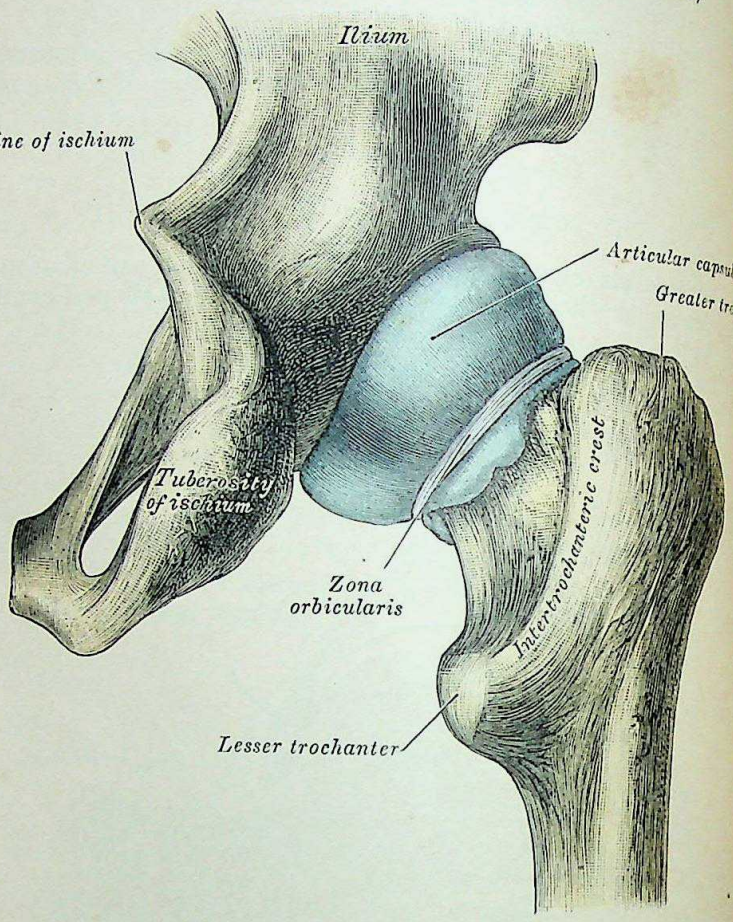

opposite the acetabular notch, to the transverse acetabular ligament a
edge of the obturator foramen. It surrounds the neck of the femur,
attached, in front, to the intertrochanteric line; above, to the base
neck; behind, to the neck, about 1 cm. above the intertrochanteric
below, to the lower part of the neck close to the lesser trochanter.
its femoral attachment some of the fibres are reflected upwards alon
neck as longitudinal bands, termed *retinacula*. The capsule is much thi
the upper and fore part of the joint, where the greatest amount of resist
required; behind and below, it is thin and loose. It consists of two s
fibres, circular and longitudinal. The circular fibres (*zona orbicularis*) are
abundant at the lower and back part of the capsule (figs. 507, 508), and
sling or collar around the neck of the femur. Anteriorly, they blend wi
deep surface of the iliofemoral ligament, and gain an attachment to the a
inferior iliac spine. The longitudinal fibres are greatest in amount
upper and front part of the capsule, where they are reinforced by the *iliof*
ligament. The articular capsule is also strengthened by the *pubocapsular*

CC-0. In Public Domain. Gurukul Kangri Collection, Haridwar

Digitized by Arya Samaj Foundation Chennai and eGangotri

ischiocapsular ligaments. The external surface of the capsule is rough, ered by numerous muscles, and separated in front from the Psoas major d Iliacus by a bursa which not infrequently communicates through a ular aperture with the cavity of the joint.

The **synovial stratum** is very extensive. Commencing at the margin of cartilaginous surface of the head of the femur, it covers the portion of the k which is contained within the joint; from the neck it is reflected on internal surface of the fibrous stratum of the capsule, covers both surfaces the glenoidal labrum, ensheathes the ligamentum teres as far as the head

FIG. 509.—The right hip-joint. Anterior aspect.

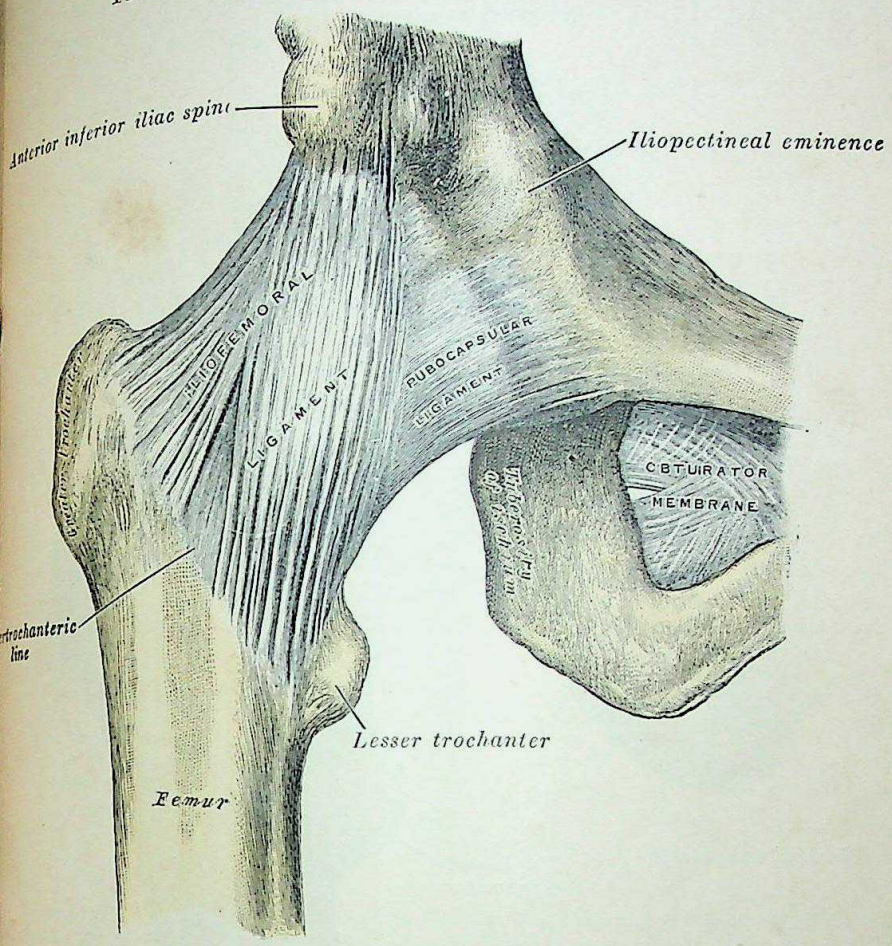

the femur, and covers the mass of fat contained in the bottom of the aceta- lum. The joint-cavity sometimes communicates, through a hole between e vertical band of the iliofemoral ligament and the pubocapsular ligament, h a bursa situated on the deep surfaces of the Psoas major and Iliacus.

The **iliofemoral ligament** (fig. 509), triangular in shape and of great ength, lies in front of the joint and is intimately connected with the capsule. a apex is attached to the lower part of the anterior inferior iliac spine, its e to the intertrochanteric line of the femur. The medial and lateral parts the ligament are strong bands, while the central part is relatively thin d weak; the medial band is vertical in direction and is fixed to the lower t of the intertrochanteric line; the lateral band is oblique and is attached the upper part of the same line. The iliofemoral ligament is frequently led the Y-shaped ligament of Bigelow, and its lateral band the *iliotrochanteric ment.*

The **pubocapsular ligament** (fig. 509) is triangular in form with its base the hip-bone, where it is attached to the iliopectineal eminence, the superior rus of the os pubis, the obturator crest and obturator membrane; below, blends with the capsule and with the deep surface of the medial band of the ofemoral ligament.

CC-0. In Public Domain. Gurukul Kangri Collection, Haridwar

Digitized by Arya Samaj Foundation Chennai and eGangotri

The **ischiocapsular ligament** (fig. 510) has a somewhat spiral di on the back of the joint. From its attachment to the ischium b behind the acetabulum, it is directed upwards and lateralwards over t of the neck of the femur. Some of its fibres are continuous with the zona orbicularis, others are fixed to the base of the greater trochante

The **ligamentum teres femoris** (fig. 511) is a triangular, somewhat band implanted by its apex on the anterosuperior part of the fove femoris; its base is attached by two bands, one into either side of the ac notch, and between these bony attachments it blends with the tr ligament. It is ensheathed by the synovial stratum, and varies g strength in different subjects; occasionally only the synovial stratu and in rare cases even this is absent. The ligament is made tense w thigh is adducted; it is relaxed when the limb is abducted.

FIG. 510.—The right hip-joint. Posterior aspect.

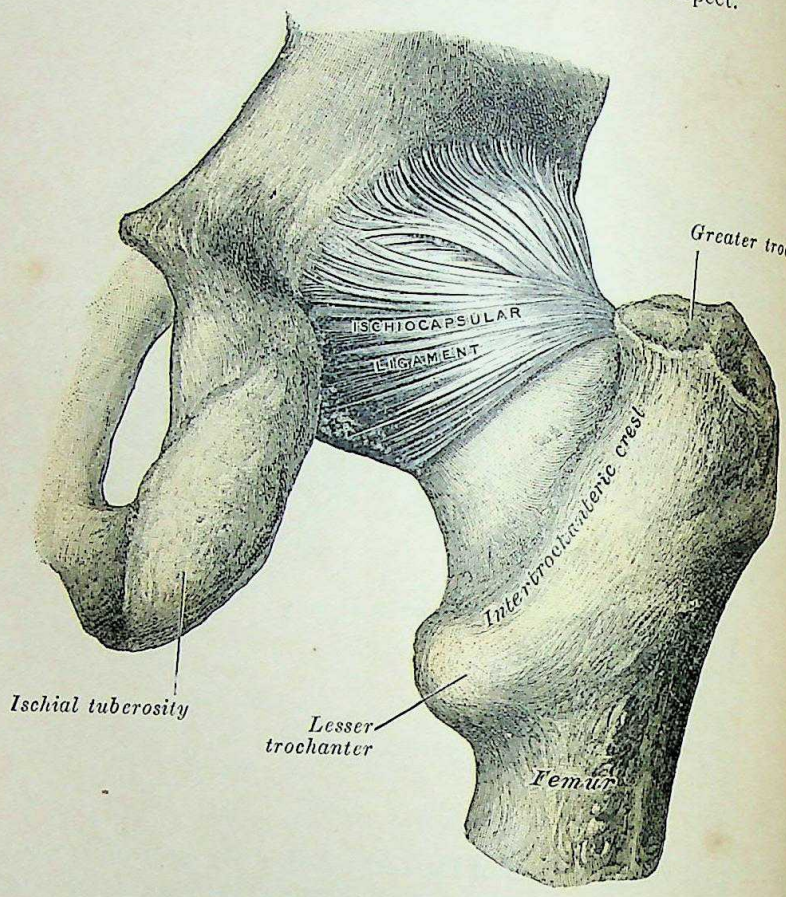

The **glenoidal labrum** (cotyloid ligament) (fig. 503) is a fibrocartil rim attached to the margin of the acetabulum, the cavity of which it de at the same time it protects the edge of the bone, and fills up the ineq of its surface. It bridges over the acetabular notch as the *transverse ace ligament*, and thus forms a complete circle, which closely surrounds th of the femur and assists in holding it in its place. It is triangular on s its base being attached to the margin of the acetabulum, while its op edge is free and sharp. Its surfaces are invested by the synovial stratum internal surface is inclined inwards so as to narrow the acetabulum, and e the cartilaginous surface of the head of the femur. It is much thicker and behind than below and in front.

The **transverse acetabular ligament** (fig. 503) is in reality a p of the glenoidal labrum, though differing from it in having no cartilag among its fibres. It consists of strong, flattened fibres, which cros acetabular notch, and convert it into a foramen through which the n vessels enter the joint.

The *muscles* in relation with the joint are, in front, the Psoas major and I

CC-0. In Public Domain. Gurukul Kangri Collection, Haridwar

Digitized by Arya Samaj Foundation Chennai and eGangotri

ated from the capsule by a bursa; above, the rectus and tendon of the Rectus ris and the insertion of Glutæus minimus, the latter being closely adherent e capsule; medially, the Obturator externus and Pectineus; behind, the rmis, Gemellus superior, tendon of Obturator internus, Gemellus inferior, of Obturator externus, and Quadratus femoris (fig. 512).

e arteries supplying the joint are derived from the obturator, medial femoral nflex, and superior and inferior glutæal arteries.

FIG. 511.—The left hip-joint, opened by removing the floor of the acetabulum from within the pelvis.

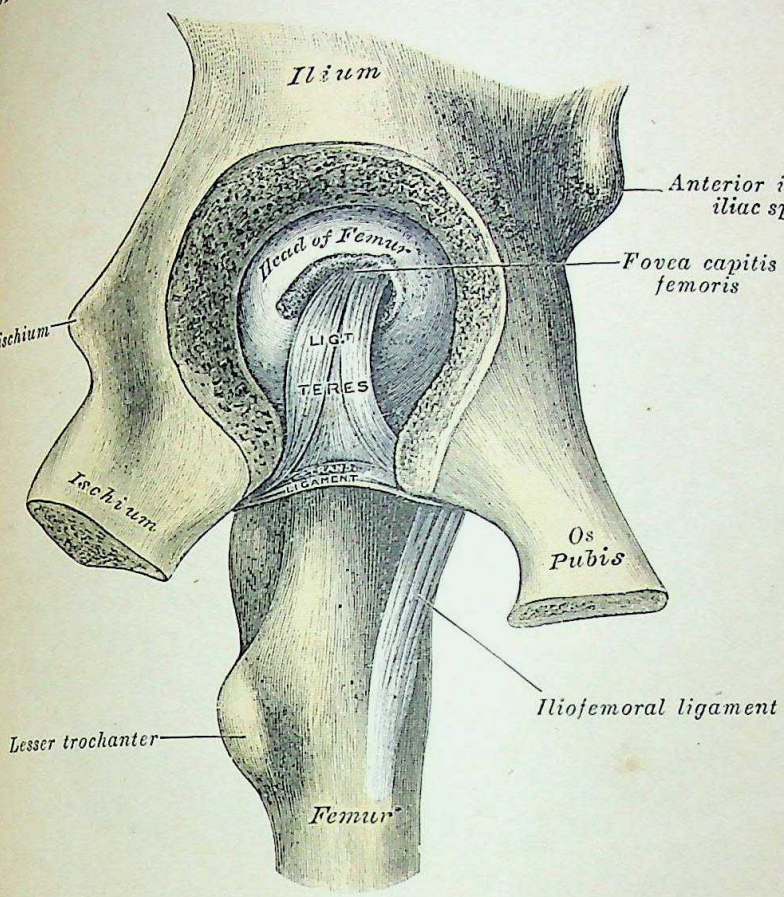

e nerves are articular branches from the sacral plexus, the sciatic, obturator, ccessory obturator nerves, a branch from the nerve to the quadratus ris, and a filament from the branch of the femoral nerve supplying the us femoris.

Movements.—The movements of the hip-joint are very extensive, and consist xion, extension, adduction, abduction, circumduction, and rotation.

e length of the neck of the femur and its inclination to the body of the bone the effect of converting the angular movements of flexion, extension, adduc- and abduction partially into rotatory movements in the joint. Thus when igh is flexed or extended, the head of the femur, on account of the *medial* ation of the neck, rotates within the acetabulum. The *forward* slope of the similarly affects the movements of adduction and abduction. Conversely on of the thigh, which is permitted by the *upward* inclination of the neck, is simple rotation of the head of the femur in the acetabulum, but is accom- d by a certain amount of gliding.

e hip-joint presents a very striking contrast to the shoulder-joint in the much complete mechanical arrangements for its security and for the limitation of its ments. In the shoulder, as has been seen, the head of the humerus is not ed at all in size to the glenoid cavity, and is hardly restrained in any of its ary movements by the capsule. In the hip-joint, on the contrary, the head of emur is closely fitted to the acetabulum for an area extending over nearly sphere, and at the margin of the bony cup it is still more closely embraced by

CC-0. In Public Domain. Gurukul Kangri Collection, Haridwar

Digitized by Arya Samaj Foundation Chennai and eGangotri

the glenoidal labrum, so that the head of the femur is held in its place b
ment even when the fibres of the capsule have been quite divided. The
ligament is the strongest of all the ligaments in the body, and is put on
by any attempt to extend the femur beyond a straight line with the tr
is to say, this ligament is the chief agent in maintaining the erect posit
muscular fatigue; for a vertical line passing through the centre of gra
trunk falls behind the centres of rotation in the hip-joints, and therefore
tends to fall backwards, but is prevented by the tension of the iliofemoral
The security of the joint may be provided for also by the two bones bei
united through the ligamentum teres, but it is doubtful whether th
has much influence upon the mechanism of the joint. When the kne

FIG. 512.—The structure surrounding the right hip-joint.

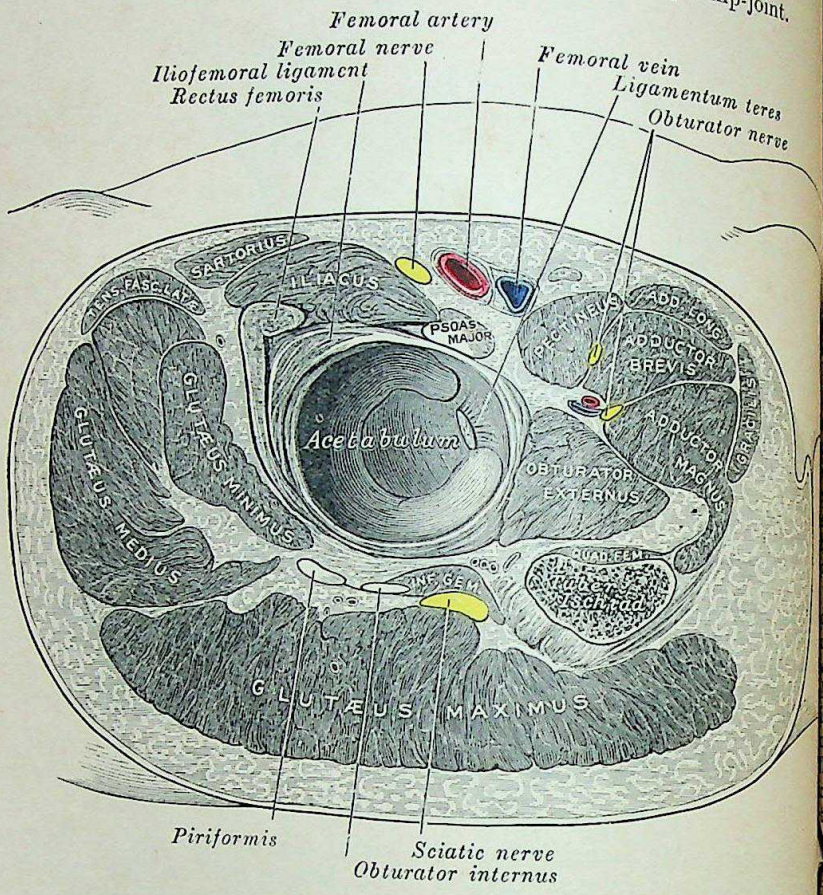

flexion of the hip-joint is arrested by the soft parts of the thigh and abdo
brought into contact, and when the knee is extended, by the action of the h
muscles; extension is checked by the tension of the iliofemoral ligament;
tion by the thighs coming into contact; adduction with flexion by the late
of the iliofemoral ligament and the lateral part of the capsule; abductio
medial band of the iliofemoral ligament and the pubocapsular ligament;
outwards by the lateral band of the iliofemoral ligament; and rotation
by the ischiocapsular ligament and the hinder part of the capsule.

Muscles producing the movements:

Flexion.—Psoas major, Iliacus, Pectineus, Rectus femoris, Sartorius,
tores.

Extension.—Glutæus maximus, Biceps femoris, Semitendinosus, S
branosus.

Abduction.—Glutæi medius et minimus, Sartorius, Tensor fasciæ lat

Adduction.—Adductores, Pectineus, Gracilis.

Rotation inwards.—Glutæi medius et minimus (anterior fibres), Tens
latæ.

Rotation outwards.—Piriformis, Obturatores, Gemelli, Quadratus
Adductores, Sartorius.

CC-0. In Public Domain. Gurukul Kangri Collection, Haridwar

Digitized by Arya Samaj Foundation Chennai and eGangotri

Applied Anatomy.—In dislocation of the hip, the head of the thigh-bone may rest at point around its socket' (Bryant); but whatever position it ultimately assumes, primary displacement is generally downwards and medialwards, the capsule giving way at its weakest—that is, its lower and medial—part. The situation subsequently held by the head of the bone is determined by the degree of flexion or extension, and forward or inward rotation of the thigh at the moment of dislocation, influenced, no doubt, by the iliofemoral ligament, which is easily ruptured. When, for instance, the head of the bone is forced backwards, this fulcrum forms a fixed axis, round which the head of the bone rotates, and the latter is driven on the dorsum of the ilium. The iliofemoral ligament also influences the position of the limb in the various dislocations; in the dislocations backwards it is tense, and produces flexion of the limb; in the dislocation on to the pubis, it is relaxed, and therefore allows the external rotator muscles to evert the thigh; and in dislocation into the obturator foramen it is tense, and produces flexion. The muscles attached into the upper part of the femur, with the exception of the Obturator internus, have but little direct influence in determining the position of the head of the bone. Bigelow, however, has endeavoured to show that the obturator internus is the principal agent in dislocating whether, in the backward dislocations, the head of the bone shall be ultimately lodged on the dorsum of the ilium, or in or near the lower sciatic notch; in both dislocations the head passes, in the first instance, in the same direction. But, as Bigelow asserts, in the dislocation on to the dorsum the head of the femur travels up behind the acetabulum, in front of the muscle; while in the dislocation into the lower sciatic notch the head passes behind the muscle, and is prevented from reaching the dorsum, in consequence of the tendon of the muscle arching over the neck of the bone, and therefore remains in the neighbourhood of the pelvis. Bigelow distinguishes these two forms of dislocation by describing them as dislocations backwards, 'above and below' the obturator internus.

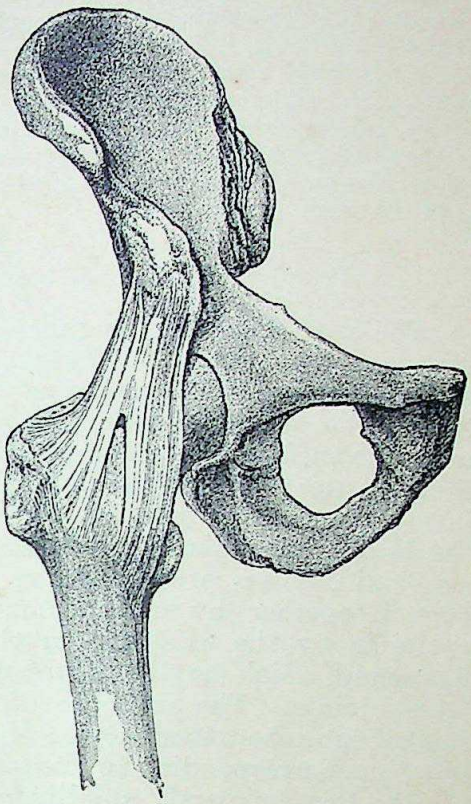

FIG. 513.—The right hip-joint, showing the iliofemoral ligament. (After Bigelow.)

The iliofemoral ligament is rarely torn in dislocations of the hip, and this fact is taken advantage of by the surgeon in reducing these dislocations by manipulation. It is made use of as the fulcrum to a lever, of which the long arm is the body of the femur, and the short arm the neck of the bone (fig. 513).

The hip-joint is rarely the seat of acute synovitis from injury, on account of its deep situation and its thick covering of soft parts. Acute inflammation may, and does, frequently occur, and in these cases, when the joint is distended with fluid, the swelling is very easy to detect on account of the thickness of the capsule and the depth of the situation. It is principally to be found on the front of the joint, just medial to the iliofemoral ligament; or behind, at the lower and back part. In these two places the capsule is thinner than elsewhere.

In chronic hip-disease the affected limb assumes an altered position, the cause of which it is important to understand. In the early stage of a typical case, the limb is flexed, abducted, and rotated outwards. In this position all the ligaments of the joint are relaxed: the front of the capsule by flexion; the lateral band of the iliofemoral ligament by abduction; and the medial band of this ligament and the back of the capsule by rotation outwards. It is, therefore, the position of greatest ease. The condition is readily obvious at first, upon examining a patient. If the patient be laid in the supine position, the affected limb will be found to be extended and parallel with the other. But it will be seen that the pelvis is tilted downwards on the diseased side and the limb apparently longer than its fellow, and that the lumbar portion of the vertebral column is tilted forwards (lordosis). The condition is thus explained: a limb which is flexed and abducted is obviously useless for progression, and in order to overcome the difficulty the patient depresses the affected side of his pelvis, thus producing parallelism of his limbs, and at the same time rotates his pelvis on its transverse horizontal axis, so as to carry the limb downwards, instead of forwards. In the later stages of the disease the limb becomes flexed and adducted and inverted. This position, at all events as regards adduction, probably results from muscular action and from the patient lying on his

CC-0. In Public Domain. Gurukul Kangri Collection, Haridwar

Digitized by Arya Samaj Foundation Chennai and eGangotri

sound side. The adductor muscles are supplied by the obturator nerve, and largely supplies the joint. These muscles are therefore thrown into reflex spasm irritation of the peripheral terminations of this nerve in the inflamed articulation.

Congenital dislocation is more commonly met with in the hip-joint than in any articulation. The displacement always takes place on to the dorsum ilii. It is to extreme lordosis, in order to throw the weight of the body backwards.

Excision of the hip may be required for disease or for injury, especially gun may be performed either by an anterior or a posterior incision. The former avoids interference with important structures, especially muscles, than the latter, but of less efficient drainage. In the operation from the front an incision is made about in length, starting immediately below and lateral to the anterior superior spine downwards between the Sartorius and Tensor fasciæ latæ. The interspace between Glutæus minimus and Rectus femoris is then opened, exposing the upper part capsule, which being incised discloses the neck of the bone. The posterior consists in making an incision 8 to 10 cm. long, commencing midway between of the greater trochanter and the iliac crest, and extending down the posterior of the trochanter. The muscles are detached from the greater trochanter, and the opened freely. When there is a possibility of ankylosis occurring, treatment is with the thigh abducted.

IV. THE KNEE-JOINT

The knee-joint is a ginglymus or hinge-joint. It consists of three tions in one: two condyloid joints, one between either condyle of the and the corresponding meniscus and condyle of the tibia; and a third the patella and the femur, partly arthrodial, but not completely so, articular surfaces are not mutually adapted to each other, so that the ment is not a simple gliding one. This view of the construction knee-joint receives confirmation from a study of the articulation in the lower mammals, where, corresponding to these three subdivisions synovial cavities are sometimes found, either entirely distinct or connected together by small communications. This view is further probable by the existence in the middle of the joint of the two ligaments, which may be regarded as the collateral ligaments of the medial lateral joints. The existence of the patellar fold of synovial membrane further indicate a tendency to separation of the synovial cavity into two sacs, one corresponding to the lateral and the other to the medial joint.

The joint is partly subdivided by two menisci (semilunar fibrocartilages) which are placed between the femur and the tibia.

The ligaments of the joint are:

The articular capsule.	Anterior and posterior cruciate.
Ligamentum patellæ.	Transverse.
Oblique and arcuate popliteal.	Coronary.
Tibial and fibular collateral.	

The **articular capsule** (figs. 514, 517) consists of a fibrous stratum is strengthened in almost its entire extent by bands inseparably connected it; above and in front, beneath the tendon of the Quadriceps femoris represented only by the synovial stratum. Its chief strengthening bands derived from the fascia lata and from the tendons surrounding the joint front, expansions from the Vasti and from the fascia lata and its iliotibial fill the intervals between the collateral and anterior ligaments, constitute the *medial and lateral patellar retinacula.* Behind, the capsule consists vertical fibres which arise from the condyles of the femur and tibia and the sides of the inter-condyloid fossa of the femur; the posterior part capsule is therefore situated on the sides of the cruciate ligaments and of them, and they are thus excluded from the joint-cavity. Behind the ligaments is the oblique popliteal ligament which is augmented by fibres from the tendon of the Semimembranosus. Laterally, a prolongation the iliotibial tract fills the interval between the oblique popliteal and the collateral ligaments, and partly covers the latter. Medially, expansions from the Sartorius and Semimembranosus pass upwards to the tibial collateral ligament and strengthen the capsule.

The **synovial stratum** of the knee-joint is the largest in the Commencing at the upper border of the patella, it forms a large beneath the Quadriceps femoris on the lower part of the front of the

CC-0. In Public Domain. Gurukul Kangri Collection, Haridwar

Digitized by Arya Samaj Foundation Chennai and eGangotri

514, 522), and usually communicates with a bursa interposed between endon and the front of the femur. The pouch between the Quadriceps front of the femur is supported, during the movements of the knee, by ll muscle, the Articularis genus, which is inserted into it. On either the patella, the synovial stratum extends beneath the aponeuroses Vasti, and more especially beneath that of the Vastus medialis. Below patella it is separated from the ligamentum patellæ by a considerable ity of fat, known as the *infrapatellar pad*. From the medial and lateral ers of the articular surface of the patella, reduplications of the synovial

. 514.—The articular capsule of the right knee-joint (distended). Lateral aspect. (From a specimen prepared by J. C. B. Grant.)

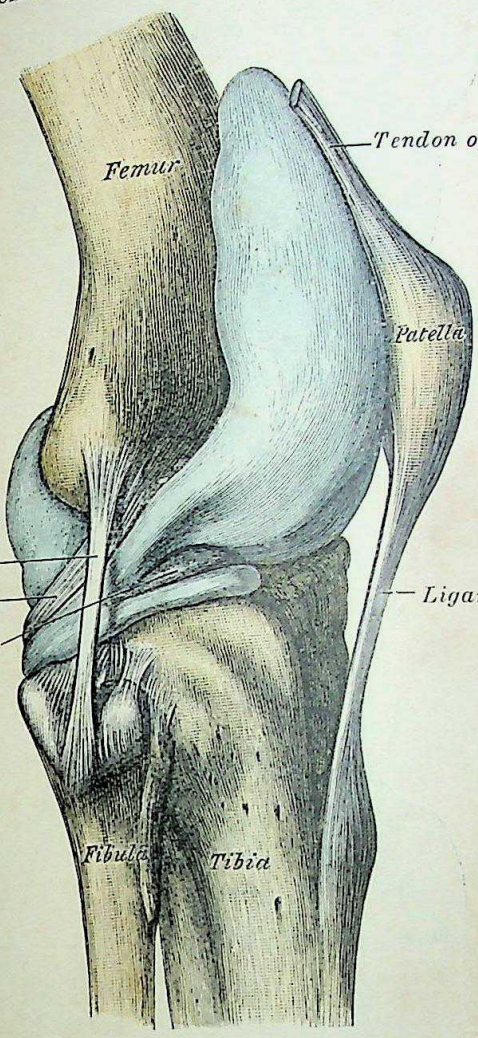

tum project into the interior of the joint. These form two fringe-like folds ed the *alar folds*; below, these folds converge and are continued as a single d the *patellar fold* (ligamentum mucosum), to the front of the intercondyloid of the femur (fig. 515). On either side of the joint, the synovial stratum es downwards from the femur, lining the fibrous stratum of the capsule as far attachment to the menisci; it may then be traced over the upper surfaces these to their free borders, and thence along their under surfaces to the At the back part of the lateral meniscus it forms a cul-de-sac between groove on the surface of the meniscus and the tendon of the Popliteus.

The **ligamentum patellæ** (fig. 517) is the central portion of the common on of the Quadriceps femoris, which is continued from the patella to the rosity of the tibia. It is a strong, flat, ligamentous band, about 8 cm. in gh, attached, above, to the apex and adjoining margins and to the rough ension on the posterior surface of the patella; and below, to the tuberosity the tibia; its superficial fibres are continuous over the front of the patella

CC-0. In Public Domain. Gurukul Kangri Collection, Haridwar

Digitized by Arya Samaj Foundation Chennai and eGangotri

FIG. 515.—The right knee-joint. Opened from the front.

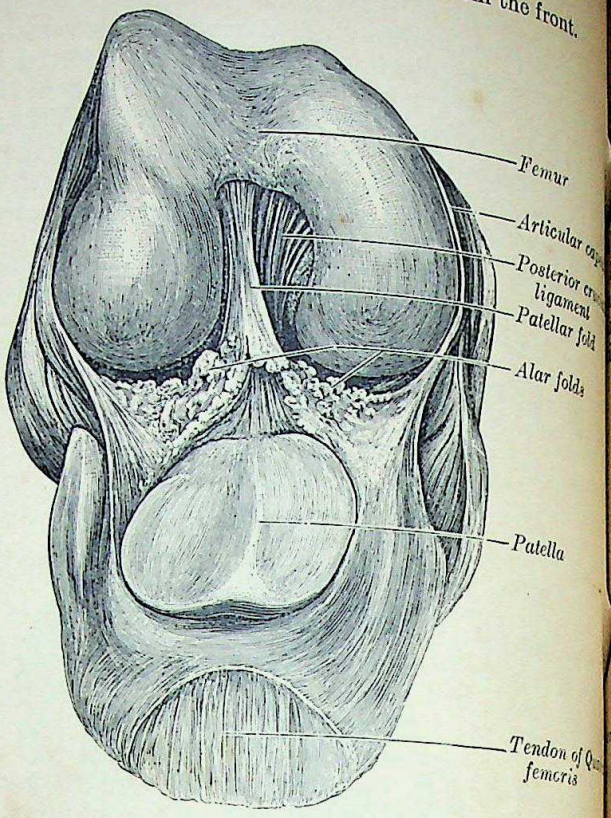

FIG. 516.—The articular capsule of the right knee-joint (distended). Poste aspect of the specimen represented in fig. 514.

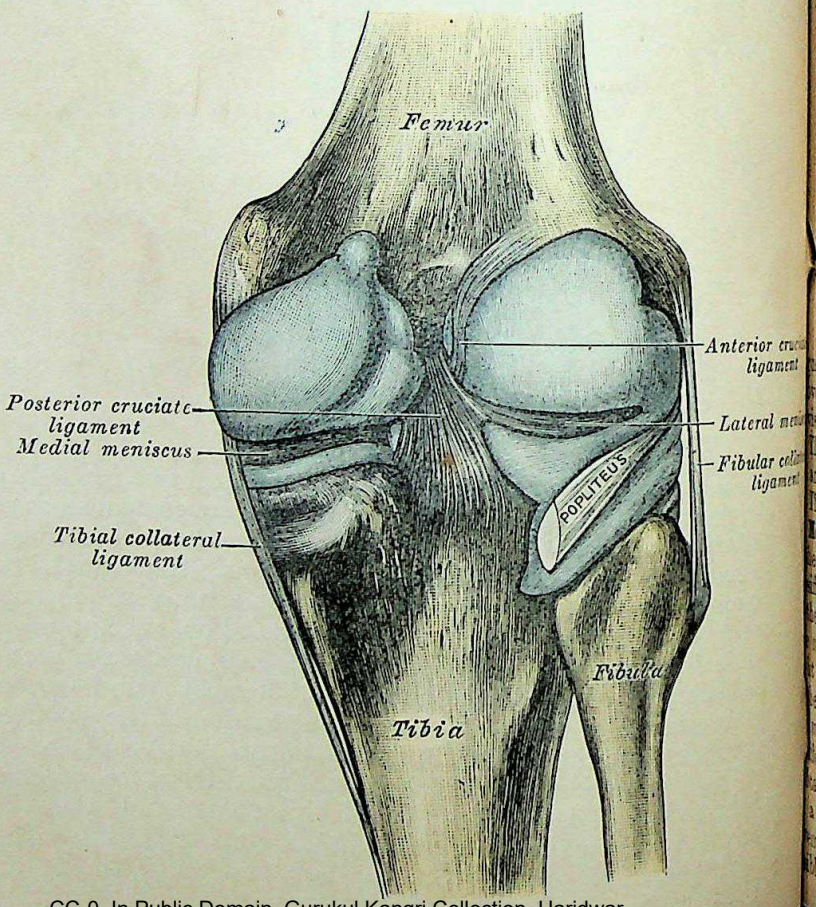

CC-0. In Public Domain. Gurukul Kangri Collection, Haridwar

Digitized by Arya Samaj Foundation Chennai and eGangotri

The **calcaneofibular ligament** (fig. 527) is a long rounded cord, running from the apex of the fibular malleolus downwards and slightly backwards to a tubercle on the lateral surface of the calcaneus. It is crossed by the tendons of the Peronæi longus et brevis.

The anterior and posterior talofibular and the calcaneofibular ligaments are formerly described as the three fasciculi of the *external lateral ligament* of the ankle-joint.

Relations.—The tendons, vessels, and nerves in relation with the joint are, in front from the medial side; the Tibialis anterior, Extensor hallucis longus, anterior tibial vessels, deep peronæal nerve, Extensor digitorum longus, and Peronæus tertius; behind, from the medial side, the Tibialis posterior, Flexor digitorum longus, posterior tibial vessels, tibial nerve, Flexor hallucis longus; and, in the groove behind the fibular malleolus, the tendons of the Peronæi longus et brevis.

Fig. 527.—The ligaments of the right ankle and tarsus. Lateral aspect.

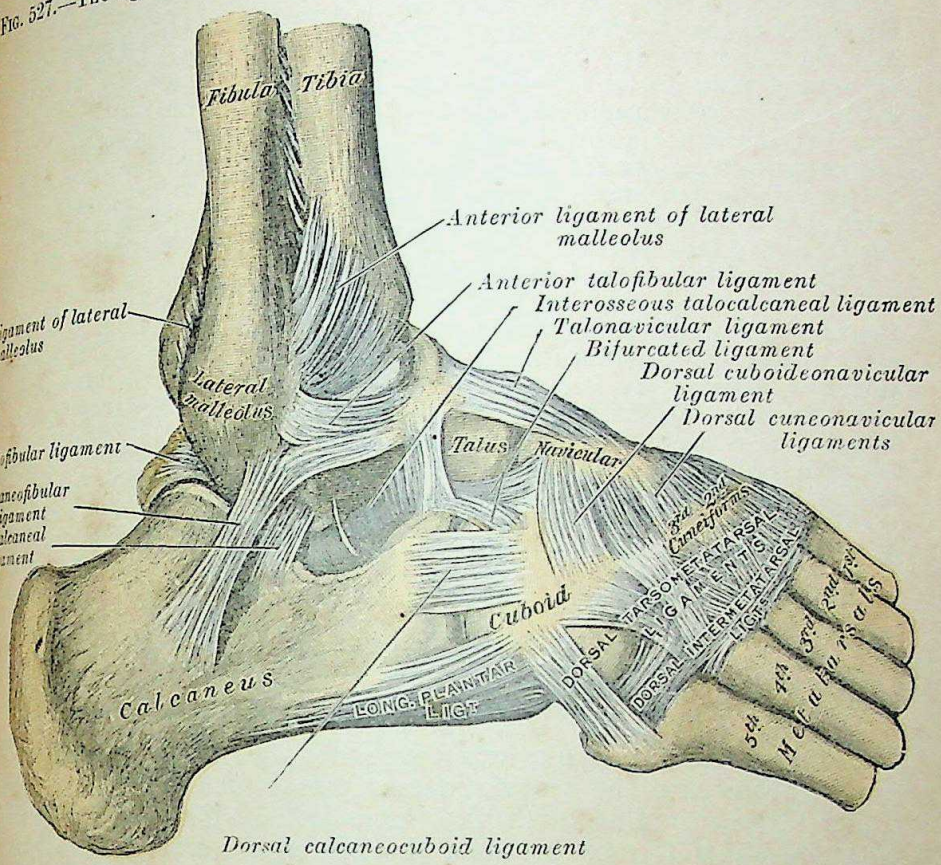

Dorsal calcaneocuboid ligament

The *arteries* supplying the joint are derived from the malleolar branches of the anterior tibial and from the peronæal.

The *nerves* are derived from the deep peronæal and tibial.

Movements.—When the body is in the erect position, the foot is at right angles to the leg. The movements of the ankle-joint are those of dorsiflexion and extension; dorsiflexion consists in the approximation of the dorsum of the foot to the front of the leg; in extension the heel is drawn up and the toes pointed downwards. The malleoli tightly embrace the talus in all positions of the joint, so that any slight degree of side-to-side movement which may exist is simply due to stretching of the ligaments of the distal talofibular joint, and slight bending of the fibula. The superior articular surface of the talus is broader in front than behind. In dorsiflexion, therefore, greater space is required between the two malleoli. This is obtained by a slight outward rotatory movement of the lower end of the fibula by a stretching of the ligaments of the distal talofibular joint; this lateral movement is facilitated by a slight gliding at the proximal tibiofibular joint, and also by the bending of the body of the fibula. Of the ligaments, the deltoid

CC-0. In Public Domain. Gurukul Kangri Collection, Haridwar

Digitized by Arya Samaj Foundation Chennai and eGangotri

is of great power—so much so, that it usually resists a force which fra process of bone to which it is attached. Its middle portion, together calcaneofibular ligament, binds the bones of the leg firmly to the foot, a displacement in every direction. Its anterior and posterior fibres limit and flexion of the foot respectively, and the anterior fibres also limit The posterior talofibular ligament assists the calcaneofibular in resisting placement of the foot backwards, and deepens the cavity for the recepti talus. The anterior talofibular ligament is a security against the dis of the foot forwards, and limits extension of the joint.

Muscles producing the movements :

Flexion.—Tibialis anterior, Extensor digitorum longus, Extensor longus, Peronæus tertius.

Extension.—Gastrocnemius, Soleus, Plantaris, Tibialis posterior, digitorum longus, Flexor hallucis longus, Peronæi longus et brevis

Applied Anatomy.—As the ankle-joint is a very strong and powerful articula placement of the talus from the tibiofibular mortise is a rare accident, and grea required to produce it. Nevertheless, dislocation does occasionally occur, either posteriorly or to one or other side. In the latter, which is the more common, is a necessary accompaniment of the injury. The dislocation in these cases is peculiar, and is not a displacement in a horizontal direction, such as usually o dislocations of ginglymoid joints, but the talus undergoes a partial rotation anteroposterior axis drawn through its own centre, so that the superior surface, being directed upwards, is inclined more or less medialwards or lateralwards acc the variety of the displacement.

The ankle-joint is more frequently sprained than any joint in the body, and lead to acute synovitis. In these cases, when the synovial sac is distended w the bulging appears principally in the front of the joint, beneath the anterior and on either side, between the Tibialis anterior and the deltoid ligament on th side, and between the Peronæus tertius and the anterior talofibular ligament In addition to this, bulging often occurs posteriorly, and a fluctuating swelling detected on either side of the tendo calcaneus. A large proportion of so-called of the ankle have been proved by *x*-ray examination to be some variety of fractu the malleoli, with or without displacement.

When disease or injury of the ankle-joint is likely to lead to ankylosis, the joi dorsiflexed to rather less than a right angle.

VII. THE INTERTARSAL ARTICULATIONS

1. The Talocalcaneal Articulation

There are two articulations between the calcaneus and talus, an and a posterior; the anterior forms part of the talocalcaneonavicular and will be described with that articulation. The posterior or talocal articulation is formed between the posterior calcaneal facet on the surface of the talus, and the posterior facet on the superior surface calcaneus. It is an arthrodial joint, and the two bones are conne articular capsule and by anterior, posterior, lateral, medial and inter talocalcaneal ligaments.

The **articular capsule** envelops the joint, and consists for the m of short fibres; it is split up into distinct slips, and between these only a weak fibrous investment. It is lined with a synovial stratum, joint-cavity does not communicate with any of the other tarsal joints.

The **anterior talocalcaneal ligament** (fig. 530) extends from the and lateral surfaces of the neck of the talus to the superior surface calcaneus.

The **posterior talocalcaneal ligament** (fig. 526) connects the tubercle on the posterior surface of the talus with the upper and medi of the calcaneus; it is a short band, and its fibres radiate from their attachment to the talus.

The **lateral talocalcaneal ligament** (figs. 524, 527) is a short, fasciculus, passing from the lateral surface of the talus, immediately b its fibular facet, to the lateral surface of the calcaneus. It is placed i of, but on a deeper plane than, the calcaneofibular ligament, with the of which it is parallel.

CC-0. In Public Domain. Gurukul Kangri Collection, Haridwar

Digitized by Arya Samaj Foundation Chennai and eGangotri

The medial talocalcaneal ligament connects the medial tubercle on the erior surface of the talus with the back of the sustentaculum tali. Its fibres d with those of the plantar calcaneonavicular ligament.

The interosseous talocalcaneal ligament (figs. 524, 528) is very thick trong, and forms the chief bond of union between the bones. It is, in a portion of the united capsules of the talocalcaneonavicular and the alcaneal joints, and consists of two partially united layers of fibres, one ging to the former and the other to the latter joint. It is attached, w, to the sulcus tali; below, to the sulcus calcanei.

Movements.—The movements permitted between the talus and calcaneus are ed to gliding of the one bone on the other, backwards and forwards and from to side.

Fig. 528.—A coronal section through the right talocrural and talocalcaneal joints.

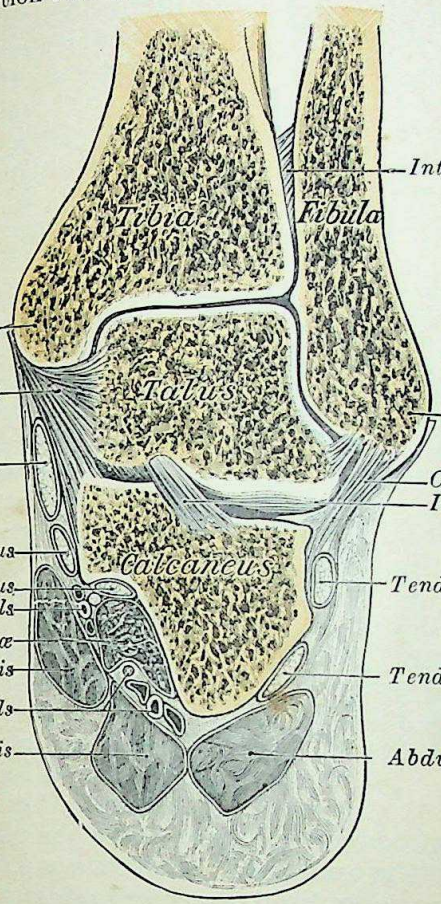

2. The Talocalcaneonavicular Articulation

This articulation is an arthrodial joint: the rounded head of the talus g received into the concavity formed by the posterior surface of the navi- r bone, the anterior articular surface of the calcaneus, and the upper surface e plantar calcaneonavicular ligament. There are two ligaments in this : the articular capsule and the talonavicular.

The articular capsule is imperfectly developed except posteriorly, where considerably thickened and forms, with a part of the capsule of the talo- neal joint, the strong interosseous ligament which fills the sinus tarsi d by the opposing sulci on the calcaneus and talus, as mentioned above.

The talonavicular ligament (fig. 526) is a broad, thin band, connecting ck of the talus to the dorsal surface of the navicular bone; it is covered the extensor tendons. The plantar calcaneonavicular ligament supplies ace of a plantar ligament for this joint.

Movements.—This articulation permits of a considerable range of gliding ements.

CC-0. In Public Domain. Gurukul Kangri Collection, Haridwar

Digitized by Arya Samaj Foundation Chennai and eGangotri

3. The Calcaneocuboid Articulation

The articular surfaces of the calcaneocuboid joint are somewh shaped. The ligaments of the joint are: the articular capsule, th calcaneocuboid, the calcaneocu tion of the bifurcated ligam long plantar, and the plantar cuboid.

Fig. 529.—The ligaments of the plantar surface of the right foot.

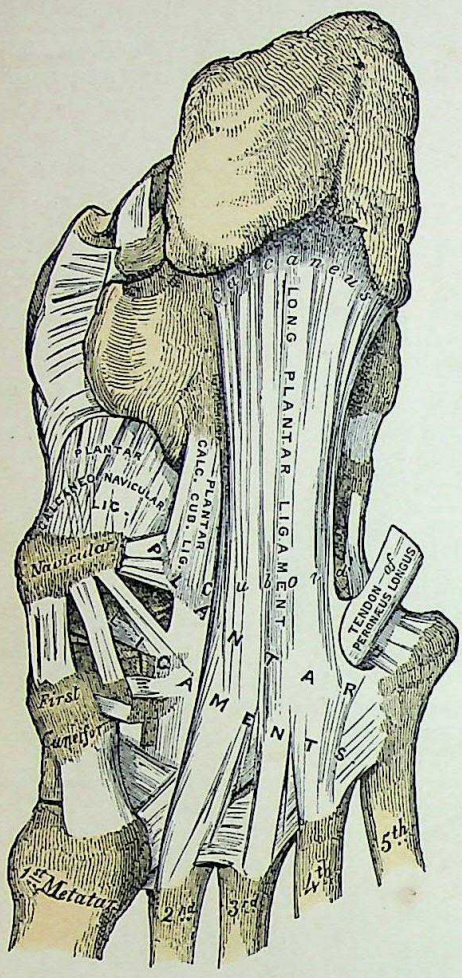

The **articular capsule** certain bands, which form ligaments of the joint. Its stratum is distinct from the other tarsal articulations (fig.

The **dorsal calcaneocub ment** (fig. 527) is a thin b fasciculus, which passes betw contiguous surfaces of the ca and the cuboid bone, on the surface of the joint.

The **bifurcated** ligame 527, 530) is a strong band behind to the deep hollow on th surface of the calcaneus and in front in a **Y**-shaped manne calcaneocuboid and a calca cular part. The *calcaneocub* is fixed to the medial side of the bone and forms one of the bonds between the first and rows of the tarsal bones. The *navicular part* is attached to the side of the navicular bone.

The **long plantar** ligame 529), the longest of the tarsal lig is attached behind to the surface of the calcaneus in front tuberosity, and in front to the tu on the plantar surface of the bone, the more superficial fibre continued forwards to the bases second, third, and fourth me bones. This ligament converts the groove on the plantar surface of the bone into a canal for the tendon of the Peronæus longus.

The **plantar calcaneocuboid ligament** (short plantar ligament) lies nearer to the bones than the preceding, from which it is separate little areolar tissue. It is a short but wide band of great streng extends from the tubercle and the depression in front of it, on the fo of the plantar surface of the calcaneus, to the plantar surface of the bone behind the peronæal groove.

Movements.—The movements permitted between the calcaneus and the bone are limited to slight gliding of the bones upon each other.

The *transverse tarsal joint* is formed by the articulation of the calcaneu the cuboid bone, and the articulation of the talus with the navicular bon movement which takes place in this joint is more extensive than that in th tarsal joints, and consists of a sort of rotation by means of which the foot slightly flexed or extended, the sole being at the same time carried medi (inverted) or lateralwards (everted).

Muscles producing the movements :

Inversion.—Tibialis anterior, Tibialis posterior.

Eversion.—Peronæus longus.

CC-0. In Public Domain. Gurukul Kangri Collection, Haridwar

Digitized by Arya Samaj Foundation Chennai and eGangotri

4. The Ligaments connecting the Calcaneus and Navicular

Though the calcaneus and the navicular bone do not directly articulate, are connected by two ligaments: the calcaneonavicular part of the rcated, and the plantar calcaneonavicular.

The calcaneonavicular part of the bifurcated ligament is described p. 426.

The plantar calcaneonavicular ligament (fig. 530) is a broad, thick band necting the anterior margin of the sustentaculum tali of the calcaneus to plantar surface of the navicular bone. This ligament not only unites the aneus with the navi- ar bone, but supports head of the talus, ming part of the arti- ar cavity in which it received. The *dorsal face* of the ligament ents a fibrocartilagi- s facet, lined with the vial stratum, and upon a portion of the head the talus rests. Its *lar surface* is supported the tendon of the alis posterior; its *al border* is blended h the anterior part of deltoid ligament of the le-joint. The plantar aneonavicular and tar calcaneocuboid aments together form *deep ligament* of the ns.

Fig. 530.—The right talocalcaneal and talocalcaneonavicular articulations, exposed by removing the talus. Superior aspect.

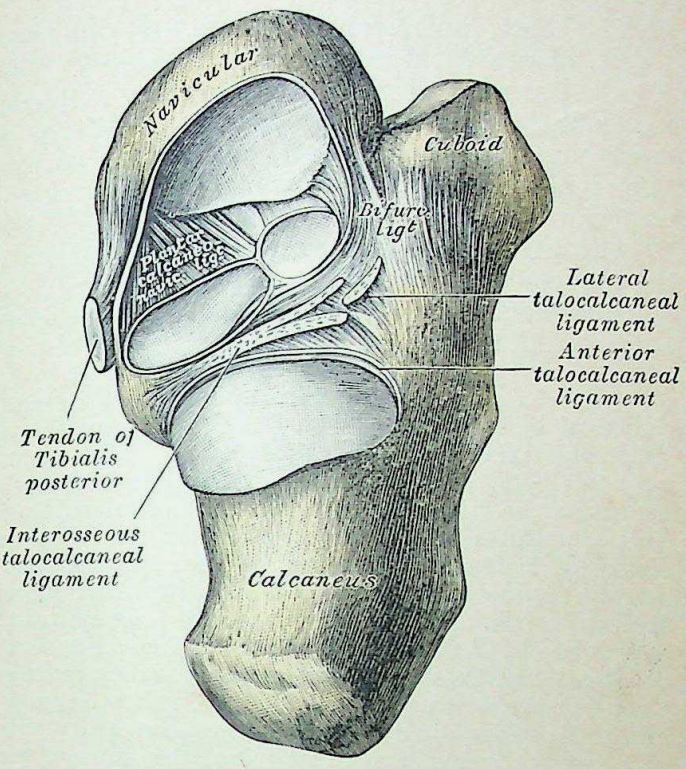

pplied Anatomy. — The lar calcaneonavicular liga- t, by supporting the head of talus, is concerned in main- ng the arch of the foot. it yields the head of lus is pressed downwards, medialwards, and forwards by the weight of the body, the foot becomes flattened, expanded, and turned lateralwards, and exhibits the tion known as *flat-foot*. This ligament contains a considerable amount of elastic e, so as to give elasticity to the arch and spring to the foot; hence it is sometimes d the 'spring' ligament. It is supported, on its plantar surface, by the tendon of Tibialis posterior, which spreads out at its insertion into a number of fasciculi, to be ched to most of the tarsal and metatarsal bones. This prevents undue stretching s ligament, and is a protection against the occurrence of flat-foot; hence muscular ess is, in most cases, the primary cause of the deformity.

5. The Cuneonavicular Articulation

The navicular bone is connected to the three cuneiform bones by dorsal and tar ligaments.

The dorsal ligaments are three small fasciculi, one attached to each of the iform bones. The fasciculus connecting the navicular bone with the first iform bone is continuous round the medial side of the articulation with the ar ligament which unites these two bones.

The plantar ligaments have a similar arrangement to the dorsal, and are engthened by slips from the tendon of the Tibialis posterior.

Movements.—Gliding movements are permitted between the navicular and iform bones.

CC-0. In Public Domain. Gurukul Kangri Collection, Haridwar

Digitized by Arya Samaj Foundation Chennai and eGangotri

6. The Cuboideonavicular Articulation

The cuboid bone is connected with the navicular bone by dorsal, p and interosseous ligaments.

The **dorsal ligament** extends obliquely forwards and lateralward the **plantar** passes nearly transversely from the cuboid bone to the n bone

The **interosseous ligament** consists of strong transverse fib connects the rough non-articular portions of the adjacent surfaces of bones.

Movements.—The movements permitted between the navicular and cub are limited to a slight gliding upon each other.

7. The Intercuneiform and Cuneocuboid Articulations

The three cuneiform bones and the cuboid bone are connected toge dorsal, plantar, and interosseous ligaments.

The **dorsal and plantar ligaments** each consist of three transverse one connects the first and second cuneiform bones, another the seco third cuneiform bones, and another the third cuneiform and cuboid The plantar ligaments are strengthened by slips from the tendon of the posterior.

The **interosseous ligaments** connect the rough non-articular por the adjacent surfaces of the bones.

Movements.—The movements permitted between these bones are lim a slight gliding upon each other.

Applied Anatomy.—In spite of the great strength of the ligaments which the tarsal bones together, dislocation at some of the tarsal joints does occasiona When this takes place, it is most commonly in connexion with the talus; for may this bone be dislocated from the tibia and fibula at the ankle-joint, but t bones may be dislocated from it, the talus remaining *in situ* in the tibiofibular This constitutes what is known as the *subtalar* dislocation. Or, again, the talus dislocated from all its connexions—from the tibia and fibula above, the calcaneu and the navicular in front—and may even undergo a rotation, on either a vert horizontal axis. In the former case the long axis of the bone is directed across t so that the head faces the articular surface on one or other malleolus; in the la collateral surfaces are directed upwards and downwards, so that the superior surf to one or the other side. Reduction in these cases is often very difficult or imp and the displaced talus may require removal by open operation. Dislocation m occur at the transverse tarsal joint, the anterior tarsal bones being luxated f talus and calcaneus. The other tarsal bones are occasionally, though rarely, di from their connexions.

The talus is sometimes removed to remedy certain types of club-foot. The in made between the tendons of the Peronæus tertius and Peronæus brevis; the anter posterior talofibular and the calcaneofibular ligaments are divided, and the ank freely opened. In separating the medial side of the talus, the deltoid ligament sheath of the Flexor hallucis longus must be divided close to the bone.

VIII. THE TARSOMETATARSAL ARTICULATIONS

These are arthrodial joints. The first metatarsal bone articulates w first cuneiform bone; the second is deeply wedged in between the f third cuneiform bones, articulating by its base with the second cu bone; the third articulates with the third cuneiform bone; the fourth the cuboid and third cuneiform bones; and the fifth with the cuboid The bones are connected by dorsal, plantar, and interosseous ligaments

The **dorsal ligaments** are strong, flat bands. The first metata joined to the first cuneiform bone by an articular capsule; the seco tarsal receives three bands, one from each cuneiform bone; the thi from the third cuneiform bone; the fourth, one from the third cuneifor and another from the cuboid bone; and the fifth, one from the cuboid b

The **plantar ligaments** consist of longitudinal and oblique bands, d with less regularity than the dorsal ligaments. Those for the first and s

CC-0. In Public Domain. Gurukul Kangri Collection, Haridwar

Digitized by Arya Samaj Foundation Chennai and eGangotri

tatarsal bones are the strongest; the second and third metatarsal bones are ted by oblique bands to the first cuneiform bone; the fourth and fifth tatarsal bones are connected by a few fibres to the cuboid bone.

The interosseous ligaments are three in number. The first is the strongest passes from the lateral surface of the first cuneiform bone to the adjacent e of the second metatarsal bone. The second connects the third cuneiform e with the adjacent angle of the second metatarsal bone. The third connects lateral angle of the third cuneiform bone with the adjacent side of the of the third metatarsal bone.

Movements.—The movements permitted between the tarsal and metatarsal es are limited to slight gliding of the bones upon each other.

IX. THE INTERMETATARSAL ARTICULATIONS

The base of the first metatarsal bone is not connected with that of the second any ligaments; in this respect the great toe resembles the thumb.

FIG. 531.—An oblique section through the left intertarsal and tarsometatarsal articulations, showing the synovial cavities.

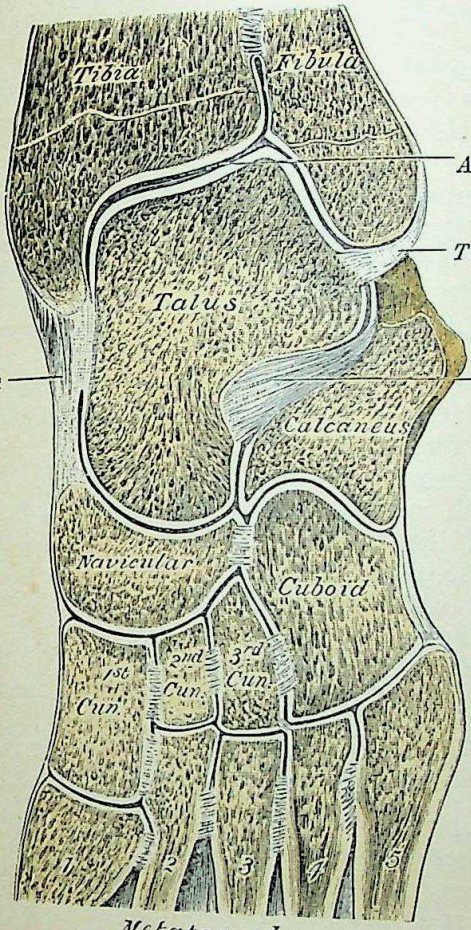

The bases of the second, third, fourth, and fifth metatarsal bones are nected by dorsal, plantar, and interosseous ligaments.

The heads of all the metatarsal bones are connected by the transverse tarsal ligament.

The **dorsal and plantar ligaments** pass transversely between the bases adjacent bones.

The **interosseous ligaments** consist of strong transverse fibres which ect the rough non-articular portions of the adjacent surfaces.

The **transverse metatarsal ligament** is a narrow band which runs across connects together the heads of all the metatarsal bones; it is blended

CC-0. In Public Domain. Gurukul Kangri Collection, Haridwar

Digitized by Arya Samaj Foundation Chennai and eGangotri

anteriorly with the accessory plantar ligaments of the metatarsopha[illegible] articulations. Its plantar surface is concave where the flexor tend[illegible] below it; above it the tendons of the Interossei pass to their inserti[illegible] differs from the transverse metacarpal ligament in that it connects t[illegible] metatarsal to the others.

Movements.—The movements permitted between the tarsal ends of th[illegible] tarsal bones are limited to a slight gliding of the articular surfaces one upon a[illegible]

The **synovial cavities** (fig. 531) present in the articulations of the [illegible] and metatarsus are six in number: one for the talocalcaneal articulati[illegible] second for the talocalcaneonavicular articulation; a third for the ca[illegible] cuboid articulation; a fourth for the cuneonavicular, intercuneiform[illegible] cuneocuboid articulations, the articulations of the second and third cu[illegible] bones with the bases of the second and third metatarsal bones, and the a[illegible] surfaces of the bases of the second, third, and fourth metatarsal bones; [illegible] for the first cuneiform bone with the metatarsal bone of the great toe; [illegible] sixth, for the articulation of the cuboid bone with the fourth and fifth met[illegible] bones. A small synovial cavity is sometimes found between the con[illegible] surfaces of the navicular and cuboid bones; it may communicate wit[illegible] between the cuboid and third cuneiform bones.

X. THE METATARSOPHALANGEAL ARTICULATIONS

The metatarsophalangeal articulations are of the condyloid kind, [illegible] by the reception of the rounded heads of the metatarsal bones in [illegible] cavities on the bases of the first phalanges.

The ligaments are the accessory plantar and collateral.

The **accessory plantar ligaments** (glenoid ligaments of Cruveilhi[illegible] thick, dense, fibrous structures. They are placed on the plantar surf[illegible] the joints in the intervals between the collateral ligaments, to which th[illegible] connected; they are loosely united to the metatarsal bones, but are [illegible] fixed to the bases of the first phalanges. Their plantar surfaces are intim[illegible] blended with the transverse metatarsal ligament, and grooved for the [illegible] tendons, the fibrous sheaths of which are connected to the sides o[illegible] grooves; the deep surfaces of the ligaments form parts of the articular [illegible] for the heads of the metatarsal bones.

The **collateral ligaments** are two strong, rounded cords, placed o[illegible] sides of the joints; each is attached by one end to the posterior tuber[illegible] the side of the head of the metatarsal bone, and by the other to the [illegible] sponding side of the base of the phalanx.

The place of *dorsal ligaments* is supplied by the extensor tendons o[illegible] dorsal surfaces of the joints.

Movements.—The movements permitted in the metatarsophalangeal ar[illegible] tions are flexion, extension, adduction, abduction and circumduction.

Muscles producing the movements:

Flexion.—Flexores digitorum longus et brevis, Quadratus plantæ, Lumb[illegible] Interossei dorsales et plantares, Flexores hallucis longus et brevis, [illegible] digiti quinti proprius.

Extension.—Extensores digitorum longus et brevis, Extensor hallucis l[illegible]

Adduction.—Interossei plantares, Adductor hallucis, long flexors of toes.

Abduction.—Interossei dorsales, Abductor hallucis, Abductor digiti q[illegible]

XI. THE ARTICULATIONS OF THE DIGITS

The interphalangeal articulations are hinge-joints, and each has a plant[illegible] two collateral ligaments.

The arrangement of these ligaments is similar to that in the metatarsopha[illegible] articulations: the extensor tendons supply the places of dorsal ligaments.

Movements.—The only movements permitted in the joints of the digi[illegible] flexion and extension; these movements are more extensive between the fir[illegible] second phalanges than between the second and third. The amount of flexion i[illegible] considerable, but extension is limited by the accessory plantar ligaments.

CC-0.In Public Domain. Gurukul Kangri Collection, Haridwar

Digitized by Arya Samaj Foundation Chennai and eGangotri

Muscles producing the movements:

Flexion.—Flexores digitorum longus et brevis, Quadratus plantæ, Flexor hallucis longus.

Extension.—Lumbricales, Interossei dorsales et plantares, Extensor hallucis longus, Extensores digitorum longus et brevis.

Applied Anatomy.—When the head of the first metatarsal bone is removed for the disease which occurs in chronic arthritis, the sesamoid bones in the Flexor hallucis tendon should not be removed, since they form a protection to the new joint. The bursa over the head of the metatarsal bone is used in this operation to make the new joint-cavity.

The Arches of the Foot

In order that the foot may support the weight of the body in the erect posture with the least expenditure of material, it is constructed of a series of arches formed by the tarsal and metatarsal bones, and strengthened by the ligaments, tendons and muscles of the foot.

The main arches are the anteroposterior arches, which may be regarded as divisible into two types—a medial and a lateral.

Fig. 532.—The skeleton of the left foot. Medial aspect.

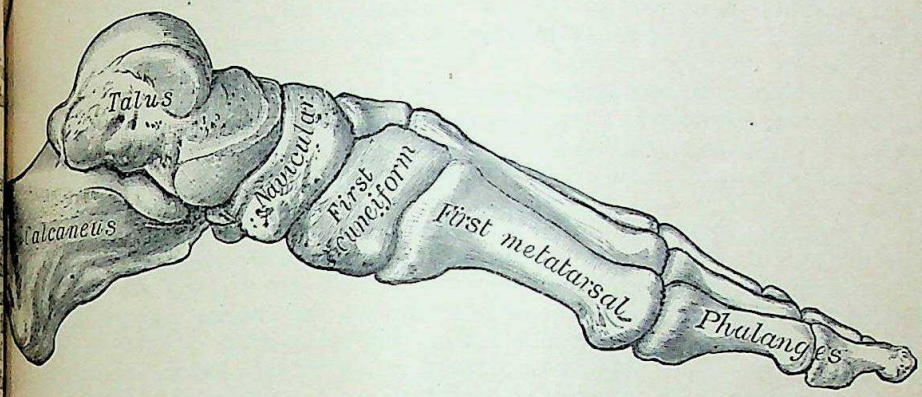

Fig. 533.—The skeleton of the left foot. Lateral aspect.

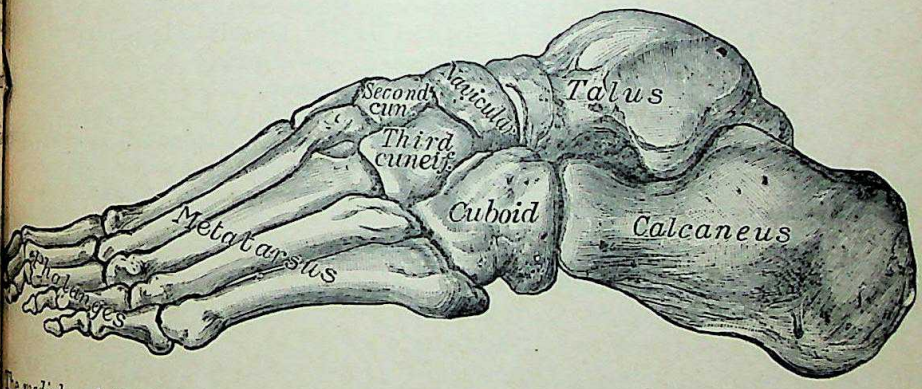

The *medial arch* (fig. 532) is made up by the calcaneus, the talus, the navicular, the three cuneiform, and the first, second, and third metatarsal bones. Its summit is the superior articular surface of the talus, and its two extremities or piers, on which it rests in standing, are the tuberosity on the plantar surface of the calcaneus posteriorly, and the heads of the first, second, and third metatarsal bones anteriorly. The chief characteristic of this arch is its elasticity, due to its height and to the number of joints between its component parts. Its weakest part, the part most liable to yield from over-pressure, is the joint between the talus and the navicular bone, but this is braced by the plantar calcaneonavicular ligament, which is elastic and is thus able quickly to restore the arch when the disturbing force is removed. This ligament is strengthened medially by blending with the deltoid ligament of the ankle-joint, and is supported inferiorly by the tendon of

CC-0. In Public Domain. Gurukul Kangri Collection, Haridwar

Digitized by Arya Samaj Foundation Chennai and eGangotri

the Tibialis posterior. The arch is further supported by the plantar a
by the small muscles in the sole of the foot, by the tendon of the Tibialis
and by the ligaments of all the articulations involved.

The *lateral arch* (fig. 533) is composed of the calcaneus, the cuboid,
fourth and fifth metatarsal bones. Its summit is at the talocalcaneal art
and its chief joint is the calcaneocuboid, which possesses a special mech
locking, and allows only a limited movement. The most marked feature
arch are its solidity and its slight elevation; two strong ligaments, the lon
and the plantar calcaneocuboid, the tendon of the Peronæus longus, the
tendons, and the short muscles of the little toe, preserve its integrity.

In addition to the longitudinal arches the foot presents a series of tr
arches. At the posterior part of the metatarsus and the anterior part of th
the arches are complete, but in the middle of the tarsus they present
characters of half-domes the concavities of which are directed downwa
medialwards, so that when the medial borders of the feet are placed in a
a complete tarsal dome is formed. The transverse arches are strengthened
interosseous, plantar, and dorsal ligaments, by the short muscles of the first
toes (especially the transverse head of the Adductor hallucis), and by the P
longus, the tendon of which stretches between the piers of the arches.

Applied Anatomy.—Pes planus or flat-foot is a very common deformity d
disappearance of the arches of the foot, from subsidence dependent on stretchi
plantar ligaments. In its early stages before the deformity is marked it is acco
by considerable pain from pressure on the plantar nerves, but when the condition
formed and the head of the talus has descended completely, the condition is pai
irremediable.

The stretching of the ligaments in this condition is most often due to muscu
ness in young adults who may have to stand for long periods daily. The deep
especially the posterior tibial group, by their tonicity are the most potent in ma
the longitudinal arch, and when overtired they relax and throw the strain on the
ligaments which yield secondarily. All three posterior tibial muscles are eff
thus supporting the longitudinal arch, but perhaps the most important one is the
hallucis longus which normally stretches like a bow-string across the whole
posterior length of the arch.

The transverse arch subsequently disappears, this having been largely held up
Peronæus longus. In the treatment of this static form of flat-foot, muscular
essential in the early stages, as once the ligamentous tissues are stretched, t
unable to return to their original condition.

There are, however, other forms of flat-foot, viz. the congenital, and the p
(due to affections of the nerve-centres supplying the post-tibial group of muscles
due to inflammation of the tarsal joints and those following injuries to the tar
metatarsus. If in the two later forms the patient put his weight on the foot be
normal condition has been fully established, pes planus is certain to result, a
arches will not be capable of restoration subsequently.

Pes cavus, the opposite of pes planus, is usually due to some contracture
posterior tibial group in certain affections of the medulla spinalis. It is also co
seen in association with talipes equinus or equinovarus, and here the longitudinal
of the foot is greatly increased, with contraction of the plantar aponeurosis which
instances becomes very pronounced.

CC-0. In Public Domain. Gurukul Kangri Collection, Haridwar

Digitized by Arya Samaj Foundation Chennai and eGangotri

MYOLOGY*

HE muscles are connected with the bones, cartilages, ligaments, and skin, either directly, or through the intervention of fibrous structures called ons or aponeuroses. Where a muscle is attached to bone or cartilage, the s end in blunt extremities upon the periosteum or perichondrium, and do come into direct relation with the osseous or cartilaginous tissue. Where les are connected with the skin, they lie as a flattened layer beneath it, and nited with its areolar tissue by larger or smaller bundles of fibres.

Muscles vary in their form. In the limbs, they are of considerable length, ecially the more superficial ones; they surround the bones, and constitute important protection to the joints. In the trunk, they are broad and tened, and assist in forming the walls of the trunk cavities. Hence the ion of the terms, *long, broad, short*, &c., used in the description of muscles.

There is considerable variation in the arrangement of the fibres of certain cles with reference to the tendons to which they are attached. In some cles the fibres are parallel and run directly from their origin to their ertion; these are quadrilateral muscles, such as the Thyreohyoideus. A dification of these is found in the fusiform muscles, in which the fibres are quite parallel, but slightly curved, so that the muscle tapers at either end; their mode of action, however, they resemble the quadrilateral muscles. ther muscles the fibres arise by a broad origin and converge to a narrow or ted insertion; this arrangement is found in the triangular muscles—e.g. Temporalis. In some muscles, which otherwise would belong to the drilateral or triangular type, the origin and insertion are not in the same ne, the plane of the line of origin intersecting that of the line of insertion: h is the case in the Pectineus. In some muscles (e.g. the Peronæi) the fibres oblique and are attached to one side of a tendon; such muscles are termed nnate. A modification of this condition is found where oblique fibres ired to both sides of a central tendon; such muscles are called bipennate, an example is afforded in the Rectus femoris. Finally, there are muscles hich the fibres are arranged in curved bundles in one or more planes, as in Sphincters. The arrangement of the fibres is of considerable importance respect to the relative strength and range of movement of the muscle. Those scles where the fibres are long and few in number have great range, but minished strength; where, on the other hand, the fibres are short and more merous, there is great power, but lessened range.

The names applied to the various muscles have been derived: 1, from their ation, as the Tibialis anterior, Tibialis posterior; 2, from their direction, as the ms abdominis, Obliqui capitis, Transversus abdominis; 3, from their uses, Flexors, Extensors, Abductors, &c.; 4, from their shape, as the Deltoideus, mboideus; 5, from the number of their divisions, as the Biceps, and Triceps; from their attachment, as the Sternocleidomastoideus, Sternohyoideus, rnothyreoideus.

* The muscles and fasciæ are described conjointly, in order that the student may consider arrangement of the latter in his dissection of the former. It is rare for the student of anatomy ose country to have the opportunity of dissecting the fasciæ separately; and it is for this son, as well as from the close connexion that exists between the muscles and their investing ia, that they are considered together. Some general observations are first made on the ny of the muscles and fasciæ, the special descriptions being given in connexion with the ent regions.

CC-0. In Public Domain. Gurukul Kangri Collection, Haridwar

Digitized by Arya Samaj Foundation Chennai and eGangotri

In the description of a muscle, the term *origin* is meant to imply its m or central attachment; and the term *insertion* the movable point to w force of the muscle is applied; but the origin is absolutely fixed in only number of muscles, such as those of the face which are attached by one immovable bones, and by the other to the movable skin. Most of the mu be made to act from either end.

In the dissection of the muscles, attention should be directed to the origi *tion*, and *actions* of each, and to their more important *relations* with sur parts. While accurate knowledge of the points of attachment of the mus great importance in determining their actions, it is not to be regarded as co The action of the muscle deduced from its attachments, or even by pulling the dead subject, is not necessarily its action in the living. By pulling, for on the Brachioradialis in the cadaver the hand may be slightly supinated the prone position and slightly pronated when in the supine position, but th evidence that these actions are performed by the muscle during life. It is im for an individual to throw into action any one muscle; in other words, mov not muscles, are represented in the central nervous system. To carry out ment a definite combination of muscles is called into play, and the individ no power either to leave out a muscle from this combination, or to add one One (or more) muscle of the combination is the chief moving force; wh muscle passes over more than one joint, other muscles (synergic muscles) co play to inhibit the movements not required; a third set of muscles (fixation m fix the limb—i.e. in the case of the limb-movements—and also prevent distu of the equilibrium of the body generally. As an example, the movement closing of the fist may be considered: (1) the prime movers are the Flexor torum, Flexor pollicis longus, and the small muscles of the thumb; (2) the s muscles are the Extensores carpi, which prevent flexion of the wrist; while fixation muscles are the Biceps and Triceps brachii, which steady the elb shoulder. A further point which must be borne in mind in considering the of muscles is that in certain positions a movement can be effected by grav in such a case the muscles acting are the antagonists of those which m supposed to be in action. Thus in flexing the trunk when no resistance is im the Sacrospinales contract to regulate the action of gravity, and the Recti ab are relaxed.*

The minute anatomy of muscular tissue is described on pp. 29 to 33.

Applied Anatomy.—By a consideration of the actions of the muscles, the su able to explain the causes of displacement in various forms of fracture, and the which produce distortion in various deformities, and, consequently, to adopt appr treatment in each case. The relations, also, of some of the muscles, especially t immediate apposition with the large blood-vessels, and the surface markings they p should be remembered, as they form useful guides in the application of ligatures to vessels. Degeneration of muscular tissue is important clinically, and is met with i main conditions. In one, the degeneration is myopathic, or primary in the muscles selves; in the other it is neuropathic, or secondary to some lesion of the nervous sys a hæmorrhage into the brain, for example, or injury or inflammation of some part medulla spinalis or peripheral nerves. In either case more or less paralysis and of the affected muscles result. When the degeneration begins primarily in the m however, it often happens that though the muscle-fibres waste away, their place is by fibrous and fatty tissue to such an extent that the affected muscles increase in and actually appear to hypertrophy.

Ossification of muscular tissue as a result of repeated strain or injury is not infr It is oftenest found about the tendon of the Adductor longus in horsemen, in the Pe major and Deltoideus of soldiers, or in the tendon of the Brachialis after dislocation elbow. It may take the form of exostoses firmly fixed to the bone—e.g. 'rider's on the femur—or of layers or spicules of bone lying in the muscles or their fascia tendons. Busse states that these bony deposits are preceded by a hæmorrhagic m due to injury, the effused blood organising and being finally converted into bone. rarer disease, progressive myositis ossificans, there is an unexplained tendency for cally any of the voluntary muscles to become converted into solid and brittle bony which are completely rigid.

* Consult in this connexion 'Muscular Movements and their representation in the C Nervous System,' by C. E. Beevor (1903), 'The Action of Muscles,' by W. Colin Mackenzie 'The principles of Anatomy as seen in the hand,' F. Wood Jones (1920).

CC-0. In Public Domain. Gurukul Kangri Collection, Haridwar

Digitized by Arya Samaj Foundation Chennai and eGangotri

THE TENDONS, APONEUROSES, AND FASCIÆ

e tendons are white, glistening cords, varying in length and thickness, evoid of elasticity. They consist almost entirely of white fibrous tissue, ibrils of which have an undulating course parallel with each other and are y united together. They are very sparingly supplied with blood-vessels, smaller tendons presenting in their interior no trace of them. Nerves ying tendons end in what are known as neurotendinous spindles or organs lgi; these are described with the organs of the senses.

he aponeuroses are flattened or ribbon-shaped tendons, of a pearly-white r, iridescent and glistening; they are only sparingly supplied with blood-

he tendons and aponeuroses connect the muscles with the movable struc- s, such as the bones and cartilages. Where the end of a muscle is continued ly into a tendon, the line of junction between the two is usually well- ed, but where the muscle meets the tendon obliquely, bundles of tendon s generally run for a variable distance into the substance of the muscle, t the line of junction is irregular. Microscopic examination shows that, er case, the tendon is subdivided into small bundles, corresponding in nd number with the fibres of the muscle. Each muscular fibre ends more or less rounded extremity covered by sarcolemma, and the fibres of tendon bundle are intimately united with the sarcolemma covering the of the muscular fibre. The mode of union is well shown when the muscle has shrunk inside its sarcolemma.

he fasciæ are fibro-areolar or aponeurotic laminæ, of variable thickness strength, found in all regions of the body, investing the softer and more ate organs. During the process of development many of the cells of the oderm are differentiated into bones, muscles, vessels, &c.; the cells of esoderm which are not so utilised form an investment for these structures are differentiated into the true skin and the fasciæ of the body. The e are subdivided into superficial and deep.

he *superficial fascia* is found immediately beneath the integument over st the entire surface of the body. It connects the skin to the subjacent , and consists of fibro-areolar tissue, containing in its meshes pellicles t in varying quantity. It varies in thickness in different parts of the ; in the groin it is so thick that it may be subdivided into several laminæ. ith the fatty layer there is generally another layer of superficial fascia, st devoid of adipose tissue, in which the trunks of the subcutaneous vessels nerves and the superficial lymph-glands are found. Certain cutaneous s are situated in the superficial fascia, e.g. the Platysma and the muscles e face. The superficial fascia is most distinct at the lower part of the men, perinæum, and extremities; it is very thin in those regions where ular fibres are inserted into the integument, as on the side of the neck, e face, and around the anus. It is very dense in the scalp, palms of the , and soles of the feet, forming a fibrofatty layer, which binds the integu- firmly to the underlying structures. It facilitates the movement of kin, serves as a soft nidus for the passage of vessels and nerves to the , and retains the warmth of the body, since the fat contained in its areolæ bad conductor of heat.

he *deep fascia* is a dense, inelastic membrane, forming sheaths for the les, and in some cases affording them broad surfaces for attachment. consists of shining tendinous fibres, placed parallel with one another, and ected together by other fibres disposed in a rectilinear manner. It forms ing investment which not only binds down collectively the muscles in each n, but gives a separate sheath to each, as well as to the vessels and nerves. sists the muscles in their actions by the degree of tension and pressure kes upon their surfaces; in certain situations the degree of tension and ure is regulated by muscles, as, for instance, by the Tensor fasciæ latæ Glutæus maximus in the thigh, and the Palmaris longus in the hand. In limbs, the fascia not only invests the limb, but gives off septa which separate various muscles, and are attached to the periosteum; these prolongations asciæ are usually spoken of as intermuscular septa.

CC-0. In Public Domain. Gurukul Kangri Collection, Haridwar

Digitized by Arya Samaj Foundation Chennai and eGangotri

The fasciæ and muscles may be grouped into those of the head and of the trunk; of the upper extremity; and of the lower extremity.

THE FASCIA AND MUSCLES OF THE HEAD

I. The Muscle of the Scalp

Epicranius

The **superficial fascia** in the cranial region is a firm, fibrofatty, intimately adherent to the integument, and to the Epicranius and its tendinous aponeurosis; behind, it is continuous with the superficial fascia at the back of the neck; laterally, is prolonged over the temporal fascia.

Fig. 534.—The muscles of the scalp and face. Left lateral aspect.

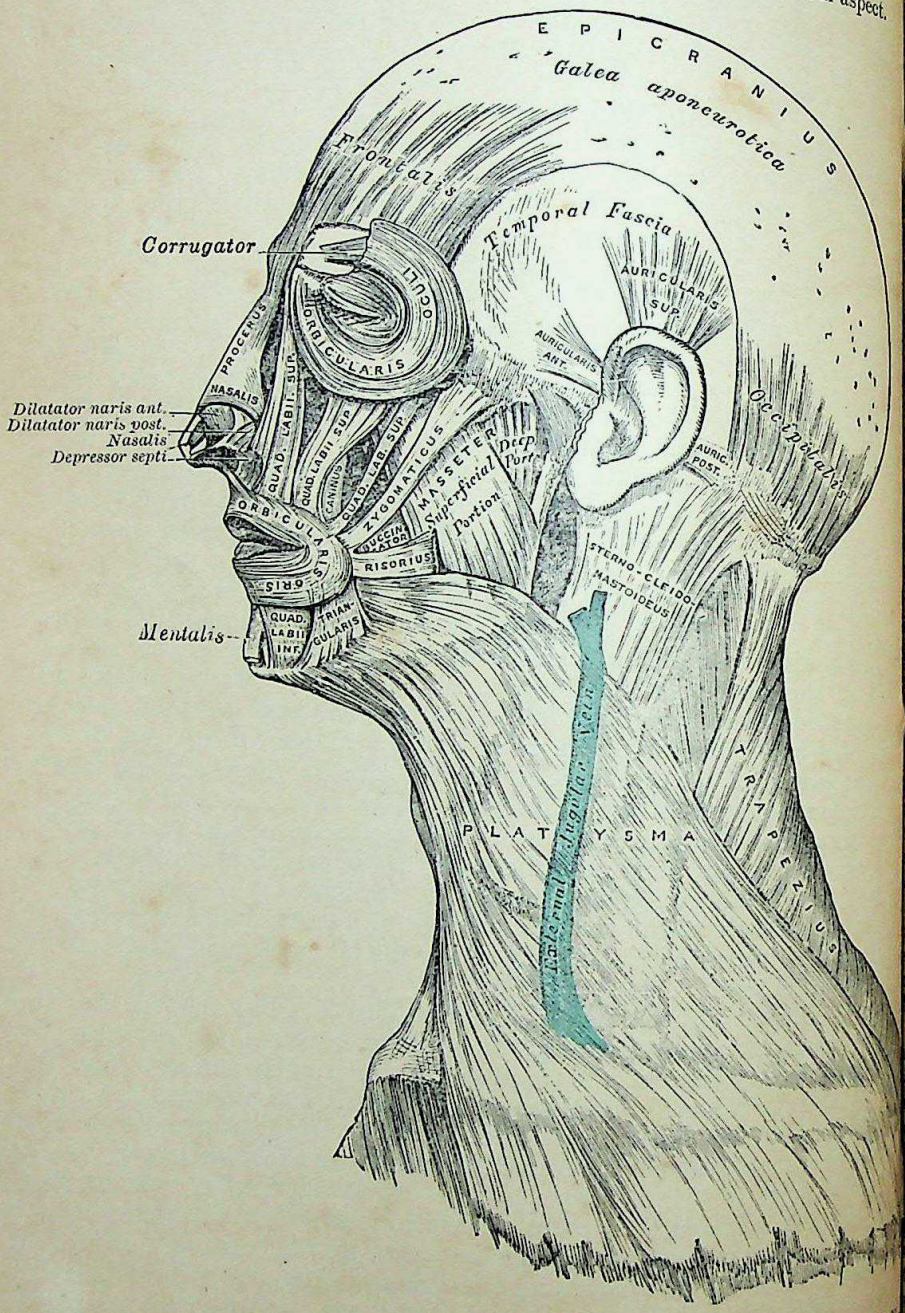

The **Epicranius** (Occipito-frontalis) (fig. 534) is a broad, musculofibrous layer, which covers the vertex of the skull on either side, from the occiput

CC-0. In Public Domain. Gurukul Kangri Collection, Haridwar

Digitized by Arya Samaj Foundation Chennai and eGangotri

to the eyebrow. It consists of two parts, the Occipitalis and the Frontalis, ected by an intervening aponeurosis, the galea aponeurotica.

The *Occipitalis*, thin and quadrilateral in form, arises by tendinous fibres the lateral two-thirds of the highest nuchal line of the occipital bone, and the mastoid part of the temporal bone. It ends in the galea aponeurotica.

The *Frontalis* is thin, of a quadrilateral form, and intimately adherent to the ficial fascia. It is broader than the Occipitalis and its fibres are longer and in colour. It has no bony attachments. Its medial fibres are continuous those of the Procerus; its intermediate fibres blend with the Corrugator Orbicularis oculi; and its lateral fibres are also blended with the latter o over the zygomatic process of the frontal bone. From these attachments bres are directed upwards, and join the galea aponeurotica in front of the al suture. The medial margins of the Frontales are joined together for distance above the root of the nose; but between the Occipitales there is considerable, though variable, interval, occupied by the galea aponeurotica.

The **galea aponeurotica** (epicranial aponeurosis) covers the upper part e cranium; behind, it is attached, in the interval between the Occipitales, e external occipital protuberance and highest nuchal line of the occipital ; in front, it forms a short and narrow prolongation between the Frontales. ther side it gives origin to the Auriculares anterior et superior; in this ion it loses its aponeurotic character, and is continued over the temporal to the zygomatic arch. It is closely united to the integument by the fibrofatty superficial fascia: it is connected to the pericranium by loose ar tissue, which allows of the movement of the aponeurosis, the latter ying with it the integument.

Nerve-supply.—The Occipitalis is supplied by the posterior auricular branch, and Frontalis by the temporal branches, of the facial nerve.

Actions.—The Occipitales draw the scalp backwards; the Frontales acting from e raise the eyebrows and the skin over the root of the nose; acting from below draw the scalp forwards, throwing the integument of the forehead into trans- wrinkles. By bringing alternately into action the Occipitales and Frontales ire scalp may be moved backwards and forwards. In the ordinary action e Frontales, the eyebrows are elevated, thus giving to the face the expression rprise: if the action be exaggerated, the eyebrows are still further raised, and kin of the forehead thrown into transverse wrinkles, as in the expression of t or horror.

A thin muscular slip, the *Transversus nuchæ*, is present in about 25 per cent. of s; it arises from the external occipital protuberance or from the superior nuchal either superficial or deep to the Trapezius; it is frequently inserted with the icularis posterior, but may join the posterior edge of the Sternocleidomastoideus.

plied Anatomy.—The scalp consists of five layers, viz. the skin, subcutaneous e, Epicranius and its aponeurosis, subaponeurotic connective tissue, and peri- um. But from a surgical standpoint it is better to regard the first three of these as ngle layer, since they are all intimately fused together, and when torn off in an ant, or turned down as a flap in a surgical operation, remain firmly connected to other. In consequence of the dense character of the subcutaneous tissue, the nt of swelling which occurs as the result of inflammation is slight; and the edges wound which does not involve the Epicranius or its aponeurosis do not gape. The d-vessels, also, which lie in this tissue, when wounded, do not contract and retract ly; and therefore the hæmorrhage from scalp wounds is often very considerable, but always be arrested by pressure—a matter of great importance, as it is often very lt or impossible to pick up with forceps a wounded vessel in the scalp.

The subaponeurotic connective tissue is, from a surgical point of view, of considerable portance. It is loose and lax, and is easily torn through; and hence, when the scalp wounded, this is the tissue which is torn when the flap is separated from the parts eath. The vessels are contained in the flap, and there is little risk of sloughing, ss the vitality of the part has been actually destroyed by the injury. In consequence e loose nature of the subaponeurotic tissue, any septic inflammation is apt to assume ry diffuse form and spread over the skull, and, unless relieved by timely incisions, lead to serious complications. Owing to the attachments of the aponeurosis to the matic arch and highest nuchal line, subaponeurotic effusions sag down in these ations, but do not extend beyond to the infratemporal fossa, or into the neck; ticularly, however, where there is no definite attachment to bone, the effusion will pass s over the nose, and into the eyelids. When making incisions into the scalp, care uld be taken to avoid the course of the temporal vessels.

CC-0. In Public Domain. Gurukul Kangri Collection, Haridwar

Digitized by Arya Samaj Foundation Chennai and eGangotri

II. The Muscles of the Eyelids

Levator palpebræ superioris. Orbicularis oculi.

The Levator palpebræ superioris is described with the anatomy of the orbit.

The **Orbicularis oculi** (figs. 534, 535) is a broad, flat, elliptical muscle which occupies the eyelids or palpebræ, surrounds the circumference of the orbit, spreads over the temporal region, and downwards on the cheek, and consists of three main portions, orbital, palpebral and lacrimal.

Fig. 535.—The left Orbicularis oculi. Posterior aspect.

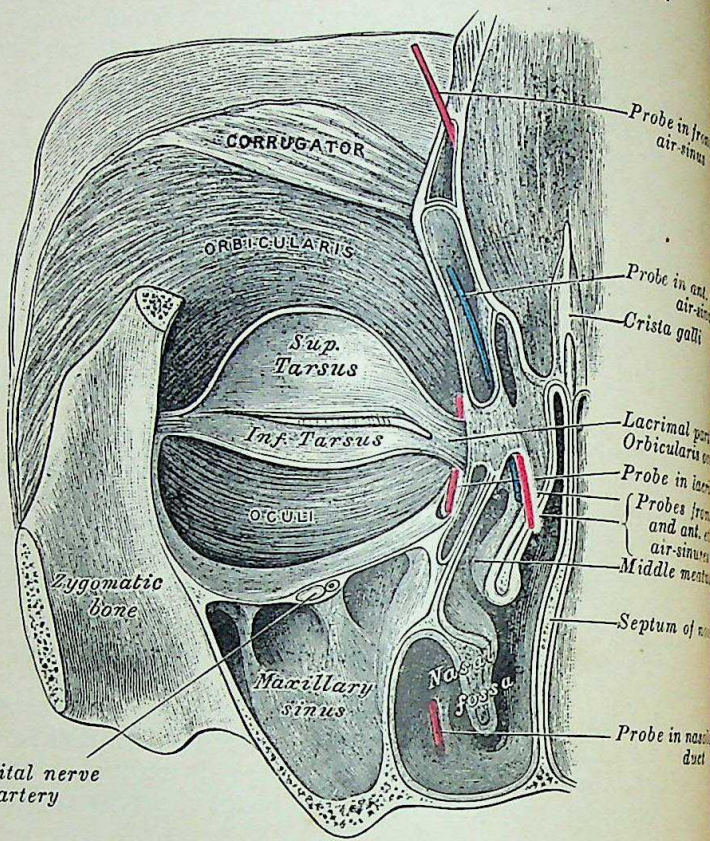

The *orbital portion* of the Orbicularis oculi, of a reddish colour and thicker than the palpebral portion, arises from the nasal part of the frontal bone, from the frontal process of the maxilla (fig. 536), and from the medial palpebral ligament (tendo oculi) which interrupts the line of the bony origin. Its fibres form complete ellipses without interruption on the lateral side, the upper part blending with the Frontalis and Corrugator.

The *palpebral portion* of the Orbicularis oculi is thin and pale; it arises from the medial palpebral ligament, chiefly from its superficial and partly from its deep surface, but not from its lower margin; it also arises from the bone immediately above and below the ligament. The muscular fibres sweep over the eyelids in front of the orbital septum, and at the lateral commissure they lace to form the lateral palpebral raphe. A small bundle of very fine fibres lies close to the margin of each eyelid, behind the eyelashes; it is called the *ciliary bundle* or muscle of Riolan.

The *lacrimal portion* of the Orbicularis oculi (Tensor tarsi) lies behind the lacrimal sac. It arises from the fascia covering the lacrimal sac, from the upper part of the posterior lacrimal crest, and the adjacent part of the bone surface of the lacrimal bone. Passing lateralwards behind the lacrimal sac the muscle divides into two slips, an upper and a lower; some of the fibres of these slips are inserted into the superior and inferior tarsi and are also related to the lacrimal ducts, but most of them are continued across the

CC-0. In Public Domain. Gurukul Kangri Collection, Haridwar

Digitized by Arya Samaj Foundation Chennai and eGangotri

front of the tarsal plates (*pars tarsalis*) and interlace in the lateral palpebral line.

The *medial palpebral ligament* (tendo oculi), about 4 mm. in length and 2 mm. in breadth, is attached to the frontal process of the maxilla in front of the lacrimal groove. Crossing the lacrimal sac, it divides into two parts, upper and lower, each attached to the medial end of the corresponding tarsus. As the ligament crosses the lacrimal sac, an aponeurotic lamina is given off from the posterior surface; this expands over the sac, and is attached to the posterior lacrimal crest.

The *lateral palpebral raphe* is a much weaker structure than the medial palpebral ligament. It is formed by the interlacing of the lateral ends of the palpebral fibres of the Orbicularis oculi, strengthened on its deep surface by the orbital septum. It passes over the orbital margin, and is attached to the bone by connective tissue only (Whitnall).

Nerve-supply.—The Orbicularis oculi is supplied by the temporal and zygomatic branches of the facial nerve.

Actions.—The Orbicularis oculi is the sphincter muscle of the eyelids. The palpebral portion acts involuntarily, closing the lids gently, as in sleep or in blinking; the orbital portion is subject to the will. When the entire muscle is brought into action, the skin of the forehead, temple, and cheek is drawn towards the medial angle of the orbit, and the eyelids are firmly closed. The skin thus drawn upon is drawn into folds, especially radiating from the lateral angle of the eyelids; these folds become permanent in old age, and form the so-called 'crow's feet.' The levator palpebræ superioris is the direct antagonist of this muscle since it raises the upper eyelid and exposes the front of the bulb of the eye. The lacrimal part of the Orbicularis oculi draws the eyelids and the papillæ lacrimales medialwards, and directs them into the lacus lacrimalis; it also dilates the lacrimal sac.

Fig. 536.—A sketch showing the attachments of the muscles around the base of the orbit.

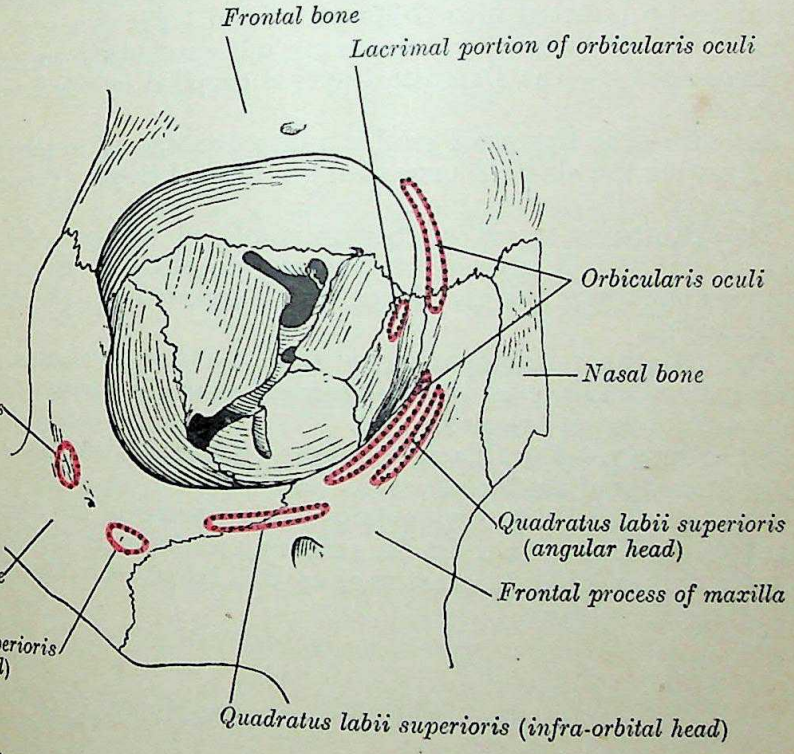

The **Corrugator** is a small pyramidal muscle, placed at the medial end of the eyebrow, beneath the Frontalis and Orbicularis oculi. It arises from the medial end of the superciliary arch; and its fibres pass lateralwards and slightly upwards, and are inserted into the deep surface of the skin, above the middle of the orbital arch.

Nerve-supply.—The Corrugator is supplied by the temporal branches of the facial nerve.

CC-0. In Public Domain. Gurukul Kangri Collection, Haridwar

Digitized by Arya Samaj Foundation Chennai and eGangotri

Actions.—The Corrugator draws the eyebrow medialwards and downwards, producing the vertical wrinkles of the forehead. It is the 'frowning' muscle, and may be regarded as the principal muscle in the expression of suffering.

III. The Muscles of the Nose (fig. 534)

Procerus.	Depressor septi.
Nasalis.	Dilatator naris posterior.

Dilatator naris anterior.

The **Procerus** (Pyramidalis nasi) is a small pyramidal slip arising by tendinous fibres from the fascia covering the lower part of the nasal bone and the upper part of the lateral nasal cartilage; it is inserted into the skin of the lower part of the forehead between the two eyebrows, its fibres decussating with those of the Frontalis.

Nerve-supply.—The Procerus is supplied by the buccal branches of the facial nerve.

Actions.—The Procerus draws down the medial angle of the eyebrow and produces the transverse wrinkles over the bridge of the nose.

The **Nasalis** (Compressor naris) consists of two parts, transverse and alar. The *transverse part* arises from the maxilla, above and lateral to the incisive fossa; its fibres proceed upwards and medialwards, expanding into an aponeurosis which is continuous on the bridge of the nose with that of the muscle of the opposite side, and with the aponeurosis of the Procerus. The *alar part* is attached by one end to the greater alar cartilage, and by the other to the integument at the apex of the nose.

Nerve-supply.—The Nasalis is supplied by the buccal branches of the facial nerve.

Actions.—The Nasalis depresses the cartilaginous part of the nose, and draws the ala towards the septum.

The **Depressor septi** arises from the incisive fossa of the maxilla; it ascends to be inserted into the septum and back part of the ala of the nose. It lies between the mucous membrane and muscular structure of the lip.

Nerve-supply.—The Depressor septi is supplied by the buccal branches of the facial nerve.

Actions.—The Depressor septi is a direct antagonist of the other muscles of the nose, drawing the ala of the nose downwards and thereby constricting the aperture of the naris.

The **Dilatator naris posterior** is placed partly beneath the Quadratus labii superioris. It arises from the margin of the nasal notch of the maxilla and from the lesser alar cartilages, and is inserted into the skin near the margin of the nostril.

The **Dilatator naris anterior** is a delicate fasciculus, passing from the greater alar cartilage to the integument near the margin of the nostril, and situated in front of the preceding.

Nerve-supply.—The Dilatatores naris, posterior et anterior, are supplied by the buccal branches of the facial nerve.

Actions.—The Dilatatores enlarge the apertures of the nares. Their action in ordinary breathing is to resist the tendency of the nares to close from atmospheric pressure, but in difficult breathing, as well as in some emotions, such as anger, they contract strongly.

IV. The Muscles of the Mouth (fig. 534)

Quadratus labii superioris.	Quadratus labii inferioris.
Caninus.	Triangularis.
Zygomaticus.	Buccinator.
Mentalis.	Orbicularis oris.

Risorius.

The **Quadratus labii superioris** is a broad sheet, the origin of which extends from the side of the nose to the zygomatic bone. Its medial

CC-0. In Public Domain. Gurukul Kangri Collection, Haridwar

Digitized by Arya Samaj Foundation Chennai and eGangotri

m the *angular head*, which arises by a pointed extremity from the upper e of the frontal process of the maxilla, and passing obliquely downwards lateralwards divides into two slips. One of these is inserted into the er alar cartilage and skin of the nose; the other is prolonged into the l part of the upper lip, blending with the infra-orbital head and with Orbicularis oris. The intermediate portion or *infra-orbital head* arises m the lower margin of the orbit immediately above the infra-orbital foramen, e of its fibres arising from the maxilla, others from the zygomatic bone. fibres converge, to be inserted into the muscular substance of the upper between the angular head and the Caninus. The lateral fibres form the matic *head*, and are separated from the rest of the muscle by a narrow rval; they arise from the malar surface of the zygomatic bone immediately nd the zygomaticomaxillary suture and pass downwards and medialwards e upper lip.

Nerve-supply.—The Quadratus labii superioris is supplied by the buccal branches e facial nerve.

Actions.—The Quadratus labii superioris raises the upper lip and at the same everts it. Its angular head also acts as a dilator of the naris; the infra-orbital zygomatic heads assist in forming the nasolabial furrow, which passes from le of the nose to the upper lip and gives to the face an expression of sadness. the whole muscle is in action it gives to the countenance the expression of mpt and disdain.

The Caninus (Levator anguli oris) arises from the canine fossa, immediately w the infra-orbital foramen; its fibres are inserted into the angle of mouth, intermingling with those of the Zygomaticus, Triangularis, and bularis oris.

Nerve-supply.—The Caninus is supplied by the buccal branches of the facial nerve.

Actions.—The Caninus raises the angle of the mouth and assists in producing the abial furrow.

The Zygomaticus arises from the zygomatic bone, in front of the zygo- ootemporal suture, and descending obliquely with a medial inclination, serted into the angle of the mouth, where it blends with the fibres of the inus, Orbicularis oris, and Triangularis.

Nerve-supply.—The Zygomaticus is supplied by the buccal branches of the facial e.

Actions.—The Zygomaticus draws the angle of the mouth upwards and lateral- ds as in laughing.

The Mentalis (Levator menti) is a conical fasciculus, situated at the side e frenulum of the lower lip. It arises from the incisive fossa of the mandible descends to be inserted into the integument of the chin.

Nerve-supply.—The Mentalis is supplied by the mandibular branch of the facial e.

Actions.—The Mentalis raises and protrudes the lower lip, and at the same time ldles the skin of the chin, expressing doubt or disdain.

The Quadratus labii inferioris is a quadrilateral muscle. It arises m the oblique line of the mandible, between the symphysis and the mental men, and passes upwards and medialwards, to be inserted into the integu- t of the lower lip, its fibres blending with the Orbicularis oris, and with e of its fellow of the opposite side. At its origin it is continuous with the s of the Platysma. Much yellow fat is intermingled with the fibres of muscle.

Nerve-supply.—The Quadratus labii inferioris is supplied by the mandibular ch of the facial nerve.

Actions.—The Quadratus labii inferioris draws the lower lip downwards and a lateralwards, as in the expression of irony.

The Triangularis (Depressor anguli oris) arises from the oblique line of the dible below and lateral to the Quadratus labii inferioris; its fibres converge are inserted by a narrow fasciculus into the angle of the mouth. At rigin it is continuous with the Platysma, and at its insertion with the icularis oris and Risorius; some of its fibres are directly continuous with e of the Caninus, and others are occasionally found crossing from the le of one side to that of the other; these latter fibres constitute the *nverserus menti*.

CC-0. In Public Domain. Gurukul Kangri Collection, Haridwar

Digitized by Arya Samaj Foundation Chennai and eGangotri

Nerve-supply.—The Triangularis is supplied by the mandibular branch of the facial nerve.

Actions.—The Triangularis draws the angle of the mouth downwards and lateralwards.

The **Buccinator** (fig. 537) is a thin quadrilateral muscle, occupying the interval between the maxilla and the mandible, at the side of the face.

FIG. 537.—The Buccinator and the muscles of the pharynx.

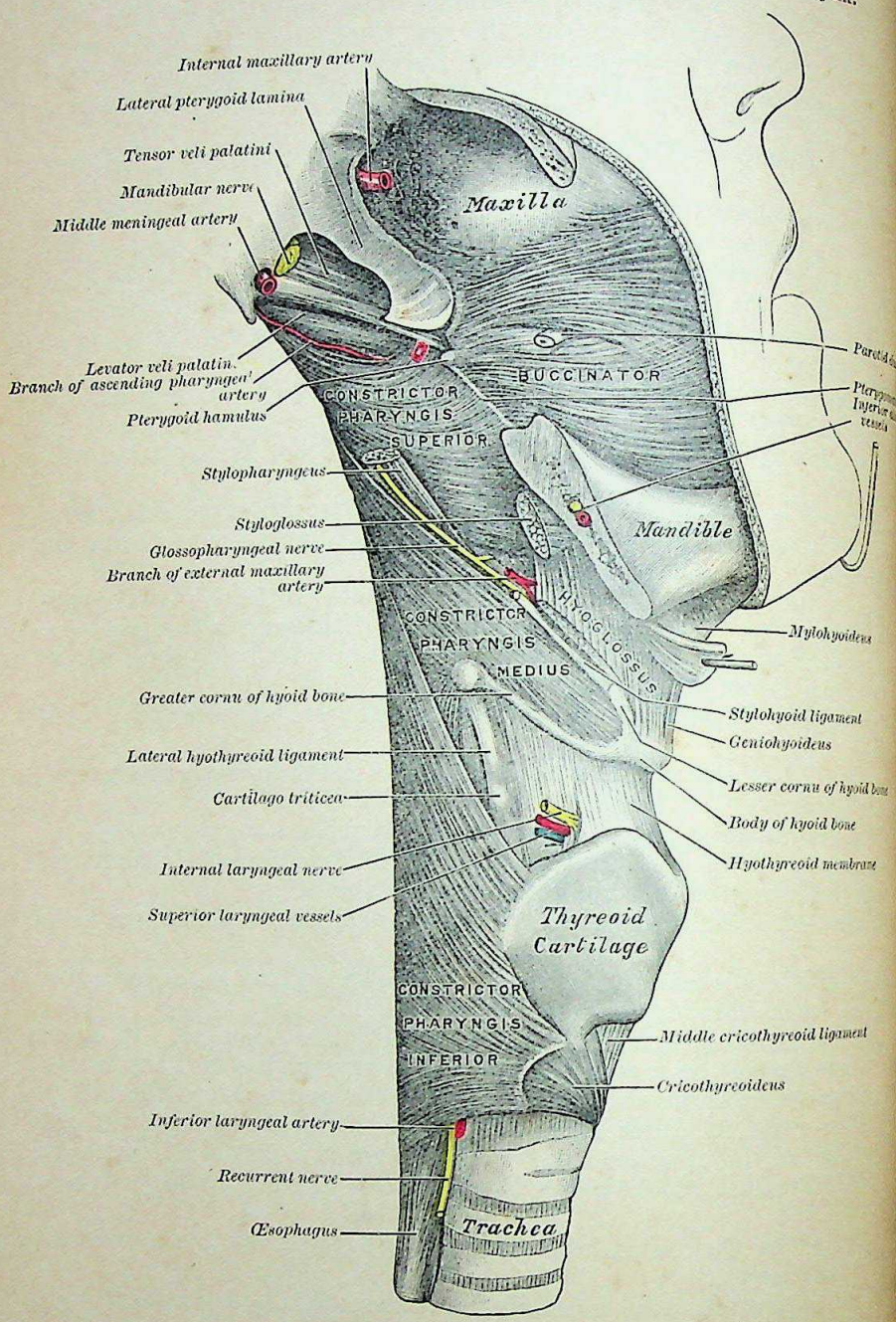

from the outer surfaces of the alveolar processes of the maxilla and mandible opposite to the three molar teeth; and behind, from the anterior border of the pterygomandibular raphe which separates the muscle from the Constrictor pharyngis superior. The fibres converge towards the angle of the mouth, where the central fibres intersect each other, those from below being continuous with the upper segment of the Orbicularis oris, and those from above with the lower segment; the highest and lowest fibres are continued forward to the corresponding lip without decussation.

CC-0. In Public Domain. Gurukul Kangri Collection, Haridwar

Digitized by Arya Samaj Foundation Chennai and eGangotri

Relations.—The Buccinator is covered by the buccopharyngeal fascia, and is in ...ction by its *superficial surface*, behind, with a large mass of fat, which separates it ...the ramus of the mandible, the Masseter, and a small portion of the Temporalis; ...t has been named the *suctorial pad*, because it is supposed to assist in the act ...ching. In front the superficial surface of the Buccinator is in relation with the ...maticus, Risorius, Caninus, Triangularis, and the parotid duct which pierces it ...sist the second molar tooth of the maxilla; the external maxillary artery and ...rior facial vein cross it from below upwards; it is also crossed by branches of the ...al and buccinator nerves. The *deep surface* is in relation with the buccal glands and ...ous membrane of the mouth.

Nerve-supply.—The Buccinator is supplied by the buccal branches of the facial ...ve.

Actions.—The Buccinator muscles compress the cheeks against the teeth, so ...during the process of mastication the food is kept under the immediate pressure ...the teeth. When the cheeks have been previously distended with air, the Bucci-...rs expel it between the lips, as in blowing a trumpet; hence the name (*buccina*, ...rumpet).

The *pterygomandibular raphe* is a tendinous band of the buccopharyngeal ..., attached by one extremity to the hamulus of the medial pterygoid lamina, ...y the other to the posterior end of the mylohyoid line of the mandible. ...ally it is covered by the mucous membrane of the mouth. *Laterally* it ...separated from the ramus of the mandible by a quantity of adipose tissue. ...eriorly it gives attachment to the Constrictor pharyngis superior, and ...riorly to a part of the Buccinator (fig. 537).

The **Orbicularis oris** (figs. 534, 538) is not a simple sphincter muscle ...the Orbicularis oculi; it consists of numerous strata of muscular fibres ...unding the orifice of the mouth but having different directions. It ...sists partly of fibres derived from the other facial muscles which are inserted ...the lips, and partly of fibres proper to the lips. Of the former, a con-...sible number are derived from the Buccinator, and form the deeper stratum ...the Orbicularis. Some of the Buccinator fibres—namely, those near the ...dle of the muscle—decussate at the angle of the mouth; the uppermost ...lowermost fibres pass across the lips from side to side without decussation. ...perficial to this is a second stratum, formed on either side by the Caninus ...Triangularis, which cross each other at the angle of the mouth; the fibres ...the Caninus pass to the lower lip, and those from the Triangularis to ...upper lip, along which they ... to be inserted into the skin ...the median line. In addition ...se there are fibres from the ...dratus labii superioris, the ...maticus, and the Quadratus ...inferioris; these intermingle ...the transverse fibres des-...ed above, and have principally ...oblique direction. The proper ...of the lips are oblique, and ...from the deep surface of the ...to the mucous membrane, ...gh the thickness of the lip. ...y there are fibres by which ...muscle is connected with the ...le and the septum of the ...above and with the mandible ... In the upper lip these ...of two bands, lateral and medial, on either side of the middle line; ...lateral band (*m. incisivus labii superioris*) arises from the alveolar border ...the maxilla, opposite the lateral incisor tooth, and arching lateralwards ...tinuous with the other muscles at the angle of the mouth; the medial ...(*m. nasolabialis*) connects the upper lip to the back of the septum ...the nose. The interval between the two medial bands corresponds with ...depression, called the *philtrum*, seen on the lip beneath the septum of the ... The additional fibres of the lower lip constitute a slip (*m. incisivus*

Fig. 538.—A scheme showing the arrangement of the fibres of the Orbicularis oris.

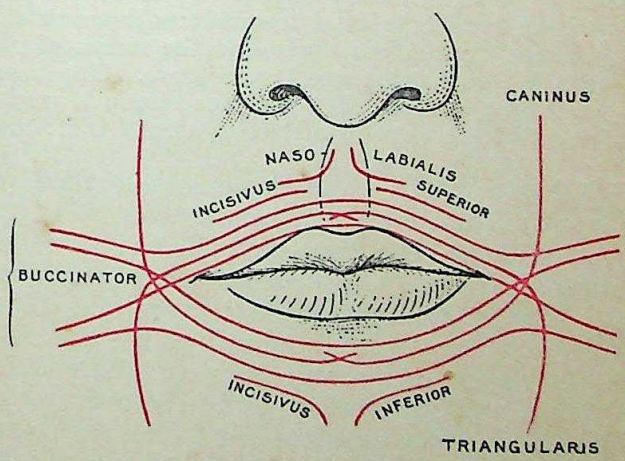

CC-0. In Public Domain. Gurukul Kangri Collection, Haridwar

Digitized by Arya Samaj Foundation Chennai and eGangotri

labii inferioris) on either side of the middle line; this slip arises from the mandible, lateral to the Mentalis, and intermingles with the other muscles at the angle of the mouth.

Nerve-supply.—The Orbicularis oris is supplied by the buccal and mandibular branches of the facial nerve.

Actions.—The Orbicularis oris in its ordinary action effects the direct closure of the lips; by its deep, assisted by its oblique, fibres, it compresses the lips against the teeth. The superficial part, consisting principally of the decussating fibres, brings the lips together and protrudes them.

The **Risorius** arises from the parotideomasseteric fascia and is inserted into the skin at the angle of the mouth (fig. 534). It is a narrow band of fibres, broadest at its origin, but varying much in its size and form.

Nerve-supply.—The Risorius is supplied by the buccal branches of the facial nerve.

Actions.—The Risorius retracts the angle of the mouth, and produces a pleasant grinning expression.

V. The Muscles of Mastication

Masseter.	Pterygoideus externus.
Temporalis.	Pterygoideus internus.

Covering the Masseter, and firmly connected with it, is a strong layer of fascia derived from the fascia colli and named the **parotideomasseteric fascia**. It is attached to the lower border of the zygomatic arch, and invests the parotid gland (p. 448).

The **Masseter** (fig. 534) is a quadrilateral muscle, consisting of two portions, superficial and deep. The *superficial portion*, the larger, arises by a strong aponeurosis from the zygomatic process of the maxilla, and from the anterior two-thirds of the lower border of the zygomatic arch; its fibres pass downwards and backwards, to be inserted into the angle and lower one-half of the lateral surface of the ramus of the mandible. The *deep portion* is much smaller and is partly concealed by the superficial portion; it arises from the posterior one-third of the lower border and from the whole of the medial surface of the zygomatic arch; its fibres pass downwards and forwards, to be inserted into the lateral surfaces of the coronoid process and the upper one-half of the ramus of the mandible.

Relations.—*Superficial* to the muscle are the integument, the Platysma, the Risorius, the Zygomaticus, and the parotid gland; the parotid duct, branches of the facial nerve, and the transverse facial vessels cross the muscle. The *deep surface* is in relation with the insertion of the Temporalis and the ramus of the mandible; a mass of fat separates it from the Buccinator muscle and nerve. The masseteric nerve and artery enter the muscle on its deep surface. The *posterior margin* is overlapped by the parotid gland; the *anterior margin* projects over the Buccinator and is crossed below by the anterior facial vein.

Nerve-supply.—The Masseter is supplied by the masseteric branch of the anterior trunk of the mandibular nerve.

Actions.—The Masseter pulls the mandible towards and against the maxilla; from its relation to the axis of movement it can act with very great force.

The **temporal fascia** covers the Temporalis. It is a strong, fibrous investment, covered, laterally, by the Auriculares anterior et superior, the galea aponeurotica, and a part of the Orbicularis oculi. The superficial temporal vessels and the auriculotemporal nerve cross it from below upwards. Above it is a single layer, attached to the entire extent of the superior temporal line; below, it consists of two layers, one of which is attached to the lateral, the other to the medial border of the zygomatic arch. A small quantity of fat, the zygomatico-orbital branch of the superficial temporal artery, and the zygomaticotemporal branch of the maxillary nerve, are contained between these two layers. The deep surface of the fascia affords attachment to the superficial fibres of the Temporalis.

The **Temporalis** (fig. 539) is a fan-shaped muscle, situated at the side of the head. It arises from the whole of the temporal fossa (except the part formed by the zygomatic bone) and from the deep surface of the temporal

CC-0. In Public Domain. Gurukul Kangri Collection, Haridwar

Digitized by Arya Samaj Foundation Chennai and eGangotri

The **Mylohyoideus**, flat and triangular, is situated immediately above the anterior belly of the Digastricus, and forms, with its fellow of the opposite side, a muscular floor for the cavity of the mouth. It arises from the whole length of the mylohyoid line of the mandible. The posterior fibres pass medialwards and slightly downwards, to be inserted into the front of the body of the hyoid bone near its lower border. The middle and anterior fibres are inserted into a median fibrous raphe extending from the mandibular symphysis to the hyoid bone, where they join at an angle with the fibres of the opposite muscle. The median raphe is sometimes wanting; the fibres of the two muscles are then continuous.

Relations.—Its *superficial or inferior surface* is in relation with the Platysma, the anterior belly of the Digastricus, the suprahyoid aponeurosis, the superficial part of the submaxillary gland, the external maxillary and submental vessels, and the mylohyoid vessels and nerve. Its *deep or superior surface* is in relation with the Geniohyoideus, part of the Hyoglossus, and the Styloglossus, the hypoglossal and lingual nerves, the submaxillary ganglion, the sublingual gland, the deep portion of the submaxillary gland and the submaxillary duct, the lingual and sublingual vessels, and the buccal mucous membrane.

Nerve-supply.—The Mylohyoideus is supplied by the mylohyoid branch of the inferior alveolar nerve.

Actions.—Acting from below the Mylohyoideus depresses the front of the mandible; acting from above it raises the hyoid bone and the floor of the mouth.

The **Geniohyoideus** is a narrow muscle, situated above the medial part of the Mylohyoideus. It arises from the inferior mental spine on the back of the symphysis menti, and runs backwards and slightly downwards, to be inserted into the anterior surface of the body of the hyoid bone; it is in contact with its fellow of the opposite side.

Nerve-supply.—The Geniohyoideus is supplied by the first cervical nerve through the hypoglossal nerve.

Actions.—When the Geniohyoideus acts from the hyoid bone, it depresses the chin of the mandible; when it acts from the mandible it raises and pulls forwards the hyoid bone.

The infrahyoid muscles are:

Sternohyoideus.	Thyreohyoideus.
Sternothyreoideus.	Omohyoideus.

The **Sternohyoideus**, a thin, narrow muscle, arises from the posterior surface of the medial end of the clavicle, the capsule of the sternoclavicular joint, and the upper and posterior part of the manubrium sterni. Passing upwards and medialwards, it is inserted into the lower border of the body of the hyoid bone. It sometimes presents, immediately above its origin, a transverse tendinous inscription. Below, the Sternohyoideus is separated from its fellow by a considerable interval; but the two muscles come into contact with one another in the middle of their course, and, from this upwards, are contiguous.

Nerve-supply.—The Sternohyoideus is supplied by branches from the loop (ansa hypoglossi) between the descendens hypoglossi and the communicantes cervicales.

Action.—The Sternohyoideus depresses the hyoid bone.

The **Sternothyreoideus** is shorter and wider than the Sternohyoideus, and lies under cover of it. It arises from the posterior surface of the manubrium sterni, below the origin of the Sternohyoideus, and from the edge of the cartilage of the first, and sometimes that of the second, rib; it is inserted into the oblique line on the lamina of the thyreoid cartilage. This muscle is close contact with its fellow at the lower part of the neck, but diverges somewhat as it ascends; it is occasionally traversed by a transverse or oblique tendinous inscription.

Nerve-supply.—The Sternothyreoideus is supplied by branches from the ansa hypoglossi.

Action.—The Sternothyreoideus draws the larynx down.

The **Thyreohyoideus**, a small, quadrilateral muscle, may be looked upon as an upward continuation of the Sternothyreoideus. It arises from the

CC-0. In Public Domain. Gurukul Kangri Collection, Haridwar

Digitized by Arya Samaj Foundation Chennai and eGangotri

oblique line on the lamina of the thyreoid cartilage, and is inserted lower border of the greater cornu of the hyoid bone.

Nerve-supply.—The Thyreohyoideus is supplied by a branch from the hy nerve.

Actions.—The Thyreohyoideus depresses the hyoid bone, or raises the l

The **Omohyoideus** consists of two fleshy bellies united by a central It arises from the upper border of the scapula, and occasionally f superior transverse ligament which crosses the scapular notch, its e attachment to the scapula varying from a few millimetres to 2·5 cm this origin, the *inferior belly* forms a flat, narrow fasciculus, which forwards and slightly upwards across the lower part of the neck, bein to the clavicle by a fibrous expansion; it then passes behind the Ster mastoideus, becomes tendinous and changes its direction, forming an angle. It ends in the *superior belly*, which passes almost vertically close to the lateral border of the Sternohyoideus, and is inserted into th border of the body of the hyoid bone, lateral to the insertion of the hyoideus. The central tendon of this muscle varies in length and for is held in position by a process of the fascia colli, which ensheathes is prolonged down to be attached to the clavicle and first rib; it is means that the angular form of the muscle is maintained.

Nerve-supply.—The superior belly of the Omohyoideus is supplied descendens hypoglossi; the inferior belly by a branch from the ansa hypo

Actions.—The Omohyoideus depresses the hyoid bone and carries it ba and lateralwards. The Omohyoidei are concerned also in prolonged ins efforts; by rendering tense the lower part of the fascia colli they lessen th suction of the soft parts, which would otherwise compress the great vessels apices of the lungs.

The inferior belly of the Omohyoideus divides the posterior triangle of th into an upper or *occipital* and a lower or *subclavian* triangle, while its superi divides the anterior triangle into an upper or *carotid* and a lower or triangle.

III. The Anterior Vertebral Muscles (fig. 544)

Longus colli.	Rectus capitis anterior.
Longus capitis.	Rectus capitis lateralis.

The **Longus colli** is situated on the anterior surface of the vertebral between the atlas and the third thoracic vertebra. It is divisible into portions, a superior oblique, an inferior oblique, and a vertical; its and insertion consist of tendinous slips. The *superior oblique portion* from the anterior tubercles of the transverse processes of the third, and fifth cervical vertebræ; it is directed upwards and medialwards is inserted by a narrow tendon into the tubercle on the anterior arch atlas. The *inferior oblique portion*, the smallest part of the muscle, from the front of the bodies of the first two or three thoracic vertebræ; upwards and lateralwards, and is inserted into the anterior tubercles transverse processes of the fifth and sixth cervical vertebræ. The *portion* arises from the front of the bodies of the upper three thorac lower three cervical vertebræ, and is inserted into the front of the bo the second, third, and fourth cervical vertebræ.

Nerve-supply.—The Longus colli is supplied by branches from the an divisions of the second, third and fourth cervical nerves.

Actions.—The Longus colli bends the cervical portion of the vertebral forwards and lateralwards, and slightly rotates it.

The **Longus capitis** (Rectus capitis anticus major), broad and thick narrow below, arises by tendinous slips, from the anterior tubercles transverse processes of the third, fourth, fifth, and sixth cervical vert and is inserted into the inferior surface of the basilar part of the occ bone.

Nerve-supply.—The Longus capitis is supplied by branches from the an divisions of the first, second and third cervical nerves.

Action.—The Longus capitis flexes the head.

CC-0. In Public Domain. Gurukul Kangri Collection, Haridwar

Digitized by Arya Samaj Foundation Chennai and eGangotri

The **Rectus capitis anterior** (Rectus capitis anticus major) is a short, muscle, situated behind the upper part of the Longus capitis. It arises the anterior surface of the lateral mass of the atlas, and from the root transverse process, and is inserted into the inferior surface of the basilar of the occipital bone in front of the occipital condyle.

Nerve-supply.—The Rectus capitis anterior is supplied by branches from the between the anterior divisions of the first and second cervical nerves.

Action.—The Rectus capitis anterior flexes the head.

FIG. 544.—The anterior and lateral vertebral muscles.

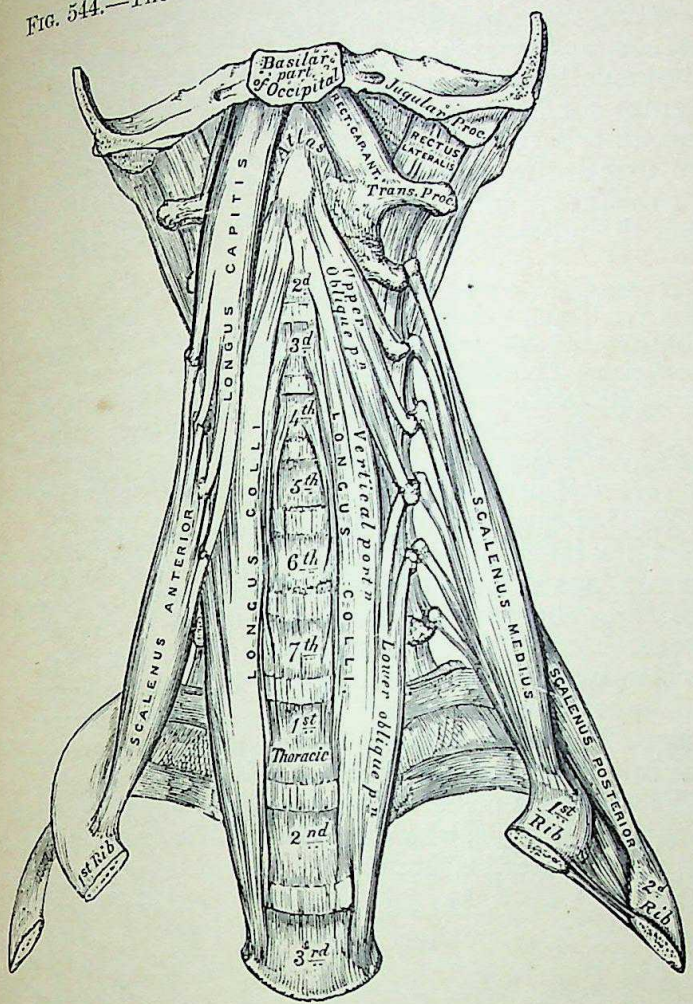

The **Rectus capitis lateralis**, a short, flat muscle, arises from the upper ce of the transverse process of the atlas, and is inserted into the under ce of the jugular process of the occipital bone.

Nerve-supply.—The Rectus capitis lateralis is supplied by branches from the between the anterior divisions of the first and second cervical nerves.

Action.—The Rectus capitis lateralis bends the head lateralwards.

IV. THE LATERAL VERTEBRAL MUSCLES (fig. 544)

Scalenus anterior. Scalenus medius.
Scalenus posterior.

The **Scalenus anterior** lies deeply at the side of the neck, behind the cleidomastoideus. It arises from the anterior tubercles of the transverse sses of the third, fourth, fifth, and sixth cervical vertebræ, and descending, ser vertically, is inserted by a narrow, flat tendon into the scalene tubercle

CC-0. In Public Domain. Gurukul Kangri Collection, Haridwar

Digitized by Arya Samaj Foundation Chennai and eGangotri

on the inner border of the first rib, and into the ridge on the upper of the rib in front of the subclavian groove.

Relations.—*In front* of it are the clavicle, the Subclavius, Sternocleidomastoid and Omohyoideus muscles, the transverse cervical, transverse scapular and cervical arteries, the subclavian vein, and the phrenic nerve. Its *posterior* relation with the nerves forming the brachial plexus, the subclavian artery, and which separate it from the Scalenus medius. Below, it is separated from colli by the vertebral artery, and above, from the Longus capitis by the cervical branch of the inferior thyreoid artery.

Nerve-supply.—The Scalenus anterior is supplied by branches from the divisions of the fourth, fifth and sixth cervical nerves.

Actions.—Acting from below the Scalenus anterior bends the cervical of the vertebral column forwards and lateralwards and rotates it towards the side. When the muscle acts from above it assists in elevating the thorax.

The **Scalenus medius**, the largest and longest of the three Scaleni from the posterior tubercles of the transverse processes of the lower six vertebræ, and descending along the side of the vertebral column, is by a broad attachment into the upper surface of the first rib, betw tubercle of the rib and the subclavian groove.

Relations.—Its *anterior surface* is in relation with the Sternocleidomastoid crossed by the clavicle and the Omohyoideus; the subclavian artery and the nerves separate it from the Scalenus anterior. *Lateral* to it are the Levator sca the Scalenus posterior. The long thoracic nerve is formed in the substance of the and emerges from it; the dorsal scapular nerve pierces it.

Nerve-supply.—The Scalenus medius is supplied by branches from the divisions of the cervical nerves.

Actions.—The Scalenus medius, acting from below, bends the cervical the vertebral column lateralwards; acting from above it helps to raise the

The **Scalenus posterior**, the smallest and most deeply seated of the Scaleni, arises from the posterior tubercles of the transverse processes lower two or three cervical vertebræ, and is inserted by a thin tend the outer surface of the second rib, behind the attachment of the S anterior. It is occasionally blended with the Scalenus medius.

Nerve-supply.—The Scalenus posterior is supplied by branches from the divisions of the lower three cervical nerves.

Actions.—The Scalenus posterior bends the lower end of the cervical par vertebral column lateralwards, when the second rib is fixed; if its upper atta be fixed it helps to elevate the thorax.

THE FASCIÆ AND MUSCLES OF THE TRUNK

The muscles of the trunk may be arranged in six groups:

I. Deep muscles of the back.
II. Suboccipital muscles.
III. Muscles of the thorax.
IV. Muscles of the abdomen.
V. Muscles of the pelvis.
VI. Muscles of the perinæum.

I. The Deep Muscles of the Back (fig. 546)

The deep or intrinsic muscles of the back consist of a complex group muscles extending from the pelvis to the skull. They are:

Splenius capitis.
Splenius cervicis.
Sacrospinalis.
Semispinalis.
Multifidus.
Rotatores.
Interspinales.
Intertransversarii.

CC-0. In Public Domain. Gurukul Kangri Collection, Haridwar

Digitized by Arya Samaj Foundation Chennai and eGangotri

The lumbodorsal fascia covers the deep muscles of the back of the trunk. ve, it passes in front of the Serratus posterior superior and is continuous the *nuchal fascia*, a similar investing layer on the back of the neck.

In the thoracic region the lumbodorsal fascia is a thin fibrous lamina covering tensor muscles of the vertebral column and separating them from the les connecting the vertebral column to the upper extremity. It contains longitudinal and transverse fibres, and is attached, *medially*, to the spinous esses of the thoracic vertebræ; *laterally*, to the angles of the ribs.

In the lumbar region the lumbodorsal fascia (lumbar aponeurosis) is in two rs, anterior and posterior (fig. 545). The posterior layer is attached to the ous processes of the lumbar and sacral vertebræ and to the supraspinal ment; the anterior is attached, *medially*, to the tips of the transverse esses of the lumbar vertebræ, and to the intertransverse ligaments, *below*, the iliolumbar ligament, and *above*, to the lumbocostal ligament (p. 369). e two layers unite at the lateral margin of the Sacrospinalis, to form the on of origin of the Transversus abdominis.

Fig. 545.—A transverse section through the posterior abdominal wall, to show the disposition of the lumbodorsal fascia. Diagrammatic.

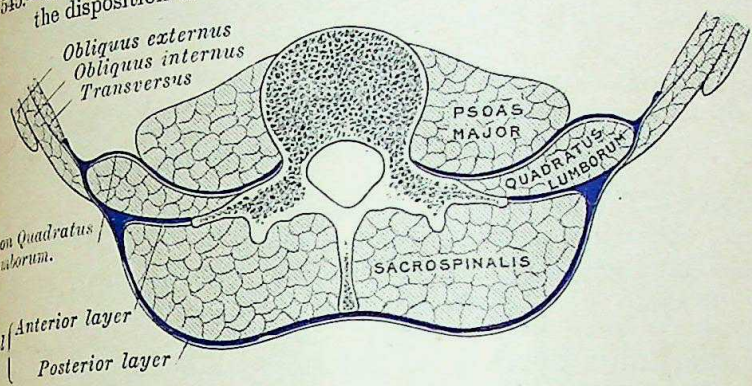

The Splenius capitis (fig. 568) arises from the lower half of the ligamentum e, from the spinous process of the seventh cervical vertebra, and from spinous processes of the upper three or four thoracic vertebræ. The fibres the muscle are directed upwards and lateralwards and are inserted, under er of the Sternocleidomastoideus, into the mastoid process of the temporal e, and into the rough surface on the occipital bone just below the lateral d of the superior nuchal line.

Nerve-supply.—The Splenius capitis is supplied by lateral branches of the rior divisions of the middle cervical nerves.

Actions.—The Splenius capitis acts in conjunction with the Splenius cervicis.

The Splenius cervicis (fig. 568) arises from the spinous processes of the d to the sixth thoracic vertebræ; it is inserted into the posterior tubercles the transverse processes of the upper two or three cervical vertebræ.

Nerve-supply.—The Splenius cervicis is supplied by lateral branches of the erior divisions of the lower cervical nerves.

Actions.—The Splenii of the two sides, acting together, draw the head directly kwards; acting separately, they draw the head to one side, and slightly rotate turning the face to the same side.

The Sacrospinalis (Erector spinæ) (fig. 546), and its prolongations in the acic and cervical regions, lie in the groove on the side of the vertebral mn. They are covered in the lumbar and thoracic regions by the lumbo-al fascia, and in the cervical region by the nuchal fascia. They form large muscular and tendinous mass which varies in size and structure at ent parts of the vertebral column. In the sacral region it is narrow pointed, and at its origin chiefly tendinous in structure. In the lumbar n it is larger, and forms a thick fleshy mass which, on being followed ards, is subdivided into three columns; these gradually diminish in size they ascend to be inserted into the vertebræ and ribs.

The Sacrospinalis arises from the anterior surface of a broad and thick ion, which is attached to the middle sacral crest, to the spinous processes

CC-0. In Public Domain. Gurukul Kangri Collection, Haridwar

Digitized by Arya Samaj Foundation Chennai and eGangotri

of the lumbar and the eleventh and twelfth thoracic vertebræ, to the spinal ligament, to the posterior part of the inner lip of the iliac crest, to the lateral crest of the sacrum, where it blends with the sacrotuberous and posterior sacro-iliac ligaments; some of its fibres are continuous with fibres of origin of the Glutæus maximus. The muscular fibres form a fleshy mass which splits in the upper lumbar region into three columns, lateral, the *Iliocostalis*, an intermediate, the *Longissimus*, and a medial, *Spinalis*. Each of these consists, from below upwards, of three parts, as follows:

Lateral Column.	*Intermediate Column.*	*Medial Column.*
Iliocostalis.	Longissimus.	Spinalis.
(*a*) I. lumborum.	(*a*) L. dorsi.	(*a*) S. dorsi.
(*b*) I. dorsi.	(*b*) L. cervicis.	(*b*) S. cervicis.
(*c*) I. cervicis.	(*c*) L. capitis.	(*c*) S. capitis.

The **Iliocostalis lumborum** is inserted, by flattened tendons, into the inferior borders of the angles of the lower six or seven ribs.

The **Iliocostalis dorsi** (Musculus accessorius) arises from the upper borders of the angles of the lower six ribs medial to the tendons of insertion of the Iliocostalis lumborum; it is inserted into the upper borders of the angles of the upper six ribs and into the back of the transverse process of the seventh cervical vertebra.

The **Iliocostalis cervicis** (Cervicalis ascendens) arises from the angles of the third, fourth, fifth, and sixth ribs, and is inserted into the posterior tubercles of the transverse processes of the fourth, fifth, and sixth cervical vertebræ.

Nerve-supply.—The Iliocostales are supplied by the posterior divisions of the lower cervical, thoracic, and upper lumbar nerves.

Actions.—The Iliocostales are extensors of the vertebral column; they bend it to one side. The slips attached to the ribs act as depressors of the thorax.

The **Longissimus dorsi** is the intermediate and largest of the continuations of the Sacrospinalis. In the lumbar region, where it is as yet blended with the Iliocostalis lumborum, some of its fibres are attached to the whole length of the posterior surfaces of the transverse processes and the accessory processes of the lumbar vertebræ, and to the anterior layer of the lumbar fascia. In the thoracic region it is inserted, by rounded tendons, into the tips of the transverse processes of all the thoracic vertebræ, and by fleshy processes into the lower nine or ten ribs between their tubercles and angles.

The **Longissimus cervicis** (Transversalis cervicis), situated medial to the Longissimus dorsi, arises by long thin tendons from the summits of the transverse processes of the upper four or five thoracic vertebræ, and is inserted by similar tendons into the posterior tubercles of the transverse processes of the cervical vertebræ from the second to the sixth inclusive.

The **Longissimus capitis** (Trachelomastoideus) lies between the Longissimus cervicis and the Semispinalis capitis. It arises by tendons from the transverse processes of the upper four or five thoracic vertebræ, and the articular processes of the lower three or four cervical vertebræ, and is inserted into the posterior margin of the mastoid process, beneath the Splenius capitis and Sternocleidomastoideus. It is usually crossed by a tendinous inscription near its insertion.

Nerve-supply.—The Longissimi are supplied by the posterior divisions of the lower cervical, thoracic, and lumbar nerves.

Actions.—The Longissimi dorsi et cervicis bend the vertebral column backwards and lateralwards; the Longissimus capitis extends the head, and turns the face towards the same side.

The **Spinalis dorsi**, the medial continuation of the Sacrospinalis, is scarcely separable as a distinct muscle. It is situated at the medial side of the Longissimus dorsi, and is intimately blended with it; it arises by three or four tendons from the spinous processes of the eleventh and twelfth thoracic, and first and second lumbar, vertebræ: these, uniting, form a small muscle which is inserted by separate tendons into the spinous processes of the upper thoracic vertebræ, the number varying from four to eight. It is intimately united with the Semispinalis dorsi situated beneath it.

CC-0. In Public Domain. Gurukul Kangri Collection, Haridwar

Digitized by Arya Samaj Foundation Chennai and eGangotri

FIG. 546.—The deep muscles of the back.

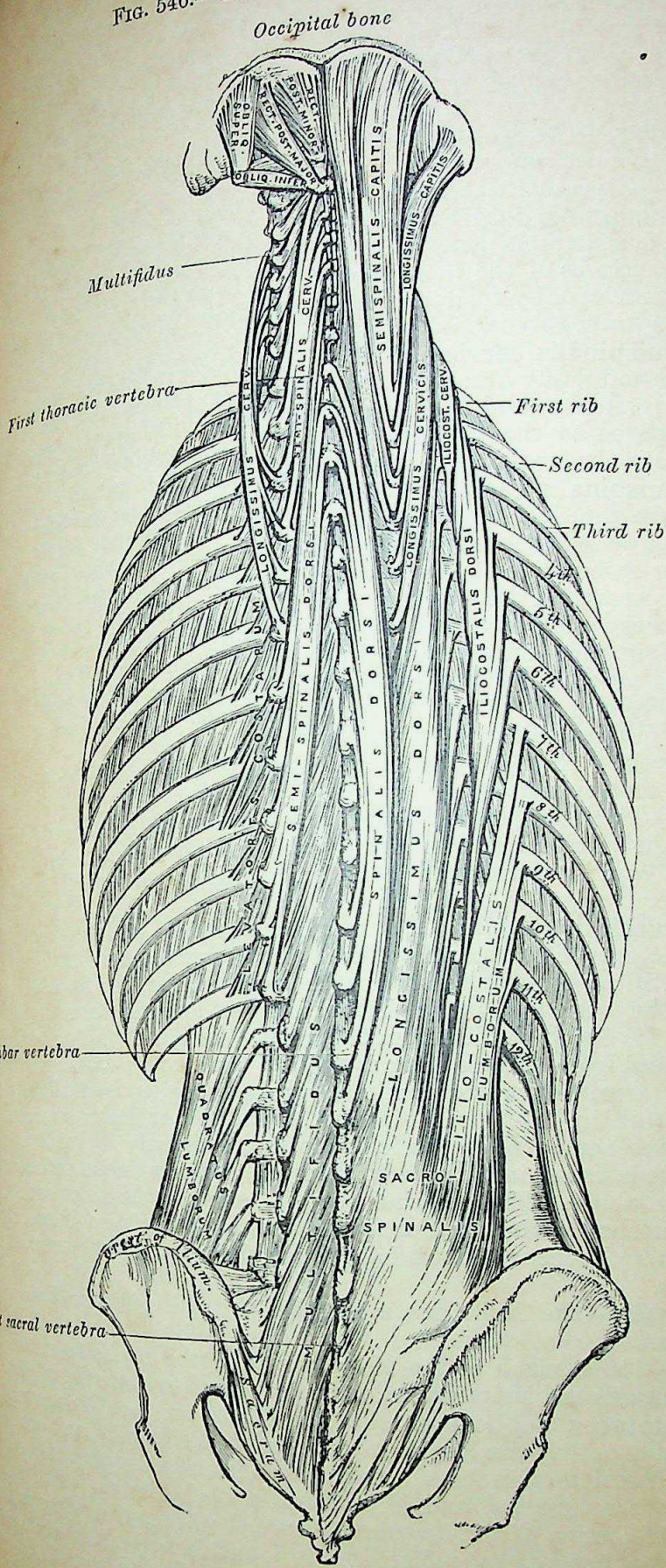

CC-0. In Public Domain. Gurukul Kangri Collection, Haridwar

Digitized by Arya Samaj Foundation Chennai and eGangotri

The **Spinalis cervicis** is an inconstant muscle, which arises from the part of the ligamentum nuchæ, the spinous process of the seventh cervical sometimes from the spinous processes of the first and second thoracic vertebræ and is inserted into the spinous process of the epistropheus, and occasionally into the spinous processes of the two vertebræ below it.

The **Spinalis capitis** is usually inseparably connected with the spinalis capitis.

Nerve-supply.—The Spinales are supplied by the posterior divisions of the cervical and thoracic nerves.

Actions.—The Spinales extend the vertebral column.

The **Semispinalis dorsi** consists of thin, fleshy fasciculi, interposed between tendons of considerable length. It arises by a series of tendons from the transverse processes of the thoracic vertebræ from the sixth to the tenth inclusive, and is inserted, by tendons, into the spinous processes of the upper thoracic and lower two cervical vertebræ.

The **Semispinalis cervicis**, thicker than the preceding, arises by a series of tendinous and fleshy fibres from the transverse processes of the upper five or six thoracic vertebræ, and is inserted into the cervical spinous processes from the epistropheus to the fifth inclusive. The fasciculus connected with the epistropheus is the largest, and is chiefly muscular in structure.

The **Semispinalis capitis** (Complexus) is situated at the back part of the neck, beneath the Splenius, and medial to the Longissimi cervicis et capitis. It arises by a series of tendons from the tips of the transverse processes of the upper six or seven thoracic and the seventh cervical vertebræ, and from the articular processes of the fourth, fifth, and sixth cervical vertebræ. These tendons are succeeded by a broad muscle which passes upwards and is inserted between the superior and inferior nuchal lines of the occipital bone. The medial part, usually more or less distinct from the remainder of the muscle, is termed the *Spinalis capitis*; it is also named the *Biventer cervicis* since it is traversed by an imperfect tendinous inscription.

Nerve-supply.—The Semispinales are supplied by the posterior divisions of the cervical and thoracic nerves.

Actions.—The Semispinalis dorsi et cervicis extend the thoracic and cervical portions of the vertebral column, and rotate them towards the opposite side. Semispinalis capitis extends the head, and turns the face slightly towards the opposite side.

The **Multifidus** consists of a number of fleshy and tendinous fasciculi which fill the groove on the side of the spinous processes of the vertebræ, from the sacrum to the epistropheus. In the sacral region, the fasciculi arise from the back of the sacrum, as low as the fourth sacral foramen, from the aponeurosis of origin of the Sacrospinalis, from the medial surface of the posterior superior iliac spine, and from the posterior sacro-iliac ligaments; in the lumbar region from all the mamillary processes; in the thoracic region, from all the transverse processes; and in the cervical region, from the articular processes of the lower four vertebræ. Each fasciculus passes obliquely upwards and medialwards and is inserted into the whole length of the spinous process of one of the vertebræ above. The fasciculi vary in length: the most superficial reach from one vertebra to the third or fourth above; those next in order run from one vertebra to the second or third above; while the deepest connect contiguous vertebræ.

Nerve-supply.—The Multifidus is supplied by the posterior divisions of the spinal nerves.

Actions.—The fasciculi of the Multifidus bend the segments of the vertebral column backwards and lateralwards, and rotate them towards the opposite side.

The **Rotatores** lie beneath the Multifidus and are found only in the thoracic region; they are eleven in number on either side, and are small and somewhat quadrilateral in form. Each arises from the upper and posterior part of the transverse process, and is inserted into the lower border and lateral surface of the lamina of the vertebra above, the fibres extending as far as the root of the spinous process. The first is found between the first and second thoracic vertebræ; the last, between the eleventh and twelfth. Sometimes the number of these muscles is diminished by the absence of one or more from the upper or lower end of the series.

CC-0. In Public Domain. Gurukul Kangri Collection, Haridwar

Digitized by Arya Samaj Foundation Chennai and eGangotri

Nerve-supply.—The Rotatores are supplied by the posterior divisions of the spinal nerves.

Actions.—The Rotatores mainly rotate the individual vertebræ towards the opposite side.

The **Interspinales** are short muscular fasciculi, placed in pairs between the spinous processes of the contiguous vertebræ, one on either side of the interspinal ligament. In the *cervical region* they are most distinct, and consist of six pairs, the first being situated between the epistropheus and third vertebra, and the last between the seventh cervical and the first thoracic. They are small narrow bundles, attached, above and below, to the apices of the spinous processes. In the *thoracic region* they are found between the first and second vertebræ, and sometimes between the second and third, and the eleventh and twelfth. In the *lumbar region* there are four pairs in the intervals between the five lumbar vertebræ. A pair is occasionally found between the last thoracic and first lumbar, and another between the fifth lumbar and the sacrum.

Nerve-supply.—The Interspinales are supplied by the posterior divisions of the spinal nerves.

Actions.—The Interspinales extend those segments of the vertebral column to which they are attached.

The **Extensor coccygis** is a slender muscular fasciculus, which is not always present; it extends over the lower part of the posterior surface of the sacrum and coccyx. It arises by tendinous fibres from the last segment of the sacrum, or first piece of the coccyx, and passes downwards to be inserted into the lower part of the coccyx. It is a rudiment of the Levator caudæ muscle of the lower animals.

The **Intertransversarii** are small muscles placed between the transverse processes of the vertebræ. In the *cervical region* they are best developed and consist of paired fasciculi which pass between the anterior and the posterior tubercles respectively of the transverse processes of two contiguous vertebræ; the muscles of each pair are separated by the anterior division of the cervical nerve, which lies in the groove between them. The muscles connecting the anterior tubercles are termed the *Intertransversarii anteriores*; those between the posterior tubercles the *Intertransversarii posteriores*. There are seven pairs of these muscles, the first pair being between the atlas and epistropheus, and the last between the seventh cervical and first thoracic vertebræ. In the *thoracic region* they are present between the transverse processes of the lower three thoracic, and between the transverse processes of the last thoracic and the first lumbar vertebræ. In the *lumbar region* they are arranged in pairs, on either side of the vertebral column; one set, occupying the entire interspace between the transverse processes of the lumbar vertebræ, the *Intertransversarii laterales*; the other set, *Intertransversarii mediales*, passing from the accessory process of one vertebra to the mamillary of the vertebra below.

Nerve-supply.—The Intertransversarii mediales are supplied by posterior divisions of the spinal nerves; all the others are supplied by anterior divisions.

Actions.—The Intertransversarii act as lateral flexors of those segments of the vertebral column to which they are attached.

II. The Suboccipital Muscles (fig. 546)

Rectus capitis posterior major.	Obliquus capitis inferior.
Rectus capitis posterior minor.	Obliquus capitis superior.

The **Rectus capitis posterior major** arises by a pointed tendon from the spinous process of the epistropheus and, becoming broader as it ascends, is inserted into the lateral part of the inferior nuchal line of the occipital bone, and also into the bone immediately below the line. As the muscles of the two sides pass upwards and lateralwards, they leave between them a triangular space, in which the Recti capitis posteriores minores are seen.

Nerve-supply.—The Rectus capitis posterior major is supplied by the posterior division of the suboccipital nerve.

Actions.—The Rectus capitis posterior major extends the head, and turns the face towards the same side.

CC-0. In Public Domain. Gurukul Kangri Collection, Haridwar

Digitized by Arya Samaj Foundation Chennai and eGangotri

The **Rectus capitis posterior minor** arises by a narrow pointed from the tubercle on the posterior arch of the atlas, and, widening ascends, is inserted into the medial part of the inferior nuchal line occipital bone and also into the bone between that line and the magnum.

Nerve-supply.—The Rectus capitis posterior minor is supplied by the division of the suboccipital nerve.

Action.—The Rectus capitis posterior minor extends the head.

The **Obliquus capitis inferior**, the larger of the two Oblique arises from the apex of the spinous process of the epistropheus, and lateralwards and slightly upwards, to be inserted into the lower and of the transverse process of the atlas.

Nerve-supply.—The Obliquus capitis inferior is supplied by the posterior of the suboccipital nerve.

Action.—The Obliquus capitis inferior turns the face towards the same

The **Obliquus capitis superior**, narrow below, wide and expanded arises by tendinous fibres from the upper surface of the transverse the atlas, joining with the insertion of the Obliquus capitis inferior. upwards and medialwards, and is inserted into the occipital bone, superior and inferior nuchal lines, lateral to the Semispinalis capitis.

Nerve-supply.—The Obliquus capitis superior is supplied by the posterior of the suboccipital nerve.

Actions.—The Obliquus capitis superior bends the head backwards and wards.

The suboccipital triangle.—This triangle is bounded, above and medial the Rectus capitis posterior major; above and laterally, by the Obliquus superior; below and laterally, by the Obliquus capitis inferior. It is covered a layer of dense fibrofatty tissue, situated beneath the Semispinalis capitis. floor is formed by the posterior occipito-atlantal membrane, and the posterior of the atlas. In the groove on the upper surface of the posterior arch of the are the vertebral artery and the first cervical nerve.

III. The Muscles of the Thorax

Intercostales externi.	Levatores costarum.
Intercostales interni.	Serratus posterior superior.
Subcostales.	Serratus posterior inferior.
Transversus thoracis.	Diaphragm.

The **Intercostales** (fig. 570) are two thin plates of muscular and tendinous fibres occupying each of the intercostal spaces. They are named *external* and *internal* from their surface relations—the external being superficial the internal.

The **Intercostales externi** are eleven in number on either side. attachments extend from the tubercles of the ribs behind, to near the cartilages of the ribs in front, where each is replaced by a layer of fascia named the *intercostal membrane*, which is continued forwards to the sternum. Each arises from the lower border of one rib, and is inserted into the upper of the rib below. In the lower two spaces they extend to the ends of the cartilages, and in the upper two or three spaces they do not quite reach the of the ribs. They are thicker than the Intercostales interni, and their are directed obliquely downwards and lateralwards on the back of the and downwards, forwards, and medialwards on the front.

The **Intercostales interni** are also eleven in number on either side. attachments commence anteriorly at the sternum, in the interspaces the cartilages of the true ribs, and at the anterior extremities of the of the false ribs, and extend backwards as far as the angles of the ribs, each is replaced by a layer of fascia named the *posterior intercostal* which is continuous with the anterior costotransverse ligament. Each arises from the ridge on the inner surface of one rib, as well as from corresponding costal cartilage, and is inserted into the upper border of

CC-0. In Public Domain. Gurukul Kangri Collection, Haridwar

Digitized by Arya Samaj Foundation Chennai and eGangotri

Their fibres are also directed obliquely, but at right angles to those of
Intercostales externi.*

Nerve-supply.—The Intercostales externi et interni are supplied by the inter-
nerves.

Actions.—The Intercostales externi et interni have probably little action in
the ribs. They contract simultaneously and form strong elastic supports
prevent the intercostal spaces being drawn in or bulged out during respir-
The anterior portions of the Intercostales interni probably have an
additional function in keeping the sternocostal and interchondral joint-surfaces in
position, the posterior portions of the Intercostales externi performing a similar
function for the costovertebral joints.

The **Subcostales** consist of muscular and aponeurotic fasciculi, and are
only well developed in the lower part of the thorax; each arises from
inner surface of one rib near its angle, and is inserted into the inner
surface of the second or third rib
below. Their fibres run in the same
direction as those of the Intercos-
tales interni.

Nerve-supply.—The Subcostales
are supplied by intercostal nerves.

Actions.—The Subcostales depress
the ribs.

The **Transversus thoracis**
(Triangularis sterni) is a thin plane
of muscular and tendinous fibres,
situated upon the inner surface of
the front wall of the chest (fig. 547).
It arises on either side from the
lower third of the posterior surface
of the body of the sternum, from
the posterior surface of the xiphoid
process, and from the posterior
surfaces of the costal cartilages of
the lower three or four true ribs
near their sternal ends. Its fibres
converge upwards and lateralwards,
to be inserted by slips into the
lower borders and inner surfaces of
the costal cartilages of the second,
third, fourth, fifth, and sixth ribs.
The lowest fibres of this muscle are
horizontal, and are continuous with
those of the Transversus abdominis;
the intermediate fibres are oblique,
while the highest are almost vertical.
This muscle varies in its attach-
ments not only in different subjects,
but on opposite sides of the same
subject.

Fig. 547.—The left Transversus thoracis. Posterior aspect.

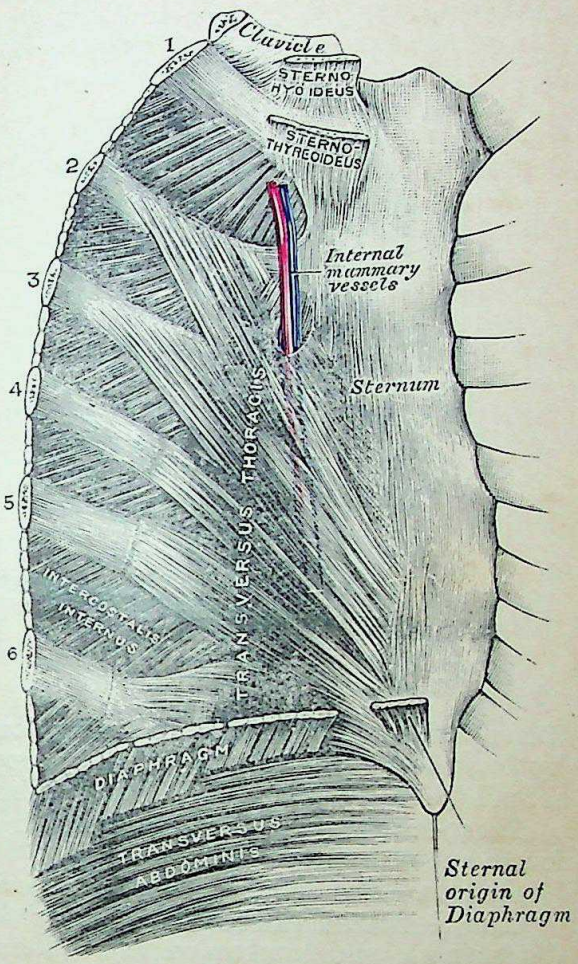

Nerve-supply.—The Transversus thoracis is supplied by intercostal nerves.

Actions.—The Transversus thoracis draws down the costal cartilages to which it is attached.

The **Levatores costarum** (fig. 546), twelve in number on either side, are
long bundles, which arise from the ends of the transverse processes of the
seventh cervical and upper eleven thoracic vertebræ; they pass obliquely down-
wards and lateralwards, parallel with the posterior borders of the Intercostales
externi, and each is inserted into the upper edge and outer surface of the rib
immediately below the vertebra from which it takes origin, between the

* T. Walmsley (*Journal of Anatomy*, vol. l.) describes each Internal intercostal muscle as consisting of (*a*) a superficial part, confined to the anterior two-thirds of the intercostal space, and properly named the Intercostalis internus, and (*b*) a deep or *intracostal* part, present in the middle two-fourths of each space, and in the same plane as the Transversus thoracis and the Subcostalis.

CC-0. In Public Domain. Gurukul Kangri Collection, Haridwar

Digitized by Arya Samaj Foundation Chennai and eGangotri

tubercle and the angle (Levatores costarum breves). Each of the four muscles divides into two fasciculi, one of which is inserted as above described, the other passes down to the second rib below its origin (Levatores costarum longi).

Nerve-supply.—The Levatores costarum are supplied by the intercostal nerves.

Actions.—The Levatores costarum being inserted near the fulcra of the ribs, have little or no elevating action on the ribs; they act as rotators and lateral flexors of the vertebral column.

The **Serratus posterior superior** is a thin, quadrilateral muscle, situated at the upper and posterior part of the thorax. It arises by a thin aponeurosis from the lower part of the ligamentum nuchæ, from the spinous processes of the seventh cervical and upper two or three thoracic vertebræ and

Fig. 548.—The posterior one-half of the Diaphragm. Anterior aspect. (Modified from a model by His.)

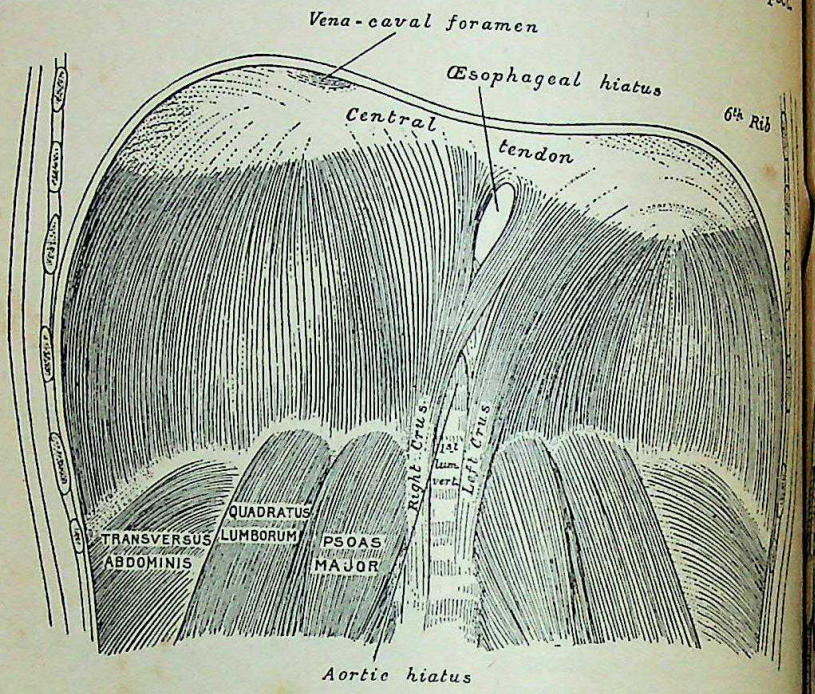

the supraspinal ligament. Inclining downwards and lateralwards it is inserted by four fleshy digitations, into the upper borders and outer surfaces of the second, third, fourth, and fifth ribs, a little beyond their angles.

Nerve-supply.—The Serratus posterior superior is supplied by the second, third, fourth and fifth intercostal nerves.

Actions.—The Serratus posterior superior elevates the ribs.

The **Serratus posterior inferior** (fig. 568) is situated at the junction of the thoracic and lumbar regions: it is of an irregularly quadrilateral form, broader than the preceding, and separated from it by a wide interval. It arises by a thin aponeurosis from the spinous processes of the lower two thoracic and upper two or three lumbar vertebræ, and from the supraspinal ligament; this aponeurosis is intimately blended with the lumbodorsal fascia. Passing obliquely upwards and lateralwards, it becomes fleshy, and is inserted by four digitations into the inferior borders and outer surfaces of the lower four ribs, a little beyond their angles.

Nerve-supply.—The Serratus posterior inferior is supplied by the ninth, tenth, eleventh and twelfth thoracic nerves.

Actions.—The Serratus posterior inferior draws the lower ribs downwards and backwards and thus elongates the thorax; it also fixes the lower ribs, thus assisting the inspiratory action of the Diaphragm and resisting the tendency of the latter to draw the lower ribs upwards and forwards.

The **Diaphragm** (figs. 548, 549) is a dome-shaped musculofibrous septum which separates the thoracic from the abdominal cavity, its convex

CC-0. In Public Domain. Gurukul Kangri Collection, Haridwar

Digitized by Arya Samaj Foundation Chennai and eGangotri

...ce forming the floor of the former, and its concave or abdominal surface the ...of the latter. Its peripheral part consists of muscular fibres which take ...n from the circumference of the thoracic outlet and converge to be inserted ...s central tendon.

...e muscular fibres may be grouped according to their origins into three —sternal, costal, and lumbar. The *sternal part* arises by two fleshy ...from the back of the xiphoid process; the *costal part* from the inner ...ces of the cartilages and adjacent portions of the lower six ribs on either ...interdigitating with the Transversus abdominis; and the *lumbar part* ...aponeurotic arches, named the lumbocostal arches, and from the lumbar ...bræ by two pillars or *crura*. There are two lumbocostal arches, a medial ...lateral, on either side.

Fig. 549.—The Diaphragm. Inferior aspect.

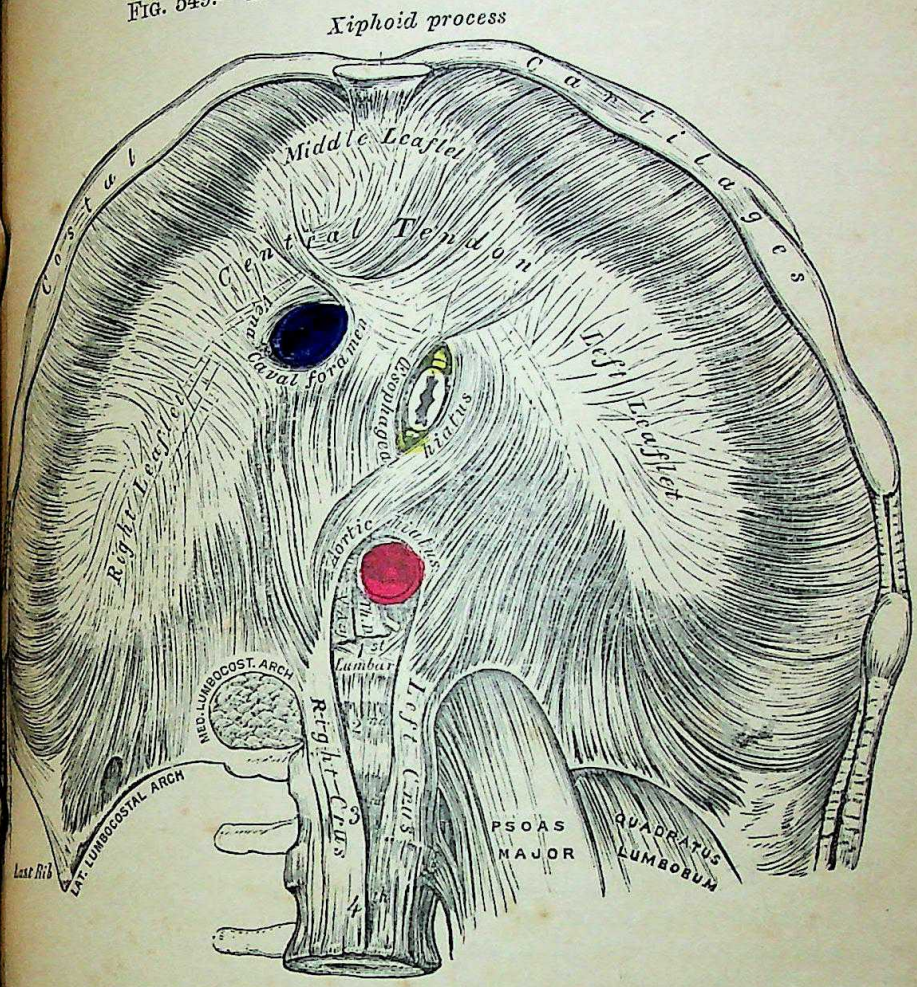

...The *medial lumbocostal arch* (internal arcuate ligament) is a tendinous ...in the fascia covering the upper part of the Psoas major; medially, it ...continuous with the lateral tendinous margin of the corresponding crus, and ...ttached to the side of the body of the first or second lumbar vertebræ; ...rally, it is fixed to the front of the transverse process of the first lumbar ...ebra.

...The *lateral lumbocostal arch* (external arcuate ligament) arches across the ...er part of the Quadratus lumborum, and is attached, medially, to the ...of the transverse process of the first lumbar vertebra, and, laterally, to ...lower margin of the twelfth rib.

...*The crura.*—At their origins the crura are tendinous in structure, and blend ...the anterior longitudinal ligament of the vertebral column. The *right* ...larger and longer than the left, arises from the anterior surfaces of the ...es and intervertebral fibrocartilages of the upper three lumbar vertebræ, ...the *left crus* arises from the corresponding parts of the upper two only.

CC-0. In Public Domain. Gurukul Kangri Collection, Haridwar

Digitized by Arya Samaj Foundation Chennai and eGangotri

The medial tendinous margins of the crura occasionally meet in the line to form an arch across the front of the aorta; this arch is often defined.

From this series of origins the fibres of the Diaphragm converge to inserted into the central tendon. The fibres arising from the xiphoid are very short, and occasionally aponeurotic; those from the ribs and lateral lumbocostal arches, and more especially those from the ribs and cartilages, are longer, and describe marked curves as they ascend and to their insertion. The fibres arising from the crura diverge as they the most lateral being directed upwards and lateralwards to the centre. The medial fibres of the right crus ascend on the left side of the œsophageal hiatus, and occasionally a fasciculus of the left crus crosses the aorta, runs obliquely through the fibres of the right crus towards the venacaval foramen (Low *).

The *central tendon* of the Diaphragm is a thin but strong aponeurosis near the centre of the vault formed by the muscle, but somewhat nearer the front than to the back of the thorax, so that the posterior muscular fibres are the longer. It is situated immediately below the pericardium, with which it is partially blended. It is shaped somewhat like a trefoil leaf, consisting of three divisions or leaflets separated from one another by slight indentations. The right leaflet is the largest, the middle, directed towards the xiphoid process, the next in size, and the left the smallest. In structure the tendon is composed of several planes of fibres, which intersect one another at right angles and unite into straight or curved bundles—an arrangement which gives it additional strength.

Openings in the Diaphragm.—The Diaphragm is pierced by a number of apertures to permit of the passage of structures between the thorax and abdomen. Three large openings—the aortic, the œsophageal, and the venacaval—and a number of smaller ones are present.

The *aortic hiatus* is the lowest and most posterior of the large apertures; it lies at the level of the twelfth thoracic vertebra slightly to the left of the middle line. Strictly speaking, it is an osseo-aponeurotic opening between the vertebral column and the Diaphragm, and therefore behind the latter. Occasionally some tendinous fibres from the medial parts of the crura pass behind the aorta, and convert the hiatus into a fibrous ring. Through it pass the aorta, the azygos vein, and the thoracic duct; occasionally the azygos vein pierces the right crus.

The *œsophageal hiatus* is situated in the muscular part of the Diaphragm at the level of the tenth thoracic vertebra; it is elliptical in shape, and "formed by the splitting of the medial fibres of the right-crus" (Low). It is placed above, in front, and a little to the left of the aortic hiatus, and transmits the œsophagus, the vagus nerves, and some small œsophageal vessels.

The *venacaval foramen* is the highest of the three, and is situated at the level of the fibrocartilage between the eighth and ninth thoracic vertebrae. It is quadrilateral in form, and is placed at the junction of the right and middle leaflets of the central tendon, so that its margins are tendinous. It transmits the inferior vena cava, the wall of which is adherent to the margins of the opening, and some branches of the right phrenic nerve.

Of the *lesser apertures*, two in the right crus transmit the greater and lesser right splanchnic nerves; three in the left crus give passage to the greater and lesser left splanchnic nerves and the hemiazygos vein. The gangliated trunks of the sympathetic usually enter the abdominal cavity behind the Diaphragm under the medial lumbocostal arches. The structures piercing the crura are sometimes utilised to divide each crus into medial, intermediate, and lateral parts, the last consisting of the fibres arising from the medial lumbocostal arch. Between the medial and intermediate parts the hemiazygos vein and the splanchnic nerves pass; between the intermediate and lateral parts the gangliated trunks of the sympathetic occasionally pass.

On either side two small intervals exist at which the muscular fibres of the Diaphragm are deficient and are replaced by areolar tissue. One between the sternal and costal parts transmits the superior epigastric branch of the internal mammary artery, and some lymphatics from the abdominal wall.

* Alex. Low, *Journal of Anatomy and Physiology*, vol. xlii.

CC-0. In Public Domain. Gurukul Kangri Collection, Haridwar

Digitized by Arya Samaj Foundation Chennai and eGangotri

ax surface of the liver. The other, between the fibres springing from medial and lateral lumbocostal arches, is less constant; when this interval the upper and back part of the kidney is separated from the pleura by tissue only.

ations.—The upper surface of the Diaphragm is in relation with three serous ranes, viz. on either side the pleura, which separates it from the base of the ponding lung, and on the middle leaflet of the central tendon the pericardium, intervenes between it and the heart. The central portion lies on a slightly lower than the summits of the lateral portions. The greater part of the under surface ered by the peritoneum. The right side is accurately moulded over the convex of the right lobe of the liver, the right kidney, and right suprarenal gland; the r the left lobe of the liver, the fundus of the stomach, the spleen, the left kidney, left suprarenal gland.

erve-supply.—The Diaphragm is supplied by the phrenic nerve and the lower seven intercostal nerves.

ctions.—The Diaphragm is the principal muscle of inspiration, and presents orm of a dome concave towards the abdomen. The central part of the dome ninous, and the pericardium is attached to its upper surface; the circum- is muscular. During inspiration the lowest ribs are fixed, and from these e crura the muscular fibres contract and draw downwards and forwards the tendon with the attached pericardium. In this movement the curvature Diaphragm is scarcely altered, the dome moving downwards nearly parallel original position and pushing before it the abdominal viscera. The descent abdominal viscera is permitted by the extensibility of the abdominal wall, but mit of this is soon reached. The central tendon applied to the abdominal n then becomes a fixed point for the action of the Diaphragm, the effect of is to elevate the lower ribs and through them to push forwards the body sternum and the upper ribs. The right cupola of the Diaphragm, lying on iver, has a greater resistance to overcome than the left, which lies over the ch, but to compensate for this the right crus and the fibres of the right side ly are stronger than those of the left.

all expulsive acts the Diaphragm is called into action to give additional power effort. Thus, before sneezing, coughing, laughing, crying, or vomiting, and ns to the expulsion of urine or fæces, or of the fœtus from the uterus, a deep ation takes place.

The height of the Diaphragm is constantly varying during respiration; it also s with the degree of distension of the stomach and intestines and with the of the liver. After a forced expiration the right cupola is on a level in front the fourth costal cartilage, at the side with the fifth, sixth, and seventh ribs, hind with the eighth rib; the left cupola is a little lower than the right. Dally* states that the absolute range of movement between deep inspiration eep expiration averages in the male and female 30 mm. on the right side and on the left; in quiet respiration the average movement is 12·5 mm. on the side and 12 mm. on the left.

ography shows that the height of the Diaphragm in the thorax varies considerably the position of the body. It stands highest when the body is horizontal and the on his back, and in this position it performs the largest respiratory excursions normal breathing. When the body is erect the dome of the Diaphragm falls, and piratory movements become smaller. The dome falls still lower when the sitting e is assumed, and in this position its respiratory excursions are smallest. When the is horizontal and the patient on his side, the two halves of the Diaphragm do not e alike. The uppermost half sinks to a level lower even than when the patient sits, ves little with respiration; the lower half rises higher in the thorax than it does the patient is supine, and its respiratory excursions are much increased.

ears that the position of the Diaphragm in the thorax depends upon three main s, viz.: (1) the elastic retraction of the lung-tissue, tending to pull it upwards; pressure exerted on its under surface by the viscera: this naturally tends to be a ve pressure, or downward suction, when the patient sits or stands, and a positive, ard pressure, when he lies; (3) the intra-abdominal tension due to the abdominal es. These muscles are in a state of contraction in the standing position and not in ting; hence the Diaphragm is pushed up higher in the former position.

* *Journal of Anatomy and Physiology*, vol. xliii.

CC-0. In Public Domain. Gurukul Kangri Collection, Haridwar

Digitized by Arya Samaj Foundation Chennai and eGangotri

Applied Anatomy.—The oblique rise of the Diaphragm from the costal [illegible] level of the fifth costal cartilage on the right side, and the sixth on the left, ha[illegible] in mind in opening an empyema. If the drainage tube be put in too low do[illegible] abscess cavity contracts the Diaphragm is drawn up against and blocks the [illegible] the abscess is cured.

The Mechanism of Respiration

The respiratory movements must be examined during (*a*) quiet respi[illegible] (*b*) deep respiration.

Quiet respiration.—The first and second pairs of ribs are fixed by the [illegible] of the cervical structures; the last pair, and through them the eleventh [illegible] Quadratus lumborum. The other ribs are elevated, so that the first two [illegible] spaces are diminished while the others are increased in width. It has al[illegible] shown (p. 373) that elevation of the third, fourth, fifth, and sixth ribs le[illegible] increase in the anteroposterior and transverse diameters of the thorax: th[illegible] diameter is increased by the descent of the diaphragmatic dome so that [illegible] are expanded in all directions except backwards and upwards. Elevati[illegible] eighth, ninth, and tenth ribs is accompanied by a lateral and backward m[illegible] leading to an increase in the transverse diameter of the upper part of the a[illegible] the elasticity of the anterior abdominal wall allows a slight increase in th[illegible] posterior diameter of this part, and in this way the decrease in the vertical [illegible] of the abdomen is compensated and space provided for its displaced viscera. [illegible] tion is effected by the elastic recoil of its walls and by the action of the a[illegible] muscles, which push back the viscera displaced downwards by the Diaph[illegible]

Deep respiration.—All the movements of quiet respiration are here ex[illegible] but to a greater extent. In deep respiration the shoulders and the vertebr[illegible] of the scapulæ are fixed and the limb muscles, the Trapezius, Serratus [illegible] Pectorales, and Latissimus dorsi, called into play. The Scaleni are i[illegible] action, and the Sternocleidomastoidei also assist, when the head is fixed, by [illegible] up the sternum and by fixing the clavicles. The first rib is therefore [illegible] stationary, but, with the sternum, is raised; with it all the other ribs ex[illegible] last are raised to a higher level. In conjunction with the increased descen[illegible] Diaphragm this provides for a considerable augmentation of all the [illegible] diameters. The anterior abdominal muscles come into action so that the [illegible] is drawn upwards and backwards, but this allows the Diaphragm to exert [illegible] powerful influence on the lower ribs; the transverse diameter of the upper [illegible] the abdomen is greatly increased and the subcostal angle opened out. Th[illegible] muscles of the back, e.g. the Serrati posteriores superiores and the Sacro[illegible] and their continuations, are also brought into action; the thoracic curv[illegible] vertebral column is partially straightened, and the whole column, above th[illegible] lumbar vertebræ, drawn backwards. This increases the anteroposterior di[illegible] of the thorax and upper part of the abdomen and widens the intercostal [illegible] Deep expiration is effected by the recoil of the walls and by the contractio[illegible] anterolateral muscles of the abdominal wall, and the Transversus thoracis.

Halls Dally (*loc. cit.*) gives the following figures as representing the average [illegible] which occur during deepest possible respiration. The manubrium sterni moves [illegible] in an upward and 14 mm. in a forward direction; the width of the subcostal an[illegible] level of 30 mm. below the articulation between the body of the sternum and the [illegible] process, is increased by 26 mm.; the umbilicus is retracted and drawn upwa[illegible] distance of 18 mm.

Applied Anatomy.—The changes in the height of the Diaphragm during alter[illegible] posture explain why patients suffering from severe dyspnœa are most comfort[illegible] least short of breath when they sit up. In unilateral disease of the pleura or lu[illegible] ference with the position or movement of the Diaphragm can generally be obser[illegible] graphically.

The referred pains felt when the Diaphragm is inflamed are described with the [illegible] of the phrenic nerve.

CC-0. In Public Domain. Gurukul Kangri Collection, Haridwar

Digitized by Arya Samaj Foundation Chennai and eGangotri

IV. The Muscles of the Abdomen

muscles of the abdomen may be divided into two groups: 1. The
steral muscles; 2. The posterior muscles.

1. The Anterolateral Muscles

Transversus.
Rectus.
Obliquus externus.
Obliquus internus.
Pyramidalis.

superficial fascia of the abdomen consists, over the greater part of
dominal wall, of a single layer containing a variable amount of fat; but

Fig. 550.—The left Obliquus externus abdominis.

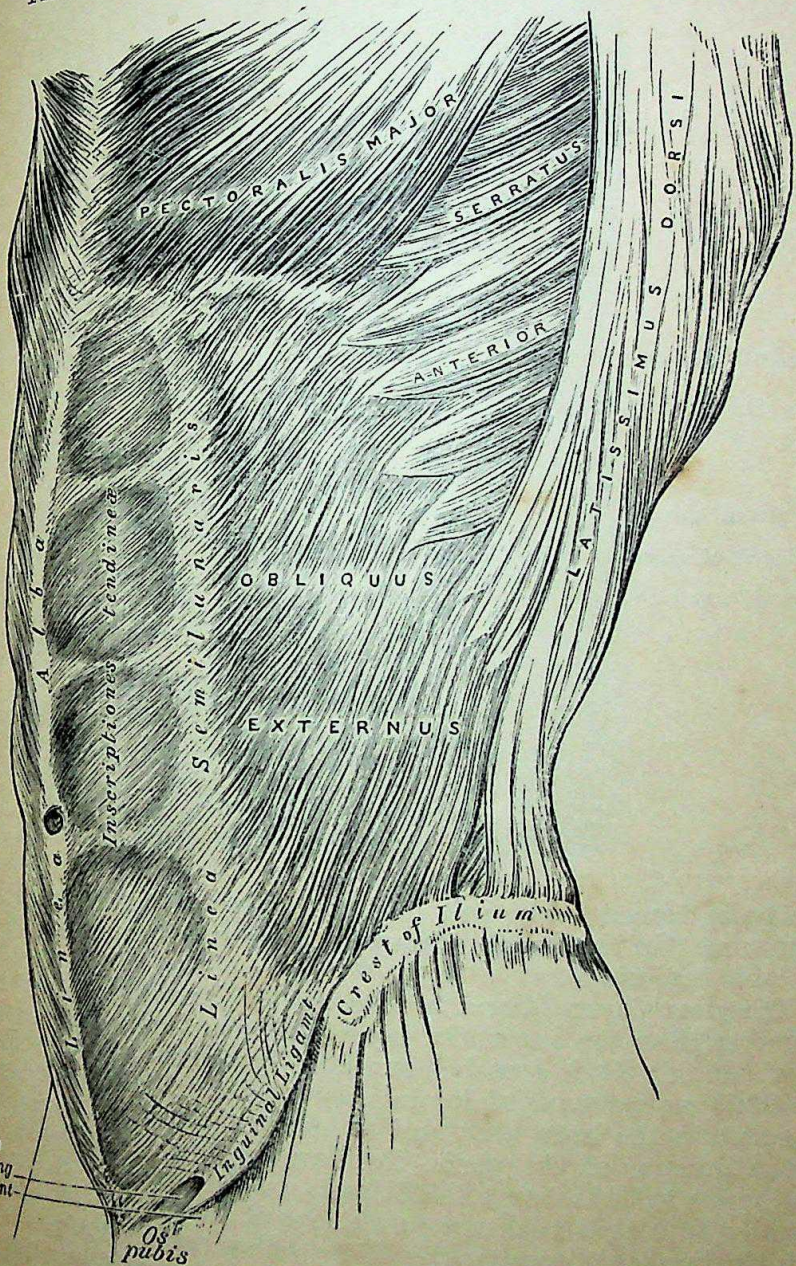

the groin it is easily divisible into two layers, between which are found
superficial vessels and nerves and the superficial inguinal lymph glands.

CC-0. In Public Domain. Gurukul Kangri Collection, Haridwar

Digitized by Arya Samaj Foundation Chennai and eGangotri

The superficial layer (*fascia of Camper*) is thick, areolar in te contains in its meshes a varying quantity of adipose tissue. Below over the inguinal ligament, and is continuous with the superficial fa thigh. In the male, Camper's fascia is continued over the penis surface of the spermatic cord to the scrotum, where it helps to form As it passes to the scrotum it changes its characteristics, becoming thi of adipose tissue, and of a pale reddish colour; in the scrotum i some involuntary muscular fibres and forms the *dartos tunic*. From th

Fig. 551.—A superficial dissection of the groin and the lower part of the abdominal wall. Right side.

it may be traced backwards into continuity with the superficial fasci perinæum. In the female, Camper's fascia is continued from the abd the labia majora.

The deep layer (*fascia of Scarpa*) is thinner and more membra character than the superficial layer, and contains a considerable qu elastic fibres. It is loosely connected by areolar tissue to the apone the Obliquus externus abdominis, but in the middle line it is more in adherent to the linea alba and to the symphysis pubis, and is prol to the dorsum of the penis, forming the *fundiform ligament*; abo continuous with the superficial fascia over the rest of the trunk; be laterally, it blends with the fascia lata of the thigh a little below and with the inguinal ligament (fig. 551); below and medially, it is contin the penis and spermatic cord to the scrotum, where it helps to form th From the scrotum it may be traced backwards into continuity with layer of the superficial fascia of the perinæum (*fascia of Colles*). In th it is continued into the labia majora and thence to the fascia of Colles

CC-0. In Public Domain. Gurukul Kangri Collection, Haridwar

Digitized by Arya Samaj Foundation Chennai and eGangotri

The Obliquus externus abdominis (fig. 550), situated on the lateral and anterior parts of the abdomen, is the largest and the most superficial of the broad flat muscles in this region. It arises, by eight fleshy slips, from the external surfaces and inferior borders of the lower eight ribs; these slips digitate with the slips of origin of the Serratus anterior and Latissimus and are arranged in an oblique line which runs downwards and backwards, the upper ones being attached close to the cartilages of the corresponding ribs, the lowest to the apex of the cartilage of the last rib, the intermediate ones to

Fig. 552.—A superficial dissection of the groin and the lower part of the anterior abdominal wall. Left side.

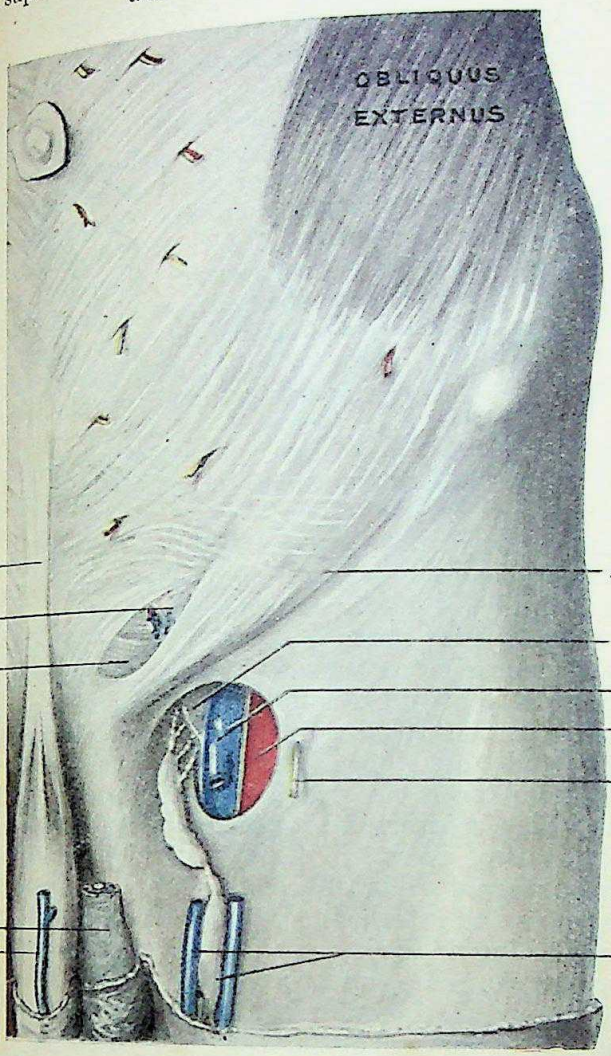

ribs at some distance from their cartilages. From these attachments the fibres proceed in various directions. Those from the lowest ribs pass vertically downwards, and are inserted into the anterior half of the lip of the iliac crest; the middle and upper fibres, directed downwards wards, end in an aponeurosis, opposite a line drawn from the prominence ninth costal cartilage to the anterior superior iliac spine. The posterior of the muscle is free.

The *aponeurosis* of the Obliquus externus abdominis is a thin but strong membranous structure, the fibres of which are directed downwards and medialwards. It is joined with that of the opposite muscle along the middle line, and aponeuroses of the two muscles cover the front of the abdomen; above, covered by, and gives origin to, the lower fibres of the Pectoralis major; its fibres are closely aggregated together, and extend obliquely across the anterior superior iliac spine to the pubic tubercle and the pectineal In the middle line, its fibres end in the *linea alba* (fig. 550), a tendinous which extends from the xiphoid process to the symphysis pubis.

CC-0. In Public Domain. Gurukul Kangri Collection, Haridwar.

Digitized by Arya Samaj Foundation Chennai and eGangotri

The margin of that portion of the aponeurosis which extends be anterior superior iliac spine and the pubic tubercle is a thick ba inwards upon itself to present a grooved upper surface, and contin with the fascia lata; it is called the *inguinal ligament*. A small reflected from the medial part of the inguinal ligament, and is attac pecten pubis; it is called the *lacunar ligament*. From the attachm latter to the pecten pubis, a few fibres pass upwards and medialwar the medial crus of the subcutaneous inguinal ring, to the linea alb diverge as they ascend, and form a thin triangular fibrous band whic the *reflected inguinal ligament* (fig. 557).

In the aponeurosis of the Obliquus externus, immediately above of the os pubis, is a triangular opening, the *subcutaneous inguinal ring* by a separation of the fibres of the aponeurosis in this situation.

Nerve-supply.—The Obliquus externus abdominis is supplied by the divisions of the lower thoracic nerves.

Actions.—When the thorax and pelvis are fixed the Obliqui externi a compress the abdominal viscera and thus assist in expelling the fæces from the urine from the bladder, the fœtus from the uterus, and the conte stomach in vomiting. If the pelvis and vertebral column be fixed the depress and compress the lower part of the thorax, assisting in expir the pelvis alone be fixed, the trunk is bent forwards when both muscles a muscle of one side act, the trunk is bent towards that side and the front of men turned towards the opposite side. If the thorax be fixed the muscl together, draw the front of the pelvis upwards; acting singly they will i bend the lumbar part of the vertebral column, and turn the front of the to the same side.

The following structures require further description, viz. the sub inguinal ring, the intercrural fibres and fascia, and the inguinal, lacu reflected inguinal ligaments.

The **subcutaneous inguinal ring** (external abdominal ring) (figs. is an interval in the aponeurosis of the Obliquus externus, just above a to the crest of the os pubis. The aperture is somewhat triangular in f its direction is oblique, corresponding with the course of the fibres aponeurosis. It measures from base to apex about 2·5 cm., and a base about 1·25 cm. It is bounded below by the crest of the os pubis; o side by the margins of the opening in the aponeurosis, which are ca *crura of the ring*; and above, by a series of curved *intercrural fibr* inferior crus (external pillar) is the stronger, and is formed by that portio inguinal ligament which is inserted into the pubic tubercle; it is so c to form a kind of groove, upon which, in the male, the spermatic cor The superior crus (internal pillar) is a thin, flat band, attached to th of the symphysis pubis and interlacing with its fellow of the opposite sid

The subcutaneous inguinal ring gives passage to the spermatic c ilio-inguinal nerve in the male, and to the round ligament of the ute the ilio-inguinal nerve in the female; it is much larger in men than i on account of the size of the spermatic cord.

The **intercrural fibres** (intercolumnar fibres) are a series of tendinous fibres, which arch across the lower part of the aponeuros Obliquus externus, describing curves with the convexities downwards have received their name from stretching across between the two c the subcutaneous inguinal ring, and they are much thicker and strong inferior crus, where they are connected to the inguinal ligament, than su where they are inserted into the linea alba. The intercrural fibres the strength of the lower part of the aponeurosis, and tend to prev divergence of the crura from one another; they are more strongly d in the male than in the female.

As they pass across the subcutaneous inguinal ring, they are c together by delicate fibrous tissue, forming a fascia, called the *fascia*. This **intercrural fascia** is continued down as a tubular p tion around the spermatic cord and testis, and encloses them in a hence it is also called the *external spermatic fascia*. The subcutaneous ring is seen as a distinct aperture only after the intercrural fascia h removed.

CC-0. In Public Domain. Gurukul Kangri Collection, Haridwar

Digitized by Arya Samaj Foundation Chennai and eGangotri

The **inguinal ligament** (Poupart's ligament) (figs. 551 to 553) is the lower
er of the aponeurosis of the Obliquus externus, and extends from the
rior superior iliac spine to the pubic tubercle. Its general direction is
r downwards towards the thigh, where it is continuous with the fascia
Its lateral one-half is rounded, and oblique in direction; its medial
lf gradually widens at its attachment to the os pubis, is more horizontal
rection, and supports the spermatic cord.

The **lacunar ligament** (Gimbernat's ligament) (fig. 553) is that portion of the
eurosis of the Obliquus externus which is reflected backwards and lateral-
s from the medial part of the inguinal ligament, and is attached to the
os pubis. It is of a triangular form, and is almost horizontal in direction

FIG. 553.—The left inguinal and lacunar ligaments.

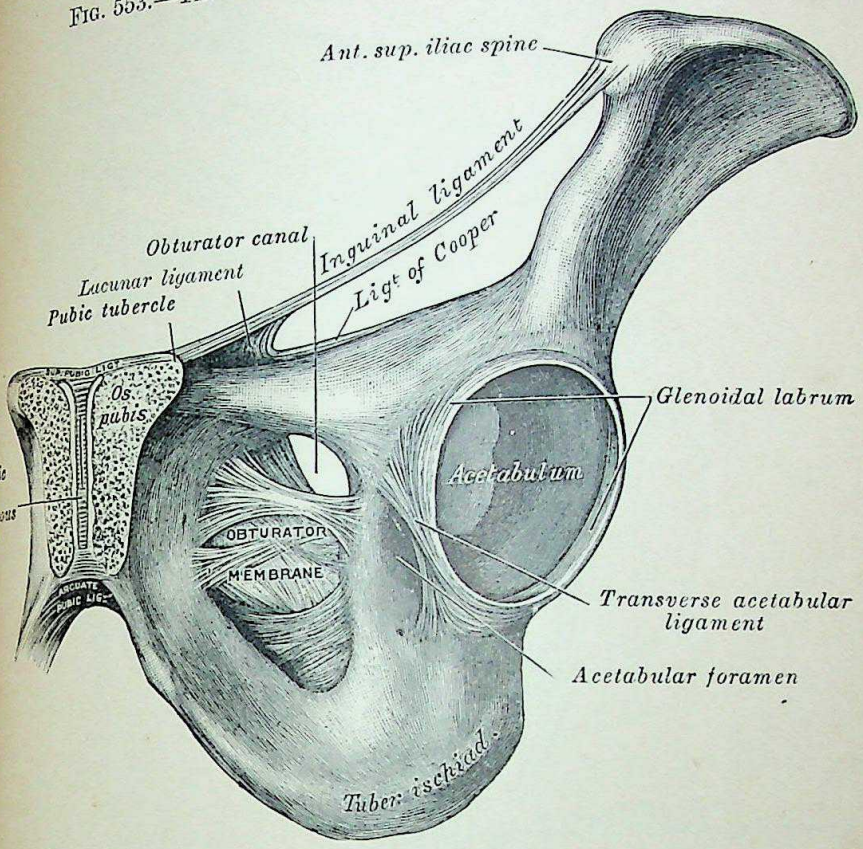

n the body is in the erect posture; it is a little larger in the male than
he female, and measures about 2 cm. from base to apex. Its base,
ed laterally, is concave and thin and forms the medial boundary of the
ral ring; its apex corresponds to the pubic tubercle. Its posterior margin
ached to the pecten pubis, and is continuous with the pectineal fascia;
nterior margin blends with the inguinal ligament. Its surfaces are directed
rds and downwards.

The **reflected inguinal ligament** (triangular fascia) (figs. 552, 557) is a
gular-shaped layer of tendinous fibres; it is formed by an expansion
the lacunar ligament and the inferior crus of the subcutaneous inguinal
It passes medialwards behind the spermatic cord, expands into a some-
fan-shaped band behind the superior crus of the subcutaneous inguinal
and in front of the inguinal aponeurotic falx, and interlaces with the
ent of the other side at the linea alba.

gament of Cooper.—This is a strong fibrous band, which was first described
Astley Cooper. It extends lateralwards from the base of the lacunar
ent (fig. 553) along the pecten pubis, to which it is attached. It is
gthened by the pectineal fascia, and by a lateral expansion from the lower
ment of the linea alba (adminiculum lineæ albæ).

CC-0. In Public Domain. Gurukul Kangri Collection, Haridwar

Digitized by Arya Samaj Foundation Chennai and eGangotri

The **Obliquus internus abdominis** (fig. 554), thinner and smaller than the Obliquus externus, beneath which it lies, is of an irregularly quadrilateral form. It arises, by fleshy fibres, from the lateral one-half of the groove on the surface of the inguinal ligament, from the anterior two-thirds of the middle lip of the iliac crest, and from the posterior lamella of the lumbodorsal fascia. From this origin the fibres diverge; those from the inguinal ligament are few in number, and paler in colour than the rest, arch downwards and medialwards across the spermatic cord in the male, and the round ligament of the uterus in the female, and, becoming tendinous, are inserted, conjointly with

FIG. 554.—The left Obliquus internus abdominis.

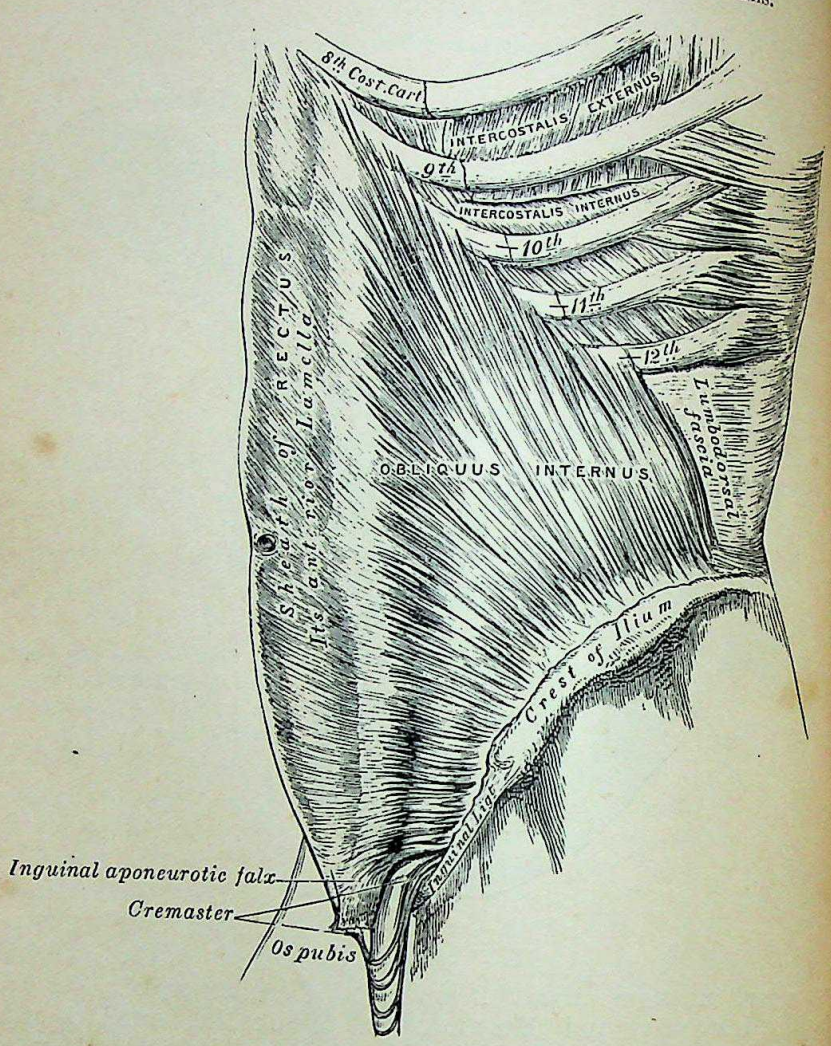

the Transversus, into the crest of the os pubis and into the medial part of the pecten pubis behind the lacunar ligament, forming what is known as the inguinal aponeurotic falx. Those from the anterior one-third of the iliac origin are horizontal in their direction, and, becoming tendinous along the lower one-third of the linea semilunaris, pass in front of the Rectus abdominis to be inserted into the linea alba. Those arising from the middle one-third of the iliac crest run obliquely upwards and medialwards, and end in an aponeurosis which divides at the lateral border of the Rectus into two lamellæ, which are carried forwards, one in front of and the other behind this muscle, to the linea alba; the posterior lamella has an attachment to the cartilages of the seventh, eighth and ninth ribs. The most posterior fibres pass almost vertically upwards to be inserted into the inferior borders of the cartilages of the lower three, being continuous with the Intercostales interni.

Nerve-supply.—The Obliquus internus abdominis is supplied by the anterior divisions of the lower thoracic and first lumbar nerves.

CC-0. In Public Domain. Gurukul Kangri Collection, Haridwar

Digitized by Arya Samaj Foundation Chennai and eGangotri

ions.—The actions of the Obliqui interni abdominis are similar to those of liqui externi in compressing the abdomen (p. 472). Acting from below the s internus bends the thorax and turns the front of the abdomen towards e side; acting from above it bends the lumbar part of the vertebral column wn side and turns the front of the abdomen to the opposite side.

Cremaster (figs. 554, 556) is a thin muscular layer, composed of a of fasciculi which arise from the middle of the inguinal ligament, where

FIG. 555.—The left Transversus abdominis and right Rectus abdominis.

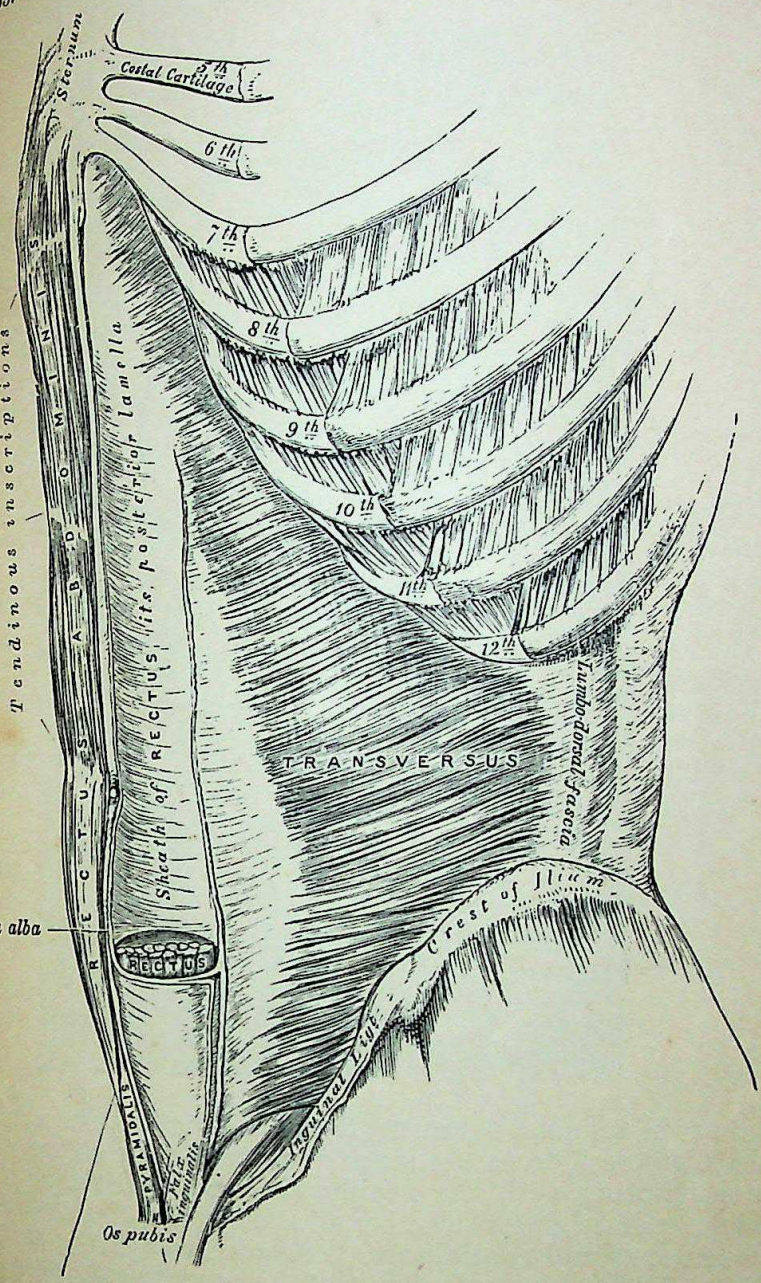

es are continuous with those of the Obliquus internus and also occasionally the Transversus. It passes along the lateral side of the spermatic cord, ds with it through the subcutaneous inguinal ring upon the front and of the cord, and forms a series of loops which differ in thickness and in different subjects. At the upper part of the cord the loops are short, ey become successively longer, the longest reaching down as far as the where a few are inserted into the tunica vaginalis. These loops are d together by areolar tissue, and form a thin covering over the cord and the *cremasteric fascia*. The fibres ascend along the medial side of the

CC-0. In Public Domain. Gurukul Kangri Collection, Haridwar

Digitized by Arya Samaj Foundation Chennai and eGangotri

cord, and are inserted by a small pointed tendon into the tubercle of the os pubis and into the front of the sheath of the Rectus abdominis.

Nerve-supply.—The Cremaster is supplied by the external spermatic of the genitofemoral nerve.

Action.—The Cremaster is an involuntary muscle which pulls up the testis.

The **Transversus abdominis** (fig. 555), so called from the direction of its fibres, is the most internal of the flat muscles of the abdomen, being deep to the Obliquus internus. It arises by fleshy fibres from the

FIG. 556.—A dissection of the regions shown in fig. 551, but with a part of the Obliquus externus removed.

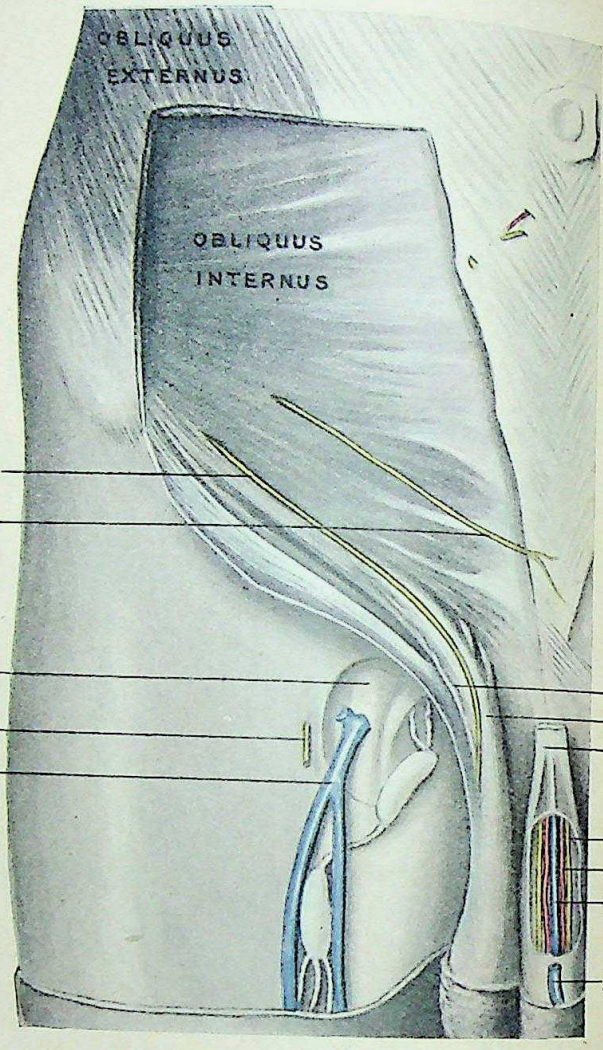

one-third of the inguinal ligament, from the anterior three-fourths of the lip of the iliac crest, from the inner surfaces of the cartilages of the lower ribs, interdigitating with the Diaphragm, and from the lumbodorsal fascia. The muscle ends in front in a broad aponeurosis, the lower fibres of which curve downwards and medialwards, and are inserted, together with those of the Obliquus internus, into the crest of the os pubis and pecten pubis, forming the inguinal aponeurotic falx. Throughout the rest of its extent the aponeurosis passes horizontally to the middle line, and is inserted into the linea alba; its upper three-fourths lie behind the Rectus and blend with the posterior lamella of the aponeurosis of the Obliquus internus; its lower one-fourth in front of the Rectus.

The *inguinal aponeurotic falx*, or *conjoined tendon* of the Obliquus internus and Transversus (figs. 557, 558), is mainly formed by the lower part of the tendon of the Transversus, and is inserted into the crest of the os pubis and pecten pubis, immediately behind the subcutaneous inguinal ring, serving to protect what would otherwise be a weak point in the abdominal wall. It

CC-0. In Public Domain. Gurukul Kangri Collection, Haridwar

Digitized by Arya Samaj Foundation Chennai and eGangotri

the falx is a ligamentous band connected with the lower margin of the transversus and extending down to the superior ramus of the os pubis; it is named the *interfoveolar ligament* (of Hesselbach) (fig. 558), and sometimes contains a few muscular fibres.

Nerve-supply.—The Transversus abdominis is supplied by the anterior divisions of the lower thoracic and first lumbar nerves.

Actions.—The Transversi abdominis almost completely encircle the abdominal cavity; in action they compress the abdominal contents.

FIG. 557.—A dissection of the regions shown in fig. 552, but with portions of the Obliqui externus et internus removed.

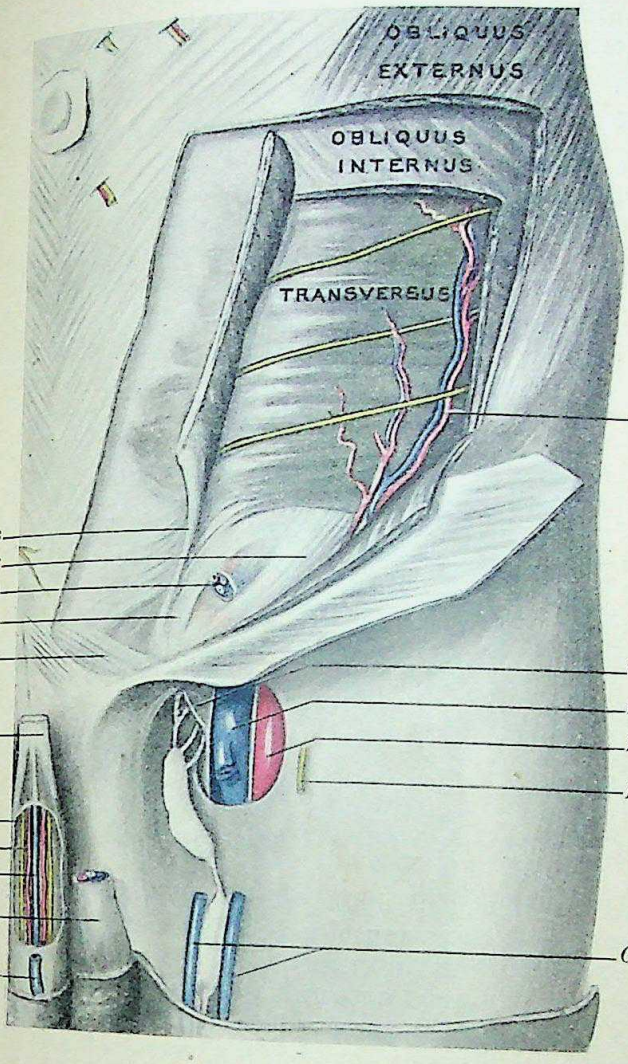

Rectus abdominis (fig. 559) is a long flat muscle, broader above than below, which extends along the whole length of the front of the abdomen, and is separated from its fellow of the opposite side by the linea alba. It arises by two tendons; the lateral and larger is attached to the crest of the pubis, the medial interlaces with its fellow of the opposite side and is continuous with the ligamentous fibres covering the front of the symphysis pubis. The muscle is inserted by three slips of unequal size into the cartilages of the fifth, sixth, and seventh ribs; some fibres of the upper slip are usually inserted into the anterior extremity of the fifth rib; some are occasionally connected with the costoxiphoid ligaments and the side of the xiphoid process.

The Rectus is crossed by three fibrous bands, named *tendinous inscriptions*; one is usually situated opposite the umbilicus, the second opposite the end of the xiphoid process, and the third about midway between the xiphoid process and the umbilicus. These inscriptions pass transversely or obliquely across the muscle in a zigzag course; they rarely extend completely through its substance and may pass only halfway across it; they are intimately

CC-0. In Public Domain. Gurukul Kangri Collection, Haridwar

Digitized by Arya Samaj Foundation Chennai and eGangotri

adherent to the anterior lamina of the sheath of the muscle. Sometimes two additional but incomplete inscriptions are present below the umbilicus.

The Rectus abdominus is enclosed in a sheath (figs. 554, 559, 560) formed by the aponeuroses of the Obliqui and Transversus, which are arranged as follows. At the lateral margin of the Rectus, the aponeurosis of the Obliquus externus divides into two lamellæ, one of which passes in front of the Rectus, to blend with the aponeurosis of the Obliquus externus, the other, behind it, blends with the aponeurosis of the Transversus, and these, joining again at the lateral border of the Rectus, are inserted into the linea alba. This arrangement of the aponeuroses exists from the costal margin to midway between the umbilicus and symphysis pubis, where the posterior wall of the sheath ends in a concave curved margin, the *linea semicircularis* (fig. 559), the concavity of which is directed downwards. In the upper part of the sheath muscular fibres of the Transversus extend into its posterior wall, and not infrequently do so

FIG. 558.—The interfoveolar ligament. Anterior aspect. (Modified from Braune.)

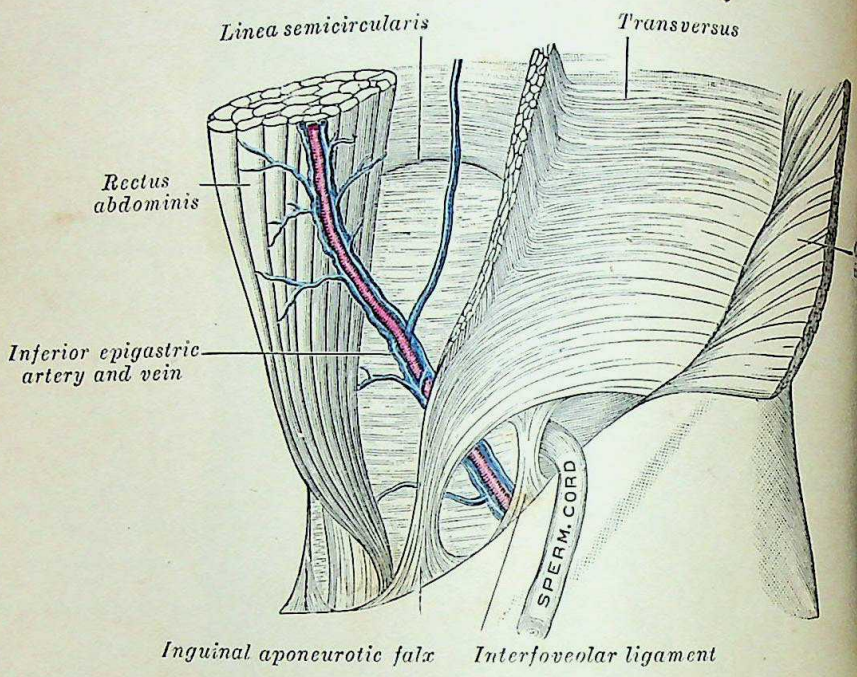

considerable extent (figs. 559, 560). Below the level of the linea semicircularis the aponeuroses of all three muscles pass in front of the Rectus; those of the Transversus and Obliquus internus are intimately fused together, the aponeurosis of the Obliquus externus is bound to them merely by loose connective tissue except in and near the middle line; behind, the Rectus is separated from the peritoneum by the transversalis fascia (fig. 561). Since the aponeuroses of the Obliquus internus and Transversus only reach as far as the costal margin, it follows that above this level the sheath of the Rectus is deficient posteriorly, the muscle resting directly on the cartilages of the ribs; the front of this part of the Rectus is covered merely by the tendon of the Obliquus externus.

Nerve-supply.—The Rectus abdominis is supplied by the anterior divisions of the lower thoracic nerves.

Actions.—The Rectus abdominis acting from above elevates the front of the pelvis; acting from below it depresses the thorax, and in continued action flexes the vertebral column. The two muscles are also powerful compressors of the abdominal viscera.

Applied Anatomy.—In suturing incisions through the upper part of the sheath of the Rectus abdominis it is necessary to suture the Transversus abdominis where it enters into the formation of the posterior wall of the sheath. The fibres of the Transversus abdominis being very pale, fine, and sometimes covered with a thin layer of fascia, are liable to be overlooked.

CC-0. In Public Domain. Gurukul Kangri Collection, Haridwar

Digitized by Arya Samaj Foundation Chennai and eGangotri

Pyramidalis (fig. 559) is a triangular muscle, placed at the lower part of abdomen, in front of the Rectus abdominis and within the sheath of that It arises by tendinous fibres from the front of the os pubis and from mentous fibres in front of the symphysis; the fleshy portion of the passes upwards, diminishing in size as it ascends, and ends in a pointed

559.—The right Rectus abdominis and the left Pyramidalis. The greater part of the left Rectus abdominis has been removed to show the superior and inferior epigastric vessels.

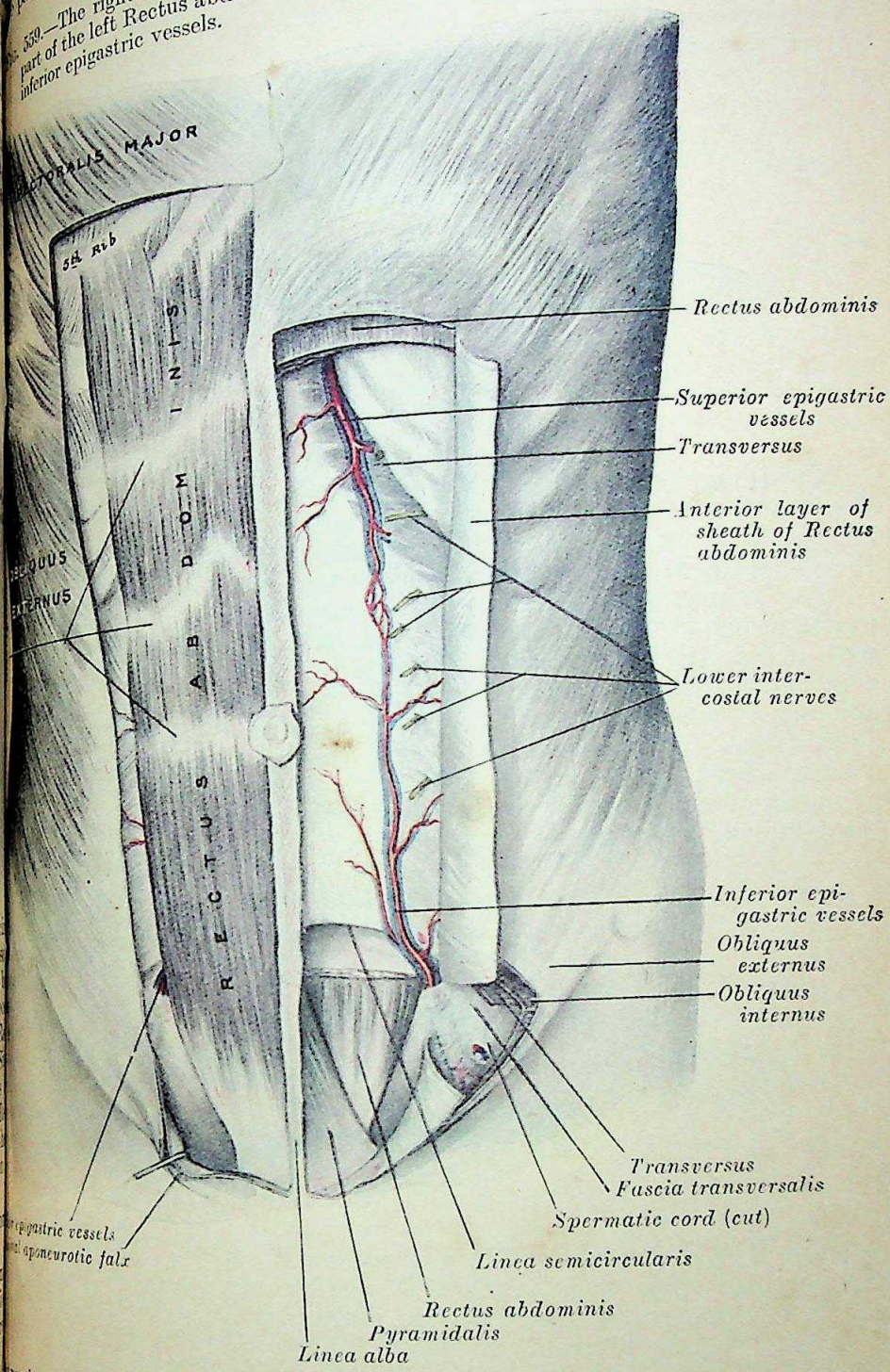

remity which is inserted into the linea alba midway between the umbilicus os pubis, but may extend to a higher level. This muscle may be larger one side than on the other, or may be wanting on one or both sides. Besides the Rectus and Pyramidalis, the sheath of the Rectus contains the superior inferior epigastric arteries, and the terminal portions of the lower intercostal nerves.

Nerve-supply.—The Pyramidalis is supplied by the twelfth thoracic nerve.

Action.—The Pyramidalis is a tensor of the linea alba.

CC-0. In Public Domain. Gurukul Kangri Collection, Haridwar

Digitized by Arya Samaj Foundation Chennai and eGangotri

The **linea alba** (fig. 559) is a tendinous band in the middle line of the stretching between the xiphoid process and the symphysis pubis. It is formed by the blending between the medial borders of the Recti, and is narrow below, broader above, aponeuroses of the Obliqui and Transversi. It is narrow below, corresponding to the linear interval existing between the Recti; but broader above, where these muscles diverge from one another. Its lower end has a double attachment—its superficial fibres passing in front of the medial heads of the Recti to the symphysis pubis, while its deeper fibres form a triangular lamella behind the Recti to the posterior surface of the crest of the os pubis, as the *adminiculum lineæ albæ*. The linea alba presents apertures for the passage of vessels and nerves; the umbilicus, which in the fœtus exists as an aperture and transmits the umbilical vessels, is closed a few days after birth.

Fig. 560.—A transverse section through the anterior abdominal wall, above the umbilicus. Diagrammatic.

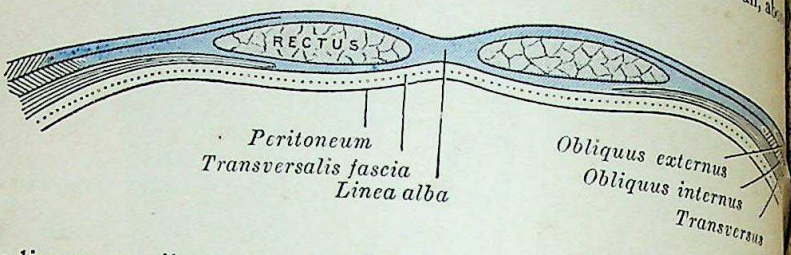

The **lineæ semilunares** are two curved tendinous lines corresponding to the lateral borders of the Recti; each extends from the cartilage of the ninth rib to the pubic tubercle, and marks the line along which the aponeurosis of the Obliquus internus splits to enclose the Rectus abdominis.

The **transversalis fascia** is a thin membrane which lies between the inner surface of the Transversus muscle and the extraperitoneal fat. It is a part of the general layer of fascia lining the abdominal parietes, and is continuous with the iliac and pelvic fasciæ. In the inguinal region it is thin and dense in structure, and is joined by fibres from the aponeurosis of the Transversus, but it becomes thin as it ascends to the Diaphragm, and is lost with the fascia covering the under surface of this muscle. Behind, it is lost in the fat which covers the posterior surfaces of the kidneys. Below, it has the following attachments: posteriorly, to the whole length of the iliac crest

Fig. 561.—A transverse section through the anterior abdominal wall, below the linea semicircularis. Diagrammatic.

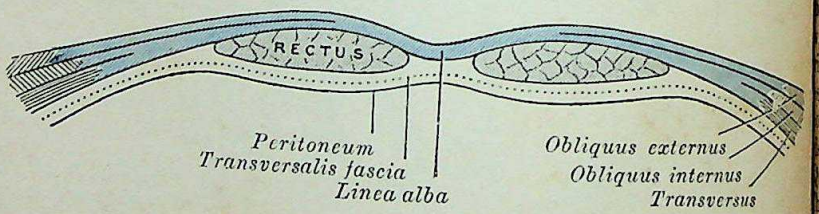

between the origins of the Transversus and Iliacus; between the anterior superior iliac spine and the femoral vessels it is connected to the posterior margin of the inguinal ligament, and is there continuous with the iliac fascia. Medial to the femoral vessels it is thin and is fixed to the pecten pubis, behind the inguinal aponeurotic falx, with which it is united; it descends in front of the femoral vessels to form the anterior wall of the femoral sheath. The spermatic cord in the male, and the round ligament of the uterus in the female, pass through the transversalis fascia at a spot called the *abdominal inguinal ring*. This opening is not visible externally since the transversalis fascia is prolonged on these structures as the infundibuliform fascia.

The **abdominal inguinal ring** (internal abdominal ring) is situated in the transversalis fascia, midway between the anterior superior iliac spine

CC-0. In Public Domain. Gurukul Kangri Collection, Haridwar

Digitized by Arya Samaj Foundation Chennai and eGangotri

mphysis pubis, and 1·25 cm. above the inguinal aponeurosis. It is of al form, the long axis of the oval being vertical; it varies in size rent subjects, and is much larger in the male than in the female. It is d above by the arched lower margin of the Transversus, and medially inferior epigastric vessels. It transmits the spermatic cord in the male e round ligament of the uterus in the female. From its circumference funnel-shaped membrane, the *infundibuliform fascia*, is continued as a ng on the spermatic cord and testis.

e inguinal canal contains the spermatic cord and the ilio-inguinal nerve male, and the round ligament of the uterus and the ilio-inguinal nerve in male. It is an oblique canal about 4 cm. long, slanting downwards and wards, and placed parallel with and a little above the inguinal ligament; nds from the abdominal inguinal ring to the subcutaneous inguinal ring. bounded *in front* by the integument, superficial fascia, and aponeurosis of bliquus externus throughout its whole length, and by the Obliquus internus lateral one-third; *behind* by the reflected inguinal ligament, the inguinal urotic falx, the transversalis fascia, the extraperitoneal connective tissue, e peritoneum; *above* by the arched fibres of the Obliquus internus and versus abdominis; *below* by the union of the transversalis fascia with uinal ligament, and at its medial end by the lacunar ligament.

extraperitoneal connective tissue.—Between the inner surface general layer of the fascia which lines the interior of the abdominal and cavities, and the peritoneum, there is a considerable amount of connec- tissue, termed the *extraperitoneal or subperitoneal connective tissue.* For tive purposes it may be divided into a parietal and a visceral portion. e *parietal* portion lines the cavity, and varies in quantity in different ions. It is especially abundant on the posterior wall of the abdomen, ticularly around the kidneys, where it contains much fat. It is scanty anterolateral wall of the abdomen, except in the pubic region and above crest; there is a considerable amount in the pelvis.

e *visceral* portion follows the course of the branches of the abdominal between the layers of the mesenteries and other folds of peritoneum connect the viscera to the abdominal and pelvic walls.

2. The Posterior Muscles of the Abdomen

Psoas major.	Iliacus.
Psoas minor.	Quadratus lumborum.

Psoas major, the Psoas minor, and the Iliacus, with the fasciæ covering re described with the muscles of the lower extremity (p. 530).

fascia covering the Quadratus lumborum is a thin layer attached, ly, to the bases of the transverse processes of the lumbar vertebræ; to the iliolumbar ligament; above, to the apex and lower border of the b. The upper margin of this fascia, which extends from the transverse s of the first lumbar vertebra to the apex and lower border of the last ssitutes the lateral lumbocostal arch (p. 465). Laterally, the fascia with the layer of the lumbodorsal fascia, which intervenes between adratus lumborum and the Sacrospinalis.

Quadratus lumborum (fig. 546, p. 459) is irregularly quadrilateral in and broader below than above. It arises by aponeurotic fibres from lumbar ligament and the adjacent portion of the iliac crest for about d is inserted into the lower border of the last rib for about one-half its and by four small tendons into the apices of the transverse processes upper four lumbar vertebræ. Occasionally a second portion of this is found in front of the preceding; it arises from the upper borders of nsverse processes of the lower three or four lumbar vertebræ, and is d into the lower margin of the last rib.

ront of the Quadratus lumborum are the colon, the kidney, the Psoas major , and the Diaphragm; between the fascia and the muscle are the twelfth , iliohypogastric, and ilio-inguinal nerves.

rve-supply.—The Quadratus lumborum is supplied by the anterior divisions twelfth thoracic and upper three or four lumbar nerves.

CC-0. In Public Domain. Gurukul Kangri Collection, Haridwar

Digitized by Arya Samaj Foundation Chennai and eGangotri

Actions.—The Quadratus lumborum draws down the last rib, and is a muscle of inspiration by helping to fix the origin of the Diaphragm. If the pelvis and vertebral column are fixed, it may act upon the pelvis, raising it on its own side when only one muscle is put in action; and when both muscles act either from below or above, they flex the trunk.

V. The Muscles of the Pelvis

Obturator internus.
Piriformis.

Levator ani.
Coccygeus.

The muscles within the pelvis may be divided into two groups: (1) the Piriformis and the Obturator internus, which are described with the muscles of the lower extremity (pp. 543, 544); (2) the Levator ani and the Coccygeus, which together form the *pelvic diaphragm* and are associated with the pelvic viscera. The classification of the two groups under a common heading is convenient in connexion with the fasciæ investing the muscles. These fasciæ are closely related to one another and to the deep fascia of the perineum, and in addition are connected with the fascial coverings of the pelvic viscera. It is customary therefore to describe them together under the term *pelvic fascia*.

Fig. 562.—A coronal section through the pelvis, showing the arrangement of the fasciæ. Posterior aspect. Diagrammatic.

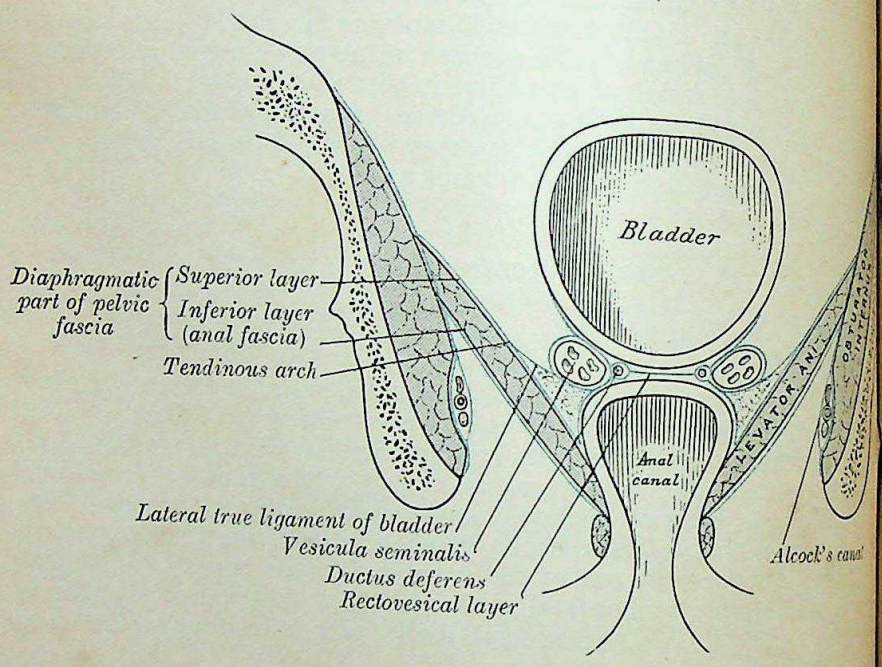

Pelvic fascia.—The fascia of the pelvis may be resolved into: (A) the fascial sheaths of the Obturator internus, Piriformis, and pelvic diaphragm; (B) the fascial sheaths of the pelvic viscera (see section on Splanchnology).

The *fascia of the Obturator internus* covers the pelvic surface of the muscle, attached round the margin of the origin of, the muscle. Above, it is continuous with the posterior part of the arcuate line, and is there continuous with the iliac fascia. In front of this, as it follows the line of origin of the Obturator internus, it gradually separates from the iliac fascia, and the continuity between them is retained only through the periosteum. It arches beneath the obturator vessels and nerve, completing the obturator canal, and at the front of the canal is attached to the back of the superior ramus of the os pubis. The lower part of the obturator fascia forms the lateral wall of the ischiorectal fossa, and is attached inferiorly to the falciform process of the sacrotuberous ligament.

CC-0. In Public Domain. Gurukul Kangri Collection, Haridwar

Digitized by Arya Samaj Foundation Chennai and eGangotri

pubic arch; at the pubic arch it is continuous with the superior fascia urogenital diaphragm. Behind, it is prolonged into the glutæal region. internal pudendal vessels and pudendal nerve are placed in the lateral the ischiorectal fossa, and are enclosed in a special sheath of the fascia, Alcock's canal.

fascia of the Piriformis is very thin and is attached to the front of the around the margins of the anterior sacral foramina; it is prolonged on scle into the glutæal region. At its sacral attachment it comes into

563.—A median sagittal section through the pelvis, showing the arrangement of the fasciæ. Diagrammatic.

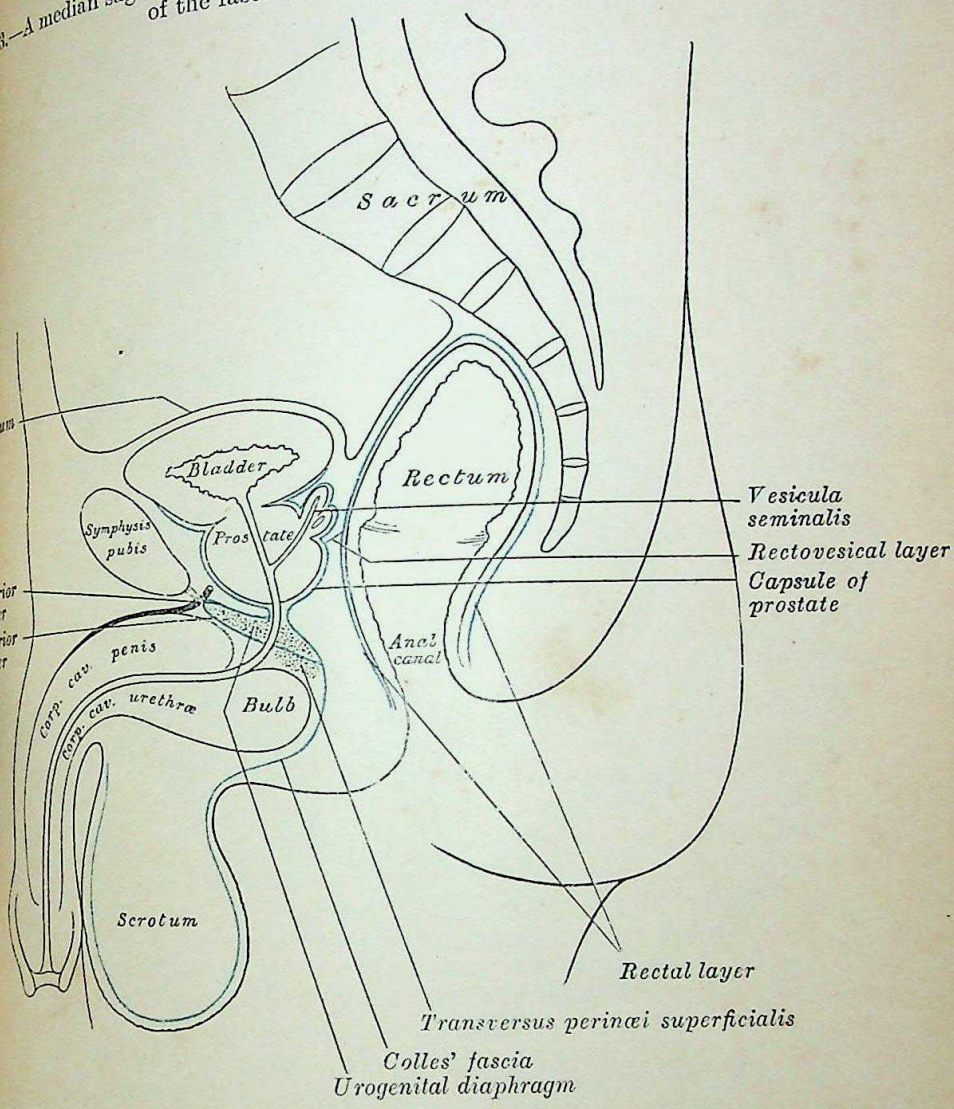

ate association with and ensheathes the nerves emerging from these mina; hence the sacral nerves are frequently described as lying behind the a. The internal iliac vessels and their branches, on the other hand, lie in subperitoneal tissue in front of the fascia, and the branches of these vessels the glutæal region emerge in special sheaths of this tissue, above and below Piriformis muscle.

The *diaphragmatic part of the pelvic fascia* (fig. 562) covers both surfaces of Levatores ani. That on the inferior surface of the muscle is very thin, and wn as the *anal fascia*; it forms the medial wall of the ischiorectal fossa, is attached above to the obturator fascia along the line of origin of the ator ani; it is continuous below with the superior fascia of the urogenital phragm, and with the fascia on the Sphincter ani externus. The layer ering the upper surface of the Levator ani follows, above, the line of origin the muscle, and is therefore somewhat variable. In front it is attached to

CC-0. In Public Domain. Gurukul Kangri Collection, Haridwar

Digitized by Arya Samaj Foundation Chennai and eGangotri

the back of the symphysis pubis about 2 cm. above its lower bor
be traced lateralwards across the back of the superior ramus of
for a distance of 1·25 cm., when it reaches the obturator fascia. T
to this fascia along a line which pursues a somewhat irregular c
spine of the ischium. The irregularity of this line is explained by t
the origin of the Levator ani, which in lower mammals is from the

FIG. 564.—The left Levator ani. Pelvic aspect.

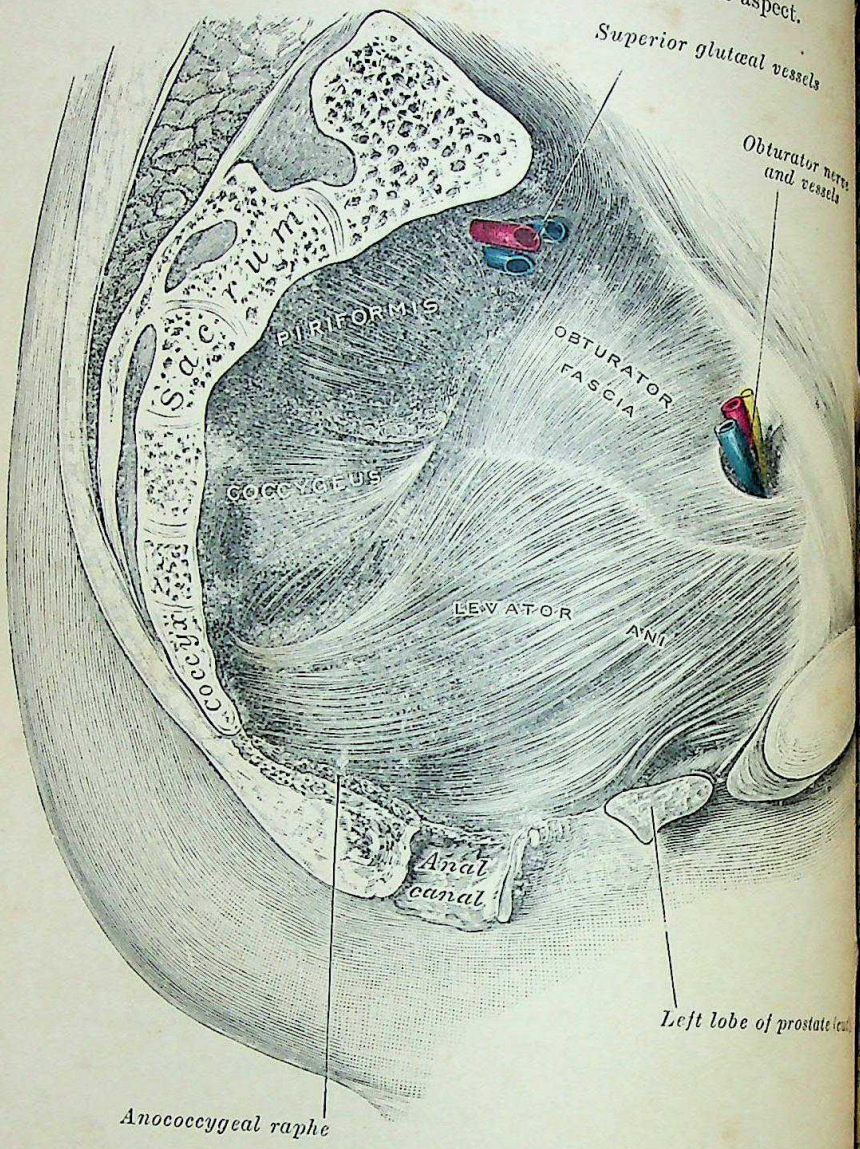

is in man lower down, on the obturator fascia, but tendinous fibres of
of the muscle are often found extending up towards, and in some cases re
the pelvic brim, and on these the fascia is carried. The lower margin
fascia covering the upper surface of the pelvic diaphragm is attached
the line of insertion of the Levator ani. The fascia covering that part
Obturator internus which lies above the origin of the Levator ani is th
a composite structure and includes, (*a*) the obturator fascia, (*b*) the fa
the Levator ani, and (*c*) the degenerated fibres of origin of the Levator a

At the level of a line extending from the lower part of the symphysis
to the spine of the ischium is a thickened whitish band in this upper la
the diaphragmatic part of the pelvic fascia. It is termed the *tendinous*
or *white line* of the pelvic fascia, and marks the line of attachment of the
true ligament of the urinary bladder. Anteriorly the fascia forms two thi
bands, the *puboprostatic ligaments*, one on either side of the middle line.

CC-0. In Public Domain. Gurukul Kangri Collection, Haridwar

Digitized by Arya Samaj Foundation Chennai and eGangotri

The **Levator ani** (fig. 564) is a broad, thin muscle; it is attached to the r surface of the side of the lesser pelvis, and unites with its fellow of the osite side to form the greater part of the floor of the pelvic cavity. It in front, from the pelvic surface of the superior ramus of the os pubis t to the symphysis; behind, from the inner surface of the spine of the ; and between these two points, from the obturator fascia. Posteriorly origin from the obturator fascia corresponds, more or less closely, with the tinous arch or white line of the pelvic fascia, but in front, the muscle arises the fascia at a varying distance above the arch, in some cases reaching ly as high as the canal for the obturator vessels and nerve. The fibres pass wards and backwards to the middle line of the floor of the pelvis; the erior fibres are inserted into the side of the last two segments of the coccyx into a median fibrous raphe (*anococcygeal raphe*), which extends between the yx and the margin of the anus. The middle fibres are inserted into the side e anal canal, blending with those of the Sphincter ani muscles; the anterior s descend upon the side of the prostate to unite beneath it with the muscle the opposite side, joining with the fibres of the Sphincter ani externus Transversus perinæi superficialis at the central tendinous point of the neum.

e anterior portion is occasionally separated from the rest of the muscle nnective tissue. From this circumstance, as well as from its peculiar on with the prostate, which it supports as in a sling, it has been described distinct muscle, under the name of *Levator prostatæ*. In the female the erior fibres of the Levator ani descend upon the side of the vagina.

e Levator ani may be divided into Iliococcygeus and Pubococcygeus.

e *Iliococcygeus* arises from the ischial spine and from the posterior part of the ten- arch of the pelvic fascia, and is attached to the coccyx and anococcygeal raphe; it lly thin, and may fail entirely or be largely replaced by fibrous tissue. An acces- lip at its posterior part is sometimes named the *Iliosacralis*. The *Pubococcygeus* from the back of the os pubis and from the anterior part of the obturator fascia, and ted backwards almost horizontally along the side of the anal canal. Between the x and the anal canal the Pubococcygei come together and form a thick, fibro- ular layer lying on the raphe formed by the Iliococcygei. The fibres which form a for the rectum are named the *Puborectalis* or *Sphincter recti*; they rise from ower part of the symphysis pubis, and from the superior fascia of the urogenital ragm; they meet with the corresponding fibres of the opposite side around the lower of the rectum, and form for it a strong sling.

Symington* suggests that the Pubococcygeus should be named *Pubo-analis*, as it is ntil if any of its fibres reach the coccyx.

Relations.—The *upper or pelvic surface* of the Levator ani is in relation with the agmatic part of the pelvic fascia which separates it from the bladder, prostate, m, and peritoneum. Its *lower or perinæal surface* forms the medial boundary of the ectal fossa, and is covered by the inferior layer of the diaphragmatic part of the fascia (*anal fascia*). Its *posterior border* is free and separated from the Coccygeus by areolar tissue. Its *anterior border* is separated from the muscle of the opposite by a triangular space, through which the urethra, and in the female the urethra and , pass from the pelvic.

Nerve-supply.—The Levator ani is supplied by a branch from the fourth sacral ve and by a branch which arises either from the perinæal, or from the inferior orrhoidal, division of the pudendal nerve.

Actions.—The Levatores ani constrict the lower end of the rectum and vagina. ther with the Coccygei they form a muscular diaphragm which supports the e viscera.

The **Coccygeus** (fig. 561) is situated behind the Levator ani. It is a trian- r plane of muscular and tendinous fibres, arising by its apex from the e of the ischium and from the sacrospinous ligament, and inserted by its s into the margin of the coccyx and into the side of the lowest piece of acrum. It assists the Levator ani and Piriformis in closing the posterior of the outlet of the pelvic.

Nerve-supply.—The Coccygeus is supplied by a branch from the fourth and sacral nerves.

Actions.—The Coccygei pull forward and support the coccyx, after it has been ed backwards during defæcation or parturition.

* *Journal of Anatomy and Physiology*, vol. xxiii.

CC-0. In Public Domain. Gurukul Kangri Collection, Haridwar

Digitized by Arya Samaj Foundation Chennai and eGangotri

Applied Anatomy.—Injury to the muscles forming the pelvic diaphragm occ infrequently during parturition. Where the damage is considerable or in cases muscles are weak the Levatores ani fail to act as efficient supports and prol uterus results; in severe cases the ovaries, bladder and rectum may also prolap

VI. The Muscles of the Perinæum

The perinæum corresponds to the outlet of the pelvis. Its deep b are—in front, the pubic arch and the arcuate pubic ligament; be tip of the coccyx; and on either side the inferior rami of the os p ischium, the ischial tuberosity, and the sacrotuberous ligament. T is somewhat lozenge-shaped and is limited on the surface of the body scrotum in front, by the buttocks behind, and by the medial sid thighs laterally. A line drawn transversely in front of the ischial tub divides the space into two portions. The posterior contains the term of the anal canal, and is known as the *anal region*; the anterior the external urogenital organs, and is termed the *urogenital region*.

The muscles of the perinæum may therefore be divided into two gr

1. Those of the anal region.
2. Those of the urogenital region: A, In the male; B, In the f

1. The Muscles of the Anal Region

Corrugator cutis ani. Sphincter ani externus. Sphincter ani int

The **superficial fascia** is very thick, areolar in texture, and contai fat in its meshes. On either side a pad of fatty tissue extends deeply b the Levator ani and Obturator internus into a space known as the is *fossa*.

The **deep fascia** forms the lining of the ischiorectal fossa; it co the anal fascia, and the portion of obturator fascia below the co Levator ani.

Ischiorectal fossa.—The fossa is somewhat prismoid in shape, with i directed to the surface of the perinæum, and its apex at the line of u of the obturator and anal fasciæ. It is bounded medially by the Sp ani externus and the anal fascia; laterally, by the tuberosity of the is and the obturator fascia; anteriorly, by the fascia of Colles coverin Transversus perinæi superficialis, and by the fascia of the urogenital diaph posteriorly, by the Glutæus maximus and the sacrotuberous ligament. Cr the space transversely are the inferior hæmorrhoidal vessels and nerve the posterior part are the perinæal and perforating cutaneous bran the pudendal plexus; while from the anterior part the posterior scro labial) vessels and nerves emerge. The internal pudendal vessels and pu nerve lie on the lateral wall of the fossa, in Alcock's canal (p. 483). Th is filled with fatty tissue, across which numerous fibrous bands extend.

Applied Anatomy.—Abscess in the ischiorectal fossa commonly occurs; it may at the side of the anus, at the border of Glutæus maximus, or against the rectal wall. is great pain on defæcation. On examining the bowel, fullness on the side of the may be detected. If left to itself the pus will find exit through the skin, or into t canal between the two Sphincters; and the condition will degenerate into one varieties of fistula, owing to the Sphincter ani externus closing the outlet of the and so causing the pus to track and burrow widely into the soft fat in the fossa, a in the subcutaneous tissues. To open an ischiorectal abscess an incision should be tangential to the anus over the region of the ischiorectal fossa, and should then verted into a T, by making a second incision laterally at right angles to it, so th wound may be kept open and may heal up from the bottom. Frequently, how spite of care, a fistula ensues which requires division of the Sphincter ani externus cure.

The **Corrugator cutis ani.**—Around the anus is a thin stratum of in tary muscular fibres which radiate from the anal orifice. Medially the fade off into the submucous tissue; laterally they blend with the tru When the muscle contracts the skin around the anus is raised into ridge

CC-0. In Public Domain. Gurukul Kangri Collection, Haridwar

Digitized by Arya Samaj Foundation Chennai and eGangotri

The **Sphincter ani externus** (figs. 565, 567) is a flat sheet of muscular elliptical in shape and intimately adherent to the skin surrounding the It measures from 8 to 10 cm. in length and is about 2·5 cm. in width site the anus. It consists of two portions, superficial and deep. The *ficial portion* constitutes the chief part of the muscle, and arises from a ow tendinous band, the *anococcygeal raphe*, which stretches from the tip he coccyx to the posterior margin of the anus; it forms two flattened s of muscular tissue, which encircle the anus and meet in front to be inserted the central tendinous point of the perinæum, joining with the Transversus ni superficialis, the Levator ani, and the Bulbocavernosus. The *deep* ion forms a complete sphincter to the anal canal. Its fibres surround canal, closely applied to the Sphincter ani internus, and in front blend the other muscles at the central point of the perinæum. In a considerable portion of cases the fibres decussate in front of the anus, and are continuous the Transversi perinæi superficiales. Posteriorly, they are not attached he coccyx, but are continuous with those of the opposite side behind the canal. The upper edge of the muscle is ill-defined, since fibres are given from it to join the Levator ani.

Nerve-supply.—The Sphincter ani externus is supplied by a branch from the sacral nerve and by twigs from the inferior hæmorrhoidal branch of the dal nerve.

Actions.—The action of the Sphincter ani externus is peculiar. 1. It is normally state of tonic contraction, and having no antagonistic muscle it keeps the anal and orifice closed. 2. It can be put into a condition of greater contraction under fluence of the will, so as more firmly to occlude the anal aperture. 3. Taking xed point at the coccyx, it helps to fix the central point of the perinæum.

The **Sphincter ani internus** is a muscular ring which surrounds about m. of the anal canal; its inferior border is in contact with, but distinct the Sphincter ani externus. It is about 5 mm. thick, and is formed by aggregation of the involuntary circular fibres of the intestine. Its lower r is about 6 mm. from the orifice of the anus.

Actions.—Its action is entirely involuntary. It helps the Sphincter ani externus clude the anal aperture.

THE MUSCLES OF THE UROGENITAL REGION IN THE MALE (fig. 565)

Transversus perinæi superficialis. Ischiocavernosus.
Bulbocavernosus. Transversus perinæi profundus.
Sphincter urethræ membranaceæ.

The **superficial fascia** of this region consists of two layers, superficial deep.

The *superficial layer* is thick, loose, areolar in texture, and contains a variable nt of fat in its meshes. In front, it is continuous with the dartos tunic he scrotum; behind, with the subcutaneous areolar tissue surrounding anus; and, on either side, with the same fascia on the medial sides of the s. In the middle line, it is adherent to the skin and to the deep layer he superficial fascia.

The *deep layer of superficial fascia* (fascia of Colles) (fig. 563) is thin, apo-tic in structure, and of considerable strength, serving to bind down the les of the root of the penis. It is continuous, in front, with the dartos the deep fascia of the penis, the fascia of the spermatic cord, and Scarpa's upon the anterior wall of the abdomen; on either side it is attached to margins of the rami of the os pubis and ischium, lateral to the crus penis as far back as the tuberosity of the ischium; posteriorly, it curves round Transversi perinæi superficiales to join the posterior margin of the inferior a of the urogenital diaphragm. In the middle line, it is connected with superficial fascia and with the median septum of the Bulbocavernosus. s posterior part this fascia sends upwards from its deep surface a median um which incompletely divides the posterior portion of the subjacent space.

The central tendinous point of the perinæum.—This is a fibrous point in middle line of the perinæum, about 1·25 cm. in front of the anus, and

CC-0. In Public Domain. Gurukul Kangri Collection, Haridwar

Digitized by Arya Samaj Foundation Chennai and eGangotri

close to the urethral bulb. Towards this point six muscles converge, are attached: viz. the Sphincter ani externus, the Bulbocavernosus, the two Transversi perinæi superficiales, and the anterior fibres of the Levatores ani.

The **Transversus perinæi superficialis** is a narrow muscular slip which passes more or less transversely across the perinæal space in front of the anus. It is often feebly developed, and is sometimes absent. It arises by a

Fig. 565.—The muscles of the male perinæum.

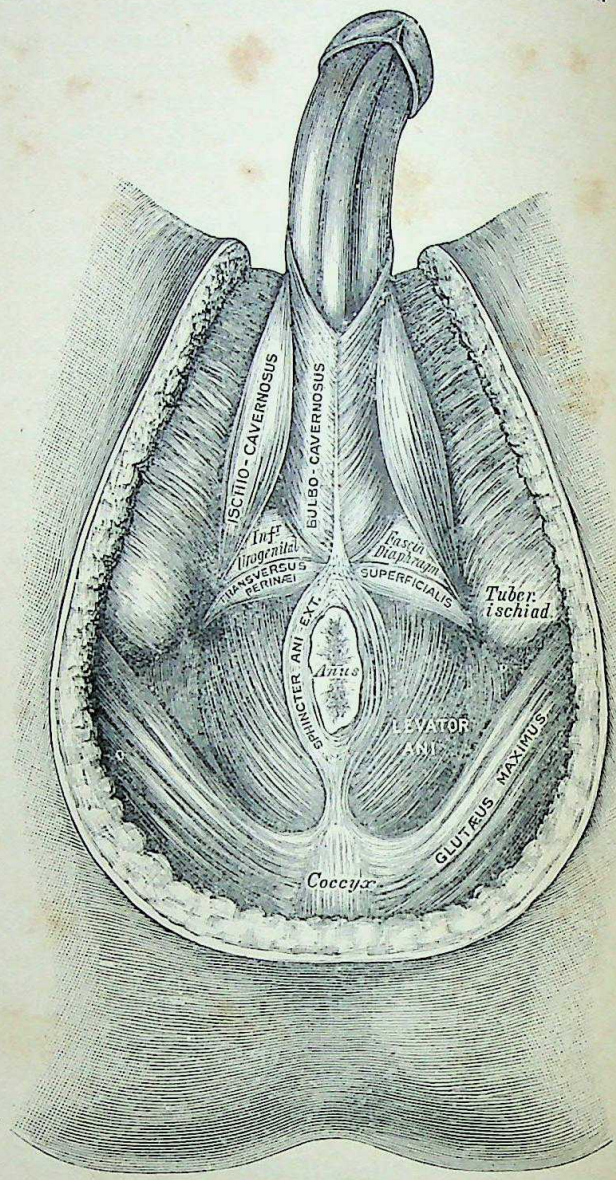

fibres from the medial and anterior part of the tuberosity of the ischium, running medialwards, is inserted into the central tendinous point of the perinæum, joining in this situation with the muscle of the opposite side, the Sphincter ani externus behind, and with the Bulbocavernosus in front. In some cases, the fibres of the deeper layer of the Sphincter ani externus decussate in front of the anus and are continued into this muscle. Occasionally it gives off fibres which join with the Bulbocavernosus of the same side.

Nerve-supply.—The Transversus perinæi superficialis is supplied by the perineal branch of the pudendal nerve.

Action.—The simultaneous contraction of the two Transversi perinæi superficiales serves to fix the central tendinous point of the perinæum.

CC-0. In Public Domain. Gurukul Kangri Collection, Haridwar

Digitized by Arya Samaj Foundation Chennai and eGangotri

The **Bulbocavernosus** (Ejaculator urinæ) is placed in the middle line of the
næum, in front of the anus, and consists of two symmetrical parts, united
a median tendinous raphe. It arises from this median raphe and the central
dinous point of the perinæum. Its fibres diverge like the barbs of a quill-
, the most posterior form a thin layer, which is lost on the inferior fascia
he urogenital diaphragm; the middle fibres encircle the bulb and adjacent
ts of the corpus cavernosum urethræ, and are inserted into a strong
neurosis on the upper part of the corpus cavernosum urethræ; the anterior
ws spread out over the side of the corpus cavernosum penis, to be inserted
ly into that body, anterior to the Ischiocavernosus, and partly into a
dinous expansion which covers the dorsal vessels of the penis.

Nerve-supply.—The Bulbocavernosus is supplied by the perinæal branch of the
endal nerve.

Actions.—The Bulbocavernosus serves to empty the canal of the urethra, after
bladder has expelled its contents; during the greater part of the act of micturition
fibres are relaxed, and they only come into action at the end of the process.
e middle fibres are supposed by Krause to assist in the erection of the corpus
vernosum urethræ, by compressing the erectile tissue of the bulb. The anterior
es, according to Tyrrel, also contribute to the erection of the penis by compressing
deep dorsal vein of the penis, as their tendinous expansion is inserted into, and
ntinuous with, the fascia of the penis.

The **Ischiocavernosus** (Erector penis) covers the crus penis. It arises
tendinous and fleshy fibres from the inner surface of the tuberosity of the
hium, behind the crus penis; and from the inferior ramus of the ischium
either side of the crus. The muscular fibres end in an aponeurosis which
serted into the sides and under surface of the crus penis.

Nerve-supply.—The Ischiocavernosus is supplied by the perinæal branch of the
endal nerve.

Action.—The Ischiocavernosus compresses the crus penis, and retards the return
the blood through the veins, and thus serves to maintain the penis erect.

Between the muscles just examined a triangular space exists, bounded medially
the Bulbocavernosus, laterally by the Ischiocavernosus, and behind by the
nsversus perinæi superficialis; the floor is formed by the inferior fascia of
urogenital diaphragm. Running from behind forwards in the space are the
erior scrotal vessels and nerves, and the perinæal branch of the posterior femoral
taneous nerve; the transverse perinæal artery courses along its posterior boundary
the Transversus perinæi superficialis.

The deep **fascia** of the urogenital region forms an investment for the
nsversus perinæi profundus and the Sphincter urethræ membranaceæ, but
hin it there are also the deep vessels and nerves of this part, the whole forming
ansverse septum which is known as the *urogenital diaphragm*. From its
pe this part of the deep fascia is sometimes termed the *triangular ligament*,
d it is stretched almost horizontally across the pubic arch, so as to close the
erior part of the pelvic outlet. It consists of two membranous laminæ
. 566), which are united at the free edges of the muscles. The stronger and
re superficial of these laminæ is named the *inferior fascia of the urogenital*
phragm (superficial layer of the triangular ligament). Its base, directed
kwards, is connected to the central tendinous point of the perinæum and is
ntinuous with the anal fascia, and, behind the Transversus perinæi super-
ialis, with the deep layer of the superficial fascia. Its lateral margins are
ached to the inferior rami of the os pubis and ischium, above the crus
nis. Its apex, directed forwards is thickened to form the *transverse ligament*
the pelvis; between this ligament and the arcuate pubic ligament the deep
rsal vein of the penis (or clitoris) enters the pelvis. It is perforated, from
to 3 cm. below the symphysis pubis, by the urethra, the aperture for which
rcular and about 6 mm. in diameter; by the arteries and nerves to the
b and the ducts of the bulbo-urethral glands close to the urethra; by
deep arteries of the penis, one on either side close to the pubic arch and
ut halfway along the attached margin of the fascia; by the dorsal arteries
d nerves of the penis near the apex of the fascia. Its base is also perforated
the posterior scrotal vessels and nerves, while between its apex and the
uate pubic ligament the deep dorsal vein of the penis passes upwards into
e pelvis.

CC-0. In Public Domain. Gurukul Kangri Collection, Haridwar

Digitized by Arya Samaj Foundation Chennai and eGangotri

If the inferior fascia of the urogenital diaphragm be detached, the fo structures will be seen between it and the superior fascia: the membr portion of the urethra, the Transversus perinæi profundus and S urethræ membranaceæ, the bulbo-urethral glands and their ducts, the vessels and dorsal nerves of the penis, the arteries and nerves of the bulb, and a plexus of veins.

FIG. 566.—A coronal section through the anterior part of the pelvis. Anterior aspect. Diagrammatic.

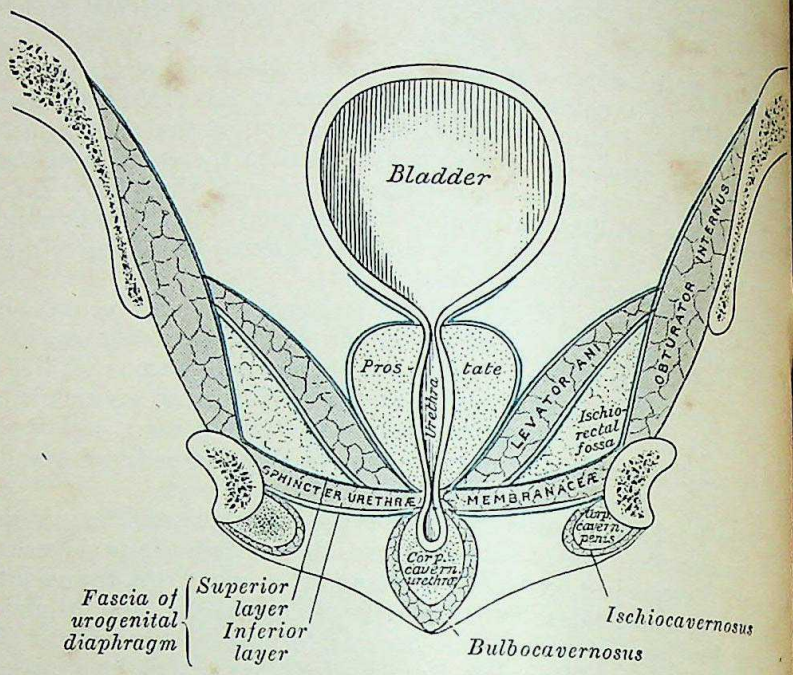

The *superior fascia of the urogenital diaphragm* (deep layer of the trian ligament) is continuous with the obturator fascia and stretches across the arch. If the obturator fascia be traced medialwards after leaving the Obtu internus muscle, it will be found attached by some of its anterior fibre the inner margin of the pubic arch, while its posterior fibres pass over attachment to become continuous with the superior fascia of the urog diaphragm. Behind, this layer of the fascia blends with the inferior of the urogenital diaphragm and with the fascia of Colles; in front it is tinuous with the fascial sheath of the prostate, and is fused with the in fascia.

The **Transversus perinæi profundus** arises from the inferior ra the ischium and runs to the median line, where it interlaces in a tend raphe with its fellow of the opposite side. It lies in the same plane as Sphincter urethræ membranaceæ; formerly the two muscles were desc together as the *Constrictor urethræ*.

Nerve-supply.—The Transversus perinæi profundus is supplied by the pe branch of the pudendal nerve.

Action.—The Transversus perinæi profundus is a tensor of the central p the perinæum.

The **Sphincter urethræ membranaceæ** surrounds the membr portion of the urethra, and is enclosed in the fascia of the urogenital phragm. Its *external* fibres arise from the junction of the inferior rami os pubis and ischium, to the extent of 1·25 or 2 cm., and from the neighb fasciæ. They arch across the front of the urethra and bulbo-urethral gl pass round the urethra, and behind it unite with the muscle of the opp side, by means of a tendinous raphe. Its *innermost* fibres form a contin circular investment for the membranous urethra.

CC-0. In Public Domain. Gurukul Kangri Collection, Haridwar

Digitized by Arya Samaj Foundation Chennai and eGangotri

Nerve-supply.—The Sphincter urethræ membranaceæ is supplied by the perinæal branch of the pudendal nerve.

Actions.—The muscles of both sides act together as a sphincter, compressing the membranous portion of the urethra. During micturition they, like the Bulbocavernosus, are relaxed, and only come into action at the end of the process to expel the last drops of urine.

The Muscles of the Urogenital Region in the Female (fig. 567)

Transversus perinæi superficialis. Ischiocavernosus.
Bulbocavernosus. Transversus perinæi profundus.
Sphincter urethræ membranaceæ.

The **Transversus perinæi superficialis** in the female is a narrow muscular which arises by a small tendon from the inner and fore part of the tuberosity of the ischium, and is inserted into the central tendinous point of the perinæum, joining in this situation with the muscle of the opposite side, the Sphincter ani externus behind, and the Bulbocavernosus in front.

Fig. 567.—The muscles of the female perinæum. (Modified from a drawing by Peter Thompson.)

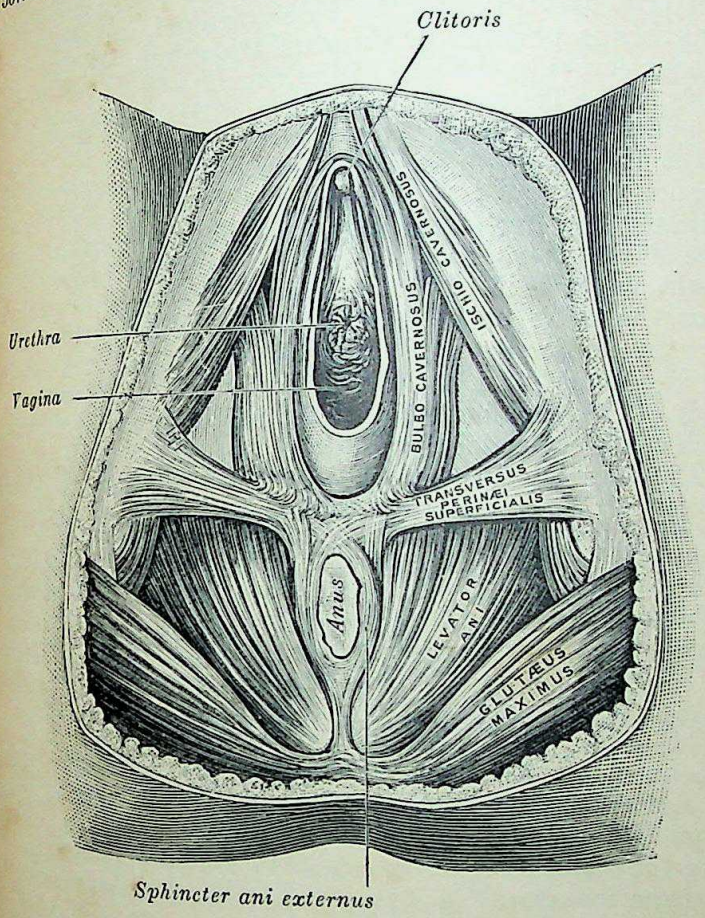

Nerve-supply.—The Transversus perinæi superficialis is supplied by the perinæal branch of the pudendal nerve.

Action.—The simultaneous contraction of the two Transversi perinæi superficiales serves to fix the central tendinous point of the perinæum.

The **Bulbocavernosus** (Sphincter vaginæ) surrounds the orifice of the vagina. It covers the lateral parts of the vestibular bulbs, and is attached posteriorly to the central tendinous point of the perinæum, where it blends with the Sphincter ani externus. Its fibres pass forwards on either side of the vagina, to be inserted into the corpora cavernosa clitoridis, a fasciculus crossing over the body of the clitoris so as to compress the deep dorsal vein.

CC-0. In Public Domain. Gurukul Kangri Collection, Haridwar

Digitized by Arya Samaj Foundation Chennai and eGangotri

Nerve-supply.—The Bulbocavernosus is supplied by the perinæal b the pudendal nerve.

Actions.—The Bulbocavernosus diminishes the orifice of the vagi anterior fibres contribute to the erection of the clitoris by the compre deep dorsal vein.

The **Ischiocavernosus** (Erector clitoridis), smaller than the corre muscle in the male, covers the unattached surface of the crus clitor arises by tendinous and fleshy fibres from the inner surface of the t of the ischium, behind the crus clitoridis; from the surface of the c from the adjacent portion of the ramus of the ischium. The muscle end in an aponeurosis which is inserted into the sides and under s the crus clitoridis.

Nerve-supply.—The Ischiocavernosus is supplied by the perinæal bra pudendal nerve.

Actions.—The Ischiocavernosus compresses the crus clitoridis and re return of blood through the veins, and thus serves to maintain the clitori

The *fascia of the urogenital diaphragm* in the female is weaker tha the male, and is divided by the aperture of the vagina, with the exter of which it blends. As in the male, it consists of two layers; betwe are the following structures: a portion of the urethra, the Transversus p profundus and Sphincter urethræ membranaceæ muscles, the greater v glands and their ducts, the internal pudendal vessels, the dorsal nerve clitoris, the arteries and nerves of the bulbi vestibuli, and a plexus of ischium and runs across to the side of the vagina.

The **Transversus perinæi profundus** arises from the inferior ram

Nerve-supply.—The Transversus perinæi profundus is supplied by the branch of the pudendal nerve.

Action.—The Transversus perinæi profundus helps to fix the central te point of the perinæum.

The **Sphincter urethræ membranaceæ**, like the corresponding m the male, consists of external and internal fibres. The *external* fibres either side from the margin of the inferior ramus of the os pubis. T directed across the pubic arch in front of the urethra, and pass rou blend with the muscular fibres of the opposite side, between the ure vagina. The *innermost* fibres encircle the lower end of the urethra.

Nerve-supply.—The Sphincter urethræ membranaceæ is supplied perinæal branch of the pudendal nerve.

Actions.—The muscles of the two sides act as a constrictor of the ure slightly of the vagina.

THE FASCIÆ AND MUSCLES OF THE UPPER EXTREMI

The muscles of the upper extremity are divisible into the following g

I. Muscles connecting the upper extremity with the vertebral column.
II. Muscles connecting the upper extremity with the anterior and thoracic walls.
III. Muscles of the shoulder.
IV. Muscles of the arm.
V. Muscles of the forearm.
VI. Muscles of the hand.

I. The Muscles connecting the Upper Extremity with the Verte Column

Trapezius.
Latissimus dorsi.
Rhomboideus major.
Rhomboideus minor.
Levator scapulæ.

The **superficial fascia** of the back forms a layer of considerable thi and strength, and contains a quantity of granular fat. It is continuou the general superficial fascia.

CC-0. In Public Domain. Gurukul Kangri Collection, Haridwar

Digitized by Arya Samaj Foundation Chennai and eGangotri

The deep fascia is a dense fibrous layer, attached above to the superior nal line of the occipital bone; in the middle line it is fixed to the ligamentum ve and supraspinal ligament, and to the spinous processes of all the vertebræ the seventh cervical; laterally, in the neck it is continuous with the colli; over the shoulder it is attached to the spine of the scapula and to acromion, and is continued downwards over the Deltoideus to the arm; on thorax it is continuous with the deep fascia of the axilla and chest, and the abdomen with that covering the abdominal muscles; below, it is attached the crest of the ilium.

The Trapezius (fig. 568) is a flat, triangular muscle, covering the back of neck and shoulder. It arises from the medial one-third of the superior nal line of the occipital bone, the external occipital protuberance, the mentum nuchæ, the spinous process of the seventh cervical, and the spinous esses of all the thoracic vertebræ, and the corresponding portion of the raspinal ligament. The superior fibres proceed downwards and lateralwards, inferior upwards and lateralwards, and the middle horizontally; the superior s are inserted into the posterior border of the lateral one-third of the cle; the middle fibres into the medial margin of the acromion and the erior lip of the posterior border of the spine of the scapula; the inferior converge and end in an aponeurosis, which glides over the smooth tri- ar surface on the medial end of the spine of the scapula, and is inserted a tubercle at the apex of this smooth triangular surface. The upper of the Trapezius is connected to the occipital bone by a thin fibrous lamina, y adherent to the skin; the middle part arises by a broad semi-elliptical neurosis, which reaches from the sixth cervical to the third thoracic vertebra; lower part arises by short tendinous fibres. The two Trapezius muscles ether resemble a trapezium, or quadrangle; two angles corresponding the shoulders; a third to the occipital protuberance; and the fourth to spinous process of the twelfth thoracic vertebra.*

The clavicular insertion of this muscle varies in extent; it sometimes hes as far as the middle of the clavicle, and occasionally blends with or rlaps the posterior edge of the Sternocleidomastoideus.

Nerve-supply.—The Trapezius is supplied by the accessory nerve and by hes from the third and fourth cervical nerves.

Actions.—The Trapezius retracts the scapula and braces back the shoulders. If head be fixed the upper fibres elevate the point of the shoulder; the middle and er fibres rotate the scapula so as to raise the point of the shoulder. When the ulder is fixed the Trapezius draws the head backwards and lateralwards.

The Latissimus dorsi (fig. 568) is a large triangular, flat muscle, which ys the lumbar region and the lower one-half of the thoracic region; but its converge to a narrow tendon of insertion. It arises by tendinous fibres the spinous processes of the lower six thoracic vertebræ in front of the rzius, and from the posterior layer of the lumbodorsal fascia (p. 457), by h it is attached to the spines of the lumbar and sacral vertebræ, to the raspinal ligament, and to the posterior part of the crest of the ilium. In ition, it arises by muscular fibres from the external lip of the crest of the m lateral to the margin of the Sacrospinalis, and from the three or four er ribs by fleshy digitations which are interposed between similar processes the Obliquus abdominis externus (fig. 550). From this extensive origin e fibres pass in different directions, the upper ones horizontally, the middle ewhat upwards, and the lower almost vertically upwards, so as to converge d form a thick fasciculus, the upper part of which crosses, and usually ives a few fibres from, the inferior angle of the scapula. The muscle ses around the lower border of the Teres major, and is twisted upon itself, that the superior fibres become at first posterior and then inferior, and the ending fibres at first anterior and then superior. It ends in a quadrilateral ion, about 7 cm. long, which passes in front of the tendon of the Teres r, and is inserted into the bottom of the intertubercular sulcus of the erus, giving an expansion to the deep fascia of the arm; its insertion ends higher on the humerus than that of the tendon of the Pectoralis major. lower border of its tendon is united with that of the Teres major, the

* The two muscles cover the back of the neck and shoulders like a monk's cowl, and therefore Trapezius is sometimes termed the *Musculus cucullaris*.

CC-0. In Public Domain. Gurukul Kangri Collection, Haridwar

Digitized by Arya Samaj Foundation Chennai and eGangotri

FIG. 568.—The muscles connecting the upper extremity with the vertebral co

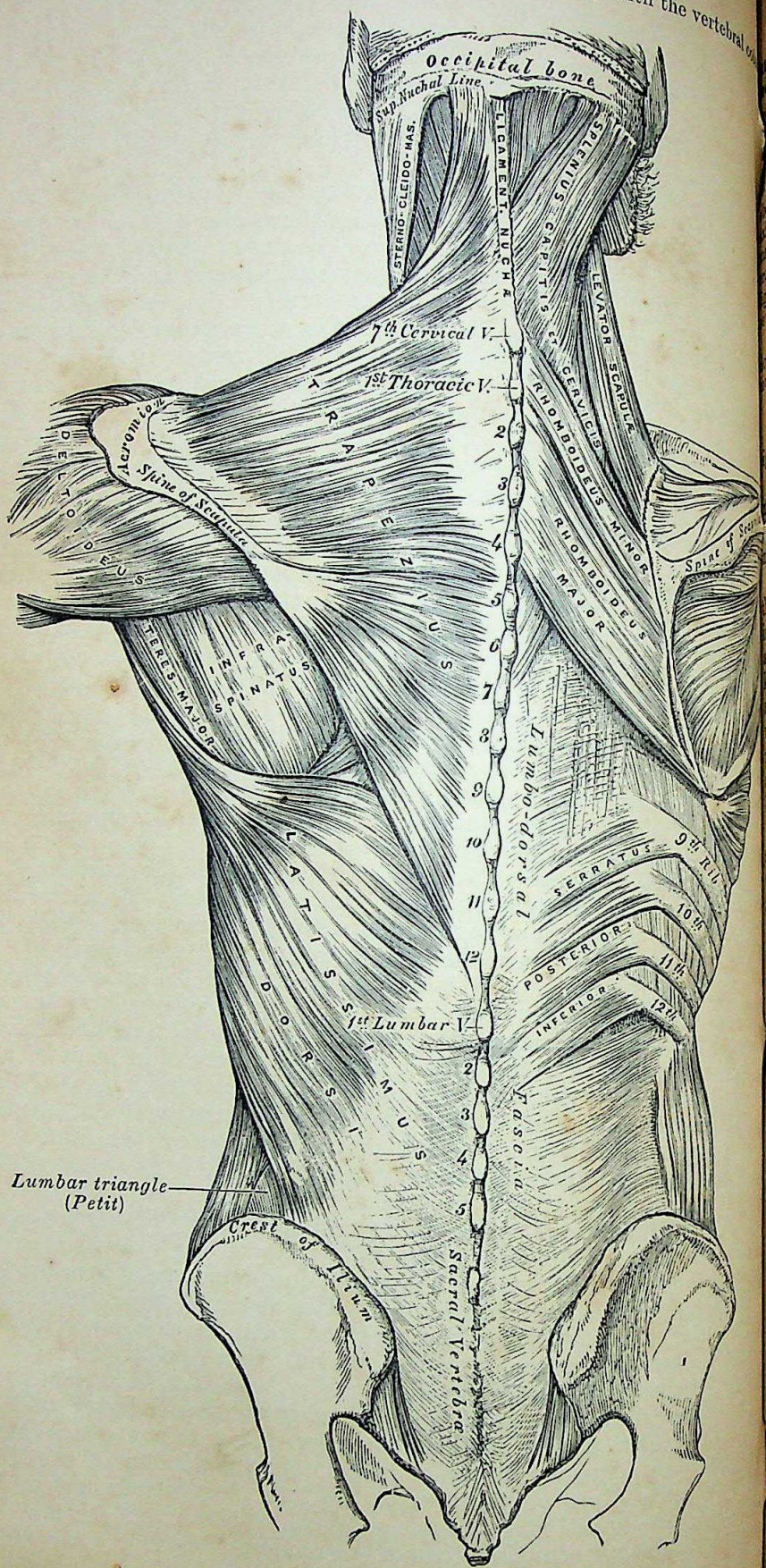

CC-0. In Public Domain. Gurukul Kangri Collection, Haridwar

Digitized by Arya Samaj Foundation Chennai and eGangotri

surfaces of the two tendons being separated near their insertions by a bursa; another bursa is sometimes interposed between the muscle and the inferior angle of the scapula.

A muscular slip, the *axillary arch*, varying from 7 to 10 cm. in length, and from 5 to 2 mm. in breadth, occasionally springs from the upper edge of the Latissimus dorsi near the middle of the posterior fold of the axilla, and crosses the axilla in front of the axillary vessels and nerves, to join the under surface of the tendon of the Pectoralis major, the Coracobrachialis, or the fascia over the Biceps brachii. This axillary arch crosses the axillary artery, just above the spot usually selected for the application of a tourniquet, and may mislead the surgeon during the operation. It is present in about seven per cent. of subjects and may be easily recognised by the direction of its fibres.

A fibrous slip usually passes from the lower border of the tendon of the Latissimus dorsi, near its insertion, to the long head of the Triceps brachii. This is occasionally muscular, and is the representative of the *Dorso-epitrochlearis brachii* of apes.

Nerve-supply.—The Latissimus dorsi is supplied by the sixth, seventh and eighth cervical nerves through the thoracodorsal (long subscapular) nerve.

Actions.—The Latissimus dorsi depresses the humerus, draws it backwards, and rotates it inwards. If the arm be fixed, the muscle may elevate the lower ribs in forced inspiration; when both arms are fixed it helps to pull the trunk upwards and forwards as in climbing.

The lower part of the lateral margin of the Latissimus dorsi is separated from the posterior free border of the Obliquus externus abdominis by a small triangular interval, the *lumbar triangle* (of Petit), the base of which is formed by the iliac crest, and its floor by the Obliquus internus abdominis (fig. 568). Another triangle, known as the *triangle of auscultation*, is situated behind the scapula. It is bounded above by the Trapezius, below by the Latissimus dorsi, and laterally by the vertebral border of the scapula; the floor is partly formed by the Rhomboideus major. If the scapula be drawn forwards by folding the arms across the chest, and the trunk bent forwards, parts of the sixth and seventh ribs and the interspace between them become subcutaneous and available for auscultation of the lung.

The **Rhomboideus major** (fig. 568) arises by tendinous fibres from the spinous processes of the second, third, fourth, and fifth thoracic vertebræ and the supraspinal ligament. The fibres of the muscle are directed downwards and lateralwards and are inserted into the vertebral border of the scapula between the triangular surface of the root of the spine and the inferior angle. Usually the insertion is an indirect one, the muscular fibres ending in a tendinous band which is fixed at its ends to the two points mentioned and joined to the vertebral border by a thin membrane; occasionally the arch is incomplete, and some of the muscular fibres are then inserted directly into the scapula.

Nerve-supply.—The Rhomboideus major is supplied by the fifth cervical through the dorsal scapular nerve.

Actions.—The Rhomboideus major retracts the scapula, and rotates it so that the inferior angle is carried backwards and upwards.

The **Rhomboideus minor** (fig. 568) arises from the lower part of the ligamentum nuchæ and from the spinous processes of the seventh cervical and first thoracic vertebræ; it is inserted into the base of the triangular smooth surface at the root of the spine of the scapula. It is usually separated from the Rhomboideus major by a slight interval, but the adjacent margins of the two muscles are occasionally united.

Nerve-supply.—The Rhomboideus minor is supplied by the fifth cervical nerve through the dorsal scapular nerve.

Action.—The Rhomboideus minor draws the scapula backwards, upwards and medialwards.

The **Levator scapulæ** (fig. 568) is situated at the back and side of the neck. It arises by tendinous slips from the transverse processes of the atlas and epistropheus and from the posterior tubercles of the transverse processes of the third and fourth cervical vertebræ. It is inserted into the vertebral border of the scapula, between the medial angle and the triangular smooth surface at the root of the spine.

Nerve-supply.—The Levator scapulæ is supplied directly by branches from the third and fourth cervical nerves, and by a branch from the fifth cervical nerve through the dorsal scapular nerve.

CC-0. In Public Domain. Gurukul Kangri Collection, Haridwar

Digitized by Arya Samaj Foundation Chennai and eGangotri

Actions.—If the cervical part of the vertebral column be fixed, the L. scapulæ raises the medial angle of the scapula; this produces a rotation of scapula by which the point of the shoulder is depressed. If the shoulder be f the muscle inclines the neck to the same side.

II. The Muscles connecting the Upper Extremity with the Anter and Lateral Thoracic Walls

Pectoralis major.	Subclavius.
Pectoralis minor.	Serratus anterior.

The **superficial fascia** of the anterior thoracic region is continuous w that of the neck and upper extremity above, and of the abdomen below encloses the mamma and gives off numerous septa which pass into the gla support its various lobes. From the fascia over the front of the mamma, fib processes pass forwards to the integument and mammary papilla; these called by Sir A. Cooper the *ligamenta suspensoria.*

The **pectoral fascia** is a thin lamina, covering the surface of the Pecto major, and sending numerous prolongations between its fasciculi; it is attach in the middle line, to the front of the sternum; above, to the clavicle; late and below, it is continuous with the fascia of the shoulder, axilla, and tho It is very thin over the upper part of the Pectoralis major, but thicker in interval between it and the Latissimus dorsi, where it closes in the axil space and forms the *axillary fascia*; this divides at the lateral margin of Latissimus dorsi into two layers, one of which passes in front of, and the o behind this muscle; these proceed as far as the spinous processes of the thor vertebræ, to which they are attached. As the fascia leaves the lower edge the Pectoralis major to cross the floor of the axilla it sends a layer upwa under cover of the muscle; this lamina splits to envelop the Pectoralis min and at the upper edge of this muscle is continuous with the coracoclavic fascia. The hollow of the armpit, seen when the arm is abducted, is produ mainly by the traction of this fascia on the axillary floor, and hence the lam is sometimes named the *suspensory ligament* of the axilla. At the lower p of the thoracic region the deep fascia is well developed, and is continuous w the fibrous sheath of the Rectus abdominis.

Applied Anatomy.—In cases of suppuration in the axilla, the pus is prevented fr extending downwards by the axillary fascia, and therefore tends to spread upwar beneath the pectoral muscles, towards the root of the neck. Early evacuation of the p is therefore necessary. The incision should be made midway between the anterior a posterior axillary folds, so as to avoid the lateral thoracic and subscapular vessels, a the edge of the knife should be directed away from the axillary vessels.

The **Pectoralis major** (fig. 569) is a thick, triangular muscle situated o the upper and front part of the chest. It arises from the anterior surface o the sternal half of the clavicle; from half the breadth of the anterior surfac of the sternum, as low down as the attachment of the cartilage of the sixth o seventh rib; from the cartilages of all the true ribs, with the exceptio frequently, of the first, or seventh, or both, and from the aponeurosis of th Obliquus externus abdominis. From this extensive origin the fibres converg towards their insertion; those arising from the clavicle pass obliquely down wards and lateralwards, and are usually separated from the rest by a sligh interval; those from the lower part of the sternum, and the cartilages of th lower true ribs, run upwards and lateralwards; while the middle fibres pas horizontally. They all end in a flat tendon, about 5 cm. broad, which is inserte into the crest of the greater tubercle of the humerus. This tendon consis of two laminæ, placed one in front of the other, and usually blended togethe below. The anterior lamina, the thicker, receives the clavicular and th uppermost sternal fibres; they are inserted in the same order as that in which they arise: that is to say, the most lateral of the clavicular fibres are inserted at the upper part of the anterior lamina, and the uppermost sternal fibre to the lower part of the lamina, which extends as low as the tendon of th Deltoideus and joins with it. The posterior lamina of the tendon receive

CC-0. In Public Domain. Gurukul Kangri Collection, Haridwar

Digitized by Arya Samaj Foundation Chennai and eGangotri

attachment of the greater part of the sternal portion and the deep fibres, those from the costal cartilages. These deep fibres, and particularly those the lower costal cartilages, turn backwards successively behind and a higher level than the superficial and upper ones, so that the tendon ars to be twisted. The posterior lamina of the tendon reaches higher the humerus than the anterior, and gives off an expansion which covers

FIG. 569.—The superficial muscles of the front of the chest and arm. Left side.

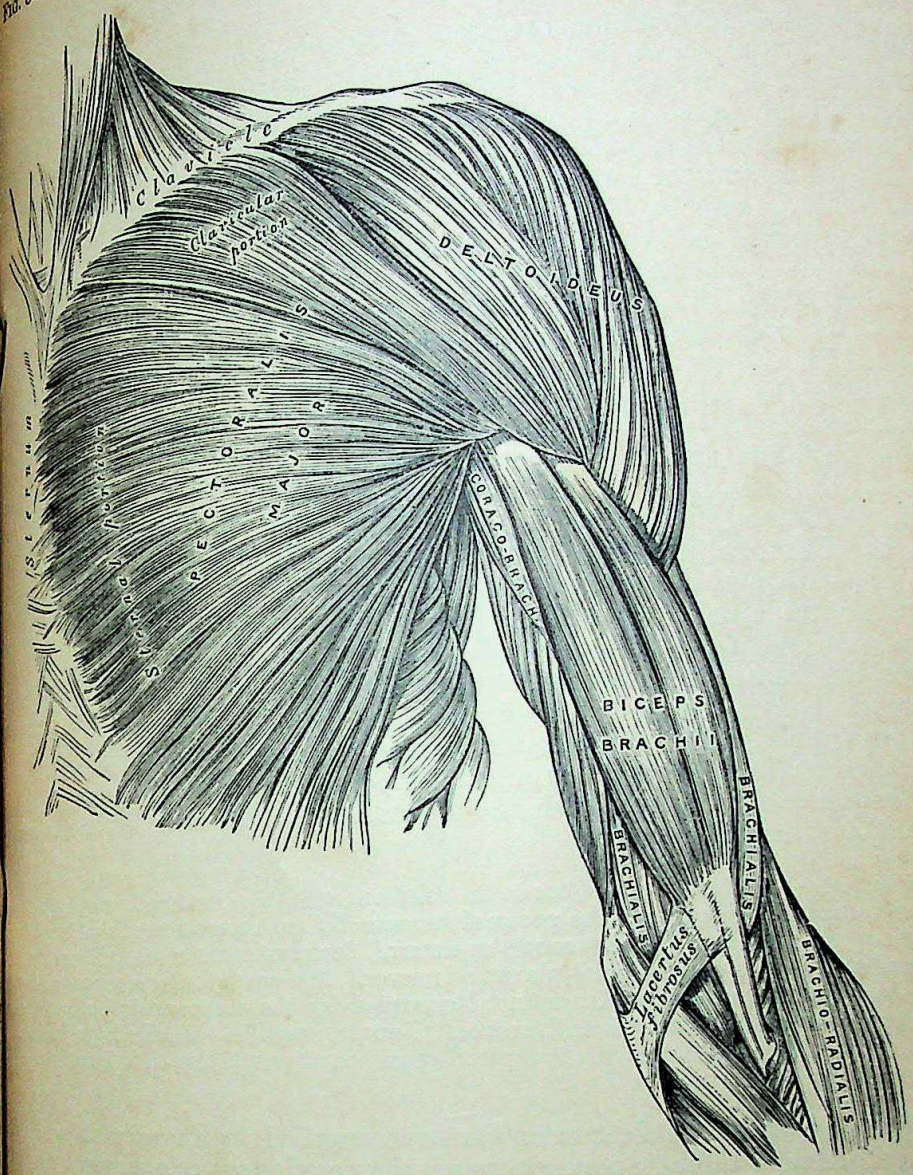

the intertubercular sulcus and blends with the capsule of the shoulder-joint. From the deepest fibres of this lamina at its insertion an expansion is given off which lines the intertubercular sulcus, while from the lower border of the tendon a third expansion passes downwards to the fascia of the arm.

Relations.—In front of the Pectoralis major are the skin, superficial fascia, Platysma, anterior and middle supraclavicular nerves, mamma, and deep fascia; its *posterior surface* is in contact with the sternum, ribs and costal cartilages, coracoclavicular fascia, subclavius, Pectoralis minor, Serratus anterior, and Intercostales; it forms the anterior wall of the axillary space, and covers the axillary vessels and nerves and the upper parts of the Biceps brachii and Coracobrachialis. Its *upper border* is separated from the deltoideus by a slight interspace—the *deltoid* or *clavicular triangle*, or *infraclavicular fossa*,

CC-0. In Public Domain. Gurukul Kangri Collection, Haridwar

Digitized by Arya Samaj Foundation Chennai and eGangotri

in which the cephalic vein and deltoid branch of the thoraco-acromial artery lie; *lower border* forms the anterior fold of the axilla; it is separated from the latissimus dorsi by a considerable interval at the medial wall of the axilla, but the two muscles gradually converge towards the lateral wall of the space.

Nerve-supply.—The Pectoralis major is supplied by the medial and lateral anterior thoracic nerves; through these it receives filaments from all the nerves entering into the formation of the brachial plexus; the fibres for the clavicular part of the muscle are derived from the fifth and sixth cervical nerves.

Actions.—The Pectoralis major adducts the arm. If the arm be flexed the muscle draws it forwards across the front of the chest and rotates it inwards. When the arms are fixed the Pectorales majores draw the trunk upwards and forwards in climbing.

The **coracoclavicular fascia** (costocoracoid membrane) is a strong fascia situated under cover of the clavicular portion of the Pectoralis major, and occupies the interval between the Pectoralis minor and Subclavius, and protects the axillary vessels and nerves. Traced upwards, it splits to enclose the Subclavius, and is attached to the clavicle, in front of and behind the muscle; the layer behind the muscle fuses with the fascia colli and with the sheath of the axillary vessels. Medially, the coracoclavicular fascia blends with the fascia covering the first two intercostal spaces, and is attached also to the first rib medial to the origin of the Subclavius. Laterally, it is thick and dense and is attached to the coracoid process. The portion extending from the first rib to the coracoid process is often stronger than the rest, and is sometimes called the *costocoracoid ligament.* Below this, the fascia is thin; it splits to ensheathe the Pectoralis minor; and from the lower border of this muscle it is continued downwards to join the axillary fascia, and lateralwards to blend with the fascia covering the short head of the Biceps brachii. The coracoclavicular fascia is pierced by the cephalic vein, thoraco-acromial artery and vein, and lateral anterior thoracic nerve.

The **Pectoralis minor** (fig. 570) is a thin, triangular muscle, situated in the upper part of the thorax, deep to the Pectoralis major. It arises from the upper margins and outer surfaces of the third, fourth, and fifth ribs, near their cartilages, and from the aponeuroses covering the Intercostales externi; its fibres pass upwards and lateralwards, and converge to form a flat tendon, which is inserted into the medial border and upper surface of the coracoid process of the scapula. Sometimes a part or the whole of the tendon is continued over the coracoid process and through the coraco-acromial ligament; when this occurs the tendon blends with the coracohumeral ligament and thus gains attachment to the humerus.

Relations.—Its *anterior surface* is in relation with the Pectoralis major, the lateral anterior thoracic nerve, and the pectoral branch of the thoraco-acromial artery; its *posterior surface*, with the ribs, Intercostales externi, Serratus anterior, the axillary space, and the axillary vessels and brachial plexus of nerves. Its *upper border* is separated from the clavicle by a narrow triangular interval occupied by the coracoclavicular fascia, behind which are the axillary vessels and nerves. Running parallel with the *lower border* of the muscle is the lateral thoracic artery; piercing and partly supplying the muscle is the medial anterior thoracic nerve.

Nerve-supply.—The Pectoralis minor is supplied by the seventh and eighth cervical and first thoracic nerves through the anterior thoracic nerves.

Actions.—The Pectoralis minor depresses the scapula and rotates it by drawing the lateral angle downwards and forwards. When the arm is fixed it assists in elevating the ribs in forced inspiration.

The **Subclavius** (fig. 570) is a small triangular muscle, placed between the clavicle and first rib. It arises by a short, thick tendon from the junction of the first rib and first costal cartilage, in front of the costoclavicular ligament; the fleshy fibres proceed obliquely upwards and lateralwards, to be inserted into the groove on the under surface of the clavicle between the costoclavicular and coracoclavicular ligaments.

Relations.—Its *posterior surface* is separated from the first rib by the subclavian vessels and brachial plexus of nerves. Its *anterior surface* is separated from the Pectoralis major by the coracoclavicular fascia, which, with the clavicle, forms an osseo-fibrous sheath for the muscle.

CC-0. In Public Domain. Gurukul Kangri Collection, Haridwar

Digitized by Arya Samaj Foundation Chennai and eGangotri

Nerve-supply.—The Subclavius is supplied by a branch which derives its fibres from the fifth and sixth cervical nerves.

Action.—The Subclavius pulls the shoulder downwards and forwards.

The **Serratus anterior** (Serratus magnus) (fig. 570) is a muscular sheet, situated between the ribs and scapula at the upper and lateral parts of the chest. It arises by fleshy slips or digitations from the outer surfaces and anterior borders of the upper eight or nine ribs, and from the aponeuroses covering the intervening Intercostales. Each digitation arises from the

FIG. 570.—The deep muscles of the front of the chest and arm. Left side.

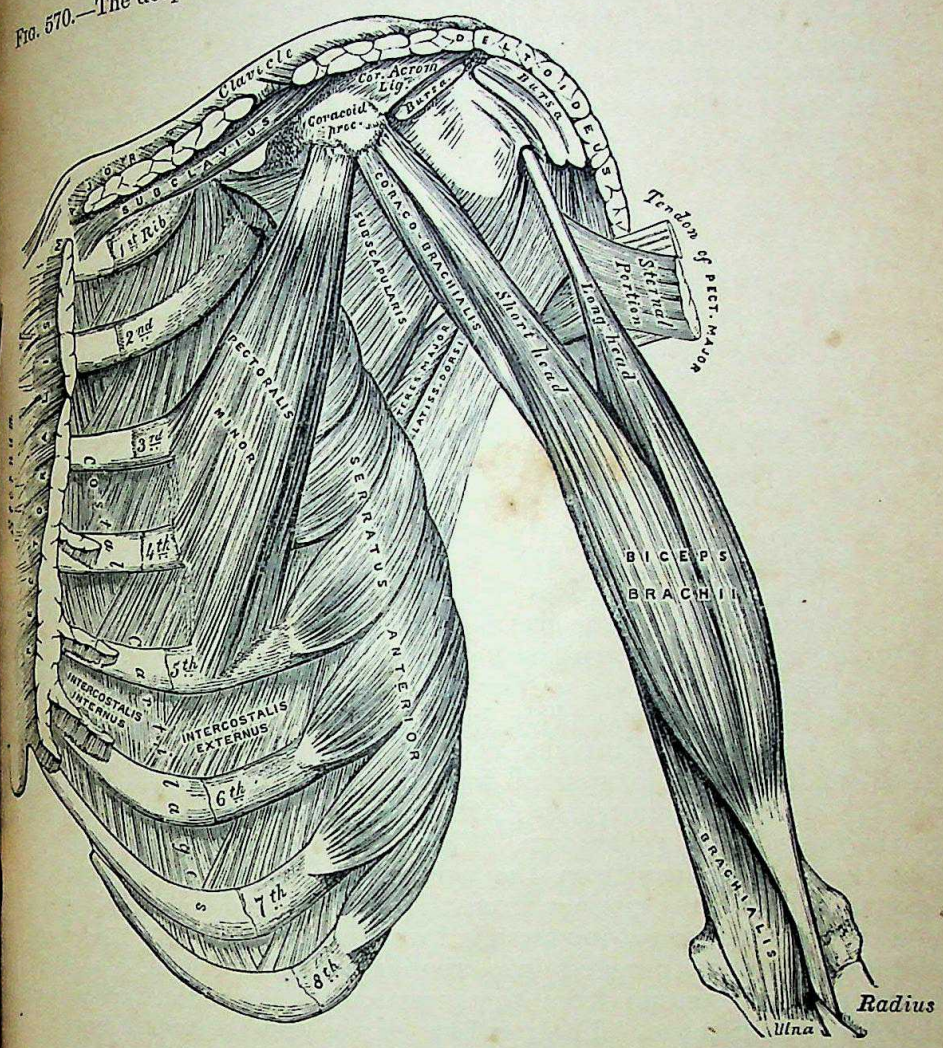

responding rib, but the first springs in addition from the second rib, and from the fascia covering the first intercostal space. The lower four slips digitate with the upper five slips of the Obliquus externus abdominis. From this extensive attachment the fibres pass backwards, closely applied to the chest-wall, and are inserted into the ventral surface of the vertebral border of the scapula in the following manner. The first digitation is inserted into a triangular area on the ventral surface of the medial (superior) angle. The next two or three digitations spread out to form a thin, triangular sheet, the base of which is directed backwards and is inserted into nearly the whole length of the ventral surface of the vertebral border. The lower five or six digitations converge to form a fan-shaped mass, the apex of which is inserted, by muscular and tendinous fibres, into a triangular impression on the ventral surface of the inferior angle.

Nerve-supply.—The Serratus anterior is supplied by the long thoracic nerve, which is derived from the fifth, sixth, and seventh cervical nerves.

CC-0. In Public Domain. Gurukul Kangri Collection, Haridwar

Digitized by Arya Samaj Foundation Chennai and eGangotri

Actions.—The Serratus anterior, as a whole, carries the scapula forwards, at the same time raises the vertebral border of the bone. Its lower and stronger fibres move the lower angle forwards and assist the Trapezius in rotating the bone on the sternoclavicular joint, and thus aid this muscle in raising the acromion. It is also an assistant to the Deltoideus in raising the arm, inasmuch as during the action of this latter muscle it fixes the scapula and so steadies the glenoid cavity on which the head of the humerus moves. After the Deltoideus has raised the arm at a right angle with the trunk, the Serratus anterior and the Trapezius, by rotating the scapula, raise the arm into an almost vertical position.

Applied Anatomy.—When the Serratus anterior is paralysed, the vertebral border, especially the lower angle of the scapula, leave the ribs and stand out prominently on the surface, giving a peculiar 'winged' appearance to the back (p. 279). The patient is unable to raise the arm, and an attempt to do so is followed by a further projection of the angle of the scapula from the back of the thorax.

The long thoracic nerve supplying the Serratus anterior is exposed in the operation for removal of cancer of the breast, and should always be carefully preserved.

III. The Muscles of the Shoulder

Deltoideus.	Infraspinatus.
Subscapularis.	Teres minor.
Supraspinatus.	Teres major.

The **deep fascia** covering the Deltoideus invests the muscle, and sends numerous septa between the fasciculi. In front, it is continuous with the pectoral fascia; behind, where it is thick and strong, with the fascia infraspinata; above, it is attached to the clavicle, the acromion, and the spine of the scapula; below, it is continuous with the brachial fascia.

The **Deltoideus** (fig. 569) is a thick, triangular muscle, which covers the shoulder-joint. It arises from the anterior border and upper surface of the lateral one-third of the clavicle; from the lateral margin and upper surface of the acromion, and from the lower lip of the posterior border of the spine of the scapula, as far back as the triangular surface at its medial end. The fibres converge towards their insertion, the middle passing vertically, the anterior inclining backwards, and the posterior forwards; they unite in a thick tendon which is inserted into the deltoid tuberosity on the lateral side of the body of the humerus. At its insertion the tendon gives off an expansion to the deep fascia of the arm. This muscle is remarkably coarse in texture, and the part arising from the acromion consists of oblique fibres; these arise in a bipennate manner from the sides of tendinous septa, generally three in number, which pass downwards from the acromion into the muscle. The oblique fibres are inserted into similar tendinous septa, generally three in number, which ascend from the insertion of the muscle and alternate with the descending septa. The portions of the muscle arising from the clavicle and spine of the scapula are not arranged in this manner, but are inserted into the margins of the inferior tendon.

Relations.—Its *superficial surface* is in relation with the skin, the superficial and deep fasciæ, Platysma, posterior supraclavicular, and lateral brachial cutaneous nerves. Its *deep surface* is separated from the articular capsule of the shoulder-joint by a large bursa and covers the coracoid process, coraco-acromial ligament, Pectoralis minor, Coracobrachialis, both heads of the Biceps brachii, the tendon of the Pectoralis major, the insertions of the Supraspinatus, Infraspinatus, and Teres minor, the long and lateral heads of the Triceps brachii, the humeral circumflex vessels, the axillary nerve, and the surgical neck and upper part of the body of the humerus. Its *anterior border* is separated in its upper part from the Pectoralis major by the deltoideopectoral triangle in which the cephalic vein and deltoid branch of the thoraco-acromial artery lie; lower down the two muscles are in contact. Its *posterior border* rests on the Infraspinatus and Teres minor, brachii.

Nerves.—The Deltoideus is supplied by the fifth and sixth cervical nerves through the axillary nerve.

CC-0. In Public Domain. Gurukul Kangri Collection, Haridwar

Digitized by Arya Samaj Foundation Chennai and eGangotri

Actions.—The Deltoideus raises the arm from the side, so as to bring it at right angles with the trunk. Its anterior fibres draw the arm forwards; and its posterior fibres draw it backwards.

Applied Anatomy.—The Deltoideus is very liable to atrophy, and in this condition the prominence of the shoulder-joint is simulated, as there is flattening of the shoulder and prominence of the acromion; the distance also between the acromion and the head of the bone is increased, and the tips of the fingers can be inserted between them.

The **subscapular fascia** is a thin membrane attached to the entire circumference of the subscapular fossa, and giving origin by its deep surface to some of the fibres of the Subscapularis.

The **Subscapularis** (fig. 570) is a large triangular muscle which fills the subscapular fossa, and arises from its medial two-thirds and from the lower two-thirds of the groove on the axillary border of the scapula. Some fibres arise from tendinous laminæ which intersect the muscle and are attached to ridges on the bone; others from an aponeurosis, which separates the muscle from the Teres major and the long head of the Triceps brachii. The fibres pass laterally, and, gradually converging, end in a tendon which is inserted into the lesser tubercle of the humerus and the front of the capsule of the shoulder-joint. The tendon of the muscle is separated from the neck of the scapula by a large bursa, which communicates with the cavity of the shoulder-joint through an aperture in the articular capsule.

Relations.—The *anterior surface* of this muscle forms a considerable part of the posterior wall of the axilla, and is in relation with the Serratus anterior, Coracobrachialis, and Biceps brachii, the axillary vessels and brachial plexus of nerves, and the subscapular vessels and nerves. Its *posterior surface* is in relation with the scapula and the capsule of the shoulder-joint. Its *lower border* is in contact with the Teres major and Latissimus dorsi.

Nerves.—The Subscapularis is supplied by the fifth and sixth cervical nerves through the upper and lower subscapular nerves.

Actions.—The Subscapularis rotates the head of the humerus inwards; when the arm is raised, it draws the humerus forwards and downwards. It is a powerful defence to the front of the shoulder-joint.

The **fascia supraspinata** completes the osseofibrous case in which the supraspinatus muscle is contained, and its deep surface gives origin to some of the fibres of the muscle. It is thick medially, but thinner laterally under the coraco-acromial ligament.

The **Supraspinatus** (fig. 571) occupies the supraspinatous fossa, arising in its medial two-thirds, and from the fascia supraspinata. The muscular fibres pass under the acromion, and converge to a tendon which crosses the upper part of the shoulder-joint and is inserted into the highest of the three impressions on the greater tubercle of the humerus; the tendon is intimately adherent to the capsule of the shoulder-joint.

Nerve-supply.—The Supraspinatus is supplied by the fifth and sixth cervical nerves through the suprascapular nerve.

Action.—The Supraspinatus abducts the arm.

The **fascia infraspinata** is a dense fibrous membrane, covering the infraspinatus muscle and fixed to the circumference of the infraspinatous fossa; its deep surface gives origin to some fibres of that muscle. It is intimately attached to the deltoid fascia along the overlapping border of the Deltoideus.

The **Infraspinatus** (fig. 571) is a thick triangular muscle, which occupies the chief part of the infraspinatous fossa; it arises by fleshy fibres from the medial two-thirds of the fossa, and by tendinous fibres from the ridges on its surface: it also arises from the fascia infraspinata which covers it and separates it from the Teretes major et minor. The fibres converge to a tendon, which passes over the lateral border of the spine of the scapula, and, passing across the posterior part of the capsule of the shoulder-joint, is inserted into the middle impression on the greater tubercle of the humerus. The tendon of this muscle is sometimes separated from the capsule of the shoulder-joint by a bursa which may communicate with the joint-cavity.

CC-0. In Public Domain. Gurukul Kangri Collection, Haridwar

Digitized by Arya Samaj Foundation Chennai and eGangotri

Nerve-supply.—The Infraspinatus is supplied by the fifth and sixth c nerves through the suprascapular nerve.

Action.—The Infraspinatus rotates the arm outwards.

The **Teres minor** (fig. 571) is a narrow, elongated muscle, which arise the dorsal surface of the axillary border of the scapula for the upper two of its extent, and from two aponeurotic laminæ, one of which separates the Infraspinatus, the other from the Teres major. Its fibres run ob upwards and lateralwards; the upper ones end in a tendon which is in into the lowest of the three impressions on the greater tubercle of the hu the lower fibres are inserted directly into the humerus immediately bel

Fig. 571.—The muscles on the dorsum of the scapula, and the Triceps brac Left side.

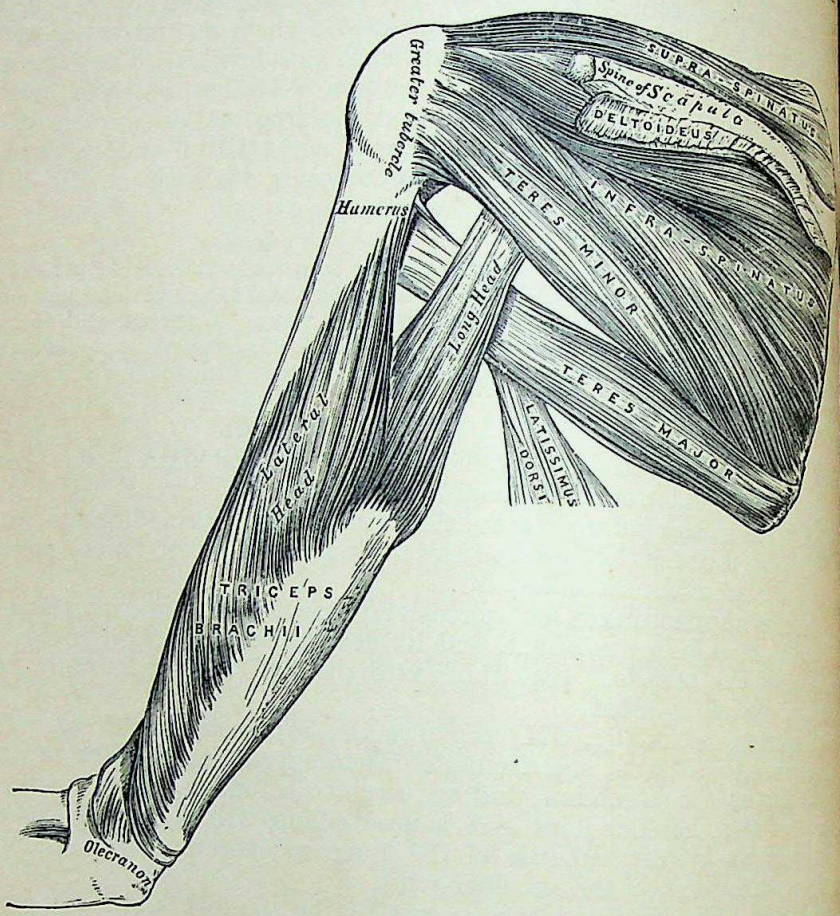

impression and just above the origin of the lateral head of the Triceps bra The tendon of this muscle passes across, and is united with, the posterior p of the capsule of the shoulder-joint.

Nerve-supply.—The Teres minor is supplied by the fifth cervical nerve thro the axillary nerve.

Action.—The Teres minor rotates the arm outwards.

The **Teres major** (fig. 571) is a thick, somewhat flattened muscle, w arises from the oval area on the dorsal surface of the inferior angle of scapula, and from the fibrous septa interposed between the muscle a the Teres minor and Infraspinatus; the fibres are directed upwards a lateralwards and end in a flat tendon, about 5 cm. long, which is inser into the crest of the lesser tubercle of the humerus. At its insertion t tendon lies behind that of the Latissimus dorsi, from which it is separ by a bursa, the two tendons being, however, united along their lower bord for a short distance.

CC-0. In Public Domain. Gurukul Kangri Collection, Haridwar

Digitized by Arya Samaj Foundation Chennai and eGangotri

erve-supply.—The Teres major is supplied by the fifth and sixth cervical nerves ugh the lower subscapular nerve

ctions.—The Teres major draws the humerus medialwards and backwards, rotates it inwards.

IV. The Muscles of the Arm

Coracobrachialis.
Biceps brachii.
Brachialis.
Triceps brachii.

The **brachial fascia** or deep fascia of the arm is continuous with that ering the Deltoideus and the Pectoralis major; it forms a thin, loose sheath the muscles of the arm, and sends septa between them; it is composed bres disposed in a circular or spiral direction, and connected together vertical and oblique fibres. It is thin over the Biceps brachii, but thicker re it covers the Triceps brachii, and over the epicondyles of the humerus: strengthened by fibrous aponeuroses, derived from the Pectoralis major Latissimus dorsi medially, and from the Deltoideus laterally. On either gives off a strong intermuscular septum, which is attached to the ponding supracondylar ridge and epicondyle of the humerus.

The *lateral intermuscular septum* extends from the lower part of the crest the greater tubercle of the humerus, along the lateral supracondylar ridge, e epicondyle; it is blended with the tendon of the Deltoideus, gives ment to the Triceps brachii behind, to the Brachialis, Brachioradialis Extensor carpi radialis longus in front, and is perforated by the radial and arteria profunda brachii. The *medial intermuscular septum*, thicker the preceding, extends from the lower part of the crest of the lesser tubercle humerus below the Teres major, along the medial supracondylar ridge e epicondyle; it is blended with the tendon of the Coracobrachialis, and attachment to the Triceps brachii behind and the Brachialis in front. perforated by the ulnar nerve, the superior ulnar collateral artery, and posterior branch of the inferior ulnar collateral artery.

the elbow, the brachial fascia is attached to the epicondyles of the rus and the olecranon of the ulna, and is continuous with the antibrachial . Just below the middle of the medial side of the arm, an oval opening e fascia transmits the basilic vein and some lymphatic vessels.

The **Coracobrachialis** (figs. 570, 572) is situated at the upper and medial of the arm. It arises from the apex of the coracoid process, in common the tendon of the short head of the Biceps brachii, and by muscular fibres the upper 10 cm. of this tendon; it is inserted into an impression at middle of the medial surface and border of the body of the humerus between origins of the Triceps brachii and Brachialis.

elations.—It is perforated by the musculocutaneous nerve, and is in relation, in with the Pectoralis major above, and at its insertion with the brachial vessels and nerve which cross it; *behind*, with the tendons of the Subscapularis, Latissimus and Teres major, the medial head of the Triceps brachii, the humerus, and the r humeral circumflex vessels; by its *medial border*, with the third part of the y artery, the upper part of the brachial artery, the median and musculocutaneous ; by its *lateral border*, with the Biceps brachii and Brachialis.

erve-supply.—The Coracobrachialis is supplied by the seventh cervical nerve gh the musculocutaneous nerve.

ction.—The Coracobrachialis draws the arm forwards and medialwards.

The **Biceps brachii** (figs. 570, 572, 573), a long fusiform muscle placed on ont of the arm, has received its name from the circumstance that it has heads of origin. The *short head* arises by a thick flattened tendon from pex of the coracoid process, in common with the Coracobrachialis. The *head* arises by a long narrow tendon from the supraglenoid tuberosity at pex of the glenoid cavity, and is continuous with the glenoidal labrum). The tendon of the long head, enclosed in a sheath of the synovial m of the articular capsule of the shoulder-joint, arches over the head of the

CC-0. In Public Domain. Gurukul Kangri Collection, Haridwar

Digitized by Arya Samaj Foundation Chennai and eGangotri

humerus; it emerges from the joint through an opening in the articular capsule close to its humeral attachment and descends in the intertubercular groove; it is retained in the sulcus by the transverse humeral ligament and by a expansion from the tendon of the Pectoralis major. Each tendon is preceded by an elongated muscular belly, and the two bellies, although applied to each other, can be readily separated until within about 7 cm. of the elbow-joint. Here they end in a flattened tendon, which is inserted into the rough posterior portion of the tuberosity of the radius, a bursa being interposed between the tendon and the front part of the tuberosity. As the tendon of the muscle approaches the radius it is twisted upon itself, so that its medial surface becomes lateral and is applied to the tuberosity of the radius in its insertion. Opposite the bend of the elbow the tendon gives off, from its medial side, a broad aponeurosis, the *lacertus fibrosus* or *bicipital fascia*, which passes obliquely downwards and medialwards across the brachial artery and is continuous with the deep fascia covering the origins of the flexor muscles of the forearm (fig. 569). With very little force the tendon of insertion may be split down to the radial tuberosity, when it can be seen that the anterior portion of the tendon receives the fibres of the short head, and the posterior portion those of the long head.

Fig. 572.—A transverse section through the arm at the junction of the proximal with the intermediate one-third of the humerus.

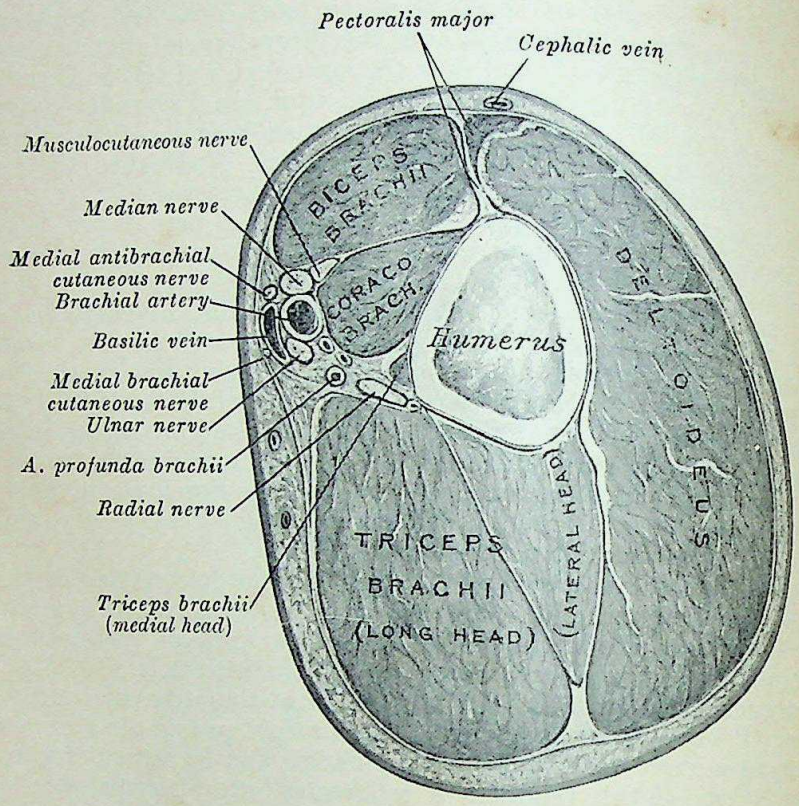

A third head to the Biceps brachii is occasionally found, arising at the upper medial part of the Brachialis, with which it is blended, and inserted into the lacertus fibrosus and medial side of the tendon of the muscle; in most cases this additional head lies behind the brachial artery. In some instances the third head consists of two slips which pass down, one in front of, the other behind the artery.

Relations.—The Biceps brachii is overlapped above by the Pectoralis major and Deltoideus; in the rest of its extent it is covered by the fasciæ and skin. Above, its long head passes through the shoulder-joint, and its short head rests on the joint and the upper part of the humerus; below, it lies on the Brachialis, the musculocutaneous nerve, and the Supinator. Its *medial border* is in relation with the Coracobrachialis, and overlaps

CC-0. In Public Domain. Gurukul Kangri Collection, Haridwar

Digitized by Arya Samaj Foundation Chennai and eGangotri

ial vessels and median nerve; its *lateral border*, with the Deltoideus and
hioradialis.

erve-supply.—The Biceps brachii is supplied by the fifth and sixth cervical
s through the musculocutaneous nerve.

ctions.—The Biceps brachii is a powerful supinator of the forearm; it also
the elbow-joint, and to a slight extent the shoulder-joint. Through the
us fibrosus it is a tensor of the antibrachial fascia.

pplied Anatomy.—The long tendon of the Biceps brachii is sometimes dislocated
the intertubercular sulcus. When this occurs, the arm is fixed in a position of
ction, but the head of the humerus can be felt in its proper position. The tendon
generally be replaced by flexing the forearm on the arm and rotating the limb.
ure of the long tendon of the Biceps brachii may also take place.

Fig. 573.—A transverse section through the arm, a little below the middle of the body of the humerus.

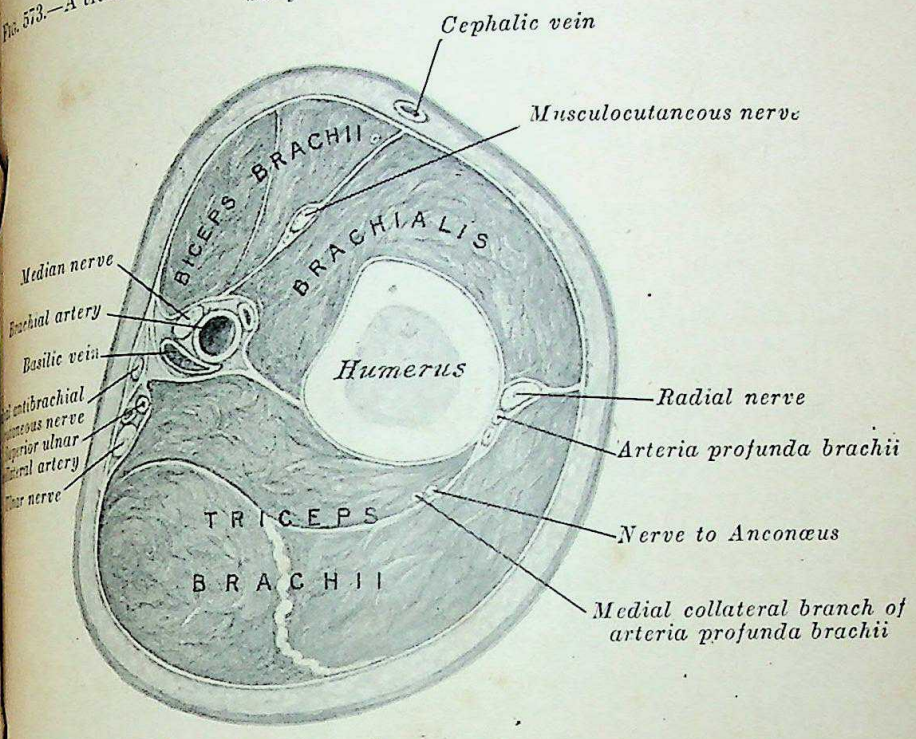

The **Brachialis** (Brachialis anticus) (figs. 570, 573, 574) covers the front
the elbow-joint and the lower one-half of the humerus. It arises from the
r one-half of the front of the humerus, commencing above at the insertion
the Deltoideus, which it embraces by two angular processes, and extending
r to within 2·5 cm. of the margin of the articular surface. It also arises
the intermuscular septa, but more extensively from the medial than the
al; it is separated from the lower part of the lateral intermuscular septum
the Brachioradialis and Extensor carpi radialis longus. Its fibres converge
thick tendon, which is inserted into the tuberosity of the ulna and the
h depression on the anterior surface of the coronoid process.

Relations.—It is in relation, in *front*, with the Biceps brachii, the brachial vessels,
ocutaneous and median nerves; *behind*, with the humerus and articular capsule
the elbow-joint; by its *medial border*, with the Pronator teres, and with the medial
muscular septum which separates it from the Triceps brachii and the ulnar nerve;
its *lateral border*, with the radial nerve, radial recurrent artery, the Brachioradialis,
Extensor carpi radialis longus.

Nerve-supply.—The Brachialis is chiefly supplied by the fifth and sixth cervical
es through the musculocutaneous nerve, but receives an additional filament
the seventh cervical through the radial nerve.

Action.—The Brachialis flexes the elbow-joint.

CC-0. In Public Domain. Gurukul Kangri Collection, Haridwar

Digitized by Arya Samaj Foundation Chennai and eGangotri

The **Triceps brachii** (figs. 571, 572, 573, 574), situated on the ba arm, is of large size, and arises by three heads (long, lateral, and medial its name.

The *long head* arises by a flattened tendon from the infraglenoid tu of the scapula, being blended at its upper part with the capsule of the joint; the muscular fibres pass downwards between the other two heads muscle, and join with them in the tendon of insertion.

The *lateral head* arises from a narrow ridge on the posterior surfa body of the humerus, extending from the insertion of the Teres minor upper part of the sulcus for the radial nerve, and from the lateral b the humerus and the lateral intermuscular septum; the fibres from th converge towards the tendon of insertion.

Fig. 574.—A transverse section through the arm, 2 cm. proximal to the med epicondyle of the humerus.

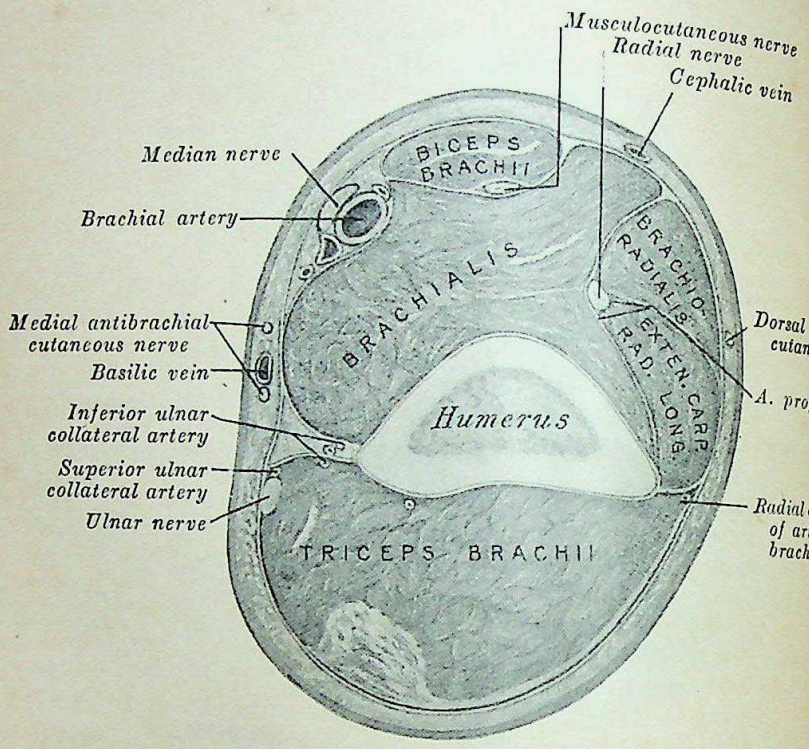

The *medial head* arises from the posterior surface of the body of the hum below the sulcus for the radial nerve; it is narrow and pointed above extends from the insertion of the Teres major to within 2·5 cm. of the tro humeri; it also arises from the medial border of the bone and from the of the whole length of the medial intermuscular septum. Some of the are directed downwards to the olecranon, while others converge to the te of insertion.

The tendon of insertion of the Triceps brachii begins about the mid the muscle. It consists of two aponeurotic laminæ, one of which cover back of the lower one-half of the muscle; the other is more deeply sea the substance of the muscle. After receiving the attachment of the mus fibres, the two lamellæ join together above the elbow, and are inserted, fo most part, into the posterior portion of the upper surface of the olecra a band of fibres is, however, continued downwards, on the lateral side the Anconæus, to blend with the antibrachial fascia.

The long head of the Triceps brachii descends between the Teres minor Teres major, dividing the triangular space between these two muscles and humerus into two smaller spaces, one triangular, the other quadrangular (fig. The triangular space contains the scapular circumflex vessels; it is bounded the Teres minor above, the Teres major below, and the scapular head of the Tr

CC-0. In Public Domain. Gurukul Kangri Collection, Haridwar

Digitized by Arya Samaj Foundation Chennai and eGangotri

lly. The quadrangular space transmits the posterior humeral circumflex
s and the axillary nerve; it is bounded by the Subscapularis, the Teres minor
the capsule of the shoulder-joint above, the Teres major below, the long head
Triceps brachii medially, and the humerus laterally.

e Subanconæus is the name given to a few fibres which spring from the deep sur-
of the lower part of the Triceps brachii, and are inserted into the posterior part of
ticular capsule of the elbow-joint.

erves.—The Triceps brachii is supplied by the sixth, seventh and eighth cervical
s through the radial nerve.*

ctions.—The Triceps brachii is the great extensor muscle of the forearm.
n the arm is extended, the long head of the muscle may assist in drawing the
ers backwards and in adducting it to the thorax. The long head supports
ulder part of the shoulder-joint. The Subanconæus draws up the posterior part
e articular capsule of the elbow-joint during extension of the forearm.

pplied Anatomy.—The insertion of the Triceps brachii into the deep fascia of the
ers is of importance in the operation of excision of the elbow, and should always
ssibly preserved. By means of it the patient is enabled to extend the forearm, a
ment which would otherwise be accomplished mainly by gravity—that is to say, by
g the forearm to drop by its own weight.

V. The Muscles of the Forearm

The **antibrachial fascia** (deep fascia of the forearm), continuous above
the brachial fascia, is a dense investment, which forms a general sheath
the muscles in this region; it is attached, behind, to the olecranon and
l border of the ulna, and sends off from its deep surface numerous inter-
ular septa. It gives origin to muscular fibres, especially at the upper part
e medial and lateral sides of the forearm, and forms the boundaries of a
s of cone-shaped cavities, in which the muscles are contained; transverse
s are given off both on the volar and dorsal surfaces of the forearm,
ating the deep from the superficial layers of muscles. It is much thicker
e dorsal than on the volar surface, and at the lower than at the upper
of the forearm, and is strengthened above by tendinous fibres derived
the Biceps brachii in front, and from the Triceps brachii behind. Over
lexor tendons as they approach the wrist it is especially thickened, and
s the volar carpal ligament. This is continuous with the transverse
l ligament, and forms a sheath for the tendon of the Palmaris longus
h passes over the transverse carpal ligament to be inserted into the palmar
onrosis. Behind, near the wrist-joint, it is thickened by the addition
any transverse fibres, and forms the dorsal carpal ligament. Apertures
in the fascia for the passage of vessels and nerves; one of these apertures,
rge size and situated at the front of the elbow, transmits a communicating
h between the superficial and deep veins.

e antibrachial or forearm muscles consist of a volar and a dorsal group.

1. The Volar Antibrachial Muscles

ese muscles are divided for convenience of description into two groups,
cial and deep.

(*a*) *Superficial Group* (fig. 575)

Pronator teres.	Palmaris longus.
Flexor carpi radialis.	Flexor carpi ulnaris.
Flexor digitorum sublimis.	

e muscles of this group take origin from the medial epicondyle of the
rus by a common tendon; they receive additional fibres from the anti-

Fitzwilliam Harris (*Journal of Anatomy*, vol. xxxviii.) is of opinion that the Triceps brachii is
y supplied by the sixth and seventh cervical nerves.

CC-0. In Public Domain. Gurukul Kangri Collection, Haridwar

Digitized by Arya Samaj Foundation Chennai and eGangotri

brachial fascia near the elbow, and from the septa which pass from the between the individual muscles.

The **Pronator teres** (figs. 575, 576) has a humeral and an ulnar origin. The *humeral head*, the larger and more superficial, arises in above the medial epicondyle, and tendon common to the origin of muscles; also from the intermuscular between it and the Flexor carpi radi from the antibrachial fascia. The *ulnar head* arises from the medial side coronoid process of the ulna, and humeral head at an acute angle. The nerve enters the forearm between the of the muscle, and is separated from artery by the ulnar head. The muscle obliquely across the forearm, and ends tendon, which is inserted into a rough sion at the middle of the lateral surface body of the radius. The lateral border muscle forms the medial boundary of a hollow, which is situated in front of the joint and contains the median nerve, artery, and tendon of the Biceps brach

Fig. 575.—The left volar antibrachial muscles. Superficial group.

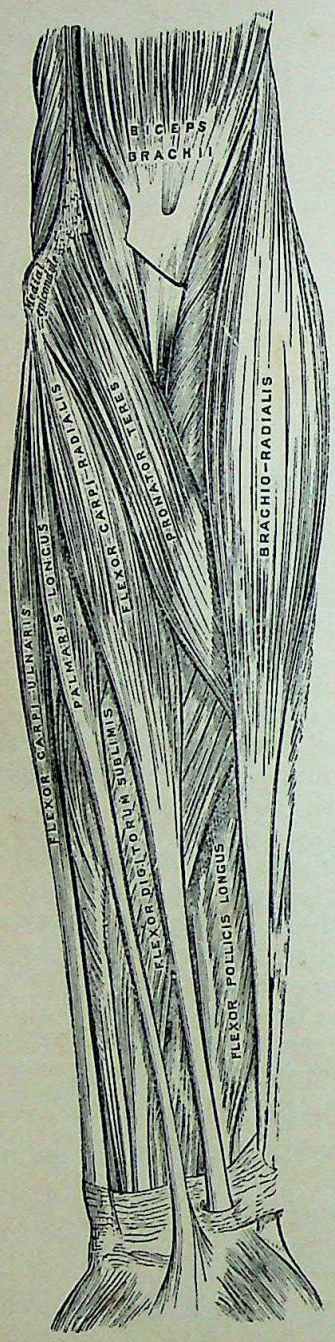

Nerve-supply.—The Pronator teres is by the sixth cervical nerve through the nerve.

Actions.—The Pronator teres rotates radius upon the ulna, turning the palm hand backwards; it also flexes the elbow.

Applied Anatomy.—This muscle, when brought into active use, as in the game of tennis, is apt to be strained, producing slight tenderness, and pain on putting the muscle action. This is known as 'lawn-tennis arm.'

The **Flexor carpi radialis** (figs. 575, 579) lies on the medial side of the Pronator teres. It arises from the medial epicondyle by the common tendon, from the antibrachial fascia, and from the intermuscular between it and the adjacent muscles. Small and aponeurotic in structure at its commencement, it increases in size, and ends in a tendon which passes through a canal in lateral part of the transverse carpal ligament and through a groove on the greater angular bone; the groove is converted canal by fibrous tissue and lined by a sheath. The tendon is inserted into the of the second metacarpal bone, and slip to the base of the third metacarpal In the lower part of the forearm the artery lies between the tendon of this and that of the Brachioradialis.

Nerve-supply.—The Flexor carpi radialis is supplied by the sixth cervical through the median nerve.

Action.—The Flexor carpi radialis flexes the wrist.

The **Palmaris longus** (figs. 575, 576, 587) is a slender, muscle, lying on the medial side of the Flexor carpi radialis. It arises the medial epicondyle of the humerus by the common tendon, from the muscular septa between it and the adjacent muscles, and from the antibrachial fascia. It ends in a long slender tendon which passes over the upper the transverse carpal ligament and is inserted into the anterior surface

CC-0. In Public Domain. Gurukul Kangri Collection, Haridwar

Digitized by Arya Samaj Foundation Chennai and eGangotri

-half of this ligament and into the central part of the palmar apo-
frequently sending a tendinous slip to the short muscles of the thumb.
the wrist, the median nerve lies deep to the tendon.
muscle is often absent, and is subject to very considerable variations: it
tendinous above and muscular below, or muscular in the middle with
above and below; it may consist of two muscular bundles with a
tendon; or may be represented solely by a tendinous band.
-supply.—The Palmaris longus is supplied by the sixth cervical nerve
the median nerve.
ions.—The Palmaris longus tightens the palmar aponeurosis and flexes
forearm.

Flexor carpi ulnaris (figs. 575, 576, 579) lies along the ulnar side
forearm. It arises by two heads, humeral and ulnar, connected by a

ig. 576.—A transverse section through the forearm at the level of the radial (bicipital) tuberosity.

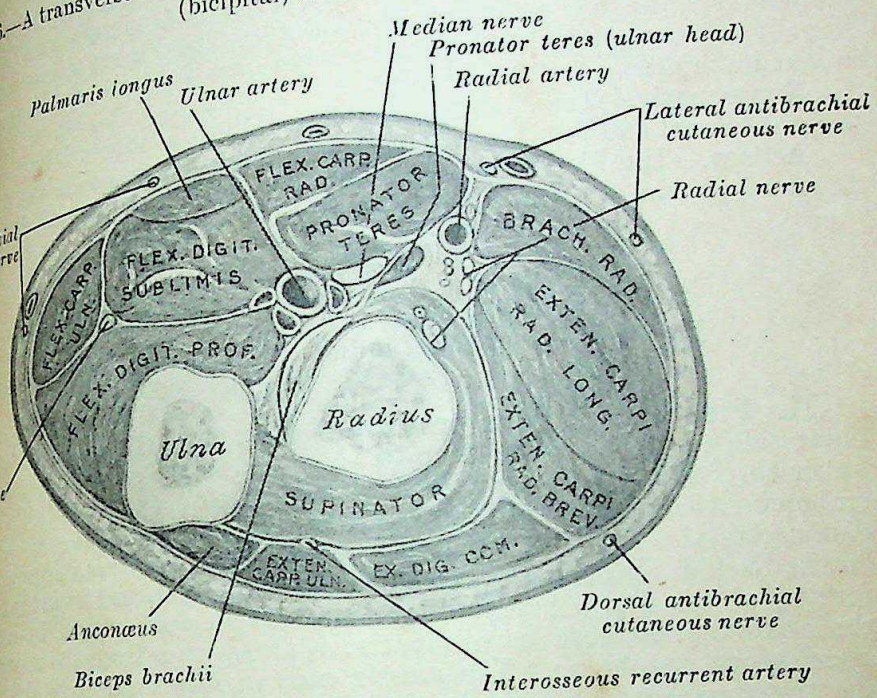

ous arch, beneath which the ulnar nerve passes downwards and the
ior ulnar recurrent artery upwards. The *humeral head* is very small
rises from the medial epicondyle of the humerus by the common tendon;
ar head arises from the medial margin of the olecranon and from the
two-thirds of the dorsal border of the ulna by an aponeurosis common
and the Extensor carpi ulnaris and Flexor digitorum profundus; and
the intermuscular septum between it and the Flexor digitorum sublimis.
ibres end in a tendon, which occupies the anterior part of the distal one-half
muscle and is inserted into the pisiform bone, whence it is prolonged to
hamate and fifth metacarpal bones by the pisohamate and pisometacarpal
ents; it is also attached by a few fibres to the transverse carpal ligament.
ulnar vessels and nerve lie on the lateral side of the tendon of insertion
muscle.
Nerve-supply.—The Flexor carpi ulnaris is supplied by the eighth cervical and
thoracic nerves through the ulnar nerve.
Actions.—The Flexor carpi ulnaris flexes the wrist and slightly adducts the

The **Flexor digitorum sublimis** (figs. 575, 576, 579) is dorsal to the
ding muscle; it is the largest of the muscles of the superficial group, and
by two heads, humero-ulnar and radial. The *humero-ulnar head* arises
the medial epicondyle of the humerus by the common tendon, from the
collateral ligament of the elbow-joint, from the intermuscular septa

CC-0. In Public Domain. Gurukul Kangri Collection, Haridwar

Digitized by Arya Samaj Foundation Chennai and eGangotri

between it and the preceding muscles, and from the medial side of the process, above the ulnar origin of the Pronator teres. The radial head, sheet of muscle, arises from the oblique line of the radius, extending radial tuberosity to the insertion of the Pronator teres. The muscle separates into two planes of muscular fibres, superficial and deep; the plane divides into two parts which end in tendons for the middle fingers; the deep plane gives off a muscular slip to join that part of ficial plane which is associated with the tendon of the ring finger divides into two parts, which end in tendons for the index and little As the four tendons pass beneath the transverse carpal ligament palm of the hand, they are arranged in pairs, the superficial pair the middle and ring fingers, the deep pair to the index and little fingers tendons diverge from one another in the palm and form deep relations superficial volar arch and digital branches of the median and ulnar Opposite the bases of the first phalanges each tendon divides into to allow of the passage of the corresponding tendon of the Flexor profundus; the two slips then reunite, partially decussate, and form channel for the reception of the tendon of the Flexor digitorum Finally the tendon divides and is inserted into the sides of the second about its middle.

Nerve-supply.—The Flexor digitorum sublimis is supplied by the eighth cervical and first thoracic nerves through the median nerve.

Actions.—The Flexor digitorum sublimis flexes first the middle and proximal phalanges. It also acts as a flexor of the wrist.

(*b*) *Deep Group* (fig. 577)

Flexor digitorum profundus. Flexor pollicis longus.
Pronator quadratus.

The **Flexor digitorum profundus** (figs. 576, 577, 579) is situated ulnar side of the forearm, deep to the superficial flexors. It arises from upper three-fourths of the volar and medial surfaces of the body of the embracing the insertion of the Brachialis above, and extending to within distance of the Pronator quadratus below. It also arises from a deep on the medial side of the coronoid process of the ulna, and from the upper fourths of the dorsal border of the bone by an aponeurosis, in common the Flexor and Extensor carpi ulnaris; it also springs from the ulnar half interosseous membrane. The muscle ends in four tendons which run the transverse carpal ligament, dorsal to the tendons of the Flexor digitorum sublimis. The portion of the muscle for the index finger is usually distinct throughout, but the tendons for the middle, ring, and little fingers are nected together by areolar tissue and tendinous slips, as far as the palm hand. Opposite the first phalanges the tendons pass through the openings the tendons of the Flexor digitorum sublimis, and are inserted into the of the last phalanges.

Nerve-supply.—The Flexor digitorum profundus is supplied by the cervical and first thoracic nerves through the ulnar nerve and the volar interosseous branch of the median nerve.

Actions.—The Flexor digitorum profundus flexes the terminal phalanges the Flexor digitorum sublimis has bent the middle phalanges; it also assists flexing the wrist.

Four small muscles, the Lumbricales, are connected with the tendons the Flexor digitorum profundus in the palm. They will be described with muscles of the hand (p. 526).

Fibrous sheaths of the flexor tendons.—After leaving the the tendons of the Flexores digitorum sublimis et profundus lie in aponeurotic canals (fig. 589, p. 525), formed behind by the phalanges, front by fibrous bands which arch across the tendons, and are attached either side to the margins of the phalanges and to the volar accessory ligaments of the interphalangeal joints. Opposite the middle of the proximal and phalanges the bands (*digital vaginal ligaments*) are very strong, and the are transverse; but opposite the joints they are much thinner, and

CC-0. In Public Domain. Gurukul Kangri Collection, Haridwar

Digitized By Arya Samaj Foundation Chennai and eGangotri

annular and *cruciate* fibres. ch canal is lined by a mucous ath, which is reflected on the ained tendons.

s the flexor tendons approach r insertions they are con- ed to the dorsal parts of the losing sheaths by triangular l thread-like bands of the ous sheaths. These bands, ed *vincula tendinum* (fig. 578), very minute vessels to the dons, and are of two kinds, vincula brevia and (*b*) vincula

The *vincula brevia*, two in ber in each finger, are tri- ular bands attached to the deep ces of the tendons close to insertions; one connects the n of the Flexor digitorum nis to the front of the first rphalangeal joint and adjacent of the first phalanx, and the the tendon of the Flexor orum profundus to the front the second interphalangeal joint adjacent part of the second nx. The *vincula longa* are d-like slips, of which two are ly attached to each tendon of Flexor digitorum sublimis, and to each tendon of the Flexor orum profundus. Those of Flexor digitorum sublimis are ed to the slips of that n where these fold over the n of the Flexor digitorum ndus, and, passing one on side of the latter tendon, ached to the sheath at the l margins of the proximal of the first phalanx. That of ndon of the Flexor digitorum ndus is fixed to its tendon y after the latter has pierced ndon of the Flexor digitorum . It runs upwards and rds, perforates one of the ps of the latter tendon, or between the two slips; er it blends with the vin- breve of the Flexor digi- sublimis, and is attached sheath at the distal end of phalanx.

The **Flexor pollicis longus** 577, 579) is situated on the side of the forearm in the plane as the Flexor digi- profundus. It arises from oved volar surface of the of the radius, extending

Fig. 577.—The left volar antibrachial muscles. Deep group.

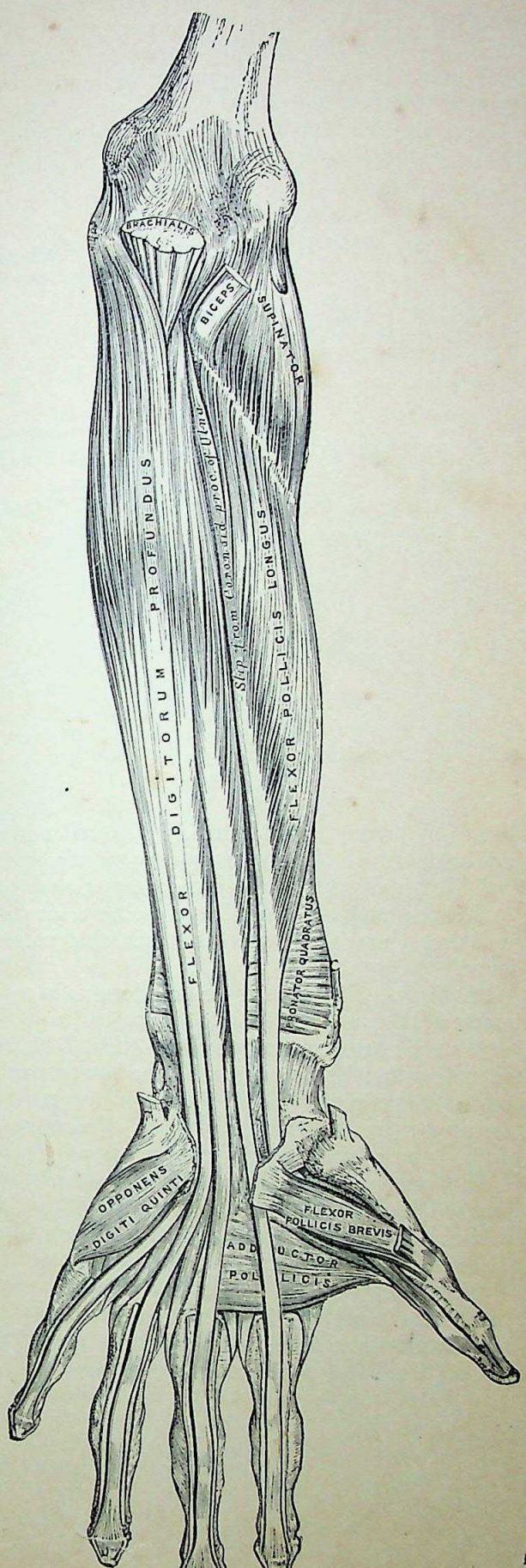

CC-0. In Public Domain. Gurukul Kangri Collection, Haridwar

Digitized by Arya Samaj Foundation Chennai and eGangotri

from immediately below the tuberosity and oblique line, to within a distance of the Pronator quadratus. It arises also from the adjacent part of interosseous membrane, and generally by a fusiform fleshy slip from the border of the coronoid process below the Flexor digitorum sublimis and p teres, or from the medial epicondyle of the humerus. The fibres e flattened tendon, which passes behind the transverse carpal ligament lodged between the lateral head of the Flexor pollicis brevis and the part of the Adductor pollicis, and, entering an osseo-aponeurotic canal to those for the flexor tendons of the fingers, is inserted into the ba

FIG. 578.—The tendons and the vincula tendinum of the right forefinger. Lateral aspect.

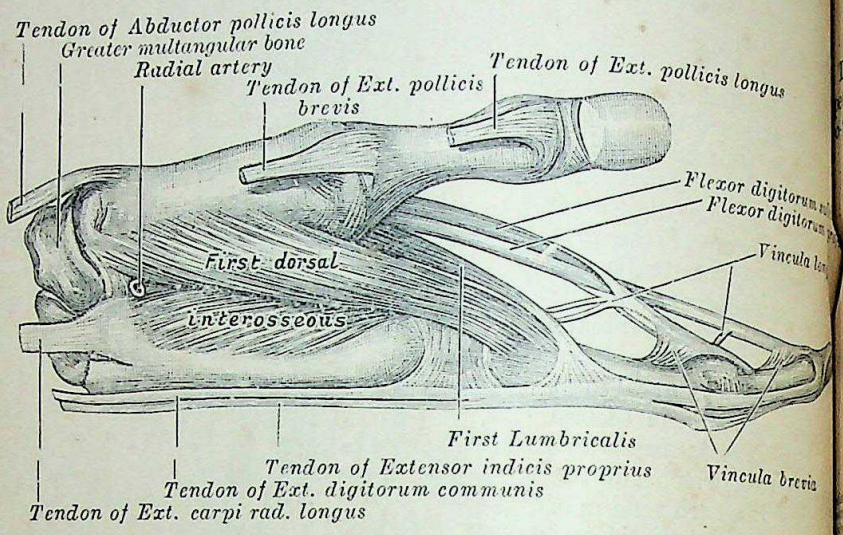

distal phalanx of the thumb. The volar interosseous nerve and vessels on the front of the interosseous membrane between the Flexor pollicis and Flexor digitorum profundus.

Nerve-supply.—The Flexor pollicis longus is supplied by the eighth and first thoracic nerves through the volar interosseous branch of the nerve.

Actions.—The Flexor pollicis longus is a flexor of the phalanges of the it also acts as a flexor of the wrist.

The **Pronator quadratus** (figs. 577, 583) is a flat, quadrilateral extending across the front of the lower parts of the radius and ulna. It from the pronator ridge on the lower part of the volar surface of the the ulna; from the medial part of the volar surface of the lower one of the ulna; and from a strong aponeurosis which covers the medial of the muscle. The fibres pass lateralwards and slightly downwards inserted into the lower one-fourth of the lateral border and the volar of the body of the radius; the deeper fibres are inserted into the area above the ulnar notch of the radius.

Nerve-supply.—The Pronator quadratus is supplied by the eighth first thoracic nerves through the volar interosseous branch of the median

Action.—The Pronator quadratus pronates the forearm, i.e. turns it so palm of the hand is directed backwards.

CC-0. In Public Domain. Gurukul Kangri Collection, Haridwar

Digitized by Arya Samaj Foundation Chennai and eGangotri

2. The Dorsal Antibrachial Muscles

These muscles are divided for convenience of description into two groups, superficial and deep.

(a) *Superficial Group* (fig. 580)

Brachioradialis.
Extensor carpi radialis longus.
Extensor carpi radialis brevis.
Anconæus.
Extensor digitorum communis.
Extensor digiti quinti proprius.
Extensor carpi ulnaris.

The **Brachioradialis** (Supinator longus) (figs. 575, 576, 580) is the most superficial muscle on the radial side of the forearm. It arises from the upper two-thirds of the lateral supracondylar ridge of the humerus, and from the

Fig. 579.—A transverse section through the middle of the forearm.

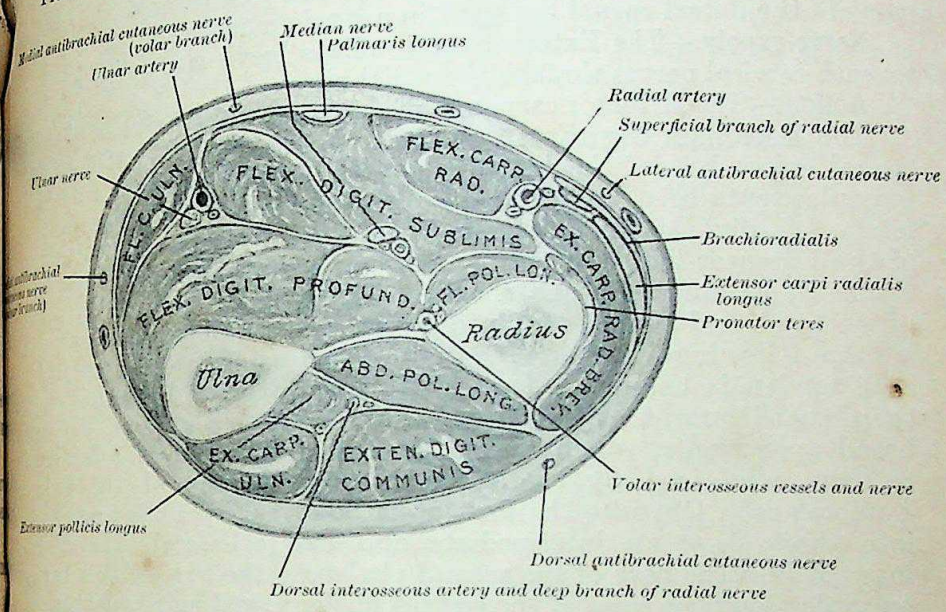

intermuscular septum. Interposed between it and the Brachialis are the nerve and the anastomosis between the arteria profunda brachii and radial recurrent artery. The fibres end above the middle of the forearm in a tendon which is inserted into the lateral side of the base of the styloid process of the radius. The tendon is crossed at its insertion by the tendons of the Abductor pollicis longus and Extensor pollicis brevis; on its ulnar side is the radial artery.

Nerve-supply.—The Brachioradialis is supplied by the fifth and sixth cervical nerves through the radial nerve.

Action.—The Brachioradialis is a flexor of the elbow-joint, but is supplied by a nerve of the extensor muscles, i.e. the radial nerve.

The **Extensor carpi radialis longus** (figs. 576, 580) is partly covered by the Brachioradialis. It arises mainly from the lower one-third of the lateral supracondylar ridge of the humerus and from the lateral intermuscular septum, but it receives a few fibres from the common tendon of origin of the extensor muscles of the forearm. The muscle ends at the upper one-third of the forearm in a flat tendon, which runs along the lateral border of the radius, passes to the Abductor pollicis longus and Extensor pollicis brevis; it then passes under cover of the dorsal carpal ligament, where it lies on the back of

CC-0. In Public Domain. Gurukul Kangri Collection, Haridwar

Digitized by Arya Samaj Foundation Chennai and eGangotri

the radius in a groove immediately behind the styloid process. It is
into the radial side of the dorsal surface of the base of the second me
bone.

Nerve-supply.—The Extensor carpi radialis longus is supplied by the
seventh cervical nerves through the deep radial nerve.

Actions.—The Extensor carpi radialis longus extends the wrist and
abducts the hand.

The **Extensor carpi radialis brevis** (figs. 576, 579, 580) is sho
the preceding muscle and is covered by it. It arises from the lateral
of the humerus, by a tendon common to it and the next three muscle
the radial collateral ligament of the elbow-joint; from a strong apo
which covers its surface; and from the intermuscular septa betwee
the adjacent muscles. The fibres end about the middle of the fore
flat tendon, which closely accompanies that of the preceding muscle
wrist; it passes beneath the Abductor pollicis longus and Extensor
brevis, then under cover of the dorsal carpal ligament, and is
into the dorsal surface of the base of the third metacarpal bone on its
side and distal to the styloid process. Under the dorsal carpal ligam
tendon lies on the back of the radius in a shallow groove, on the ulna
of that which lodges the tendon of the Extensor carpi radialis long
separated from it by a faint ridge.

The tendons of the two preceding muscles pass through the same co
ment of the dorsal carpal ligament in a single mucous sheath.

Nerve-supply.—The Extensor carpi radialis brevis is supplied by the
seventh cervical nerves through the radial nerve.

Action.—The Extensor carpi radialis brevis extends the wrist.

The **Extensor digitorum communis** (figs. 576, 579, 580) arises fr
lateral epicondyle of the humerus, by the common tendon; from the
muscular septa between it and the adjacent muscles, and from the anti
fascia. It divides below into four tendons, which pass, together wi
of the Extensor indicis proprius, through a compartment of the dorsal
ligament, within a mucous sheath. The tendons then diverge on the
of the hand, and are inserted into the second and third phalanges of the
in the following manner. Opposite the metacarpophalangeal arti
each tendon is bound by fasciculi to the collateral ligaments and se
the dorsal ligament of this joint; after crossing the joint, it spreads
broad aponeurosis, which covers the dorsal surface of the first phala
is there reinforced by the corresponding tendons of the Interosse
Lumbricalis. Opposite the first interphalangeal joint this aponeurosis
into three slips, an intermediate and two collateral: the interme
inserted into the base of the second phalanx; the two collateral are co
onwards along the sides of the second phalanx, and uniting by their co
margins, are inserted into the dorsal surface of the ungual phalanx.
tendons cross the interphalangeal joints, they serve as dorsal ligaments
tendon to the index finger is accompanied by the Extensor indicis pr
which lies on its ulnar side. On the back of the hand, the tendons
middle, ring, and little fingers are connected by two obliquely placed
one from the third tendon passing distalwards and lateralwards
second tendon, and the other passing from the fourth tendon to the
Occasionally the second tendon is connected to the first by a thin
band.

Nerve-supply.—The Extensor digitorum communis is supplied by the
cervical nerve through the deep radial nerve.

Actions.—The Extensor digitorum communis extends the phalanges
the wrist. Owing to its attachments to the collateral ligaments of the meta
phalangeal joints it acts principally on the proximal phalanges, the midd
terminal phalanges being extended mainly by the Interossei and Lumbrica
tends to separate the fingers as it extends them.

The **Extensor digiti quinti proprius** (fig. 580) is a slender muscle
to, and usually connected with, the Extensor digitorum communis. It
from the common extensor tendon by a thin tendinous slip, and fro
intermuscular septa between it and the adjacent muscles. Its tendon
through a compartment of the dorsal carpal ligament behind the

CC-0. In Public Domain. Gurukul Kangri Collection, Haridwar

Digitized by Arya Samaj Foundation Chennai and eGangotri

-ulnar joint, then divides
wo as it crosses the hand,
ually joins the expansion
Extensor digitorum com-
tendon on the dorsum of
first phalanx of the fifth

erve-supply.—The Extensor
quinti proprius is supplied by
seventh cervical nerve through
deep radial nerve.

ctions.—The Extensor digiti
ti proprius extends the little
and by its continued action
ds the wrist.

The **Extensor carpi ulnaris**
370, 580) arises from the
epicondyle of the humerus,
common extensor tendon;
the dorsal border of the ulna
aponeurosis in common with
Flexor carpi ulnaris and the
digitorum profundus; and
the antibrachial fascia. It
in a tendon, which runs in
ove between the head and
styloid process of the ulna,
through a separate com-
ment of the dorsal carpal
ment, and is inserted into
tubercle on the ulnar side of
se of the fifth metacarpal

erve-supply.—The Extensor
ulnaris is supplied by the
cervical nerve through the
adial nerve.

ctions.—The Extensor carpi
extends the wrist and
s the hand.

The **Anconæus** (figs. 580, 581)
small triangular muscle on
ck of the elbow-joint, and
rs to be a continuation of
iceps brachii. It arises by a
tendon from the posterior
of the lateral epicondyle of
umerus; its fibres diverge
are inserted into the side of
ecranon, and upper one-
of the dorsal surface of the
of the ulna.

erve-supply.—The Anconæus
plied by the seventh and
cervical nerves through the
nerve.

ction.—The Anconæus assists
iceps in extending the elbow-

FIG. 580.—The left dorsal antibrachial muscles. Superficial group.

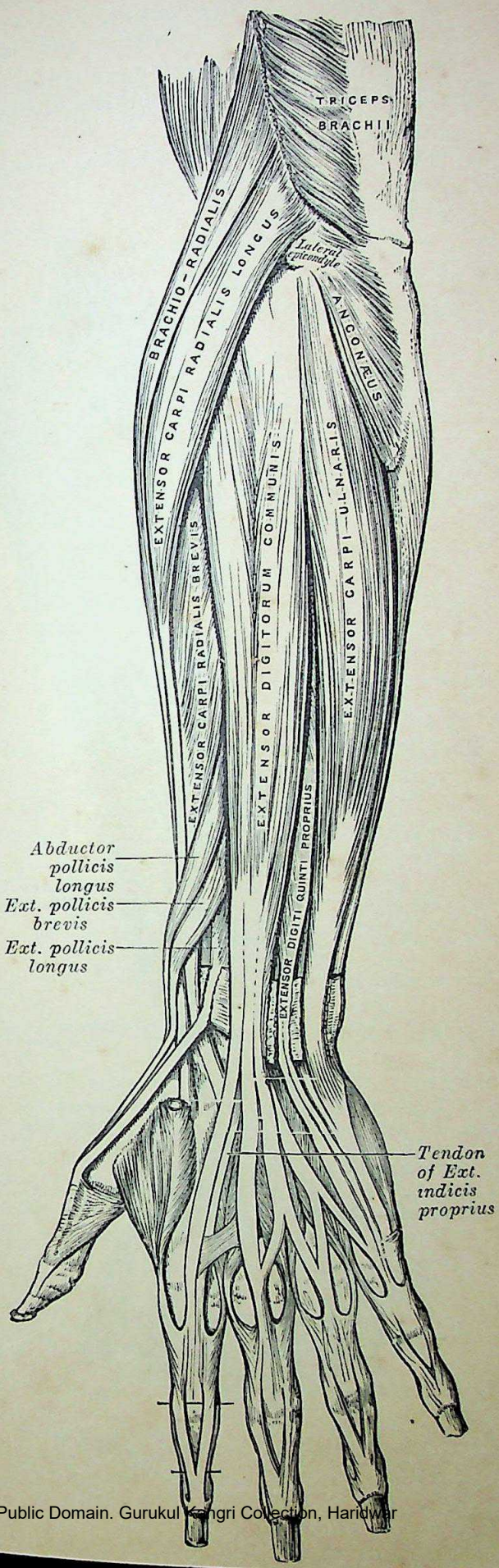

CC-0. In Public Domain. Gurukul Kangri Collection, Haridwar

Digitized by Arya Samaj Foundation Chennai and eGangotri

(*b*) *Deep Group* (fig. 581)

Supinator.
Abductor pollicis longus.
Extensor pollicis brevis.
Extensor pollicis longus.
Extensor indicis proprius.

The **Supinator** (Supinator brevis) (figs. 576, 581, 582) curves round one-third of the radius. It consists of fibres arranged in two planes which the deep bra radial nerve passes. planes arise in com superficial one by t and the deeper by t fibres—from the lat condyle of the humer the radial collateral l of the elbow-joint, annular ligament of t mal radio-ulnar joint the ridge on the ulna runs obliquely do from the dorsal en radial notch; from t part of the triangula sion below the notch from a tendinous ex which covers the s the muscle. The sup fibres surround the up of the radius, and are into the lateral edge radial tuberosity an oblique line of the ra low down as the inser the Pronator teres. Th fibres of the deeper pla a sling-like fasciculus encircles the neck of the above the tuberosity attached to the back its medial surface: the part of this portion muscle is inserted in dorsal and lateral surf the body of the radius, be the oblique line and the of the bone.

Fig. 581.—The left dorsal antibrachial muscles. Deep group.

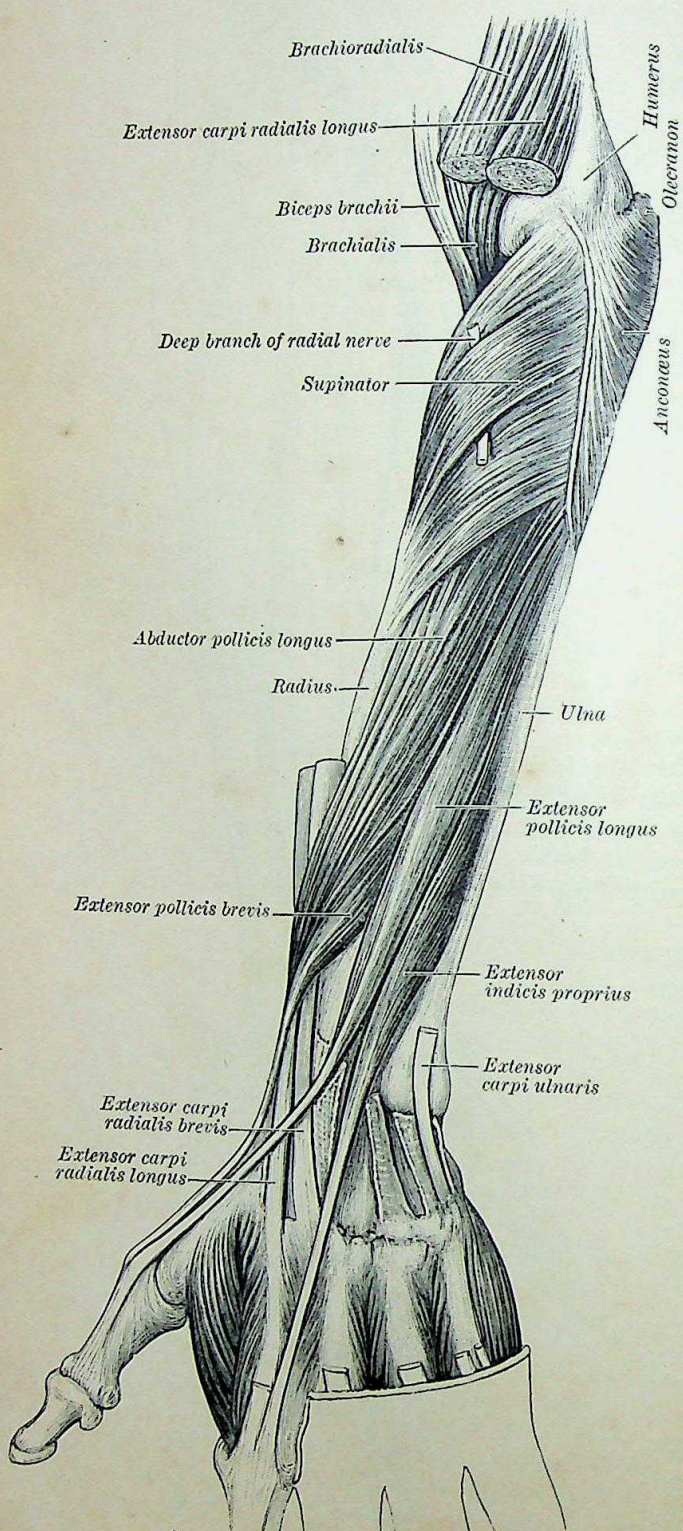

Nerve-supply.—The ator is supplied by the sixth cervical nerves the deep radial nerve.

Actions. — The Su rotates the radius so as t the palm of the hand f

The **Abductor p longus** (Extensor ossis carpi pollicis) (figs. 57 581) lies immediately the Supinator and is times united with it. It from the lateral part o dorsal surface of the b the ulna below the inse of the Anconæus, fro

CC-0. In Public Domain. Gurukul Kangri Collection, Haridwar

Digitized by Arya Samaj Foundation Chennai and eGangotri

osseous membrane, and from the middle one-third of the dorsal surface of body of the radius. Passing obliquely downwards and lateralwards, it ends tendon (frequently two tendons), which runs through a groove on the side of the lower end of the radius, accompanied by the tendon of the or pollicis brevis, and is inserted into the radial side of the base of st metacarpal bone. It occasionally gives off two slips near its insertion: o the greater multangular and the other to blend the origin of the Abductor is brevis.

Fig. 582.—The right Supinator. Dorsolateral aspect.

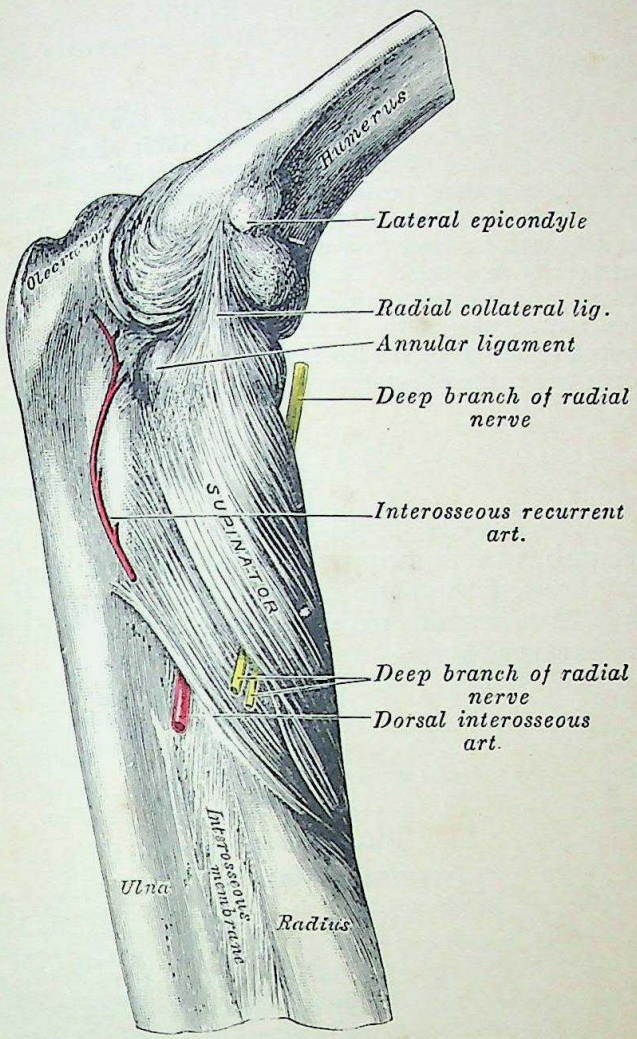

erve-supply.—The Abductor is longus is supplied by the h cervical nerve through eep radial nerve.

ctions.—The Abductor pol- ongus abducts the thumb hand. In the absence h paralysis of the two s of the wrist-joint the may flex the hand on st with some considerable F. Wood Jones).*

The **Extensor pollicis** is (figs. 580, 581) lies on radial side of, and is closely ated with, the Abductor is longus. It arises from orsal surface of the body radius below that muscle, from the interosseous mem- Its direction is similar of the Abductor pollicis its tendon passing h the same groove on teral side of the lower the radius, to be inserted the dorsal surface of the the first phalanx of the

erve-supply.—The Extensor brevis is supplied by the h cervical nerve through eep radial nerve.

ctions.—The Extensor pol- brevis extends the proximal phalanx of the thumb; by its continued action it the wrist, and abducts the hand.

The **Extensor pollicis longus** (figs. 580, 581) is larger than the preceding the origin of which it partly covers. It arises from the lateral part of dle one-third of the dorsal surface of the body of the ulna below the of the Abductor pollicis longus, and from the interosseous membrane. in a tendon, which passes through a compartment of the dorsal carpal ent, lying in a narrow, oblique groove on the back of the lower end of the It then crosses obliquely the tendons of the Extensores carpi radiales et brevis, and is separated from the Extensor brevis pollicis by a ular interval, in which the radial artery is found; it is inserted into the the last phalanx of the thumb. The radial artery is crossed by the s of the Abductor pollicis longus and of the Extensores pollicis longus is.

erve-supply.—The Extensor pollicis longus is supplied by the seventh cervical through the deep radial nerve.

ctions.—The Extensor pollicis longus extends the terminal phalanx of the by its continued action it extends the wrist, and abducts the hand.

* 'The principles of Anatomy as seen in the hand,' 1920.

CC-0. In Public Domain. Gurukul Kangri Collection, Haridwar

Digitized by Arya Samaj Foundation Chennai and eGangotri

The **Extensor indicis proprius** (fig. 581) is a narrow, elongated medial to, and parallel with, the preceding. It arises from the dorsal of the body of the ulna below the origin of the Extensor pollicis longus from the interosseous membrane. Its tendon passes under cover of the carpal ligament in the compartment which transmits the tendons of Extensor digitorum communis; opposite the head of the second metacarpal bone it joins the ulnar side of the tendon of the Extensor digitorum communis which runs to the index finger.

Nerve-supply.—The Extensor indicis proprius is supplied by the seventh nerve through the deep radial nerve.

Actions.—The Extensor indicis proprius extends the index finger, and also extending the wrist.

Applied Anatomy.—The tendons of the Abductor longus and extensors of the are liable to become strained, and their sheaths inflamed (*tenosynovitis*) after exercise, producing a sausage-shaped swelling along the course of the tendons and a peculiar grating sensation to the touch when the muscles are put in action.

Paralysis of the extensor muscles of the wrists and fingers resulting in 'wrist is common in lead poisoning in painters. The different extensor muscles are unequally as a rule. Thus the thumb, or index, or little finger may be but slightly cated, and recover rapidly while the extensors of the other fingers or wrist remain less; and some of the flexor muscles of the fingers may become paretic. This selective action of the lead in cases of lead poisoning depends in reality upon over use of the affected muscles or groups of muscles.

VI. The Muscles of the Hand

The muscles of the hand are subdivided into three groups: 1, those thumb, which occupy the radial side and produce the *thenar* eminence; 2, those of the little finger, which occupy the ulnar side and give rise *hypothenar* eminence; 3, those in the middle of the palm and between metacarpal bones.

Fig. 583.—A transverse section through the distal ends of the left radius and ulna. Superior aspect.

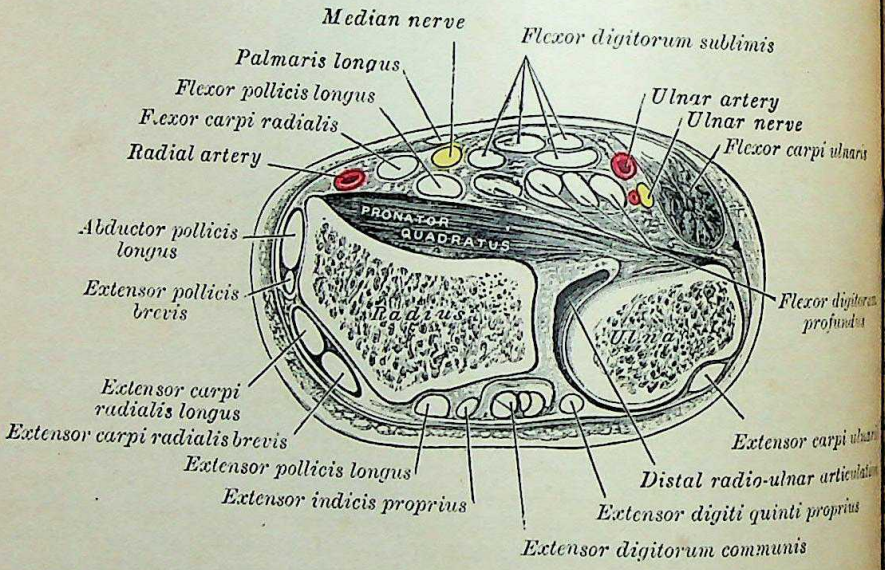

The **volar carpal ligament** is the thickened band of antibrachial which extends from the radius to the ulna in front of the flexor tendons they approach the wrist.

The **transverse carpal ligament** (anterior annular ligament) (figs. 584, is a strong, fibrous band, which crosses the front of the carpus, and converts the concavity formed by the volar surfaces of the carpal bones into a through which the flexor tendons of the digits and the median nerve It is attached, medially, to the pisiform bone and to the hamulus of the hamate bone; laterally, it splits into two laminæ, a superficial attached to the tubercle

CC-0. In Public Domain. Gurukul Kangri Collection, Haridwar

Digitized by Arya Samaj Foundation Chennai and eGangotri

the navicular and greater multangular bones, and a deep to the posterior lip the groove on the latter bone; the two laminæ form with the groove on the greater multangular bone a tunnel which is traversed by a mucous sheath containing the tendon of the Flexor carpi radialis. The ligament is continuous, above, with the volar carpal ligament; and below, with the palmar aponeurosis. It is crossed superficially by the ulnar vessels and nerve, and the cutaneous branches of the median and ulnar nerves. On its volar surface the tendons of the Palmaris longus and Flexor carpi ulnaris are partly inserted; below, it gives origin to the short muscles of the thumb and little finger.

The mucous sheaths of the tendons on the front of the wrist.—Two mucous sheaths envelop the flexor tendons as they traverse the carpal tunnel, one for the Flexores digitorum sublimis et profundus, the other for the Flexor pollicis longus (fig. 585). These sheaths extend into the forearm for about 4 cm. above the transverse carpal ligament, and occasionally communicate with each other behind the ligament. The sheath of the Flexores digitorum

Fig. 584.—A transverse section through the left wrist. Superior aspect.

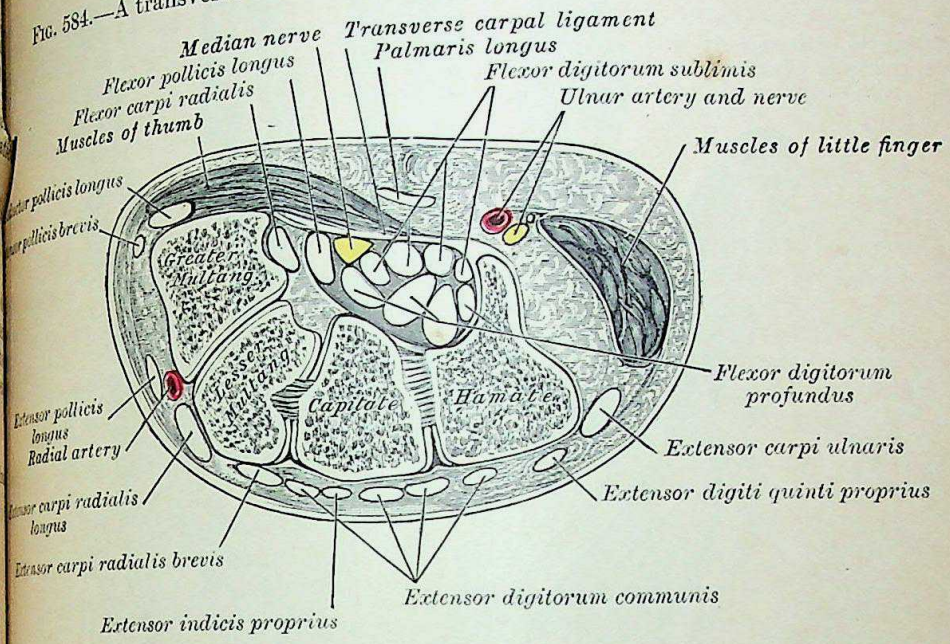

ulum reaches about halfway along the metacarpal bones, where it ends in and diverticula around the tendons to the index, middle, and ring fingers. is prolonged on the tendons to the little finger and usually communicates with the digital mucous sheath of these tendons. The sheath of the tendon the Flexor pollicis longus is continued along the thumb as far as the insertion the tendon. The mucous sheaths enveloping the terminal parts of the tendons of the Flexores digitorum have been described (p. 510).

The **dorsal carpal ligament** (posterior annular ligament) (fig. 586) is a long, fibrous band, extending obliquely across the back of the wrist, and consisting of part of the antibrachial fascia, strengthened by the addition of some transverse fibres. It is attached, medially, to the styloid process of the ulna and to the triquetral and pisiform bones; laterally, to the lateral margin of the radius; and, in its passage across the wrist, to the ridges on the dorsal surface of the radius.

The mucous sheaths of the tendons on the back of the wrist.—Beneath the dorsal carpal ligament there are six compartments for the passage of the extensor tendons, each compartment containing a mucous sheath. This is found in each of the following positions (fig. 586): (1) on the lateral side of the styloid process, for the tendons of the Abductor pollicis longus and Extensor pollicis brevis; (2) behind the styloid process, for the tendons of the Extensores carpi radiales longus et brevis; (3) about the middle of the dorsal surface of the radius, for the tendon of the Extensor pollicis longus; (4) to the medial side of the latter, for the tendons of the Extensor digitorum

CC-0. In Public Domain. Gurukul Kangri Collection, Haridwar

Digitized by Arya Samaj Foundation Chennai and eGangotri

communis and Extensor indicis proprius; (5) opposite the interval the radius and ulna, for the Extensor digiti quinti proprius; (6) betw head and the styloid process of the ulna, for the tendon of the Extens ulnaris. The sheaths of the tendons of the Abductor pollicis longus, E

FIG. 585.—The mucous sheaths of the tendons on the front of the left wrist and (From a specimen prepared by J. C. B. Grant.)

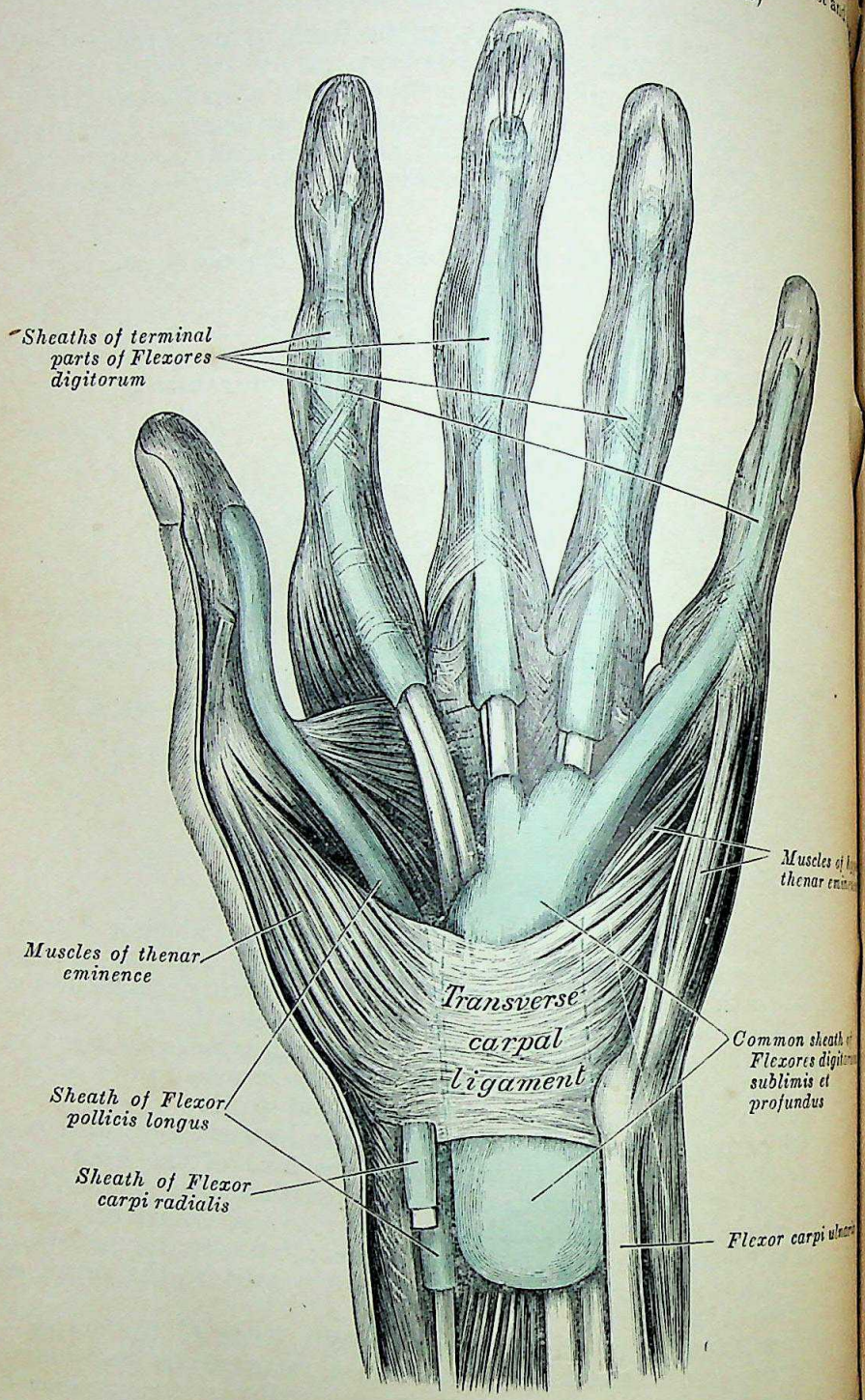

pollicis brevis, Extensores carpi radialis, and Extensor carpi ulnaris s immediately proximal to the bases of the metacarpal bones, while these the Extensor digitorum communis, Extensor indicis proprius, and Exte digiti quinti proprius are prolonged to the junction of the proximal with intermediate one-third of the metacarpus.

CC-0. In Public Domain. Gurukul Kangri Collection, Haridwar

Digitized by Arya Samaj Foundation Chennai and eGangotri

The palmar aponeurosis (fig. 587) invests the muscles of the palm, and consists of central, lateral, and medial portions.

The central portion occupies the middle of the palm, is triangular in shape, and of great strength and thickness. Its apex is continuous with the distal

FIG. 586.—The mucous sheaths of the tendons on the back of the left wrist. (From a specimen prepared by J. C. B. Grant.)

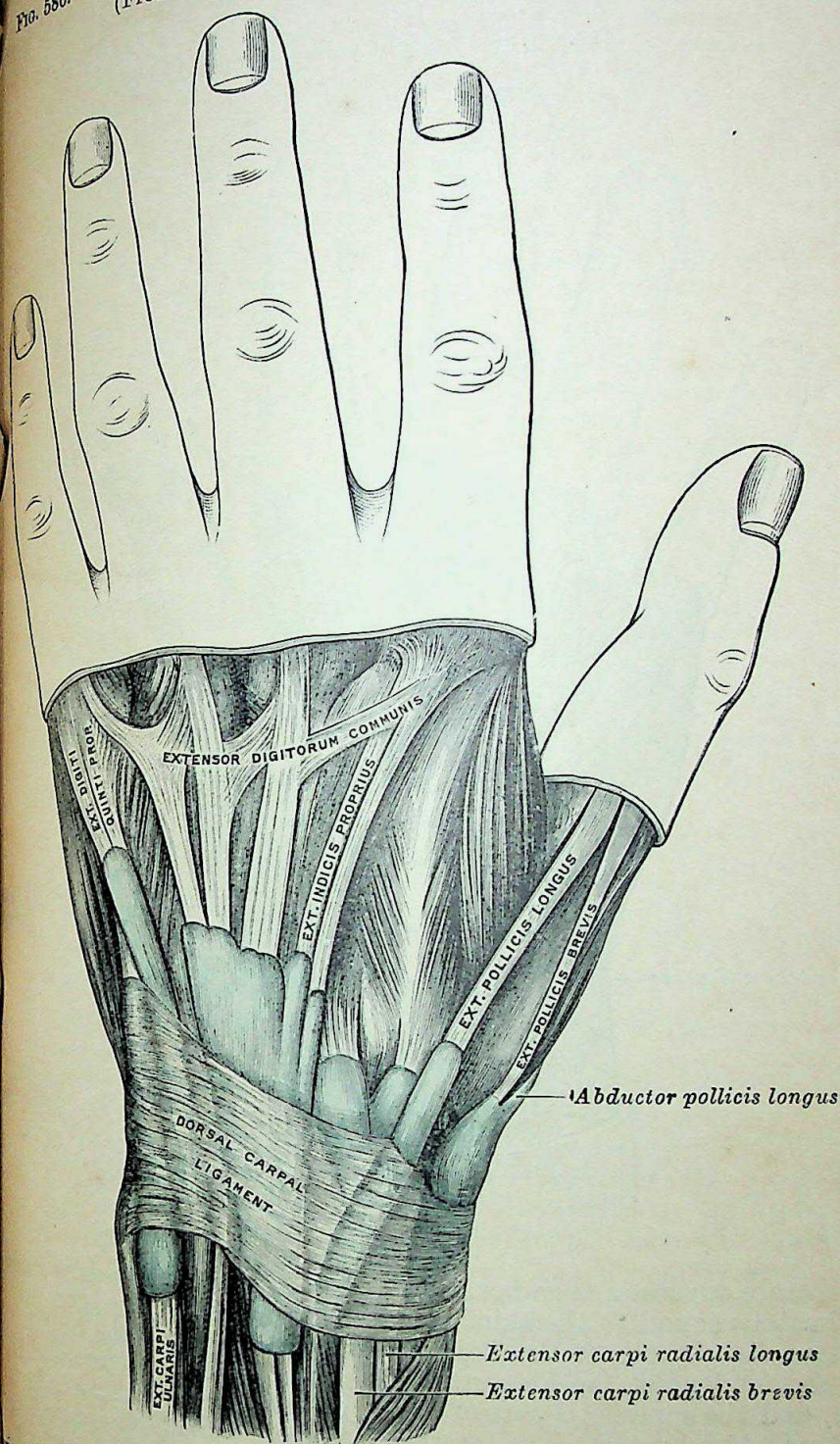

[illegible]n of the transverse carpal ligament, and gives insertion to the expanded [illegible]n of the Palmaris longus. Its base divides into four slips, one for each [illegible]. The slips give off superficial fibres to the skin of the palm and fingers; [illegible] to the palm joining the skin at the furrow corresponding to the meta-[illegible]phalangeal articulations, and those to the fingers passing into the skin [illegible] transverse folds at the roots of the fingers. The deeper part of each

CC-0. In Public Domain. Gurukul Kangri Collection, Haridwar

Digitized by Arya Samaj Foundation Chennai and eGangotri

slip subdivides into two processes, which are inserted into the fibrous
of the flexor tendons; from the sides of these processes offsets are
to the transverse metacarpal ligament. By this arrangement short
are formed on the front of the heads of the metacarpal bones; through
the flexor tendons pass. The intervals between the four slips trans
digital vessels and nerves, and the tendons of the Lumbricales. At the
of division into the slips mentioned, numerous strong, transverse fib

Fig. 587.—The right palmar aponeurosis.

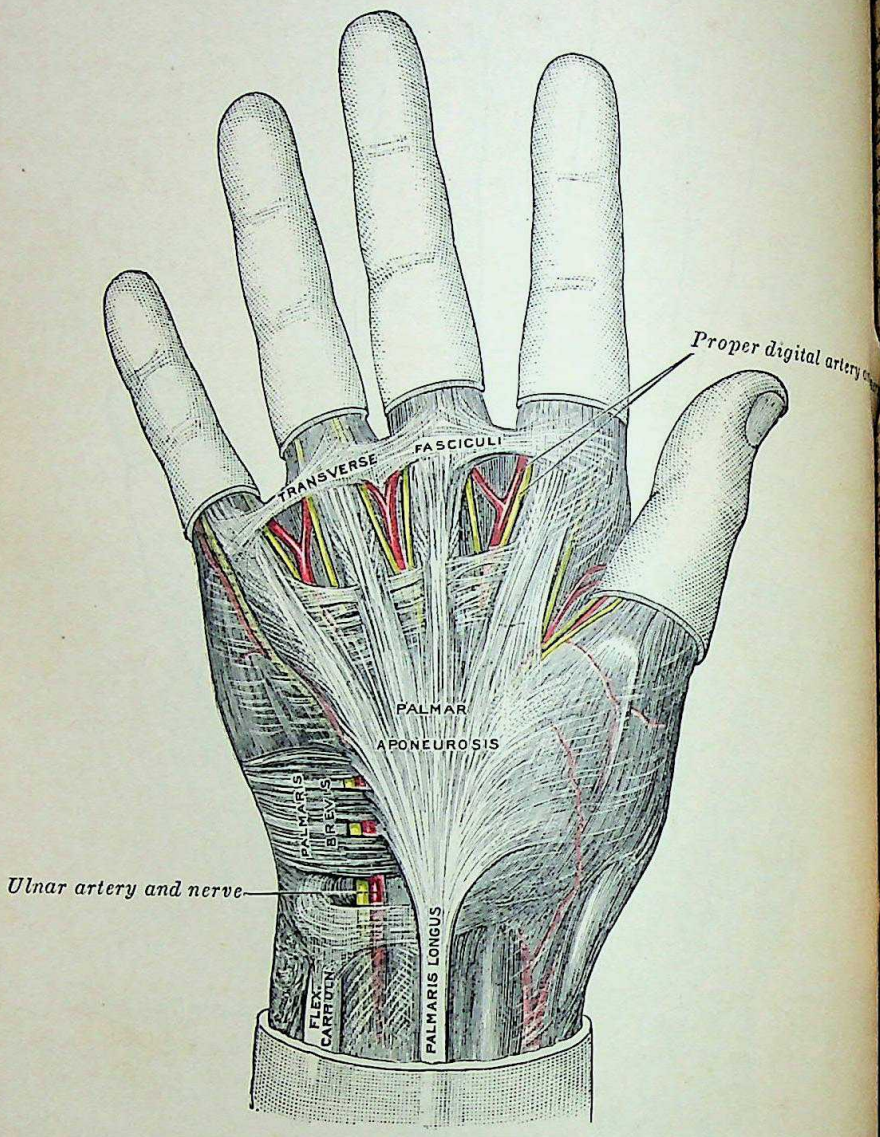

the separate processes together. The central part of the palmar aponeu
is intimately bound to the skin by dense fibro-areolar tissue, and gives
by its medial margin to the Palmaris brevis. It covers the superficial
arch, the tendons of the Flexores digitorum, the terminal part of the m
nerve, and the superficial part of the ulnar nerve; on either side it give
a septum which separates the intermediate from the lateral and medial
of muscles.

The *lateral and medial portions* of the palmar aponeurosis are thin, fi
layers, which cover the muscles of the ball of the thumb, and the short m
of the little finger respectively; they are continuous with the central p
and with the fascia on the dorsum of the hand.

The **superficial transverse fasciculi** form a thin band (fig. 587)
stretches across the roots of the fingers, and is attached to the skin

CC-0. In Public Domain. Gurukul Kangri Collection, Haridwar

Digitized by Arya Samaj Foundation Chennai and eGangotri

...s, and medially to the fifth metacarpal bone, forming a sort of rudimentary ... The digital vessels and nerves pass beneath these fasciculi.

...*plied Anatomy.*—The palmar aponeurosis is liable to undergo contraction, pro-... a very inconvenient deformity known as 'Dupuytren's contraction.' The ring ... little fingers are most frequently implicated, but the others may also be involved. ... proximal phalanx is flexed and cannot be straightened, and the two distal phalanges ... are similarly flexed as the disease advances.

Owing to their constant exposure to injury and septic influences, the fingers are very ... to become the seat of serious inflammatory mischief. In some cases, the inflam-... may involve the theca of the flexor tendons, and a *thecal paronychia* may result. ... inflammation then rapidly spreads up the sheath; but the extent will depend upon ... particular digit involved. From the description of the flexor sheaths given above, it ... evident that inflammation of the mucous sheaths of the thumb and little finger ... prove a far more formidable affection than that of the other three digits, because the ... of these two digits communicate with the large mucous sheath which surrounds ... flexor tendons (p. 519), and the inflammation may extend into the palm of the hand ... behind the transverse carpal ligament into the forearm.

In order to relieve these conditions, free and early incisions are necessary, and must be ... with discrimination, in order to avoid wounding important structures. In the pulp ... finger—i.e. over the distal phalanx—the incision should be made in the middle line ... down to the bone. In the rest of the finger, the incision should be made in the middle ... over the phalanges, and not over the interphalangeal joints. In the palm of the hand, ... may be made either on the distal or proximal side of the superficial volar arch. ... distal side the incisions should be made over the metacarpal bones, preferably ... of the index and middle finger. On the proximal side, the safest line of incision is ... the radial side of the hypothenar eminence, between the ulnar artery and nerve ... and the median nerve laterally. When suppuration has extended under the ... transverse carpal ligament, and incisions are required in the forearm, the positions in ... they should be made are over the tendons of the Flexor digitorum sublimis, ... the median nerve and the ulnar artery, and over the tendon of the Flexor pollicis ... between the radial artery and the tendon of the Flexor carpi radialis.

Chronic inflammation of the common flexor sheath is occasionally met with, consti-... a disease known as *compound palmar ganglion*; it presents an hour-glass outline, ... a swelling in front of the wrist and another in the palm of the hand, and a constric-... corresponding to the transverse carpal ligament, between the two. The fluid can ... from the one swelling to the other under the ligament, and when this is done, a ... sensation is sometimes perceived, from the presence of 'melon-seed' bodies in ... interior of the ganglion.

1. The Lateral Volar Muscles (figs. 588, 589)

Abductor pollicis brevis.	Flexor pollicis brevis.
Opponens pollicis.	Adductor pollicis.

The **Abductor pollicis brevis** (fig. 589) is a thin, subcutaneous muscle; ... arises from the transverse carpal ligament, the tuberosity of the navicular ... and the ridge of the greater multangular bone. It is inserted by a thin, ... tendon into the radial side of the base of the first phalanx of the thumb ... the capsule of the metacarpophalangeal articulation.

Nerve-supply.—The Abductor pollicis brevis is supplied by the sixth and seventh ... nerves through the median nerve.

Actions.—The Abductor pollicis brevis draws the thumb forwards in a plane ... angles to the palm of the hand and abducts the proximal phalanx.

The **Opponens pollicis** (figs. 588, 589) is placed beneath the Abductor ... brevis. It arises from the ridge on the greater multangular bone, and ... the transverse carpal ligament, and is inserted into the whole of the ... lateral surface of the metacarpal bone of the thumb on its radial side.

Nerve-supply.—The Opponens pollicis is supplied by the sixth and seventh ... nerves through the median nerve.

Actions.—The Opponens pollicis flexes the metacarpal bone of the thumb, i.e. ... it medialwards across the palm of the hand.

The **Flexor pollicis brevis** (fig. 589) consists of two portions, superficial ... deep. The *superficial portion* arises from the lower border of the transverse ... ligament and the lower part of the ridge on the greater multangular

CC-0. In Public Domain. Gurukul Kangri Collection, Haridwar

Digitized by Arya Samaj Foundation Chennai and eGangotri

bone ; it passes along the radial side of the tendon of the Flexor pollicis l and is inserted into the radial side of the base of the first phalanx of the th in its tendon of insertion there is a sesamoid bone. The *deep portion* small. It arises from the ulnar side of the base of the first metacarpal and is inserted into the ulnar side of the base of the first phalanx oblique part of the Adductor pollicis ; it is sometimes described as *volar interosseous* muscle.

Nerve-supply.—The superficial portion of the Flexor pollicis brevis is by the sixth and seventh cervical nerves through the median nerve ; the deep by the eighth cervical nerve through the ulnar nerve.

Actions.—The Flexor pollicis brevis flexes and adducts the proximal ph the thumb.

FIG. 588.—The right Opponens pollicis, Adductor pollicis and Opponens digiti q

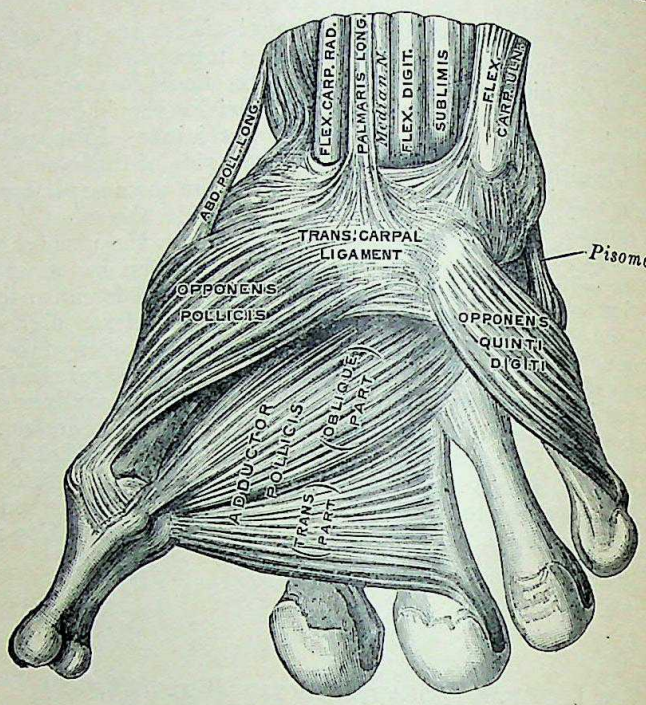

The **Adductor pollicis** (fig. 588) consists of an oblique and a trans part. The *oblique part* arises from the capitate and lesser multangular bo the bases of the second and third metacarpal bones, the intercarpal ligam and the sheath of the tendon of the Flexor carpi radialis. Most of its converge to a tendon, which, uniting with the tendons of the deep portio the Flexor pollicis brevis and the transverse part of the Adductor, is inser into the ulnar side of the base of the first phalanx of the thumb, a sesam bone being present in the tendon. A considerable fasciculus, however, p beneath the tendon of the Flexor pollicis longus and joins the superficial po of the Flexor pollicis brevis and the Abductor pollicis brevis. The *trans part* (fig. 588) is the most deeply seated of this group of muscles. It is triangular form, and arises from the distal two-thirds of the volar surfa the third metacarpal bone ; the fibres converge, to be inserted with the obl part of the muscle and with the deep part of the Flexor pollicis brevis the ulnar side of the base of the first phalanx of the thumb.

Nerve-supply.—The Adductor pollicis is supplied by the eighth cervical n through the ulnar nerve.

Action.—The Adductor pollicis approximates the thumb to the palm of hand.

CC-0. In Public Domain. Gurukul Kangri Collection, Haridwar

Digitized by Arya Samaj Foundation Chennai and eGangotri

2. The Medial Volar Muscles (figs. 588, 589)

Palmaris brevis.
Abductor digiti quinti.
Flexor digiti quinti brevis.
Opponens digiti quinti.

The **Palmaris brevis** (fig. 587) is a thin, quadrilateral muscle, placed beneath the skin of the ulnar side of the hand. It arises by tendinous fasciculi

Fig. 589.—The muscles of the left hand. Volar aspect.

the transverse carpal ligament and palmar aponeurosis; the fleshy fibres inserted into the skin on the proximal part of the ulnar border of the hand. **Nerve-supply.**—The Palmaris brevis is supplied by the eighth cervical nerve through the ulnar nerve.

CC-0. In Public Domain. Gurukul Kangri Collection, Haridwar

Digitized by Arya Samaj Foundation Chennai and eGangotri

Action.—The Palmaris brevis corrugates the skin on the ulnar side of the hand.

The **Abductor digiti quinti** (fig. 589) is situated on the ulnar side of the palm of the hand. It arises from the pisiform bone and from the tendon of the Flexor carpi ulnaris, and ends in a flat tendon which divides into two; one is inserted into the ulnar side of the base of the first phalanx of the little finger, the other into the ulnar border of the aponeurosis of the Extensor digiti quinti proprius.

Nerve-supply.—The Abductor digiti quinti is supplied by the eighth cervical nerve through the ulnar nerve.

Action.—The Abductor digiti quinti abducts the proximal phalanx of the little finger.

The **Flexor digiti quinti brevis** (fig. 589) lies on the radial side of the preceding muscle. It arises from the convex surface of the hamulus of the hamate bone and the volar surface of the transverse carpal ligament; it is inserted into the ulnar side of the base of the first phalanx of the little finger. It is separated from the Abductor by the deep volar branches of the ulnar artery and nerve. This muscle is sometimes wanting; the Abductor is usually, of large size.

Nerve-supply.—The Flexor digiti quinti brevis is supplied by the eighth cervical nerve through the ulnar nerve.

Actions.—The Flexor digiti quinti brevis flexes and abducts the proximal phalanx of the little finger.

The **Opponens digiti quinti** (fig. 588) is of a triangular form, and lies under cover of the Flexor and Abductor. It arises from the convex surface of the hamulus of the hamate bone, and contiguous portion of the transverse carpal ligament; it is inserted into the whole length of the ulnar margin of the fifth metacarpal bone.

Nerve-supply.—The Opponens digiti quinti is supplied by the eighth cervical nerve through the ulnar nerve.

Action.—The Opponens digiti quinti draws forwards the fifth metacarpal so as to deepen the hollow of the palm.

3. The Intermediate Muscles

Lumbricales. Interossei.

The **Lumbricales** (fig. 589) are four small fleshy fasciculi, which take origin from the tendons of the Flexor digitorum profundus. The first and second arise from the radial sides and volar surfaces of the tendons of the index and middle fingers respectively; the third, from the contiguous sides of the tendons of the middle and ring fingers; and the fourth, from the contiguous sides of the tendons of the ring and little fingers. Each passes to the radial side of the corresponding finger, and opposite the metacarpophalangeal articulation is inserted into the tendinous expansion of the Extensor digitorum communis covering the dorsal surface of the finger.

Nerve-supply.—The first and second Lumbricales are supplied by the eighth and seventh cervical nerves through the median nerve; the third and fourth Lumbricales by the eighth cervical through the ulnar nerve. The third Lumbricalis frequently receives a twig from the median nerve.

Actions.—The Lumbricales flex the proximal and extend the middle and terminal phalanges.

The **Interossei** occupy the intervals between the metacarpal bones, and are divided into a dorsal and a volar set.

The **Interossei dorsales** (fig. 590), four in number, are bipennate muscles, each arising by two heads from the adjacent sides of the metacarpal bones, but more extensively from the metacarpal bone of the finger into which the muscle is inserted. They are inserted into the bases of the first phalanges and into the aponeuroses of the tendons of the Extensor digitorum communis. Between the double origin of each of these muscles is a narrow triangular interval; through the first of these intervals the radial artery passes; through each of the others a perforating branch from the deep volar arch is transmitted. The *first* or *Abductor indicis* is larger than the others; it is inserted into

CC-0. In Public Domain. Gurukul Kangri Collection, Haridwar

Digitized by Arya Samaj Foundation Chennai and eGangotri

dial side of the index finger. The *second* and *third* are inserted into the dle finger, the former into its radial, the latter into its ulnar side. The rth is inserted into the ulnar side of the ring finger.

The **Interossei volares** (fig. 591), three in number, are smaller than the rossei dorsales, and are placed upon the volar surfaces of the metacarpal es, rather than between them. Each arises from the entire length of the tacarpal bone of one finger, and is inserted into the side of the base of the first alanx of the same finger, and into the aponeurosis of the Extensor digitorum communis tendon.

Fig. 590.—The Interossei dorsales of the left hand. Dorsal aspect.

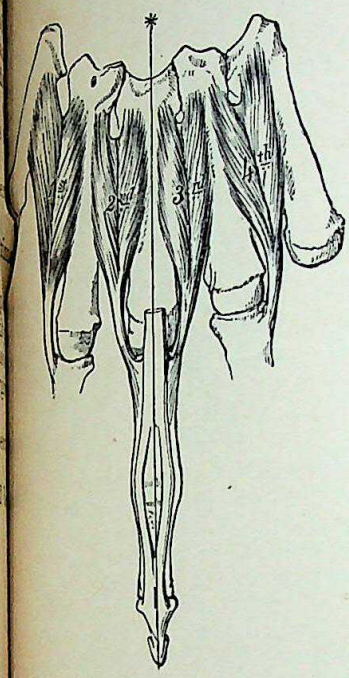

Fig. 591.—The Interossei volares of the left hand. Volar aspect.

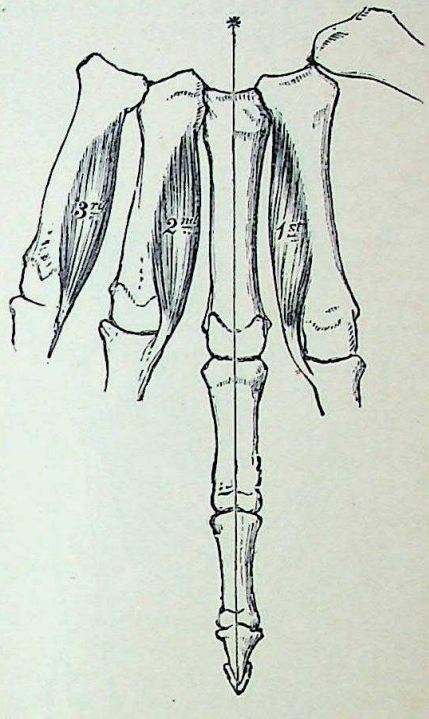

The *first* arises from the ulnar side of the second metacarpal bone, and is rted into the same side of the first phalanx of the index finger. The *second* s from the radial side of the fourth metacarpal bone, and is inserted into ame side of the ring finger. The *third* arises from the radial side of the metacarpal bone, and is inserted into the same side of the little finger. n this account it may be seen that each finger is provided with a pair of rossei, with the exception of the little finger, in which the Abductor digiti ti takes the place of one of the pair.

s already mentioned (p. 524), the deep head of Flexor pollicis brevis is times described as the first volar interosseous muscle.

Nerve-supply.—The Interossei dorsales et volares are supplied by the eighth al nerve through the ulnar nerve.

Actions.—The Interossei dorsales abduct the fingers from an imaginary line n longitudinally through the centre of the middle finger; and the Interossei s adduct the fingers to that line. The Interossei, in conjunction with the bricales, flex the first phalanges, and, in consequence of their insertions into xpansions of the Extensor tendons, extend the second and third phalanges.

pplied Anatomy.—In considering the actions of the various muscles upon fractures e upper extremity, the most common forms of injury have been selected both for ation and description.

fracture of the *middle of the clavicle* (fig. 592) is usually attended with considerable acement of the lateral fragment, which is drawn downwards and medialwards, and e same time rotated, so that its lateral end is carried forwards and its medial end wards.

CC-0. In Public Domain. Gurukul Kangri Collection, Haridwar

Digitized by Arya Samaj Foundation Chennai and eGangotri

The displacement is produced as follows: the lateral fragment is drawn down by the weight of the arm, the Trapezius not being able to support this. It is drawn forwards by the Subclavius and Pectoralis minor, possibly assisted by the Pectoralis major and Latissimus dorsi; and is rotated on an axis drawn through its own centre. Serratus anterior, which causes the scapula to rotate on the wall of the chest, and the acromion and the end of the lateral fragment of the clavicle forwards, and the medial end of the lateral portion backwards. Lying on the back keeps the parts in position and allows gravity to rectify the displacement of the lateral fragment.

In fracture of the *acromial end of the clavicle*, between the conoid and the ligaments, only slight displacement occurs, as these ligaments, from their obliquity, serve to hold both portions of the bone in apposition. Fracture, also, of the *end*, medial to the costoclavicular ligament, is attended with only slight displacement, this ligament serving to retain the fragments in close apposition.

Fig. 592.—A fracture of the middle of the clavicle.

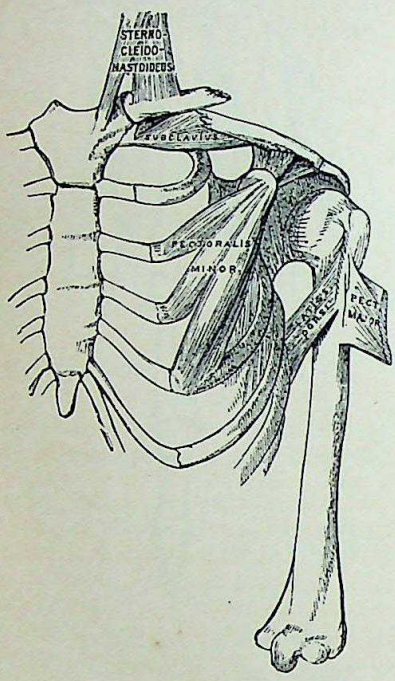

Fig. 593.—A fracture of the surgical neck of the humerus.

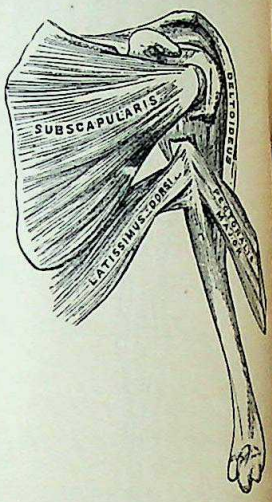

Fracture of the *acromion* is usually caused by violence applied to the upper and back part of the shoulder. There is great displacement; the lateral fragment being drawn downwards by the weight of the arm, and rotated forwards and medialwards, so that it forms a right angle with the rest of the bone.

Fracture of the *surgical neck of the humerus* (fig. 593) is very common. It is attended with considerable displacement, and its appearances correspond somewhat with those of dislocation of the head of the humerus into the axilla. The upper fragment remains in its place under the coraco-acromial ligament; the lower is drawn medialwards by the Pectoralis major, Latissimus dorsi, and Teres major; and the humerus is thrust obliquely from the side of the chest by the Deltoideus, and occasionally elevated so as to cause the upper end of the lower fragment to project beneath and in front of the coracoid process.

In fracture of the *body of the humerus* below the insertion of the Pectoralis major, Latissimus dorsi, and Teres major, and above the insertion of the Deltoideus, there is considerable deformity, the upper fragment being drawn medialwards by the above mentioned muscles, and the lower fragment upwards and lateralwards by the Deltoideus. Shortening of the limb results, with a considerable prominence at the seat of fracture from the fractured ends of the bone riding over one another, especially if the fracture take place in an oblique direction.

In fracture of the *body of the humerus* immediately below the insertion of the Deltoideus the amount of deformity depends greatly upon the direction of the fracture. If it occur in a transverse direction, only slight displacement takes place, the upper fragment being drawn a little forwards; but in oblique fracture, the combined action of the Biceps brachii and Brachialis in front and the Triceps brachii behind draw up the lower fragment, causing it to glide over the upper, either backwards or forwards

CC-0. In Public Domain. Gurukul Kangri Collection, Haridwar

Digitized by Arya Samaj Foundation Chennai and eGangotri

ording to the direction of the fracture. It is in this fracture that the chest-wall is found make the best splint for the medial side of the bone.

Fracture of the *humerus* immediately above the condyles (fig. 594) deserves very attentive deration, as the general appearances correspond somewhat with those produced by ation of the epiphysis of the humerus, and with those of dislocation of the radius and backwards. If the direction of the fracture is oblique, from above, downwards and

Fig. 594.—A fracture of the humerus above the condyles.

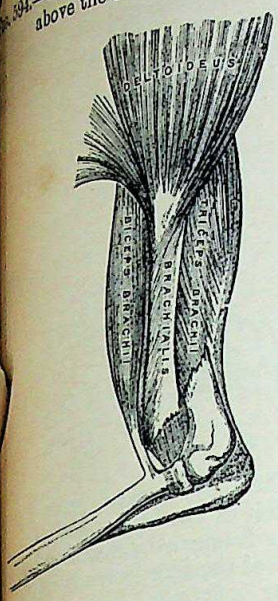

Fig. 595.—A fracture of the olecranon.

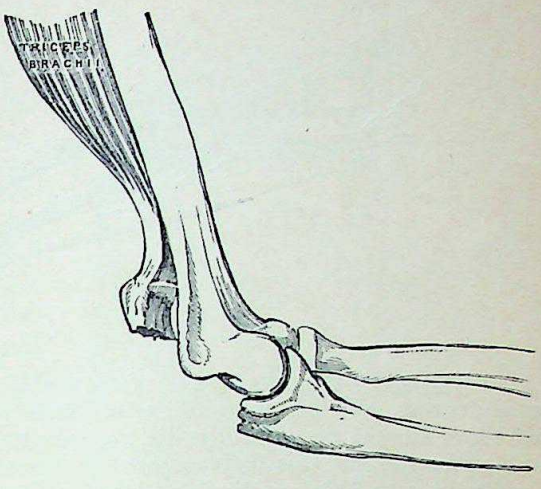

wards, the lower fragment is drawn upwards by the Brachialis and Biceps brachii in and the Triceps brachii behind; and at the same time is drawn backwards behind upper fragment by the Triceps brachii. This fracture may be diagnosed from dis- ion, by the increased mobility, the existence of crepitus, and the fact that the deformity medied by extension, but is reproduced on the discontinuance of it. The age of the nt is of importance in distinguishing this form of injury from separation of the epiphysis. me cases where the injury has been produced by falls on the elbow, the lower fragment own upwards and forwards, causing a considerable prominence in front, the upper ment projecting backwards beneath the tendon of the Triceps brachii. In the treatment ftures of the lower end of the humerus, acute flexion of the elbow-joint gives the best ts; this is especially so in children.

In fracture of the *olecranon* (fig. 595) the detached fragment is displaced upwards from to 5 cm. by the action of the Triceps brachii; the prominence of the elbow is con- ently lost, and a deep hollow is felt at the back part of the joint, which is much increased ering the limb. The patient at the same time loses, more or less, the power of extending forearm.

In fracture of the *radius* below the insertion of the Biceps brachii, but above the insertion Pronator teres, the upper fragment is strongly supinated by the Biceps brachii and nator, and at the same time drawn ards by the Biceps brachii, the r fragment is pronated and drawn ds the ulna by both Pronators. there is extreme displacement very little deformity. This frac- should be treated with the hand full supination so as to insure that fragment of the radius will be ated to the extent of the upper ment.

Fig. 596.—A fracture of the body of the radius.

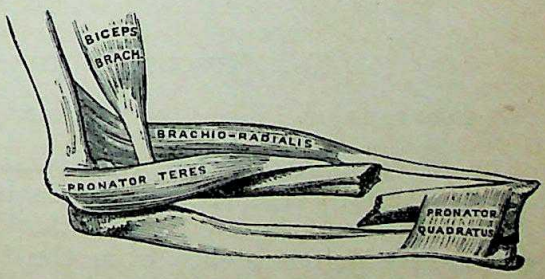

In fractures of the radius below the tion of the Pronator teres (fig. 596), upper fragment is drawn upwards the Biceps brachii and medialwards by the Pronator teres, into a position midway en pronation and supination, and a degree of fulness in the upper half of the forearm s produced. The lower fragment is drawn downwards towards the ulna and pronated the Pronator quadratus; at the same time, the Brachioradialis, by elevating the styloid ess, into which it is inserted, will serve to depress the upper end of the lower fragment more towards the ulna.

CC-0. In Public Domain. Gurukul Kangri Collection, Haridwar

Digitized by Arya Samaj Foundation Chennai and eGangotri

In fracture of the *body of the ulna* the upper fragment retains its usual position, the lower is drawn towards the radius by the Pronator quadratus, producing a well depression at the seat of fracture, and some fulness on the dorsal and volar surfaces of the forearm.

In fracture of the *bodies of the radius and ulna together*, the lower fragments are drawn upwards, sometimes forwards, sometimes backwards, according to the direction of the fracture, by the combined actions of the flexor and extensor muscles, producing a fulness on either the dorsal or volar surface of the forearm. At the same time the fragments are drawn into contact by the Pronator quadratus, the radius being in the of pronation. The upper fragment of the radius is drawn upwards and medially by the Biceps brachii and Pronator teres to a higher level than the ulna; the upper of the ulna is slightly elevated by the Brachialis.

Fig. 597.—A fracture of the lower end of the radius.

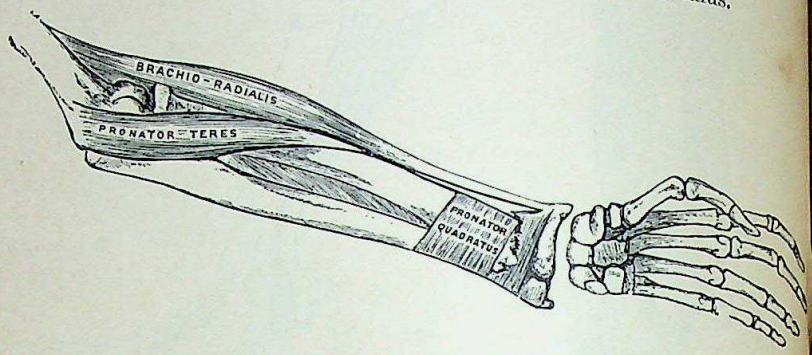

In fracture of the *lower end of the radius* (fig. 597) the displacement produced is considerable, and bears some resemblance to dislocation of the carpus backwards, which it should be carefully distinguished. The lower fragment is displaced backwards and upwards, but this displacement is due to the force of the blow driving the portion of the bone into this position, and not to any muscular influence. The upper fragment projects forwards, often lacerating the substance of the Pronator quadratus, and is held by this muscle into close contact with the lower end of the ulna, causing a projection on the volar surface of the forearm, immediately above the carpus, from the flexor tendons being thrust forwards. This fracture may be distinguished from dislocation by the relative positions of the styloid processes of the radius and ulna (the former of which is displaced upwards in fracture) and by the deformity being removed on making sufficient extension when crepitus may be occasionally detected. The age of the patient will assist in determining whether the injury is fracture or separation of the epiphysis. During treatment of this fracture the wrist should be kept fully hyperextended (p. 395).

THE FASCIÆ AND MUSCLES OF THE LOWER EXTREMITY

The muscles of the lower extremity are subdivided into groups corresponding with the different regions of the limb.

I. Muscles of the iliac region.
II. Muscles of the thigh.
III. Muscles of the leg.
IV. Muscles of the foot.

I. The Muscles of the Iliac Region (fig. 598)

Psoas major. Psoas minor. Iliacus.

The **fascia iliaca** covers the Psoas and Iliacus. It is thin above, but becomes gradually thicker as it approaches the inguinal ligament.

The *portion covering the Psoas* is thickened above to form the medial lumbo-costal arch which stretches from the transverse process of the first to the body of the second lumbar vertebra. Medially, this portion of the fascia is attached by a series of arched processes to the intervertebral fibrocartilages and prominent margins of the bodies of the vertebræ, and to the upper part of the sacrum. Laterally, above the crest of the ilium, it is continuous with the fascia covering the front of the Quadratus lumborum (p. 481), while below the crest of the ilium it is continuous with the fascia covering the Iliacus.

CC-0. In Public Domain. Gurukul Kangri Collection, Haridwar

Digitized by Arya Samaj Foundation Chennai and eGangotri

The portion covering the Iliacus is con-
cted, laterally, to the whole length of
e inner lip of the iliac crest; and medi-
ly to the brim of the lesser pelvis, where
blends with the periosteum. It is
ached to the iliopectineal eminence,
d there receives a slip from the tendon
insertion of the Psoas minor when that
scle exists. The external iliac vessels
e in front of the fascia but the branches
the lumbar plexus are behind it; it is
parated from the peritoneum by a part
the subperitoneal connective tissue
ascia of Abernethy).

Lateral to the femoral vessels, the iliac
ascia is intimately connected to the pos-
rior margin of the inguinal ligament,
d is continuous with the transversalis
ascia. It passes behind the femoral
essels, and beyond the inguinal ligament
mes the *iliopectineal fascia*. This
n divides the space between the
guinal ligament and the hip-bone into
edial and a lateral lacuna; the medial
cuna vasorum) transmits the femoral
essels, the lateral (lacuna musculorum)
e Psoas major, the Iliacus and the
moral nerve. Medial to the vessels the
pectineal fascia is attached to the pecten
bis, and is continuous with the pectineal
ascia. In the thigh the iliopectineal
ascia covers the Iliacus and the Psoas
jor, and forms the posterior wall of the
moral sheath.

The **Psoas major** (fig. 598) is a long
form muscle placed on the side of the
mbar region of the vertebral column and
e brim of the lesser pelvis. It arises
from the anterior surfaces and lower
rders of the transverse processes of all
e lumbar vertebræ; (2) by five slips or
tations, each of which takes origin from
e bodies of two vertebræ and their inter-
ertebral fibrocartilage; the highest slip
ises from the lower margin of the body
the twelfth thoracic vertebra, the upper
rgin of the body of the first lumbar
rtebra and the interposed fibrocartilage,
e lowest slip from the adjacent margins
the bodies of the fourth and fifth lumbar
rtebræ and the interposed fibrocartilage;
from a series of tendinous arches
anding across the constricted parts of
e bodies of the lumbar vertebræ between
e preceding slips; the lumbar arteries
d veins, and filaments from the sympa-
hic trunk, pass beneath these arches.
e muscle proceeds downwards across
brim of the lesser pelvis, passes behind
inguinal ligament and in front of the
ule of the hip-joint, and ends in a
on. The latter receives nearly the
le of the fibres of the Iliacus and is

FIG. 598.—The muscles of the iliac region and the anterior femoral muscles. Right side.

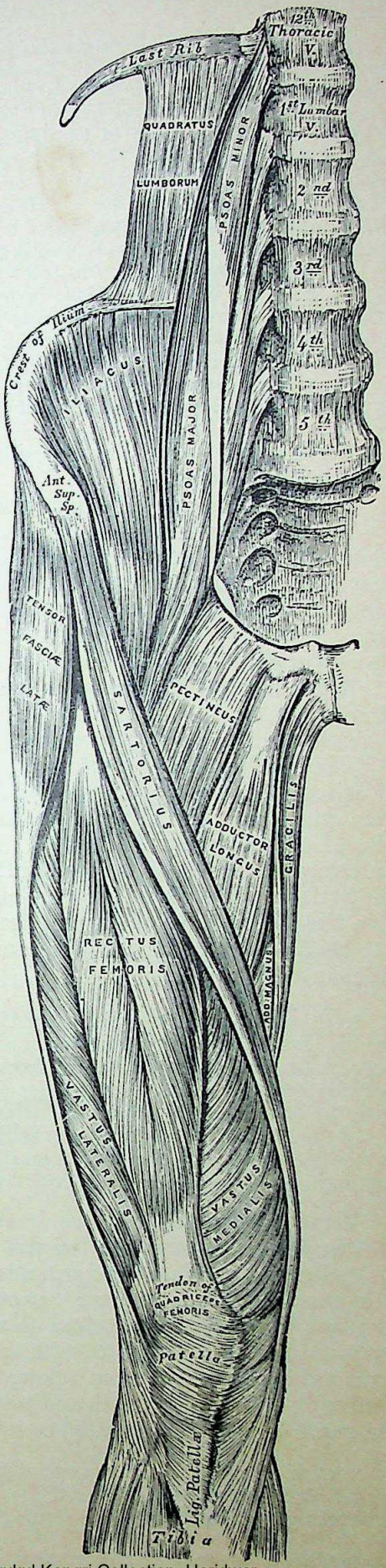

CC-0. In Public Domain. Gurukul Kangri Collection, Haridwar

Digitized by Arya Samaj Foundation Chennai and eGangotri

inserted into the lesser trochanter of the femur. A large bursa, which communicate with the cavity of the hip-joint, separates the tendon from os pubis and the capsule of the joint.

Relations.—In the abdomen the Psoas major is in relation by its *anterior surface* with the medial lumbocostal arch, the fascia covering the muscle, the extraperitoneal connective tissue and peritoneum, the kidney, Psoas minor, renal vessels, ureter, testicular (or ovarian) vessels, and genito-femoral nerve. In front of the right Psoas is the inferior vena cava, and the terminal portion of the ileum, and in front of the left the colon. Its *posterior surface* is in relation with the transverse processes of the lumbar vertebræ, and the quadratus lumborum. The lumbar plexus is situated in the posterior part of the muscle, and the of the muscle. *Medially*, the muscle is in relation with the bodies of the lumbar vertebræ, the lumbar arteries, the gangliated trunk of the sympathetic, the lumbar lymph-glands, and along the brim of the pelvis with the external iliac artery; medial to the right is the inferior vena cava, and to the left muscle the aorta.

In the thigh it is in relation, *in front*, with the fascia lata; *behind*, with the capsule of the hip-joint from which it is separated by a bursa; by its *medial border*, with the obturator tineus and medial femoral circumflex artery, and also with the femoral artery, which slightly overlaps it; by its *lateral border*, with the Iliacus.

The femoral nerve descends at first through the fibres of Psoas major, then lies between it and the Iliacus, and at the level of the inguinal ligament is in front of the muscle.

Nerve-supply.—The Psoas major is supplied by branches from the second and third lumbar nerves.

Actions.—The Psoas major acts conjointly with the Iliacus.

The **Psoas minor** (fig. 598) is placed in front of the Psoas major within the abdomen. It arises from the sides of the bodies of the twelfth thoracic and first lumbar vertebræ and from the fibrocartilage between them. It ends in a long flat tendon which is inserted into the pecten pubis and iliopectineal eminence, and, by its lateral border, into the iliac fascia. This muscle is absent in about 40 per cent. of subjects.

Nerve-supply.—The Psoas minor is supplied by a branch from the first lumbar nerve.

Action.—The Psoas minor is a tensor of the iliac fascia.

The **Iliacus** (fig. 598) is a flat, triangular muscle, which fills the iliac fossa. It arises from the upper two-thirds of the iliac fossa, from the inner lip of the iliac crest, from the anterior sacro-iliac and iliolumbar ligaments, and from the ala of the sacrum; in front, it reaches as far as the anterior superior and anterior inferior iliac spines, and receives a few fibres from the upper part of the articular capsule of the hip-joint. Most of its fibres converge to be inserted into the lateral side of the tendon of the Psoas major, but some of them are attached to the body of the femur for 2·5 cm. below and in front of the lesser trochanter.*

Relations.—Within the abdomen the Iliacus is in relation by its *anterior surface* with the iliac fascia, which separates the muscle from the extraperitoneal connective tissue and peritoneum, and with the lateral femoral cutaneous nerve; on the right side, with the cæcum; on the left side, with the iliac part of the descending colon; by its *posterior surface* with the iliac fossa; by its *medial border*, with the Psoas major and femoral nerve.

In the thigh, it is in relation, by its *anterior surface*, with the fascia lata, Rectus femoris, Sartorius, and arteria profunda femoris; by its *posterior surface*, with the capsule of the hip-joint, a bursa common to it and the Psoas major being interposed.

Nerve-supply.—The Iliacus is supplied by branches of the second and third lumbar nerves, through the femoral nerve.

Actions.—The Psoas major, acting from above, flexes the thigh upon the pelvis, being assisted by the Iliacus; acting from below, with the femur fixed, it bends the lumbar portion of the vertebral column forwards and to its own side, and thereby, in conjunction with the Iliacus, tilts the pelvis forwards. When the Psoas major and Iliacus of both sides act from below, they serve to maintain the erect posture by supporting the vertebral column and pelvis upon the femora, or in continued action bend the trunk and pelvis forwards, as in raising the trunk from the recumbent posture.

Applied Anatomy.—There is no definite septum between the portions of fascia covering the Psoas and Iliacus respectively, and the fascia is only connected to the subjacent muscles by a quantity of loose connective tissue. When an abscess forms beneath the

* The Psoas major and Iliacus are sometimes regarded as a single muscle named the *Iliopsoas*.

CC-0. In Public Domain. Gurukul Kangri Collection, Haridwar

Digitized by Arya Samaj Foundation Chennai and eGangotri

...a, as it is very apt to do, the pus is contained in an osseofibrous cavity which is closed ...all sides within the abdomen, and is open only at its lower part, where the fascia is ...nged over the muscles into the thigh. When the disease is in the thoracic vertebræ, ...matter tracks down the posterior mediastinal cavity in front of the bodies of the ...brræ, and, passing beneath the medial lumbocostal arch, enters the sheath of the ...s, down which it travels as far as the pelvic brim; it then gets beneath the iliac ...ion of the fascia, and fills up the iliac fossa. In consequence of the attachment of ...fascia to the linea terminalis, it rarely finds its way into the lesser pelvis, but passes ...a narrow opening under the inguinal ligament into the thigh, lateral to the femoral ...sels. It thus follows that a psoas abscess may be described as consisting of four parts, ...(1) somewhat narrow channel at its upper part, in the psoas sheath; (2) a dilated sac ...the iliac fossa; (3) a constricted neck under the inguinal ligament; and (4) a dilated ...the upper part of the thigh. When the lumbar vertebræ are the seat of the disease, ...matter finds its way directly into the substance of the Psoas. The muscular fibres ...destroyed, and the nerves contained in the abscess are isolated and exposed in its ...rior; the iliac vessels which lie in front of the fascia remain intact, and the peri-...um seldom becomes implicated. All psoas abscesses do not, however, pursue this ...se; the pus may leave the sheath of the muscle above the crest of the ilium, and ...ing backwards may point in the loin (*lumbar abscess*); or it may point above the ...inal ligament in the inguinal region; or it may follow the course of the branches of ...hypogastric vessels into the lesser pelvis, and, passing through the greater sciatic ...men, discharge itself on the back of the thigh.

II. The Muscles of the Thigh

1. The Anterior Femoral Muscles (fig. 598)

Tensor fasciæ latæ.
Sartorius.
Quadriceps femoris { Rectus femoris. Vastus lateralis. Vastus medialis. Vastus intermedius.
Articularis genus.

The **superficial fascia** forms a continuous layer over the whole of the ...; it consists of areolar tissue containing in its meshes much fat, and ...be separated into two or more layers, between which are found the super-...l vessels and nerves. It varies in thickness in different parts of the limb; ...the groin it is thick, and the two layers are separated from one another ...the superficial inguinal lymph-glands, the great saphenous vein, and several ...er vessels. The superficial layer is continuous above with the super-...l fascia of the abdomen. The deep layer of the superficial fascia is a ...thin, fibrous stratum, best marked on the medial side of the great saphenous ...and below the inguinal ligament. It is placed beneath the subcutaneous ...ls and nerves and upon the surface of the fascia lata. It is intimately ...rent to the fascia lata a little below the inguinal ligament. It covers the ...a ovalis (saphenous opening), being closely united to its circumference, ...is connected to the sheath of the femoral vessels. The portion covering ...fossa ovalis is perforated by the great saphenous vein, small blood-...ls, and lymph-vessels, hence it has been termed the *fascia cribrosa*, the ...ings for these vessels having been likened to the holes in a sieve. A large ...taneous bursa is found in the superficial fascia over the patella.

The **deep fascia** of the thigh is named, from its great extent, the *fascia* ...; it constitutes an investment for the whole of this region of the limb, ...varies in thickness in different parts. Thus, it is thicker in the upper ...lateral parts of the thigh, where it receives a fibrous expansion from the ...us maximus, and where the Tensor fasciæ latæ is inserted between its ...s; it is very thin behind, and at the upper and medial parts, where it covers ...adductor muscles, but becomes stronger around the knee, where it receives ...us expansions from the tendon of the Biceps femoris laterally, from the ...torius medially, and from the Quadriceps femoris in front. The fascia lata ...tached, above and behind, to the back of the sacrum and coccyx; laterally, ...the iliac crest; in front, to the inguinal ligament and to the superior ramus of ...s pubis; and medially, to the inferior ramus of the os pubis, to the inferior ...us and tuberosity of the ischium, and to the lower border of the sacro-...ous ligament. From its attachment to the iliac crest it descends as a ...e fascia over the Glutæus medius to the upper border of the Glutæus

CC-0. In Public Domain. Gurukul Kangri Collection, Haridwar

Digitized by Arya Samaj Foundation Chennai and eGangotri
maximus, where it splits into two layers, one passing superficial and the deep to this muscle; at the lower border of the muscle the two layers re The portion of the fascia lata attached to the front part of the iliac crest corresponding to the origin of the Tensor fasciæ latæ, extends down the side of the thigh as two layers, one superficial and the other deep muscle; at the lower end of the muscle these two layers unite, and strong band, having first received the insertion of the muscle. This continued downwards, under the name of the *iliotibial tract* (iliotibial band is attached to the lateral condyle of the tibia. The layer of the iliotibial which lies deep to the Tensor fasciæ latæ is prolonged upwards to lateral part of the capsule of the hip-joint. The greater part of the the Glutæus maximus is inserted into the iliotibial tract. Below, the lata is attached to all the prominent points around the knee-joint, condyles of the femur and tibia, and the head of the fibula. On either of the patella it is strengthened by transverse fibres from the lower the Vasti, which are attached to and support this bone. Of these the are the stronger, and are continuous with the iliotibial tract. The fascia gives off two strong intermuscular septa which are attached to the length of the linea aspera of the femur and its prolongations above below: the lateral and stronger septum, which extends from the inserti the Glutæus maximus to the lateral condyle, separates the Vastus lateralis front from the short head of the Biceps femoris behind, and gives partial to these muscles; the medial and thinner septum separates the Vastus m from the Adductores and the Pectineus. Besides these there are mu smaller septa, separating the individual muscles, and enclosing each distinct sheath.

The **fossa ovalis** (saphenous opening) (fig. 599).—At the upper and part of the thigh, a little below the medial end of the inguinal ligament a large oval aperture in the fascia lata; it transmits the great saphenous vein, and other smaller vessels, and is termed the *fossa ovalis*. The cribrosa, which is pierced by the structures passing through the opening the aperture and must be removed to expose it. The fascia lata in the of the thigh is described as consisting of a superficial and a deep portion.

The *superficial portion* of the fascia lata is the part on the lateral side the fossa ovalis. It is attached to the crest and anterior superior spine of ilium, to the whole length of the inguinal ligament, and to the pecten pubis conjunction with the lacunar ligament. From the tubercle of the os it is reflected downwards and lateralwards, as an arched margin, the *falciform margin*, forming the lateral boundary of the fossa ovalis; this margin over and is adherent to the anterior layer of the sheath of the femoral vessels the fascia cribrosa is attached to it. The upward and medial prolongation the falciform margin is named the *superior cornu*; its downward and medial prolongation, the *inferior cornu*. The latter is well defined, and is continued behind the great saphenous vein with the pectineal fascia.

The *deep portion* is situated on the medial side of the fossa ovalis, and continuous with the superficial portion at the lower margin of the fossa; upwards, it covers the Pectineus, Adductor longus, and Gracilis, and, behind the sheath of the femoral vessels, to which it is closely united continuous with the iliopectineal fascia, and is attached to the pecten pubis.

From this description it may be observed that the superficial portion fascia lata lies in front of the femoral vessels, and the deep portion them, so that an apparent aperture exists between the two, through the great saphenous vein passes to join the femoral vein.

The **Tensor fasciæ latæ** (fig. 598) arises from the anterior 5 cm. of outer lip of the iliac crest; from the outer surface of the anterior superior spine, and part of the outer border of the notch below it, between the Glutæus medius and Sartorius; and from the deep surface of the fascia lata. inserted between the two layers of the iliotibial tract of the fascia lata the junction of the middle with the upper one-third of the thigh.

Nerve-supply.—The Tensor fasciæ latæ is supplied by the fourth and fifth lumbar and first sacral nerves through the superior glutæal nerve.

Actions.—The Tensor fasciæ latæ tightens the fascia lata; continuing its action it abducts the thigh and rotates it inwards. In the erect posture, acting

CC-0. In Public Domain. Gurukul Kangri Collection, Haridwar

Digitized by Arya Samaj Foundation Chennai and eGangotri

w, it serves to steady the pelvis on the head of the femur; through the iliotibial it steadies the condyles of the femur on the tibia.

The **Sartorius** (figs. 598, 600, 602), the longest muscle in the body, is w and ribbon-like; it arises by tendinous fibres from the anterior superior spine and the upper one-half of the notch below it. It crosses obliquely upper and anterior parts of the thigh, from the lateral to the medial side, descends vertically, as far as the medial side of the knee, passing behind medial condyle of the femur to end in a tendon. This curves obliquely wards and expands into a broad aponeurosis, which is inserted, in front the Gracilis and Semitendinosus, into the upper part of the medial surface the body of the tibia, nearly as far forwards as the anterior crest. The

FIG. 599.—The right fossa ovalis (saphenous opening).

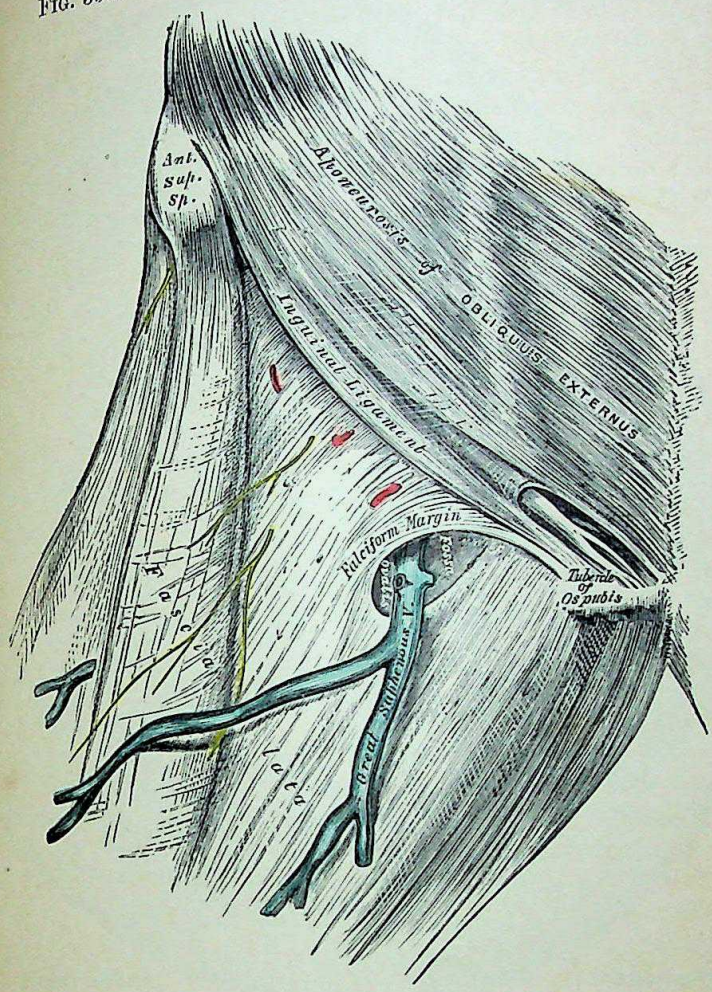

er part of the aponeurosis is curved backwards over the upper edge of tendon of the Gracilis so as to be inserted behind it. An offset, from its er margin, blends with the capsule of the knee-joint, and another, from its er border, with the fascia on the medial side of the leg.

The relations of this muscle to the femoral artery are important, as it constitutes the guide in tying the vessel. In the upper one-third of the thigh it forms the lateral of a triangle, the *femoral* (*Scarpa's*) *triangle*, the medial side of which is formed by the al border of the Adductor longus, and the base by the inguinal ligament; the oral artery passes through the middle of this triangle from its base to its apex. In middle one-third of the thigh, the femoral artery is contained in the *adductor* (*Hunter's*) , on the roof of which the Sartorius lies (fig. 602).

Nerve-supply.—The Sartorius is supplied by the second and third lumbar nerves ugh the femoral nerve.

Actions.—The Sartorius flexes the leg on the thigh, and the thigh on the pelvis; also abducts the thigh and rotates it outwards. Acting from below it flexes the on the thigh and rotates it towards the opposite side.

CC-0. In Public Domain. Gurukul Kangri Collection, Haridwar

Digitized by Arya Samaj Foundation Chennai and eGangotri

The **Quadriceps femoris** (figs. 598, 600, 602) is the great extensor of the leg, and consists of a large fleshy mass which covers the front and of the femur. It is subdivided into separate portions, which have no distinctive names. One occupies the middle of the thigh, and arises the ilium; from its straight course it is called the *Rectus femoris*. The three take origin from the body of the femur, which they cover from trochanters to the condyles; that on the lateral side of the femur is the *Vastus lateralis*; that on the medial side, the *Vastus medialis*; that in front, the *Vastus intermedius*.

FIG. 600.—A transverse section through the thigh at the level of the apex of the femoral triangle. Four-fifths of natural size.

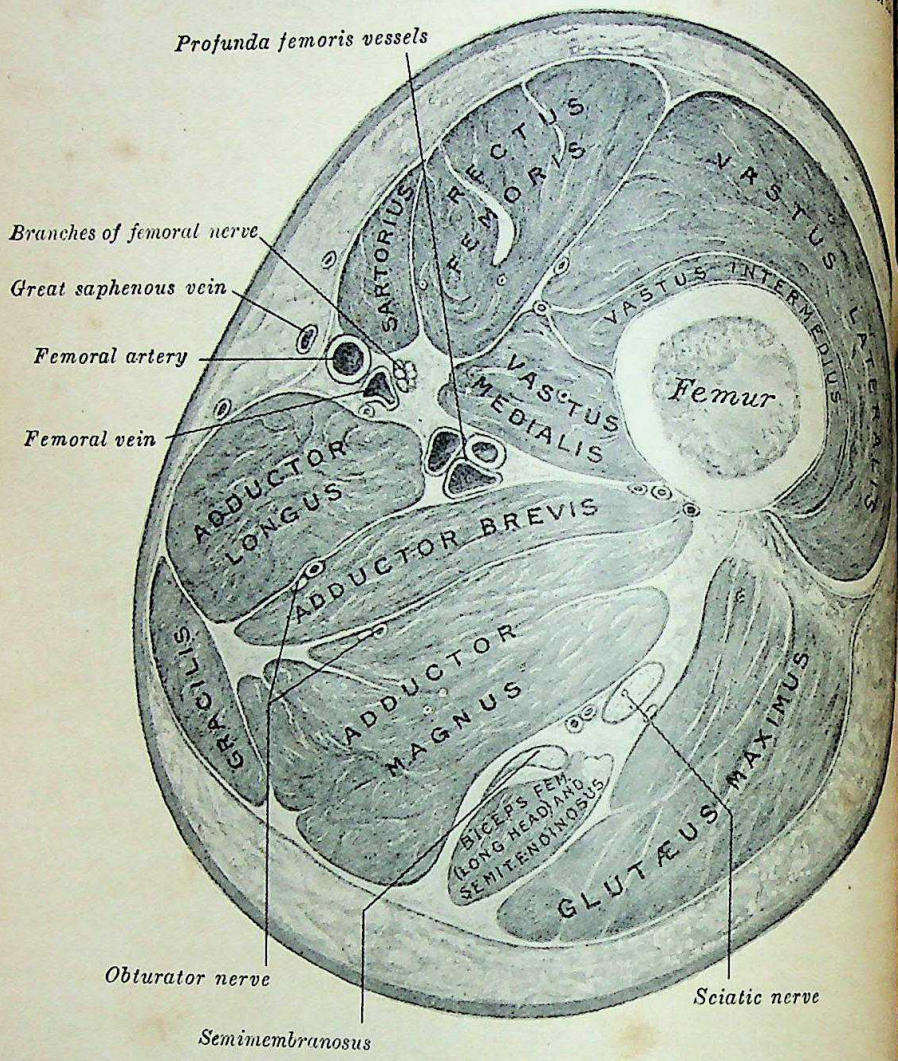

The **Rectus femoris** is fusiform in shape, and its superficial fibres are arranged in a bipennate manner, the deep fibres running straight down to the deep aponeurosis. It arises by two tendons: an anterior or straight, from the anterior inferior iliac spine, and a posterior or reflected, from a groove above the brim of the acetabulum. The two unite at an acute angle, and spread into an aponeurosis which is prolonged downwards on the anterior surface of the muscle, and from this the muscular fibres arise. The muscle ends in a broad and thick aponeurosis which occupies the lower two-thirds of its posterior surface, and, gradually becoming narrowed into a flattened tendon, is inserted into the base of the patella.

The **Vastus lateralis** is the largest part of the Quadriceps femoris. It arises by a broad aponeurosis, which is attached to the upper part of the intertrochanteric line, to the anterior and inferior borders of the great trochanter, to the lateral lip of the gluteal tuberosity, and to the upper one-

CC-0. In Public Domain. Gurukul Kangri Collection, Haridwar

Digitized by Arya Samaj Foundation Chennai and eGangotri

the lateral lip of the linea aspera: this aponeurosis covers the upper three-
ths of the muscle, and from its deep surface many fibres take origin. A
additional fibres arise from the tendon of the Glutæus maximus, and
the lateral intermuscular septum between the Vastus lateralis and short
of the Biceps femoris. The fibres form a large fleshy mass, which is
ed to a strong aponeurosis, placed on the deep surface of the lower part
e muscle: this aponeurosis contracts into a flat tendon which is inserted
the lateral border of the patella, blending with the Quadriceps femoris
on, and giving an expansion to the capsule of the knee-joint.

The Vastus medialis and Vastus intermedius appear to be inseparably
ed, but when the Rectus femoris has been reflected a narrow interval will
be observed extending upwards from the medial border of the patella between
two muscles, and the separation may be carried to the lower part of the
trochanteric line, where, however, the two muscles are frequently continuous.

The **Vastus medialis** arises from the lower one-half of the intertrochanteric
the medial lip of the linea aspera, the upper part of the medial supra-
ylar ridge, the tendons of the Adductor longus and Adductor magnus,
the medial intermuscular septum. Its fibres are directed downwards
forwards, and are chiefly attached to an aponeurosis which lies on the
surface of the muscle and is inserted into the medial border of the patella
e Quadriceps femoris tendon, an expansion being sent to the capsule
knee-joint.

The **Vastus intermedius** (Crureus) arises from the front and lateral surfaces
upper two-thirds of the body of the femur, and from the lower part of
lateral intermuscular septum. Its fibres end in a superficial aponeurosis,
forms the deep part of the Quadriceps femoris tendon.

The *tendons* of the different portions of the Quadriceps unite at the lower
of the thigh, to form a single strong tendon which is inserted into the
of the patella, some fibres passing over it to blend with the ligamentum
e. More properly, the patella may be regarded as a sesamoid bone
ped in the tendon of the Quadriceps; and the ligamentum patellæ,
is continued from the apex of the patella to the tuberosity of the tibia,
e proper tendon of insertion of the muscle, the medial and lateral patellar
cula (p. 410) being expansions from its borders. A bursa, which usually
unicates with the cavity of the knee-joint, is situated between the femur
the portion of the Quadriceps tendon above the patella; another is
osed between the ligamentum patellæ and the upper part of the front
e tibia (fig. 522).

The **Articularis genus** (Subcrureus) is a small muscle, usually distinct
the Vastus intermedius, but occasionally blended with it; it consists of
al muscular bundles which arise from the anterior surface of the lower
of the body of the femur, and are inserted into the upper part of the
vial stratum of the articular capsule of the knee-joint.

Nerve-supply.—The Quadriceps femoris and the Articularis genus are supplied
e second, third, and fourth lumbar nerves, through the femoral nerve.

Actions.—The Quadriceps femoris extends the leg upon the thigh. The Rectus
assists the Psoas major and Iliacus in supporting the pelvis and trunk upon
mur; it also assists in flexing the thigh on the pelvis, or if the thigh be fixed
flex the pelvis. The Vastus medialis draws the patella medialwards as well
wards. The Articularis genus pulls upwards the synovial stratum of the
r capsule of the knee-joint during extension of the leg.

Applied Anatomy.—A few fibres of the Rectus femoris are occasionally ruptured from
strain. This accident is especially liable to occur during the games of football and
, and is sometimes known as 'cricket thigh.' The patient experiences a sudden
the part, as if he had been struck, and the Rectus stands out and is felt to be tense
d. The accident is often followed by considerable swelling from inflammatory
. The Quadriceps femoris may be torn away from its insertion into the patella.
dent is caused in the same manner as fracture of the patella by muscular action,
y a violent muscular effort to prevent falling while the knee is in a position of
ction. A distinct gap can be felt above the patella, and, owing to the retraction
muscular fibres, union may fail to take place. The ligamentum patellæ may be
d about 2·5 cm. above the tibia; or the tuberosity of the tibia may be torn
the bone; the last condition is more likely to happen before the ossification of the
ity is completed, i.e. before the age of twenty years.

CC-0. In Public Domain. Gurukul Kangri Collection, Haridwar

Digitized by Arya Samaj Foundation Chennai and eGangotri

2. The Medial Femoral Muscles.

Gracilis.	Adductor longus.
Pectineus.	Adductor brevis.

Adductor m

The **Gracilis** (figs. 598, 600, 602) is the most superficial muscle medial side of the thigh. It is thin and flattened, broad above, na tapering below. It arises by aponeurosis from the anterior of the lower one-half of the sy pubis and the upper one-half pubic arch. The fibres run v downwards, and end in a tendon, which passes behind the condyle of the femur, curves r medial condyle of the tibia, becomes flattened, and is inserted the upper part of the medial sur the body of the tibia, below the c A few fibres from the lower the tendon are prolonged into the fascia of the leg. At its insertion tendon is situated immediately that of the Semitendinosus, upper edge is overlapped by the of the Sartorius, with which it is blended. It is separated from the collateral ligament of the knee-j a bursa common to it and the of the Semitendinosus.

Fig. 601.—The deep medial femoral muscles. Right side.

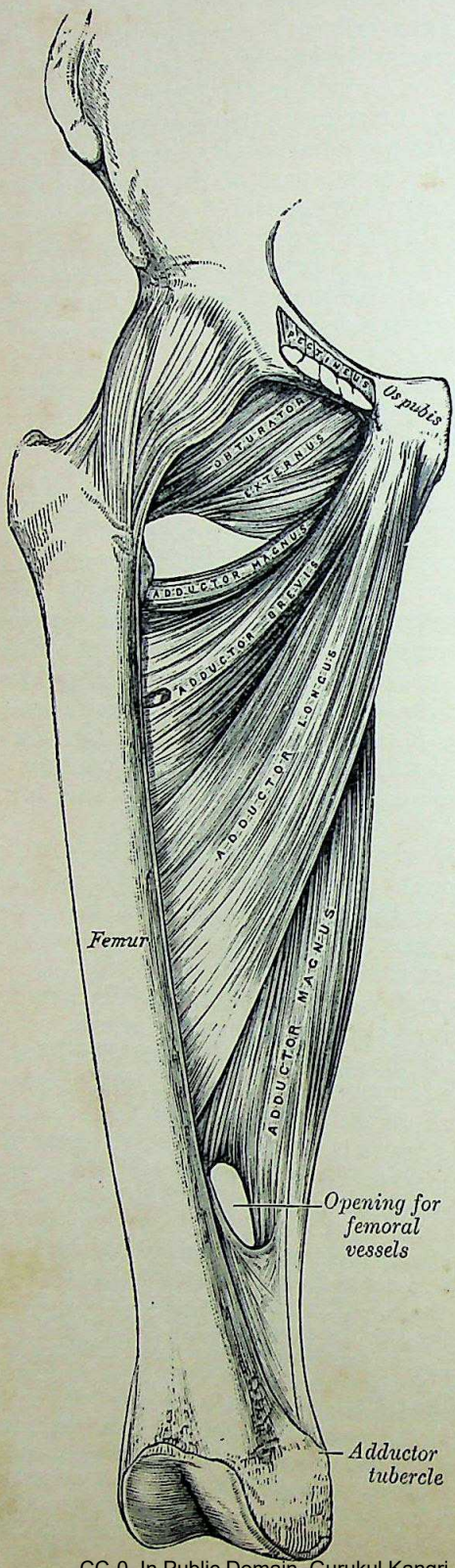

Nerve-supply.—The Gracilis is by the second and third lumbar through the obturator nerve.

Actions.—The Gracilis flexes and rotates it inwards; it also the thigh.

The **Pectineus** (fig. 598) flat, quadrangular muscle, situ the anterior part of the upper medial aspect of the thigh. It from the pecten pubis, and to a extent from the surface of bone in of it, between the iliopectineal e and pubic tubercle, and from the covering the anterior surface muscle; the fibres pass down backwards, and lateralwards, inserted into the femur, along leading from the lesser trocha the linea aspera.*

Relations.—Its *anterior surface* is tion with the fascia lata, which sep from the femoral vessels and great s vein; its *posterior surface*, with the of the hip-joint, the Adductor brevis rator externus, and the anterior b

* The Pectineus may consist of two pletely separated strata: the lateral or stratum, which is constant, is supp branch from the femoral nerve, or absence of this branch by the accesso ator nerve; the medial or ventral strat present, is supplied by the obturator ner M. Paterson, *Journal of Anatomy and Phy*

CC-0. In Public Domain. Gurukul Kangri Collection, Haridwar

Digitized by Arya Samaj Foundation Chennai and eGangotri

the obturator nerve; its *lateral border*, with the Psoas major and the medial femoral circumflex vessels; its *medial border*, with the margin of the Adductor longus.

Nerve-supply.—The Pectineus is supplied by the second and third lumbar nerves, through the femoral nerve; and by the third lumbar through the accessory obturator when this nerve is present. Occasionally it receives a branch from the obturator nerve.

Actions.—The Pectineus adducts the thigh and flexes it on the pelvis.

The Adductor longus (figs. 601, 602), the most superficial of the three adductors, is a triangular muscle, lying in the same plane as the Pectineus. It arises by a flat, narrow tendon, from the front of the os pubis in the angle between the crest and the symphysis. It soon expands into a broad fleshy plate which passes downwards, backwards, and lateralwards, and is inserted, by an aponeurosis, into the middle one-third of the linea aspera of the femur, between the Vastus medialis and the Adductor magnus, with both of which it is usually blended.

Relations.—Its *anterior surface* is in relation with the fascia lata, the Sartorius, and, near its insertion, with the femoral artery and vein; its *posterior surface*, with the Adductores brevis et magnus, the anterior branch of the obturator nerve, and near its insertion with the profunda femoris vessels; its *lateral border*, with the Pectineus; its *medial border*, with the Gracilis.

Nerve-supply.—The Adductor longus is supplied by the second and third lumbar nerves through the obturator nerve.

Actions.—The Adductor longus adducts the thigh, flexes it on the pelvis, and rotates it outwards.

Applied Anatomy.—The Adductor longus is liable to be severely strained in those who ride much on horseback, or its tendon may be ruptured by suddenly gripping the saddle. Occasionally, especially in cavalry soldiers, the tendon becomes ossified, constituting the 'rider's bone.'

The Adductor brevis (figs. 600, 601) is situated behind the Pectineus and the Adductor longus. It is somewhat triangular in form, and arises by a narrow origin from the outer surface of the inferior ramus of the os pubis, between the Gracilis and Obturator externus. Its fibres, passing backwards, lateralwards, and downwards, are inserted by an aponeurosis into the femur, along the line leading from the lesser trochanter to the linea aspera and into the upper part of the linea aspera, immediately behind the Pectineus and the upper part of the Adductor longus.

Relations.—Its *anterior surface* is in relation with the Pectineus, Adductor longus, the profunda femoris, and anterior branch of the obturator nerve; its *posterior surface*, with the Adductor magnus, and posterior branch of the obturator nerve; its *lateral border*, with the medial femoral circumflex artery, the Obturator externus, and conjoined tendon of the Psoas major and Iliacus; its *medial border*, with the Gracilis and Adductor longus. It is pierced near its insertion by the second, or first and second, perforating branches of the arteria profunda femoris.

Nerve-supply.—The Adductor brevis is supplied by the third and fourth lumbar nerves, through the obturator nerve.

Actions.—The Adductor brevis adducts the thigh, flexes it on the pelvis and rotates it outwards.

The Adductor magnus (figs. 600, 601, 602) is a large triangular muscle, situated on the medial side of the thigh. It arises from a small part of the inferior ramus of the os pubis, from the inferior ramus of the ischium, and from the lateral margin of the inferior part of the tuberosity of the ischium. Those fibres which arise from the ramus of the os pubis are short, horizontal in direction, and are inserted into the rough line leading from the greater trochanter of the femur to the linea aspera, medial to the Glutæus maximus*; those from the ramus of the ischium are directed downwards and lateralwards with different degrees of obliquity, to be inserted, by means of a broad aponeurosis, into the

* These uppermost fibres are sometimes described as a separate muscle—the *Adductor minimus* which is situated somewhat in front of the other parts of the muscle.

CC-0. In Public Domain. Gurukul Kangri Collection, Haridwar

Digitized by Arya Samaj Foundation Chennai and eGangotri

linea aspera and the upper part of this medial prolongation below. The portion of the muscle, composed principally of the fibres arising from tuberosity of the ischium, forms a thick fleshy mass which descends vertically, and ends about the lower one-third of the thigh in a rounded which is inserted into the adductor tubercle on the medial condyle femur, and is connected by a fibrous expansion to the line leading from the tubercle to the linea aspera. At the insertion of the muscle is a series of osseo-aponeurotic openings, formed by tendinous arches

FIG. 602.—A transverse section through the middle of the thigh. Four-fifths of natural size.

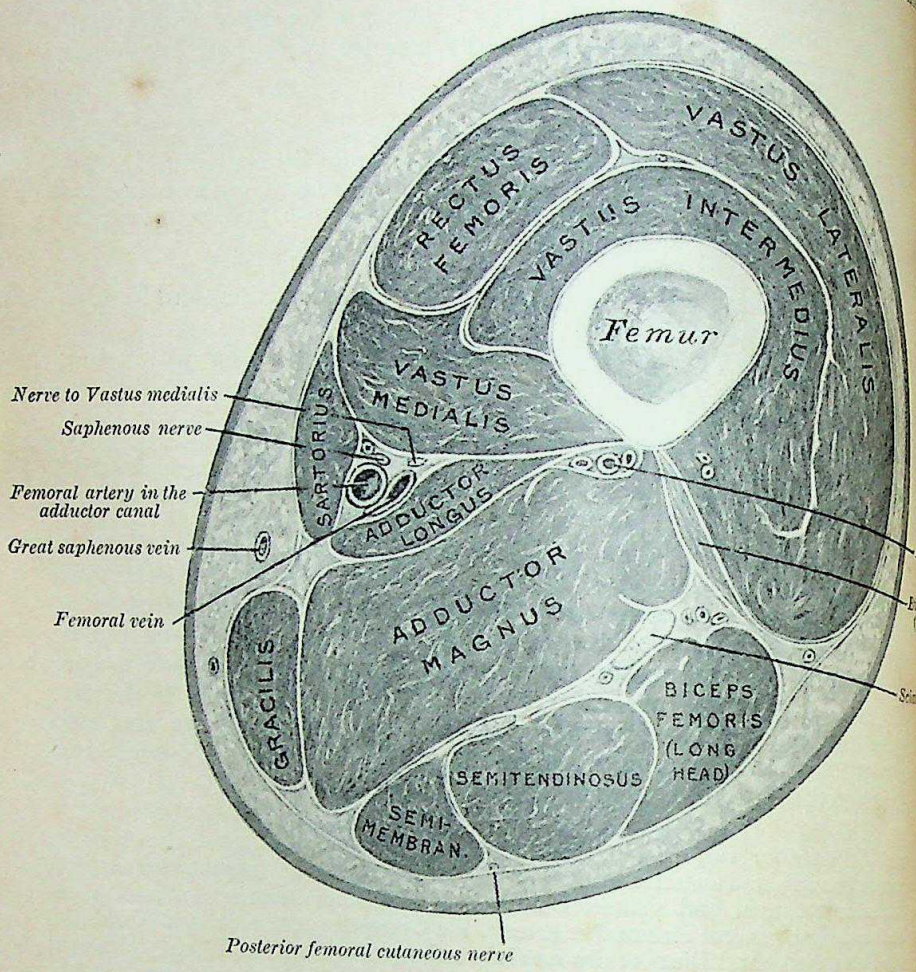

to the bone. The upper four openings are small, and give passage to perforating branches of the arteria profunda femoris. The lowest is of size, and transmits the femoral vessels to the popliteal fossa.

Relations.—Its *anterior surface* is in relation with the Pectineus, Adductores brev longus, the femoral and profunda vessels, and the posterior branch of the obturator a bursa intervenes between the highest part of the muscle and the lesser trochanter femur; its *posterior surface*, with the sciatic nerve, the Glutæus maximus, Biceps fem Semitendinosus, and Semimembranosus. Its *superior border* lies parallel with the ratus femoris, the superficial branch of the medial femoral circumflex artery passing bet them; its *medial border* is in relation with the Gracilis, Sartorius, and fascia lata.

Nerve-supply.—The Adductor magnus is supplied by the third and fourth lum nerves through the obturator nerve, and by a branch from the sacral through the sciatic nerve.

Actions.—The Adductor magnus adducts the thigh and rotates it outwa it also flexes the thigh on the pelvis. The Pectineus and the Adductores ad the thigh powerfully; they are especially used in horse exercise, the sides of

CC-0. In Public Domain. Gurukul Kangri Collection, Haridwar

Digitized by Arya Samaj Foundation Chennai and eGangotri

while being grasped between the knees by the contraction of these muscles; they rotate the thigh outwards, and when the limb has been abducted, they draw it inwards, carrying the thigh across that of the opposite side. In progression, they assist in drawing forwards the lower limb. If the lower extremities be fixed, the muscles, taking their fixed points below, act upon the pelvis, serving to maintain the body in an erect posture; or, if their action be continued, flex the pelvis forwards upon the femur.

3. The Muscles of the Glutæal Region

Glutæus maximus.
Glutæus medius.
Glutæus minimus.
Piriformis.
Obturator externus.
Obturator internus.
Gemellus superior.
Gemellus inferior.
Quadratus femoris.

The **Glutæus maximus** (fig. 603), the largest and most superficial muscle in the glutæal region, is a broad and thick fleshy mass of a quadrilateral shape, and

Fig. 603.—The right glutæus maximus muscle.

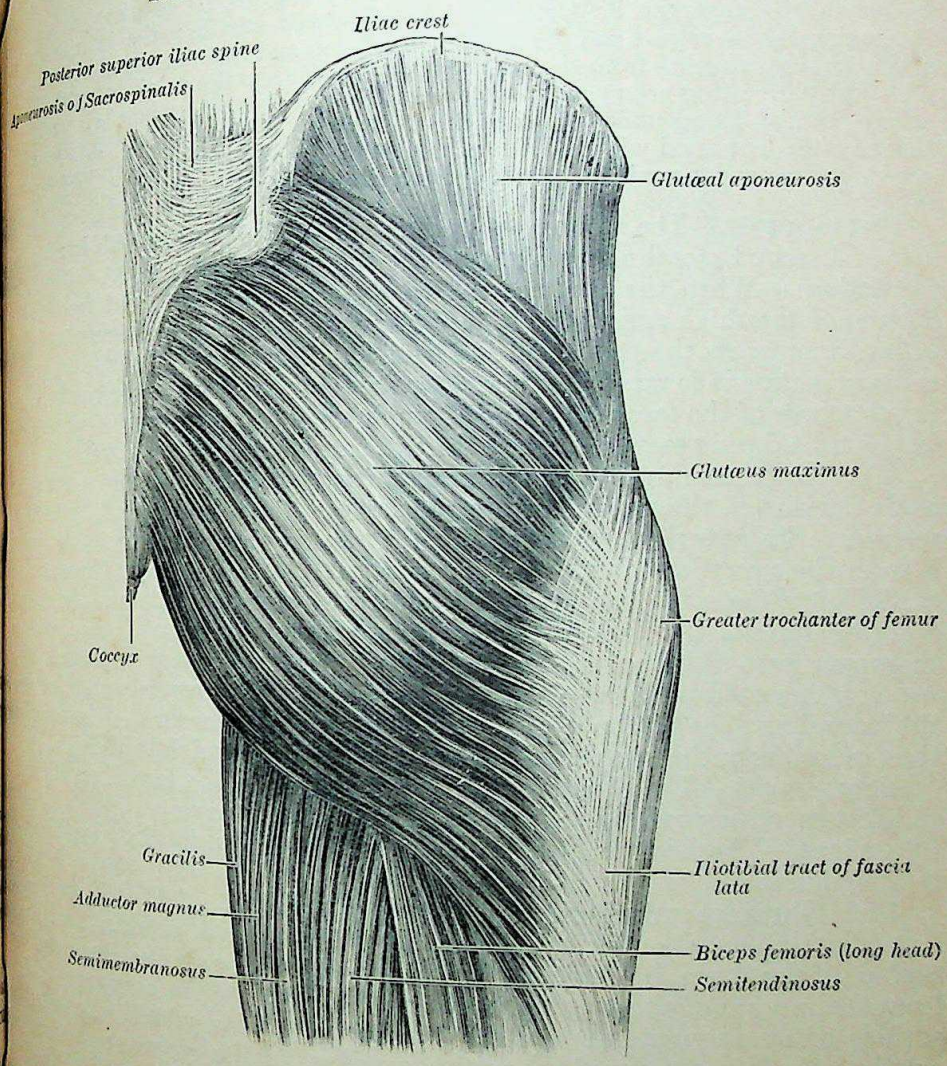

forms the prominence of the buttock. Its large size is one of the most characteristic features of the muscular system in man, connected as it is with the power he has of maintaining the trunk in the erect posture. The muscle is remarkably coarse in structure, being made up of fasciculi lying parallel with one another, and collected into large bundles separated by fibrous septa. It

CC-0. In Public Domain. Gurukul Kangri Collection, Haridwar

Digitized by Arya Samaj Foundation Chennai and eGangotri

arises from the posterior glutæal line of the ilium, and the rough portion of the ilium including the crest, immediately above and behind it; from the aponeurosis of the lower part of the Sacrospinalis; from the posterior surface of the sacrum, and from the side of the coccyx; from the sacrotuberous ligament, and from the deep fascia (glutæal aponeurosis) covering the Glutæus medius. The fibres forming the upper part of the muscle run obliquely downwards and lateralwards; those forming the upper and middle portion of the muscle, together with the superficial fibres of the lower part, pass across the greater trochanter, and end in a thick tendinous lamina, which passes across the fascia lata; the deeper fibres of the lower portion of the muscle are inserted into the glutæal tuberosity of the femur between the Vastus lateralis and Adductor magnus.

Three *bursæ* are usually found in relation with the deep surface of the muscle. One, of large size, and generally multilocular, separates it from the greater trochanter; a second, often wanting, is situated on the tuber of the ischium; a third is found between the tendon of the muscle and the Vastus lateralis.

Relations.—Its *superficial surface* is in relation with a thin fascia which separates it from the subcutaneous tissue; its *deep surface*, with the ilium, sacrum, coccyx, sacrotuberous ligament, part of the Glutæus medius, Piriformis, Gemelli, Obturator internus, Quadratus femoris, the tuberosity of the ischium, greater trochanter, the origin of the Biceps femoris, Semitendinosus, Semimembranosus, and the Adductor magnus. The superficial part of the superior glutæal artery reaches the deep surface of the muscle by passing between the Piriformis and the Glutæus medius; the inferior glutæal, internal pudendal vessels and the sciatic, pudendal, and lateral femoral cutaneous nerves and muscular branches from the sacral plexus, issue from the pelvis below the Piriformis. The first perforating artery and the terminal branches of the medial circumflex femoral artery are also found under cover of the lower part of the muscle. Its *upper border* is thin, and is connected with the Glutæus medius by the glutæal aponeurosis. Its *lower border* is free and prominent, and is crossed by the fold of the nates.

Nerve-supply.—The Glutæus maximus is supplied by the fifth lumbar and first and second sacral nerves through the inferior glutæal nerve.

Actions.—When the Glutæus maximus takes its fixed point from the pelvis it extends the thigh and brings it into line with the trunk. Taking its fixed point below, it supports the pelvis and the trunk upon the head of the femur. Its most powerful action is to raise the trunk after stooping by drawing the pelvis backwards. It is a tensor of the fascia lata, and through the iliotibial tract it steadies the femur on the tibia during standing, when the extensor muscles are relaxed.

The **Glutæus medius** is a broad, thick, radiating muscle, situated on the outer surface of the pelvis. Its posterior one-third is covered by the Glutæus maximus, its anterior two-thirds by the glutæal aponeurosis, which separates it from the superficial fascia and integument. It arises from the outer surface of the ilium between the iliac crest and posterior glutæal line above, and the anterior glutæal line below; it also arises from the strong fascia which covers the upper part of its outer surface. The fibres converge to a flattened tendon which is inserted into the oblique ridge directed downwards and forwards on the lateral surface of the greater trochanter of the femur. A bursa separates the tendon from the surface of the trochanter over which it glides.

Nerve-supply.—The Glutæus medius is supplied by the fourth and fifth lumbar and first sacral nerves, through the superior glutæal nerve.

Actions.—The Glutæus medius abducts the thigh; its anterior fibres rotate the thigh inwards.

The **Glutæus minimus** (fig. 604), the smallest of the Glutæi, is placed immediately beneath the preceding. It is fan-shaped, arising from the outer surface of the ilium, between the anterior and inferior glutæal lines, and below from the margin of the greater sciatic notch. The fibres converge to the outer surface of an aponeurosis, and this ends in a tendon which is inserted into a ridge on the lateral part of the anterior surface of the greater trochanter of the femur, and gives an expansion to the capsule of the hip-joint. A bursa is interposed between the tendon and the medial part of the anterior surface of the greater trochanter.

Between the Glutæus medius and Glutæus minimus are the deep branches of the superior glutæal vessels, and the superior glutæal nerve. Deep to the Glutæus minimus are the reflected tendon of the Rectus femoris and the capsule of the hip-joint.

CC-0. In Public Domain. Gurukul Kangri Collection, Haridwar

Digitized by Arya Samaj Foundation Chennai and eGangotri

Fig. 604.—The muscles of the glutæal region and the posterior femoral muscles. Right side.

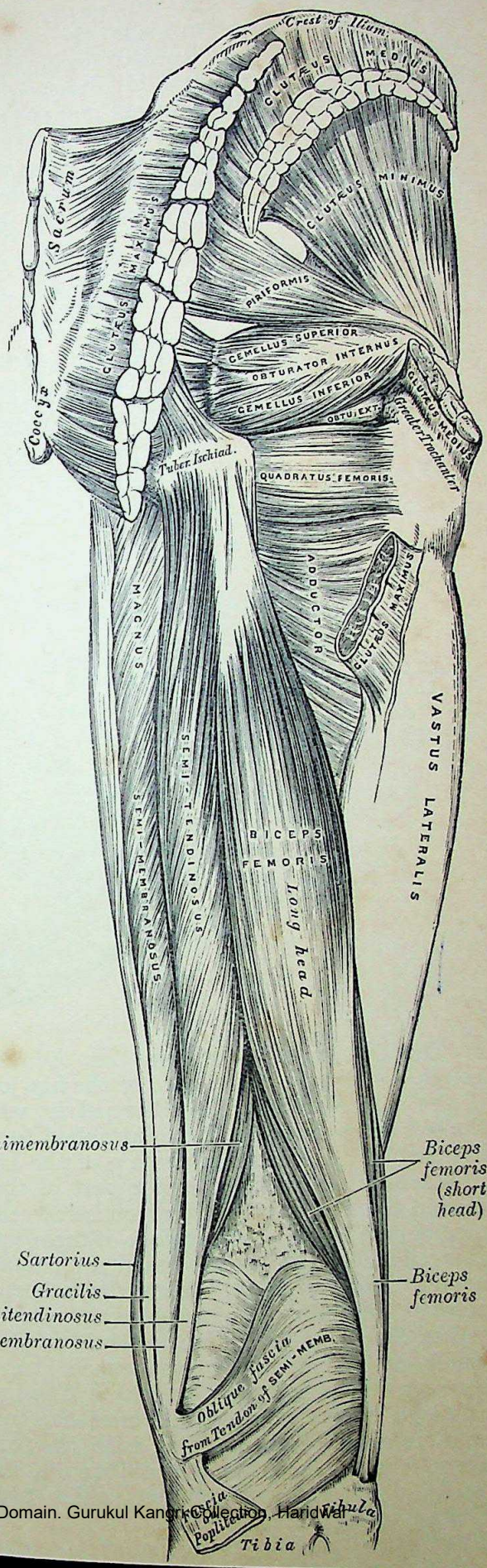

Nerve-supply.—The Glutæus medius is supplied by the fourth and fifth lumbar and first sacral nerves, through the superior glutæal nerve.

Actions. — The Glutæus medius is an abductor of the thigh; its anterior fibres rotate the thigh inwards.

The **Piriformis** (fig. 604) lies almost parallel with the posterior margin of the Glutæus medius. It is situated partly within the pelvis and partly at the back of the hip-joint. It arises from the front of the sacrum by three fleshy digitations, attached to portions of bone between the anterior sacral foramina, and to the grooves leading from the foramina: a few fibres also arise from the margin of the greater sciatic foramen, and from the anterior surface of the sacrotuberous ligament. The muscle passes out of the pelvis through the greater sciatic foramen, and is inserted by a rounded tendon into the upper border of the greater trochanter of the femur, behind and above, but partly blended with, the common tendon of the Obturator internus and Gemelli.

Relations.—*Within the pelvis* the *anterior surface* of the Piriformis is in relation with the rectum (especially on the left side), the sacral plexus of nerves, the branches of the hypogastric vessels; its *posterior surface* with the sacrum. *Outside the pelvis*, its *anterior surface* is in contact with the posterior surface of the rectum and capsule of the hip-joint, and its *posterior surface*, with the Glutæus maximus. Its *upper border* is in relation with the Glutæus medius, and the superior glutæal vessels and nerve; its *lower border*, with the Gemelli superior and Coccygeus. Inferior glutæal and internal pudendal vessels, and the sciatic, posterior femoral cutaneous, and pudendal nerves, and muscular branches from the sacral plexus, appear on the buttock between the Piriformis and Gemellus superior. The muscle is frequently pierced by the common

CC-0. In Public Domain. Gurukul Kangri Collection, Haridwar

Digitized by Arya Samaj Foundation Chennai and eGangotri

Nerve-supply.—The Piriformis is supplied by twigs from the first and sacral nerves.

Action.—The Piriformis rotates the thigh outwards.

The **obturator membrane** (fig. 605) is a thin fibrous sheet, which completely closes the obturator foramen. Its fibres are arranged in two bundles mainly transverse in direction; the uppermost bundle is attached to the obturator tubercles and completes the obturator canal for the passage of the obturator vessels and nerve. The membrane is attached to the margin of the obturator foramen except at its lower lateral angle, where it is fixed to the pelvic surface of the inferior ramus of the ischium, i.e. to the margin. Both Obturator muscles are connected with this membrane.

FIG. 605.—The left obturator membrane. External aspect.

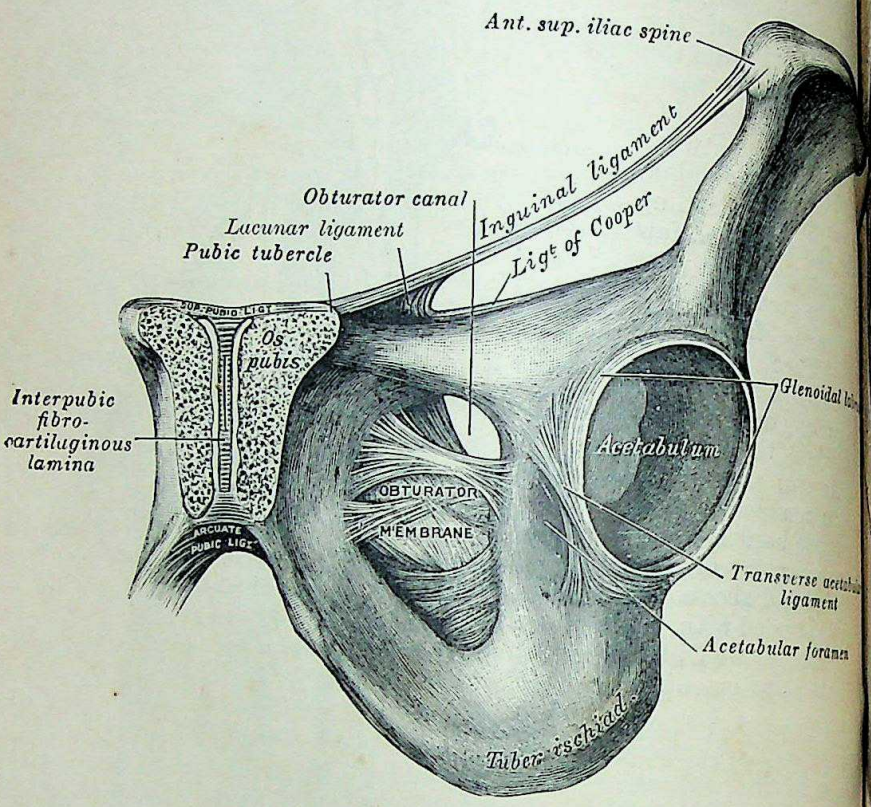

The **Obturator internus** (fig. 606) is situated partly within the lesser pelvis, and partly at the back of the hip-joint. It arises from the inner surface of the anterolateral wall of the pelvis, where it surrounds the greater part of the obturator foramen, being attached to the inferior rami of the os pubis and ischium and to the inner surface of the hip-bone below and behind the pelvic brim, reaching from the upper part of the greater sciatic foramen above and behind to the obturator foramen below and in front. It also arises from the medial part of the pelvic surface of the obturator membrane, from the tendinous arch which completes the canal for the passage of the obturator vessels and nerve, and to a slight extent from the obturator fascia, which covers the muscle. The fibres converge rapidly towards the lesser sciatic foramen and end in four or five tendinous bands on the deep surface of the muscle; these bands are reflected at a right angle over the grooved surface of the ischium between its spine and tuberosity. The grooved surface is covered by synovial cartilage, which is separated from the tendon by a bursa, and presents two or more ridges corresponding with the furrows between the tendinous bands. These bands leave the pelvis through the lesser sciatic foramen and unite into a single flattened tendon, which passes horizontally across the capsule of the hip-joint, and, after receiving the attachments of the Gemelli, is inserted into the fore part of the medial surface of the greater trochanter of the femur.

CC-0. In Public Domain. Gurukul Kangri Collection, Haridwar

Digitized by Arya Samaj Foundation Chennai and eGangotri

e and in front of the trochanteric fossa. A bursa, narrow and elongated rm, is usually found between the tendon and the capsule of the hip-joint; asionally communicates with the bursa between the tendon and the

ations.—*Within the pelvis*, the *anterolateral surface* of the muscle is in relation the obturator membrane and inner surface of the anterior wall of the pelvis; its *surface*, with the obturator fascia, and the origin of the Levator ani, and with the

Fig. 606.—The left Obturator internus. Pelvic aspect.

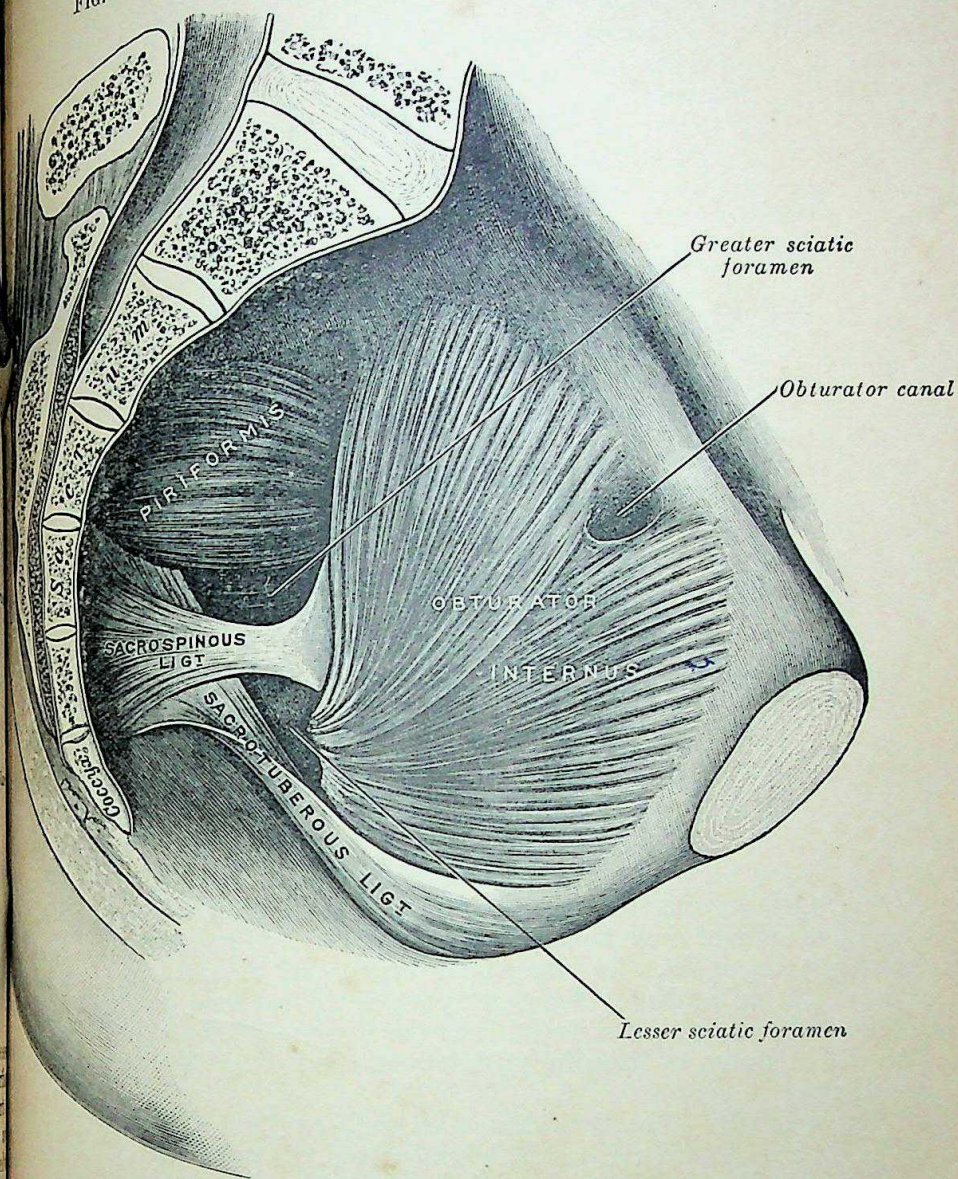

l pudendal vessels and pudendal nerve, which cross it. The pelvic surface forms ral boundary of the ischiorectal fossa. *Outside the pelvis*, the muscle is covered e Glutæus maximus, crossed by the sciatic nerve, and rests on the back of the . As the tendon of the Obturator internus emerges from the lesser sciatic it is overlapped both in front and behind by the two Gemelli which form a canal for it; near its insertion the Gemelli pass in front of the tendon and form e in which it lies.

rve-supply.—The Obturator internus is supplied by a branch which receives es from the fifth lumbar and first and second sacral nerves.

ction.—The Obturator internus rotates the thigh outwards.

e Gemelli (fig. 604) are two small muscular fasciculi, accessories to the n of the Obturator internus which is received into a groove between them.

CC-0. In Public Domain. Gurukul Kangri Collection, Haridwar

Digitized by Arya Samaj Foundation Chennai and eGangotri

The **Gemellus superior**, the smaller of the two, arises from surface of the spine of the ischium, blends with the upper part of of the Obturator internus, and is inserted with it into the medial the greater trochanter of the femur. It is sometimes wanting.

Nerve-supply.—The Gemellus superior is supplied by the fifth lumbar and second sacral nerves, through the nerve to the Obturator internus.

The **Gemellus inferior** arises from the upper part of the tuber the ischium, immediately below the groove for the Obturator intern It blends with the lower part of the tendon of the Obturator intern is inserted with it into the medial surface of the greater trochanter.

Nerve-supply.—The Gemellus inferior is supplied by the fourth and first sacral nerves through the nerve to the Quadratus femoris.

Actions.—The Gemelli superior et inferior rotate the thigh outwards.

Fig. 607.—The left Obturator externus.

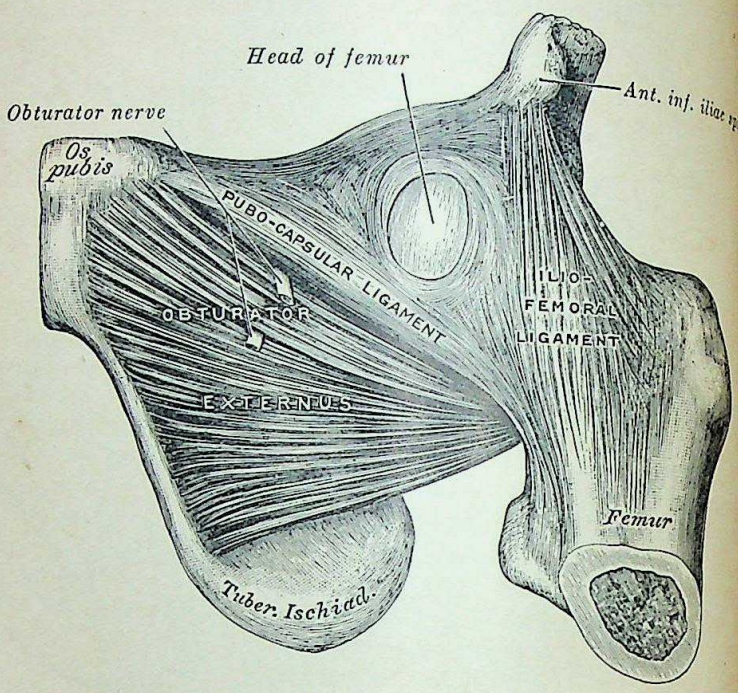

The **Quadratus femoris** (fig. 604) is a flat, quadrilateral muscle, betw Gemellus inferior and the upper margin of the Adductor magnus; it is sep from the latter by the superficial branch of the medial femoral circ artery. It arises from the upper part of the external border of the tube of the ischium, and is inserted into the upper part of the linea quadrata femur. A bursa is often found between the front of this muscle and the trochanter.

Nerve-supply.—The Quadratus femoris is supplied by a branch which its fibres from the fourth and fifth lumbar and first sacral nerves.

Action.—The Quadratus femoris is an external rotator of the thigh.

The **Obturator externus** (fig. 607) is a flat, triangular muscle, which the outer surface of the anterior wall of the pelvis. It arises from the of bone immediately around the medial side of the obturator foramen from the rami of the os pubis, and the inferior ramus of the ischium; arises from the medial two-thirds of the outer surface of the obturator brane, and from the tendinous arch which completes the canal for the of the obturator vessels and nerves. The fibres springing from the ramus of the ischium extend on to the inner surface of the bone, where obtain a narrow origin between the margin of the foramen and the attach of the obturator membrane. The fibres converge and pass backwards, wards, and upwards, and end in a tendon which runs across the back neck of the femur and lower part of the capsule of the hip-joint and is into the trochanteric fossa of the femur. The obturator vessels lie be

CC-0. In Public Domain. Gurukul Kangri Collection, Haridwar

Digitized by Arya Samaj Foundation Chennai and eGangotri

muscle and the obturator membrane; the anterior branch of the obturator reaches the thigh by passing in front of the muscle, and the posterior by piercing it.

Nerve-supply.—The Obturator externus is supplied by the third and fourth nerves through the obturator nerve.

Action.—The Obturator externus is an external rotator of the thigh.

4. The Posterior Femoral Muscles (fig. 604)

Biceps femoris. Semitendinosus. Semimembranosus.

The **Biceps femoris** (figs. 600, 602, 604) is situated on the posterolateral back of the thigh. It has two heads of origin: one, the long head, arises from the lower and medial impression on the posterior part of the ischial tuberosity, by a tendon common to it and the Semitendinosus, and from the lower part of the sacrotuberous ligament; the other, the short head, from the lateral lip of the linea aspera of the femur, between the Adductor magnus and Vastus lateralis, extending up almost as high as the insertion of the Gluteus maximus; from the lateral prolongation of the linea aspera to within 5 cm. of the lateral condyle; and from the lateral intermuscular septum. The fibres of the long head form a fusiform belly, which passes downwards and lateralwards across the sciatic nerve to end in an aponeurosis; this aponeurosis covers the posterior surface of the muscle, receives on its deep surface the fibres of the short head, and gradually contracts into a tendon, which is inserted into the lateral side of the head of the fibula, and by a small slip into the lateral condyle of the tibia. This tendon forms the lateral hamstring and divides into two portions which embrace the fibular collateral ligament of the knee-joint; from its posterior border a thin expansion is given off to the fascia of the leg. The common peronæal nerve descends along its medial border.

Nerve-supply.—The Biceps femoris is supplied by the fifth lumbar, and first, second and third sacral nerves; the long head through the tibial nerve, the short head through the common peronæal nerve.

Actions.—The Biceps femoris, acting from above, flexes the leg on the thigh, and when the knee is semiflexed rotates the leg slightly outwards. Acting from below it serves to support the pelvis on the head of the femur and draws the trunk backwards as in raising it from the stooping position.

The **Semitendinosus** (figs. 602, 604), remarkable for the great length of its tendon of insertion, is situated at the posterior and medial aspect of the thigh. It arises from the lower and medial impression on the tuberosity of the ischium, by a tendon common to it and the long head of the Biceps femoris; it also arises from an aponeurosis connecting the adjacent surfaces of the two muscles to the extent of about 7·5 cm. from their origin. The belly is fusiform and ends a little below the middle of the thigh in a long flat tendon which lies along the medial side of the popliteal fossa; the tendon curves around the medial condyle of the tibia, passes over the tibial collateral ligament of the knee-joint, from which it is separated by a bursa, and is inserted into the upper part of the medial surface of the body of the tibia behind the insertion of the Sartorius and below that of the Gracilis. Near its insertion it is united with the tendon of the Gracilis and gives off a prolongation to the deep fascia of the leg. A tendinous intersection is usually observed about the middle of the muscle.

Nerve-supply.—The Semitendinosus is supplied by the fifth lumbar, and first, second and third sacral nerves, through the tibial nerve.

Actions.—Acting from above it flexes the knee-joint, and when the joint is flexed rotates the leg slightly inwards. When its fixed point is below its action is similar to that of the Biceps femoris.

The **Semimembranosus** (figs. 602, 604, 608), so called from its membranous form of origin, is situated at the back and medial side of the thigh. It arises by a thick tendon from the upper and lateral impression on the tuberosity of the ischium, above and lateral to the Biceps femoris and Semitendinosus, and is inserted into the groove on the back of the medial condyle of the tibia.

CC-0. In Public Domain. Gurukul Kangri Collection, Haridwar

Digitized by Arya Samaj Foundation Chennai and eGangotri

The tendon of origin expands into an aponeurosis, which passes d under cover of the Semitendinosus and long head of the Biceps femo this aponeurosis muscular fibres arise, and converge to another a which covers the lower part of the posterior surface of the muscle and into the tendon of insertion. The tendon of insertion gives off cert expansions: one, of considerable size, passes upwards and lateral inserted into the back part of the lateral condyle of the femur, for of the oblique popliteal ligament of the knee-joint; a second is downwards to the fascia which covers the Popliteus muscle; while a

FIG. 608.—A transverse section through the thigh, 4 cm. proximal to th adductor tubercle of the femur. Four-fifths of natural size.

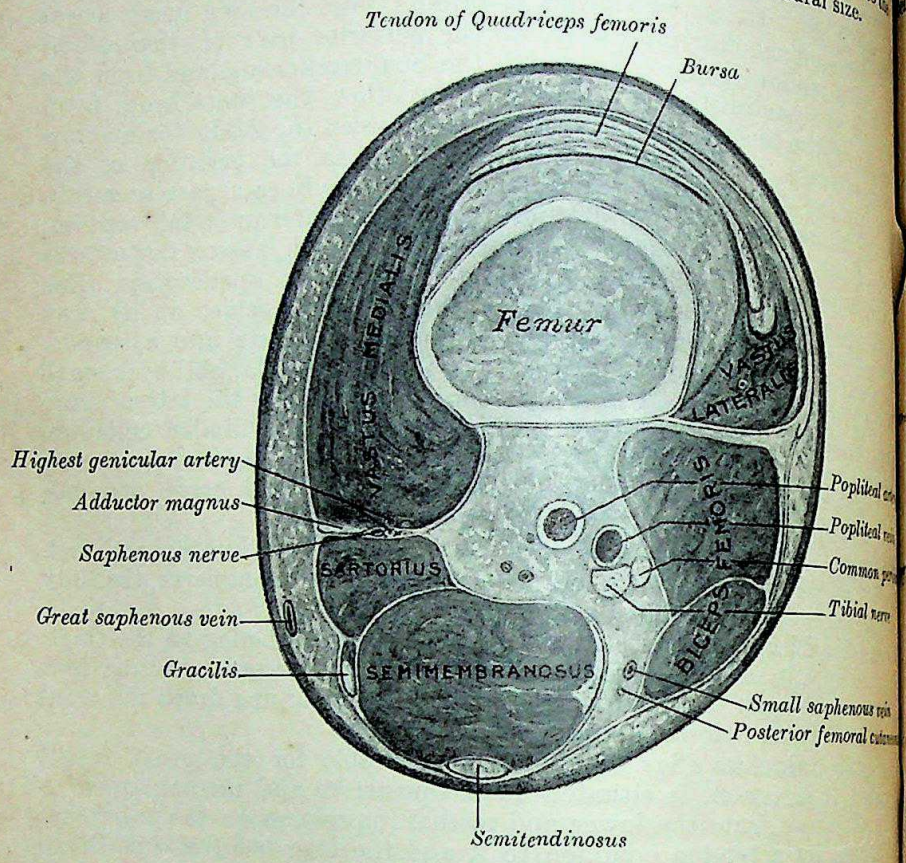

join the tibial collateral ligament of the knee-joint and the fascia of th The muscle overlaps the upper part of the popliteal vessels.

The tendons of insertion of the Semitendinosus and Semimembranosu the medial hamstrings.

Nerve-supply.—The Semimembranosus is supplied by the fifth lumbar and second and third sacral nerves through the tibial nerve.

Actions.—The actions of the Semimembranosus are similar to those o Semitendinosus.

Applied Anatomy.—In disease of the knee-joint, contraction of the ham tendons is a frequent complication; this causes flexion of the leg, and a partial dislo of the tibia backwards, with a slight degree of rotation outwards, probably due action of the Biceps femoris. The hamstring tendons occasionally require subcut division in some forms of spurious ankylosis of the knee-joint dependent upon perm contraction and rigidity of the muscles, or from contracture of the ligamentous and tissues surrounding the joint, the result of disease. The relation of the common p nerve, which lies in close apposition to the medial border of the tendon of the femoris, must always be borne in mind in dividing this tendon, and a free incision exposure of the tendon, before division, is the safer proceeding.

In the operation of stretching the sciatic nerve to cure sciatica the tendon of orig the Semimembranosus may be mistaken for the nerve.

CC-0. In Public Domain. Gurukul Kangri Collection, Haridwar

Digitized by Arya Samaj Foundation Chennai and eGangotri

III. The Muscles of the Leg

e muscles of the leg may be divided into three groups: anterior, posterior, teral.

1. The Anterior Crural Muscles (fig. 610)

Tibialis anterior.
Extensor hallucis longus.
Extensor digitorum longus.
Peronæus tertius.

The fascia cruris or deep fascia of the leg is continuous above with the ta lata, and is attached around the knee to the patella, the ligamentum lle, the tuberosity and condyles of the tibia, and the head of the fibula.

FIG. 609.—A transverse section through the leg, 9 cm. distal to the knee-joint.

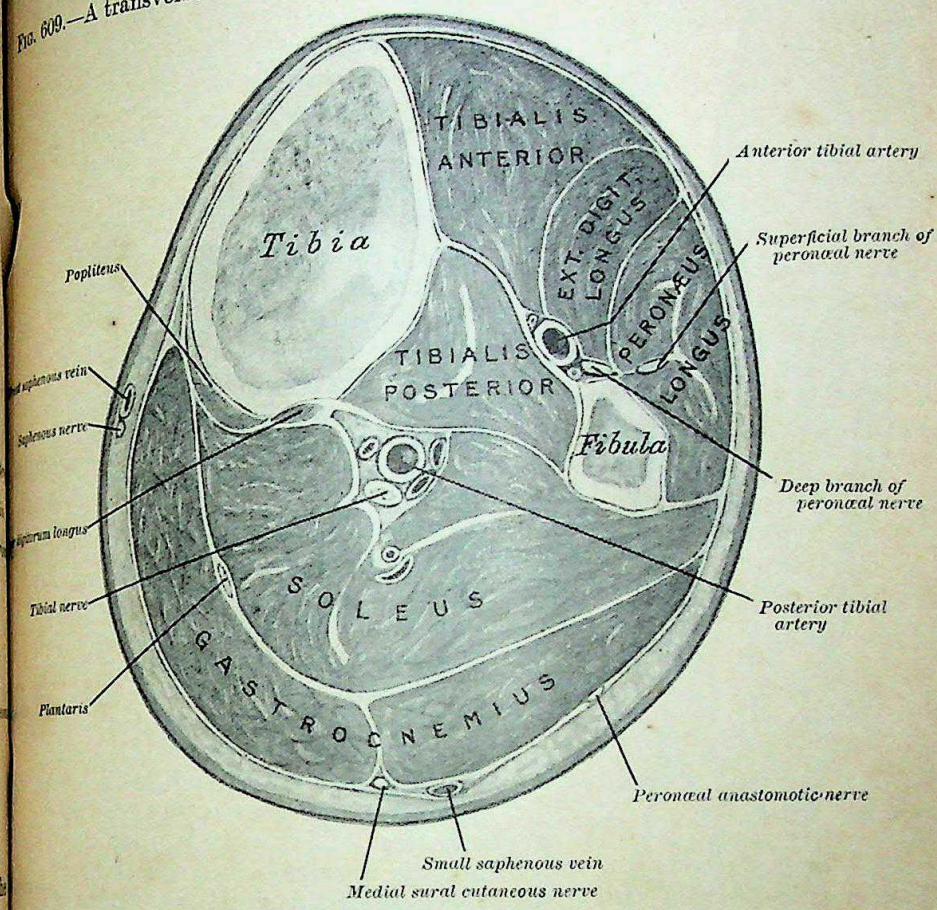

nd, it forms the popliteal fascia which covers the popliteal fossa; here it engthened by transverse fibres, and perforated by the small saphenous It receives an expansion from the tendon of the Biceps femoris laterally, xpansions from the tendons of the Sartorius, Gracilis, Semitendinosus, Semimembranosus medially; it blends with the periosteum covering the utaneous surface of the tibia, and with that covering the head and malleolus the fibula; below, it is continuous with the transverse crural and laciniate ents. It is thick and dense in the upper and anterior part of the leg, and origin, by its deep surface, to some fibres of the Tibialis anterior and sor digitorum longus; it is thinner behind, where it covers the Gastro- nius and Soleus. On the lateral side of the leg it gives off the *anterior* and *rior fibular intermuscular septa* which are attached respectively to the olateral and posterolateral borders of the fibula; in the anterior and rior crural regions the fascia also gives off several slender processes which the individual muscles. A broad transverse intermuscular septum, the *deep transverse fascia of the leg*, intervenes between the superficial deep posterior crural muscles.

CC-0. In Public Domain. Gurukul Kangri Collection, Haridwar

Digitized by Arya Samaj Foundation Chennai and eGangotri

Fig. 610.—The right anterior crural muscles.

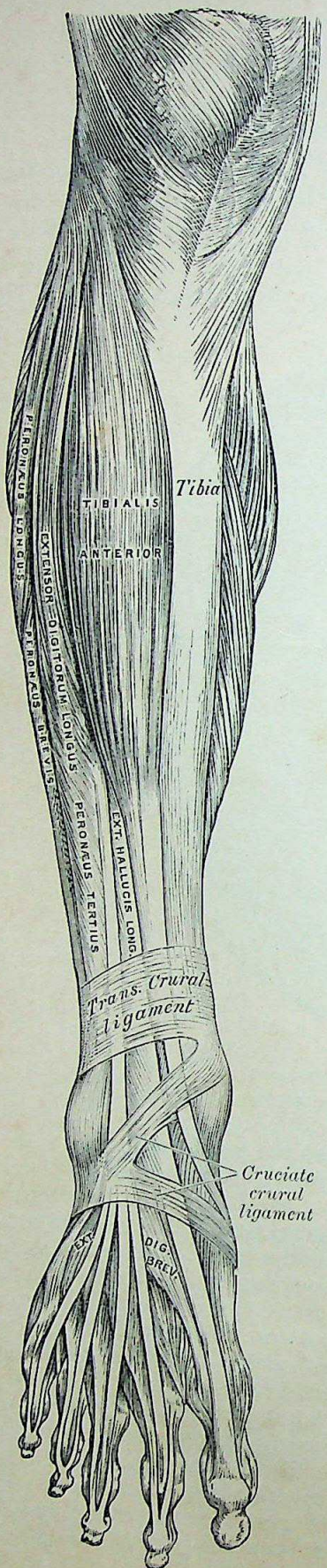

The **Tibialis anterior** (figs. 609, 610) is situated on the lateral side of the tibia, thick and fleshy above, tendinous below. It arises from the lateral condyle and upper half or two-thirds of the lateral surface of the body of the tibia; from the adjoining part of the anterior surface of the interosseous membrane; from the deep surface of the fascia cruris; and from the intermuscular septum between it and the Extensor digitorum longus. The fibres run vertically downwards, and end in a tendon which is apparent on the lower part of the muscle at the lower end of the leg; after passing through the middle compartments of the transverse and cruciate crural ligaments, it is inserted into the medial and under surfaces of the first cuneiform bone and the base of the first metatarsal bone. This muscle overlaps the anterior tibial vessels and deep peronæal nerve in the upper part of the leg.

Nerve-supply.—The Tibialis anterior is supplied by the fourth and fifth lumbar and first sacral nerves, through the deep peronæal nerve.

Actions.—The Tibialis anterior is a flexor of the ankle-joint; it also raises the medial edge of the foot, i.e. inverts the foot.

The **Extensor hallucis longus** (figs. 609, 615) is a thin muscle, situated between the Tibialis anterior and the Extensor digitorum longus. It arises from the anterior surface of the fibula for about the middle two-fourths of its extent, medial to the origin of the Extensor digitorum longus; it also arises from the anterior surface of the interosseous membrane to a similar extent. The anterior tibial vessels and deep peronæal nerve lie between it and the Tibialis anterior. The fibres pass downwards, and end in a tendon, which crosses the anterior border of the muscle, passes through a compartment in the cruciate crural ligament, crosses to the medial side of the anterior tibial vessels near the ankle-joint, and is inserted into the base of the distal phalanx of the great toe. Opposite the metatarsophalangeal articulation a thin prolongation is given off from either side of the tendon to cover the dorsal surface of the joint. The expansion from the medial side of the tendon is usually inserted into the base of the proximal phalanx.

Nerve-supply.—The Extensor hallucis longus is supplied by the fourth and fifth lumbar and first sacral nerves through the deep peronæal nerve.

Actions. — The Extensor hallucis longus extends the phalanges of the great toe; in continued action it flexes the ankle-joint.

The **Extensor digitorum longus** (figs. 609, 610, 615) is a pennate muscle, situated on the lateral part of the front of the leg. It arises from the lateral condyle of the tibia, the upper three-fourths of the anterior surface

CC-0. In Public Domain. Gurukul Kangri Collection, Haridwar

Digitized by Arya Samaj Foundation Chennai and eGangotri

the body of the fibula, the upper part of the anterior surface of the rosseous membrane, the deep surface of the fascia cruris, the anterior fibular rmuscular septum and the septum between it and the Tibialis anterior. ween it and the Tibialis anterior are the upper portions of the anterior vessels and the deep peronæal nerve. The tendon passes under the verse and cruciate crural ligaments in company with the Peronæus tertius, divides into four slips, which run forward on the dorsum of the foot, are inserted into the second and third phalanges of the four lesser toes. tendons to the second, third, and fourth toes are each joined, opposite the tarsophalangeal articulation, on the lateral side by a tendon of the tensor digitorum brevis. The tendons are inserted as follows: each receives rous expansion from the corresponding Lumbricalis and Interossei, and spreads out into a broad aponeurosis, which covers the dorsal surface of first phalanx; at the articulation of the first with the second phalanx this neurosis divides into three slips—an intermediate, which is inserted into the of the second phalanx; and two collateral slips, which, after uniting one another on the dorsal surface of the second phalanx, are inserted the base of the third phalanx.

Nerve-supply.—The Extensor digitorum longus is supplied by the fourth and lumbar and first sacral nerves, through the deep peronæal nerve.

Actions.—The Extensor digitorum longus extends the phalanges of the toes, when its action is continued flexes the ankle-joint.

The **Peronæus tertius** (figs. 610, 615) is a part of the Extensor digitorum is, and might be described as its fifth tendon. The fibres belonging to tendon arise from the lower one-third or more of the anterior surface of fibula, the lower part of the anterior surface of the interosseous mem- e, and the anterior fibular intermuscular septum. The tendon passes er the transverse and cruciate crural ligaments in the same compartment the Extensor digitorum longus, and is inserted into the dorsal surface of base of the fifth metatarsal bone, but often spreads into a thin sheet h extends forwards along the shaft of the bone. This muscle is some- s wanting.

Nerve-supply.—The Peronæus tertius is supplied by the fourth and fifth lumbar first sacral nerves, through the deep peronæal nerve.

Actions.—The Peronæus tertius flexes the ankle-joint; it also raises the al border of the foot, i.e. everts the foot.

2. The Posterior Crural Muscles

The muscles of the back of the leg are subdivided into two groups—superficial deep. Those of the superficial group constitute a powerful muscular forming the calf of the leg. Their large size is one of the most acteristic features of the muscular apparatus in man, and bears a direct on to his erect attitude and his mode of progression.

Superficial Group (fig. 611).

Gastrocnemius. Soleus. Plantaris.

The **Gastrocnemius** (figs. 609, 611) is the most superficial of the group, forms the greater part of the calf. It arises by two heads, which are ected to the condyles of the femur by strong, flat tendons. The medial larger head takes its origin from a depression at the upper and posterior of the medial condyle behind the adductor tubercle, and from a rounded cle on the popliteal surface of the femur just above the medial condyle. lateral head arises from an impression on the lateral surface of the lateral yle and from the lower part of the corresponding epicondylar ridge. Both s also arise from the subjacent part of the articular capsule of the knee Each head spreads out into a tendinous expansion which covers the rior surface of the corresponding part of the muscle. From the anterior aces of these tendinous expansions, muscular fibres are given off; those of medial head being thicker and extending lower than those of the lateral

CC-0. In Public Domain. Gurukul Kangri Collection, Haridwar

Digitized by Arya Samaj Foundation Chennai and eGangotri

The fibres unite at an angle in the middle line of the muscle, in a te raphe which expands into a broad aponeurosis on the anterior surface muscle, and into this the remaining fibres are inserted. The apo gradually contracting, unites w tendon of the Soleus, and forms with the tendo calcaneus.

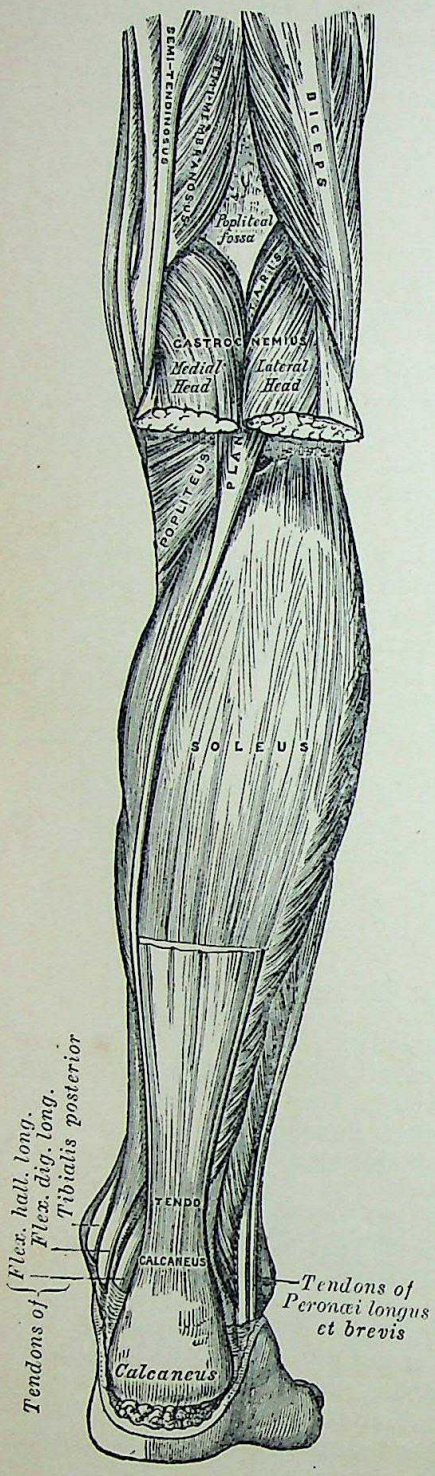

FIG. 611.—The right posterior crural muscles. Superficial group.

Relations.—The fascia cruris separ *superficial surface* of the muscle from saphenous vein, and the peronæal and medial sural cutaneous, and sural nerves common peronæal nerve crosses the lat of the muscle, lying partly under cover of femoris. The *deep surface* is in relat the oblique popliteal ligament of the kn the Popliteus, Soleus, Plantaris, vessels, and tibial nerve. In front tendon of the medial head is a bursa, some cases, communicates with the ca the knee-joint. The tendon of the latera sometimes contains a sesamoid fibrocart bone, where it plays over the corresp condyle; and one is occasionally found in tendon of the medial head.

Nerve-supply.—The Gastrocnem supplied by the first and second nerves, through the tibial nerve.

Actions.—Acting from above the Ga nemius extends the ankle-joint; acting below it flexes the knee-joint.

The **Soleus** (figs. 609, 611) is a flat muscle situated immediately in of the Gastrocnemius. It arises by dinous fibres from the back of the and from the upper one-fourth of posterior surface of the body, of the fi from the popliteal line and the m one-third of the medial border of the ti and from a fibrous band which stre between these origins and arches over popliteal vessels and tibial nerve. muscular fibres end in a flat tendon w covers the posterior surface of the mu and, gradually becoming thicker narrower, joins with the tendon of Gastrocnemius, and forms with it the te calcaneus.

Relations.—Its *superficial surface* is in tion with the Gastrocnemius and Plantar *deep surface*, with the Flexor digitorum Flexor hallucis longus, Tibialis posteri posterior tibial vessels and nerve, from which it is separated by the deep tra fascia of the leg.

Nerve-supply.—The Soleus is supplied the first and second sacral nerves throug tibial nerve.

Actions.—The Soleus is an extensor of the ankle-joint; in standing, Soleus, taking its fixed point from below, steadies the leg on the foot.

The Gastrocnemius and Soleus together form a muscular mass which occasionally described as the *Triceps suræ*; its tendon of insertion is the te calcaneus.

The **tendo calcaneus** (tendo Achillis) (fig. 611), the common tendo the Gastrocnemius and Soleus, is the thickest and strongest in the body.

CC-0. In Public Domain. Gurukul Kangri Collection, Haridwar

Digitized by Arya Samaj Foundation Chennai and eGangotri

...15 cm. long, and begins near the middle of the leg, but receives fleshy ...on its anterior surface, almost to its lower end. It gradually narrows and ...ons until it reaches a level about 4 cm. above the calcaneus; below this ...it expands and is inserted into the middle part of the posterior surface ...calcaneus, a bursa being interposed between the tendon and the upper ...of this surface.

...ctions.—The muscles of the calf—Gastrocnemius and Soleus—are the chief ...sors of the ankle-joint. They possess considerable power, and are called into ...in standing, walking, dancing, and leaping; hence the large size they usually ...ent. In walking, these muscles raise the heel from the ground; the body being ...supported on the raised foot, the opposite limb can be carried forwards.

The **Plantaris** (fig. 611) arises from the lower part of the lateral prolonga- ...of the linea aspera, and from the oblique popliteal ligament of the knee-joint. ...ms a small fusiform belly, from 7 cm. to 10 cm. long; this ends in a long ...r tendon which crosses obliquely between the Gastrocnemius and Soleus, ...l runs along the medial border of the tendo calcaneus, to be inserted with ...g the posterior part of the calcaneus. This muscle is sometimes double, ...at other times wanting. Occasionally, its tendon is lost in the laciniate ...ment, or in the fascia of the leg.

...erve-supply.—The Plantaris is supplied by the fourth and fifth lumbar and ...acral nerves, through the tibial nerve.

...ctions.—The Plantaris is the rudiment of a large muscle, the tendon of which ...ce of the lower animals is inserted into the plantar aponeurosis: in man it ...an accessory to the Gastrocnemius, extending the ankle-joint if the foot be free, ...ing the knee-joint if the foot be fixed.

Deep Group (fig. 612)

Popliteus.
Flexor hallucis longus.
Flexor digitorum longus.
Tibialis posterior.

The **deep transverse fascia** of the leg is a septum between the superficial ...deep muscles of the back of the leg. At the sides it is connected to the ...al margin of the tibia and the posterolateral border of the fibula. Above, ...re it covers the Popliteus, it is thick and dense, and receives an expansion ...the tendon of the Semimembranosus; it is thin in the middle of the ...; but below, where it covers the tendons passing behind the malleoli, it ...ck and continuous with the laciniate ligament.

The **Popliteus** (fig. 612) is a thin, flat, triangular muscle, which forms the ...of the lower part of the popliteal fossa. It arises by a strong tendon ...2·5 cm. long, from a depression at the anterior part of the groove on ...lateral condyle of the femur, and to a small extent from the oblique ...al ligament of the knee-joint. It is inserted into the medial two-thirds ...e triangular surface above the popliteal line on the posterior surface of ...dy of the tibia, and into the tendinous expansion covering the muscle.

...ctions.—Its tendon of origin is covered by the tendon of the Biceps femoris and by ...ular collateral ligament of the knee-joint: it grooves the posterior border of the ...meniscus, and is invested by the synovial stratum of the capsule of the knee-joint. ...ascia covering the muscle separates it from the Gastrocnemius, Plantaris, popliteal ...s, and tibial nerve. The deep surface of the muscle is in contact with the oblique ...al ligament of the knee-joint and the back of the tibia.

...erve-supply.—The Popliteus is supplied by the fourth and fifth lumbar and ...acral nerves, through the tibial nerve.

...ctions.—The Popliteus flexes the knee-joint; when the joint is flexed, it ...s the tibia inwards. It is specially called into action at the beginning of ...n of the knee-joint inasmuch as it produces the slight inward rotation of the ...which is essential in the early stage of this movement.

The **Flexor hallucis longus** (figs. 612, 615) is situated on the fibular side ...leg. It arises from the inferior two-thirds of the posterior surface of the ...of the fibula, with the exception of about 2·5 cm. at its lowest part; from ...lower part of the interosseous membrane; from the posterior fibular inter- ...ular septum, and from the fascia covering the Tibialis posterior. The fibres ...obliquely downwards and backwards, and end in a tendon which occupies ...the whole length of the posterior surface of the muscle. This tendon lies

CC-0. In Public Domain. Gurukul Kangri Collection, Haridwar

Digitized by Arya Samaj Foundation Chennai and eGangotri

in a groove which crosses the posterior surface of the lower end of the the posterior surface of the talus, and the under surface of the sustentaculum tali of the calcaneus. In the sole of the foot it runs forwards between the two heads of Flexor hallucis brevis, and is inserted into the base of the distal phalanx of the great toe. The grooves on the talus and calcaneus, which contain the tendon of the muscle, are converted by tendinous fibres into a canal which is lined by a mucous sheath. As the tendon passes forwards in the sole of the foot, it is situated medially and crosses from the lateral to the medial side of, the tendon of the Flexor digitorum longus, with which it is connected by a fibrous slip.

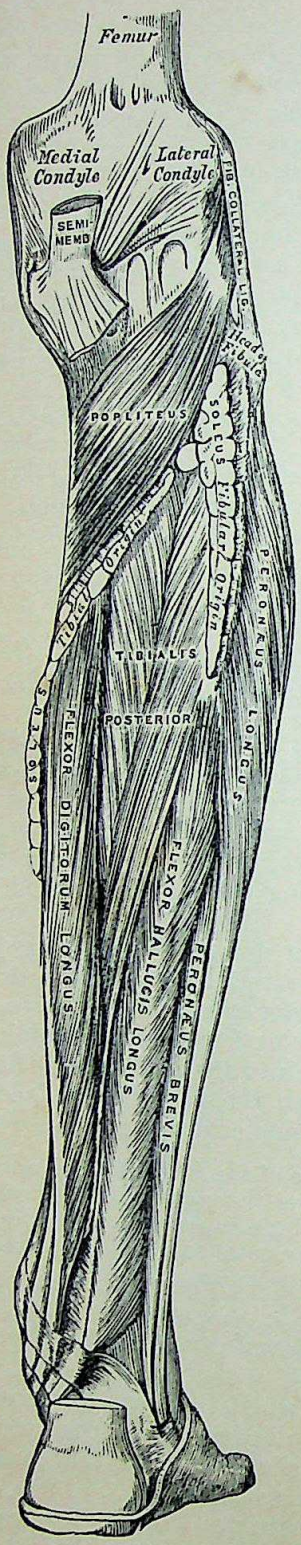

FIG. 612.—The right posterior crural muscles. Deep group.

Relations.—Its *superficial surface* is in relation with the Soleus and tendo calcaneus, from which it is separated by the deep transverse fascia; its *deep surface*, with the fibula, Tibialis posterior, the peronæal vessels, the lower part of the interosseous membrane, and the ankle-joint; its *lateral border*, with the Peronæi; its *medial border*, with the Tibialis posterior, posterior tibial vessels and tibial nerve.

Nerve-supply.—The Flexor hallucis longus is supplied by the fifth lumbar and first and second sacral nerves, through the tibial nerve.

Actions.—The Flexor hallucis longus flexes the great toe, and, continuing its action, extends the ankle-joint.

The **Flexor digitorum longus** (fig. 613) is situated on the tibial side of the leg. At its origin it is thin and pointed, but it gradually increases in size as it descends. It arises from the posterior surface of the body of the tibia, medial to the tibial origin of the Tibialis posterior; this origin extends from immediately below the popliteal line to within 7 cm. or so of the lower extremity of the bone; it also arises from the fascia covering the Tibialis posterior. The fibres end in a tendon, which runs nearly the whole length of the posterior surface of the muscle. This tendon passes behind the medial malleolus, in a groove common to it and the Tibialis posterior, but separated from the latter by a fibrous septum; the tendon being contained in a special compartment lined by a separate mucous sheath. It passes obliquely forwards and laterally in contact with the medial side of the sustentaculum tali (fig. 613), and deep to the laciniate ligament, and enters the sole of the foot (fig. 620), where it crosses below (or superficial to) the tendon of the Flexor hallucis longus, and receives from it a strong slip. It then expands and is joined by the Quadratus plantæ, and finally divides into four tendons which are inserted into the bases of the distal phalanges of the second, third, fourth, and fifth toes, each tendon passing through an opening in the corresponding tendon of the Flexor digitorum brevis opposite the base of the first phalanx.

Relations.—In the leg its *superficial surface* is in relation with the posterior tibial vessels and tibial nerve, and the deep transverse fascia which separates it from the Soleus; its *deep surface*, with the tibia and Tibialis posterior. In the foot, it is covered

CC-0. In Public Domain. Gurukul Kangri Collection, Haridwar

Digitized by Arya Samaj Foundation Chennai and eGangotri

Abductor hallucis and Flexor digitorum brevis, and crosses superficial to the
hallucis longus.

Nerve-supply.—The Flexor digitorum longus is supplied by the fifth lumbar and
ral nerves through the tibial nerve.

Action.—The Flexor digitorum longus flexes the phalanges of the toes, and in
ed action extends the ankle-joint. In consequence of the oblique direc-
of its tendons it draws the toes medialwards, but this is counteracted by the
rsus plantæ which is inserted into the lateral side of the tendon.

Fig. 613.—A coronal section through the right talocrural and talocalcaneal joints.

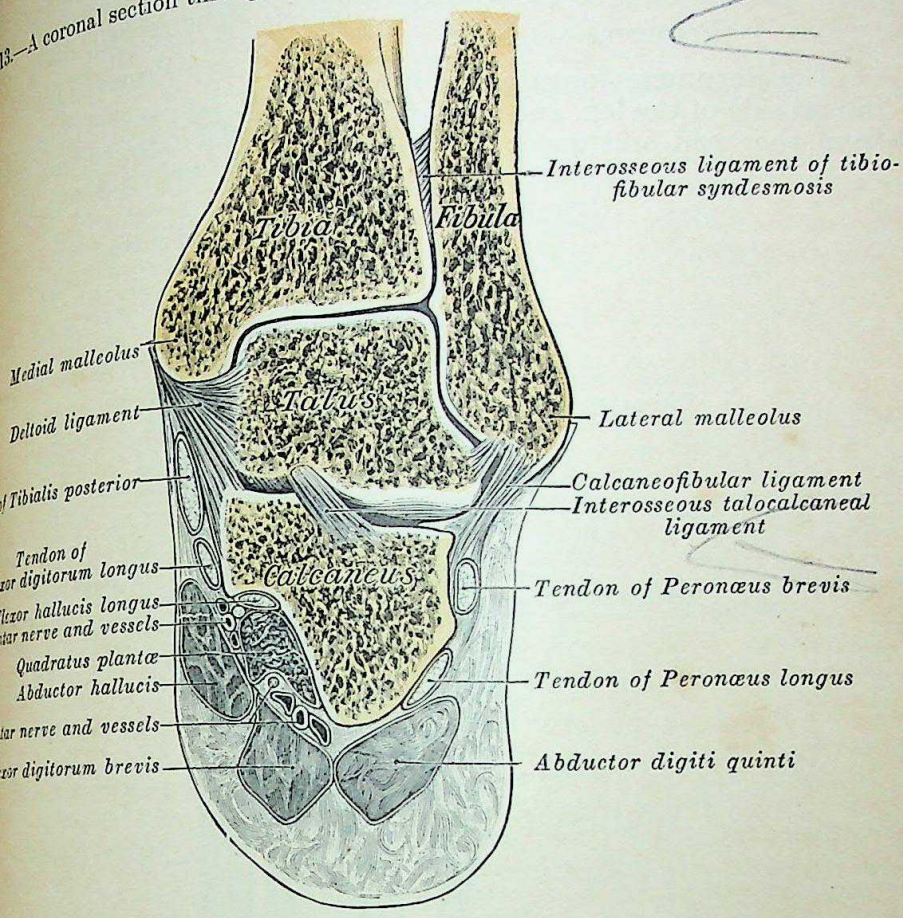

Tibialis posterior (figs. 609, 612) lies between the Flexor hallucis
and Flexor digitorum longus, and is the deepest muscle on the back of
g. It begins above by two pointed processes, separated by an angular
l through which the anterior tibial vessels pass to the front of the leg.
es from the posterior surface of the crural interosseous membrane,
the exception of its lowest part; from the lateral portion of the posterior
e of the body of the tibia, between the commencement of the popliteal
ve and the junction of the middle with the lower one-third of the body
; and from the upper two-thirds of the medial surface of the fibula;
s also arise from the deep transverse fascia, and from the inter-
r septa separating it from the adjacent muscles. In the lower one-
of the leg its tendon passes in front of that of the Flexor digitorum
and lies with it in a groove behind the medial malleolus, but enclosed
parate sheath; it next passes under the laciniate and over the deltoid
t into the foot, and then below the plantar calcaneonavicular ligament,
it contains a sesamoid fibrocartilage. It is inserted into the tuberosity
avicular bone, and gives off fibrous slips, one of which passes backwards
attached to the sustentaculum tali of the calcaneus, while others pass
ch and lateralwards and are fixed to the three cuneiform bones, the
l bone, and the bases of the second, third, and fourth metatarsal bones.

CC-0. In Public Domain. Gurukul Kangri Collection, Haridwar

Digitized by Arya Samaj Foundation Chennai and eGangotri

Relations.—Its *superficial surface* is in relation with the Soleus, from w separated by the deep transverse fascia, the Flexor digitorum longus, the post vessels and tibial nerve, and the peronæal vessels; its *deep surface* with the in membrane, the tibia, fibula, and ankle-joint.

Nerve-supply.—The Tibialis posterior is supplied by the fifth lumbar and sacral nerves through the tibial nerve.

Actions.—The Tibialis posterior extends the ankle-joint; it also pu medial border of the foot, i.e. inverts the foot. In the sole of the foot it lies directly below the plantar calcaneonavicular ligament, and is an im factor in maintaining the longitudinal arch of the foot.

3. The Lateral Crural Muscles (fig. 614)

Peronæus longus. Peronæus brevis.

The **Peronæus longus** (figs. 609, 612, 614) is situated at the upper pa lateral side of the leg, and is the more superficial of the two muscles. It from the head and upper two-thirds of the lateral surface of the body

Fig. 614.—The right lateral crural muscles.

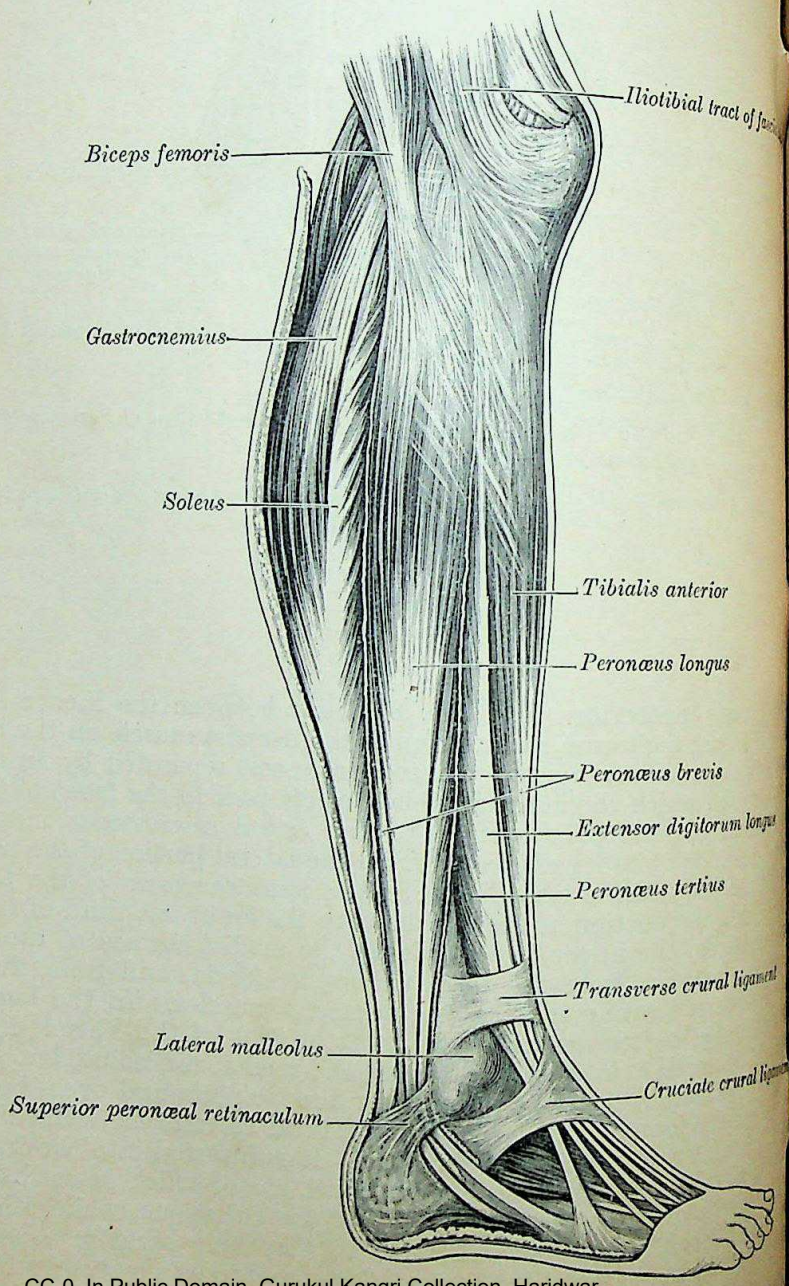

CC-0. In Public Domain. Gurukul Kangri Collection, Haridwar

Digitized by Arya Samaj Foundation Chennai and eGangotri

from the deep surface of the fascia, and from the anterior and posterior intermuscular septa: occasionally also by a few fibres from the lateral side of the tibia. Between its attachments to the head and body of the there is a gap through which the common peronæal nerve passes to the front of the leg. It ends in a long tendon, which runs behind the lateral malleolus, in a groove common to it and the tendon of the Peronæus brevis, in which it lies; the groove is converted into a canal by the superior peronæal retinaculum, and the tendons in it are contained in a common mucous sheath. The tendon then extends obliquely forwards across the lateral side of the calcaneus, below the trochlear process and the tendon of the Peronæus tertius, and under cover of the inferior peronæal retinaculum; it crosses the lateral side of the cuboid bone, and then runs on the under surface of that bone in a groove which is converted into a canal by the long plantar ligament.

FIG. 615.—A transverse section through the leg, 6 cm. proximal to the tip of the medial malleolus.

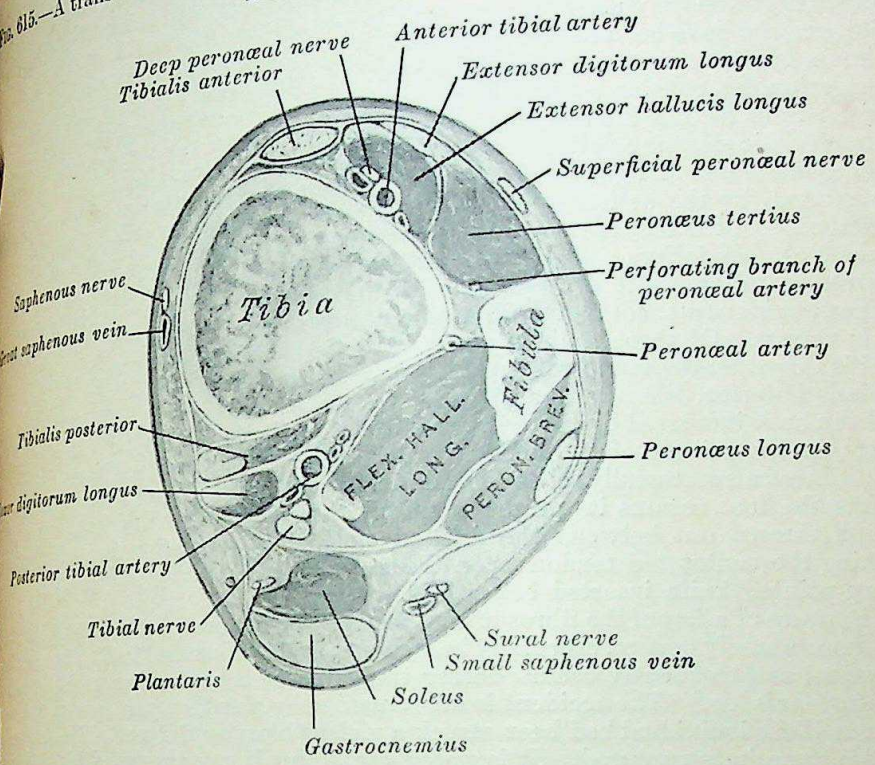

then crosses the sole of the foot obliquely, and is inserted by two slips (a) the lateral side of the base of the first metatarsal bone and (b) the medial side of the first cuneiform bone; occasionally a third slip is attached to the base of the second metatarsal bone. The tendon changes its direction two points: (a) below the lateral malleolus, (b) on the cuboid bone; in both these situations it is thickened, and, in the latter, a sesamoid fibro-cartilage (sometimes a bone) is usually developed in its substance.

Nerve-supply.—The Peronæus longus is supplied by the fourth and fifth lumbar and first sacral nerves through the superficial peronæal nerve.

Actions.—The Peronæus longus extends the ankle-joint and everts the foot. As a consequence of the oblique direction of its tendon across the sole it is an important agent in maintaining the transverse arch of the foot. Taking its fixed point on the Peronæus longus serves to steady the leg on the foot; this is especially of use in standing on one leg, when the tendency of the superincumbent weight to throw the leg medialwards; the Peronæus longus overcomes this tendency by pulling on the lateral side of the leg.

The **Peronæus brevis** (figs. 614, 615) arises from the lower two-thirds of the lateral surface of the body of the fibula, in front of the Peronæus longus; from the anterior and posterior fibular intermuscular septa. The fibres run vertically downwards, and end in a tendon which runs behind the lateral

CC-0. In Public Domain. Gurukul Kangri Collection, Haridwar

Digitized by Arya Samaj Foundation Chennai and eGangotri

malleolus along with, but in front of, that of the Peronæus longus, the two being enclosed in the same compartment, and lubricated by a common sheath. It then runs forwards on the lateral side of the calcaneus, above the trochlear process and the tendon of the Peronæus longus, and is inserted into the tuberosity at the base of the fifth metatarsal bone, on its lateral side.

On the lateral surface of the calcaneus the tendons of the Peronæus longus et brevis occupy separate osseo-aponeurotic canals formed by the retinacula and the inferior peronæal reticulum; each tendon is enveloped by a sheath, prolongation of the common mucous sheath.

Nerves.—The Peronæus brevis is supplied by the fourth and fifth lumbar and first sacral nerves through the superficial peronæal nerve.

Action.—The Peronæus brevis extends the foot upon the leg.

Applied Anatomy.—Rigidity and contraction of the tendons of the various muscles of the leg give rise to one or other of the kinds of deformity known as *club foot*. The simple and common deformity, and one that is rarely, if ever, congenital, is *talipes equinus*, the heel being raised by the rigidity and contraction of the Gastrocnemius, so that the patient walks upon the ball of the foot. A condition of temporary talipes equinus is often produced by the weight of the bed-clothes in patients, particularly children, who have been kept lying on their backs in bed for a few weeks. In this case, unless a cradle is used to protect the feet, the weight of the bed-clothes will cause them extended, causing a temporary shortening of the calf-muscles that will prevent the patient from flexing the ankles to anything less than a right angle, and will produce the characteristic shuffling gait when he first gets up and walks. In *talipes varus*, the sole is forcibly adducted and the medial side of the sole raised, sometimes to a right angle, from the ground, by the action of the Tibiales anterior et posterior. In *talipes valgus* the lateral edge of the foot is raised by the Peronæi, and the patient walks on the medial side of the foot. In *talipes calcaneus* the toes are raised by the extensor muscles, the heel depressed and the patient walks upon it. Other varieties of deformity are met with, as *talipes equinovarus*, *equinovalgus*, and *calcaneovalgus*, names which sufficiently indicate their nature. Of these, talipes equinovarus is the most common congenital form. The heel is raised by the tendo calcaneus, the medial border of the foot drawn upwards by the Tibialis anterior, the anterior two-thirds twisted medialwards by the Tibialis posterior, and the arch increased by the contraction of the plantar aponeurosis, so that the patient walks on the middle of the lateral border of the foot. Each of these deformities may sometimes be successfully relieved by division of the opposing tendons and fascia; by this means the foot regains its proper position, and the tendons heal by the organization of lymph thrown out between the divided ends. The operation is easily performed by putting the contracted tendon upon the stretch, and dividing it by means of a narrow sharp-pointed knife inserted beneath it.

Rupture of a few of the fibres of the Gastrocnemius, or rupture of the Plantaris tendon, not uncommonly occurs, especially in men somewhat advanced in life, from some sudden exertion, and frequently occurs during the game of lawn-tennis, and is hence known as 'lawn-tennis leg.' The accident is accompanied by a sudden pain, and produces a sensation as if the individual had been struck a violent blow on the part. The tendo calcaneus is also sometimes ruptured. It is stated that John Hunter ruptured his tendo calcaneus while dancing, at the age of forty. The bursa between the tendo calcaneus and the posterior surface of the calcaneus sometimes becomes inflamed, especially in pedestrians and 'long-distance' walkers. It causes great and disabling pain, and entirely prevents the sufferer from continuing his walk.

THE FASCIA ROUND THE ANKLE

Fibrous bands, thickened portions of fascia, bind down the tendons in front of and behind the ankle in their passage to the foot. They consist of the transverse crural, cruciate crural, and laciniate ligaments, and the superior and inferior peronæal retinacula.

The **transverse crural ligament** (upper part of anterior annular ligament) (figs. 610, 616) binds down the tendons of the Tibialis anterior, Extensor hallucis longus, Extensor digitorum longus and Peronæus tertius as they descend on the front of the tibia and fibula; the anterior tibial vessels and the deep peronæal nerve also pass under cover of it. It is attached laterally to the lower end of the fibula, and medially to the tibia; above, it is continuous with the fascia of the leg.

CC-0. In Public Domain. Gurukul Kangri Collection, Haridwar

Digitized by Arya Samaj Foundation Chennai and eGangotri

The cruciate crural ligament (lower part of anterior annular ligament) (610, 616) is a Y-shaped band placed in front of the ankle-joint. The of the Y is attached to the upper surface of the calcaneus, in front of sulcus calcanei; it is directed medialwards in front of the tendons of the

Fig. 616.—The mucous sheaths of the tendons round the right ankle. Lateral aspect. (From a specimen prepared by J. C. B. Grant.)

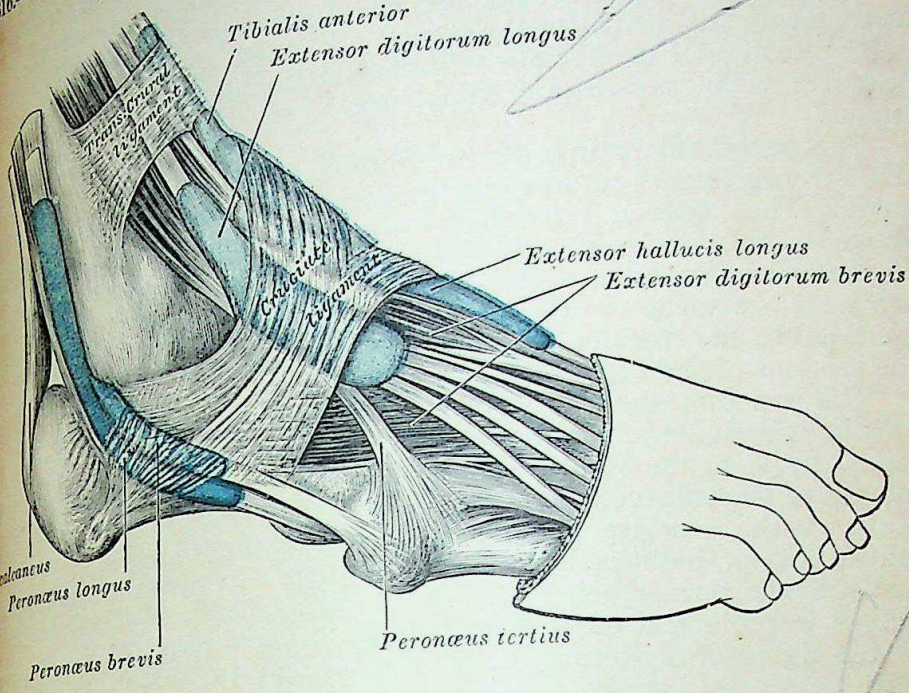

Fig. 617.—The mucous sheaths of the tendons round the right ankle. Medial aspect. (From a specimen prepared by J. C. B. Grant.)

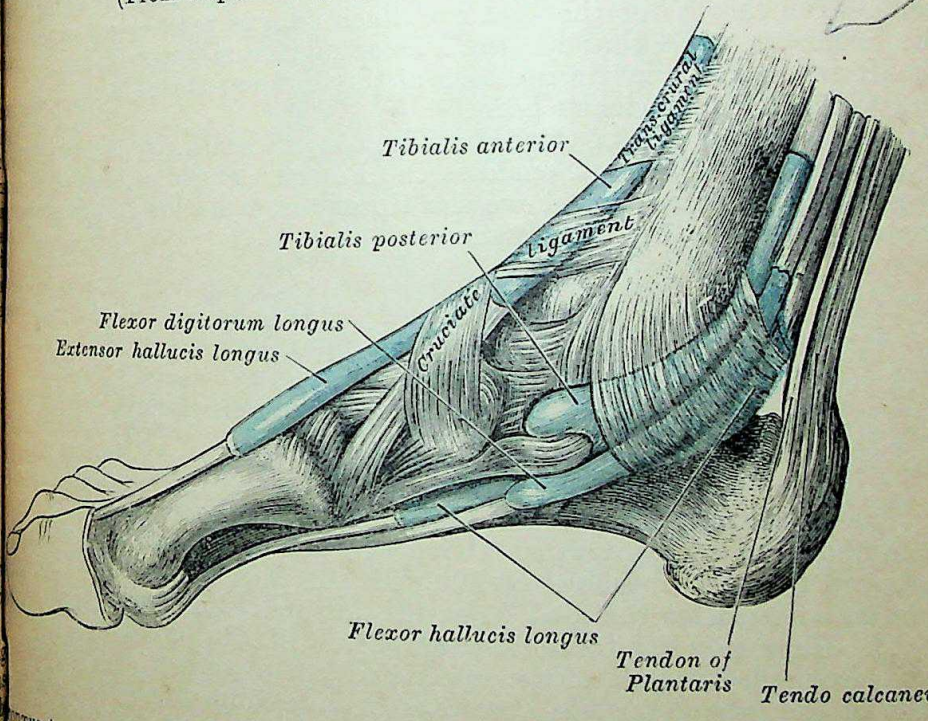

Peronæus tertius and Extensor digitorum longus and divides into two limbs. The limb is directed upwards and medialwards, to be attached to the tibial malleolus, passing over the Extensor hallucis longus and the anterior tibial vessels and deep peronæal nerve, but enclosing the Tibialis anterior by splitting into two laminæ. The other limb extends downwards and medialwards to be

CC-0. In Public Domain. Gurukul Kangri Collection, Haridwar

Digitized by Arya Samaj Foundation Chennai and eGangotri

attached to the plantar aponeurosis; it crosses the tendons of the Ex hallucis longus and Tibialis anterior, the arteria dorsalis pedis, a terminal branches of the deep peronæal nerve.

The **laciniate ligament** (internal annular ligament) extends fr tibial malleolus above to the margin of the calcaneus below; its upper is continuous with the deep fascia of the leg, its lower with the aponeurosis and the fibres of origin of the Abductor hallucis muscle. It a series of bony grooves in this situation into canals for the passage tendons of the flexor muscles into the sole of the foot and also affords pro to the posterior tibial vessels and tibial nerve as they enter the sole foot. From the medial to the lateral side, these structures lie in the fo order: tendon of the Tibialis posterior, tendon of the Flexor digitorum posterior tibial vessels and tibial nerve, and tendon of the Flexor longus.

The **peronæal retinacula** are fibrous bands which retain the tend the Peronæi longus et brevis in position as they cross the lateral side ankle. The *superior retinaculum* (external annular ligament) is att above to the lateral malleolus and below to the lateral surface of the calc The *inferior retinaculum* is continuous in front with the cruciate crural ligam behind it is attached to the lateral surface of the calcaneus; some of its are fixed to the trochlear process of the calcaneus, forming a septum betw the tendons of the Peronæi longus et brevis.

The **mucous sheaths of the tendons round the ankle.**—The te crossing the ankle-joint are enclosed in mucous sheaths. On the *front* ankle (fig. 616) the sheath for the Tibialis anterior extends from the margin of the transverse crural ligament to the interval between the div limbs of the cruciate ligament; those for the Extensor digitorum l and Extensor hallucis longus reach upwards to just above the level malleoli, the former being the higher. The sheath of the Extensor ha longus is prolonged on to the base of the first metatarsal bone, while of the Extensor digitorum longus reaches only to the level of the base fifth metatarsal bone. On the *medial side* of the ankle (fig. 617) the sheat the Tibialis posterior extends for about 4 cm. above the malleolus; belo ends just short of the insertion of the tendon into the tuberosity of the navi bone. The sheath for the Flexor hallucis longus reaches up to the lev the malleolus, while that for the Flexor digitorum longus is slightly hig the former is continued to the base of the first metatarsal bone, but the l ends opposite the navicular bone.

On the *lateral side* of the ankle (fig. 616) a sheath, which is single for greater part of its extent, encloses the Peronæi longus et brevis. It exte upwards for about 4 cm. above the tip of the malleolus and downwards forwards for about the same distance.

IV. The Muscles of the Foot

1. The Dorsal Muscle of the Foot

Extensor digitorum brevis

The **fascia** on the dorsum of the foot (fascia dorsalis pedis) is a membranous layer, continuous above with the transverse and cruciate cru ligaments; on either side it blends with the plantar aponeurosis; anteri it forms a sheath for the tendons on the dorsum of the foot.

The **Extensor digitorum brevis** (figs. 610, 616) is a thin muscle, wh arises from the forepart of the upper and lateral surface of the calcaneus front of the groove for the Peronæus brevis; from the lateral talocalcan ligament, and the stem of the cruciate crural ligament. It passes oblique forwards and medialwards across the dorsum of the foot, and ends in tendons. The medial part of the muscle is usually a more or less distinct ending in a tendon which crosses the dorsalis pedis artery and is inserted the dorsal surface of the base of the first phalanx of the great toe; it sometimes described as a separate muscle—the *Extensor hallucis brevis*.

CC-0. In Public Domain. Gurukul Kangri Collection, Haridwar

Digitized by Arya Samaj Foundation Chennai and eGangotri

three tendons are inserted into the lateral sides of the tendons of the Extensor digitorum longus of the second, third, and fourth toes.

Nerve-supply.—The Extensor digitorum brevis is supplied by the fourth and lumbar and first sacral nerves through the deep peronæal nerve.

Actions.—The Extensor digitorum brevis extends the phalanges of the four toes on which it is inserted, but, in the great toe, acts only on the first phalanx.

2. The Plantar Muscles of the Foot

The **plantar aponeurosis** (fig. 618) is of great strength, and consists of white fibres disposed, for the most part, longitudinally: it is divided into central, lateral, and medial portions.

Fig. 618.—The plantar aponeurosis of the right foot.

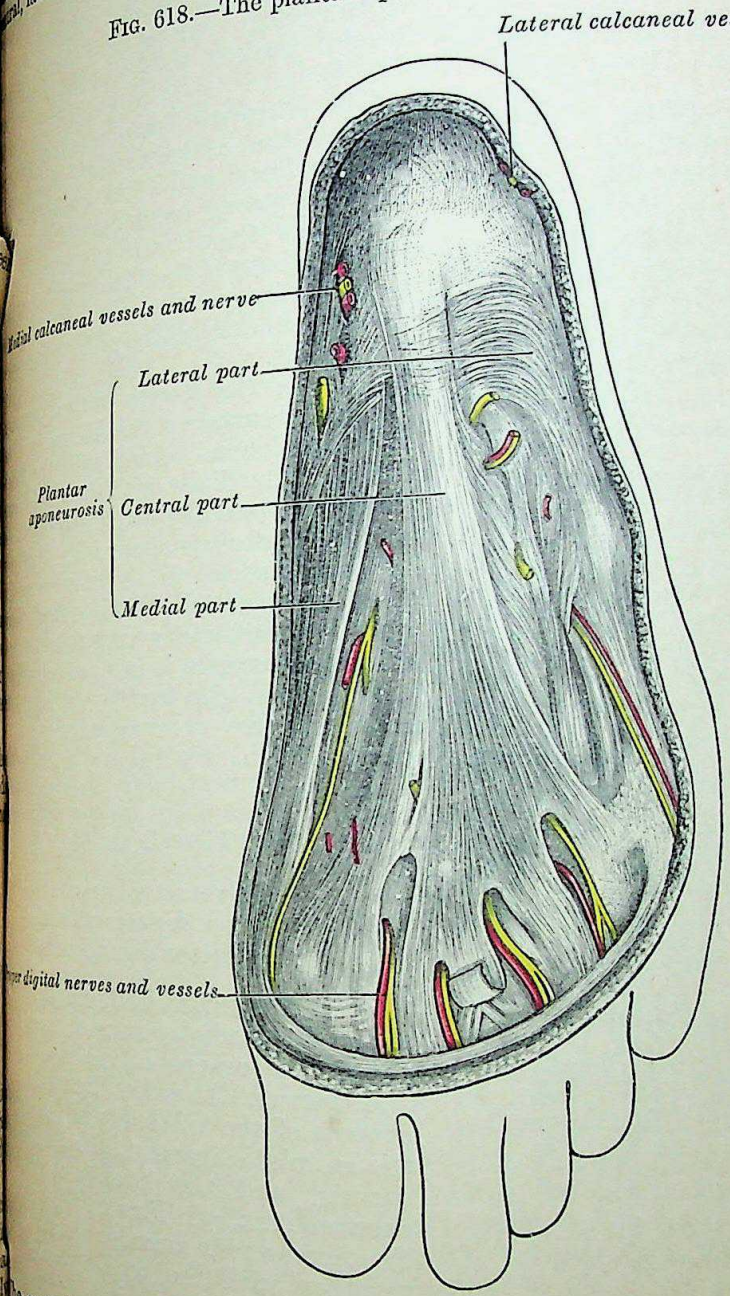

The *central portion*, the thickest, is narrow behind, and attached to the medial process of the tuberosity of the calcaneus, posterior to the origin of the Flexor digitorum brevis; it becomes broader and thinner in front, and divides near the heads of the metatarsal bones into five processes, one for each of the toes. Each of these processes splits opposite the metatarsophalangeal articulation into two strata, superficial and deep. The superficial stratum

CC-0. In Public Domain. Gurukul Kangri Collection, Haridwar

Digitized by Arya Samaj Foundation Chennai and eGangotri

is inserted into the skin of the transverse sulcus which separates the to the sole. The deep stratum divides into two slips which embrace th of the flexor tendons of the toes, and blend with the sheaths of the t and with the transverse metatarsal ligament, thus forming a series of through which the tendons of the short and long flexors pass to t Through the intervals between the five processes the digital vessels a and the tendons of the Lumbricales are transmitted. At the point of of the aponeurosis are numerous transverse fasciculi which bind the together, and connect them with the integument. The central p the plantar aponeurosis is continuous with the lateral and medial porti sends upwards into the foot, at the lines of junction, two vertical inter septa, which separate the intermediate from the lateral and medial g plantar muscles; from these vertical septa thinner transverse septa are which separate the different layers of muscles in this region. The deep of the central part of the aponeuro origin behind to the Flexor dig brevis.

FIG. 619.—The plantar muscles of the right foot. First layer.

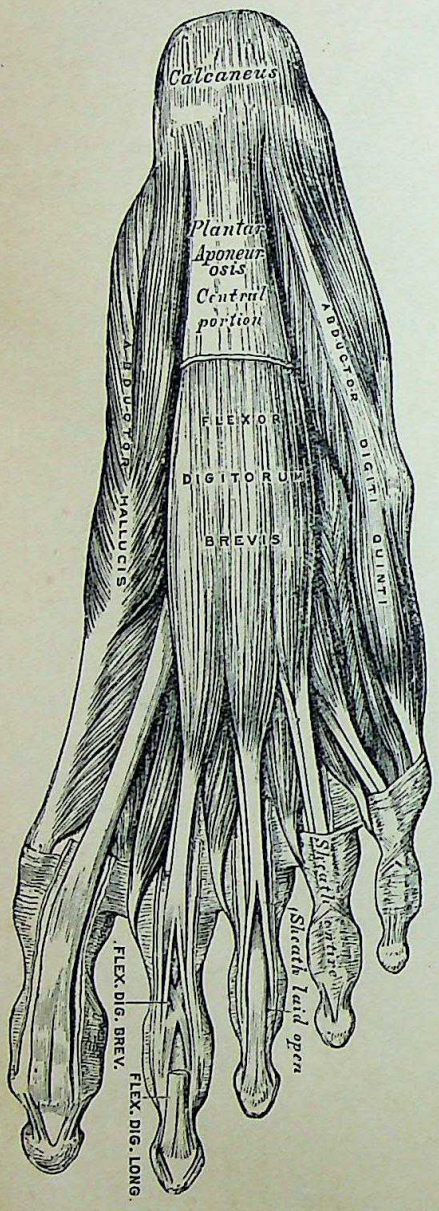

The *lateral portion* covers the und face of the Abductor digiti quinti thin in front and thick behind, w forms a strong band between the process of the tuberosity of the ca and the base of the fifth metatarsal it is continuous medially with the portion, and laterally with the fas salis pedis.

The *medial portion* is thin, and the under surface of the Abductor ha it is continuous behind with the la ligament, medially with the fascia d pedis, and laterally with the central p of the plantar aponeurosis.

The muscles in the plantar reg the foot may be divided into medial, l and intermediate groups; but for criptive purposes it is more convenie divide them into four layers, in the in which they are successively expo dissecting this region.

The First Layer (fig. 619)

Abductor hallucis.
Flexor digitorum brevis.
Abductor digiti quinti.

The **Abductor hallucis** (fig. 619 along the medial border of the foot covers the origins of the plantar v and nerves. It arises from the m process of the tuberosity of the calca the laciniate ligament, the plantar a eurosis, and the intermuscular se between it and the Flexor digitorum b The fibres end in a tendon which is inse together with the medial tendon of Flexor hallucis brevis, into the medial s of the base of the first phalanx of the g toe.

Nerve-supply.—The Abductor hallucis is supplied by the fifth lumbar and sacral nerves, through the medial plantar nerve.

Actions.—The Abductor hallucis flexes the proximal phalanx of the great and draws it medialwards.

CC-0. In Public Domain. Gurukul Kangri Collection, Haridwar

Digitized by Arya Samaj Foundation Chennai and eGangotri

The **Flexor digitorum brevis** (fig. 619) lies immediately above the central part of the plantar aponeurosis. Its deep surface is separated from the lateral plantar vessels and nerves by a thin layer of fascia. It arises by a narrow process, from the medial process of the tuberosity of the calcaneus, from the central part of the plantar aponeurosis, and from the intermuscular septa between it and the adjacent muscles. It divides into four tendons, one for each of the four lesser toes. Opposite the bases of the first phalanges, each tendon divides into two slips, to allow of the passage of the corresponding tendon of the Flexor digitorum longus; the two slips then unite, partially ensheathe, and form a grooved channel for the reception of the tendon of the Flexor digitorum longus. The tendon divides again and is inserted into the sides of the second phalanx about its middle. The mode of division of the tendons of the Flexor digitorum brevis, and of their insertion into the phalanges, is analogous to that of the tendons of the Flexor digitorum sublimis in the hand.

Nerve-supply.—The Flexor digitorum brevis is supplied by fifth lumbar and first sacral nerves, through the medial plantar nerve.

Actions.—The Flexor digitorum brevis flexes the second phalanges upon the first; continuing its action it flexes the first phalanges and brings the toes together.

The fibrous sheaths of the flexor tendons (fig. 619).—The terminal portions of the tendons of the long and short flexor muscles are contained in fibro-aponeurotic canals similar in their arrangement to those in the fingers. These canals are bounded above by the phalanges, and below by fibrous bands, which arch across the tendons, and are attached on either side to the margins of the phalanges. Opposite the bodies of the proximal and second phalanges the fibrous bands (*vaginal ligaments*) are strong, and the fibres are transverse; but opposite the joints they are much thinner, and the fibres are directed obliquely. Each canal contains a mucous sheath, which is reflected on the contained tendons; within this sheath are *vincula tendinum* arranged similarly to those in the fingers.

The **Abductor digiti quinti** (fig. 619) lies along the lateral border of the foot, and its medial margin is in relation with the lateral plantar vessels and nerve. It arises from the lateral and medial processes of the tuberosity of the calcaneus, from the under surface of the bone between the processes, from the plantar aponeurosis, and from the intermuscular septum between it and the Flexor digitorum brevis. Its tendon glides over a smooth facet on the inferior surface of the base of the fifth metatarsal bone and is inserted, with the tendon of the Flexor digiti quinti brevis, into the lateral side of the base of the first phalanx of the fifth toe.

Nerve-supply.—The Abductor digiti quinti is supplied by the first and second sacral nerves through the lateral plantar nerve.

Actions.—The Abductor digiti quinti flexes the proximal phalanx of the little toe and draws it lateralwards.

The Second Layer (fig. 620)

Quadratus plantæ. Lumbricales.

The **Quadratus plantæ** (Flexor accessorius) (fig. 620) arises by two heads, which are separated from each other by the long plantar ligament: the medial, larger, head is muscular, and is attached to the medial concave surface of the calcaneus, below the groove for the tendon of the Flexor hallucis longus; the lateral head, flat and tendinous, arises from the calcaneus in front of the medial process of its tuberosity, and from the long plantar ligament. The two heads join at an acute angle, and end in a flattened band which is inserted into the inferior surface and lateral margin of the tendon of the Flexor digitorum longus, forming a kind of groove in which the tendon is lodged. It usually sends slips to those tendons of the Flexor digitorum longus which pass to the second, third, and fourth toes.

Nerve-supply.—The Quadratus plantæ is supplied by the first and second sacral nerves, through the lateral plantar nerve.

Actions.—The Quadratus plantæ assists the Flexor digitorum longus and converts the oblique pull of the tendons of that muscle into a direct backward pull on the toes.

CC-0. In Public Domain. Gurukul Kangri Collection, Haridwar

Digitized by Arya Samaj Foundation Chennai and eGangotri

The **Lumbricales** (fig. 620) are four small muscles, accessory to the t of the Flexor digitorum longus, and numbered from the medial side of the they arise from these tendons, as far back as their angles of separation springing from two tendons, except the first, which arises only from the m border of the first tendon of the Flexor digitorum longus. The muscle in tendons, which pass forwards on the medial sides of the four lesser and are inserted into the expansions of the tendons of the Extensor digi longus on the dorsal surfaces of the first phalanges.

FIG. 620.—The plantar muscles of the right foot. Second layer.

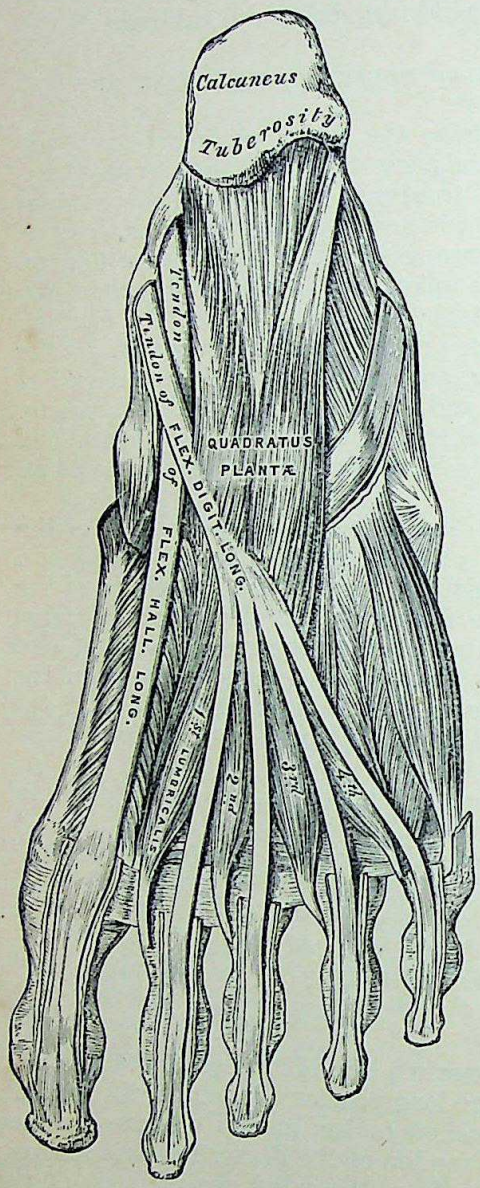

FIG. 621.—The plantar muscles of right foot. Third layer.

Nerve-supply.—The first Lumbricalis is supplied by the fifth lumbar and f sacral nerves through the medial plantar nerve; the others by the first and secon sacral nerves through the lateral plantar nerve.

Actions.—The Lumbricales flex the proximal phalanges, and by th insertions into the tendons of the Extensor digitorum longus, extend the mi and terminal phalanges.

CC-0. In Public Domain. Gurukul Kangri Collection, Haridwar

Digitized by Arya Samaj Foundation Chennai and eGangotri

The Third Layer (fig. 621)

Adductor hallucis.
Flexor hallucis brevis.
Flexor digiti quinti brevis.

The **Flexor hallucis brevis** (fig. 621) arises by a pointed tendinous ...ss from the medial part of the under surface of the cuboid bone, from ...e contiguous portion of the third cuneiform bone, and from the part of the ...ion of the Tibialis posterior which is attached to that bone. It divides ...o a medial and a lateral portion, and the tendons of these are inserted into ...e corresponding sides of the base of the first phalanx of the great toe, a ...sesamoid bone being present in each tendon at its insertion. The medial ...ion is blended with the Abductor hallucis previous to its insertion; the ...eral with the Adductor hallucis. The lateral portion of the Flexor hallucis ...evis is sometimes described as the *first plantar interosseous* muscle.

Nerve-supply.—The Flexor hallucis brevis is supplied by the fifth lumbar and ...st sacral nerves, through the medial plantar nerve.

Action.—The Flexor hallucis brevis flexes the proximal phalanx of the great toe.

The **Adductor hallucis** (fig. 621) arises by two heads—oblique and ...nsverse. The *oblique head* springs from the bases of the second, third, ...fourth metatarsal bones, and from the sheath of the tendon of the Peronæus ...gus, and is inserted, together with the lateral portion of the Flexor hallucis ...evis, into the lateral side of the base of the first phalanx of the great toe. ...e *transverse head* (Transversus pedis), a narrow, flat fasciculus, arises from ...e plantar metatarsophalangeal ligaments of the third, fourth, and fifth toes ...metimes only from the third and fourth), and from the transverse meta-...sal ligament. It is inserted into the lateral side of the base of the first ...alanx of the great toe, its tendon of insertion blending with that of the ...ique head.

Nerve-supply.—The Adductor hallucis is supplied by the first and second sacral ...ves, through the lateral plantar nerve.

Actions.—The oblique head of the Adductor hallucis is chiefly concerned in ad-...ting, but it also assists in flexing, the great toe; the transverse head approximates ...e ties and thus increases the curve of the transverse arch of the metatarsus.

The **Flexor digiti quinti brevis** (fig. 621) arises from the base of the ...th metatarsal bone, and from the sheath of the Peronæus longus; its tendon ...serted into the lateral side of the base of the first phalanx of the fifth toe. ...sionally a few of the deeper fibres are inserted into the lateral part of the ...al one-half of the fifth metatarsal bone; these are described by some as ...stinct muscle, the *Opponens digiti quinti*.

Nerve-supply.—The Flexor digiti quinti brevis is supplied by the first and second ...al nerves, through the lateral plantar nerve.

Action.—The Flexor digiti quinti brevis flexes the little toe.

The Fourth Layer.

Interossei.

The Interossei in the foot are similar to those in the hand, but are grouped ...n either side of the middle line of the *second* digit, instead of that of the *third*. ...ey consist of a dorsal and a plantar set.

The **Interossei dorsales** (fig. 622), four in number, are situated between ...e metatarsal bones. They are bipennate muscles, each arising by two heads ...m the adjacent sides of the metatarsal bones between which it is placed; ...e tendons are inserted into the bases of the first phalanges, and into the ...oneuroses of the tendons of the Extensor digitorum longus. The first ...serted into the medial side of the second toe; the other three into the ...eral sides of the second, third, and fourth toes. In the angular interval ...ween the heads of each of the three lateral muscles, one of the perforating ...eries passes to the dorsum of the foot; through the space between the ...ads of the first muscle the deep plantar branch of the dorsalis pedis artery ...ches the sole of the foot.

CC-0. In Public Domain. Gurukul Kangri Collection, Haridwar

Digitized by Arya Samaj Foundation Chennai and eGangotri

The **Interossei plantares** (fig. 623), three in number, lie beneath the bones of the foot, rather than between the metatarsal bones, and each is connected with the medial sides of the bodies of the metatarsal bone. They arise from the bases and medial sides of the bodies of the third, fourth, and fifth metatarsal bones, and are inserted into the medial sides of the bases of the first phalanges of the same toes, and into the aponeuroses of the tendons of the Extensor digitorum longus.

Nerve-supply.—The Interossei dorsales et plantares are supplied by the first and second sacral nerves, through the lateral plantar nerve. The first Interosseous dorsalis frequently receives an extra filament from the medial branch of the peronæal nerve on the dorsum of the foot, and the second Interosseous dorsalis receives a twig from the lateral branch of the same nerve.

Fig. 622.—The Interossei dorsales of the left foot. Dorsal aspect.

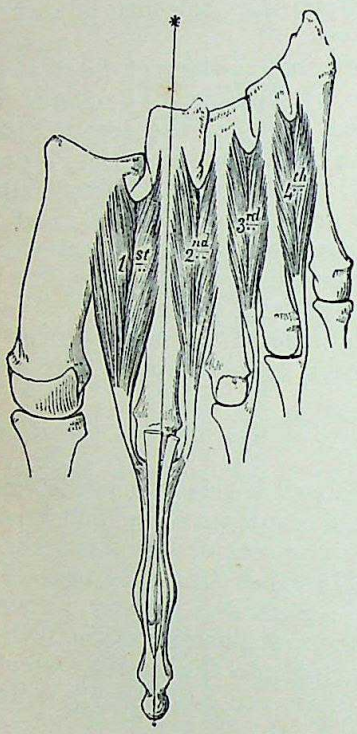

Fig. 623.—The Interossei plantares of the left foot. Plantar aspect.

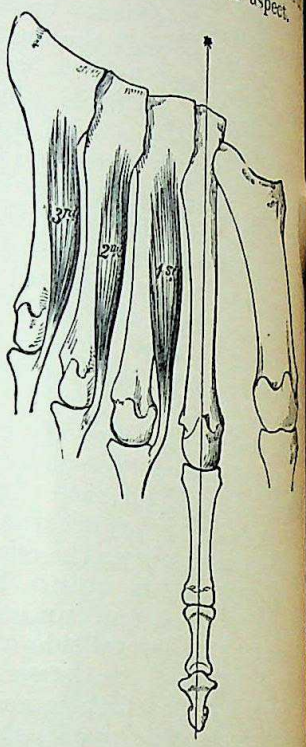

Actions.—The Interossei dorsales are abductors from an imaginary line passing through the axis of the second toe, so that the first muscle draws the second toe medialwards, the second muscle draws the same toe lateralwards, and the third and fourth draw the third and fourth toes lateralwards. They assist in flexing the first and extending the second and third phalanges. The Interossei plantares adduct the third, fourth, and fifth toes towards the imaginary line passing through the second toe, and, by means of their insertions into the aponeuroses of the Extensor tendons, assist in flexing the proximal phalanges and extending the middle and terminal phalanges.

Applied Anatomy.—The student should now consider the effects produced by the action of the various muscles in fractures of the bones of the lower extremity. The more common forms of fracture are selected for illustration and description.

In fracture of the *neck of the femur inside the articular capsule* (fig. 624), the characteristic signs are slight shortening of the limb, and eversion of the foot, neither of which may appear until some time after the injury. The eversion is caused by the weight of the limb rotating it outwards. The shortening is produced by the contraction of all the muscles about the joint. The fragment which carries the head of the femur receives its nutrition through the vessels in the ligamentum teres.

In fracture of the *femur just below the trochanters* (fig. 625), the upper fragment is drawn forwards almost at right angles with the pelvis, by the Psoas major and Iliacus; and at the same time, everted and abducted by the external rotator muscles and Glutæi, causing a marked prominence at the upper and lateral side of the thigh, and much pain from the

CC-0. In Public Domain. Gurukul Kangri Collection, Haridwar

Digitized by Arya Samaj Foundation Chennai and eGangotri

and laceration of the muscles. The limb is shortened, because the lower fragment is upwards by the Rectus femoris in front, and the Biceps femoris, Semimembranosus, Semitendinosus behind; it is, at the same time, everted.

FIG. 624.—A fracture of the neck of the femur within the articular capsule.

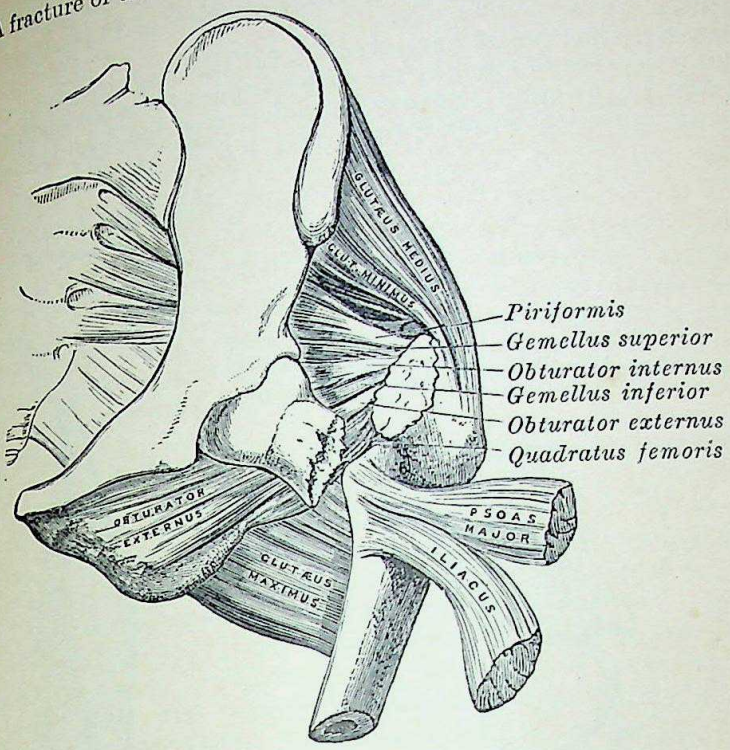

FIG. 625.—A fracture of the femur below the trochanters.

FIG. 626.—A fracture of the femur above the condyles.

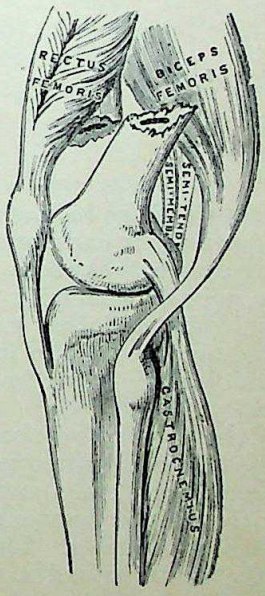

CC-0. In Public Domain. Gurukul Kangri Collection, Haridwar

Digitized by Arya Samaj Foundation Chennai and eGangotri

Oblique fracture of the femur *immediately above the condyles* (fig. 626) is a fa injury, and attended with considerable displacement. On examination of the lower fragment may be felt deep in the popliteal fossa, being drawn backwa Gastrocnemius, and upwards by the hamstrings and Rectus femoris, and in the the fragment may compress the popliteal artery and so cause gangrene. The end of the upper fragment is drawn medialwards by the Pectineus and Addu tilted forwards by the Psoas major and Iliacus, piercing the Rectus, and occa integument.

In transverse fracture of the *patella* (fig. 627) the fragments are separated by of the Quadriceps femoris and by the effusion which takes place into the joint; of separation of the two fragments depending upon the degree of laceration of mentous structures around the bone.

Fig. 628.—An oblique fracture the body of the tibia.

Fig. 627.—A fracture of the patella.

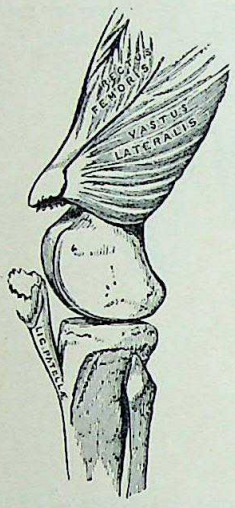

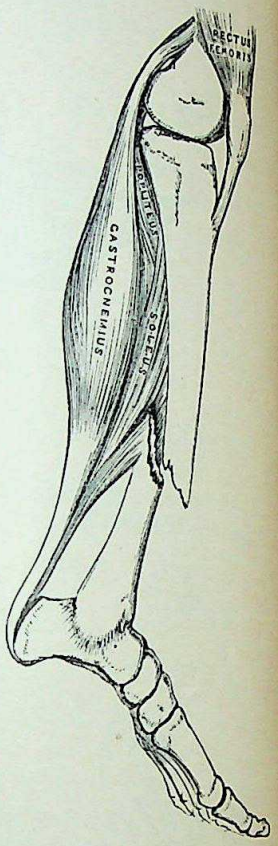

Oblique fracture of the *body of the tibia* (fig. 628). If the fracture takes place obl from above, downwards and forwards, the fragments ride over one another, the fragment being drawn backwards and upwards by the powerful action of the mus the calf; the pointed extremity of the upper fragment projects forwards immed beneath the integument, often protruding through it, and rendering the fracture pound. If the direction of the fracture is the reverse of that shown in the figure pointed extremity of the lower fragment projects forwards, rising up on the lower the upper one.

Fracture of the *fibula with dislocation of the foot lateralwards*, commonly known as 'P fracture,' is one of the most frequent injuries in the region of the ankle-joint. The is fractured about 7 or 8 cm. above the ankle; in addition to this the medial malleo broken off, or the deltoid ligament torn through, and the talus displaced from the sponding surface of the tibia. The foot is markedly everted, and the sharp edge upper end of the fractured malleolus presses strongly against the skin; at the same the heel is drawn up by the muscles of the calf.

CC-0. In Public Domain. Gurukul Kangri Collection, Haridwar

Digitized by Arya Samaj Foundation Chennai and eGangotri

ANGIOLOGY

THE vascular system is divided for descriptive purposes into (*a*) the *blood-vascular system*, comprising the heart and blood-vessels through which the blood circulates;* and (*b*) the *lymph-vascular system*, consisting of lymph-vessels and lymphatic vessels, through which a colourless fluid, the lymph, circulates. The two systems communicate with each other and are intimately associated developmentally.

The heart, the central organ of the blood-vascular system, is situated within the thorax. It is a muscular bag, by the contraction of which the blood is propelled to all parts of the body through a complicated series of tubes, termed vessels. The arteries undergo enormous ramification in their course throughout the body, and end in minute vessels, called *arterioles*, which open into a fine-meshed network of microscopic vessels, termed *capillaries*. After the blood has passed through the capillaries it is collected into a series of minute vessels called *venules*, and which join with one another to form *veins*: the veins unite with one another, and ultimately two large venous trunks, named the superior and inferior venæ cavæ, are formed which return the blood to the heart. While the blood is passing through the capillaries a transudation of certain of its fluid elements takes place into the tissue-spaces; this fluid is collected by the lymphatic vessels, and returned to the large veins at the base of the neck. The passage of the blood through the heart and blood-vessels is termed the *circulation* of the blood, of which the following is an outline.

The heart is divided into right and left halves, and each half consists of two cavities, an atrium and a ventricle, which communicate freely with one another; the atria are receiving chambers and the ventricles distributing chambers. The right atrium and ventricle form the right half, and the left atrium and ventricle the left half of the heart; the right half contains venous or impure blood; the left, arterial or pure blood. From the cavity of the left ventricle the arterial or pure blood is carried into a large artery, the branches of which it is distributed to all parts of the body, with the exception of the lungs. As the blood traverses the capillaries of the body it gives up to the tissues the materials necessary for their growth and nourishment, and receives from the tissues the waste products resulting from their metabolism. In doing so it is changed from arterial into venous blood, and the latter is returned by the veins to the right atrium of the heart. From this cavity the venous blood passes into the right ventricle, and from it is conveyed through the pulmonary arteries to the lungs, where it becomes arterialised, and is carried thence to the left atrium by the pulmonary veins. From the left atrium it passes into the left ventricle, from which the cycle once more begins.

The course of the blood from the left ventricle through the body generally to the right side of the heart constitutes the greater or *systemic* circulation, while its passage from the right ventricle through the lungs to the left side of the heart is termed the lesser or *pulmonary* circulation.

It is necessary, however, to state that the blood which circulates through the spleen, pancreas, stomach, small intestine, and the greater part of the large intestine is not returned directly from these organs to the heart, but is conveyed by the *portal vein* to the liver. In the liver this vein divides like an artery, and ultimately ends in capillary-like vessels (sinusoids), from which

* The blood is described on pp. 26 to 28.

CC-0. In Public Domain. Gurukul Kangri Collection, Haridwar

Digitized by Arya Samaj Foundation Chennai and eGangotri

the rootlets of the *hepatic veins* arise; the hepatic veins carry the bl the inferior vena cava which conveys it to the right atrium. Fro will be understood that the blood supplied to the above-named viscera through two sets of minute vessels before reaching the inferior ve (1) the capillaries in the spleen, pancreas, stomach, &c., draining into the hepa portal vein, and (2) the sinusoids in the liver, draining into the

The **structure of the arteries** (figs. 629, 630).—The wall of an artery of three coats, an internal or *tunica intima*, a middle or *tunica media*, and or *tunica adventitia*. The external coat is tougher than the other two, ruptured when a ligature is tied round the vessel, and, in virtue of their become retracted from the site of the ligature.

The *tunica intima* consists of (*a*) an internal layer of flattened cells, (*b*) these, a small quantity of loose connective tissue, and (*c*) an elastic lami flattened or endothelial cells are in shape with the long axis of the long axis of the blood-vessel cell possesses a nucleus, and is att adjacent cells by cement-substance reduces silver nitrate. The co tissue layer is very thin, and c branched cells, and, in the larger ar fine elastic fibres. The elastic la built up of longitudinally arrange fibres fused together, and is fenestrated, having round or ov tures at irregular intervals. In a verse section of an artery it as a characteristic wavy line, o the contracted condition of the vessel.

Fig. 629.—A transverse section through a small artery and vein of the mucous membrane of the epiglottis of a child. × 350. (Klein and Noble Smith.)

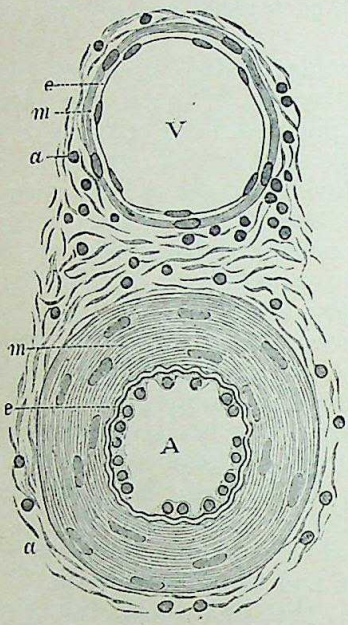

A. Artery; *a*, tunica adventitia; *e*, endothelium resting on the elastic lamina; *m*, tunica media.

V. Vein; *a*, tunica adventitia; *m*, tunica media; *e*, endothelium.

The *tunica media*, in the smal medium-sized arteries, consists pri of smooth muscular fibres arrange larly round the vessel; the fibre well-marked, rod-shaped nuclei. smallest arteries the middle coat is composed of smooth muscular (fig. 630). In medium-sized arteri 631) there are in addition elastic and fine elastic membranes lying b the layers of muscular fibres. I larger arteries, as the iliac and c the proportion of elastic tissue is increased, and in the aorta relatively thick elastic laminæ form the greater the thickness of the middle coat.

The *tunica adventitia* consists mainly of fine and closely felted bundles of connective tissue; in all but the smallest arteries it contains some elastic The elastic tissue is most abundant next the tunica media, and it is so described as forming here, between the adventitia and media, a special the *tunica elastica externa*; this layer is most marked in arteries of m size. In the largest vessels the external coat is relatively thin. From the m sized to the smaller arteries it diminishes gradually in thickness; in the s arteries the elastic fibres are wanting, and the connective tissue, of which th is composed, becomes more homogeneous the nearer it approaches the ca and is gradually reduced to a thin membranous envelope, which finally disa

Some arteries have extremely thin walls in proportion to their size; especially the case in those situated within the cranium and vertebral canal the external and middle coats of the arteries are reduced in thickness.

The arteries, in their distribution throughout the body, are enclos thin fibro-areolar *sheaths*. An artery is loosely connected with its shea delicate areolar tissue; and the sheath usually encloses the accompanying and sometimes a nerve. Some arteries, as those in the cranium, are dev sheaths.

CC-0. In Public Domain. Gurukul Kangri Collection, Haridwar

Digitized by Arya Samaj Foundation Chennai and eGangotri

The larger arteries are supplied with blood-vessels. These nutrient vessels, called the *vasa vasorum*, arise from branches of the artery itself, or of a neighbouring trunk at some considerable distance from the parts at which they are distributed; they ramify in the loose areolar tissue surrounding the artery with its sheath, and are distributed to the external coat; in general they do not penetrate the other coats; but in some of the larger mammals these vessels have been traced into the middle coat. Minute veins return the blood from these vessels; they empty themselves into the vein or veins accompanying the artery. Lymphatic vessels are also present in the outer coat.

Arteries are also supplied with nerves, which form intricate plexuses upon the coats of the larger trunks, and run with the smaller arteries as single cords, or bundles of filaments. Most of the nerve-fibres are non-medullated, and are derived from the sympathetic; but some are medullated. The non-medullated fibres are mostly efferent, and lie in the middle coat. The medullated fibres are believed to be afferent and are distributed to the outer and inner coats. Pacinian corpuscles are occasionally found in the outer coat of the aorta.

FIG. 630.—A small artery and vein, from the pia mater of a sheep. × 250.

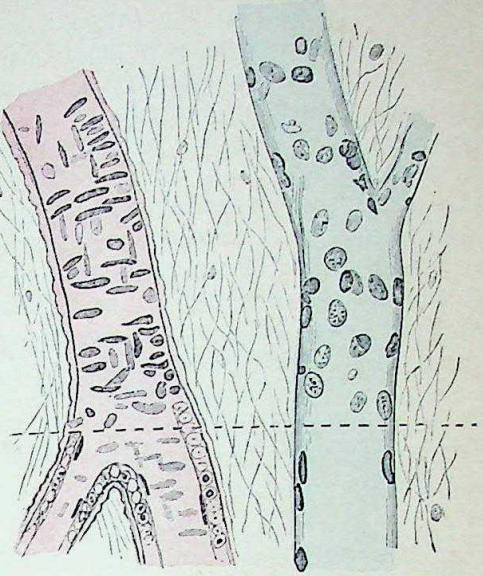

Surface view above the interrupted line; optical section below. Artery in red; vein in blue.

FIG. 631.—A transverse section through the wall of a femoral artery of a dog. × 250.



The capillaries.—The arterioles (excepting those of the cavernous structure of the sexual organs, of the splenic pulp, and of the placenta), subdivide into minute

CC-0. In Public Domain. Gurukul Kangri Collection, Haridwar

Digitized by Arya Samaj Foundation Chennai and eGangotri

vessels named *capillaries* which are interposed between the arterioles and the and constitute a network, the branches of which maintain the same throughout.

The *diameters* of the capillaries vary in the different tissues of the usual size being about 8 μ when the blood is circulating. The smallest in the brain and in the mucous membrane of the intestines; the larg skin, and in the marrow of bone, where they may have a diameter of 20 μ.

The *form* of the capillary network varies in the different tissues, the mes generally round or elongated. Round or angular meshes are most com prevail where there is a dense network, as in the lungs, in most glands and membranes, and in the cutis. Elongated meshes occur in muscles and nerves axis of the mesh running parallel with that of the muscle or nerve. Some capillaries have a looped arrangement, as in the papillae of the tongue and

The number of the capillaries and the size of the meshes determine the of vascularity of a part; the smallest meshes are found in the lungs and chorioid coat of the eye. As a general rule, the more active the functio organ, the closer is its capillary net and the larger its supply of blood. Few vessels are present in tendons, because in the latter little organic change after their formation.

The **structure of the capillaries.**—The wall of a capillary consists of flatte joined edge to edge by cement-substance, and continuous with the endothel which line the arteries and veins. When with nitrate of silver the material which u edges of the epithelial cells is display showing the outlines of the cells (fig. 632). cells are of large size and of an irregular p or lanceolate shape, each containing a nucleus which may be displayed by car hæmatoxylin. Between their edges, at points of their meeting, roundish dark sp sometimes seen, which have been desc stomata, though they are closed by inte substance. By some they are believed the situations through which the colourl puscles of the blood, when migrating fro blood-vessels, emerge; but this view universally accepted.

Fig. 632.—Capillaries from the mesentery of a guinea-pig, after treatment with a solution of nitrate of silver.

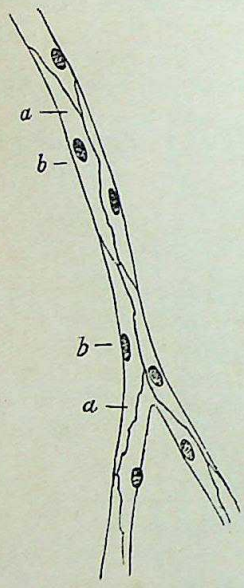

a. Cells. *b*. Their nuclei.

In developing capillaries, and in the ca of the glomeruli of the kidneys, the intesti and the chorioid coat of the eye, inter cement cannot be demonstrated, and th are believed to form a syncytium.

In many situations a delicate sheath or e of branched nucleated connective tissue found around the simple capillary tubes, cularly the larger ones; and in other especially in the glands, the capillaries are with retiform connective tissue.

The **sinusoids.**—In the heart, the liver, the suprarenal and parathyreoid the glomera carotica and glomus coccygeum, the smallest blood-vessels diffe true capillaries. They are wider, with an irregular lumen, and have no com tissue covering, their endothelial cells being in direct contact with the cells organ. Moreover, their walls are often incomplete. These vessels have been *sinusoids* by Minot. They are formed by columns of cells or trabeculæ their way into a large blood-vessel or blood-space and carrying its endo before them; at the same time the wall of the vessel or space grows out the columns of cells.

The **structure of the veins.**—The walls of the veins, like those of the are composed of three coats—internal, middle, and external; and these are the necessary modifications, analogous to the coats of the arteries; the in being the endothelial, the middle the muscular, and the external the com tissue or areolar (fig. 629). The main difference between the veins and the is in the comparative thickness of the middle coat in the former.

CC-0. In Public Domain. Gurukul Kangri Collection, Haridwar

Digitized by Arya Samaj Foundation Chennai and eGangotri

In the smallest veins the three coats are hardly to be distinguished (fig. 630). endothelium is supported on a membrane separable into two layers, the outer which is the thicker, and consists of a delicate, nucleated membrane (tunica intima), while the inner is composed of a network of longitudinal elastic fibres (tunica media). In the veins next above these in size (0·4 mm. in diameter), a connective tissue layer containing numerous smooth muscular fibres circularly disposed can be traced, forming the middle coat, while the elastic and connective tissue elements of the outer coat are more distinctly perceptible. In the middle-sized veins (fig. 633) the endothelium is of the same character as in the arteries, but nuclei are shorter and broader. It is supported by a connective tissue layer, consisting of a delicate network of branched cells, and external to this is a layer of elastic fibres disposed in the form of a network in place of the infinite fenestrated membrane seen in arteries. This constitutes the *tunica intima*. The *tunica media* is composed of a thick layer of connective tissue with elastic fibres, interspersed, in some veins, with a layer of smooth muscular fibres arranged circularly. The white fibres are in considerable excess, and the elastic fibres are in much greater proportion in the veins than in the arteries. The *tunica adventitia* consists, as in the arteries, of areolar tissue with longitudinal elastic fibres.

FIG. 633.—A transverse section through the wall of a femoral vein of a dog. ×250. The elastic tissue is not differentiated in this preparation.

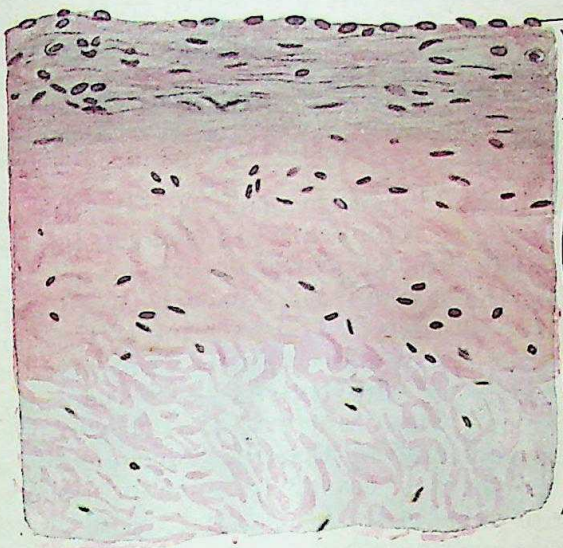

In the largest veins from two to five times thicker than the tunica media, and contains a large number of longitudinal muscular fibres. These are most distinct in the inferior vena cava, especially at the termination of this vein in the heart, in the trunks of the hepatic veins, in all the large trunks of the portal vein, and in the external renal, and azygos veins. In the inferior vena cava, renal and portal veins they extend through the whole thickness of the outer coat, but in the other veins a layer of connective and elastic tissue is found external to the muscular coat. The large veins which open into the heart are covered for a short distance by a layer of striped muscular tissue continued on to them from the heart. Muscular tissue is wanting—(1) in the veins of the maternal part of the placenta; (2) in the venous sinuses of the dura mater and the veins of the pia mater; (3) in the veins of the retina; (4) in the veins of the spongy substance of bones; (5) in the cavernous spaces of the corpora cavernosa. The veins of the above-mentioned parts consist of an endothelial lining supported on one or more layers of areolar tissue.

Most veins are provided with *valves* which serve to prevent the reflux of the blood. Each valve is formed by a reduplication of the inner coat, strengthened by connective tissue and elastic fibres, and is covered on both surfaces by endothelium, the arrangement of which differs on the two surfaces. On the surface of the valve next the wall of the vein, the cells are arranged transversely; while on the other surface, over which the current of blood flows, the cells are arranged longitudinally in the direction of the current. Most commonly two such valves are found placed opposite one another, more especially in the smaller veins or in larger trunks at the point where they are joined by smaller branches; occasionally there are three and sometimes only one. The valves are semilunar. They are attached by their convex edges to the wall of the vein; the concave margins are directed in the course of the venous current, and lie in close apposition with the wall of the vein as long as the current of blood takes its natural course; however, any regurgitation takes place, the valves become distended, their free edges are brought into contact, and the current is interrupted. The attached side of the vein on the cardiac side of the attachment of each valve is expanded

CC-0. In Public Domain. Gurukul Kangri Collection, Haridwar

Digitized by Arya Samaj Foundation Chennai and eGangotri

into a pouch or sinus, which gives to the vessel, when injected or distended, blood, a knotted appearance. The valves are very numerous in the veins of the extremities, especially in the veins of the lower extremities, these vessels to conduct the blood against the force of gravity. They are absent in the small veins, i.e. those less than 2 mm. in diameter, also in the venæ cavæ, the renal, uterine, and ovarian veins. The cerebral and spinal veins, the veins of cancellated tissue of bone, the pulmonary veins, and the umbilical vein and its branches, are also destitute of valves. A few valves are found in each renal vein, and one also at its point of junction with the renal vein or inferior vena cava respectively. A few valves are occasionally found in the azygos and hemiazygos veins. Valves are present in the tributaries of the portal vein in the foetus for a short time after birth; as a rule they soon atrophy and disappear, but sometimes they persist in a degenerate form.

The larger veins, like the arteries, are supplied with nutrient vessels, *vasorum*. Nerves also are distributed to the veins in the same manner as the arteries, but in much less abundance.

The Thoracic Cavity

The heart and lungs are situated within the thorax, the walls of which afford them protection. The heart lies between the two lungs, and is enclosed in a fibrous bag, the *pericardium*, while each lung is covered with a serous membrane, the *pleura*; the space between the pleural membranes is called the *mediastinal cavity*. The skeleton of the thorax, and the shape and boundaries of the cavity, have already been described (p. 193).

The **cavity of the thorax**.—The capacity of the thoracic cavity does not correspond with its apparent size externally, because (1) the lower part of the space enclosed by the ribs is occupied by some of the abdominal viscera, and (2) the thoracic cavity extends for a short distance into the neck above the anterior parts of the first ribs. During life the size of the thoracic cavity is constantly varying with the movements of the ribs and Diaphragm, and with the degree of distension of the abdominal viscera.

The **upper opening of the thorax**.—The parts which pass through the upper opening of the thorax are, from before backwards in or near the middle line, the Sternohyoideus and Sternothyreoideus muscles, the remains of the thymus, the inferior thyreoid veins, the trachea, œsophagus, thoracic duct, and the Longus colli muscles; laterally the innominate veins, the innominate artery, the left common carotid and left subclavian arteries, the internal mammary arteries and the costocervical trunks, the vagus, cardiac, phrenic and sympathetic nerves, the greater parts of the anterior divisions of the thoracic nerves, and the left recurrent nerve. The apex of each lung, covered by the pleura, also projects through this aperture, a little above the level of the sternal end of the first rib.

The **lower opening of the thorax** is wider transversely than from before backwards. It slopes obliquely downwards and backwards, so that the thoracic cavity is much deeper behind than in front. The Diaphragm (p. 195) closes the opening and forms the floor of the thorax. The floor is higher at the centre than at the sides, and higher on the right side than on the left; in the dead body the right side reaches the level of the upper border of the fifth costal cartilage, while the left extends only to the corresponding part of the sixth costal cartilage. From the highest point on either side the floor slopes suddenly downwards to the costal and vertebral attachments of the Diaphragm; this slope is more marked behind than in front, so that only a narrow space is left between the Diaphragm and the posterior wall of the thorax.

The Pericardium

The **pericardium** (fig. 634) is a conical fibroserous sac which contains the heart and the roots of the great vessels. It is placed in the mediastinal cavity behind the sternum and the cartilages of the third, fourth, fifth, sixth

CC-0. In Public Domain. Gurukul Kangri Collection, Haridwar

Digitized by Arya Samaj Foundation Chennai and eGangotri

fourth ribs of the left side, and in front of the thoracic vertebræ, from the fifth to the eighth inclusive.

In front, it is separated from the anterior wall of the thorax, in the greater part of its extent, by the lungs and pleuræ; but a small area, usually corresponding with the left half of the lower part of the body of the sternum, and the internal ends of the cartilages of the fourth and fifth ribs of the left side, has a direct relationship with the chest-wall. Until puberty or adolescence

FIG. 634.—The posterior wall of the pericardial sac, showing the lines of reflection of the serous pericardium on to the great vessels.

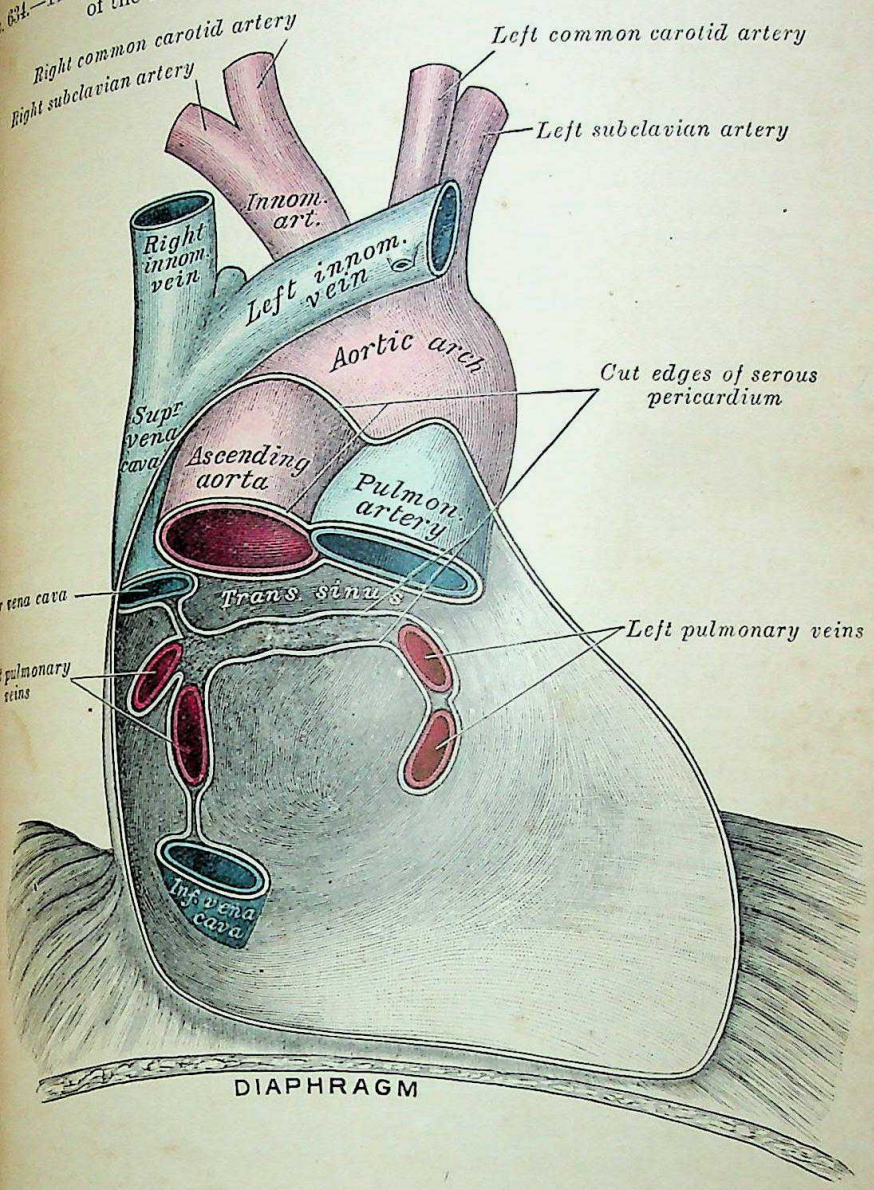

lower end of the thymus is in contact with the front of the upper part of the pericardium. *Behind*, the pericardium rests upon the bronchi, the œsophagus, the œsophageal plexus of nerves, the descending thoracic aorta, and the posterior part of the mediastinal surface of each lung. *Laterally*, it is covered by the pleuræ, and is in relation with the mediastinal surfaces of the lungs; the phrenic nerve, with its accompanying vessels, descends between the pericardium and the mediastinal pleura on either side.

The structure of the pericardium.—Although the pericardium is usually described as a single sac, an examination of its structure shows that it consists partially of two sacs intimately connected with one another, but totally different in structure. The outer sac, known as the *fibrous pericardium*, consists of fibrous tissue. The inner sac, or *serous pericardium*, is a delicate membrane

CC-0. In Public Domain. Gurukul Kangri Collection, Haridwar

Digitized by Arya Samaj Foundation Chennai and eGangotri

which lies within the fibrous sac and lines its walls; it is composed of a layer of flattened cells resting on loose connective tissue. The heart-tube the wall of the serous sac from above and behind, and practically obl its cavity, the space being a potential one.

The *fibrous pericardium* forms a flask-shaped bag, the neck of closed by its continuity with the external coats of the great vessels base is attached to the central tendon and to the muscular fibres of half of the Diaphragm. In some of the lower mammals the base completely separated from the Diaphragm or joined to it by some loose tissue; in man much of its diaphragmatic attachment consists of loose tissue which can be readily broken down, but over a small area the tendon of the Diaphragm and the pericardium are fused. Above, the pericardium not only blends with the external coats of the great ves is continuous with the pretracheal layer of the fascia colli (deep cervical By means of these upper and lower connexions it is securely anchored the thoracic cavity. It is also attached to the posterior surface of the by a *superior* and an *inferior sternopericardial ligament*; the superior to the manubrium, and the inferior to the xiphoid process.

The vessels receiving prolongations from the fibrous pericardium the aorta, the superior vena cava, the right and left pulmonary arteries the four pulmonary veins. The inferior vena cava enters the pericardium through the central tendon of the Diaphragm, and receives no covering from the fibrous layer.

The *serous pericardium* is, as already stated, a closed sac which lines fibrous pericardium and is invaginated by the heart; it therefore consists of a *visceral* and a *parietal* portion. The visceral portion, or *epicardium*, the heart and the great vessels, and from the latter is continuous with parietal layer which lines the fibrous pericardium. The portion which the vessels is arranged in the form of two tubes. The aorta and pulmonary artery are enclosed in one tube, the *arterial mesocardium*. The superior inferior venæ cavæ and the four pulmonary veins are enclosed in a tube, the *venous mesocardium*, the attachment of which to the parietal is ∩-shaped. The cul-de-sac between the limbs of the ∩ lies behind the atrium and is known as the *oblique sinus*, while the passage between venous and arterial mesocardia—i.e. between the aorta and pulmonary in front and the atria behind—is termed the *transverse sinus*.

The ligament of the left vena cava.—Between the left pulmonary and subjacent pulmonary vein is a triangular fold of the serous pericardium known as the *ligament of the left vena cava* (vestigial fold of Marshall), formed by the duplicature of the serous layer over the remnant of the part of the left duct of Cuvier (left superior vena cava) (p. 127). This becomes obliterated during fœtal life, and remains as a fibrous band stretching from the upper part of the left superior intercostal vein to the back of left atrium, where it is continuous with a small vein, the *oblique vein of left atrium* (oblique vein of Marshall), which opens into the coronary (fig. 637).

The *arteries* of the pericardium are derived from the internal mammary and their musculophrenic branches, and from the descending thoracic aorta *nerves* are derived from the vagus and phrenic nerves, and the sympathetic trunk.

Applied Anatomy.—Effusion of fluid into the pericardial sac often occurs in rheumatism or pneumonia, or in patients with chronic vascular and renal disease, embarrassing the heart's action and giving rise to signs of cardiac distress, such as pallor, and feeble pulse, dyspnœa, and restlessness. On examination, the apical cardiac impulse is absent, or replaced by a more extensive indefinite and wavering pulsation; it appear to be in the second, third, or fourth left space, and is then not an apex-beat as Potain has stated, but due to the impact of some portion of the heart-wall near base. In children the precordial intercostal spaces may bulge outwards. The striking sign, however, is the great increase in all directions of the precordial dulness percussion. This becomes pear-shaped, the stalk of the pear reaching up to about left sternoclavicular articulation; the dulness also extends some distance to the right the sternum, particularly in the fifth interspace (Rotch). The fluid collects mainly either side of the heart, and below it, especially on the left side, where the Diaphragm yield more readily to pressure than it can on the right. Ewart has drawn attention to presence of a square patch of dulness over the base of the left lung behind, reaching

CC-0. In Public Domain. Gurukul Kangri Collection, Haridwar

Digitized by Arya Samaj Foundation Chennai and eGangotri

the level of the ninth or tenth rib, and extending laterally as far as the inferior angle of the scapula; the underlying lung-tissue gives the physical signs of compression or collapse.

Paracentesis of the pericardium and withdrawal of the fluid within it is sometimes necessary to relieve embarrassment of the heart's action. The puncture may be made in the fifth or sixth left intercostal space near the sternum, with care to avoid wounding the internal mammary artery that usually runs 1·25 cm. lateral to the sternal edge. Alternatively the exploring needle may be entered at the left costoxiphoid angle, and passed upwards and backwards into the pericardial sac. Curschmann recommends paracentesis in or lateral to the left mammary line in the fifth or sixth left interspace, in view of the fact that the fluid tends to collect on either side of and below the heart rather than in front of it.

Pericardiotomy is required when the effusion is of a purulent nature. In this operation a portion of the fifth or sixth costal cartilage is excised. An incision is made along the left border of the sternum from the upper border of the fourth cartilage to the seventh. The fifth costal cartilage is now separated from the sternum and raised, the tissues beneath it being peeled off, so as to avoid wounding the internal mammary artery or the pleura. The fibres of the Transversus thoracis are then separated close to the sternum, and the pericardium felt for and opened, the finger guarding the pleura and left internal mammary artery.

Cardiolysis, or the operation of opening the pericardial sac and dividing adhesions between its visceral and parietal layers, is one that appears to have much to recommend it on clinical grounds. In practice, however, it has rarely proved satisfactory, owing to the great toughness and extent of the adhesions when they are present, and the free hæmorrhage that occurs when they are divided.

The Heart (Cor)

The heart is a muscular bag of a somewhat conical form; it lies between the lungs in the middle mediastinal cavity (fig. 635), and is enclosed in the

Fig. 635.—The heart and lungs. Anterior aspect.

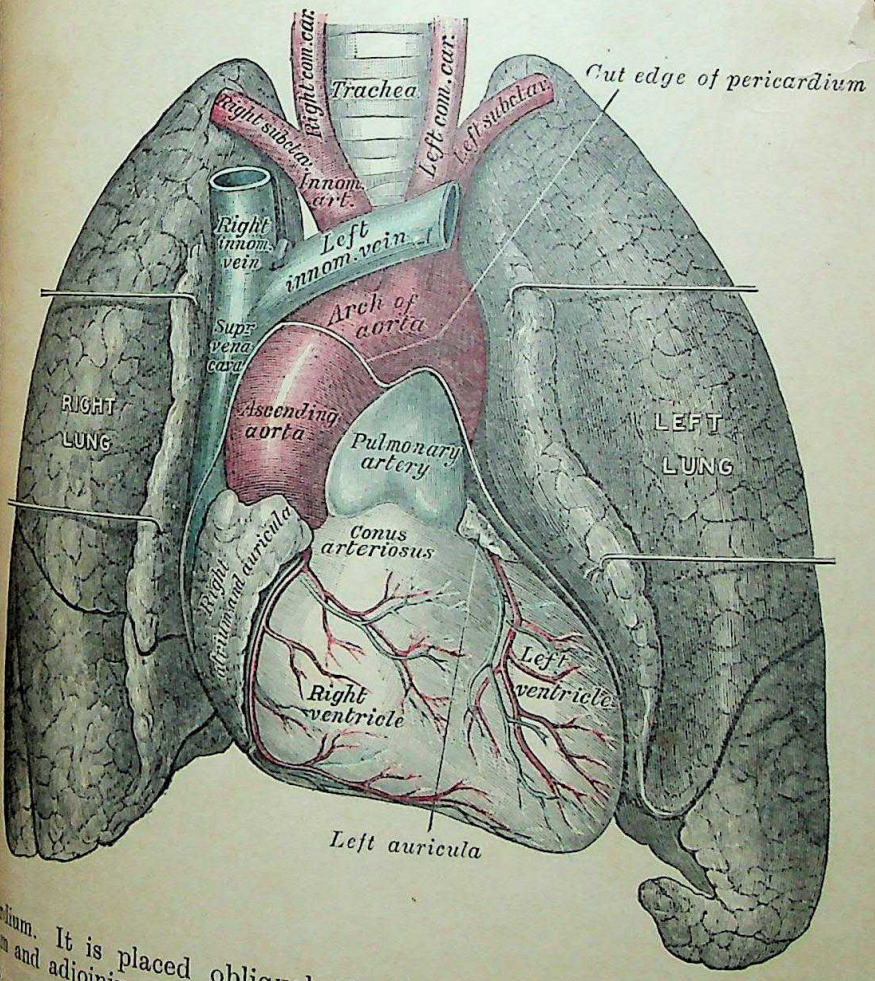

...ium. It is placed obliquely in the chest behind the body of the ...m and adjoining parts of the rib cartilages, and projects farther into

CC-0. In Public Domain. Gurukul Kangri Collection, Haridwar

Digitized by Arya Samaj Foundation Chennai and eGangotri

the left than into the right half of the thoracic cavity, so that about one-th of it is situated on the right and two-thirds on the left of the median plane.

Size.—The heart of the adult measures about 12 cm. from base to ap 8 to 9 cm. transversely at the broadest part, and 6 cm. anteroposteriorly. Its weight, in the male, varies from 280 to 340 grammes; in the female, from to 280 grammes. It continues to increase in weight and size up to an advan period of life, and this increase is more marked in men than in women.

Component parts.—As already stated (p. 567) the heart is divided four chambers, viz. right and left atria, and right and left ventricles: the sion is indicated on the surface of the heart by grooves or sulci. The are separated from the ventricles by the *coronary sulcus* (auriculoventric groove); this sulcus contains the trunks of the coronary vessels of the he

FIG. 636.—A section through the heart, showing the ventricular septum.

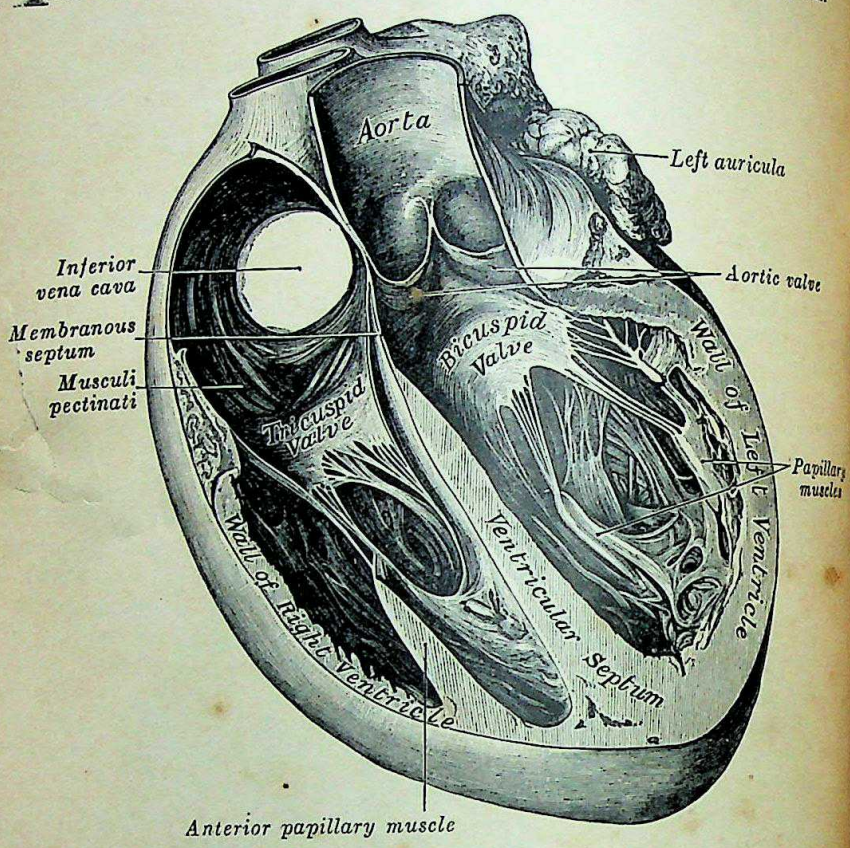

and is deficient in front, where it is crossed by the root of the pulmonary ar The *interatrial groove*, separating the two atria, is scarcely marked on posterior surface, while anteriorly it is hidden by the pulmonary artery aorta. The ventricles are separated by two grooves, one of which, the *longitudinal sulcus*, is situated on the sternocostal surface of the heart its left margin, the other, the *posterior longitudinal sulcus*, on the diaphrag surface near the right margin; these grooves extend from the base ventricular portion to a notch, the *incisura apicis cordis*, situated a li the right of the apex of the heart.

The *base* (fig. 637) is somewhat quadrilateral in form; it looks up backwards, and to the right, and is separated from the fifth, sixth, seven eighth thoracic vertebræ by the pericardium, œsophagus, aorta, and th duct. It is formed mainly by the left atrium, and, to a small extent, b posterior part of the right atrium. It is in relation above with the bifurc of the pulmonary artery, and is bounded below by the posterior part coronary sulcus, containing the coronary sinus. On the right it is limi the sulcus terminalis of the right atrium, and on the left by the ligament cava and the oblique vein of the left atrium. The four pulm either side, open into the left atrium, whilst the superior

CC-0. In Public Domain. Gurukul Kangri Collection, Haridwar

Digitized by Arya Samaj Foundation Chennai and eGangotri

ss into the upper part, and the inferior vena cava into the lower part, right atrium. The portion of the left atrium between the openings of and left pulmonary veins constitutes the anterior wall of the oblique the pericardium (p. 576).

upper, formed by the left ventricle, is directed downwards, forwards, the left, and is overlapped by the left lung and pleura: it lies behind left intercostal space, about 8 cm. from the mid-sternal line, or, in the about 4 cm. below and 2 cm. to the medial side of the left mammary

sternocostal surface (fig. 638) is directed forwards, upwards, and to It consists of an atrial and a ventricular portion, the former being and to the right, the latter below and to the left, of the anterior part

FIG. 637.—The base and the diaphragmatic surface of the heart.

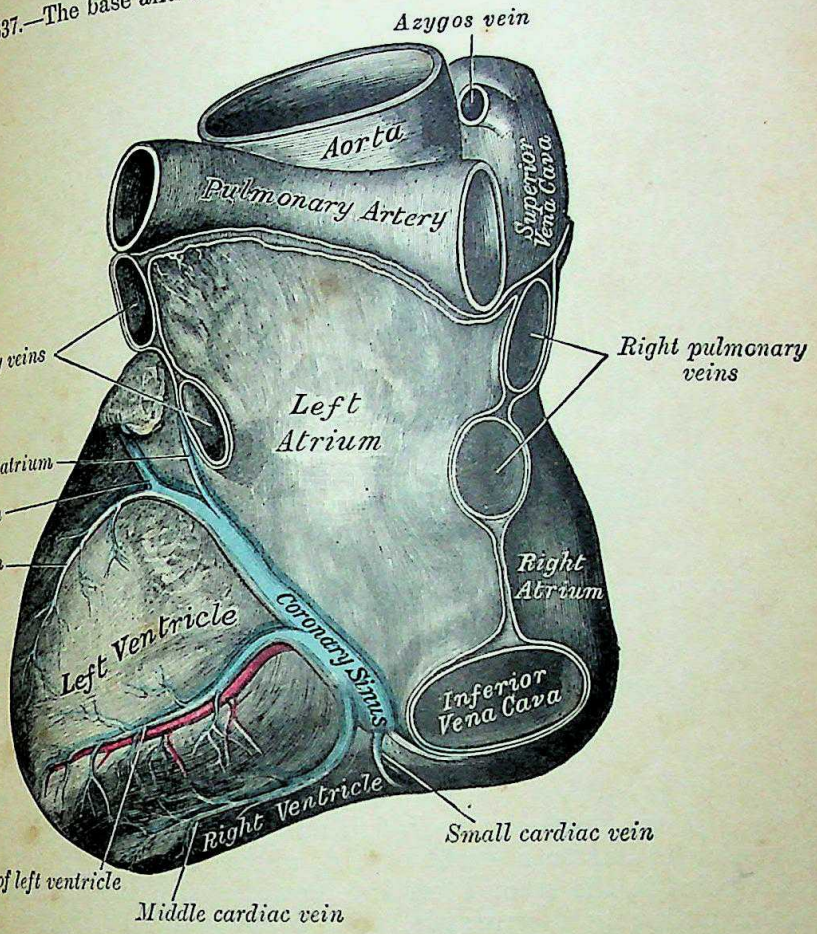

coronary sulcus. The atrial portion is almost entirely formed by the atrium; the greater part of the left atrium is hidden by the ascending and pulmonary artery (fig. 638), and only a small part of its auricula forwards on the left side of the pulmonary artery. About two-thirds ventricular part are formed by the right, and one-third by the left, the line of separation between the ventricles being marked by the longitudinal sulcus. The sternocostal surface lies behind the body of sternum, the Transversus thoracis muscles and the cartilages of the third, fifth, and sixth ribs; owing to the bulging of the heart towards the a much larger part of the surface lies behind the left than the right cartilages. The sternocostal surface is also covered by the pleuræ and anterior parts of the lungs, with the exception of a small triangular corresponding with the cardiac notch in the left lung. The base of area is represented by a line on the middle of the sternum from the of the fourth costal cartilages to the junction of the body of the sternum the xiphoid process, and the sides by lines from the apex of the heart to upper and lower ends of the base line.

CC-0. In Public Domain. Gurukul Kangri Collection, Haridwar

Digitized by Arya Samaj Foundation Chennai and eGangotri

The *diaphragmatic surface* (fig. 637), directed downwards and backwards, is formed by the ventricles (chiefly by the left ventricle), and upon the central tendon and a small part of the left muscular portion of the Diaphragm. It is separated from the base by the posterior part of the coronary sulcus, and is traversed obliquely by the posterior longitudinal sulcus.

The *right margin* of the heart, formed by the right atrium, is nearly almost vertical; it is situated behind the third, fourth, and fifth right costal cartilages 1·25 cm. from the margin of the sternum.

The *inferior or acute margin*, formed almost entirely by the right ventricle, is nearly horizontal, and extends from the sternal end of the sixth right costal cartilage to the apex of the heart.

FIG. 638.—The sternocostal surface of the heart.

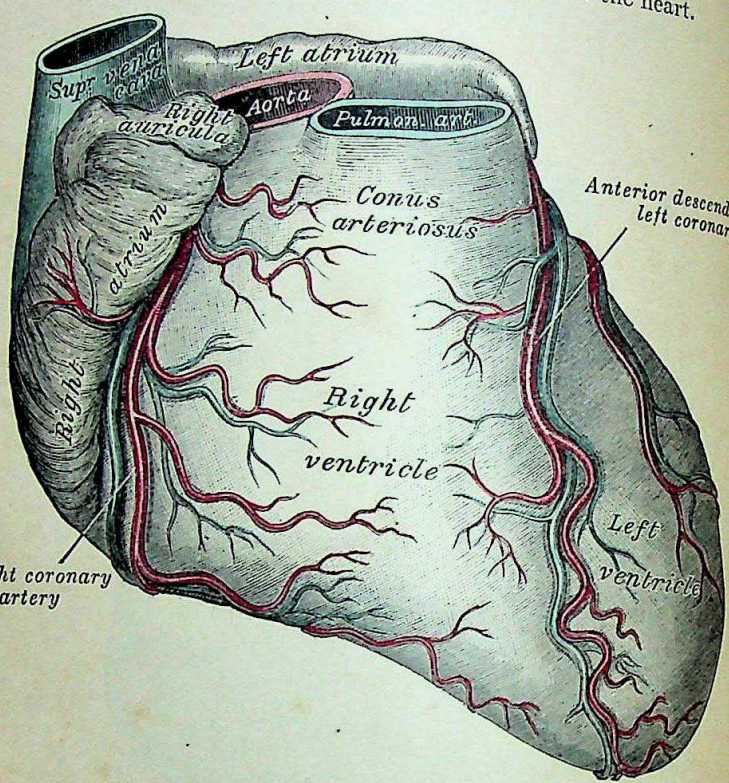

The *left or obtuse margin* is full and rounded; it is formed mainly by the left ventricle, but to a slight extent, above, by the left auricula. It extends from a point in the second left intercostal space, about 2 cm. from the sternal margin, obliquely downwards, with a convexity to the left, to the apex of the heart.

The atrial septum.—A partition, named the *atrial septum* (figs. 636, 642), intervenes between the right and left atria, and is so obliquely placed that the right atrium lies in front and to the right of the left atrium.

The ventricular septum.—The right ventricle is separated from the left by the *ventricular septum* (figs. 636, 642), which slopes obliquely from the left backwards and towards the right, and is curved with the convexity towards the right ventricle: its margins correspond with the anterior and posterior longitudinal sulci on the surface of the heart. The greater portion of the septum is thick and muscular, and constitutes the *muscular ventricular septum*, but its upper and posterior part, which separates the aortic vestibule from the lower part of the right atrium and upper part of the right ventricle, is thin and fibrous, and is termed the *membranous ventricular septum*. A communication may exist between the ventricles at this part, owing to defective development of the membranous septum.

The right atrium (figs. 639, 642) consists of two parts: a principal cavity or sinus venarum, situated posteriorly, and an anterior, smaller portion, the auricula.

CC-0. In Public Domain. Gurukul Kangri Collection, Haridwar

Digitized by Arya Samaj Foundation Chennai and eGangotri

The *sinus venarum* is the large quadrangular pouch placed between the venæ cavæ. Its walls, which are extremely thin, are connected below the right ventricle, and medially with the left atrium.

The *auricula* is a small, conical, muscular pouch, the margins of which are dentated edge. It projects from the upper and front part of the venarum forwards and towards the left side, overlapping the root of the (fig. 638).

The separation of the auricula from the sinus venarum is indicated, on outer surface of the atrium, by a groove, the *sulcus terminalis*, which extends the front of the superior vena cava to the front of the inferior vena cava, represents the line of union of the sinus venosus of the embryo with the

FIG. 639.—The interior of the right side of the heart.

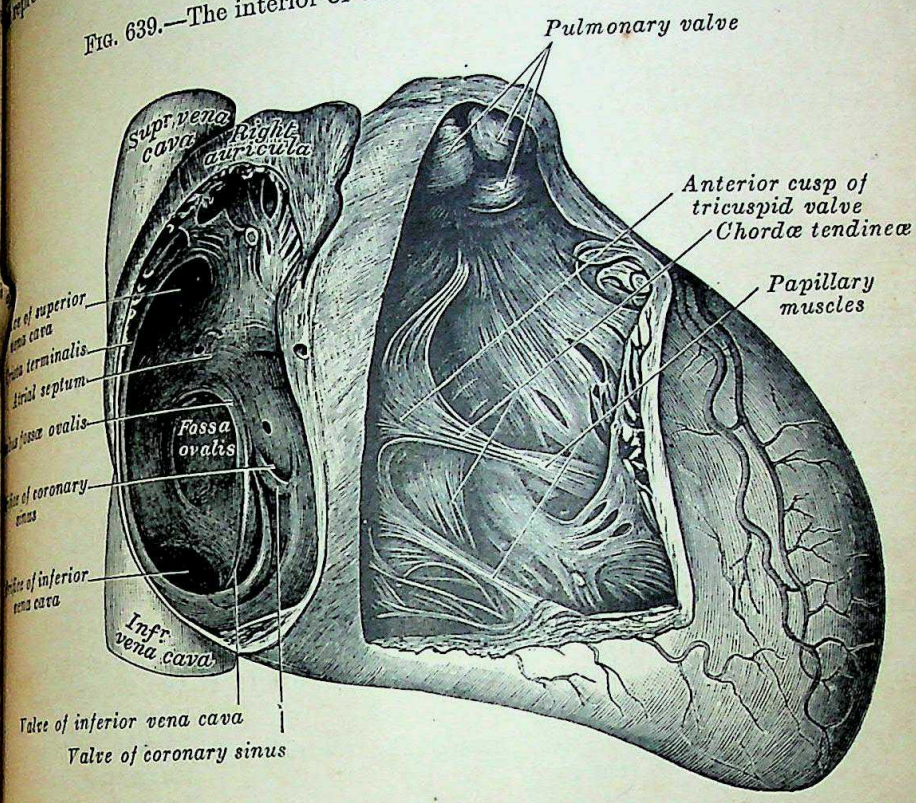

tive atrium. On the inner surface of the atrium the separation is marked vertical, smooth, muscular ridge, the *crista terminalis*. Behind the crista nalis the internal surface of the atrium is smooth, while in front of it the ular fibres of the wall are raised into parallel ridges resembling the teeth comb, and hence named the *musculi pectinati*.

The interior of the right atrium (fig. 639) presents the following parts for mination:

Orifices:
- Superior vena cava.
- Inferior vena cava.
- Coronary sinus.
- Foramina venarum minimarum.
- Right atrioventricular.

Valves:
- Valve of the inferior vena cava.
- Valve of the coronary sinus.

Fossa ovalis.
Limbus fossæ ovalis.
Intervenous tubercle.
Musculi pectinati.
Crista terminalis.

The *superior vena cava* (fig. 638) returns the blood from the upper half of body, and opens into the upper and posterior part of the atrium. Its orifice ected downwards and forwards, and has no valve.

CC-0. In Public Domain. Gurukul Kangri Collection, Haridwar

Digitized by Arya Samaj Foundation Chennai and eGangotri

The *inferior vena cava* (fig. 639), larger than the superior, returns the blood from the lower half of the body, and opens into the lowest part of the right atrium near the atrial septum; its orifice, directed upwards and backwards, is guarded by a rudimentary valve, the *valve of the inferior vena cava* (valve of Eustachius). The blood entering the atrium through the superior vena cava is directed downwards and forwards towards the atrioventricular orifice, while that entering through the inferior vena cava is directed upwards and backwards towards the atrial septum. This is the normal direction of the two streams in fœtal life.

The *coronary sinus* (fig. 637) returns the greater part of the blood from the substance of the heart. Its opening is placed between the orifice of the inferior vena cava and the atrioventricular opening, and is protected by a semilunar circular valve, the *valve of the coronary sinus* (valve of Thebesius).

The *foramina venarum minimarum* are the orifices of minute veins (*venæ cordis minimæ*), which return a small quantity of blood directly from the substance of the heart.

The *right atrioventricular orifice* is the large opening between the right atrium and ventricle; it is described with the right ventricle (p. 583).

The *valve of the inferior vena cava* is situated in front of the orifice of the inferior vena cava. It is semilunar in form, its convex margin being attached to the anterior margin of the orifice; its concave margin, which is free, ends in two cornua, of which the left is continuous with the anterior edge of the limbus fossæ ovalis, while the right is lost on the wall of the atrium. The valve is formed by a duplicature of the lining membrane of the atrium, containing a few muscular fibres. During fœtal life this valve is of large size, and serves to direct the blood from the inferior vena cava into the left atrium through an opening, named the foramen ovale, in the atrial septum. It occasionally persists in the adult, and may assist in preventing the return of blood into the inferior vena cava; it may present a cribriform or filamentous appearance; sometimes it is absent.

The *valve of the coronary sinus* (fig. 639) is a semicircular fold of the lining membrane of the atrium, at the orifice of the coronary sinus. It prevents the regurgitation of blood into the sinus during the contraction of the atrium. This valve may be double or it may be cribriform.

The *fossa ovalis* (fig. 639) is an oval depression on the lower part of the septal wall of the atrium, above and to the left of the orifice of the inferior vena cava. It corresponds to the situation of the foramen ovale in the fœtus.

FIG. 640.—A transverse section through the ventricles of the heart.

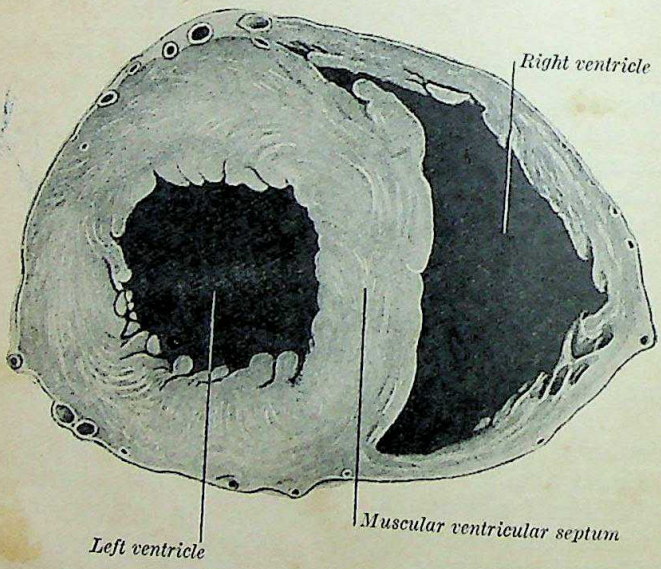

The *limbus fossæ ovalis* (annulus ovalis) (fig. 639) is the prominent margin of the fossa ovalis. It is most distinct above and at the sides of the fossa; below, it is deficient. A small slit-like valvular opening is occasionally found, at the upper margin of the fossa, leading upwards, beneath the limbus, into the left atrium; it is the remnant of the foramen ovale between the two atria.

The *intervenous tubercle* (tubercle of Lower) is a small projection on the posterior wall of the right atrium, above the fossa ovalis. It is distinct in the hearts of quadrupeds, but in man is scarcely visible. During fœtal life it may direct the blood from the superior vena cava towards the atrioventricular opening.

CC-0. In Public Domain. Gurukul Kangri Collection, Haridwar

Digitized by Arya Samaj Foundation Chennai and eGangotri

The *crista terminalis* and the *musculi pectinati* have been described (p. 581).

The **right ventricle** (figs. 639, 640, 642) extends from the right atrium to the apex of the heart. Its anterosuperior surface is convex, and forms

FIG. 641.—The heart. Superior aspect.

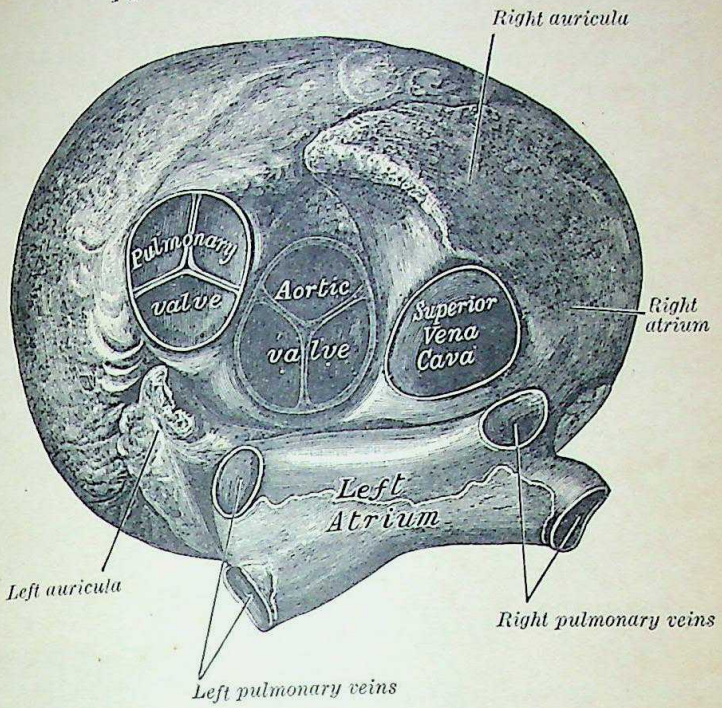

the part of the sterno-
surface of the heart.
rior surface is flat-
rests upon the
phragm, and forms a
part of the dia-
matic surface of the
Its posterior wall
formed by the ventri-
septum, which bulges
the right ventricle, so
a transverse section
the cavity presents a
entic outline (fig. 640).
upper left angle forms
ical pouch, the *conus*
ensus, from which the
nary artery arises.
ndinous band, the
of the conus arterio-
connects the posterior
e of the conus
osus to the aorta;
tendon is continuous
the membranous
ricular septum. The
of the right ventricle is thinner than that of the left, the proportion
en them being as 1 to 3; it is thickest at the base, and gradually
mes thinner towards the apex of the ventricle. The cavity of the right
cle is capable of holding about 85 c.c. of blood.

The interior of the right ventricle (fig. 639) presents the following parts
examination:

Orifices { Right atrioventricular. Pulmonary artery.	Valves { Tricuspid. Pulmonary.
Trabeculæ carneæ.	Chordæ tendineæ.

The *right atrioventricular orifice* is the large oval aperture between the right
m and ventricle. Situated at the base of the ventricle, it measures about
in diameter and is encircled by a fibrous ring, covered with the lining
brane of the heart; it is considerably larger than the left atrioventricular
e, being sufficient to admit the tips of four fingers. It is guarded by the
spid valve.

The *orifice of the pulmonary artery* is circular in form, and situated at the
nt of the conus arteriosus, close to the ventricular septum. It is placed
e and to the left of the atrioventricular opening, and is guarded by the
nary semilunar valves.

The *tricuspid valve* (figs. 639, 643) guards the right atrioventricular orifice,
consists of three somewhat triangular cusps or segments, *anterior*, *posterior*
medial; in the angles between the cusps small intermediate segments are
times seen. The anterior cusp, the largest, is interposed between the
ventricular orifice and the conus arteriosus, while the medial cusp is in
with the ventricular septum. Each cusp is formed by a duplicature of
ning membrane of the heart, strengthened by intervening layers of fibrous
. The central parts of the cusps are comparatively thick and strong,
marginal portions thin and translucent. Their bases are attached to the
s ring surrounding the atrioventricular orifice and are also joined to
other so as to form a continuous annular membrane, while their apices
into the ventricular cavity. Their atrial surfaces, directed towards
blood-current from the atrium, are smooth; their ventricular surfaces,
ed towards the wall of the ventricle, are rough and irregular and, together

CC-0. In Public Domain. Gurukul Kangri Collection, Haridwar

Digitized by Arya Samaj Foundation Chennai and eGangotri

with the apices and margins of the cusps, give attachment to a number of delicate tendinous cords, the *chordæ tendineæ*.

The *trabeculæ carneæ* are round or irregular muscular columns which rise from the whole of the inner surface of the ventricle, with the exception of the conus arteriosus, the wall of which is smooth. They are of three kinds: some are mere ridges, others are fixed at their ends but free in their middle, while a third set (*musculi papillares*) are continuous by their bases with the wall of the ventricle, while their apices project into the cavity, and give rise to the chordæ tendineæ which pass to be attached to the segments of the

FIG. 642.—A transverse section through the mediastinal cavity at the level of the body of the seventh thoracic vertebra.

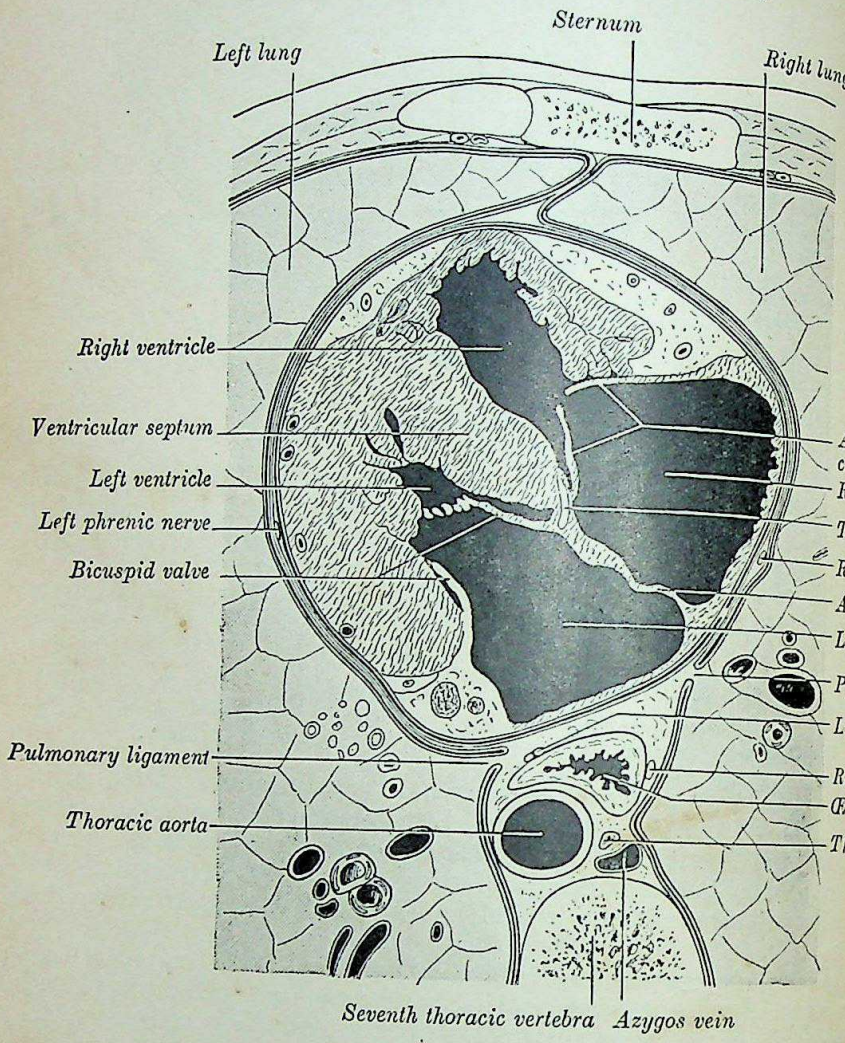

tricuspid valve. There are two papillary muscles, anterior and posterior; the anterior is the larger, and its chordæ tendineæ are connected with the anterior and posterior cusps of the valve; the posterior papillary muscle sometimes consists of two or three parts, and its chordæ tendineæ are connected with the posterior and medial cusps. Some chordæ tendineæ also spring directly from the ventricular septum, or from small papillary eminences on it, and pass to the anterior and medial cusps. A muscular band, well marked in sheep and some other animals, frequently extends from the base of the anterior papillary muscle to the ventricular septum. From its attachment it may assist in preventing over-distension of the ventricle, and so has been named the *moderator band*.

The *pulmonary semilunar valves* (figs. 639, 641) are three in number, two in front and one behind, and are formed by duplicatures of the lining membrane strengthened by fibrous tissue. They are attached, by their convex margins

CC-0. In Public Domain. Gurukul Kangri Collection, Haridwar

Digitized by Arya Samaj Foundation Chennai and eGangotri

the wall of the pulmonary artery at its junction with the ventricle, their borders being directed upwards into the lumen of the vessel. The free attached margins are strengthened by tendinous fibres, and at the middle the free margin there is a thickened nodule (*corpus Arantii*). From this are absent tendinous fibres radiate through the valve to its attached margin, on either side of the two narrow crescentic portions, the *lunulæ*, placed immediately adjoining the free margin (fig. 644). Opposite to the semilunar valves the pulmonary artery presents three slight dilatations or sinuses (sinuses of Valsalva).

Fig. 643.—The bases of the ventricles, exposed by removal of the atria.

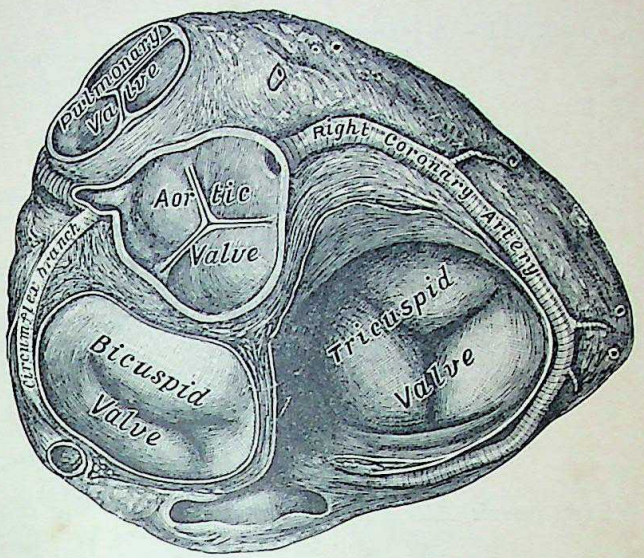

The **left atrium** is rather smaller than the right, but its walls are thicker, measuring about 3 mm.; it consists, like the right, of two parts, a *principal cavity* and an *auricula*.

The *principal cavity* is cubical in form, and concealed, in front, by the pulmonary artery and aorta. It is separated from the right atrium by the atrial septum, and opening into it on either side are the two pulmonary veins.

The *auricula* is somewhat constricted at its junction with the principal cavity; it is longer, narrower, and more curved than that of the right atrium, and its margins are more deeply indented. It is directed forwards on the left side of the pulmonary artery, and overlaps the root of this vessel.

The interior of the left atrium (fig. 645) presents the following parts for examination:

Orifices of the four pulmonary veins.
Left atrioventricular orifice.
Foramina venarum minimarum.
Musculi pectinati.

The *pulmonary veins*, four in number, open into the upper part of the posterior surface of the left atrium—two on either side of its middle line; their orifices are not provided with valves. The two left veins frequently end by a common opening.

The *left atrioventricular orifice* is the aperture between the left atrium and ventricle; it is described on p. 586.

The *foramina venarum minimarum* are the orifices of minute veins (venæ cordis minimæ) which return a small quantity of blood directly from the muscular substance of the heart.

The *musculi pectinati*, fewer and smaller than those in the right atrium, are confined to the inner surface of the auricula.

On the atrial septum may be seen a lunate impression, bounded below by a crescentic ridge, the concavity of which is directed upwards. The depression is just above the fossa ovalis of the right atrium.

The **left ventricle** is longer and more conical in shape than the right, and in transverse section its cavity presents an oval or nearly circular outline (fig. 640). It forms a small part of the sternocostal, and a considerable part of the diaphragmatic, surface of the heart; it also forms the apex of the heart. Its walls are about three times as thick as those of the right ventricle.

Its interior (fig. 645) presents the following parts for examination:

Orifices { Left atrioventricular. Aortic.
Trabeculæ carneæ.
Valves { Bicuspid or mitral. Aortic.
Chordæ tendineæ.

CC-0. In Public Domain. Gurukul Kangri Collection, Haridwar

Digitized by Arya Samaj Foundation Chennai and eGangotri

The *left atrioventricular orifice* is placed below and to the left of the orifice. It is a little smaller than the right atrioventricular orifice, and the tips of only three fingers. It is surrounded by a dense fibrous ring is guarded by the bicuspid or mitral valve.

The *aortic orifice* is a circular aperture in front and to the right of atrioventricular orifice, from which it is separated by the anterior cusp of bicuspid valve. Its orifice is guarded by the aortic semilunar valves portion of the ventricle immediately below the aortic orifice is termed the *vestibule*, and possesses fibrous instead of muscular walls.

FIG. 644.—A transverse section through the mediastinal cavity at the level of the lower part of the body of the sixth thoracic vertebra.

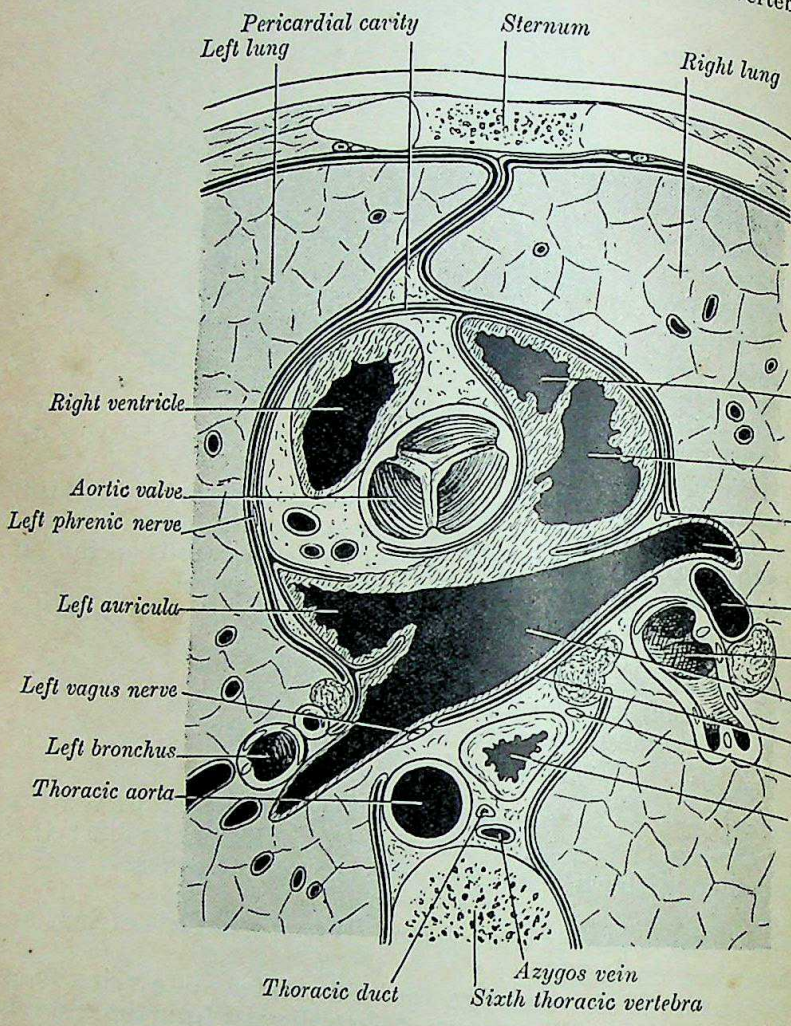

The *bicuspid or mitral valve* (figs. 643, 645) is attached to the fibrous which encircles the left atrioventricular orifice in the same way as tricuspid valve is attached around the right atrioventricular orifice. It consists of two triangular cusps, formed by duplicatures of the lining membrane strengthened by fibrous tissue, and containing a few muscular fibres. The cusps are of unequal size, and are larger, thicker, and stronger than those the tricuspid valve. The larger cusp is placed in front and to the right between the atrioventricular and aortic orifices, and is known as the *anterior or aortic cusp*; the smaller or *posterior cusp* is placed behind and to the left of the opening. Two small cusps are usually found in the angles between the larger cusps. The cusps of the bicuspid valve are furnished with chordæ tendineæ, which are attached in a manner similar to those on the right side the heart; they are, however, thicker, stronger, and less numerous.

The *aortic semilunar valves* (figs. 643, 646) are three in number, and surround the orifice of the aorta; two are posterior (right and left), and one anterior

CC-0. In Public Domain. Gurukul Kangri Collection, Haridwar

Digitized by Arya Samaj Foundation Chennai and eGangotri

are similar in structure, and in their mode of attachment, to the monary semilunar valves, but are larger, thicker, and stronger; the lunulæ more distinct, and the noduli or corpora Arantii thicker and more pro-. Opposite the valves the aorta presents slight dilatations, the *aortic* (sinuses of Valsalva), which are larger than those at the origin of the monary artery.

The *trabeculæ carneæ* are of three kinds, like those in the right ventricle, but are more numerous, and present a dense interlacement, especially at the and upon the posterior wall, of the ventricle. The *musculi papillares* two in number, one springing from the anterior, the other from the posterior they are of large size, and end in rounded extremities from which the tendineæ arise. Chordæ tendineæ from each papillary muscle are nected to both cusps of the bicuspid valve.

FIG. 645.—The interior of the left side of the heart.

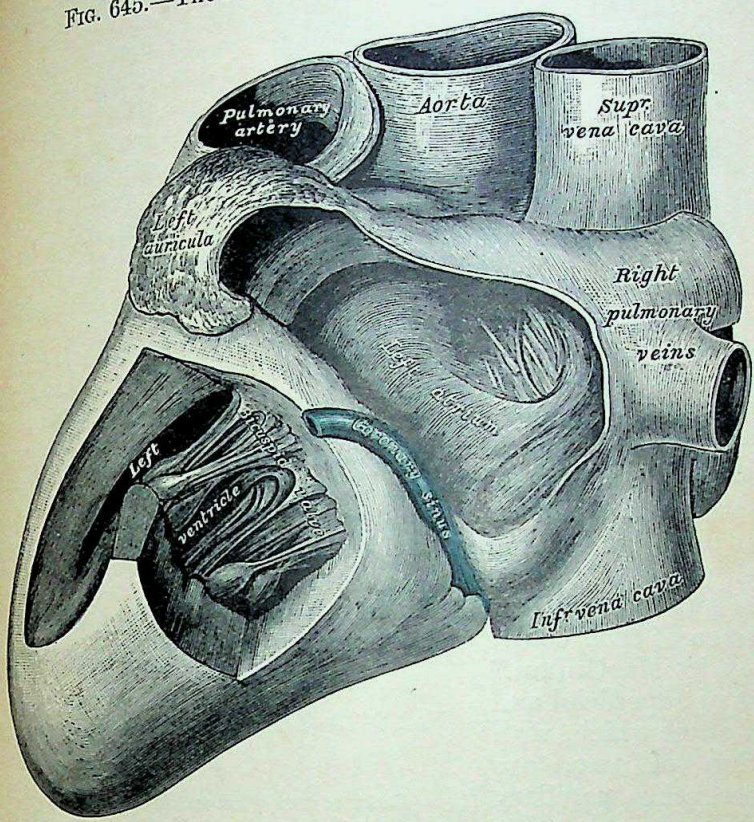

structure.—The heart consists of muscular fibres (*myocardium*), and of fibrous which partly serve for their attachment. It is covered with the visceral of the serous pericardium (*epicardium*), and lined with the *endocardium*.

The *endocardium* is a thin, smooth, glistening membrane which lines the bers of the heart, and is continuous with the lining membrane of the large d-vessels; by its reduplications it assists in forming the valves. It consists layer of endothelial cells placed on a stratum of connective tissue and elastic

The *fibrous rings* surround the atrioventricular and arterial orifices, and are ger on the left than on the right side of the heart. The atrioventricular rings e for the attachment of the muscular fibres of the atria and ventricles, and the attachment of the bicuspid and tricuspid valves. The left atrioventricular is closely connected, by its anterior margin, with the aortic arterial ring; en these and the right atrioventricular ring is a triangular mass of fibrous , the *trigonum fibrosum*, which represents the *os cordis* of some of the larger als, as the ox and elephant. There is also the tendon of the conus arteriosus, ly referred to (p. 583).

The fibrous rings surrounding the arterial orifices serve for the attachment of great vessels and the semilunar valves. Each ring receives, by its ventricular

CC-0. In Public Domain. Gurukul Kangri Collection, Haridwar

Digitized by Arya Samaj Foundation Chennai and eGangotri

margin, the attachment of some of the muscular fibres of the ventricles; its o margin presents three deep semicircular notches, to which the middle coat artery is firmly fixed. The attachment of an artery to its fibrous ring is strengt by the external coat of the artery and the epicardium externally, and endocardium internally. From the margins of the semicircular notches, the structure of the continued into ments of the valves middle coat of the in this situation and the vessel is to form the sinus the aorta and pul artery.

FIG. 646.—The aorta laid open to show the semilunar valves.

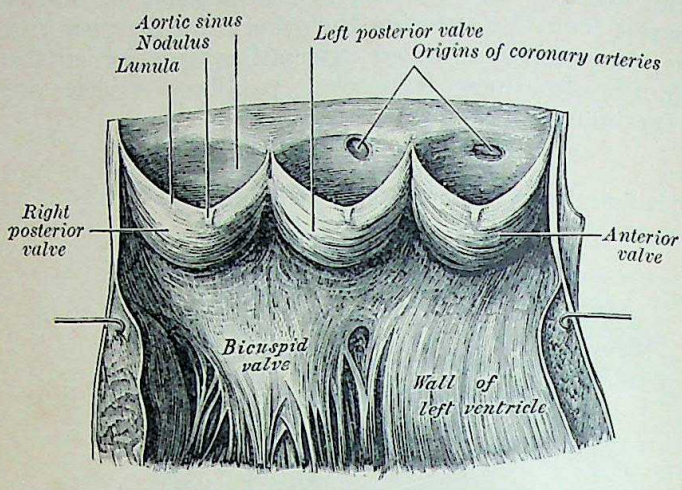

The *muscular* of the heart con fibres, which are versely and longitu striated (p. 33), and sent an exceedingly cate interlacement. comprise (*a*) the fib the atria, (*b*) the of the ventricles, (*c*) the atrioventr bundle.

The *fibres of the atria* are arranged in two layers—a superficial, common to atria, and a deep, proper to each. The *superficial fibres* are most distinct o front of the atria, across the bases of which they run in a transverse dire forming a thin and incomplete layer; some of them pass into the atrial se The *deep fibres* consist of looped and annular fibres. The *looped fibres* pass up over each atrium, and are attached by their extremities to the correspo atrioventricular ring, in front and behind; the *annular fibres* surround the aur and form annular bands around the terminations of the veins and around fossa ovalis.

The *fibres of the ventricles* are arranged in a complex manner, and various acco have been given of their course and connexions; the following description is ba on that given by MacCallum.* They consist of superficial and deep layers, all of which, with the exception of two, are inserted into the papillary muscles of the ventricles. The *superficial layers* comprise the following: (*a*) Fibres which spring from the tendon of the conus arteriosus (p. 583) and sweep downwards and towards the left across the anterior longitudinal sulcus and around the apex of the heart, where they form a vortex (fig. 647) and pass upwards and inwards to terminate in the papillary muscles of the left ventricle; those arising from the upper half of the tendon of the conus arteriosus pass to the anterior papillary muscle, those from the lower half to the posterior papillary muscle and papillary muscles of the septum (fig. 648). (*b*) Fibres which arise from the right a ventricular ring and run diagonally across the diaphragmatic surface of the r ventricle and round its right border on to its sternocostal surface, where they

FIG. 647.—The two vortices at the apex of the heart (Mall.)

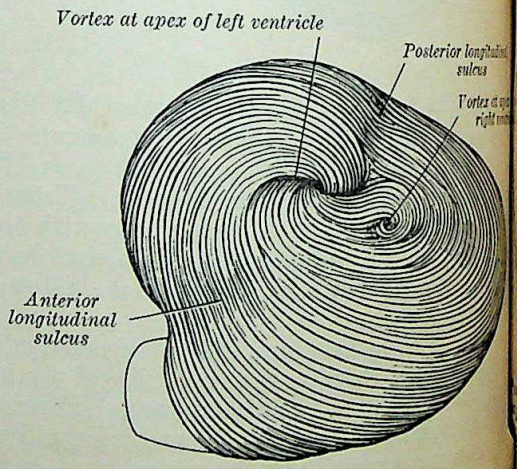

* John Bruce MacCallum, *Johns Hopkins Hospital Reports*, vol. ix.

CC-0. In Public Domain. Gurukul Kangri Collection, Haridwar

Digitized by Arya Samaj Foundation Chennai and eGangotri

...ith the fibres just described, and, crossing the anterior longitudinal sulcus, ...around the apex of the heart and end in the posterior papillary muscle of ...left ventricle. (*c*) Fibres which spring from the left atrioventricular ring, ...crossing the posterior longi-...al sulcus, pass successively ...the right ventricle and end ...its papillary muscles. The ...layers are three in number; ...arise in the papillary muscles ...ne ventricle and, curving in ...S-shaped manner, turn in at ...longitudinal sulcus and end ...the papillary muscles of the ...r ventricle (fig. 649). The ...which is most superficial in ...right ventricle lies next the ...of the left, and vice versa. ...of the first layer almost ...the right ventricle, and, ...in the septum to the left ...cle, unite with the super-...fibres from the right atrio-...ular ring to form the ...r papillary muscle. Those ...second layer have a less ...ve course in the wall of ...ight ventricle, and a corre-...ly greater course in the ...where they join with the ...rficial fibres from the anterior half of the tendon of the conus arteriosus to ...the papillary muscles of the septum. Those of the third layer pass almost ...ly round the left ventricle and unite with the superficial fibres from the ...r half of the tendon of the conus arteriosus to form the anterior papillary muscle. Besides the layers just described there are two bands which do not end in papillary muscles. One springs from the right atrioventricular ring, crosses in the atrioventricular septum, encircles the deep layers of the left ventricle, and ends in the left atrioventricular ring. The second band is apparently confined to the left ventricle; it is attached to the left atrioventricular ring, and encircles the portion of the ventricle adjacent to the aortic orifice.*

FIG. 648.—A diagram of the superficial muscular fibres of the ventricles of the heart originating in the tendon of the conus arteriosus. (After MacCallum.)

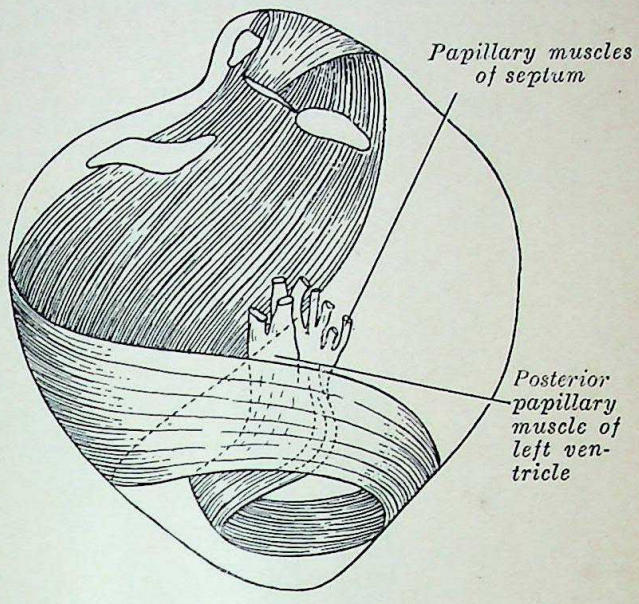

...6. 649.—A diagram of the course of the ...ngest layer of muscular fibres of the ...ft ventricle. (After MacCallum.)

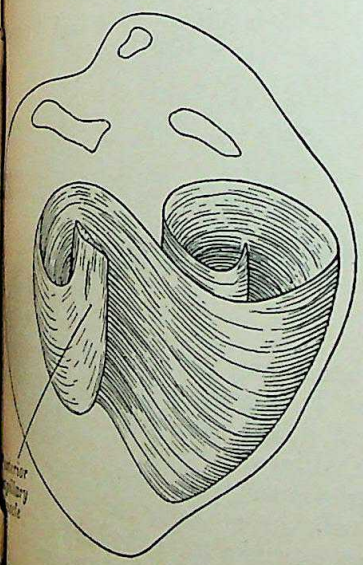

The *atrioventricular bundle* (fig. 650) is a direct muscular connexion between the atria and the ventricles. It arises in association with two small collections of spindle-shaped cells, the sino-atrial and atrioventricular nodes. The *sino-atrial node* is situated on the right border of the opening of the superior vena cava in the upper part of the sulcus terminalis; from it strands of fusiform fibres run under the endocardium of the wall of the right atrium to the *atrioventricular node* which lies near the orifice ...the coronary sinus in the annular and septal fibres of the right atrium. From ...atrioventricular node the atrioventricular bundle passes forwards below the ...branous septum, and divides into right and left fasciculi. These run down in

* Franklin P. Mall gives an account of his researches 'On the muscular architecture of the ...ventricles of the human heart' in the *American Journal of Anatomy*, vols. 11 and 13.

CC-0. In Public Domain. Gurukul Kangri Collection, Haridwar

Digitized by Arya Samaj Foundation Chennai and eGangotri

the right and left ventricles, one on either side of the ventricular septum, e with endocardium. The right fasciculus passes into the moderator band breaks up into numerous strands which end in an intricate network on the pa muscles and on the wall of the right ventricle. The left fasciculus consists of main strands, an anterior and a posterior, which are distributed to the papillary muscles and the wall of the left ventricle. The atrioventricular bundle divisions are enveloped in a sheath of connective tissue; by injecting this with Indian ink the ramifications of the bundle can be demonstrated. The and greater portion of the bundle consists of narrow, somewhat fusiform fibres the terminal strands of the bundle are composed of Purkinje fibres.

FIG. 650.—A schematic representation of the atrioventricular bundle. The course of the bundle is represented in red.

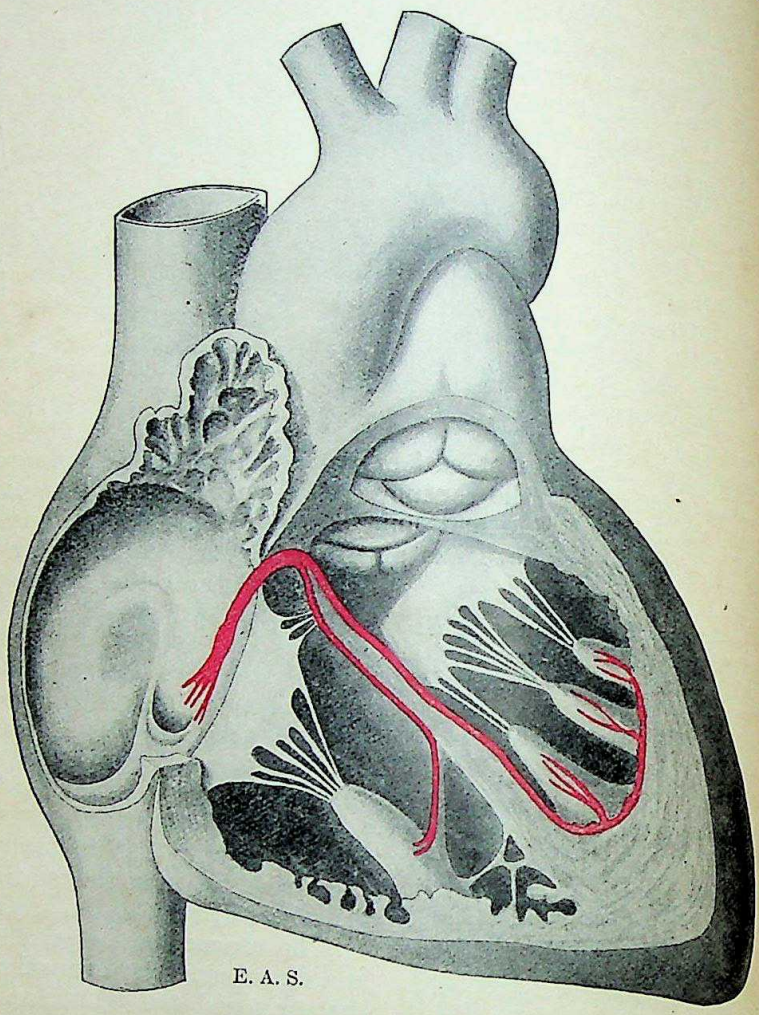

E. A. S.

Kent has described a second atrioventricular bundle in the right lateral of the heart, containing cardiac muscle-fibres, fine nerve-fibres, and fibres resem those of Purkinje. This bundle is connected with a node in the wall of the atrium, formed of fine, faintly striated muscle-fibres.

A. Morison * has shown that in the sheep and pig the atrioventricular b 'is a great avenue for the transmission of nerves from the auricular to ventricular heart'; large and numerous nerve-trunks enter the bundle and with it. Branches arise from these nerve-trunks and form plexuses around of Purkinje cells, and from these plexuses fine fibrils go to innervate individual

The sino-atrial and atrioventricular nodes, the atrioventricular bundle and its fasciculus, are supplied by the right coronary artery; the left fasciculus of the bun supplied by both coronary arteries.

CC-0. In Public Domain. Gurukul Kangri Collection, Haridwar

* *Journal of Anatomy and Physiology*, vol. xlvi.

Digitized by Arya Samaj Foundation Chennai and eGangotri

Applied Anatomy.—Clinical and experimental evidence go to prove that this bundle ...ves the impulse to systolic contraction from the atrial septum to the ventricles, and ...h attention has been paid to it, because it appears to become fibrosed and to lose much ...conducting power (heart-block) in many cases of Adams-Stokes' syndrome. This ...tion is characterised by a slow pulse, a tendency to syncopal or epileptiform seizures, ...the fact that while the cardiac atria beat at a normal rate, the ventricles contract ...h less frequently.

Vessels and Nerves.—The *arteries* supplying the heart are the right and left ...nary branches of the aorta (p. 598); the majority of the *veins* are drained by ...coronary sinus into the right atrium.

The *lymphatic* vessels are described on p. 778.

The *nerves* are derived from the cardiac plexus (p. 978), which is formed by ...ches from the vagi and sympathetic. They are freely distributed both on the ...rdiac and in the substance of the heart, the separate nerve-filaments being furnished ...h small ganglia. The atrioventricular bundle receives nerve-fibres from ganglia ...the atrial septum. Other ganglia are found in relation with the sino-atrial ...le, and supply it with nerve-filaments.

The cardiac cycle and the actions of the valves.—By the contractions of the ...r the blood is pumped through the arteries to all parts of the body. These ...ractions occur regularly and at the rate of about seventy per minute. Each ...e of contraction or *period of activity* is followed by a *period of rest*, the two ...ods constituting what is known as a *cardiac cycle*.

Each cardiac cycle consists of three phases, which succeed each other as follows: ...a short simultaneous contraction of both atria, termed the *atrial systole*, followed, ...r a slight pause, by (2) a simultaneous, but more prolonged, contraction of ...h ventricles, named the *ventricular systole*, and (3) a *period of rest*, during which ...e whole heart is relaxed. The atrial contraction commences around the venous ...ings, and sweeping over the atria forces their contents through the atrio-...ntricular openings into the ventricles, regurgitation into the veins being prevented ...the contraction of their muscular coats. When the ventricles contract, the ...spid and bicuspid valves are closed, and prevent the passage of the blood ...k into the atria; the musculi papillares at the same time are shortened, and, ...ing on the chordæ tendineæ, prevent the inversion of the valves into the atria. ...soon as the pressure in the ventricles exceeds that in the pulmonary artery ...l aorta, the valves guarding the orifices of these vessels are opened, and the ...d is driven from the right ventricle into the pulmonary artery, and from the left ...the aorta. The moment the systole of the ventricles ceases, the pressure ...the blood in the pulmonary artery and aorta closes the pulmonary and aortic ...lunar valves, thus preventing regurgitation of blood into the ventricles, and ...valves remain shut until re-opened by the next ventricular systole. During ...period of rest the tension of the tricuspid and bicuspid valves is relaxed, and ...d flows from the veins through the atria into the ventricles. The filling of ...ventricles is completed by the systole of the atria. The average duration ...a cardiac cycle is about $\frac{8}{10}$ of a second, made up as follows:

Atrial systole, $\frac{1}{10}$.	Atrial diastole, $\frac{7}{10}$.
Ventricular systole, $\frac{3}{10}$.	Ventricular diastole, $\frac{5}{10}$.
Total systole, $\frac{4}{10}$.	Complete diastole, $\frac{4}{10}$.

The rhythmical action of the heart is *muscular* in origin—that is to say, the ...t-muscle possesses the inherent property of contraction apart from any ...vous stimulation. The more embryonic the muscle the better is it able to ...te the contraction wave, and the normal systole of the heart starts at the ...-atrial node, where the muscle is most embryonic in nature: for this reason ...e sino-atrial node has been called the "pace-maker" of the heart. A slight ...e occurs between systole of the atria and that of the ventricles. This is due ...the fact that the contraction of the ventricles is excited by an impulse conveyed ...the atrioventricular bundle, conduction along the fibres of which is relatively ...w. The nerves, although not concerned in originating the contractions of the ...t-muscle, play an important rôle in regulating their force and frequency in ...der to subserve the physiological needs of the organism.

Applied Anatomy.—Wounds of the heart are often immediately fatal, but not neces-...ily so. They may be non-penetrating, when death may occur from hæmorrhage if one ...the coronary vessels has been wounded, or subsequently from pericarditis. Even a

CC-0. In Public Domain. Gurukul Kangri Collection, Haridwar

Digitized by Arya Samaj Foundation Chennai and eGangotri

penetrating wound is not necessarily fatal, as many cases have been recorded in which the wound has been sutured successfully. When blood is effused into the pericardium it presses especially on the thin-walled atria, and so interferes with the circulation through the heart.

The Chief Peculiarities in the Vascular System of the Fœtus

The development of the heart and vascular system is described on pp. 131 to 132.

The chief peculiarities of the fœtal heart are the communication between the atria through the foramen ovale, and the large size of the valve of the inferior vena cava. The following points may also be noted: (1) In early fœtal life the heart lies immediately below the mandibular arch, and as development proceeds it is gradually drawn within the thorax. (2) For a time the atrial portion exceeds the ventricular in size, and the walls of the ventricles are of equal thickness, since each ventricle bears the pressure of the systemic circulation. Towards the end of fœtal life the ventricular portion becomes larger, and the wall of the left ventricle exceeds that of the right in thickness, thus becoming adapted to bear the pressure of the whole systemic circulation. (3) Its size is large as compared with that of the rest of the body, the proportion at the second month of fœtal life being 1 to 50; at birth 1 to 120; in the adult about 1 to 160.

The *foramen ovale* is an opening between the atria until the end of fœtal life; it is obliterated shortly after birth (p. 115).

The *valve of the inferior vena cava* directs the blood from the inferior vena cava through the foramen ovale into the left atrium.

The chief peculiarities in the arterial system of the fœtus are (1) the communication between the pulmonary artery and the aorta by means of the ductus arteriosus, and (2) the continuation of the hypogastric arteries as the umbilical arteries to the placenta.

The *ductus arteriosus* is a short tube, about 1 cm. in length at birth, and of the diameter of a goose-quill. In early fœtal life it forms the continuation of the pulmonary artery, and opens into the aorta, just beyond the origin of the left subclavian artery; and so conducts a great part of the blood from the right ventricle into the aorta. When the branches of the pulmonary artery have become larger relatively to the ductus arteriosus, the latter is chiefly connected to the left pulmonary artery. It is obliterated within a few days after birth.

In the fœtus the *hypogastric arteries* are continued along the sides of the urinary bladder, thence upwards on the back of the anterior abdominal wall to the umbilicus, through which they pass out of the abdomen and run, under the name of the *umbilical arteries*, in the umbilical cord to the placenta. They convey blood from the fœtus to the placenta.

The chief peculiarities in the venous system of the fœtus are the communications established between the placenta and the liver and portal vein through the umbilical vein; and between the umbilical vein and the inferior vena cava through the ductus venosus.

The Fœtal Circulation (fig. 651)

The fœtal blood is carried to the placenta by the umbilical arteries and returned from the placenta to the fœtus by the two umbilical veins. These veins unite in the umbilical cord to form a single vein (vena umbilicalis impar) which divides within the embryo into a right and a left umbilical vein. After the formation of the liver the right umbilical vein atrophies and disappears, but the left persists until the end of fœtal life. It enters the abdomen at the umbilicus, and passes along the free margin of the falciform ligament of the liver, to the visceral surface of that organ, where it gives off two or three branches, one of large size to the left lobe, and others to the lobus quadratus and lobus caudatus. At the porta hepatis (transverse fissure of the liver) it divides into two branches; of these, the larger is joined

CC-0. In Public Domain. Gurukul Kangri Collection, Haridwar

Digitized by Arya Samaj Foundation Chennai and eGangotri

the portal vein, and enters the right lobe; the smaller is continued upwards under the name of the ductus venosus, and joins the inferior vena cava. The blood conveyed by the left umbilical vein passes to the inferior vena cava in

FIG. 651.—A plan of the fœtal circulation.

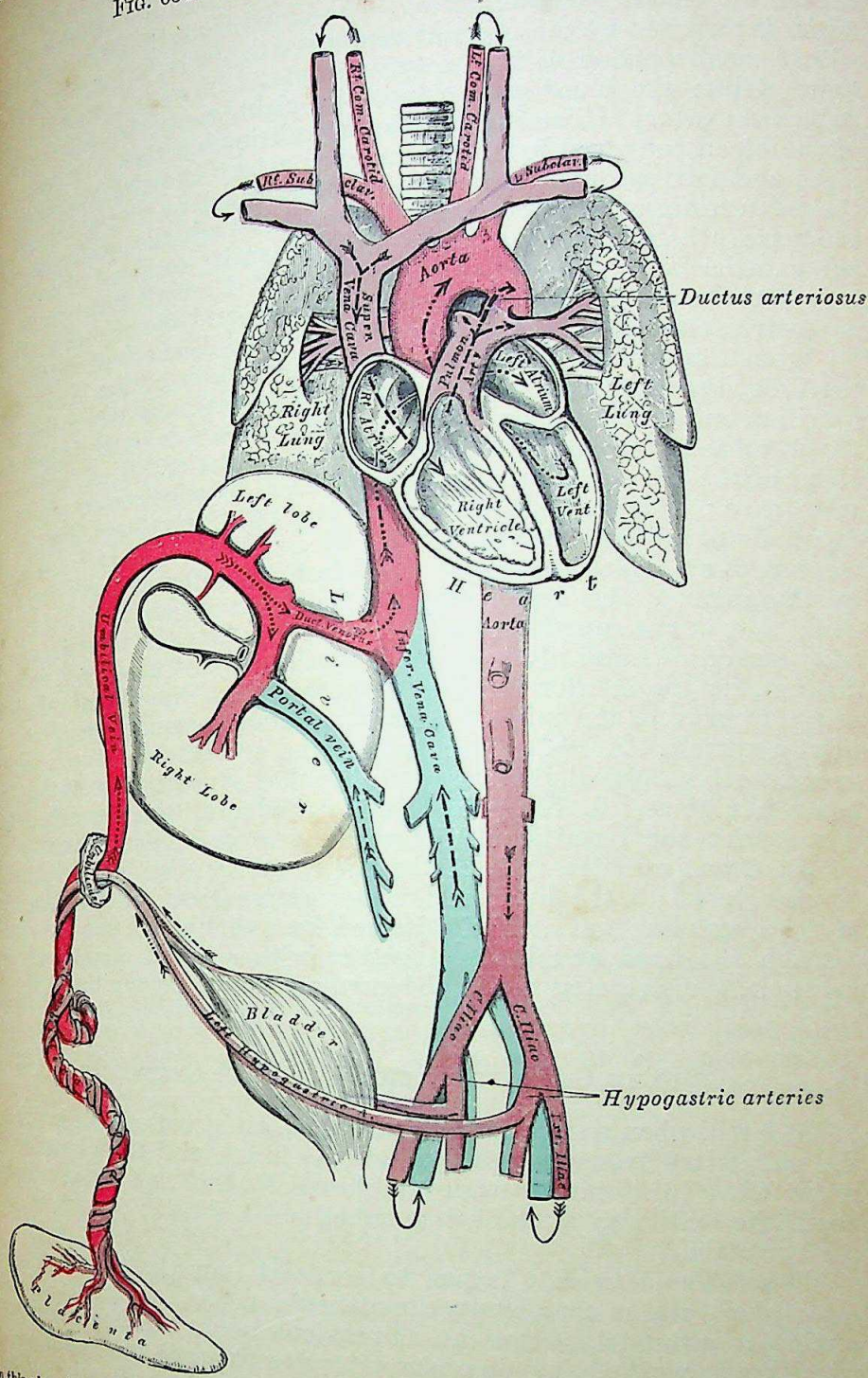

In this plan the arrows represent the course which the blood takes in the heart and vessels.

the different ways. Some enters the liver directly and is carried to the inferior vena cava by the hepatic veins; a considerable quantity circulates through the liver with the portal venous blood, before entering the inferior vena cava by the hepatic veins; the remainder passes directly into the inferior vena cava through the ductus venosus.

In the inferior vena cava, the blood carried by the ductus venosus and hepatic veins mixes with that returning from the lower extremities and

CC-0. In Public Domain. Gurukul Kangri Collection, Haridwar

Digitized by Arya Samaj Foundation Chennai and eGangotri

abdominal wall. It enters the right atrium, and, guided by the valve of the inferior vena cava, passes through the foramen ovale into the left atrium, where it mingles with a small quantity of blood returned from the lungs by the pulmonary veins. From the left atrium it passes into the left ventricle, and from that cavity into the aorta, by means of which it is distributed almost entirely to the head and upper extremities, a small quantity being probably carried into the descending aorta. The blood from the head and upper extremities is returned by the superior vena cava to the right atrium, where it mixes with a small portion of that returned by the inferior vena cava. From the right atrium the blood passes into the right ventricle, and thence into the pulmonary artery. The lungs of the fœtus being inactive, only a small quantity of the blood conveyed by the pulmonary artery is distributed to them by the right and left pulmonary arteries, and returned by the pulmonary veins to the left atrium: the greater part passes through the ductus arteriosus into the aorta, where it mixes with the small quantity of blood transmitted by the left ventricle into this part of the aorta. It descends through the aorta, is in part distributed to the lower extremities and the viscera of the abdomen and pelvis, but most of it is conveyed by the umbilical arteries to the placenta.

From the preceding account of the circulation of the blood in the fœtus the following facts will be inferred: 1. The placenta serves the purposes of nutrition and excretion, receiving the impure blood from the fœtus, and returning it purified and charged with nutritive material. 2. A large part of the blood of the left umbilical vein traverses the liver before entering the inferior vena cava; this is correlated with the relatively large size of the liver, especially at an early period of fœtal life. 3. The right atrium is the place of meeting of a double current, the blood from the inferior vena cava being guided by the valve of this vessel through the foramen ovale into the left atrium, while that in the superior vena cava descends into the right ventricle. At an early period of fœtal life it is highly probable that the two streams are quite distinct, for the inferior vena cava opens almost directly into the left atrium, and the valve of the inferior vena cava would exclude the current from the right ventricle. At a later period, as the separation between the two streams becomes more marked, it seems probable that some mixture of the two streams must take place. 4. The pure blood carried from the placenta to the fœtus, mixed with the blood from the portal vein and inferior vena cava, passes almost directly to the arch of the aorta, and is distributed by the branches of that vessel to the head and upper extremities. 5. The blood contained in the descending aorta, chiefly derived from that which has already circulated through the head and limbs, together with a small quantity from the right ventricle, is distributed to the abdomen and lower extremities.

The Changes in the Vascular System at Birth

At birth, when respiration is established, an increased amount of blood from the pulmonary artery passes through the lungs, and the placental circulation is cut off. The foramen ovale is closed by the septum secundum (p. 1[illegible]) about the tenth day after birth; sometimes a slit-like opening is left between the two atria.

The *ductus arteriosus* begins to contract immediately after respiration is established, and is completely closed between the fourth and fifth days after birth; it ultimately forms an impervious cord, the *ligamentum arteriosum*, which connects the left pulmonary artery to the arch of the aorta.

The parts of the *hypogastric arteries* extending from the sides of the bladder to the umbilicus become obliterated between the second and fifth days after birth, and project towards the abdominal cavity as fibrous cords; these cords are termed the lateral umbilical ligaments, and are enveloped by folds of peritoneum.

The *left umbilical vein* and the *ductus venosus* are completely obliterated between the second and fifth days after birth; the former becomes the ligamentum teres, the latter the ligamentum venosum, of the liver.

CC-0. In Public Domain. Gurukul Kangri Collection, Haridwar

Digitized by Arya Samaj Foundation Chennai and eGangotri

THE ARTERIES

The distribution of the systemic arteries is like a highly branched tree, the common trunk of which, formed by the aorta, commences at the left ventricle, while the smallest ramifications extend to the viscera and to the peripheral parts of the body. Arteries are found in all parts of the body, except in the hairs, nails, epidermis, cartilages, and corneæ; the larger trunks usually occupy the most protected situations, running, in the limbs, along the flexor surfaces, where they are less exposed to injury.

There is considerable variation in the mode of division of the arteries: occasionally a short trunk subdivides into several branches at the same point, as in the cœliac artery and the thyreocervical trunk; more usually the vessel gives off several branches in succession, and still continues as the main trunk, as in the arteries of the limbs.

A branch of an artery is smaller than the trunk from which it arises; but when an artery divides into two branches, the combined sectional area of the two vessels is, in nearly every instance, somewhat greater than that of the trunk; and the combined sectional area of all the arterial branches greatly exceeds that of the aorta.

The arteries unite with one another, forming what are called *anastomoses*. Anastomosis between trunks of nearly equal size is found in the brain, where the two vertebral arteries unite to form the basilar artery, and the two anterior cerebral arteries are connected by the anterior communicating artery; and in the abdomen, where the intestinal arteries have free anastomoses between their larger branches. In the limbs, the anastomoses are largest and most numerous around the joints; the branches arising from an artery above a joint uniting with branches from the vessels below it. These anastomoses are of considerable interest to the surgeon, as it is by their enlargement that a *collateral circulation* is established after the application of a ligature to a main artery. The smaller branches of arteries anastomose more frequently than the larger; and between the smallest twigs these anastomoses may be so numerous that they constitute a close network. In certain regions of the body, however, there are arteries which have no anastomoses with neighbouring arteries except through the agency of the capillaries. Such are found in the spleen and kidney, and in certain parts of the brain, and are called *end arteries*. If an artery of this type be occluded, serious nutritional disturbances resulting in death (necrosis) will occur in the terrtiory supplied by the vessel.

Applied Anatomy.—The walls of all the arteries, and most of all of the aorta, are liable to various forms of hardening with loss of elasticity, known collectively as *arteriosclerosis*, and are of the greatest clinical importance. The two chief varieties of arteriosclerosis are: (1) hypertrophy of the muscular tunica media of the arteries, clinically associated with chronic arterial vasoconstriction and high blood-pressure, and (2) atheroma or atherosclerosis, essentially a senile degenerative change of the intima, that leads to loss of arterial elasticity by the replacement of elastic by fibrous tissue. Whatever the cause of arterial sclerosis its chief ill-effects on the patient are two. In the first place, it is associated with a permanent and often considerable rise in the arterial blood-pressure, involving a corresponding hypertrophy of the heart; in the second, it weakens the vessel walls, tendering them more liable to rupture, while at the same time it is apt to lessen the calibre of the affected vessels.

The arteries are also frequently attacked by syphilis, which gives rise to inflammation and degeneration of their middle coats. Arterial aneurysms, other than those due to direct injury, occur almost solely in syphilitic patients.

The Pulmonary Artery

The **pulmonary artery** (figs. 652, 653) conveys venous blood from the right ventricle of the heart to the lungs. It is about 5 cm. in length and 3 cm. in diameter, and arises from the conus arteriosus of the right ventricle. It runs upwards and backwards, passing at first in front and then to the left of the ascending aorta, as far as the under surface of the aortic arch, where it divides, at the level of the fibrocartilage between the fifth and sixth thoracic vertebræ, into the right and left branches of nearly equal size.

CC-0. In Public Domain. Gurukul Kangri Collection, Haridwar

Digitized by Arya Samaj Foundation Chennai and eGangotri

Relations.—The whole of the pulmonary artery is contained within the cardium. It and the ascending aorta are enclosed in a common tube of visceral layer of the serous pericardium. The fibrous layer of the pericardium gradually lost upon the external coats of the two branches of the artery. In the the pulmonary artery is separated from the anterior end of the second left intercostal space by the pleura, the left lung, and the pericardium; it lies first upon the ascending aorta; higher up it lies in front of the left atrium; the ascending aorta is on its right side. On either side of its origin is auricula of the corresponding atrium, and a coronary artery; the left coronary artery, in the first part of its course passes behind the vessel. The superior part of the cardiac plexus lies between the division of the pulmonary artery the arch of the aorta.

Fig. 652.—A transverse section through the thorax, showing the relations of the pulmonary artery, etc. Diagrammatic.

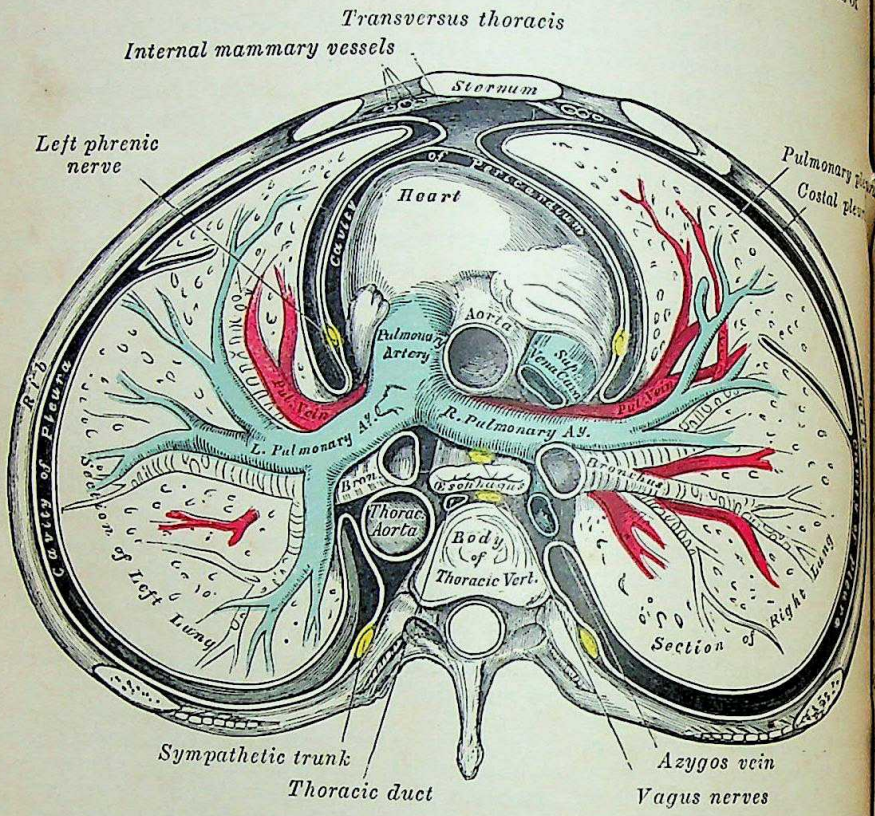

The **right branch** of the pulmonary artery, slightly longer and larger than the left, runs horizontally to the right, behind the ascending aorta, superior vena cava, and upper right pulmonary vein, and in front of the right bronchus to the root of the right lung, where it divides into two branches. The lower and larger of these is distributed to the middle and lower lobes of the lung; the upper and smaller accompanies the eparterial bronchus to the upper lobe.

The **left branch** of the pulmonary artery, a little shorter and smaller than the right, runs horizontally in front of the descending aorta and the bronchus to the root of the left lung, where it divides into two branches, one for either lobe of the lung. Above, it is united to the concavity of the aortic arch by the ligamentum arteriosum, on the left of which is the left recurrent nerve, and on the right the superficial part of the cardiac plexus. Below it is joined to the upper left pulmonary vein by the ligament of the left vena cava (p. 576).

The terminal branches of the pulmonary arteries are described with the anatomy of the lungs.

Applied Anatomy.—Stenosis (narrowing) or atresia (non-perforation) of the pulmonary orifice, usually combined with other developmental anomalies such as defect of the upper part of the interventricular septum, patency of the ductus arteriosus, or patency of

CC-0. In Public Domain. Gurukul Kangri Collection, Haridwar

Digitized by Arya Samaj Foundation Chennai and eGangotri

...ovale, is the commonest form of congenital heart disease. It is due to mal-...opment, and not to fœtal endocarditis; possibly, as Keith suggests, to malformation ...the bulbus cordis. In well-marked cases the child with congenital heart disease is ...cyanosed, short of breath on exertion, and puny, generally dying of sudden heart failure ...endocarditis before adolescence. The chief signs of the condition are the loud, harsh ...cardiac murmur best heard over the second left costal cartilage, cyanosis, club-...of the finger-tips, and the presence of an excess of red corpuscles in the blood.

Embolism of the pulmonary artery by a clot of blood coming from the right side of ...heart in patients with heart-disease, or from a thrombosed vein in cases, for example, ...influenza, enteric fever, puerperal sepsis, or fractured limbs, is a common cause of ...sudden or rapid death. The patient may cry out with sudden excruciating pain in the ...chest when the detached embolus lodges, and after a brief period of intense dyspnœa, ...cyanosis, and anguish, die.

The Aorta

The **aorta** is the main trunk of the series of vessels which convey the ...oxygenated blood to the tissues of the body. It begins at the upper part of ...the left ventricle, where it is about 3 cm. in diameter, and after ascending for

Fig. 653.—A transverse section through the mediastinal cavity at the level of the upper part of the body of the sixth thoracic vertebra.

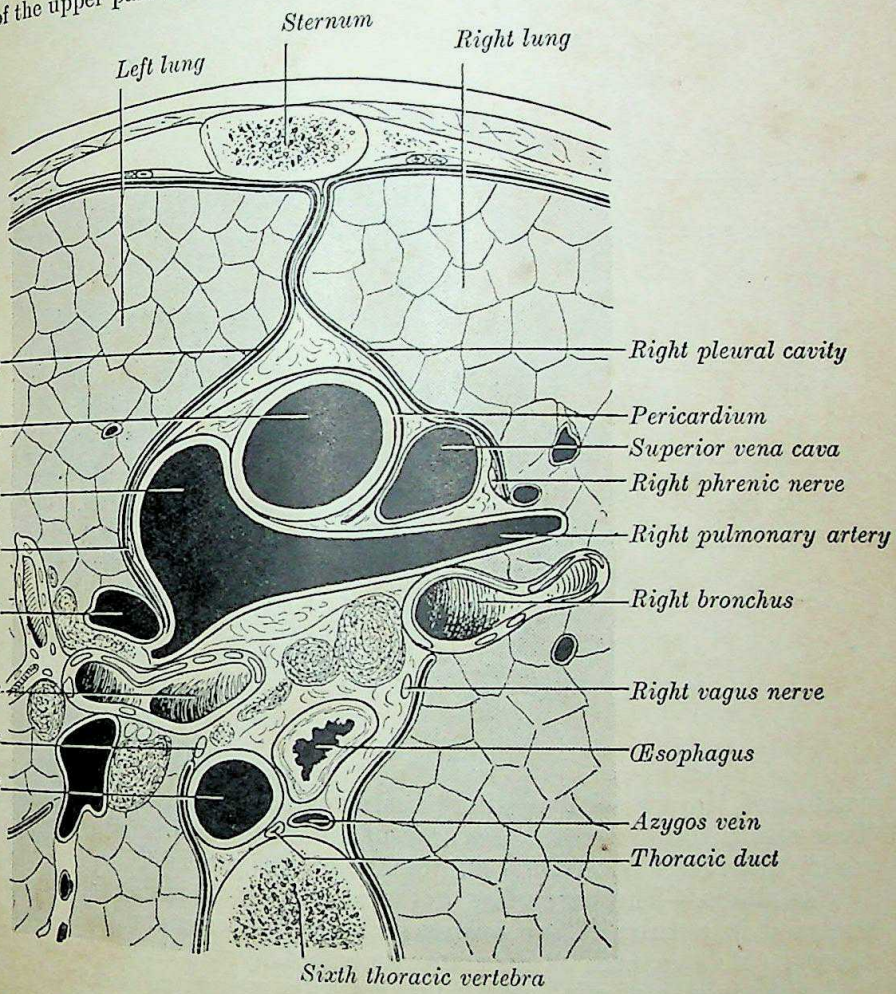

...short distance, arches backwards and to the left, over the root of the left ...lung; it then descends within the thorax on the left side of the vertebral column, ...and enters the abdominal cavity through the aortic hiatus in the Diaphragm. ...considerably diminished in size (about 1·75 cm. in diameter), it ends, on the ...left of the median plane, at the level of the lower border of the fourth lumbar ...vertebra, by dividing into the right and left common iliac arteries. Hence it is ...described in several portions, viz. the *ascending aorta*, the *arch of the aorta*, ...and the *descending aorta*, which last is divided into the *thoracic* and *abdominal*

CC-0. In Public Domain. Gurukul Kangri Collection, Haridwar

Digitized by Arya Samaj Foundation Chennai and eGangotri

The Ascending Aorta

The **ascending aorta** (figs. 635, 655) is about 5 cm. long. It l at the base of the left ventricle, on a level with the lower border of third costal cartilage, behind the left half of the sternum; it obliquely upwards, forwards, and to the right behind the sternum, direction of the heart's axis, as high as the upper border of the secon costal cartilage, describing a slight curve in its course. At its origin it p opposite the segments of the aortic valve, three small dilatations call aortic sinuses. At the union of the ascending aorta with the aortic a

Fig. 654.—A transverse section through the mediastinal cavity at the level of the lower part of the body of the fourth thoracic vertebra.

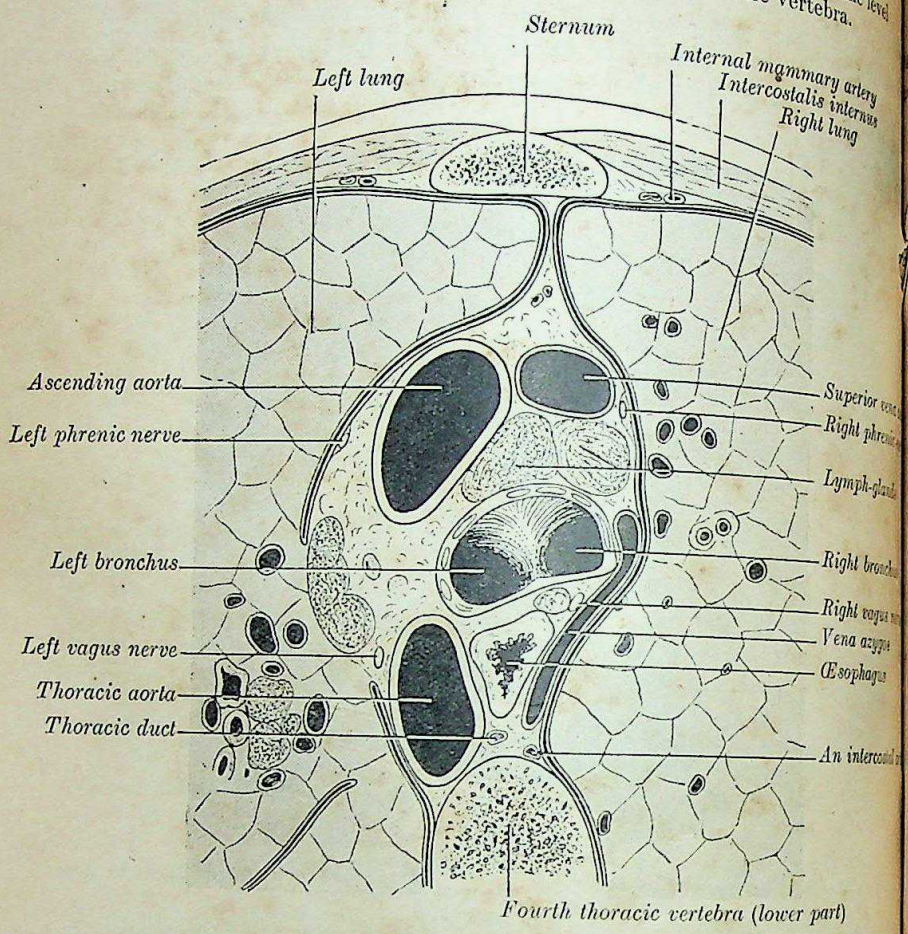

calibre of the vessel is slightly increased, owing to a bulging of its right This dilatation is termed the *bulb of the aorta*, and on transverse section at level, the vessel presents a somewhat oval figure.

Relations.—The ascending aorta is contained within the pericardium, and enclosed in a tube of the serous pericardium, common to it and the pulm artery. It is covered at its commencement by the trunk of the pulmonary a and the right auricula, and, higher up, is separated from the sternum by pericardium, the right pleura, the anterior margin of the right lung, some areolar tissue, and the remains of the thymus; *posterior* to it are the left atri the right pulmonary artery, and the right bronchus. On its *right side* are superior vena cava and right atrium, the former lying partly behind it; on *left side* is the pulmonary artery.

Branches.—The branches of the ascending aorta are the right and left coro arteries (figs. 638, 655) which supply the heart; they arise from the aortic sin immediately above the attached margins of the aortic semilunar valves.

The **right coronary artery** arises from the anterior aortic sinus. It passes first between the conus arteriosus and the right auricle, turns round the right margin and then runs in the

CC-0. In Public Domain. Gurukul Kangri Collection, Haridwar

Digitized by Arya Samaj Foundation Chennai and eGangotri

of the coronary sulcus, coursing on the front of the heart from left to right, on the back of the heart from right to left as far as the posterior longi- sulcus; under the name of the *posterior descending branch* it proceeds down sulcus, sometimes as far as the apex of the heart. The right coronary artery a large *marginal branch* which follows the acute margin of the heart towards ex, and ramifies on both surfaces of the right ventricle. It also supplies ss to the right atrium and to the part of the left ventricle which adjoins posterior longitudinal sulcus.

FIG. 655.—The arch of the aorta, and its branches.

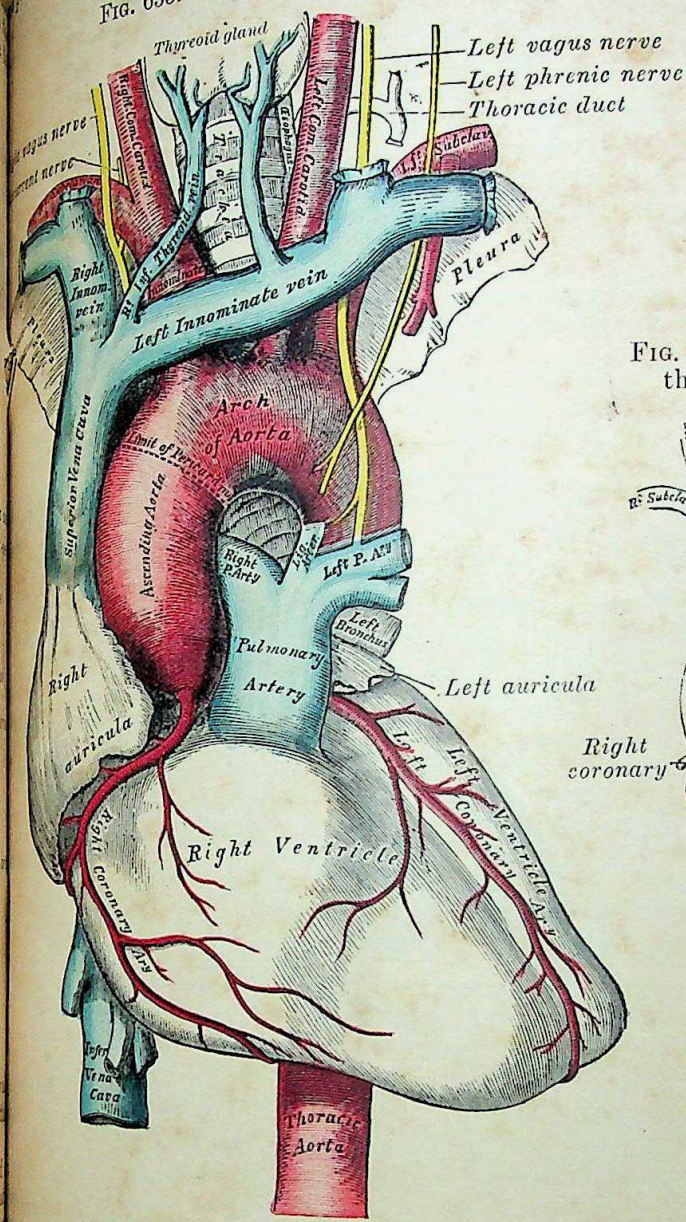

FIG. 656.—Plan of the branches.

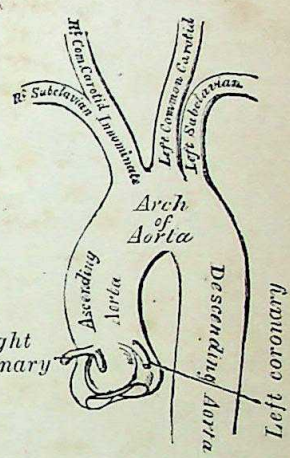

The **left coronary artery**, larger than the right, arises from the left posterior sinus and, after a short forward course between the pulmonary artery and left auricula, divides into an anterior descending and a circumflex branch. *Anterior descending branch* runs forwards between the pulmonary artery and left auricula, and reaching the anterior longitudinal sulcus, descends in it to the fossa apicis cordis; it gives branches to both ventricles. In many subjects the anterior descending branch turns round the apex (fig. 638) and ascends for a varying distance in the posterior longitudinal sulcus. The *circumflex branch* follows the part of the coronary sulcus, running first to the left and then to the right, reaching nearly as far as the posterior longitudinal sulcus; it gives branches to the left atrium and ventricle.

CC-0. In Public Domain. Gurukul Kangri Collection, Haridwar

Digitized by Arya Samaj Foundation Chennai and eGangotri

There is a very free anastomosis between the minute branches and between capillaries of the two coronary arteries in the substance of the heart.*

Peculiarities.—The coronary arteries occasionally arise by a common trunk; number may be increased to three or four.

Applied Anatomy.—The sudden blocking of a coronary artery by an embolus, or more gradual obstruction by arterial disease or thrombosis, is a common cause of death in persons past middle age. If the obstruction to the passage of blood is complete, *angina pectoris* may occur. In this condition the patient is suddenly seized with spasm of agonising pain in the precordial region and down the left arm, together with an indescribable sense of anguish. He may die in such an attack, or succumb a few hours or days later from heart failure, or survive a number of attacks.

The Arch of the Aorta

The **arch of the aorta** (figs. 655, 657) connects the ascending with the descending aorta; it begins at the level of the upper border of the second sternocostal articulation, and runs at first upwards, backwards, and to the left in front of the trachea; it is then directed backwards on the left side of

Fig. 657.—A transverse section through the mediastinal cavity at the level of the upper part of the body of the fourth thoracic vertebra.

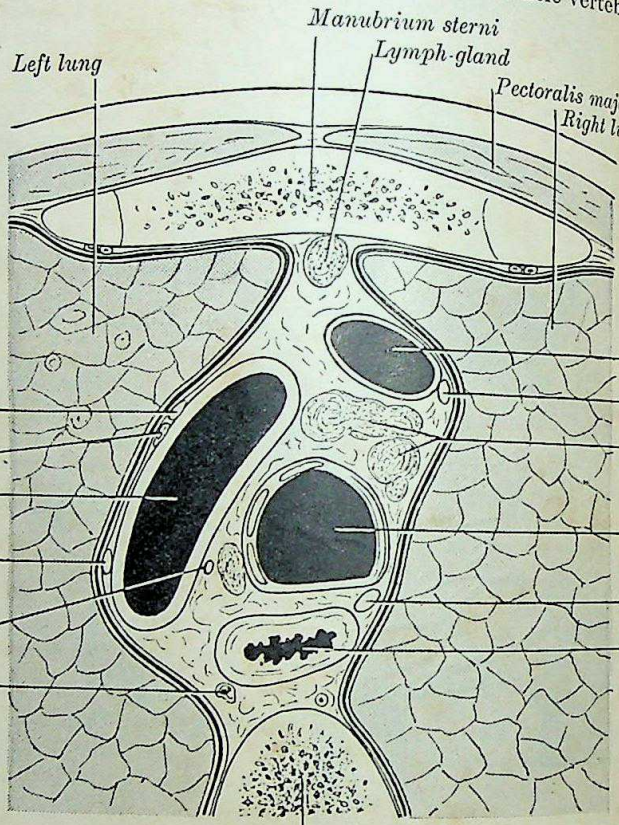

the trachea, and finally passes downwards on the left side of the body of the fourth thoracic vertebra, at the lower border of which it is continuous with the descending aorta. It thus forms two curvatures: one with its convexity upwards, the other with its convexity forwards and to the left. Its upper border is usually about 2·5 cm. below the superior border of the manubrium sterni.

Relations.—The arch of the aorta is covered *anteriorly* by the pleura, the anterior margins of the lungs, and by the remains of the thymus. As the vessel runs backwards its *left* side is in contact with the left lung and pleura. Its

* Consult in this connexion 'The blood-supply of the heart' by Louis Gross, 1921.

CC-0. In Public Domain. Gurukul Kangri Collection, Haridwar

Digitized by Arya Samaj Foundation Chennai and eGangotri

wards on the left side of this part of the arch are four nerves, in order from backwards these are: the left phrenic, the lower of the superior cardiac ves of the left vagus, the superior cardiac branch of the left sympathetic, and nk of the left vagus. As the left vagus crosses the arch it gives off its recurrent which hooks round below the vessel and then passes upwards on its right The left superior intercostal vein runs obliquely upwards and forwards e left side of the arch, between the phrenic and vagus nerves. On the are the deep part of the cardiac plexus, the left recurrent nerve, and the agus; the trachea lies behind and to the right of the vessel. *Above* e innominate, left common carotid, and left subclavian arteries, which arise the convexity of the arch and are crossed close to their origins by the left minate vein. *Below* are the bifurcation of the pulmonary artery, the left chus, the ligamentum arteriosum, the superficial part of the cardiac plexus, e left recurrent nerve. As already stated (p. 596), the ligamentum arteriosum ks the commencement of the left pulmonary artery to the aortic arch.

In the fœtus the lumen of the aorta is considerably narrowed between the origin the left subclavian artery and the attachment of the ductus arteriosus, forming is termed the *aortic isthmus*, while immediately beyond the ductus arteriosus vessel presents a fusiform dilatation which His has named the *aortic spindle*—point of junction of the two parts being marked in the concavity of the arch indentation or angle. These conditions persist, to some extent, in the adult, e His found that the average diameter of the spindle exceeded that of the us by 3 mm.

Peculiarities.—The summit of the arch of the aorta is usually about 2·5 cm. below the r border of the sternum; but it may reach nearly to the top of the bone. Occasion- it is found 4 cm., more rarely from 5 to 8 cm., below this point. Sometimes the aorta s over the root of the right lung (right aortic arch) instead of over that of the left, passes down on the right side of the vertebral column, a condition which is normal s. In such cases there is a transposition of the thoracic and of the abdominal viscera. frequently the aorta, after arching over the root of the right lung, is directed to its position on the left side of the vertebral column; this peculiarity is not accompanied transposition of the viscera. The aorta occasionally divides, as in some quadrupeds, an ascending and a descending trunk, the former of which is directed vertically upwards, subdivides into three branches, to supply the head and upper extremities. Some- the aorta subdivides near its origin into two branches, which soon reunite; in one of this kind the œsophagus and trachea passed through the interval between the two ches; this is the normal condition of the vessel in the reptilia.

Applied Anatomy.—The ascending aorta and the arch of the aorta are frequent sites eurysm.

Aneurysm of the ascending aorta, in a majority of cases affects the anterior sinus, owing the fact that the regurgitation of blood which follows the closing of the aortic valves ected chiefly against the anterior wall of the vessel. If the aneurysmal sac projects rds it may destroy part of the sternum and the costal cartilages, usually on the right , and appear as a pulsating tumour on the front of the chest. In other cases it may press or open into the right lung, bronchi, or trachea; it may burst into the peri- rdium (a common cause of death in these aneurysms), or may compress the right atrium, pulmonary artery and the adjoining part of the right ventricle, and open into one or er of these structures. It may press upon the superior vena cava or the innominate s, causing great venous engorgement in their tributaries; an aneurysm has occasionally rated into the superior vena cava setting up an arteriovenous aneurysm.

Regarding the arch of the aorta, the student is reminded that the vessel lies against trachea, left bronchus, œsophagus, and thoracic duct; that the recurrent nerve winds und it; and that from its upper part are given off three large trunks, which supply head, neck, and upper extremities. An aneurysmal tumour taking origin from the erior part of the vessel, its most usual site, may press upon the trachea and give rise the sign known as 'tracheal tugging,' impede the breathing, or produce cough, ea, bronchiectasis, hæmoptysis, or stridulous breathing, or it may ultimately burst that tube, producing fatal hæmorrhage. Again, its pressure on the left recurrent may give rise to symptoms of laryngeal paralysis; or it may press upon the thoracic and destroy life by inanition; or it may involve the œsophagus, producing dysphagia, has not infrequently been mistaken for œsophageal stricture; or it may burst into phagus, when fatal hæmorrhage will occur. Pressure on the sympathetic filaments produce (1) dilatation of the pupil by stimulation, or later (2) contraction of the pupil bolition of the conducting power of the nerves, on the affected side. The pupillary ges have however been attributed to the alterations of the blood-pressure in the carotid y on the affected side—lowering of pressure leading to partial collapse of the tortuous ls of the iris and dilatation of the pupil, increase of pressure tending to straighten these vessels and diminish the pupillary aperture. Again, the innominate artery, or

CC-0. In Public Domain. Gurukul Kangri Collection, Haridwar

Digitized by Arya Samaj Foundation Chennai and eGangotri

the subclavian, or left carotid, may be so obstructed by clots as to produce a or even a disappearance, of the pulse in one or the other wrist, or in the left temporal artery; or the tumour may present itself at or above the manubrium, either in the median line, or to the right of the sternum, and may simulate of one of the arteries of the neck.

Many of the physical signs of an aortic aneurysm may be simulated with fidelity by the preternatural pulsation or throbbing of a distended and elastic no true aneurysmal dilatation exists. This condition may be met with in with aortic reflux and greatly hypertrophied hearts, in patients who are of a hysterical temperament, and in cases of Graves's disease or of marked condition is known as dynamic dilatation of the aorta, and in no way threatens

Branches (figs. 655, 658).—Three branches are given off from the of the arch of the aorta, viz.: the innominate, the left common caro the left subclavian.

Peculiarities.—The branches may spring from the commencement of the arch part of the ascending aorta; or the distance between them at their origin increased or diminished, the most frequent change in this respect being the tion of the left carotid to the innominate artery.

The number of the primary branches may be reduced to one; more com are two, the left carotid arising from the innominate artery, or (more rarely) and subclavian arteries of the left side arising from a left innominate artery. number may be increased to four, through the right carotid and subclavian arising directly from the aorta; in most of these cases the right subclavian arises left end of the arch; in other cases it is the second or third branch given off. common variation in which there are four primary branches is that where the bral artery arises from the arch of the aorta between the left carotid and arteries. Lastly, the number of trunks may be increased to five or six; in these the external and internal carotid arteries arise separately, the common caro absent on one or both sides. In some few cases six branches have been found, condition is associated with the origin of both vertebral arteries from the arch.

When the aorta arches over to the right side, the three branches have an arra the reverse of what is usual: there is a left innominate artery, and the right ca right subclavian arise separately. In other cases, where the aorta takes its usual the two carotids may be joined in a common trunk, and the subclavians arise from the arch, the right subclavian generally arising from the left end of the arch.

Other arteries may spring from the arch of the aorta. Of these the most are the bronchial, one or both, and the thyreoidea ima; the internal mammary inferior thyreoid have been seen to arise from it.

The Innominate Artery (figs. 655, 658, 659)

The **innominate artery** (arteria anonyma) is the largest branch arch of the aorta, and is from 4 to 5 cm. in length. It arises from the con of the arch of the aorta, posterior to the centre of the manubrium ster passes obliquely upwards, backwards, and to the right to the level of the border of the right sternoclavicular articulation, where it divides into right common carotid and right subclavian arteries.

Relations.—*Anteriorly*, it is separated from the manubrium sterni by the hyoideus and Sternothyreoideus, the remains of the thymus, the left inno and right inferior thyreoid veins which cross its root, and sometimes the cardiac branches of the right vagus nerve. *Posterior* to it is the trachea, crosses obliquely. On the *right side* are the right innominate vein, the upper of the superior vena cava, and the pleura; and on the *left side*, the remains thymus, the origin of the left common carotid artery, the inferior thyreoid and at a higher level the trachea.

Branches.—The innominate artery is usually devoid of branches than its terminal ones, but occasionally the *thyreoidea ima* arises from it. sometimes it gives off a *thymic* or a *bronchial branch*.

The **thyreoidea ima**, small and inconstant, ascends in front of the tra to the lower part of the thyreoid gland, in which it ends. It occasionally from the aorta, or from the right common carotid, subclavian or internal ma arteries.

Peculiarities.—The innominate artery sometimes projects above the upper bo the manubrium sterni. It may divide above the level of the sternoclavicular joint

CC-0. In Public Domain. Gurukul Kangri Collection, Haridwar

Digitized by Arya Samaj Foundation Chennai and eGangotri

...ly below it. When the aortic arch is on the right side, the innominate artery ...ed to the left side of the neck.

...ical Anatomy.—The innominate artery may be wounded in performing the low ...ion of tracheotomy, and an ill-fitting tracheotomy tube may ulcerate into the vessel. ...sm of the innominate artery not infrequently occurs as an accompaniment of ...pushing forwards the arch of the aorta. It causes bulging of the right sternoclavicular articu-. It produces serious pressure symptoms: from pressure on the innominate veins ...y cause œdema of the upper extremities, and of the head and neck; from pressure

FIG. 658.—Dissection of the lower part of the neck, and the upper part of the thorax. Anterior aspect.

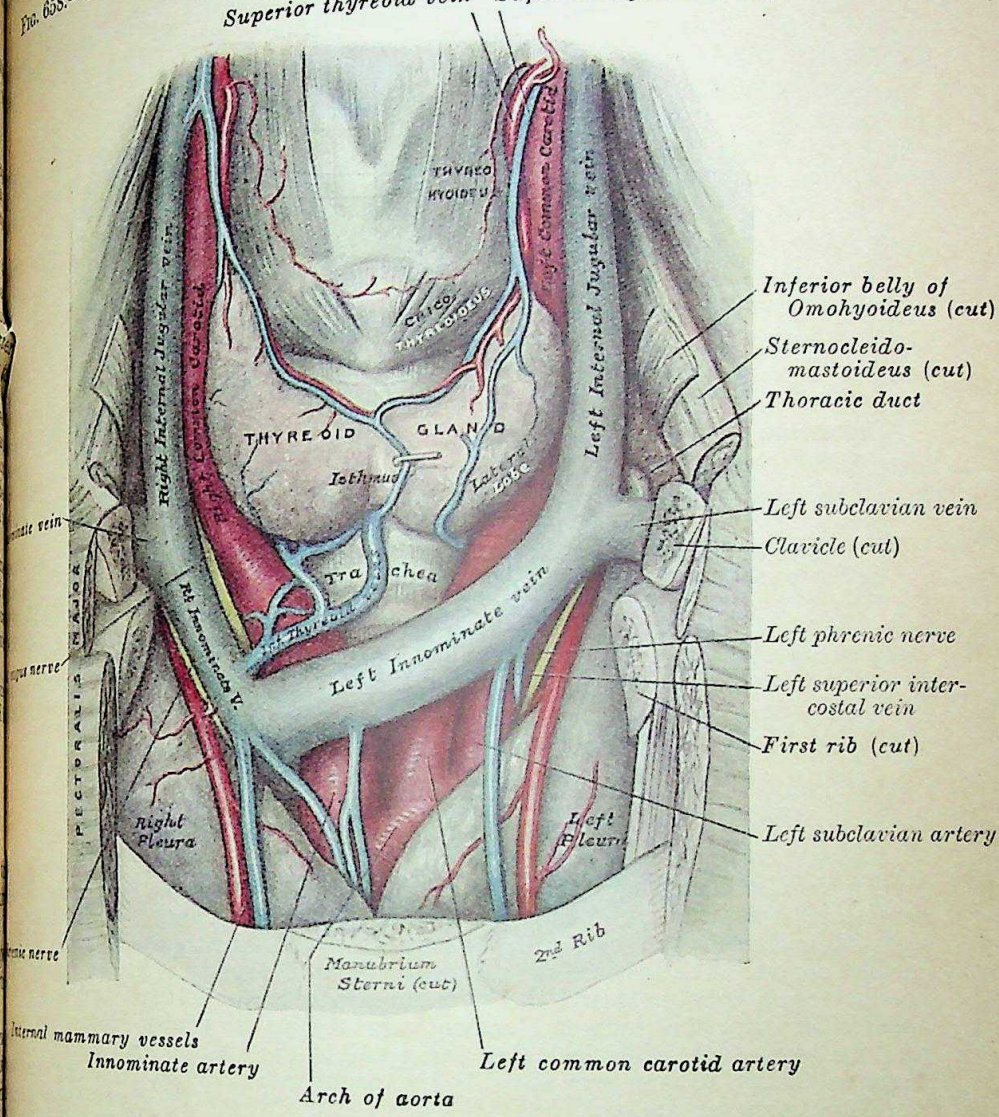

...the trachea it produces dyspnœa; and from pressure on the right recurrent nerve, ...ness and laryngeal cough.

...Although the operation of tying the innominate artery has been performed by several ...ons, few successes have been recorded. The chief danger of the operation appears ...the frequency of secondary hæmorrhage; but in the present day, with the practice ...ic surgery and our greater knowledge of the use of the ligature, more favourable ...may be anticipated. The main obstacles to the operation are the deep situa-... of the artery behind the sternum and the number of important structures which ...d it.

...order to apply a ligature to this vessel, the patient is to be placed upon his back ...the thorax slightly raised, the head bent a little backwards, and the right shoulder ...ly depressed, so as to draw out the artery from behind the sternum into the neck. ...ision 7 cm. or more in length is then made along the anterior border of the Sterno-...mastoideus, terminating at the sternal end of the clavicle. From this point, a ...incision is carried about the same length along the upper border of the clavicle.

CC-0. In Public Domain. Gurukul Kangri Collection, Haridwar

Digitized by Arya Samaj Foundation Chennai and eGangotri

The skin is then dissected back, and the Platysma divided: the sternal end of the cleidomastoideus is now brought into view, and a director being passed beneath it close to its deep surface so as to avoid any small vessels, it is to be divided; in the clavicular origin is to be divided throughout the whole or greater part of the ment. By pressing aside any loose cellular tissue or vessels that may now appear Sternohyoideus and Sternothyreoideus muscles will be exposed, and must be carefully drawn The inferior thyreoid veins may come into view, and must be carefully drawn upwards or downwards, by means of a blunt hook, or tied with double ligatures divided. After tearing through a strong fibrocellular lamina, the right common carotid brought into view, and being traced downwards, the innominate artery is reached left innominate vein should now be depressed; the right innominate vein, the

FIG. 659.—A transverse section through the mediastinal cavity at the level of the body of the third thoracic vertebra.

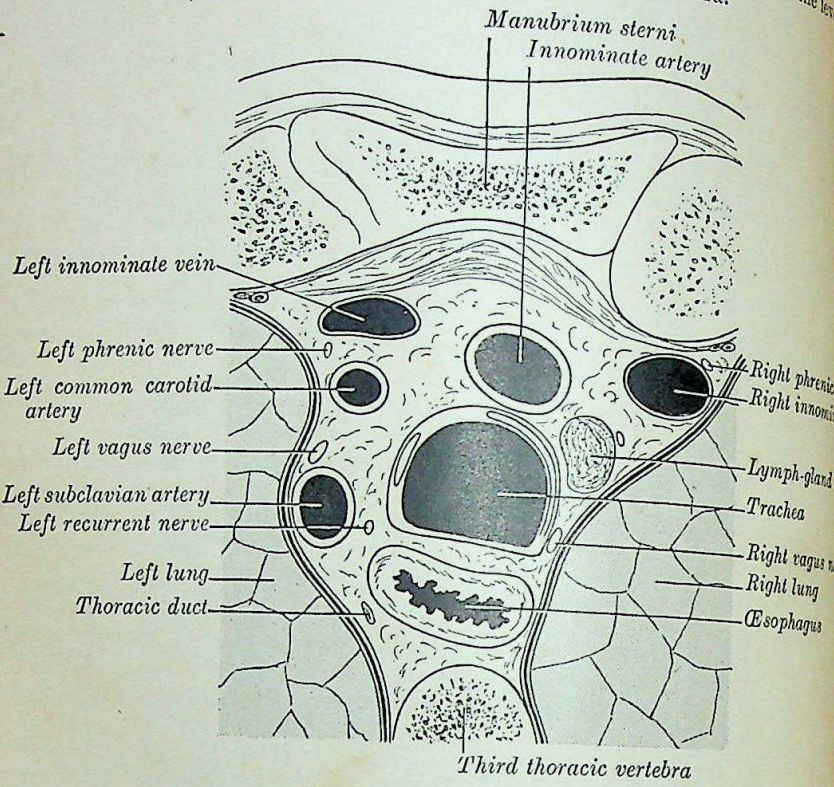

jugular vein, and the vagus nerve drawn to the right side; and a curved aneurysm may then be passed around the vessel, close to its surface, and in a direction from upwards and medially; care being taken to avoid the right pleural sac, the trachea cardiac nerves. The ligature should be applied to the artery as high as possible, in to allow room between it and the aorta for the formation of the coagulum. The tance of avoiding the thyreoid plexus of veins during the primary steps of the operation and the pleural sac while including the vessel in the ligature, should be most carefully borne in mind. To give freer access to the innominate artery a portion of the manubrium sterni is sometimes removed.

Collateral Circulation.—Allan Burns demonstrated, on the dead subject, the bility of the establishment of the collateral circulation after ligature of the innominate artery, by tying and dividing that artery. He then found that 'Even coarse injection impelled into the aorta, passed freely by the anastomosing branches into the arteries of the right arm, filling them and all the vessels of the head completely.'* The branches which this circulation is carried on are numerous; thus, all the communications across the middle line between the branches of the carotid arteries of opposite sides are available for the supply of blood to the right side of the head and neck; the anastomosis between the costocervical of the subclavian and the first aortic intercostal (see *infra* on the lateral circulation after obliteration of the thoracic aorta) brings the blood, by a direct course, into the right subclavian; the numerous connexions between the costal arteries and the branches of the axillary and internal mammary arteries supply of blood to the right arm, while the inferior epigastric from the external the by means of its anastomosis with the internal mammary, compensates for any defect in the vascularity of the wall of the chest.

* *Surgical Anatomy of the Head and Neck*, p. 62.

CC-0. In Public Domain. Gurukul Kangri Collection, Haridwar

Digitized by Arya Samaj Foundation Chennai and eGangotri

THE ARTERIES OF THE HEAD AND NECK

he principal arteries of the head and neck are the two common carotids; ascend in the neck and each divides into two branches, viz. (1) the external rotid, supplying the exterior of the head, the face, and the greater part of neck; (2) the internal carotid, supplying to a great extent the parts within cranial and orbital cavities.

The Common Carotid Arteries

The common carotid arteries differ in length and in their mode of origin. e *right* artery begins at the bifurcation of the innominate artery behind the ternoclavicular joint and is confined to the neck. The *left* artery springs from highest part of the arch of the aorta immediately behind and to the left e innominate artery, and therefore consists of a thoracic and a cervical rtion.

e thoracic portion of the left common carotid artery (figs. 658, 659) ds from the arch of the aorta to the level of the left sternoclavicular joint, re it is continuous with the cervical portion.

Relations.—*In front*, it is separated from the manubrium sterni by the Sternohyoideus and Sternothyreoideus, the anterior portions of the left pleura and lung, left innominate vein, and the remains of the thymus; *behind* it are the left bclavian artery, the trachea, the œsophagus, the left recurrent nerve, and the oracic duct. To its *right side* below, is the innominate artery, and above, trachea, the inferior thyreoid veins, and the remains of the thymus; to its *left* are the left vagus and phrenic nerves, the left pleura and lung.

The cervical portions of the common carotid arteries resemble each other ely that one description will apply to both (figs. 660, 661). Each passes ly upwards, from behind the sternoclavicular articulation, to the level upper border of the thyreoid cartilage, where it divides into the external internal carotid arteries; behind the point of division there is a small ish brown, ductless gland, named the *glomus caroticum* (carotid body).

At the lower part of the neck the two arteries are separated from each other narrow interval which contains the trachea; but at the upper part, the roid gland, the larynx, and the pharynx project forwards between the two ks. The common carotid artery is contained in a sheath, which is derived the fascia colli (deep cervical fascia) and encloses also the internal jugular and vagus nerve, the vein lying lateral to the artery, and the nerve between artery and vein, on a plane posterior to both. In the sheath, each of these ctures has a separate fibrous investment.

Relations.—In the lower part of its course the common carotid artery is very y seated, there being *in front* of it the skin, superficial fascia, Platysma, deep ical fascia, Sternocleidomastoideus, Sternohyoideus, Sternothyreoideus, and hyoideus; in the upper part of its course it is more superficial, being covered r by the skin, the superficial fascia, Platysma, deep cervical fascia, and the al margin of the Sternocleidomastoideus. When the latter muscle is drawn wards, the artery is seen to be contained in the *carotid triangle* (p. 621); this of the artery is crossed obliquely, from its medial to its lateral side, by the cleidomastoid branch of the superior thyreoid artery. In front of or within sheath is the descending branch of the hypoglossal nerve, this branch being ed by the descendens cervicalis nerve which springs from the second and third al nerves and crosses the vessel obliquely. The superior thyreoid vein crosses artery near its termination, and the middle thyreoid vein a little below the of the cricoid cartilage: the anterior jugular vein crosses the artery just above clavicle, but is separated from it by the Sternohyoideus and Sternothyreoideus. ind, the artery is separated from the transverse processes of the cervical vertebræ the Longus colli and Longus capitis, the sympathetic trunk being interposed ween the artery and the muscles; the inferior thyreoid artery crosses behind er part of the vessel. *Medial* to it are the œsophagus, trachea, and thyreoid ind (which overlaps it), the inferior thyreoid artery and recurrent nerve being

CC-0. In Public Domain. Gurukul Kangri Collection, Haridwar

Digitized by Arya Samaj Foundation Chennai and eGangotri

interposed; higher up, the larynx and pharynx. *Lateral* to the artery internal jugular vein and vagus nerve.

At the lower part of the neck, the right recurrent nerve crosses oblique the artery; the right internal jugular vein diverges from the artery, b approaches and often overlaps the lower part of the artery. Below the

FIG. 660.—A superficial dissection of the right side of the neck, showing the carotid and subclavian arteries.

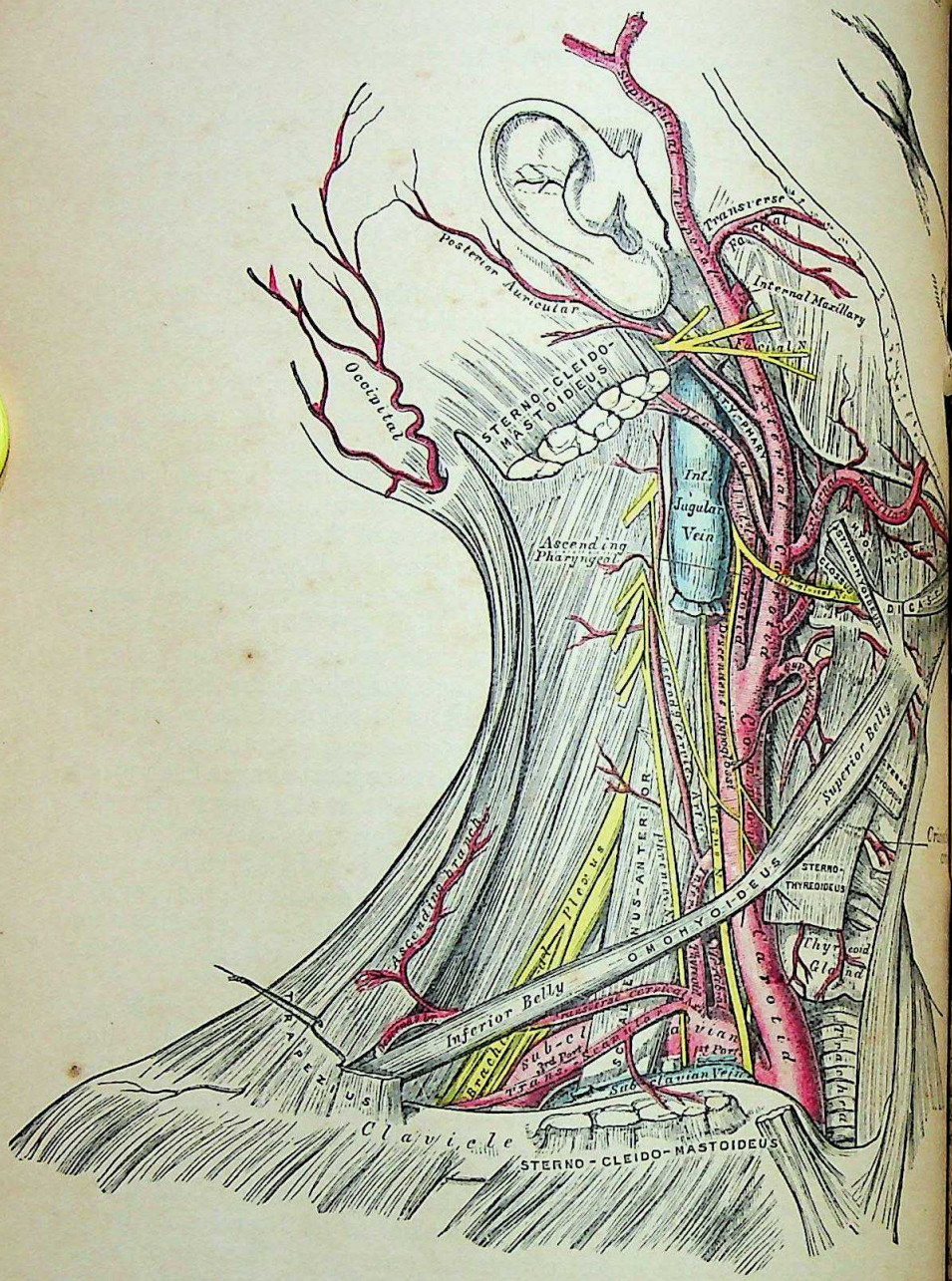

the sixth cervical vertebra the left common carotid artery is in relation poste with the vertebral artery, the cervical part of the thoracic duct crossing betw the two vessels.

Peculiarities.—In about 12 per cent. of subjects the *right* common-carotid artery a above the level of the upper border of the sternoclavicular articulation. It may ar a separate branch from the arch of the aorta, or in conjunction with the left carotid. *left* common carotid artery varies in its origin more frequently than the right. In majority of abnormal cases it arises with the innominate artery; if that artery be a the two carotids arise usually by a single trunk. It is rarely joined with the left subcl except in cases of transposition of the aortic arch.

CC-0. In Public Domain. Gurukul Kangri Collection, Haridwar

Digitized by Arya Samaj Foundation Chennai and eGangotri

division of the common carotid artery may occur at or about the level of the hyoid more rarely it occurs below the usual level, opposite the middle of the larynx, or upper border of the cricoid cartilage; one case is described by Morgagni, where the was only 4 cm. in length and divided at the root of the neck. Very rarely the artery in the neck without undergoing subdivision, either the external or the internal being wanting. In a few cases the artery has been found absent, the external internal carotid arteries arising directly from the arch of the aorta; this peculiarity on both sides in some instances, on one side only in others.

common carotid artery usually supplies no branch; but it may give origin to the the superior thyreoid or its laryngeal branch, the ascending pharyngeal, the thyreoid, or the occipital.

Anatomy.—Aneurysms are not often found on the common carotid artery; they do occur they are usually situated low down at the root of the neck, or just the point of bifurcation of the vessel. They do not often assume a large size, and commonly found on the right side. As they increase in size they displace the and larynx, and therefore dyspnœa becomes a prominent symptom. Dysphagia

FIG. 661.—A transverse section through the anterior part of the neck at the level of the body of the first thoracic vertebra.

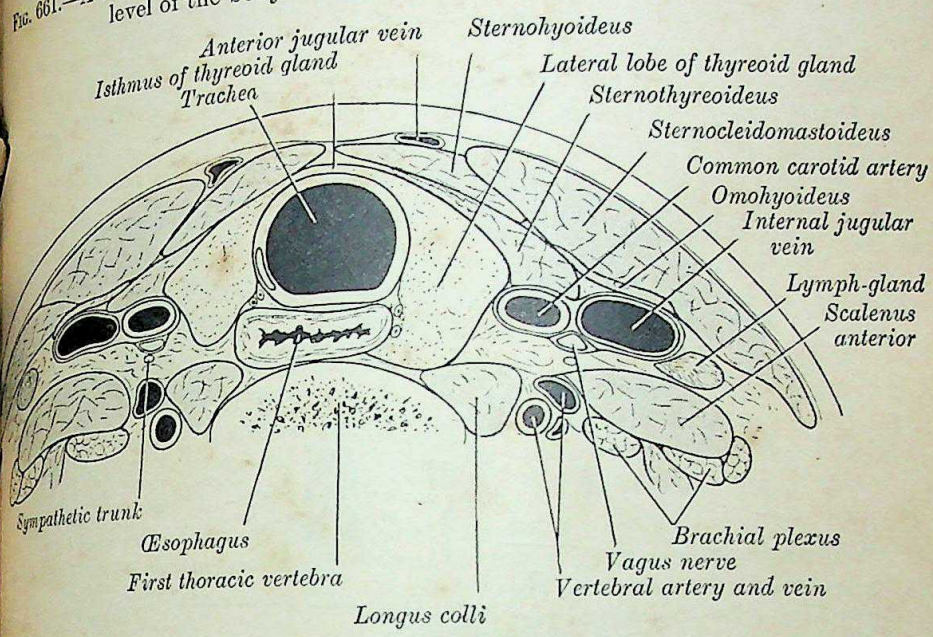

may be present from pressure on the œsophagus, especially if the aneurysm is on the side; and pressure on the recurrent nerve may produce hoarseness and laryngeal . Pressure on the sympathetic will cause pupillary changes—dilatation of the pupil the sympathetic is irritated or the arterial blood-supply to the eye is lessened, con- when the sympathetic has become paralysed; sympathetic irritation may also unilateral sweating of the head and neck. Pressure on the superficial branches of vical plexus may give rise to pain in the head, face and neck; pressure on the vagus gular action of the heart and to asthmatic attacks. It is important to bear in mind an enlarged lymph-gland in the superior carotid triangle, receiving a transmitted from the carotid artery, may simulate aneurysm of that vessel, but may be ished from it by the character of the pulsation, which is not expansile.

bolism of the left common carotid artery, or the thrombosis that may follow injury the wall of the vessel by penetrating gunshot wounds of the neck, have been known duce aphasia by interference with the blood-supply of the brain.

gital compression of the common carotid artery is sometimes required, and is best ed by pressing the vessel with the thumb against the anterior tubercle of the trans- process of the sixth cervical vertebra (p. 167).

the upper part of the common carotid artery should be selected as the spot upon which e a ligature (fig. 662 C), for the lower part is placed very deeply; moreover, on the s, the internal jugular vein, in most cases, passes obliquely in front of it. The part vessel which is most favourable for the operation is that opposite the level of the d cartilage. It occasionally happens that the artery divides below its usual position: artery be exposed at its point of bifurcation, both divisions of the vessel should be ear their origin, in preference to tying the trunk of the artery near its termination; d, in consequence of the entire absence of the common carotid artery, or from its division, two arteries, the external and internal carotids, are met with, the ligature ld be placed on that vessel which is found on compression to be connected with the ased area.

CC-0. In Public Domain. Gurukul Kangri Collection, Haridwar

Digitized by Arya Samaj Foundation Chennai and eGangotri

In this operation, the direction of the vessel and the anterior margin of the cleidomastoideus are the chief guides to its performance. The patient should be on his back with the head extended and turned slightly to the opposite side; an is to be made, 7 or 8 cm. long, in the direction of the anterior border of the Ster mastoideus, so that the centre corresponds to the level of the cricoid cartilage; dividing the integument, superficial fascia, Platysma, and deep fascia, the margins wound are held asunder by retractors, and the ramus descendens hypoglossi exposed must be avoided. The sheath of the vessel is to be raised by forceps, and opened small extent over the artery at its medial side. The internal jugular vein must itself alternately distended and relaxed, and must be carefully avoided. The needle is passed from the lateral aspect, care being taken to keep the needle contact with the artery, and thus avoid the risk of injuring the internal jugular including the vagus nerve. Before the ligature is tied, it should be ascertained nothing but the artery is included in it.

Fig. 662.—Dissections to show (A) the accessory nerve, (B) the lingual artery, (C) the common carotid artery, and (D) the third part of the subclavian artery.

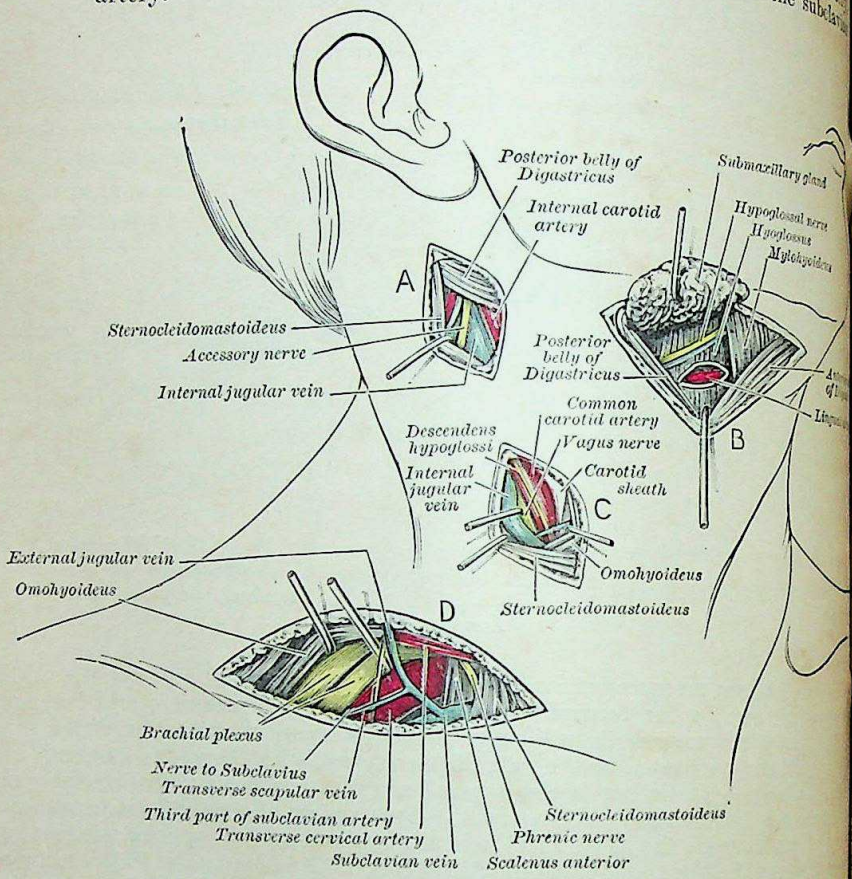

Ligature of the common carotid near the root of the neck is sometimes required in cases of aneurysm of the upper part of the artery, especially if the sac is of large size. It is best performed by dividing the sternal origin of the Sternocleidomastoideus, which may be done in some cases, if the aneurysm is not of very large size, by an incision along the anterior border of the muscle, extending down to the sternoclavicular articulation, and by then retracting the muscle. Beneath it are two additional muscular layers, viz., the Sternohyoideus and the Sternothyreoideus; these have to be split and retracted one after the other, before the sheath of the vessel is reached. In doing this, care must be taken not to wound the anterior jugular vein, which crosses the Sternohyoideus to the external jugular or subclavian vein. The sheath must be opened on its medial or tracheal side, so as to avoid the internal jugular vein. Special care is necessary on the left side, where the artery is commonly overlapped by the vein; on the right side there is usually an interval between the artery and the vein, and the risk of wounding the latter is less.

Brasdor's method of ligaturing an artery on the distal side of an aneurysm is particularly suitable for the cure of aneurysm at the lower part of the common carotid, since no branches are given off from the artery between the aneurysm and the ligature.

CC-0. In Public Domain. Gurukul Kangri Collection, Haridwar

Digitized by Arya Samaj Foundation Chennai and eGangotri

Collateral Circulation.—After ligature of the common carotid, the collateral circulation may be perfectly established by the free communication which exists between the vessels of opposite sides, both without and within the cranium, and by enlargement of the branches of the subclavian artery. The chief communications outside the cranium take place between the superior and inferior thyreoid arteries, and between the ramus cervicis and ramus descendens of the occipital; the vertebral takes the place of the internal carotid within the cranium.

Wounds of the common carotid should be treated by suture whenever possible, because, after ligature of the vessel, hemiplegia or other symptom of cerebral disturbance supervenes in about twenty-five per cent. of cases.

The External Carotid Artery

The **external carotid artery** (fig. 660) begins opposite the upper border of the thyreoid cartilage, at the level of the disc between the third and fourth cervical vertebræ, and, taking a slightly curved course, passes upwards and forwards, and then inclines backwards to a point behind the neck of the mandible, where it divides into the superficial temporal and internal maxillary arteries. It diminishes rapidly in size, owing to the number and large size of the branches given off from it. In the child, it is somewhat smaller than the internal carotid; but in the adult, the two vessels are of nearly equal size. At its origin, this artery is more superficial, and placed nearer the middle line than the internal carotid artery, and is contained within the carotid triangle.

Relations.—The external carotid artery is *covered by* the skin, superficial fascia, platysma, deep fascia, and anterior margin of the Sternocleidomastoideus; it is crossed by the Digastricus and Stylohyoideus, the hypoglossal nerve and its vena comitans, the lingual and the common facial veins, and sometimes by the superior thyreoid veins, higher up it passes into the substance of the parotid gland, where it is deep to the facial nerve and the junction of the superficial temporal and internal maxillary veins. *Medial* to it are the hyoid bone, the wall of the pharynx, the superior laryngeal nerve, and a portion of the parotid gland. *Lateral* to it, in the lower part of its course, is the internal carotid artery. Higher up it is separated from the internal carotid artery by the styloid process or stylohyoid muscle, the Styloglossus and Stylopharyngeus muscles, the glossopharyngeal nerve, and pharyngeal branch of the vagus nerve, and part of the parotid gland.

Applied Anatomy.—Ligature of the external carotid may be required in cases of wound of this vessel, or of its branches when these cannot be tied, and in some cases of pulsating tumours of the scalp or face. It is also done as a preliminary measure to excision of the maxilla or tonsil. The seat of election for ligature is between the origins of the superior thyreoid and lingual branches, about a finger's breadth below the tip of the greater cornu of the hyoid bone. To tie the vessel, an incision is made from the angle of the mandible to the upper border of the thyreoid cartilage, and the superficial tissues and deep fascia divided. The anterior border of the Sternocleidomastoideus must be retracted and the lower border of the parotid gland raised, so as to expose the tendon of the Digastricus and the hypoglossal nerve, which cross the artery. The great difficulty in this is due to the plexus of veins derived from the superior thyreoid and lingual veins, which overlie the artery; if necessary, these must be ligatured and divided. Care must be taken not to mistake the lingual and external maxillary arteries, when they arise by a common trunk, as they sometimes do, for the external carotid artery. The needle is to be passed from the lateral to the medial side of the vessel, carefully avoiding the superior laryngeal nerve, which lies in close proximity to the artery.

Collateral Circulation.—The circulation is re-established by the free communication between most of the large branches of the artery (external maxillary, lingual, superior thyreoid, occipital) and the corresponding arteries of the opposite side, and by the anastomosis of its branches with those of the internal carotid artery, and of the occipital and with branches of the subclavian, &c.

The Branches of the External Carotid Artery (figs. 660, 663)

The branches of the external carotid artery are:

1. Superior thyreoid.
2. Ascending pharyngeal.
3. Lingual.
4. External maxillary.
5. Occipital.
6. Posterior auricular.
7. Superficial temporal.
8. Internal maxillary.

1. The **superior thyreoid artery** (fig. 660) arises from the external carotid just below the level of the greater cornu of the hyoid bone and ends in the thyreoid gland.

CC-0. In Public Domain. Gurukul Kangri Collection, Haridwar

Digitized by Arya Samaj Foundation Chennai and eGangotri

Relations.—From its origin beneath the anterior border of the St mastoideus it runs upwards and forwards for a short distance in the triangle, where it is covered by the skin, Platysma, and fascia; it p downwards beneath the Omohyoideus, Sternohyoideus, and Sternoth To its medial side are the Constrictor pharyngis inferior and the exter of the superior laryngeal nerve.

FIG. 663.—Plan of the branches of the external carotid artery.

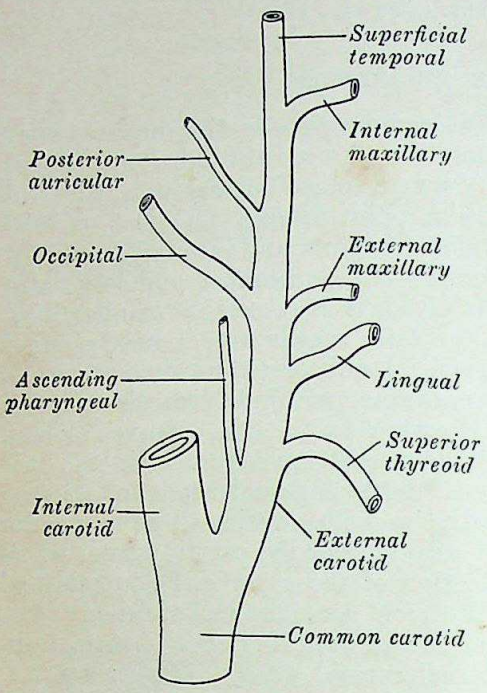

Branches.—It distributes the adjacent muscles, and bran thyreoid gland; it anastomoses fellow of the opposite side, and inferior thyreoid arteries. The to the gland are generally two to an anterior and a posterior; the and larger branch supplies the anterior surface; on the of the gland it anastomoses corresponding artery of the side; the posterior branch des the posterior surface of the gl anastomoses with the inferior artery.

Besides the arteries distrib the muscles and to the thyreoid the superior thyreoid artery supp following branches:

Hyoid.
Sternocleidomastoid.
Superior laryngeal.
Cricothyreoid.

The **hyoid branch** is small a along the lower border of the hy beneath the Thyreohyoideus, and anastomoses with the vessel of the side.

The **sternocleidomastoid branch** frequently arises from the external artery; it runs downwards and lateralwards across the sheath of the carotid artery, and enters the Sternocleidomastoideus.

The **superior laryngeal artery**, larger than either of the preceding, is quently a separate branch of the external carotid artery; it accompa internal laryngeal branch of the superior laryngeal nerve, beneath the hyoideus; it pierces the lower part of the hyothyreoid membrane, and supp muscles, mucous membrane and glands of the larynx, anastomosing w artery of the opposite side, and with the inferior laryngeal branch of the thyreoid artery.

The **cricothyreoid branch** is small and runs transversely across the upp of the cricothyreoid membrane, communicating with the artery of the oppo

Applied Anatomy.—The superior thyreoid artery, or one of its branches, divided in cases of cut throat, giving rise to considerable hæmorrhage. The thyreoid is ligatured in cases of bronchocele where the removal of a lobe of the gland may present special dangers.

The position of the sternocleidomastoid branch is of importance in connexion the operation of ligature of the common carotid artery. It crosses and lies on the of this vessel and may chance to be wounded in opening the sheath. The position cricothyreoid branch should be remembered, as it may prove the source of tro hæmorrhage during the operation of laryngotomy.

2. The **ascending pharyngeal artery** (fig. 668), the smallest bran the external carotid artery, is a long, slender vessel, deeply seated in the It arises close to the origin of the external carotid artery, and ascends cally between the internal carotid artery and the side of the pharynx under surface of the base of the skull, lying on the Longus capitis; it anast freely with the ascending palatine branch of the external maxillary arte

Its branches are:

Pharyngeal. Inferior tympanic. Posterior meningeal.

CC-0. In Public Domain. Gurukul Kangri Collection, Haridwar

Digitized by Arya Samaj Foundation Chennai and eGangotri

The **pharyngeal branches** are three or four in number. Two of these descend
upply the Constrictores pharyngis medius et inferior and the Stylopharyngeus,
ying in their substance and in the underlying mucous membrane. A branch of
he size is distributed to the palate, and may take the place of the ascending
o branch of the external maxillary artery; it runs downwards and forwards
n the superior border of the Constrictor pharyngis superior and the Levator
alatini, and accompanies the latter muscle to the soft palate; it gives branches
o tonsil, and supplies a twig to the auditory tube.

The **inferior tympanic artery** is a small branch which passes through the inferior
anic canaliculus of the temporal bone, in company with the tympanic branch
he glossopharyngeal nerve, to supply the medial wall of the tympanic cavity
nastomose with the other tympanic arteries.

The **meningeal branches** are several small vessels which supply the dura mater.
the *posterior meningeal*, enters the cranium through the foramen lacerum;
ond passes through the jugular foramen; and occasionally a third through
anal for the hypoglossal nerve.

Numerous small vessels supply the Longi capitis et colli, the sympathetic trunk,
ypoglossal and vagus nerves, and the lymph-glands; they anastomose with
ascending cervical and vertebral arteries.

The **lingual artery** (fig. 668) arises from the external carotid artery
n the superior thyreoid and external maxillary arteries; it runs
ely upwards and medialwards to the greater cornu of the hyoid bone,
then curves downwards and forwards, forming a loop which is crossed by
ypoglossal nerve; it passes beneath the Digastricus and Stylohyoideus,
horizontally forwards beneath the Hyoglossus, and finally, ascending
st perpendicularly to the tongue, courses forwards on its lower surface as
as the tip.

Relations.—Its first portion is contained within the carotid triangle; it rests
the Constrictor pharyngis medius, and is under cover of the Platysma and
fascia of the neck. Its second portion also lies upon the Constrictor
ngis medius, being at first under cover of the tendon of the Digastricus
the Stylohyoideus, and afterwards of the Hyoglossus. Its third portion
between the Hyoglossus and Genioglossus. The fourth or terminal part,
the name of the *arteria profunda linguæ* (ranine artery), runs along the inferior
e of the tongue to its tip, covered only with the mucous membrane; above
the Longitudinalis inferior, and medial to it the Genioglossus. The hypoglossal
e crosses the first part of the lingual artery, but is separated from the second
by the Hyoglossus.

The branches of the lingual artery are:

Hyoid.	Sublingual.
Rami dorsales linguæ.	Arteria profunda linguæ.

The **hyoid branch** is very small; it runs along the upper border of the hyoid
supplying the muscles attached to the bone, and anastomosing with its fellow
e opposite side.

The **rami dorsales linguæ** consist usually of two or three small branches; they
beneath the Hyoglossus, ascend to the posterior part of the dorsum of the
e, and supply the mucous membrane of the tongue, the glossopalatine arch,
alatine tonsil, soft palate, and epiglottis; they anastomose with the vessels
e opposite side.

The **sublingual artery** arises at the anterior margin of the Hyoglossus, and
forward between the Genioglossus and Mylohyoideus to the sublingual gland.
ies the gland and gives branches to the Mylohyoideus and neighbouring
s, and to the mucous membrane of the mouth and gums. One branch
behind the alveolar part of the mandible in the substance of the gum to
ose with a similar artery from the other side; another pierces the Mylo-
s and anastomoses with the submental branch of the external maxillary

The **arteria profunda linguæ** (ranine artery) is the terminal portion of the lingual
; it pursues a tortuous course and runs along the under surface of the tongue
side of the frenulum linguæ, between the Longitudinalis linguæ inferior and
ucous membrane; it lies on the lateral side of the Genioglossus, accompanied
the lingual nerve.

CC-0. In Public Domain. Gurukul Kangri Collection, Haridwar

Digitized by Arya Samaj Foundation Chennai and eGangotri

Applied Anatomy.—The lingual artery is not infrequently divided near its origin in cases of cut throat; while severe hæmorrhage, which cannot be restrained by ordinary means, may ensue from a wound, or deep ulcer, of the tongue. In the former case the primary wound may be enlarged if necessary, and the bleeding vessel secured; in the latter, it has been suggested that the lingual artery should be tied near its origin.

Ligature of the lingual artery (fig. 662, B) has been practised as a preliminary to removal of the tongue. The operation is a difficult one on account of the size of the artery, the number of important parts by which it is surrounded, and its irregularity of origin. An incision is to be made in a curved direction from the breadth behind the symphysis menti downwards to the cornu of the hyoid bone, and upwards to near the angle of the mandible. Care must be taken not to carry the incision too far backwards, for fear of endangering the anterior facial vein. In the first incision the skin, superficial fascia, and Platysma will be divided, and the deep fascia exposed. This is then to be incised and the submaxillary gland exposed and pulled upwards. A triangular space is now seen, bounded in front by the posterior border of the Mylohyoid, below and behind by the tendon of the Digastricus, and above by the hypoglossal. The floor of the space is formed by the Hyoglossus, beneath which the artery lies. The parts are to be drawn forwards by a blunt hook inserted beneath the tendon of the Digastricus, and the fibres of the Hyoglossus cut through horizontally just above the Digastricus. The artery will then be exposed lying on the Constrictor pharyngis medius, and in passing the aneurysm needle, care must be taken not to pierce the latter. The hypoglossal nerve must also be avoided.

Troublesome hæmorrhage may occur in the division of the frenulum linguæ in case if the aa. profundæ linguæ, which lie one on either side of it, be wounded. This operation should always be performed with a pair of blunt-pointed scissors, and the mucous membrane alone divided by a very superficial cut, which cannot endanger any vessel. The further liberation of the tongue which may be necessary can be effected by tearing.

4. The **external maxillary artery** (facial artery) (fig. 664) arises from the external carotid artery in the carotid triangle a little above the lingual. Sheltered by the ramus of the mandible, it passes obliquely up beneath the Digastricus and Stylohyoideus, above which it arches to enter a groove on the posterior border of the submaxillary gland. It then curves upwards on the body of the mandible at the antero-inferior angle of the Masseter; forwards and upwards across the cheek to the angle of the mouth, then along the side of the nose, and ends as the *angular artery* at the palpebral commissure. The external maxillary artery is remarkably tortuous in the neck to accommodate itself to the movements of the pharynx in deglutition, and on the face to the movements of the mandible, lips, cheeks.

Relations.—*In the neck*, its origin is superficial, being placed under cover of skin, Platysma, and fascia; it then passes beneath the Digastricus and Stylohyoid muscles and part of the submaxillary gland, and frequently beneath the hypoglossal nerve. It lies upon the Constrictores pharyngis medius et superior, the latter which separates it, at the summit of its arch, from the lower and posterior part of the tonsil. *On the face*, where it passes over the body of the mandible, it is comparatively superficial, lying immediately beneath the Platysma. In its course over the face, it is under cover of the skin, the fat of the cheek, and, near the angle of the mouth, the Platysma, Risorius, and Zygomaticus. It rests on the Buccinator and Caninus, and passes either over or through the infra-orbital head of the Quadratus labii superioris. The anterior facial vein lies posterior to the artery, and takes a more direct course across the face, where it is separated from the artery by a considerable interval; in the neck it lies superficial to the artery. The branches of the facial nerve cross the artery from behind forwards.

The branches of the external maxillary artery may be divided into two sets: those given off in the neck (cervical), and those on the face (facial).

Cervical branches.	*Facial branches.*
Ascending palatine.	Inferior labial.
Tonsillar.	Superior labial.
Glandular.	Lateral nasal.
Submental.	Angular.

The **ascending palatine artery** (fig. 668) arises close to the origin of the external maxillary artery and passes up between the Styloglossus and Stylopharyngeus to the side of the pharynx, along which it is continued between the Constrictor pharyngis superior and the Pterygoideus internus towards the base of the

CC-0. In Public Domain. Gurukul Kangri Collection, Haridwar

Digitized by Arya Samaj Foundation Chennai and eGangotri

the Levator veli palatini it divides into two branches: one follows the course is muscle, and, winding over the upper border of the Constrictor pharyngis supplies the soft palate and the palatine glands, anastomosing with its of the opposite side and with the descending palatine branch of the internal ry artery; the other pierces the Constrictor pharyngis superior and supplies latine tonsil and auditory tube, anastomosing with the tonsillar and ascending ngeal arteries.

Fig. 664.—The arteries of the right side of the face and scalp.

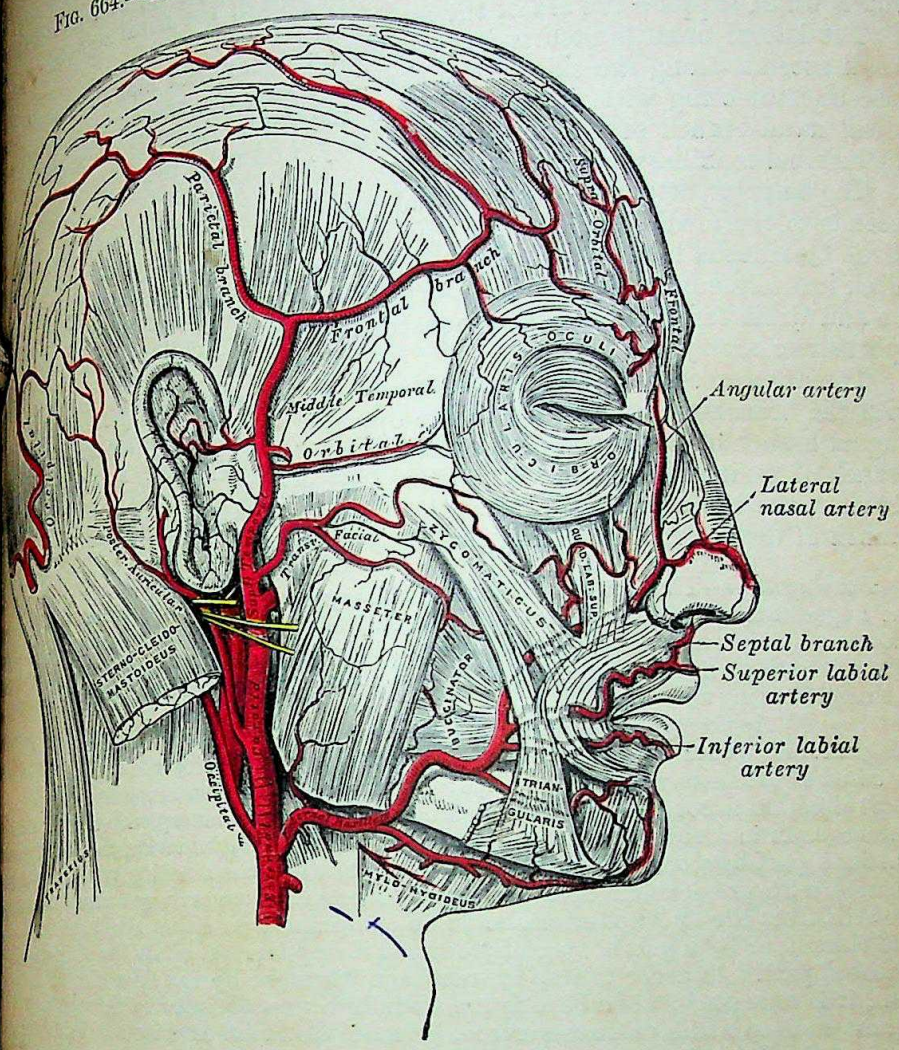

The **tonsillar branch** (fig. 668), sometimes derived from the ascending palatine ry, ascends between the Pterygoideus internus and Styloglossus, and then g the side of the pharynx; it perforates the Constrictor pharyngis superior and tes in the palatine tonsil and the root of the tongue.

The **glandular branches**, three or four large vessels, supply the submaxillary ary gland and lymph-glands, the neighbouring muscles, and the skin.

The **submental artery**, the largest cervical branch of the external maxillary ry, springs from that artery just as it quits the submaxillary gland: it runs wards upon the Mylohyoideus, below the body of the mandible, and beneath anterior belly of the Digastricus. It supplies the surrounding muscles, and stomoses with the sublingual artery and with the mylohyoid branch of the or alveolar artery; at the chin it turns upwards over the inferior border of mandible and divides into a superficial and a deep branch. The superficial ch passes between the skin and the Quadratus labii inferioris, and anastomoses the inferior labial artery; the deep branch runs between the muscle and bone, supplies the lip, and anastomoses with the inferior labial and mental ries.

CC-0. In Public Domain. Gurukul Kangri Collection, Haridwar

Digitized by Arya Samaj Foundation Chennai and eGangotri

The **inferior labial artery** (inferior coronary artery) arises near the the mouth; it passes upwards and forwards beneath the Triangularis, and trating the Orbicularis oris, runs in a tortuous course near the edge of the between this muscle and the mucous membrane. It supplies the gland membrane and muscles of the lower lip; and anastomoses with the artery opposite side, and with the mental branch of the inferior alveolar artery.

The **superior labial artery** (superior coronary artery) is larger and more than the inferior. It follows a similar course near the edge of the upper between the mucous membrane and the Orbicularis oris, and anastomoses the artery of the opposite side. It supplies the upper lip, and gives off *branch* which ramifies on the lower and front part of the nasal septum, and *branch* which supplies the ala of the nose.

The **lateral nasal branch** is derived from the external maxillary artery vessel ascends along the side of the nose. It supplies the ala and dorsum nose anastomosing with its fellow, with the septal and alar branches dorsal nasal branch of the ophthalmic artery, and with the infra-orbital the internal maxillary artery.

The **angular artery** is the terminal part of the external maxillary ascends to the medial angle of the eye, imbedded in the fibres of the of the Quadratus labii superioris, and accompanied by the angular vein. cheek it anastomoses with the infra-orbital artery, and, after supplying the sac and Orbicularis oculi, ends by anastomosing with the dorsal nasal branch ophthalmic artery.

The anastomoses of the external maxillary artery are very numerous, with the branches of the vessel of the opposite side, but, *in the neck*, with the lingual branch of the lingual, with the ascending pharyngeal, and with the branch of the internal maxillary; *on the face*, with the mental branch of the alveolar, the transverse facial branch of the superficial temporal, the infra- branch of the internal maxillary, and the dorsal nasal branch of the ophthal

Peculiarities.—The external maxillary artery not infrequently arises in common the lingual artery. It varies in size, and in the extent to which it supplies the occasionally ends as the submental, and not infrequently extends only as high as the of the mouth or nose. The deficiency is then compensated for by enlargement of the neighbouring arteries.

Applied Anatomy.—The passage of the external maxillary artery over the the mandible would appear to afford a favourable position for the application of in cases of hæmorrhage from the lips; but such application is useless, except for short time, on account of the free communication of the artery with its fellow, and numerous branches from different sources. In a wound involving the lip, it is seize the part between the fingers, and evert it, when the bleeding vessel may be secured with pressure-forceps. In order to prevent hæmorrhage during the growths from the lip, the latter should be compressed on either side between the and thumb, or by a pair of specially devised clamp-forceps, while the surgeon diseased part. In order to stop hæmorrhage when the lip has been divided in tion, it is necessary, when closing the wound, to pass the sutures through the almost as deep as its mucous surface, because the labial arteries run in the layer of the lips; by these means, not only are the cut surfaces more neatly and adapted to each other, but the possibility of hæmorrhage is prevented by including divided artery in the suture. If, on the contrary, the suture be passed through the cutaneous portion of the wound, hæmorrhage occurs into the cavity of the The student should observe that the angular artery ascends on the nasal side lacrimal sac; in operating for fistula lacrimalis, the sac should always be opened lateral side, in order to avoid this vessel.

The external maxillary artery is separated from the lower and hinder part of the by the Constrictor pharyngis superior, and may be wounded in operations in that

The free anastomosis of the branches of the external maxillary artery contrib the success of plastic operations on the face.

5. The **occipital artery** (fig. 664) arises from the posterior part of external carotid artery, opposite to the external maxillary artery, and the lower margin of the posterior belly of the Digastricus; it ends in posterior part of the scalp.

Relations.—At its origin, it is under cover of the posterior belly of the Digastricus and the Stylohyoideus, and the hypoglossal nerve winds round it from behind forwards; higher up, it crosses the internal carotid artery, the internal jugular vein, and the vagus and accessory nerves. It next ascends along the lower bord

CC-0. In Public Domain. Gurukul Kangri Collection, Haridwar

Digitized by Arya Samaj Foundation Chennai and eGangotri

posterior belly of the Digastricus to the interval between the transverse process the atlas vertebra and the mastoid process of the temporal bone, and passes zontally backwards, grooving the surface of the latter bone, being covered by Sternocleidomastoideus, Splenius capitis, Longissimus capitis, and Digastricus, sting upon the Rectus capitis lateralis, Obliquus superior, and Semispinalis It then runs vertically upwards, pierces the fascia connecting the cranial chment of the Trapezius with the Sternocleidomastoideus, and ascends in a uous course in the superficial fascia of the scalp, where it divides into numerous ches. Its terminal portion is accompanied by the greater occipital nerve.

The branches of the occipital artery are:

Sternocleidomastoid.	Auricular.	Meningeal.
Mastoid.	Muscular.	Occipital.
	Ramus descendens.	

The **sternocleidomastoid branch** generally arises from the beginning of the occipital ry, but sometimes springs directly from the external carotid artery. It passes wards and backwards over the hypoglossal nerve, and enters the sub- e of the Sternocleidomastoideus, in company with the accessory nerve; it stomoses with the sternocleidomastoid branch of the superior thyreoid artery.

The **mastoid branch**, small in size and sometimes absent, enters the cranial through the mastoid foramen; it gives branches to the mastoid air-sinuses e dura mater, and anastomoses with the middle meningeal artery.

The **auricular branch** supplies the back of the concha and anastomoses with sterior auricular artery.

Muscular branches are supplied to the Digastricus, Stylohyoideus, Splenius, and issimus capitis.

The **ramus descendens** (arteria princeps cervicis) (fig. 668) arises from the al artery as the latter lies on the Obliquus superior, and divides into a rficial and a deep branch. The superficial branch passes beneath the Splenius, anastomoses with the ascending branch of the transverse cervical artery; the branch descends between the Semispinales capitis et colli, and anastomoses the vertebral artery, and with the arteria profunda cervicalis, a branch of the vertebral trunk. The anastomosis between these vessels assists in establishing llateral circulation after ligature of the common carotid or subclavian artery.

The **meningeal branches** ascend with the internal jugular vein, and enter the through the jugular foramen and condyloid canal, to supply the dura mater e posterior fossa.

The **occipital branches**, the terminal branches, are distributed to the scalp, and as high as the vertex of the skull; they are very tortuous, and lie between kin and the Occipitalis, anastomosing with the artery of the opposite side and the posterior auricular and temporal arteries, and supplying the Occipitalis, kin, and the pericranium. One of the terminal branches may give off a ngeal twig which passes through the parietal foramen.

The **posterior auricular artery** (fig. 664) is small and arises from the nal carotid artery immediately above the Digastricus and Stylohyoideus. ends, under cover of the parotid gland, on the styloid process of the oral bone, to the groove between the cartilage of the auricula and the oid process, where it divides into auricular and occipital branches.

In addition to supplying small branches to the Digastricus, Stylohyoideus, rnocleidomastoideus, and parotid gland, this vessel gives off the three wing branches:

Stylomastoid.	Auricular.	Occipital.

The **stylomastoid artery** enters the stylomastoid foramen and supplies the panic cavity, the tympanic antrum, the mastoid air-sinuses, and the semicircular als. In the young subject a branch from this vessel forms, with the anterior panic artery from the internal maxillary, a vascular circle which surrounds supplies small vessels to the deep surface of the tympanic membrane. It stomoses with the superficial petrosal branch of the middle meningeal artery a twig which enters the hiatus canalis facialis.

The **auricular branch** ascends beneath the Auricularis posterior, and ramifies the back of the auricula; some of its branches pierce the auricula, and others e round its margin to supply its lateral surface. It anastomoses with the ral and anterior auricular branches of the superficial temporal artery.

CC-0. In Public Domain. Gurukul Kangri Collection, Haridwar

Digitized by Arya Samaj Foundation Chennai and eGangotri

The **occipital branch** passes backwards over the Sternocleidomastoid, the Occipitalis muscle and the scalp above and behind the ear; it anastomoses with the occipital artery.

7. The **superficial temporal artery** (fig. 664), the smaller terminal branch of the external carotid artery, begins in the parotid gland, behind the neck of the mandible, and crosses over the posterior root of the zygomatic process of the temporal bone; about 5 cm. above this process it divides into a frontal and a parietal branch.

Relations.—As it crosses the zygomatic process, it is covered by the Auricularis anterior; it is crossed by the temporal and zygomatic branches of the facial nerve and is accompanied by the auriculotemporal nerve, which lies immediately behind it.

It supplies some twigs to the parotid gland, the mandibular joint, and the Masseter, and gives off the following branches:

Transverse facial.	Zygomatico-orbital.	Frontal.
Anterior auricular.	Middle temporal.	Parietal.

The **transverse facial artery** (fig. 664) arises from the superficial temporal artery before that vessel quits the parotid gland; it runs forwards through the substance of the gland, passes across the Masseter between the parotid duct and the zygomatic arch, accompanied by one or two branches of the facial nerve. It divides into numerous branches which supply the parotid gland and the Masseter, and the skin, and anastomose with the external maxillary, masseteric, buccinator, and infra-orbital arteries.

The **anterior auricular branches** are distributed to the lobule and anterior part of the auricula, and to the external acoustic meatus; they anastomose with the posterior auricular artery.

The **zygomatico-orbital artery,** sometimes a branch of the middle temporal artery, runs along the upper border of the zygomatic arch between the two layers of the temporal fascia to the lateral angle of the orbit. It supplies branches to the Orbicularis oculi, and anastomoses with the lacrimal and palpebral branches of the ophthalmic artery.

The **middle temporal artery** arises immediately above the zygomatic arch and, perforating the temporal fascia, gives branches to the Temporalis; it anastomoses with the deep temporal branches of the internal maxillary artery.

The **frontal branch** runs tortuously upwards and forwards towards the frontal tuberosity; it supplies the muscles, skin, and pericranium in this region, and anastomoses with its fellow of the opposite side, and with the supra-orbital and frontal arteries.

The **parietal branch,** larger than the frontal, curves upwards and backwards on the side of the head, lying superficial to the temporal fascia, and anastomoses with its fellow of the opposite side, and with the posterior auricular and occipital arteries.

Applied Anatomy.—As the superficial temporal artery crosses the zygomatic process it lies beneath the skin and fascia, and its pulsations may be readily felt during administration of an anæsthetic, or under circumstances where the radial pulse is not available; it may be easily compressed against the bone in order to check bleeding from the temporal region of the scalp. When a flap is raised from this part of the head in trephining, the incision should be shaped like a horseshoe, with its convexity upwards, so that the flap shall contain the superficial temporal artery, which ensures a free supply of blood.

8. The **internal maxillary artery** (figs. 665, 666), the larger terminal branch of the external carotid artery, arises behind the neck of the mandible and is at first imbedded in the parotid gland; it passes forwards between the ramus of the mandible and the sphenomandibular ligament, and then runs either upon or beneath the Pterygoideus externus, to the pterygopalatine fossa. It may be divided into mandibular, pterygoid, and pterygopalatine portions.

The *first or mandibular portion* passes horizontally forwards, between the neck of the mandible and the sphenomandibular ligament, where it lies parallel to and a little below the auriculotemporal nerve; it crosses the inferior alveolar nerve, and runs along the lower border of the Pterygoideus externus.

CC-0. In Public Domain. Gurukul Kangri Collection, Haridwar

Digitized by Arya Samaj Foundation Chennai and eGangotri

The *second or pterygoid portion* runs obliquely forwards and upwards under the lower of the Temporalis, and superficial to the lower head of the Pterygoideus

FIG. 665.—The right internal maxillary artery.

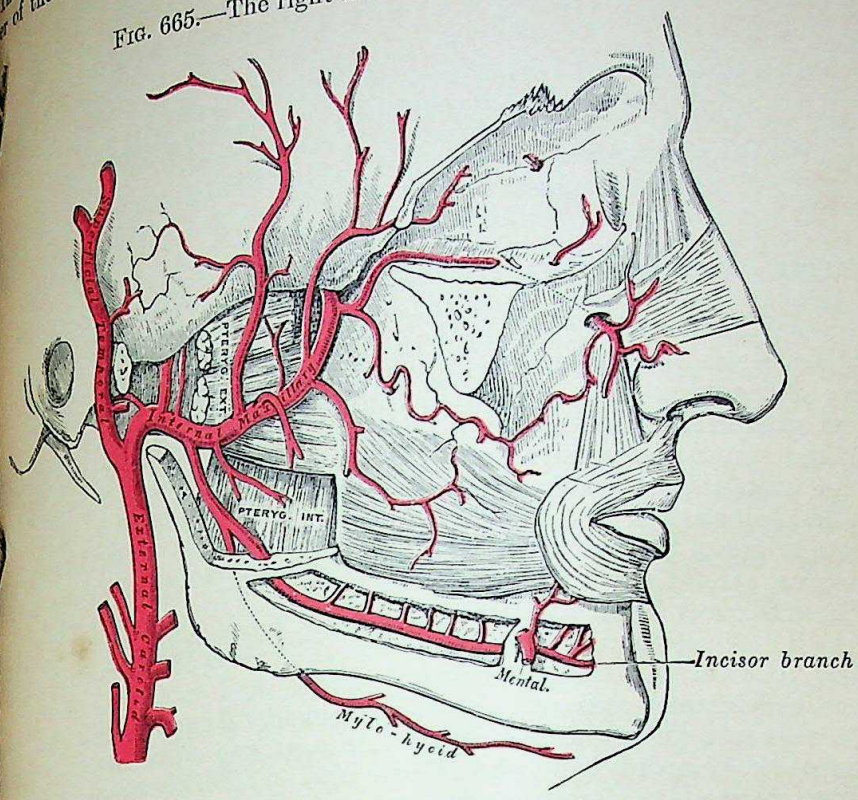

FIG. 666.—A plan of the branches of the internal maxillary artery.

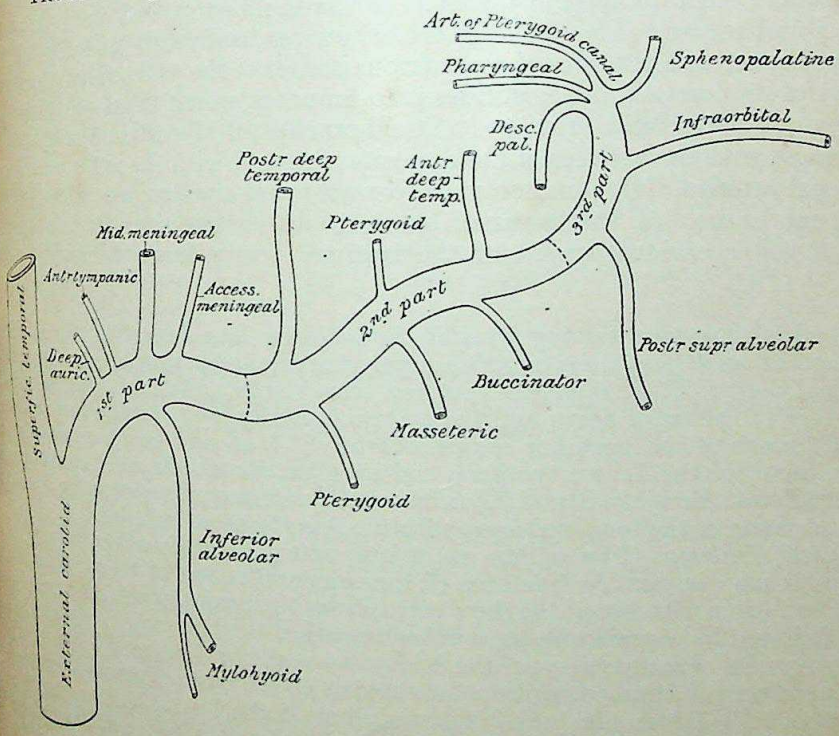

externus; very frequently it lies beneath the latter muscle between it and the branches of the mandibular nerve.

The *third or pterygopalatine portion* passes between the upper and lower heads of the Pterygoideus externus, and through the pterygomaxillary fissure

CC-0. In Public Domain. Gurukul Kangri Collection, Haridwar

Digitized by Arya Samaj Foundation Chennai and eGangotri

into the pterygopalatine fossa, where it lies in front of the sphenopa ganglion.

The branches of the vessel may be divided into three groups (fig corresponding with its three portions.

The Branches of the First or Mandibular Portion of the Internal Maxillary Artery (fig. 666)

Deep auricular.
Anterior tympanic.
Middle meningeal.
Accessory meningeal.
Inferior alveolar.

The **deep auricular artery**, a small branch, often arises in common w anterior tympanic. It ascends in the substance of the parotid gland, be temporomandibular joint, pierces the cartilaginous or bony wall of the e acoustic meatus, and supplies its cuticular lining and the outer surface tympanic membrane; it gives a branch to the mandibular joint.

The **anterior tympanic artery**, a small branch, ascends behind the ma joint, and enters the tympanic cavity through the petrotympanic fiss ramifies upon the tympanic membrane, and forms a vascular circle arou with the stylomastoid branch of the posterior auricular artery; it anast with the artery of the pterygoid canal and with the caroticotympanic branc the internal carotid artery.

The **middle meningeal artery** is the largest of the meningeal arteries. It between the sphenomandibular ligament and the Pterygoideus externus and the two roots of the auriculotemporal nerve, and enters the cranial through the foramen spinosum of the sphenoidal bone; it then runs for and lateralwards for a variable distance in a groove on the anterior part squama of the temporal bone, and divides into an anterior and a posterior b The *anterior branch*, the larger, crosses the great wing of the sphenoidal bone, the groove, or canal, in the sphenoidal angle of the parietal bone, and then into branches which spread out between the dura mater and internal surf the cranium, some passing upwards as far as the vertex, and others backwa the occipital region. The *posterior branch* curves backwards on the squam temporal bone, and, reaching the squamous border of the parietal bone some in front of its mastoid angle, divides into branches which supply the posteri of the dura mater and cranium. The branches of the middle meningeal a anastomose with the arteries of the opposite side, and with the anterior and po meningeal arteries. One branch runs forwards and anastomoses with the rec meningeal branch of the lacrimal artery; an enlargement of this anast explains the occasional origin of the lacrimal artery from the middle men artery.

The middle meningeal artery gives off the following branches within the cranial c 1. Numerous small *ganglionic branches* supply the semilunar ganglion and the roots trigeminal nerve. 2. A *superficial petrosal branch* enters the hiatus of the facial c gives twigs to the facial nerve and the tympanic cavity, and anastomoses with the mastoid branch of the posterior auricular artery. 3. A *superior tympanic artery* the semicanal for the Tensor tympani, and supplies this muscle and the lining me of the canal. 4. *Temporal branches* pass through foramina in the great wing of the sp and anastomose in the temporal fossa with the deep temporal arteries.

Applied Anatomy.—The middle meningeal artery is of considerable surgical im tance, as it may be torn in fractures of the temporal region of the skull, or, inde injuries causing separation of the dura mater from the bone without fracture. The may be followed by considerable hæmorrhage between the bone and dura mater, which duces symptoms of compression of the brain, and requires trephining for its relief (p. As the compression implicates the motor region of the cortex, paralysis on the opp side of the body forms the prominent symptom of the lesion. The anterior bran this artery lies in a groove or a bony canal on the sphenoidal angle of the parietal bo a point 4 cm. behind the zygomatic process of the frontal bone, and 4·5 cm. above zygomatic arch. From this point it passes upwards and slightly backwards to the sag suture, lying about 1·25 to 2 cm. behind the coronal suture. The posterior branch backwards over the squama of the temporal bone. In order to expose the anterior bra of the artery, a point is taken 4 cm. above the zygomatic arch and the same distance be the zygomatic process of the frontal bone. Here the pin of the trephine is to be ap

CC-0. In Public Domain. Gurukul Kangri Collection, Haridwar

Digitized by Arya Samaj Foundation Chennai and eGangotri

horseshoe-shaped flap, measuring 8 cm. in length and transversely, and consisting of all structures of the scalp down to and including the pericranium, is first made, with its just above the zygomatic arch. This flap is reflected and a 2·5 cm. trephine applied. the circle of bone has been removed, the blood-clot is exposed, and gently got rid of, possible the bleeding point must be found and controlled.

The **accessory meningeal branch** may arise from the internal maxillary artery from the middle meningeal artery. It enters the cranial cavity through the foramen ovale, and supplies branches to the semilunar ganglion and the dura mater.

The **inferior alveolar artery** (inferior dental artery) descends with the inferior alveolar nerve to the mandibular foramen on the medial surface of the ramus of the mandible. It runs in the mandibular canal, accompanied by the inferior alveolar nerve, and, opposite the first premolar tooth, divides into two branches, incisor and mental. The *incisor* branch is continued forwards below the incisor teeth as far as the middle line, where it anastomoses with the artery of the opposite side; the inferior alveolar artery and its incisor branch give off a few twigs to the mandible, and a series of branches which correspond in number to the roots of the teeth; these enter the minute apertures at the extremities of the roots, and supply the pulp of the teeth. The *mental* branch escapes at the mental foramen, supplies the chin, and anastomoses with the submental and inferior labial arteries. Near its origin the inferior alveolar artery gives off a *lingual* branch which descends with the lingual nerve and supplies the mucous membrane of the mouth. Before the inferior alveolar artery enters the mandibular foramen, it gives off a *mylohyoid* branch which pierces the sphenomandibular ligament, and descends with the mylohyoid nerve in the mylohyoid groove on the ramus of the mandible; it ramifies on the superficial surface of the Mylohyoideus and anastomoses with the submental branch of the external maxillary artery.

The Branches of the Second or Pterygoid Portion of the Internal Maxillary Artery (fig. 666)

Deep temporal. Pterygoid. Masseteric. Buccinator.

The **deep temporal branches,** an anterior and a posterior, ascend between the Temporalis and the pericranium; they supply the muscle, and anastomose with the middle temporal artery; the anterior communicates with the lacrimal artery by means of small branches which perforate the zygomatic bone and great wing of the sphenoidal bone.

The **pterygoid branches,** irregular in their number and origin, supply the Pterygoidei.

The **masseteric artery** is small and passes with the masseteric nerve behind the tendon of the Temporalis, and through the mandibular notch to the deep surface of the Masseter. In the substance of that muscle it anastomoses with the masseteric branches of the external maxillary artery and with branches of the transverse facial artery.

The **buccinator artery** is small and runs obliquely forwards with the buccinator nerve, between the Pterygoideus internus and the insertion of the Temporalis, to the outer surface of the Buccinator, to which it is distributed, anastomosing with branches of the external maxillary and infra-orbital arteries.

The Branches of the Third or Pterygopalatine Portion of the Internal Maxillary Artery (fig. 666)

Posterior superior alveolar. Pharyngeal.
Infra-orbital. Artery of the pterygoid canal.
Descending palatine. Sphenopalatine.

The **posterior superior alveolar artery** (posterior dental artery) is given off from the internal maxillary artery as that vessel enters the pterygopalatine fossa; it frequently arises in conjunction with the infra-orbital artery. Descending upon the infratemporal surface of the maxilla, it divides into branches, some of which supply the molar and premolar teeth and the lining of the maxillary sinus, while others are continued forwards on the alveolar process to supply the gums.

CC-0. In Public Domain. Gurukul Kangri Collection, Haridwar

Digitized by Arya Samaj Foundation Chennai and eGangotri

The **infra-orbital artery** often arises in conjunction with the posterior alveolar artery. It enters the orbital cavity through the posterior part of the orbital fissure, runs along the infra-orbital groove and canal with the infra-orbital nerve, and emerges with the nerve on the face through the infra-orbital foramen beneath the infra-orbital head of the Quadratus labii superioris. While in the canal, it gives off (*a*) *orbital* branches which assist in supplying the Rectus inferior and Obliquus inferior and the lacrimal sac, and (*b*) *anterior superior alveolar* branches which descend through the anterior alveolar canals to supply the upper incisor and canine teeth and the mucous membrane of the maxillary sinus. On the face the branches ascend to the medial angle of the orbit and the lacrimal sac, anastomose with the angular branch of the external maxillary artery; others run towards the nose, anastomosing with the dorsal nasal branch of the ophthalmic artery, and others descend between the Quadratus labii superioris and the Canine and anastomose with the external maxillary, transverse facial, and buccal arteries.

The remaining branches of the internal maxillary artery arise from that part of the artery which is contained in the pterygopalatine fossa.

The **descending palatine artery** descends through the pterygopalatine ganglion, and with the anterior palatine branch of the sphenopalatine ganglion, and gives two or three *smaller palatine arteries* which are transmitted through the palatine canals to supply the soft palate and palatine tonsil, and to anastomose with the ascending palatine artery. The continuation of the vessel is now the *greater palatine artery*; it emerges on the oral surface of the palate through the greater palatine foramen, runs forwards in a groove near the alveolar border of the hard palate to the incisive canal; its terminal part passes upwards through this canal, and anastomoses with a branch of the sphenopalatine artery. Branches are distributed to the gums, the palatine glands, and the mucous membrane of the roof of the mouth.

Applied Anatomy.—The position of the descending palatine artery on the hard palate should be borne in mind in performing an operation for the closure of a cleft in the hard palate, as it is in danger of being wounded, and may give rise to formidable hæmorrhage; it has even been found necessary to plug the pterygopalatine canal in order to arrest the bleeding.

The **pharyngeal branch** is very small; it runs backwards through the pharyngeal canal with the pharyngeal nerve, and is distributed to the roof of the nose and pharynx, to the sphenoidal air-sinus, and the auditory tube.

The **artery of the pterygoid canal** (Vidian artery), frequently a branch of the descending palatine artery, passes backwards along the pterygoid canal with the corresponding nerve. It is distributed to the upper part of the pharynx and to the auditory tube, and sends into the tympanic cavity a small branch which anastomoses with the other tympanic arteries.

The pharyngeal branch and the artery of the pterygoid canal lie on the medial and lateral aspects respectively of the sphenopalatine ganglion, while the trunk of the internal maxillary artery is in front of it.

The **sphenopalatine artery** is really the terminal part of the internal maxillary artery; it passes through the sphenopalatine foramen into the cavity of the nose at the posterior part of the superior meatus. Here it gives off its *posterior lateral nasal* branches which ramify over the conchæ and meatuses, anastomose with the ethmoidal arteries and the nasal branches of the descending palatine artery, and assist in supplying the frontal, maxillary, ethmoidal, and sphenoidal air-sinuses. Crossing the anterior part of the under surface of the sphenoidal bone, the sphenopalatine artery ends on the nasal septum as the *posterior septal* branches, which anastomose with the ethmoidal arteries and the septal branch of the superior labial artery; one branch descends in a groove on the vomer to the incisive canal and anastomoses with the terminal ascending branch of the greater palatine artery.

The Triangles of the Neck (fig. 667)

The side of the neck presents a somewhat quadrilateral outline, limited above, by the lower border of the body of the mandible, and a line drawn

CC-0. In Public Domain. Gurukul Kangri Collection, Haridwar

Digitized by Arya Samaj Foundation Chennai and eGangotri

from the angle of the mandible to the mastoid process; below, by the upper border of the clavicle; in front, by the middle line of the neck; behind, by the anterior margin of the Trapezius. This space is subdivided by the Sternocleidomastoideus, which passes obliquely across the neck, from the sternum and clavicle below, to the mastoid process and occipital bone above. The space in front of this muscle is called the *anterior triangle* of the neck; that behind it, the *posterior triangle*.

The Anterior Triangle of the Neck (fig. 667)

The anterior triangle of the neck is bounded anteriorly by the middle line of the neck, posteriorly, by the anterior margin of the Sternocleidomastoideus; its base, directed upwards, is formed by the lower border of the body of the mandible, and a line from the angle of the mandible to the mastoid process: its apex is below, at the sternum. This triangle is subdivided into muscular, carotid, submaxillary, and suprahyoid triangles.

Fig. 667.—The triangles of the neck.

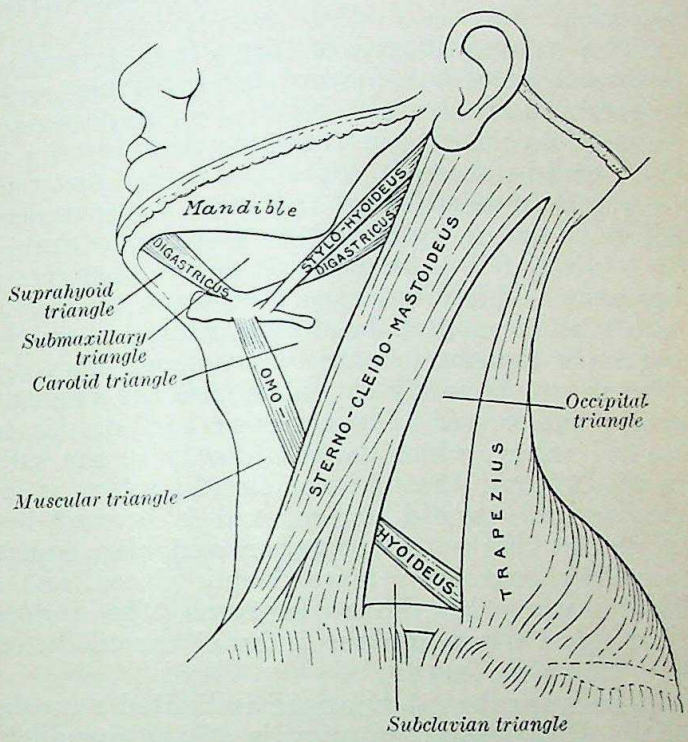

The muscular, or inferior carotid, triangle is bounded, in front, by the median line of the neck from the hyoid bone to the sternum; behind and below, by the anterior margin of the Sternocleidomastoideus; behind and above, by the superior belly of the Omohyoideus. It is covered by the skin, superficial fascia, Platysma, and deep fascia, ramifying in which are some of the branches of the cutaneous cervical and supraclavicular nerves. Beneath these superficial structures are the Sternohyoideus and Sternothyreoideus, which, together with the anterior margin of the Sternocleidomastoideus, conceal the lower part of the carotid sheath and its contents. In front of the sheath are a few descending filaments from the ansa hypoglossi; behind the sheath are the inferior thyreoid artery, the recurrent nerve, and the sympathetic trunk; and on its medial side, the œsophagus, the trachea, the thyreoid gland, and the lower part of the larynx.

The carotid triangle is limited, behind, by the Sternocleidomastoideus; in front and below, by the superior belly of the Omohyoideus; and above, by the Stylohyoideus and the posterior belly of the Digastricus. It is covered by the skin, superficial fascia, Platysma, and deep fascia, ramifying in which are branches of the facial and the cutaneous cervical nerves. Its floor is formed by parts of the Thyreohyoideus, Hyoglossus, and the Constrictores pharyngis medius et inferior. When this space is dissected it is seen to contain the upper part of the common carotid artery, which divides opposite the superior border of the thyreoid cartilage into the external and internal carotid arteries. These vessels are overlapped by the anterior margin of the Sternocleidomastoideus. The external and internal carotid arteries lie side by side, the internal being the more anterior. The following branches of the external carotid artery are also met with: the superior thyreoid, running forwards and downwards; the lingual, directly forwards; the external maxillary,

CC-0. In Public Domain. Gurukul Kangri Collection, Haridwar

Digitized by Arya Samaj Foundation Chennai and eGangotri

forwards and upwards; the occipital, backwards; and the ascending pha-geal, directly upwards on the medial side of the internal carotid. veins met with are: the internal jugular, which lies on the lateral of the common and internal carotid arteries; and veins corresponding the above-mentioned branches of the external carotid artery—viz. superior thyreoid, the lingual, common facial, ascending pharyngeal, sometimes the occipital—all of which end in the internal jugular. The hypoglossal nerve crosses both the internal and external carotid, curving round the origin of the occipital artery; in this position it gives descending ramus which runs down in front of the carotid sheath. In the sheath, between the common carotid artery and the internal jugular and behind both, is the vagus nerve; behind the sheath, the sympathetic trunk. The accessory nerve appears at the lower border of the posterior belly of the Digastricus, and descends for a short distance on the lateral of the vessels before it pierces the Sternocleidomastoideus. On the side of the external carotid artery, below the hyoid bone, is the internal branch of the superior laryngeal nerve; and, still more inferiorly, external branch of the same nerve. The upper portion of the and lower portion of the pharynx are also found in the anterior part triangle.

The **submaxillary, or digastric, triangle** is bounded, above, by lower border of the body of the mandible, and a line drawn from its to the mastoid process; below, by the posterior belly of the Digastricus, the Stylohyoideus; in front, by the anterior belly of the Digastricus. is covered by the skin, superficial fascia, Platysma, and deep fascia, rami in which are branches of the facial and cutaneous cervical nerves. Its is formed by the Mylohyoideus, Hyoglossus, and Constrictor pharyngis sup. It is divided into an anterior and a posterior part by the stylomandibular ligament. The anterior part contains the submaxillary gland, superficial which is the anterior facial vein, while imbedded in a groove on the posterior border of the gland is the external maxillary artery; beneath the gland, the surface of the Mylohyoideus, are the submental artery and the mylohyoid artery and nerve. The posterior part of this triangle contains the external carotid artery, which ascends deeply in the substance of the parotid gland; in this triangle the external carotid artery is in front of, and superficial to the internal carotid artery, and is crossed by the facial nerve; it gives off in its course the posterior auricular, superficial temporal, and internal maxillary branches: more deeply placed, and separated from the external carotid artery by the Styloglossus, the Stylopharyngeus, and the glossopharyngeal nerve, are the internal carotid artery, the internal jugular vein and the vagus nerve.

The **suprahyoid triangle** is limited on either side by the anterior belly of the Digastricus; its apex is at the mandible; its base is formed by the body of the hyoid bone, and its floor by the Mylohyoidei. It contains one two lymph-glands and some small veins; the latter unite to form the anterior jugular vein.

The Posterior Triangle of the Neck (fig. 667)

The **posterior triangle** of the neck is bounded, in front, by the Sternocleidomastoideus; behind, by the anterior margin of the Trapezius; its is formed by the middle one-third of the clavicle; its apex is at the occipital bone between the attachments of the Sternocleidomastoideus and the Trapezius. The triangle is crossed, about 2·5 cm. above the clavicle, by the inferior belly of the Omohyoideus, which divides the triangle into an occipital and a subclavian triangle.

The **occipital triangle**, the upper and larger division of the posterior triangle, is bounded in front by the Sternocleidomastoideus; behind, by the Trapezius; below, by the Omohyoideus. Its floor is formed from above downwards by the Splenius capitis, Levator scapulæ, and the Scaleni medius et posterior; sometimes a small part of the Semispinalis capitis is seen at the apex of the triangle. It is covered by the skin, the superficial and deep fascia

CC-0. In Public Domain. Gurukul Kangri Collection, Haridwar

Digitized by Arya Samaj Foundation Chennai and eGangotri

by the Platysma below. The accessory nerve pierces the Sternocleido-
oideus and is directed obliquely across the space to the under surface of
Trapezius; while the cutaneous and muscular branches of the cervical
s appear at the posterior border of the Sternocleidomastoideus; below,
upraclavicular nerves and the transverse cervical vessels and the upper
of the brachial plexus cross the space. A chain of lymph-glands is also
and running along the posterior border of the Sternocleidomastoideus, from
mastoid process to the root of the neck.

The **subclavian triangle**, the lower and smaller division of the posterior
angle, is bounded, above, by the inferior belly of the Omohyoideus; below,
the clavicle; its base is formed by the lower part of the posterior border
the Sternocleidomastoideus. Its floor consists of the first rib and the first
tation of the Serratus anterior. The size of this triangle varies with the
ent of attachment of the clavicular portions of the Sternocleidomastoideus
Trapezius, and also with the level at which the inferior belly of the
hyoideus crosses the neck; this level is lowered when the arm is raised,
raised when the arm is depressed. The triangle is covered by the skin,
superficial and deep fasciæ, and the Platysma, and crossed by the supra-
vicular nerves. Just above the level of the clavicle, the third portion of
subclavian artery curves lateralwards and downwards from the lateral
in of the Scalenus anterior, across the first rib, to the axilla. The sub-
vian vein lies behind the clavicle, and is not usually seen in this space;
in some cases it rises as high as the artery, and has even been seen to
mpany that vessel behind the Scalenus anterior. The brachial plexus of
es lies partly above and partly behind the artery, and in close contact
h it. Passing transversely behind the clavicle are the transverse scapular
sels; and running in the same direction, but at a slightly higher level are
transverse cervical artery and vein. The external jugular vein descends
hind the posterior border of the Sternocleidomastoideus, to terminate in the
clavian vein; it receives the transverse cervical and transverse scapular
s, which form a plexus in front of the third part of the subclavian artery,
occasionally it is joined by a small vein which crosses the clavicle from the
halic vein. The small nerve to the Subclavius also crosses this triangle
ort its middle, and some lymph-glands are contained within the space.

The Internal Carotid Artery

The **internal carotid artery** (fig. 668) supplies the greater part of the
rebral hemisphere, the eye and its appendages, and sends branches to the
rehead and nose. It begins at the bifurcation of the common carotid artery,
ends to the base of the skull, and enters the cranial cavity through the
rotid canal of the temporal bone. It then runs forward through the cavernous
s, lying in the carotid sulcus on the side of the body of the sphenoidal bone,
d ends below the anterior perforated substance of the brain by dividing into
e anterior and the middle cerebral arteries.

The internal carotid artery may be divided into four portions: cervical,
trous, cavernous, and cerebral.

The cervical portion.—This portion of the internal carotid artery begins at the
rcation of the common carotid artery, at the upper border of the thyreoid cartilage,
d ascends in front of the transverse processes of the upper three cervical vertebræ
the lower end of the carotid canal in the petrous portion of the temporal bone.
is comparatively superficial at its commencement, where it is contained in the
rotid triangle, and lies behind and lateral to the external carotid artery, overlapped
the Sternocleidomastoideus, and covered by the deep fascia, Platysma, and
n; it then passes beneath the parotid gland, being crossed by the hypoglossal
rve, the Digastricus and Stylohyoideus, and the occipital and posterior auricular
teries. Higher up, it is separated from the external carotid artery by the
yloglossus and Stylopharyngeus, the tip of the styloid process and the stylo-
oid ligament, the glossopharyngeal nerve and the pharyngeal branch of the
gus. It is in relation, *behind*, with the Longus capitis, the superior cervical
ngion of the sympathetic trunk, and the superior laryngeal nerve; *laterally*,

CC-0. In Public Domain. Gurukul Kangri Collection, Haridwar

Digitized by Arya Samaj Foundation Chennai and eGangotri

with the internal jugular vein and vagus nerve, the nerve lying on posterior to the artery; *medially*, with the pharynx, superior laryngeal and ascending pharyngeal artery. At the base of the skull the glossopharyngeal, vagus, accessory, and hypoglossal nerves lie between the internal carotid and the internal jugular vein.

FIG. 668.—The right internal carotid and vertebral arteries.

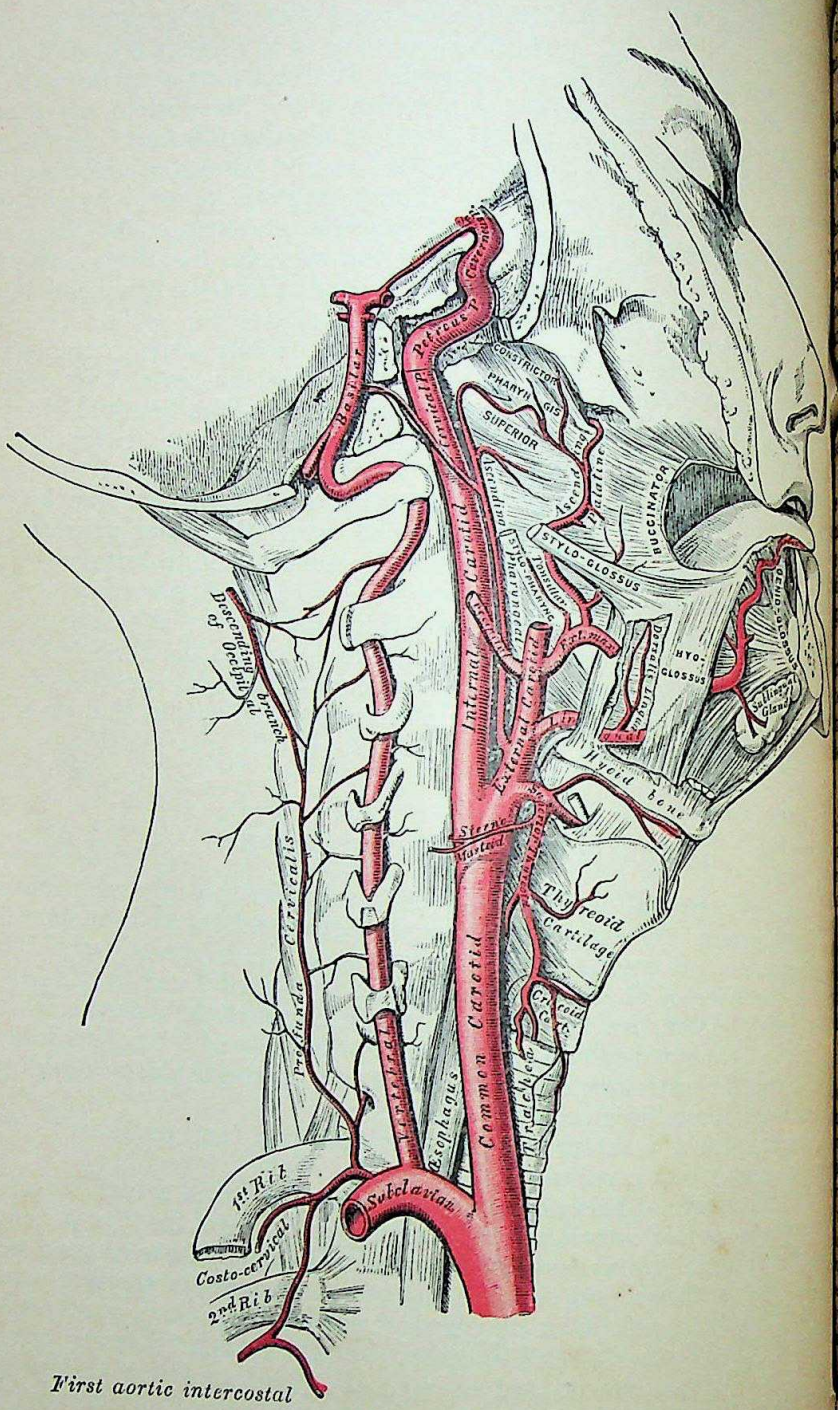

The **petrous portion.**—When the internal carotid artery enters the carotid canal in the petrous portion of the temporal bone, it first ascends, then curves forwards and medialwards, and again ascends as it leaves the canal to enter the cranial cavity between the lingula and petrosal process of the sphenoidal bone. The artery lies at first in front of the cochlea and tympanic cavity; it is separated from

CC-0. In Public Domain. Gurukul Kangri Collection, Haridwar

Digitized by Arya Samaj Foundation Chennai and eGangotri

latter cavity and from the auditory tube by a thin, bony lamella, which is
deform in the young subject, and often partly absorbed in old age. Farther
ards it is separated from the semilunar ganglion by a thin plate of bone, which
the floor of the trigeminal impression and the roof of the horizontal portion of
rotid canal. Frequently this bony plate is more or less deficient, and then
anglion is separated from the artery by fibrous membrane. The artery is
ounded by a number of small veins and by the carotid plexus of nerves which
eived from the ascending branch of the superior cervical ganglion of the
pathetic trunk.

The cavernous portion of the internal carotid artery is situated in the cavernous
s, but is covered by the lining membrane of the sinus. It at first ascends
ards the posterior clinoid
ess, then passes forwards
the side of the body of the
noidal bone, and again
ves upwards on the medial
of the anterior clinoid
ess, and perforates the dura
r forming the roof of the
occasionally the anterior
middle clinoid processes
a bony ring round the
. The cavernous portion
the artery is surrounded by
avernous plexus of the
pathetic, and lateral to it
the oculomotor, trochlear,
thalmic and abducent nerves
169).

FIG. 669.—An oblique section through the left cavernous sinus.

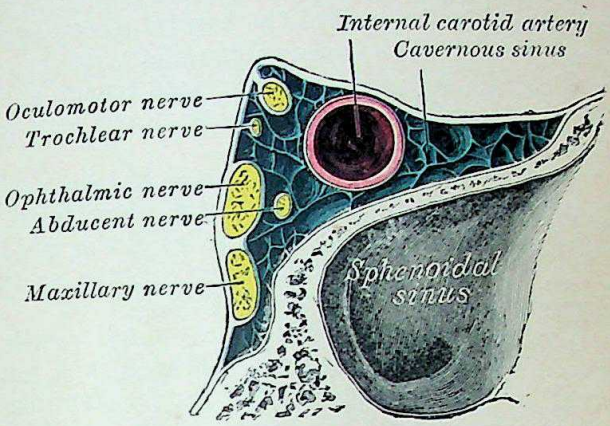

The cerebral portion.—After
ssing the dura mater on the medial side of the anterior clinoid process, the
nal carotid artery passes between the optic and oculomotor nerves to the
ior perforated substance at the medial end of the lateral cerebral fissure,
re it divides into the anterior and middle cerebral arteries.

Peculiarities.—The length of the internal carotid artery varies with the length of the
, and with the point of bifurcation of the common carotid. It arises occasionally
the arch of the aorta, and then has been found on the medial side of the external
id, as far as the larynx, where it crossed behind the latter vessel to reach its usual
ion. The course of the artery, instead of being straight, may be very tortuous. A
instances are recorded in which it was absent; in one of these the common carotid
passed up the neck, and gave off the branches normally arising from the external
id; the cranial portion of the internal carotid artery was replaced by two branches
e internal maxillary artery, which entered the skull through the foramen rotundum
foramen ovale, and joined to form a single vessel.

Applied Anatomy.—The cervical part of the internal carotid artery is very rarely
ded. Although the internal carotid lies about 2 cm. behind and lateral to the
, instances have occurred in which the artery has been wounded during the opera-
of excision of the tonsil, and fatal hæmorrhage has supervened. The incision for
ure of the cervical portion of the internal carotid should be made along the anterior
er of the Sternocleidomastoideus, from the angle of the mandible to the upper border
e thyreoid cartilage. The superficial structures being divided, and the Sternocleido-
deus defined and drawn backwards, the areolar tissue must be carefully separated,
the posterior belly of the Digastricus and the hypoglossal nerve sought as guides to
vessel. The external carotid should be drawn medialwards and the Digastricus
wards, and the aneurysm needle passed from the lateral to the medial side of the
id.

Obstruction of the internal carotid by embolism or thrombosis may give rise to
ms of cerebral anæmia and softening if the collateral circulation is ill-developed.
patient suffers from giddiness, with failure of the mental powers; and convulsions,
, or hemiplegia on the opposite side of the body, may be observed.
ligature of the internal carotid artery is not so effective as ligature of the common
id artery in diminishing the blood supply to the brain, because blood is conveyed to
brain through the anastomoses of the branches of the external carotid artery with the
ches of the petrous and cavernous parts of the internal carotid artery—especially
the ophthalmic artery.

CC-0. In Public Domain. Gurukul Kangri Collection, Haridwar

Digitized by Arya Samaj Foundation Chennai and eGangotri

Branches.—No branches arise from the cervical portion of the carotid artery. Those from the other portions are :

From the petrous portion	1. Caroticotympanic. 2. Pterygoid.
From the cavernous portion	3. Cavernous. 4. Hypophysial. 5. Semilunar. 6. Anterior meningeal. 7. Ophthalmic.
From the cerebral portion	8. Anterior cerebral. 9. Middle cerebral. 10. Posterior communicating. 11. Anterior chorioidal.

1. The **caroticotympanic branch** is small ; it enters the tympanic cavity by a foramen in the wall of the carotid canal, and anastomoses with the anterior tympanic branch of the internal maxillary artery, and with the stylomastoid artery.

2. A small, inconstant **pterygoid branch** passes into the pterygoid canal with the nerve of that canal, and anastomoses with a branch of the descending palatine artery.

3. The **cavernous branches** are numerous small vessels which supply the semilunar ganglion, and the walls of the cavernous and inferior petrosal sinuses. Some of them anastomose with branches of the middle meningeal artery.

4. The **hypophysial branches** are one or two minute vessels which supply the hypophysis.

5. The **semilunar branches** are small vessels supplying the semilunar ganglion.

6. The **anterior meningeal branch** is a minute branch which passes over the small wing of the sphenoid to supply the dura mater of the anterior cranial fossa; it anastomoses with the meningeal branch from the posterior ethmoidal artery.

7. The **ophthalmic artery** (fig. 670) arises from the internal carotid artery as that vessel emerges from the cavernous sinus, on the medial side of the anterior clinoid process ; it enters the orbital cavity through the optic foramen, below and lateral to the optic nerve. In the orbital cavity it runs for a short distance medial to the optic nerve and medial to the oculomotor, trochlear and abducent nerves, the ciliary ganglion, and the Rectus lateralis. It next crosses obliquely above the optic nerve and beneath the Rectus superior to reach the medial wall of the orbit. It then runs forwards between the Obliquus superior and the Rectus medialis, and at the medial end of the upper eyelid, divides into two branches, named the *frontal* and *dorsal nasal*. As the artery crosses the optic nerve it is accompanied by the nasociliary nerve, and is separated from the frontal nerve by the Rectus superior and Levator palpebræ superioris ; the terminal part of the artery is accompanied by the infratrochlear nerve. In about 15 per cent. of subjects the ophthalmic artery crosses below the optic nerve.

The branches of the ophthalmic artery are :—

Central artery of the retina.	Long posterior ciliary.	Anterior meningeal.
Lacrimal.	Anterior ciliary.	Medial palpebral.
Muscular.	Supra-orbital.	Frontal.
Short posterior ciliary.	Posterior ethmoidal.	Dorsal nasal.
	Anterior ethmoidal.	

The **central artery of the retina**, the first and one of the smallest branches of the ophthalmic artery, arises from that vessel whilst it lies beneath the optic nerve. It runs for a short distance within the dural sheath of the optic nerve, and about 1·25 cm. behind the eyeball it pierces the inferomedial surface of the nerve, and runs forward in the substance of the nerve to the retina. Its mode of distribution is described with the anatomy of the eye.

The **lacrimal artery** arises from the ophthalmic artery close to the optic foramen, is one of its largest branches ; sometimes it is given off before the ophthalmic artery enters the orbit ; occasionally its place is taken by a branch of the middle meningeal artery (p. 618). It accompanies the lacrimal nerve along the upper border of the Rectus lateralis and supplies the lacrimal gland. Its terminal branches, escaping from the gland, are distributed to the eyelids and conjunctiva : of those supplying the eyelids, two are considerable size and are named the **lateral palpebral arteries** ; they run medialwards in the upper and lower lids respectively and anastomose with the medial palpebral arteries. The lacrimal artery gives off one or two **zygomatic branches**, one of which passes through

CC-0. In Public Domain. Gurukul Kangri Collection, Haridwar

Digitized by Arya Samaj Foundation Chennai and eGangotri

zygomaticotemporal foramen to the temporal fossa, and anastomoses with the deep temporal arteries; another appears on the cheek through the zygomaticofacial foramen and anastomoses with the transverse facial artery. A **recurrent meningeal branch** passes forwards through the lateral part of the superior orbital fissure, and anastomoses with branch of the middle meningeal artery.

The muscular branches frequently spring from a common trunk. They consist of a superior and an inferior group, and most of them accompany the branches of the oculomotor nerve. The superior group supplies the Levator palpebræ superioris, Recti superior and lateralis, and Obliquus superior. The inferior group, more constantly present, is distributed to the Recti medialis et inferior, and the Obliquus inferior. This group gives branches of the anterior ciliary arteries. Additional muscular branches are derived from the lacrimal and supra-orbital arteries, or from the trunk of the ophthalmic artery.

The **ciliary arteries** are divisible into three groups, long and short posterior, and anterior. The **long posterior ciliary arteries**, two in number, pierce the posterior part of the sclera at a short distance from the entrance of the optic nerve, and run forwards, along either side of the eyeball, between the sclera and the choroid, to the ciliary body, where each divides into a superior and an inferior branch; these form, together with the anterior ciliary arteries, an arterial circle, the **circulus arteriosus major**, around the circumference of the iris; from the circulus arteriosus major numerous converging branches ramify in the substance of the iris to its pupillary margin, where they form a second arterial circle, the **circulus arteriosus iridis**. The **short posterior ciliary arteries**, about seven in number, pass forwards around the optic nerve to the posterior pole of the eyeball, and, after giving into from fifteen to twenty branches, pierce the sclera around the entrance of the optic nerve, and supply the vascular coat and the ciliary processes. The **anterior ciliary arteries** are derived from the muscular branches of the ophthalmic artery; they run to the front of the eyeball in company with the tendons of the Recti, form a vascular zone beneath the conjunctiva, and then pierce the sclera a short distance from the sclerocorneal junction and join in the circulus arteriosus iridis.

Fig. 670.—The ophthalmic artery and its branches.

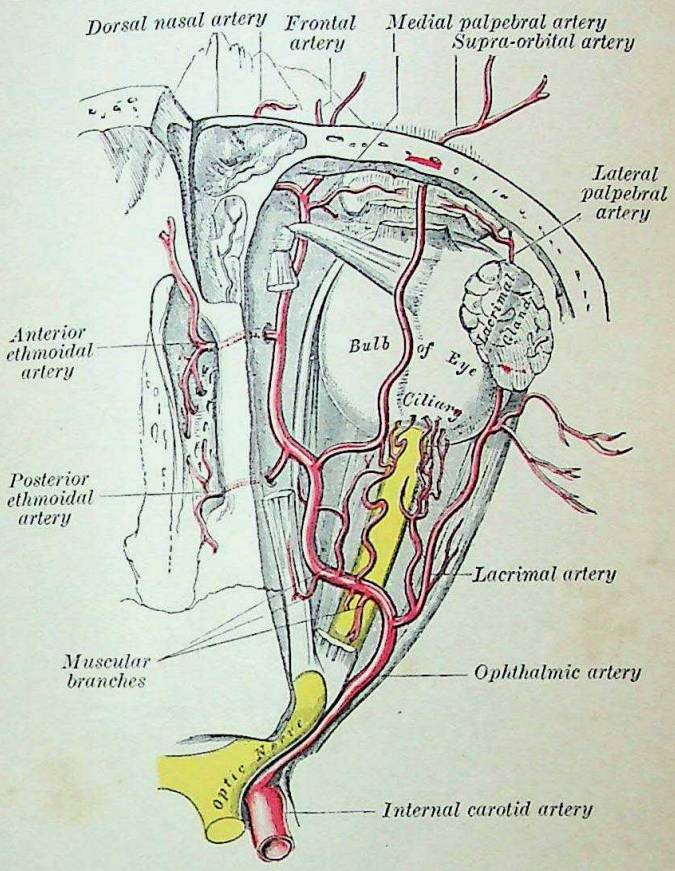

The **supra-orbital artery** leaves the ophthalmic artery as that vessel crosses the optic nerve. It ascends on the medial borders of the Rectus superior and Levator palpebræ superioris, and meeting the supra-orbital nerve accompanies it between the periosteum and the Levator palpebræ superioris to the supra-orbital foramen; passing through this foramen it divides into a superficial and a deep branch, which supply the skin, muscles, and pericranium of the forehead, anastomosing with the frontal artery, the frontal branch of the superficial temporal artery, and the artery of the opposite side. In the orbit it supplies twigs to the Rectus superior and the Levator palpebræ, and sends a branch across the pulley of the Obliquus superior, to the parts at the medial palpebral commissure. At the supra-orbital foramen it frequently sends a branch to the diploë.

The **posterior ethmoidal artery** runs through the posterior ethmoidal canal, supplies the posterior ethmoidal air-sinuses, and, entering the cranium, gives off a meningeal branch to the dura mater, and nasal branches which descend into the nasal cavity through the lamina cribrosa of the ethmoidal bone, to anastomose with branches of the sphenopalatine artery.

The **anterior ethmoidal artery** accompanies the anterior ethmoidal nerve through the anterior ethmoidal canal, supplies the anterior and middle ethmoidal and frontal air-sinuses, and, entering the cranium, gives off a meningeal branch to the dura mater, and nasal branches; the latter descend into the nasal cavity with the anterior ethmoidal nerve and, running along the groove on the inner surface of the nasal bone, supply twigs to the

CC-0. In Public Domain. Gurukul Kangri Collection, Haridwar

Digitized by Arya Samaj Foundation Chennai and eGangotri

lateral wall and septum of the nose, and a terminal branch which appears on the of the nose between the nasal bone and the lateral nasal cartilage.

The **anterior meningeal artery** is a small branch which passes to the middle fossa through the superior orbital fissure and anastomoses with the middle and meningeal arteries.

The **medial palpebral arteries**, two in number, superior and inferior, arise ophthalmic artery below the pulley of the Obliquus superior. They descend lacrimal sac, and enter the eyelids where each divides into two branches lateralwards along the edges of the tarsal plates, thus forming two arches (a an inferior) in each eyelid. The superior palpebral artery anastomoses with orbital artery, and, at the lateral part of the eyelid, with the zygomatico-orbital

FIG. 671.—The arteries at the base of the brain.

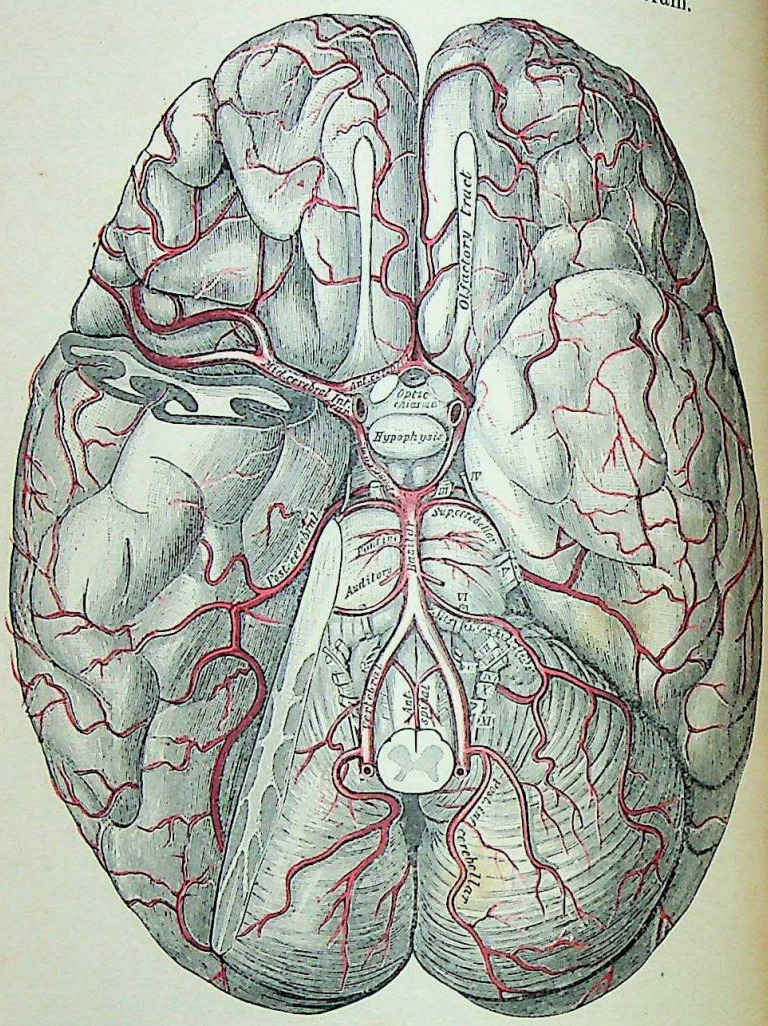

of the temporal artery, and with the upper of the two lateral palpebral branches lacrimal artery. The inferior palpebral artery anastomoses at the lateral part eyelid with the lower of the two lateral palpebral branches of the lacrimal artery the transverse facial artery, and at the medial part of the eyelid with a twig fr angular artery; from this last anastomosis a branch passes to the nasolacrimal ramifying in its mucous membrane, as far as the inferior meatus of the nasal cavity.

The **frontal artery**, one of the terminal branches of the ophthalmic artery, lea orbit at its medial angle, with the supratrochlear nerve, and, ascending on the fore supplies the skin, muscles, and pericranium, anastomosing with the supra-orbital and with the artery of the opposite side.

The **dorsal nasal artery**, the other terminal branch of the ophthalmic artery, from the orbit between the trochlea of the Obliquus superior and the medial p ligament, and, after giving a twig to the upper part of the lacrimal sac, divides branches, one of which crosses the root of the nose, and anastomoses with the artery; the other runs along the dorsum of the nose, supplies its outer surface, and moses with the artery of the opposite side, and with the lateral nasal branch of the maxillary artery.

CC-0. In Public Domain. Gurukul Kangri Collection, Haridwar

Digitized by Arya Samaj Foundation Chennai and eGangotri

The **anterior cerebral artery** (figs. 671, 672, 673) arises from the internal carotid artery, at the medial end of the lateral cerebral fissure. It passes forwards and medialwards across the anterior perforated substance, above the optic nerve, to the commencement of the longitudinal fissure. Here it comes into close relation-

FIG. 672.—The lateral surface of the cerebral hemisphere, showing the areas supplied by the cerebral arteries. In this and the next figure the areas supplied by the anterior cerebral artery are coloured *blue*; those by the middle cerebral artery, *pink*; and those by the posterior cerebral artery, *yellow*.

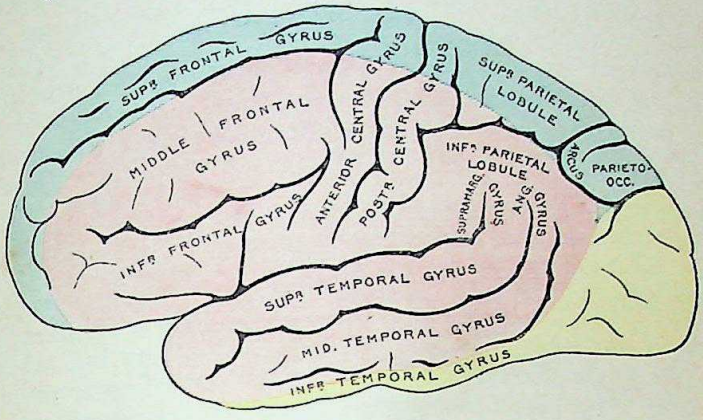

with the opposite side and is joined to it by a short transverse (sometimes duplicated) named the anterior communicating artery. At this point, the two anterior cerebral arteries side by side in the longitudinal cerebral fissure, curving round the genu of the corpus callosum and running backwards along the upper surface of this structure to its posterior extremity, where they end by anastomosing with the posterior cerebral arteries.

The *anterior communicating artery* has an average length of about 4 mm. It connects the two anterior cerebral arteries across the commencement of the longitudinal fissure; in about 7 per cent. of subjects it is double. It gives off a few anteromedial ganglionic branches.

In its course the anterior cerebral artery gives off the following branches:

Anteromedial ganglionic.	Anterior.	Posterior.
Inferior.	Middle.	

The *anteromedial ganglionic branches* are a group of small arteries which arise near the commencement of the anterior cerebral artery; they pierce the anterior perforated substance and lamina terminalis, and supply the rostrum of the corpus callosum, the septum pellucidum, and the head of the caudate nucleus. The *inferior branches*, two or three in number, are distributed to the orbital surface of the frontal lobe, where they supply the olfactory lobe, gyrus rectus, and medial orbital gyrus. The *anterior branches* supply a part of the superior frontal gyrus, and send twigs over the superomedial border of the cerebral hemisphere to the superior and middle frontal gyri and upper part of the anterior central gyrus. The *middle branches* supply the corpus callosum, the cingulate gyrus, the medial surface of the superior frontal gyrus, and the upper part of the anterior central gyrus. The *posterior branches* supply the præcuneus and adjacent lateral surface of the hemisphere.

673.—The medial surface of the cerebral hemisphere, showing the areas supplied by the cerebral arteries (see description of fig. 672).

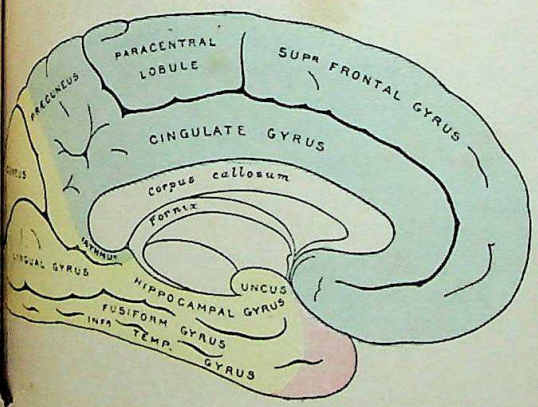

The **middle cerebral artery** (figs. 671, 672), the largest branch of the internal carotid artery, runs at first lateralwards in the lateral cerebral fissure and then forwards and upwards on the surface of the insula, where it divides into branches

CC-0. In Public Domain. Gurukul Kangri Collection, Haridwar

Digitized by Arya Samaj Foundation Chennai and eGangotri

which are distributed to the insula and to the lateral surface of the hemisphere.

The branches of this vessel are the

Anterolateral ganglionic.	Ascending parietal.
Inferior lateral frontal.	Parietotemporal.
Ascending frontal.	Temporal.

The *anterolateral ganglionic branches* comprise a group of small arteries arise from the commencement of the middle cerebral artery and enter the substance of the brain through the anterior perforated substance.* They are arranged sets: one, the *medial striate*, ascends through the inner segments of the nucleus, and supplies it, the caudate nucleus, and the internal capsule; the the *lateral striate*, ascends through the outer segment of the lentiform nucleus supplies the caudate nucleus. One artery of this group is larger than the of special importance, as being the artery in the brain most frequently it has been termed by Charcot the '*artery of cerebral hæmorrhage*.' It between the lentiform nucleus and the external capsule, and ends in the nucleus. The *inferior lateral frontal* the inferior frontal gyrus and the part of the orbital surface of the lobe. The *ascending frontal* supplies anterior central gyrus. The *parietal* is distributed to the posterior gyrus and the lower part of the parietal lobule. The *parietotemporal* the supramarginal and angular gyri, posterior parts of the superior and temporal gyri. The *temporal branches* or three in number, are distributed lateral surface of the temporal lobe.

Fig. 674.—A diagram of the arteries at the base of the brain.

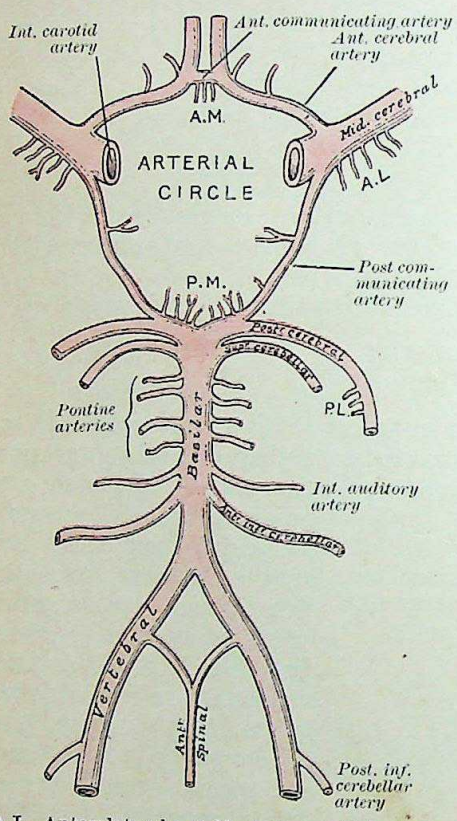

A.L. Anterolateral; A.M. Anteromedial; P.L. Posterolateral; P.M. Posteromedial ganglionic branches.

10. The **posterior communicating** (figs. 671, 674) runs backwards from internal carotid above the oculomotor and anastomoses with the posterior cerebral a branch of the basilar artery. usually a small vessel, but is occasionally large that the posterior cerebral may be sidered as arising from the internal rather than from the basilar. frequently larger on one side than other. From its posterior half arise off several small *posteromedial* branches, which, with similar vessels the posterior cerebral artery, pierce posterior perforated substance and the medial surfaces of the thalamus the walls of the third ventricle.

11. The **anterior chorioidal artery**, but constant branch, arises from the carotid, near the posterior communicating artery. Passing backwards and wards between the uncus and the cerebral peduncle, it enters the inferior of the lateral ventricle through the chorioidal fissure and ends in the plexus. It is distributed to the hippocampus, fimbria, tela chorioidea of the ventricle, and chorioid plexus.

The arterial circle of Willis.—A considerable part of the brain is supplied by the two vertebral arteries (p. 636), and a remarkable anastomosis, the *arterial circle of Willis*, exists between these vessels and the two internal carotid arteries. This circle is situated in the cisterna interpeduncularis the base of the brain, and encloses the optic chiasma and the structures interpeduncular fossa (p. 842). It is formed as follows: in front, the

* Consult an article on 'The basal arteries of the forebrain' by Joseph L. Shellshear, *of Anatomy*, vol. lv. 1920.

CC-0. In Public Domain. Gurukul Kangri Collection, Haridwar

Digitized by Arya Samaj Foundation Chennai and eGangotri

ior cerebral arteries are joined to one another by the anterior communicating artery; behind, the basilar artery (formed by the union of the bral arteries) divides into the two posterior cerebral arteries, each of is joined to the internal carotid artery of the same side by the posterior unicating artery (fig. 674).

THE ARTERIES OF THE BRAIN

The mode of distribution of the vessels of the brain has an important bearing upon considerable number of the pathological lesions which may occur in this part of the

us system.

The arteries which supply the brain give origin to two systems of vessels. One of these ned the **ganglionic system**, and its vessels supply the thalami and corpora striata; ther is the **cortical system**, and its vessels ramify in the pia mater and supply the r and subjacent brain-substance. These two systems are independent of one another do not communicate at any point of their peripheral distribution, and there is between ts supplied by them a borderland of diminished nutritive activity where, it is said, ion of the brain is especially liable to occur.

The **ganglionic system**.—All the vessels of this system are given off from the circle of (p. 630), or from the vessels close to it. They form six principal groups: (I) eromedial group, derived from the anterior cerebral and anterior communicating ies; (II) a **posteromedial group**, from the posterior cerebral and posterior communi- e arteries; (III and IV) right and left **anterolateral groups**, from the middle cerebral ies; and (V and VI) right and left **posterolateral groups**, from the posterior cerebral ies after they have wound round the cerebral peduncles. The vessels of the ganglionic m are larger than those of the cortical system, and are known as end arteries or al arteries—that is to say, vessels which from their origin to their termination r supply nor receive any anastomotic branch, so that, through any one vessel only ted area of the thalamus or corpus striatum can be injected.

The **cortical system**.—The vessels of this system are the terminal branches of the r, middle, and posterior cerebral arteries. They divide in the substance of the ter, give off branches which penetrate the brain-cortex perpendicularly, and are le into two classes, long and short. The **long or medullary arteries** pass through ey substance and penetrate the subjacent white substance to the depth of 3 or 4 cm., t intercommunicating otherwise than by very fine capillaries, and thus constitute ny independent small systems. The **short vessels** are confined to the cortex, where form with the long vessels a compact network in the middle zone of the grey sub- e, the outer and inner zones being sparingly supplied with blood. The vessels of ortical system are not so strictly 'terminal' as those of the ganglionic system, but approach this type very closely, so that injection of one area from the vessel of another though possible, is difficult, and only effected through vessels of small calibre; ction of one of these vessels may therefore produce softening in a limited area of the n cortex.

THE ARTERIES OF THE UPPER EXTREMITY

The artery which supplies the upper extremity runs as a single trunk as as the elbow; but is differently named, according to the regions verses. From its origin to the outer border of the first rib it is termed *clavian*; from the outer border of the first rib to the lower border of the on of the Teres major, it is named *axillary*; and from the lower border of Teres major to a point opposite the neck of the radius it is termed *brachial*.

The Subclavian Arteries (fig. 675)

The right **subclavian artery** arises from the innominate artery, the left m the arch of the aorta. The vessels, therefore, in the first parts of their ses, differ in length, direction, and relation with neighbouring structures. To facilitate description, each subclavian artery is divided into three parts; t extends from the origin of the vessel to the medial border of the us anterior, the second lies behind this muscle, and the third runs from lateral margin of the muscle to the outer border of the first rib, where it

CC-0. In Public Domain. Gurukul Kangri Collection, Haridwar

Digitized by Arya Samaj Foundation Chennai and eGangotri

becomes the axillary artery. The first portions of the two vessels dif one another in their origin, course and relations, and therefore require descriptions. The relations of the second and third parts are alm on the two sides of the neck.

The First Part of the Right Subclavian Artery (figs. 668,

The **first part** of the **right subclavian artery** arises from the inn artery, behind the upper part of the right sternoclavicular articulat passes upwards and lateralwards to the medial margin of the Scalenus It ascends, on an average, about 2 cm. above the clavicle, but the reaches varies considerably in different cases.

Relations.—*In front* of the artery are the skin, superficial fascia, Pl anterior supraclavicular nerves, deep fascia, the clavicular origin of the cleidomastoideus, the Sternohyoideus, and Sternothyreoideus. It is cr the internal jugular and vertebral veins, by the vagus nerve and the cardiac of the vagus and sympathetic; the subclavian loop of the sympathet encircles the vessel. The anterior jugular vein is directed lateralwards in the artery, but is separated from it by the Sternohyoideus and Sternothy *Below and behind* the artery are the pleura and the apex of the lung; beh artery are the sympathetic trunk, the Longus colli and the first thoracic ve The right recurrent nerve winds round the lower and posterior part of the

The First Part of the Left Subclavian Artery (figs. 655, 65

The **first part** of the **left subclavian artery** arises from the arch aorta, behind the left common carotid, and at the level of the upper bo the fourth thoracic vertebra; it ascends to the root of the neck an arches lateralwards to the medial border of the Scalenus anterior.

Relations.—It is in relation, *in front*, with the left vagus, cardiac, and nerves, the left common carotid artery, the left internal jugular and vertebr and the beginning of the left innominate vein, and is covered by the Sterno deus, Sternohyoideus, and Sternocleidomastoideus; *behind*, it is in relatio the œsophagus, thoracic duct, left recurrent nerve, inferior cervical gang the sympathetic trunk, and Longus colli; higher up, however, the œsopha thoracic duct lie to its right side, the latter ultimately arching over the v join the angle of union between the subclavian and internal jugular veins. to it are the œsophagus, trachea, thoracic duct, and left recurrent nerve; to it, the left pleura and lung.

The Second and Third Parts of the Subclavian Artery (fig.

The **second portion** of the subclavian artery lies behind the S anterior; it is very short, and forms the highest part of the arch des by the vessel.

Relations.—*In front* of it are the skin, superficial fascia, Platysma, cervical fascia, Sternocleidomastoideus, and Scalenus anterior. On the ri of the neck the phrenic nerve is separated from the second part of the art the Scalenus anterior, while on the left side it crosses the first part of the close to the medial edge of the muscle. *Behind* and *below* the vessel are the and lung; *above*, the brachial plexus of nerves. The subclavian vein lies and in front of the artery, separated from it by the Scalenus anterior.

The **third portion** of the subclavian artery runs downwards and la wards from the lateral margin of the Scalenus anterior to the outer bor the first rib, where it becomes the axillary artery. This is the most sup portion of the vessel, and is contained in the subclavian triangle (p. 62 portion of the vessel, and is contained in the subclavian triangle (p. 62

Relations.—*In front* of it are the skin, the superficial fascia, the Platysma supraclavicular nerves, and the deep cervical fascia. The external jugular crosses its medial part and receives the transverse scapular, transverse c and anterior jugular veins, which frequently form a plexus in front of the

CC-0. In Public Domain. Gurukul Kangri Collection, Haridwar

Digitized by Arya Samaj Foundation Chennai and eGangotri

and the veins, the nerve to the Subclavius descends in front of the artery. The vertical part of the artery lies behind the clavicle and the Subclavius, and is crossed by the transverse scapular vessels. The subclavian vein is in front of, and at a lower level than, the artery. The lowest trunk of the brachial plexus

FIG. 675.—A dissection of the right side of the neck, showing the carotid and subclavian arteries.

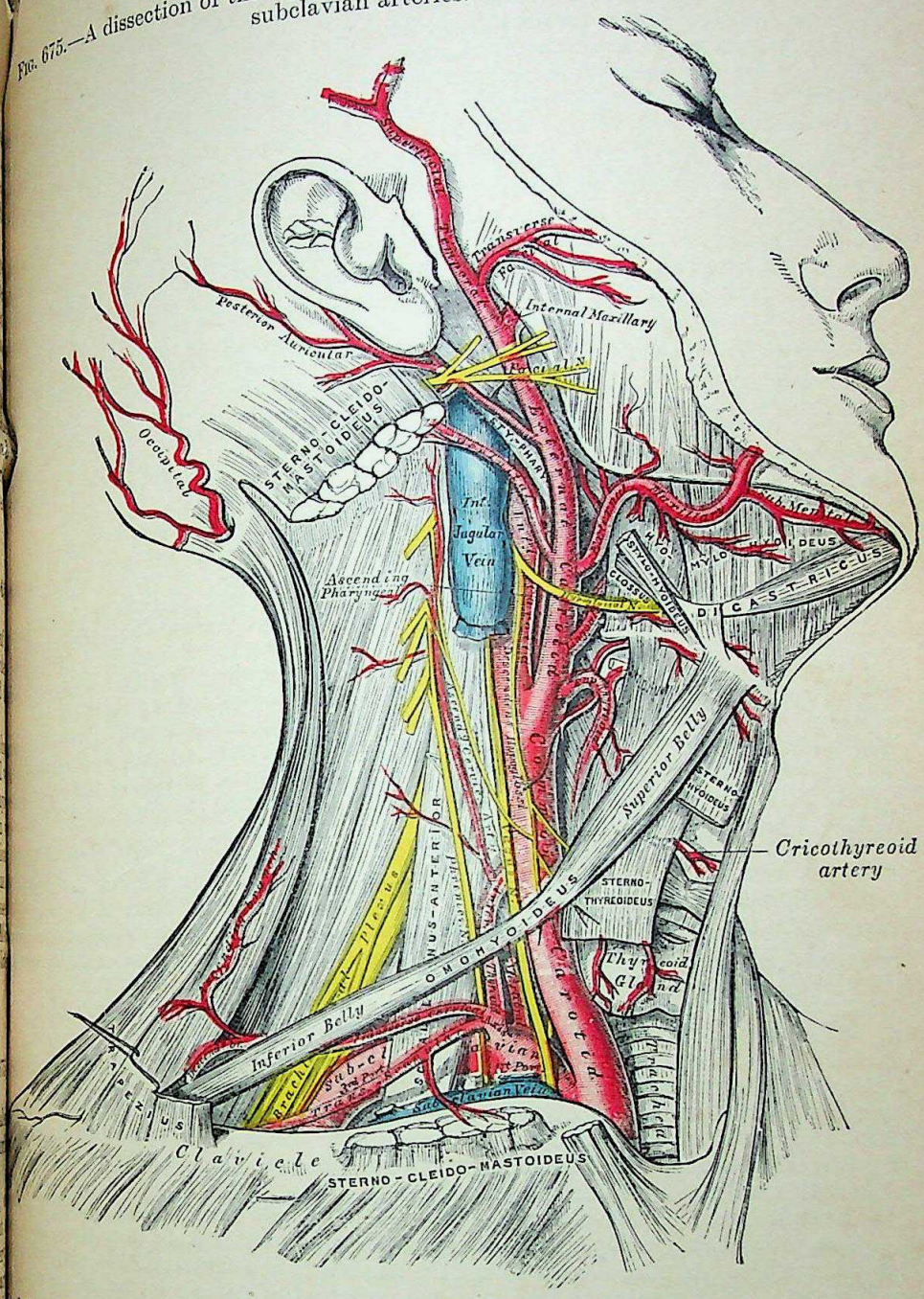

behind the artery and intervenes between it and the Scalenus medius. *Above*, to its *lateral side*, are the upper trunks of the brachial plexus, and the Omohyoideus. *Below*, it rests on the upper surface of the first rib.

Peculiarities.—The subclavian arteries vary in their origin, their course, and the height which they rise in the neck.

The right subclavian may arise from the innominate above or below the level of the sternoclavicular articulation. It may arise as a separate trunk from the arch of the aorta, and may then be either its first, second, third, or last branch; in the majority of cases it is the first or last. When it is the first branch, it occupies the ordinary position of the innominate artery; when the second or third, it passes behind the right carotid artery; and when the last it arises from the left extremity of the arch, and ascends obliquely towards

CC-0. In Public Domain. Gurukul Kangri Collection, Haridwar

Digitized by Arya Samaj Foundation Chennai and eGangotri

the right side, usually behind the trachea, œsophagus, and right carotid, sometimes the œsophagus and trachea, to the upper border of the first rib, whence it follows the course.

Occasionally the subclavian artery perforates the Scalenus anterior; very rarely passes in front of that muscle. Sometimes the subclavian vein passes with the artery behind the Scalenus anterior. The artery may ascend as high as 4 cm. above the bone, or may only reach the level of the upper border of the bone.

The left subclavian is occasionally joined at its origin with the left carotid. It is deeply placed than the right subclavian in the first part of its course, and, as a rule, not reach quite as high a level in the neck.

The posterior border of the Sternocleidomastoideus corresponds closely to the border of the Scalenus anterior, so that the third portion of the artery, the part accessible for operation, lies immediately lateral to the posterior border of the cleidomastoideus.

Applied Anatomy.—An aneurysm may form on any part of the subclavian except the intrathoracic portion of the left vessel, which is said never to be the aneurysm. The most common site is the third portion (especially on the right). In this situation it may cause pressure on the brachial plexus, producing pain and ness in the arm and fingers, with loss of power or paralysis of the muscles of the Œdema of the arm may result from pressure on the subclavian vein. The jugular vein may become distended and varicose. The treatment is unsatisfactory proximal ligature cannot be undertaken with much chance of success; the best is excision of the sac. In aneurysm of the first portion of this artery there is of the head and face, with lividity, congestion of the brain, and semiconscious pressure on the innominate veins as they enter the chest; and spasmodic action Diaphragm from pressure on the phrenic nerve. The collateral circulation is that blocking of the subclavian artery by embolism or thrombosis often fails to to any striking signs or symptoms, beyond occasional pains in the neck and shoulder some degree of weakness and wasting in the muscles of the arm.

Compression of the subclavian artery may be required to control hæmorrhage can be effectually applied in one situation only, viz. where the artery passes over upper surface of the first rib. In order to compress the vessel in this situation shoulder should be depressed, and the surgeon grasping the side of the neck should with his thumb in the angle formed by the posterior border of the Sternocleidomastoideus with the upper border of the clavicle, downwards, backwards, and medialwards the rib; if from any cause the shoulder cannot be sufficiently depressed, pressure made from before backwards, so as to compress the artery against the Scalenus and transverse process of the seventh cervical vertebra. In appropriate cases, liminary incision may be made through the cervical fascia, and the finger may be down directly upon the artery.

In cases of through-and-through gunshot wounds about the clavicle the formation an arteriovenous aneurysm, or direct communication between the subclavian artery some neighbouring vein, is not rare. This enables arterial blood at high pressure escape into the vein; the vein is distended thereby, with the production of a swelling that can be felt above or below the clavicle. In addition, a thrill can and a loud rushing murmur can be heard in the neighbourhood of the swelling. thrill and murmur are continuous, but more forcible during cardiac systole. Not quently these arteriovenous aneurysms call for relief by operation.

Ligature of the subclavian artery may be required in cases of wounds, or of aneurysm in the axilla, or in cases of aneurysm on the cardiac side of the point of ligature. vessel is also ligatured as a preliminary measure to the complete interscapulo-thoracic amputation of the upper extremity, in which case the transverse scapular and transverse cervical arteries may, if found, be ligatured at the same time, making the 'fore-quarter' amputation an almost bloodless procedure.

The third part of the artery is that which is most favourable for an operation account of its being comparatively superficial and most remote from the origin of large branches. In those cases where the clavicle is not displaced, this operation performed with comparative facility; but where the clavicle is pushed up by an aneurysmal tumour in the axilla, the artery lies at a great depth from the surface this materially increases the difficulty. Under these circumstances, it becomes a matter of importance to consider the height to which this vessel reaches above the bone. ordinary cases, its arch is about 1·25 cm. above the clavicle, occasionally as high 4 cm., and sometimes so low as to be on a level with its upper border. If the clavicle be displaced, these variations will necessarily make the operation more or less difficult according as the vessel is less or more accessible.

The procedure in the operation of tying the third portion of the subclavian artery 662, D) is as follows: The patient being placed on a table in the supine position, the head drawn over to the opposite side, and the shoulder depressed as much as possible the skin should be pulled downwards over the clavicle, and an incision made through upon that bone, from the anterior border of the Trapezius to the posterior border of Sternocleidomastoideus. The object in drawing the skin downwards is to avoid an

CC-0. In Public Domain. Gurukul Kangri Collection, Haridwar

Digitized by Arya Samaj Foundation Chennai and eGangotri

...ending the external jugular vein, which perforates the deep fascia above the clavicle, ...cannot be drawn downwards with the skin. The soft parts are allowed to glide up, ...the cervical fascia is divided; if the interval between the Trapezius and Sternocleido-...leus be insufficient, a portion of one or both may be divided. The external jugular ...will now be seen towards the medial side of the wound; this and the transverse ...ar and transverse cervical veins which end in it should be held aside. If any large ...ch at all in the way and exposed to injury, it should be tied in two places and divided. ...transverse scapular artery should be avoided, and the Omohyoideus held aside if ...ssary. In the space beneath this muscle a deep layer of fascia and some connective ...are divided, the lateral margin of the Scalenus anterior muscle felt for, and the ...being guided by it to the first rib, the pulsation of the subclavian artery will be ...as it passes over the rib. The sheath of the vessels having been opened, the aneurysm ...may then be passed around the artery from above downwards and medialwards so ...avoid including the lowest trunk of the brachial plexus which lies behind the artery ...the first rib. If the clavicle be so raised by the tumour that the application of the ...ture cannot be effected in this situation, the artery may be tied above the first rib, or ...behind the Scalenus anterior.

The second part of the subclavian artery, the portion which rises highest in the neck, ...been considered favourable for the application of the ligature when it is difficult to tie ...artery in the third part of its course. There are, however, many objections to the ...tion in this situation. It is necessary to divide the Scalenus anterior, upon which ...the phrenic nerve, and at the medial side of which is situated the internal jugular ...and a wound of either of these structures might lead to the most dangerous ...quences. Again, the artery is in contact, below, with the pleura, which must also ...ded; and, lastly, the proximity of so many of its large branches arising medial to ...point is a further objection to the operation. In cases, however, where the sac of an ...ry aneurysm encroaches on the neck, it may be necessary to divide the lateral half ...-thirds of the Scalenus anterior, so as to place the ligature on the vessel at a greater ...ce from the sac. The operation is performed exactly in the same way as a ligature ...the third portion, until the Scalenus anterior is exposed, when it is to be divided on ...tior (never to a greater extent than its lateral two-thirds), and it immediately ...ts. This is therefore merely an extension of the operation for ligature of the third ...on of the vessel.

In those cases of aneurysm of the axillary or subclavian artery which encroach upon ...lateral portion of the Scalenus anterior to such an extent that a ligature cannot be ...ed in that situation, it may be deemed advisable, as a last resource, to tie the first ...on of the subclavian artery. On the left side, this operation is almost impracticable; ...great depth of the artery from the surface, its intimate relation with the pleura, and ...close proximity to the thoracic duct and to so many important veins and nerves, ...ent a series of difficulties which it is next to impossible to overcome. On the right ...the operation is practicable, the main difficulty being the smallness of the interval ...h usually exists between the commencement of the vessel and the origin of the ...ous branch. The operation is essentially similar to that described on p. 603 for ...ure of the innominate artery. The exact position of the vagus, recurrent, and ...nic nerves and the sympathetic trunk should be borne in mind, and the ligature ...ld be applied near the origin of the vertebral, in order to afford as much room as ...ble for the formation of a coagulum between the ligature and the origin of the vessel. ...ould be remembered that the right subclavian artery is occasionally deeply placed in ...first part of its course, when it arises from the left side of the aortic arch, and passes ...ch cases behind the œsophagus, or between it and the trachea.

Collateral Circulation.—After ligature of the third part of the subclavian artery, the ...eral circulation is established mainly by three sets of vessels, thus described in ...section:

1. A posterior set, consisting of the transverse scapular artery and the descending ...ch of the transverse cervical branch of the subclavian, anastomosing with the sub-...ar from the axillary.

2. A medial set, produced by the connexion of the internal mammary on the one hand, ...the arteria intercostalis suprema and the lateral thoracic and subscapular arteries ...the other.

3. A middle or axillary set, consisting of a number of small vessels derived from ...ches of the subclavian and, passing through the axilla, terminating either in the ...ry artery, or some of its branches. This last set presented most conspicuously ...peculiar character of newly formed or, rather, dilated arteries, being excessively ...us, and forming a complete plexus.

The chief agent in the restoration of the axillary artery below the aneurysm was the ...capular artery, which communicated freely with the internal mammary, transverse ...ar, and descending ramus of the transverse cervical arteries of the subclavian, ...all of which it received so great an influx of blood as to dilate it to three times its ...ral size.*

* *Guy's Hospital Reports*, vol. i. 1836. Case of axillary aneurysm, in which Aston Key had ...the subclavian artery at the lateral edge of the Scalenus anterior, twelve years previously.

CC-0. In Public Domain. Gurukul Kangri Collection, Haridwar

Digitized by Arya Samaj Foundation Chennai and eGangotri

When a ligature is applied to the first part of the subclavian artery, the circulation is carried on by the following anastomoses: 1, between the inferior thyreoids; 2, the two vertebrals; 3, the internal mammary with the epigastric and the aortic intercostals; 4, the costocervical with the aortic 5, the a. profunda cervicalis with the descending branch of the occipital; 6, the branches of the thyreocervical trunk with the branches of the axillary; and 7, the branches of the axillary with the aortic intercostals.

Branches.—The branches of the subclavian artery are:

Vertebral.	Thyreocervical.
Internal mammary.	Costocervical.

On the left side of the neck all four branches generally rise from the portion of the artery; on the right side the costocervical trunk usually from the second portion. On both sides, the first three branches close together at the medial border of the Scalenus anterior.

1. The **vertebral artery** (fig. 668) arises from the upper and part of the first portion of the subclavian artery. It ascends through foramina in the transverse processes of the upper six cervical vertebræ behind the superior articular process of the atlas, enters the skull through foramen magnum, and, at the lower border of the pons, unites with the of the opposite side to form the basilar artery.

Relations.—The vertebral artery may be divided into four parts. The *part* runs upwards and backwards between the Longus colli and the Scalenus and behind the common carotid artery. In front of it are the internal jugular vertebral veins, and it is crossed by the inferior thyreoid artery; the left artery is crossed also by the thoracic duct. Behind it are the transverse the seventh cervical vertebra, the sympathetic trunk and its inferior cervical The *second part* ascends through the foramina transversaria of the upper six vertebræ, and is surrounded by a plexus of nerves derived from the inferior sympathetic ganglion, and by a plexus of veins which unite to form the vertebral vein at the lower part of the neck. It lies in front of the trunks of the nerves, and pursues an almost vertical course as far as the transverse the epistropheus, through which it runs upwards and lateralwards to the transversarium of the atlas. The *third part* issues from the latter the medial side of the Rectus capitis lateralis, and curves backwards behind superior articular process of the atlas, the anterior ramus of the first cervical being on its medial side; it then lies in the groove on the upper surface posterior arch of the atlas, and enters the vertebral canal by passing beneath the arched border of the posterior atlanto-occipital membrane. This part artery is covered by the Semispinalis capitis and is contained in the *triangle*, which is bounded by the Rectus capitis posterior major, the superior, and the Obliquus inferior. The posterior division of the first nerve lies between the artery and the posterior arch of the atlas. The *fourth* pierces the dura mater and the arachnoid membrane, ascends in front of the of the hypoglossal nerve, and inclines medialwards to the front of the oblongata, where, at the lower border of the pons, it unites with the vessel opposite side to form the basilar artery.

The branches of the vertebral artery may be divided into two sets—those off in the neck, and those within the cranium.

Cervical branches.	*Cranial branches.*
Spinal.	Meningeal.
Muscular.	Posterior spinal.
	Anterior spinal.
	Posterior inferior cerebellar.
	Medullary.

Spinal branches enter the vertebral canal through the intervertebral foramina and each divides into two branches. Of these, one passes along the roots of nerves to supply the medulla spinalis and its membranes, anastomosing with other arteries of the medulla spinalis; the other divides into an ascending

* The vertebral artery sometimes [illegible] the transverse process of the vertebra, and has been seen entering that of the seventh vertebra.

CC-0. In Public Domain. Gurukul Kangri Collection, Haridwar

Digitized by Arya Samaj Foundation Chennai and eGangotri

ascending branch, which unite with similar branches from the arteries above and below, so that two lateral anastomotic chains are formed on the posterior surfaces of the bodies of the vertebræ, near the attachment of the pedicles. From these anastomotic chains branches are supplied to the periosteum and the bodies of the vertebræ, and others communicate with similar branches from the opposite side and below, to form a central anastomotic chain on the posterior surfaces of the bodies of the vertebræ.

Muscular branches arise from the vertebral artery as it curves round the superior articular process of the atlas. They supply the deep muscles of the neck and anastomose with the occipital artery, and the ascending and deep cervical arteries.

One or two **meningeal branches** spring from the vertebral artery opposite the foramen magnum, ramify between the bone and dura mater in the cerebellar fossa, and supply the falx cerebelli.

The **posterior spinal artery** arises from the vertebral artery at the side of the medulla oblongata, but is frequently derived from the posterior cerebellar artery. It passes backwards, and then descends behind the posterior roots of the spinal nerves, and is reinforced by a succession of small branches, which arise from the vertebral, ascending cervical, intercostal and lumbar arteries, and enter the vertebral canal through the intervertebral foramina; by means of these it is continued on the lower part of the medulla spinalis, and to the cauda equina. Branches of the posterior spinal arteries form a free anastomosis round the posterior roots of the spinal nerves, and communicate with the vessels of the opposite side. Near the origin each posterior spinal artery gives off an ascending branch, which ends at the side of the fourth ventricle.

The **anterior spinal artery** is a small branch, which arises near the termination of the vertebral artery; it descends in front of the medulla oblongata and unites with its fellow of the opposite side near the level of the lower end of the olive of the medulla oblongata. The single trunk, thus formed, descends on the front of the medulla spinalis, and is reinforced by a succession of small branches which enter the vertebral canal through the intervertebral foramina; these branches are derived from the vertebral, the ascending cervical, intercostal, and lumbar arteries. They unite, by means of ascending and descending branches, to form a single anterior spinal artery, which extends as far as the lower part of the medulla spinalis, and is continued as a slender twig on the filum terminale. This vessel is placed in the pia mater along the anterior median fissure; it supplies that membrane, and the substance of the medulla spinalis, and sends off branches at its lower part to be distributed to the cauda equina. Branches pass from the anterior spinal arteries and from the beginning of the trunk formed by their union to the medulla oblongata.

The **posterior inferior cerebellar artery** (fig. 671) is the largest branch of the vertebral artery, but is not infrequently absent. It arises near, and winds backwards round, the lower end of the olive of the medulla oblongata; it then ascends behind the roots of the glossopharyngeal and vagus nerves to the under surface of the cerebellum, where it divides into a medial and a lateral branch. The medial branch runs backwards to the notch between the hemispheres of the cerebellum, while the lateral supplies the under surface of the hemisphere, as far as its lateral border, where it anastomoses with the anterior inferior cerebellar and the superior cerebellar branches of the basilar artery. Branches supply the medulla oblongata and the choroid plexus of the fourth ventricle. A branch of this artery ascends between the inferior lobe and the tonsil of the cerebellum to supply the dentate nucleus of the cerebellum (Shellshear*).

The **medullary arteries** are several minute vessels which spring from the vertebral and its branches, and are distributed to the medulla oblongata.

The **basilar artery** (figs. 671, 674), so named from its position at the base of the brain, is formed by the junction of the two vertebral arteries; it extends from the pons to the upper border of the pons, and is contained within the cisterna pontis. It lies in a shallow, median groove on the ventral surface of the pons. It is placed between the two abducent nerves at the lower border, and between the two oculomotor nerves at the upper border, of the pons, where it divides into the two posterior cerebral arteries.

* J. L. Shellshear, *Lancet*, May 27th, 1922.

CC-0. In Public Domain. Gurukul Kangri Collection, Haridwar

Digitized by Arya Samaj Foundation Chennai and eGangotri

Its branches, on either side, are the following :

Pontine.	Anterior inferior cerebellar.
Internal auditory.	Superior cerebellar.
	Posterior cerebral.

The **pontine branches** are a number of small vessels which come off from the and sides of the basilar artery, and supply the pons and adjacent parts of the

The **internal auditory artery,** a long slender branch, may arise from the part of the basilar artery, but is more often derived from the anterior inferior bellar artery; it accompanies the acoustic nerve through the internal meatus and is distributed to the internal ear.

The **anterior inferior cerebellar artery** arises from the lower part of the artery. It runs backwards and lateralwards, usually ventral to the abducens and then between the pons and the facial and acoustic nerves, to the anterior of the under surface of the cerebellum, where it anastomoses with the inferior cerebellar branch of the vertebral artery. A few branches are supplied the anterior inferior cerebellar artery to the lower and lateral parts of the pons sometimes to the upper part of the medulla oblongata.

The **superior cerebellar artery** arises near the termination of the basilar passes lateralwards immediately below the oculomotor nerve which separates from the posterior cerebral artery, winds round the cerebral peduncle close below the trochlear nerve, and, arriving at the upper surface of the cerebellum divides into branches which ramify in the pia mater and anastomose with of inferior cerebellar arteries. Branches are given to the pons, the pineal the anterior medullary velum, and the tela chorioidea of the third ventricle.

The **posterior cerebral artery** (figs. 671, 672, 673), frequently double, is than the superior cerebellar artery, from which it is separated near its origin the oculomotor nerve, and on the side of the mesencephalon by the trochlear Passing lateralwards, parallel to the superior cerebellar artery, and receiving posterior communicating branch from the internal carotid artery, it winds the cerebral peduncle, and reaches the tentorial surface of the cerebrum, where breaks up into branches for the supply of the temporal and occipital lobes.

The branches of the posterior cerebral artery are divided into two ganglionic and cortical :

Ganglionic	Posteromedial.	*Cortical*	Anterior temporal.
	Posterior chorioidal.		Posterior temporal.
	Posterolateral.		Calcarine.
			Parieto-occipital.

Ganglionic branches.—The *posteromedial ganglionic branches* (fig. 674) are small arteries which arise at the commencement of the posterior cerebral and these with similar branches from the posterior communicating, pierce the posterior perforated substance, and supply the medial surfaces of the thalami and the of the third ventricle. The *posterior chorioidal branches* run forwards beneath the splenium of the corpus callosum, supply the tela chorioidea of the third ventricle, and end in the chorioid plexus of the lateral ventricle. The *posterolateral ganglionic branches* are small arteries which arise from the posterior cerebral after it has turned round the cerebral peduncle ; they supply a considerable portion of the thalamus.

Cortical branches.—These are : the *anterior temporal,* distributed to the and the anterior part of the fusiform gyrus ; the *posterior temporal,* to the fusiform and the inferior temporal gyri ; the *calcarine,* to the cuneus, gyrus lingualis, the posterior part of the lateral surface of the occipital lobe ; and the *parieto-occipital,* to the cuneus and the præcuneus.

2. The **internal mammary artery** (fig. 676) arises from the under surface of the first portion of the subclavian artery, opposite the thyreocervical trunk. It descends behind the cartilages of the upper six ribs at a distance of 1·25 cm. from the lateral border of the sternum, and at the level of the sixth intercostal space divides into the *musculophrenic* and *superior epigastric* arteries.

* Consult an article on 'The arteries of the pons and medulla oblongata' by J. S. B. Stopford, *Journal of Anatomy,* vols. l., li.

CC-0. In Public Domain. Gurukul Kangri Collection, Haridwar

Digitized by Arya Samaj Foundation Chennai and eGangotri

Relations.—It runs at first downwards, forwards, and medialwards behind the sternal end of the clavicle, the internal jugular and innominate veins, and the first costal cartilage. As the artery enters the thorax, the phrenic nerve crosses obliquely from the lateral to the medial side, the nerve usually passing in front of the artery. Below the first costal cartilage it descends almost vertically to its

FIG. 676.—The left internal mammary artery.

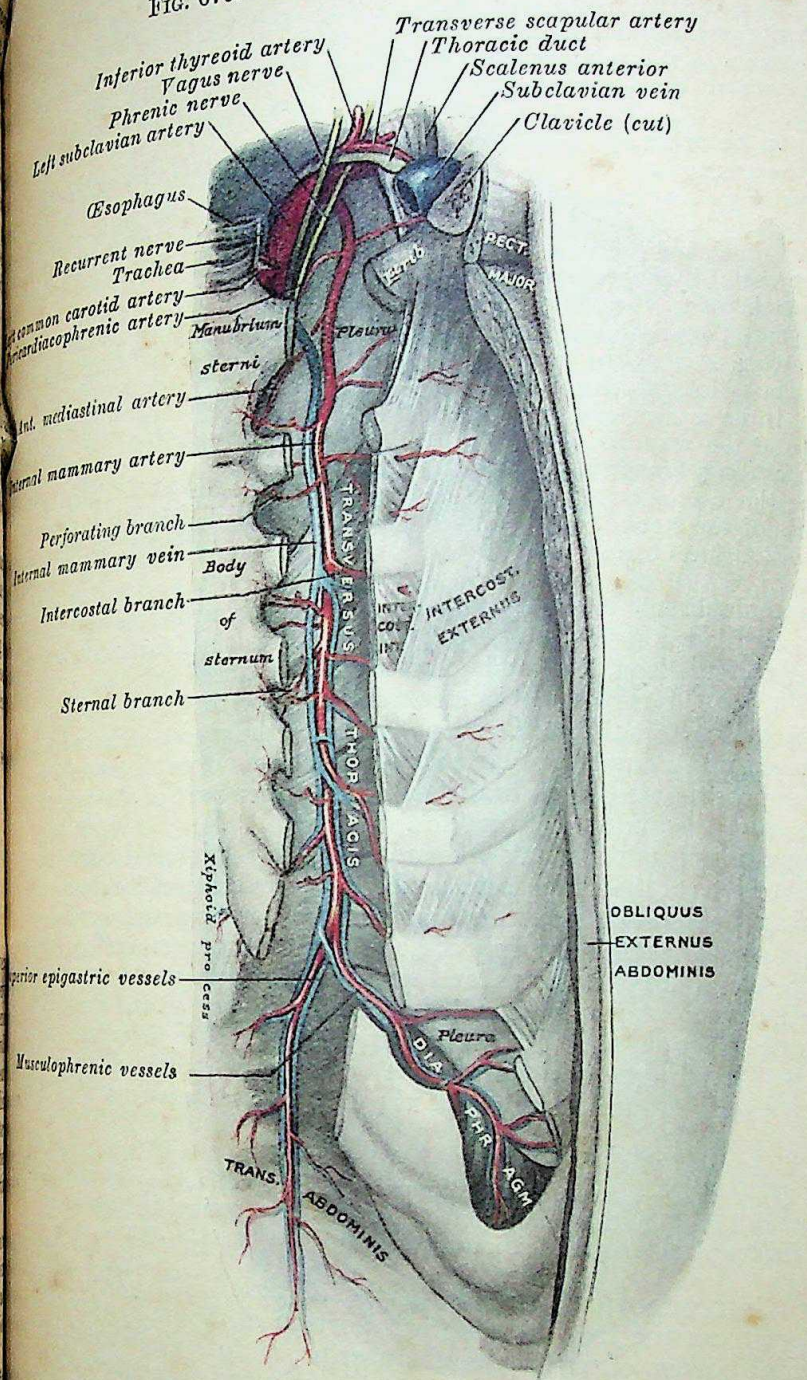

of bifurcation. It is covered in front by the Pectoralis major, the cartilages upper six ribs and the intervening anterior intercostal membranes and Inter- s interni, and is crossed by the terminal portions of the upper six intercostal a. It is separated from the pleura, as far as the second or third costal cartilage, a strong layer of fascia; below this level, by the Transversus thoracis. It is companied by a chain of lymph-glands and a pair of veins: about the level of third costal cartilage the veins unite to form a single vessel, which runs medial the artery and ends in the innominate vein.

CC-0. In Public Domain. Gurukul Kangri Collection, Haridwar

Digitized by Arya Samaj Foundation Chennai and eGangotri

The branches of the internal mammary artery are:

Pericardiacophrenic.	Sternal.	Musculophrenic.
Anterior mediastinal.	Intercostal.	Superior epigastric.
Pericardial.	Perforating.	

The **pericardiacophrenic artery** (a. comes nervi phrenici) is a long slender which accompanies the phrenic nerve, between the pleura and pericardium Diaphragm; it gives branches to the pleura, pericardium and Diaphragm, and moses with the musculophrenic and inferior phrenic arteries.

The **anterior mediastinal arteries** are small vessels, distributed to the areolar and lymph-glands in the anterior mediastinal cavity, and to the remains of the

The **pericardial branches** supply the upper part of the anterior surface pericardium.

The **sternal branches** are distributed to the Transversus thoracis, and to the surface of the sternum.

The anterior mediastinal, pericardial, and sternal branches, together with from the pericardiacophrenic, anastomose with branches from the intercostal bronchial arteries, and form a **subpleural mediastinal plexus.**

The **intercostal branches** supply the upper five or six intercostal spaces. number in each space, they pass lateralwards, one lying near the lower margin of above, and the other near the upper margin of the rib below, and anastomose intercostal arteries from the aorta. They are at first situated between the pl the Intercostales interni, and then between the Intercostales interni et externi supply the Intercostales and send branches through the Intercostales externi Pectorales and the mamma.

The **perforating branches** emerge through the upper five or six intercostal They pierce the Pectoralis major, and curving lateralwards, supply that muscle skin. Those of the second, third, and fourth spaces give branches to the mamma during lactation are of large size.

The **musculophrenic artery** is directed obliquely downwards and lateral behind the cartilages of the false ribs; it perforates the Diaphragm at the or ninth costal cartilage, and ends, considerably reduced in size, opposite intercostal space. It gives off intercostal branches to the seventh, eighth ninth intercostal spaces; these diminish in size as the spaces decrease in length are distributed in a manner similar to the intercostals from the internal mam The musculophrenic also gives branches to the lower part of the pericardium Diaphragm, and the abdominal muscles.

The **superior epigastric artery** descends through the interval between the and xiphoid origins of the Diaphragm, and enters the sheath of the Rectus abd at first lying behind the muscle, and then perforating and supplying it anastomosing with the inferior epigastric artery from the external iliac. Branches perforate the sheath of the Rectus, and supply the muscles and skin of the abd and a small branch passes in front of the xiphoid process and anastomoses the artery of the opposite side. The superior epigastric artery also gives twigs to the Diaphragm, while from the artery of the right side small branches extend into the falciform ligament of the liver and anastomose with the hepatic artery.

Applied Anatomy.—The internal mammary artery is liable to be wounded in of the chest-wall and in the operation of paracentesis pericardii (p. 577). It is easily reached by a transverse incision in the second intercostal space.

3. The **thyreocervical trunk** (thyreoid axis) (fig. 675), a short trunk, arises from the front of the first portion of the subclavian artery to the medial border of the Scalenus anterior, and divides almost immediately into three branches, the *inferior thyreoid*, *transverse scapular*, and *transverse cervical*.

The **inferior thyreoid artery** runs upwards in front of the vertebral artery Longus colli; it then turns medialwards behind the carotid sheath and its contents and also behind the sympathetic trunk, the middle cervical ganglion of which lies upon the vessel; it finally descends to the lower border of the lateral lobe of thyreoid gland. At a little distance below the gland the inferior thyreoid usually passes behind the recurrent nerve, but when the gland is reached the is often behind the branches of the artery.*

CC-0. In Public Domain. Gurukul Kangri Collection, Haridwar

* F. G. Parsons, *Journal of Anatomy*, vol. liv. p. 172.

Digitized by Arya Samaj Foundation Chennai and eGangotri

The branches of the inferior thyreoid are :

Muscular.	Inferior laryngeal.	Œsophageal.
Ascending cervical.	Tracheal.	Glandular.

The muscular branches supply the depressors of the hyoid bone, and the Longus colli, Rectus anterior, and Constrictor pharyngis inferior.

The ascending cervical artery is a small branch which arises from the inferior thyreoid artery as that vessel is passing behind the carotid sheath ; it ascends on the anterior tubercles of the transverse processes of the cervical vertebræ in the interval between the Rectus anterior and Longus capitis. It gives twigs to the muscles of the neck, and sends one or two spinal branches into the vertebral canal through the intervertebral foramina to be distributed to the medulla spinalis and its membranes, and to the bodies of the vertebræ, in the same manner as the spinal branches from the vertebral artery. It anastomoses with the vertebral, ascending pharyngeal and occipital arteries.

The inferior laryngeal artery ascends upon the trachea in company with the recurrent nerve ; it enters the larynx under the lower border of the Constrictor pharyngis inferior, and supplies its muscles and mucous membrane, anastomosing with the artery from the opposite side, and with the superior laryngeal branch of the superior thyreoid artery.

The tracheal branches are distributed to the trachea, and anastomose below with the bronchial arteries.

The œsophageal branches supply the œsophagus, and anastomose with the œsophageal branches of the thoracic aorta.

The glandular branches consist of an inferior and an ascending branch ; they are distributed to the posterior and inferior parts of the thyreoid gland, and anastomose with the superior thyreoid artery and with the opposite inferior thyreoid artery ; the ascending branch supplies the superior parathyreoid gland.

The **transverse scapular artery** (suprascapular artery) (fig. 675) passes at first outwards and lateralwards across the Scalenus anterior and phrenic nerve, under cover of the Sternocleidomastoideus ; it then crosses the subclavian artery and the brachial plexus, and runs upward and parallel with the Clavicle and Subclavius, and beneath the inferior belly of the Omohyoideus, to the superior border of the scapula ; here it passes over (occasionally under) the superior transverse ligament which separates it from the suprascapular nerve, and enters the supraspinatous fossa (fig. 677). In this situation it lies on the bone, and supplies branches to the Supraspinatus. It then descends behind the neck of the scapula, through the great scapular notch and beneath the inferior transverse ligament, to reach the deep surface of the Infraspinatus, where it anastomoses with the scapular circumflex artery and the descending branch of the transverse cervical artery. Besides distributing branches to the Sternocleidomastoideus, Subclavius, and neighbouring muscles, it gives off a *suprasternal branch*, which crosses over the sternal end of the clavicle to the skin of the upper part of the chest ; and an *acromial branch*, which pierces the Trapezius and supplies the skin over the acromion, anastomosing with the thoraco-acromial artery. As the transverse scapular artery passes over the superior transverse ligament of the scapula, it sends a branch into the subscapular fossa, where it ramifies beneath the Subscapularis, and anastomoses with the subscapular artery and with the descending branch of the transverse cervical artery. The transverse scapular artery also sends articular branches to the

FIG. 677.—The right scapular and circumflex arteries.

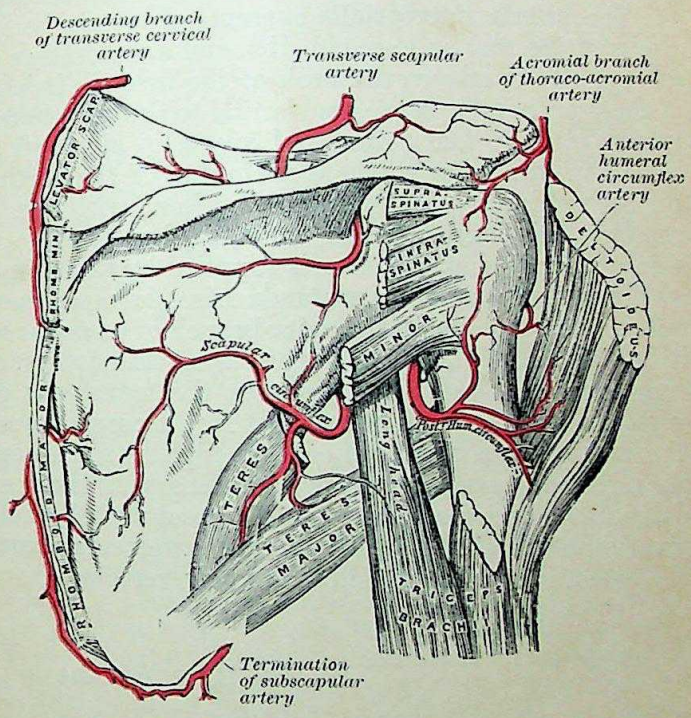

CC-0. In Public Domain. Gurukul Kangri Collection, Haridwar

Digitized by Arya Samaj Foundation Chennai and eGangotri

acromioclavicular and shoulder-joints, and nutrient arteries to the cla[illegible] scapula. Occasionally the transverse scapular artery arises from the third [illegible] the subclavian artery.

The **transverse cervical artery** (a. transversa colli) (fig 675) lies at a hig[illegible] than the transverse scapular artery; it crosses in front of the phrenic [illegible] the Scaleni, and in front of or between the divisions of the brachial plex[illegible] covered by the Platysma and Sternocleidomastoideus. It passes behind [illegible] hyoideus and runs transversely above the inferior belly of that muscle [illegible] anterior margin of the Levator scapulæ, where it divides into an ascendi[illegible] descending branch.

The *ascending branch* (superficial cervical artery) ascends beneath the [illegible] part of the Trapezius, distributing branches to it and to the neighbouring [illegible] and lymph-glands in the neck, and anastomosing with the superficial bran[illegible] ramus descendens of the occipital artery.

The *descending branch* (posterior scapular artery) (fig. 677) passes bene[illegible] Levator scapulæ to the medial angle of the scapula, and then descends [illegible] cover of the Rhomboidei along the vertebral border of the scapula as fa[illegible] inferior angle of the bone. It supplies branches to the Rhomboidei, Le[illegible] dorsi and Trapezius, and anastomoses with the transverse scapular and sub[illegible] arteries, and with the posterior branches of some of the intercostal arteries.

Peculiarities.—Frequently the ascending branch (superficial cervical artery) [illegible] directly from the thyreocervical trunk, and the descending branch (posterior [illegible] artery) from the third, more rarely from the second, part of the subclavian.

4. The **costocervical artery** (superior intercostal artery) (fig. 668) [illegible] from the posterior aspect of the second part of the subclavian artery o[illegible] right side, but from the first part of the artery on the left side. It [illegible] backwards above the cupula of the pleura to the neck of the first rib, and d[illegible] into the arteria intercostalis suprema and the arteria cervicalis profun[illegible]

The **arteria intercostalis suprema** descends behind the pleura in front [illegible] necks of the first and second ribs, and anastomoses with the first aortic inte[illegible] artery. As it crosses the neck of the first rib it is medial to the anterior [illegible] of the first thoracic nerve, and lateral to the first thoracic ganglion of the sympa[illegible] trunk. In the first intercostal space, it gives off a branch which is distr[illegible] in a manner similar to the distribution of the aortic intercostals. The bran[illegible] the second intercostal space usually joins with one from the first aortic inte[illegible] artery; this branch is not constant, but is more commonly found on the [illegible] side; when absent, its place is supplied by an intercostal branch from the aor[illegible]

The **arteria cervicalis profunda** arises, in most cases, from the costocervical [illegible] and is analogous to the posterior branch of an aortic intercostal artery: occas[illegible] it is a separate branch from the subclavian artery. Passing backwards abo[illegible] eighth cervical nerve and between the transverse process of the seventh ce[illegible] vertebra and the neck of the first rib, it ascends on the back of the neck, bet[illegible] the Semispinales capitis et colli, as high as the second cervical vertebra, sup[illegible] the adjacent muscles, and anastomosing with the deep division of the ramus de[illegible] dens of the occipital artery (p. 615) and with branches of the vertebral artery [illegible] gives off a spinal twig which enters the vertebral canal through the foramen bet[illegible] the seventh cervical and first thoracic vertebræ.

The Axilla

The **axilla** is a pyramidal space, situated between the upper part o[illegible] lateral wall of the chest and the upper part of the medial side of the arm.

The *apex* of the axilla is directed upwards towards the root of the n[illegible] and corresponds to the interval between the outer border of the first [illegible] the superior border of the scapula, and the posterior surface of the clav[illegible] through it the axillary vessels and nerves enter the space from the neck. [illegible] *base*, directed downwards, is broad at the chest but narrow and pointe[illegible] the arm; it is formed by the skin and a thick layer of fascia, the *axillary f*[illegible] extending between the lower border of the Pectoralis major in front, and [illegible] lower border of the Latissimus dorsi behind. The *anterior wall* is formed [illegible] the Pectorales major et minor, the former covering the whole of this [illegible]

CC-0. In Public Domain. Gurukul Kangri Collection, Haridwar

Digitized by Arya Samaj Foundation Chennai and eGangotri

latter only its central part. The space between the upper border of the oralis minor and the clavicle is occupied by the coracoclavicular fascia coracoid membrane). The *posterior wall* is formed by the Subscapularis the Teres major and Latissimus dorsi below. On the *medial side* are st four ribs with their corresponding Intercostales, and the upper part Serratus anterior. On the *lateral side*, where the anterior and posterior converge, the space is narrow, and bounded by the humerus, the Coraco-

The axilla contains the axillary vessels, the infraclavicular part of the chialis, and the Biceps brachii.

chial plexus of nerves, with its branches, the lateral branches of some of the rcostal nerves, and a large number of lymph-glands, together with a quantity fat and loose areolar tissue. The axillary vessels and the brachial plexus nerves run from the apex to the base along the lateral wall of the axilla; are placed nearer to the anterior than to the posterior wall, the axillary lying to the thoracic side of the axillary artery and partially concealing The thoracic branches of the axillary artery are in contact with the ratorales, and along the lower margin of the Pectoralis minor the lateral racic artery passes to the side of the thorax. The subscapular vessels and ves descend on the posterior wall in contact with the lower margin of the scapularis; the scapular circumflex vessels wind round the axillary border scapula, and the posterior humeral circumflex vessels and the axillary curve backwards close to the neck of the humerus. No vessel of any portance exists along the medial or thoracic side, the upper part of the being crossed merely by a few small branches from the highest thoracic ery. The long thoracic nerve descends on the surface of the Serratus anterior, which it is distributed; and the intercostobrachial nerve perforates the er and anterior part of this wall, and passes across the axilla to the medial of the arm.

The position and arrangement of the lymph-glands are described on 758 to 760.

Applied Anatomy.—The axilla is a space of considerable surgical importance. Its sels and nerves may be the seat of injury or disease: its lymph-glands may require ment; its loose connective tissue may be readily infiltrated with blood or inflamma- y exudation. Moreover, its base is covered by thin skin, which is well supplied with aceous and sweat glands, and is frequently the seat of small abscesses and boils.

Penetrating wounds in the axilla are sometimes accompanied by extensive hæmor- ge, either from wound of the main vessels, or of one of the large branches of the illary artery, e.g. the lateral thoracic or the subscapular. Where the blood cannot find easy exit it collects in the space and forms a large swelling which projects in the floor the axilla and also bulges forwards the Pectoralis major. The treatment consists in ly opening up the cavity, searching for and securing the bleeding vessel.

When suppuration occurs in the axilla, the arrangement of the fasciæ plays a very portant part in the direction which the pus takes. As described on p. 498, the coraco- ricular fascia, after covering the space between the clavicle and the upper border of Pectoralis minor, splits to enclose this muscle, and at its lower border is incorporated th the axillary fascia at the anterior fold of the axilla. Suppuration may take place her superficial to or beneath this layer of fascia; that is, either between the Pectorales behind the Pectoralis minor; in the former case, the abscess would point either at e border of the anterior axillary fold, or in the groove between the Deltoideus and the toralis major; in the latter, the pus would have a tendency to surround the vessels d nerves, and ascend into the neck, that being the direction in which there is least stance. Its progress towards the surface is prevented by the axillary fascia; its gress backwards, by the insertion of the Serratus anterior; forwards, by the coraco- ricular fascia; medialwards, by the wall of the thorax; and lateralwards, by the upper ch. The pus in these cases, after extending into the neck, has been known to spread ough the superior opening of the thorax into the mediastinal cavity. Instances have en recorded where the pus found its way along the vessels into the arm.

When opening an axillary abscess, the knife should be entered in the floor of the a, midway between the anterior and posterior margins and near the thoracic side of space so as to avoid the lateral thoracic, subscapular, and axillary vessels which are ntact respectively with the anterior, posterior and lateral walls of the axilla. After incision has been made through the skin and fascia, it is well to use a director and ding forceps in the manner directed by Hilton.

The relations of the vessels and nerves in the several parts of the axilla are important, y it is the universal plan to remove the lymph-glands from the axilla in operating for cer of the breast. In performing such an operation, it is necessary to proceed with

CC-0. In Public Domain. Gurukul Kangri Collection, Haridwar

Digitized by Arya Samaj Foundation Chennai and eGangotri

much caution in the direction of the lateral wall and apex of the space, axillary vessels are in danger of being wounded. The thoracodorsal nerve to simus dorsi and the long thoracic nerve to the Serratus anterior must be isolated. In clearing out the axilla, the axillary vein should first be defined up to the apex of the space by means of a director. In order to do this the major, together with the whole of the Pectoralis minor, must be divided and by which means the surgeon is enabled to clear out the axillary cavity more When the apex of the space is reached all the fat and the lymph-glands must removed and the whole axilla cleared by separating the tissues from above from the vessels, and from the medial and posterior walls, so that when the completed the axilla is emptied of all its contents except the main vessels and

The Axillary Artery (fig. 678)

The axillary artery, the continuation of the subclavian artery, the outer border of the first rib, and ends at the lower border of the major, beyond which the artery takes the name of brachial. Its varies with the position of the limb: thus the vessel is nearly straight

Fig. 678.—The right axillary artery and its branches.

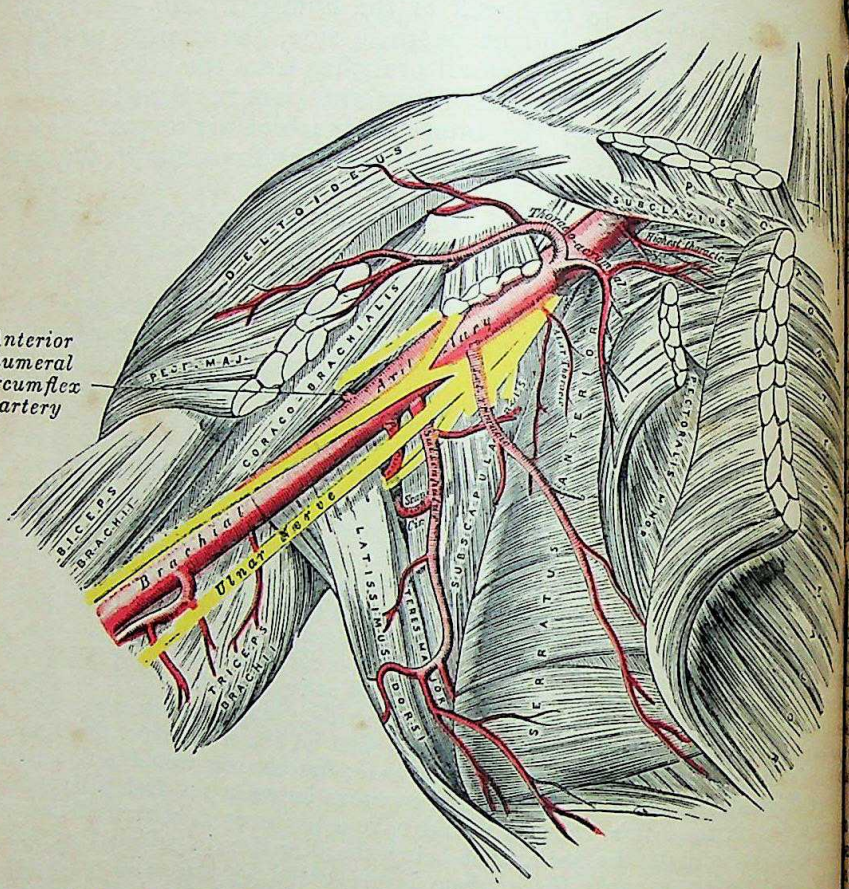

the arm is directed at right angles with the trunk, concave upwards when arm is elevated above this, and convex upwards and lateralwards when arm lies by the side of the trunk. The first part of the artery is deeply situ but its terminal part is superficial and is covered only by the skin and fas The Pectoralis minor crosses the vessel and divides it into three portions first part is proximal to, the second behind, and the third distal to the mus

Relations of the first part.—*In front* of the first part of the axillary artery the skin, superficial fascia, Platysma, supraclavicular nerves from the cer plexus, deep fascia, clavicular fibres of the Pectoralis major, and the coracoclav fascia. This part of the artery is crossed by the lateral anterior thoracic and by the thoraco-acromial and cephalic veins. *Behind* the artery are the intercostal space and Intercostalis externus, the first and second digitations of

CC-0. In Public Domain. Gurukul Kangri Collection, Haridwar

Digitized by Arya Samaj Foundation Chennai and eGangotri

...us anterior, the long thoracic and medial anterior thoracic nerves, and the ...al cord of the brachial plexus. On the *lateral side* of the artery are the lateral ...posterior cords of the brachial plexus; on the *medial side* is the axillary vein ...overlaps the artery. The first part of the artery is enclosed, together with ...illary vein and the brachial plexus, in a fibrous sheath, the *axillary sheath*, ...uous above with the deep cervical fascia.

Relations of the second part.—In front of the second part of the axillary artery ...the skin, superficial and deep fascia, and the Pectorales major et minor; *behind* ...the posterior cord of the brachial plexus and some areolar tissue which inter- ...between it and the Subscapularis; on the *medial side* is the axillary vein, ...rated from the artery by the medial cord of the brachial plexus and the medial ...rior thoracic nerve; on the *lateral side* is the lateral cord of the brachial plexus. ...cords of the brachial plexus thus surround the second part of the artery on ...sides, and separate it from direct contact with the vein and adjacent muscles.

Relations of the third part.—The third part of the axillary artery extends from ...lower border of the Pectoralis minor to the lower border of the Teres major. ...upper part is covered *in front* by the lower part of the Pectoralis major; its ...er part by the skin and fasciæ only. *Behind* it are the lower part of the Sub- ...ularis and the tendons of the Latissimus dorsi and Teres major. On its *lateral* ...is the Coracobrachialis, and on its *medial side*, the axillary vein. The nerves ...brachial plexus bear the following relations to this part of the artery; on ...*lateral side* are the lateral head and the trunk of the median, and, for a short ...ance the musculocutaneous; on the *medial side* are the medial antibrachial ...aneous, ulnar, and medial brachial cutaneous nerves. The medial antibrachial ...aneous nerve lies between the artery and vein anteriorly, and the ulnar nerve ...ween the axillary artery and vein posteriorly; the medial brachial cutaneous ...e is on the medial side of the vein; *in front* is the medial head of the median ...e, and *behind*, the radial and axillary nerves, the latter only as far as the lower ...der of the Subscapularis.

Applied Anatomy.—Compression of the axillary artery may be required in the removal ...mours, or in amputation of the upper part of the arm. The only situation in which ...pression can be effectually made is in the lower part of its course; by pressing the ...y against the humerus in this situation, the circulation may be effectually arrested.

With the exception of the popliteal, the axillary artery is perhaps more frequently ...ated than any other artery in the body by violent movements, particularly in those ...es where its coats are diseased. It has occasionally been ruptured in attempts to reduce ...dislocations of the shoulder-joint, especially where the artery has become fixed to the ...sule of the joint. Aneurysm of the axillary artery sometimes occurs and is often ...matic in its origin.

Ligature of the axillary artery may be required in cases of aneurysm of the upper part ...the brachial, or as a distal operation for aneurysm of the subclavian.

Ligature of the *third part* of the axillary artery is easy, and may be performed as follows ...679, A): The arm is drawn from the side, the hand supinated, and an incision about ...n long made through the skin of the floor of the axilla, a little nearer to the anterior ...n to the posterior fold of the axilla. After dissecting through the areolar tissue and ...n, the median nerve and axillary vein are exposed; these are retracted and, the elbow ...ng bent so as relax the structures, the ligature is applied. This portion of the artery ...ccasionally crossed by a muscular slip, the *axillary arch* (p. 495), derived from the ...issimus dorsi.

The *first portion* of the axillary artery may be tied in cases of aneurysm encroaching ...ar upwards that a ligature cannot be applied to the lower part of the artery. Its ...formance is attended with much difficulty and danger. The student will remark that, ...this situation, it would be necessary to divide a thick muscle, and, after incising the ...coclavicular fascia, the artery would be exposed at the bottom of a more or less deep ...e, with the cephalic and axillary veins in such relation with it as must render the ...ation of a ligature to it particularly hazardous. Under such circumstances, it is ...easier and, at the same time, a more advisable operation, to tie the third part of the ...clavian artery. The first part of the axillary artery can be best secured by a curved ...ision with the convexity downwards from a point 1·25 cm. lateral to the sterno- ...ular joint to a point 1·25 cm. on the medial side of the coracoid process. The limb ...be well abducted, and the incision carried through the superficial structures, care ...g taken of the cephalic vein at the lateral end of the incision. The clavicular origin ...the Pectoralis major is then divided in the whole extent of the wound. The arm is ...brought to the side, and the upper edge of the Pectoralis minor defined and drawn ...wards. The coracoclavicular fascia is divided, and the axillary sheath exposed; ...is to be opened with especial care on account of the vein overlapping the artery. ...e needle should be passed from below, so as to avoid wounding the vein.

CC-0. In Public Domain. Gurukul Kangri Collection, Haridwar

Digitized by Arya Samaj Foundation Chennai and eGangotri

The *second portion* of the axillary artery may be tied through an incision the junction of the middle with the lateral one-third of the clavicle, and carried wards between the Deltoideus and the clavicular part of the Pectoralis major and junction of the anterior fold of the axilla with the upper arm. These two muscles separated and the Pectoralis minor divided. The artery must be clearly defined surrounded by the large nerve-trunks.

FIG. 679.—Dissections to show (A) the third part of the axillary artery, (B) brachial artery at the middle of the arm, and (C) the brachial artery at lower part of the arm.

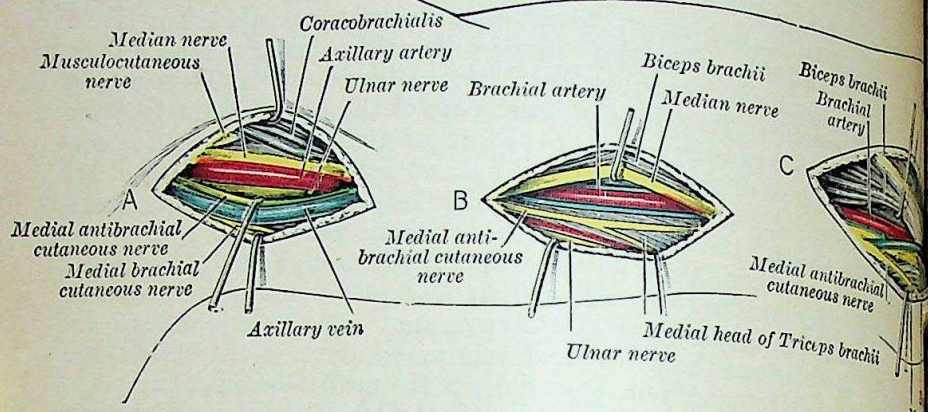

Collateral Circulation.—If the axillary artery be tied above the origin of the acromial artery, the collateral circulation will be carried on by the same branches the ligature of the third part of the subclavian (p. 635), if at a lower point, between thoraco-acromial and the subscapular arteries, the latter vessel, by its free anastomosis with the transverse scapular and transverse cervical arteries, will become the chief in carrying on the circulation; the lateral thoracic artery, if it be below the ligature, materially contribute by its anastomoses with the intercostal and internal mammary arteries. If the ligature be applied below the origin of the subscapular artery, it most probably also be below the origins of the two humeral circumflex arteries chief agents in restoring the circulation will then be the subscapular and the two humeral circumflex arteries anastomosing with the arteria profunda brachii.

The branches of the axillary artery are :

From first part 1. Highest thoracic. *From second part* { 2. Thoraco-acromial. 3. Lateral thoracic.

From third part { 4. Subscapular. 5. Anterior humeral circumflex. 6. Posterior humeral circumflex.

1. The **highest thoracic artery** (superior thoracic artery) (fig. 678) is a small vessel, which arises from the axillary artery near the lower border of the Subclavius muscle, but may take origin from the thoraco-acromial artery. Running forwards and medialwards along the upper border of the Pectoralis minor, it passes between it and the Pectoralis major to the side of the chest. It supplies branches to the muscles, and to the thoracic wall, and anastomoses with the internal mammary and intercostal arteries.

2. The **thoraco-acromial artery** (thoracic axis) (fig. 678) is a short trunk which arises from the front of the axillary artery, its origin being overlapped by the upper edge of the Pectoralis minor. Passing forwards at the upper border of this muscle, it pierces the coracoclavicular fascia and divides into four branches, pectoral, acromial, clavicular, and deltoid. The *pectoral branch* descends between the two Pectorales, and is distributed to them and to the mamma, anastomoses with the intercostal branches of the internal mammary artery and with the lateral thoracic artery. The *acromial branch* runs lateralwards over the coracoid process and under the Deltoideus, to which it gives branches; it then pierces that muscle and ends on the acromion, where it anastomoses with branches of the transverse scapular, thoraco-acromial, and posterior humeral circumflex arteries.

CC-0. In Public Domain. Gurukul Kangri Collection, Haridwar

Digitized by Arya Samaj Foundation Chennai and eGangotri

clavicular branch runs upwards and medialwards between the clavicular part of the Pectoralis major and the coracoclavicular fascia; it gives branches to the sterno-clavicular joint, and to the Subclavius. The *deltoid* or *humeral branch* often joins with the acromial branch; it crosses over the Pectoralis minor and runs with the cephalic vein between the Pectoralis major and Deltoideus, giving branches to the muscles.

The **lateral thoracic artery** (long thoracic artery) (fig. 678) follows the lower border of the Pectoralis minor to the side of the chest, supplies the Serratus anterior and the Pectorales, and sends branches to the axillary lymph-glands, and to the Subscapularis; it anastomoses with the internal mammary, subscapular, and intercostal arteries, and with the pectoral branch of the thoraco-acromial artery. In the female, the lateral thoracic artery is large, and gives off an *external mammary* branch which turns round the free edge of the Pectoralis major and supplies the mamma.

The **subscapular artery** (fig. 678), the largest branch of the axillary artery, arises from the lower border of the Subscapularis, which it follows to the inferior angle of the scapula, where it anastomoses with the lateral thoracic and intercostal arteries with the descending branch of the transverse cervical artery and ends in the surrounding muscles and adjacent part of the chest-wall. In the lower part of its course it is accompanied by the thoracodorsal nerve; about 2 in. from its origin it gives off the *scapular circumflex* artery.

Fig. 680.—The right scapular and circumflex arteries.

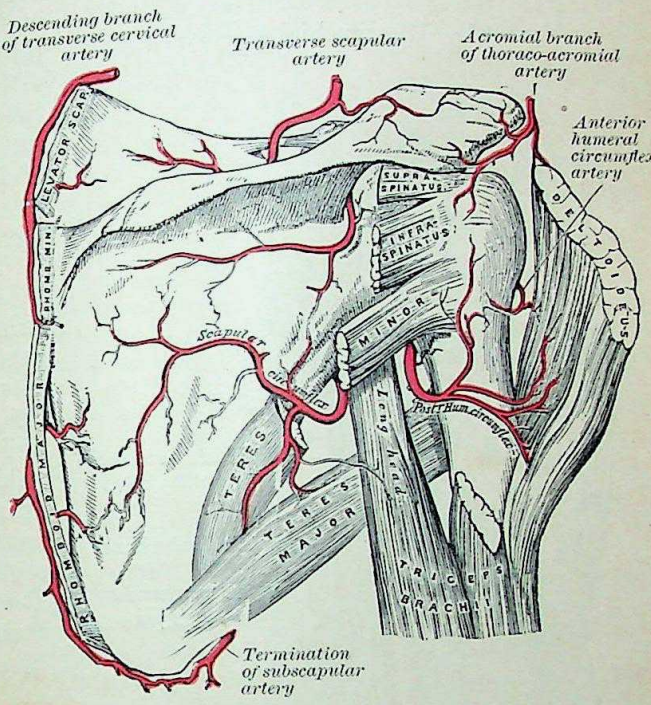

The **scapular circumflex** artery (arteria dorsalis scapulæ) is generally larger than the continuation of the subscapular. It curves round the axillary border of the scapula, traversing the triangular space between the Subscapularis above, the Teres major below, and the long head of the Triceps laterally (fig. 680); it enters the infraspinatous fossa under cover of the Teres minor, and anastomoses with the transverse scapular artery and the descending branch of the transverse cervical artery. It gives off two branches: one (*infrascapular*) enters the scapular fossa beneath the Subscapularis, which it supplies, and anastomoses with the transverse scapular artery and the descending branch of the transverse cervical artery; the other is continued along the axillary border of the scapula, between the Teres major and the Teres minor, and at the dorsal surface of the inferior angle anastomoses with the descending branch of the transverse cervical artery. In addition to these, small branches are distributed to the posterior part of the Deltoideus and the long head of the Triceps brachii, anastomosing with an ascending branch of the arteria profunda brachii.

The **anterior humeral circumflex artery** (fig. 680), a small artery, arises from the lateral side of the axillary artery at the lower border of the Subscapularis. It passes horizontally, beneath the Coracobrachialis and short head of the Biceps brachii, round the neck of the humerus. On reaching the intertubercular sulcus, it gives off a branch which ascends in the sulcus to supply the head of the humerus and the shoulder-joint. The trunk of the vessel is then continued onwards beneath the long head of the Biceps brachii and the Deltoideus, and anastomoses with the posterior humeral circumflex artery.

The **posterior humeral circumflex artery** (fig. 680), considerably larger than the anterior, arises from the axillary artery at the lower border of the Subscapularis,

CC-0. In Public Domain. Gurukul Kangri Collection, Haridwar

Digitized by Arya Samaj Foundation Chennai and eGangotri

and runs backwards with the axillary nerve through the quadrangular space by the Subscapularis, the Teres minor and the capsule of the shoulder-joint, the Teres major below, the long head of the Triceps brachii medially, and the neck of the humerus laterally. It winds round the neck of the humerus and tributes branches to the shoulder-joint, the Deltoideus, the Teretes major and the long and lateral heads of the Triceps brachii. It anastomoses anterior humeral circumflex, transverse scapular, thoraco-acromial, and brachii arteries.

Peculiarities.—The branches of the axillary artery vary considerably in subjects. One, named *alar thoracic*, and frequently derived from the second part artery, is distributed to the fat and the lymph-glands in the axilla. Occasionally subscapular, humeral circumflex, and profunda arteries arise from a common trunk; when this occurs the branches of the brachial plexus surround this trunk instead main vessel. Sometimes the axillary artery divides into the radial and ulnar and occasionally it gives origin to the volar interosseous artery of the forearm.

The Brachial Artery (figs. 681, 682, 683)

The **brachial artery** is a continuation of the axillary artery. It begins the distal border of the tendon of the Teres major, runs down the arm, ends about 1 cm. below the elbow joint by dividing into radial and ulnar arteries. At first it lies on the medial side of the humerus but, gradually passing to the front of the arm, is placed midway between the humeral epicondyles and the elbow.

Fig. 681.—The brachial artery.

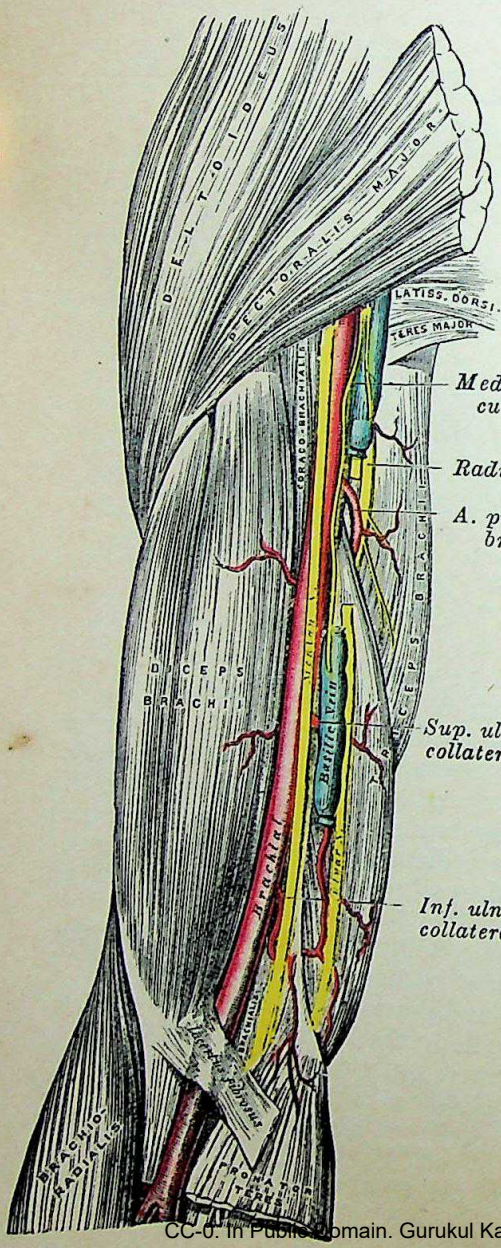

Relations.—The artery is superficial throughout its entire course being covered with the skin and superficial and deep fascia; the lacertus fibrosus (bicipital fascia) lies in front of it opposite the elbow and separates it from the median cubital vein; the median nerve crosses the artery from the lateral to the medial side opposite the insertion of the Coracobrachialis. *Posteriorly*, it is separated from the long head of the Triceps brachii by the radial nerve and arteria profunda brachii. It lies successively on the medial head of the Triceps brachii, the insertion of the Coracobrachialis, and the Brachialis. *Laterally*, it is in relation above with the median nerve and the Coracobrachialis, below with the Biceps brachii, the muscles overlapping the artery to some extent. *Medially*, its upper half is in relation with the median, antibrachial cutaneous and ulnar nerves, its lower half with the median nerve. The basilic vein lies on its medial side, but is separated from it in the lower part of the arm by the deep fascia. The artery is closely accompanied by two venæ comitantes which are connected at intervals by short transverse branches.

CC-0. In Public Domain. Gurukul Kangri Collection, Haridwar

Digitized by Arya Samaj Foundation Chennai and eGangotri

The Cubital Fossa

At the bend of the elbow the brachial artery sinks deeply into a triangular
al, the *cubital fossa*. The base of the triangle is represented by a line
ting the two humeral epicondyles; the sides are formed by the medial
of the Brachioradialis and the lateral margin of the Pronator teres; the
consists of the Brachialis and Supinator. This fossa contains the tendon
the Biceps brachii, the terminal part of the brachial artery, and its accom-
ying veins, the origins of the radial and ulnar arteries, and parts of the
dian and radial nerves. The brachial artery occupies the middle of the
and divides opposite the neck of the radius into the radial and ulnar
ries; it is covered, *in front*, by the skin, the superficial fascia, and the
dian cubital vein, the last being separated from the artery by the lacertus
rosus. *Behind* it is the Brachialis, which separates it from the elbow-joint.
e median nerve lies close to the medial side of the artery above, but is
rated from it below by the ulnar head of the Pronator teres. The tendon
the Biceps brachii is lateral to the artery; the radial nerve rests upon the
nator, and is concealed by the Brachioradialis.

Peculiarities.—The brachial artery, accompanied by the median nerve, may leave the
al border of the Biceps brachii, and descend towards the medial epicondyle of the
rus; in such cases it usually passes behind the *supracondylar process* of the humerus,
which a fibrous arch is in most cases thrown over the artery; it then runs beneath
ough the substance of the Pronator teres, to the bend of the elbow. This variation
considerable analogy with the normal condition of the artery in some of the carni-
, and has been referred to in the description of the humerus (p. 284*). Occasionally,
upper part of the artery splits into two trunks which reunite. Frequently it divides
higher level than usual, and the vessels concerned in this high division are three:
radial, ulnar, and interosseous arteries. Most frequently the radial is given off high
the other limb of the division consisting of the ulnar and interosseous; in some
ces the ulnar originates above the ordinary level, and the radial and interosseous
the other limb of the division; occasionally the interosseous arises high up.
Sometimes long slender vessels, termed *vasa aberrantia*, connect the brachial or the
ary artery with one or other of the arteries of the forearm. These vessels usually
the radial.
The brachial artery is occasionally concealed in some part of its course, by muscular
dinous slips derived from the Coracobrachialis, Biceps brachii, Brachialis, or
nator teres.

Applied Anatomy.—In spite of the fact that the brachial artery is very superficial
but little protected by surrounding parts, it is seldom wounded. This, no doubt, is
to its situation on the medial side of the arm, which is little exposed to injury.
Compression of the brachial artery is required in cases of amputation and some other
ations in the arm and forearm, and may be effected in almost any part of the course
the artery. If pressure be made in the upper part of the arm, it should be directed
rdwards; if in the lower part, backwards, as the artery lies on the medial side of
humerus above, and in front of it below. The most favourable situation is about
middle of the arm, where the artery lies on the tendon of the Coracobrachialis on the
al surface of the humerus.
Ligature of the brachial artery may be required in cases of wound of the vessel, and in
e cases of wound of the volar arch where an extensive dissection might be required to
e the bleeding point in the hand. It is also sometimes necessary in cases of
ysm of the brachial, radial, ulnar, or interosseous arteries. The artery may be
ed in any part of its course. The chief guides in determining its position are the
e markings produced by the medial margins of the Coracobrachialis and Biceps
hii, and the known course of the vessel; its pulsation should be carefully felt for
re any operation is performed, as the vessel occasionally deviates from its usual
ion. It is essential in applying a ligature to this vessel that the arm should be held
er from the side of the body, and supported only from the elbow, for if the arm be
ed to rest on any firm structure the Triceps brachii is pressed forwards and overlaps
vessel, thus making the operation much more difficult.
the upper third of the arm the brachial artery may be exposed in the following
er. The patient being placed supine, the limb should be raised from the side, and
and supinated. An incision about 5 cm. in length is made on the medial side of the
ochialis (fig. 682), and the subjacent fascia cautiously divided, so as to avoid
ing the medial antibrachial cutaneous nerve or basilic vein, as the latter some-
runs on the surface of the artery as high as the axilla. The fascia having been
d, it should be remembered that the ulnar nerve and the medial antibrachial
nerve lie on the medial side of the artery, the median nerve on the lateral side

CC-0. In Public Domain. Gurukul Kangri Collection, Haridwar

Digitized by Arya Samaj Foundation Chennai and eGangotri

but occasionally superficial to the artery in this situation, and that the venæ comitantes are also in relation with the vessel, one on either side. These being carefully [illegible]

FIG. 682.—A transverse section through the arm at the junction of the proximal with the intermediate one-third of the humerus.

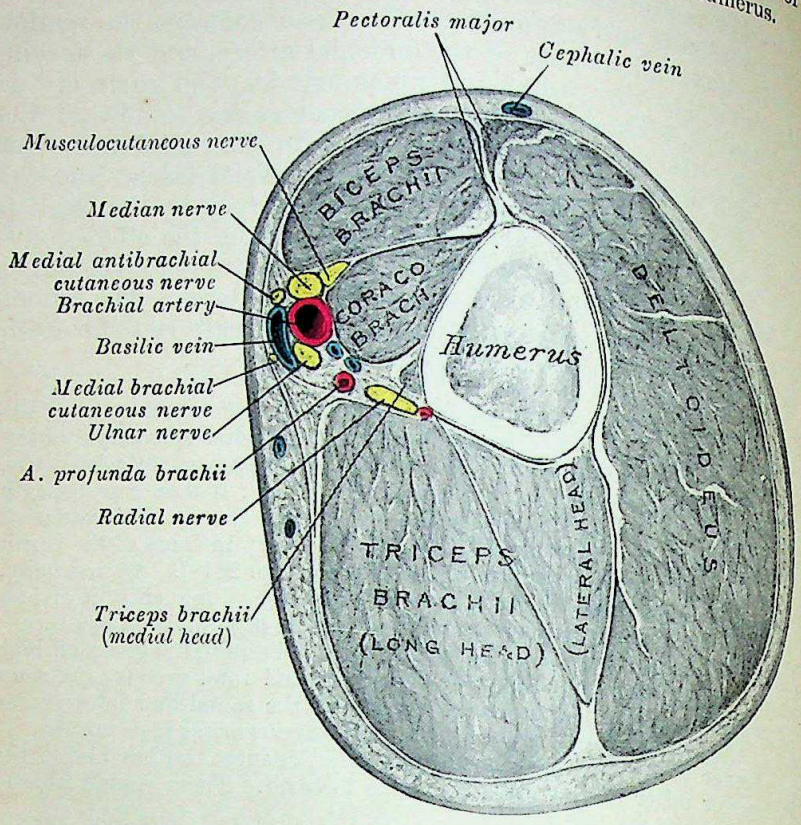

FIG. 683.—A transverse section through the arm, a little below the middle of the body of the humerus.

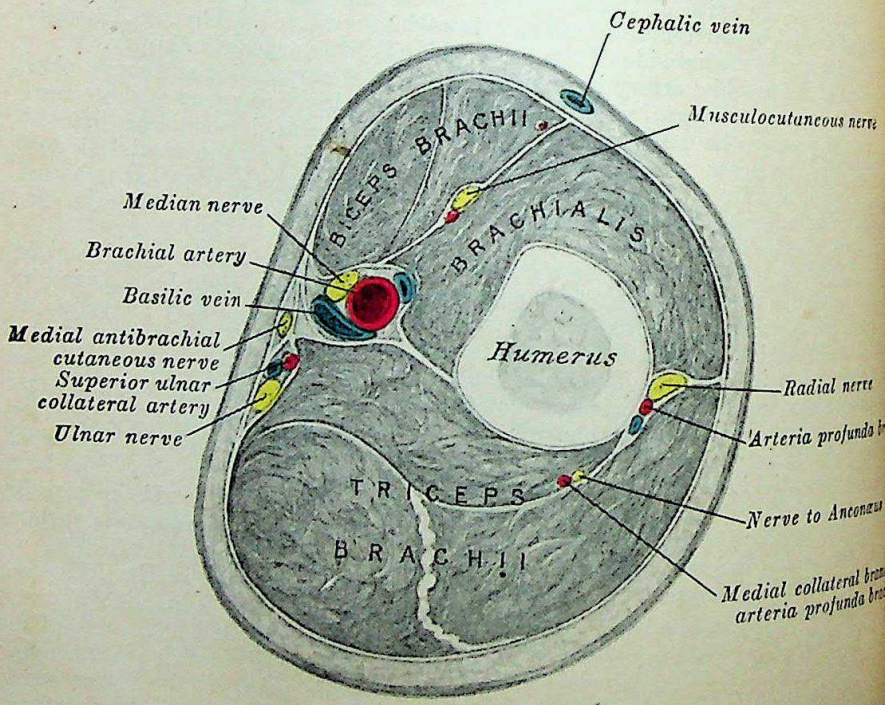

the aneurysm needle should be passed round the artery from the medial side so as to avoid injuring the basilic vein.

CC-0. In Public Domain. Gurukul Kangri Collection, Haridwar

Digitized by Arya Samaj Foundation Chennai and eGangotri

In the case of a high division, the two arteries are usually placed side by side; and they are exposed in an operation, the surgeon should endeavour to ascertain, by alternately pressing on each vessel, which is connected with the wound or aneurysm, when a pulse may be applied accordingly; if pulsation or hæmorrhage ceases only when both are compressed, both must be tied.

In the middle of the arm the brachial artery may be exposed by making an incision along the medial margin of the Biceps brachii (fig. 679, B). The forearm is then bent so as to relax this muscle which should be drawn aside, and the fascia carefully divided, when the median nerve will be exposed lying upon (sometimes behind) the artery; the nerve being drawn medialwards and the muscle lateralwards, the artery should be separated from its accompanying veins and secured. In this situation the superior ulnar collateral artery (inferior profunda artery) may be mistaken for the main trunk, especially if enlarged

FIG. 684.—A transverse section through the arm, 2 cm. proximal to the medial epicondyle of the humerus.

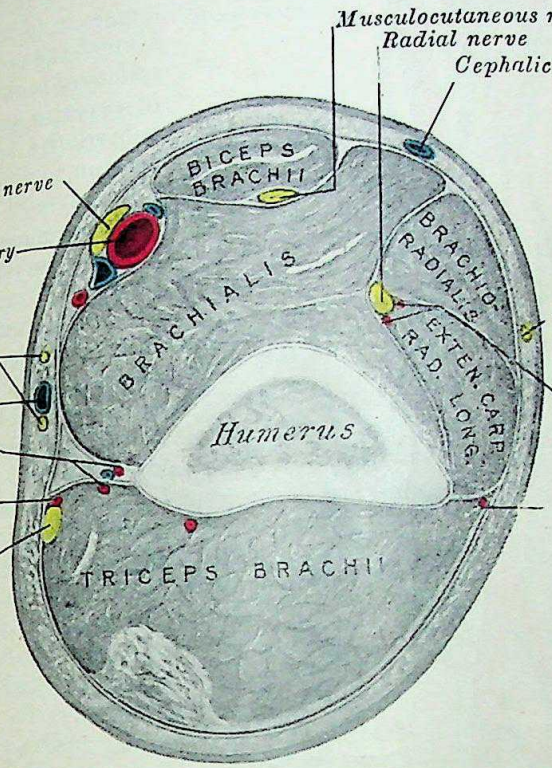

on the collateral circulation having become established; this may be avoided by directing the incision towards the Biceps brachii, rather than towards the Triceps brachii.

The lower part of the brachial artery (fig. 679, C) is of interest on account of the relation it bears to the veins most commonly opened in venesection. Of these vessels, the median basilic vein (median basilic vein) is the largest and most prominent, and consequently is one usually selected for the operation. This vein runs parallel with the brachial artery, from which it is separated by the lacertus fibrosus (bicipital fascia), and care should be taken, in opening the vein, not to carry the incision so deep as to endanger the artery.

Collateral Circulation.—After the application of a ligature to the brachial artery in the upper third of the arm, the circulation is carried on by branches from the humeral circumflex and subscapular arteries anastomosing with ascending branches from the arteria profunda brachii. If the artery be tied below the origins of the arteria profunda brachii and the superior ulnar collateral artery, the circulation is maintained through the anastomoses around the elbow-joint (p. 652).

The branches of the brachial artery are:

1. Arteria profunda brachii
2. Nutrient.
3. Superior ulnar collateral.
4. Inferior ulnar collateral.
5. Muscular.

1. The **arteria profunda brachii** (superior profunda artery) (figs. 681, 683) is a large vessel which arises from the medial and posterior part of the brachial artery,

CC-0. In Public Domain. Gurukul Kangri Collection, Haridwar

Digitized by Arya Samaj Foundation Chennai and eGangotri

just distal to the lower border of the Teres major. It follows closely the nerve, running at first backwards between the long and medial heads of the brachii, then along the sulcus for the radial nerve, where it is covered by the head of the Triceps brachii. Reaching the lateral side of the arm, it pierces the lateral intermuscular septum, and, descending between the Brachioradialis and Brachialis to the front of the lateral epicondyle of the humerus, ends by anastomosing with the radial recurrent artery. It gives branches to the Deltoideus and muscles between which it lies; it supplies an occasional *nutrient artery* which enters the humerus behind the deltoid tuberosity. A branch ascends between the medial and lateral heads of the Triceps brachii to anastomose with the posterior circumflex artery; a second *lateral branch* descends to the medial head of the Triceps brachii with the nerve; it supplies the Anconeus and assists in forming the anastomosis above the olecranon; a third *collateral branch* (posterior branch of superior profunda) runs behind the lateral intermuscular septum to the back of the lateral epicondyle of the humerus, where it anastomoses with the interosseous recurrent and the inferior ulnar collateral arteries.

Fig. 685.—A diagram of the arterial anastomosis around the elbow-joint.

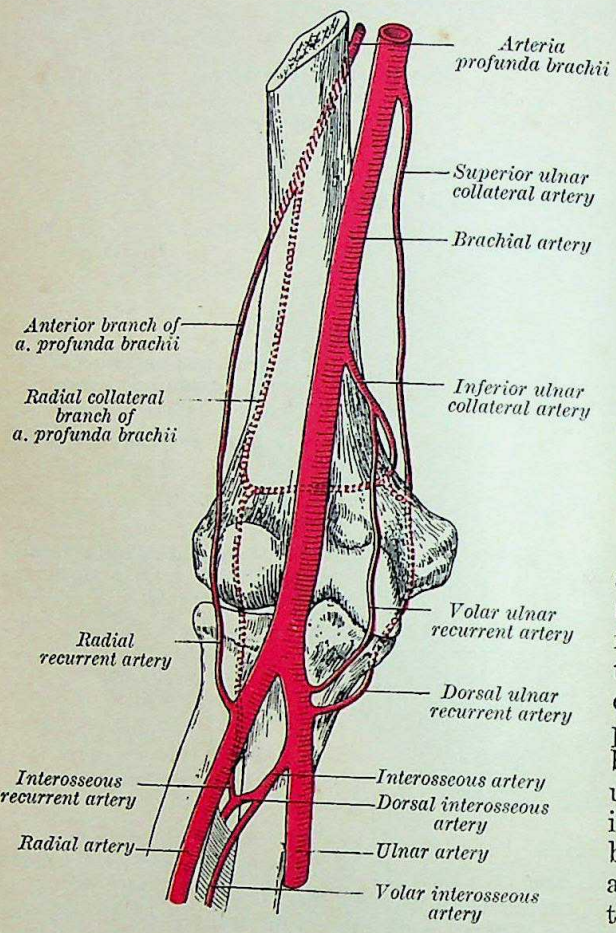

2. The **nutrient artery** of the humerus arises about the middle of the arm; it enters the nutrient canal near the insertion of the Coracobrachialis, and is directed downwards.

3. The **superior ulnar collateral artery** (inferior profunda artery) (figs. 681, 683), of small size, arises from the brachial a little below the middle of the arm; it frequently springs from the common part of the arteria profunda brachii. It accompanies the ulnar nerve, pierces the medial intermuscular septum, descends between the medial epicondyle and the olecranon, and ends under the Flexor carpi ulnaris by anastomosing with the dorsal ulnar recurrent and inferior ulnar collateral arteries. It sometimes sends a branch in front of the medial epicondyle, to anastomose with the volar ulnar recurrent artery.

4. The **inferior ulnar collateral artery** (arteria anastomotica magna) (figs. 681, 683) arises about 5 cm. above the elbow. It passes medialwards upon the Brachialis and, piercing the medial intermuscular septum, winds round the back of the humerus between the Triceps brachii and the bone, forming, by its junction with the superior profunda brachii, an arch above the olecranon fossa. As the vessel lies on the Brachialis, it gives off branches which ascend to join the superior ulnar collateral artery; others descend in front of the medial epicondyle, to anastomose with the volar ulnar recurrent artery. Behind the medial epicondyle a branch anastomoses with the superior ulnar collateral and dorsal ulnar recurrent arteries.

5. The **muscular branches,** three or four in number, are distributed to the Coracobrachialis, Biceps brachii, and Brachialis.

The **anastomosis around the elbow-joint** (fig. 685.)—The vessels engaged in the anastomosis may be conveniently divided into those situated *in front* of, and those *behind* the medial and lateral epicondyles of the humerus. The branches anastomosing *in front* of the medial epicondyle are: the anterior branches of

CC-0. In Public Domain. Gurukul Kangri Collection, Haridwar

Digitized by Arya Samaj Foundation Chennai and eGangotri

...or and inferior ulnar collateral arteries and the volar ulnar recurrent artery. ...se *behind* the medial epicondyle are: the superior and inferior ulnar collateral ...ries and the dorsal ulnar recur- ... artery. The branches ana- ...ssing *in front* of the lateral ...ndyle are: the terminal part ...the arteria profunda brachii and ... radial recurrent artery. Those ... the lateral epicondyle are: ... radial collateral branch (pos- ...r branch) of the arteria pro- ...da brachii, the inferior ulnar ...teral, and interosseous recur- ... arteries. There is also an arch ...anastomosis above the olecra- ... formed by the inferior ulnar ...teral artery joining with the ...le and radial collateral branches ...the arteria profunda brachii, and ... the interosseous recurrent and ...orsal ulnar recurrent arteries ...85).

Fig. 686.—The right radial and ulnar arteries. Superficial dissection.

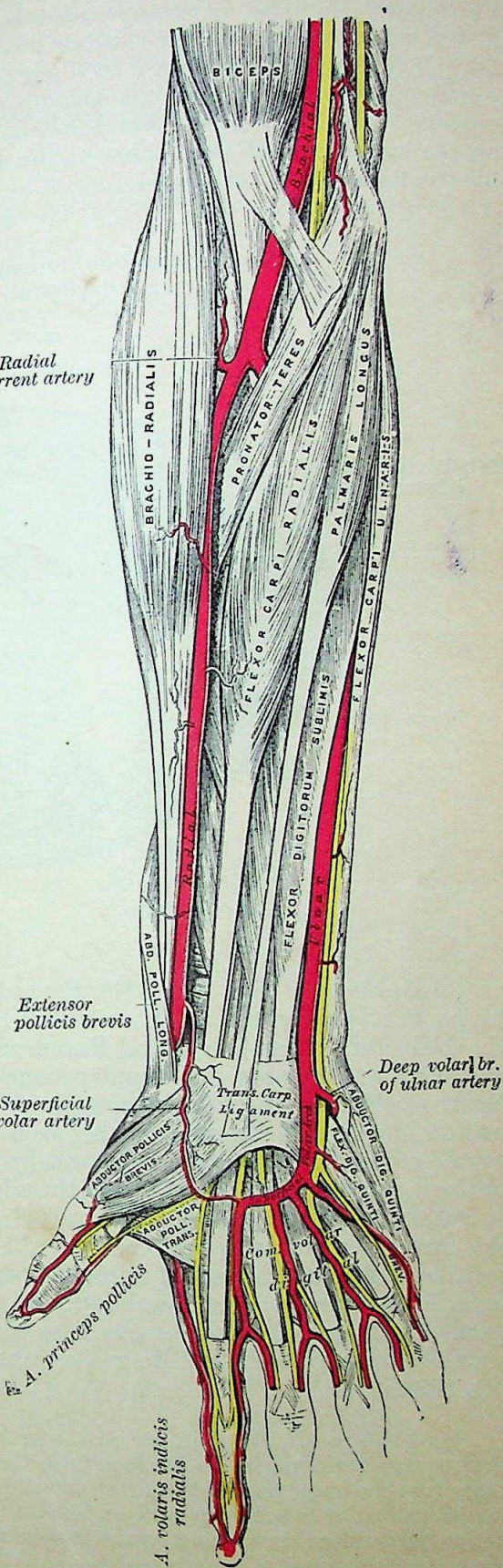

The Radial Artery
(figs. 686, 687, 689)

The **radial artery**, though ...ller than the ulnar artery, ...pears, from its course, to be the ...re direct continuation of the ...chial trunk. It begins at the ...sion of the brachial, about ...cm. below the bend of the ...ow, and passes along the radial ... of the forearm to the wrist. ...then winds backwards, round ... lateral side of the carpus, ...der cover of the tendons of the ...ductor pollicis longus and ...tensores pollicis brevis et longus ...the proximal end of the space ...ween the first and second ...acarpal bones where it passes ...wards between the two heads ...the first Interosseus dorsalis, ...to the palm of the hand; it ...sses towards the ulnar side of ...e palm, and unites with the ...ep volar branch of the ulnar ...ery to form the deep volar arch. ...e radial artery is therefore divi- ...ble into three portions, one in ...e forearm, a second at the wrist, ...d a third in the hand.

Relations.—(*a*) *In the forearm* ...686, 687 692), the radial ...ry extends from the neck of the ...s to the front part of its styloid ...cess, being placed to the medial ...e of the body of the bone above, ...d in front of it below. Its upper ...rt is overlapped by the fleshy belly of the Brachioradialis; the rest of the ...ery is only covered with the skin, and the superficial and deep fasciæ. It lies

CC-0. In Public Domain. Gurukul Kangri Collection, Haridwar

Digitized by Arya Samaj Foundation Chennai and eGangotri

successively upon the tendon of the Biceps brachii, the Supinator, the in the Pronator teres, the radial origin of the Flexor digitorum sublimis, the pollicis longus, the Pronator quadratus, and the lower end of the radius. upper one-third of its course it is placed between the Brachioradialis and the teres; in the lower two-thirds, between the tendons of the Brachioradialis Flexor carpi radialis. The superficial branch of the radial nerve is close lateral side of the middle one-third of the artery; and some filaments of the antibrachial cutaneous nerve run along the lower part of the artery as round the wrist. The artery is accompanied by a pair of venæ comitantes portion of the radial artery which lies in front of the lower end of the radius on the lateral side of the tendon of the Flexor carpi radialis is used clinically observations on the pulse.

Fig. 687.—A transverse section through the forearm at the level of the radial (bicipital) tuberosity.

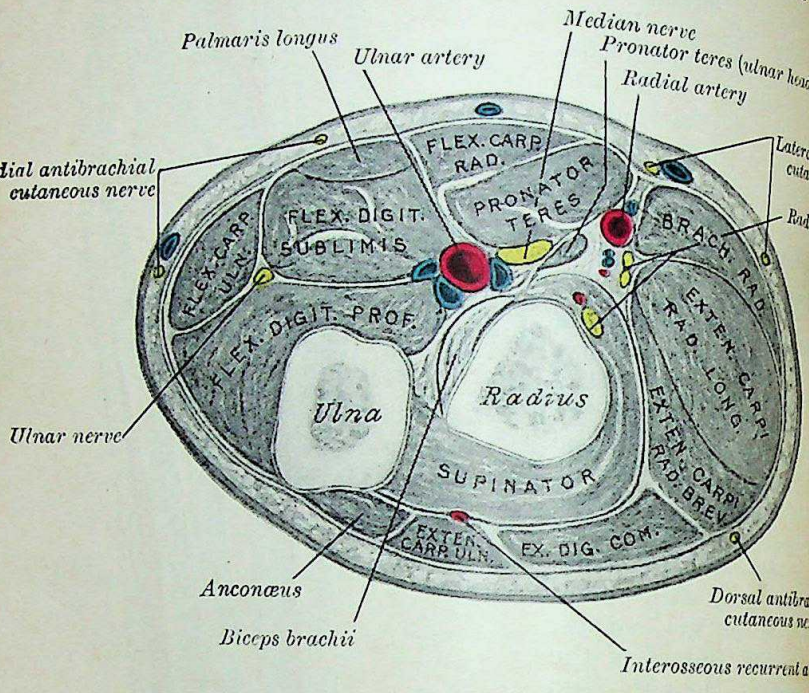

(*b*) *At the wrist* (figs. 690, 691), the radial artery reaches the back of the wrist by passing between the radial collateral ligament of the wrist and the tendons of the Abductor pollicis longus and Extensor pollicis brevis. It then descends on the navicular and greater multangular bones, and before disappearing between the heads of the first Interosseus dorsalis is crossed by the tendon of the Extensor pollicis longus. In the interval between the two Extensores pollicis it is crossed by the origin of the cephalic vein, and by the digital rami of the superficial branch of the radial nerve, which go to the thumb and index finger.

(*c*) *In the hand* (fig. 689), the radial artery passes from the proximal end of the first interosseous space, between the heads of the first Interosseus dorsalis, transversely across the palm; it lies at first beneath the oblique part of the Adductor pollicis, then runs between the oblique and transverse parts, or through the transverse part, of that muscle, and, at the base of the fifth metacarpal bone, anastomoses with the deep volar branch from the ulnar artery, completing the *deep volar arch* (fig. 689).

Peculiarities.—In about 12 per cent. of subjects the origin of the radial artery is higher than usual; it then arises more often from the axillary or upper part of the brachial than from the lower part of the latter vessel. In the forearm it sometimes lies on the fascia instead of beneath it, and on the surface of the Brachioradialis instead of on its medial border; in turning round the wrist, it occasionally lies on, instead of beneath, the extensor tendons of the thumb.

Applied Anatomy.—The radial artery is much exposed to injury in its lower course and is frequently wounded; the injury may be followed by a traumatic aneurysm.

CC-0. In Public Domain. Gurukul Kangri Collection, Haridwar

Digitized by Arya Samaj Foundation Chennai and eGangotri

ligature of the radial artery is required in cases of wounds either of its trunk, or of its branches, or for aneurysm.

To tie the artery in the proximal one-third of the forearm (fig. 688, B), an incision 7 or long should be made through the skin, in a line drawn from the centre of the bend elbow to the front of the styloid process of the radius, avoiding the branches of dial antibrachial vein; when the fascia of the arm is divided, and the Brachioradialis aside, the artery will be exposed. The venæ comitantes should be separated from vessel and the ligature passed from the radial to the ulnar side.

In the middle one-third of the forearm the artery may be exposed by making an incision similar length on the medial border of the Brachioradialis. In this situation, the superpart of the radial nerve lies in close relation with the lateral side of the artery, and d be avoided.

In the distal one-third of the forearm (fig. 688, C) the artery is easily secured by dividing skin and fascia between the tendons of the Brachioradialis and Flexor carpi radialis. n operating on the cadaver, students are apt to forget how near to the surface the artery this situation.

FIG. 688.—Dissections to show the radial and median nerves, and the radial and ulnar arteries.

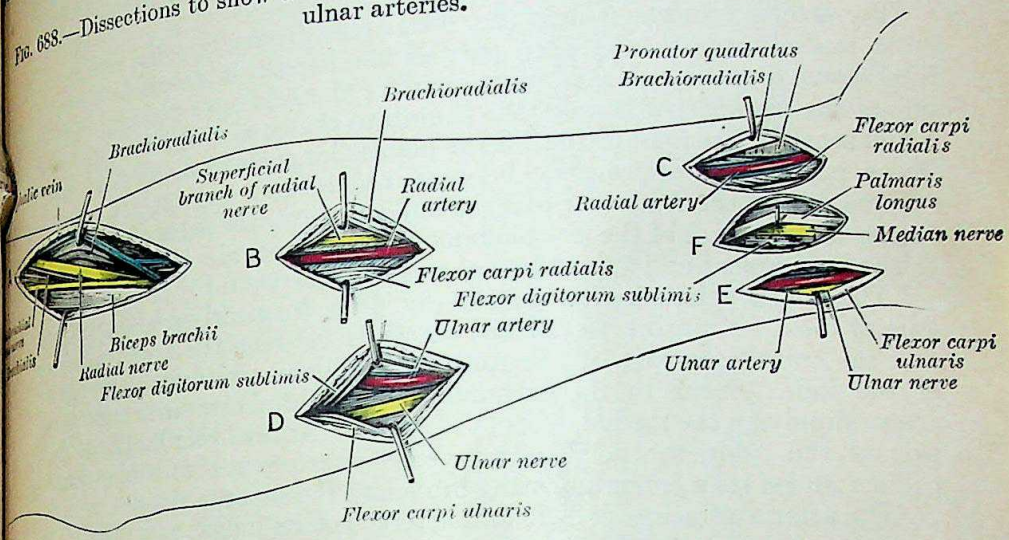

The branches of the radial artery may be divided into three groups, corresponding with the three regions in which the vessel is situated.

In the forearm.	*At the wrist.*	*In the hand.*
Radial recurrent.	Dorsal carpal.	Princeps pollicis.
Muscular.	First dorsal metacarpal.	Volaris indicis radialis.
Volar carpal.		
Superficial volar.		

The **radial recurrent artery** arises immediately below the elbow. It passes between the branches of the radial nerve, and ascends beneath the Brachioradialis, lying on the Supinator and Brachialis; it supplies these muscles and the elbow-joint, and anastomoses with the anterior terminal part of the arteria profunda brachii.

The **muscular branches** are distributed to the muscles on the radial side of the forearm.

The **volar carpal branch** is a small vessel which arises near the lower border of the Pronator quadratus, and, running across the volar surface of the carpus, anastomoses under cover of the flexor tendons, with the volar carpal branch of the ulnar artery. This anastomosis is joined by a branch from the volar interosseous artery, and by recurrent branches from the deep volar arch, thus forming a *volar carpal network* which supplies the articulations of the wrist and carpus.

The **superficial volar branch** (fig. 686) arises from the radial artery, where this vessel is about to wind round the lateral side of the wrist. Running forwards, it passes through, occasionally over, the muscles of the ball of the thumb, which it supplies, and sometimes anastomoses with the terminal portion of the ulnar artery completing the superficial volar arch. This vessel varies considerably in size: usually it is very small, and ends in the muscles of the thumb; sometimes it is as large as the continuation of the radial artery.

CC-0. In Public Domain. Gurukul Kangri Collection, Haridwar

Digitized by Arya Samaj Foundation Chennai and eGangotri

The **dorsal carpal branch** (fig. 693) is a small vessel which arises beneath the extensor tendons of the thumb, and, running across the dorsal surface of the carpus under cover of the extensor tendons, anastomoses with the dorsal carpal branch of the ulnar artery, and with the volar and dorsal interosseous arteries, to form the *dorsal carpal network*. Arising from this network are three slender *dorsal metacarpal arteries*, which descend on the second, third, and fourth Interossei dorsales, and bifurcate into dorsal digital branches for the supply of the adjacent sides of the index, middle, ring, and little fingers; they anastomose with the proper digital branches of the superficial volar arch; near their origins they anastomose with the deep volar arch by the *superior perforating arteries*, and near their bifurcation with the common volar digital vessels of the superficial volar arch by the *inferior perforating arteries*.

The **first dorsal metacarpal artery** (fig. 693) arises just before the radial artery passes between the two heads of the first Interosseus dorsalis, and divides immediately into two branches which supply the adjacent sides of the thumb and index finger; the radial side of the thumb receives a branch directly from the radial artery.

The **arteria princeps pollicis** (fig. 689) arises from the radial artery as the latter turns medialwards to the deep part of the hand; it descends between the first Interosseus dorsalis and the oblique part of the Adductor pollicis, along the medial side of the metacarpal bone of the thumb to the base of the first phalanx, where it lies beneath the tendon of the Flexor pollicis longus and divides into two branches. These make their appearance between the medial and lateral insertions of the oblique part of the Adductor pollicis, and run along the sides of the thumb, forming on the volar surface of the last phalanx an arch, from which branches are distributed to the integument and subcutaneous tissue of the thumb.

The **arteria volaris indicis radialis** (fig. 689), frequently a branch of the proper part of the arteria princeps pollicis, descends between the first Interosseus dorsalis and the transverse part of the Adductor pollicis, and runs along the lateral side of the index finger to its extremity: it anastomoses with the proper digital artery supplying the medial side of the finger. At the lower border of the transverse part of the Adductor pollicis this vessel anastomoses with the arteria princeps pollicis, and gives a communicating branch to the superficial volar arch.

The arteria princeps pollicis and arteria volaris indicis radialis may spring by a common trunk which is named the *first volar metacarpal artery*.

The **deep volar arch** (deep palmar arch) (fig. 689) is formed by the anastomosis of the terminal part of the radial artery with the deep volar branch of the ulnar artery. It lies upon the proximal ends of the metacarpal bones and on the Interossei and is covered by the oblique part of the Adductor pollicis, the flexor tendons of the fingers, and the Lumbricales. Alongside of it, but running towards the lateral side of the hand, is the deep branch of the ulnar nerve.

The branches of the deep volar arch are: volar metacarpal, perforating, and recurrent.

The **volar metacarpal arteries** (fig. 689), three in number, arise from the concavity of the deep volar arch; they run distally upon the Interossei of the second, third and fourth spaces, and join, at the clefts of the fingers, the common digital branches of the superficial volar arch.

The **perforating branches,** three in number, pass backwards from the deep volar arch, through the second, third, and fourth interosseous spaces and between the heads of the corresponding Interossei dorsales, to anastomose with the dorsal metacarpal arteries.

The **recurrent branches** arise from the concavity of the deep volar arch, and ascend in front of the wrist, supply the intercarpal articulations, and end in the volar carpal network.

The Ulnar Artery (figs. 686, 689, 692)

The **ulnar artery**, the larger of the two terminal branches of the brachial artery, begins about 1 cm. below the bend of the elbow, and, passing obliquely downwards, reaches the medial side of the forearm at a point about midway between the elbow and the wrist. It then runs along the medial side of the wrist, crosses the transverse carpal ligament on the lateral side of the pisiform

CC-0. In Public Domain. Gurukul Kangri Collection, Haridwar

Digitized by Arya Samaj Foundation Chennai and eGangotri

and immediately beyond this bone divides into two branches, which into the formation of the superficial and deep volar arches.

Relations.—(*a*) *In the forearm.*—The *proximal half* of the vessel (figs. 686, 687) deeply seated, passing obliquely under cover of the Pronator teres, Flexor carpi alis, Palmaris longus, and xor digitorum sublimis to the dial side of the forearm, where is overlapped by the Flexor ris ulnaris; it lies upon the ris and the Flexor digi- orum profundus. The median ve is on the medial side of e artery for about 2·5 cm. and en crosses the vessel, but is arated from it by the ulnar d of the Pronator teres. The *ddle half* (figs. 686, 692) lies upon e Flexor digitorum profundus; is covered by the skin, super- al and deep fasciæ, and is ed between the Flexor carpi aris and Flexor digitorum limis.

It is accompanied by two ne comitantes, and is over- ped in its middle one-third the Flexor carpi ulnaris; the ar nerve lies on the medial de of the lower two-thirds of e artery, and the palmar aneous branch of this nerve ends on the distal part of the essel to the palm of the hand.

(*b*) *At the wrist* (figs. 689, 690, 691) the ulnar artery is covered the skin and the volar carpal ament, and lies upon the trans- rse carpal ligament. On its dial side are the pisiform bone d the ulnar nerve.

Peculiarities.—The ulnar artery ries in its origin in about 8 per nt. of cases; it frequently arises ove the elbow, the brachial being re often the source of origin than e axillary. When its origin is rmal, the course of the vessel is ndy changed. When the artery ves high up, it is usually super- al to the flexor muscles in the earm, lying commonly beneath e fascia more rarely between the scia and skin; the brachial artery ion gives off the common inter- seous artery, and the latter, the terior and posterior ulnar recur- nt arteries. Occasionally it is pcutaneous in the upper part of the forearm, and subaponeurotic in the lower

Fig. 689.—The right radial and ulnar arteries. Deep dissection.

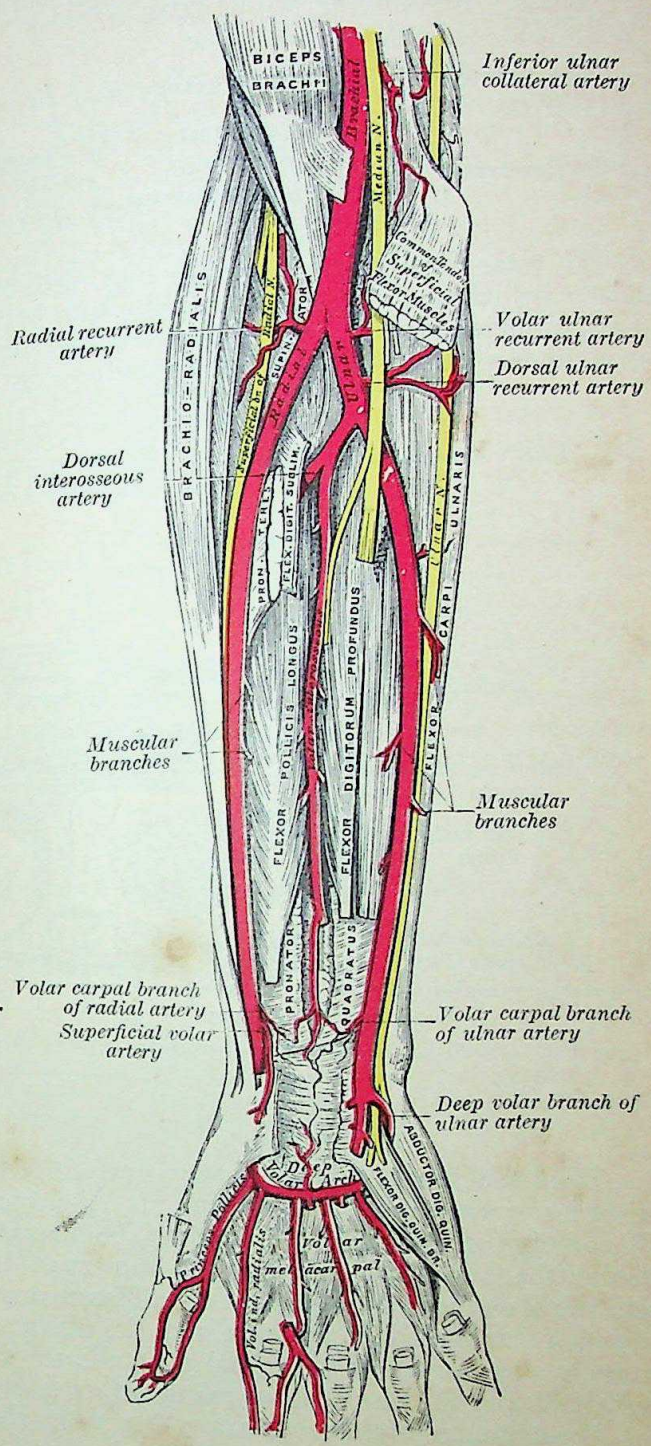

When the ulnar artery is superficial there is some danger of its being wounded in opening the median cubital vein for the purpose of transfusing blood or injecting saline solution.

Applied Anatomy.—Ligature of the ulnar artery (fig. 688, D) in the upper one-half of the forearm is difficult as this part of the vessel is deeply seated beneath the superficial flexor muscles. An incision is to be made in the course of a line drawn from the front of the medial epicondyle of the humerus to the lateral side of the pisiform bone, so that

CC-0. In Public Domain. Gurukul Kangri Collection, Haridwar

Digitized by Arya Samaj Foundation Chennai and eGangotri

the centre of the incision is three fingers' breadths below the medial epicondyle. T and superficial fascia having been divided, and the deep fascia exposed, the w which separates the Flexor carpi ulnaris from the other flexor muscles is to be so and the fascia incised in this line. On separating the Flexor carpi ulnaris from th muscles the ulnar nerve will be exposed lying on the Flexor digitorum profund must be drawn aside. The artery, accompanied by its venæ comitantes, lies b the nerve. In the middle and lower parts (fig. 688, E) of the forearm, the artery secured easily by making an incision on the radial side of the tendon of the Flex ulnaris: when the deep fascia is divided, and the tendon separated from the Flex torum sublimis, the artery and its venæ comitantes will be exposed, lying lateral ulnar nerve.

The branches of the ulnar artery may be arranged in the following gr

In the forearm
- Anterior recurrent.
- Posterior recurrent.
- Common interosseous.
- Muscular.

At the wrist
- Volar carpal.
- Dorsal carpal.

In the hand
- Deep volar.
- Superficial volar a

The **volar ulnar recurrent artery** (figs. 685, 689), a small branch, arises diately below the elbow-joint, runs upwards between the Brachialis and Pr teres, supplies twigs to those muscles, and, in front of the medial epico anastomoses with the superior and inferior ulnar collateral arteries.

Fig. 690.—A transverse section through the distal ends of the left radius and ulna. Superior aspect.

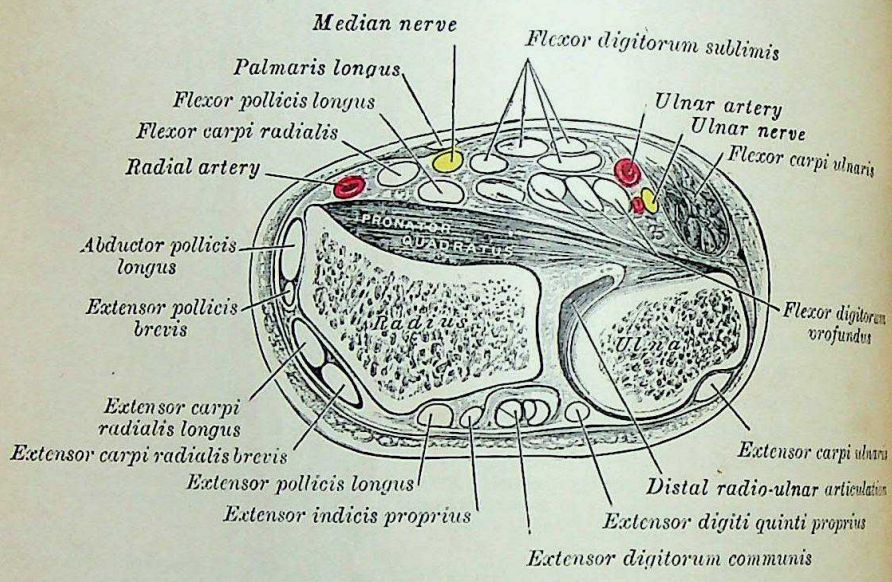

The **dorsal ulnar recurrent artery** (figs. 685, 689) is much larger, and arises what lower than the volar artery. It passes backwards and medialwards on Flexor digitorum profundus, behind the Flexor digitorum sublimis, and asc behind the medial epicondyle of the humerus. In the interval between this p and the olecranon, it lies beneath the Flexor carpi ulnaris, and ascends betwee heads of this muscle, in relation with the ulnar nerve; it supplies the neighb muscles and the elbow-joint, and anastomoses with the superior and inferior collateral and the interosseous recurrent arteries (fig. 693).

The **common interosseous artery** (fig. 689), about 1 cm. in length, arises imm ately below the tuberosity of the radius, and, passing backwards to the up border of the antibrachial interosseous membrane, divides into two branches, *volar* and *dorsal interosseous arteries*.

The **volar interosseous artery** (figs. 689, 692) descends on the volar surface of antibrachial interosseous membrane, accompanied by the volar interosseous br of the median nerve, and overlapped by the contiguous margins of the Fl digitorum profundus and Flexor pollicis longus; it gives off *muscular* branches, the *nutrient* arteries of the radius and ulna. At the upper border of the Pron quadratus it pierces the interosseous membrane and reaches the back of the forea

CC-0. In Public Domain. Gurukul Kangri Collection, Haridwar

Digitized by Arya Samaj Foundation Chennai and eGangotri

ow it anastomoses with the dorsal interosseous artery and descends on the back of wrist in the compartment of the dorsal carpal ligament containing the tendons the Extensor digitorum communis and Extensor indicis proprius, and joins orsal carpal network. The volar interosseous artery gives off a slender branch,

FIG. 691.—A transverse section through the left wrist. Superior aspect.

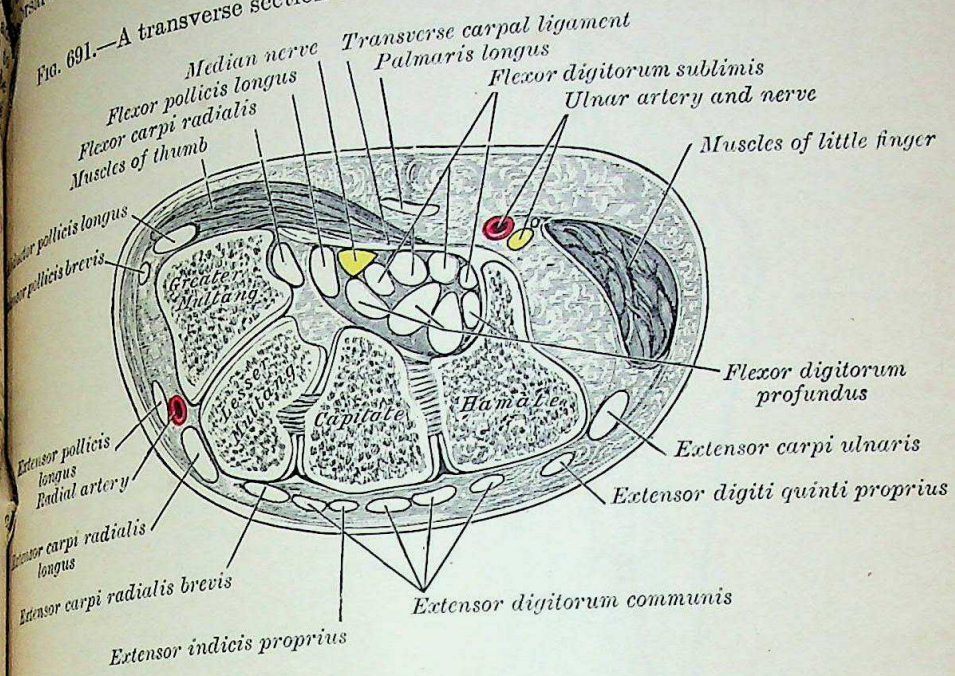

e arteria mediana, which accompanies the median nerve, and sends offsets to substance; this artery is sometimes much enlarged, and runs with the median ve into the palm of the hand. Before the volar interosseous artery pierces the rosseous membrane, it sends a branch downwards behind the Pronator uadratus to join the volar carpal network.

FIG. 692.—A transverse section through the middle of the forearm.

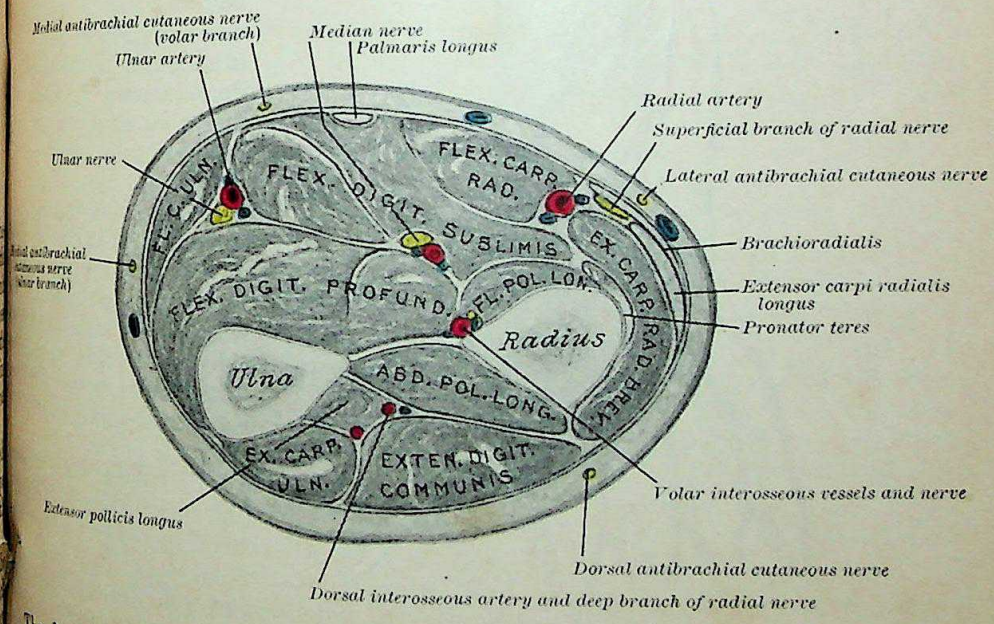

The **dorsal interosseous artery** (figs. 692, 693), usually smaller than the volar interosseous artery, passes backwards between the oblique cord and the upper border of the antibrachial interosseous membrane. It appears on the back of the forearm between the contiguous borders of the Supinator and the Abductor

CC-0. In Public Domain. Gurukul Kangri Collection, Haridwar

Digitized by Arya Samaj Foundation Chennai and eGangotri

pollicis longus, and descends between the superficial and deep layers of ... to both of which it distributes branches. As it lies upon the Abductor ... longus, it is accompanied by the deep branch of the radial nerve. At the ... part of the forearm ... stomoses with the ... of the volar ... artery, and with the ... carpal network. ... off, near its origin, the ... osseous recurrent artery ... ascends to the ... tween the lateral ... and olecranon, on or ... the fibres of the ... but beneath the ... and anastomoses ... radial collateral ... the arteria profunda ... the dorsal ulnar ... and the inferior ulnar ... lateral arteries.

FIG. 693.—The arteries of the dorsal surface of the right forearm and hand.

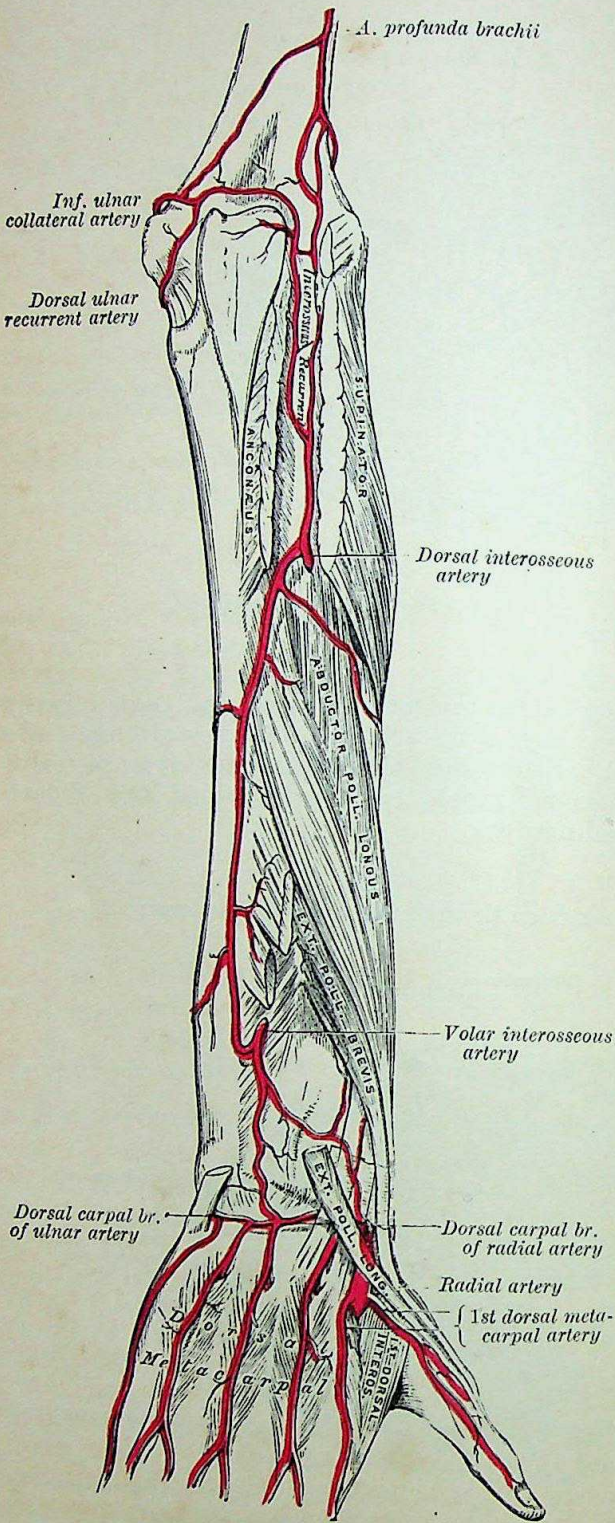

The **muscular** branches are distributed to the ... along the ulnar side of ... forearm.

The **volar carpal** branch is a small vessel which ... the front of the carpus ... the tendons of the ... digitorum profundus; it ... stomoses with the ... carpal branch of the ... artery, and assists in forming the volar carpal network.

The **dorsal carpal** branch arises immediately ... the pisiform bone, and ... backwards beneath the ... don of the Flexor ... ulnaris; it passes across ... dorsal surface of the carpus under cover of the extensor tendons, anastomoses ... the dorsal carpal branch ... the radial artery, and assists in forming the dorsal carpal network. Near its ... it gives off a small branch which runs along the ... side of the fifth metacarpal bone, and supplies the ... side of the dorsal surface ... the little finger.

The **deep volar** branch (fig. 689) passes between ... Abductor digiti quinti ... Flexor digiti quinti brevis ... and through the origin ... the Opponens digiti quinti; it anastomoses with the radial artery, and completes the deep volar arch.

The **superficial volar arch** (superficial palmar arch) (fig. 686) is formed ... by the ulnar artery, and is usually completed by a branch from the arteria volaris indicis radialis, but sometimes by the superficial volar artery or by a branch from ...

CC-0. In Public Domain. Gurukul Kangri Collection, Haridwar

Digitized by Arya Samaj Foundation Chennai and eGangotri

princeps pollicis. The arch passes across the palm, describing a curve, its convexity downwards.

Relations.—It lies upon the transverse carpal ligament, the Flexor digiti quinti of the flexor tendons, the Lumbricales, and the branches of the median nerve.

Branches.—The **common volar digital arteries** (fig. 686) arise from the convexity of the superficial volar arch and proceed downwards on the second, third, and fourth interosseoi, Each is joined by the corresponding volar metacarpal artery, and divides into a pair of *proper volar digital arteries* which run along the contiguous sides of the index, middle, ring, and little fingers, behind the corresponding digital arteries; they anastomose freely in the subcutaneous tissue of the finger tips and give smaller branches near the interphalangeal joints. Each gives off two dorsal branches which anastomose with the dorsal digital arteries, and supply the soft parts on the back of the second and third phalanges, including the matrix of the nail. The proper volar digital artery for the medial side of the little finger arises from the ulnar artery under cover of the Palmaris brevis.

Applied Anatomy.—Wounds of the volar arches are always difficult to deal with. When the superficial arch is involved it is generally possible (enlarging the wound when necessary) to secure the vessel and tie it on both sides of the bleeding point; or in cases where it is found impossible to encircle the vessel with a ligature, a pair of artery clips may be applied and left on for twenty-four or forty-eight hours. Failing this, the wound may be plugged with gauze and an outside dressing carefully bandaged on. The plug should remain undisturbed for three or four days. It is useless in these cases to ligature one of the arteries of the forearm alone, and simultaneous ligature of both radial and ulnar arteries above the wrist is often unsuccessful, on account of the anastomosis carried on by the carpal arches. Therefore, upon the failure of pressure to arrest hæmorrhage, it is expedient to apply a ligature to the brachial artery.

When an incision for deep-seated suppuration in the tendon-sheath is required, the position of the superficial arch must always be borne in mind, and the incisions placed either above or below it. The position of the common digital branches of the artery must be remembered, and the incisions made in front of the heads of the metacarpal bones and not between them.

THE ARTERIES OF THE TRUNK

The Descending Aorta

The descending **aorta** is divided into two portions, the *thoracic* and *abdominal*, in correspondence with the two great cavities in which it is situated.

The Thoracic Aorta (fig. 694)

The thoracic **aorta** is contained in the posterior mediastinal cavity. It begins at the lower border of the fourth thoracic vertebra where it is continuous with the aortic arch (p. 600), and ends in front of the lower border of the twelfth thoracic vertebra at the aortic hiatus in the Diaphragm. At its origin, it is situated on the left of the vertebral column; as it descends it approaches the median line, and at its termination lies in front of the column.

Relations.—It is in relation, *anteriorly*, from above downwards, with the root of the left lung, the pericardium, which separates it from the left atrium, the œsophagus, and the Diaphragm; *posteriorly*, with the vertebral column, the hemiazygos and accessory hemiazygos veins; on the *right side*, with the azygos vein and thoracic duct; on the *left side*, with the left pleura and lung. The œsophagus, with its accompanying plexus of nerves, lies on the right side of the aorta above; but at the lower part of the thorax it is placed in front of the aorta, and, close to the Diaphragm, is situated on its left side.

Peculiarities.—The lumen of the aorta is occasionally found to be partly or completely obliterated, either at the aortic isthmus, or close to the point where the ductus arteriosus opens into it. This condition is known as *coarctation of the aorta*. It may be either congenital or acquired. In the former case the infant usually dies at or soon after birth. When acquired it is apparently due to an abnormal growth of the peculiar tissue of

CC-0. In Public Domain. Gurukul Kangri Collection, Haridwar

Digitized by Arya Samaj Foundation Chennai and eGangotri

the ductus into the aortic wall, giving rise to a simultaneous stenosis of both vessels. contracts after birth. This form of coarctation is compatible with many years of life, and leads to the establishment of an extensive collateral circulation to carry the aorta immediately below the stenosis by means of the following vessels—p internal mammary, anastomosing with the intercostal arteries, with the inferior of the abdominal aorta by means of the musculophrenic and pericardiacophrenic largely with the inferior epigastric. Secondly, the costocervical trunk, and

Fig. 694.—The heart and the thoracic aorta. Left lateral aspect.

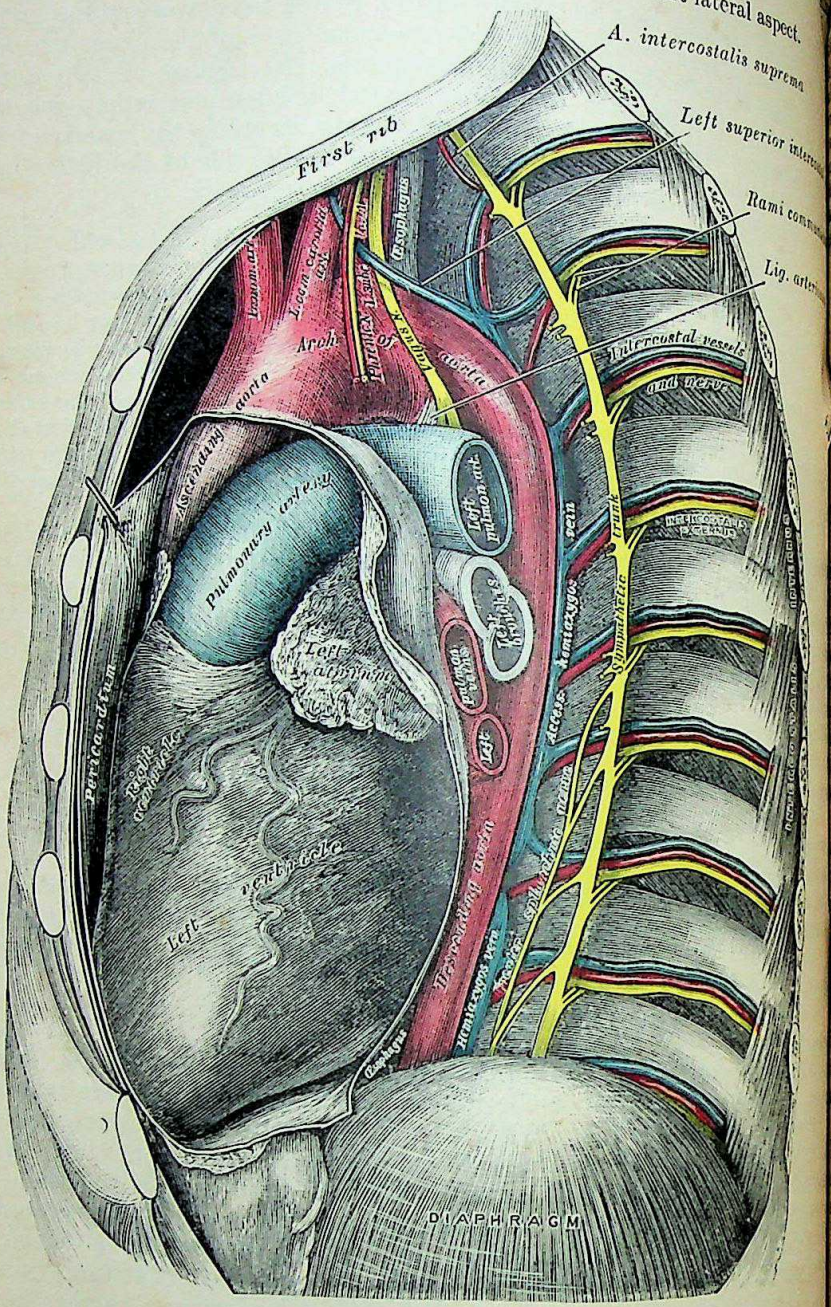

anteriorly by means of a large branch with the first aortic intercostal, and posteriorly with the posterior branch of the same artery. Thirdly, the inferior thyreoid, by means of a branch about the size of an ordinary radial, forming a communication with the aortic intercostal. Fourthly, the transverse cervical, by means of very large communications with the posterior branches of the intercostals. Fifthly, the branches (of the clavian and axillary) going to the side of the chest enlarge, and anastomose freely with lateral branches of the intercostals. In a second case Wood describes the anastomoses in a somewhat similar manner, adding the remark, that 'the blood which was brought into the aorta through the anastomoses of the intercostal arteries appeared to be expended principally in supplying the abdomen and pelvis; while the supply to the lower extremities had passed through the internal mammary and epigastrics.

CC-0. In Public Domain. Gurukul Kangri Collection, Haridwar

Digitized by Arya Samaj Foundation Chennai and eGangotri

Applied Anatomy.—Aneurysm of the thoracic aorta most commonly extends backwards on the left side of the vertebral column and leads to absorption of the bodies of the vertebræ (but not of the intervertebral fibrocartilages) and of the ribs; pressure on the intercostal nerves may give rise to radiating pains in the left upper intercostal spaces; erosion of the vertebræ the aneurysm may compress the spinal nerve-roots or ultimately the medulla spinalis producing pains in the chest, back or loins, or paralysis below the site of the lesion; at the same time the aneurysm may project backwards under the skin as a pulsating swelling. If the aneurysm extend forward, it may press upon and displace the heart, giving rise to palpitation and other symptoms of disease of that organ; or may displace or compress the œsophagus, causing pain and difficulty of swallowing, and ultimately even open into it by ulceration, producing fatal hæmorrhage. If the aneurysm extend to the right side, it may press upon the thoracic duct; it may burst into the pleural cavity, or into the lung; or it may open into the posterior mediastinal cavity. Pressure upon one of the bronchi, usually the left, will cause cough, and in time set up bronchiectasis; pressure on the left pulmonary plexus has been said to give rise to asthmatic attacks. Of late years, the diagnosis of thoracic aneurysm has been much facilitated by the employment of x-rays, by means of which the outline of the sac may be demonstrated.

The Branches of the Thoracic Aorta

Visceral { Pericardial. Bronchial. Œsophageal.

Parietal { Mediastinal. Superior phrenic. Intercostal. Subcostal.

The **pericardial branches** consist of a few small vessels which are distributed to the posterior surface of the pericardium.

The **bronchial arteries** vary in number, size, and origin. There is as a rule one left **bronchial artery,** which arises from the first aortic intercostal artery, or from the upper left bronchial artery. It runs on the posterior surface of the right bronchus, dividing and subdividing along the bronchial tubes, supplying them, the areolar tissue of the lung, and the bronchial lymph-glands; it also sends branches to the pericardium and the œsophagus. The **left bronchial arteries,** usually two in number, arise from the thoracic aorta, the upper opposite the fifth thoracic vertebra, and the lower just below the left bronchus. They run on the posterior surface of the left bronchus and have a distribution similar to that of the right bronchial artery.

The **œsophageal arteries,** four or five in number, arise from the front of the aorta, and pass obliquely downwards to the œsophagus; on this they form a vascular plexus which anastomoses above with the œsophageal branches of the inferior thyroid arteries, and below with ascending branches from the left inferior phrenic and left gastric arteries.

The **mediastinal branches** are numerous small vessels which supply the lymph-glands and loose areolar tissue in the posterior mediastinal cavity.

The **superior phrenic branches** are small, and arise from the lower part of the thoracic aorta; they are distributed to the posterior part of the upper surface of the Diaphragm, and anastomose with the musculophrenic and pericardiacophrenic arteries.

The **intercostal arteries.**—There are usually nine pairs of aortic intercostal arteries. They arise from the back of the aorta, and are distributed to the lower nine intercostal spaces, the first and second spaces being supplied by the arteria intercostalis suprema, a branch of the costocervical trunk of the subclavian artery (p. 642). The *right* aortic intercostal arteries are longer than the left, on account of the position of the aorta on the left side of the vertebral column; they cross the bodies of the vertebræ behind the œsophagus, thoracic duct, and vena azygos, and are covered by the right lung and pleura. The *left* aortic intercostal arteries run backwards on the sides of the vertebræ and are covered by the left lung and pleura; the upper two vessels are crossed by the left superior intercostal vein, the lower vessels by the hemiazygos and accessory hemiazygos veins. The further course of the intercostal arteries is practically the same on both sides. Opposite the heads of the ribs the sympathetic trunk passes downwards in front of them, and the splanchnic nerves also descend in front of the lower arteries. Each artery then divides into an anterior and a posterior ramus.

Each *anterior ramus* (fig. 694) crosses its intercostal space obliquely towards the angle of the upper rib, and thence is continued forwards in the costal groove. It

CC-0. In Public Domain. Gurukul Kangri Collection, Haridwar

Digitized by Arya Samaj Foundation Chennai and eGangotri

is placed at first between the pleura and the posterior intercostal membr[illegible] far as the angle of the rib; from this onward it runs between the Inter[illegible] externus et internus, and anastomoses in front with the intercostal branch[illegible] internal mammary or musculophrenic artery. Each artery is accompanied [illegible] vein and a nerve, the former being above and the latter below the artery, [illegible] the upper spaces, where the nerve is at first above the artery. The fir[illegible] intercostal artery anastomoses with the arteria intercostalis suprema, a[illegible] form the chief supply of the second intercostal space. The lower two in[illegible] arteries are continued anteriorly from the intercostal spaces into the ab[illegible] wall and anastomose with the subcostal, superior epigastric, and lumbar art[illegible]

Each anterior ramus gives off the following branches:

Collateral intercostal.	Lateral cutaneous.
Muscular.	Mammary.

The **collateral intercostal branch** comes off the anterior ramus of the intercostal [illegible] near the angle of the rib, and descends to the upper border of the rib below, along [illegible] it courses to anastomose with an intercostal branch of the internal mammary or m[illegible] phrenic artery. The collateral branches of the lower two anterior rami are so[illegible] absent; if present, they are small and end in the abdominal muscles.

Muscular branches are given to the Intercostales and Pectorales and to the S[illegible] anterior; they anastomose with the highest and lateral thoracic branches of the a[illegible] artery.

The **lateral cutaneous branches** accompany the lateral cutaneous branches of [illegible] thoracic nerves.

Mammary branches are given off by the vessels in the second, third, and f[illegible] spaces; they increase considerably in size during the period of lactation.

The **right bronchial artery** may arise from the first intercostal artery (p. 663).

Each *posterior ramus* runs backwards through a space which is bounded [illegible] and below by the necks of the ribs, medially by the body of a vertebra, and la[illegible] by an anterior costotransverse ligament. It gives off a *spinal branch* which [illegible] the vertebral canal through the intervertebral foramen, and is distributed [illegible] vertebræ and to the medulla spinalis and its membranes, anastomosing wi[illegible] spinal arteries above and below and with the artery of the opposite side. [illegible] posterior ramus then courses over the transverse process with the posterior di[illegible] of the thoracic nerve, supplies branches to the muscles of the back, and a cuta[illegible] branch which accompanies the cutaneous branch of the posterior division of [illegible] nerve.

Applied Anatomy.—The position of the anterior rami of the intercostal vessels [illegible] be borne in mind in performing the operation of paracentesis thoracis. The pu[illegible] should never be made nearer the middle line posteriorly than the angle of the rib, a[illegible] artery crosses the space medial to this point. In the lateral portion of the chest, [illegible] the puncture is usually made, the artery lies at the upper part of the intercostal [illegible] and therefore the puncture should be made just above the upper border of the rib [illegible] the lower boundary of the space.

The relation of the Diaphragm to the deep surface of the lower intercostal spaces [illegible] be remembered, otherwise the abdominal cavity may be opened inadvertently [illegible] making incisions in these spaces.

The **subcostal arteries,** so named because they lie below the last ribs, [illegible] series with the intercostal arteries. Each passes along the lower border of [illegible] twelfth rib behind the kidney and in front of the Quadratus lumborum. [illegible] is accompanied by the twelfth thoracic nerve. It then pierces the posterior [illegible] neurosis of the Transversus abdominis, and, passing forward between this [illegible] and the Obliquus internus, anastomoses with the superior epigastric, lower [illegible] costal, and lumbar arteries. Each subcostal artery gives off a posterior b[illegible] which has a distribution similar to the posterior ramus of an intercostal arte[illegible]

A small **aberrant artery** is sometimes found arising from the right side of the thor[illegible] aorta near the origin of the right bronchial. It passes upwards and to the right b[illegible] the trachea and the œsophagus, and may anastomose with the right arteria interc[illegible] suprema. It represents the remains of the right dorsal aorta (p. 121), and in a [illegible] proportion of cases is enlarged to form the first part of the right subclavian artery.

CC-0. In Public Domain. Gurukul Kangri Collection, Haridwar

Digitized by Arya Samaj Foundation Chennai and eGangotri

The Abdominal Aorta (fig. 695)

The abdominal aorta begins at the aortic hiatus of the Diaphragm, in front of the lower border of the body of the last thoracic vertebra, and, ending in front of the vertebral column, ends on the body of the fourth lumbar vertebra, a little to the left of the middle line, by dividing into the two common iliac arteries. It diminishes rapidly in size, in consequence of the large branches which arise from it.

Fig. 695.—The abdominal aorta and its branches.

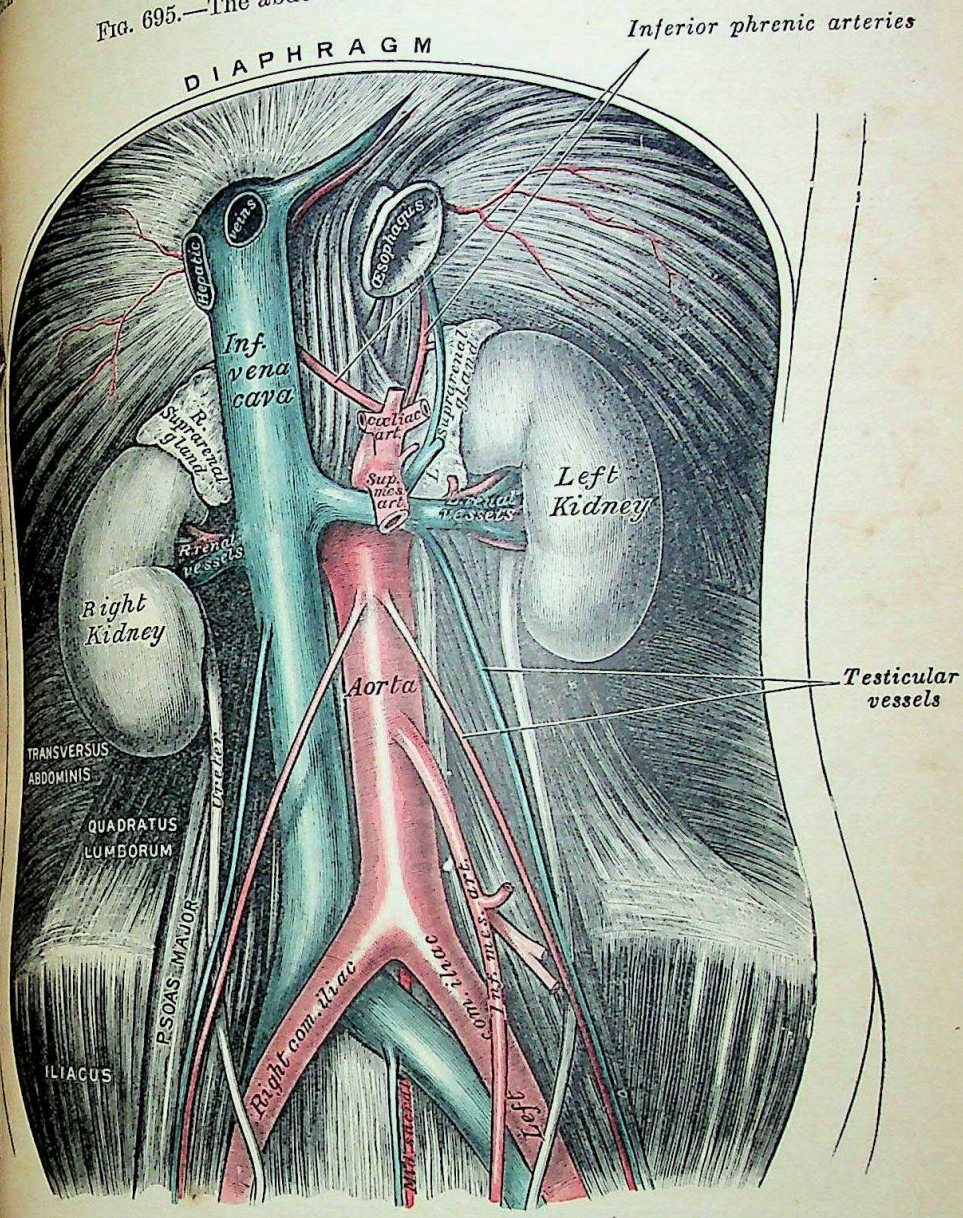

Relations.—The abdominal aorta is covered, *anteriorly*, by the omental bursa and stomach, behind which are the branches of the cœliac artery and the cœliac plexus of nerves; below these, by the lienal vein, the pancreas, the left renal vein, the horizontal part of the duodenum, the root of the mesentery, the peritoneum and coils of the small intestine, and the aortic plexus of nerves. *Posteriorly*, it is separated from the lumbar vertebræ and intervertebral fibrocartilages by the anterior longitudinal ligament and the left lumbar veins. On the *right side* it is in relation above with the cisterna chyli, thoracic duct, azygos vein, and the right crus of the Diaphragm—the last separating it from the upper part of the inferior vena cava, and from the right cœliac ganglion; the inferior vena cava is in contact with the aorta below the level of the second lumbar vertebra. On the *left side* are

CC-0. In Public Domain. Gurukul Kangri Collection, Haridwar

Digitized by Arya Samaj Foundation Chennai and eGangotri

the left crus of the Diaphragm, the left cœliac ganglion, the ascending pa duodenum, some coils of the small intestine, the left sympathetic trunk, mesenteric and left testicular (spermatic) vessels, and the left ureter.

Applied Anatomy.—Aneurysm of the abdominal aorta occurs most frequen upper part close to and often involving the cœliac artery, since here the ves narrows after giving off several large branches, and its walls have lost the suppo higher up by the crura of the Diaphragm.

If the aneurysm enlarges forwards it forms a pulsating tumour in the p chondriac or epigastric regions; by pressure upwards at the same time it may with the movements of the Diaphragm and embarrass respiration, or may com œsophagus and produce dysphagia; pressure on the stomach and cœliac plexus to dyspepsia, while jaundice may follow pressure on the bile duct and duodenum, or albuminuria, hæmaturia and anuria pressure on the renal vessels and nerves; if the vena cava is compressed there may be œdema of the lower limbs. This form of may burst into the peritoneal cavity, behind the peritoneum, between the layers mesentery, or more rarely into the duodenum.

When an aneurysm of the abdominal aorta enlarges backwards it usually absorption of the bodies of the vertebræ, pain is invariably present and is usually kinds—a fixed and constant pain in the back, caused by the tumour eroding the and a sharp lancinating pain radiating to the loins, hypogastrium and buttocks branches of the lumbar nerves which are pressed on by the tumour.

Occlusion of the abdominal aorta by thrombosis or embolism is rare, but produ severe symptoms when it does occur. The patient complains of intense pain in the pallor of the legs, followed by coldness, lividity, paresis, paralysis, and finally are likely to succeed, death usually supervening within a fortnight.

The abdominal aorta has been tied in several cases, and although none of the permanently recovered, still, as one case lived forty-eight days, the possibility re-establishment of the circulation may be considered to be proved.

Collateral Circulation.—The collateral circulation would be carried on by the moses between the internal mammary and the inferior epigastric arteries; by the communication between the superior and inferior mesenteric arteries, if the ligature placed between these vessels; or by the anastomosis between the inferior mesenteric the internal pudendal arteries, when (as is more common) the point of ligature is the origin of the inferior mesenteric artery; and possibly by the anastomoses of the arteries with the branches of the hypogastric artery.

The Branches of the Abdominal Aorta (fig. 695)

The branches of the abdominal aorta may be divided into three visceral, parietal, and terminal.

Visceral branches.	*Parietal branches.*
Cœliac.	Inferior phrenic.
Superior mesenteric.	Lumbar.
Inferior mesenteric.	Middle sacral.
Middle suprarenal.	
Renal.	
Testicular (in the male).	*Terminal branches.*
Ovarian (in the female).	Common iliac.

Of the visceral branches, the cœliac artery and the superior and in mesenteric arteries are unpaired; the suprarenal, renal, testicular, and ov arteries are paired. Of the parietal branches, the middle sacral arter unpaired; the inferior phrenic and lumbar arteries are paired. The term branches are paired.

The Cœliac Artery (figs. 696, 697)

The **cœliac artery** is a thick trunk, about 1·25 cm. long, which a from the front of the aorta, just below the aortic hiatus of the Diaphra it passes nearly horizontally forwards above the pancreas and the lienal and divides into three large branches, (1) *left gastric*, (2) *hepatic*, and (3) or *splenic*; it occasionally gives off one of the inferior phrenic arteries.

CC-0. In Public Domain. Gurukul Kangri Collection, Haridwar

Digitized by Arya Samaj Foundation Chennai and eGangotri

Relations.—The cœliac artery is covered by the omental bursa and surrounded by the cœliac plexus of nerves. On its *right side* are the right cœliac ganglion, the right crus of the Diaphragm, and the caudate process of the liver, on its *left side* the left cœliac ganglion, the left crus of the Diaphragm, and the cardiac end of the stomach. *Below* it are the upper border of the pancreas and the lienal vein.

The **left gastric artery** (coronary artery) (fig. 696), the smallest branch of the cœliac artery, passes upwards and to the left, behind the omental bursa, to the cardiac orifice of the stomach. Here it gives off branches which

FIG. 696.—The cœliac artery and its branches; the liver has been raised, and the lesser omentum, the anterior layer of the greater omentum, and the posterior wall of the omental bursa removed.

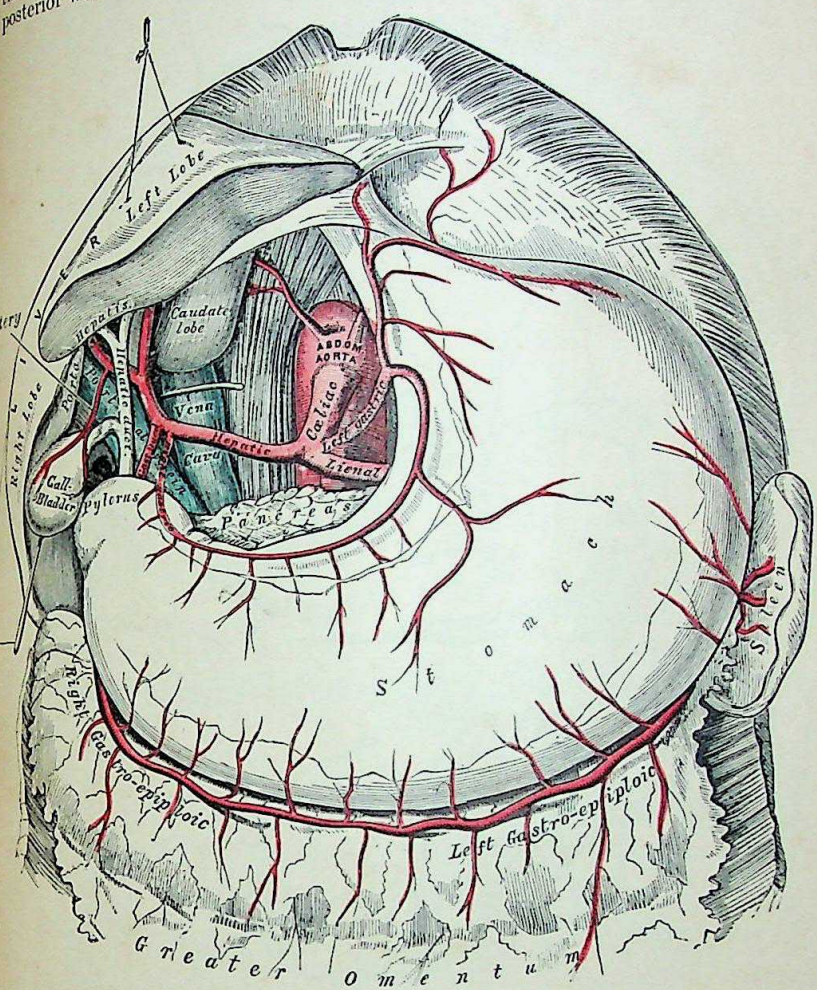

spread on the œsophagus, and anastomose with the aortic œsophageal arteries; others supply the cardiac part of the stomach, and anastomose with branches of the lienal artery. The artery then turns forwards and downwards, and runs along the lesser curvature of the stomach to the pylorus, between the layers of the lesser omentum; it gives branches to both surfaces of the stomach and anastomoses with the right gastric artery.

2. The **hepatic artery** (fig. 696) is intermediate in size between the left gastric and lienal arteries. It is first directed forwards and to the right, to the upper margin of the superior part of the duodenum, forming the lower boundary of the epiploic foramen (foramen of Winslow). It then crosses in front of the portal vein, and ascends between the layers of the lesser omentum, and in front of the epiploic foramen, to the porta hepatis, where it divides into a right and a left branch, which supply the corresponding lobes of the liver, accompanying the ramifications of the portal vein and hepatic ducts. In the lesser omentum the hepatic artery lies in front of the portal vein, and on the

CC-0. In Public Domain. Gurukul Kangri Collection, Haridwar

Digitized by Arya Samaj Foundation Chennai and eGangotri

left of the bile-duct. The distribution of the hepatic artery within the liver is described with the anatomy of the liver, in the section on Splanchnology.

Its branches are:

Right gastric. Gastroduodenal. Cystic.

The **right gastric artery** (pyloric artery) (fig. 696) arises from the hepatic above the superior part of the duodenum; it descends in the lesser omentum to the pyloric end of the stomach, and passes from right to left along its lesser curvature, supplying it with branches, and anastomosing with the left gastric artery.

FIG. 697.—The cœliac artery and its branches; the stomach has been raised, and the peritoneum removed.

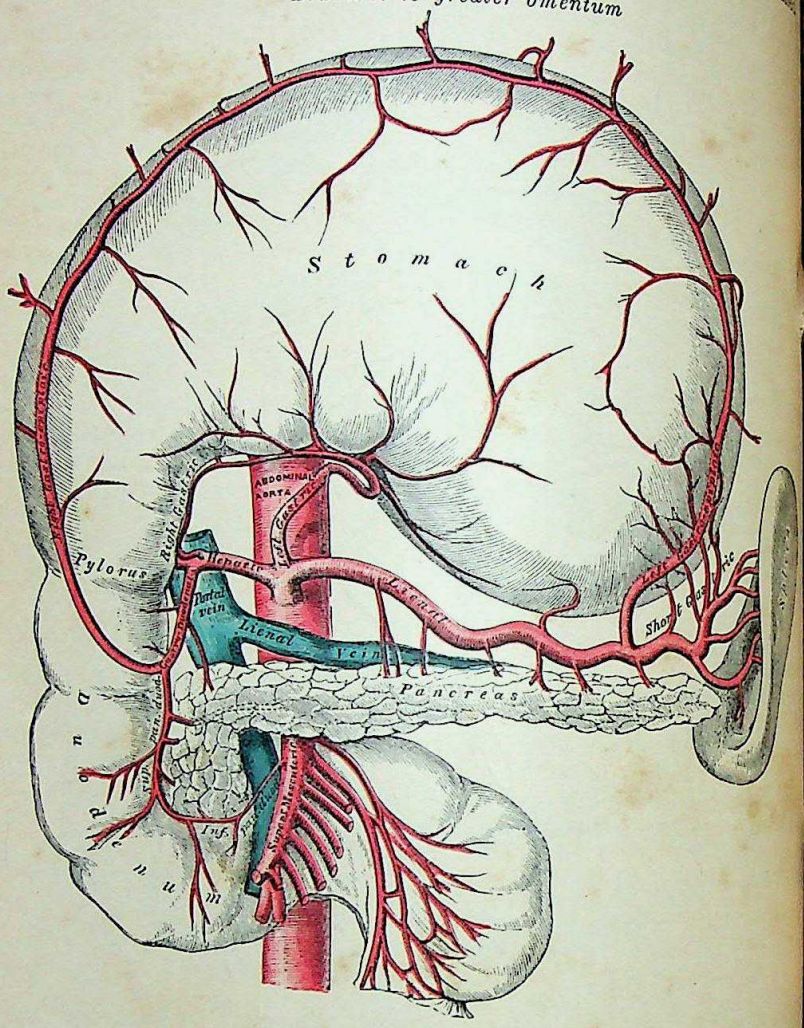

The **gastroduodenal artery** (fig. 697) is a short but large branch, which descends near the pylorus, between the superior part of the duodenum and the neck of the pancreas, and divides at the lower border of the duodenum into two branches, the *right gastro-epiploic* and the *superior pancreaticoduodenal* arteries. Previous to its division it gives off two or three small branches to the pyloric end of the stomach and to the pancreas.

The **right gastro-epiploic artery** (figs. 696, 697), the larger terminal branch of the gastroduodenal artery, runs from right to left along the greater curvature of the stomach, between the layers of the greater omentum, and ends by anastomosing with the left gastro-epiploic branch of the lienal artery. Except at the pylorus, where it is in contact with the stomach, it lies about a finger's breadth from the greater curvature. This vessel gives off numerous branches, some of which ascend to supply both surfaces of the stomach, while others descend in the greater omentum and anastomose with branches of the middle colic artery.

The **superior pancreaticoduodenal artery** (fig. 697) descends between the duodenum and the head of the pancreas. It supplies both these organs, and anastomoses

CC-0. In Public Domain. Panini Kanya Maha Vidyalaya Collection.

Digitized by Arya Samaj Foundation Chennai and eGangotri

the inferior pancreaticoduodenal branch of the superior mesenteric artery, with the pancreatic branches of the lienal artery.

The **cystic artery** (fig. 696), usually a branch of the right hepatic artery, passes wards and forwards along the neck of the gall-bladder, and divides into two es, one of which ramifies on the free surface, the other on the attached surface gall-bladder.

The **lienal or splenic artery** (figs. 696, 697), the largest branch of the e artery, is remarkable for the tortuosity of its course. Accompanied by lienal vein which lies below it, it passes horizontally to the left, behind stomach and the omental bursa of the peritoneum, and along the upper der of the pancreas; it then crosses in front of the left suprarenal gland the upper part of the left kidney, and, on arriving near the spleen, divides branches. Some of these branches enter the hilum of the spleen between two layers of the lienorenal ligament; some are given to the pancreas, e others pass to the greater curvature of the stomach between the ers of the gastrolienal ligament. Its branches are:

Short gastric.

Pancreatic.

Left gastro-epiploic.

The **pancreatic branches** (fig. 697) are numerous small vessels supplying the body il of the pancreas; they are derived from the lienal artery as it runs along pper border of the pancreas. One branch, larger than the rest, is sometimes n off near the tail of the pancreas; it runs from left to right near the posterior ce of the gland, following the course of the pancreatic duct, and is called the *ria pancreatica magna*. These vessels anastomose with the pancreatic branches the superior and inferior pancreaticoduodenal arteries.

The **short gastric arteries** (vasa brevia) (fig. 697) consist of from five to seven all branches which arise from the end of the lienal artery, and from its terminal sions. They pass from left to right, between the layers of the gastrolienal liga- , and are distributed to the greater curvature of the stomach, anastomosing h branches of the left gastric and left gastro-epiploic arteries.

The **left gastro-epiploic artery** (figs. 696, 697), the largest branch of the lienal ry, runs from left to right about a finger's breadth from the greater curvature the stomach, between the layers of the greater omentum, and anastomoses with right gastro-epiploic artery. It distributes several ascending branches to both aces of the stomach; others descend to supply the greater omentum and stomose with branches of the middle colic artery.

Applied Anatomy.—Embolism of branches of the lienal artery is tolerably common heart disease, the embolus coming from the left side of the heart. It is characterised the occurrence of a sudden sharp pain or 'stitch' in the splenic region, with subse- t local enlargement of the spleen from the formation of an infarct in its substance.

The Superior Mesenteric Artery (fig. 698)

The **superior mesenteric artery** supplies the whole of the small intestine ept the superior part of the duodenum; it also supplies the cæcum and ascending colon and about one-half of the transverse colon. It arises m the front of the aorta about 1 cm. below the cœliac artery, and is ssed at its origin by the lienal vein and the neck of the pancreas. It passes wards and forwards, anterior to the processus uncinatus of the head of pancreas and the horizontal part of the duodenum, and descends between the rts of the mesentery to the right iliac fossa, where, considerably diminished size, it anastomoses with one of its own branches, viz. the ileocolic artery. its course it crosses in front of the inferior vena cava, the right ureter, and s major, and forms an arch, the convexity of which is directed forwards, wards, and to the left side. It is accompanied by the superior mesenteric which lies to its right side, and is surrounded by the superior mesenteric rts of nerves. Its branches are:

Inferior pancreaticoduodenal.

Jejunal and ileal.

Ileocolic.

Right colic.

Middle colic.

CC-0. In Public Domain. Gurukul Kangri Collection, Haridwar

Digitized by Arya Samaj Foundation Chennai and eGangotri

The **inferior pancreaticoduodenal artery** (fig. 697) springs from the mesenteric artery or from its first jejunal branch, opposite the upper the inferior part of the duodenum. It courses to the right between the pancreas and duodenum, and then ascends to anastomose with the creaticoduodenal artery. It distributes branches to the head of the and to the descending, horizontal and ascending parts of the duodenum.

Fig. 698.—The superior mesenteric artery and its branches.

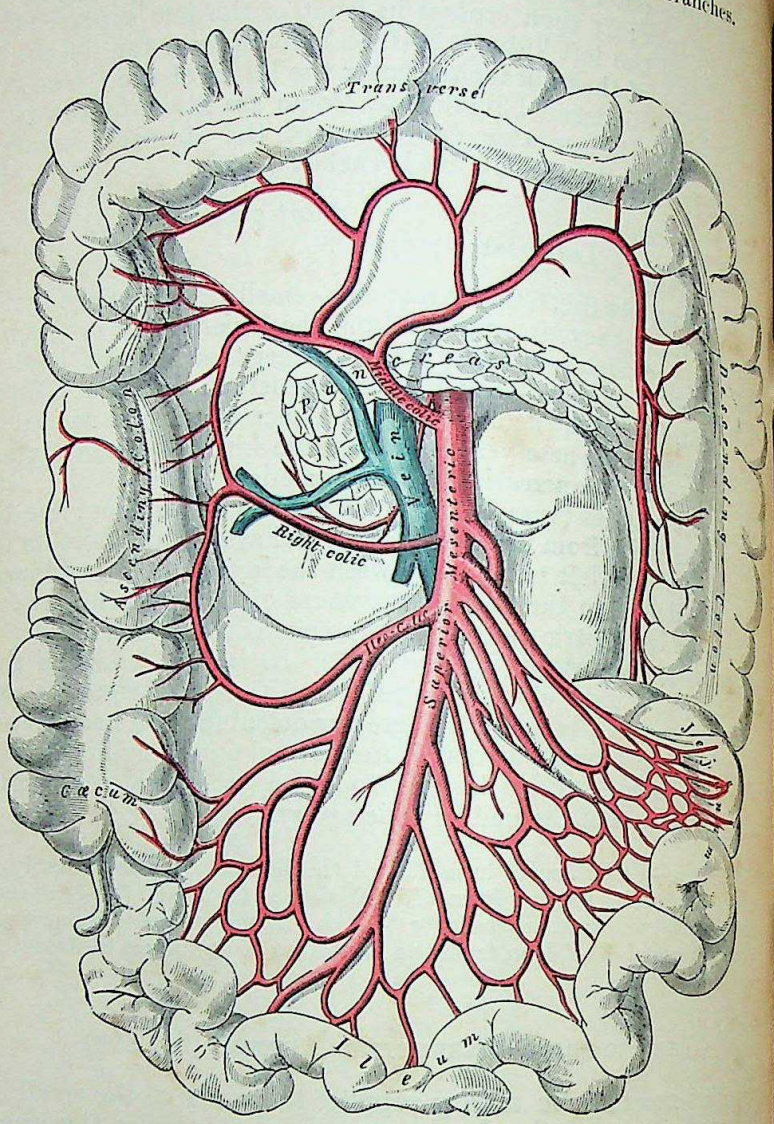

The **jejunal and ileal arteries** (vasa intestini tenuis) (fig. 698) arise from the side of the superior mesenteric artery. They are usually from twelve to fifteen number, and are distributed to the jejunum and ileum, with the exception of the terminal part of the latter which is supplied by the ileocolic artery. They nearly parallel with one another between the layers of the mesentery, vessel dividing into two branches, which unite with adjacent branches, to series of arches (fig. 699). From these arches branches arise and unite to a second series of arches, and the process may be repeated three or four In the short, upper part of the mesentery only one set of arches exists, but mesentery increases in depth, second, third, fourth, and even fifth groups present. From the terminal arches numerous small straight vessels arise which distributed to the intestine. From the jejunal and ileal arteries small are given off to the lymph-glands and other structures between the layers mesentery.

CC-0. In Public Domain. Gurukul Kangri Collection, Haridwar

Digitized by Arya Samaj Foundation Chennai and eGangotri

FIG. 699.—A loop of the small intestine showing the distribution of the intestinal arteries. (From a preparation by Hamilton Drummond.)

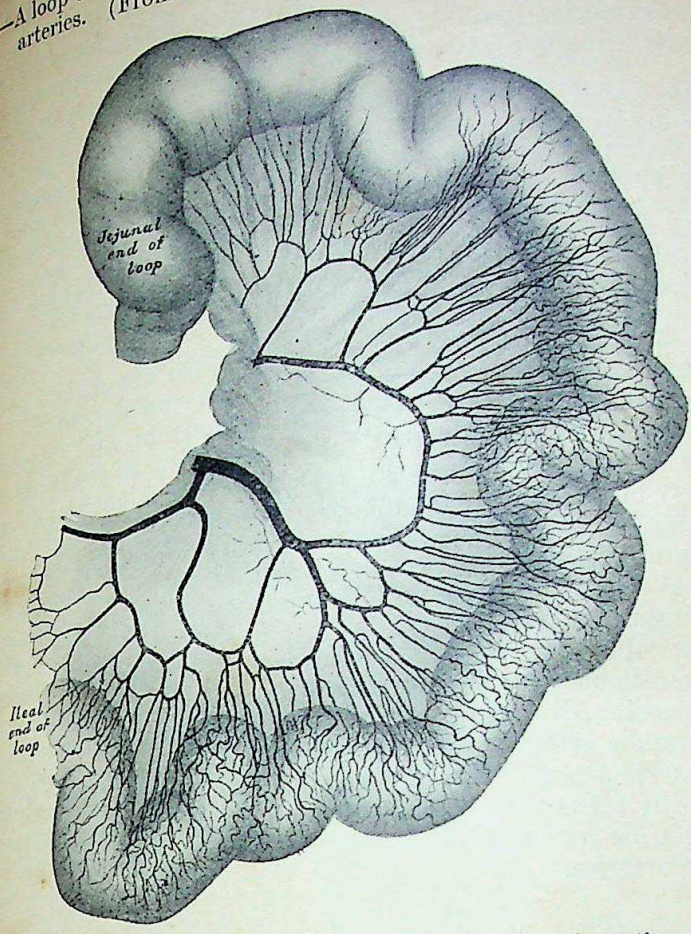

The vessels were injected while the gut was *in situ*; the gut was then removed, and an *x*-ray photograph taken.

FIG. 700.—The arteries of the cæcum and vermiform process.

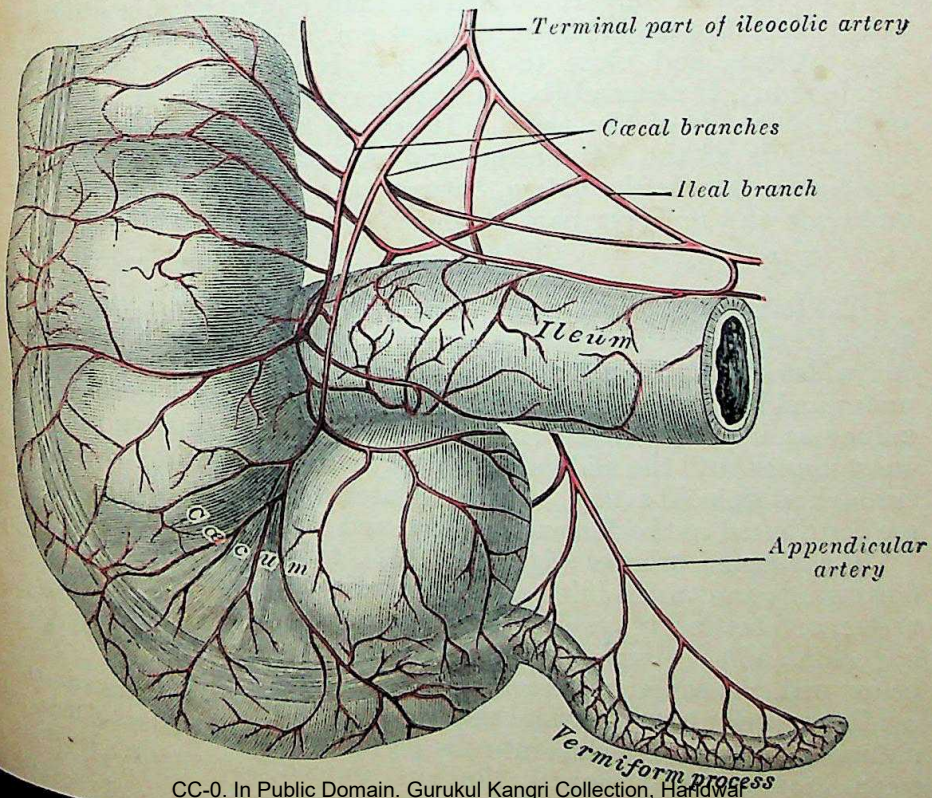

CC-0. In Public Domain. Gurukul Kangri Collection, Haridwar

Digitized by Arya Samaj Foundation Chennai and eGangotri

The **ileocolic artery** (fig. 698) is the lowest of the branches arising from the cavity of the superior mesenteric artery. It passes downwards and to the right behind the peritoneum, towards the right iliac fossa, where it divides into a superior and an inferior branch; the superior branch anastomoses with the right colic artery, the inferior with the end of the superior mesenteric artery.

The inferior branch of the ileocolic runs towards the upper border of the junction and supplies the following branches (fig. 700): (*a*) *colic*, which pass to the ascending colon; (*b*) *anterior and posterior cæcal*, which are distributed to the and back of the cæcum; (*c*) an *appendicular artery*, which descends behind the tion of the ileum and enters the mesenteriole of the vermiform process; it runs free margin of this mesenteriole and ends in branches which supply the process; and (*d*) *ileal*, which runs upwards and to the left on the lower part of the and anastomoses with the termination of the superior mesenteric artery.

The **right colic artery** (fig. 698) arises from near the middle of the of the superior mesenteric artery, or from a stem common to it and the artery. It passes to the right behind the peritoneum, and in front of the testicular (or ovarian) artery and vein, the right ureter, and the Psoas major, the ascending colon. Sometimes the vessel lies at a higher level, and cross descending part of the duodenum and the lower end of the right kidney. colon it divides into a descending branch, which anastomoses with the artery, and an ascending branch, which anastomoses with the middle colic These branches form arches, from the convexity of which vessels are distr to the ascending colon.

The **middle colic artery** (fig. 698) arises from the superior mesenteric ar below the pancreas and, passing downwards and forwards between the layers transverse mesocolon, divides into a right and a left branch; the former anast with the right colic artery; the latter with the left colic artery, a branch inferior mesenteric artery. The arches thus formed are placed about two breadth from the transverse colon, to which they distribute branches. Br of the middle colic artery also anastomose with branches of the right a gastro-epiploic arteries.

The Inferior Mesenteric Artery (fig. 701)

The **inferior mesenteric artery** supplies the left half of the tran colon, the whole of the descending colon, the sigmoid colon, and the g part of the rectum. It is smaller than the superior mesenteric artery, arises from the aorta, about 3 or 4 cm. above its division into the com iliac arteries, and close to the lower border of the horizontal part of duodenum. It descends behind the peritoneum, lying at first in front, and on the left side of the aorta. It crosses the left common iliac artery medial side of the left ureter, and is continued into the lesser pelvis as *superior hæmorrhoidal artery*, between the two layers of the sigmoid mes and ends on the upper part of the rectum. Its branches are:

Left colic. Sigmoid. Superior hæmorrhoidal.

The **left colic artery** (fig. 701) runs to the left behind the peritoneum and in of the Psoas major, and, after a short but variable course, divides into an as and a descending branch; the trunk or the branches of the artery cross the ureter and left testicular vessels. The ascending branch passes in front of the kidney and then between the two layers of the transverse mesocolon wh anastomoses with the middle colic artery; the descending branch anastomoses the highest sigmoid artery. From the arches formed by these anastomoses bran are distributed to the descending colon and the left half of the transverse colon.

The **sigmoid arteries** (figs. 701, 702), two or three in number, run obli downwards and to the left behind the peritoneum and in front of the Psoas m ureter, and testicular vessels. Their branches supply the lower part of the des ing colon and the sigmoid colon, anastomosing above with the left colic artery below with the superior hæmorrhoidal artery.

The **superior hæmorrhoidal artery** (figs. 701, 702), the continuation of the in mesenteric artery, descends into the pelvis between the layers of the sigmoid m colon, crossing, in its course, the left common iliac vessels. It divides, opp

CC-0. In Public Domain. Gurukul Kangri Collection, Haridwar

Digitized by Arya Samaj Foundation Chennai and eGangotri

third sacral vertebra, into two branches; these descend one on either side of the rectum, and supply its mucous membrane as far as the anal canal, and the upper part of its muscular coat; about 10 or 12 cm. from the anus the two arteries break into several small branches. These pierce the muscular coat of the bowel and run straight downwards in the wall of the gut between its muscular and mucous

FIG. 701.—The inferior mesenteric artery and its branches.

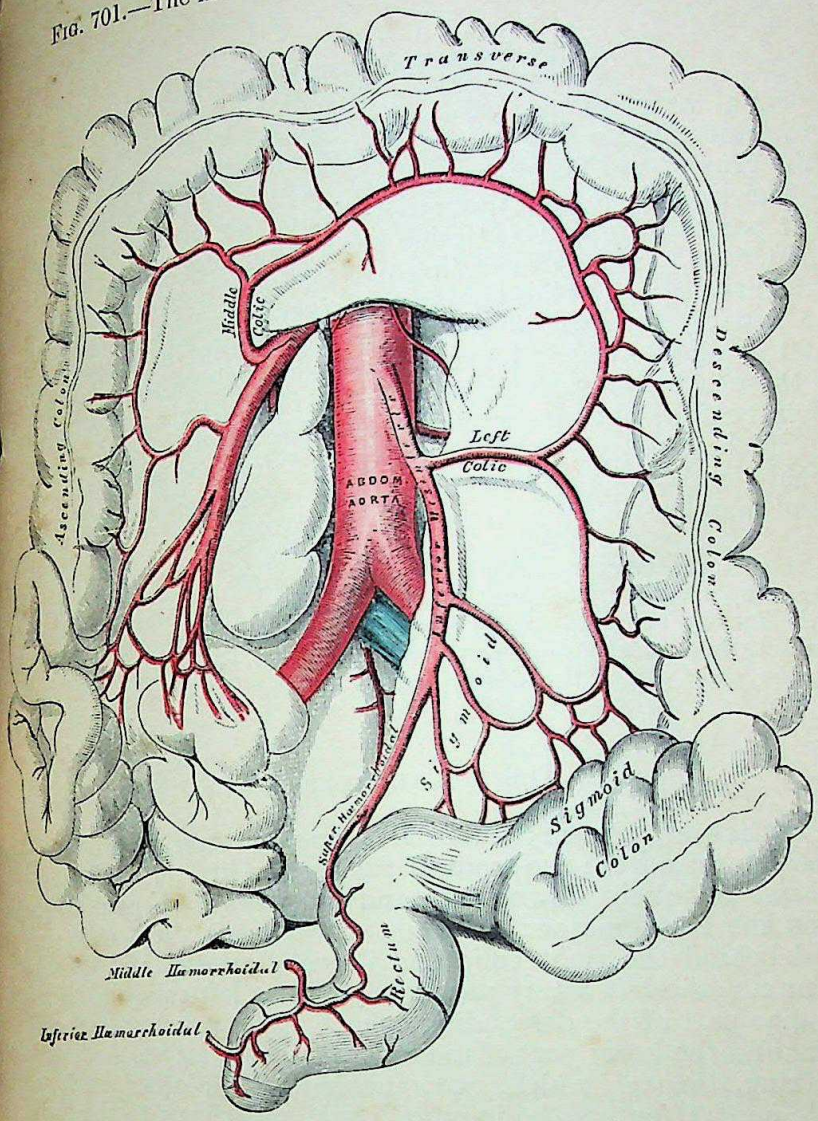

ch, to the level of the Sphincter ani internus; here they form a series of loops round the lower end of the rectum, and communicate with the middle hæmorrhoidal branches of the hypogastric artery, and with the inferior hæmorrhoidal branches of the internal pudendal artery.

Applied Anatomy.—Embolism of the mesenteric arteries produces acute and severe symptoms, of which the chief are abdominal pain and tenderness, nausea and vomiting, diarrhœa or constipation; blood is found in the stools of nearly half the patients. In many cases the symptoms closely resemble those of intestinal obstruction.

As a result of the free anastomoses between the left colic and sigmoid arteries a vascular "marginal artery" descends, near the gut, from the left colic flexure to the upper end of the sigmoid flexure, where it stops, because the superior hæmorrhoidal artery does not divide into arch-forming branches. The point where the lowest sigmoid artery anastomoses with the superior hæmorrhoidal artery is therefore sometimes named the "critical point." Ligature of these two arteries will almost certainly result in gangrene of the part of the rectum which is supplied by them. If, however, the inferior mesenteric may be tied proximal to the origin of its lowest sigmoid branch, blood can pass through the other branch into the superior hæmorrhoidal artery.

CC-0. In Public Domain. Gurukul Kangri Collection, Haridwar

Digitized by Arya Samaj Foundation Chennai and eGangotri

The Middle Suprarenal Arteries

The **middle suprarenal arteries** are two small vessels which arise from either side of the aorta, opposite the superior mesenteric artery; passes lateralwards and slightly upwards, over the crus of the Diaphragm to the suprarenal gland, where it anastomoses with suprarenal branches of the inferior phrenic and renal arteries.

The Renal Arteries (fig. 695)

The **renal arteries** are two large trunks, which arise from the sides of the aorta, immediately below the superior mesenteric artery. Each is directed across the crus of the Diaphragm, so as to form nearly a right angle with the aorta. The *right* is longer than the left, on account of the position of the aorta; it passes behind the inferior vena cava, the right renal vein, the head of the pancreas, and the descending part of the duodenum. The *left* is higher than the right; it lies behind the left renal vein, the body of the pancreas and the lienal vein, and is crossed by the inferior mesenteric vein. On reaching the hilum of the kidney, each artery divides into four or five branches, most of these lie between the renal vein and renal pelvis, the vein being in front of the pelvis behind, but one or more branches are usually situated behind the pelvis. Each vessel gives off some small *inferior suprarenal branches* to the suprarenal gland, and supplies twigs to the ureter and the surrounding connective tissue and muscles.

One or two accessory renal arteries are frequently found, more especially on the left side: they usually arise from the aorta, and may come off above or below the renal artery, the former being the more common position. Instead of entering the kidney at the hilum, they usually pierce the upper or lower part of the kidney; an accessory artery to the lower part of the kidney crosses in front of the ureter.

The Testicular Arteries (fig. 695)

The **testicular arteries** (internal spermatic arteries) are two long slender vessels which arise from the front of the aorta a little below the renal arteries. Each passes obliquely downwards and lateralwards behind the peritoneum, resting on the Psoas major; the right artery lies in front of the inferior vena cava and behind the right colic and ileocolic arteries and the terminal part of the ileum; the left artery passes behind the left colic and sigmoid arteries and the iliac part of the descending colon. Each artery crosses obliquely over the ureter and the lower part of the external iliac artery to reach the abdominal inguinal ring, through which, accompanied by the other constituents of the spermatic cord, it enters the inguinal canal and passes to the scrotum, where it becomes tortuous and divides into several branches. Two or three of these accompany the ductus deferens, and supply the epididymis, anastomosing with the artery of the ductus deferens; others pierce the back part of the tunica albuginea, and supply the substance of the testis. The testicular artery supplies one or two small branches to the ureter, and in the inguinal canal gives one or two twigs to the Cremaster.

The Ovarian Arteries

The **ovarian arteries** in the female correspond to the testicular arteries in the male. They supply the ovaries, are shorter than the testicular arteries, and end in the pelvic cavity. The origin and course of the first part of the artery are the same as those of the testicular artery, but on arriving at the upper opening of the lesser pelvis the artery passes medialwards between the two layers of the broad ligament of the uterus below the uterine tube. At the level of the ovary it runs backwards in the mesovarium and breaks up into branches which are distributed to the ovary. Small branches

CC-0. In Public Domain. Gurukul Kangri Collection, Haridwar

Digitized by Arya Samaj Foundation Chennai and eGangotri

to the ureter and the uterine tube, and one passes on to the side of the uterus, and unites with the uterine artery. Other offsets are continued on round ligament of the uterus, through the inguinal canal, to the skin of bium majus and the groin.

FIG. 702.—The sigmoid colon and rectum, showing the distribution of the branches of the inferior mesenteric artery, and their anastomoses. (From a preparation by Hamilton Drummond.)

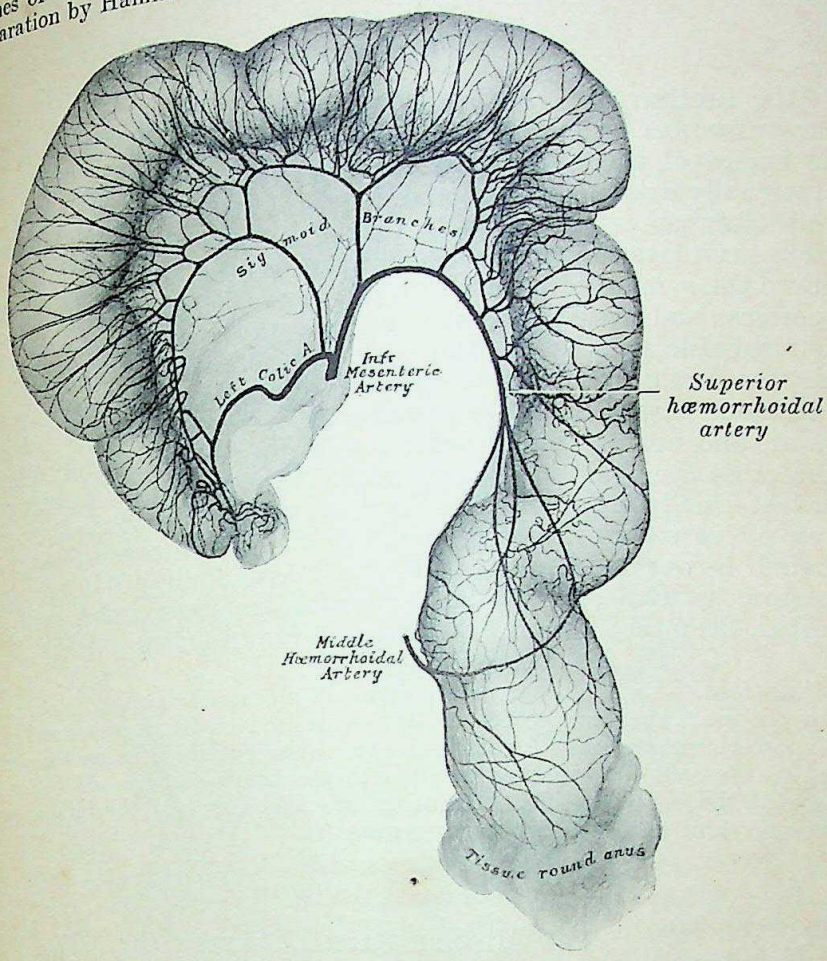

At an early period of fœtal life, when the testes or ovaries lie by the side the vertebral column, below the kidneys, the testicular and ovarian arteries short; but with the descent of the testicles into the scrotum, and of the aries into the pelvis, the arteries are gradually lengthened.

The Inferior Phrenic Arteries (fig. 695)

The **inferior phrenic arteries** are two small vessels which supply the aphragm. They present much variety in their origins; they may arise rately from the front of the aorta, immediately above the cœliac artery, a common trunk, which may spring either from the aorta or from the iac artery; sometimes one artery is derived from the aorta, and the one of the renal arteries. They diverge from one another across the of the Diaphragm, and then run obliquely upwards and lateralwards upon under surface. The left phrenic passes behind the œsophagus, and runs wards on the left side of the œsophageal hiatus. The right phrenic passes ind the inferior vena cava, and along the right side of the foramen which mits that vein. Near the posterior border of the central tendon of the aphragm each vessel divides into a medial and a lateral branch. The medial

CC-0. In Public Domain. Gurukul Kangri Collection, Haridwar

Digitized by Arya Samaj Foundation Chennai and eGangotri

branch curves forwards, and anastomoses with its fellow of the opp and with the musculophrenic and pericardiacophrenic arteries. The branch passes towards the side of the thorax, and anastomoses with intercostal arteries, and with the musculophrenic artery. The latter of the right artery gives off a few twigs to the inferior vena cava; and artery sends some branches to the œsophagus. Each vessel gives off *suprarenal branches* to the suprarenal gland of its own side. The the spleen also receive a few twigs from the right and left vessels resp

The Lumbar Arteries

The **lumbar arteries** are in series with the intercostal arteries. four in number on either side, they arise from the back of the aorta, the bodies of the upper four lumbar vertebræ. A fifth pair, small occasionally arises from the middle sacral artery; but the lumbar bra the iliolumbar arteries usually take the place of the fifth pair. The arteries run lateralwards and backwards on the bodies of the lumbar behind the sympathetic trunk, to the intervals between the adjacent tr processes, and are then continued into the abdominal wall. The art the right side pass behind the inferior vena cava, and the upper two on side run behind the corresponding crus of the Diaphragm. The arte both sides pass beneath the tendinous arches which give origin to the major, and are continued behind this muscle and the lumbar plexus then cross the Quadratus lumborum, the upper three arteries running the last usually in front of it. At the lateral border of the Quadratus they pierce the posterior aponeurosis of the Transversus abdominis, carried forwards between this muscle and the Obliquus internus anastomose with one another and with the lower intercostal, subcost lumbar, deep iliac circumflex, and inferior epigastric arteries.

Branches.—Each lumbar artery gives off a *posterior ramus* which, passing between the transverse processes, is distributed to the muscles and skin of The posterior ramus also furnishes a *spinal branch* which enters the vertebral supplies its contents, anastomosing with the arteries above and below it, and artery of the opposite side. Branches are also given by the lumbar arteries posterior rami to the neighbouring muscles.

The Middle Sacral Artery (fig. 695)

The **middle sacral artery** is a small vessel, which arises from the the aorta, a little above its bifurcation. It descends in the middle front of the fourth and fifth lumbar vertebræ, the sacrum and coccyx ends in the glomus coccygeum (coccygeal gland). At the level of the lumbar vertebra it is crossed by the left common iliac vein, and it gives off on either side a small lumbar artery (*arteria lumbalis ima*). branches are said to pass from it to the posterior surface of the rectum the last lumbar vertebra it anastomoses with the lumbar branch of the lumbar artery; in front of the sacrum it anastomoses with the lateral arteries, and sends offsets into the anterior sacral foramina.

The Common Iliac Arteries (figs. 695. 703)

The abdominal aorta divides, on the left side of the body of the lumbar vertebra, into the two **common iliac arteries** which diverge fr termination of the aorta, pass downwards and lateralwards, and divide the fibrocartilage between the last lumbar vertebra and the sacrum, branches, the *external iliac* and *hypogastric arteries*: the former supp greater part of the lower extremity; the latter, the viscera and parietes pelvis, and the gluteal region.

CC-0. In Public Domain. Gurukul Kangri Collection, Haridwar

Digitized by Arya Samaj Foundation Chennai and eGangotri

The right common iliac artery (figs. 695, 703), about 5 cm. long, passes obliquely across the body of the last lumbar vertebra. *In front* of it are the peritoneum, the small intestine, branches of the sympathetic nerves, and, at the point of division, the ureter. *Behind*, it is separated from the bodies of the fourth and fifth lumbar vertebræ and the intervening fibrocartilage by the terminations of the two common iliac veins and the commencement of the inferior vena cava. *Laterally*, it is in relation, above, with the inferior vena cava and the right common iliac vein; below, with the Psoas major. Medial to it, above, is the left common iliac vein.

Fig. 703.—The arteries of the pelvis. Right side.

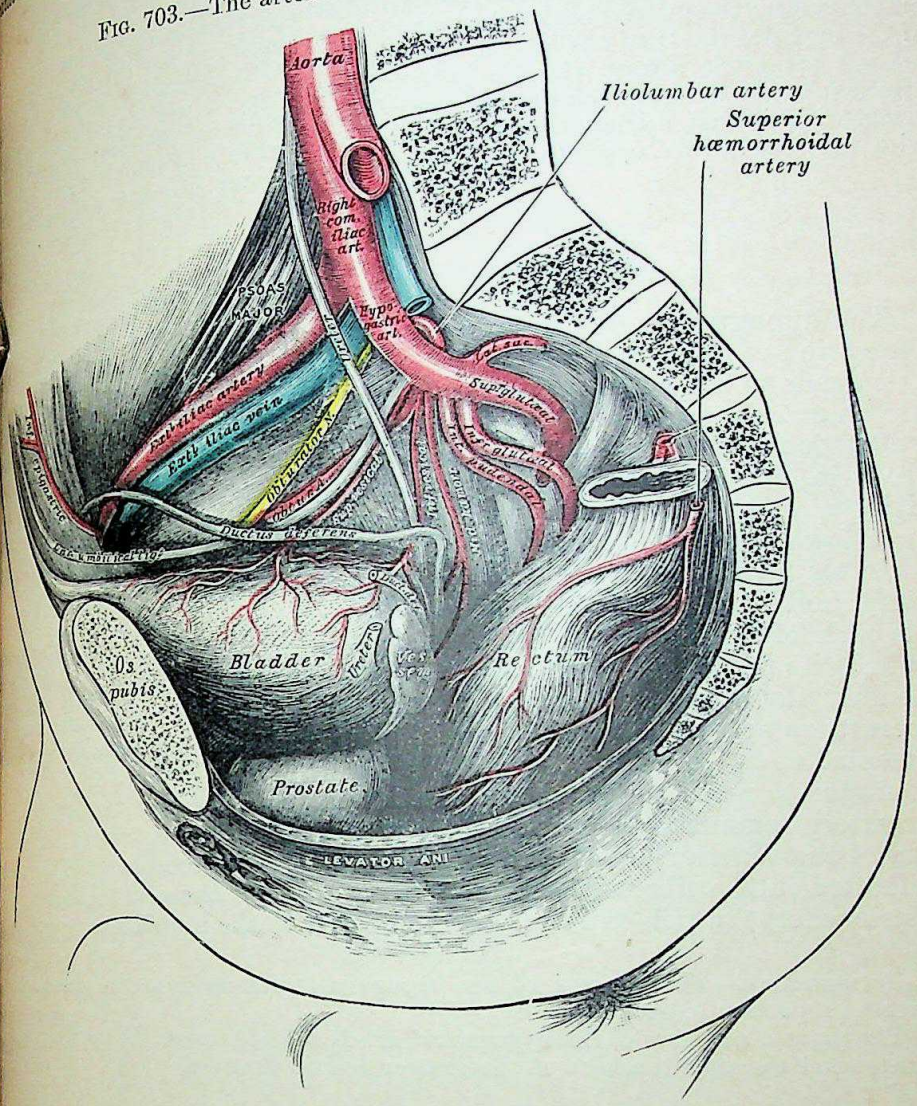

The left common iliac artery (695), about 4 cm. long, is in relation, *in front* with the peritoneum, the small intestine, branches of the sympathetic nerves, and the superior hæmorrhoidal artery, and is crossed at its point of bifurcation by the ureter. It rests on the bodies of the fourth and fifth lumbar vertebræ, and the intervening fibrocartilage. The left common iliac vein lies partly *medial* to, and partly *behind*, the artery; *laterally*, the artery is in relation with the Psoas major.

Branches.—The common iliac arteries give off small branches to the peritoneum, Psoas major, ureters, and the surrounding areolar tissue, and occasionally give origin to the iliolumbar or to the accessory renal arteries.

Peculiarities.—The points of origin of the common iliac arteries vary according to the bifurcation of the aorta, which in most cases occurs either upon the fourth lumbar vertebra, or upon the fibrocartilage between it and the fifth.

CC-0. In Public Domain. Gurukul Kangri Collection, Haridwar

Digitized by Arya Samaj Foundation Chennai and eGangotri

The common iliac arteries may divide above or below the usual level.

The length of the arteries varies from 3·5 to 7·5 cm. In rare instances the common iliac has been found wanting, the external iliac and hypogastric arteries directly from the aorta.

Applied Anatomy.—The easiest and best method of tying the common iliac is by a transperitoneal route. The abdomen is opened, the intestines are drawn aside, the peritoneum covering the artery divided and the ureter carefully identified, the sheath of the artery is then opened, and the needle passed from the medial to the lateral side. On the right side great care must be exercised in passing the needle, since the common iliac veins lie behind the artery.

Collateral Circulation.—The principal agents in carrying on the collateral circulation after the application of a ligature to the common iliac are: the anastomoses of the hæmorrhoidal branches of the hypogastric artery with the superior hæmorrhoidal branches from the inferior mesenteric artery; of the uterine, ovarian, and vesical arteries of the opposite sides; of the lateral sacral arteries with the middle sacral artery; of the inferior epigastric artery with the internal mammary, lower intercostal, and lumbar arteries; of the deep iliac circumflex artery with the lumbar arteries; of the first lumbar artery with the last lumbar artery; of the obturator artery, by means of its pubic branch, with the vessel of the opposite side and with the inferior epigastric artery.

The Hypogastric Artery (fig. 703)

The **hypogastric or internal iliac artery**, about 4 cm. long, arises at the bifurcation of the common iliac artery, opposite the lumbosacral articulation; it descends to the upper margin of the greater sciatic foramen where it divides into an *anterior* and a *posterior* trunk.

Relations.—It is in relation *in front* with the ureter; *behind*, with the internal iliac vein, the lumbosacral nerve-trunk, and the Piriformis; *laterally*, near its origin, with the external iliac vein, which lies between it and the Psoas; and lower down, with the obturator nerve.

In the fœtus, the hypogastric artery is twice as large as the external iliac artery, and is the direct continuation of the common iliac artery. It ascends from the back of the anterior wall of the abdomen to the umbilicus, converging towards its fellow of the opposite side. Having passed through the umbilical opening, the two arteries, now termed *umbilical*, enter the umbilical cord, where they are coiled round the umbilical vein, and ultimately ramify in the placenta.

At birth, when the placental circulation ceases, the pelvic portion of the artery remains patent and constitutes the hypogastric artery and the main part of the superior vesical artery of the adult; the remainder of the vessel is converted into a fibrous cord, the *lateral umbilical ligament* (obliterated hypogastric artery), which extends from the pelvis to the umbilicus.

Peculiarities.—The lengths of the hypogastric and common iliac arteries bear an inverse proportion to each other.

The place of division of the hypogastric artery varies between the upper margin of the sacrum and the upper border of the greater sciatic foramen.

Applied Anatomy.—For the application of a ligature to the hypogastric artery the vessel is best secured by an abdominal section in the median line, the vessel being reached through the peritoneal cavity. It should be remembered that the vein lies behind, and, on the right side, a little lateral to the artery; the ureter lies in front.

Collateral Circulation.—The circulation after ligature of the hypogastric artery is carried on by the anastomoses of the uterine and ovarian arteries; of the vesical arteries of the two sides; of the hæmorrhoidal branches of the hypogastric artery with those of the inferior mesenteric artery; of the pubic branch of the obturator artery with the vessel of the opposite side, and with the inferior epigastric and medial femoral circumflex arteries; of the circumflex and perforating branches of the arteria profunda femoris with the inferior glutæal artery; of the superior glutæal artery with the posterior branches of the lateral sacral arteries; of the iliolumbar with the last lumbar artery; of the middle sacral arteries with the lateral sacral artery; and of the iliac circumflex with the lumbar and superior glutæal arteries.*

* For a description of a case in which Owen made a dissection ten years after ligaturing the hypogastric artery, see *Med.-Chir. Trans.*, Vol. xvi.

CC-0. In Public Domain. Gurukul Kangri Collection, Haridwar

Digitized by Arya Samaj Foundation Chennai and eGangotri

The branches of the hypogastric artery are:

From the Anterior Trunk.
Superior vesical.
Inferior vesical.
Middle hæmorrhoidal.
Uterine. } *In the female.*
Vaginal. }
Obturator.
Internal pudendal.
Inferior glutæal.

From the Posterior Trunk.
Iliolumbar.
Lateral sacral.
Superior glutæal.

The **superior vesical artery** (fig. 703) supplies numerous branches to the upper of the bladder. From one of these a slender vessel, the *artery to the ductus*

704.—The left uterine and ovarian arteries of an unmarried girl aged 17½ years. Posterior aspect. (From a preparation by Hamilton Drummond.)

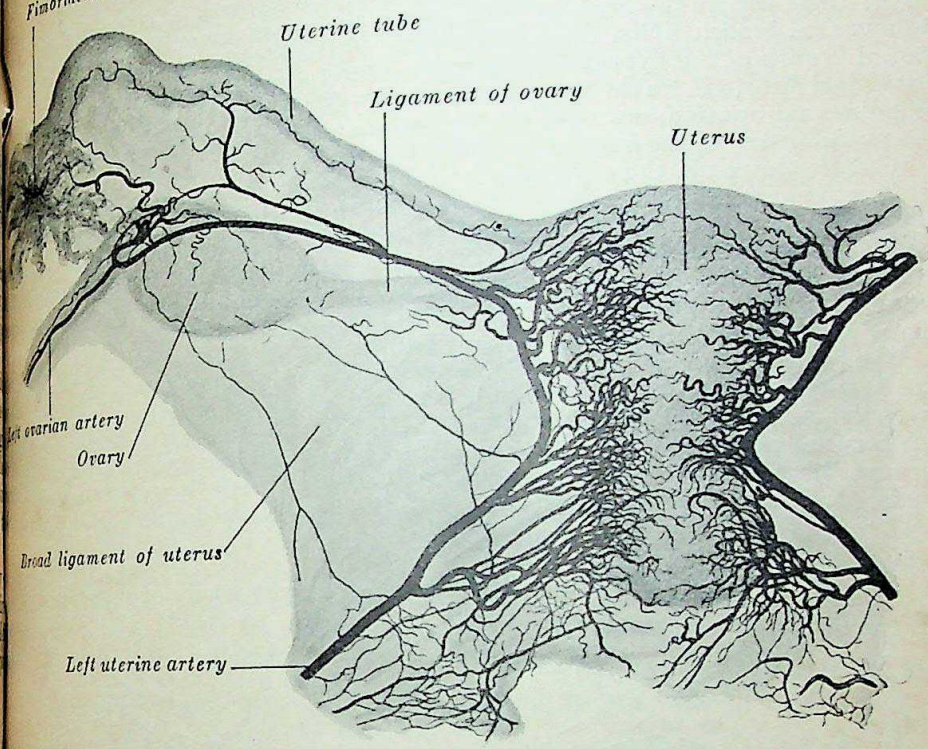

ens, takes origin and accompanies the ductus deferens in its course to the testis, where it anastomoses with the testicular artery. Other branches supply the ter. The first part of the superior vesical artery is the proximal, pervious portion the fœtal hypogastric artery.

The **inferior vesical artery** (fig. 703) frequently arises in common with the middle morrhoidal artery, and is distributed to the fundus of the bladder, the prostate, e vesiculæ seminales and the lower part of the ureter. The branches to the nate communicate with the corresponding vessels of the opposite side.

The **middle hæmorrhoidal artery** (figs. 702, 703) usually arises with the preceding nal. It is distributed to the muscular coats of the rectum, anastomosing with inferior vesical artery and with the superior and inferior hæmorrhoidal arteries. gives offsets to the vesiculæ seminales and prostate.

The **uterine artery** (fig. 704) runs medialwards on the Levator ani and towards e cervix uteri; about 2 cm. from the cervix it crosses above and in front of the ter, to which it supplies a small branch. Reaching the side of the uterus it ends in a tortuous manner between the two layers of the broad ligament to the tion of the uterine tube and uterus. It then runs lateralwards towards the um of the ovary, and ends by joining with the ovarian artery. It supplies

CC-0. In Public Domain. Gurukul Kangri Collection, Haridwar

Digitized by Arya Samaj Foundation Chennai and eGangotri

branches to the cervix uteri and others which descend on the vagina, and anastomose with branches of the vaginal arteries and form with them two longitudinal vessels—the *azygos arteries of the vagina*—one of which descends in front of, and the other behind, the vagina. It supplies numerous branches to the body of the uterus, and from its terminal portion twigs are distributed to the tube and the round ligament of the uterus.

The **vaginal artery** usually corresponds to the inferior vesical in the male; it descends upon the vagina, supplying its mucous membrane, and sends branches to the bulb of the vestibule, the fundus of the bladder, and the contiguous part of the rectum. It assists in forming the azygos arteries of the vagina, and is frequently represented by two or three branches.

The **obturator artery** (fig. 703) passes forwards and downwards on the lateral wall of the pelvis, to the upper part of the obturator foramen, and, escaping from the pelvic cavity through the obturator canal, divides into an anterior and a posterior branch. In the pelvic cavity this vessel is in relation, laterally, with the obturator fascia, which separates it from the Obturator internus muscle; medially, with the ureter, ductus deferens, and peritoneum; the obturator nerve is above, and the obturator vein below it.

Branches.—Inside the pelvis, the obturator artery gives off (*a*) iliac branches to the iliac fossa; these supply the bone and the Iliacus, and anastomose with the iliolumbar; (*b*) a **vesical branch** which runs medialwards to the bladder and may replace the superior vesical branch of the hypogastric artery; and (*c*) a **pubic branch** which springs from the vessel just before it leaves the pelvic cavity; this branch ascends upon the back of the os pubis and anastomoses with the corresponding vessel of the opposite side, and with the pubic branch of the inferior epigastric artery.

Outside the pelvis, the obturator artery divides at the upper margin of the obturator foramen, into an anterior and a posterior branch which encircle the foramen under cover of the Obturator externus.

The **anterior branch** runs forwards on the outer surface of the obturator membrane and then curves downwards along the anterior margin of the foramen. It gives branches to the Obturator externus, Pectineus, Adductores, and Gracilis, and anastomoses with the posterior branch, and with the medial femoral circumflex artery.

The **posterior branch** follows the posterior margin of the foramen and turns forwards on the inferior ramus of the ischium where it anastomoses with the anterior branch; it gives twigs to the muscles attached to the ischial tuberosity and anastomoses with the inferior glutæal artery. It also supplies an articular branch which enters the hip through the acetabular notch, ramifies in the fat at the bottom of the acetabulum, and sends a twig along the ligamentum teres to the head of the femur.

Fig. 705.—Variations in the course of an abnormal obturator artery.

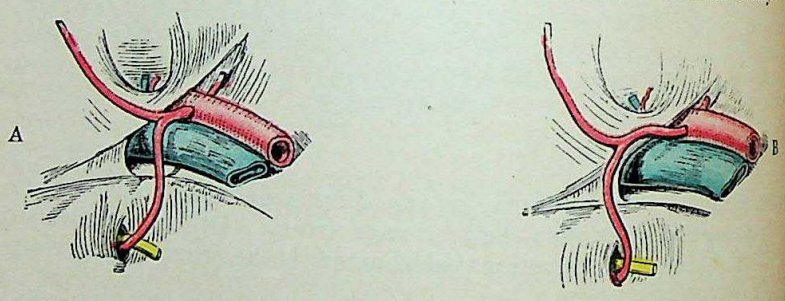

Peculiarities.—In about 28 per cent. of subjects the place of the obturator artery is taken by an enlarged pubic branch of the inferior epigastric artery (p. 686); this branch descends almost vertically to the upper part of the obturator foramen. The artery usually lies in contact with the external iliac vein, and on the lateral side of the femoral ring (fig. 705A); in such cases it would not be endangered in the operation for strangulated femoral hernia. Occasionally, however, it curves along the free margin of the lacunar ligament (fig. 705B), and if in such circumstances a femoral hernia occurred the vessel would almost completely encircle the neck of the hernial sac, and would be in great danger of being wounded if an operation were performed for strangulation. It sometimes arises from the main stem or from the posterior trunk of the hypogastric artery, or it may spring from the superior glutæal artery: occasionally it arises from the external iliac artery.

The **internal pudendal artery** (figs. 703, 706, 707), the smaller of the two terminal branches of the anterior trunk of the hypogastric artery, supplies the external

CC-0. In Public Domain. Gurukul Kangri Collection, Haridwar

Digitized by Arya Samaj Foundation Chennai and eGangotri

ans of generation. Though the course of the artery is the same in the two sexes, vessel is smaller in the female than in the male, and the distribution of its has somewhat different. The description of the artery in the male will first en, and subsequently the differences which it presents in the female will be ned.

he **internal pudendal artery in the male** passes downwards and lateralwards the lower border of the greater sciatic foramen, and emerges from the pelvis ween the Piriformis and Coccygeus; it then crosses the ischial spine, and enters perinæum through the lesser sciatic foramen. The artery now crosses the ator internus, along the lateral wall of the ischiorectal fossa, being situated t 4 cm. above the lower margin of the ischial tuberosity. It gradually aches the margin of the inferior ramus of the ischium and passes forwards ween the two layers of the fascia of the urogenital diaphragm; it then runs ards along the medial margin of the inferior ramus of the os pubis, and at a nce of about 1·25 cm. behind the pubic arcuate ligament it pierces the inferior h of the urogenital diaphragm and divides into the *dorsal* and *deep arteries* he penis.

Relations.—Within the pelvis, it lies in front of the Piriformis, the sacral plexus nerves, and the inferior glutæal artery. As it crosses the ischial spine, it is ered by the Glutæus maximus; here the pudendal nerve lies to the medial and the nerve to the Obturator internus to the lateral side, of the vessel. In rinæum it lies on the lateral wall of the ischiorectal fossa in a fascial canal ck's canal); it is accompanied by a pair of venæ comitantes and the pudendal ve.

Branches.—The branches of the internal pudendal artery (figs. 706, 707) are:

Muscular.	Artery of the urethral bulb.
Inferior hæmorrhoidal.	Urethral.
Perinæal.	Deep artery of the penis.
Dorsal artery of the penis.	

The **muscular branches** consist of two sets; one given off in the pelvis; the other, as vessel crosses the ischial spine. The first set consists of several small offsets which ly the Levator ani, the Obturator internus, the Piriformis, and the Coccygeus. The ches of the second set are distributed to the Glutæus maximus and the external tor muscles of the thigh; they anastomose with branches of the inferior glutæal ery.

The **inferior hæmorrhoidal artery** arises from the internal pudendal as it passes above ischial tuberosity. Piercing the wall of Alcock's canal it divides into two or three nches which cross the ischiorectal fossa, and are distributed to the muscles and skin the anal region, and send offshoots round the lower edge of the Glutæus maximus to skin of the buttock. They anastomose with the corresponding vessels of the opposite e, with the superior and middle hæmorrhoidal arteries, and with the perinæal artery.

The **perinæal artery** arises from the internal pudendal artery, in front of the preceding nches, crosses either superficial or deep to the Transversus perinæi superficialis, and runs rwards in the interspace between the Bulbocavernosus and Ischiocavernosus, to both of ch it supplies branches, and finally divides into several **posterior scrotal branches** which distributed to the skin and dartos tunic of the scrotum. As it crosses the Transversus rinæi superficialis it gives off the **transverse perinæal artery** which runs transversely on s cutaneous surface of the muscle, and anastomoses with the corresponding vessel the opposite side and with the perinæal and inferior hæmorrhoidal arteries. It plies the Transversus perinæi superficialis and the structures between the anus and the thral bulb.

The **artery of the urethral bulb** is a short vessel of relatively large calibre which arises m the internal pudendal artery between the two layers of the fascia of the urogenital phragm; it passes medialwards, pierces the inferior fascia of the urogenital diaphragm, gives off branches which ramify in the bulb of the urethra and in the posterior part the corpus cavernosum urethræ. It supplies a small branch to the bulbo-urethral nd.

The **urethral artery** arises a short distance in front of the artery of the urethral bulb. ns forwards and medialwards, pierces the inferior fascia of the urogenital diaphragm enters the corpus cavernosum urethræ, in which it is continued forwards to the glans ch.

The **deep artery of the penis** (artery of the corpus cavernosum penis), one of the terminal nches of the internal pudendal artery, arises from that vessel while it is situated between e two fasciæ of the urogenital diaphragm; it pierces the inferior fascia, and, entering e crus penis obliquely, runs forwards in the centre of the corpus cavernosum penis close the septum.

CC-0. In Public Domain. Gurukul Kangri Collection, Haridwar

Digitized by Arya Samaj Foundation Chennai and eGangotri

The **dorsal artery of the penis** ascends between the crus penis and the pubic arch, and, piercing the inferior fascia of the urogenital diaphragm, passes between the layers of the suspensory ligament of the penis, and runs forwards on the dorsum of the penis to the glans, where it divides into two branches which supply the glans and prepuce. On the penis, it lies between the dorsal nerve and deep dorsal vein, the latter being on its lateral side. It supplies the skin and the fibrous sheath of the corpus cavernosum penis, sending branches through the sheath to anastomose with the deep artery of the penis.

The **internal pudendal artery in the female** is smaller than in the male; its origin and course are similar, and there is considerable analogy in the distribution of its branches. The perinæal artery supplies the labia pudendi; the artery to the bulb is distributed to the bulbus vestibuli and the erectile tissue of the vulva; the deep artery of the clitoris supplies the corpus cavernosum clitoridis; the dorsal artery of the clitoris gives branches to the dorsum of that organ, and ends in the glans and prepuce of the clitoris.

Peculiarities.—The internal pudendal artery is sometimes relatively small, and fails to give off one or two of its usual branches; in such cases the deficiency is supplied by branches derived from an additional vessel, the *accessory pudendal*, which sometimes arises from the internal pudendal artery before its exit from the greater sciatic foramen. It passes forwards along the lower part of the bladder and across the side of the prostate to the root of the penis, where it perforates the urogenital diaphragm, and gives off the branches usually derived from the internal pudendal artery. The deficiency most frequently met with is that in which the internal pudendal artery ends as the artery of the urethral bulb, the dorsal and deep arteries of the penis being derived from the internal pudendal artery. The internal pudendal artery may also end as the perinæal, the artery of the urethral bulb being derived, with the other two branches, from the accessory vessel. Occasionally the accessory pudendal artery is derived from one of the other branches of the hypogastric artery, most frequently the inferior vesical or the obturator.

The **inferior glutæal artery** (sciatic artery) (figs. 703, 708), the larger of the terminal branches of the anterior trunk of the hypogastric artery, is distributed chiefly to the buttock and the back of the thigh. It passes down on the sacral plexus of nerves and the Piriformis, behind the internal pudendal artery, to the lower part of the greater sciatic foramen, through which it escapes from the pelvis between the first and second sacral nerves, and between the Piriformis and Coccygeus. It then descends in the interval between the greater trochanter of the femur and the tuberosity of the ischium, accompanied by the sciatic and posterior femoral cutaneous nerves, and covered by the Glutæus maximus; it is continued down the back of the thigh, supplying the skin, and anastomosing with branches of the perforating arteries.

Branches.—*Inside the pelvis.* It distributes (*a*) branches to the Piriformis, Coccygeus, and Levator ani; (*b*) branches supplying the fat around the rectum, which occasionally take the place of the middle hæmorrhoidal artery; and (*c*) branches to the fundus of the bladder, vesiculæ seminales, and prostate.

Outside the pelvis.—**Muscular branches** supply the Glutæus maximus, the external rotators of the thigh, and the muscles attached to the tuberosity of the ischium; they anastomose with the superior glutæal, internal pudendal, obturator and medial femoral circumflex arteries.

Coccygeal branches run medialwards, pierce the sacrotuberous ligament, and supply the Glutæus maximus and the structures on the back of the coccyx.

The **arteria comitans nervi ischiadici**, a long slender vessel, accompanies the sciatic nerve for a short distance; it then penetrates it, and runs in its substance to the lower part of the thigh.

An **anastomotic branch**, directed obliquely downwards across the external rotator muscles of the thigh, assists in forming the so-called *cruciate anastomosis* by joining with the first perforating and the medial and lateral femoral circumflex arteries.

An **articular branch**, generally derived from the anastomotic, is distributed to the capsule of the hip-joint.

Cutaneous branches are distributed to the skin of the buttock and back of the thigh.

The **iliolumbar artery** (fig. 703), a branch of the posterior trunk of the hypogastric artery, runs upwards and lateralwards, in front of the sacro-iliac joint and the lumbosacral trunk, and behind the obturator nerve and the external iliac vessels to the medial border of the Psoas major, behind which it divides into a lumbar and an iliac branch.

CC-0. In Public Domain. Gurukul Kangri Collection, Haridwar

Digitized by Arya Samaj Foundation Chennai and eGangotri

FIG. 706.—The superficial branches of the internal pudendal artery, in the male.

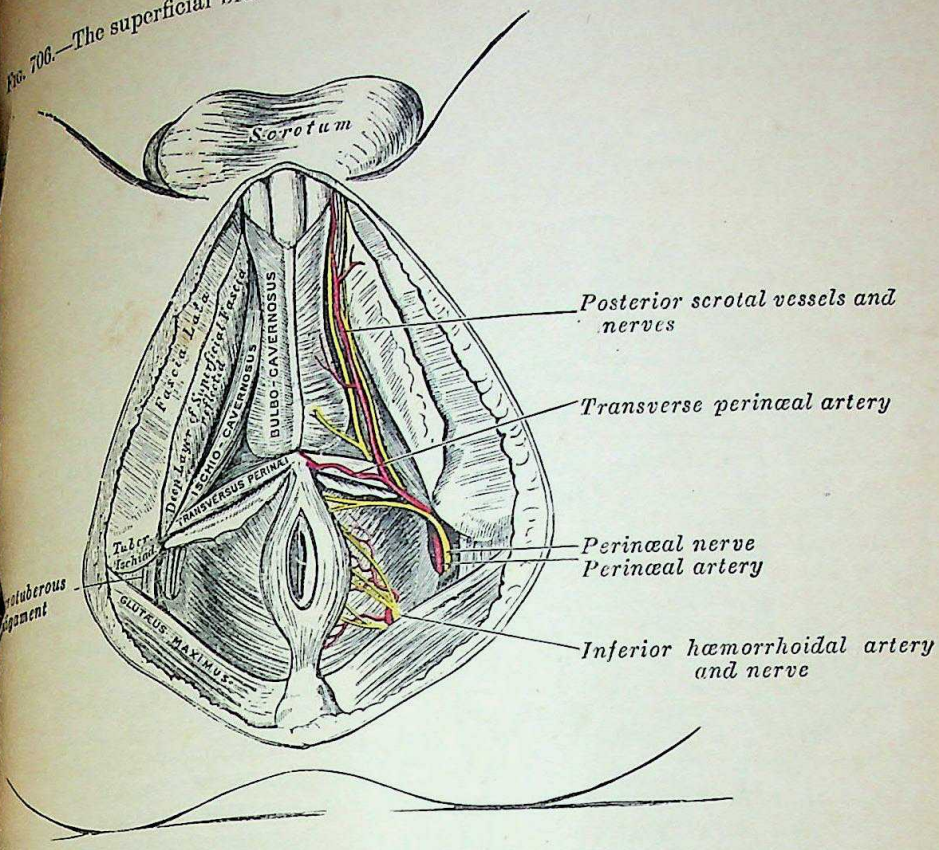

FIG. 707.—The deeper branches of the internal pudendal artery, in the male.

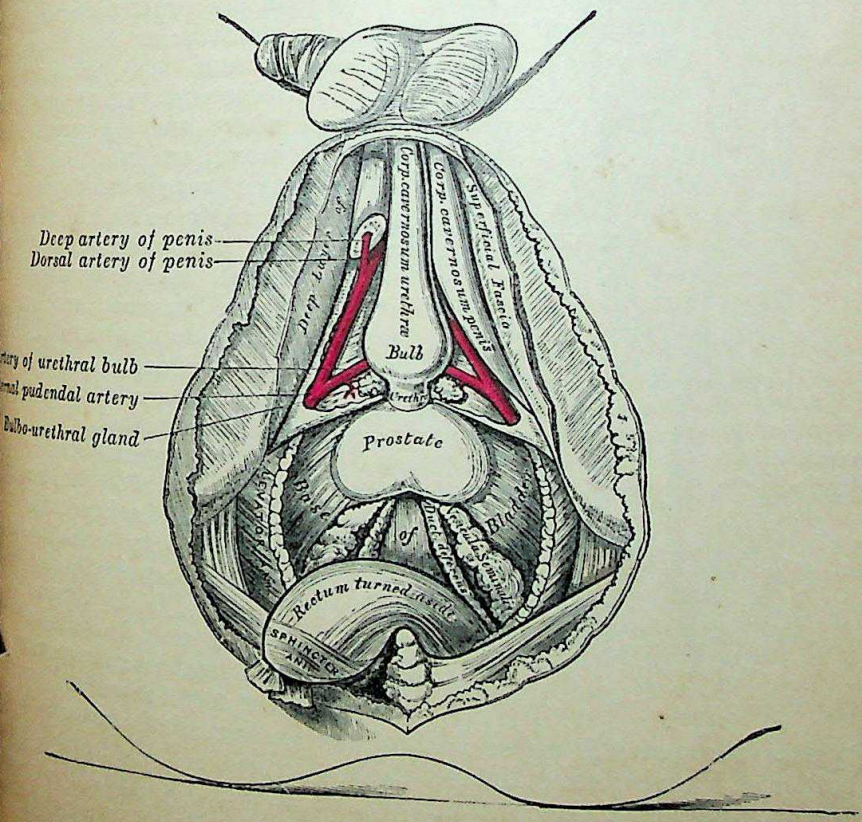

CC-0. In Public Domain. Gurukul Kangri Collection, Haridwar

Digitized by Arya Samaj Foundation Chennai and eGangotri

The **lumbar branch** supplies the Psoas major and Quadratus lumborum, and with the fourth lumbar artery, and sends a small *spinal branch* through the inter foramen between the fifth lumbar vertebra and the base of the sacrum, into the canal to supply the cauda equina.

The **iliac branch** supplies the Iliacus; some offsets run between the muscle bone and anastomose with the iliac branches of the obturator artery; one of these an oblique canal to supply while others run along the the ilium, distributing the glutæal and abdominal and anastomoses in their the superior glutæal, iliac flex, and lateral femoral arteries.

FIG. 708.—The arteries of the glutæal and posterior femoral regions.

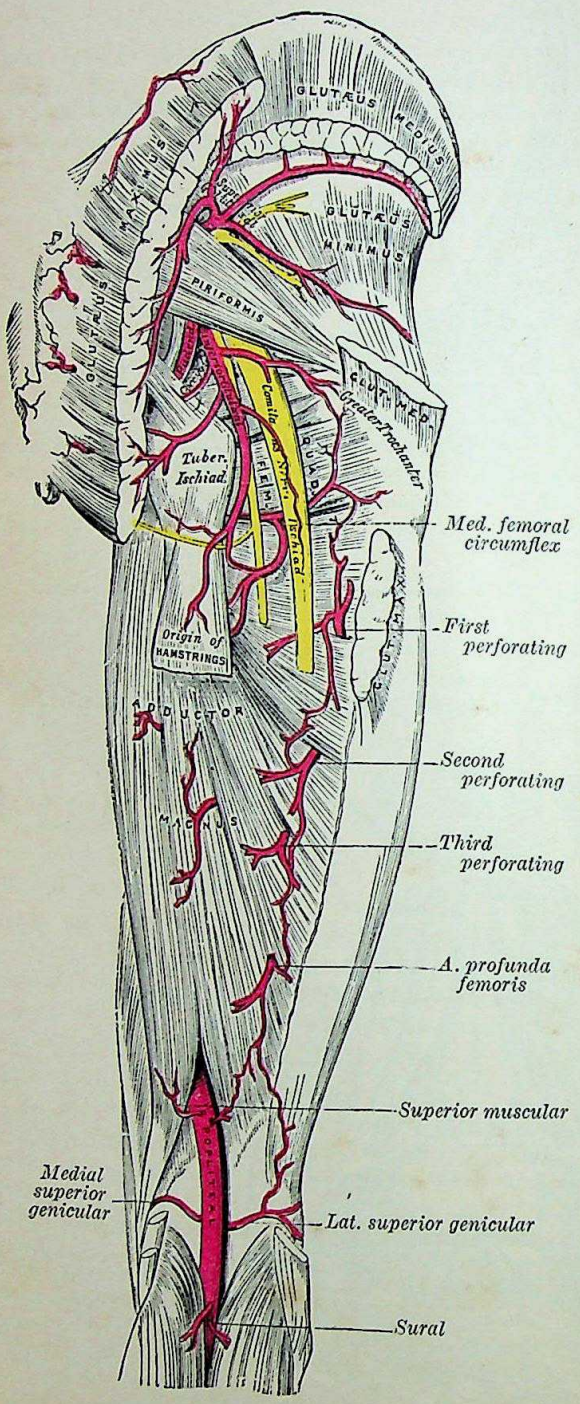

The **lateral sacral** (fig. 703) arise from the division of the hypogastric there are usually two, a and an inferior. The larger passes medialwards after anastomosing with from the middle sacral enters the first or second sacral foramen, supplies to the contents of the sacral and, escaping by the corresponding posterior sacral foramina distributed to the skin muscles on the dorsum of sacrum, anastomosing with superior glutæal artery. The *ferior* runs obliquely across front of the Piriformis and sacral nerves, to the medial of the anterior sacral foramina descends on the front of sacrum, and anastomoses the coccyx with the middle artery and the opposite lateral sacral arteries. Branches this vessel enter the anterior sacral foramina, and, after supplying the contents of the canal, escape by the posterior sacral foramina, and are distributed to the muscles and on the dorsal surface of sacrum, anastomosing with glutæal arteries.

The **superior glutæal** (figs. 703, 708) is the branch of the hypogastric and appears to be the continuation of the posterior division of vessel. It is a short which runs backwards between the lumbosacral trunk and first sacral nerve, and, passing of the pelvis through the upper part of the greater sciatic foramen above upper border of the piriformis divides into a *superficial* and a *deep branch*. the pelvis it gives off a few branches to the Iliacus, Piriformis, and Obturator internus, and a nutrient artery to the hip-bone.

The *superficial branch* enters the deep surface of the Glutæus maximus, and divides into numerous branches; some of these supply the muscle and anastomose

CC-0. In Public Domain. Gurukul Kangri Collection, Haridwar

Digitized by Arya Samaj Foundation Chennai and eGangotri

the inferior glutæal artery; others perforate the tendinous origin of the muscle, under the skin covering the posterior surface of the sacrum, and anastomose with the posterior branches of the lateral sacral arteries.

The *deep branch* lies under the Glutæus medius and soon splits into a superior and inferior division. The *superior division* runs along the upper border of the Glutæus minimus to the anterior superior iliac spine, anastomosing with the deep circumflex artery and the ascending branch of the lateral femoral circumflex artery. The *inferior division* crosses the Glutæus minimus obliquely to the greater trochanter, distributes branches to this muscle and to the Glutæus medius, and anastomoses with the lateral femoral circumflex artery; some branches pierce the Glutæus minimus and supply the hip-joint.

Applied Anatomy.—The *superior glutæal artery* is ligatured by turning the patient on his side over on to his face and making an incision from the posterior superior spine of the iliac ilium to the upper and posterior angle of the greater trochanter. This exposes the Glutæus maximus, and its fibres are to be separated through the whole thickness of the muscle and pulled apart with retractors. The contiguous margins of the Glutæus minimus and Piriformis are now to be separated from each other, and the artery will be found emerging from the greater sciatic foramen. In ligature of the *inferior glutæal* artery, the incision should be made parallel with that for ligature of the superior glutæal about 4 cm. lower down. After the fibres of the Glutæus maximus have been separated, the vessel is to be sought at the lower border of the Piriformis; the sciatic nerve, which lies just above it, forms the chief guide to the artery.

The External Iliac Artery (fig. 703)

The **external iliac artery** is larger than the hypogastric artery, and runs obliquely downwards and lateralwards, along the medial border of the Psoas major, from the bifurcation of the common iliac artery to a point beneath the inguinal ligament, midway between the anterior superior iliac spine and the symphysis pubis, where it enters the thigh as the femoral artery.

Relations.—*In front and medially* the external iliac artery is in relation with the peritoneum and subperitoneal areolar tissue which separate the right artery from the termination of the ileum and frequently the vermiform process, and the left artery from the sigmoid colon and some coils of the small intestine. The beginning of the artery may be crossed by the ureter; in the female it is crossed by the ovarian vessels. The testicular vessels lie for some distance upon it near its termination, and it is crossed in this situation by the external spermatic branch of the genitofemoral nerve, the deep iliac circumflex vein, the ductus deferens in the male, and the round ligament of the uterus in the female. *Posteriorly*, it is separated from the medial border of the Psoas major by the iliac fascia. The external iliac vein lies partly behind the upper part of the artery, but is on the medial side of its lower part. *Lateral* to it is the Psoas major, from which it is separated by the iliac fascia. Numerous lymphatic vessels and lymph-glands lie on the front and sides of the vessel.

Applied Anatomy.—The external iliac artery may be ligatured in any part of its course, excepting near its upper end, which is to be avoided on account of the proximity of the hypogastric artery, and near its lower end, which should also be avoided on account of the proximity of its inferior epigastric and deep iliac circumflex branches. The operation may be performed by opening the abdomen and incising the peritoneum over the artery (*transperitoneal*); or by an incision in the iliac region, dividing all the structures down to the peritoneum, which is then separated unopened from the iliac fossa until the artery is reached (*retroperitoneal*).

The transperitoneal ligature is essentially similar to that described on p. 678 for the common iliac artery. The advantages of this operation are: (1) if it be found necessary, the common iliac artery can be ligatured instead of the external iliac without extension or modification of the incision; and (2) the vessel can be ligatured without in any way interfering with the sac of an aneurysm.

The retroperitoneal ligature may be performed by an incision above and parallel to the lateral half of the inguinal ligament. The abdominal muscles and transversalis fascia having been divided, the peritoneum should be separated from the iliac fossa and pushed towards the pelvis; and on introducing the finger to the bottom of the wound, the artery may be felt pulsating along the medial border of the Psoas major. The external iliac vein, generally found on the medial side of the artery, must be cautiously separated from it, and the aneurysm needle introduced on the medial side, between the artery and vein.

CC-0. In Public Domain. Gurukul Kangri Collection, Haridwar

Digitized by Arya Samaj Foundation Chennai and eGangotri

Collateral Circulation.—The principal anastomoses by which the collateral circulation is established, after ligature of the external iliac artery, are: the iliolumbar with the iliac circumflex arteries; the superior glutæal with the lateral femoral circumflex; the obturator with the medial femoral circumflex artery; the inferior glutæal with the circumflex and first perforating branches of the arteria profunda femoris; and the internal pudendal with the external pudendal artery. When the obturator artery arises from the inferior epigastric artery, it is supplied with blood by branches from either the epigastric, the lateral sacral, or the internal pudendal arteries. The inferior epigastric artery receives its supply from the internal mammary and lower intercostal arteries and from the hypogastric artery by the anastomoses of its branches with the obturator artery.*

Branches.—Besides supplying several small branches to the Psoas muscle and the neighbouring lymph-glands, the external iliac artery gives off the inferior epigastric and deep circumflex iliac branches.

Fig. 709.—The right inferior epigastric artery, and the relations of the right femoral and abdominal inguinal rings. Seen from within the abdomen.

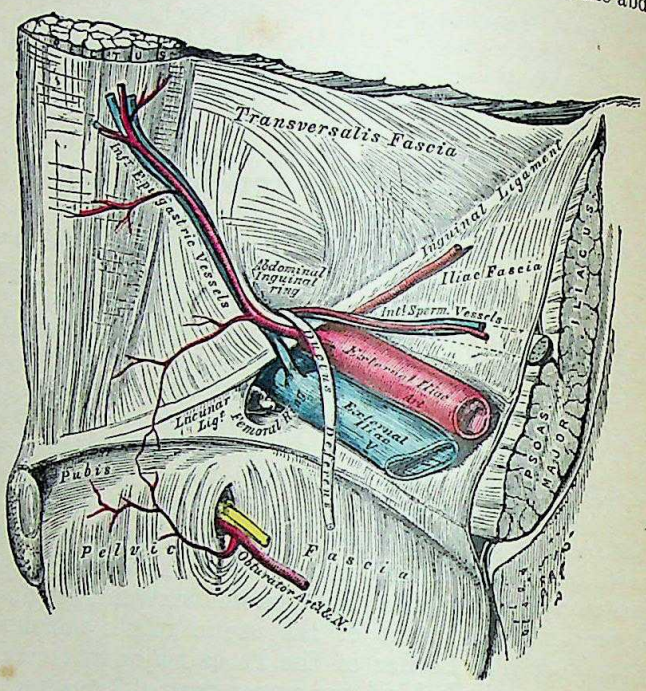

The **inferior epigastric artery** (deep epigastric artery) (figs. 559, 709) arises from the external iliac artery, immediately above the inguinal ligament. It curves forwards in the subperitoneal tissue, and then ascends obliquely along the medial margin of the abdominal inguinal ring; continuing its upward course, it pierces the transversalis fascia, passes in front of the linea semicircularis, and ascends between the Rectus abdominis and the posterior lamella of its sheath. It finally divides into numerous branches, which anastomose, above the umbilicus, with the superior epigastric branch of the internal mammary artery and with the lower intercostal arteries. As the inferior epigastric artery passes obliquely upwards from its origin it lies along the lower and medial margins of the abdominal inguinal ring, and behind the commencement of the spermatic cord. In the male the ductus deferens, and in the female the round ligament of the uterus, winds round the lateral and posterior aspects of the artery. The inferior epigastric artery supplies the following branches:

The **external spermatic artery** (cremasteric artery) accompanies the spermatic cord, supplies the Cremaster and other coverings of the cord, and anastomoses with the testicular artery. In the female the external spermatic artery is very small and accompanies the round ligament of the uterus.

A **pubic branch** descends along the medial margin of the femoral ring to the back of the os pubis, and there anastomoses with the pubic branch of the obturator artery.

* Sir Astley Cooper describes in vol. i. of the *Guy's Hospital Reports* the dissection of a limb eighteen years after successful ligature of the external iliac artery.

CC-0. In Public Domain. Gurukul Kangri Collection, Haridwar

Digitized by Arya Samaj Foundation Chennai and eGangotri

28 per cent. of subjects the pubic branch is large, and takes the place of the obturator (p. 680).

Branches are distributed to the abdominal muscles and the peritoneum, and anastomose the iliac circumflex and lumbar arteries.

Cutaneous branches perforate the tendon of the Obliquus externus abdominis, supply skin and anastomose with branches of the superficial epigastric artery.

Peculiarities.—The inferior epigastric artery may spring from any part of the external artery between the inguinal ligament and a point 6 cm. above it; or it may arise below this ligament, from the femoral artery. It frequently springs from the external iliac artery, by a common trunk with the obturator artery. Sometimes it arises from the obturator artery, or it may be formed of two branches, one from the external iliac artery, the other from the hypogastric artery.

Applied Anatomy.—The inferior epigastric artery has important surgical relations, and is one of the principal means, through its anastomosis with the internal mammary, in establishing the collateral circulation after ligature of either the common or external iliac arteries. It lies close to the abdominal inguinal ring, and is therefore *medial* to an oblique inguinal hernia, but *lateral* to a direct inguinal hernia, as these emerge from the abdomen. It forms the lateral boundary of Hesselbach's triangle, and is in close relationship with the spermatic cord, which lies in front of it in the inguinal canal, separated from it by the transversalis fascia. The ductus deferens hooks round its lateral side.

The **deep iliac circumflex artery** arises from the lateral side of the external iliac artery nearly opposite the inferior epigastric artery. It ascends obliquely behind the inguinal ligament, in a sheath formed by the junction of the transversalis and iliac fasciæ, to the anterior superior iliac spine, where it anastomoses with the ascending branch of the lateral femoral circumflex artery. It then pierces the transversalis fascia and passes along the inner lip of the crest of the ilium to about the middle, where it perforates the Transversus abdominis and runs backwards between that muscle and the Obliquus internus, to anastomose with the iliolumbar and superior glutæal arteries. Opposite the anterior superior iliac spine it gives off a large branch (fig. 557), which ascends between the Obliquus internus and Transversus, supplying them, and anastomosing with the lumbar and inferior epigastric arteries.

THE ARTERIES OF THE LOWER EXTREMITY

The chief artery of the lower extremity is a direct continuation of the external iliac. It extends from the level of the inguinal ligament to the lower border of the Popliteus, where it divides into the anterior and posterior tibial arteries. Its upper part is named the femoral artery, its lower the popliteal artery.

The Femoral Artery (figs. 714, 716)

The **femoral artery** is the continuation of the external iliac artery. It runs behind the inguinal ligament, midway between the anterior superior iliac spine and the symphysis pubis, and passes down the front and medial side of the thigh. It ends at the junction of the middle with the lower one-third of the thigh where it passes through an opening in the Adductor magnus to become the popliteal artery. The first 3 cm. or 4 cm. of the vessel are enclosed, together with the femoral vein, in the *femoral sheath*. The upper part of the femoral artery is contained in the *femoral triangle* (Scarpa's triangle), the lower part in the *adductor canal* (Hunter's canal).

The **femoral sheath** (figs. 710, 711) is formed by a prolongation downwards, behind the inguinal ligament, of the fasciæ which line the abdomen, the transversalis fascia being continued down in front of the femoral vessels and the iliopectineal fascia behind them. The sheath has the form of a short funnel, the wide end of which is directed upwards, while the lower, narrow end blends with the fascial investment of the vessels, about 3 or 4 cm. below the inguinal ligament. The lateral wall of the sheath is vertical and is perforated by the lumbo-inguinal nerve; the medial wall is directed obliquely downwards and lateralwards, and is pierced by the great saphenous vein and by some lymphatic vessels. The sheath is divided by two vertical partitions which

CC-0. In Public Domain. Gurukul Kangri Collection, Haridwar

Digitized by Arya Samaj Foundation Chennai and eGangotri

FIG. 710.—The femoral sheath laid open to show its three compartments.

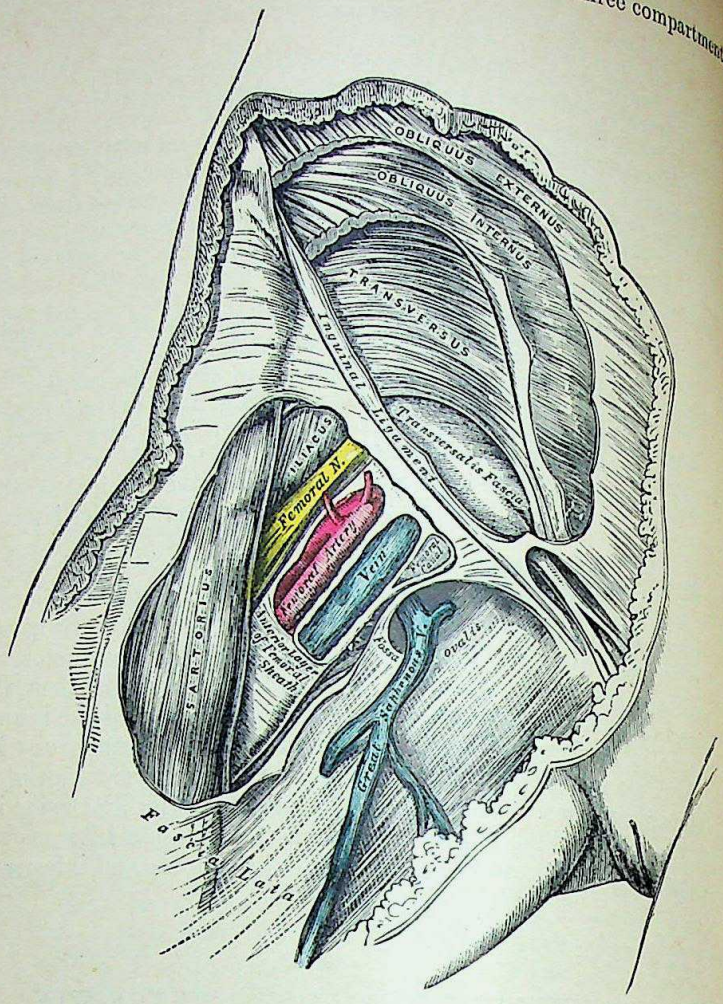

FIG. 711.—The structures passing behind the inguinal ligament.

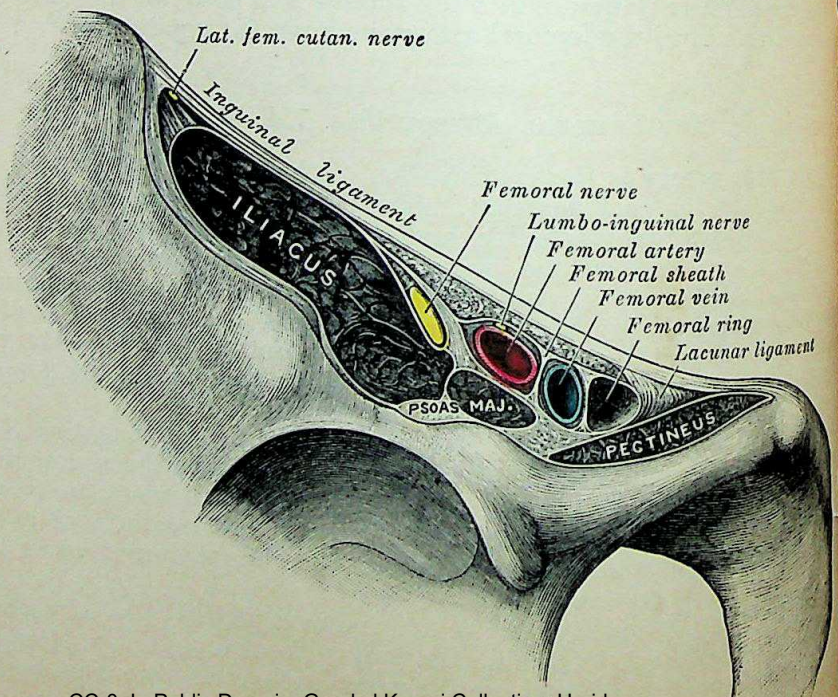

CC-0. In Public Domain. Gurukul Kangri Collection, Haridwar

Digitized by Arya Samaj Foundation Chennai and eGangotri

stretch between its anterior and posterior walls. The lateral compartment contains the femoral artery, and the intermediate the femoral vein; the medial and smallest compartment is named the *femoral canal*, and contains some lymphatic vessels and a lymph-gland, imbedded in a small amount of areolar tissue. The femoral canal is conical and measures 1·25 cm. in length; its base, directed upwards and named the *femoral ring*, is oval in form, its long transverse diameter measuring 1·25 cm. The femoral ring (fig. 711) is bounded in front by the inguinal ligament, behind by the Pectineus covered by its fascia, medially by the crescentic base of the lacunar ligament, and

Fig. 712.—A transverse section through the thigh at the level of the apex of the femoral triangle. Four-fifths of natural size.

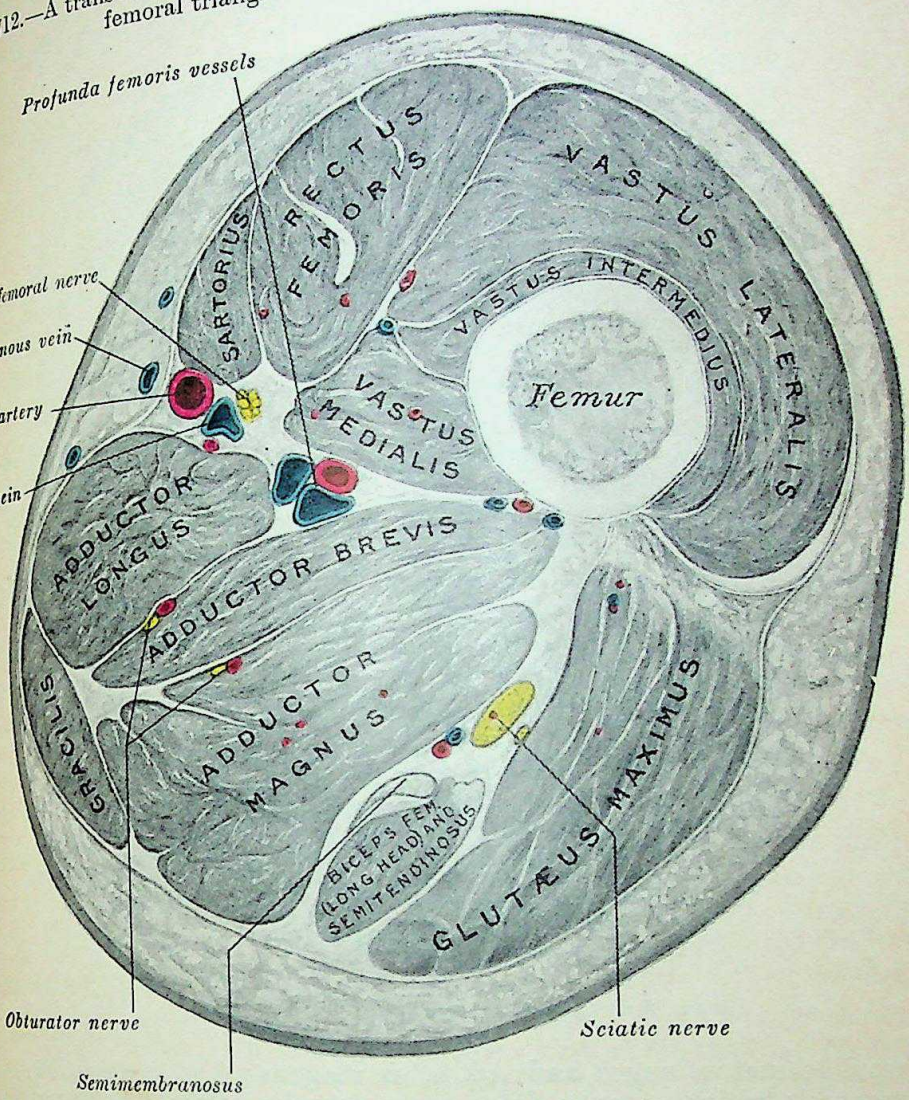

laterally by the femoral vein. The spermatic cord in the male, and the round ligament of the uterus in the female, lie immediately above the anterior margin of the ring, while the inferior epigastric vessels are close to its upper and lateral angle. The femoral ring is closed by a somewhat condensed portion of the extraperitoneal connective tissue, named the *septum femorale* (crural septum), the abdominal surface of which supports a small lymph-gland and is covered by the parietal layer of the peritoneum. The septum femorale is pierced by numerous lymphatic vessels passing from the deep inguinal to the external iliac lymph-glands, and the parietal peritoneum immediately above it presents a slight depression named the *femoral fossa*.

The **femoral triangle** (triangle of Scarpa) (fig. 714) corresponds to the depression seen immediately below the fold of the groin. Its apex is directed downwards, and the sides are formed, laterally by the medial margin of the Sartorius, medially by the medial margin of the Adductor longus, above by

CC-0. In Public Domain. Gurukul Kangri Collection, Haridwar

Digitized by Arya Samaj Foundation Chennai and eGangotri

the inguinal ligament. The floor of the triangle is formed from its lateral side by the Iliacus, Psoas major, Pectineus, and Adductor longus; and it is divided into two nearly equal parts by the femoral vessels. On the lateral side extend from near the middle of its base to its apex. On the lateral side of the femoral artery is the femoral nerve dividing into its branches. Besides the vessels and nerves, this triangle contains some fat and lymphatics.

The **adductor canal** (Hunter's canal) (fig. 713) is an aponeurotic tube in the middle one-third of the thigh, extending from the apex of the femoral triangle to the opening in the Adductor magnus. It is triangular on transverse section, and is bounded, in front and laterally, by the Vastus medialis; behind

FIG. 713.—A transverse section through the middle of the thigh. Four-fifths of natural size.

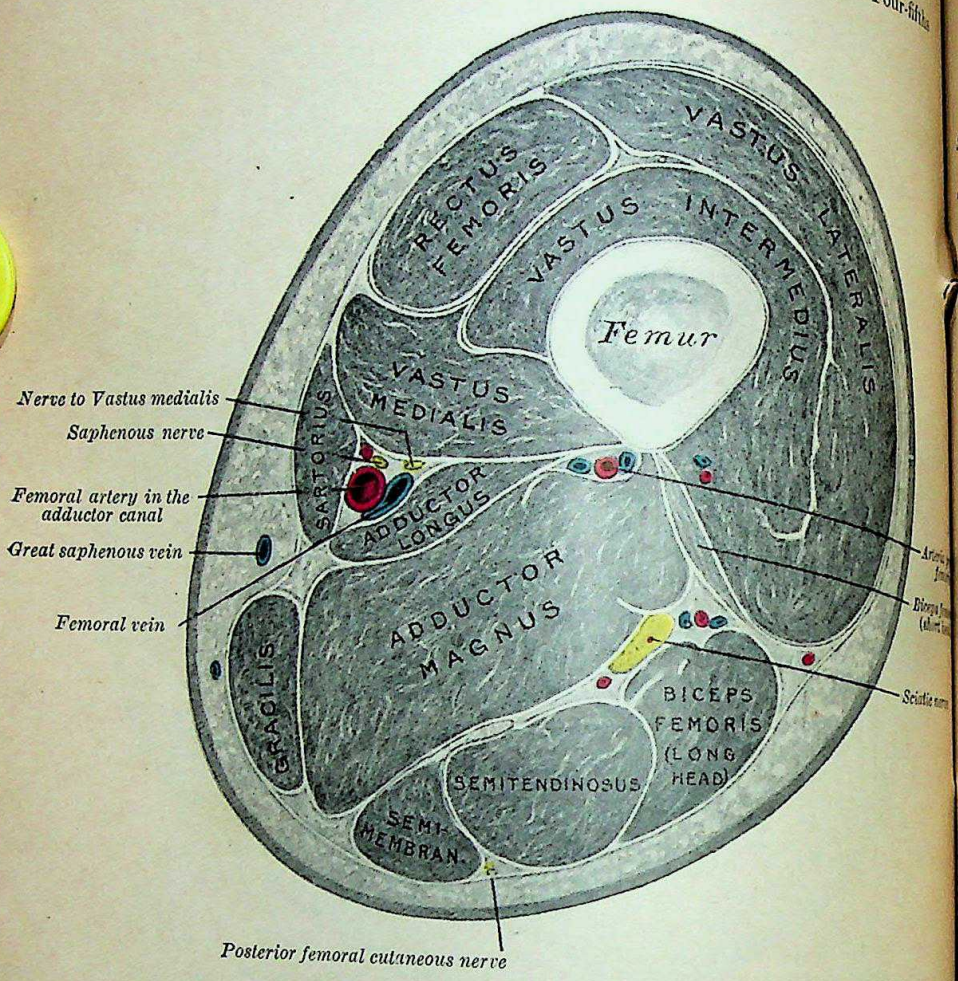

by the Adductor longus and Adductor magnus; and is roofed by a strong aponeurosis which extends from these muscles, across the femoral vessels, to the Vastus medialis; lying on the aponeurosis is the Sartorius. The canal contains the femoral artery and vein, the saphenous nerve; the nerve to the Vastus medialis traverses the proximal part of the abductor canal, and then enters its muscle.

The **relations of the femoral artery**.—In the *femoral triangle* (fig. 714) the artery is covered by the skin and superficial fascia, the superficial subinguinal lymph glands, the superficial iliac circumflex vein, the superficial layer of the fascia lata and the anterior part of the femoral sheath. The lumbo-inguinal nerve course for a short distance within the lateral compartment of the femoral sheath, and then at first in front of and then lateral to the artery. Near the apex of the femoral triangle the medial branch of the anterior femoral cutaneous nerve crosses the artery from its lateral to its medial side.

Behind the artery are the posterior part of the femoral sheath, the pectineal fascia, the tendon of the Psoas major, the Pectineus and the Adductor longus.

CC-0. In Public Domain. Gurukul Kangri Collection, Haridwar

Digitized by Arya Samaj Foundation Chennai and eGangotri

artery is separated from the capsule of the hip-joint by the tendon of the Psoas ; from the Pectineus by the femoral vein and profunda vessels, and from the ctor longus by the femoral vein. The nerve to the Pectineus passes medial- behind the artery. On the *lateral* side of the artery, is the femoral nerve. moral vein is medial to the artery in the upper part of the femoral triangle, osterior to the artery in the lower part.

In the *adductor canal* (figs. 713, 716) the femoral artery is more deeply situated, covered by the skin, the superficial and deep fasciæ, the Sartorius, and the

FIG. 714.—The left femoral triangle.

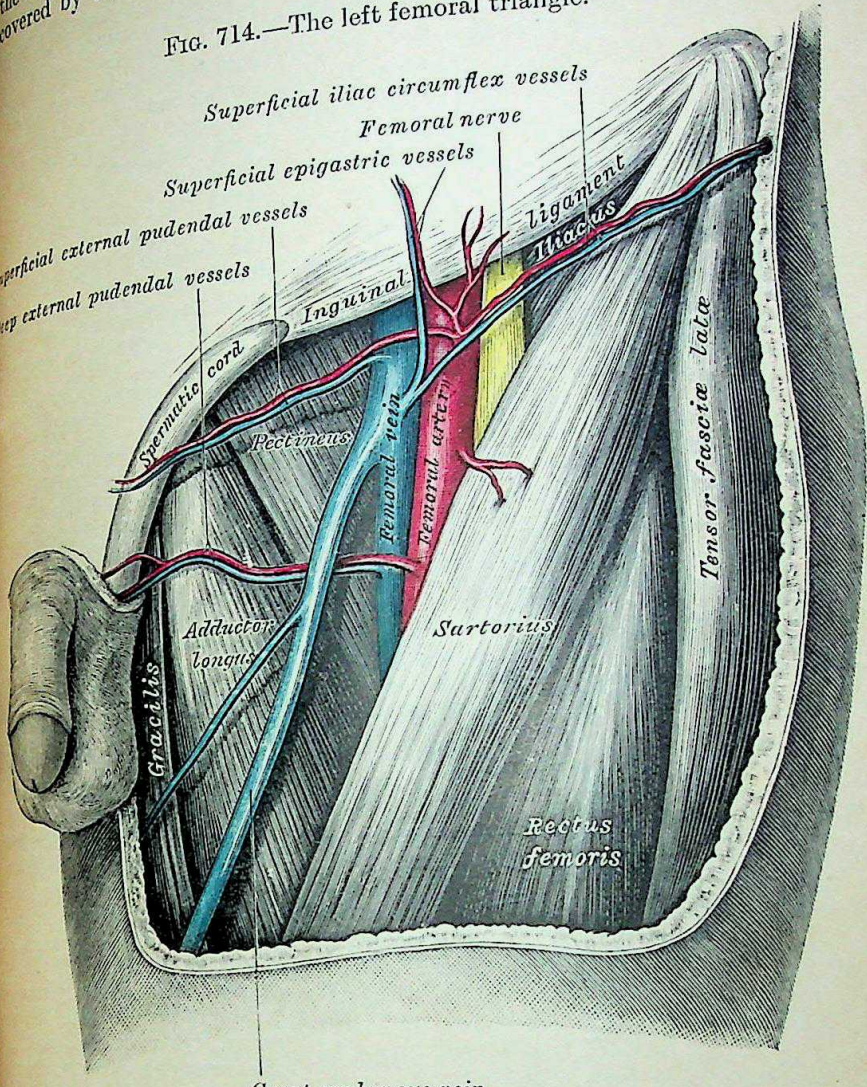

orms roof of the canal. The saphenous nerve is at first on the lateral side of the ery; it then lies in front of it, and below is placed on its medial side. Behind e artery are the Adductor longus and Adductor magnus ; in front and lateral to s the Vastus medialis. The femoral vein lies posterior to the upper, and lateral the lower, part of the artery.

Peculiarities.—Several instances are recorded where the femoral artery divided, below origin of the arteria profunda femoris, into two trunks, which reunited near the opening the Adductor magnus ; a few have been reported where the femoral artery was absent, lace being supplied by the inferior glutæal artery which accompanied the sciatic nerve e popliteal fossa ; in these the external iliac artery was small, and ended as the arteria nda femoris. The femoral vein is occasionally placed along the medial side of the ery throughout the entire extent of the femoral triangle ; or it may be duplicated so a large vein is placed on either side of the artery for a greater or lesser distance.

Applied Anatomy.—Compression of the femoral artery, which is constantly requisite amputations and other operations on the lower limb, is most effectually made immedi- below the inguinal ligament. In this situation the artery is superficial, and is separated

CC-0. In Public Domain. Gurukul Kangri Collection, Haridwar

Digitized by Arya Samaj Foundation Chennai and eGangotri

from the superior ramus of the os pubis by the Psoas major; here digital compression effectually control the circulation through it. The vessel may also be controlled in the middle third of the thigh by a tourniquet, which presses the vessel against the neck of the femur.

The femoral artery may be exposed and tied in any part of its course. The favourable situation is at the apex of the femoral triangle (fig. 715, B). An incision long should be made in the [illegible] the vessel, the patient being in the recumbent position with the [illegible] slightly flexed and abducted [illegible] rotated outwards. A large [illegible] frequently met with, passing [illegible] course of the artery to join the [illegible] saphenous vein, and must [illegible] avoided. The fascia lata [illegible] been cautiously divided, and [illegible] Sartorius displayed, the [illegible] must be drawn laterally [illegible] order to expose fully the sheath [illegible] the vessels. The finger [illegible] been introduced into the [illegible] and the pulsation of the [illegible] felt, the sheath is opened [illegible] lateral side of the vessel [illegible] sufficient extent to allow of [illegible] introduction of the aneurysm [illegible] needle. In this part of the [illegible] tion the saphenous nerve and [illegible] nerve to the Vastus medialis, which are in close relation with the sheath, should be avoided. The aneurysm [illegible] needle must be kept close to [illegible] artery, to avoid the femoral [illegible] which lies behind the vessel in [illegible] part of its course, and is very closely bound up with it.

Fig. 715.—Dissections to show the femoral artery (A) at the base of the femoral triangle, (B) at the apex of the femoral triangle, and (C) in the adductor (Hunter's) canal.

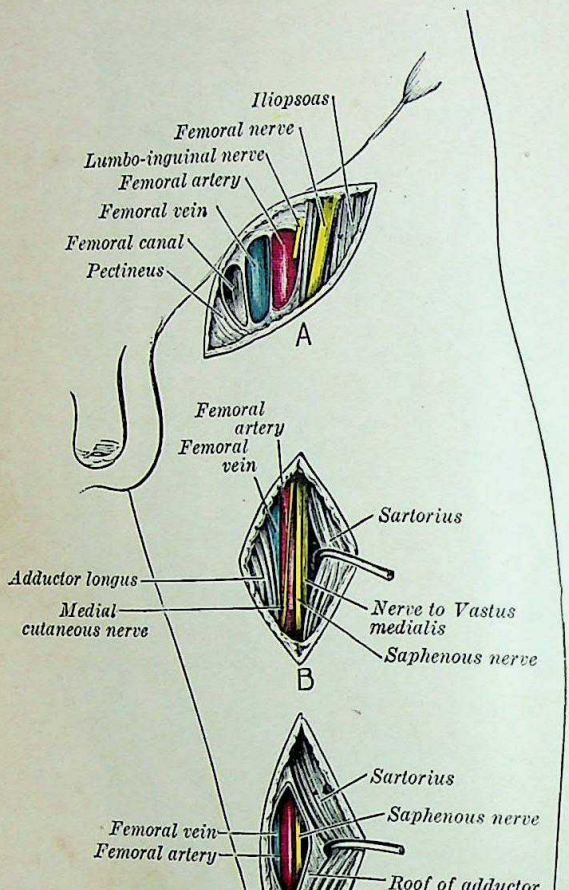

To ligature the artery immediately below the inguinal ligament (fig. 715, A) an incision 7 cm. in length is made with its centre a little below the ligament. The fascia lata is divided, and the sheath of the artery opened on the lateral side, where the lumbo-inguinal nerve may be met with. The aneurysm needle is now passed within the sheath from the medial to the lateral side of the artery so as to avoid injury to the femoral vein. The femoral nerve, lying on the lateral side of the artery, is separated from it by the femoral sheath and the fascia iliaca, and should not be seen (fig. 711).

To expose the artery in the adductor canal (fig. 715, C), an incision 7 cm. in length should be made a finger's breadth medial to the line of the artery, the centre of the incision being in the middle of the thigh—i.e. midway between the groin and the knee. The fascia lata having been divided, and the lateral border of the Sartorius exposed, this muscle should be drawn medialwards, when the strong fascia which is stretched across from the Adductors to the Vastus medialis will be observed, and must be freely divided; the sheath of the vessels is now seen, and must be opened, and the artery secured by passing an aneurysm needle between it and the vein, from the lateral to the medial side of the artery. In this situation the femoral vein lies lateral to, and the saphenous nerve in front of the artery.

Collateral Circulation.—After ligature of the femoral artery, the main channels carrying on the circulation are the following anastomoses:—(1) the superior and inferior glutæal branches of the hypogastric artery with the medial and lateral femoral circumflex and first perforating branches of the arteria profunda femoris; (2) the obturator branch of the hypogastric artery with the medial femoral circumflex of the arteria profunda femoris; (3) the internal pudendal branch of the hypogastric artery with the superficial and deep external pudendal branches of the femoral artery; (4) the deep iliac circumflex branch

CC-0. In Public Domain. Gurukul Kangri Collection, Haridwar

Digitized by Arya Samaj Foundation Chennai and eGangotri

internal iliac artery with the lateral femoral circumflex branch of the arteria profunda and the superficial iliac circumflex branch of the femoral artery; and (5) the inferior glutæal branch of the hypogastric artery with the perforating branches of the profunda femoris.

Branches.—The branches of the femoral artery are:

1. Superficial epigastric.
2. Superficial iliac circumflex.
3. Superficial external pudendal.
4. Deep external pudendal.
5. Muscular.
6. Profunda femoris.
7. Highest genicular.

1. The **superficial epigastric artery** (fig. 714) arises from the front of the femoral artery about 1 cm. below the inguinal ligament, and, piercing the femoral sheath and the fascia cribrosa, ascends in front of the inguinal ligament, and between the layers of the superficial fascia of the abdominal wall nearly as far as the umbilicus. It distributes branches to the superficial subinguinal lymph-glands, the superficial fascia, and the skin; it anastomoses with branches of the inferior epigastric artery, and with its fellow of the opposite side.

2. The **superficial iliac circumflex artery** (fig. 714), the smallest of the superficial branches of the femoral artery, arises close to the preceding vessel, and, piercing the fascia lata, runs lateralwards, parallel with the inguinal ligament, as far as the iliac crest; it gives branches to the skin, superficial fascia, and superficial subinguinal lymph-glands, and anastomoses with the deep iliac circumflex, the superior glutæal and the lateral femoral circumflex arteries.

3. The **superficial external pudendal artery** (fig. 714) arises from the medial side of the femoral artery, close to the preceding vessels, and, after piercing the femoral sheath and fascia cribrosa, courses medialwards, across the spermatic cord (or round ligament of the uterus in the female), to be distributed to the skin on the lower part of the abdomen, the penis and scrotum in the male, and the labium majus in the female, anastomosing with branches of the internal pudendal artery.

4. The **deep external pudendal artery** (fig. 714) passes medialwards across the Pectineus and the Adductor longus; it is covered by the fascia lata, which it pierces on the medial side of the thigh, and is distributed, in the male, to the skin of the scrotum and perinæum, in the female to the labium majus; its branches anastomose with the scrotal (or labial) branches of the perinæal artery.

5. **Muscular branches** are supplied by the femoral artery to the Sartorius, Vastus medialis, and Adductores.

6. The **arteria profunda femoris** (figs. 713, 716) is a large vessel arising from the lateral side of the femoral artery, about 3·5 cm. below the inguinal ligament. At first it lies lateral to the femoral artery; and then runs behind it and the femoral vein to the medial side of the femur; it is continued downwards behind the Adductor longus, and ends at the lower one-third of the thigh in a small branch which pierces the Adductor magnus and anastomoses with the superior muscular branches of the popliteal artery. The terminal part of the profunda is sometimes named the *fourth perforating artery*.

Relations.—*Behind* it, from above downwards, are the Iliacus, Pectineus, Adductor brevis, and Adductor magnus. *In front*, it is separated from the femoral artery by the femoral and profunda veins above, and by the Adductor longus below. *Laterally*, the origin of the Vastus medialis intervenes between it and the femur.

Peculiarities.—This vessel sometimes arises from the medial side, more rarely from the back of the femoral artery. In most cases it arises between 2·25 cm. and 5 cm. below the inguinal ligament; in a few cases the distance is less than 2·25 cm.; more rarely it arises opposite the ligament. Occasionally the distance between the origin of the vessel and the inguinal ligament exceeds 5 cm.

The arteria profunda femoris gives off the following branches:

Lateral femoral circumflex.	Perforating.
Medial femoral circumflex.	Muscular.

The **lateral femoral circumflex artery** (external circumflex artery) (fig. 716) arises from the lateral side of the profunda artery, passes lateralwards between the divisions of the femoral nerve and behind the Sartorius and Rectus femoris, and divides into ascending, transverse, and descending branches.

CC-0. In Public Domain. Gurukul Kangri Collection, Haridwar

Digitized by Arya Samaj Foundation Chennai and eGangotri

The *ascending branch* passes upwards beneath the Tensor fasciæ latæ, lateral part of the hip, and anastomoses with the terminal branches of the glutæal and deep iliac circumflex arteries.

The *descending branch* runs downwards, behind the Rectus femoris, over Vastus lateralis, to which it gives offsets; one long branch descends in the muscle as far as the knee, and anastomoses with the superior genicular branch of the popliteal artery. It is accompanied by the nerve to the Vastus lateralis.

Fig. 716.—The right femoral artery.

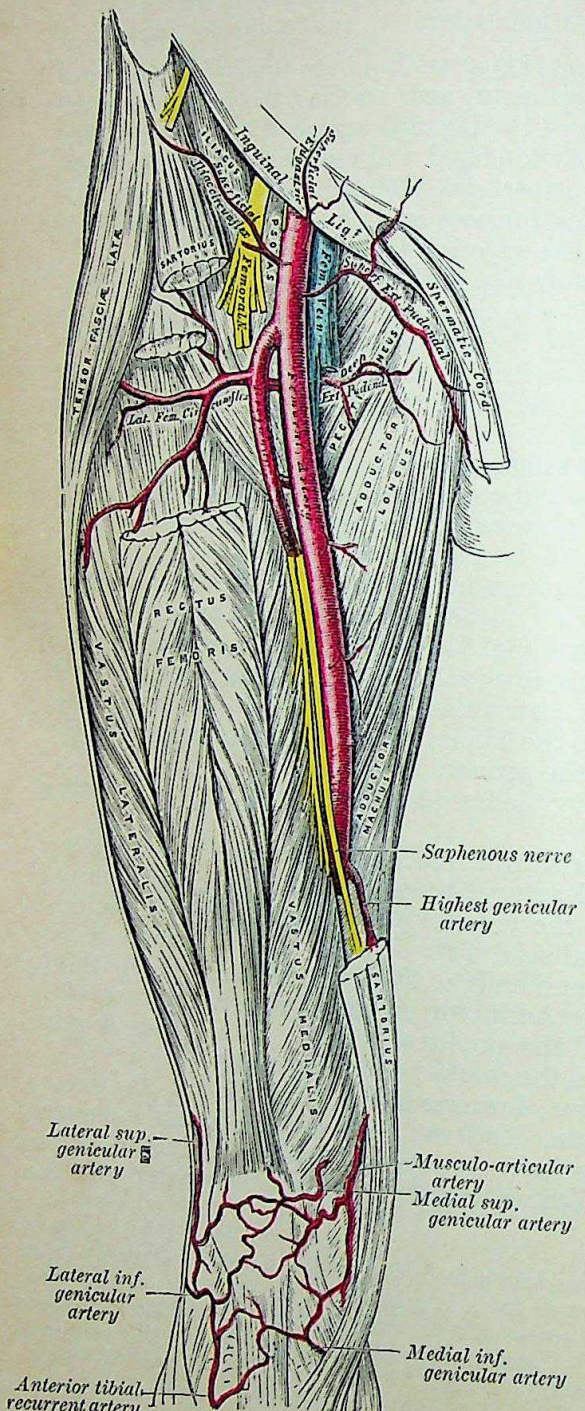
Inguinal
Superficial Epigastric
Superficial Circumflex Iliac
Sartorius
Tensor fasciæ latæ
Lig. T
Sup. Ext. Pudendal
Sheath of Femoral
Sheath of Femoral
Sheath of Femoral

Digitized by Arya Samaj Foundation Chennai and eGangotri

anastomosis arches in the insertion of the muscle. The first is given off above the Adductor brevis, the second in front of that muscle, and the third immediately below it.

The *first perforating artery* passes backwards between the Pectineus and Adductor brevis (sometimes it perforates the latter muscle); it then pierces the Adductor magnus close to the linea aspera. It gives branches to the Adductor brevis, Adductor magnus, Biceps femoris, and Glutæus maximus, and anastomoses with the inferior glutæal, medial and lateral femoral circumflex, and second perforating arteries.

The *second perforating artery*, larger than the first, but frequently arising in common with it, pierces the tendons of the Adductor brevis and Adductor magnus, and divides into ascending and descending branches which supply the posterior femoral muscles, anastomosing with the first and third perforating. The *nutrient* artery of the femur is usually given off from this artery; when two nutrient arteries are present they usually spring from the first and third perforating vessels.

The *third perforating artery* is given off below the Adductor brevis; it pierces the Adductor magnus and divides into branches which supply the posterior femoral muscles, and anastomose above with the higher perforating arteries, and below with the termination of the profunda and the muscular branches of the popliteal. The nutrient artery of the femur may arise from this branch.

The termination of the profunda artery, already described, is sometimes called the *fourth perforating artery*.

The perforating arteries form a double chain of anastomosing vessels, (*a*) in the muscles and (*b*) close to the linea aspera.

Numerous **muscular branches** arise from the arteria profunda femoris; some of these end in the Adductores, others pierce the Adductor magnus, give branches to the hamstrings, and anastomose with the medial femoral circumflex artery and with the superior muscular branches of the popliteal artery.

The **highest genicular artery** (arteria anastomotica magna) (figs. 716, 717) arises from the femoral just before it passes through the opening in the tendon of the Adductor magnus, and immediately divides into a saphenous and a musculo-articular branch.

The *saphenous branch* pierces the lower part of the roof of the adductor canal, and accompanies the saphenous nerve to the medial side of the knee. It passes between the Sartorius and Gracilis, and is distributed to the skin of the upper and medial part of the leg, anastomosing with the medial inferior genicular artery.

The *musculo-articular branch* descends in the substance of the Vastus medialis, and in front of the tendon of the Adductor magnus, to the medial side of the knee, where it anastomoses with the medial superior genicular and anterior recurrent tibial arteries. An offset from the musculo-articular branch crosses above the patellar surface of the femur, forming an anastomotic arch with the lateral superior genicular artery, and supplying branches to the knee-joint.

The Popliteal Fossa (figs. 717, 719)

Boundaries.—The **popliteal fossa or space** is a lozenge-shaped space at the back of the knee-joint. Laterally it is bounded by the Biceps femoris above, and by the Plantaris and the lateral head of the Gastrocnemius below; medially it is limited by the Semitendinosus and Semimembranosus above, and by the medial head of the Gastrocnemius below. The floor is formed by the popliteal surface of the femur, the oblique popliteal ligament of the knee-joint, the back of the upper end of the tibia, and the fascia covering the Popliteus; the fossa is covered by the popliteal fascia.

Contents (figs. 717, 719).—The popliteal fossa contains the popliteal vessels, the tibial and the common peronæal nerves, the termination of the small saphenous vein, the lower part of the posterior femoral cutaneous nerve, the articular branch from the obturator nerve, a few small lymph-glands, and a considerable quantity of fat. The tibial nerve descends through the middle of the fossa, lying under the popliteal fascia, and crossing the vessels posteriorly from the lateral to the medial side. The common peronæal nerve descends on the lateral side of the upper part of the fossa, close to the tendon of the Biceps femoris. On the floor of the fossa are the popliteal vessels, the vein being

CC-0. In Public Domain. Gurukul Kangri Collection, Haridwar

Digitized by Arya Samaj Foundation Chennai and eGangotri

superficial to the artery and united to it by dense areolar tissue; the vein is a thick-walled vessel, and lies lateral to the artery above, and then crosses it posteriorly to gain its medial side below; sometimes it is double, the artery lying between the two veins, which are usually connected by short transverse branches. The articular branch from the obturator nerve descends upon the artery to the knee-joint. The popliteal lymph-glands, six or seven in number,

FIG. 717.—A transverse section through the thigh, 4 cm. proximal to the adductor tubercle of the femur. Four-fifths of natural size.

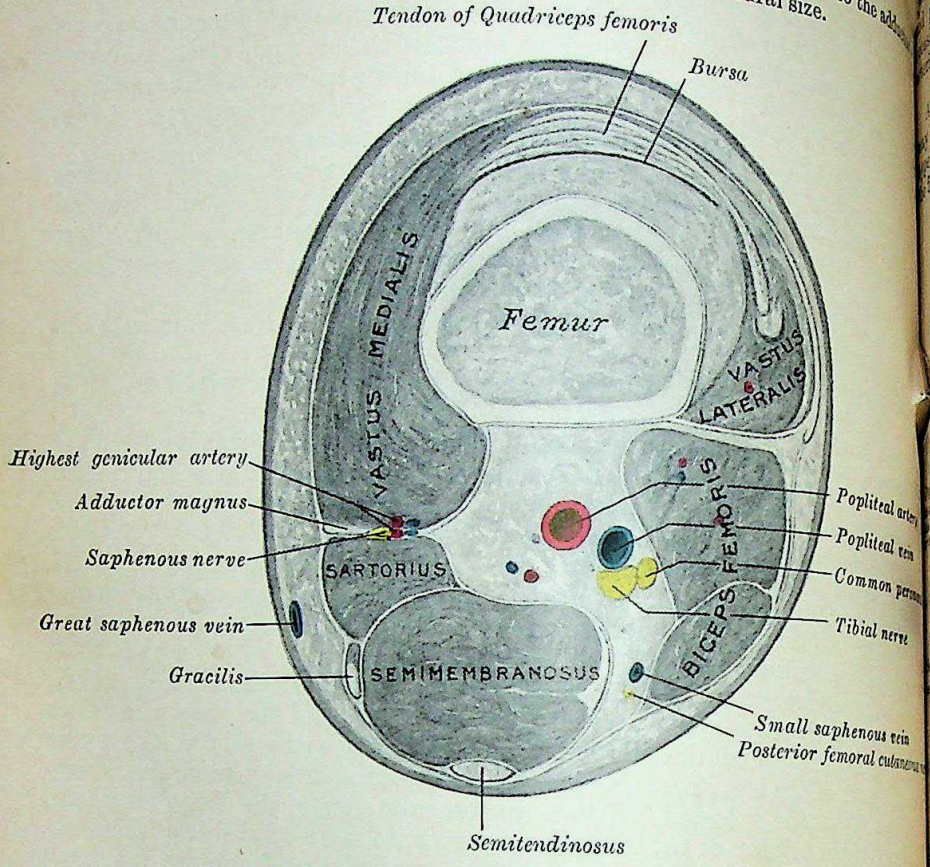

are imbedded in the fat; one lies beneath the popliteal fascia near the termination of the external saphenous vein, another between the popliteal artery and the back of the knee-joint, while the others are placed at the sides of the popliteal vessels.

THE POPLITEAL ARTERY (figs. 717, 719)

The popliteal artery is the continuation of the femoral artery, and courses through the popliteal fossa. It extends from the opening in the Adductor magnus, at the junction of the middle with the lower one-third of the thigh, downwards and lateralwards to the intercondyloid fossa of the femur, and then vertically downwards to the lower border of the Popliteus, where it divides into *anterior* and *posterior tibial arteries*.

Relations.—In *front* of the artery, from above downwards, are the popliteal surface of the femur (separated from the vessel by some fat), the back of the knee-joint, and the fascia covering the Popliteus. *Behind*, it is overlapped by the Semimembranosus above, and is covered by the Gastrocnemius and Plantaris below. In the middle part of its course the artery is separated from the skin and fascia by a quantity of fat, and is crossed from the lateral to the medial side by the tibial nerve and the popliteal vein, the vein being between the nerve and the artery and closely adherent to the latter. On its *lateral side*, above, are the Biceps femoris, the tibial nerve, the popliteal vein, and the lateral condyle of the femur; below, the Plantaris and the lateral head of the Gastrocnemius. On its *medial* side, above, are the Semimembranosus and the medial condyle of the femur; below, the tibial

CC-0. In Public Domain. Gurukul Kangri Collection, Haridwar

Digitized by Arya Samaj Foundation Chennai and eGangotri

the popliteal vein, and the medial head of the Gastrocnemius. The ...s of the popliteal lymph-glands to the artery are described on the ...ous page.

...liarities.—Occasionally the popliteal artery divides into its terminal branches ...ce the knee-joint; when this occurs the anterior tibial artery usually descends in ...of the Popliteus. The popliteal artery sometimes divides into the anterior tibial ...peroneal arteries, the posterior tibial artery being wanting or rudimentary; ...ally it divides into three branches, the anterior and posterior tibial, and peroneal ...

...plied Anatomy.—The popliteal artery is not infrequently the seat of injury. It ...be torn by direct violence, as by the passage of a cart-wheel over the knee, or by ...hyperextension of the knee. It may also be lacerated by fracture of the lower part of ...femur, or by anteroposterior dislocation of the knee-joint. It has been torn in break-

FIG. 718.—Dissections to show (A) the popliteal artery, (B) the upper part of the posterior tibial artery, and (C) the lower part of the posterior tibial artery.

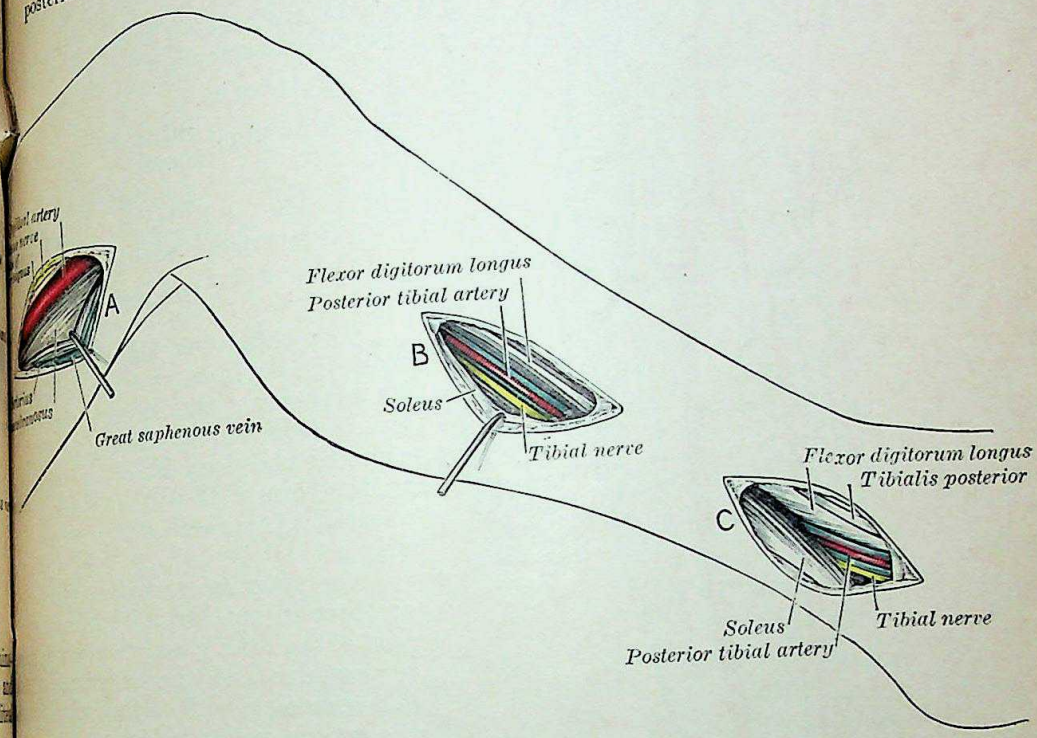

...down adhesions in cases of fibrous ankylosis of the knee, and is in danger of being ...nded in performing Macewen's operation of osteotomy of the lower end of the femur ...genu valgum. It is more frequently the seat of aneurysm than any other artery ...ge the thoracic aorta. No doubt this is due in a great measure to the amount of ...ement to which it is subjected, and to the fact that it is supported by loose and lax ...ue only, and not by muscles, as is the case with most arteries. When the knee is ...ely flexed, the popliteal artery becomes bent on itself to such an extent as entirely ...arrest the circulation through it.

In order to expose the upper part of the vessel (fig. 718, A), the patient should be placed ...the supine position, with the knee flexed and the thigh abducted and rotated outwards ...that it rests on its lateral surface; an incision 7 cm. or 8 cm. in length, beginning at ...junction of the middle with the lower one-third of the thigh, is to be made parallel to ...immediately behind the tendon of the Adductor magnus, and the skin, superficial ...deep fasciæ divided. The tendon of the muscle is thus exposed, and is to be drawn ...wards, and that of the Sartorius backwards. A quantity of fatty tissue will now be ...ed up, in which the artery will be felt pulsating. This tissue is to be separated with ...point of a director until the artery is exposed. The vein and nerve will not be seen, ...they lie to the lateral side of the artery. The sheath is to be opened, and the aneurysm ...le passed from before backwards, keeping its point close to the artery for fear of injuring ...vein. The only structure to avoid in the superficial incision is the great saphenous

CC-0. In Public Domain. Gurukul Kangri Collection, Haridwar

Digitized by Arya Samaj Foundation Chennai and eGangotri

To expose the vessel in the lower part of its course, where it lies between the heads of the Gastrocnemius, the patient should be placed in the prone position, the limb extended. An incision should be made through the skin in the popliteal space, commencing opposite the bend of the knee-joint, care being taken to avoid the saphenous vein and the medial cutaneous nerve. After dividing the deep fascia and separating some dense cellular tissue, the artery, vein, and nerve will be found between the two heads of the Gastrocnemius. Some muscular branches of the artery may be avoided if possible, or, if divided, immediately. The leg being now flexed, in order the more effectually to separate the heads of the Gastrocnemius, the nerve may be drawn medialwards and the vessels outwards, and the aneurysm needle passed between the artery and vein from the lateral to the medial side.

Fig. 719.—The right popliteal, posterior tibial, and peronæal arteries.

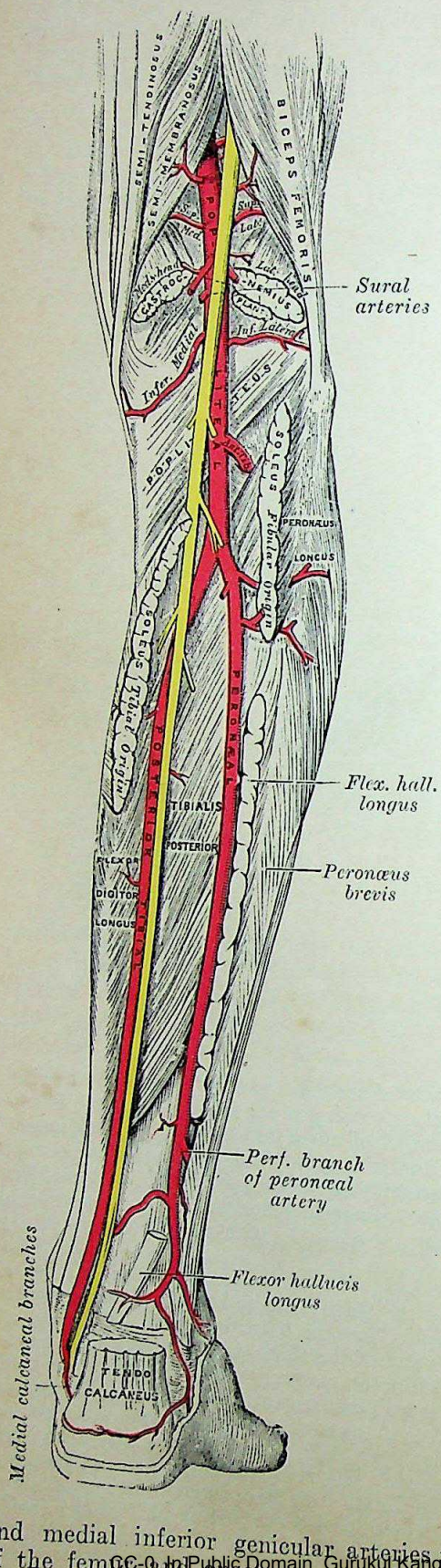

Branches.—The branches of the popliteal artery are:

- Cutaneous.
- Muscular { Superior. / Sural.
- Genicular { Superior { medial. / lateral. / Middle / Inferior { medial. / lateral.

The **cutaneous branches** arise from the popliteal artery or from some of its branches; they descend between the two heads of the Gastrocnemius, and, piercing the deep fascia, are distributed to the skin of the back of the leg; one usually accompanies the small saphenous vein.

The **superior muscular branches**, two or three in number, arise from the upper part of the artery, and pass to the Adductor magnus and the hamstring muscles, anastomosing with the terminal part of the arteria profunda femoris.

The **sural arteries** are two large branches which arise opposite the knee-joint and are distributed to the Gastrocnemius, Soleus, and Plantaris.

The **superior genicular arteries** (superior articular arteries) (figs. 719, 720), two in number, arise one on each side of the popliteal artery, and wind round the femur immediately above the condyles to the front of the knee-joint. The *medial superior genicular artery* runs in front of the Semimembranosus and Semitendinosus, above the medial head of the Gastrocnemius, and passes behind the tendon of the Adductor magnus, and divides into two branches, one of which supplies the Vastus medialis and anastomoses with the highest genicular of the femur, and anastomoses with the lateral superior genicular artery; the other ramifies close to the surface and medial inferior genicular arteries.

CC-0. In Public Domain. Gurukul Kangri Collection, Haridwar

Digitized by Arya Samaj Foundation Chennai and eGangotri

of the medial superior genicular artery varies inversely with that of the genicular. The *lateral superior genicular artery* passes beneath the tendon Biceps femoris, and divides into a superficial and a deep branch; the ial branch supplies the Vastus lateralis, and anastomoses with the ding branch of the lateral femoral circumflex artery and with the lateral r genicular artery; deep branch anasto- with the medial r genicular artery, forms an arch across front of the bone the highest genicular y.

The **middle genicular** (azygos articular y), a small branch, from the popliteal r opposite the back of knee-joint; it pierces lique popliteal liga- and supplies the te ligaments and ynovial stratum of articular capsule.

The **inferior genicular** es (inferior articular es) (figs. 719, 720), in number, arise from popliteal artery be- the Gastrocnemius. *medial inferior geni- artery* descends along upper margin of the teus, to which it s branches; it then es below the medial dyle of the tibia and eath the tibial col- eral ligament; at the erior border of this

Fig. 720.—The arterial anastomosis around the knee-joint.

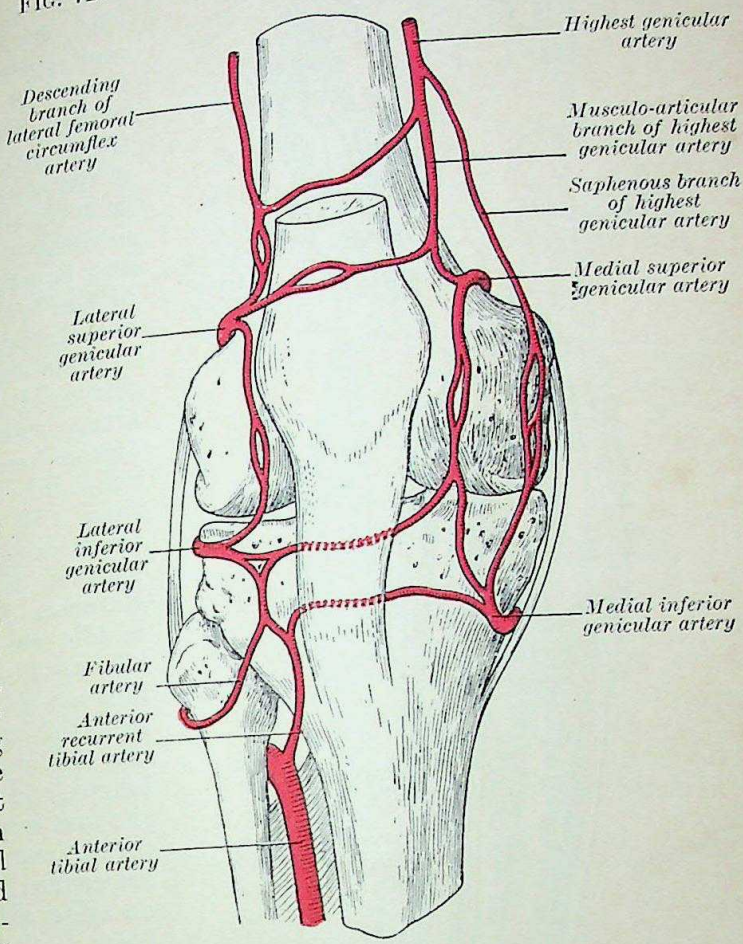

ment it ascends to the front and medial side of the joint, supplies the joint the upper end of the tibia, and anastomoses with the lateral inferior and medial erior genicular arteries. The *lateral inferior genicular artery* runs lateralwards ss the Popliteus, and then forwards above the head of the fibula to the front the knee-joint, passing in its course beneath the lateral head of the Gastro- nius, the fibular collateral ligament, and the tendon of the Biceps femoris. divides into branches which anastomose with the medial inferior genicular, eral superior genicular, and anterior recurrent tibial arteries.

The **anastomosis around the knee-joint** (fig. 720).—Around and above the tella, and on the contiguous ends of the femur and tibia, an intricate arterial stomosis forms a superficial and a deep network. The *superficial network* is ated between the fascia and skin round about the patella, and forms three well- ed arches; one above the patella in the loose connective tissue over the Quad- s femoris, and two below the patella in the fat behind the ligamentum patellæ. *deep network* lies on the lower end of the femur and upper end of the tibia around r articular surfaces, and sends numerous offsets into the interior of the joint. arteries which form the anastomosis are the two medial and the two lateral ular branches of the popliteal, the highest genicular, the descending branch of lateral femoral circumflex, the fibular, and the anterior recurrent tibial.

CC-0. In Public Domain. Gurukul Kangri Collection, Haridwar

Digitized by Arya Samaj Foundation Chennai and eGangotri

The Anterior Tibial Artery (figs. 721, 723)

The **anterior tibial artery** begins at the bifurcation of the popliteal at the lower border of the Popliteus. It passes forwards between the heads of the Tibialis posterior and through the upper part of the crural interosseous membrane, to the front of the leg, lying close to the fibula side of the neck of the fibula; now descends on the anterior face of the crural interosseous membrane, gradually approaching the tibia: at the lower part of the tibia it lies on this bone (fig. 724), then on the front of the ankle-joint, midway between the two malleoli, and is continued on to the dorsum of the foot under the name of the *dorsalis pedis* artery.

Fig. 721.—The right anterior tibial and dorsalis pedis arteries.

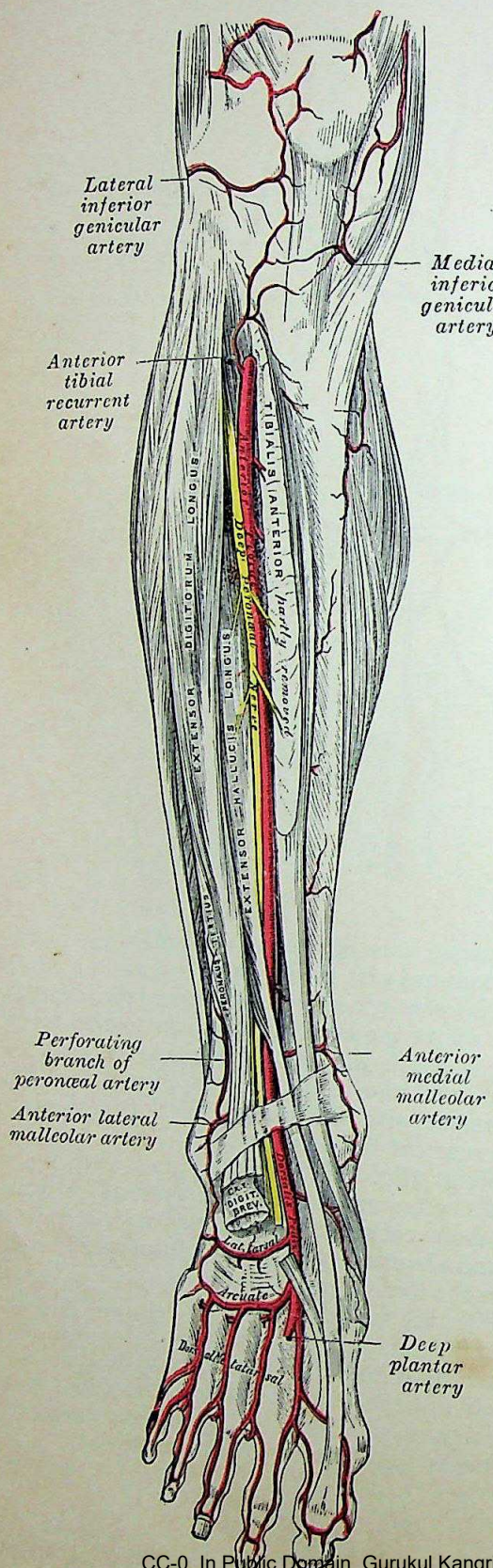

Relations.—In the upper two-thirds of its extent, the anterior tibial artery rests upon the crural interosseous membrane; in the lower one-third, upon the front of the tibia and the ankle-joint. In the upper one-third of its course, it is between the Tibialis anterior and Extensor digitorum longus; in the middle one-third between the Tibialis anterior and Extensor hallucis longus. At the ankle it is crossed from the lateral to the medial side by the tendon of the Extensor hallucis longus, and then lies between it and the first tendon of the Extensor digitorum longus. Its upper two-thirds are covered by the muscles which lie on either side of it, and by the deep fascia; its lower one-third, by the skin and fascia, and the transverse and cruciate crural ligaments.

A pair of venæ comitantes lie one on either side of the artery. The deep peronæal nerve, coursing round the lateral side of the neck of the fibula, comes into relation with the lateral side of the artery shortly after it reaches the front of the leg; about the middle of the leg the nerve is in front of the artery, at the lower part it is generally on the lateral side again.

Peculiarities.—This vessel may be smaller than usual, or may be absent, its place being supplied by perforating branches from the posterior tibial, or the perforating branch of the peroneal artery. The artery occasionally deviates towards the fibular side of the leg, but gaining its usual position at the front of the ankle. Very occasionally it approaches the surface at the middle of the leg, and is covered merely by the skin and fascia below that point

CC-0. In Public Domain. Gurukul Kangri Collection, Haridwar

Digitized by Arya Samaj Foundation Chennai and eGangotri

Applied Anatomy.—The anterior tibial artery is liable to be injured in fractures of the lower third of the tibia, on account of its close proximity to the bone. Ligature of the anterior tibial artery in the upper third of the leg is difficult on account of the depth of the vessel from the surface (fig. 722, B). An incision about 10 cm. in length is made 3 cm. lateral to the anterior border of the tibia. The skin and superficial structures having been divided and the deep fascia exposed, the white line separating the Tibialis anterior from the Extensor digitorum longus is sought. When this has been clearly defined, the deep fascia is to be divided in this line, and the Tibialis anterior separated from adjacent muscles until the interosseous membrane is reached. The foot is to be flexed in order to relax the muscles, and upon drawing them apart the artery will be found lying on the interosseous membrane with the nerve lateral or superficial to it. The nerve should be drawn lateralwards, the venæ comitantes separated from the artery and the needle passed around it.

To tie the vessel in the lower one-third of the leg (fig. 722, C), an incision about 7 cm. in length should be made through the skin between the tendons of the Tibialis anterior and Extensor hallucis longus, the deep fascia being divided to the same extent. The tendon on either side should be retracted, when the vessel, accompanied by the venæ comitantes, will be seen lying upon the tibia, with the nerve on the lateral side.

FIG. 722.—Dissections to show (A) the upper, (B) the lower, part of the anterior tibial artery, and (C) the arteria dorsalis pedis.

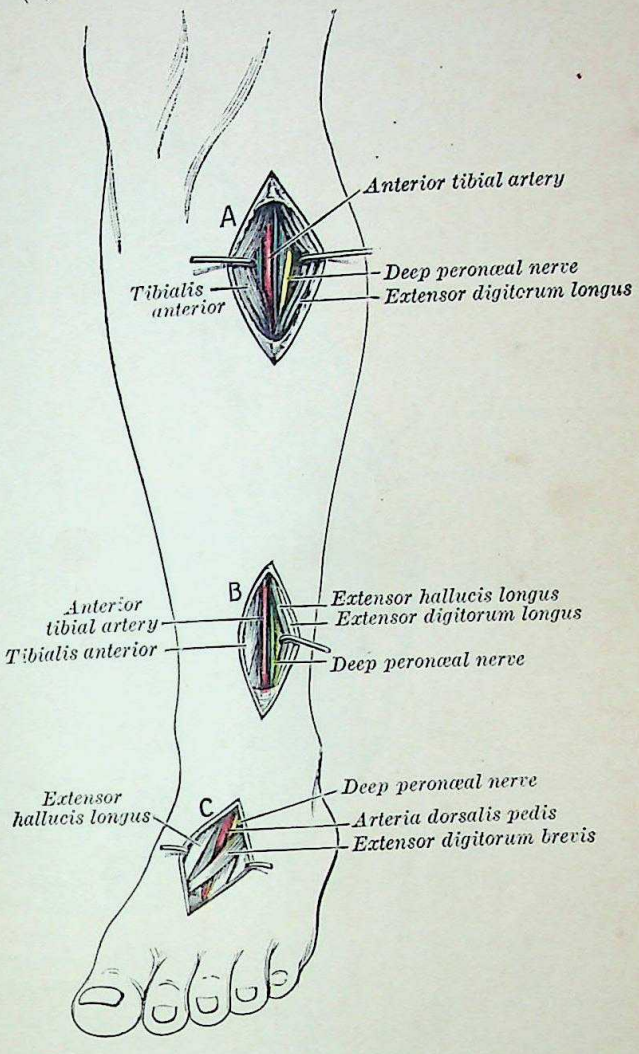

Branches.—The branches of the anterior tibial artery are :

Posterior tibial recurrent.	Anterior medial malleolar.
Anterior tibial recurrent.	Anterior lateral malleolar.
Muscular.	

The **posterior tibial recurrent artery,** an inconstant branch, is given off from the anterior tibial artery before that vessel reaches the front of the leg. It ascends in front of the Popliteus in company with the nerve to that muscle, anastomoses with the inferior genicular branches of the popliteal artery, and gives an offset to the tibiofibular joint.

The **anterior tibial recurrent artery** (fig. 721) arises from the anterior tibial artery, as soon as that vessel has reached the front of the limb ; it ascends in the Tibialis anterior, ramifies on the front and sides of the knee-joint, and assists in the formation of the patellar network by anastomosing with the genicular branches of the popliteal artery, and with the highest genicular artery.

The **muscular branches** are numerous and are distributed to the muscles which lie on either side of the vessel ; some pierce the deep fascia to supply the skin, others pass through the crural interosseous membrane, and anastomose with branches of the posterior tibial and peronæal arteries.

The **anterior medial malleolar artery** (internal malleolar artery) (fig. 721) arises about 5 cm. above the ankle-joint, and passes behind the tendons of the Extensor

CC-0. In Public Domain. Gurukul Kangri Collection, Haridwar

Digitized by Arya Samaj Foundation Chennai and eGangotri

hallucis longus and Tibialis anterior, to the medial side of the ankle, and anastomoses with branches of the posterior tibial and medial plantar arteries.

The **anterior lateral malleolar artery** (external malleolar artery) (fig. 721), beneath the tendons of the Extensor digitorum longus and Peronæus tertius, supplies the lateral side of the ankle and anastomoses with the perforating branch of the peronæal artery and with ascending twigs from the lateral tarsal artery.

FIG. 723.—A transverse section through the leg, 9 cm. distal to the knee-joint.

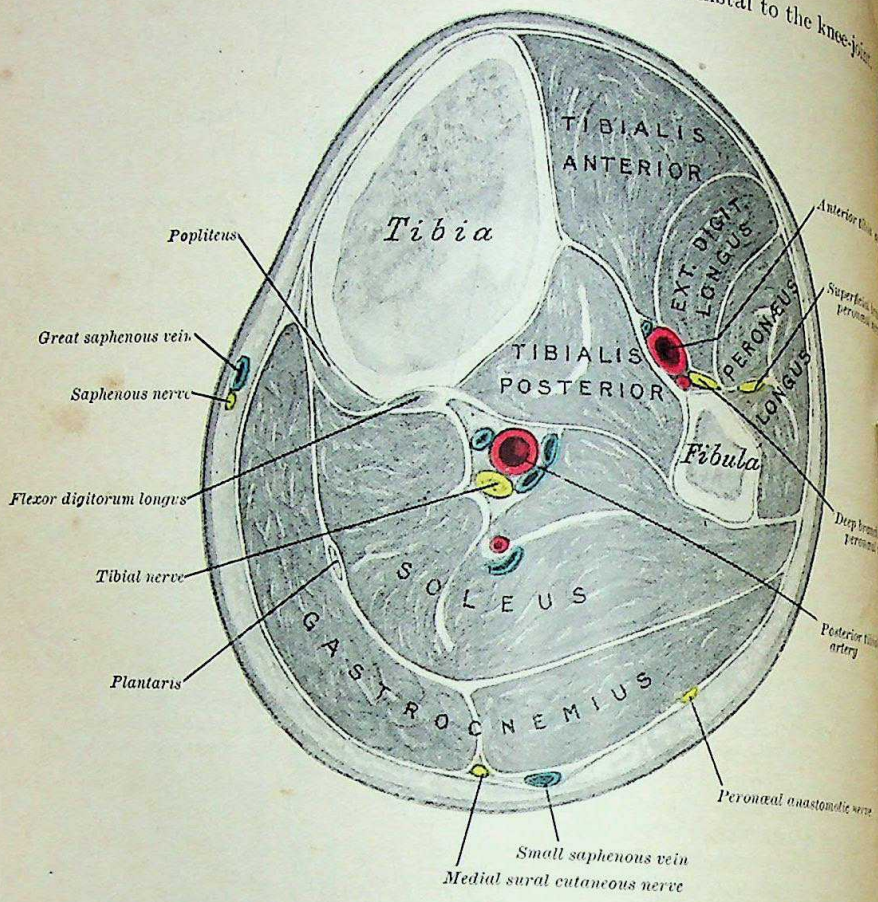

The arteries around the ankle-joint anastomose freely with one another and form networks below the corresponding malleoli. The *medial malleolar network* is formed by the anterior medial malleolar branch of the anterior tibial artery, the medial tarsal branches of the dorsalis pedis artery, the posterior medial malleolar and medial calcaneal branches of the posterior tibial artery, and branches from the medial plantar artery. The *lateral malleolar network* is formed by the anterior lateral malleolar branch of the anterior tibial artery, the lateral tarsal branch of the dorsalis pedis artery, the perforating and the lateral calcaneal branches of the peronæal artery, and twigs from the lateral plantar artery.

THE ARTERIA DORSALIS PEDIS (fig. 721)

The **arteria dorsalis pedis**, the continuation of the anterior tibial artery, passes forwards from the ankle-joint along the tibial side of the dorsum of the foot to the proximal part of the first intermetatarsal space, where it divides into the *first dorsal metatarsal* and the *deep plantar arteries*.

Relations.—The arteria dorsalis pedis is accompanied by two veins, and lies successively upon the front of the articular capsule of the ankle-joint, the talus, navicular, and second cuneiform bones, and the ligaments connecting them. It is covered by the skin, fascia, and cruciate crural ligament, and crossed near its termination by the first tendon of the Extensor digitorum brevis. On its *tibial side* is the tendon of the Extensor hallucis longus; on its *fibular side*, the first tendon

CC-0. In Public Domain. Gurukul Kangri Collection, Haridwar

Digitized by Arya Samaj Foundation Chennai and eGangotri

the Extensor digitorum longus, and the medial terminal branch of the deep peroneal nerve.

Peculiarities.—The arteria dorsalis pedis may be larger than usual, to compensate for a deficient plantar artery; or its place may be taken by a large perforating branch of the peroneal artery. It frequently curves lateralwards, lying lateral to the line between the middle of the ankle and the proximal part of the first interosseous space.

Applied Anatomy.—The arteria dorsalis pedis may be tied, by making an incision 5 cm. in length, through the skin on the fibular side of the tendon of the Extensor hallucis longus, in the interval between it and the medial border of the Extensor digitorum brevis (fig. 722, c). The incision should not extend farther forwards than the proximal part of the first intermetatarsal space, as the artery divides in that situation. When the deep fascia has been divided the artery will be exposed, with the deep peroneal nerve lying lateral to it.

Branches.—The branches of the arteria dorsalis pedis are:

Lateral tarsal.
Medial tarsal.
Arcuate.
First dorsal metatarsal.
Deep plantar.

The **lateral tarsal artery** (fig. 721) arises from the arteria dorsalis pedis as the latter crosses the navicular bone, and passes lateralwards beneath the Extensor digitorum brevis; it supplies this muscle and the articulations of the tarsus, and anastomoses with branches of the arcuate, anterior lateral malleolar, and lateral plantar arteries, and with the perforating branch of the peroneal artery.

The **medial tarsal arteries** are two or three small branches; they ramify on the medial border of the foot and join the medial malleolar network.

The **arcuate artery** (metatarsal artery) (fig. 721) arises from the arteria dorsalis pedis opposite the first cuneiform bone; it passes lateralwards over the bases of the metatarsal bones beneath the tendons of the Extensores digitorum longus et brevis, and anastomoses with the lateral tarsal and lateral plantar arteries. It gives off the *second, third,* and *fourth dorsal metatarsal arteries,* which run forwards upon the corresponding Interossei dorsales; in the clefts between the toes each divides into two dorsal digital branches for the sides of the adjoining toes. At the proximal parts of the interosseous spaces the dorsal metatarsal arteries receive the posterior perforating branches from the plantar arch, and at the distal parts of the spaces they are joined by the anterior perforating branches from the plantar metatarsal arteries. The fourth dorsal metatarsal artery gives off a branch which supplies the lateral side of the fifth toe.

The **first dorsal metatarsal artery** (arteria dorsalis hallucis) runs forward on the first Interosseus dorsalis, and at the cleft between the first and second toes divides into two branches, one of which passes beneath the tendon of the Extensor hallucis longus, and is distributed to the medial border of the great toe; the other bifurcates to supply the adjoining sides of the great and second toes.

The **deep plantar artery** (communicating artery) descends into the sole of the foot, between the two heads of the first Interosseus dorsalis, and completes the plantar arch by uniting with the lateral plantar artery. At its junction with this artery it gives off the *first plantar metatarsal artery* (p. 707).

The Posterior Tibial Artery (figs. 719, 723 724)

The **posterior tibial artery** begins at the lower border of the Popliteus, opposite the interval between the tibia and fibula, and passes downwards and medialwards on the back of the leg. In the lower part of its course it is situated midway between the medial malleolus and the medial process of the calcaneal tuberosity. It divides beneath the origin of the Abductor hallucis into the *medial and lateral plantar arteries.*

Relations.—The posterior tibial artery lies successively upon the Tibialis posterior, the Flexor digitorum longus, the tibia, and the back of the ankle-joint. Its upper part is beneath the Gastrocnemius and Soleus, and the deep transverse fascia of the leg; in the lower one-third of the leg it is covered only by the skin and fascia, and runs parallel with, and about 2·5 cm. in front of, the medial border of the tendo calcaneus; its terminal part is covered by the laciniate ligament and the Abductor hallucis. It is accompanied by two veins, and by the tibial nerve

CC-0. In Public Domain. Gurukul Kangri Collection, Haridwar

Digitized by Arya Samaj Foundation Chennai and eGangotri

which lies at first to its medial side, but soon crosses it posteriorly, and is greater part of its course, on its lateral side.

The structures which pass from the back of the leg to the sole of the foot cover of the laciniate ligament are arranged in the following order from the to the lateral side; first, the tendons of the Tibialis posterior and Flexor longus lying in the same groove behind the malleolus, the former being medial; then the posterior tibial artery, with a vein on either side of it; to the posterior tibial vessels is the tibial nerve; and about 1·25 cm. heel is the tendon of the Flexor hallucis longus.

Fig. 724.—A transverse section through the leg, 6 cm. proximal to the tip of the medial malleolus.

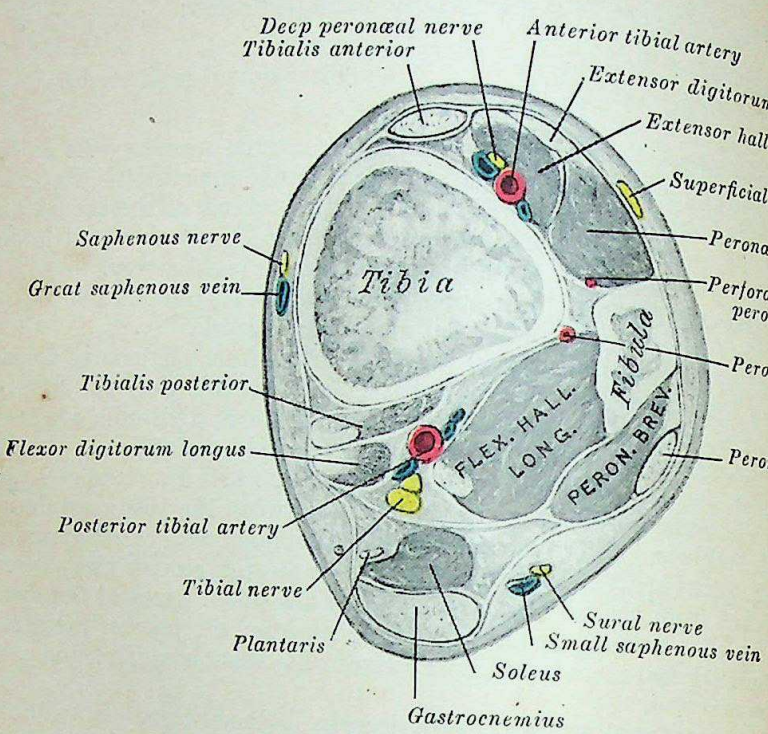

Peculiarities.—The posterior tibial artery may be small or absent, its place being supplied by a large peronæal artery, which either joins the small posterior tibial artery, or continues alone to the sole of the foot.

Applied Anatomy.—Ligature of the posterior tibial artery may be required in cases of wound of the sole of the foot, attended with great hæmorrhage; the vessel should then be tied at the ankle. In cases of wound of the posterior tibial, it will be necessary to enlarge the opening so as to expose the vessel at the wounded point, excepting where the vessel is injured by a punctured wound from the front of the leg.

To tie the posterior tibial artery at the ankle, a curved incision, about 6 cm. long, and with its convexity directed backwards, should be made through the skin about one finger's breadth behind the medial malleolus. The subcutaneous tissue having been divided, the laciniate (internal annular) ligament is seen. This is divided, and the sheath of the vessels exposed and opened, when the artery is seen with one of the venæ comitantes on either side. The aneurysm needle should be passed round the vessel from the heel towards the ankle, in order to avoid the tibial nerve.

Ligature of the vessel in the middle of the leg (fig. 718, B) is a difficult operation, on account of its depth from the surface. The patient being placed in the recumbent position, the limb should rest on its fibular side, the knee being partially bent, and the foot extended to relax the muscles of the calf. An incision about 10 cm. long should be made through the skin, a finger's breadth behind the medial margin of the tibia, care being taken to avoid the great saphenous vein. The deep fascia having been divided, the margin of the Gastrocnemius is exposed, and drawn aside, and the tibial attachment of the Soleus divided. The artery may now be felt pulsating beneath the deep transverse fascia, 2·5 cm. from the medial margin of the tibia. This fascia having been divided, and the limb placed in such a position as will relax the muscles of the calf as much as possible, the veins should be separated from the artery and the aneurysm needle passed round the vessel from the lateral to the medial side, so as to avoid the tibial nerve.

CC-0. In Public Domain. Gurukul Kangri Collection, Haridwar

Digitized by Arya Samaj Foundation Chennai and eGangotri

The four **plantar metatarsal arteries** (fig. 726) run forwards between the metatarsal bones and in contact with the Interossei. Each divides into a pair of plantar digital arteries which supply the adjacent sides of the toes. Near their points of division each plantar metatarsal artery sends upwards an *anterior perforating branch* to join the corresponding dorsal metatarsal artery. The first plantar metatarsal artery (arteria magna hallucis) springs from the junction between the lateral and medial plantar arteries (p. 703), and sends a digital branch to the medial side of the big toe. The digital branch for the lateral side of the fifth toe arises from the lateral plantar artery near the base of the fifth metatarsal bone.

Applied Anatomy.—Wounds of the plantar arch are always serious, on account of the depth of the vessel and the important structures which must be interfered with in an attempt to ligature it. They must be treated on similar lines to those of wounds of the palmar arches (p. 661). Pressure locally, combined with elevation of the limb, may in some cases be sufficient to arrest the bleeding, but if this fails, an attempt should be made to find the bleeding point and ligature it. Should this prove unsuccessful, it may be necessary to ligature the femoral artery below the origin of the arteria profunda femoris, as ligature of the anterior and posterior tibial arteries may not be sufficient to control the hæmorrhage, and under the circumstances it is safer and quicker to tie the femoral artery.

THE VEINS

The veins convey the blood from the different parts of the body to the heart. They receive the blood from the capillaries, and unite with one another to form larger vessels which, in their passage towards the heart, increase in size as they receive tributaries, or join other veins. The veins are larger and more numerous than the arteries; hence, the capacity of the veins is greater than that of the arteries; the capacity of the pulmonary veins, however, only slightly exceeds that of the pulmonary arteries. The veins are cylindrical like the arteries; their walls, however, are thin and they collapse when the vessels are empty, and the uniformity of their surfaces is interrupted at intervals by slight constrictions, which indicate the existence of valves in their interior (p. 573). They communicate very freely with one another, especially in certain regions of the body. Thus, between the venous sinuses of the cranium, and between the veins of the neck, where obstruction would be attended with imminent danger to the cerebral circulation, frequent anastomoses are found. Free communications also exist between the veins of the vertebral canal, and between the veins composing the various venous plexuses in the abdomen and pelvis.

The veins consist of two sets, *pulmonary* and *systemic*.

The **pulmonary veins**, unlike other veins, contain arterial blood which they return from the lungs to the left atrium of the heart.

The **systemic venous channels** return the venous blood from the body generally, to the right atrium of the heart, and are subdivided into three sets, viz. superficial and deep veins, and venous sinuses.

The **superficial veins** lie in the superficial fascia, beneath the skin; they return the blood from these structures, and eventually join the deep veins.

The **deep veins** accompany the arteries, and are usually enclosed in the same sheaths with those vessels. With the smaller arteries—as the radial, ulnar, brachial, tibial, peronæal—they exist generally in pairs, one lying on either side of the artery, and are called *venæ comitantes*. The larger arteries—such as the axillary, subclavian, popliteal, and femoral—have usually only one accompanying vein. In certain regions, however, the deep veins do not accompany the arteries; for instance, the cerebral veins, the veins of the skull and vertebral canal, the hepatic veins in the liver, and the larger veins returning blood from the bones.

Venous sinuses are found only in the interior of the skull, and are canals between the two layers of the dura mater.

The **portal vein**, an appendage to the systemic venous system, is confined to the abdominal cavity, and conveys the venous blood from the spleen and the viscera of digestion to the liver, where it breaks up into a network of capillary-like vessels, from which the blood is drained by the hepatic veins to the inferior vena cava.

CC-0. In Public Domain. Gurukul Kangri Collection, Haridwar

Digitized by Arya Samaj Foundation Chennai and eGangotri

THE PULMONARY VEINS

The **pulmonary veins** return the arterialised blood from the lungs to the left atrium of the heart. They are four in number, two from each lung, and are destitute of valves. They commence in the capillary network on the walls of the alveoli of the lungs, and, joining together, form one vessel from each lobule of the lung. These vessels, uniting successively, form a single vessel from each lobe, three from the right lung and two from the left. The vessel from the middle lobe of the right lung generally unites with that from the upper lobe, so that ultimately two veins, a superior and an inferior, from each lung; they perforate the fibrous layer of the pericardium and open separately into the upper and posterior part of the left atrium. Occasionally the three veins on the right side remain separate. Sometimes the two pulmonary veins end by a common opening.

In the root of the lung, the superior pulmonary vein lies in front of and a little below the pulmonary artery; the inferior is situated at the lowest part of the root of the lung and on a plane posterior to that of the superior vein. Behind the pulmonary artery is the bronchus.

On the right side the upper pulmonary vein passes behind the superior vena cava, and the lower behind the right atrium.

On the left side both pulmonary veins pass in front of the descending thoracic aorta.

Within the pericardium, their anterior surfaces are invested by the serous layer of this membrane.

THE SYSTEMIC VEINS

The **systemic veins** may be arranged into three groups: 1. The veins of the heart. 2. The veins of the upper extremities, head, neck, and thorax, which end in the superior vena cava. 3. The veins of the lower extremities, abdomen, and pelvis, which end in the inferior vena cava.

THE VEINS OF THE HEART

The **coronary sinus.**—Most of the veins of the heart open into the coronary sinus. This is a wide venous channel about 2 or 3 cm. long, situated in the posterior part of the coronary sulcus of the heart (fig. 727), between the left atrium and left ventricle, and covered by muscular fibres from the left atrium. It ends in the right atrium between the opening of the inferior vena cava and the atrioventricular orifice, its aperture being guarded by a semilunar valve, the *valve of the coronary sinus* (valve of Thebesius).

Its tributaries are the great, small, and middle cardiac veins, the posterior vein of the left ventricle, and the oblique vein of the left atrium, all of which, except the last, are provided with valves at their orifices.

1. The **great cardiac vein** (fig. 727) begins at the apex of the heart and ascends in the anterior longitudinal sulcus to the bases of the ventricles. It then curves to the left in the coronary sulcus, and, reaching the back of the heart, opens into the left extremity of the coronary sinus. It receives tributaries from the left atrium and from both ventricles: one, the *left marginal vein*, is of considerable size, and ascends along the left margin of the heart.

2. The **small cardiac vein** (fig. 727) runs in the coronary sulcus between the right atrium and ventricle, and opens into the right extremity of the coronary sinus. It receives blood from the back of the right atrium and ventricle; the *right marginal vein* ascends along the right margin of the heart and joins the small cardiac vein in the coronary sulcus, or opens directly into the right atrium.

3. The **middle cardiac vein** (fig. 727) begins at the apex of the heart, ascends in the posterior longitudinal sulcus, and ends in the coronary sinus near its right extremity.

4. The **posterior vein of the left ventricle** (fig. 727) runs on the diaphragmatic surface of the left ventricle a little to the left of the middle cardiac vein; it usually opens into the coronary sinus, but may end in the great cardiac vein.

CC-0. In Public Domain. Gurukul Kangri Collection, Haridwar

Digitized by Arya Samaj Foundation Chennai and eGangotri

3. The **oblique vein of the left atrium** (oblique vein of Marshall) (fig. 727) is a small vessel which descends obliquely on the back of the left atrium and ends in the coronary sinus near its left extremity; it is continuous above with the *ligament of the left vena cava* (vestigial fold of Marshall), and the two structures are remnants of the left duct of Cuvier.

FIG. 727.—The base and the diaphragmatic surface of the heart.

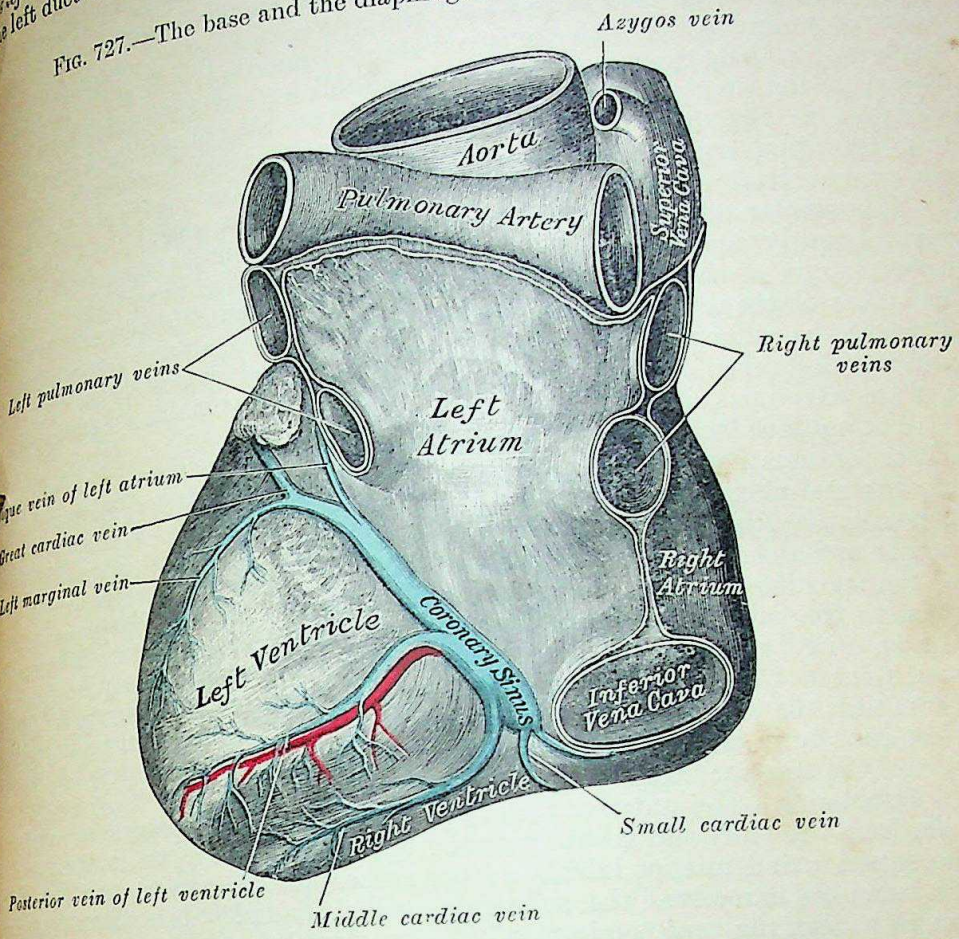

The following cardiac veins do not end in the coronary sinus: (1) the **anterior cardiac veins**, comprising three or four small vessels which collect blood from the front of the right ventricle and open into the right atrium; the right marginal vein frequently opens into the right atrium, and is therefore sometimes regarded as belonging to this group; (2) the **smallest cardiac veins** (vv. cordis minimæ), consisting of a number of minute veins which lie in the muscular wall of the heart and open directly into its cavities, most of them into the atria, but a few into the ventricles.

THE VEINS OF THE HEAD AND NECK

The veins of the head and neck may be subdivided into three groups: 1. The veins of the exterior of the head and face. 2. The veins of the neck. 3. The diploic veins, the veins of the brain, and the venous sinuses of the dura mater.

THE VEINS OF THE EXTERIOR OF THE HEAD AND FACE (fig. 728)

Frontal.	Superficial temporal.
Supra-orbital.	Internal maxillary.
Angular.	Posterior facial.
Anterior facial.	Posterior auricular.

Occipital.

The **frontal vein** begins on the forehead in a venous network which communicates with the frontal tributaries of the superficial temporal vein. Veins converge

CC-0. In Public Domain. Gurukul Kangri Collection, Haridwar

Digitized by Arya Samaj Foundation Chennai and eGangotri

from the network to form a single trunk, which descends near the middle of the forehead parallel with the vein of the opposite side. At the root of the nose the two frontal veins are joined by a transverse branch which is called the *supra-orbital arch*, and receives small veins from the dorsum of the nose. The frontal veins diverge, and at the medial angle of the orbit, each joins with the supra-orbital vein to form the *angular vein*. Occasionally the frontal veins unite in a single trunk which divides at the root of the nose into the two angular veins.

The **supra-orbital vein** begins near the zygomatic process of the frontal bone where it communicates with the superficial and middle temporal veins. It runs medialwards along the upper margin of the orbit beneath the Orbicularis oculi, and at the medial angle of the orbit, pierces this muscle and unites with the angular vein to form the *angular vein*. It sends a branch through the supra-orbital notch into the orbital cavity to join the superior ophthalmic vein; as this branch traverses the supra-orbital notch it is joined by the frontal diploic vein.

The **angular vein,** formed by the junction of the frontal and supra-orbital veins, runs obliquely downwards on the side of the root of the nose, to the level of the lower margin of the orbit, where it becomes the anterior facial vein. It receives the veins of the ala nasi, and communicates with the superior ophthalmic vein. Through the communication of the superior ophthalmic vein with the supra-orbital and angular veins, an anastomosis is established between the anterior facial vein and the cavernous sinus.

The **anterior facial vein** (facial vein) (fig. 728) begins at the side of the nose as a direct continuation of the angular vein. It runs downwards and backwards with the external maxillary (facial) artery, but follows a less tortuous course. It passes beneath the Zygomaticus, Risorius and Platysma, descends along the anterior border and then on the superficial surface of the Masseter, crosses over the body of the mandible, and runs obliquely backwards, beneath the Platysma and superficial to the submaxillary gland, Digastricus, and Stylohyoideus. It unites with the anterior branch of the posterior facial vein to form the *common facial vein*, which enters the internal jugular vein at a variable point below the hyoid bone. From near the termination of the common facial vein a branch of considerable size often runs down the anterior border of the Sternocleidomastoideus to join the lower part of the anterior jugular vein.

Tributaries.—The anterior facial vein receives a large branch, the *deep facial vein*, from the pterygoid venous plexus. It is also joined by the inferior palpebral, the superior and inferior labial, the buccinator and the masseteric veins. Below the mandible it receives the submental, palatine, and submaxillary veins, and generally also, the vena comitans of the hypoglossal nerve.

Applied Anatomy.—There are some points about the anterior facial vein which render it of great importance in surgery. It is not so flaccid as are most superficial veins, and in consequence of this, remains more patent when divided. It has, moreover, no valves. It communicates freely with the intracranial circulation, not only at its commencement by the angular and supra-orbital veins which are connected with the ophthalmic vein, a tributary of the cavernous sinus, but also by the deep facial vein, which communicates through the pterygoid plexus with the cavernous sinus by branches passing through the foramen ovale and foramen lacerum (p. 724). These facts have an important bearing upon the surgery of some diseases; any phlegmonous inflammation of the face following a poisoned wound is liable to set up thrombosis in the anterior facial vein, and detached portions of the clot may give rise to purulent foci in other parts of the body. These thrombi may extend upwards into the cranial sinuses, and so induce a fatal issue; this has been known to follow in cases of ordinary carbuncle of the face. The position of the vein must be borne in mind when incisions are made for the relief of suppuration above the mandible.

The **superficial temporal vein** (fig. 728) begins on the side and vertex of the skull in a network which joins with the corresponding vein of the opposite side, and with the frontal, supra-orbital, posterior auricular and occipital veins. From this network, frontal and parietal branches arise, and unite above the zygomatic arch to form the superficial temporal vein, which is joined in this situation by the *middle temporal vein*. It then crosses the posterior root of the zygomatic arch, enters the substance of the parotid gland, and unites with the internal maxillary vein to form the posterior facial vein.

Tributaries.—The superficial temporal vein receives some veins from the parotid gland, articular veins from the mandibular joint, anterior auricular veins from

CC-0. In Public Domain. Gurukul Kangri Collection, Haridwar

Digitized by Arya Samaj Foundation Chennai and eGangotri

the auricula, and the *transverse facial* from the side of the face. The middle temporal vein, after receiving the *orbital vein* which is formed by some lateral palpebral branches, passes backwards between the layers of the temporal fascia to join the superficial temporal vein.

The **pterygoid plexus** is of considerable size, and is situated partly between the Temporalis and Pterygoideus externus, and partly between the two Pterygoidei. It receives the sphenopalatine, deep temporal, pterygoid, masseteric, buccinator,

FIG. 728.—The veins of the right side of the head and neck.

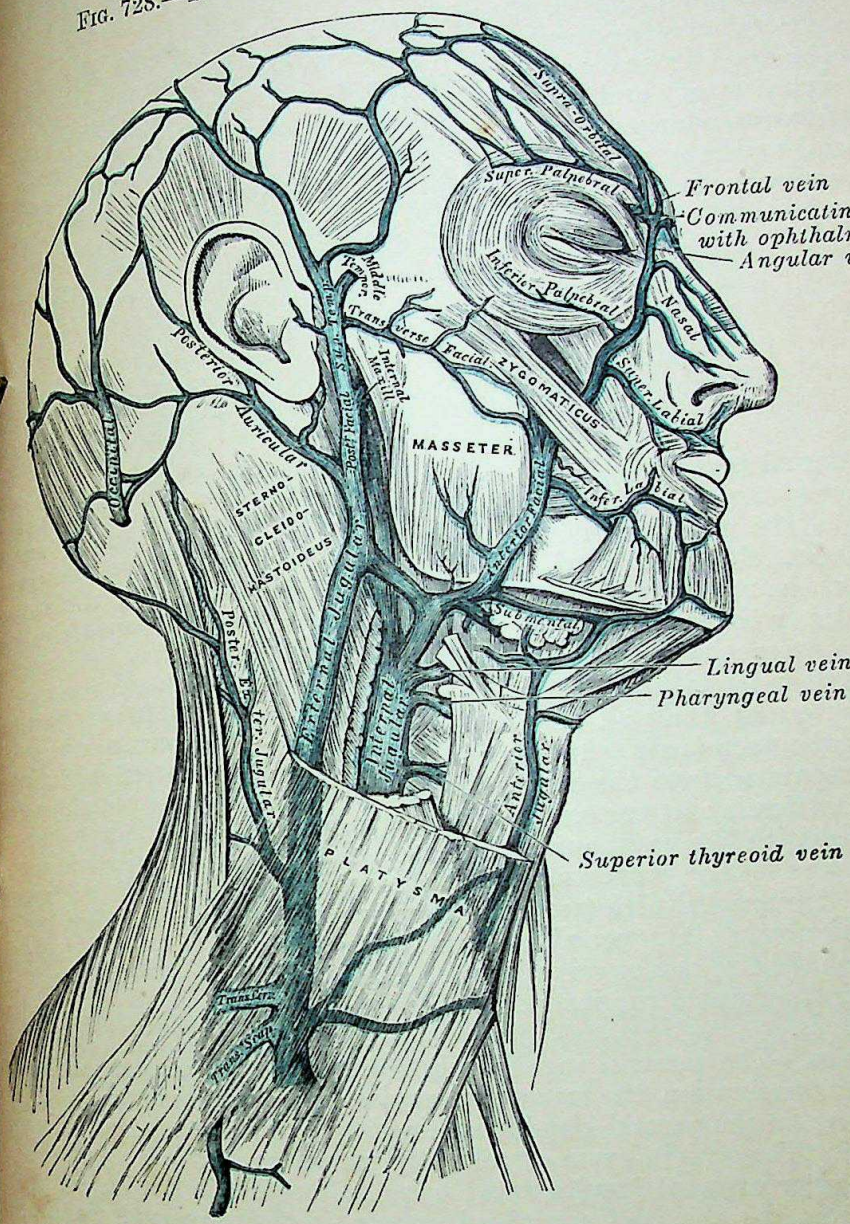

alveolar, and some palatine veins, and a branch or branches from the inferior ophthalmic vein. The pterygoid plexus anastomoses with the anterior facial vein, through the deep facial vein; it is also connected with the cavernous sinus by veins which pass through the foramen Vesalii, foramen ovale, and foramen lacerum.

The **internal maxillary vein** is a short trunk which accompanies the first part of the internal maxillary artery and is formed by a confluence of the veins of the pterygoid plexus. It passes backwards between the sphenomandibular ligament and the neck of the mandible, and unites with the temporal vein to form the posterior facial vein.

The **posterior facial vein** (temporomaxillary vein), formed by the union of the superficial temporal and internal maxillary veins, descends in the substance of

CC-0. In Public Domain. Gurukul Kangri Collection, Haridwar

Digitized by Arya Samaj Foundation Chennai and eGangotri

the parotid gland, superficial to the external carotid artery but deep to the nerve, between the ramus of the mandible and the Sternocleidomastoideus; divides into two branches, an anterior, which passes forwards and unites with anterior facial vein to form the common facial vein, and a posterior, which is joined by the posterior auricular vein and becomes the external jugular vein.

The **posterior auricular vein** (fig. 728) begins on the posterior part of the side of the head, in a network which communicates with the tributaries of the occipital and superficial temporal veins. It descends behind the auricula, and joins the posterior division of the posterior facial vein to form the external jugular vein. It receives the stylomastoid vein and some tributaries from the cranial surface of the auricula.

The **occipital vein** begins in a venous network at the posterior part of the scalp. It pierces the cranial attachment of the Trapezius, dips into the suboccipital triangle and joins the deep cervical and vertebral veins. Occasionally it follows the course of the occipital artery and ends in the internal jugular vein; sometimes it joins the posterior auricular vein and through it opens into the external jugular vein. The parietal emissary vein connects it with the superior sagittal sinus, and the mastoid emissary vein with the transverse sinus. The occipital diploic vein sometimes joins it.

The Veins of the Neck (figs. 728, 729)

External jugular. Anterior jugular.
Posterior external jugular. Internal jugular.
Vertebral.

The **external jugular vein** (fig. 728) receives the greater part of the blood from the exterior of the cranium and from the deep parts of the face, and is formed by the union of the posterior division of the posterior facial vein with the posterior auricular vein. It begins in the substance of the parotid gland, on a level with the angle of the mandible, and runs down the neck, where its course is represented by a line drawn from the angle of the mandible to the middle of the clavicle. It crosses the Sternocleidomastoideus obliquely, and in the subclavian triangle perforates the deep fascia, and ends in the subclavian vein, lateral to or in front of the Scalenus anterior; the wall of the vein is adherent to the circumference of the opening in the deep fascia. It is covered by the Platysma, superficial fascia, and skin, and separated from the Sternocleidomastoideus by the investing layer of the deep cervical fascia; it crosses the cutaneous cervical nerve, and its upper half runs parallel with the great auricular nerve. The external jugular vein varies in size, bearing an inverse proportion to the other veins of the neck; it is occasionally double. It is provided with two pairs of valves, a lower pair at its entrance into the subclavian vein, an upper about 4 cm. above the clavicle. The portion of the vein between the two sets of valves is often dilated, and is termed the *sinus*. These valves do not prevent regurgitation of the blood, or the passage of injection from below upwards.

Tributaries.—The external jugular vein receives the posterior external jugular, and, near its termination, the transverse cervical, transverse scapular, and anterior jugular veins; in the parotid gland it is joined by a large branch from the internal jugular vein. The occipital vein occasionally opens into it.

The **posterior external jugular vein** begins in the occipital region and returns the blood from the skin and superficial muscles in the upper and posterior part of the neck. It opens into the middle part of the external jugular vein.

The **anterior jugular vein** (figs. 728, 729) is devoid of valves and begins near the hyoid bone by the confluence of several superficial veins from the submaxillary region. It descends between the median line and the anterior border of the Sternocleidomastoideus; at the lower part of the neck it turns lateralwards beneath the muscle, but superficial to the depressors of the hyoid bone, and opens into the termination of the external jugular vein, or into the subclavian vein. Its size varies considerably, and usually bears an inverse proportion to that of the external jugular vein. It communicates with the internal jugular vein and receives as tributaries some laryngeal veins, and occasionally a small thyreoid vein. There are usually two anterior jugular veins, a right and a left; just above the sternum they are united by a large transverse trunk, the *venous jugular arch*, which receives

CC-0. In Public Domain. Gurukul Kangri Collection, Haridwar

Digitized by Arya Samaj Foundation Chennai and eGangotri

tributaries from the inferior thyreoid veins. The anterior jugular veins may be joined by a single trunk which descends in the middle line of the neck.

Applied Anatomy.—Venesection used formerly to be performed on the external jugular vein, but is now probably never resorted to. When the vein is cut there is some risk of air being drawn into it.

The **internal jugular vein** (fig. 729) collects the blood from the brain, from the superficial parts of the face, and from the neck. It begins at the base of the skull in the posterior compartment of the jugular foramen, where it is directly continuous

Fig. 729.—The veins of the neck. Anterior aspect. (After Spalteholz.)

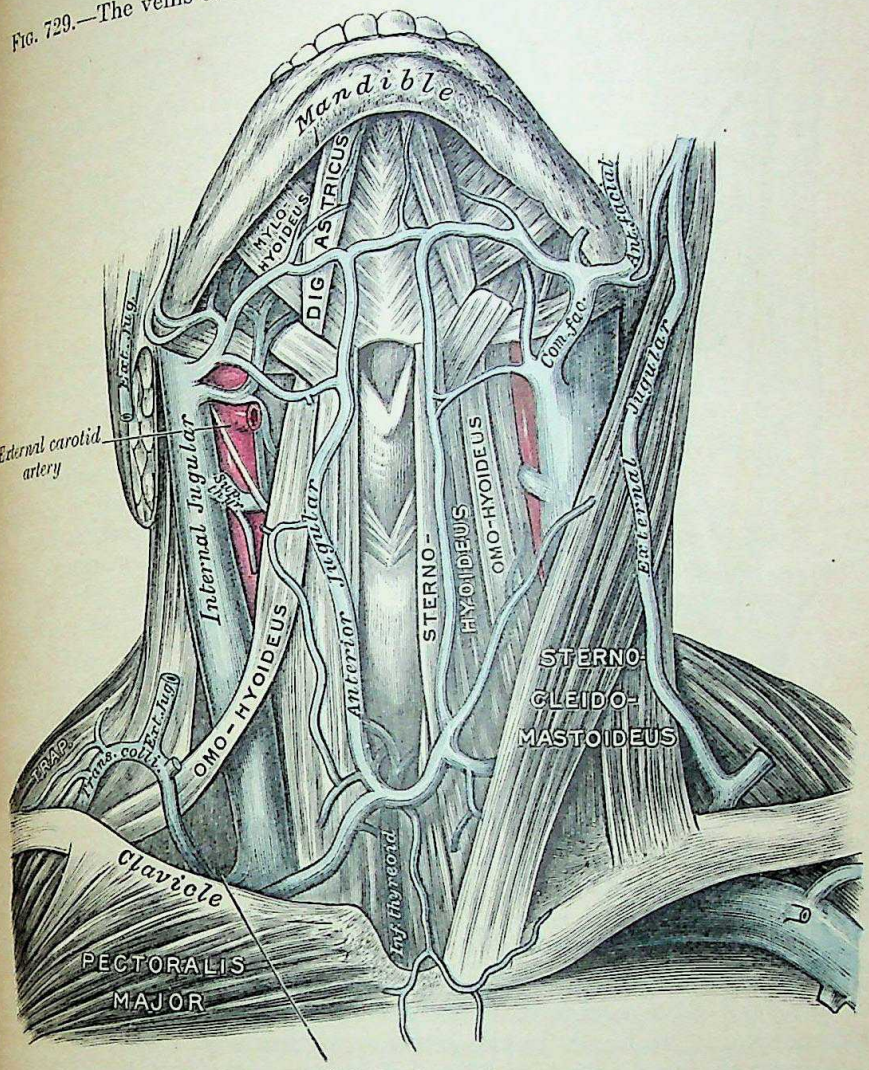

with the transverse sinus. At its origin it is somewhat dilated; this dilatation is called the *superior bulb* and lies below the posterior part of the floor of the tympanic cavity. The vein runs down the side of the neck under cover of the Sternocleido-mastoideus, lying at first lateral to the internal carotid artery, and then lateral to the common carotid artery. At the root of the neck it unites with the subclavian vein to form the innominate vein. The internal jugular vein is dilated near its termination to form what is known as the *inferior bulb*; directly above this bulb the vein contains a pair of valves. In the upper part of its course, it lies upon the rectus capitis lateralis, behind the internal carotid artery and the nerves passing through the jugular foramen; lower down, the vein and artery lie upon the same plane: the glossopharyngeal and hypoglossal nerves passing forwards between them; the vagus nerve descends in the same sheath as the vein and artery, but lies between and on a plane posterior to them; the accessory nerve runs obliquely backwards,

CC-0. In Public Domain. Gurukul Kangri Collection, Haridwar

Digitized by Arya Samaj Foundation Chennai and eGangotri

superficial or deep to the vein. The deep cervical glands lie along the c the vein, mainly on its superficial aspect. At the root of the neck the right jugular vein is placed at a little distance from the common carotid artery crosses the first part of the subclavian artery, while the left internal jugular usually overlaps the common carotid artery.

Tributaries.—The internal jugular vein receives the inferior petrosal sinus common facial, lingual, pharyngeal, superior and middle thyreoid veins, and times the occipital vein. The thoracic duct opens into the angle of union of the left clavian and internal jugular veins, and the right lymphatic duct into the angle of the right subclavian and internal jugular veins.

Fig. 730.—The veins of the thyreoid gland.

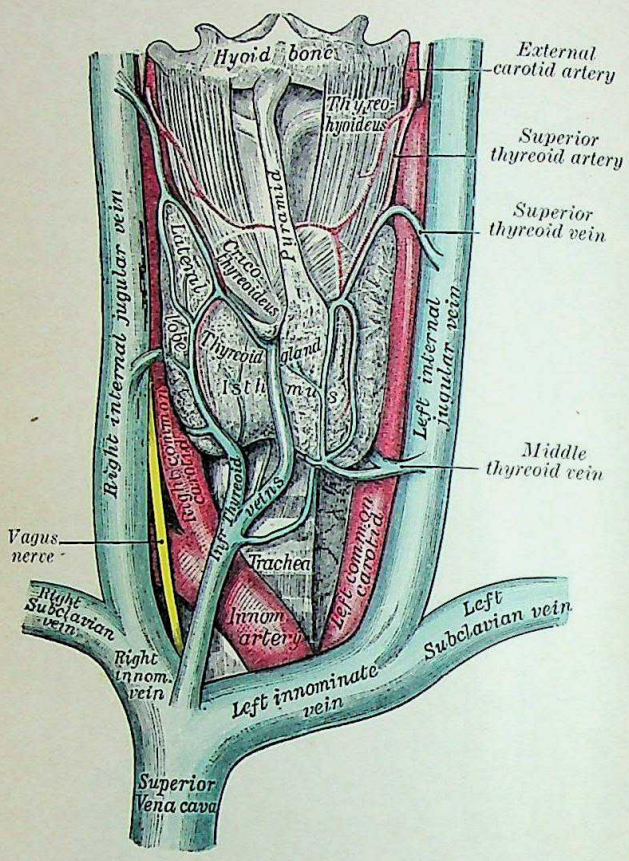

The **inferior petrosal** leaves the skull through anterior part of the foramen, and joins the bulb of the internal vein.

The **lingual veins** begin the dorsum, sides, and surface of the tongue, passing backwards along course of the lingual end in the internal jugular The **vena comitans hypoglossi** (ranine vein), a branch of siderable size, begins the tip of the tongue, may join the lingual generally, however, it backwards superficial to Hyoglossus, and opens the common facial vein.

The **pharyngeal veins** in the *pharyngeal plexus* on outer surface of the pharynx and, after receiving posterior meningeal veins and the vein of the pterygoid canal, end in the internal jugular vein. They occasionally open into the facial, the lingual, or the superior thyreoid vein.

The **superior thyreoid vein** (fig. 730) begins in the substance and on the surface of the thyreoid gland, by tributaries corresponding with the branches of the superior thyreoid artery. It accompanies this artery, receives the superior laryngeal and cricothyreoid veins, and ends in the internal jugular vein.

The **middle thyreoid vein** (fig. 730) collects the blood from the lower part of the thyreoid gland, receives some veins from the larynx and trachea, and ends in the lower part of the internal jugular vein.

The inferior thyreoid veins are described on p. 729.

The **common facial** and **occipital veins** have been described (pp. 710, 712).

Applied Anatomy.—The internal jugular vein requires ligature in cases of septic thrombosis of the transverse sinus, secondary to suppurative otitis media, in order to prevent septic emboli being carried into the general circulation. This operation has been performed in many cases, with the most satisfactory results. The cases are generally those of chronic disease of the middle ear, with discharge of pus which perhaps has existed for many years. Such cases are always extremely grave, for there is a danger of portions of the thrombus or clot being detached and causing septic embolism in the lungs. If the condition be suspected, the diseased bone should be removed at once in the mastoid process. The sinus is then investigated, and if it be found thrombosed, the surgeon should proceed to ligature the internal jugular vein, through an incision along the anterior border of the Sternocleidomastoideus, the centre of the incision being on

CC-0. In Public Domain. Gurukul Kangri Collection, Haridwar

Digitized by Arya Samaj Foundation Chennai and eGangotri

with the greater cornu of the hyoid bone. The vein should be ligatured in two sinus and divided between. After the vessel has been secured and divided, the trans-
sinus is to be thoroughly cleared out, and, by removing the ligature from the upper
of the divided vein, all septic clots removed by syringing from the sinus through the
If hæmorrhage occur from the distal end of the sinus, it can be arrested by careful
ng with gauze between the sinus and the bone. When the thrombosis involves the
or bulb of the internal jugular vein, the glossopharyngeal, vagus and accessory nerves
be paralysed. The hypoglossal nerve is sometimes paralysed by extension of the
bus to the veins of the hypoglossal canal.

The internal jugular vein is also surgically important, because it is surrounded by a
ber of deep cervical lymph-glands; and when these are enlarged in tuberculous or
gnant disease, they are apt to adhere to the vessel, rendering their removal difficult
often dangerous. The proper course to pursue in these cases is to ligature the vessel
ve and below the glandular mass, and remove the included portion with the glands.

Cardiac pulsation is often demonstrable in the internal jugular vein at the root of the
There are no valves in the innominate veins or superior vena cava; in conse-
nce, the systole of the right atrium causes a wave to pass up these vessels, and when
conditions are favourable this wave appears as a somewhat feeble flicker over the
rnal jugular vein at the root of the neck, quite distinct from, and just preceding, the
e forcible impulse transmitted from the underlying common carotid artery and due to
ventricular systole. This atrial systolic venous impulse is much increased in condi-
s in which the right atrium is abnormally distended with blood or is hypertrophied,
often the case in disease of the bicuspid valve. In the Adams-Stokes' syndrome
l) it is this pulsation which gives evidence of the fact that the atria are beating
—often two or three times faster—than the ventricles.

The **vertebral vein** is formed in the suboccipital triangle, from numerous small
tributaries which spring from the internal vertebral venous plexuses and issue from
vertebral canal above the posterior arch of the atlas. They unite with small
s from the deep muscles at the upper part of the back of the neck, and form a
el which enters the foramen in the transverse process of the atlas, and descends,
ming a dense plexus around the vertebral artery, in the canal formed by the
mina transversaria of the cervical vertebræ. This plexus ends in the vertebral
n, which emerges from the foramen transversarium of the sixth cervical vertebra,
d opens into the upper and posterior part of the innominate vein, the opening
guarded by a pair of valves. On the right side, it crosses the first part of the
clavian artery.

Tributaries.—The vertebral vein communicates with the transverse sinus of
skull by a vein which passes through the condyloid canal, when that canal exists.
receives branches from the occipital vein, from the prevertebral muscles, and
m the internal and external vertebral venous plexuses. It is joined by the
terior vertebral and the deep cervical veins; close to its termination it sometimes
eives the first intercostal vein.

The **anterior vertebral vein** commences in a plexus around the transverse processes
the upper cervical vertebræ, descends in company with the ascending cervical
ery between the Scalenus anterior and Longus capitis, and opens into the
minal part of the vertebral vein.

The **deep cervical vein** accompanies its artery between the Semispinales capitis
colli. It begins in the suboccipital region by communicating branches from
occipital vein and by small veins from the deep muscles at the back of the
k. It receives tributaries from the plexuses around the spinous processes of
cervical vertebræ, and passes forwards between the transverse process of the
enth cervical vertebra and the neck of the first rib to end in the lower part of
vertebral vein.

The Diploic Veins (fig. 731)

The **diploic veins** occupy channels in the diploë of the cranial bones
are devoid of valves. They are large, and exhibit at irregular intervals
h-like dilatations; their walls are thin, and formed of endothelium sup-
ted by a layer of elastic tissue.

They communicate with the meningeal veins, the sinuses of the dura mater,
the veins of the pericranium. They consist of (1) the *frontal diploic vein*,
h emerges from the bone at the supra-orbital foramen, and opens into the
ra-orbital vein; (2) the *anterior temporal diploic vein*, which is confined
ly to the frontal bone and pierces the great wing of the sphenoidal bone

CC-0. In Public Domain. Gurukul Kangri Collection, Haridwar

Digitized by Arya Samaj Foundation Chennai and eGangotri

to end in the sphenoparietal sinus or in the anterior deep temporal vein. (3) the *posterior temporal diploic vein*, which is situated in the parietal bone; it descends to the mastoid angle of the parietal bone and joins the transverse sinus through

FIG. 731.—The veins of the diploë. Displayed by the removal of the outer table of the skull.

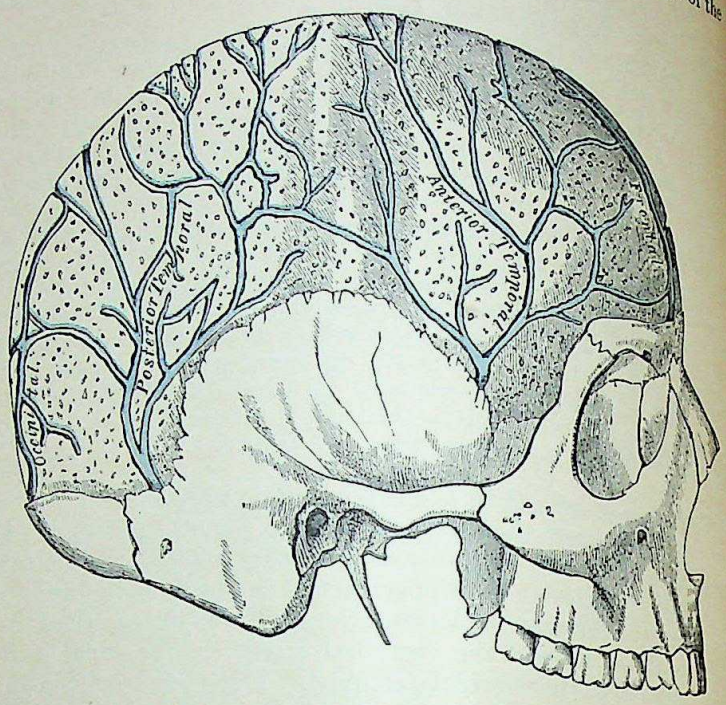

an aperture at the mastoid angle of the parietal bone or through the mastoid foramen; and (4) the *occipital diploic vein*, the largest of the four, which is confined to the occipital bone, and opens into the occipital vein, or into the transverse sinus near the confluence of the sinuses.

THE VEINS OF THE BRAIN

The veins of the brain possess no valves, and their walls, owing to the absence of muscular tissue, are extremely thin. They pierce the arachnoid membrane and the inner or meningeal layer of the dura mater, and open into the cranial venous sinuses. They consist of two sets, cerebral and cerebellar.

The **cerebral veins** are divisible into external and internal groups according as they drain the outer surfaces or the inner parts of the hemispheres.

The **external cerebral veins** are the superior, middle, and inferior.

The *superior cerebral veins*, eight to twelve in number, drain the superior, lateral and medial surfaces of the hemispheres, and are mainly lodged in the sulci between the gyri, but some run across the gyri. They open into the superior sagittal sinus; the anterior veins run nearly at right angles to the sinus; the posterior and large veins are directed obliquely forwards, and thus open into the sinus in a direction opposed to the current of the blood contained within it.

The *middle cerebral veins* (superficial Sylvian veins) are two in number. Each begins on the lateral surface of the hemisphere, and, running along the lateral cerebral fissure, ends in the cavernous sinus. Each is connected (*a*) with the superior sagittal sinus by the *great anastomotic vein of Trolard*, which opens into one of the superior cerebral veins; (*b*) with the transverse sinus by the *posterior anastomotic vein of Labbé*, which courses over the temporal lobe.

The *inferior cerebral veins*, of small size, drain the under surfaces of the hemispheres. Those on the orbital surfaces of the frontal lobes join the superior cerebral veins, and through these open into the superior sagittal sinus; those of the temporal lobes anastomose with the basal and middle cerebral veins, and join the cavernous, superior petrosal and transverse sinuses.

CC-0. In Public Domain. Gurukul Kangri Collection, Haridwar

Digitized by Arya Samaj Foundation Chennai and eGangotri

The **basal veins** are two in number. Each begins at the anterior perforated substance by the union of (*a*) a small *anterior cerebral vein* which accompanies the anterior cerebral artery, (*b*) the *deep middle cerebral vein* (deep Sylvian vein), which receives tributaries from the insula and neighbouring gyri, and runs in the upper part of the lateral cerebral fissure, and (*c*) the *inferior striate veins* which drain the corpus striatum through the anterior perforated substance. The basal vein passes backwards round the cerebral peduncle, and ends in the internal cerebral vein (vein of Galen); it receives tributaries from the interpeduncular fossa, the inferior horn of the lateral ventricle, the hippocampal gyrus, and the mid-brain.

The **internal cerebral veins** (veins of Galen), two in number, drain the deep parts of the hemisphere; each is formed near the interventricular foramen by the union of the *terminal* and *chorioid veins*. They run backwards parallel with one another, between the layers of the tela chorioidea of the third ventricle, and beneath the splenium of the corpus callosum, where they unite to form a short trunk, the *great cerebral vein*; just before their union each receives the corresponding basal vein.

The *terminal vein* (vena corporis striati) runs in the groove between the corpus striatum and thalamus, receives numerous veins from both of these structures, and unites behind the crus fornicis with the chorioid vein, to form one of the internal cerebral veins. The *chorioid vein* runs along the whole length of the chorioid plexus, and receives veins from the hippocampus, the fornix, and the corpus callosum.

The **great cerebral vein** (vena magna Galeni), formed by the union of the two internal cerebral veins, is a short median trunk which curves backwards and upwards around the splenium of the corpus callosum and opens into the anterior extremity of the straight sinus.

The **cerebellar veins** are placed on the surface of the cerebellum, and consist of two sets, superior and inferior. The *superior cerebellar veins* pass partly forwards and medialwards, across the superior vermis, to end in the straight sinus and the internal cerebral veins, partly lateralwards to the transverse and superior petrosal sinuses. The *inferior cerebellar veins*, of large size, end in the transverse, superior petrosal, and occipital sinuses.

The Venous Sinuses of the Dura Mater (figs. 732 to 736)

The sinuses of the dura mater are venous channels which drain the blood from the brain; they are situated between the two layers of the dura mater and are lined by endothelium continuous with that which lines the veins; they contain no valves and their walls are devoid of muscular tissue. They may be divided into two groups: (1) a posterosuperior, at the upper and posterior parts of the skull, and (2) an antero-inferior, at the base of the skull.

1. The posterosuperior group of venous sinuses:

Superior sagittal.	Straight.
Inferior sagittal.	Two transverse.
Occipital.	

The **superior sagittal sinus** (superior longitudinal sinus) (figs. 732, 733) occupies the attached or convex margin of the falx cerebri. It commences in front of the crista galli, and receives through the foramen cæcum, if this foramen be patent, a vein from the nasal cavity; it runs backwards, grooving the inner surface of the frontal bone, the adjacent margins of the two parietal bones, and the superior division of the cruciate eminence of the occipital bone; near the internal occipital protuberance it deviates to one or other side (usually the right) and is continued as the corresponding transverse sinus. It is triangular in cross-section and gradually increases in size as it passes backwards. On its inner surface are the openings of the superior cerebral veins, and numerous fibrous bands (*chordæ Willisii*) which cross the inferior angle of the sinus; the sinus also communicates through small openings with irregularly-shaped *venous lacunæ* (lacunæ laterales) in the dura mater near the sinus. There are usually three lacunæ laterales on each side of the sinus: a small frontal, a large parietal, and an occipital which is intermediate in size between the other two (Sargent *).

* Percy Sargent, *Journal of Anatomy and Physiology*, vol. xlv.

CC-0. In Public Domain. Gurukul Kangri Collection, Haridwar

Digitized by Arya Samaj Foundation Chennai and eGangotri

Many fine fibrous bands cross the lacunæ, and numerous arachnoidal gra-
tions (Pacchionian bodies) project into them from below. The superior sa-
sinus receives the superior cerebral veins, veins from the diploë and dura ma-
and, near the posterior extremity of the sagittal suture, veins from the p-
cranium, which pass through the parietal foramina.

Fig. 732.—The superior sagittal sinus laid open after the removal of the sk-
cap. The chordæ Willisii and venous lacunæ are clearly seen; from tw-
of the lacunæ probes are passed into the sinus. (Poirier and Charpy.)

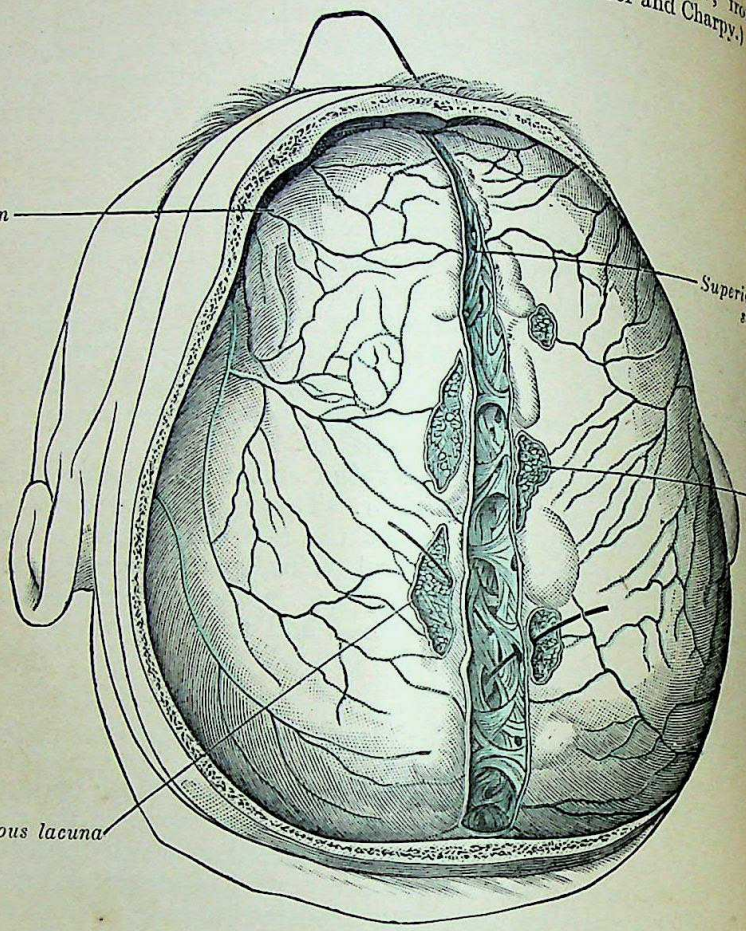

Clark * says the lacunæ lateralis should not be described as single well-defined cavi-
but rather as a complicated meshwork of veins into which the diploic veins and the superi-
terminations of the meningeal veins open. He asserts that the superior cerebral ve-
never open into the lacunæ, but pass beneath them and open directly into the supe-
sagittal sinus.

Applied Anatomy.—The communications which take place between the superior sagi-
sinus and the veins of the nose, scalp, and diploë, cause it to be at times the seat
infective thrombosis from suppurative processes in these parts.

The **inferior sagittal sinus** (inferior longitudinal sinus) (fig. 733) is
tained in the posterior one-half or two-thirds of the free margin of the
cerebri. It increases in size as it passes backwards, and ends in the straig
sinus. It receives several veins from the falx cerebri, and occasionally a
from the medial surfaces of the hemispheres.

The **straight sinus** (figs. 733, 734) is situated in the line of junction of t
falx cerebri with the tentorium cerebelli. It is triangular in cross-section, a
is traversed by a few transverse bands. It runs backwards and downwa
from the end of the inferior sagittal sinus to the transverse sinus of the sid
opposite to that into which the superior sagittal sinus is prolonged. Its te
minal part communicates by a cross branch with the confluence of the sinuse
Besides the inferior sagittal sinus, it receives some of the superior cerebell

* W. F. de Gruchy, *Journal of Anatomy*, vol. lv.

CC-0. In Public Domain. Gurukul Kangri Collection, Haridwar

Digitized by Arya Samaj Foundation Chennai and eGangotri

...s, and, at its commencement, the great cerebral vein (vena magna Galeni), ...site of opening of this vein being marked by a dilatation.

The **transverse sinuses** (lateral sinuses) (figs. 734, 735) are of large size, ...begin at the internal occipital protuberance; one, generally the right, ...the direct continuation of the superior sagittal sinus, the other of the ...ght sinus. Each transverse sinus passes lateralwards and forwards, ...rribing a slight curve with its convexity upwards, to the base of the petrous ...tion of the temporal bone and lies, in this part of its course, in the attached

FIG. 733.—The dura mater and its processes. Exposed by removing part of the right half of the skull, and the brain.

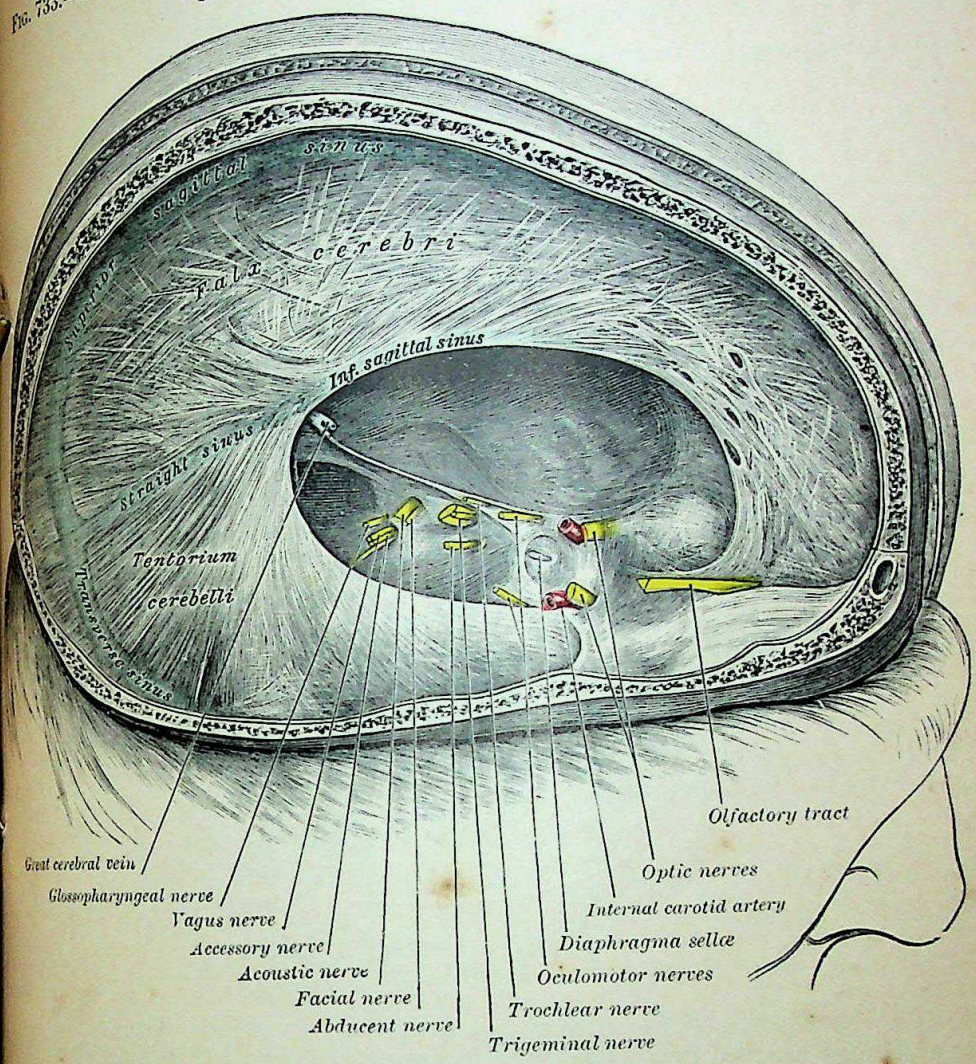

...margin of the tentorium cerebelli; it then leaves the tentorium and curves ...downwards and medialwards to reach the posterior part of the jugular foramen, ...through which it passes, and ends in the internal jugular vein. It rests succes-...sively upon the squama of the occipital bone, the mastoid angle of the parietal ...bone, the mastoid part of the temporal bone, and the jugular process of the ...occipital bone; the portion which occupies the groove on the mastoid part ...of the temporal bone is sometimes termed the *sigmoid sinus*. The transverse ...sinuses are frequently of unequal size, that formed by the superior sagittal ...being the larger; they increase in size as they proceed from behind ...forwards. On transverse section the horizontal portion of the sinus exhibits ...a prismoid, the curved portion a semicylindrical, form. They communicate ...with the veins of the pericranium by means of the mastoid and condyloid ...emissary veins, and receive the superior petrosal sinuses, some inferior cerebral, ...inferior cerebellar, and diploic veins, and the posterior anastomotic vein of

CC-0. In Public Domain. Gurukul Kangri Collection, Haridwar

Digitized by Arya Samaj Foundation Chennai and eGangotri

Labbé (p. 716). The *petrosquamous sinus*, when present, runs back along the junction of the squama and petrous portion of the temporal bone opens into the transverse sinus.

The **occipital sinus** (fig. 735), the smallest of the cranial sinuses, is situated in the attached margin of the falx cerebelli, and is generally single, but occasionally there are two. It commences around the margin of the foramen magnum by several small venous channels, one of which joins the terminal part of the transverse sinus; it communicates with the posterior internal vertebral venous plexuses, and ends in the confluence of the sinuses.

Fig. 734.—The tentorium cerebelli. Superior aspect.

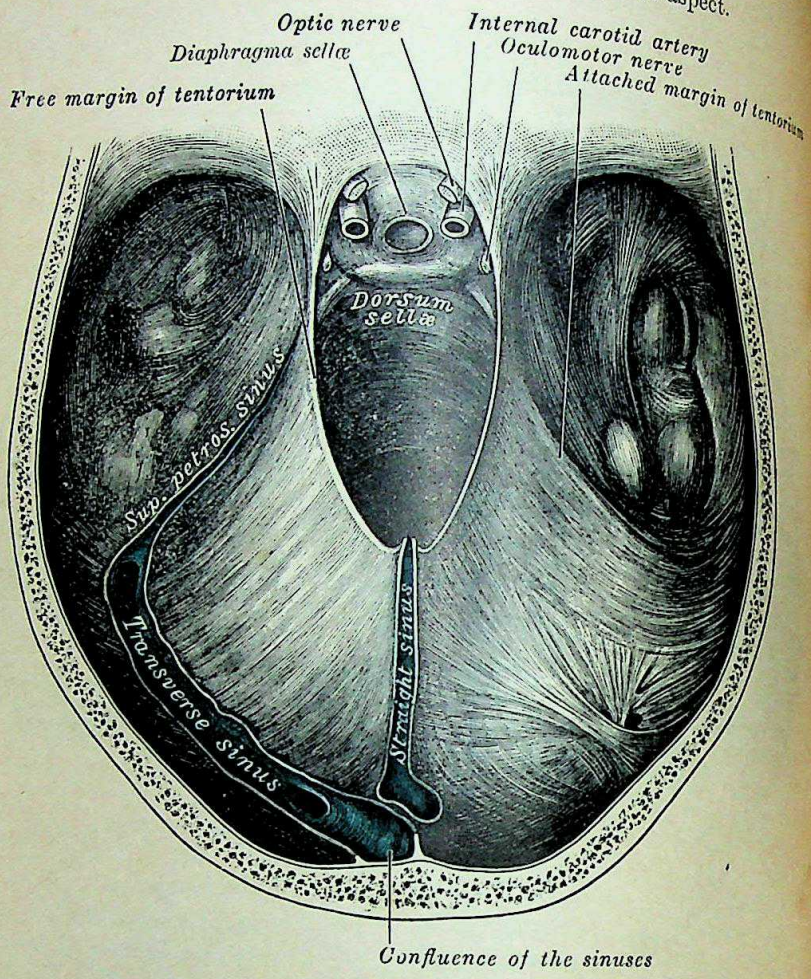

The *confluence of the sinuses*, or *torcular Herophili*, is the term applied to the dilated extremity of the superior sagittal sinus. It is lodged on one side (generally the right) of the internal occipital protuberance, and from it the transverse sinus of the same side is derived. It receives also the blood from the occipital sinus. and is connected by a channel with the commencement of the opposite transverse sinus.

2. The antero-inferior group of venous sinuses:

Two cavernous.	Two inferior petrosal.
Two sphenoparietal.	Basilar plexus.
Two intercavernous.	Middle meningeal.
Two superior petrosal.	

The **cavernous sinuses** (figs. 735, 736) are placed on the sides of the body of the sphenoidal bone, and are so named because they present a reticulated structure, due to their being traversed by numerous interlacing filaments. Each extends from the superior orbital fissure in front, to the apex of the petrous part of the temporal bone behind, and has an average length of 2 cm. and a width of 1 cm. Passing through each sinus is the internal carotid artery

CC-0. In Public Domain. Gurukul Kangri Collection, Haridwar

Digitized by Arya Samaj Foundation Chennai and eGangotri

surrounded by filaments of the carotid plexus; near to the lateral side of the cavernous sinus is the abducent nerve; on the lateral wall of the sinus are the oculomotor and trochlear nerves, and the ophthalmic and maxillary divisions of the trigeminal nerve (fig. 736). These structures are separated from the blood in the sinus by the lining membrane of the sinus. Medial to the cavernous sinus the sphenoidal air-sinus and the hypophysis (pituitary body); lateral to it, the temporal lobe of the cerebrum; posterior to it, the semilunar ganglion of the trigeminal nerve.

FIG. 735.—The sinuses at the base of the skull.

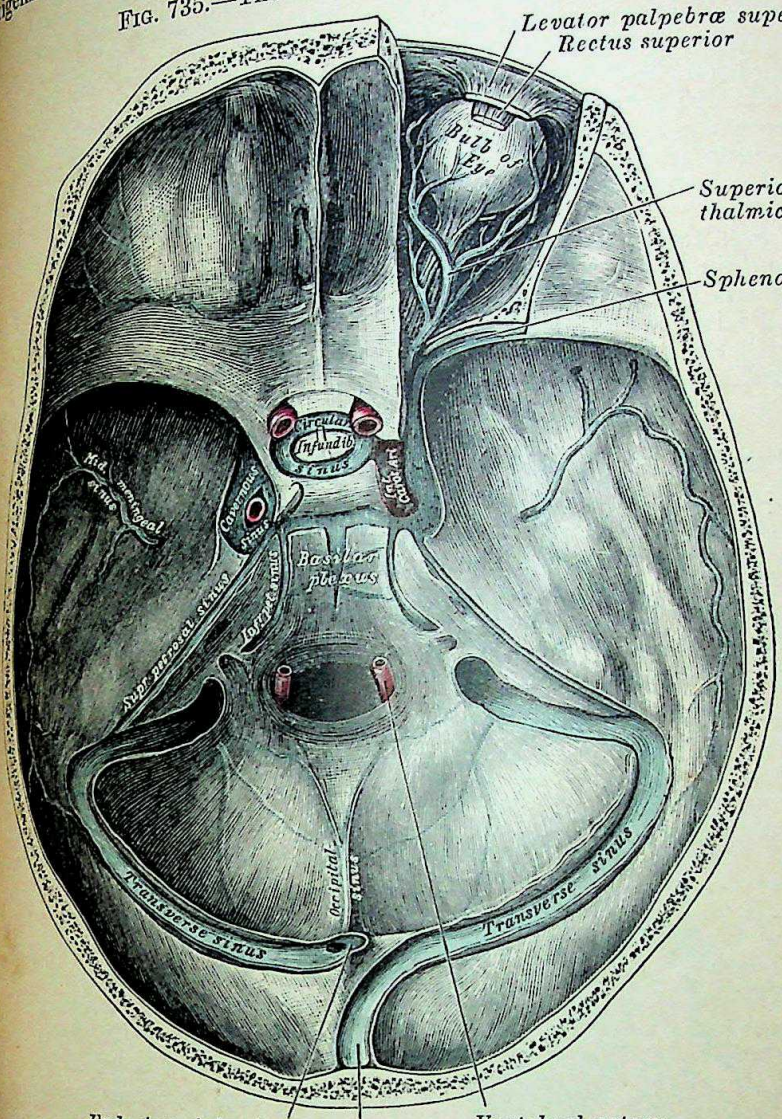

The tributaries of the cavernous sinus are the superior ophthalmic vein, a branch from the inferior ophthalmic vein, the middle cerebral or superficial Sylvian vein, some inferior cerebral veins, and the sphenoparietal sinus; the central vein of the retina sometimes opens into it. The cavernous sinus communicates with the transverse sinus through the superior petrosal sinus; with the internal jugular vein through the inferior petrosal sinus and a plexus of veins on the internal carotid artery; with the pterygoid venous plexus by veins which pass through the foramen Vesalii, foramen ovale, and foramen lacerum; and with the angular vein through the superior ophthalmic vein. The two sinuses also communicate with each other by means of the anterior and posterior intercavernous sinuses and the basilar plexus.

The **sphenoparietal sinuses** course along the under surfaces of the small wings of the sphenoidal bone, near their posterior edges. Each sinus receives some small veins from the adjacent part of the dura mater and may receive

CC-0. In Public Domain. Gurukul Kangri Collection, Haridwar

Digitized by Arya Samaj Foundation Chennai and eGangotri

one of the middle meningeal sinuses; it opens into the anterior part of the cavernous sinus.

Applied Anatomy.—An arteriovenous communication may be established between the cavernous sinus and the internal carotid artery, giving rise to a pulsating tumour in the orbit. Such communication may be the result of a bullet wound, a stab, a blow or fall sufficiently severe to cause a fracture of the base of the skull in this situation. The symptoms are sudden noise and pain in the head, followed by exophthalmos, swelling and congestion of the eyelids and conjunctivæ, and development of a pulsating tumour at the margin of the orbit, with thrill and the characteristic bruit; accompanying symptoms there may be impairment of sight, paralysis of the iris and orbital muscles, and pain of varying intensity. In some cases the opposite orbit becomes affected by the passage of the arterial blood into the opposite sinus by means of the intercavernous sinuses; or the arterial blood may find its way through the emissary veins (p. 734) into the pterygoid plexus, and thence into the veins of the face. Pulsating tumours of the orbit may also be due to traumatic aneurysm of one of the orbital arteries, and symptoms resembling those of pulsating tumour may be produced by the pressure of an aneurysm of the internal carotid artery upon the ophthalmic veins as they enter the sinus. Ligature of the internal or common carotid artery has been performed in these cases with considerable success.

It is now well known that caries in the upper parts of the nasal cavities and suppuration in certain of the accessory sinuses of the nose are frequently responsible for septic thrombosis of the cavernous sinuses, in exactly the same way as thrombosis of the transverse sinus is due to septic disease in the mastoid process. Many deaths from meningitis, hitherto unaccounted for, are in reality due to the spread of an infection from the ethmoidal or sphenoidal air-sinuses to the cavernous sinuses, and thence to the meninges.

The **ophthalmic veins** (fig. 737), two in number, superior and inferior, are devoid of valves.

The *superior ophthalmic vein* begins behind the medial angle of the upper eyelid by the union of two branches which communicate anteriorly with the angular and supra-orbital veins (p. 710). It runs alongside the ophthalmic artery, receives tributaries corresponding to the branches of the vessel, passes through the medial part of the superior orbital fissure, and ends in the cavernous sinus.

Fig. 736.—An oblique section through the left cavernous sinus.

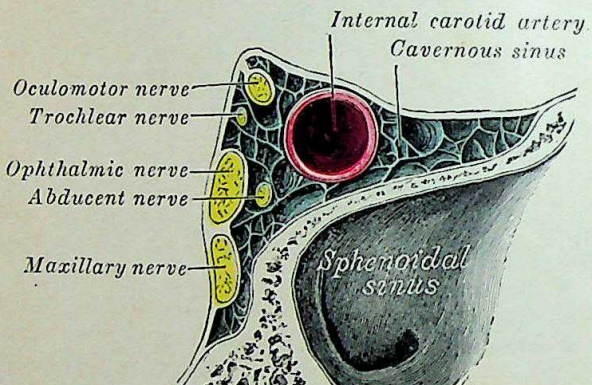

The *inferior ophthalmic vein* begins in a venous network on the fore part of the floor and medial wall of the orbit; it receives some veins from the Rectus inferior, Obliquus inferior, lacrimal sac and eyelids, and runs backwards above the Rectus inferior. It frequently joins the superior ophthalmic vein, but may open into the cavernous sinus. It communicates with the pterygoid venous plexus by means of small veins which pass through the inferior orbital fissure.

The **intercavernous sinuses**, an anterior and a posterior, connect the cavernous sinuses across the middle line, and are situated in the anterior and posterior borders of the diaphragma sellæ; they form with the cavernous sinuses a venous circle (*circular sinus*) (fig. 735); the posterior intercavernous sinus is sometimes absent.

The **superior petrosal sinuses** (fig. 735), small and narrow, drain the cavernous sinuses into the transverse sinuses. Each runs lateralwards and backwards, from the posterosuperior part of the corresponding cavernous sinus, over the trigeminal nerve, and lies in the attached margin of the tentorium cerebelli and in the superior petrosal sulcus of the temporal bone; it joins the transverse sinus where the latter curves downwards on the inner surface of the mastoid part of the temporal bone. It receives some cerebellar and inferior cerebral veins, and veins from the tympanic cavity.

CC-0. In Public Domain. Gurukul Kangri Collection, Haridwar

Digitized by Arya Samaj Foundation Chennai and eGangotri

The **inferior petrosal sinuses** drain the cavernous sinuses into the internal jugular vein. Each (fig. 735) begins in the postero-inferior part of the corresponding cavernous sinus, runs backwards in a groove between the petrous part of the temporal bone and the basilar part of the occipital bone, and passing through the anterior part of the jugular foramen, ends in the inferior bulb of the internal jugular vein. It receives the internal auditory veins and also veins from the medulla oblongata, pons, and under surface of the cerebellum.

The relations of the structures transmitted through the jugular foramen are as follows: the inferior petrosal sinus lies medially and anteriorly with the meningeal branch of the ascending pharyngeal artery, and is directed obliquely forwards and backwards; the transverse sinus is situated at the lateral and posterior part of the foramen with a meningeal branch of the occipital artery, between the two sinuses are the glossopharyngeal, vagus, and accessory

Fig. 737.—The veins of the orbit. (Poirier and Charpy.)

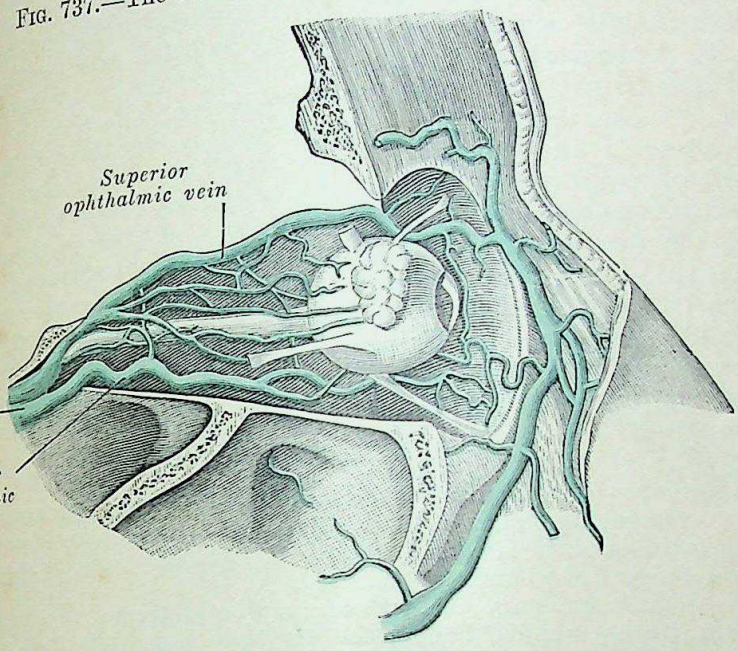

nerves. These three sets of structures are divided from each other by two processes of the dura mater. The junction of the inferior petrosal sinus with the internal jugular vein takes place on the lateral aspect of the nerves.

The **basilar plexus** (fig. 735) consists of several interlacing venous channels situated between the layers of the dura mater over the basilar part of the occipital bone; it connects the two inferior petrosal sinuses, and communicates with the anterior internal vertebral venous plexus.

The **middle meningeal sinuses** (middle meningeal veins) (fig. 735) accompany the branches of the middle meningeal arteries. They communicate above with the superior sagittal sinus and adjoining venous lacunæ, and unite to form two principal trunks, an anterior and a posterior, which accompany more or less closely the branches of the middle meningeal arteries in the grooves on the inner surface of the parietal bone; sometimes they occupy grooves apart from the arteries. Their mode of ending is subject to some variation. The posterior trunk may leave the cranial cavity through the foramen spinosum and open into the pterygoid venous plexus. The anterior trunk may reach the pterygoid plexus by emerging through the foramen ovale, or it may end in the sphenoparietal sinus or in the cavernous sinus. Besides their meningeal tributaries they receive some small inferior cerebral veins, and communicate with the diploic veins and with the middle cerebral vein.

Wood Jones * has pointed out that the grooves on the inner surfaces of the parietal bones are in reality impressed by the middle meningeal sinuses

* *Journal of Anatomy and Physiology*, vol. xlvi.

CC-0. In Public Domain. Gurukul Kangri Collection, Haridwar

Digitized by Arya Samaj Foundation Chennai and eGangotri

and not by the middle meningeal arteries, and says, "contrary to the gen belief of surgeons, the vascular tunnel at the pterion, although it lodges a venous sinus," branches, is typically formed by, and typically lodges a venous sinus." finds that the sinuses do not commonly pass out of the skull through the men spinosum, but adds that the limited number of his dissections for det mining this point does not warrant any dogmatic statement. He is inc to think that the blood which is poured out in most cases of middle menin hæmorrhage may be derived from the easily torn sinuses, and a similar is expressed in Poirier and Charpy's *Treatise of Human Anatomy*, vol. ii. pag p. 930.

The Emissary Veins

The **emissary veins** pass through apertures in the cranial wall and estab communications between the venous sinuses inside the skull and the ve external to it. Some are always present, others occasionally so. 1. A mast vein runs through the mastoid foramen and unites the transverse sinus with posterior auricular or occipital vein. 2. A parietal vein passes through parietal foramen and connects the superior sagittal sinus with the veins the scalp. 3. A network of minute veins (rete canalis hypoglossi) trav the hypoglossal canal and joins the transverse sinus with the inter jugular vein. 4. An inconstant condyloid vein passes through the condy canal and connects the transverse sinus with the deep veins of the n 5. A network of veins (rete foraminis ovalis) unites the cavernous sinus w the pterygoid plexus through the foramen ovale. 6. Two or three small ve run through the foramen lacerum and connect the cavernous sinus with t pterygoid plexus. 7. A vein traverses the foramen of Vesalius and conn the same parts. 8. An internal carotid plexus of veins accompanies t internal carotid artery through the carotid canal of the temporal bone and uni the cavernous sinus with the internal jugular vein. 9. A vein passes throu the foramen cæcum and connects the veins of the nose with the super sagittal sinus.

Applied Anatomy.—These emissary veins are of importance in surgery. Inflamma tory processes commencing on the outside of the skull may travel inwards through the and lead to thrombosis of the sinuses. To this in former days was to be attributed m of the principal dangers of wounds of the scalp.

By means of these emissary veins blood may be abstracted from the intracrani circulation—e.g. leeches applied behind the ear drain blood from the transverse sinu through the mastoid vein. Again, epistaxis in children may relieve severe headache the blood which flows from the nose being partly derived from the superior sagittal sinu by means of the vein passing through the foramen cæcum.

THE VEINS OF THE UPPER EXTREMITY AND THORAX

The veins of the upper extremity are divided into two sets, *superficial* an *deep*, which anastomose freely with each other. The superficial veins are pla beneath the skin, in the superficial fascia; the deep veins accompany th arteries. Both sets are provided with valves, which are more numerous the deep than in the superficial veins.

The Superficial Veins of the Upper Extremity (figs. 738, 739)

The **superficial veins** of the upper extremity are the cephalic, basilic, an median antibrachial veins, and their tributaries.

The *dorsal digital veins* pass along the sides of the fingers and are joine to one another by oblique communicating branches. Those from the adjace sides of the fingers unite to form three *dorsal metacarpal veins* (fig. 738), whic end in a *dorsal venous network* opposite the middle of the metacarpus. Th radial part of the network is joined by the dorsal digital vein from the radi

CC-0. In Public Domain. Gurukul Kangri Collection, Haridwar

Digitized by Arya Samaj Foundation Chennai and eGangotri

of the index finger and by the dorsal digital veins of the thumb, and prolonged upwards as the cephalic vein. The ulnar part of the network receives the dorsal digital vein of the ulnar side of the little finger and is continued upwards as the basilic vein. A communicating branch frequently connects the dorsal venous network with the cephalic vein about the middle of the forearm.

FIG. 738.—The veins of the dorsum of the hand. (Bourgery.)

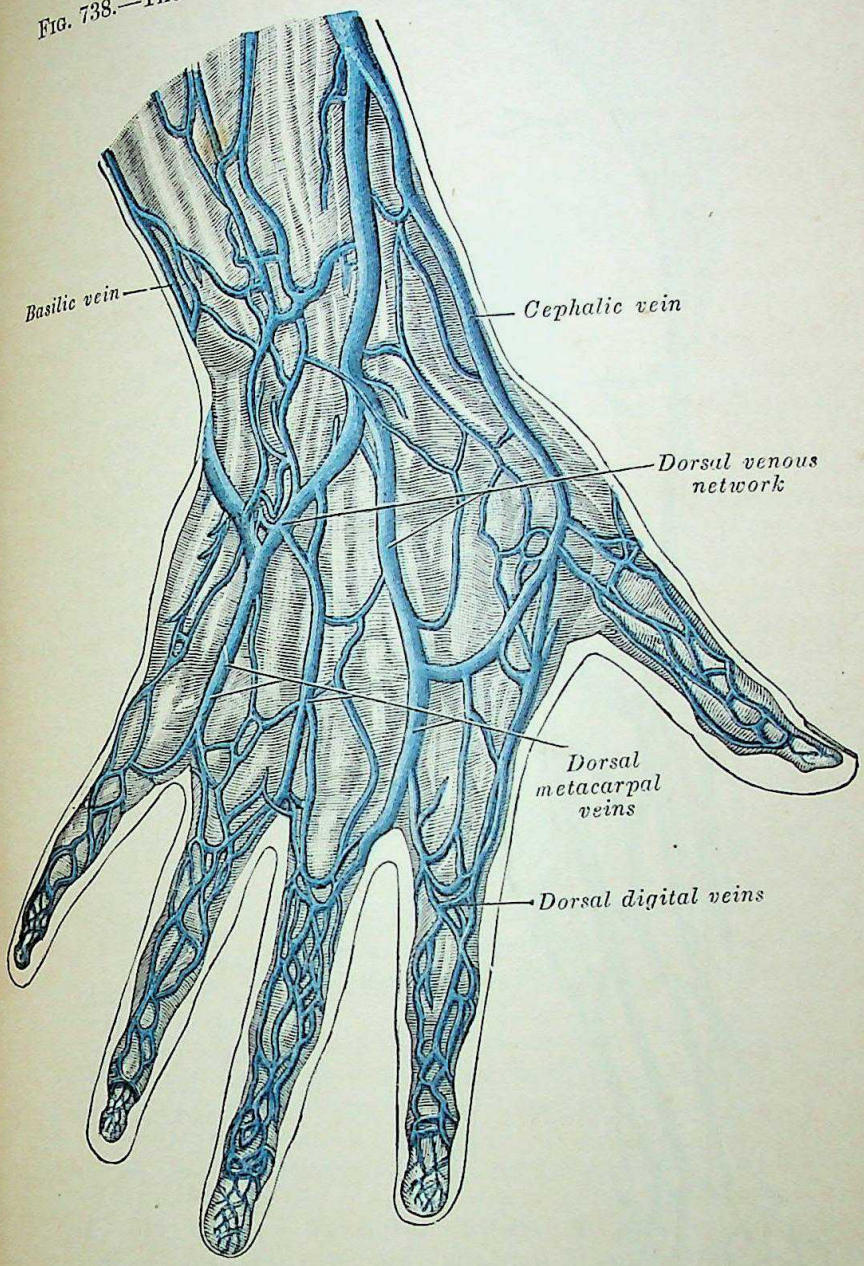

The *proper volar digital veins* are connected to the dorsal digital veins by oblique *intercapitular veins* which pass backwards between the heads of the metacarpal bones. They also drain into a venous plexus which lies superficial to the palmar aponeurosis, and extends over the thenar and hypothenar eminences.

The **cephalic vein** (fig. 739) begins in the radial part of the dorsal venous network of the hand and winds upwards round the radial border of the forearm to its volar surface, receiving tributaries from both surfaces. Below the front of the elbow it gives off the *median cubital vein* (median basilic vein), which receives a communicating branch from the deep veins of the forearm and passes medialwards to join the basilic vein. The cephalic vein then ascends in

CC-0. In Public Domain. Gurukul Kangri Collection, Haridwar

Digitized by Arya Samaj Foundation Chennai and eGangotri

front of the elbow in the groove between the Brachioradialis and the Biceps brachii. It crosses superficial to the lateral antibrachial cutaneous nerve, runs upwards along the lateral border of the Biceps muscle. In the upper one-third of the arm it passes between the Pectoralis major and Deltoideus, where it is accompanied by the deltoid branch of the thoraco-acromial artery. It pierces the coracoclavicular fascia, crosses the axillary artery, and ends in the axillary vein just below the clavicle. Sometimes it communicates with the external jugular vein by a branch which ascends in front of the clavicle.

Fig. 739.—The superficial veins of the right upper extremity.

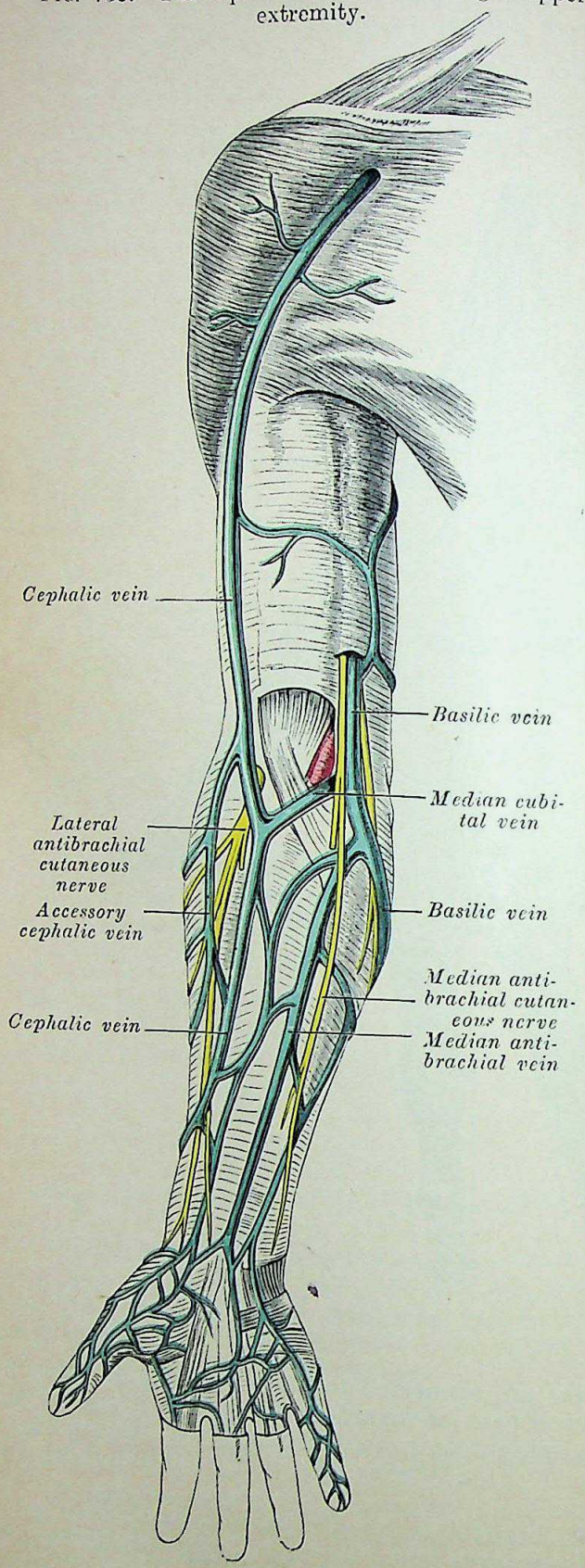

In some cases the median cubital vein is large and carries all or most of the blood from the cephalic to the basilic vein, the reverse being that the proximal part of the cephalic vein is either absent or of small size.

The *accessory cephalic* vein arises from a small tributary plexus on the back of the forearm or from the ulnar side of the dorsal venous network; it joins the cephalic below the elbow. In some cases it springs from the cephalic vein above the wrist and joins it again higher up. A large oblique branch frequently connects the basilic and cephalic veins on the back of the forearm.

The **basilic vein** (fig. 739) begins in the ulnar part of the dorsal venous network of the hand. It runs up for some distance on the posterior surface of the ulnar side of the forearm but inclines forward to the anterior surface below the elbow. It is joined by the median cubital vein and ascends obliquely in the groove between the Biceps brachii and Pronator teres. The filaments of the medial antibrachial cutaneous nerve pass both in front of and behind this portion of the vein. It then runs upwards along the medial border of the arm, Biceps brachii, perforates the deep fascia a little below the middle of the arm, and, ascending on the medial side of the brachial artery to the lower border of the Teres major, is continued onwards as the axillary vein.

CC-0. In Public Domain. Gurukul Kangri Collection, Haridwar

Digitized by Arya Samaj Foundation Chennai and eGangotri

The **median antibrachial vein** (fig. 739) drains the venous plexus on the volar surface of the hand. It ascends on the front of the forearm and ends in the basilic vein or the median cubital vein; in a small proportion of cases it divides below the elbow into two branches, one of which joins the basilic vein, the other the cephalic vein.

Applied Anatomy.—*Venesection* is generally performed at the bend of the elbow, and as a matter of practice the largest vein in this situation, the median cubital (median basilic), is commonly selected.

Intravenous infusion of normal saline solution is frequently required in modern surgery for conditions of severe shock and after profuse hæmorrhages, when suitable donors are not available for transfusion of blood. The patient's arm is surrounded by a tourniquet bandage so as to impede the venous return, and a small incision is made over the largest vein visible in front of the elbow; a double ligature is passed around the vein, and the lower ligature is tied; the vein is then opened and a cannula, connected with a syringe by tubing, is inserted. The bandage is next removed from the arm, and two, three, or more pints of hot saline solution are allowed to flow into the vein; when a sufficient quantity has gone in, the upper ligature round the vein is tied and a stitch put in the skin wound.

The Deep Veins of the Upper Extremity

The **deep veins** follow the course of the arteries, and form their venæ comitantes. They are generally arranged in pairs, and are situated one on each side of the corresponding artery, and connected at intervals by short transverse branches.

The **deep veins of the hand.**—The superficial and deep volar arterial arches are each accompanied by a pair of venæ comitantes which constitute respectively the *superficial* and *deep volar venous arches*, and receive the veins corresponding to the branches of the arterial arches; thus the *common volar digital veins* formed by the union of the *proper volar digital veins*, open into the superficial, and the *volar metacarpal veins* into the deep, volar venous arches. The deep veins accompanying the dorsal metacarpal arteries receive perforating branches from the volar metacarpal veins, and end in the radial veins and in the dorsal venous network.

The **deep veins of the forearm** are the venæ comitantes of the radial and ulnar arteries and constitute respectively the upward continuations of the deep and superficial volar venous arches; they unite in front of the elbow to form the brachial veins. The radial veins are smaller than the ulnar, and receive the deep veins of the dorsum of the hand. The ulnar veins receive tributaries from the deep volar venous arches and communicate with the superficial veins at the wrist; near the elbow they receive the volar and dorsal interosseous veins and send a large communicating branch (profunda vein) to the median cubital vein.

The **brachial veins** are placed one on either side of the brachial artery, and receive tributaries corresponding with the branches of that artery; near the lower margin of the Subscapularis, they join the axillary vein; the medial one frequently joins the basilic vein.

These deep veins have numerous anastomoses, not only with each other, but also with the superficial veins.

The **axillary vein** begins at the lower border of the Teres major, as the continuation of the basilic vein, increases in size as it ascends, and ends at the outer border of the first rib as the subclavian vein. Near the lower border of the Subscapularis it receives the brachial veins and, close to its termination, the cephalic vein; its other tributaries correspond with the branches of the axillary artery. It lies on the medial side of the axillary artery, which it partly overlaps; between the two vessels are the medial anterior thoracic nerve, the medial cord of the brachial plexus, the ulnar nerve and the medial anti-brachial cutaneous nerve. It is provided with a pair of valves opposite the lower border of the Subscapularis; valves are also found at the ends of the cephalic and subscapular veins.

Applied Anatomy.—Since the axillary vein is superficial to and larger than the axillary artery, which it overlaps, it is more liable to be wounded than the artery in the operation of extirpation of the axillary glands, especially as these glands, when diseased,

CC-0. In Public Domain. Gurukul Kangri Collection, Haridwar

Digitized by Arya Samaj Foundation Chennai and eGangotri

are apt to become adherent to it. To avoid wounding the vein, it is advisable to expose it as soon as possible; no sharp cutting instruments should be used after the axillary cavity has been freely exposed, and no undue force employed in isolating the glands (p. 6[illegible]).

The **subclavian vein** (fig. 741), the continuation of the axillary vein, extends from the outer border of the first rib to the medial border of the Scalenus anterior, where it unites with the internal jugular vein to form the innominate

FIG. 740.—Dissection of the lower part of the neck, and the upper part of the thorax. Anterior aspect.

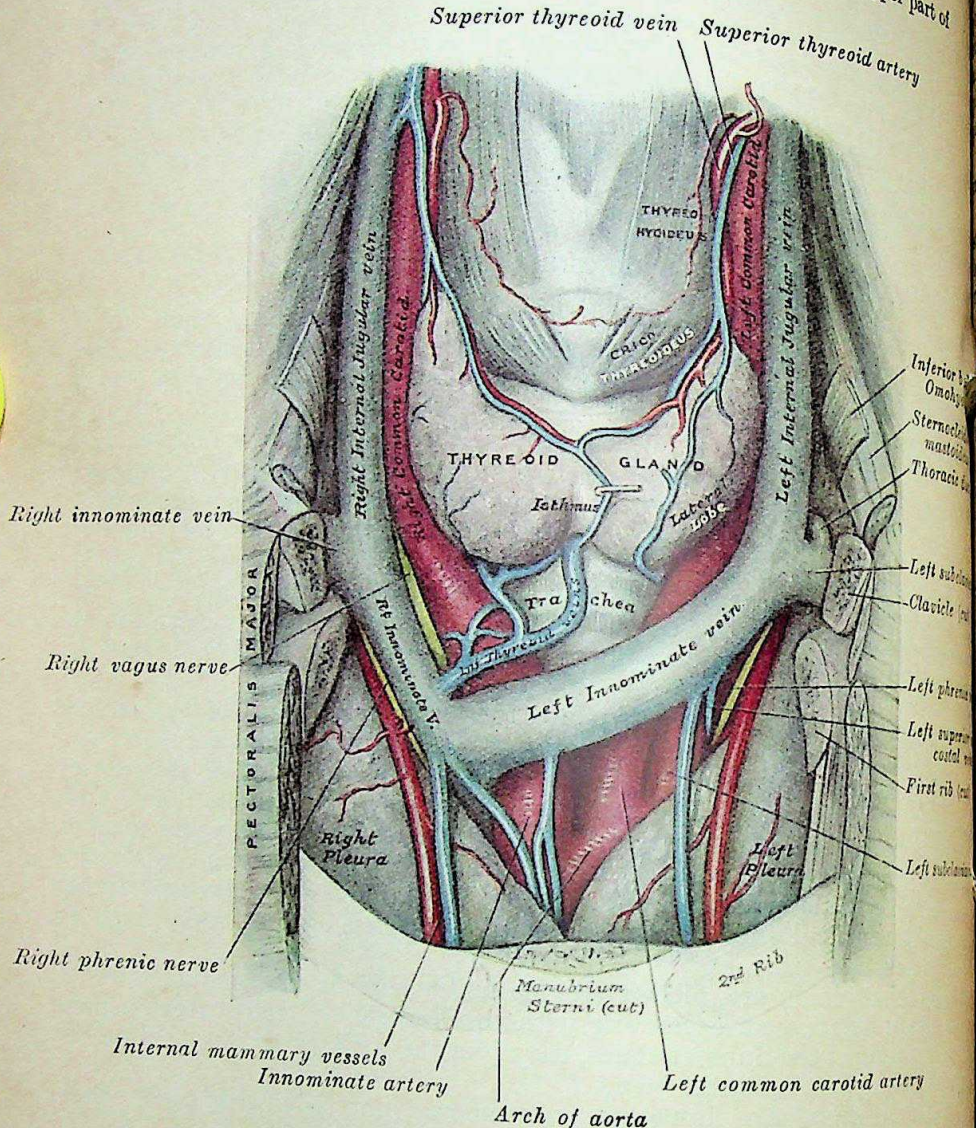

vein. It is in relation, in front, with the clavicle and Subclavius; behind and above, with the subclavian artery, from which it is separated by the Scalenus anterior and the phrenic nerve. Below, it rests in a depression on the first rib and upon the pleura. It is usually provided with a pair of valves, which are situated about 2 cm. from its termination.

Its tributaries are the external jugular vein, sometimes the anterior jugular vein, and occasionally a small branch, which ascends in front of the clavicle, from the cephalic vein.

At its angle of junction with the internal jugular vein, the left subclavian vein receives the thoracic duct, and the right subclavian vein the right lymphatic duct.

CC-0. In Public Domain. Gurukul Kangri Collection, Haridwar

Digitized by Arya Samaj Foundation Chennai and eGangotri

The Veins of the Thorax (figs. 740, 741)

The **innominate veins** are two large trunks, placed one on either side of root of the neck, and formed by the union of the internal jugular and vian veins of the corresponding side; they are devoid of valves.

The **right innominate vein** (fig. 740), about 2·5 cm. long, begins behind the nal end of the right clavicle, and, passing almost vertically downwards, the left innominate vein behind the cartilage of the first rib, close to the e border of the sternum, to form the superior vena cava. It lies in front to the right of the innominate artery and the right vagus nerve. The right ra, phrenic nerve, and internal mammary artery are posterior to the upper , and lateral to the lower part of the vein.

Its tributaries are the right vertebral, the right internal mammary and the right erior thyreoid veins, and sometimes the first right intercostal vein.

The **left innominate vein** (fig. 740), about 6 cm. long, begins behind the rnal end of the left clavicle and runs obliquely downwards and to the right hind the upper half of the manubrium sterni to the sternal end of the first e costal cartilage, where it unites with the right innominate vein to form e superior vena cava. It is separated from the manubrium sterni by the rnohyoideus and Sternothyreoideus, the thymus or its remains, and some areolar tissue. Behind it are the left pleura, the left internal mammary, clavian and common carotid arteries, the left phrenic and vagus nerves, the chea and the innominate artery. Below it, is the arch of the aorta.

Its tributaries are the left vertebral, left internal mammary, left inferior thyreoid, d left superior intercostal veins, sometimes the first left intercostal vein and asionally some thymic and pericardial veins.

Peculiarities.—Sometimes the innominate veins open separately into the right atrium; such cases the right vein takes the ordinary course of the superior vena cava; the left —*left superior vena cava*, as it is then termed—which may communicate by a small nch with the right one, passes in front of the root of the left lung, and, turning to the ck of the heart, ends in the right atrium. This occasional condition in the adult is due the persistence of the early fœtal condition (p. 127), and is the normal state of things birds and some mammals.

The left innominate vein sometimes projects above the level of the manubrium sterni, ssing the jugular notch, and lying in front of the trachea.

The **internal mammary veins** (fig. 740) are venæ comitantes to the lower half of internal mammary artery, and receive tributaries corresponding to the branches the artery. They unite to form a single trunk, which runs up on the medial de of the artery and ends in the corresponding innominate vein. The *superior renic vein* (i.e. the vein accompanying the pericardiacophrenic artery) usually ens into the internal mammary vein.

The **inferior thyreoid veins** (figs. 730, 740), two or more in number, arise in the yreoid gland in a venous network which communicates with the middle and superior yreoid veins. They form a plexus in front of the trachea. From this plexus left vein descends and joins the left innominate trunk, and a right vein passes liquely downwards and to the right across the innominate artery to open into e right innominate vein, at its junction with the superior vena cava; frequently e right and left veins open by a common trunk in the latter situation. These ins receive œsophageal, tracheal, and inferior laryngeal veins, and are provided th valves at their terminations.

The **left superior intercostal vein** (fig. 741) receives the second and third (and metimes the fourth) left intercostal veins; it runs obliquely upwards and forwards the left side of the aortic arch between the left phrenic and vagus nerves and ens into the left innominate vein. It usually receives the left bronchial veins, d sometimes the left superior phrenic vein; it communicates below with the bsidiary hemiazygos vein.

The **superior vena cava** (figs. 653, 654, 655, 657) drains the blood from the per half of the body. It measures about 7 cm. in length, is formed by the ion of the two innominate veins, and is devoid of valves. It begins hind the cartilage of the right first rib close to the sternum, and, descend- g vertically behind the first and second intercostal spaces, ends in the upper t of the right atrium opposite the third right costal cartilage; the lower

CC-0. In Public Domain. Gurukul Kangri Collection, Haridwar

Digitized by Arya Samaj Foundation Chennai and eGangotri

half of the vessel is within the pericardium. In its course it describes a curve, the convexity of which is to the right side.

FIG. 741.—The venæ cavæ and the azygos vein, with their tributaries.

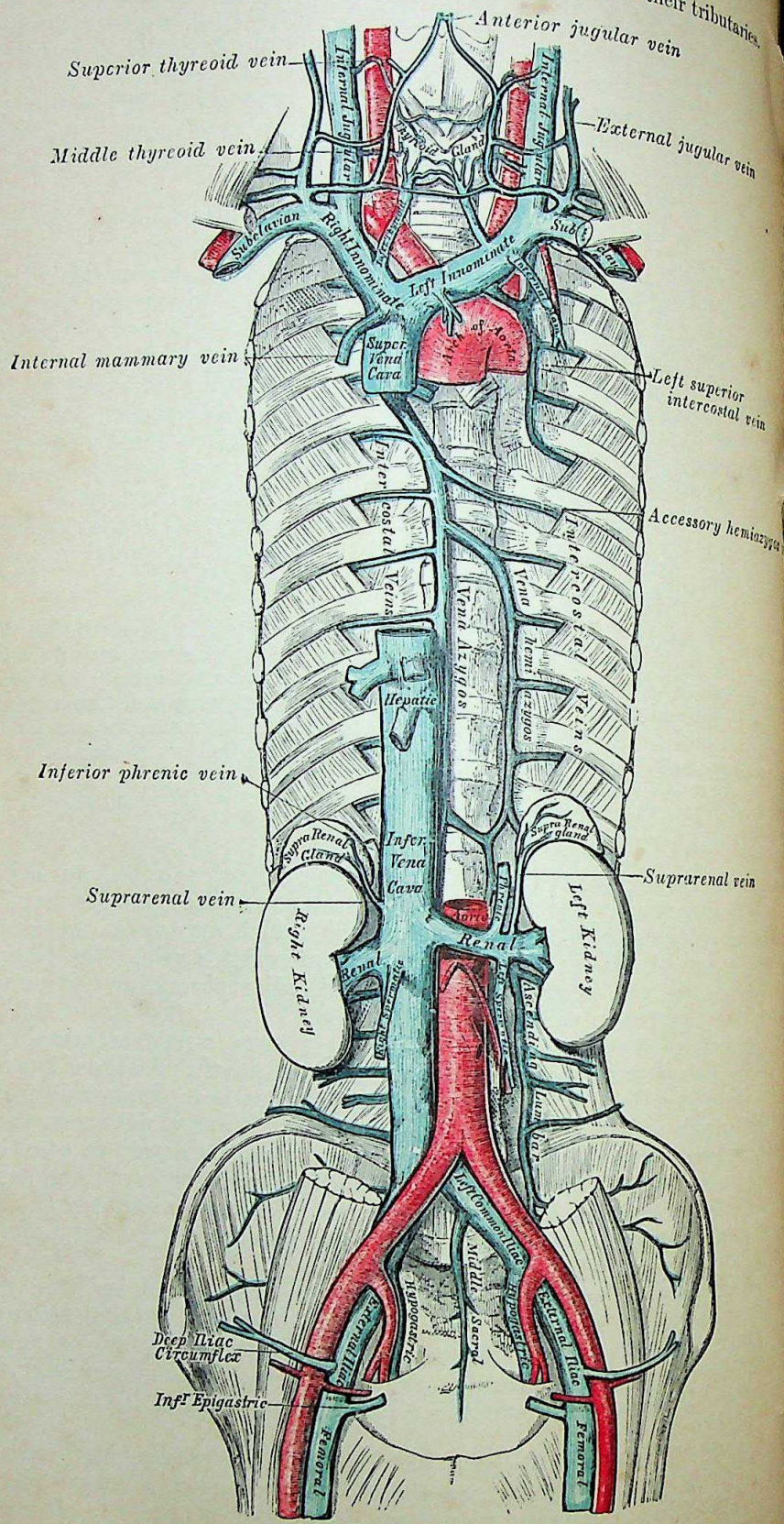

Relations.—*In front* of the superior vena cava are the anterior margins of the right lung and pleura with the pericardium intervening; these separate

CC-0. In Public Domain. Gurukul Kangri Collection, Haridwar

Digitized By Arya Samaj Foundation Chennai and eGangotri

the first and second intercostal spaces, and from the second and third right cartilages; *behind* it are the trachea above, and the root of the right lung. On its *right side* are the right phrenic nerve and right pleura; on its *left* the commencement of the innominate artery and the ascending aorta, the overlapping it. The portion contained within the pericardium is covered, front and laterally, by the serous pericardium.

Tributaries.—Before it pierces the pericardium, the superior vena cava receives the azygos vein and several small veins from the pericardium and other structures the mediastinal cavity.

The **azygos vein** (fig. 741) begins opposite the first or second lumbar vertebra as a branch of the right ascending lumbar vein (p. 741); sometimes as a branch of the right renal vein, or of the inferior vena cava. It enters the thorax through the aortic hiatus in the Diaphragm, and ascends through the posterior mediastinal cavity to the level of the fourth thoracic vertebra where it arches forward over the root of the right lung, and ends in the superior vena cava, just before that vessel pierces the pericardium. In the *abdomen* it is in front of the upper two lumbar vertebræ, behind the right crus of the diaphragm, and to the right of the cisterna chyli and the aorta. In the *thorax* it ascends in front of the bodies of the lower eight thoracic vertebræ, the anterior longitudinal ligament, and the right intercostal arteries. On its right side are the right lung and pleura; on its left side, throughout the greater part of its course, are the thoracic duct and aorta, and higher up, where it arches forward above the root of the right lung, the œsophagus, trachea and right vagus.

Tributaries.—It receives the right subcostal vein and the right posterior intercostal veins, with the exception of the vein from the first intercostal space; the veins from the second, third and fourth intercostal spaces open by a common stem and the right superior intercostal vein. It also receives the hemiazygos and accessory hemiazygos veins, several œsophageal, mediastinal, and pericardial veins, and, near its termination, the right bronchial veins. A few imperfect valves are found in the azygos vein; but its tributaries are provided with complete valves.

The **hemiazygos vein** (fig. 741) begins in the left ascending lumbar vein or in the left renal vein. It enters the thorax through the left crus of the diaphragm, and, ascending on the left side of the vertebral column as high as the eighth thoracic vertebra, passes across the column, behind the aorta, œsophagus, and thoracic duct, to end in the azygos vein. It receives the lower three posterior intercostal veins and the subcostal vein of the left side, and some œsophageal and mediastinal veins.

The **accessory hemiazygos vein** (fig. 694) descends on the left side of the vertebral column. It receives the veins from the fourth (or fifth) to the eighth intercostal spaces inclusive, and sometimes the left bronchial veins. It crosses the body of the seventh thoracic vertebra and joins the azygos vein. The accessory hemiazygos vein sometimes joins the hemiazygos vein, and the common trunk thus formed opens into the azygos vein.

The **intercostal veins** (figs. 694, 741) are sometimes named the *posterior intercostal veins* to distinguish them from the small *anterior intercostal veins* which are tributaries of the musculophrenic and internal mammary veins. They run with the anterior rami of the intercostal arteries and are eleven in number on either side. As they approach the vertebral column each receives a tributary which accompanies the posterior ramus of an intercostal artery, and returns blood from the muscles and skin of the back and from the vertebral venous plexuses.

On both sides of the thorax the first intercostal vein ascends in front of the neck of the first rib and ends in the corresponding innominate or vertebral vein.

On the right side the second, third and fourth posterior intercostal veins unite to form the *right superior intercostal vein*, which joins the terminal part of the azygos vein. The veins from the intercostal spaces below the fourth open separately into the vena azygos.

On the left side the second and third (and sometimes the fourth) posterior intercostal veins unite to form the left superior intercostal vein (p. 729). The veins from the fourth (or fifth) to the eighth intercostal spaces inclusive end in the accessory hemiazygos vein, and the veins from the lower three spaces in the hemiazygos vein.

Applied Anatomy.—In obstruction of the superior vena cava, the azygos and hemiazygos veins are one of the principal means by which the venous circulation is carried on, connecting as they do the superior and inferior vena cavæ, and communicating with the

CC-0. In Public Domain. Gurukul Kangri Collection, Haridwar

Digitized by Arya Samaj Foundation Chennai and eGangotri

common iliac veins by the ascending lumbar veins, and with many of the tributaries of the inferior vena cava.

Thrombosis of the superior vena cava is oftenest due to pressure exerted on the vena by an aneurysm or a tumour; it may also occur by propagation of clotting from a tributary peripheral vein. If occlusion of the vessel take place slowly, a collateral venous circulation may be established; the patient will have some œdema with dilatation and congestion of the veins about the head and neck, and may also suffer from attacks of dyspnœa and recurrent pleural effusion. In most cases, however, the blockage of the superior cava takes place rapidly, and is rapidly fatal.

The **bronchial veins,** usually two on either side, return the blood from the lungs, bronchi, and from the structures at the roots of the lungs; those of the right side open into the terminal part of the vena azygos; those of the left side, into the left superior intercostal vein or the accessory hemiazygos vein. Some of the blood carried to the lungs through the bronchial arteries is returned to the heart through the pulmonary veins.

The Veins of the Vertebral Column (figs. 742, 743)

The veins which drain the blood from the vertebral column, the neighbouring muscles, and the meninges of the medulla spinalis form intricate plexuses extending along the entire length of the column; these plexuses are divisible into two groups, external and internal, according to their positions outside or inside the vertebral canal. The plexuses of the two groups anastomose freely with each other, and also in the intervertebral veins.

Fig. 742.—A transverse section through a thoracic vertebra, showing the vertebral venous plexuses.

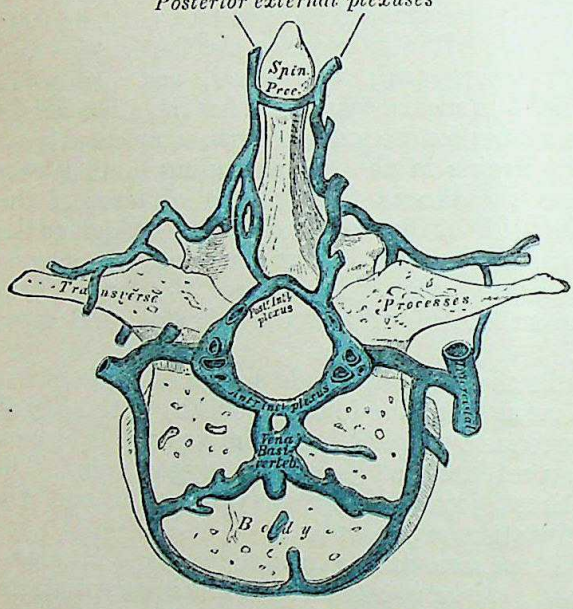

The **external vertebral venous plexuses**, best marked in the cervical region, consist of anterior and posterior plexuses which anastomose freely with each other. The *anterior external plexuses* lie in front of the bodies of the vertebræ, communicating with the basivertebral and intervertebral veins, and receiving tributaries from the vertebral bodies. The *posterior external plexuses* are placed partly on the posterior surfaces of the vertebral arches and their processes, and partly between the deep dorsal muscles. In the cervical region they anastomose with the vertebral, occipital, and deep cervical veins.

The **internal vertebral venous plexuses** lie within the vertebral canal between the dura mater and the vertebræ, and receive tributaries from the bones and from the medulla spinalis. They form a closer network than the external plexuses and, running mainly in a vertical direction, form four longitudinal veins, two in front and two behind; they therefore may be divided into anterior and posterior groups. The *anterior internal plexuses* consist of large veins which lie on the posterior surfaces of the vertebral bodies and intervertebral fibrocartilages, on either side of the posterior longitudinal ligament; under cover of this ligament they are connected by transverse branches into which the basivertebral veins open. The *posterior internal plexuses* are placed one on either side of the middle line in front of the vertebral arches and ligamenta flava, and anastomose, by veins passing through those ligaments, with the posterior external plexuses.

The anterior and posterior internal plexuses communicate freely with each another by a series of venous rings, one opposite each vertebra. Around the foramen magnum they form an intricate network which opens into the vertebral

CC-0. In Public Domain. Gurukul Kangri Collection, Haridwar

Digitized by Arya Samaj Foundation Chennai and eGangotri

...ses and is connected above with the occipital sinus, the basilar plexus, the ...yloid emissary vein, and the rete canalis hypoglossi.

The **basivertebral veins** emerge from the foramina on the posterior surfaces ...the vertebral bodies. They are contained in large, tortuous channels in the ...bstance of the bones, similar in every respect to those found in the diploë of ...cranial bones. They communicate through small openings on the front and ...s of the bodies of the vertebræ with the anterior external vertebral plexuses, ...d converge behind to form single (sometimes double) veins which open by valved ...ices into the transverse branches uniting the anterior internal vertebral plexuses. ...the basivertebral veins become ...ously enlarged in advanced ...ge.

The **intervertebral veins** ...ccompany the spinal nerves ...rough the intervertebral fora-...mina; they receive the veins ...from the medulla spinalis, ...ain the internal and external ...ertebral plexuses and end in ...e vertebral, intercostal, lum-... and lateral sacral veins, ...r orifices being provided with ...lves.

The **veins of the medulla** ...nalis are situated in the pia ...ater and form a tortuous, ...ous plexus. In this plexus ...ere are: (1) two median ...ongitudinal veins, one in front of the anterior fissure, and the other behind the ...nterior sulcus of the medulla spinalis; and (2) four lateral longitudinal veins ...hich run behind the nerve-roots. They end in the internal vertebral venous ...exuses. Near the base of the skull they unite to form two or three small trunks, ...hich communicate with the vertebral veins, and end in the inferior cerebellar ...ins, or in the inferior petrosal sinuses.

Fig. 743.—A median sagittal section through two thoracic vertebræ, showing the vertebral venous plexuses.

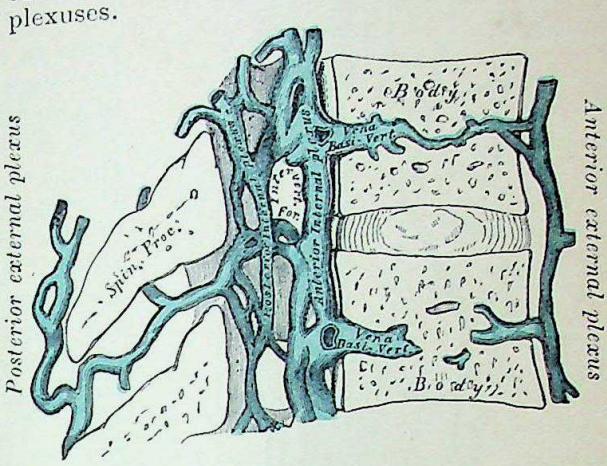

THE VEINS OF THE LOWER EXTREMITY, ABDOMEN, AND PELVIS

The veins of the lower extremity are subdivided, like those of the upper ...tremity, into two sets, *superficial* and *deep*: the superficial veins are placed ...neath the skin in the superficial fascia; the deep veins accompany the ...teries. Both sets are provided with valves, which are more numerous in ...e deep than in the superficial set. Valves are more numerous in the veins of ...e lower than in those of the upper extremity.

The Superficial Veins of the Lower Extremity

The **superficial veins** of the lower extremity are the great and small ...henous veins and their tributaries.

The *dorsal digital veins* receive, in the clefts between the toes, the *inter-...gitular veins* from the plantar digital veins, and then join to form *dorsal ...tatarsal veins*, which unite across the distal ends of the metatarsal bones ...a *dorsal venous arch*. Proximal to this arch is an irregular dorsal venous ...work which receives tributaries from the deep veins and is continuous with ... venous network on the front of the leg. At the sides of the foot this ...work communicates with a *medial* and a *lateral marginal vein*, which are ...ed mainly by the union of veins from the superficial parts of the sole of ...e foot.

CC-0. In Public Domain. Gurukul Kangri Collection, Haridwar

Digitized by Arya Samaj Foundation Chennai and eGangotri

On the sole of the foot the superficial veins form a *plantar cutaneous* [illegible] *arch* which extends across the roots of the toes and opens at the sides of [illegible] foot into the medial and lateral marg[illegible] veins. Proximal to this arch is a [illegible] *cutaneous venous network* which is [illegible] dense in the fat beneath the heel [illegible] network communicates with the [illegible] cutaneous venous arch and with the [illegible] veins, but is chiefly drained into the [illegible] and lateral marginal veins.

Fig. 744.—The great saphenous vein and its tributaries.

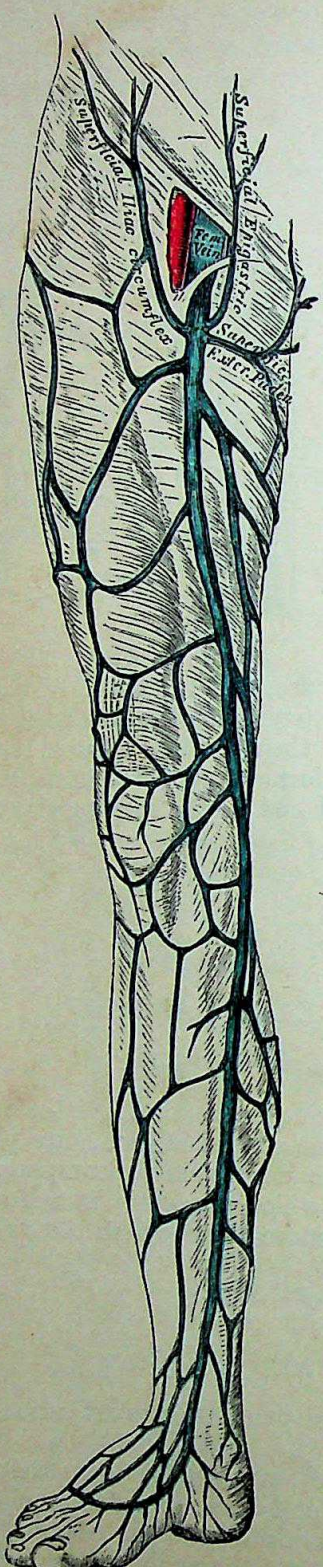

The **great saphenous vein** (figs. [illegible] 745), the longest vein in the body, begins [illegible] the medial marginal vein of the foot, [illegible] ends in the femoral vein about 3 cm. [illegible] the inguinal ligament. It ascends in [illegible] of the tibial malleolus and along the [illegible] side of the distal one-third of the tibia, [illegible] then behind the medial border of the [illegible] It runs upwards behind the medial con[illegible] of the tibia and femur and along the [illegible] side of the thigh and, passing through [illegible] fossa ovalis, ends in the femoral vein. [illegible] the thigh it is accompanied by some bran[illegible] of the medial femoral cutaneous nerve [illegible] the knee by the saphenous branch of [illegible] highest genicular artery, and in the leg [illegible] foot by the saphenous nerve which is pl[illegible] in front of the vein. The great saphe[illegible] vein is often duplicated, especially below [illegible] knee. The valves in it number from ten [illegible] twenty and are more numerous in the [illegible] than in the thigh.

Tributaries.—At the ankle it receives [illegible] from the sole of the foot through the me[illegible] marginal vein; in the leg it communic[illegible] freely with the small saphenous vein and [illegible] the anterior and posterior tibial veins, [illegible] receives many cutaneous veins; in the thi[illegible] it receives numerous tributaries; those fr[illegible] the medial and posterior parts of the thi[illegible] frequently unite to form a large *acces[illegible] saphenous vein* which joins the main [illegible] at a variable level. Near the fossa ov[illegible] (fig. 744) it is joined by the superf[illegible] epigastric, superficial iliac circumflex, [illegible] superficial external pudendal veins. [illegible] superficial epigastric and superficial iliac [illegible] cumflex veins drain the lower part of [illegible] abdominal wall, the latter vein also rece[illegible] tributaries from the upper and lateral p[illegible] of the thigh; the superficial external pude[illegible] vein drains part of the scrotum and rece[illegible] the superficial dorsal vein of the penis.

A vein, named the *thoraco-epigastric*, [illegible] along the anterolateral wall of the tru[illegible] connecting the superficial epigastric vein, or [illegible] femoral vein, with the lateral thoracic ve[illegible] and establishing an important communica[illegible] between the femoral and axillary veins.

The **small saphenous vein** (fig. 746) begins behind the lateral malleolus [illegible] a continuation of the lateral marginal vein of the foot; it first ascends on th[illegible] lateral border of the tendo calcaneus, and then along the middle of the be[illegible] of the leg. It perforates the deep fascia in the lower part of the popli[illegible]

CC-0.In Public Domain. Gurukul Kangri Collection, Haridwar

Digitized by Arya Samaj Foundation Chennai and eGangotri

and ends in the popliteal vein, between the heads of the Gastro-
It communicates with the deep veins on the dorsum of the foot,
receives numerous large tributaries from the back of the leg. Before
the deep fascia, it gives off a branch which runs upwards and
wards to join the great saphenous vein; this branch is sometimes

FIG. 745.—The great saphenous vein and its tributaries at the fossa ovalis.

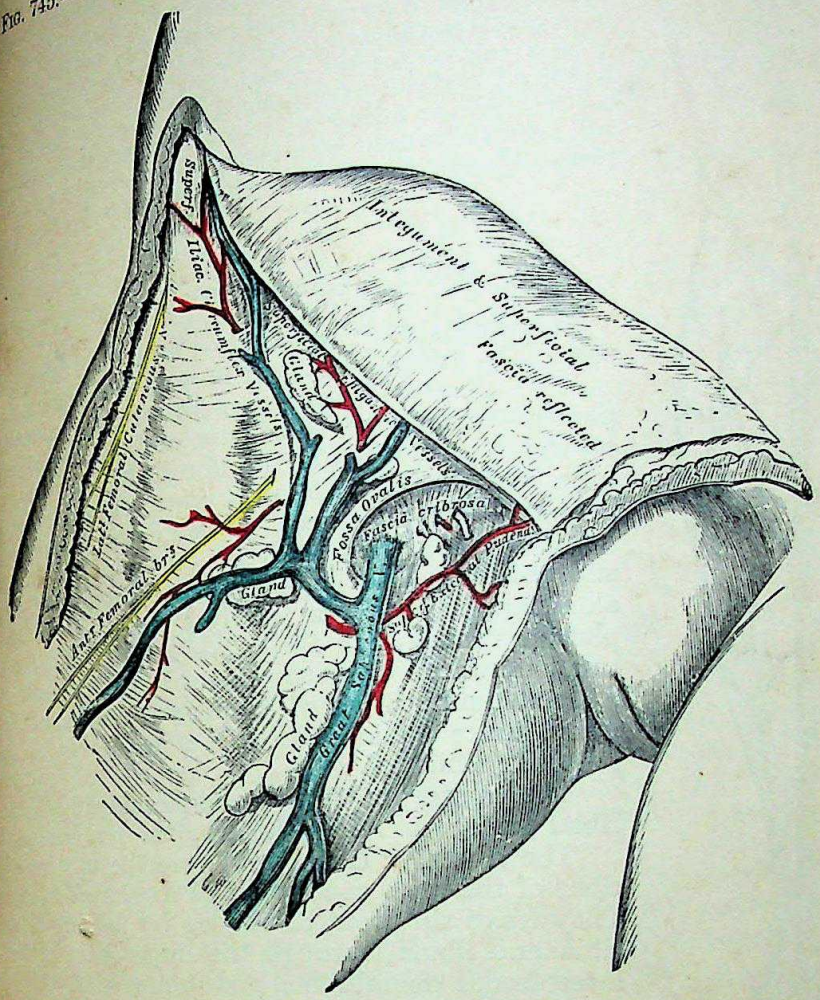

, and may then form the direct continuation of the small saphenous
In the lower one-third of the leg the vein is in close relation with the
nerve, in the upper two-thirds with the medial sural cutaneous nerve.
The small saphenous vein possesses from nine to twelve valves, one of
h is found near its termination in the popliteal vein.

plied Anatomy.—A varicose condition is more frequently met with in the saphenous
than in the other veins of the body, except perhaps the testicular and hæmorrhoidal
The main cause of this is the high blood-pressure, determined chiefly by the erect
on, and the length of the column of blood, which has to be propelled in an uphill
ion. In normal vessels there is only just sufficient force to perform this task; and
ese cases where there is diminished resistance of the walls of the veins, these vessels
able to dilate and a varicose condition is set up. This diminished resistance may be
o heredity, the vein-walls being congenitally weak, or may follow inflammatory
tions of the vessels. Increased blood-pressure in the veins, caused by any obstacle
e return of the venous blood, such as the pressure of a tumour, or the gravid uterus,
ight gartering, may also produce varix. In the normal condition of the veins, the
s in their interior break up the column of blood into a number of smaller columns,
s to a considerable extent mitigate the ill effects of the erect position; but when
dilatation of the veins has reached a certain limit, the valves become incapable of
ting the overlying column of blood, and the pressure is increased, tending to

CC-0. In Public Domain. Gurukul Kangri Collection, Haridwar

Digitized by Arya Samaj Foundation Chennai and eGangotri

emphasise also the varicose condition. Both the saphenous veins in the leg are accompanied by nerves, the great saphenous being joined by its companion nerve just below the level of the knee-joint; no doubt much of the pain of varicose veins in the leg is due to this fact.

Operations for the relief of varicose veins are frequently required, portions of the veins being removed after having been ligatured above and below. It is important to note whether the main varicose area drains into the great or the small saphenous vein—the former condition being much the more common. It is important to control the venous return by removing a small portion of the main trunk just before it opens into the deep vein by passing through the deep fascia; thus in most cases a piece of the vein is removed from the great saphenous before it passes through the fossa ovalis (saphenous opening), leaving sufficient of the base of a cone to form a surface for the attachment of the base of a clot. In addition the affected veins should be excised just above and below the level of the knee-joint. In other cases the small saphenous will have to be dealt with immediately below the point where it pierces the fascial roof of the popliteal fossa.

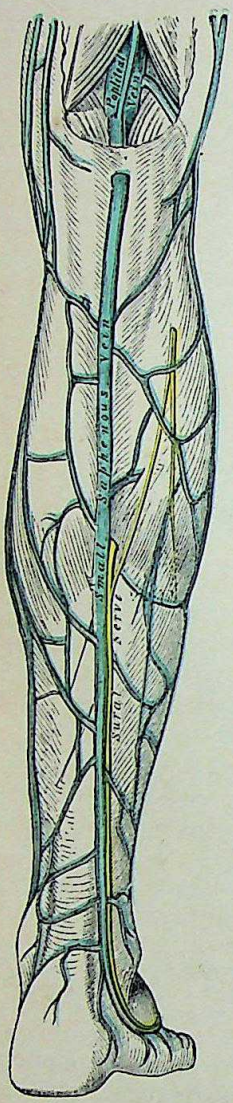

Fig. 746.—The small saphenous vein.

The Deep Veins of the Lower Extremity

The **deep veins** of the lower extremity accompany the arteries and their branches; they possess numerous valves.

The *plantar digital veins* arise from plexuses on the plantar surfaces of the digits, and, after sending the *capitular veins* to join the dorsal digital veins, unite to form four *plantar metatarsal veins*; these run backwards in the metatarsal spaces, communicate, by means of perforating veins, with the veins on the dorsum of the foot and unite to form the *deep plantar venous arch* which lies alongside the plantar arterial arch. From the deep plantar venous arch the *medial* and *lateral plantar veins* run backwards close to the corresponding arteries and, after communicating with the great and small saphenous veins, unite behind the medial malleolus to form the posterior tibial veins.

The **posterior tibial veins** accompany the posterior tibial artery, and are joined by the *peronæal veins*.

The **anterior tibial veins** are the upward continuations of the venæ comitantes of the dorsalis pedis artery. They leave the front of the leg by passing between the tibia and fibula, through the upper part of the crural interosseous membrane, and unite with the posterior tibial veins to form the *popliteal vein*.

The **popliteal vein**, formed by the junction of the anterior and posterior tibial veins at the lower border of the Popliteus, ascends through the popliteal fossa to an aperture in the Adductor magnus, where it becomes the femoral vein. In the lower part of its course it is medial to the popliteal artery; between the heads of the Gastrocnemius it is superficial to it; above the knee-joint, it is posterolateral to it. Its tributaries are the small saphenous vein and the veins corresponding to the branches of the popliteal artery. There are usually four valves in the popliteal vein.

The **femoral vein** accompanies the femoral artery, beginning at the opening in the Adductor magnus, as a continuation of the popliteal vein, and ending at the level of the inguinal ligament, by becoming the external iliac vein. In the lower part of the adductor canal it is posterolateral to the femoral artery; in the upper part of the canal, and in the lower part of the femoral triangle, it is behind the artery. At the base of the femoral triangle it is medial to the artery (figs. 710, 711); here it occupies the middle compartment of the femoral sheath, and is placed between the femoral artery and the femoral canal. It receives numerous muscular tributaries, and about 4 cm. below the inguinal ligament is joined by the vena profunda femoris and a little higher by the great saphenous vein. It contains three valves.

CC-0. In Public Domain. Gurukul Kangri Collection, Haridwar

Digitized by Arya Samaj Foundation Chennai and eGangotri

The *vena profunda femoris* lies superficial to the arteria profunda femoris artery; it receives tributaries corresponding to the muscular and perforating branches of the artery, and through these establishes communications with the popliteal below and the inferior glutæal vein above. It also receives the medial and lateral femoral circumflex veins.

The Veins of the Abdomen and Pelvis (fig. 747)

The **external iliac vein**, the upward continuation of the femoral vein, begins behind the inguinal ligament, and ascends along the brim of the lesser pelvis, to a point opposite the sacro-iliac articulation, where it unites with the hypogastric vein to form the common iliac vein. On the right side, it lies at first medial to the artery; but, as it passes upwards, gradually inclines behind it. On the left side, it lies altogether on the medial side of the artery. It frequently contains one, sometimes two, valves.

Tributaries.—It receives the inferior epigastric, deep iliac circumflex, and pubic veins.

The **inferior epigastric vein** is formed by the union of the venæ comitantes of the inferior epigastric artery, which communicate above with the superior epigastric vein; it joins the external iliac vein about 1 cm. above the inguinal ligament.

The **deep iliac circumflex vein** is formed by the union of the venæ comitantes of the deep iliac circumflex artery, and joins the external iliac vein about 2 cm. above the inguinal ligament.

The **pubic vein** communicates with the obturator vein in the obturator foramen, ends on the pelvic surface of the os pubis alongside the pubic branch of the inferior epigastric artery and ends in the external iliac vein.

The **hypogastric or internal iliac vein** begins near the upper part of the greater sciatic foramen, ascends behind and slightly medial to the hypogastric artery, and, at the brim of the pelvis, joins with the external iliac vein to form the common iliac vein.

Tributaries.—With the exception of the fœtal umbilical vein, which passes towards and backwards from the umbilicus to the liver, and the iliolumbar vein, which usually joins the common iliac vein, the tributaries of the hypogastric vein correspond with the branches of the hypogastric artery. It receives (*a*) the glutæal, internal pudendal, and obturator veins, which have their origins outside the pelvis; (*b*) the lateral sacral veins, which lie in front of the sacrum; and (*c*) the middle hæmorrhoidal, the vesical, uterine, and vaginal veins, which originate in venous plexuses connected with the pelvic viscera.

1. The **superior glutæal veins** (glutæal veins) are the venæ comitantes of the superior glutæal artery; they receive tributaries from the buttock corresponding with the branches of the artery, enter the pelvis through the greater sciatic foramen, above the Piriformis, and end in the hypogastric vein; they frequently unite to form a single trunk before ending in this vein.

2. The **inferior glutæal veins** (sciatic veins) are the venæ comitantes of the inferior glutæal artery; they begin on the upper part of the back of the thigh, where they anastomose with the medial femoral circumflex and first perforating veins; they enter the pelvis through the lower part of the greater sciatic foramen and join to form a stem which opens into the lower part of the hypogastric vein.

3. The **internal pudendal veins** (internal pudic veins) are the venæ comitantes of the internal pudendal artery. They begin in the pudendal plexus, accompany the internal pudendal artery, and unite to form a single vessel, which ends in the hypogastric vein. They receive the veins from the urethral bulb, and the perinæal and inferior hæmorrhoidal veins. The deep dorsal vein of the penis and the dorsal vein of the clitoris communicate with the internal pudendal veins, but end mainly in the pudendal plexus.

4. The **obturator vein** begins in the upper portion of the adductor region of the thigh, and enters the pelvis through the upper part of the obturator foramen. It runs backwards and upwards on the lateral wall of the pelvis below the obturator artery and lateral to the peritoneum; it passes between the ureter and the hypogastric artery, and ends in the hypogastric vein. Sometimes it is replaced by an enlarged pubic vein which joins the external iliac vein.

5. The **lateral sacral veins** accompany the lateral sacral arteries and end in the hypogastric vein.

CC-0. In Public Domain. Gurukul Kangri Collection, Haridwar

Digitized by Arya Samaj Foundation Chennai and eGangotri

6. The **middle hæmorrhoidal vein** varies in size; it begins in the hæmorrhoidal plexus and receives tributaries from the bladder, prostate, and seminal vesicles; it runs lateralwards on the pelvic surface of the Levator ani and ends in the hypogastric vein.

The **hæmorrhoidal plexus** surrounds the rectum, and communicates in front with the vesical plexus in the male, and the uterovaginal plexus in the

FIG. 747.—The veins of the right half of the male pelvis. (Spalteholz.)

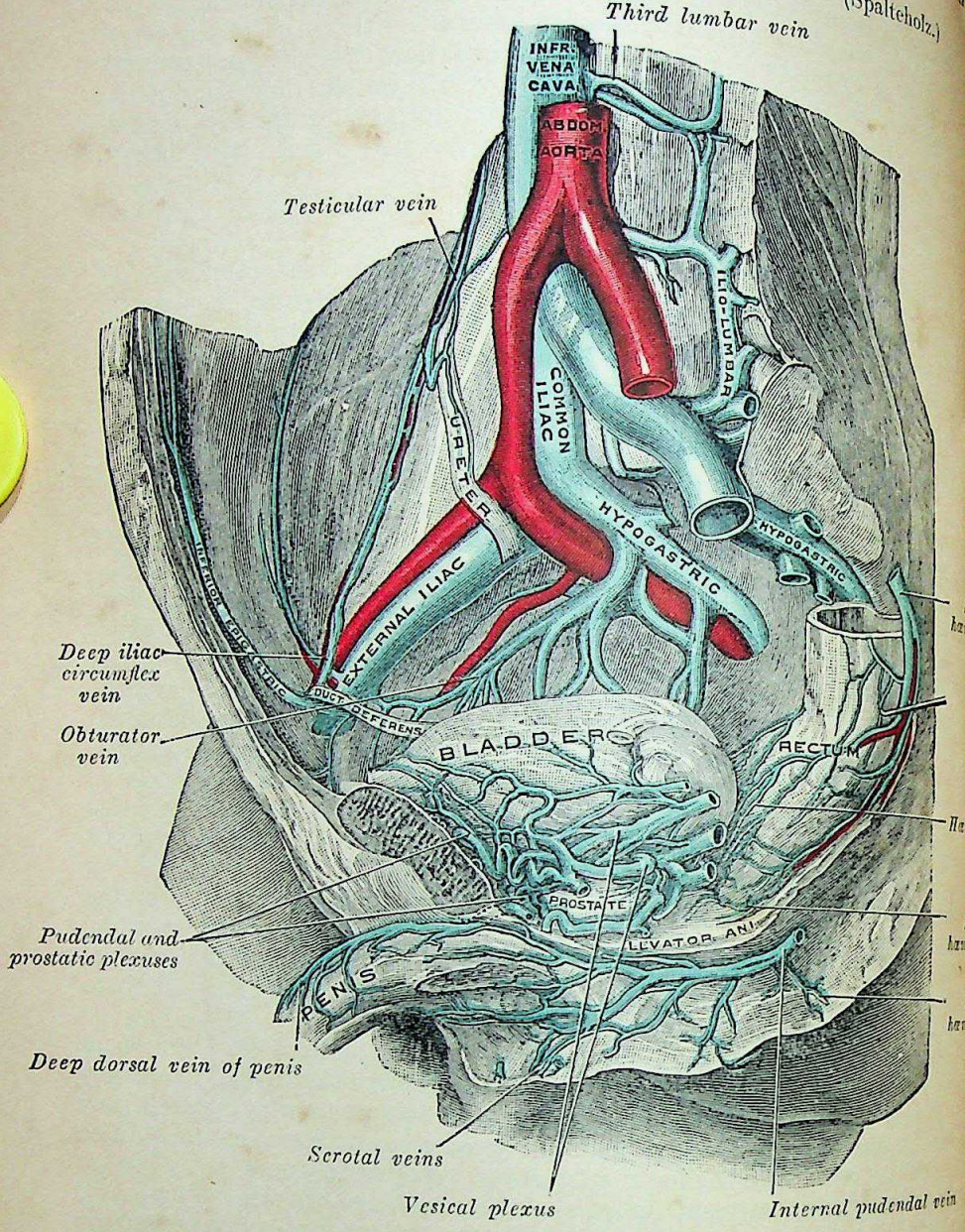

female. It consists of two parts, an *internal* in the submucosa, and an *external* outside the muscular coat of the rectum. The internal plexus presents a series of dilated pouches which are arranged in a circle around the tube, immediately above the anal orifice, and are connected by transverse branches: it drains mainly into the superior hæmorrhoidal vein. The lower part of the external plexus is drained by the inferior hæmorrhoidal veins into the internal pudendal vein; the middle part by the middle hæmorrhoidal vein into the hypogastric vein; and the upper part by the superior hæmorrhoidal vein which forms the commencement of the inferior mesenteric vein, a tributary of the portal vein. A free communication between the portal and systemic venous systems is established through the hæmorrhoidal plexus.

The **pudendal plexus** lies behind the arcuate pubic ligament and the lower part of the symphysis pubis, and in front of the bladder and prostate

CC-0. In Public Domain. Gurukul Kangri Collection, Haridwar

Digitized by Arya Samaj Foundation Chennai and eGangotri

The chief tributary is the deep dorsal vein of the penis, but it also receives branches from the front of the bladder and prostate. It communicates with the vesical plexus and with the internal pudendal vein, and drains into the veins and hypogastric veins. The *prostatic veins* form a well-marked *prostatic* plexus which lies partly in the fascial sheath of the prostate and partly between the sheath and the prostatic capsule; it communicates with the pudendal and vesical plexuses.

The **vesical plexus** envelops the lower part of the bladder and, in the male, the base of the prostate. It communicates with the pudendal plexus and in the male with the prostatic plexus, and in the female with the vaginal plexus. It is drained, by means of several vesical veins, into the hypogastric veins.

Applied Anatomy.—The veins of the hæmorrhoidal plexus are apt to become dilated and varicose, and form piles. This is due to several anatomical reasons: the vessels are contained in very loose connective tissue, so that they get less support from surrounding structures than most other veins, and are less capable of resisting increased blood-pressure; the condition is favoured by the fact that the superior hæmorrhoidal and portal veins have no valves; the veins pass through muscular tissue and are liable to be compressed by its contraction, especially during the act of defæcation; they are affected by any form of portal obstruction.

The prostatic plexus of veins is apt to become congested in inflammatory conditions in the neighbourhood such as acute gonorrhœal prostatitis. It is owing to the free communication which exists between this and the middle hæmorrhoidal plexus that great relief can be given by free saline purgation. Hæmorrhage may be very free from the prostatic plexus after operations on that gland, but can usually be checked by hot fluid injection.

The **dorsal veins of the penis** are two in number, a superficial and a deep. The *superficial dorsal vein* drains the prepuce and skin of the penis, and, running backwards in the subcutaneous tissue, inclines to the right or left, and opens into the corresponding superficial external pudendal vein, a tributary of the great saphenous vein. The *deep dorsal vein* lies within the fibrous envelope of the penis; it receives blood from the glans penis and corpora cavernosa penis, and courses backwards in the middle line between the dorsal arteries; near the root of the penis it passes between the two parts of the suspensory ligament and then through an aperture between the arcuate pubic ligament and the transverse ligament of the pelvis, and divides into two branches, which enter the pudendal plexus. It also communicates over the symphysis pubis with the internal pudendal vein. The *dorsal vein of the clitoris*, after a similar course to that of the deep dorsal vein of the penis, ends in the pudendal plexus.

The **uterine plexuses** lie along the sides and superior angles of the uterus between the two layers of the broad ligament, and communicate with the ovarian and vaginal plexuses. They are drained by a pair of uterine veins on either side; these arise from the lower parts of the plexuses, opposite the external orifice of the uterus, and open into the corresponding hypogastric vein.

The **vaginal plexuses** are placed at the sides of the vagina; they communicate with the uterine, vesical, and hæmorrhoidal plexuses, and are drained by the vaginal veins, one on either side, into the hypogastric veins.

The **common iliac veins** (fig. 747) are formed by the union of the external iliac and hypogastric veins, in front of the sacro-iliac articulation; passing upwards they end on the right side of the fifth lumbar vertebra by joining with each other at an acute angle to form the inferior vena cava. The *right common iliac vein*, shorter than the left, is nearly vertical in its direction, and ascends behind, and then lateral to its artery. The *left common iliac vein*, longer and more oblique than the right, is at first situated on the medial side of its artery, and then behind the right common iliac artery. Each common iliac vein receives the iliolumbar, and sometimes the lateral sacral veins; the right vein receives the middle sacral vein. There are no valves in these veins.

The **middle sacral veins** accompany the corresponding artery along the front of the sacrum, and join to form a single vein, which usually ends in the left common iliac vein, but sometimes in the angle of junction of the two common iliac veins.

Peculiarities.—The left common iliac vein, instead of joining with the right in its normal position, occasionally ascends on the left side of the aorta as high as the kidney, and, after receiving the left renal vein, it crosses the aorta and joins the right vein from the vena cava.

CC-0. In Public Domain. Gurukul Kangri Collection, Haridwar

Digitized by Arya Samaj Foundation Chennai and eGangotri

The **inferior vena cava** (figs. 695, 741) conveys the blood from the below the Diaphragm to the right atrium of the heart. It is formed by the junction of the two common iliac veins, in front of the body of the fifth lumbar vertebra, a little to the right of the middle line. It ascends in front of the vertebral column, on the right side of the aorta, and, having reached the liver, is contained in a deep groove on its posterior surface—a groove which is occasionally converted into a tunnel by a band of liver substance. It then perforates the Diaphragm between the median and right portions of its central tendon; it subsequently inclines forwards and medialwards for about 2 cm., and, piercing the fibrous pericardium, passes behind the serous pericardium to open into the lower and posterior part of the right atrium. In front and to the left of its atrial orifice is a semilunar valve, termed the *valve of the inferior vena cava* (Eustachian valve); this valve is rudimentary in the adult, but of large size and exercises an important function in the fœtus (p. 594). The trunk of the inferior vena cava is devoid of valves.

Relations.—The *abdominal portion* of the inferior vena cava is in relation *in front* with the right common iliac artery, the lower part of the mesentery and its vessels, the right testicular artery, the inferior part of the duodenum, the head of the pancreas, the portal vein, the superior portion of the duodenum, the epiploic foramen, and the posterior surface of the liver; *behind*, with the bodies of the lumbar vertebræ and the anterior longitudinal ligament, the right Psoas muscle, the right crus of the Diaphragm, the right inferior phrenic, suprarenal, renal and lumbar arteries, right sympathetic trunk and right cœliac ganglion, and the medial part of the right suprarenal gland; on the *right side*, with the right kidney and ureter; on the *left side*, with the aorta, right crus of the Diaphragm, and the caudate lobe of the liver.

The *thoracic portion* is only about 2 cm. in length, and is situated partly within and partly outside the pericardial sac. The *extrapericardial part* is separated from the right pleura and lung by a fibrous band, named the *right phrenicopericardiac ligament*. This ligament, often feebly marked, is attached below to the margin of the vena-caval opening in the Diaphragm and above to the pericardium in front of the root of the right lung. The *intrapericardiac part* is very short and is covered on the front and sides by the serous layer of the pericardium.

Peculiarities.—This vessel is sometimes placed on the left side of the aorta, as high as the left renal vein, and, after receiving this vein, crosses over to its usual position on the right side; or it may be placed altogether on the left side of the aorta, and in such a case the abdominal and the thoracic viscera, together with the great vessels, are transposed. Occasionally it joins the azygos vein, which is then of large size. In such cases, the superior vena cava receives the whole of the blood from the body, except that from the hepatic veins, which passes directly into the right atrium.

Applied Anatomy.—Thrombosis of the inferior vena cava is due to much the same causes as that of the superior (p. 732). It usually causes œdema of the legs and trunk without ascites; if the renal veins are involved, blood and albumin will often appear in the urine. An extensive collateral venous circulation is soon established by enlargement either of the superficial or of the deep veins, or of both. In the first case the epigastric, the iliac circumflex, the lateral thoracic, the internal mammary, the intercostals, the external pudendal, and the lumbovertebral anastomotic veins of Braune effect a communication with the superior cava; in the second, the deep anastomosis is made by the azygos and hemiazygos and the lumbar veins.*

Tributaries.—In addition to the two common iliac veins the inferior vena cava receives the following veins:

Lumbar.	Renal.	Right inferior phrenic.
Right testicular or ovarian.	Right suprarenal.	Hepatic.

The **lumbar veins**, four in number on either side, collect the blood by direct tributaries from the muscles and skin of the loins, and by abdominal tributaries from the walls of the abdomen, where they communicate with the epigastric veins. At the vertebral column, they receive veins from the vertebral plexus, behind and then pass forwards on the sides of the bodies of the vertebræ, behind the Psoas major, and end in the posterior part of the inferior vena cava. The left lumbar veins are longer than the right, and run behind the aorta. The lumbar veins are connected together by a longitudinal vein which passes

* G. Blumer, in Osler and McCrae's System of Medicine, London, 1908, vol. iv.

CC-0. In Public Domain. Gurukul Kangri Collection, Haridwar

Digitized by Arya Samaj Foundation Chennai and eGangotri

of the transverse processes of the lumbar vertebræ, and is called the ending *lumbar vein*; it forms the most frequent origin of the corresponding azygos or hemiazygos vein, and serves to connect the common iliac, iliolumbar, azygos or hemiazygos veins of its own side of the body.

The **testicular veins** (spermatic veins) (fig. 695) emerge from the back the testis, and receive tributaries from the epididymis; they unite and form convoluted plexus, called the *pampiniform plexus* which constitutes the greater mass of the spermatic cord and ascends along the cord, in front of the ductus deferens. Below the subcutaneous inguinal ring the veins of the plexus unite to form three or four veins, which pass along the inguinal canal, and, entering the abdomen through the abdominal inguinal ring, coalesce to form two veins, which run upwards in front of the Psoas major and the ureter, behind the peritoneum, lying one on either side of the testicular artery. These two veins join to form a single vessel, which opens on the right side into the inferior vena cava at an acute angle; on the left side into the left renal vein at a right angle. The testicular veins are provided with valves.* The left vein passes behind the iliac part of the descending colon and the lower margin of the pancreas, the right behind the terminal part of the ileum and the inferior part of the duodenum.

Applied Anatomy.—The testicular veins are very frequently varicose, constituting the condition known as *varicocele*. Varicocele almost invariably occurs on the left side, and this has been accounted for by the facts that the left testicular vein joins the left renal at a right angle; that it is overlaid by the iliac part of the descending colon, and that when this portion of the gut is full of fæcal matter, in cases of constipation, its weight impedes the return of the venous blood.

The operation for the removal of a varicocele consists in making a small incision just over the subcutaneous inguinal ring; the cord is lifted out and the spermatic fasciæ opened; the plexus of veins is then isolated from the ductus deferens and ligatured above and below, as high and as low as possible, and the intermediate portion cut away; the cut ends are fixed together with a suture, and the skin wound closed. The venous return is subsequently carried out by the small veins of the ductus deferens, of the epididymis and those connecting with the scrotal tissues. In removing a varicocele the testicular artery is generally removed at the same time.

The **ovarian veins** in the female correspond with the testicular veins in the male; each forms a plexus between the layers of the broad ligament near the ovary and uterine tube, and communicates with the uterine plexus. Two veins arise from this plexus and ascend in front of the external iliac artery, one lying on either side of the ovarian artery. Their further course and their mode of termination are the same as those of the testicular veins. Valves are occasionally found in the ovarian veins. Like the uterine veins, they become much enlarged during pregnancy.

The **renal veins**, of large size, are placed in front of the renal arteries, and almost at right angles to the inferior vena cava. The left is thrice the length of the right (7·5 cm. to 2·5 cm.), and passes in front of the aorta, just below the origin of the superior mesenteric artery. It receives the left testicular (ovarian) vein, and one of the left inferior phrenic veins, and, generally, the left suprarenal vein. It opens into the inferior vena cava at a slightly higher level than the right.

The **suprarenal veins** are two in number: the right ends in the inferior vena cava; the left usually in the left renal.

The **inferior phrenic veins** follow the course of the inferior phrenic arteries on the Diaphragm; the right ends in the inferior vena cava; the left is often represented by two branches, one of which ends in the left renal or suprarenal vein, while the other passes in front of the œsophageal hiatus of the Diaphragm and opens into the inferior vena cava.

The **hepatic veins** drain the liver, and commence in the *intralobular veins* which receive the blood from the sinusoids of the liver lobules. The intralobular veins open into the *sublobular veins*, and these in turn unite to form the hepatic veins which open into that portion of the inferior vena cava which

* Rivington has pointed out that valves are usually found at the orifices of both the right and left testicular veins. When, however, valves are not found at the opening of the left testicular vein into the left renal vein, they are generally present in the left testicular vein within 6 mm. from the orifice of the testicular vein. *Journal of Anatomy and Physiology*, vol. vii. p. 163.

CC-0. In Public Domain. Gurukul Kangri Collection, Haridwar

Digitized by Arya Samaj Foundation Chennai and eGangotri

lies in the groove on the posterior surface of the liver. The hepatic are arranged in two groups, upper and lower. The *upper group* usually of three large veins, right, left and middle, the last emerging from the lobe; those of the *lower group* vary in number; they are of small size come from the right and caudate lobes. The hepatic veins are in direct with the hepatic tissue and are destitute of valves.

The Portal System of Veins (fig. 748)

The portal system includes all the veins which drain the blood from abdominal part of the digestive tube (with the exception of the lower of the rectum) and from the spleen, pancreas, and gall-bladder. From viscera the blood is conveyed to the liver by the *portal vein*. In the liver vein ramifies like an artery and ends in capillary-like vessels termed sin from which the blood is conveyed to the inferior vena cava by the veins. The blood of the portal system therefore passes through two minute vessels, viz. (*a*) the capillaries of the digestive tube, spleen, and gall bladder; and (*b*) the sinusoids of the liver. In the adult the vein and its tributaries are destitute of valves; in the fœtus and for a time after birth valves can be demonstrated in the tributaries of the vein; as a rule they atrophy and disappear, but sometimes persist degenerate form.

The **portal vein** is about 8 cm. long, and is formed at the level of second lumbar vertebra by the junction of the superior mesenteric and (splenic) veins, the union of these veins taking place in front of the vena cava and behind the neck of the pancreas. It passes upwards be the superior part of the duodenum, and then ascends in the right border of lesser omentum to the right extremity of the porta hepatis (transverse of the liver), where it divides into a right and a left branch, which accom the corresponding branches of the hepatic artery into the substance of liver. In the lesser omentum it is placed behind and between the bile and the hepatic artery, the former lying to the right of the latter; it is rounded by the hepatic plexus of nerves, and is accompanied by numer lymphatic vessels and some lymph-glands. The *right branch* of the vein enters the right lobe of the liver, but before doing so generally receives the cystic vein. The *left branch*, longer but of smaller calibre than the right gives branches to the caudate and quadrate lobes, crosses the left sagittal fossa (longitudinal fissure), and then enters the left lobe of the liver. As it cross the left sagittal fossa it is joined in front by the para-umbilical veins (p. 745) and by a fibrous cord, the *ligamentum teres* or *obliterated umbilical vein*, and is united behind to the inferior vena cava by a second fibrous cord, the *ligamentum venosum* or *obliterated ductus venosus*.

The tributaries of the portal vein are:

1. Lienal (Splenic).
2. Superior mesenteric.
3. Coronary.
4. Right gastric.
5. Cystic.
6. Para-umbilical.

1. The **lienal or splenic vein** (fig. 748) is of large size, but is not tortuous like the artery; it commences by five or six branches which return the blood from the spleen. These unite to form a single vessel, which passes from left to right, grooving the upper part of the posterior surface of the pancreas, below the lienal artery, and ends behind the neck of the pancreas by uniting at right angle with the superior mesenteric vein, to form the portal vein.

Tributaries.—It receives the short gastric veins, the left gastro-epiploic vein, the pancreatic veins, and the inferior mesenteric vein.

(*a*) The **short gastric veins**, four or five in number, drain the fundus and part of the greater curvature of the stomach, and pass between the two layers of the gastrolienal ligament to end in the lienal vein or in one of its large tributaries.

(*b*) The **left gastro-epiploic vein** receives branches from the surfaces of the stomach and from the greater omentum; it runs from right to left along the greater curvature of the stomach and ends in the commencement of the lienal vein.

(*c*) The **pancreatic veins** are several small vessels which drain the body and tail of the pancreas.

CC-0. In Public Domain. Gurukul Kangri Collection, Haridwar

Digitized by Arya Samaj Foundation Chennai and eGangotri

(d) The **inferior mesenteric vein** returns blood from the rectum, and from the ...nd and descending parts of the colon. It begins in the rectum as the *superior ...rrhoidal vein*, which has its origin in the hæmorrhoidal plexus (p. 738), and ...gh this plexus communicates with the middle and inferior hæmorrhoidal ... The superior hæmorrhoidal vein leaves the lesser pelvis, crosses the left ...mon iliac vessels with the superior hæmorrhoidal artery, and is continued

Fig. 748.—The portal vein and its tributaries.

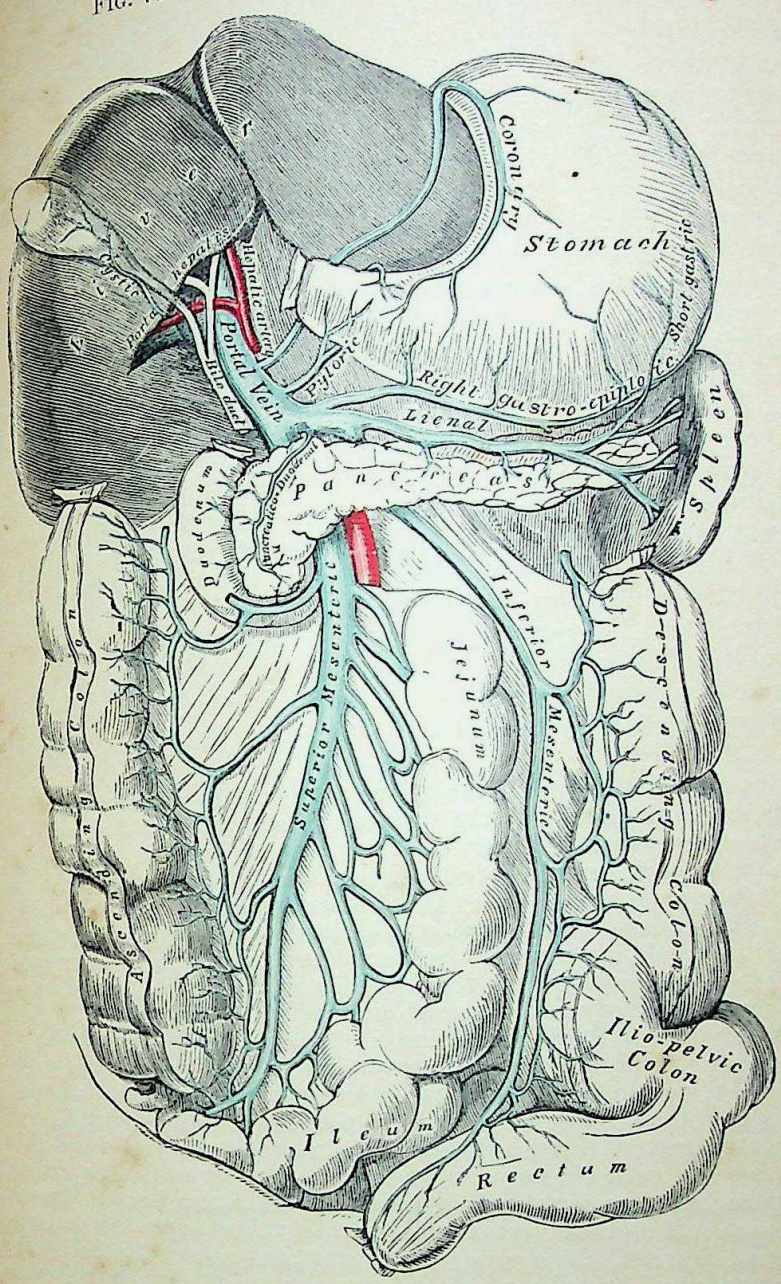

...wards as the inferior mesenteric vein. This vein lies to the left of its artery ...d ascends behind the peritoneum and in front of the left Psoas major; it then ...sses behind the body of the pancreas and opens into the lienal vein; sometimes ...ends in the angle of union of the lienal and superior mesenteric veins.

If a superior duodenal fossa be present the inferior mesenteric vein frequently ...s between the layers of the fold of peritoneum (superior duodenal fold) which ...rms the anterior wall of the fossa.

Tributaries.—The inferior mesenteric vein receives the sigmoid veins from the sigmoid ...on, and the left colic vein from the descending colon and left colic flexure.

2. The **superior mesenteric vein** (fig. 748) returns the blood from the ...all intestine, from the caecum, and from the ascending and transverse portions

CC-0. In Public Domain. Gurukul Kangri Collection, Haridwar

Digitized by Arya Samaj Foundation Chennai and eGangotri

of the colon. It begins in the right iliac fossa by the union of the veins which drain the terminal part of the ileum, the cæcum and vermiform process; it ascends between the two layers of the mesentery on the right side of the superior mesenteric artery, and in its upward course passes in front of the right ureter, the inferior vena cava, the horizontal part of the duodenum, and the pancreas; it passes behind the neck of the pancreas, behind the uncinatus of the head of the pancreas. Behind the neck of the pancreas it unites with the lienal vein to form the portal vein.

Tributaries.—The superior mesenteric vein receives the veins which correspond with the branches of the superior mesenteric artery, viz. the jejunal, ileal, ileo-colic, right colic, and middle colic veins; it is also joined by the right gastro-epiploic and the pancreaticoduodenal veins.

The **right gastro-epiploic vein** receives branches from the greater omentum and from the lower part of the stomach; it runs from left to right along the greater curvature of the stomach, between the two layers of the greater omentum.

The **pancreaticoduodenal veins** accompany their corresponding arteries; the lower one frequently joins the right gastro-epiploic vein.

3. The **coronary vein** derives tributaries from both surfaces of the stomach; it runs from right to left along the lesser curvature of the stomach between the two layers of the lesser omentum, to the œsophageal opening of the stomach, where it receives some œsophageal veins. It then turns backwards and passes from left to right behind the omental bursa, and ends in the portal vein.

4. The **right gastric vein** (pyloric vein), of small size, runs from left to right along the pyloric portion of the lesser curvature of the stomach between the two layers of the lesser omentum, and ends in the portal vein.

5. The **cystic vein** drains the blood from the gall-bladder; it accompanies the cystic duct, and usually ends in the right branch of the portal vein.

6. **Para-umbilical veins.**—In the course of the ligamentum teres of the liver and of the middle umbilical ligament, small veins (para-umbilical) are found, which establish an anastomosis between the veins of the anterior abdominal wall and the portal, hypogastric, and iliac veins. The best marked of these small veins is one which begins at the umbilicus and runs backwards and upwards in, or on the surface of, the ligamentum teres between the layers of the falciform ligament, to end in the left branch of the portal vein.

Applied Anatomy.—Obstruction to the portal vein may produce ascites, and this may arise from many causes, e.g. (1) the pressure of a tumour on the portal vein, such as cancer or hydatid cyst in the liver, enlarged lymph-glands in the lesser omentum, or cancer of the head of the pancreas; (2) from cirrhosis of the liver, when the radicles of the portal vein are pressed upon by the contracting fibrous tissue in the portal canals; (3) from valvular disease of the heart, and back pressure on the hepatic veins, and so on the whole of the circulation through the liver. In this condition the prognosis as regards life and freedom from ascites may be much improved by the establishment of a good collateral circulation between the portal and systemic veins. This is effected by communications between (*a*) the gastric veins, and the œsophageal veins which often project as a varicose bunch into the stomach, emptying themselves into the hemiazygos vein; (*b*) the veins of the colon and duodenum, and the left renal vein; (*c*) the accessory portal system of Sappey, branches of which pass in the round and falciform ligaments (particularly the latter) to unite with the epigastric and internal mammary veins, and through the diaphragmatic veins with the azygos; a single large vein, shown to be a para-umbilical vein, may pass from the hilum of the liver by the round ligament to the umbilicus, producing there a bunch of prominent varicose veins known as the *caput Medusæ*; (*d*) the veins of Retzius, which connect the intestinal veins with the inferior vena cava and its retroperitoneal branches; (*e*) the superior, middle and inferior hæmorrhoidal; (*f*) very rarely the ductus venosus remains patent, affording a direct connexion between the portal vein and the inferior vena cava.

An operation for the relief of portal obstruction by increasing the number of venous communications has been advocated by Rutherford Morison and by Talma. It consists in roughening the opposed surfaces of the liver and Diaphragm and stitching them together so as to secure vascular inflammatory adhesions between the two. The greater omentum may with advantage be interposed between them, so as to increase the amount of adhesions.

Thrombosis of the portal vein is a very serious event, and is oftenest due to pathological processes causing compression of the vessel or injury to its wall, such as tumours or inflammation about the pylorus or head of the pancreas, or to gall-stones, or cirrhosis of the liver.

Thrombosis of the mesenteric veins produces very acute symptoms, similar to those of embolism of the mesenteric arteries (p. 673).

CC-0. In Public Domain. Gurukul Kangri Collection, Haridwar

Digitized by Arya Samaj Foundation Chennai and eGangotri

infective emboli lodging in the portal venules give rise to a condition known as *septic* or *suppurative pylephlebitis* or, more shortly, *portal pyæmia*. They occur most often in those of the ileocolic radicles, and are due to appendicitis, but the infection may arise from anywhere in the portal system (e.g. the superior hæmorrhoidal radicles). Fragments of infected clot break off from the original thrombus and lodge in the smaller veins of the liver, causing the development of multiple abscesses in its substance, and a rapidly fatal result. A similar path of infection is taken by the *entamœba histolytica* of dysentery, when it passes into the liver and produces *tropical abscess*.

THE LYMPHATIC SYSTEM

The lymphatic system includes the lymphatic vessels and lymph-glands. The lymphatic vessels form a closed system of vessels and contain a transparent fluid called *lymph* (p. 29). The lymphatic vessels of the small intestine receive the special designation of *lacteals* or *chyliferous vessels*; they differ in no respect from the lymphatic vessels generally, excepting that during the process of absorption of a fatty meal they contain a milk-white fluid, the *chyle*. In most of the tissues of the body there are minute spaces which contain a fluid resembling lymph, and formed by transudation from the blood-capillaries, but these spaces in the tissues are not continuous with the lymphatic vessels. "The lymphatics are concerned with the absorption of solids, and of material insoluble in water; the blood capillaries, on the other hand, are mainly associated with the absorption of material which is soluble in water." *

Fig. 749.—A small lymphatic vessel, from the diaphragm of a rabbit. Silvered. × 65.

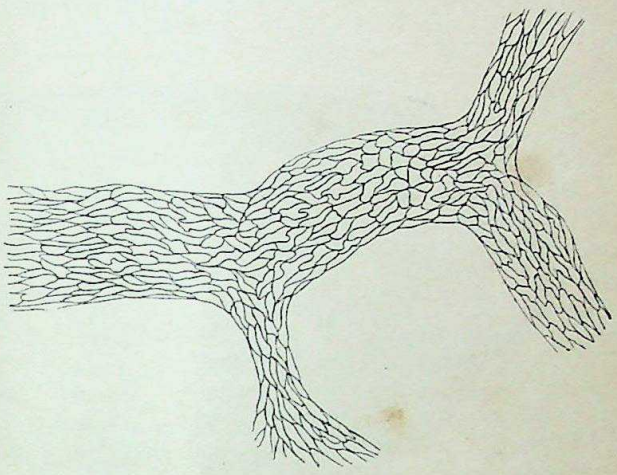

The **lymphatic vessels** are exceedingly delicate, and their coats so transparent that the fluid they contain is readily seen through them. They are constricted at intervals and so present a knotted or beaded appearance; these constrictions correspond to the attachments of valves in the interior of the vessels. The lymphatic vessels unite with one another, and ultimately form two main channels, the *thoracic duct* and the *right lymphatic duct* which open into veins at the root of the neck. Lymphatic vessels have been found in nearly every texture and organ of the body which contains blood-vessels; they are absent from the central nervous system, and from non-vascular structures such as cartilage, nails, cuticle, and hair. "In an organ like the liver they are confined to the connective tissue of the capsule and of the portal spaces."

The structure of the lymphatic vessels.—The larger lymphatic vessels are each composed of three coats. The *internal* coat is thin, transparent, slightly elastic, and consists of a layer of elongated endothelial cells supported on an elastic membrane; the cells have wavy margins by which the contiguous cells are dovetailed into one another. The *middle* coat is composed of smooth muscular, and fine elastic fibres, disposed in a transverse direction. The *external* coat consists of connective tissue, intermixed with smooth muscular fibres longitudinally or obliquely disposed; it forms a protective covering to the other coats, and serves to connect the vessel with the neighbouring structures. In the smaller vessels there are no muscular or elastic fibres, and the wall consists only of a connective tissue coat lined by endothelium (fig. 749). The thoracic duct has a more complex structure than the other lymphatic vessels; it presents a distinct subendothelial layer, similar to that found in the arteries; in the middle coat there is, in addition to the muscular and elastic fibres, a layer of connective tissue with its fibres arranged longitudinally. The

* P. T. Herring and J. C. Macnaughton, *The Lancet*, June 3rd, 1922.

CC-0. In Public Domain. Gurukul Kangri Collection, Haridwar

Digitized by Arya Samaj Foundation Chennai and eGangotri

larger lymphatic vessels are supplied by nutrient vessels, which are distri[illegible] their outer and middle coats; and here also have been traced many non-me[illegible] nerves in the form of fine plexuses.

In the lymphatic vessels the valves are placed at much shorter interval[illegible] in the veins. They are most numerous near the lymph-glands, and are fo[illegible] frequently in the lymphatic vessels of the neck and upper extremity than [illegible] of the lower extremity; they are wanting in the vessels composing the p[illegible] network in which the lymphatic vessels usually originate on the surface of th[illegible] The valves are formed of thin layers of fibrous tissue covered on both sur[illegible] endothelium which presents the same arrangement as on the valves of veins [illegible] They are semilunar in form, and are attached by their convex edges to th[illegible] of the vessel, the concave edges being free and directed along the course [illegible] lymph-current. Usually two valves, of equal size, are found opposite one a[illegible] but occasionally exceptions occur, especially at or near the anastomoses of lym[illegible] vessels; thus, one valve may be of small size and the other increased in pro[illegible] The wall of a lymphatic vessel immediately above the attachment of each [illegible] of a valve is expanded into a pouch or sinus which gives the vessel, when dis[illegible] the knotted or beaded appearance already referred to.

FIG. 750.—A section through a lymph-gland of a cat. Stained with hæmatoxy[illegible] and eosin. × 15.

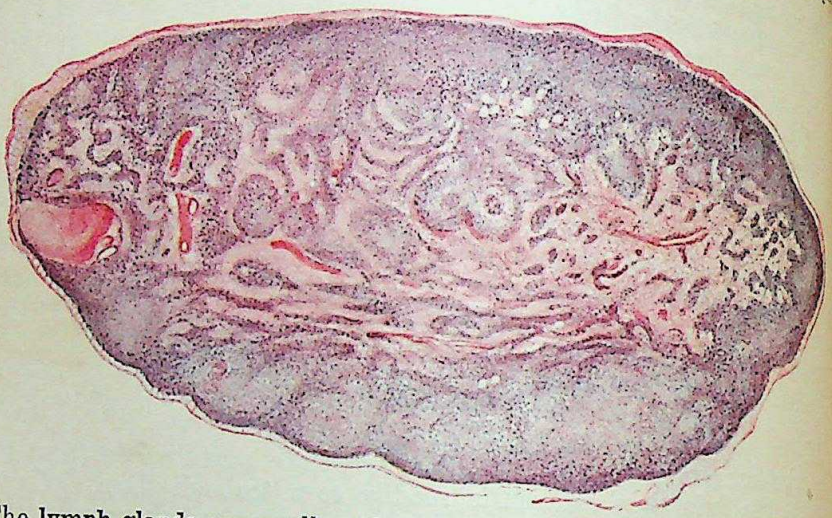

The **lymph-glands** are small oval or bean-shaped bodies, situated in the cou[illegible] of lymphatic and lacteal vessels so that the lymph and chyle pass through them [illegible] their way to the blood. Each generally presents on one side a slight depressi[illegible] the *hilum*, through which the blood-vessels enter and leave the gland. The effe[illegible] lymphatic vessel also emerges from the gland at this spot, while the afferent ves[illegible] enter it at different parts of the periphery. On section (fig. 750), a lymph-gl[illegible] displays two different structures: an external, of lighter colour—the *cortex*[illegible] and an internal, darker—the *medullary*. The cortical structure does not form [illegible] complete investment, but is deficient at the hilum, where the medullary portio[illegible] reaches the surface of the gland; so that the efferent lymphatic vessel is deri[illegible] directly from the medullary structure, while the afferent vessels empty themse[illegible] into the cortical substance.

The **structure of the lymph-glands** (figs. 750, 751). A lymph-gland consists [illegible] (1) a fibrous envelope, or *capsule*, from which a framework of processes (*trabec*[illegible] proceeds inwards, imperfectly dividing the gland into open spaces freely co[illegible] municating with each other; (2) a quantity of lymphoid tissue occupying th[illegible] spaces without completely filling them; (3) a free supply of blood-vessels, whi[illegible] are supported in the trabeculæ; and (4) the *afferent* and *efferent lymphatic* vess[illegible] communicating through the lymph-paths in the substance of the gland. The nerv[illegible] passing into the hilum are few in number and are chiefly distributed to the blood[illegible] vessels supplying the gland.

In man the *capsule* and *trabeculæ* are composed of connective tissue with so[illegible] plain muscular fibres, but in many of the lower animals they consist almo[illegible] entirely of the latter. The trabeculæ pass inwards towards the centre of th[illegible]

CC-0. In Public Domain. Gurukul Kangri Collection, Haridwar

Digitized by Arya Samaj Foundation Chennai and eGangotri

...for about one-third or one-fourth of the distance between the circumference and the centre of the gland. In some animals they are sufficiently well marked to divide the peripheral or cortical portion of the gland into a number of compart-, but in man this arrangement is not obvious. The larger trabeculæ springing the capsule break up into finer bands, and these interlace to form a meshwork the central or medullary portion of the gland. The gland-pulp or lymphoid tissue arranged in masses in the cortex of the gland, but in the medulla these masses into cords which alternate with bands derived from the trabeculæ. The capsule and the trabeculæ are everywhere separated from the lymphoid tissue a *lymph-path* or *lymph-sinus* which is bridged by a network of retiform tissue fig. 751) and is continuous throughout the gland.

FIG. 751.—Retiform and adenoid tissue, from a lymph-gland. × 255.

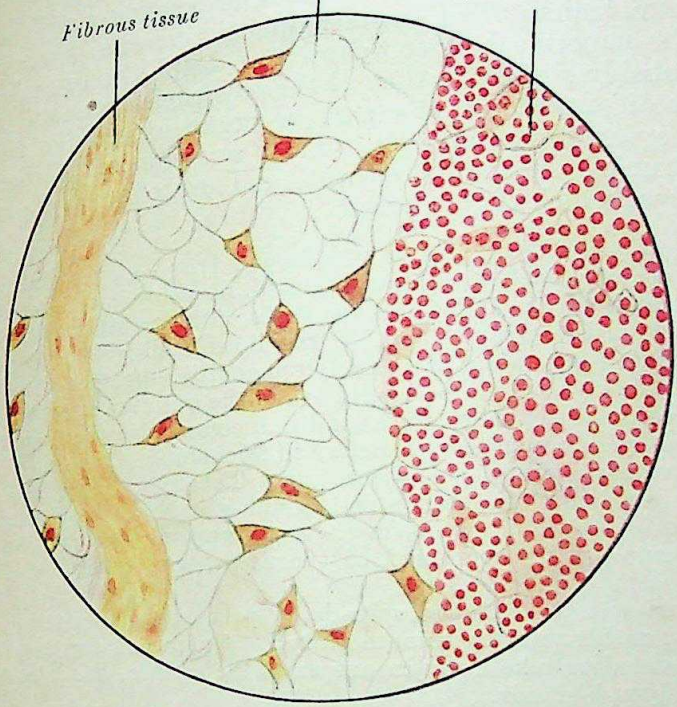

The gland-pulp consists of ordinary lymphoid tissue (fig. 751), being made up a delicate network of retiform tissue packed with lymphocytes. The network the gland-pulp is continuous with that in the lymph-paths, but marked off from by a closer reticulation ; moreover, the fibres of the retiform tissue of the lymph- are continuous with those of the trabeculæ. The gland-pulp is traversed by dense plexus of capillary blood-vessels. The nodules or follicles in the cortical ion of the gland frequently show areas where karyokinetic figures indicate a sion of the lymph-corpuscles. These areas are termed *germ-centres*. The tively dividing cells have more abundant protoplasm than those which are not dergoing division, and consequently in stained sections the germ-centres appear ker than the surrounding gland-pulp.

The *afferent vessels*, as stated above, enter at different parts of the periphery of gland, and after branching and forming a dense plexus in the substance of the sule, open into the lymph-sinuses of the cortical part. In doing this they lose their coats except their endothelial lining, which is continuous with a layer of ilar cells lining the lymph-paths. The *efferent vessel* commences from the mph-sinuses of the medullary portion. The stream of lymph carried to the gland the afferent vessels thus passes through the plexus in the capsule to the lymph- ths of the cortical portion, where it is exposed to the action of the gland-pulp ; ving through these it enters the paths or sinuses of the medullary portion, and ally emerges from the hilum by means of the efferent vessel. The stream of mph in its passage through the lymph-sinuses is much retarded by the presence

CC-0. In Public Domain. Gurukul Kangri Collection, Haridwar

Digitized by Arya Samaj Foundation Chennai and eGangotri

of the reticulum, hence morphological elements, either normal or morbid, easily arrested and deposited in the sinuses. Many lymph-corpuscles pass out by the efferent lymph-stream to join the general blood-stream. The arteries of the gland enter at the hilum, and go to the gland-pulp, to break up into a capillary plexus either directly or after running in the trabeculæ for a certain distance. The veins emerge from the gland at the hilum.

The lymphatic vessels are arranged into a superficial and a deep set. The superficial lymphatic vessels are placed immediately beneath the skin and accompany the superficial veins; they join the deep lymphatic vessels in certain situations. In the interior of the body they are found in the submucous areolar tissue throughout the whole length of the digestive, respiratory and genito-urinary tracts; and in the subserous tissue of the thoracic and abdominal walls. Networks of minute lymphatic vessels are found interspersed among the elements and blood-vessels of the several tissues; the vessels composing the network as well as the meshes between them are much larger than those of the capillary plexus. From these networks the vessels emerge, which pass, either to a neighbouring gland, or to join a larger lymphatic trunk. The *deep* lymphatic vessels, fewer in number, larger than the superficial, accompany the deep blood-vessels. Their mode of origin is probably similar to that of the superficial vessels.

The lymphatic vessels of any part or organ exceed the veins in number, but in size they are much smaller. Their anastomoses also, especially those of the large trunks, are more frequent, and are effected by vessels equal in diameter to those which they connect.

Applied Anatomy.—The lymphatic vessels and lymph-glands draining any infected area of the body are very liable to become inflamed, resulting in acute or chronic lymphangitis and lymphadenitis. In acute cases the paths of the superficial lymphatic vessels are often marked out on the skin by painful, red lines leading to tender, swollen lymph-glands, which may suppurate. Chronic lymphangitis, together with the blocking of numerous lymphatic vessels by the escaped ova of the minute parasitic worm *Microfilaria nocturna*, is the cause of elephantiasis, a condition common in the tropics and subtropics and characterised by enormous enlargement and thickening of the skin of some part of the body, most frequently of the leg and scrotum. Tuberculous, syphilitic and cancerous enlargements of the lymphatic vessels and lymph-glands are very commonly met with. Primary tumours of the lymphatic vessels are lymphangioma and endotheliomata; the so-called 'congenital cystic hygroma' of the neck, arm, trunk, or thigh, is a cystic lymphangioma.

The present view is that cancer spreads by permeating the lymphatic vessels as a solid cell-growth, rather than by minute emboli. Operations for the removal of cancer are therefore planned to take away in one mass the cancer, the intervening lymphatic vessels, and the lymph-glands.

The appearance of secondary malignant deposits or of secondary infection in parts of the body that seem not to be directly associated by any lymphatic connexion with the seat of the primary growth or infection has often been observed, and explained as due to 'retrograde transport' of cancer-cells or bacteria by a reversed flow of lymph. Weleminsky,* however, believes that the explanation is to be found in the fact that when the infected lymph-glands have grown to a certain size they no longer permit the normal flow of lymph through them, and that under these circumstances very delicate lymphatic connexions, whose existence normally remains unsuspected, develop to a surprising extent between groups of lymph-glands that at first sight appear to be unconnected with one another.

The Thoracic Duct

The thoracic duct (fig. 752) conveys the chyle and the greater part of the lymph into the blood. It is the common trunk of all the lymphatic vessels of the body, excepting those of the right side of the head, neck, and thorax, of the wall, the right upper extremity, right lung, right side of the heart, and part of the convex surface of the liver. In the adult it varies in length from 38 cm. to 45 cm. and extends from the second lumbar vertebra to the root of the neck. It begins in a dilatation, the *cisterna chyli*, which is from 5 cm. to 7 cm. long, and is situated on the front of the bodies of the first and second lumbar vertebræ, to the right side of and behind the aorta, by the side of the right crus of the Diaphragm. It enters the thorax through the aortic

* *Berliner Klinische Wochenschrift*, 1906, No. 24, p. 743.

CC-0. In Public Domain. Gurukul Kangri Collection, Haridwar

Digitized by Arya Samaj Foundation Chennai and eGangotri

tions of the Diaphragm, and ascends through the posterior mediastinal cavity with the aorta on its left and the azygos vein on its right side. Behind it in this region are the vertebral column and anterior longitudinal ligament, the right intercostal arteries, and the terminal accessory hemiazygos veins. In front of it are the Diaphragm, œsophagus, and pericardium, the last being separated from it by a recess of the right pleural cavity. Opposite the fifth thoracic vertebra, it inclines towards the left side, enters the superior mediastinal cavity, and descends on the right side of the aortic arch and behind the thoracic part of the left subclavian artery and between the left side of the œsophagus and the left pleura, to the upper orifice of the thorax. Passing into the neck it forms an arch which rises about 3 cm. or 1 cm. above the clavicle and turns forwards anterior to the first part of the subclavian artery, the vertebral artery and vein, and the thyreocervical trunk or its branches. It also passes in front of the phrenic nerve and the medial border of the Scalenus anterior, but is separated from these two structures by the prevertebral fascia. In front of it are the left common carotid artery, vagus nerve, and internal jugular vein. It ends by opening into the angle of junction of the left subclavian vein with the left internal jugular vein. The thoracic duct, at its commencement, is about equal in diameter to a goose-quill, but it diminishes considerably in calibre in the middle of the thorax, and is again slightly dilated just before its termination. It is generally flexuous, and constricted at intervals so as to present a varicose appearance. Not infrequently it divides in the middle of its course into two vessels of unequal size which soon reunite, or into several branches which form a plexiform interlacement. It occasionally divides at its upper part into two branches, right and left; the left ending in the usual manner, while the right opens into the right subclavian vein, in connexion with the right lymphatic duct. The thoracic duct has several valves; at its termination it is provided with a pair, the free borders of which are turned towards the vein, so as to prevent the passage of venous blood into the duct.

FIG. 752.—The thoracic and right lymphatic ducts.

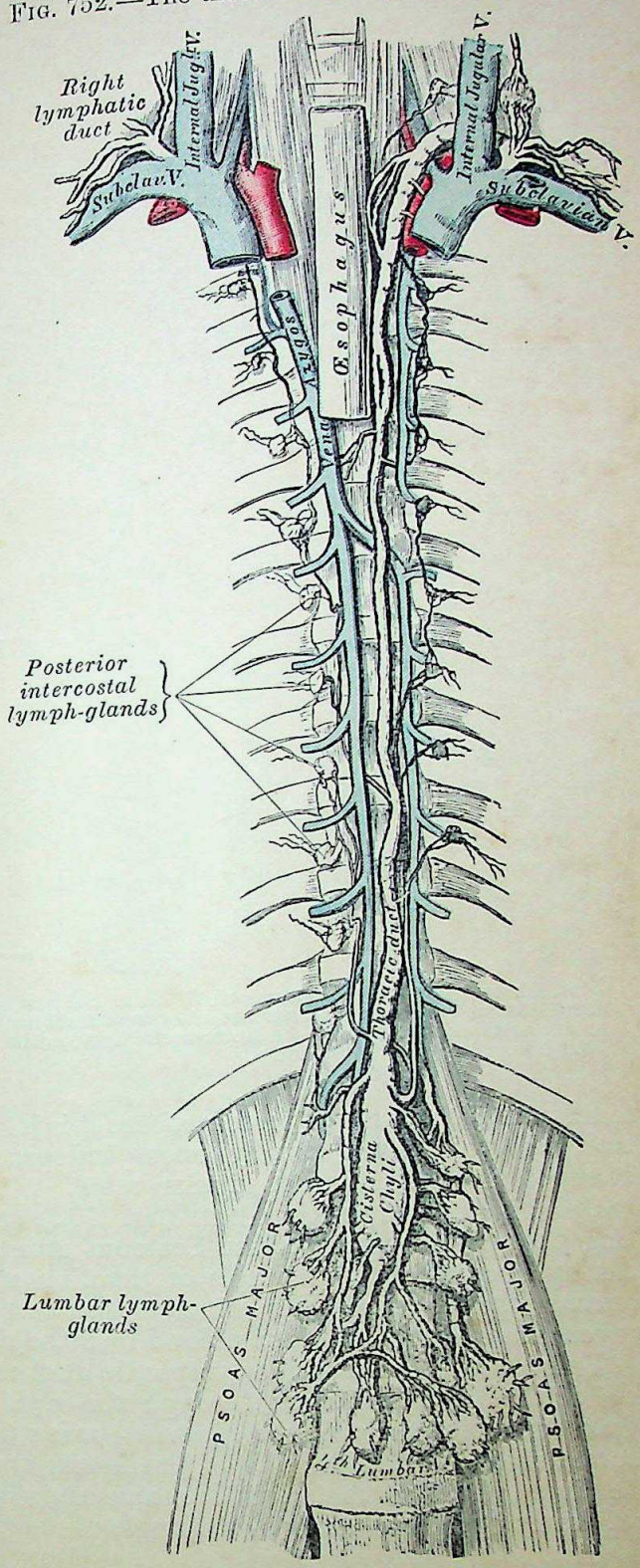

CC-0. In Public Domain. Gurukul Kangri Collection, Haridwar

Digitized by Arya Samaj Foundation Chennai and eGangotri

The **cisterna chyli** (figs. 752, 753) receives the two lumbar lymphatic trunks, right and left, and the intestinal lymphatic trunk. The *lumbar* trunks are formed by the union of the efferent vessels from the lateral aortic lymph-glands; they receive the lymph from the lower limbs, from the walls and viscera of the pelvis, from the kidneys and suprarenal glands, and the deep lymphatics of the greater part of the abdominal wall. The *intestinal trunk* receives the lymph from the stomach, intestine, pancreas and spleen, and from the lower and front part of the liver.

Tributaries.—Opening into the commencement of the thoracic duct on either side, is a descending trunk from the posterior intercostal lymph-glands of the lower six or seven intercostal spaces. In the thorax the duct receives on either side by a trunk which drains the upper lumbar lymph-glands and pierces the crus of the Diaphragm. It also receives the efferents from the posterior mediastinal lymph-glands and from the posterior intercostal lymph-glands of the upper six left spaces. In the neck it is joined by the *left jugular trunk* from the left side of the head and neck, and *left subclavian trunk* from

FIG. 753.—Modes of origin of the thoracic duct. (Poirier and Charpy.)

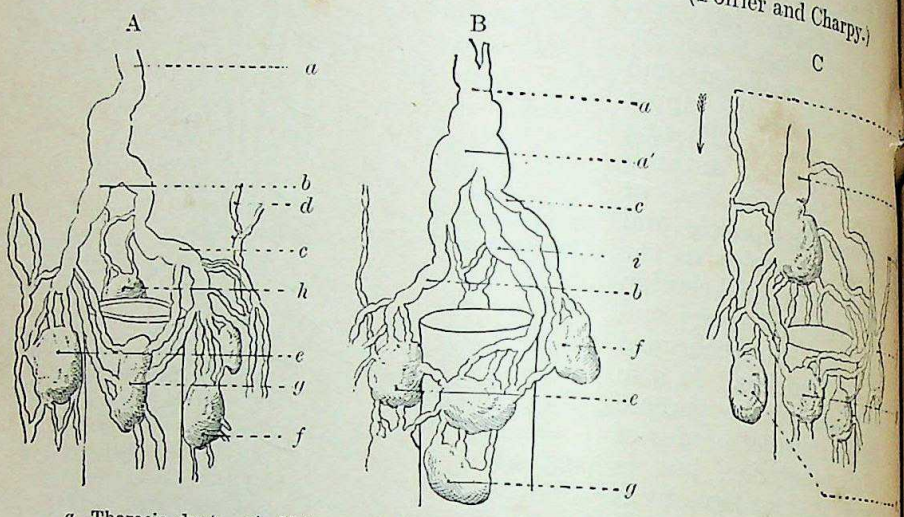

a. Thoracic duct. *a'*. Cisterna chyli. *b*, *c*. Efferent trunks from lateral aortic lymph-glands. *d*. An efferent vessel which pierces the left crus of the Diaphragm. *e*, *f*. Lateral aortic lymph-glands. *g*. Pre-aortic lymph-glands. *h*. Retro-aortic lymph-glands. *i*. Intestinal trunk. *j*. Descending branch from intercostal lymphatics.

the left superior extremity; sometimes it is joined by the *left bronchomediastinal trunk*, but this trunk usually opens independently into the junction of the left subclavian and internal jugular veins.

The right lymphatic duct (fig. 752), about 1 cm. in length, courses along the medial border of the Scalenus anterior at the root of the neck, and ends by opening into the angle of junction of the right subclavian and right internal jugular veins. Its orifice is guarded by two semilunar valves which prevent the passage of venous blood into the duct.

Tributaries.—The right lymphatic duct receives the lymph from the right side of the head and neck through the *right jugular trunk*; from the right upper extremity through the *right subclavian trunk*; from the right side of the thorax, right lung, right side of the heart, and part of the convex surface of the liver, through the *right bronchomediastinal trunk*. These three trunks frequently open separately in the angle of union of the two veins (fig. 754).

Applied Anatomy.—Blockage of the thoracic duct by mature specimens of the minute parasitic worm *Microfilaria nocturna* gives rise to stasis of the chyle, and to its passage in various abnormal directions on its course past the obstruction. The neighbouring abdominal, renal, and pelvic lymphatics become enlarged, varicose, and tortuous, and chyle may make its way into the urine (chyluria), the tunica vaginalis (chylocele), the abdominal cavity (chylous ascites) or the pleural cavity (chylous pleural effusion), as a consequence of rupture of some of these distended lymphatic vessels.

Gunshot wounds of the chest involving laceration of the thoracic duct and the escape of chyle into the pleural cavity have been described. It appears that if left alone, such lacerations tend to heal and close up spontaneously.

CC-0. In Public Domain. Gurukul Kangri Collection, Haridwar

Digitized by Arya Samaj Foundation Chennai and eGangotri

The thoracic duct may be secondarily infected in intestinal or pulmonary tuberculosis, and may contain either miliary tubercles, caseating tuberculous masses, or even tuberculous ulcers. It is often the seat of secondary carcinomatous deposits in cases of cancer of the abdominal viscus, becoming infiltrated throughout until it becomes a stiff monilifom rod as thick as a pencil, with multiple stenoses and dilatations of its lumen; in such cases the left supraclavicular lymph-glands are often infected and enlarged, while the lungs remain free from secondary growths.

Fig. 754.—The terminal lymphatic trunks of the right side. (Poirier and Charpy.)

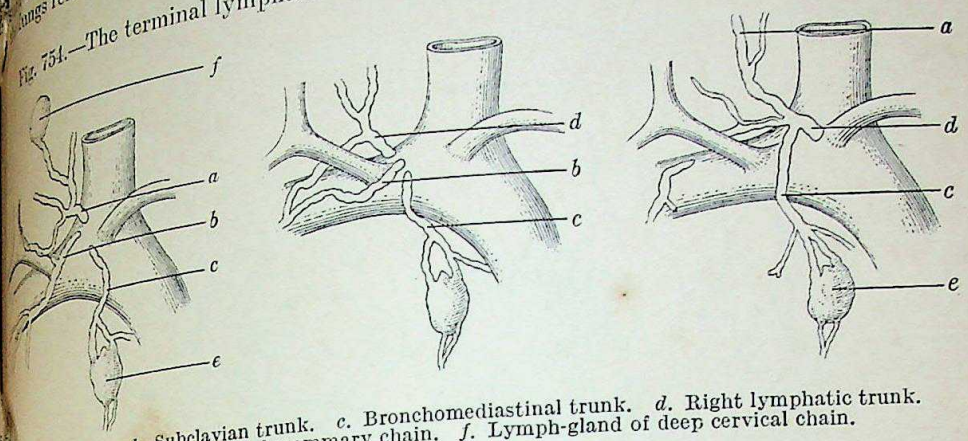

a. Jugular trunk. *b.* Subclavian trunk. *c.* Bronchomediastinal trunk. *d.* Right lymphatic trunk. *e.* Lymph-gland of internal mammary chain. *f.* Lymph-gland of deep cervical chain.

The thoracic duct has been wounded in removing tuberculous glands from the neck. When this happens the duct should be ligatured in the same way as a vein. The chyle then appears to find its way into the veins by anastomosing channels.

THE LYMPH-GLANDS OF THE HEAD AND NECK

1. The **lymph-glands of the head** (fig. 755) consist of the following groups:

Occipital.	Parotid.	Deep facial.
Posterior auricular.	Facial.	Lingual.
Anterior auricular.		

The **occipital lymph-glands**, one to three in number, are placed on the back of the head on the upper part of the Trapezius, or, if there be a gap here between the Trapezius and the Sternocleidomastoideus, on the insertion of the Semispinalis capitis. Their afferent vessels drain the lymph from the occipital region of the scalp; their efferents convey it to the superior deep cervical lymph-glands.

The **posterior auricular lymph-glands**, usually two in number, are situated on the mastoid insertion of the Sternocleidomastoideus, beneath the Auricularis posterior. Their afferent vessels drain the posterior part of the temporoparietal region, the upper part of the cranial surface of the auricula or pinna, and the back of the external acoustic meatus; their efferents pass to the superior deep cervical lymph-glands.

The **anterior auricular lymph-glands**, from one to three in number, lie immediately in front of the tragus. Their afferents drain the lateral surface of the auricula and the skin of the adjacent part of the temporal region; their efferents pass to the superior deep cervical lymph-glands.

The **parotid lymph-glands** form two groups, one imbedded in the substance of the parotid salivary gland, and the other, or subparotid group, placed on the lateral wall of the pharynx. Occasionally small lymph-glands are found in the subcutaneous tissue over the parotid salivary gland. The afferents of the subparotid lymph-glands drain the nasal part of the pharynx and the posterior parts of the nasal cavities; their efferents pass to the superior deep cervical lymph-glands. The afferents of the remaining parotid lymph-glands drain the root of the nose, the eyelids, the frontotemporal region, the external acoustic meatus and the tympanic cavity, possibly also the posterior parts of the palate and of the floor of the nasal cavity. Their efferents pass to the superior deep cervical lymph-glands.

CC-0.In Public Domain. Gurukul Kangri Collection, Haridwar

Digitized by Arya Samaj Foundation Chennai and eGangotri

The **facial lymph-glands** (figs. 755, 756) comprise three groups: (a) *orbital*, scattered over the infra-orbital region from the groove between the and cheek to the zygomatic arch; (*b*) *buccinator*, one or more on the Bucc opposite the angle of the mouth; (*c*) *supramandibular*, on the outer surface the mandible in front of the Masseter and in contact with the parotid maxillary artery and anterior facial vein. Their afferents drain the eyelids the conjunctiva, and the skin and mucous membrane of the nose and their efferents pass to the anterior auricular and submaxillary lymph-glands.

FIG. 755.—The superficial lymph-glands and lymphatic vessels of the head and neck.

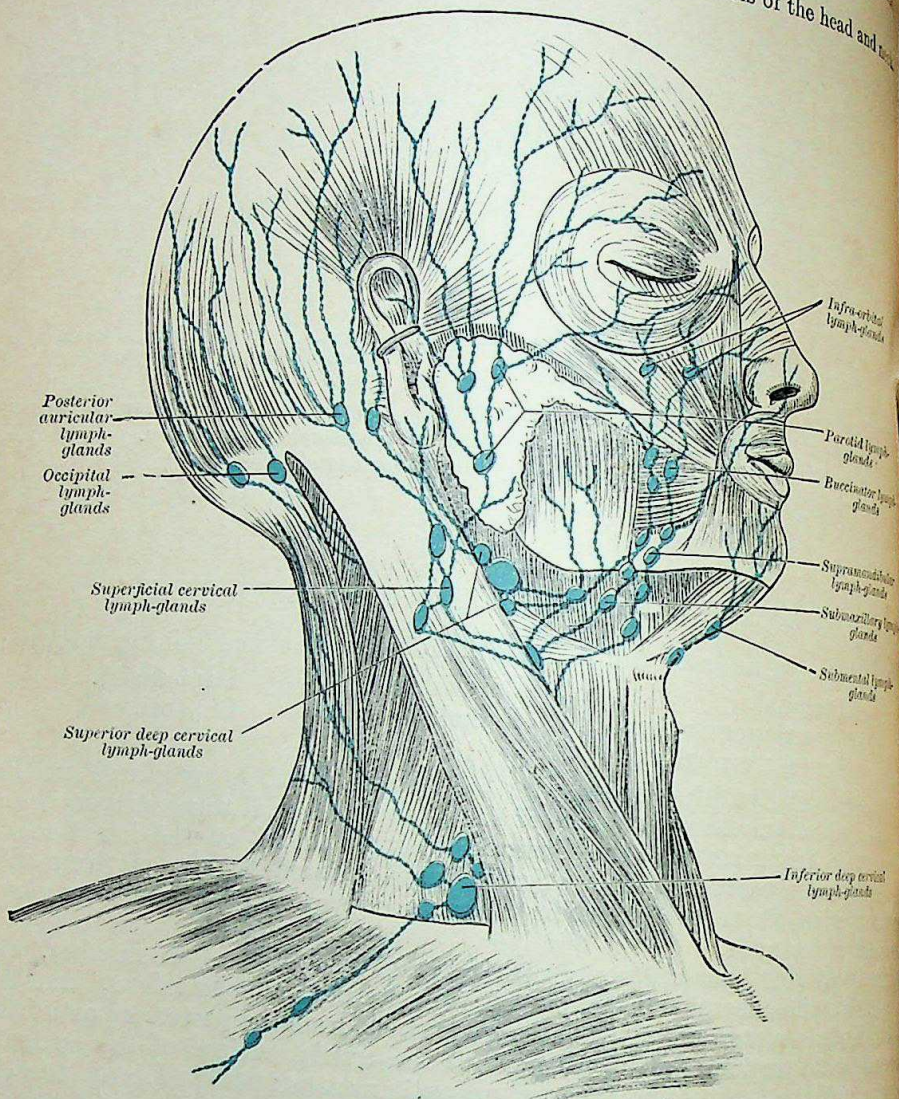

The **deep facial lymph-glands** are placed beneath the ramus of the mandible, on the outer surface of the Pterygoideus externus, in relation to the internal maxillary artery. Their afferents drain the temporal and infra-temporal fossæ, the palate and the nasal part of the pharynx; their efferents pass to the superior deep cervical lymph-glands.

The **lingual lymph-glands** are two or three small inconstant nodules lying on the Hyoglossus and between the Genioglossi. They are merely glandular nodules in the course of the lymphatic vessels of the tongue.

2. The **lymph-glands of the neck** include the following groups:

Retropharyngeal.	Anterior cervical.
Submaxillary.	Superficial cervical.
Submental.	Deep cervical.

The **retropharyngeal lymph-glands** (fig. 757), from one to three in number, lie in the buccopharyngeal fascia, behind the upper part of the pharynx.

CC-0. In Public Domain. Gurukul Kangri Collection, Haridwar

Digitized by Arya Samaj Foundation Chennai and eGangotri

and in front of the arch of the atlas, being separated, however, from the latter by the Longus capitis. Their afferents drain the posterior parts of the nasal cavities, the nasal part of the pharnyx, and the auditory tubes; their efferents go to the superior deep cervical lymph-glands.

The **submaxillary lymph-glands** (figs. 755, 756), usually three in number, are placed between the lower border of the mandible and the submaxillary salivary gland. One lies at the anterior end of the salivary gland, one in front of it and another behind the external maxillary artery as it reaches the mandible. The middle gland is the most constant (Stahr). Small lymph-glands are sometimes found imbedded in the submaxillary salivary gland or lying on its deep surface. The afferents of the submaxillary lymph-glands drain the medial half of the lower lip, the gums, and the margin of the tongue; efferent vessels from the facial and submental lymph-glands also enter the submaxillary lymph-glands. Their efferent vessels pass to the superior deep cervical lymph-glands.

Fig. 756.—The lymphatics of the face. (After Küttner.)

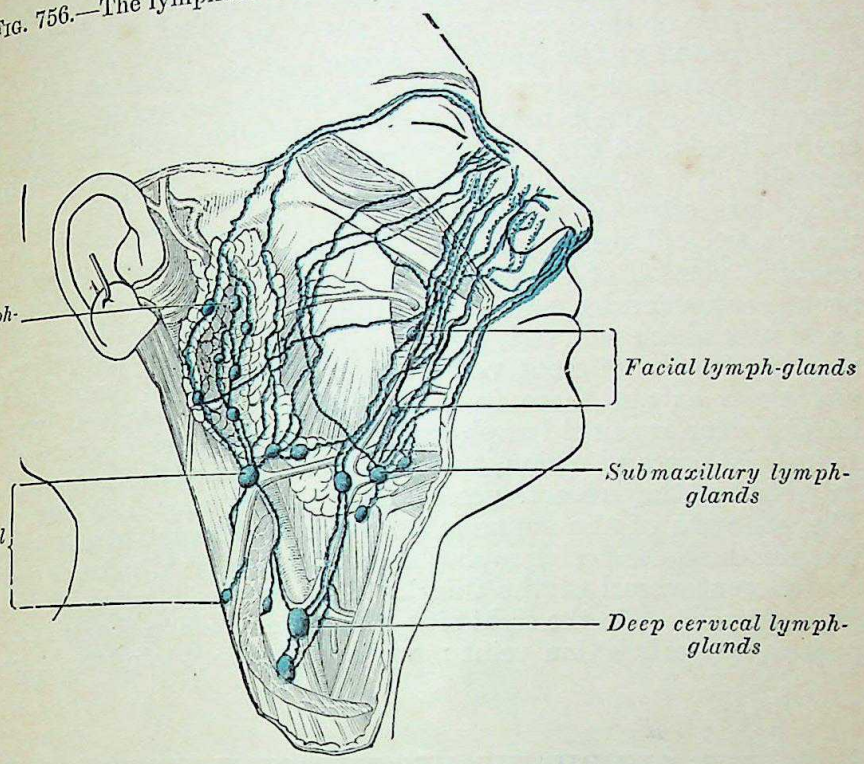

The **submental or suprahyoid lymph-glands**, three or four in number, are placed between the anterior bellies of the two Digastric muscles. Their afferents drain the central portions of the lower lip and floor of the mouth, and the apex of the tongue; their efferents pass to the submaxillary and jugulo-omohyoid lymph-glands.

The **anterior cervical lymph-glands** are placed in front of the larynx and trachea, and consist of a *superficial* and a *deep* set. Those of the superficial set lie alongside the anterior jugular vein, but are inconstant in number and size. Those of the deep set comprise: (*a*) the *infrahyoid lymph-glands* which lie in front of the hyothyreoid membrane, and receive their afferents from the neighbourhood of the epiglottis; (*b*) the *prelaryngeal lymph-glands*, which lie on the middle cricothyreoid ligament; and (*c*) the *pretracheal lymph-glands* which are placed in front of the trachea, alongside the inferior thyreoid veins. The prelaryngeal and pretracheal groups receive their afferents from the larynx, the thyreoid gland, and the cervical part of the trachea; their efferents pass to the deep cervical lymph-glands.

The **superficial cervical lymph-glands** (fig. 755) lie in close relationship with the external jugular vein as it emerges from the parotid gland, and are superficial to the Sternocleidomastoideus. Their afferents drain the parotid region and the lower part of the auricula, while their efferents pass round the

CC-0. In Public Domain. Gurukul Kangri Collection, Haridwar

Digitized by Arya Samaj Foundation Chennai and eGangotri

anterior margin of the Sternocleidomastoideus to join the superior deep cervical lymph-glands.

The **deep cervical lymph-glands** (figs. 757, 758) are numerous and of size; they form a chain along the carotid sheath, lying by the side of the pharynx, œsophagus, and trachea, and extending from the base of the skull to the root of the neck. They are usually described in two groups, the superior and inferior. The *superior deep cervical lymph-glands* lie under the sterno-cleidomastoideus in close relation with the accessory and hypoglossal nerves and the internal jugular vein, some of the glands lying in front of and behind the vein. One cluster of this group is closely associated with the lymphatic vessels of the tongue. It is placed in the triangle formed by the posterior belly of the Digastricus, the common facial vein, and the internal jugular vein, and consists of one large and several small glands which from their situation may be named the *jugulo-digastric* lymph-glands. The inferior *deep cervical lymph-glands* are situated in the supraclavicular triangle under cover of the lower part of the Sternocleidomastoideus, where they are closely related to the brachial plexus and the subclavian vessels. One gland of this group is closely related to the lymphatic vessels of the tongue. It is beneath the anterior part of the Sternocleidomastoideus on or just above the central tendon of the Omohyoideus, and may therefore be named the *omohyoid* lymph-gland (Jamieson and Dobson).* A few *paratracheal lymph-glands* are situated alongside the recurrent nerves on the lateral aspect of the trachea and œsophagus. The superior deep cervical lymph-glands drain the occipital portion of the scalp, the upper part of the auricula, the back of the neck, a considerable part of the tongue, the larynx, thyreoid gland, trachea, nasal part of the pharynx, nasal cavities, tonsils, palate, and œsophagus. They receive also the efferent vessels from all the other lymph-glands of the head and neck, except those from the inferior deep cervical lymph-glands. The inferior deep cervical lymph-glands drain the back of the scalp and neck, the superficial pectoral region, and the lateral part of the arm and forearm (p. 7[illegible]). In addition, they receive vessels from the superior deep cervical lymph-glands. The efferents of the superior deep cervical lymph-glands pass partly to the inferior deep cervical lymph-glands and partly to a trunk which unites with the efferent vessel of the inferior deep cervical lymph-glands and forms the *jugular trunk*. On the right side, this trunk ends in the junction of the internal jugular and subclavian veins; on the left side it joins the thoracic duct.

THE LYMPHATIC VESSELS OF THE HEAD AND NECK

The *lymphatic vessels of the scalp* are divisible into (*a*) those of the frontal region, which drain into the anterior auricular and parotid lymph-glands; (*b*) those of the temporoparietal region, which end in the parotid and posterior auricular lymph-gands; and (*c*) those of the occipital region, which terminate partly in the occipital lymph-glands and partly in a trunk which runs down along the posterior border of the Sternocleidomastoideus to end in the inferior deep cervical lymph-glands.

The *lymphatic vessels of the auricula and external acoustic meatus* are divisible into three groups: (*a*) an anterior, from the lateral surface of the auricula and anterior wall of the meatus to the anterior auricular lymph-glands; (*b*) a posterior, from the margin of the auricula, the upper part of its cranial surface, the internal surface and posterior wall of the meatus to the posterior auricular and superior deep cervical lymph-glands; (*c*) an inferior, from the floor of the meatus and from the lobule of the auricula to the superficial and superior deep cervical lymph-glands.

The *lymphatic vessels of the face* (figs. 755, 756) are more numerous than those of the scalp. Those from the eyelids and conjunctiva consist of a superficial plexus in the subcutaneous tissue, and a deep plexus in front of and behind the tarsi; these plexuses anastomose with one another, and open into medial and lateral groups of lymphatic vessels. The vessels of the medial

* Consult an article by J. K. Jamieson and J. F. Dobson on 'The lymphatics of the tongue,' *British Journal of Surgery*, vol. viii, No. 29, 1920.

CC-0. In Public Domain. Gurukul Kangri Collection, Haridwar

Digitized by Arya Samaj Foundation Chennai and eGangotri

group drain the caruncula lacrimalis, the skin of the medial commissure and the adjoining part of the upper eyelid, and the skin and conjunctiva of approximately the medial one-half of the lower eyelid; they accompany the anterior facial vein, and open into the submaxillary lymph-glands. The vessels of the lateral group drain the skin of the greater part, and the conjunctiva of the whole, of the upper eyelid, and the skin and conjunctiva of the central part of the lower eyelid; they open into the parotid lymph-glands. The lymphatic vessels from the posterior part of the cheek pass to the parotid lymph-glands; those from the anterior portion of the cheek, the side of the nose, the upper lip, and the lateral portions of the lower lip, end in the submaxillary lymph-glands. The deeper vessels from the temporal and infratemporal fossæ pass to the deep facial and superior deep cervical lymph-glands. The deeper vessels of the cheek and lips end, like the superficial, in the submaxillary lymph-glands. Both superficial and deep vessels of the central part of the lower lip run to the submental lymph-glands.

Fig. 757.—The lymphatics of the pharynx. (Poirier and Charpy.)

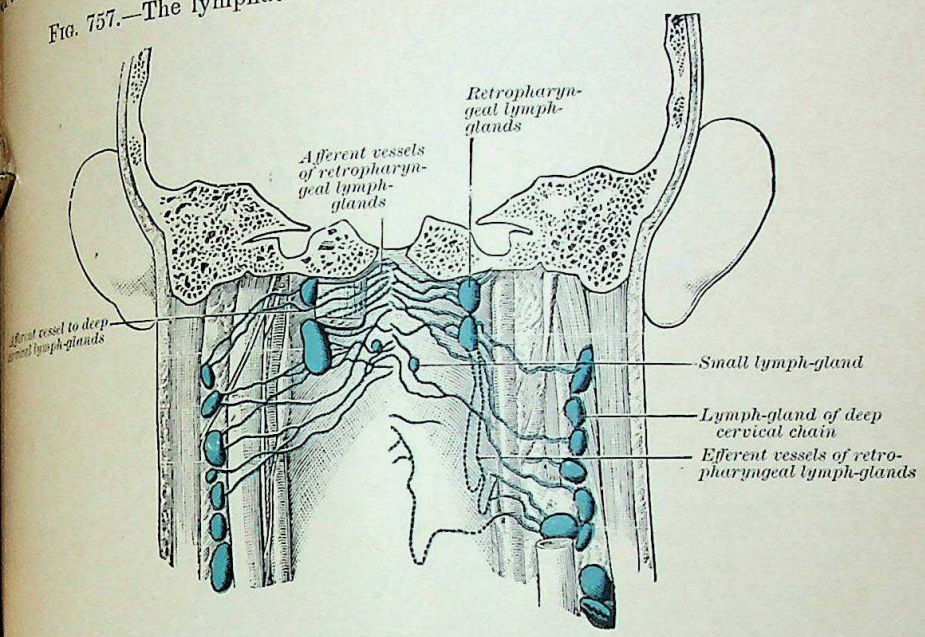

The *lymphatic vessels of the nasal cavities* can be injected from the subdural and subarachnoid cavities. Those from the anterior parts of the nasal cavities communicate with the lymphatic vessels of the skin of the nose, and end in the submaxillary lymph-glands; those from the posterior two-thirds of the nasal cavities and from the accessory air-sinuses of the nose pass partly to the retropharyngeal and partly to the superior deep cervical lymph-glands.

The *lymphatic vessels of the mouth.*—The vessels of the gums pass to the submaxillary lymph-glands; those of the hard palate are continuous in front with those of the upper gum, but run backwards to pierce the Constrictor pharyngis superior, and end in the superior deep cervical and subparotid lymph-glands; those of the soft palate pass backwards and lateralwards and end partly in the retropharyngeal and subparotid, and partly in the superior deep cervical, lymph-glands. The vessels of the anterior part of the floor of the mouth go either directly to the inferior lymph-glands of the superior deep cervical group, or indirectly through the submental lymph-glands; the vessels from the rest of the floor of the mouth pass to the submaxillary and superior deep cervical lymph-glands.

The *lymphatic vessels of the teeth.*—Lymphatic vessels were demonstrated in the pulps of the teeth by Schweitzer * in 1907, and his observations have been confirmed by Dewey and Noyes.† They pass to the submaxillary and deep cervical lymph-glands.

The *lymphatic vessels of the palatine tonsil*, usually three to five in number, pierce the buccopharyngeal fascia and Constrictor pharyngis superior and pass

* *Archiv. für Mikrosk. Anat. u. Entwick.*, 1907 and 1909. † *Dental cosmos*, vol. lix. No. 4.

CC-0. In Public Domain. Gurukul Kangri Collection, Haridwar

Digitized by Arya Samaj Foundation Chennai and eGangotri

between the Stylohyoideus and the internal jugular vein to the superior cervical lymph-glands. Most of them end in a lymph-gland which lies on the side of the posterior belly of the Digastricus, on the internal jugular vein; occasionally one or two additional vessels run to small lymph-glands on the lateral side of the vein, under cover of the Sternocleidomastoideus.

The *lymphatic vessels of the tongue* (figs. 758, 759).*—The lymphatic vessels in the mucous membrane of the tongue is continuous with the intramuscular plexus. The part of the tongue in front of the papillæ vallatæ is drained by marginal and central lymphatic vessels.

FIG. 758.—The course of the lymphatic vessels from the tongue to the submental, submaxillary, and deep cervical lymph-glands. (Jamieson and Dobson, *British Journal of Surgery*, vol. viii. 1920.

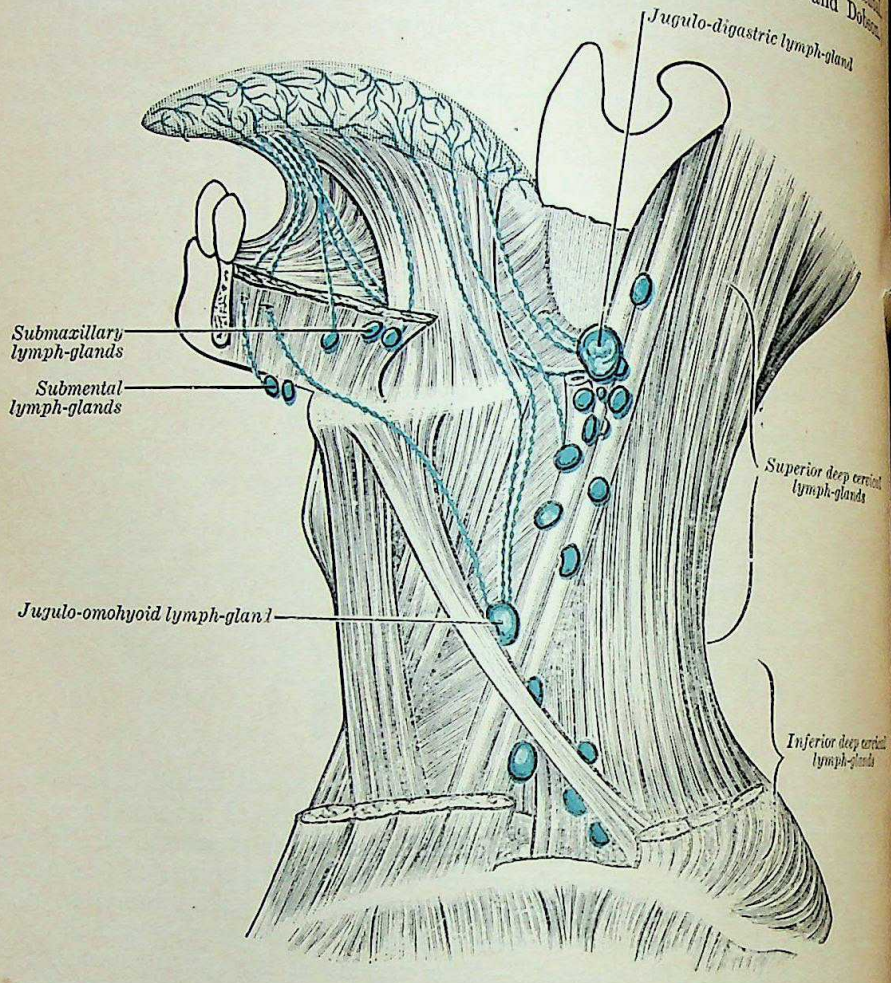

1. *Marginal vessels.*—The lymphatic vessels from the tip, and region of the frænum, of the tongue descend under the mucous membrane and end in widely distributed lymph-glands.

(*a*) Vessels pierce the origin of the Mylohyoideus in contact with the periosteum of the mandible; one or two of these vessels enter the submental lymph-glands, and one descends over the hyoid bone to the jugulo-omohyoid lymph-gland. (It should be noted (1) that vessels arising in the plexus on one side of the tongue may cross under the frænum and end in the lymph-glands of the opposite side, and (2) that the efferent vessels of the median-plane submental lymph-glands pass impartially to either side.)

(*b*) Some vessels pierce the origin of the Mylohyoideus, and enter the anterior or the middle submaxillary lymph-gland.

(*c*) Some vessels pass deeply under the sublingual salivary gland, and accompanying the ranine vein, end in the jugulo-digastric lymph-glands. One vessel

* This description of the lymphatic vessels of the tongue is based on the researches of Jamieson and Dobson (*loc. cit.* p. 754).

CC-0. In Public Domain. Gurukul Kangri Collection, Haridwar

Digitized by Arya Samaj Foundation Chennai and eGangotri

then descends over or beneath the central tendon of the Digastricus to reach the jugulo-omohyoid lymph-gland.

Some of the lymphatic vessels from the lateral margin of the tongue pass to the sublingual salivary gland, pierce the Mylohyoideus, and end in the submaxillary lymph-glands; others pass under the salivary gland and end in the jugulo-digastric lymph-glands.

The vessels from the posterior part of the margin of the tongue make their way through the pharyngeal wall to the jugulo-digastric lymph-glands.

2. *Central vessels.*—There is no clear line of demarcation between those on the surface of the tongue draining into the marginal or into the central vessels. The central lymphatic vessels descend in the middle line between the Genioglossi. Some turn lateralwards through the muscles, but the majority appear between their free borders and diverge to the right or left, i.e. the vessels from one side of the tongue may run to the lymph-glands of the opposite side. They follow the lingual blood-vessels, and end in the deep cervical lymph-glands, especially in the jugulo-digastric and jugulo-omohyoid glands. Some pierce the Mylohyoideus and enter the submaxillary lymph-glands.

FIG. 759.—A diagram to show the course of the central lymphatic vessels of the tongue to the lymph-glands on both sides of the neck. (Jamieson and Dobson.) *British Journal of Surgery*, vol. viii. 1920.

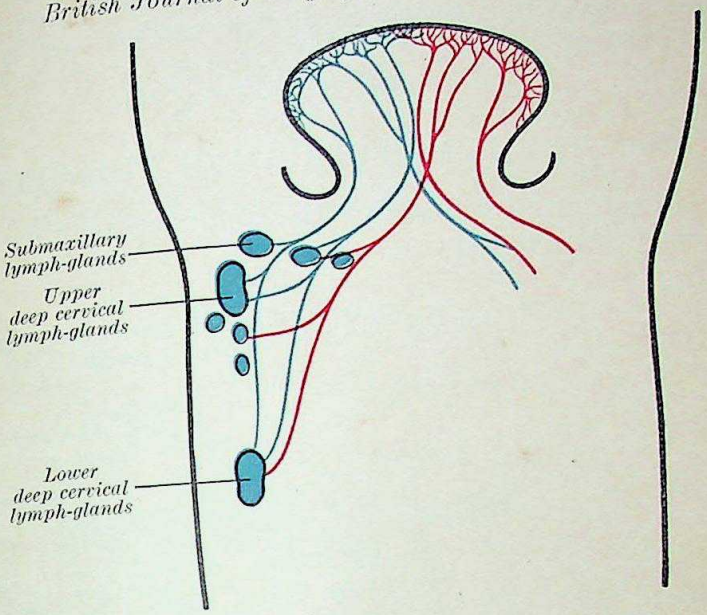

3. *Dorsal vessels.*—The vessels draining the area of the papillæ vallatæ, and the part of the tongue behind these papillæ, run backwards—those near the middle line may divide and run to both sides. They turn lateralwards to join the marginal vessels, and all pierce the pharyngeal wall passing in front of or behind the external carotid artery, to reach the jugulo-digastric and jugulo-omohyoid lymph-glands, or the glands between them. One vessel may descend behind the hyoid bone, perforate the hyothyreoid membrane, and end in the jugulo-omohyoid lymph-gland.

The *lymphatic vessels of the skin and muscles of the neck* pass to the deep cervical lymph-glands. From the upper part of the *pharynx* the lymphatic vessels pass to the retropharyngeal lymph-glands; from the lower part to the deep cervical lymph-glands. From the *larnyx* two sets of vessels arise, an upper and a lower which do not communicate very freely, the two sets being separated by the vocal folds where there are very few lymphatic vessels. The vessels of the upper set pierce the hyothyreoid membrane, accompany the laryngeal branch of the superior thyreoid artery, and join the superior deep cervical lymph-glands. Of the lower set, some pierce the conus elasticus and join the pretracheal and prelaryngeal lymph-glands; others run between the cricoid cartilage and first tracheal ring and enter the inferior deep cervical lymph-glands. The lymphatic vessels of the *thyreoid gland* consist of an upper set, which accompanies the superior thyreoid artery and enters the superior deep cervical lymph-glands, and a lower, which runs partly to the pretracheal lymph-glands and partly to the small paratracheal lymph-glands which accompany the recurrent nerves. The paratracheal lymph-glands also receive lymphatic vessels from the cervical portion of the trachea.

Applied Anatomy.—The superficial and deep cervical lymph-glands often become involved from inflammatory conditions about the mouth, teeth, tonsil and pharynx. When suppuration occurs in the deep group it is apt to spread widely beneath the deep cervical fascia unless relieved by early incision.

CC-0. In Public Domain. Gurukul Kangri Collection, Haridwar

Digitized by Arya Samaj Foundation Chennai and eGangotri

The cervical lymph-glands are very frequently the seat of tuberculous dis condition may be set up by some lesion in those parts from which they receive th It is very desirable for the surgeon, in dealing with these cases, to possess a k of the relation of the groups of lymph-glands to important structures, as in order to r them by operation a long and difficult dissection may be required. The same c of these lymph-glands when they become infiltrated with carcinomatous growth n to disease of the lip, tongue, palate, or pharynx. At times it will be found n remove a portion of the internal jugular vein, previously ligatured, with the ma

When an acute abscess forms in the retropharyngeal glands, it is opened by a through the posterior pharyngeal wall, but a chronic abscess in these glands is making an incision behind the Sternomastoideus and the carotid sheath, at the the second cervical vertebra.

THE LYMPH-GLANDS OF THE UPPER EXTREMITY

The lymph-glands of the upper extremity are divided into two *superficial* and *deep*.

FIG. 760.—The superficial lymph-glands and lymphatic vessels of the upper extremity.

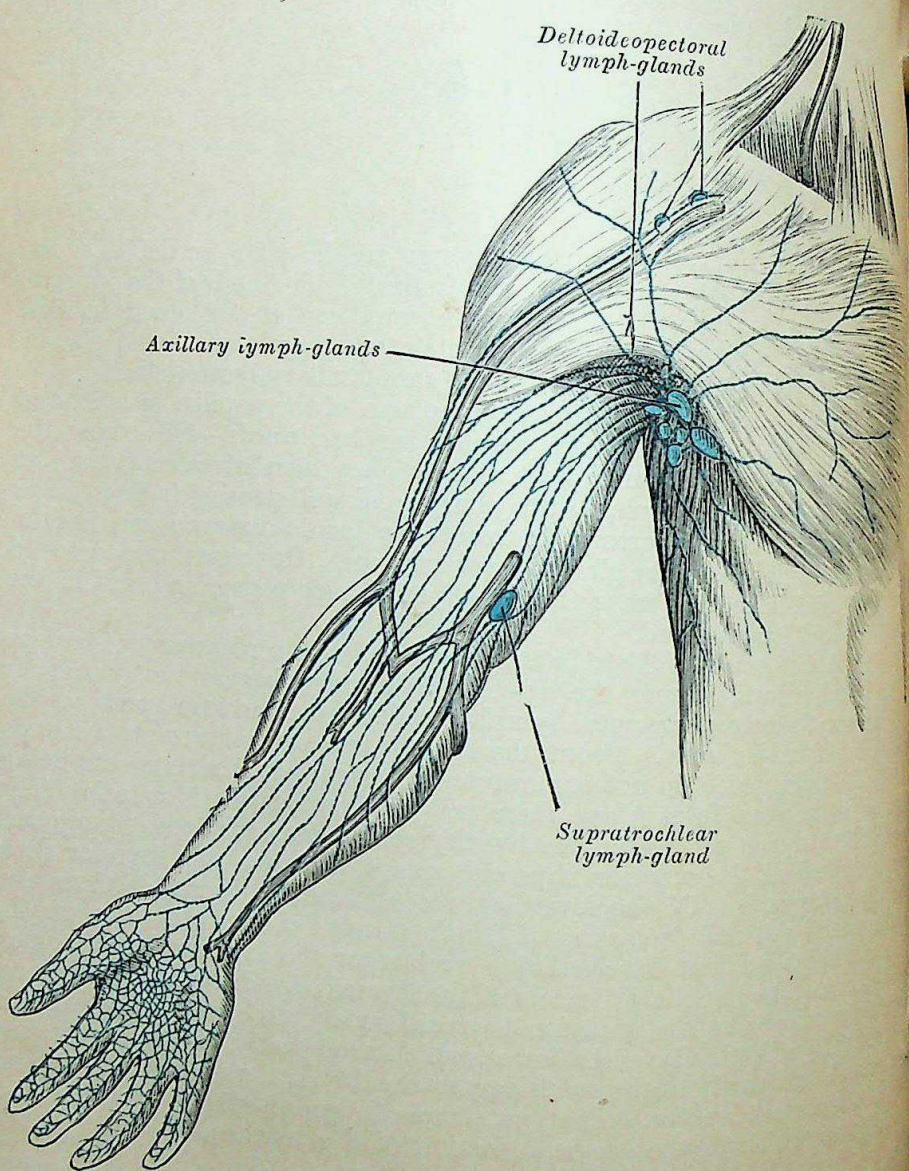

The superficial lymph-glands (fig. 760) are few and of small size. O or two *supratrochlear* lymph-glands are placed above the medial epicondy

CC-0. In Public Domain. Gurukul Kangri Collection, Haridwar

Digitized by Arya Samaj Foundation Chennai and eGangotri

the humerus, on the medial side of the basilic vein. Their afferents drain the middle, ring, and little fingers, the medial portion of the hand, and the superficial area over the ulnar side of the forearm; these vessels are, however, free communication with the other lymphatic vessels of the forearm. Their efferents accompany the basilic vein and join the deeper vessels. One or two *deltopectoral* lymph-glands are found beside the cephalic vein, between Pectoralis major and Deltoideus, immediately below the clavicle. They are situated in the course of a collecting trunk which drains the lateral side of the arm and forearm.

The **deep lymph-glands** are chiefly grouped in the axilla, although a few may be found in the forearm, in the course of the radial, ulnar, and interosseous vessels, and in the arm along the medial side of the brachial artery.

Fig. 761.—The lymphatics of the mamma, and the axillary lymph-glands. Semi-diagrammatic. (Poirier and Charpy.)

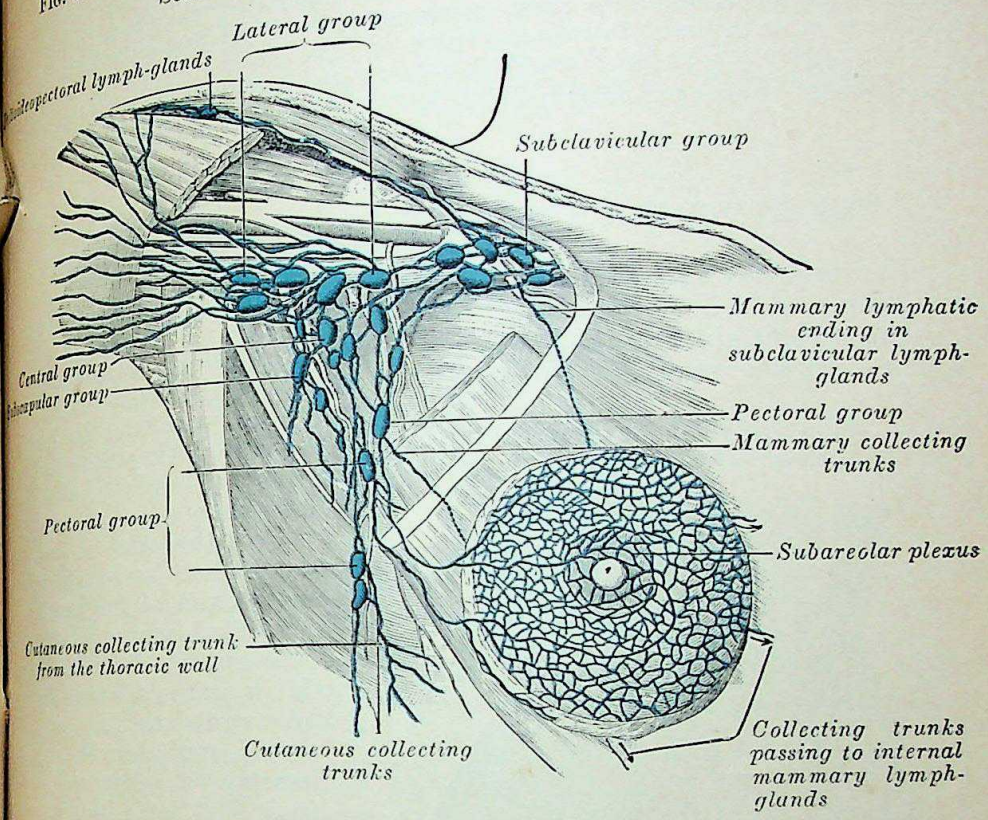

The **axillary lymph-glands** (fig. 761) are of large size; they vary from twenty to thirty in number, and may be divided into five groups:

1. A *lateral group* of from four to six lymph-glands lies in relation to the medial and posterior aspects of the axillary vein; the afferents of this group drain the whole arm with the exception of that portion whose lymphatic vessels accompany the cephalic vein. The efferent vessels pass partly to the central and subclavicular groups of axillary lymph-glands, and partly to the inferior deep cervical lymph-glands.

2. An *anterior or pectoral group*, consisting of four or five lymph-glands, lies along the lower border of the Pectoralis minor, in relation with the lateral thoracic artery. Its afferents drain the skin and muscles of the anterior and lateral walls of the body, above the level of the umbilicus, and the central and lateral parts of the mamma (p. 777); its efferents pass partly to the central, and partly to the subclavicular groups of axillary lymph-glands.

3. A *posterior or subscapular group* of six or seven lymph-glands is placed along the lower margin of the posterior wall of the axilla in the course of the subscapular artery. The afferents of this group drain the skin and muscles of the lower part of the back of the neck and of the posterior thoracic wall; their efferents pass to the central group of axillary lymph-glands.

CC-0. In Public Domain. Gurukul Kangri Collection, Haridwar

Digitized by Arya Samaj Foundation Chennai and eGangotri

4. A *central or intermediate group* of three or four large lymph-gl[illegible] imbedded in the adipose tissue near the base of the axilla. Its afferent[illegible] the efferent vessels of all the preceding groups of axillary lymph-glands. [illegible] efferents pass to the subclavicular group of lymph-glands.

5. A *medial or subclavicular group* of six to twelve lymph-glands is [illegible] partly posterior to the upper portion of the Pectoralis minor and partly [illegible] the upper border of this muscle. The only direct territorial afferents [illegible] group are those which accompany the cephalic vein and one which [illegible] the upper peripheral part of the mamma, but it receives the efferents [illegible] the other axillary lymph-glands. The efferent vessels of this group [illegible] form the *subclavian trunk*, which opens either directly into the jun[illegible] the internal jugular and subclavian veins or into the jugular lymphatic [illegible] on the left side it may end in the thoracic duct. A few efferents fr[illegible] subclavicular group usually pass to the inferior deep cervical lymph-gl[illegible]

Applied Anatomy.—Enlargement of the axillary lymph-glands is very often [illegible] malignant disease and also in infective processes implicating the upper part of [illegible] and shoulder, the front of the chest and mamma, the upper part of the front and [illegible] the abdomen, or the hand, forearm, and arm.

In the operation for the removal of a cancerous breast, all the axillary lymph-[illegible] the lymphatic vessels, and the Pectorales major et minor are removed in one mass.

THE LYMPHATIC VESSELS OF THE UPPER EXTREMITY

The *lymphatic vessels of the upper extremity* consist of two sets, superf[illegible] and deep.

The *superficial lymphatic vessels* (fig. 762) commence in the lymphatic pl[illegible] which everywhere pervades the skin; the meshes of the plexus are much [illegible] in the palm and on the fl[illegible] aspects of the digits than el[illegible] where. The digital plexuses [illegible] drained by a pair of vessels wh[illegible] run on the sides of each di[illegible] and incline backwards to re[illegible] the dorsum of the hand. Fr[illegible] the dense plexus of the pa[illegible] vessels pass in different directio[illegible] viz. upwards towards the wrist [illegible] downwards to join the digit[illegible] vessels, medialwards to join th[illegible] vessels on the ulnar border of th[illegible] hand, and lateralwards to th[illegible] on the thumb. Several vess[illegible] from the central part of th[illegible] plexus unite to form a trun[illegible] which passes round the m[illegible] carpal bone of the index fin[illegible] to join the vessels on the dors[illegible] of that digit and on the dors[illegible] of the thumb. As the lymph[illegible] vessels ascend on the dorsal a[illegible] palmar surfaces of the wrist, th[illegible] are collected into groups, wh[illegible] accompany the cephalic, med[illegible] antibrachial, and basilic veins [illegible] the forearm. A few of those [illegible] the medial side end in the sup[illegible] trochlear lymph-glands, but [illegible] majority pass directly to th[illegible] lateral group of axillary lym[illegible] glands. Some of the vessels [illegible] the lateral side are collected [illegible]

Fig. 762.—The lymphatic vessels of the dorsal surface of the hand. (Sappey.)

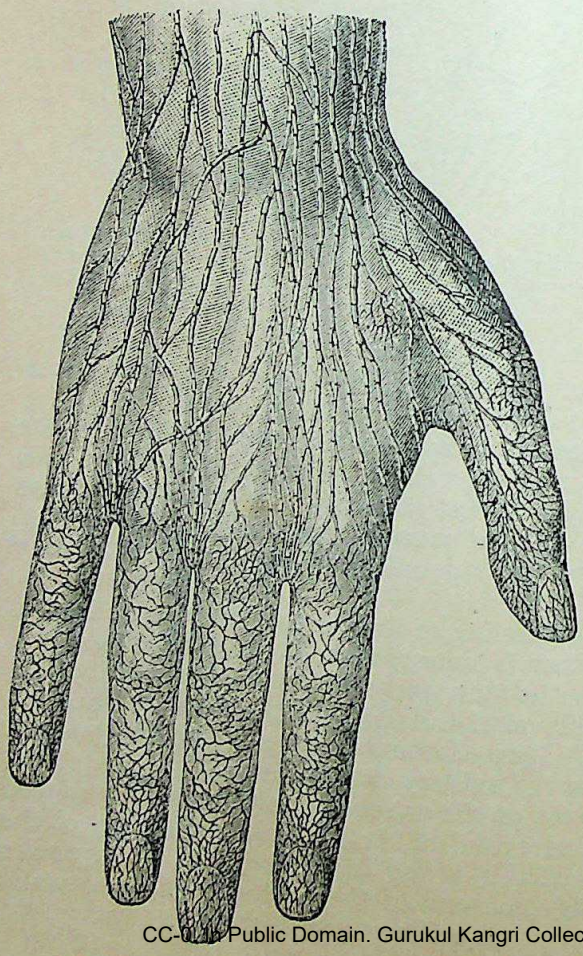

CC-0. In Public Domain. Gurukul Kangri Collection, Haridwar

Digitized by Arya Samaj Foundation Chennai and eGangotri

trunk which ascends with the cephalic vein to the deltoideo-pectoral lymph-glands; the efferents from this group enter either the subclavicular axillary lymph-glands or pass over the clavicle to the inferior deep cervical lymph-glands.

The *deep lymphatic vessels* accompany the deep blood-vessels. In the forearm, they consist of four sets, corresponding with the radial, ulnar, volar interosseous, and dorsal interosseous arteries; they communicate at intervals with the superficial lymphatic vessels, and some of them end in the lymph-glands which are occasionally found beside the arteries. A few end in the epitrochlear lymph-glands, but most of them pass to the lateral group of axillary lymph-glands.

THE LYMPH-GLANDS OF THE LOWER EXTREMITY

The lymph-glands of the lower extremity consist of three sets:—the anterior tibial, the popliteal and the inguinal.

The anterior tibial lymph-gland is small and inconstant; it lies on the interosseous membrane in relation to the upper part of the anterior tibial vessels.

Fig. 763.—The lymph-glands of the popliteal fossa. (Poirier and Charpy.)

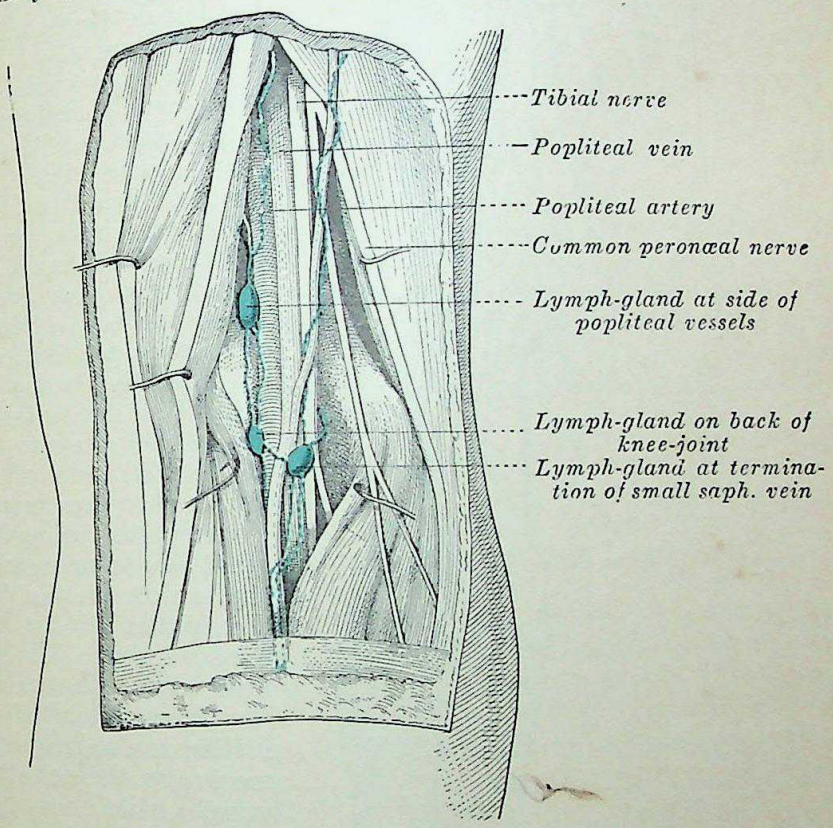

The popliteal lymph-glands (fig. 763), small in size and six or seven in number, are imbedded in the fat contained in the popliteal fossa. One lies near the termination of the small saphenous vein, and drains the region from which this vein derives its tributaries. Another is placed between the popliteal artery and the posterior surface of the knee-joint; it receives the lymphatic vessels from the knee-joint together with those which accompany the genicular arteries. The remainder lie at the sides of the popliteal vessels, and receive as afferents the trunks which accompany the anterior and posterior tibial vessels. The efferents of the popliteal lymph-glands pass almost entirely alongside the femoral vessels to the deep subinguinal lymph-glands, but a few may accompany the great saphenous vein, and end in the superficial subinguinal lymph-glands.

CC-0. In Public Domain. Gurukul Kangri Collection, Haridwar

Digitized by Arya Samaj Foundation Chennai and eGangotri

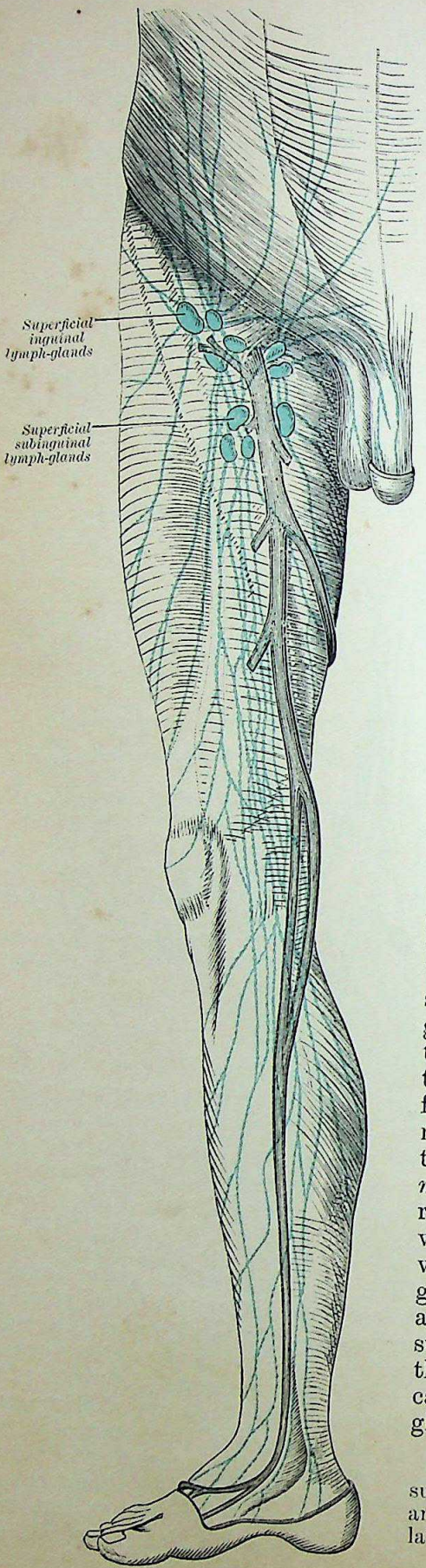

FIG. 764.—The superficial lymph-glands and lymphatic vessels of the lower extremity.

The **inguinal lymph-glands** (Fig. 764), from twelve to twenty in number, are situated at the upper part of the femoral triangle. They may be divided into two groups by a line drawn horizontally at the level of the termination of the great saphenous vein; those lying above this line are termed the superficial inguinal lymph-glands, and those below it the subinguinal lymph-glands, the latter group consisting of a superficial and a deep set.

The *superficial inguinal lymph-glands* form a chain immediately below the inguinal ligament. They receive as afferents the lymphatic vessels from the skin of the penis, scrotum (but not from the testis), perinæum, buttock, and abdominal wall below the level of the umbilicus; they also receive lymphatic vessels from the anal canal and from the mucous membrane of the anterior part of the urethra. In the female they receive the lymphatics from the vulva.

The *superficial subinguinal lymph-glands* are placed on either side of the upper part of the great saphenous vein; their afferents consist chiefly of the superficial lymphatic vessels of the lower extremity, except the back and lateral side of the calf of the leg, but they also receive some of the vessels which drain the skin of the penis, scrotum, perinæum, and buttock.

The *deep subinguinal lymph-glands* vary from one to three in number, and are placed deep to the fascia lata, on the medial side of the femoral vein. When three are present, the lowest is situated just below the junction of the great saphenous and femoral veins, the middle in the femoral canal, and the highest in the lateral part of the femoral ring. The middle one is the most inconstant, but the highest, the *lymph-gland of Cloquet or Rosenmüller*, is also frequently absent. They receive as afferents the deep lymphatic vessels which accompany the femoral vessels, the lymphatic vessels from the glans penis (or glans clitoridis), and also some of the efferents from the superficial subinguinal lymph-glands; their efferents pass through the femoral canal to the external iliac lymph-glands.

Applied Anatomy.—Inflammation and suppuration of the popliteal lymph-glands are most commonly due to a sore on the lateral side of the heel.

The inguinal and subinguinal lymph-glands frequently become enlarged in disease

CC-0. In Public Domain. Gurukul Kangri Collection, Haridwar

Digitized by Arya Samaj Foundation Chennai and eGangotri

implicating the parts from which their lymphatic vessels originate. Thus in malignant or syphilitic affections of the prepuce and penis, or labia majora, in cancer of the scrotum, in abscess in the perinæum, anus and lower part of the vagina, or in similar diseases affecting the skin and superficial structures in those parts, or the subumbilical parts of the abdominal wall, or the glutæal region, the upper group of lymph-glands is almost invariably enlarged, the lower groups being implicated in diseases affecting the lower limb.

THE LYMPHATIC VESSELS OF THE LOWER EXTREMITY

The *lymphatic vessels of the lower extremity* consist of two sets, superficial and deep, and in their distribution correspond closely with the veins.

The *superficial lymphatic vessels* lie in the superficial fascia, and are divisible into two groups: a medial, which follows the course of the great saphenous vein; and a lateral, which accompanies the small saphenous vein. The vessels of the *medial group* (fig. 764) are larger and more numerous than those of the lateral group, and commence on the tibial side and dorsum of the foot; they ascend in front of and behind the medial malleolus, run up the leg with the great saphenous vein, pass with it behind the medial condyle of the femur, and accompany it to the groin, where they end in the superficial inguinal lymph-glands. The vessels of the *lateral group* arise from the fibular side of the foot; some ascend in front of the leg, and cross the tibia below the knee to join the lymphatics on the medial side of the thigh; others pass behind the lateral malleolus, and, accompanying the small saphenous vein, enter the popliteal lymph-glands.

The *deep lymphatic vessels* are few in number, and accompany the deep blood-vessels. In the leg, they consist of three sets, anterior tibial, posterior tibial, and peronæal, which accompany the corresponding blood-vessels, two or three with each artery; they enter the popliteal lymph-glands.

The deep lymphatic vessels of the glutæal and ischial regions follow the course of the corresponding blood-vessels. Those accompanying the superior glutæal vessels end in a lymph-gland which lies on the intrapelvic portion of the superior glutæal artery, near the upper border of the greater sciatic foramen. Those following the inferior glutæal vessels traverse one or two small lymph-glands which lie below the Piriformis muscle, and end in the hypogastric lymph-glands.

THE LYMPH-GLANDS OF THE ABDOMEN AND PELVIS

The **lymph-glands of the abdomen and pelvis** may be divided, from their situations, into: 1. *parietal*, lying behind the peritoneum and in close association with the larger blood-vessels; and 2. *visceral*, which are found in relation to the visceral arteries.

1. The **parietal lymph-glands** (figs. 765, 766) include the following groups:

External iliac.	Iliac circumflex.	Lumbar: Lateral aortic.
Common iliac.	Hypogastric.	Lumbar: Pre-aortic.
Inferior epigastric.	Sacral.	Lumbar: Retro-aortic.

The **external iliac lymph-glands**, from eight to ten in number, lie along the external iliac vessels. They are arranged in three groups, one on the lateral, another on the medial, and a third on the anterior aspect of the vessels; the third group is, however, sometimes absent. Their principal afferents are derived from the inguinal and subinguinal lymph-glands, the deep lymphatic vessels of the abdominal wall below the umbilicus and of the adductor region of the thigh, and the lymphatic vessels from the glans penis vel clitoridis, the membranous urethra, the prostate, the fundus of the urinary bladder, the cervix uteri, and upper part of the vagina.

The **common iliac lymph-glands**, four to six in number, are grouped behind and on the sides of the common iliac artery, one or two (subaortic) being placed

CC-0. In Public Domain. Gurukul Kangri Collection, Haridwar

Digitized by Arya Samaj Foundation Chennai and eGangotri

below the bifurcation of the aorta, in front of the fifth lumbar vertebra. They drain chiefly the hypogastric and external iliac lymph-glands, and their efferents pass to the lateral aortic lymph-glands.

The **inferior epigastric lymph-glands**, three or four in number, are placed alongside the lower portions of the inferior epigastric vessels.

The **iliac circumflex lymph-glands**, two to four in number, lie along the course of the deep iliac circumflex vessels; they are sometimes absent.

FIG. 765.—The parietal lymph-glands of the pelvis. (Cunéo and Marcille.)

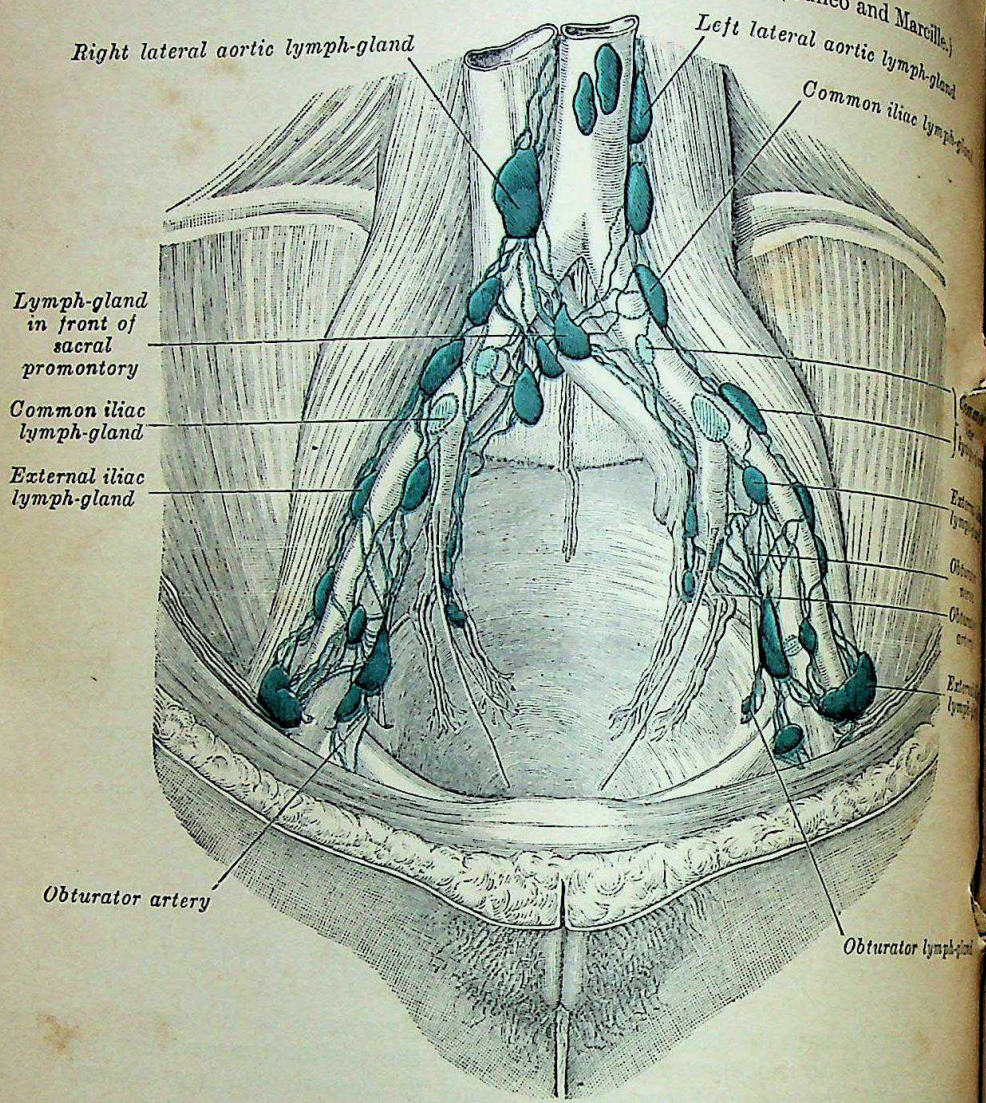

The **hypogastric lymph-glands** (fig. 766) surround the hypogastric vessels and receive the lymphatic vessels corresponding to the distribution of the branches of the hypogastric artery, i.e. they receive lymphatic vessels from all the pelvic viscera, from the deeper parts of the perinæum, including the membranous and cavernous portions of the urethra, and from the buttock and back of the thigh. An *obturator lymph-gland* is sometimes present in the upper part of the obturator foramen.

The **sacral lymph-glands** are placed in the concavity of the sacrum in relation to the middle and lateral sacral arteries; they receive lymphatic vessels from the rectum and posterior wall of the pelvis.

The efferents of the hypogastric and sacral groups end in the common iliac lymph-glands.

The **lumbar lymph-glands** are very numerous, and consist of right and left lateral aortic, pre-aortic, and retro-aortic groups.

The *right lateral aortic lymph-glands* are situated partly in front of the inferior vena cava, near the termination of the renal vein, and partly behind

CC-0. In Public Domain. Gurukul Kangri Collection, Haridwar

Digitized by Arya Samaj Foundation Chennai and eGangotri

it on the origin of the Psoas major, and on the right crus of the Diaphragm. The *left lateral aortic lymph-glands* form a chain on the left side of the abdominal aorta in front of the origin of the Psoas major and left crus of the Diaphragm. The lymph-glands on either side receive (*a*) the efferents of the common iliac lymph-glands; (*b*) the lymphatics from the testis in the male and from the ovary, uterine tube, and body of the uterus in the female; (*c*) the lymphatics from the kidney and suprarenal gland; and (*d*) the lymphatics draining the lateral abdominal muscles and accompanying the lumbar veins. Most of the efferent vessels of the lateral aortic lymph-glands converge to form the *right and left lumbar trunks* which join the cisterna chyli, but some enter the

FIG. 766.—The iliopelvic lymph-glands. (Cunéo and Marcille.)

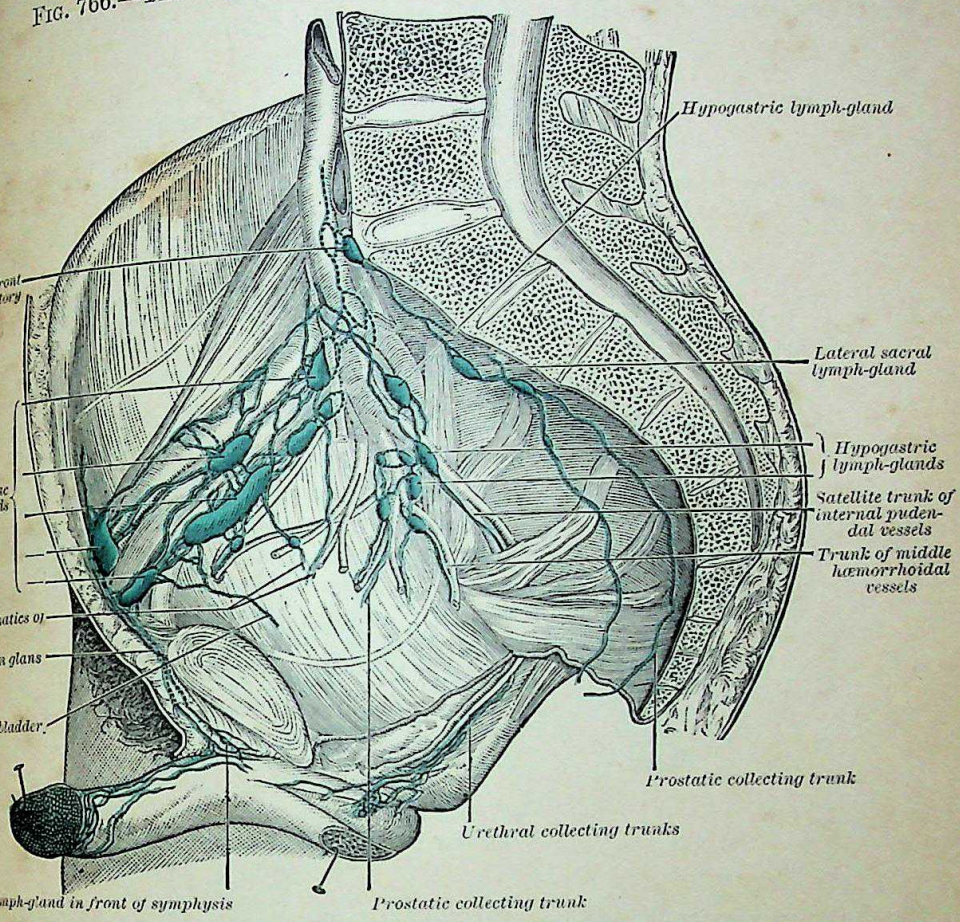

pre- and retro-aortic lymph-glands, and others pierce the crura of the Diaphragm to join the lower end of the thoracic duct. The *pre-aortic lymph-glands* lie in front of the aorta, and may be divided into *cœliac*, *superior mesenteric*, and *inferior mesenteric* groups, arranged around the origins of the corresponding arteries. They receive a few vessels from the lateral aortic lymph-glands, but their principal afferents are derived from the viscera supplied by the three arteries with which the glands are associated. Some of their efferents pass to the retro-aortic lymph-glands, but the majority unite to form the *intestinal trunk*, which enters the cisterna chyli. The *retro-aortic lymph-glands* are placed below the cisterna chyli, on the bodies of the third and fourth lumbar vertebræ. They receive lymphatic vessels from the lateral and pre-aortic lymph-glands, while their efferents end in the cisterna chyli.

2. The **visceral lymph-glands** are associated with the branches of the cœliac, and superior and inferior mesenteric arteries. Those related to the branches of the cœliac artery form three sets, gastric, hepatic, and pancreaticolienal.

The **gastric lymph-glands** (figs. 767, 768) consist of two sets, superior and inferior.

The **superior gastric lymph-glands** accompany the left gastric artery and are divisible into three groups, viz.: (*a*) *upper*, on the stem of the artery; (*b*) *lower*,

CC-0. In Public Domain. Gurukul Kangri Collection, Haridwar

Digitized by Arya Samaj Foundation Chennai and eGangotri

accompanying the descending branches of the artery along the cardiac [illegible] the lesser curvature of the stomach, between the two layers of the lesser omentum, and (*c*) *paracardial*, disposed in a manner comparable to a chain of beads [illegible] the neck of the stomach (Jamieson and Dobson).* They receive their afferents from the stomach, and also some vessels from the pylorus; their efferents pass to the cœliac group of pre-aortic lymph-glands.

The **inferior gastric lymph-glands**, four to seven in number, lie between the two layers of the greater omentum along the pyloric half of the greater curvature of the stomach. They receive afferents from the stomach; their efferents mainly pass to the subpyloric lymph-glands.

The **hepatic lymph-glands** (fig. 767) consist of the following groups: (*a*) *hepatic*, on the stem of the hepatic artery, and extending upwards along the bile-duct, between the two layers of the lesser omentum, as far as the porta hepatis; one member of this group, the *cystic lymph-gland*, is placed near

Fig. 767.—The lymphatics of the stomach, &c. (Jamieson and Dobson.)

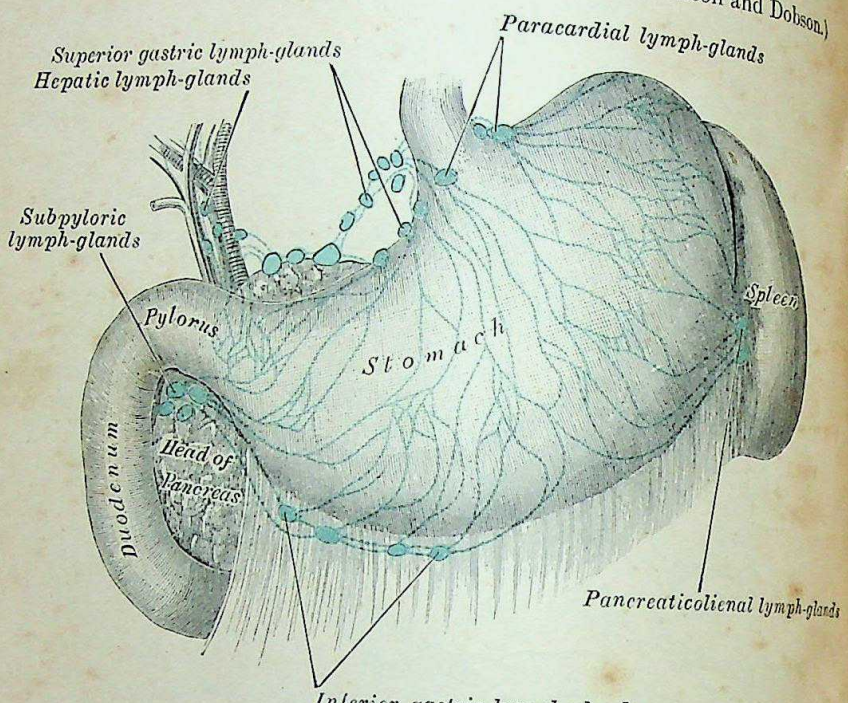

the neck of the gall-bladder; (*b*) *subpyloric*, four or five in number, in close relation to the bifurcation of the gastroduodenal artery, in the angle between the superior and descending parts of the duodenum; an outlying member of this group is sometimes found above the duodenum on the right gastric (pyloric) artery. The lymph-glands of the hepatic chain receive afferents from the stomach, duodenum, liver, gall-bladder, and pancreas; their efferents join the cœliac group of pre-aortic lymph-glands.

The **pancreaticolienal lymph-glands** (fig. 768) accompany the lienal (splenic) artery, and are situated in relation to the posterior surface and upper border of the pancreas; one or two members of this group are found in the gastrolienal ligament (Jamieson and Dobson, *loc. cit.*). Their afferents are derived from the stomach, spleen, and pancreas; their efferents join the cœliac group of pre-aortic lymph-glands.

The **superior mesenteric lymph-glands** may be divided into three principal groups: mesenteric, ileocolic, and mesocolic.

The *mesenteric lymph-glands* lie between the layers of the mesentery. They vary from one hundred to one hundred and fifty in number, and consist of three sets, viz.: one lying close to the wall of the small intestine, amongst the terminal twigs of the superior mesenteric artery; a second, in relation

* J. K. Jamieson and J. F. Dobson, *Lancet*, April 20 and 27, 1907.

CC-0. In Public Domain. Gurukul Kangri Collection, Haridwar

Digitized by Arya Samaj Foundation Chennai and eGangotri

to the loops and primary branches of the jejunal and ileal vessels; and a third along the upper part of the trunk of the superior mesenteric artery.

Applied Anatomy.—Enlargement of the mesenteric lymph-glands is seen in most ulcerated conditions of the intestinal tract, and is well marked in enteric fever, tuberculous ulceration or malignant growths of the bowel. The enlarged lymph-glands can often be felt pushed through the wall of the abdomen.

The *ileocolic lymph-glands* (figs. 769, 770), from ten to twenty in number, form a chain around the ileocolic artery, but show a tendency to subdivision into two groups, one near the duodenum and another on the lower part of

FIG. 768.—The lymphatics of the stomach, &c. The stomach has been turned upwards. (Jamieson and Dobson.)

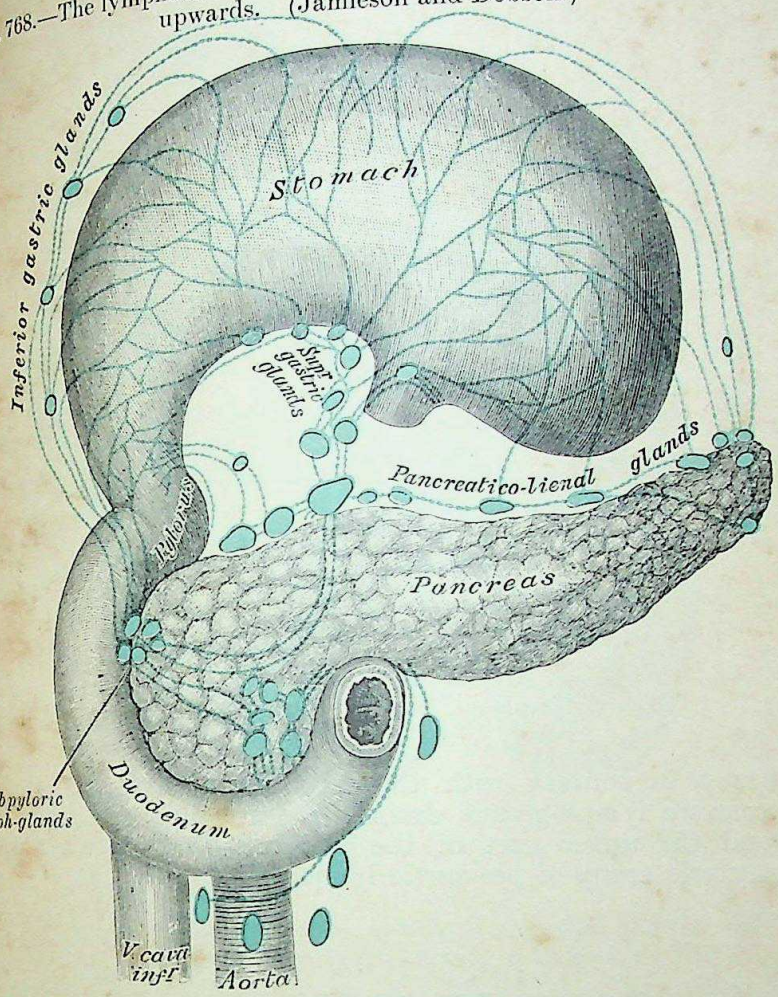

the trunk of the artery. Where the vessel divides into its terminal branches the chain is broken up into several groups, viz.: (*a*) *ileal*, in relation to the ileal branch of the artery; (*b*) *anterior ileocolic*, usually of three glands, in the ileocolic fold, near the wall of the cæcum; (*c*) *posterior ileocolic*, mostly placed in the angle between the ileum and the colon, but partly lying behind the cæcum at its junction with the ascending colon; (*d*) a single gland in the mesenteriole of the vermiform process; (*e*) *right colic*, along the medial side of the ascending colon.

The *mesocolic lymph-glands* are numerous, and lie between the layers of the transverse mesocolon, in close relation to the transverse colon; they are most developed in the neighbourhood of the right and left colic flexures. One or two small lymph-glands are occasionally seen along the trunk of the right colic artery, and others are found in relation to the trunk and branches of the middle colic artery.

The superior mesenteric lymph-glands receive afferents from the jejunum, ileum, cæcum, vermiform process, and the ascending and transverse parts of the

CC-0. In Public Domain. Gurukul Kangri Collection, Haridwar

Digitized by Arya Samaj Foundation Chennai and eGangotri

colon; their efferents pass to the superior mesenteric group of pre-aortic lymph-glands.

The **inferior mesenteric lymph-glands** (fig. 771) consist of: (a) glands on the branches of the left colic and sigmoid arteries; (b) a group on the sigmoid mesocolon, around the superior hæmorrhoidal artery; and (c)

FIG. 769.—The lymphatics of the cæcum and vermiform process. Anterior aspect. (Jamieson and Dobson.)

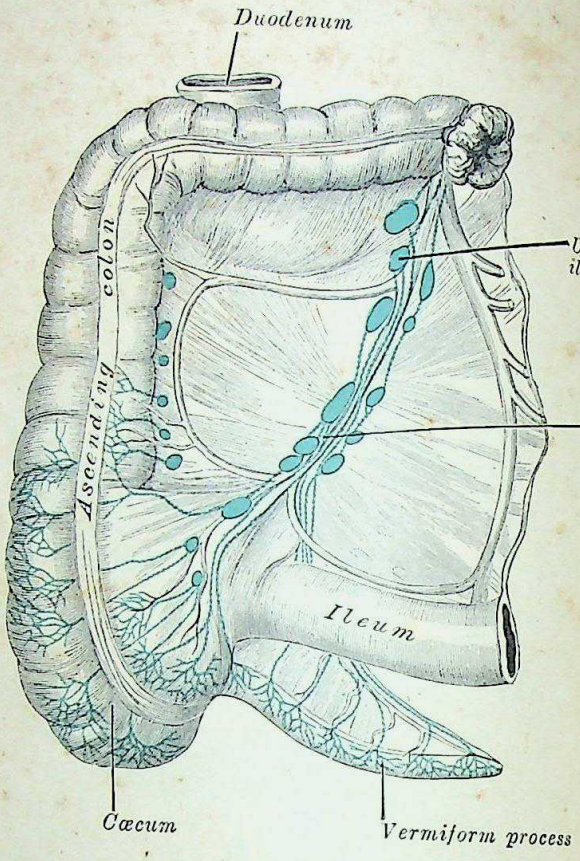

pararectal group in contact with the muscular coat of the rectum. The inferior mesenteric lymph-glands drain the descending and sigmoid parts of the colon and the upper part of the rectum; their efferents pass to the inferior mesenteric group of pre-aortic lymph-glands.

THE LYMPHATIC VESSELS OF THE ABDOMEN AND PELVIS

The lymphatic vessels of the abdomen and pelvis may be divided into 1. parietal and 2. visceral.

1. The **parietal lymphatic vessels** consist of two sets, superficial and deep.

The *superficial lymphatic vessels* follow the course of the superficial blood-vessels, and converge to the axillary and the superficial inguinal lymph-glands: those from the skin above the level of the umbilicus pass to the pectoral and subscapular groups of axillary lymph-glands; those derived from the skin of the front of the abdomen below the umbilicus follow the course of the superficial epigastric vessels, and those from the sides of the lumbar part of the abdominal wall pass along the crest of the ilium, with the superficial iliac circumflex vessels. The superficial lymphatic vessels of the glutæal region turn horizontally round the buttock, and join the superficial inguinal and subinguinal lymph-glands.

The *deep lymphatic vessels* run alongside the principal blood-vessels. Those of the parietes of the pelvis, which accompany the superior and inferior glutæal

CC-0. In Public Domain. Gurukul Kangri Collection, Haridwar

Digitized by Arya Samaj Foundation Chennai and eGangotri

and obturator vessels, follow the course of the hypogastric artery, and ultimately join the lateral aortic lymph-glands.

The *lymphatic vessels of the perinæum and external genitals.*—The lymphatic vessels of the perinæum, of the skin of the penis, and of the scrotum (or vulva) follow the course of the external pudendal vessels, and end in the superficial inguinal and subinguinal lymph-glands. Those of the glans penis (vel clitoridis) terminate partly in the deep subinguinal lymph-glands and partly in the external iliac lymph-glands.

The **visceral lymphatic vessels** consist of: (1) those of the subdiaphragmatic portion of the digestive tube and its associated glands, the liver and pancreas; (2) those of the spleen and suprarenal glands; (3) those of the urinary organs; (4) those of the reproductive organs.

FIG. 770.—The lymphatics of the cæcum and vermiform process. Posterior aspect. (Jamieson and Dobson.)

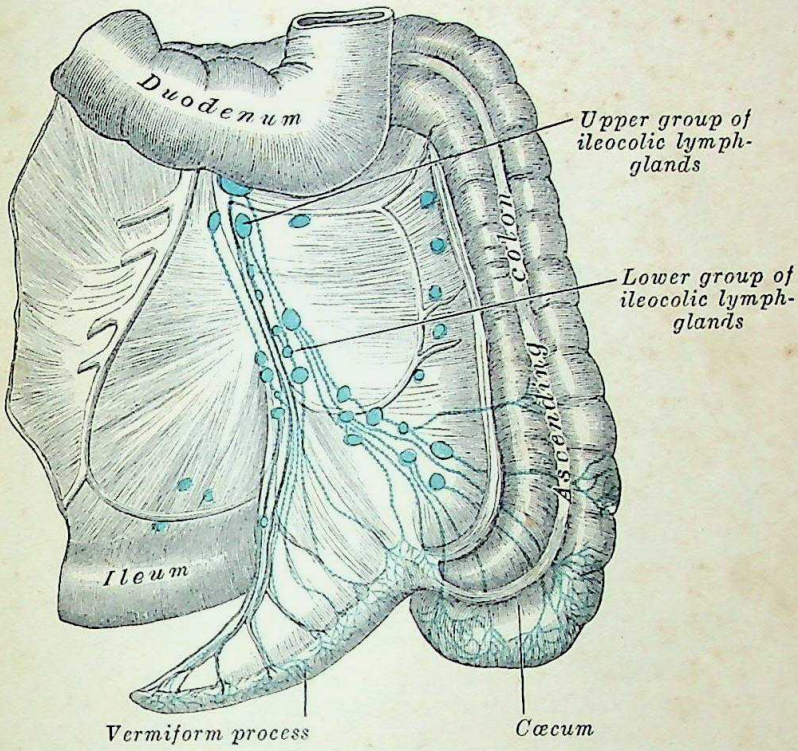

(1) The *lymphatic vessels of the subdiaphragmatic portion of the digestive tube* are situated partly in the submucous tissue and partly in the serous muscular coats, but as the former system drains into the latter, the two may be considered as one.

The *lymphatic vessels of the stomach* (figs. 767, 768) are continuous at the cardiac orifice with those of the œsophagus, and at the pylorus with those of the duodenum. They mainly follow the blood-vessels, and may be arranged in four sets. The first set accompanies the branches of the left gastric artery, receives tributaries from a large area on both surfaces of the stomach, and terminates in the superior gastric lymph-glands. Those of the second set drain the fundus and body of the stomach on the left of a line drawn vertically from the œsophagus; they accompany, more or less closely, the short gastric and left gastro-epiploic arteries, and end in the pancreaticolienal lymph-glands. The third set drains the right part of the greater curvature as far as the pyloric portion, and ends in the inferior gastric lymph-glands, the efferents of which pass to the subpyloric group. Those of the fourth set drain the pyloric portion and pass to the hepatic, subpyloric, and superior gastric lymph-glands.

The *lymphatic vessels of the duodenum* consist of an anterior and a posterior set, which open into a series of small *pancreaticoduodenal lymph-glands*, on the anterior and posterior aspects of the groove between the head of the pancreas

CC-0. In Public Domain. Gurukul Kangri Collection, Haridwar

Digitized by Arya Samaj Foundation Chennai and eGangotri

and the duodenum. The efferents of these glands run in two directions, upwards to the hepatic lymph-glands, and downwards to the pre-aortic lymph-glands around the origin of the superior mesenteric artery.

The *lymphatic vessels of the jejunum and ileum* are termed *lacteals*, from the milk-white fluid they contain during intestinal digestion. They run between the layers of the mesentery and enter the mesenteric glands, the efferents from which end in the pre-aortic lymph-glands.

The *lymphatic vessels of the vermiform process and cæcum* (figs. 769, 771) are numerous, since in the wall of the vermiform process there is a large amount of lymphoid tissue. From the body and tail of the vermiform process eight to

Fig. 771.—The lymphatics of the colon. (Jamieson and Dobson.)

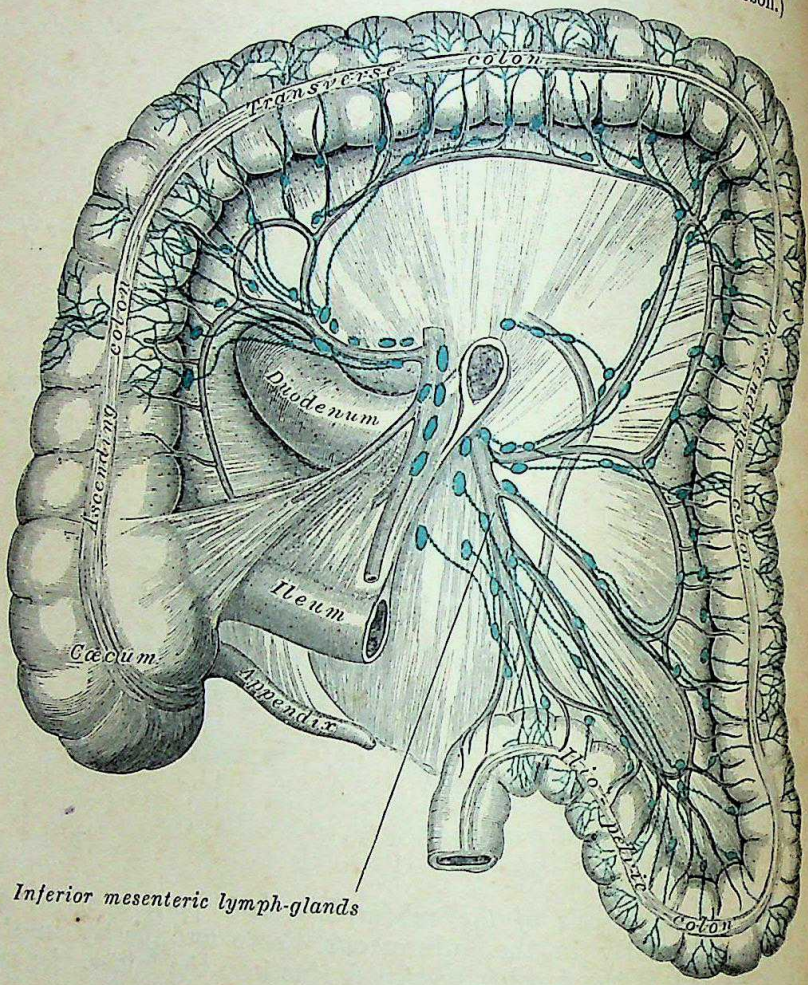

fifteen vessels ascend between the layers of the mesenteriole, one or two being interrupted in the lymph-gland which lies between the layers of this peritoneal fold. They unite to form three or four vessels, which end partly in the lower and partly in the upper lymph-glands of the ileocolic chain. The vessels from the root of the vermiform process and from the cæcum consist of an anterior and a posterior group. The anterior vessels pass in front of the cæcum, and end in the anterior ileocolic lymph-glands and in the upper and lower lymph-glands of the ileocolic chain; the posterior vessels ascend over the back of the cæcum and terminate in the posterior ileocolic lymph-glands and in the lower lymph-glands of the ileocolic chain.

Lymphatic vessels of the colon (fig. 771).—The lymphatic vessels of the ascending and transverse parts of the colon end in the mesenteric lymph-glands, after traversing the right colic and mesocolic lymph-glands. Those of the descending and sigmoid parts of the colon are interrupted by the small lymph-glands on the branches of the left colic and sigmoid arteries, and ultimately end in the pre-aortic lymph-glands around the origin of the inferior mesenteric artery.

CC-0. In Public Domain. Gurukul Kangri Collection, Haridwar

Digitized by Arya Samaj Foundation Chennai and eGangotri

in the external iliac lymph-glands, and another from the anterior surface joins the vessels which drain the membranous part of the urethra.

Lymphatic vessels of the urethra.—The lymphatics of the *cavernous* portion of the urethra accompany those of the glans penis, and end with them in the superficial and deep subinguinal and external iliac lymph-glands. Those of the *membranous* and *prostatic* portions, and those of the whole urethra in the female, pass to the hypogastric lymph-glands.

FIG. 773.—The lymphatics of the prostate. (Cunéo and Marcille.)

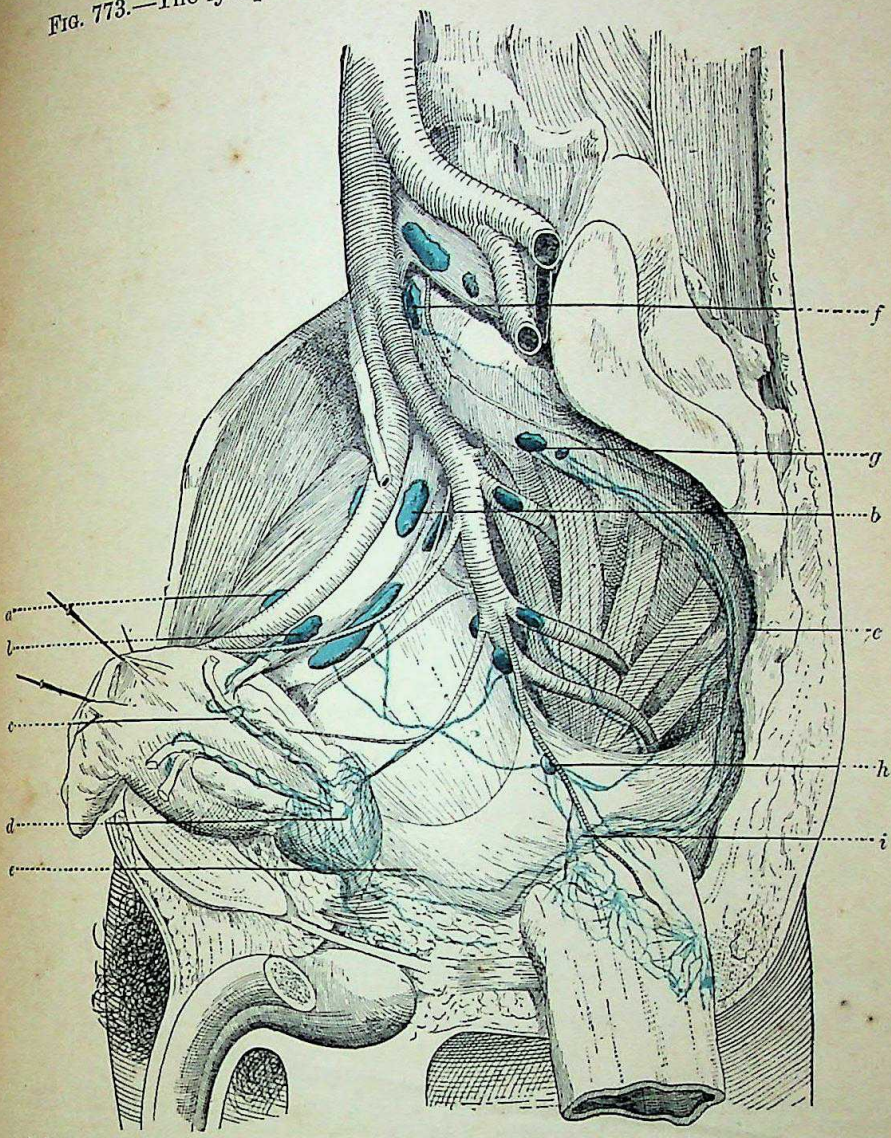

a, b. External iliac lymph-glands. *c.* Vessel draining into external iliac lymph-glands. *d.* Retro-prostatic lymph-glands. *e.* Vessels draining into lymph-gland on sacral promontory. *f.* Lymph-gland in front of sacral promontory. *g.* Lateral sacral lymph-glands. *h.* Middle hæmorrhoidal lymph-gland. *i.* Middle hæmorrhoidal lymphatic vessels.

(4) *The lymphatic vessels of the reproductive organs.*

The *lymphatic vessels of the testis* consist of two sets, superficial and deep, the former commencing on the surface of the tunica vaginalis, the latter in the epididymis and body of the testis. They form from four to eight collecting trunks which ascend with the testicular veins in the spermatic cord and along the front of the Psoas major, to end in the lateral and pre-aortic groups of lumbar lymph-glands.*

The *lymphatic vessels of the ductus deferens* pass to the external iliac lymph-glands; those of the *vesiculæ seminales* go partly to the hypogastric and partly to the external iliac lymph-glands.

* 'The lymphatics of the testicle,' by J. K. Jamieson and J. F. Dobson, *Lancet*, Feb. 19, 1900.

CC-0. In Public Domain. Gurukul Kangri Collection, Haridwar

Digitized by Arya Samaj Foundation Chennai and eGangotri

The *lymphatic vessels of the ovary* are similar to those of the testis and ascend with the ovarian artery to the lateral and pre-aortic lymph-glands.

The *lymphatic vessels of the uterine tube* pass partly with those of the ovary and partly with those of the uterus.

The *lymphatic vessels of the uterus* (fig. 774) consist of two sets, superficial and deep, the former being placed beneath the peritoneum, the latter in the substance of the organ. The lymphatics of the cervix uteri run in three directions: transversely to the external iliac lymph-glands, posterolaterally

FIG. 774.—The lymphatics of the uterus. (Cunéo and Marcille.)

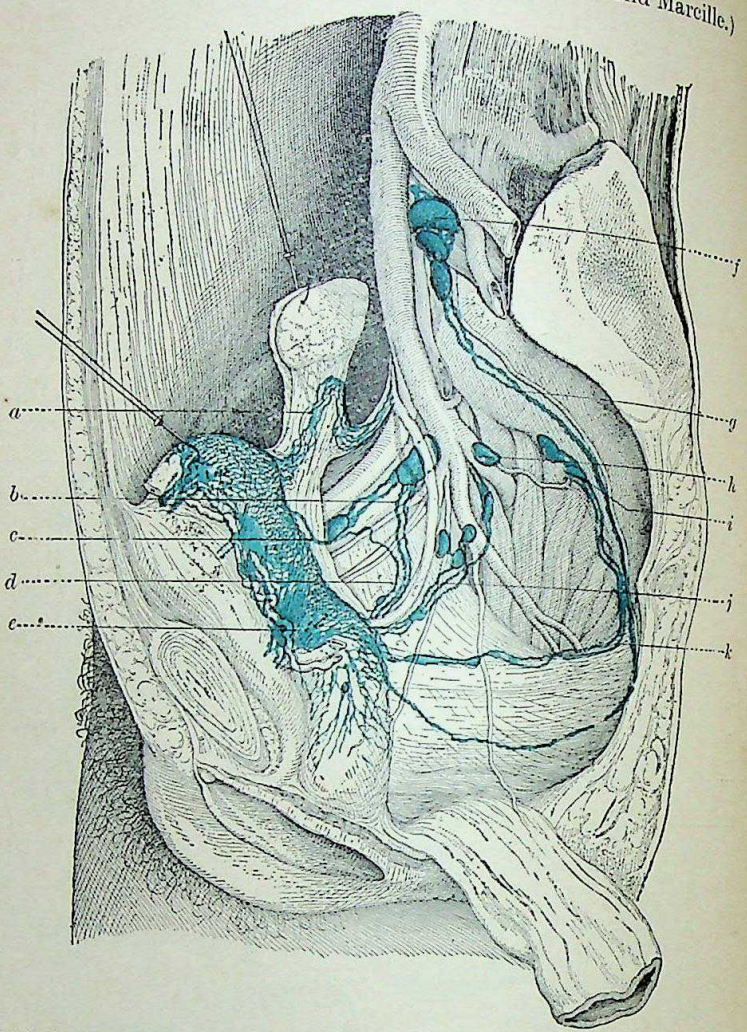

a. Efferents to lateral aortic lymph-glands. *b, c, d*. Efferents to external iliac lymph-glands. *e*. Network on lateral aspect of cervix uteri. *f*. Lymph-glands in front of sacral promontory. *g*. Efferents to lymph-glands in front of sacral promontory. *h*. Hypogastric lymph-glands. *i*. Lateral sacral lymph-glands. *j*. Vessels draining into hypogastric lymph-glands. *k*. Vessels passing to lateral sacral lymph-glands.

to the hypogastric lymph-glands, and posteriorly to the common iliac lymph-glands. The majority of the vessels of the body and fundus of the uterus pass lateralwards in the upper parts of the broad ligaments, and ascend alongside the ovarian vessels to the lateral and pre-aortic lymph-glands; a few, however, run to the external iliac lymph-glands, and one or two run along the round ligament of the uterus to the superficial inguinal lymph-glands. In the unimpregnated uterus the lymphatic vessels are very small, but during gestation they are greatly enlarged.

The *lymphatic vessels of the vagina* are carried in three directions: those of the upper part to the external iliac lymph-glands, those of the middle part to the hypogastric lymph-glands, and those of the lower part to the common iliac lymph-glands. On the course of the vessels from the middle and lower parts small lymph-glands are situated. Some lymphatic vessels from the

CC-0. In Public Domain. Gurukul Kangri Collection, Haridwar

Digitized by Arya Samaj Foundation Chennai and eGangotri

lower part of the vagina join those of the vulva and pass to the superficial inguinal lymph-glands. The lymphatic vessels of the vagina anastomose with those of the cervix uteri, vulva, and rectum, but not with those of the bladder.

THE LYMPH-GLANDS OF THE THORAX

The **lymph-glands of the thorax** may be divided into: 1. parietal and 2. visceral—the former being situated in the thoracic wall, the latter in relation to the viscera.

1. The **parietal lymph-glands** include the sternal, intercostal, and diaphragmatic glands.

(*a*) The **sternal or internal mammary lymph-glands** are four or five in number on each side, and are placed (fig. 775) at the anterior ends of the intercostal spaces, by the side of the internal mammary artery.* They derive afferents from the mamma, from the deeper structures of the anterior abdominal wall above the level of the umbilicus, from the upper surface of the liver through a small group of lymph-glands which lies behind the xiphoid process, and from the deeper parts of the anterior portion of the thoracic wall. Their efferents usually unite to form a single trunk on either side; this may open directly into the junction of the internal jugular and subclavian veins, or that of the right side may join the right subclavian trunk, and that of the left the thoracic duct.

FIG. 775.—The right sternal or internal mammary lymph-glands (E. P. Stibbe).

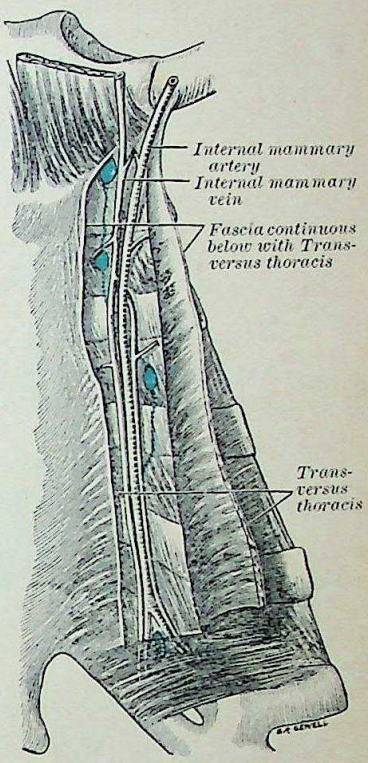

(*b*) The **intercostal lymph-glands** lie in the posterior parts of the intercostal spaces and in front of the heads of the ribs. They receive the deep lymphatics from the posterolateral aspect of the chest; some of these vessels are interrupted by small lateral intercostal lymph-glands. The efferents of the lymph-glands in the lower four or five spaces unite to form a trunk, which descends and opens either into the cisterna chyli or into the commencement of the thoracic duct. The efferents of the lymph-glands in the upper spaces of the left side end in the thoracic duct; those of the corresponding right spaces, in the right lymphatic duct.

(*c*) The **diaphragmatic lymph-glands** lie on the thoracic aspect of the Diaphragm, and consist of three sets, anterior, middle, and posterior.

The *anterior* set comprises (*a*) two or three small lymph-glands behind the base of the xiphoid process, which receive afferents from the convex surface of the liver, and (*b*) one or two lymph-glands on either side near the junction of the seventh rib with its cartilage, which receive lymphatic vessels from the front part of the Diaphragm. The efferent vessels of the anterior set pass to the sternal lymph-glands.

The *middle* set consists of two or three lymph-glands on either side close to where the phrenic nerves enter the Diaphragm. On the right side some of the lymph-glands of this group lie within the fibrous wall of the pericardium, on the front of the termination of the inferior vena cava. The afferents of this set are derived from the middle part of the Diaphragm, those on the right side also receiving afferents from the convex surface of the liver. Their efferents pass to the posterior mediastinal lymph-glands.

The *posterior* set consists of a few lymph-glands situated on the back of the crura of the Diaphragm, and connected on the one hand with the lumbar lymph-glands, and on the other with the posterior mediastinal lymph-glands.

CC-0. In Public Domain. Gurukul Kangri Collection, Haridwar

* E. P. Stibbe, *Journal of Anatomy*, vol. 52.

Digitized by Arya Samaj Foundation Chennai and eGangotri

2. The **visceral lymph-glands** consist of three groups, viz. anterior mediastinal, posterior mediastinal, and tracheobronchial.

The **anterior mediastinal lymph-glands** are placed in the anterior part of the superior mediastinal cavity, in front of the aortic arch and in relation to the innominate veins and the large arterial trunks which arise from the aortic arch. They receive afferents from the thymus and pericardium, and from the sternal lymph-glands; their efferents unite with those of the tracheobronchial lymph-glands, to form the right and left bronchomediastinal trunks.

FIG. 776.—The tracheobronchial lymph-glands. (From a figure designed by M. Hallé.)

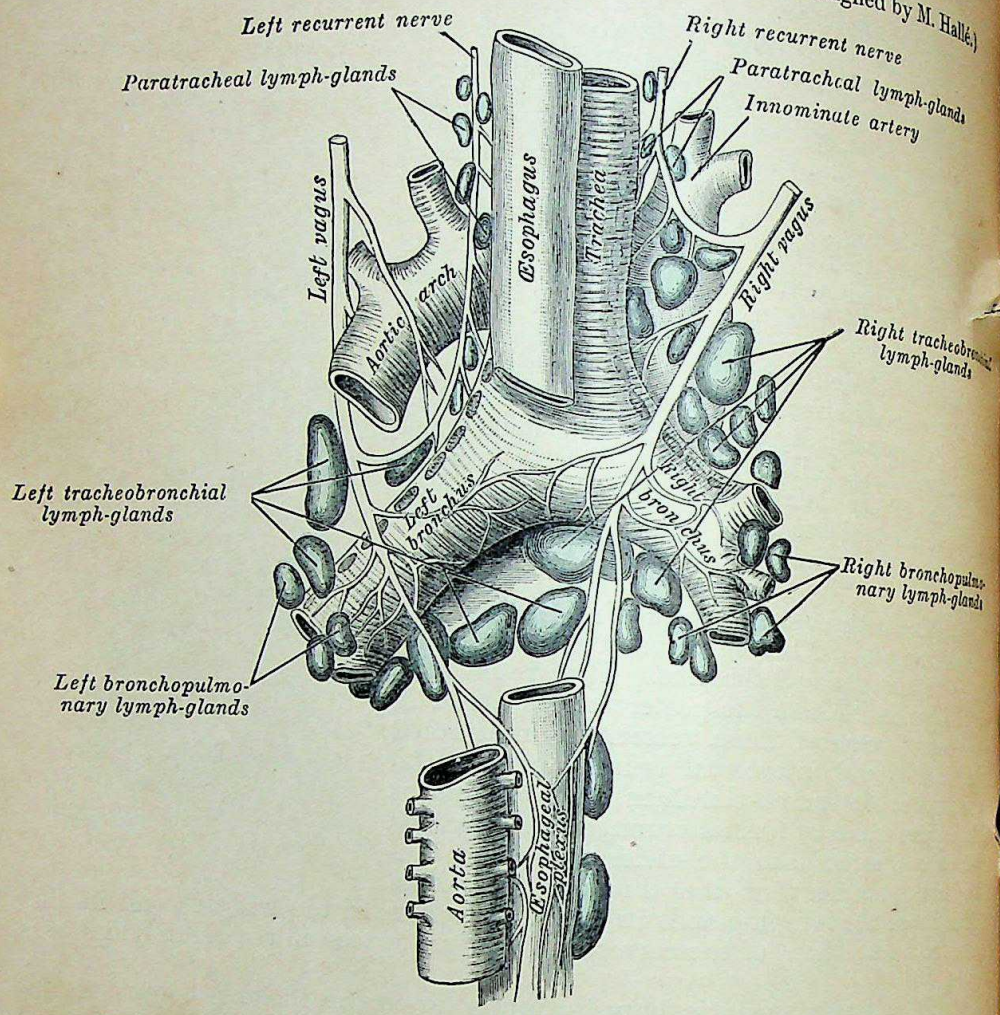

The **posterior mediastinal lymph-glands** lie behind the pericardium in relation to the œsophagus and descending thoracic aorta. Their afferents are derived from the œsophagus, the posterior part of the pericardium, the Diaphragm, and the convex surface of the liver. Their efferents mostly end in the thoracic duct, but some join the tracheobronchial lymph-glands.

The **tracheobronchial lymph-glands** (fig. 776) form four main groups, and include some of the largest lymph-glands in the body: (*a*) *tracheal*, on either side of the trachea; (*b*) *bronchial*, in the angles between the lower part of the trachea and bronchi, and in the angle between the two bronchi; (*c*) *bronchopulmonary*, in the hilum of each lung; and (*d*) *pulmonary*, in the lung substance, on the larger branches of the bronchi. The afferents of the tracheobronchial lymph-glands drain the lungs and bronchi, the thoracic part of the trachea, and the heart; some of the efferents of the posterior mediastinal lymph-glands also end in this group. Their efferent vessels ascend upon the trachea and unite with efferents of the internal mammary and anterior mediastinal lymph-glands to form the *right* and *left bronchomediastinal trunks*. The right bronchomediastinal trunk may join the right lymphatic duct, and

CC-0. In Public Domain. Gurukul Kangri Collection, Haridwar

Digitized by Arya Samaj Foundation Chennai and eGangotri

the left the thoracic duct, but more frequently they open independently of these ducts into the junction of the internal jugular and subclavian veins of their own side.

Applied Anatomy.—In all town-dwellers there are continually being swept into these lymph-glands from the bronchi and alveoli large quantities of the dust and black carbonaceous pigment that are so freely inhaled in cities. At first the lymph-glands are considerately enlarged, firm, inky black and gritty on section; later they enlarge still further, often becoming fibrous from the irritation set up by the minute foreign bodies with which they are crammed, and may break down into a soft slimy mass or may calcify. In tuberculosis of the lungs these lymph-glands are practically always infected; they enlarge, being filled with tuberculous deposits that may soften, or become fibrous, or calcify. Not infrequently an enlarged tuberculous lymph-gland perforates into a bronchus, discharging its contents into the tube. When this happens there is great danger of acute pulmonary tuberculosis, the infecting gland-substance being rapidly spread throughout the bronchial system by the coughing its presence in the air-passages excites.

Tuberculous infection with considerable enlargement of the tracheobronchial glands is common in children. It produces a characteristic patch of impaired resonance on percussion, with increase in the vocal fremitus and resonance and harsh bronchial breathsounds, over a diamond-shaped area on the back about the region of the third, fourth and fifth thoracic vertebral spines. It is thought, too, that enlargement of these glands produces an irritative dry cough in children, by pressure on the pulmonary nerves in their neighbourhood.

THE LYMPHATIC VESSELS OF THE THORAX

The lymphatic vessels of the thorax may be divided into: 1. those of the thoracic wall and 2. those of the thoracic viscera.

1. The *superficial lymphatic vessels of the thoracic wall* ramify beneath the skin and converge to the axillary lymph-glands. Those over the Trapezius and Latissimus dorsi run forwards and unite to form about ten or twelve trunks which end in the subscapular group. Those over the pectoral region, including the vessels from the skin covering the peripheral part of the mamma, run backwards, and those over the Serratus anterior upwards, to the pectoral group. Others near the lateral margin of the sternum pass inwards between the rib cartilages and end in the sternal lymph-glands, while the vessels of opposite sides anastomose across the front of the sternum. A few vessels from the upper part of the pectoral region ascend over the clavicle to the inferior deep cervical lymph-glands.

The *lymphatic vessels of the mamma* originate in a plexus in the interlobular spaces and on the walls of the galactophorous ducts. Those from the central part of the mamma pass to an intricate plexus situated beneath the areola, a plexus which receives also the lymphatics from the skin over the central part of the mamma and those from the areola and nipple. Its efferents are collected into two trunks which pass to the pectoral group of axillary lymph-glands. The vessels which drain the medial part of the mamma pierce the thoracic wall and end in the sternal lymph-glands, while a vessel occasionally emerges from the upper part of the mamma, and, piercing the Pectoralis major, terminates in the subclavicular lymph-glands (fig. 761).

The *deep lymphatic vessels of the thoracic wall* consist of:

(*a*) The lymphatic vessels of the muscles which lie on the ribs: most of these end in the axillary lymph-glands, but some from the Pectoralis major pass to the sternal lymph-glands. (*b*) The intercostal lymphatic vessels which drain the Intercostales and parietal pleura. Those draining the Intercostales externi run backwards and, after receiving the vessels which accompany the posterior branches of the intercostal arteries, end in the intercostal lymph-glands. Those of the Intercostales interni and parietal pleura consist of a single trunk in each space. These trunks run forwards in the subpleural tissue, and the upper six open separately into the sternal lymph-glands or into the vessels which unite them; while those of the lower spaces join to form a single trunk which terminates in the lowest of the sternal lymph-glands. (*c*) The lymphatic vessels of the Diaphragm, which form two plexuses, one on its thoracic and another on its abdominal surface; these plexuses anastomose freely with each other, and are best marked on the parts covered respectively by the pleuræ and

CC-0. In Public Domain. Gurukul Kangri Collection, Haridwar

Digitized by Arya Samaj Foundation Chennai and eGangotri

peritoneum. The plexus on the thoracic surface unites with the lymphatics of the costal and mediastinal parts of the pleura, and its efferents consist of three groups: anterior, passing to the lymph-glands which lie near the junction of the seventh rib with its cartilage; middle, to the lymph-glands on the œsophagus and to those around the termination of the inferior vena cava; and posterior, to the lymph-glands which surround the aorta at the point where this vessel leaves the thoracic cavity. The plexus on the abdominal surface is composed of fine vessels, and anastomoses with the lymphatics of the liver and, at the periphery of the Diaphragm, with those of the subperitoneal tissue. The efferents from the right half of this plexus terminate partly in a group of lymph-glands on the trunk of the corresponding inferior phrenic artery, while others end in the right lateral aortic lymph-glands. Those from the left half of the plexus pass to the pre-aortic and lateral aortic lymph-glands and to the lymph-glands on the terminal portion of the œsophagus.

2. The *lymphatic vessels of the thoracic viscera* comprise those of the heart and pericardium, lungs and pleura, thymus, and œsophagus.

The *lymphatic vessels of the heart* consist of two plexuses: (*a*) deep, immediately under the endocardium, and (*b*) superficial, subjacent to the visceral pericardium. The deep plexus opens into the superficial, the efferents of which form left and right collecting trunks. The *left* trunks, two or three in number, ascend in the anterior longitudinal sulcus, receiving, in their course, vessels from both ventricles. On reaching the coronary sulcus they are joined by a large trunk from the diaphragmatic surface of the heart, and then unite to form a single vessel which ascends between the pulmonary artery and the left atrium, and ends in one of the tracheobronchial lymph-glands. The *right* trunk receives its afferents from the right atrium and from the right border and diaphragmatic surface of the right ventricle. It ascends in the posterior longitudinal sulcus and then runs forward in the coronary sulcus, and passes up behind the pulmonary artery, to end in one of the tracheobronchial lymph-glands.

The *lymphatic vessels of the lungs* originate in two plexuses, a superficial and a deep. The superficial plexus is placed beneath the pulmonary pleura; the deep accompanies the branches of the pulmonary vessels and the ramifications of the bronchi. In the case of the larger bronchi the deep plexus consists of two networks—a submucous, beneath the mucous membrane, and a peribronchial, outside the walls of the bronchi. In the smaller bronchi there is but a single plexus, which extends as far as the bronchioles, but fails to reach the alveoli, in the walls of which there are no traces of lymphatic vessels. The superficial efferents turn round the borders of the lungs and the margins of their fissures, and converge to end in some lymph-glands situated at the hilum; the deep efferents are conducted to the hilum along the pulmonary vessels and bronchi, and end in the tracheobronchial lymph-glands. Little or no anastomosis occurs between the superficial and deep lymphatics of the lungs, except in the region of the hilum.

The *lymphatic vessels of the pleura* consist of two sets—one in the visceral and another in the parietal part of the membrane. Those of the visceral pleura drain into the superficial efferents of the lung, while those of the parietal pleura have three modes of ending, viz.: (*a*) those of the costal portion join the lymphatics of the Intercostales interni and so reach the sternal lymph-glands; (*b*) those of the diaphragmatic part are drained by the efferents of the Diaphragm; while (*c*) those of the mediastinal portion end in the posterior mediastinal lymph-glands.

The *lymphatic vessels of the thymus* end in the anterior mediastinal, tracheobronchial, and sternal lymph-glands.

The *lymphatic vessels of the œsophagus* form a plexus round that tube, and the collecting vessels from the plexus drain into the posterior mediastinal lymph-glands.

CC-0. In Public Domain. Gurukul Kangri Collection, Haridwar

Digitized by Arya Samaj Foundation Chennai and eGangotri

NEUROLOGY

THE **nervous system** is the most complicated and highly organised of the human body. It is built up of nervous and non-nervous tissues—the former consisting of nerve-cells and nerve-fibres, the latter of neuroglia and blood-vessels, together with certain enveloping membranes.

The minute structure of the nervous elements and neuroglia is described on pp. 32 to 39, and an outline of the development of the nervous system is given on pp. 85 to 100.

The nervous system can be resolved into two subsidiary systems, the cerebrospinal and the autonomic, which however are intimately intermingled.

The **cerebrospinal system** is composed of a central and a peripheral part. The *central part* consists of an upper expanded portion, the *encephalon* or *brain*, contained within the cranium, and a lower, elongated, cylindrical portion, the *medulla spinalis* or *spinal cord*, lodged in the upper part of the vertebral canal. The two portions are united at the level of the upper border of the atlas vertebra, and together constitute the *central nervous system* or *cerebrospinal axis*. The peripheral part consists of the cerebrospinal nerves which unite the central nervous system to the various parts of the body, and are associated with the functions of the special and general senses, and with the voluntary movements of the body. There are forty-three pairs of these nerves—twelve *cerebral*, attached to the brain, and thirty-one *spinal*, to the medulla spinalis. Three pairs of the cerebral nerves, viz. the olfactory, the optic, and the acoustic, are connected with special sense-organs, and differ somewhat in their arrangement from the others, as will be subsequently described. The other cerebral nerves and all the spinal nerves are composed of fibres which arise from nerve-cells situated either in the central nervous system or in ganglia on the roots of the nerves.

The **autonomic system** transmits impulses which govern the calibre of the blood-vessels, regulate the movements of the viscera and iris, stimulate the Arrectores pilorum and excite the secretory glands. Like the cerebrospinal system it consists of a central and a peripheral portion. The *central part* consists of groups of nerve-cells situated in certain regions of the central nervous system. The *peripheral part* is composed of fibres which arise from these nerve-cells, and emerge in certain of the cerebral and spinal nerves. The fibres of the autonomic system never run continuously from their origin in the central nervous system to their areas of distribution, but always end in ganglia; from the nerve-cells of these ganglia new fibres arise and pass to their areas of distribution without further interruption. Autonomic nerves, therefore, consist of (*a*) *preganglionic* fibres, usually medullated, which spring from cells in the central nervous system and end in ganglia, and (*b*) *postganglionic fibres*, usually non-medullated, arising from cells in these ganglia and passing to their areas of distribution. The autonomic system consists of two subsidiary systems, the parasympathetic and the sympathetic.

The *parasympathetic system* is found at the cranial and sacral ends of the autonomic system. The cranial parasympathetic fibres issue from groups of nerve-cells in the mid-brain and medulla oblongata, and run in the oculomotor, facial, glossopharyngeal, vagus and accessory cerebral nerves. The sacral parasympathetic fibres issue from cells in the sacral part of the medulla spinalis and run in the second, third and fourth sacral nerves to the nerve-plexuses of the pelvis.

The *sympathetic system* is represented by two chains of central ganglia, placed one on either side of the middle line of the vertebral column, and

CC-0. In Public Domain. Gurukul Kangri Collection, Haridwar

Digitized by Arya Samaj Foundation Chennai and eGangotri

connected centrally with nerve-cells in the thoracic and lumbar parts of the medulla spinalis; from the cells of the central ganglia peripheral fibres run to form intricate plexuses, in many of which ganglia are found; from these plexuses the ultimate branches of distribution arise.

The chief involuntary structures, *e.g.* glands, viscera, etc., receive a double nerve-supply, parasympathetic and sympathetic, and these two systems are physiologically antagonistic; thus impulses through the parasympathetic fibres inhibit, while those through the sympathetic fibres accelerate, the movements of the heart; again impulses through the parasympathetic fibres contract, while those through the sympathetic fibres dilate, the pupil.

The Structure of the Peripheral Nerves and Ganglia

The **cerebrospinal nerves** consist of numerous nerve-fibres collected into bundles which are enclosed in membranous sheaths (fig. 777); a small bundle of fibres is called a *funiculus*. Each funiculus is surrounded by a sheath, the *perineurium*;

Fig. 777.—A transverse section through two funiculi of a human tibial nerve. Stained with hæmatoxylin. ×30.

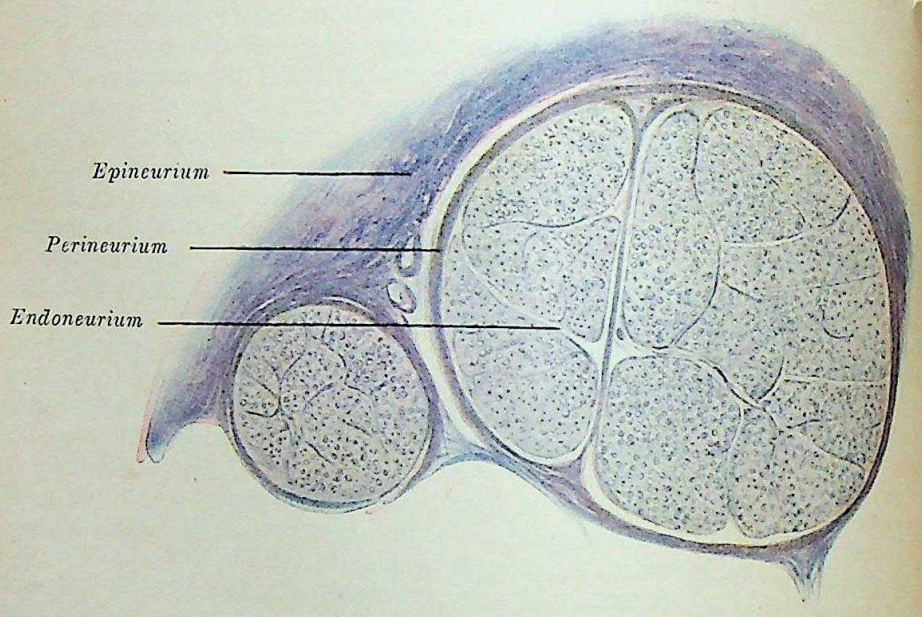

this consists of a fine, smooth, transparent membrane, made up of connective tissue, which has a lamellar arrangement; the sheath may be easily separated, in the form of a tube, from the fibres it encloses. The nerve-fibres are held together and supported within the funiculus by delicate connective tissue called the *endoneurium*; it is continuous with septa which pass inwards from the perineurium, and shows a ground substance in which are embedded fine bundles of fibrous connective tissue running for the most part longitudinally. If the nerve be small, it may consist of only a single funiculus; but if large, it consists of several funiculi held together and invested by connective tissue; this investment is known as the *epineurium*. The cerebrospinal nerves consist almost exclusively of medullated nerve-fibres, only a very small proportion of non-medullated fibres being present.

The blood-vessels supplying a nerve end in a minute plexus of capillaries which pierce the perineurium, and run, for the most part, parallel with the fibres; they are connected together by short, transverse vessels, forming narrow, oblong meshes, similar to the capillary system of muscle. Fine non-medullated nerve-fibres, *vasomotor fibres*, accompany these vessels, and break up into elementary fibrils which form a network around them. Medullated fibres, termed *nervi nervorum*, run in the epineurium and terminate in small spheroidal tactile corpuscles or end-bulbs of Krause.

CC-0. In Public Domain. Gurukul Kangri Collection, Haridwar

Digitized by Arya Samaj Foundation Chennai and eGangotri

The cerebrospinal nerve-fibres pursue an uninterrupted course from the centre to the periphery, but in separating a nerve into its component funiculi, it may be seen that bundles of fibres from one funiculus occasionally join, at a very acute angle, another funiculus proceeding in the same direction.

Nerves, in their course, subdivide into branches, and these frequently communicate with branches of neighbouring nerves; such communications form what is called a *nerve-plexus*. Sometimes a plexus is formed by the primary branches of the trunks of the nerves—as, for example, the cervical, brachial, lumbar, and sacral plexuses—and occasionally by the terminal funiculi, as in the plexuses formed at the periphery of the body. In the formation of a plexus, the component nerves divide, then join, and again subdivide in such a complex manner that the individual funiculi become intricately interlaced; so that each branch leaving a plexus may contain filaments from all the primary nervous trunks entering the plexus. In the formation also of smaller plexuses at the periphery of the body there is a free interchange of funiculi and fibres. In each case, however, the individual fibres remain separate and distinct.

Through this interchange of fibres, every nerve leaving a plexus gains a more extensive connexion with the medulla spinalis than if it had proceeded direct to its distribution without joining other nerves. Consequently the parts supplied by the nerves have more extended relations with the nervous centres; by this means groups of muscles may be associated for combined action.

The **autonomic nerves** consist largely of non-medullated fibres, collected in funiculi and enclosed in sheaths of connective tissue. There is, however, in these nerves a certain admixture of medullated fibres; thus, the cervical portions of the sympathetic trunk, and the splanchnic nerves contain many medullated preganglionic fibres.

The cerebrospinal and autonomic nerve-fibres convey various impressions. The *sensory* nerves, called also *centripetal* or *afferent* nerves, transmit to the nervous centres impressions made upon the peripheral ends of the nerves, and in this way the mind, through the medium of the brain, becomes conscious of external objects. The *centrifugal* or *efferent* nerves transmit impressions from the nervous centres to the parts to which they are distributed, these impressions either exciting muscular contraction, or influencing the process of secretion and possibly the processes of nutrition and growth.

Origins of nerves.—The origin of a nerve is in some cases single—that is to say, the whole nerve emerges from the nervous centre by a single root; in other instances the nerve arises by two or more roots. The point where the nerve-root or roots emerge from the surface of the nervous centre is named the *superficial* or *apparent* origin, but the fibres of the nerve can be traced to groups of nerve-cells in the grey substance of the nervous centre; these cell-groups constitute the *deep* or *real* origin of the nerve. The centrifugal or efferent nerve-fibres originate in the nerve-cells of the grey substance of the central nervous system, the axis-cylinder processes of these cells being prolonged to form the nerve-fibres. The centripetal or afferent nerve-fibres spring from nerve-cells in the organs of special sense (e.g. the retina) or from nerve-cells in the ganglia. Having entered the nerve-centre they branch and send their ultimate twigs among its cells, without, however, uniting with them.

Peripheral terminations of nerves.—Nerve-fibres terminate peripherally in various ways, and these may be conveniently studied in the sensory and motor nerves respectively. The terminations of the sensory nerves are dealt with in the section on the sense-organs.

Motor nerves can be traced to either unstriped or striped muscular fibres. In the *unstriped or involuntary muscles* the nerves divide into numerous branches which communicate and form fine plexuses. At the junctions of the branches small nucleated bodies (ganglion-cells) are situated. From the plexuses minute branches are given off, which divide and break up into the ultimate fibrils of which the nerves are composed. These fibrils course between the involuntary muscle-cells, and, according to Elischer, terminate on the surface of the cells, opposite the nuclei, in minute swellings.

In the *striped or voluntary muscle* the nerves enter the sheath of the muscle, break up into fibres or bundles of fibres which form plexuses, and gradually divide until, as a rule, a single nerve-fibre enters a single muscular fibre; if the muscular fibre be long, more than one nerve-fibre may enter it. Within the muscular fibre

CC-0. In Public Domain. Gurukul Kangri Collection, Haridwar

Digitized by Arya Samaj Foundation Chennai and eGangotri

the nerve ends in a special expansion, called by Kühne, who first described it accurately, a *motor end-plate* (fig. 778). The nerve-fibre, on approaching the muscular fibre, suddenly loses its medullary sheath, the neurolemma becomes continuous with the sarcolemma of the muscle, and only the axis-cylinder enters

FIG. 778.—Muscular fibres of *Lacerta viridis* with the terminations of nerves.

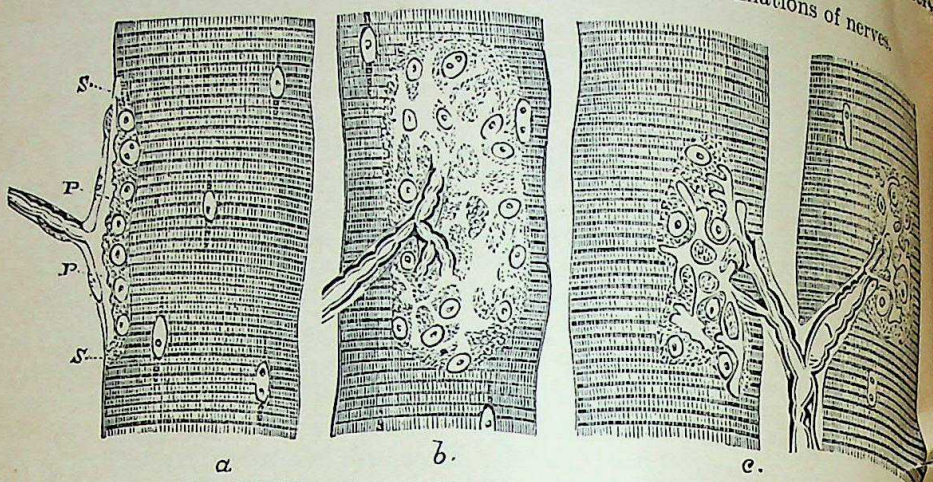

a. Seen in profile. P.P. The motor end-plate. S.S. The base of the plate, consisting of a granular mass with nuclei. *b*. The same as seen in looking at a perfectly fresh fibre, the nerve-ends being probably still excitable. (The forms of the variously divided plate can hardly be represented in a woodcut by sufficiently delicate and pale contours to reproduce correctly what is seen in Nature.) *c*. The same as seen two hours after death from poisoning by curare.

the muscular fibre. There it ramifies immediately beneath the sarcolemma, and becomes imbedded in a layer of granular matter, containing a number of clear oblong nuclei, the whole constituting a motor end-plate from which the contractile wave of the muscular fibre is said to start.

FIG. 779.—A transverse section through a human spinal ganglion. Stained with methyl blue. Note the brown pigment in some of the ganglion cells. ×60.

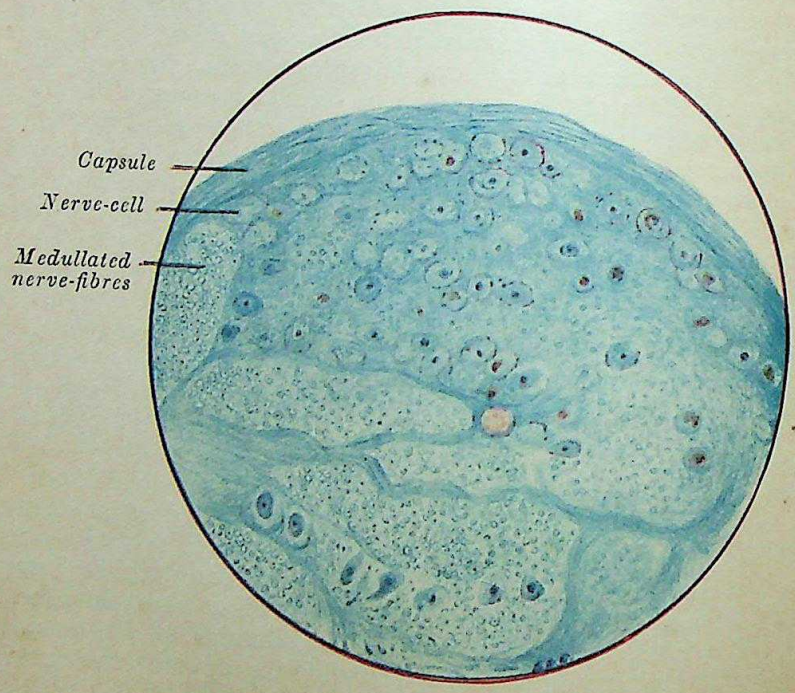

Ganglia are small aggregations of nerve-cells. They are found on the posterior roots of the spinal nerves; on the sensory roots of the trigeminal, facial, glossopharyngeal, and vagus nerves, and on the acoustic nerves. They are also found in connexion with the sympathetic nerves. They consist of a reddish-grey

CC-0. In Public Domain. Gurukul Kangri Collection, Haridwar

Digitized By Arya Samaj Foundation Chennai and eGangotri

substance, traversed by numerous white nerve-fibres, and vary considerably in form and size; the largest are found in the cavity of the abdomen; the smallest, not visible to the naked eye, exist in considerable numbers upon the nerves distributed to the viscera. Each ganglion is invested by a smooth, firm, membranous envelope, consisting of dense areolar tissue; this envelope is continuous with the perineurium of the nerves, and sends numerous processes into the interior of the ganglion.

Ganglia consist of nerve-cells and nerve-fibres. Each nerve-cell has a nucleated capsule which is continuous with the neurolemma of the nerve-fibre connected with the cell. The nerve-cells in the ganglia of the spinal nerves (figs. 779, 780) are spherical in shape, and each gives off a single fibre which runs towards the centre of the ganglion, and divides in a T-shaped manner; one limb of the cross-bar enters the medulla spinalis, the other passes outwards to the periphery. Some of these fibres are medullated, others are non-medullated. In the sympathetic ganglia (Fig. 781) the nerve-cells are multipolar, and each has one axis-cylinder process and several dendrons; the axon emerges from the ganglion as a non-medullated nerve-fibre; some dendrons form networks (glomeruli) within the cell-capsules; others pierce the cell-capsules. The spinal and sympathetic ganglia differ somewhat in the size and disposition of the nerve-cells and in the number of nerve-fibres entering and leaving them. In the spinal ganglia (fig. 779) the nerve-cells are much larger and for the most part collected in

Fig. 780.—Three types of nerve-cells from a spinal ganglion of a cat. Stained with hæmatoxylin and eosin. × 350. (The nuclei of the cells lining the capsule are shown in the left-hand figure only.)

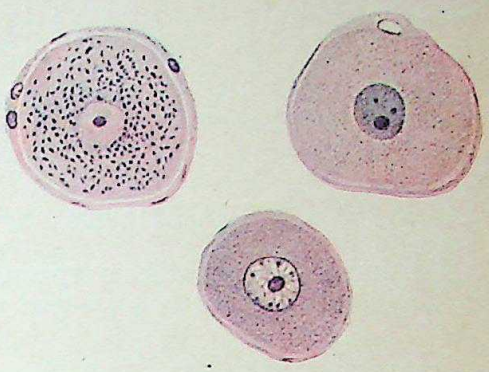

Fig. 781.—A section through a human sympathetic ganglion. Stained with hæmatoxylin and eosin. × 60.

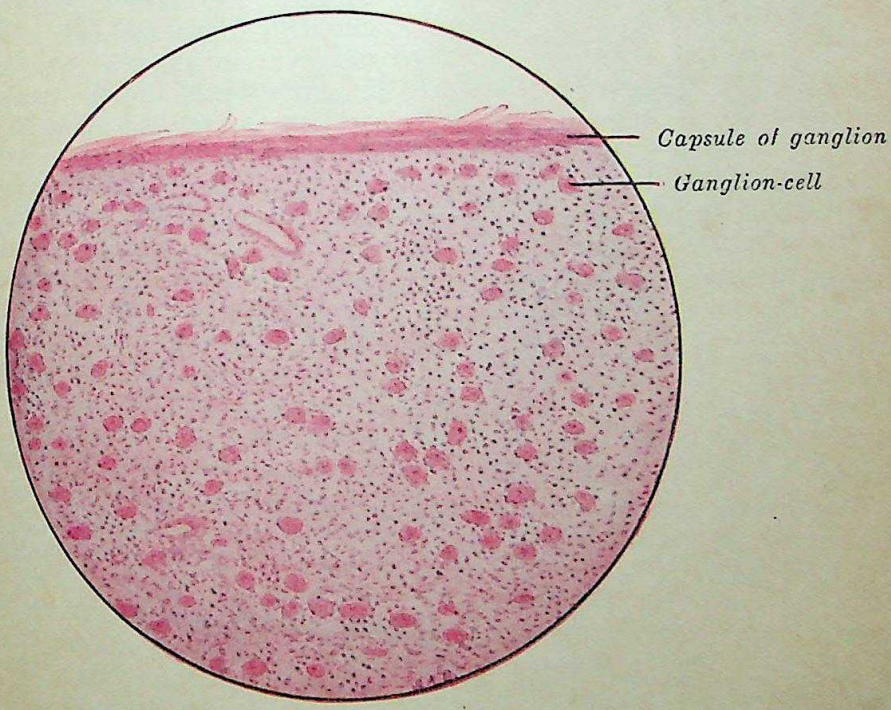

groups near the periphery, while the fibres, which are mostly medullated, traverse the central portion of the ganglion; in the sympathetic ganglia (fig. 781) the cells are smaller and distributed in irregular groups throughout the whole ganglion; the fibres also are irregularly scattered; some of those entering are medullated, while many leaving the ganglion are non-medullated.

CC-0. In Public Domain. Gurukul Kangri Collection, Haridwar

Digitized by Arya Samaj Foundation Chennai and eGangotri

Neuron theory.—The nerve-cell and its processes collectively constitute what is termed a *neuron*, and Waldeyer formulated the theory that the nervous system is built up of numerous neurons, 'anatomically and genetically independent of one another.' According to this *neuron theory* the processes of one neuron only come into contact, and are never in direct continuity, with those of other neurons; impulses being transmitted from one nerve-cell to another through the points of contact. This theory is based on the following facts, viz.: (1) each neuron is derived from a single embryonic nerve-cell or neuroblast; (2) when nervous tissues are stained by the Golgi method no continuity is seen even between neighbouring neurons; and (3) when degenerative changes occur in nervous tissue, either as the result of disease or experiment, they never spread from one neuron to another, but are limited to the individual neurons, or groups of neurons, primarily affected. It must, however, be added that the validity of the neuron theory has been called in question by certain eminent histologists who maintain that, by the employment of more delicate histological methods, minute fibrils can be followed from one nerve-cell into another.

The Medulla Spinalis or Spinal Cord

The **medulla spinalis** or **spinal cord** is the elongated, nearly cylindrical part of the central nervous system which occupies the upper two-thirds of the vertebral canal. Its average length in the male is 45 cm.; its weight is about 30 gms. It extends from the level of the upper border of the atlas vertebra to that of the lower border of the first, or upper border of the second, lumbar vertebra. Above, it is continuous with the brain; below, it ends in the *conus medullaris*, from the apex of which a delicate non-nervous filament, the *filum terminale*, descends as far as the first segment of the coccyx (fig. 782).

Fig. 782.—A sagittal section through the vertebral canal showing the lower end of the medulla spinalis and the filum terminale. (Testut.)

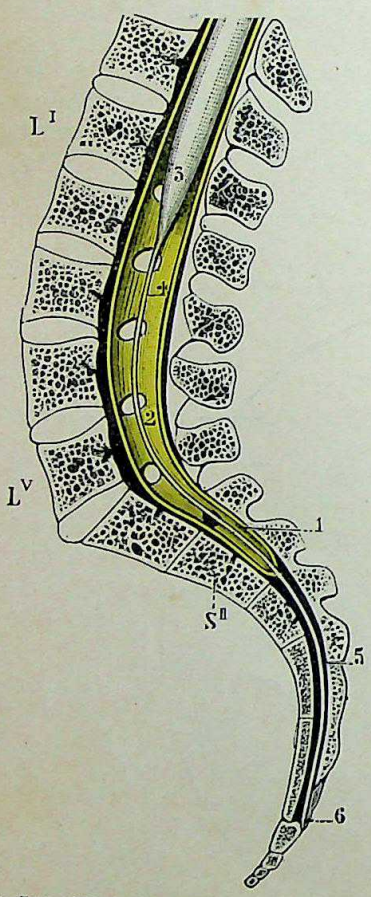

LI, LV. First and fifth lumbar vertebræ. SII. Second sacral vertebra. 1. Dura mater. 2. Lower part of tube of dura mater. 3. Lower end of medulla spinalis. 4. Intra-dural, and 5, extra-dural portions of filum terminale. 6. Attachment of filum terminale to first segment of coccyx.

The position of the medulla spinalis varies with the movements of the vertebral column, its lower extremity being raised slightly when the column is flexed. It also varies at different periods of life: in early fœtal life the medulla spinalis is as long as the vertebral canal, but after the embryo has attained a length of 30 mm. the vertebral column begins to grow farther caudalwards than the medulla spinalis, and the latter gradually assumes a higher position within the vertebral canal. The chief part of this upward migration occurs during the first half of fœtal life, so that by the twenty-fifth week of fœtal life the lower end of the medulla spinalis has ascended from the level of the second coccygeal vertebra to that of the third lumbar vertebra, *i.e.* a distance of nine segments, and there remain but two segments before the adult position is reached (Streeter). In the early embryo the nerve-roots pass transversely outwards to their respective intervertebral foramina, but owing to the relative inequality in the rates of growth of the medulla spinalis and vertebral column, the nerve-roots become more and more oblique in direction, so that in the adult the lumbar and sacral nerves descend almost vertically to reach their foramina. From the appearance these nerves present at their attachment to the medulla spinalis and from their great length they are collectively termed the *cauda equina* (fig. 784).

CC-0. In Public Domain. Gurukul Kangri Collection, Haridwar

Digitized by Arya Samaj Foundation Chennai and eGangotri

The medulla spinalis is ensheathed by three protective membranes separated from each other by spaces. The membranes are named from without inwards the dura mater, the arachnoid, and the pia mater (fig. 783). The *dura mater*, a strong, fibrous membrane, forms a wide, tubular sheath which extends below the termination of the medulla spinalis and ends in a pointed cul-de-sac at the level of the lower border of the second sacral vertebra. The dura mater is separated from the wall of the vertebral canal by the *epidural cavity*, which contains a quantity of areolar tissue, fat, and a plexus of veins; between the dura mater and the subjacent arachnoid is the *subdural cavity*, a capillary interval containing a small quantity of fluid, probably of the nature of lymph. The *arachnoid* is a thin, transparent sheath which ends at the lower border of the second sacral vertebra; it is separated from the pia mater by the *subarachnoid cavity*, which contains cerebrospinal fluid. The *pia mater* closely invests the medulla spinalis and sends delicate septa into its substance; from either side of the pia mater a fibrous band, named the *ligamentum denticulatum*, projects into the subarachnoid space, and is attached by a series of pointed processes to the inner surface of the dura mater.

Fig. 783.—A transverse section through the medulla spinalis and its membranes. Diagrammatic.

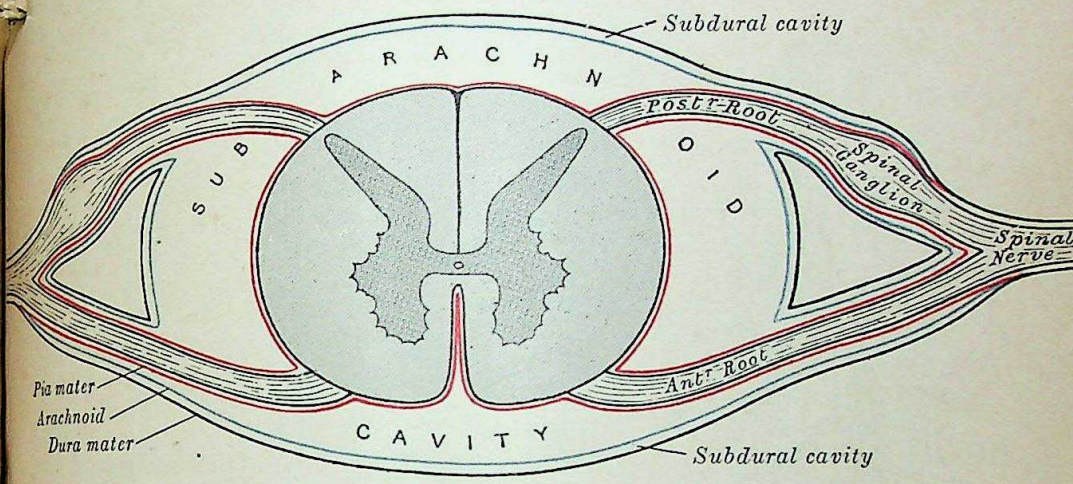

Thirty-one pairs of spinal nerves spring from the medulla spinalis, each nerve having an anterior and a posterior root, the latter being distinguished by the presence of an oval swelling, the *spinal ganglion*, which contains numerous nerve-cells. Each root consists of several bundles of nerve-fibres, and at its attachment extends for some distance along the side of the medulla spinalis. The pairs of spinal nerves are grouped as follows: cervical 8, thoracic 12, lumbar 5, sacral 5, coccygeal 1, and, for convenience of description, the medulla spinalis is divided into cervical, thoracic, lumbar, and sacral regions, corresponding with the attachments of the different groups of nerves.

Although no trace of transverse segmentation is visible on the surface of the medulla spinalis, it is convenient to regard it as being built up of a series of superimposed *spinal segments* or *neuromeres*, to each of which is attached a pair of spinal nerves. The lower limit of each spinal segment may be represented by an imaginary transverse plane at the level of the highest roots of each pair of spinal nerves.

The *filum terminale* (figs. 782, 784) is a delicate filament, about 20 cm. long, continued downwards from the apex of the conus medullaris. Its upper part, or *filum terminale internum*, about 15 cm. long, is contained within the tubular sheath of dura mater and reaches as far as the lower border of the second sacral vertebra. It is surrounded by the nerves forming the cauda equina, but can be readily distinguished from them by its bluish-white colour. Its lower part, or *filum terminale externum*, is closely invested by, and adherent to, the dura mater; it descends from the apex of the tubular sheath of dura mater and is

CC-0. In Public Domain. Gurukul Kangri Collection, Haridwar

Digitized by Arya Samaj Foundation Chennai and eGangotri

attached to the back of the first segment of the coccyx. The filum terminale consists mainly of fibrous tissue, continuous above with that of the pia mater, but adhering to its outer surface are a few strands of nerve-fibres which probably represent rudimentary second and third coccygeal nerves; further, the central canal of the medulla spinalis is continued downwards into it for 5 or 6 cm.

Enlargements.—The medulla spinalis is not quite cylindrical, being slightly flattened from before backwards; it also presents two swellings or enlargements, an upper or cervical, and a lower or lumbar (fig. 785).

Fig. 784.—The cauda equina and filum terminale seen from behind. The dura mater has been opened and spread out, and the arachnoid has been removed.

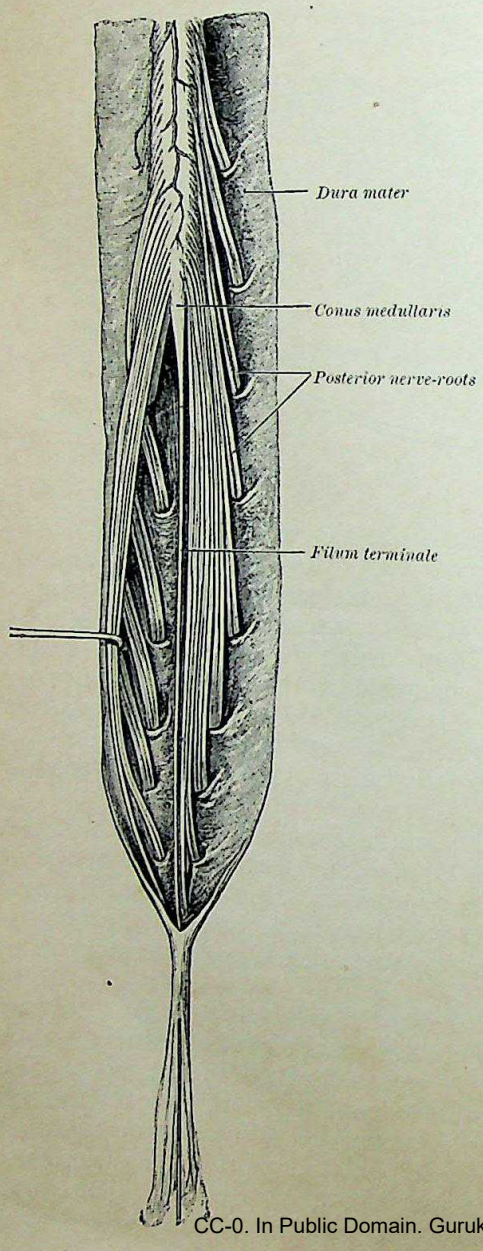

Fig. 785.—Diagrams of the medulla spinalis.

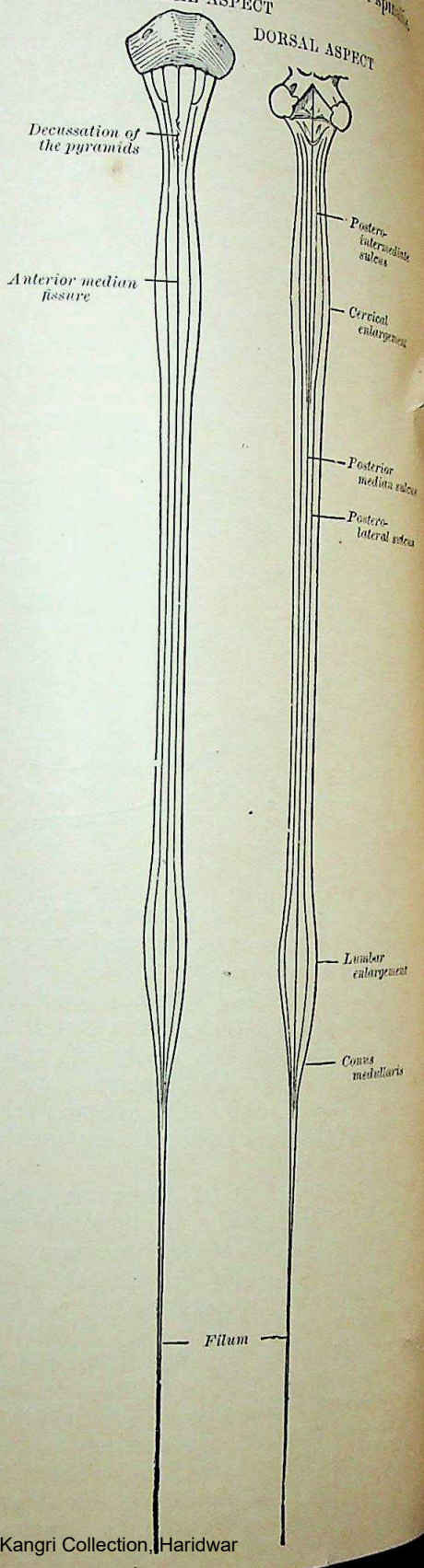

CC-0. In Public Domain. Gurukul Kangri Collection, Haridwar

Digitized by Arya Samaj Foundation Chennai and eGangotri

The *cervical enlargement* is the more pronounced, and corresponds with the attachments of the large nerves of the upper limbs. It extends from the third cervical to the second thoracic vertebra, its maximum circumference (about 38 mm.) being at the level of the roots of the sixth pair of cervical nerves.

To the *lumbar enlargement* are attached the nerves of the lower limbs. It begins at the level of the ninth thoracic vertebra, and reaches its maximum circumference, of about 33 mm., opposite the last thoracic vertebra, below which it tapers rapidly into the conus medullaris.

Fissures and sulci (fig. 786).—An anterior median fissure and a posterior median sulcus incompletely divide the medulla spinalis into two symmetrical parts, which are joined across the middle line by a commissural band of nervous matter.

The *anterior median fissure* has an average depth of about 3 mm., but is deepest in the lower part of the medulla spinalis. It contains a double fold of

Fig. 786.—A transverse section through the mid-thoracic region of the medulla spinalis. ×8.

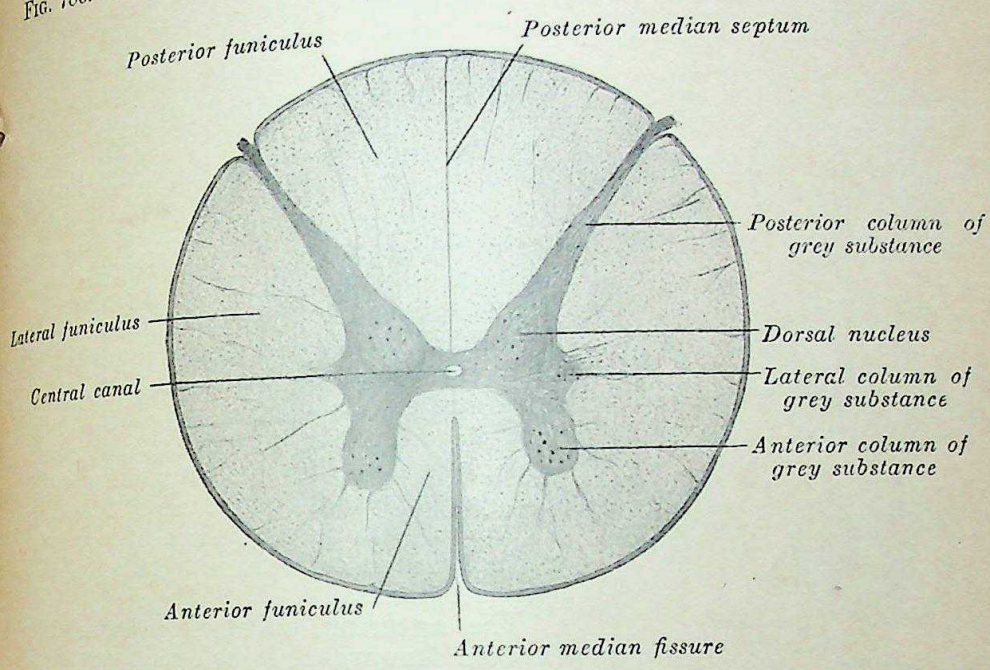

pia mater, and its floor is formed by a transverse band of white substance, the *anterior white commissure*, which is perforated by blood-vessels on their way to or from the central part of the medulla spinalis.

The *posterior median sulcus* is very shallow; from it a septum of neuroglia reaches rather more than half-way into the substance of the medulla spinalis; this septum varies in depth from 4 to 6 mm., but diminishes considerably in the lower part of the medulla spinalis.

On either side of the posterior median sulcus, and at a short distance from it, the posterior nerve-roots are attached along a vertical furrow named the *posterolateral sulcus*. The portion of the medulla spinalis which lies between this and the posterior median septum is named the *posterior funiculus*. In the cervical and upper thoracic regions the surface of this funiculus presents a longitudinal furrow, the *postero-intermediate sulcus*: this marks the position of a septum which extends into the posterior funiculus and subdivides it into two fasciculi—a medial, named the *fasciculus gracilis* (tract of Goll); and a lateral, the *fasciculus cuneatus* (tract of Burdach) (fig. 792).

The portion of the medulla spinalis between the posterolateral sulcus and the anterior median fissure is termed the *anterolateral region*. The anterior nerve-roots, unlike the posterior, are not attached in linear series, and their positions of exit are not marked by a sulcus; they arise by separate bundles which spring from the anterior column of grey substance and, passing forward through the white substance, emerge over an area of some width. The line of emergence of the most lateral of these bundles is generally taken as a dividing

CC-0. In Public Domain. Gurukul Kangri Collection, Haridwar

Digitized by Arya Samaj Foundation Chennai and eGangotri

line which separates the anterolateral region into two parts, viz. an *anterior funiculus*, between the anterior median fissure and the most lateral of the anterior nerve-roots; and a *lateral funiculus*, between the exit of these roots and the posterolateral sulcus. In the upper part of the cervical region a series of nerve-roots passes outwards through the lateral funiculus; these unite to form the spinal portion of the accessory nerve, which ascends and enters the cranial cavity through the foramen magnum (fig. 801), and conveys to the accessory nerve the fibres which supply the Sternocleidomastoideus and Trapezius.

Fig. 787.—Transverse sections through the medulla spinalis at different levels.

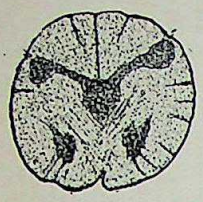
C.1.

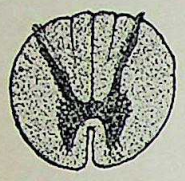
C.2.

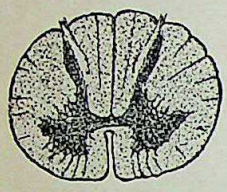
C.5.

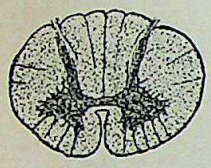
C.8.

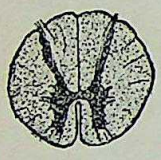
Th.2.

Th.8.

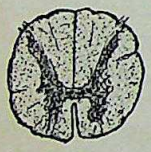
Th.12

L.3.

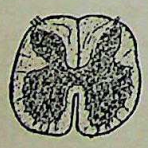
S.2.

Coc.

The Internal Structure of the Medulla Spinalis

The medulla spinalis is composed of grey and white nervous substance, in both of which there is a supporting framework of neuroglia.

The **grey substance** (substantia grisea) is enclosed within the white (fig. 786), and has the form of a fluted column which runs through the whole length of the medulla spinalis. This column consists of two symmetrical portions, one in either half of the medulla spinalis: these are joined to one another by a transverse commissure of grey substance which is traversed by the *central canal*, just visible to the naked eye. In a transverse section each half of the grey substance is shaped like a comma or crescent with its concavity directed lateralwards; and these, together with the intervening grey commissure, present the appearance of the letter H. A coronal plane through the central canal serves to divide each crescent into an anterior and a posterior column.

The **anterior column** (anterior cornu) is directed forwards; it is broad, and round or quadrangular in shape. Its posterior part is termed the *base*, and its anterior part the *head*, but these are not separated from each other by any well-defined constriction. Between the head of the column and the surface of the medulla spinalis is a layer of white substance which is traversed by the bundles of the anterior nerve-roots. In the thoracic region, the posterior part of the anterior column projects lateralwards, and is named the **lateral column** (lateral cornu).

The **posterior column** (posterior cornu) is long and slender, and is directed backwards and lateralwards; it reaches almost as far as the posterolateral sulcus, from which it is separated by a thin layer of white substance, the *tract of Lissauer*. It consists of a *base*, directly continuous with the base of the anterior column, and a *neck* or slightly constricted portion, which is succeeded by an oval or fusiform area, termed the *head*, of which the *apex* approaches the posterolateral sulcus. The apex is capped by a mass of translucent, gelatinous neuroglia, termed the *substantia gelatinosa of Rolando*, which contains both neuroglia-cells and small

CC-0. In Public Domain. Gurukul Kangri Collection, Haridwar

Digitized by Arya Samaj Foundation Chennai and eGangotri

nerve-cells and is V-shaped or crescentic on transverse section. Between the anterior and posterior columns the grey substance extends as a series of processes into the lateral funiculus, and forms a network called the *formatio reticularis*.

The quantity of grey substance and the form it presents on transverse section vary at different levels. In the thoracic region the grey substance is small in amount, not only absolutely but relatively to the surrounding white substance. In the cervical and lumbar enlargements it is greatly increased; so that in the latter, and especially in the conus medullaris, its proportion to the white substance is greater than elsewhere (fig. 787). In the cervical region the posterior column of grey substance is comparatively narrow, while the anterior column is broad and expanded; in the thoracic region, both columns are narrow, and the lateral column is evident; in the lumbar enlargement the anterior and posterior columns are both expanded; while in the conus medullaris the grey substance assumes the form of two oval masses, one in either half of the cord, connected together by a broad grey commissure.

The **central canal** traverses the entire length of the medulla spinalis. It is continued upwards through the lower part of the medulla oblongata and opens into the fourth ventricle of the brain; below, it reaches for a short distance (5-6 cm.) into the filum terminale. In the lower part of the conus medullaris it exhibits a fusiform dilatation, the *terminal ventricle*: this has a vertical measurement of from 8 to 10 mm., is triangular on cross section with its base directed forwards, and tends to undergo obliteration after the age of forty years.

Fig. 788.—A transverse section through the central canal of the medulla spinalis, showing the ependymal and neuroglial cells. (Lenhossék.)

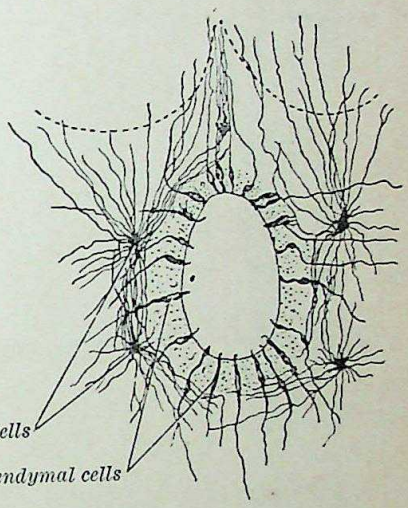

Throughout the cervical and thoracic regions the central canal is situated in the anterior one-third of the medulla spinalis: in the lumbar enlargement it is near the middle, and in the conus medullaris it approaches the posterior surface. It is filled with cerebrospinal fluid, and lined by ciliated, columnar epithelium, which is encircled by a band of gelatinous substance, the *substantia gelatinosa centralis*. This gelatinous substance consists mainly of neuroglia, but contains a few nerve-cells and nerve-fibres; it is traversed by processes from the deep ends of the cells which line the central canal (fig. 788).

The grey substance in front of the canal is named the anterior grey commissure; that behind it, the posterior grey commissure. The *anterior grey commissure* is thin, and in contact with the anterior white commissure: it contains a pair of longitudinal veins, one on either side of the middle line. The *posterior grey commissure* reaches from the central canal to the posterior median septum; it is thinnest in the thoracic region, and thickest in the conus medullaris.

The structure of the grey substance.—The grey substance of the medulla spinalis consists of neuroglia, nerve-cells, and nerve-fibres. Throughout the greater part of it the neuroglia is arranged in the form of a sponge-like network, but around the central canal and on the apices of the posterior columns it is condensed to form the gelatinous substance already referred to. The nerve-cells are multipolar, and vary greatly in size and shape, but they may be classified in three main types: (1) Motor-cells of large size, which are situated in the anterior column, and are especially numerous in the cervical and lumbar enlargements; the axons of most of these cells pass out to form the anterior nerve-roots, but before leaving the white substance they frequently give off collaterals, which re-enter and ramify in the grey

CC-0. In Public Domain. Gurukul Kangri Collection, Haridwar

Digitized by Arya Samaj Foundation Chennai and eGangotri

substance.* (2) Cells of small or medium size, the axons from which pass into the white matter, where some pursue an ascending, and others a descending course, but most of them divide in a T-shaped manner into descending and ascending processes; they give off collaterals which enter and ramify in the grey substance, and the axons end in a similar manner. Some of these axons are short and pass only between adjoining spinal segments; others are longer and connect more distant segments. These cells and their processes constitute a series of *association or intersegmental neurons* (fig. 789), which link together the different parts of the medulla spinalis. The axons of most of these cells are confined to that side of the medulla spinalis in which the nerve-cells are situated, but some cross to the opposite side through the anterior commissure, and are termed *crossed commissural fibres*. Some of the latter end directly in the grey substance, while others enter the white substance, and ascend or descend in it for varying distances, before finally terminating in the grey substance. Most of the nerve-cells are arranged in longitudinal columns, and appear as groups on transverse section (figs. 790, 791).

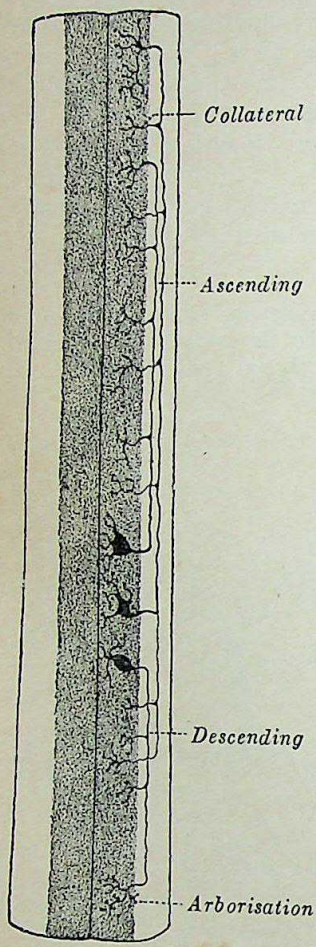

FIG. 789.—A diagram showing in longitudinal section the intersegmental neurons of the medulla spinalis. The grey and white parts correspond respectively to the grey and white substance of the medulla spinalis. (Poirier.)

Nerve-cells in the anterior column.—The nerve-cells in the anterior column are arranged in columns of varying length. The longest occupies the medial part of the anterior column and is named the *anteromedial* column; it is absent only in the fifth lumbar, the first sacral and the upper part of the second sacral segments. Behind it, is a *posteromedial* column of small cells, which extends from the second thoracic to the first lumbar segment and is also present in the lower two cervical segments.

In the cervical and lumbar enlargements, where the anterior column is expanded in a lateral direction, the following additional columns of nerve-cells are present, viz.—(*a*) *anterolateral*, in the fourth, fifth, and sixth cervical, second thoracic, lower four lumbar and upper two sacral segments; (*b*) *posterolateral*, in the lower five cervical, lower four lumbar, and upper three sacral segments; (*c*) *post-posterolateral*, in the last cervical, first thoracic, and upper three sacral segments; and (*d*) *central*, in the lower four lumbar and upper two sacral segments. Throughout the base of the anterior column are solitary cells, the axons of some of which form crossed commissural fibres, while others constitute the motor fibres of the posterior nerve-root.*

Nerve-cells in the lateral column.—These form a column which is best marked in the thoracic region; it extends from the eighth cervical segment to the lower part of the second or upper part of the third lumbar segment, but can be traced throughout the length of the medulla spinalis in the form of groups of small cells situated in the anterior part of the formatio reticularis. The cells of this column are fusiform or star-shaped, and of a medium size: the axons of many of them pass into the anterior nerve-roots, and are conveyed to the sympathetic ganglia through the white rami communicantes; while the axons of others pass into the anterior and lateral funiculi, where they become longitudinal.

* Lenhossék and Cajal found that in the embryo of the chick the axons of a few of these nerve-cells passed backwards through the posterior column, and emerged as the *motor fibres* of the *posterior nerve-roots*. These fibres are said to control the peristaltic movements of the intestine. Their presence in man has not yet been determined.

CC-0. In Public Domain. Gurukul Kangri Collection, Haridwar

Digitized by Arya Samaj Foundation Chennai and eGangotri

Nerve-cells in the posterior column.—1. The *dorsal nucleus* (*column of Clarke*) occupies the medial part of the base of the posterior column, and appears on transverse section as a well-defined oval area (figs. 786, 791). It begins below the level of the second or third lumbar nerve, and reaches its maximum size opposite the twelfth thoracic nerve. It diminishes in size above the level of the ninth thoracic nerve, and ends opposite the last cervical or first thoracic nerve. It is represented, however, in the other regions by scattered cells, which are aggregated to form a *cervical nucleus* opposite the third cervical nerve, and a *sacral nucleus* in the middle and lower part of the sacral region.

FIG. 790.—A scheme showing the mode of distribution of the nerve-cells in the grey substance. (Testut.)

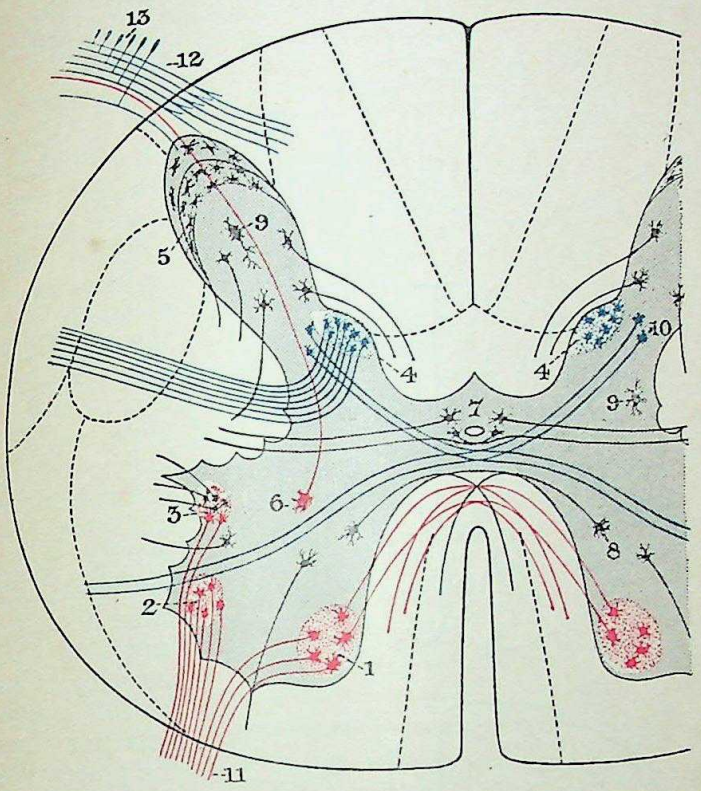

1, 2. Medial and lateral groups of nerve-cells in anterior column. 3. Nerve-cells in lateral column. 4, 4. Dorsal nucleus. 5. Group of nerve-cells in substantia gelatinosa of Rolando. 6. Nerve-cell of anterior column, the axon of which is passing into the posterior nerve-root. 7. Cells of substantia gelatinosa centralis. 8. Solitary cell. 9. Cells of Golgi. 10. Cells of origin of the superficial anterolateral fasciculus. 11. Anterior root. 12. Posterior root. 13. Spinal ganglion.

Its cells are of medium size, and oval or pyriform in shape; many of their axons pass into the peripheral part of the lateral funiculus of the same side, and there ascend, under the name of the *direct cerebellar tract*; others cross to the opposite side and ascend as the *superficial anterolateral fasciculus*.

2. *Nerve-cells in the substantia gelatinosa of Rolando.*—These are arranged in three zones: a posterior or marginal, of large triangular or fusiform cells; an intermediate, of small fusiform cells; and an anterior, of star-shaped cells. The axons of these cells pass into the lateral and posterior funiculi, and there pursue a vertical course. Some of the cells in the anterior zone belong to Golgi's type II, their short axons being confined to the grey substance.

3. *Solitary cells* of varying form and size are scattered throughout the posterior column. Some of these are grouped to form an ill-defined *posterior basal column*, lateral to the dorsal nucleus. The axons of the cells of this column pass partly to the posterior and lateral funiculi of the same side, and partly through the anterior white commissure to the lateral funiculus of the opposite side. Before leaving the grey substance, a considerable number run longitudinally for a varying distance in the head of the posterior column, forming what is termed the *longitudinal fasciculus* of the posterior column.

CC-0. In Public Domain. Gurukul Kangri Collection, Haridwar

Digitized by Arya Samaj Foundation Chennai and eGangotri

A few star-shaped or fusiform nerve-cells of varying size are found in the substantia gelatinosa centralis. Their axons pass into the lateral funiculus of the same, or the opposite side.

FIG. 791.—Transverse sections through the medulla spinalis at different levels, showing the arrangement of the principal cell-columns.

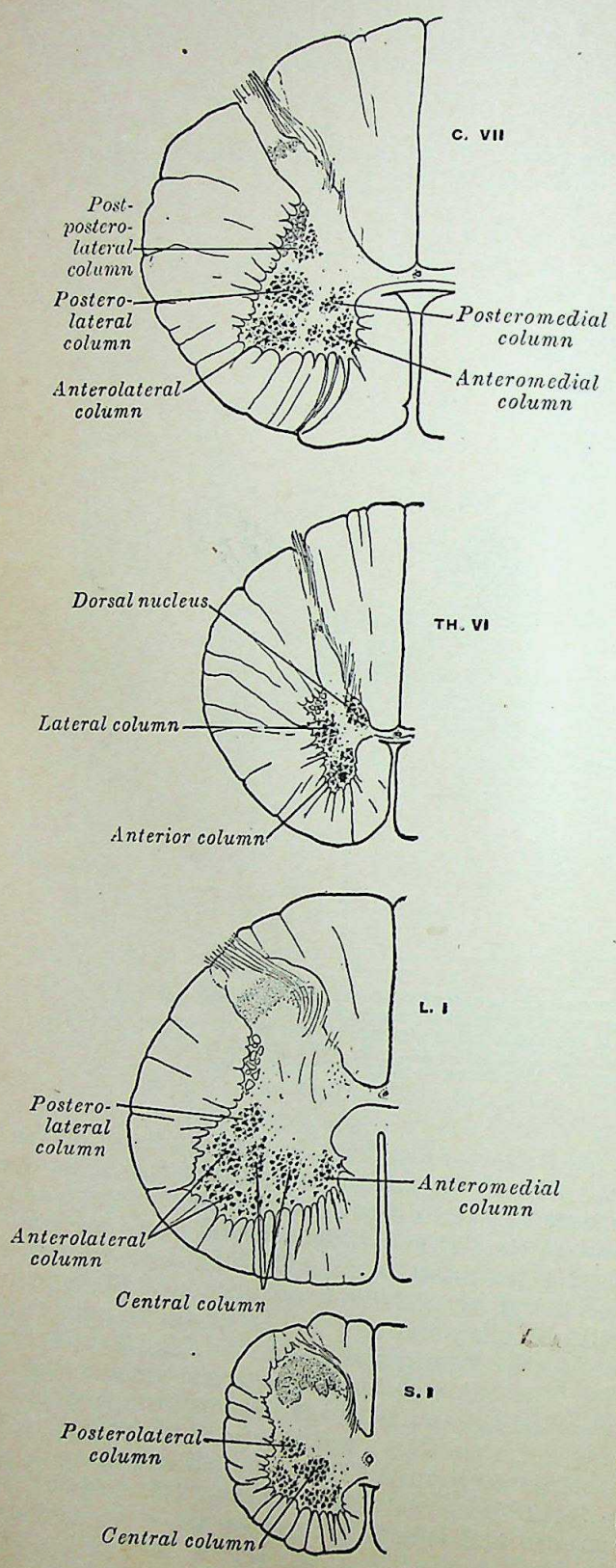

The nerve-fibres in the grey substance form a dense interlacement among the nerve-cells. This interlacement is formed partly of axons which pass from the cells in the grey substance to enter the white funiculi or the anterior nerve-roots; partly of the axons of Golgi's cells which ramify only in the grey substance; and partly of collaterals from the nerve-fibres in the white funiculi, which, as already stated, enter the grey substance and ramify within it.

The white substance (substantia alba) of the medulla spinalis surrounds the grey substance, and consists chiefly of medullated nerve-fibres. The nerve-fibres are arranged in three funiculi: anterior, lateral, and posterior. The anterior funiculus lies between the anterior median fissure and the most lateral of the anterior nerve-roots; the lateral funiculus between these nerve-roots and the postero-lateral sulcus; and the posterior funiculus between the posterolateral sulcus and the posterior median septum (fig. 792). The nerve-fibres vary in thickness; the thinnest are found in the fasciculus gracilis, the fasciculus of Lissauer, and the central part of the lateral funiculus; the thickest are situated in the anterior funiculus, and in the peripheral part of the lateral funiculus. Some of the nerve-fibres run more or less transversely, as for example those which cross the middle line in the anterior white commissure, but the majority pursue a longitudinal course and are divisible into (1) those connecting the medulla spinalis with the brain and conveying impulses to or from the latter, and (2) those which are confined to the medulla spinalis, and link together its different segments (i.e. intersegmental or association fibres).

CC-0. In Public Domain. Gurukul Kangri Collection, Haridwar

Digitized by Arya Samaj Foundation Chennai and eGangotri

Nerve-fasciculi.—The longitudinal fibres are grouped into more or less definite bundles or fasciculi. These are not recognisable from each other in the natural state, and their existence has been determined by the following methods. (1) A. Waller discovered that if a bundle of nerve-fibres be cut, the portions of the fibres which are separated from their cells rapidly degenerate and become atrophied, while their cells and the parts of the fibres connected with them undergo little alteration.* This is known as *Wallerian degeneration.* Similarly, if a group of nerve-cells be destroyed, the fibres arising from them undergo degeneration. Thus, if the motor cells of the cerebral cortex be destroyed, or if the fibres arising from these cells be severed, a *descending degeneration* from the seat of injury takes place in the fibres. In the same manner, if a spinal ganglion be destroyed, or the fibres which pass from it

FIG. 792.—A diagram of the principal fasciculi of the white substance of the medulla spinalis.

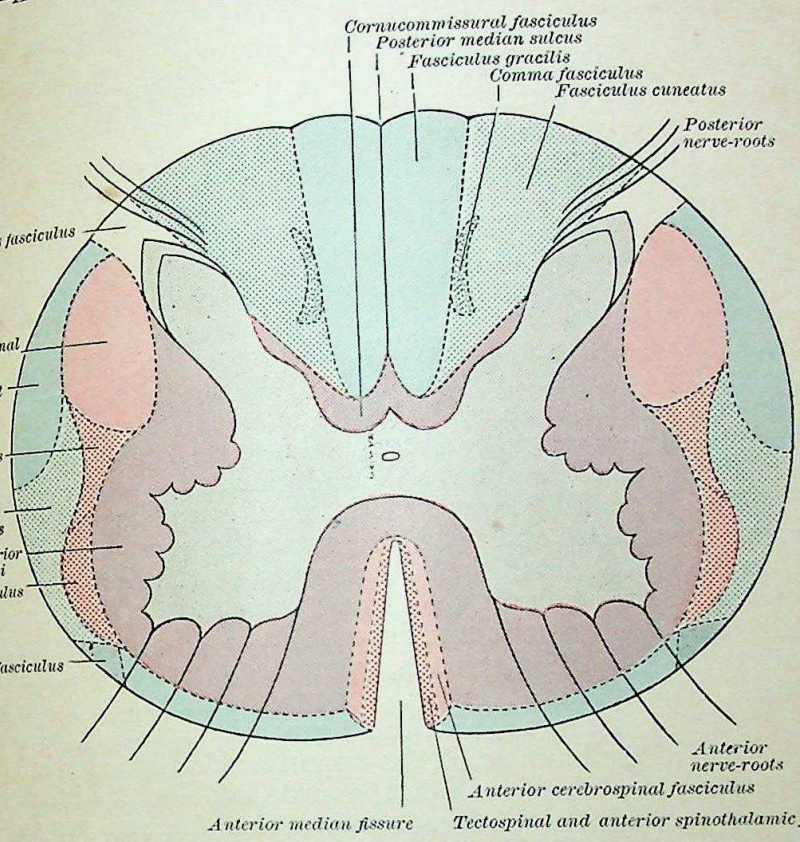

into the medulla spinalis be cut, an *ascending degeneration* occurs in these fibres above the lesion. (2) In the early stages of the development of the nervous system, the nerve-fibres are naked axis-cylinders; groups of nerve-fibres acquire their medullary sheaths at different periods; hence the fibres can be grouped according to the dates at which they receive these sheaths. The first fibres to acquire medullary sheaths are those of the nerve-roots and of the fasciculi proprii; the last, those of the cerebrospinal fasciculi. (3) Golgi's method of staining nervous tissues allows the course and mode of termination of the axis-cylinder processes to be followed.

Fasciculi in the anterior funiculus.—(*a*) The *anterior cerebrospinal fasciculus* (direct pyramidal tract) is usually small, but varies in size inversely with the lateral cerebrospinal fasciculus. It is present only in the upper part of the medulla spinalis; gradually diminishing in size as it descends, it ends about the middle of the thoracic region. It consists of fibres which arise from cells in the motor area of the cerebral hemisphere of the same side, and which,

* Somewhat later a change, termed *chromatolysis*, takes place in the nerve-cells, and consists of the breaking down and ultimate disappearance of the Nissl bodies. The cell-body swells, the nucleus is displaced towards the periphery of the cell, and the part of the axon still attached to the altered cell diminishes in size and atrophies. Under favourable conditions the cell may assume its normal appearance, and its axon may grow again.

CC-0. In Public Domain. Gurukul Kangri Collection, Haridwar

Digitized by Arya Samaj Foundation Chennai and eGangotri

as they run downwards in the medulla spinalis, cross in succession through the anterior white commissure to the opposite side, where they end by arborising around the motor cells in the anterior column.

(*b*) The *vestibulospinal fasciculus*, derived from the cells of Deiters' nucleus, one of the nuclei in which the vestibular division of the acoustic nerve ends, descends in the anterior funiculus.

(*c*) The *anterior spinothalamic* fasciculus arises from cells in the posterior grey column of the opposite side of the medulla spinalis, crosses in the anterior white commissure, and ascends in the anterior funiculus to the thalamus.

The remaining fibres of the anterior funiculus constitute what is termed the *fasciculus proprius anterior* (anterior basis bundle). It consists mainly of (1) longitudinal intersegmental fibres which arise from cells in the grey substance, more especially from those of the medial group of the anterior column, and, after a longer or shorter course, re-enter the grey substance. Some of the fibres of this fasciculus pass upwards into the medial (posterior) longitudinal fasciculus (p. 827); (2) fibres arising from cells of the cerebellum and extending down the medulla spinalis to end around the cells of the anterior column.

Fasciculi in the lateral funiculus.—1. **Descending fasciculi.**—(*a*) The *lateral cerebrospinal fasciculus* (crossed pyramidal tract) extends throughout the length of the medulla spinalis, and on transverse section appears as an oval area in front of the posterior grey column and medial to the direct cerebellar tract. In the lumbar and sacral regions, where the direct cerebellar fasciculus is absent, the lateral cerebrospinal fasciculus reaches the surface of the medulla spinalis. Its fibres arise from cells in the motor area of the cerebral hemisphere of the opposite side. They pass downwards in company with those of the anterior cerebrospinal fasciculus through the same side of the brain as that from which they originate, but cross to the opposite side in the medulla oblongata and descend in the lateral funiculus of the medulla spinalis; they end by arborising around the motor cells in the anterior column.*

The anterior and lateral cerebrospinal fasciculi constitute the motor fasciculi of the medulla spinalis and have their origins in the motor cells of the cerebral cortex. They descend through the internal capsule of the cerebrum, traverse the cerebral peduncles and pons, and enter the pyramid of the medulla oblongata. In the lower part of the latter about two-thirds of them cross the middle line and run downwards in the lateral funiculus as the lateral cerebrospinal fasciculus while the remaining fibres do not cross, but are continued into the same side of the medulla spinalis, where they form the anterior cerebrospinal fasciculus. Fibres of the latter, however, cross in succession through the anterior white commissure, and thus, generally speaking, all the motor fibres from one side of the brain reach the opposite side of the medulla spinalis. The proportion of fibres which cross in the medulla oblongata is not a constant one, and thus the anterior and lateral cerebrospinal fasciculi vary inversely in size. Sometimes the former is absent, and it is then presumed that complete decussation of the motor fibres has occurred in the medulla oblongata. Medullation of the fibres of these two fasciculi is not completed until the second year. There is experimental and clinical evidence to show that the lateral cerebrospinal fasciculus contains a few fibres which are derived from the cerebral hemisphere of the same side (*uncrossed lateral cerebrospinal fibres*).

(*b*) The *rubrospinal fasciculus* (Monakow) is anterior to the lateral cerebrospinal fasciculus, and on transverse section appears as a somewhat triangular area. Its fibres descend from the mid-brain, where they have their origins in the cells of the red nucleus of the tegmentum of the opposite side; they end by forming synapses with the cells in the anterior column.

(*c*) The *tectospinal fasciculus* originates in the superior colliculus (upper quadrigeminal body) of the opposite side, and its fibres are partly intermingled with those of the rubrospinal fasciculus, and are partly contained in the anterior funiculus.

* Sharpey Schafer (*Proc. Physiological Soc.* 1899) says it is probable that the fibres of the anterior and lateral cerebrospinal fasciculi are not related in this direct manner with the cells of the anterior column, but terminate by arborising round the cells at the base of the posterior column, which in turn link them to the motor cells in the anterior column, usually of several segments of the cord. In consequence of these interposed neurons the fibres of the cerebrospinal fasciculi correspond not to individual muscles, but to associated groups of muscles.

CC-0. In Public Domain. Gurukul Kangri Collection, Haridwar

Digitized by Arya Samaj Foundation Chennai and eGangotri

(d) The *olivospinal fasciculus* (Helweg) arises in the vicinity of the inferior olivary nucleus in the medulla oblongata and is seen only in the cervical region of the medulla spinalis, where it forms a small triangular area at the periphery, close to the most lateral of the anterior nerve-roots. Its exact origin and its mode of ending have not been definitely made out.

2. **Ascending fasciculi.**—(a) The *direct cerebellar tract of Flechsig* (posterior spinocerebellar fasciculus) is situated at the periphery of the posterior portion of the lateral funiculus, and on transverse section appears as a flattened band reaching as far forwards as a line drawn transversely through the central canal of the medulla spinalis. Medially it is in contact with the lateral cerebrospinal fasciculus; behind, with the fasciculus of Lissauer. It begins about the level of the second or third lumbar nerve, increases in size as it ascends, and finally passes to the cerebellum through the restiform body. Its fibres are the axons of the cells of the dorsal nucleus (Clarke's column) of the same side; they receive their medullary sheaths about the sixth or seventh month of fœtal life.

(b) The *superficial anterolateral fasciculus* (tract of Gowers) skirts the periphery of the lateral funiculus in front of the direct cerebellar tract. In transverse section it is shaped somewhat like a comma, the expanded end lying in front of the lateral cerebrospinal fasciculus while the tail reaches forwards into the anterior funiculus. Its fibres are derived from the cells of the dorsal nucleus and from other cells of the posterior column. The superficial anterolateral fasciculus begins about the level of the third pair of lumbar nerves, and, increasing in size as it ascends, can be followed into the medulla oblongata and pons. It consists of three fasciculi: (1) the *anterior spinocerebellar*, partly crossed and partly uncrossed, passes to the cerebellum by way of the brachia conjunctiva; (2) the *lateral spinothalamic* ends in the thalamus; and (3) the *spinotectal* passes to the corpora quadrigemina.

(c) The *fasciculus of Lissauer* is a small strand situated at the tip of the posterior grey column, close to the entrance of the posterior nerve-roots. It consists of fine fibres which do not receive their medullary sheaths until near the close of fœtal life; some of its fibres are said to remain non-medullated throughout life. It is usually regarded as being formed by some of the lateral fibres of the posterior nerve-roots, which ascend for a short distance in the tract and then enter the posterior grey column, but its fibres are myelinated later than those of the posterior nerve-roots, and do not undergo degeneration in locomotor ataxia; they are probably intersegmental in character.

(d) The *fasciculus proprius lateralis* (lateral basis bundle) constitutes the remainder of the lateral funiculus, and is continuous in front with the anterior proper fasciculus. It consists chiefly of intersegmental fibres which arise from cells in the grey substance, and, after a longer or shorter course, re-enter the grey substance and ramify in it. Most of the intersegmental fibres of the anterior and lateral proper fasciculi are confined to the same side, but some cross to the opposite side, of the medulla spinalis. Some of the fibres of the lateral proper fasciculus are continued upwards into the brain under the name of the medial longitudinal fasciculus.

Fasciculi in the posterior funiculus.—This funiculus comprises two main fasciculi, viz. the fasciculus gracilis and the fasciculus cuneatus. These are separated from each other in the cervical and upper thoracic regions by the postero-intermediate septum (p. 787), and consist mainly of ascending fibres derived from the posterior nerve-roots.

The *fasciculus gracilis* (tract of Goll) lies next the posterior median septum, and is wedge-shaped on transverse section, its base being at the surface of the medulla spinalis. It increases in size from below upwards (fig. 793), and consists of long thin fibres which are derived from the posterior nerve-roots, and ascend as far as the medulla oblongata, where they end in the nucleus gracilis.

The *fasciculus cuneatus* (tract of Burdach) is triangular on transverse section, and lies between the fasciculus gracilis and the posterior grey column, with its base on the surface of the medulla spinalis. Its fibres, larger than those of the fasciculus gracilis, are mostly derived from the same source, viz. the posterior nerve-roots. Some of its fibres ascend for only a short distance, and, entering the grey substance, come into relationship with the cells of the dorsal nucleus; others can be traced as far as the medulla oblongata, where they end in the nucleus gracilis and nucleus cuneatus.

CC-0. In Public Domain. Gurukul Kangri Collection, Haridwar

Digitized by Arya Samaj Foundation Chennai and eGangotri

Occupying the anterior or deepest part of the posterior funiculus is a strand of fibres termed the *cornucommissural fasciculus*. It is somewhat crescentic on transverse section, and is placed between the posterior grey commissure and the posterior funiculus; it is best marked in the lumbar region, but can be traced into the thoracic and cervical regions. Its fibres, derived from the cells of

FIG. 793.—A diagram showing the formation of the fasciculus gracilis. (Poirier.)

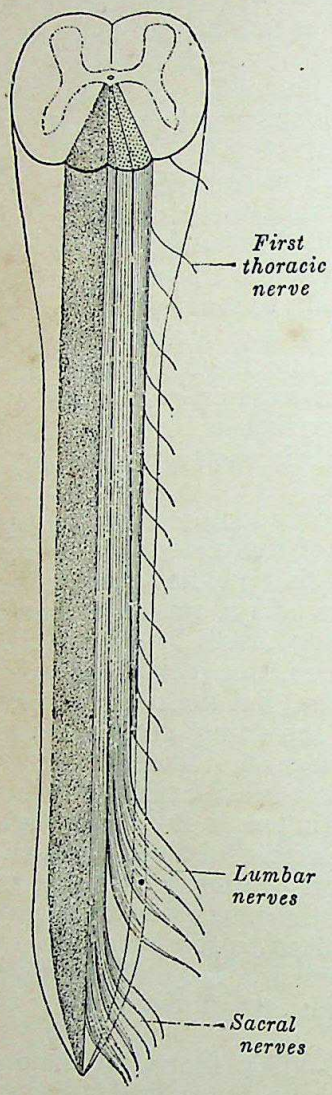

The medulla spinalis viewed from behind. To the left, the fasciculus gracilis is shaded. To the right, the drawing shows that the fasciculus gracilis is formed by the long ascending fibres of the posterior roots and that the sacral nerves lie next the median plane, the lumbar to their lateral side, and the thoracic still more laterally.

FIG. 794.—The descending fibres in the posterior funiculi, shown at different levels. (After Testut.)

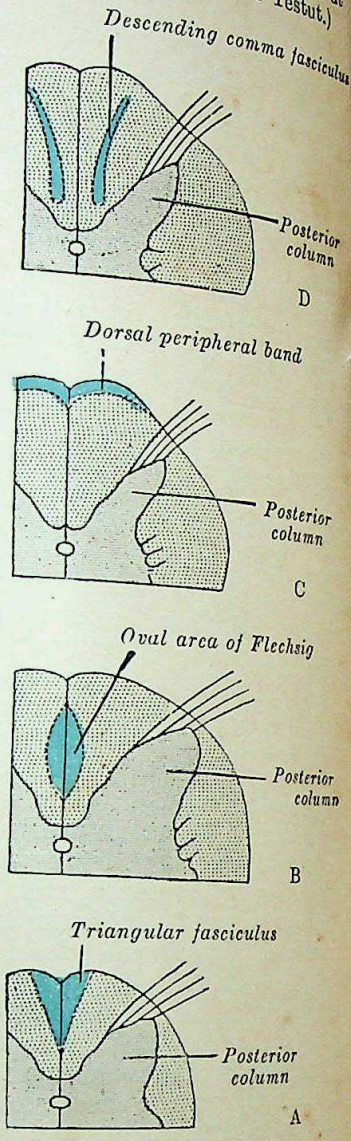

A. In the conus medullaris. B. In the lumbar region. C. In the lower thoracic region. D. In the upper thoracic region.

the posterior column, divide into ascending and descending branches which re-enter and ramify in the grey substance. This fasciculus has been found to preserve its integrity in certain cases of locomotor ataxia.

The posterior funiculus contains some descending fibres which occupy different parts at different levels (fig. 794). In the cervical and upper thoracic regions they appear as a *comma-shaped fasciculus* in the medial part of the fasciculus cuneatus, the blunt edge of the fasciculus being directed forwards; in the lower thoracic region they form a *dorsal peripheral band* on the posterior surface of the funiculus; in the lumbar region they are situated by the side of

CC-0. In Public Domain. Gurukul Kangri Collection, Haridwar

Digitized by Arya Samaj Foundation Chennai and eGangotri

the posterior median septum, and appear on section as a semi-elliptical bundle, which, together with the corresponding bundle of the opposite side, forms the *band of Flechsig*; while in the conus medullaris they assume the form of a *triangular strand* in the posteromedial part of the fasciculus gracilis. These descending fibres are mainly intersegmental in character and derived from cells in the posterior column, but some consist of the descending branches of the posterior nerve-roots. The comma-shaped fasciculus was supposed to belong to the second category, but against this view is the fact that it does not undergo descending degeneration when the posterior nerve-roots are destroyed.

Roots of the spinal nerves.—Each spinal nerve has two roots, an anterior and a posterior, which are attached to the surface of the medulla spinalis opposite the corresponding columns of grey substance (fig. 795); their fibres acquire their medullary sheaths about the fifth month of fœtal life.

The *anterior nerve-root* consists of efferent fibres, which are the axons of the nerve-cells in the anterior and lateral grey columns. A short distance from their origins, these axons are invested by medullary sheaths and, passing forwards, emerge in two or three irregular rows over an area which measures about 3 mm. in width.

FIG. 795.—A spinal nerve with its anterior and posterior roots. (Testut.)

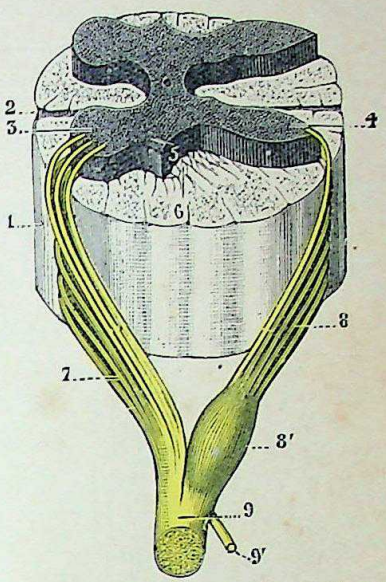

1. A portion of the medulla spinalis viewed from the left side. 2. Anterior median fissure. 3. Anterior column. 4. Posterior column. 5. Lateral column. 6. Formatio reticularis. 7. Anterior root. 8. Posterior root, with 8′, its ganglion. 9. Spinal nerve; and 9′, its posterior division.

The *posterior nerve-root* comprises six or eight fasciculi, attached in linear series along the posterolateral sulcus. It consists of afferent fibres which arise from the nerve-cells in a spinal ganglion. Each ganglion-cell gives off a single fibre which divides in a T-shaped manner into two processes, medial and lateral. The medial processes of the ganglion-cells pass into the medulla spinalis as the posterior roots of the spinal nerves, while the lateral are directed towards the periphery.

The posterior nerve-root enters the medulla spinalis in two chief bundles, medial and lateral. The *medial* strand passes directly into the fasciculus cuneatus; it consists of coarse fibres, which acquire their medullary sheaths about the fifth month of intra-uterine life; the *lateral* strand is mainly composed of fine fibres, many of which are non-medullated; they enter the fasciculus of Lissauer.

After entering the medulla spinalis, all the fibres of the posterior nerve-roots divide into ascending and descending branches, and these in their turn give off collaterals which enter the grey substance (fig. 796). The descending branches are short, and soon enter the grey substance. The ascending branches are grouped into long, short, and intermediate fibres; the long fibres ascend in the fasciculus cuneatus and fasciculus gracilis as far as the medulla oblongata, where they end by arborising around the cells of the cuneate and gracile nuclei; the short fibres run upwards for a distance of only 5 or 6 mm., and enter the grey substance; while the intermediate fibres, after a somewhat longer course, have a similar destination. All fibres entering the grey substance end by arborising around its nerve-cells; in the thoracic region those of intermediate length are especially associated with the cells of the dorsal nucleus. The collaterals which spring from the ascending and descending branches of the fibres of the posterior nerve-roots end by arborising around the cells in the anterior and posterior grey columns; in the thoracic region many of these collaterals arborise around the cells of the dorsal nucleus and the cells of the lateral grey column.

CC-0. In Public Domain. Gurukul Kangri Collection, Haridwar

Digitized by Arya Samaj Foundation Chennai and eGangotri

The long ascending fibres of the posterior nerve-roots pursue an oblique course, being situated at first in the lateral part of the fasciculus cuneatus; higher up, they occupy the middle of this fasciculus, having been displaced by the accession of other entering fibres; while still higher, they ascend in the fasciculus gracilis. In the upper cervical region the localisation of these fibres is very precise: the sacral nerves lie in the median part of the fasciculus gracilis and near its base, the lumbar nerves laterally to them, the thoracic nerves still more laterally, while the cervical nerves are confined to the fasciculus cuneatus (fig. 793).

FIG. 796.—The posterior nerve-roots dividing into ascending and descending branches. (Van Gehuchten.)

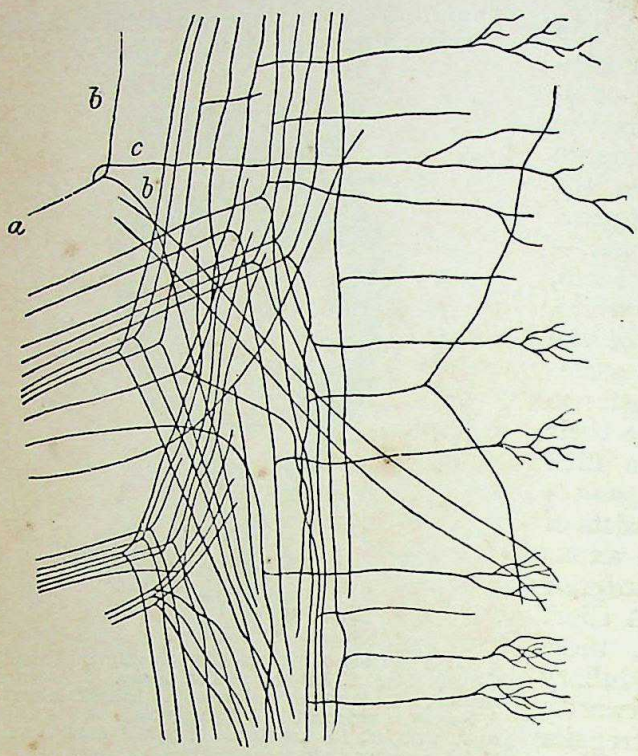

a. Nerve-fibre. *b*, *b*. Ascending and descending branches. *c*. Collateral arising from nerve-fibre.

The development of the medulla spinalis is described on pp. 85 to 88.

Applied Anatomy.—Several cases have been recorded* in which a local doubling of the medulla spinalis has taken place. The condition is probably due to some interference with the development of the neural tube in the embryo; in a few it was associated with spina bifida, while in one case† the two parts were separated by a dermoid tumour. Other *congenital abnormalities* of the medulla spinalis occur in connexion with spina bifida (p. 184), and *syringomyelia*. In this latter chronic condition an abnormal proliferation of the neuroglia takes place, generally near the central canal and usually in the cervical enlargement, and later this mass becomes absorbed, leaving an irregular cavity in its place. This gives rise to a number of interesting signs and symptoms, such as analgesia (or insensitiveness to pain), inability to distinguish between cold and heat, progressive atrophy in the muscles of the hands and arms, trophic changes in the bones and joints, and painless whitlows. Severe *injuries* to the medulla spinalis may occur in fractures or fracture-dislocations of the vertebral column anywhere above the second lumbar vertebra. If the medulla spinalis is completely crushed or torn across, total paralysis and anæsthesia of all parts of the body drawing their nerve supply from below the injured spot will follow, with loss of control over the actions of the bladder and rectum. The higher up such a lesion occurs, the worse the prognosis. Thus, in fracture of the atlas or epistropheus, the vital centres in the medulla oblongata are injured, and death occurs at once. If the origin of the phrenic nerve—mainly the fourth cervical—just escape in a case where the neck is broken, respiration will have to be carried on by the Diaphragm alone, and death is likely to ensue before long from pulmonary complications. When the back is broken in the lower thoracic region, life is not immediately threatened; but unless the patient is carefully nursed, death may follow at any time from the development of bed sores in the anæsthetic area, or from septic infection spreading up the ureters into the kidneys and secondary to the cystitis that is so prone to occur in patients who have no control over the bladder. *Inflammation* of the medulla spinalis, or *spinal myelitis*, sometimes follows influenza or one of the acute specific fevers. A transverse patch of such myelitis extending completely across the medulla spinalis produces more or less complete interruption of the passage of nervous impulses through it. Hence it will occasion more or less complete paralysis and anæsthesia of the parts of the body obtaining their nerve-supply from below it, and, in addition, a zone of cutaneous hyperæsthesia at its level, in consequence of the irritation of the sensory fibres entering the inflamed region of the medulla spinalis. The disease mainly attacking children, and known as *infantile spinal paralysis*, or *acute anterior*

* An analysis of these cases is given in the *Review of Neurology and Psychiatry*, Jan. 1916.

† Harriehausen, *Z. f. Psych. u. Nervenheilk.* Bd. 36, Hft. 3 und 4, S. 268.

CC-0. In Public Domain. Gurukul Kangri Collection, Haridwar

Digitized by Arya Samaj Foundation Chennai and eGangotri

floor of the fourth ventricle. Further, certain of the cerebral nerves pass through the substance of the medulla oblongata, and are attached to its surface in series with the roots of the spinal nerves; thus, the fibres of the hypoglossal nerve correspond in position with the anterior roots of the spinal nerves, and emerge in linear series from a furrow termed the *anterolateral sulcus*. Similarly, the accessory, vagus, and glossopharyngeal nerves correspond with the posterior roots of the spinal nerves, and are attached to the bottom of a sulcus named the *posterolateral sulcus*. Advantage is taken

Fig. 798.—The medulla oblongata, pons and mid-brain. Ventral aspect.

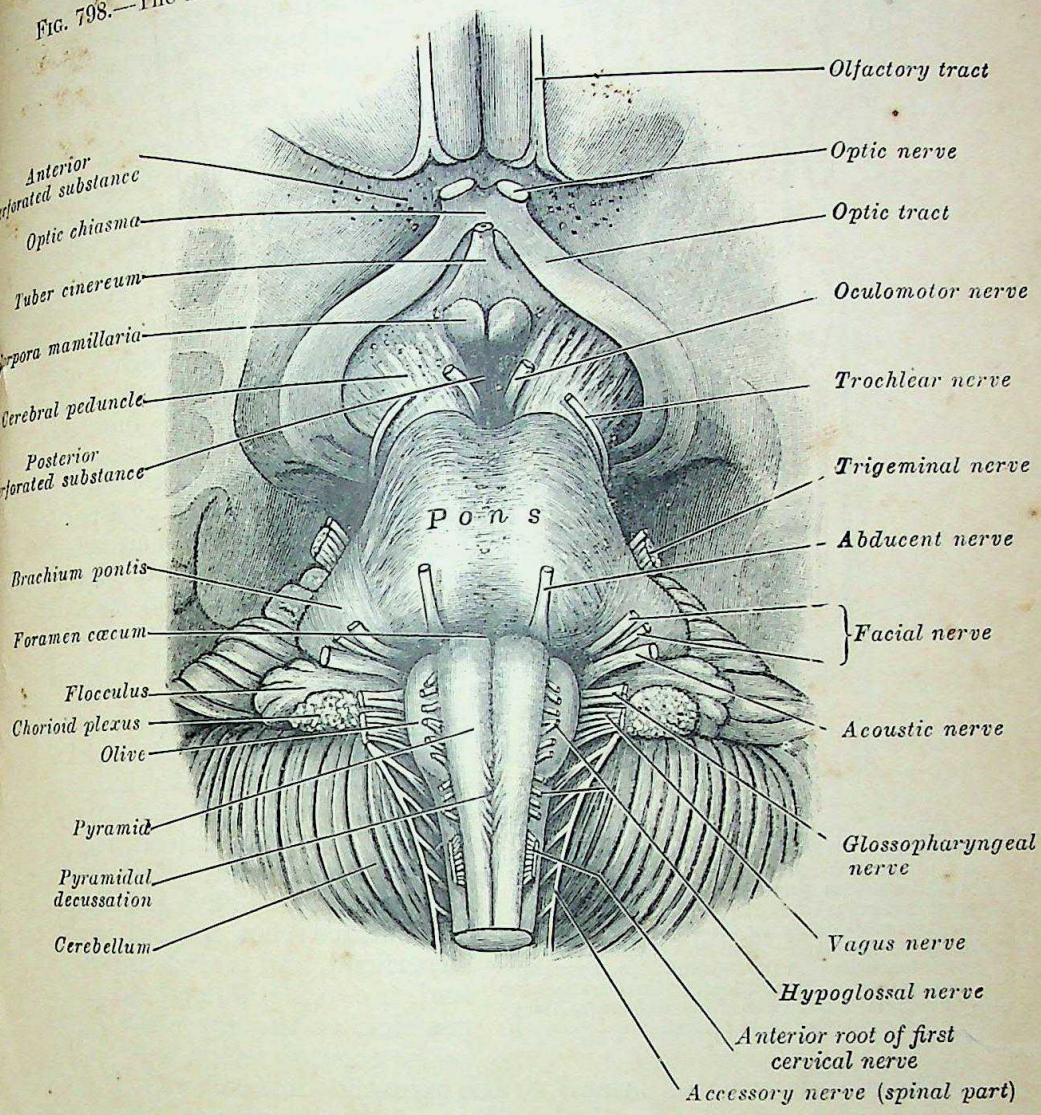

f this arrangement to subdivide each half of the medulla oblongata into nterior, middle, and posterior regions. Although these three regions appear o be directly continuous with the corresponding funiculi of the medulla pinalis, they do not necessarily contain the same nerve-fibres, since some of he fasciculi of the medulla spinalis end in the medulla oblongata, while others lter their course in passing through it.

The **anterior region** of the medulla oblongata (fig. 798) is named the *yramid*, and lies between the anterior median fissure and the anterolateral ulcus. Its upper end is slightly constricted, and between it and the pons the bres of the abducent nerve emerge; below, it tapers into the anterior funiculus f the medulla spinalis, with which, at first sight, it appears to be directly ontinuous.

The two pyramids contain the motor fibres which pass from the brain to he medulla spinalis. When traced downwards, two-thirds or more of these

CC-0. In Public Domain. Gurukul Kangri Collection, Haridwar

Digitized by Arya Samaj Foundation Chennai and eGangotri

fibres leave the pyramids in successive bundles, and decussate in the anterior median fissure, forming what is termed the *pyramidal decussation*. Having crossed the middle line, they pass down in the posterior part of the lateral funiculus of the medulla spinalis as the lateral cerebrospinal fasciculus. The remaining fibres—i.e. those which occupy the lateral part of the pyramid—do not cross the middle line, but descend as the anterior cerebrospinal fasciculus (fig. 799) into the anterior funiculus of the same side of the medulla spinalis.

FIG. 799.—A scheme showing the passage of various fasciculi through the medulla oblongata. (Testut.)

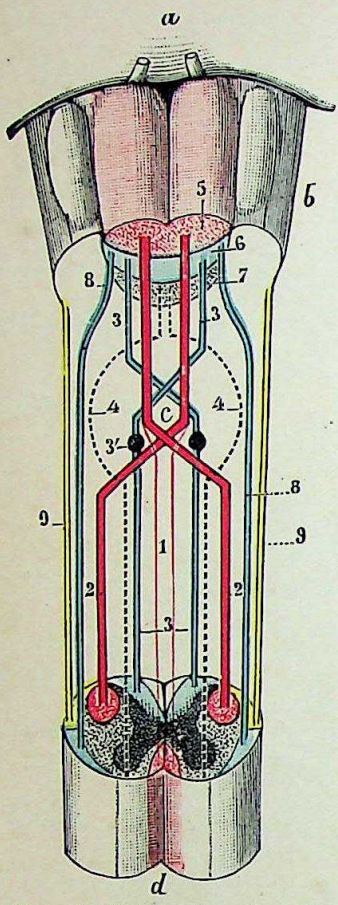

a. Pons. *b*. Medulla oblongata. *c*. Decussation of the pyramids. *d*. Section of cervical part of medulla spinalis. 1. Anterior cerebrospinal fasciculus (in red). 2. Lateral cerebrospinal fasciculus (in red). 3. Fasciculus gracilis and fasciculus cuneatus (in blue). 3'. Nucleus gracilis and nucleus cuneatus. 4. Anterolateral proper fasciculus (in dotted line). 5. Pyramid. 6. Lemniscus. 7. Medial longitudinal fasciculus. 8. Superficial anterolateral fasciculus (in blue). 9. Direct cerebellar tract (in yellow).

The greater part of the fasciculus proprius anterior of the medulla spinalis is continued upwards through the medulla oblongata under the name of the *medial longitudinal fasciculus*.

The **lateral region** of the medulla oblongata (fig. 800) is limited in front by the anterolateral sulcus and the roots of the hypoglossal nerve, and behind by the posterolateral sulcus and the roots of the accessory, vagus, and glossopharyngeal nerves. Its upper part consists of a prominent oval mass which is named the olive, while its lower part is of the same width as the lateral funiculus of the medulla spinalis, and appears on the surface to be a direct continuation of it. As a matter of fact, only a portion of the lateral funiculus of the medulla spinalis is continued upwards into this region, for the lateral cerebrospinal fasciculus passes into the pyramid of the opposite side, and the direct cerebellar tract is carried into the restiform body in the posterior region. The remainder of the lateral funiculus, which consists chiefly of the fasciculus proprius lateralis and the superficial anterolateral fasciculus, can be traced into the lateral region of the medulla oblongata. Most of these fibres dip beneath the olive and disappear from the surface; but a small strand remains superficial, and ascends between the olive and the posterolateral sulcus. In a depression at the upper end of this strand is the acoustic nerve.

The *olive* is situated lateral to the pyramid, from which it is separated by the anterolateral sulcus and the fibres of the hypoglossal nerve. Behind, it is separated from the posterolateral sulcus by the small superficial strand of the lateral funiculus already referred to. It is about 1·25 cm. long, and between its upper end and the pons there is a slight depression to which the roots of the facial nerve are attached. The external arcuate fibres wind backwards across the lower part of the pyramid and olive and enter the restiform body.

The **posterior region** of the medulla oblongata (fig. 801) lies behind the posterolateral sulcus and the roots of the accessory, vagus, and glossopharyngeal nerves, and, like the lateral region, is divisible into a lower and an upper portion.

The *lower part* is limited behind by the posterior median fissure, and consists of the *fasciculus gracilis* and the *fasciculus cuneatus*, the direct upward prolongations of the posterior funiculus of the medulla spinalis. The fasciculus gracilis is placed parallel to and along the side of the posterior median fissure, and is separated from the fasciculus cuneatus by the postero-intermediate sulcus and septum. The fasciculus gracilis and fasciculus cuneatus are at first

CC-0. In Public Domain. Gurukul Kangri Collection, Haridwar

Digitized by Arya Samaj Foundation Chennai and eGangotri

vertical; but at the lower part of the rhomboid fossa they diverge from the middle line in a V-shaped manner, and each presents an elongated swelling. The swelling on the fasciculus gracilis is named the *clava*, and is produced by a subjacent nucleus of grey substance, the *nucleus gracilis*; that on the fasciculus cuneatus is termed the *cuneate tubercle*, and is caused similarly by a grey nucleus, named the *nucleus cuneatus*. The fibres of these two fasciculi end by arborising around the cells in their respective nuclei. A third elevation, named the *tuberculum cinereum* (tubercle of Rolando), is present in the lower part of the posterior region of the medulla oblongata. It lies between the fasciculus cuneatus and the roots of the accessory nerve, and is narrow below but wider above; it ends superiorly at a distance of about 1·25 cm. below the pons. It is produced by a nucleus of grey substance which is continuous below with

FIG. 800.—The hind-brain and the mid-brain. Posterolateral aspect.

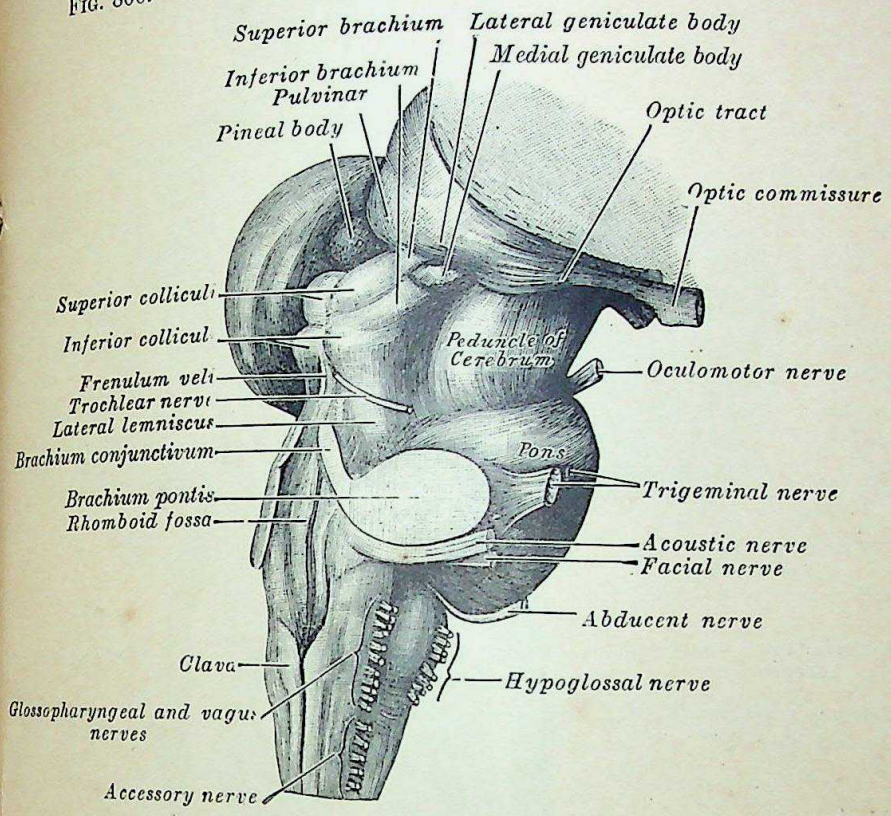

e substantia gelatinosa of Rolando, and in which the fibres of the tractus inalis, or spinal root, of the trigeminal nerve ends; these fibres separate e nucleus from the surface of the medulla oblongata.

The *upper part* of the posterior region of the medulla oblongata is occupied the *restiform body*, a thick rope-like strand situated between the lower part the fourth ventricle and the roots of the glossopharyngeal and vagus nerves. e two restiform bodies connect the medulla spinalis and medulla oblongata th the cerebellum, and are sometimes named the *inferior peduncles of the ebellum*. As they ascend, they diverge from one another, and assist in rming the lower parts of the lateral boundaries of the fourth ventricle; higher , they are directed backwards, each passing to the corresponding cerebellar misphere. Near their entrance into the cerebellum they are crossed by veral strands of fibres, which run to the median sulcus of the rhomboid fossa l are named the *striæ medullares*. The restiform body is not, although it pears to be, the upward continuation of the fasciculus gracilis and fasciculus eatus, since the fibres of these fasciculi end in the nucleus gracilis and leus cuneatus; its constitution will be subsequently discussed.

Internal structure of the medulla oblongata.—Although the external n of the medulla oblongata bears a certain resemblance to that of the upper t of the medulla spinalis, its internal structure differs widely from that of

CC-0. In Public Domain. Gurukul Kangri Collection, Haridwar

Digitized by Arya Samaj Foundation Chennai and eGangotri

the latter, and this for the following principal reasons: (1) certain fasciculi of nerve-fibres which extend from the medulla spinalis to the brain, or vice versa, undergo a rearrangement in their passage through the medulla oblongata; (2) other fasciculi of the medulla spinalis end in the medulla oblongata; (3) new fasciculi originate in the grey substance of the medulla oblongata and pass to different parts of the brain; (4) the grey substance, which in the medulla spinalis forms a continuous H-shaped column, is greatly modified and subdivided in the medulla oblongata, where also new masses of grey substance

FIG. 801.—The upper part of the medulla spinalis and the hind- and mid-brains. Exposed from behind.

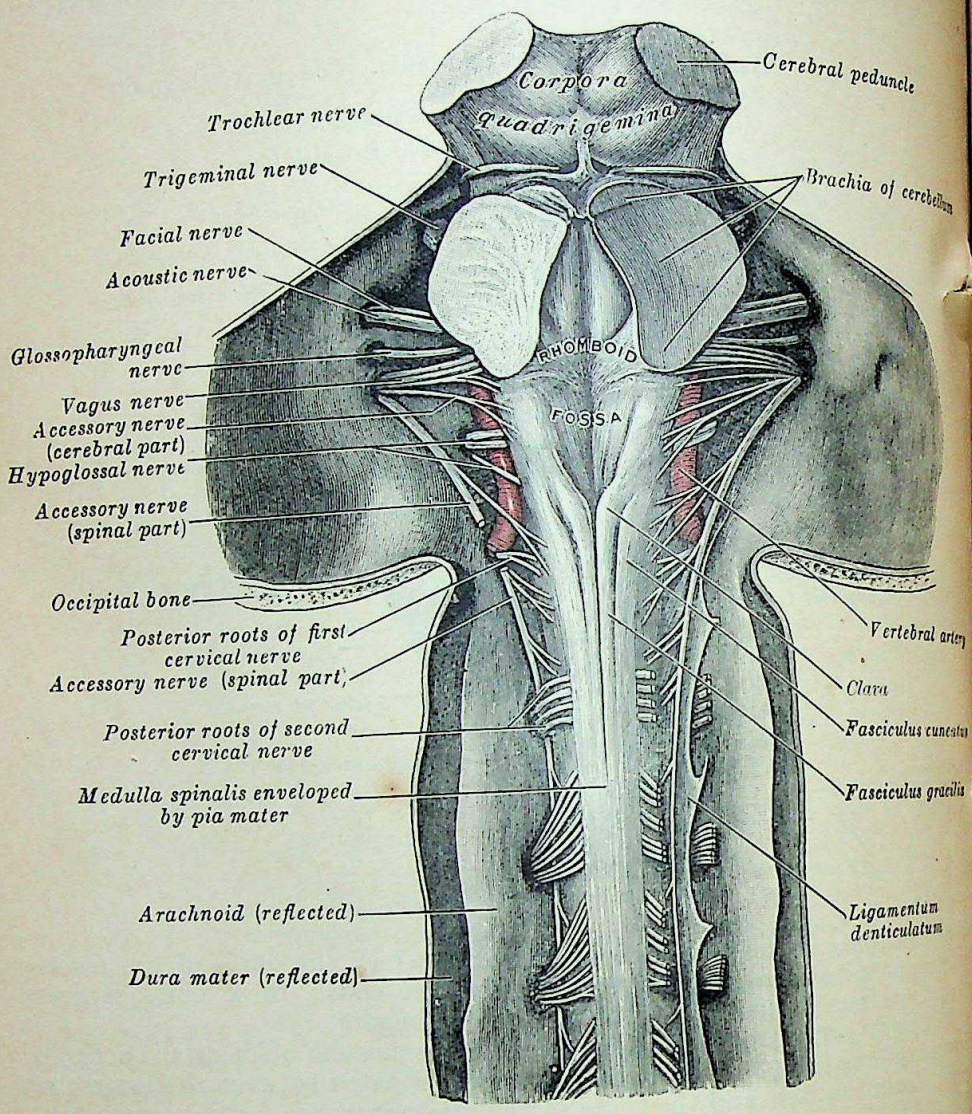

are added; (5) on account of the opening out of the central canal, certain parts of the grey substance, which in the medulla spinalis were more or less centrally situated, are displayed in the rhomboid fossa; (6) the medulla oblongata is intimately associated with many of the cerebral nerves, some arising from, and others ending in, nuclei within its substance. A short description of the course taken by the principal fasciculi, and of the arrangement of the grey substance, will now be given.

The **cerebrospinal fasciculi**.—The downward course of these fasciculi from the pyramids of the medulla oblongata and their partial decussation have already been described (p. 794). In crossing to the lateral funiculus of the opposite side, the fibres of the lateral cerebrospinal fasciculi run backwards through the anterior columns of grey substance, and separate the head of each of these columns from its base (figs. 802, 803). The base retains its

CC-0. In Public Domain. Gurukul Kangri Collection, Haridwar

Digitized by Arya Samaj Foundation Chennai and eGangotri

position in relation to the ventral aspect of the central canal, and, when the latter opens into the fourth ventricle, appears in the rhomboid fossa, or floor of the ventricle, close to the middle line, where it forms the nuclei of the hypoglossal and abducent nerves; while, above the level of the ventricle it exists as the nuclei of the trochlear and oculomotor nerves in relation to the floor of the cerebral aqueduct. The head of the column is pushed lateralwards and forms the *nucleus ambiguus* which gives origin from below upwards to the cerebral part of the accessory nerve and the motor fibres of the vagus and glossopharyngeal nerves: higher up, the head of the column is represented by the motor nuclei of the facial and trigeminal nerves.

Fig. 802.—A section through the medulla oblongata below the level of the decussation of the pyramids. Schematic. (Testut.)

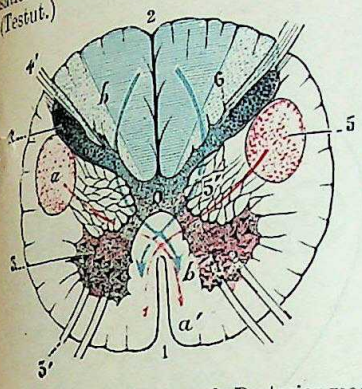

1. Anterior median fissure. 2. Posterior median sulcus. 3. Anterior column (in red), with 3', anterior root. 4. Posterior column (in blue), with 4', posterior root. 5. Lateral cerebrospinal fasciculus. 4. Posterior funiculus. The arrow, *a a'*, indicates the course of the decussation of the pyramids; the arrow, *b b'*, that of the decussation of the lemniscus.

Fig. 803.—A section through the medulla oblongata at the level of the decussation of the pyramids. Schematic. (Testut.)

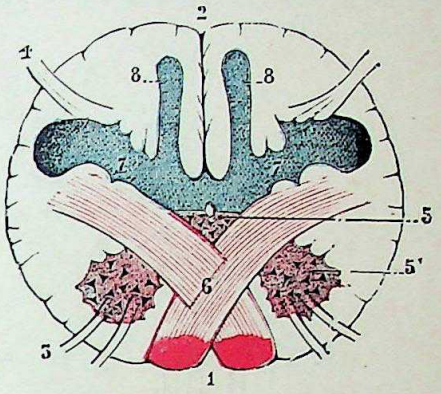

1. Anterior median fissure. 2. Posterior median sulcus. 3. Motor roots. 4. Sensory roots. 5. Base of the anterior column, from which the head (5') has been detached by the lateral cerebrospinal fasciculus. 6. Decussation of the pyramids. 7. Posterior columns (in blue). 8. Nucleus gracilis.

The **fasciculus gracilis** and **fasciculus cuneatus** constitute the posterior sensory fasciculi of the medulla spinalis; they are prolonged upwards into the lower part of the medulla oblongata, where they end in the nucleus gracilis and nucleus cuneatus. These two nuclei are continuous with the central grey substance of the medulla spinalis of which they may be regarded as dorsal projections, each being covered superficially by the fibres of the corresponding fasciculus. On transverse section, the nucleus gracilis appears as a single, more or less quadrangular mass, while the nucleus cuneatus consists of a larger *medial nucleus*, composed of small or medium-sized cells, and a smaller *lateral nucleus* containing large cells.

The fibres of the fasciculus gracilis and fasciculus cuneatus end by arborising around the cells of these nuclei (fig. 804). From the cells of the nuclei new fibres arise; some of these are continued as the external arcuate fibres into the restiform body of the same side, and through it to the cerebellum, but most of them pass forwards as the *internal arcuate fibres* through the neck of the posterior column, thus cutting off its head from its base (fig. 805). Curving forwards, they cross the middle line, and run upwards immediately behind the cerebrospinal fibres, as a flattened band, named the *lemniscus* or *fillet*. The crossing of these sensory fibres is situated above that of the motor fibres and reaches as high as the middle of the olive; it constitutes the *decussation of the lemniscus* or *sensory decussation*.

The base of the posterior column at first lies on the dorsal aspect of the central canal, but when the latter opens into the fourth ventricle, it appears in the lateral part of the rhomboid fossa. It forms the terminal nuclei of the sensory fibres of the vagus and glossopharyngeal nerves, and is associated with the vestibular part of the acoustic nerve and the sensory root of the facial nerve. Still higher, it forms a mass of pigmented cells—the *locus coeruleus*—in which some of the sensory fibres of the trigeminal nerve appear

CC-0. In Public Domain. Gurukul Kangri Collection, Haridwar

Digitized by Arya Samaj Foundation Chennai and eGangotri

to end. The head of the posterior column forms the tuberculum cinereum, a long nucleus, in which the fibres of the spinal tract of the trigeminal nerve largely end.

The direct cerebellar tract leaves the lateral region of the medulla oblongata; most of its fibres are carried backwards into the restiform body of the same side, and through it are conveyed to the cerebellum; but some run upwards with the fibres of the lemniscus, and, reaching the inferior colliculus, undergo decussation, and are carried to the cerebellum through the brachium conjunctivum.

The fasciculi proprii (basis bundles) of the anterior and lateral funiculi of the medulla spinalis largely consist of intersegmental fibres, which link together

FIG. 804.—A scheme showing the superior terminations of the fasciculus gracilis and fasciculus cuneatus of the medulla spinalis. (Testut.)

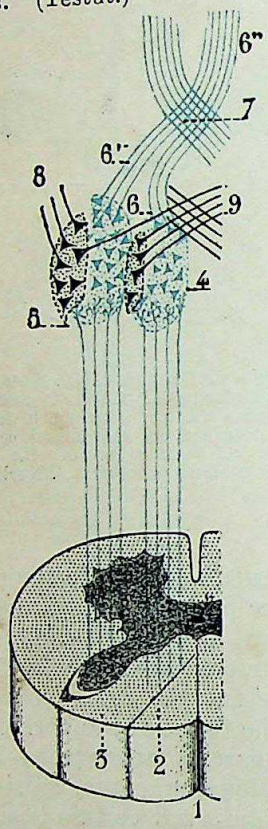

1. Posterior median sulcus. 2. Fasciculus gracilis. 3. Fasciculus cuneatus. 4. Nucleus gracilis. 5. Nucleus cuneatus. 6, 6', 6", Sensory fibres forming the lemniscus. 7. Sensory decussation. 8. Cerebellar fibres, uncrossed. 9. Cerebellar fibres, crossed.

FIG. 805.—A transverse section through the sensory decussation (decussation of the lemniscus). Schematic. (Testut.)

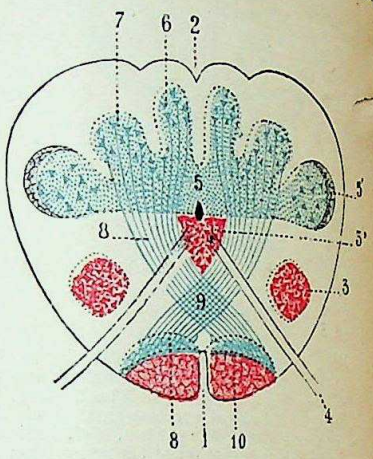

1. Anterior median fissure. 2. Posterior median sulcus. 3, 3'. Head and base of the anterior column (in red). 4. Hypoglossal nerve. 5. Bases of the posterior columns. 5'. Tuberculum cinereum (tubercle of Rolando). 6. Nucleus gracilis. 7. Nucleus cuneatus. 8, 8. Lemniscus. 9. Sensory decussation. 10. Pyramid.

its different segments; they assist in the production of the formatio reticularis of the medulla oblongata, and many of them are accumulated into a fasciculus which runs up close to the median raphe between the lemniscus and the rhomboid fossa; this strand is named the *medial longitudinal fasciculus*, and will be described more fully later (p. 827).

Grey substance of the medulla oblongata (figs. 806, 807).—In addition to the gracile and cuneate nuclei, there are several other nuclei to be considered. Some of these are traceable from the grey substance of the medulla spinalis, while others are unrepresented in it.

1. The *hypoglossal nucleus* is derived from the base of the anterior column; in the lower, closed part of the medulla oblongata it is situated on the ventro-lateral aspect of the central canal, but in the upper, open part it approaches the rhomboid fossa, where it lies close to the middle line, under an eminence named the *trigonum hypoglossi* (fig. 821). The nucleus measures about 2 cm. in length, and consists of large multipolar nerve-cells the axons of which constitute the roots of the hypoglossal nerve. These nerve-roots pass forward between the anterior and lateral regions of the medulla oblongata, and emerge at the anterolateral sulcus.

CC-0. In Public Domain. Gurukul Kangri Collection, Haridwar

Digitized by Arya Samaj Foundation Chennai and eGangotri

2. The *motor nucleus* (figs. 808, 809) common to the *glossopharyngeal, vagus,* and cerebral part of the *accessory* nerves is named the *nucleus ambiguus.* It

Fig. 806.—A transverse section through the medulla oblongata at about the middle of the olive. (Schwalbe.)

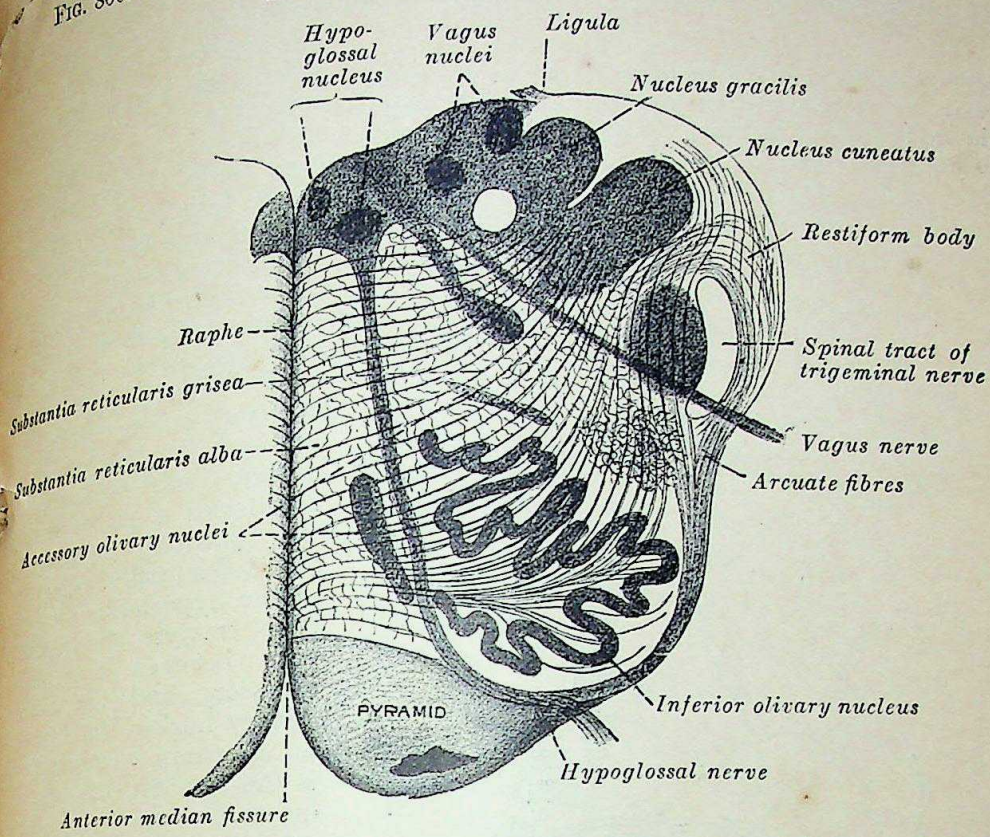

Fig. 807.—A transverse section through the medulla oblongata below the middle of the olive.

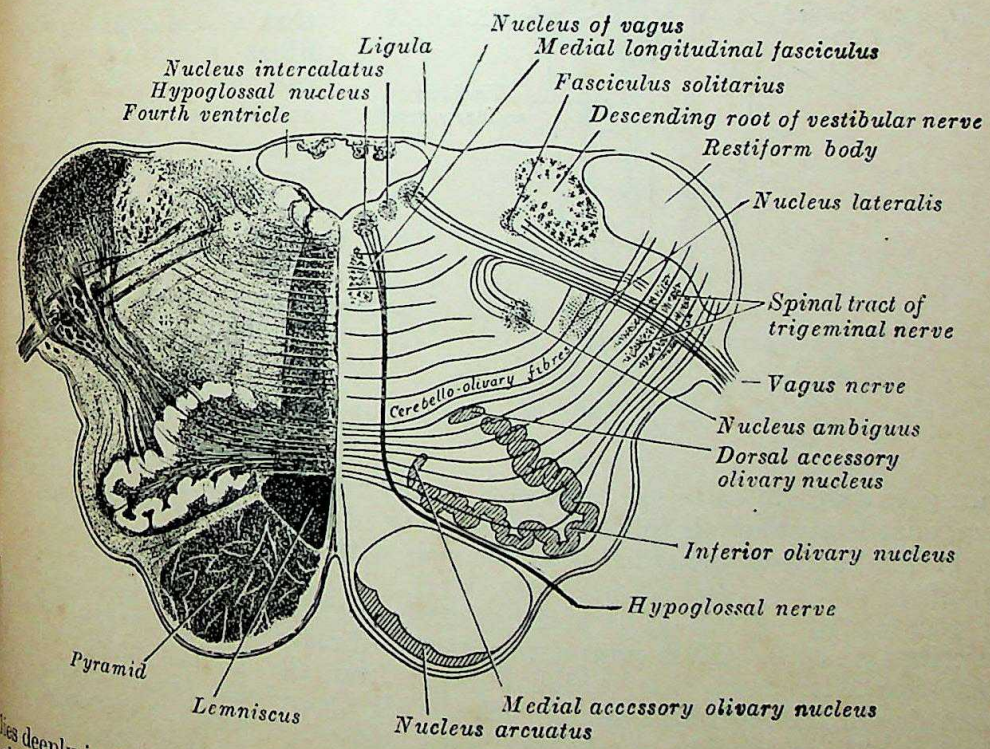

lies deeply in the formatio reticularis grisea, and extends throughout nearly the whole length of the medulla oblongata.

CC-0. In Public Domain. Gurukul Kangri Collection, Haridwar

Digitized by Arya Samaj Foundation Chennai and eGangotri

3. The afferent fibres of the *facial, glossopharyngeal* and *vagus* end in the fasciculus solitarius (p. 811).

4. The *nuclei of the acoustic nerve* are described on p. 814.

5. The *olivary nuclei* (figs. 806, 807) are three in number on either side of the middle line, viz. the inferior olivary nucleus, and the medial and dorsal accessory olivary nuclei; they consist of small, round, yellowish cells and numerous fine nerve-fibres. (*a*) The *inferior olivary nucleus* is the largest, and is situated within the olive. It consists of a grey folded lamina arranged in the form of an incomplete capsule, opening medially by an aperture called the *hilum*; emerging from the hilum are numerous fibres which collectively constitute the *peduncle of the olive*. (*b*) The *medial accessory olivary nucleus* lies between the inferior olivary nucleus and the pyramid, and forms a curved lamina, the concavity of which is directed laterally. The fibres of the hypoglossal nerve, as they traverse the medulla, pass between the medial accessory and the inferior olivary nuclei. (*c*) The *dorsal accessory olivary nucleus* is the smallest, and appears on transverse section as a curved lamina behind the inferior olivary nucleus.

FIG. 808.—The nuclei of the cerebral nerves schematically represented. Dorsal aspect. Motor nuclei, in red; sensory in blue. (The olfactory and optic centres are omitted.)

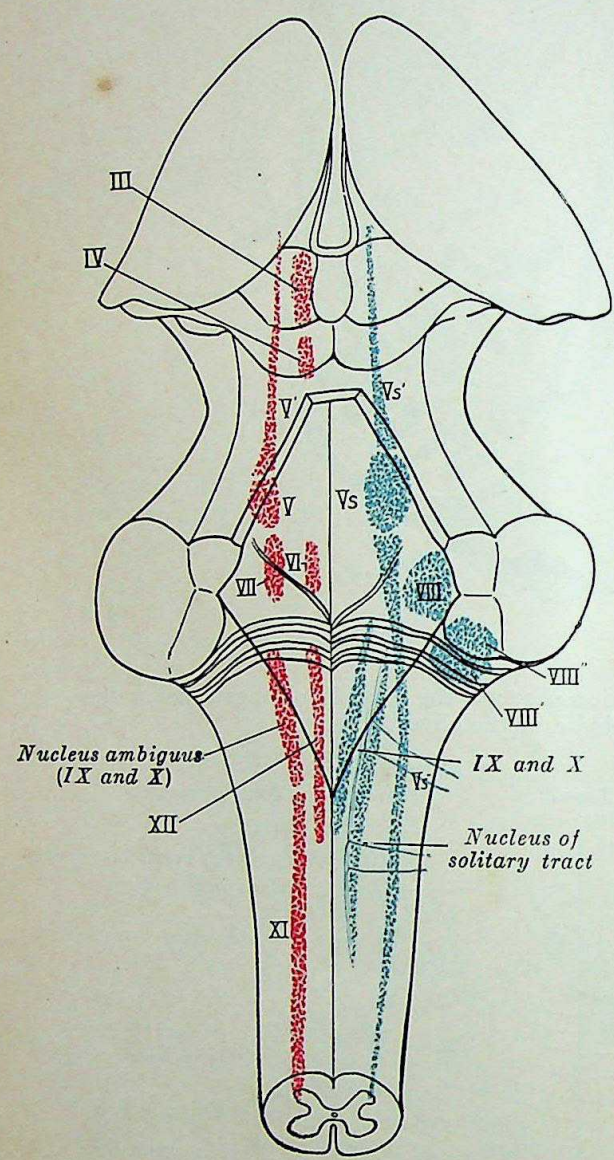

The inferior olivary nucleus is connected—(1) with that of the opposite side by fibres which cross through the raphe; (2) with the anterior column of the same side of the medulla spinalis by the *spino-olivary fasciculus*; (3) with the thalamus of the cerebrum by the *cerebro-olivary fasciculus* which passes through the pons and tegmentum; (4) with the opposite cerebellar hemisphere by the *olivo-cerebellar fasciculus* (fig. 811), the fibres of which cross the raphe and turn backwards to enter the deep part of the restiform body. Removal of one cerebellar hemisphere is followed by atrophy of the opposite olivary nucleus.

6. The *nucleus arcuatus* is described with the external arcuate fibres (p. 811).

Restiform bodies.—The position of the restiform bodies has already been described (p. 803). Each comprises: (1) the direct cerebellar tract or posterior spino-cerebellar fasciculus, which ascends from the lateral funiculus of the same side of the medulla spinalis; (2) the olivo-cerebellar fasciculus, described above; (3) descending cerebellar fibres, many of which are disseminated throughout the peripheral part of the anterior and lateral funiculi of the medulla spinalis, while others pass to the motor nuclei of the cerebral nerves; and (4) the external arcuate fibres.

CC-0. In Public Domain. Gurukul Kangri Collection, Haridwar

Digitized by Arya Samaj Foundation Chennai and eGangotri

FIG. 809.—The nuclei of origin of the cerebral motor nerves schematically represented. Lateral aspect.

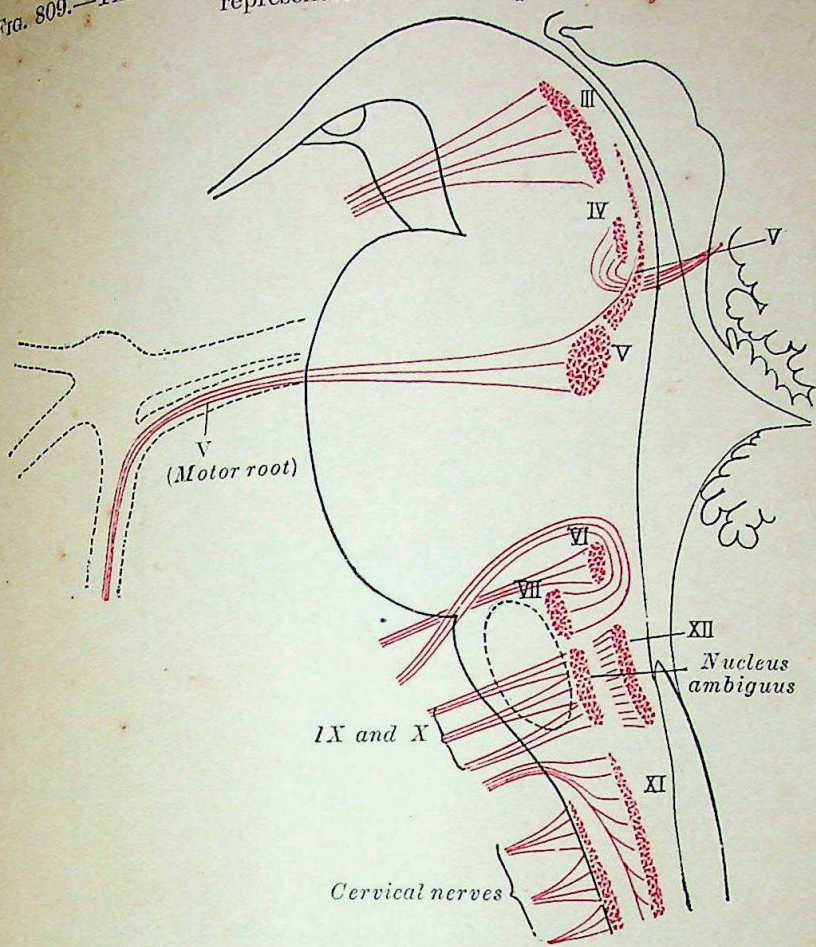

FIG. 810.—The primary terminal nuclei of the afferent (sensory) cerebral nerves schematically represented. Lateral aspect. (The olfactory and optic centres are omitted.)

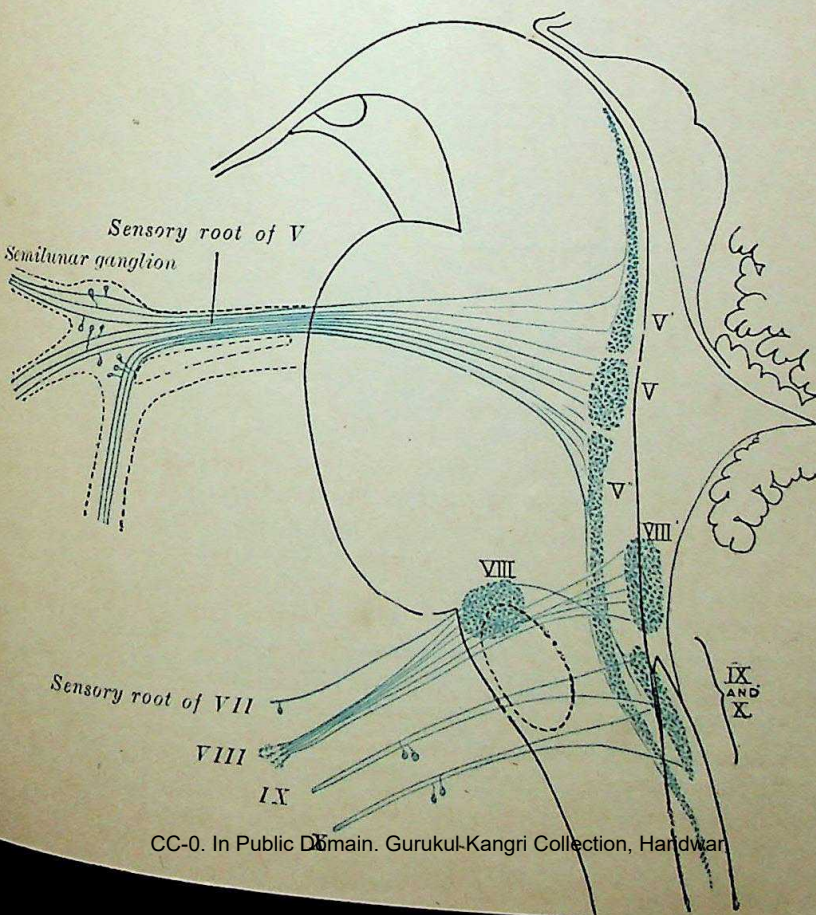

CC-0. In Public Domain. Gurukul Kangri Collection, Haridwar

Digitized by Arya Samaj Foundation Chennai and eGangotri

FIG. 811.—A scheme showing the course of the arcuate fibres. (Testut.)

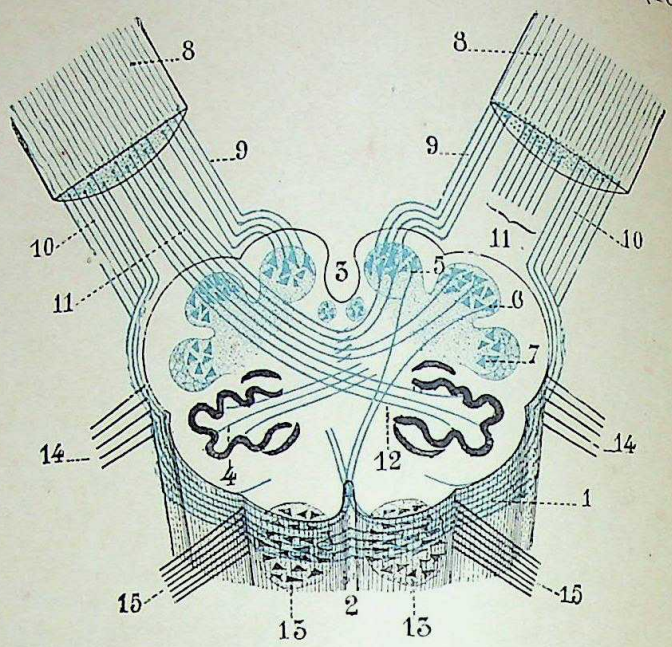

1. Medulla oblongata, anterior surface. 2. Anterior median fissure. 3. Fourth ventricle. 4. Inferior olivary nucleus, with the accessory olivary nuclei. 5. Nucleus gracilis. 6. Nucleus cuneatus. 7. Spinal tract and nucleus of trigeminal nerve. 8. Restiform bodies. 9. Posterior external arcuate fibres. 10. Anterior external arcuate fibres. 11. Olivo-cerebellar fasciculus. 12. Peduncle of inferior olivary nucleus. 13. Nucleus arcuatus. 14. Vagus nerve. 15. Hypoglossal nerve.

FIG. 812.—A transverse section of the medulla oblongata through the middle of the olive, showing the formatio reticularis. Schematic. (Testut.)

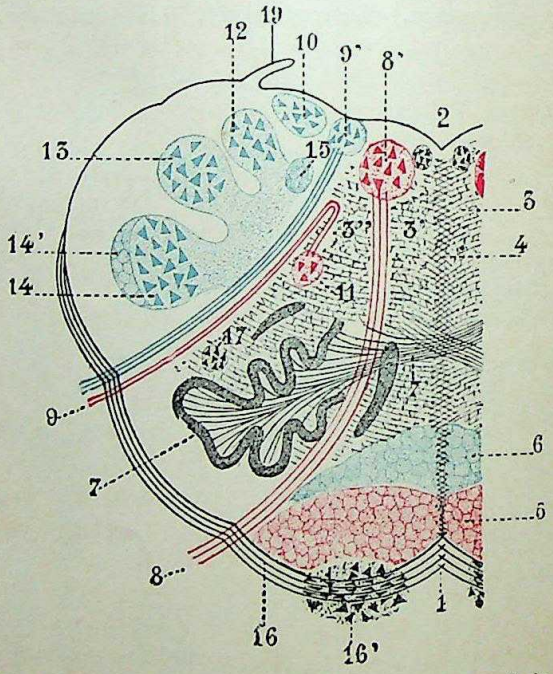

1. Anterior median fissure. 2. Fourth ventricle. 3. Formatio reticularis, with 3', its internal part (reticularis alba), and 3'', its external part (reticularis grisea). 4. Raphe. 5. Pyramid. 6. Lemniscus. 7. Inferior olivary nucleus, with the two accessory olivary nuclei. 8. Hypoglossal nerve, with 8', its nucleus of origin. 9. Vagus nerve, with 9', its nucleus of termination. 10. Medial vestibular nucleus. 11. Nucleus ambiguus (nucleus of origin of motor fibres of glossopharyngeal, vagus, and cerebral portion of accessory). 12. Nucleus gracilis. 13. Nucleus cuneatus. 14. Nucleus of trigeminal nerve, with 14', the spinal root of trigeminal nerve. 15. Fasciculus solitarius. 16. External arcuate fibres, with 16', the nucleus arcuatus. 17. Nucleus lateralis. 19. Ligula.

CC-0. In Public Domain. Gurukul Kangri Collection, Haridwar

Digitized by Arya Samaj Foundation Chennai and eGangotri

The *external arcuate fibres* vary as to their prominence in different brains; in some they form an almost continuous layer covering the pyramid and olive, while in others they are barely visible on the surface. They arise from the cells of the nucleus gracilis and nucleus cuneatus, pass forwards through the formatio reticularis, and decussate in the middle line. Most of them reach the surface by way of the anterior median fissure, and arch backwards over the pyramid. Reinforced by others which emerge between the pyramid and olive, they pass backwards over the olive and lateral region of the medulla oblongata, and enter the restiform body. They thus connect the cerebellum with the nucleus gracilis and nucleus cuneatus of the opposite side. As the fibres arch across the pyramid, they enclose a small nucleus which lies in front of and medial to the pyramid. This is named the *nucleus arcuatus*, and is serially continuous above with the nuclei pontis: it contains small fusiform cells, around which some of the arcuate fibres end, and from which others arise.

A few fibres are said to arise from the nucleus gracilis and nucleus cuneatus and to pass to the restiform body of the same side.

Formatio reticularis (fig. 812).—This term is applied to the coarse reticulum which occupies the anterior and lateral regions of the medulla oblongata. It is situated behind the pyramid and olive, extending laterally as far as the restiform bodies, and dorsally to within a short distance of the rhomboid fossa. The reticulum is caused by the intersection of bundles of fibres running at right angles to each other, some being longitudinal, others more or less transverse in direction. In the formatio reticularis of the anterior region, there is an almost entire absence of nerve-cells, and hence this part is known as the *substantia reticularis alba*; whereas in the lateral region nerve-cells are numerous, and as a consequence the formatio presents a grey appearance, and is termed the *substantia reticularis grisea*.

In the substance of the formatio reticularis are two small nuclei of grey matter: one, the *nucleus of Roller*, near the ventral surface of the hypoglossal nucleus; the other, the *nucleus lateralis*, between the olive and the spinal tract of the trigeminal nerve.

In the substantia reticularis alba the chief longitudinal fibres consist of the *lemniscus*, which lies close to the raphe, immediately behind the pyramid; the *tectospinal fasciculus*, behind the lemniscus; and still more posteriorly, the *medial longitudinal fasciculus*. In the substantia reticularis grisea the ascending fibres comprise the *spinocerebellar*, *spinothalamic*, and *spinotectal fasciculi*; the descending fibres include the *rubrospinal* and *thalamo-olivary fasciculi*, and the *fasciculus solitarius*, the last consisting of the downwardly directed afferent fibres of the facial, vagus and glosso-pharyngeal nerves. The transverse fibres of the formatio reticularis are the arcuate fibres already described (p. 805, and above).

Applied Anatomy.—In *bulbar paralysis*, i.e. paralysis of the medulla oblongata, which is really a special form of a progressive degeneration affecting the whole efferent or motor tract, the disease begins with impairment of the movements of the lips, tongue, pharynx, and larynx, due to degeneration of the cells in the motor nuclei of the medulla oblongata. Speech and swallowing become difficult, and the saliva dribbles from the open mouth. Other groups of muscles soon become involved, and death often occurs from 'aspiration pneumonia,' set up by food that has accidentally passed down the trachea.

The Pons

The **pons** (pons Varolii) or fore part of the rhombencephalon is situated in front of the cerebellum. From its upper part the cerebral peduncles emerge, one on either side of the middle line. Behind and below, the pons is continuous with the medulla oblongata, but is separated from it in front and laterally by a transverse furrow in which the abducent, facial, and acoustic nerves appear.

Its *ventral or anterior surface* (fig. 798) is prominent, markedly convex from side to side, less so from above downwards. It consists of transverse fibres arched like a bridge across the middle line, and gathered on either side into a compact mass which forms the brachium pontis. It rests upon the clivus of

CC-0. In Public Domain. Gurukul Kangri Collection, Haridwar

Digitized by Arya Samaj Foundation Chennai and eGangotri

the sphenoidal bone, and is limited above and below by well-defined borders. In the middle line is the shallow *sulcus basilaris* for the lodgment of the basilar artery; this sulcus is bounded on either side by an eminence caused by the descent of the cerebrospinal fibres through the substance of the pons. Lateral to these eminences, near the upper border of the pons, the trigeminal nerves make their exit, each consisting of a smaller, medial, motor root, and a larger, lateral, sensory root; vertical lines drawn immediately lateral to the attachments of the trigeminal nerves, may be taken as the boundaries between the ventral surface of the pons and the brachia pontis.

Its *dorsal or posterior surface*, triangular in shape, is hidden by the cerebellum, and is bounded laterally by the brachia conjunctiva; it forms the upper part of the rhomboid fossa, with which it will be described.

FIG. 813.—A coronal section through the upper part of the pons. (Testut.)

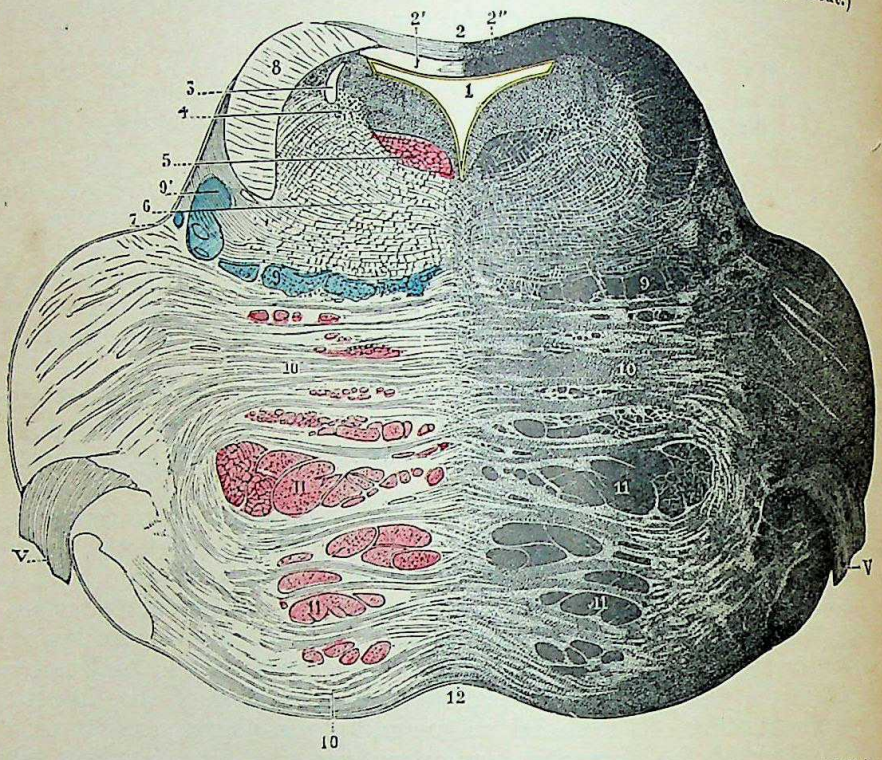

1. Fourth ventricle; its ependyma is coloured yellow. 2. Anterior medullary velum, with 2′, its white stratum, and 2″, its grey stratum. 3. Mesencephalic root of trigeminal nerve. 4. Nerve-cells associated with this root. 5. Medial longitudinal fasciculus. 6. Formatio reticularis. 7. Lateral sulcus. 8. Section of brachium conjunctivum. 9. Medial lemniscus. 9′. Lateral lemniscus. 10, 10. Transverse fibres of pons. 11, 11. Cerebrospinal fasciculi. 12. Raphe. V. Trigeminal nerve.

Structure (fig. 813).—Transverse sections through the pons show it to be composed of two parts; a ventral or basilar portion consisting for the most part of fibres arranged in transverse and longitudinal bundles, together with a small amount of grey substance; and a dorsal or tegmental portion continuous with the reticular formation of the medulla oblongata, and most of the constituents of which are prolonged into the tegmenta of the cerebral peduncles.

The *ventral or basilar part* of the pons consists of: (*a*) superficial and deep transverse fibres, (*b*) longitudinal fasciculi, and (*c*) some small nuclei of grey substance termed the nuclei pontis.

The *superficial transverse fibres* constitute a rather thick layer on the ventral surface of the pons, and are collected into a large rounded bundle on either side. This bundle, with the addition of some transverse fibres from the deeper portion of the pons, forms the greater part of the brachium pontis.

The *deep transverse fibres* partly intersect and partly lie on the dorsal aspect of the longitudinal fasciculi. They course to the lateral border of the pons, and form part of the brachium pontis; the further connexions of the brachium pontis will be discussed with the anatomy of the cerebellum.

CC-0. In Public Domain. Gurukul Kangri Collection, Haridwar

Digitized by Arya Samaj Foundation Chennai and eGangotri

The *longitudinal fasciculi* are continued from the cerebral peduncles, and enter the upper surface of the pons. They stream downwards on either side of the middle line in bundles, separated from one another by the deep transverse fibres, and give rise to the eminences on the anterior surface. Some of these fibres end in the nuclei pontis, and others, after decussating, in the nuclei of the abducent and hypoglossal nerves, and in the motor nuclei of the trigeminal and facial nerves; but many pass through the pons, at the lower margin of which they are collected into the pyramids of the medulla oblongata. The fibres which end in the motor nuclei of the cerebral nerves are derived from the pyramidal cells of the cerebral cortex, and bear the same relation to the motor cells of the cerebral nerves as the cerebrospinal fibres bear to the motor cells in the anterior column of the medulla spinalis.

The *nuclei pontis* are serially continuous with the arcuate nuclei in the medulla oblongata, and consist of small groups of multipolar nerve-cells which are scattered between the bundles of transverse fibres; the axons of these cells are continuous with the transverse fibres of the pons.

The *dorsal or tegmental part* of the pons is chiefly composed of an upward continuation of the reticular formation and grey substance of the medulla oblongata; it is divided by a median raphe. It consists of transverse and longitudinal fibres and contains important grey nuclei. In the lower part of the pons the transverse fibres of the tegmental part are collected into a strand, named the *trapezoid body*. This consists of fibres which arise from the cells of the ventral or accessory cochlear nucleus and of the superior olivary nucleus, and will be referred to in connexion with the cochlear division of the acoustic nerve. In the substance of the trapezoid body is a collection of nerve-cells, termed the *trapezoid nucleus*. Of the longitudinal fibres three fasciculi must be mentioned. They are (*a*) the upward prolongation of the *lemniscus* which, as it ascends, assumes the form of a flat band; (*b*) the *medial longitudinal* fasciculus, situated near the floor of the fourth ventricle; and (*c*) the *anterior* spinocerebellar fasciculus which passes to the cerebellum by way of the brachium conjunctivum.

The rest of the dorsal part of the pons is a continuation upwards of the formatio reticularis of the medulla oblongata, and, like it, presents the appearance of a network, in the meshes of which are numerous nerve-cells. Besides these scattered nerve-cells, there are some larger masses of grey substance, viz. the superior olivary nucleus, and the nuclei of the trigeminal, abducent, facial, and acoustic nerves (fig. 808).

1. The *superior olivary nucleus* is a small mass of grey substance situated on the dorsal surface of the lateral part of the trapezoid body. Rudimentary in man, but well developed in certain animals, it exhibits the same structure as the inferior olivary nucleus, and is situated immediately above it. Some of the fibres of the trapezoid body end by arborising around the cells of the superior olivary nucleus, while others arise from these cells.

2. The *nuclei of the trigeminal nerve* in the pons are motor and sensory. The *inferior or chief motor nucleus* is situated in the upper part of the pons close to its posterior surface and along the line of the lateral margin of the fourth ventricle. The axons of its cells form a portion of the motor root of the trigeminal nerve: the remaining fibres of the motor root of this nerve consist of a fasciculus which arises from a nucleus in the grey substance of the floor of the cerebral aqueduct, and hence is named the *mesencephalic root*.* The sensory fibres of the trigeminal nerve arise from the cells of the semilunar ganglion. Some of these fibres end in a nucleus which is placed lateral to the motor one, and beneath the brachium conjunctivum; but the greater number descend, under the name of the *spinal tract of the trigeminal nerve*, to end in a nucleus which is continuous below with the substantia gelatinosa of Rolando. The motor and sensory roots of the trigeminal nerve pass through the substance of the pons and emerge near the upper margin of its anterior surface.

3. The *nucleus of the abducent nerve* is a spherical mass of grey substance situated close to the floor of the fourth ventricle, above the striæ medullares and subjacent to the colliculus facialis. The fibres of the abducent nerve pass forward through the entire thickness of the pons on the medial side of the superior olivary nucleus and between the lateral fasciculi of the cerebrospinal

CC-0. In Public Domain. Gurukul Kangri Collection, Haridwar

* See footnote on p. 893.

Digitized by Arya Samaj Foundation Chennai and eGangotri

fibres, and emerge in the furrow between the lower border of the pons and the pyramid of the medulla oblongata.

4. The *nucleus of the facial nerve* is situated deeply in the reticular formation of the pons on the dorsal aspect of the superior olivary nucleus, and the roots of the nerve derived from it pursue a remarkably tortuous course in the substance of the pons. At first they pass backwards and medialwards until they reach the rhomboid fossa, close to the median sulcus, where they are collected into a round bundle; this bundle passes upwards and forwards, producing an elevation, the *colliculus facialis*, in the rhomboid fossa, and then taking a sharp lateral bend round the nucleus of the abducent nerve, passes through the pons to emerge at its lower border in the interval between the olive and the restiform body of the medulla oblongata.

5. The *nuclei of the acoustic nerve.*—The acoustic nerve consists of a cochlear and a vestibular nerve. The fibres of the cochlear nerve end in two nuclei: (*a*) the *lateral cochlear nucleus*, on the lateral surface of the restiform body; and (*b*) the *ventral or accessory cochlear nucleus*, on the ventral surface of the restiform body. The nuclei in which the vestibular nerve ends are (*a*) the *medial or chief vestibular nucleus*, corresponding to the lower part of the area acustica in the rhomboid fossa; the caudal end of this nucleus is termed (*b*) the *descending or spinal vestibular nucleus*; (*c*) the *lateral vestibular nucleus* (nucleus of Deiters), consisting of large multipolar cells and situated in the lateral angle of the rhomboid fossa; the dorsolateral part of this nucleus is sometimes termed (*d*) the *superior vestibular nucleus* (nucleus of Bechterew).

Applied Anatomy.—Injury to the pons, such as may occur on the occlusion or rupture of one of its blood-vessels, often gives rise to a special train of symptoms that is almost diagnostic. Pontine lesions are characterised mainly by 'alternate paralyses'; that is to say, by paralysis of the muscles supplied by one of the motor cerebral nerves on one side, and of the limbs on the other side of the body. Thus a hæmorrhage into the lower part of the pons might cause paralysis of the face ('lower segment paralysis') on the same side, from destruction of the facial nucleus or nerve-root, and paralysis of the arm and leg on the opposite side from injury to the adjacent cerebrospinal tract. In the same way, paralysis of the Rectus lateralis of one eye and of the Rectus medialis of the other ('conjugate paralysis' of the muscles turning the two eyes in one direction) and often paralysis of one side of the face as well, together with palsy of the limbs on the opposite side of the body, may be found when the lesion occurs about the nucleus of the abducent nerve. Hearing is often unaffected in pontine lesions, possibly because the central acoustic tract occupies a ventral and lateral position in the pons.

The Cerebellum

The **cerebellum**, the largest part of the hind-brain, lies behind the pons and medulla oblongata. Between its central portion and these structures is the cavity of the fourth ventricle. It rests on the inferior fossæ of the occipital bone and is covered by the tentorium cerebelli (p. 879). It is somewhat ovoid in form, but constricted in its median part, and flattened from above downwards, its greatest diameter being from side to side. Its surface is not convoluted like that of the cerebrum, but is traversed by numerous curved furrows or sulci, which vary in depth at different parts, and separate the laminæ of which it is composed. Its average weight in the male is about 150 gms. In the adult the proportion between the cerebellum and cerebrum is about 1 to 8, in the infant about 1 to 20.

Lobes of the cerebellum.—The cerebellum consists of a median constricted part, the *vermis*, and two lateral expanded portions, the *hemispheres*. On the upper surface of the cerebellum the vermis is elevated above the level of the hemispheres, but on the under surface it is sunk almost out of sight in a deep depression between them; this depression is called the *vallecula cerebelli*, and lodges also the posterior part of the medulla oblongata. The part of the vermis on the upper surface of the cerebellum is named the *superior vermis*; that on the lower surface, the *inferior vermis*. The hemispheres are separated below and behind by a deep notch, the *posterior cerebellar notch*, and in front by a broader, shallower notch, the *anterior cerebellar notch*. The posterior notch contains the upper part of the falx cerebelli, a fold of dura mater. The anterior notch lies close to the pons and upper part of the

CC-0. In Public Domain. Gurukul Kangri Collection, Haridwar

Digitized by Arya Samaj Foundation Chennai and eGangotri

medulla, and its superior edge curves round the inferior colliculi and the brachia conjunctiva cerebelli.

The cerebellum is characterised by its laminated or foliated appearance; it is marked by curved fissures, which extend for a considerable distance into its substance, and divide it into a series of layers or folia. The largest and deepest fissure is named the *horizontal sulcus*. On either side it commences in front at the pons, and passes horizontally round the free margin of the hemisphere to the middle line behind; it divides the cerebellum into an upper and a lower portion. Several secondary but deep fissures separate the cerebellum into lobes, and these are further subdivided by shallower sulci, which separate the individual folia or laminæ from each other. Sections across the laminæ show that the folia consist of central white substance covered by grey substance.

The cerebellum is connected to the cerebrum by the brachia conjunctiva, to the pons by the brachia pontis, and to the medulla oblongata by the restiform bodies.

Fig. 814.—The cerebellum. Superior aspect. (Sharpey Schafer.)

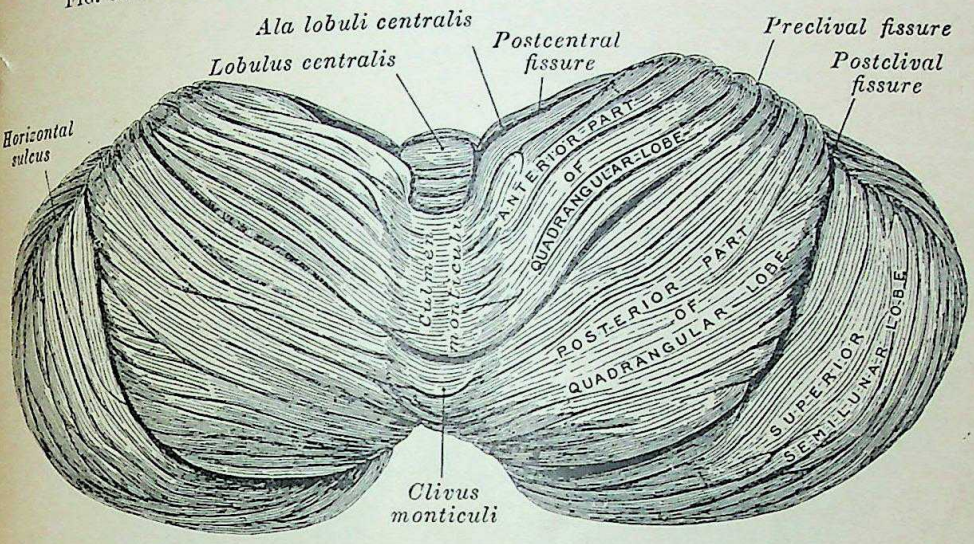

The **superior surface of the cerebellum** (fig. 814) presents a raised median ridge, the superior vermis, which is not sharply defined from the hemispheres.

The superior vermis, most prominent in front, is subdivided from before backwards into the lingula, the lobulus centralis, the monticulus, and the folium vermis, and each of these with the exception of the lingula, is continuous with corresponding parts of the hemispheres—the lobulus centralis with the alæ, the monticulus with the quadrangular lobules, and the folium vermis with the superior semilunar lobules.

The **lingula** is a small tongue-shaped process, consisting of four or five folia; it lies in front of and is concealed by the lobulus centralis. It rests on the dorsal surface of the anterior medullary velum, and its white substance is continuous with that of the velum.

The **lobulus centralis and alæ**.—The lobulus centralis is a small square lobule situated in the anterior cerebellar notch. It overlaps the lingula, but is separated from it by the *precentral fissure*; laterally, it is continued into each hemisphere, as a wing-like prolongation, the *ala lobuli centralis*.

The **monticulus and quadrangular lobules**.—The monticulus is the largest part of the superior vermis. Anteriorly, it overlaps the lobulus centralis from which it is separated by the *postcentral fissure*; laterally, it is continuous with the *quadrangular lobules* in the hemispheres. It is divided by the *preclival fissure* (fissura prima) into an anterior, raised part, the *culmen* or summit, and a posterior sloped part, the *clivus*: the quadrangular lobule is similarly divided. The culmen and the anterior parts of the quadrangular lobules form the *lobus culminis*; the clivus and the posterior parts, the *lobus clivi*.

CC-0. In Public Domain. Gurukul Kangri Collection, Haridwar

Digitized by Arya Samaj Foundation Chennai and eGangotri

The folium vermis and superior semilunar lobules.—The folium vermis (folium cacuminis) is a short, narrow, concealed band at the posterior end of the superior vermis, consisting apparently of a single folium, but in reality marked on its upper and under surfaces by secondary fissures. Laterally, it expands in either hemisphere into a considerable lobule, the *superior semilunar lobule*, which occupies the posterior one-third of the upper surface of the hemisphere, and is bounded below by the *horizontal sulcus*. The folium vermis and the superior semilunar lobules form the *lobus semilunaris*.

The inferior surface of the cerebellum (fig. 815) presents, in the middle line, the *inferior vermis*, buried in the vallecula, and separated from the hemisphere on either side by a deep groove, the *sulcus vallecullæ*. This surface, like the superior, is divided into lobules; but the arrangement is more complicated, and the relations of the parts of the vermis to those of the hemispheres are less clearly marked. The inferior vermis is subdivided from before backwards, into: (1) the *nodule*, (2) the *uvula*, (3) the *pyramid*, and (4) the *tuber*

FIG. 815.—The cerebellum. Interior aspect. (Sharpey Schaffer.)

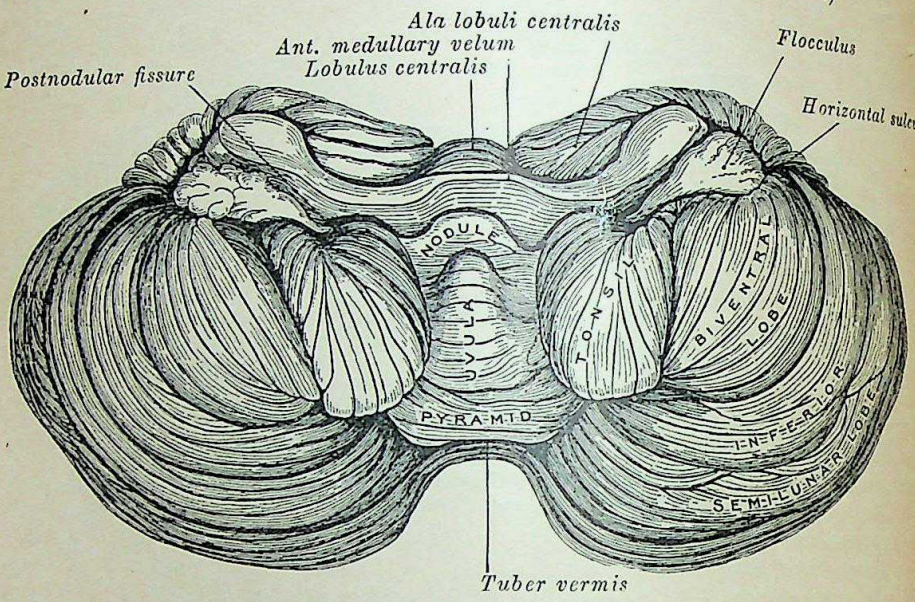

vermis; the corresponding parts in either hemisphere are: (1) the *flocculus*, (2) the *tonsilla cerebelli*, (3) the *biventral lobule*, and (4) the *inferior semilunar lobule*. The three main fissures are: (1) the *postnodular fissure*, which runs transversely across the vermis, between the nodule and the uvula; in the hemispheres this fissure passes in front of the tonsilla and the biventral lobe but behind the flocculus, and joins the anterior end of the horizontal sulcus. (2) The *prepyramidal fissure* crosses the vermis between the uvula and the pyramid, then curves forwards between the tonsilla and the biventral lobe, to join the postnodular fissure. (3) The *postpyramidal fissure* passes across the vermis between the pyramid and the tuber vermis, and, in the hemisphere, courses behind the tonsilla and biventral lobule, and then along the lateral border of the biventral lobule to the postnodular sulcus; in the hemisphere it forms the anterior boundary of the inferior semilunar lobule.

The nodule, posterior medullary velum and flocculus.—The nodule, or anterior end of the inferior vermis, abuts against the roof of the fourth ventricle, and can only be distinctly seen after the cerebellum has been separated from the medulla oblongata and pons. On either side of the nodule is a thin layer of white substance, named the *posterior medullary velum* (p. 817). The flocculus is a prominent, irregular lobule, situated in front of the biventral lobule, between it and the brachium pontis cerebelli. It is subdivided into a few small laminæ, and is connected to the posterior medullary velum by its central white core. The flocculi, nodule, and posterior medullary velum constitute the *lobus noduli*.

CC-0. In Public Domain. Gurukul Kangri Collection, Haridwar

Digitized by Arya Samaj Foundation Chennai and eGangotri

The **uvula and tonsillæ.**—The uvula forms a considerable portion of the inferior vermis; it is separated on either side from the tonsilla by the *sulcus valleculæ*, at the bottom of which it is connected to the tonsilla by a furrowed ridge of grey matter called the *furrowed band*. The tonsillæ are rounded masses, situated in the hemispheres. Each lies in a deep fossa, termed the *bird's nest* (nidus avis), between the uvula and the biventral lobule. The uvula and tonsillæ form the *lobus uvulæ*.

The **pyramid and biventral lobules** constitute the *lobus pyramidalis*. The pyramid, a conical projection, is the largest prominence of the inferior vermis. It is separated from the hemispheres by the sulcus valleculæ, across which it is connected to the biventral lobule by an indistinct grey band, analogous to the furrowed band already described. The biventral lobule is somewhat ovoid in shape; its narrower end points backwards, and is joined by the grey band to the pyramid; its broader end, directed forwards, is on a line with the anterior border of the tonsilla, and is separated from the flocculus by the postnodular fissure. The lateral border is separated from the inferior semilunar lobule by the postpyramidal fissure.

The **tuber vermis and the inferior semilunar lobules** form the *lobus tuberis*. The tuber vermis, the most posterior division of the inferior vermis, is of small size, and spreads out laterally into the large inferior semilunar lobules, which comprise at least two-thirds of the inferior surface of the hemisphere.

The **anterior medullary velum** (valve of Vieussens) is a thin, transparent lamina of white substance, which stretches between the brachia conjunctiva, and with them forms the roof of the upper part of the fourth ventricle. The velum is narrow above, where it passes beneath the inferior colliculi, and broader below, where it is continuous with the white substance of the superior vermis. The folia of the lingula are prolonged on to the dorsal surface of its lower half, and a median ridge, the *frenulum veli*, descends upon its upper part from between the inferior colliculi. The trochlear nerves emerge from the sides of the frenulum.

The **posterior medullary velum** is a thin layer of white substance, situated above and on either side of the nodule; it forms a part of the roof of the fourth ventricle, and its deep surface is covered by the ventricular epithelium. Somewhat semilunar in shape, its upper convex edge is continuous with the white substance of the cerebellum, while its lower concave margin is free; from it the ventricular epithelium is prolonged downwards to the tæniæ of the ventricle.

The two medullary vela are in contact with each other along their line of emergence from the white substance of the cerebellum; and this line of contact forms the summit of the roof of the fourth ventricle, which, in a sagittal section through the cavity, appears as a pointed angle.

The Internal Structure of the Cerebellum

The cerebellum consists of white and grey substance.

White substance.—If a sagittal section (fig. 816) be made through either hemisphere, the interior will be found to consist of a central stem of white substance, in the middle of which is a grey mass, the *dentate nucleus*. From this central white stem a series of plates diverge; these plates are covered with grey substance and form the laminæ. The main branches from the central stem divide and subdivide, and a characteristic appearance, named the *arbor vitæ*, is presented. If the sagittal section be made through the middle of the vermis, it will be seen that the central stem divides into a vertical and a horizontal branch. The *vertical* branch passes upwards to the culmen monticuli, where it subdivides freely, one of its ramifications passing forwards and upwards to the central lobule. The *horizontal* branch passes backwards to the folium vermis, greatly diminished in size in consequence of having given off large secondary branches: one of the latter ascends to the clivus monticuli; the others descend, and enter the tuber vermis, the pyramid, the uvula, and the nodule.

The white substance of the cerebellum consists of *projection fibres* and *fibræ propriæ*.

CC-0. In Public Domain. Gurukul Kangri Collection, Haridwar

Digitized by Arya Samaj Foundation Chennai and eGangotri

Projection fibres.—The cerebellum is connected to the other parts of the brain by three large bundles of projection fibres, viz. to the cerebrum by the brachia conjunctiva, to the pons by the brachia pontis, and to the medulla oblongata by the restiform bodies (fig. 817).

The **brachia conjunctiva** (superior cerebellar peduncles) are two in number, one on either side; they emerge from the upper and medial part of the white substance of the hemispheres and are placed under cover of the upper part of the cerebellum. They are joined to each other across the middle line by the anterior medullary velum, and can be followed upwards as far as the inferior colliculi, under which they disappear. Below, they form the upper lateral boundaries of the fourth ventricle, but as they ascend they converge on the dorsal aspect of the ventricle and form a part of its roof.

Most of the fibres of the brachium conjunctivum are derived from the cells of the dentate nucleus of the cerebellum (p. 821), and emerge from the hilum of

FIG. 816.—A sagittal section through the left cerebellar hemisphere, near its junction with the vermis. (Sharpey Schafer.)

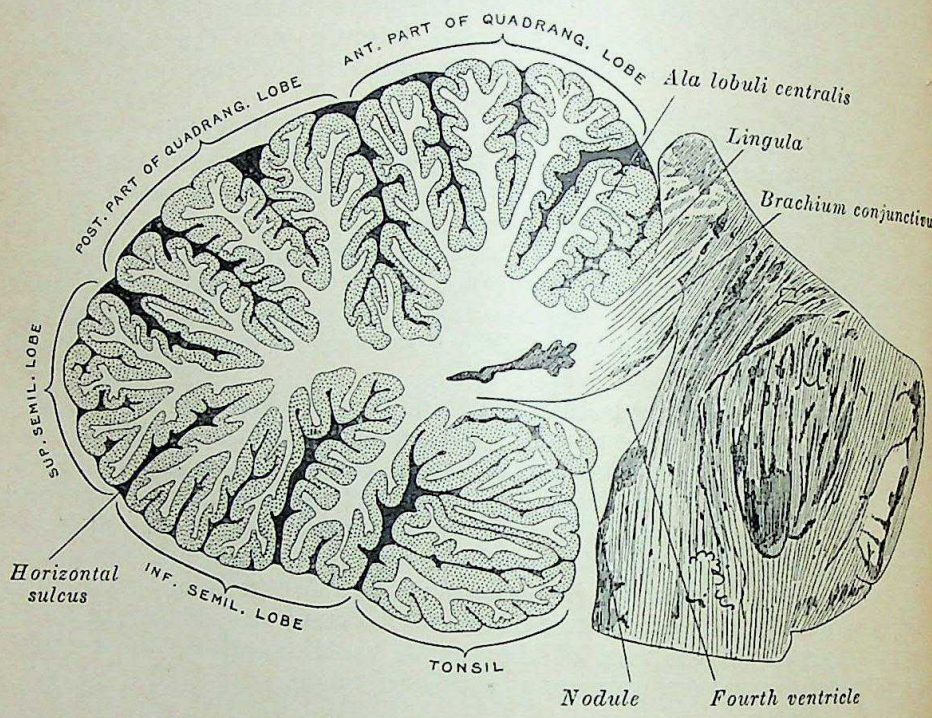

this nucleus, but a few arise from the cells of the smaller grey nuclei in this cerebellar white substance. The fibres of the two brachia are continued upwards beneath the corpora quadrigemina, and on the ventral surface of the cerebral aqueduct they undergo a complete decussation, and then divide into ascending and descending branches; most of the ascending branches end in the red nucleus, but some go to the thalamus and the nucleus of the oculomotor nerve; the descending branches can be traced into the pons and medulla oblongata; Cajal believes them to be continued into the anterior and lateral funiculi of the medulla spinalis. The fibres of the anterior spinocerebellar fasciculus pass through the brachia conjunctiva to reach the cerebellum. Tectocerebellar fibres pass from the roof of the midbrain to the cerebellum through the brachia conjunctiva.

The **brachia pontis** (middle cerebellar peduncles) (fig. 817) are largely composed of centripetal fibres, which arise from the cells of the nuclei pontis of the opposite side and end in the cerebellar cortex; they are said to contain also some efferent fibres to the nuclei pontis, and others to the medulla spinalis. The fibres of each brachium pontis are arranged in three fasciculi, superior, inferior, and deep. The *superior* fasciculus is derived from the upper transverse fibres of the pons; it is directed backwards and lateralwards superficial to the other two fasciculi, and is distributed mainly to the lobules on the inferior

CC-0. In Public Domain. Gurukul Kangri Collection, Haridwar

Digitized by Arya Samaj Foundation Chennai and eGangotri

surface of the cerebellar hemisphere, and to the parts of the superior surface adjoining the posterior and lateral margins. The *inferior* fasciculus is formed by the lowest transverse fibres of the pons; it passes under cover of the superior fasciculus and is continued downwards and backwards more or less parallel with it, to be distributed to the folia on the under surface close to the vermis. The *deep* fasciculus comprises most of the deep transverse fibres of the pons. It is at first covered by the superior and inferior fasciculi, but crossing obliquely it appears on the medial side of the superior, from which it receives a bundle; its fibres spread out and pass to the upper anterior cerebellar folia. The fibres of this fasciculus cover those of the restiform body.*

The **restiform bodies** (inferior cerebellar peduncles) pass at first upwards and lateralwards, forming parts of the lateral walls of the fourth ventricle, and then bend abruptly backwards to enter the cerebellum between the brachia conjunctiva and brachia pontis. Each restiform body contains the following

FIG. 817.—A dissection showing the projection fibres of the cerebellum. (E. B. Jamieson.)

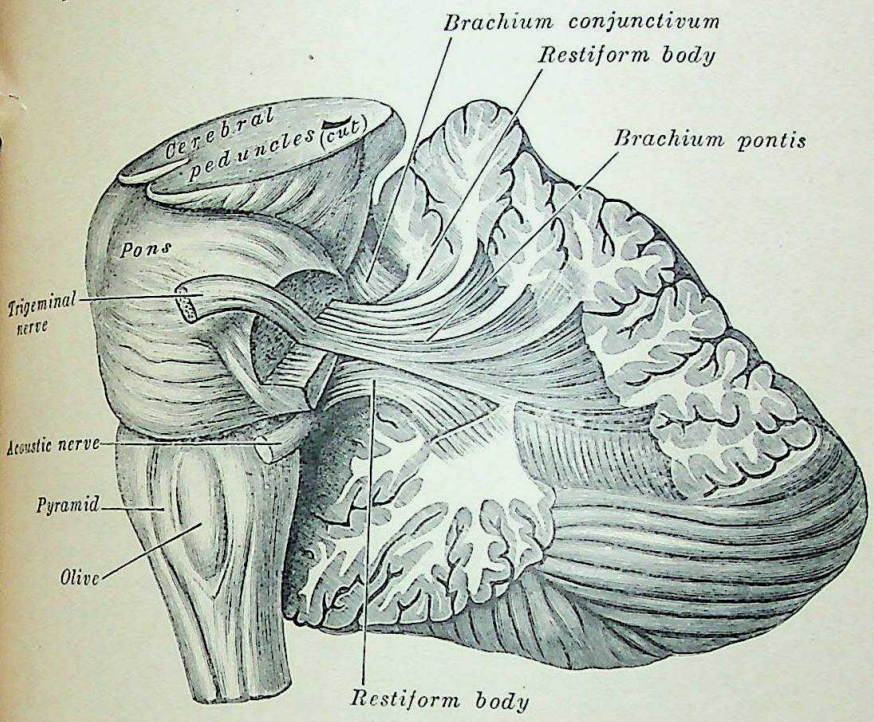

fasciculi: (1) the direct cerebellar tract (posterior spinocerebellar fasciculus) of the medulla spinalis, which ends mainly in the cortex of the superior vermis; (2) fibres from the nucleus gracilis and nucleus cuneatus, of the same and of the opposite side; (3) fibres from the opposite inferior olivary nucleus; (4) crossed and uncrossed fibres from the reticular formation of the medulla oblongata; (5) vestibular fibres, derived partly from the vestibular division of the acoustic nerve and partly from the nuclei in which this division ends—these fibres occupy the medial segment of the restiform body and divide into ascending and descending branches; the ascending branches partly end in the opposite roof nucleus and partly in the cortex of the cerebellum; (6) cerebellobulbar fibres which come from the opposite roof nucleus and probably from the dentate nucleus, and end in the nucleus of Deiters and in the formatio reticularis of the medulla oblongata.

The **fibræ propriæ** of the cerebellum are of two kinds: (1) *commissural fibres*, which cross the middle line at the anterior and posterior parts of the vermis and connect the opposite halves of the cerebellum; (2) *arcuate or association fibres*, which connect adjacent lobules and laminæ with each other.

Grey substance.—The grey substance of the cerebellum is found in two situations: (1) on the surface, forming the cortex; (2) as independent masses in the interior.

* Consult an article by E. B. Jamieson, *Journal of Anatomy and Physiology*, vol. xliv.

CC-0. In Public Domain. Gurukul Kangri Collection, Haridwar

Digitized by Arya Samaj Foundation Chennai and eGangotri

(1) The **grey substance of the cortex** presents a characteristic foliated appearance, due to the series of laminæ which project from the central white substance; these in their turn give off secondary laminæ, which are covered by grey substance. Externally the cortex is covered by pia mater; internally it rests on the white substance.

Microscopic appearance of the cortex (fig. 818).—The cortex consists of two layers, viz. an external grey, or molecular, layer, and an internal rust-coloured, or nuclear, layer; between these is an incomplete stratum of cells, the cells *of Purkinje.*

FIG. 818.—A transverse section through a cerebellar folium. Diagrammatic. (After Ramón y Cajal and Kölliker.)

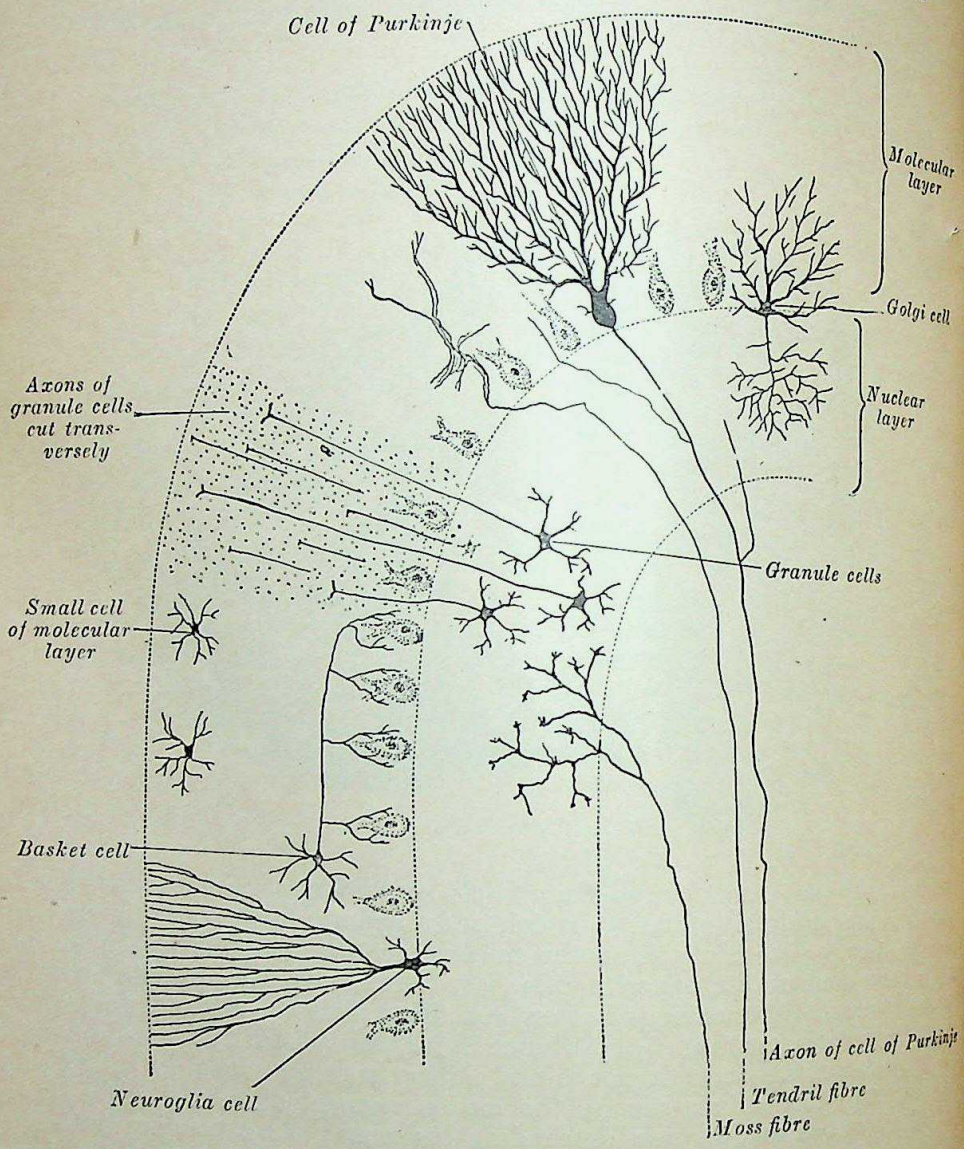

The *external grey, or molecular, layer* consists of nerve-fibres and cells. The fibres comprise: (*a*) the dendrites and axon-collaterals of Purkinje's cells; (*b*) fibres from cells in the nuclear layer; (*c*) fibres from the central white substance of the cerebellum; (*d*) fibres derived from cells in the molecular layer itself. In addition to these are other fibres, which have a vertical direction and are the processes of large neuroglia-cells situated in the nuclear layer. They pass outwards to the periphery of the grey substance, where they expand into little conical enlargements which form a sort of limiting membrane beneath the pia mater, analogous to the membrana limitans interna of the retina.

The *cells of the molecular layer* are small, and are arranged in an inner and an outer layer; they all possess branched axons. The cells of the inner layer

CC-0. In Public Domain. Gurukul Kangri Collection, Haridwar

Digitized by Arya Samaj Foundation Chennai and eGangotri

are termed *basket-cells*; their axons run for some distance parallel with the surface of the folium and give off collaterals which form basket-like networks around the bodies of Purkinje's cells.

The *cells of Purkinje* are peculiar to the cerebellum; they form a single stratum of large, flask-shaped cells at the junction of the molecular and nuclear layers, their bases resting against the latter. The cells are flattened in a direction transverse to the long axis of a folium, and thus appear broad in sections carried across a folium, and fusiform in sections parallel to the long axis of a folium. From the neck of the flask one or more dendrites arise and pass into the molecular layer, where they subdivide and form an extremely rich arborescence, the various subdivisions of the dendrites being covered by lateral spine-like processes. This arborescence, like the cell, is flattened at right angles to the long axis of a folium; in other words, it resembles the branches of a fruit-tree trained against a trellis or a wall. Hence, in sections carried across a folium the arborescence is broad and expanded; whereas in sections parallel to the long axis of a folium, the arborescence, like the cell, is seen in profile, and is limited to a narrow area.

From the bottom of the flask-shaped cell the axon arises; this passes through the nuclear layer, and, becoming medullated, is continued as a nerve-fibre in the subjacent white substance. As it traverses the nuclear layer it gives off fine collaterals, some of which run into the molecular layer.

The *internal rust-coloured, or nuclear, layer* (fig. 818) contains numerous small nerve-cells of a reddish-brown colour, together with many nerve-fibrils. Most of the cells are nearly spherical and provided with short dendrites which spread out in a spider-like manner in the nuclear layer. Their axons pass into the molecular layer, and, bifurcating at right angles, run for some distance parallel to the long axis of the folium. In the outer part of the nuclear layer are some larger cells, of the type II. of Golgi. Their axons undergo frequent division as soon as they leave the nerve-cells, and pass into the nuclear layer; while their dendrites ramify chiefly in the molecular layer.

Finally, in the grey substance of the cerebellar cortex, there are fibres which come from the white centre and penetrate the cortex. The cell-origin of these fibres is unknown, but they are presumably afferent fibres, contained in the brachia and restiform bodies. Some of them end in the nuclear layer by dividing into numerous branches, on which are to be seen peculiar moss-like appendages; hence they have been termed by Ramón y Cajal the *moss-fibres*; they form an arborescence around the cells of the nuclear layer. Other fibres, the *clinging or tendril fibres*, can be traced into the molecular layer, where their branches cling around the dendrites of Purkinje's cells.

FIG. 819.—A sagittal section through the right cerebellar hemisphere. The right olive has also been cut sagittally.

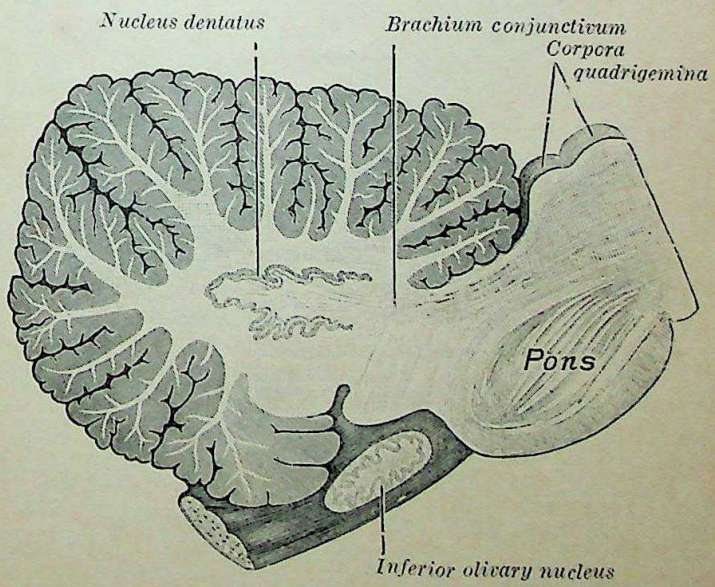

(2) The **independent centres of grey substance** are imbedded in the white substance of the cerebellum, and are four in number on either side: one is of large size, and is known as the nucleus dentatus; the other three, much smaller, are situated near the middle of the cerebellum, and are known as the nucleus emboliformis, nucleus globosus, and nucleus fastigii.

The *nucleus dentatus* (fig. 819) is situated a little to the medial side of the centre of the stem of the white substance of the hemisphere. It consists of an irregularly folded grey lamina, containing a white centre, and presenting on its anteromedial aspect

CC-0. In Public Domain. Gurukul Kangri Collection, Haridwar

Digitized by Arya Samaj Foundation Chennai and eGangotri

an opening, the hilum, from which most of the fibres of the brachium conjunctivum emerge (p. 818).

The *nucleus emboliformis* lies close to the medial side of the nucleus dentatus and partly covering its hilum. The *nucleus globosus*, an elongated mass, lies on the medial side of the nucleus emboliformis, and is directed anteroposteriorly. The *nucleus fastigii* (nucleus tecti), somewhat larger than the other two, is situated close to the middle line in the anterior part of the superior vermis, and immediately over the roof of the fourth ventricle, from which it is separated by a thin layer of white substance.

Applied Anatomy.—The general functions of the cerebellum in the human economy appear to be the co-ordination of movements, and equilibration. The exact functions of its different parts are still quite uncertain, owing to the contradictory nature of the evidence furnished by (1) ablation experiments upon animals, and (2) clinical observations in man of the effects produced by abscesses or tumours affecting different portions of the organ. According to W. Aldren Turner, 'The following localising symptoms would therefore indicate the presence of a tumour implicating the right cerebellar hemisphere and middle peduncle: deafness in the right ear, unassociated with middle ear complications and unsteady and uncertain gait with a tendency to fall more particularly to the right side; coarse nystagmoid oscillations on looking to the right; movements resembling those of disseminated sclerosis on volitional effort of the right arm; an awkward uncertain action of the right leg; a slight increase of the right knee-jerk; and, perhaps, slight blunting of sensibility over the right cornea and side of the face.'

The Fourth Ventricle

The **fourth ventricle**, or cavity of the rhombencephalon, is a somewhat lozenge-shaped space situated in front of the cerebellum, and behind the pons and upper half of the medulla oblongata. Developmentally considered, it

Fig. 820.—A scheme showing the roof of the fourth ventricle. The arrow is in the foramen of Majendie.

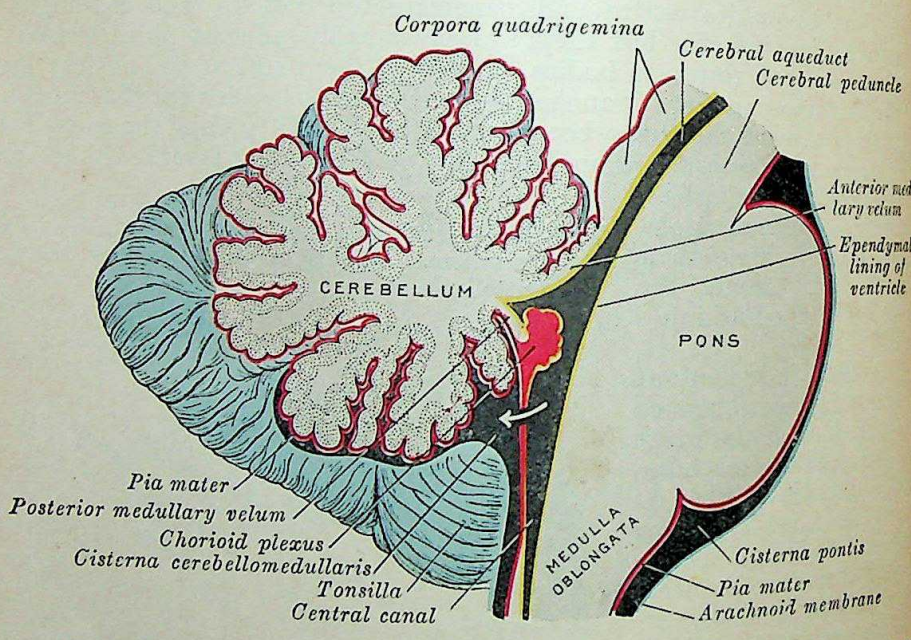

consists of three parts: a *superior* belonging to the isthmus rhombencephali, an *intermediate*, to the metencephalon, and an *inferior*, to the myelencephalon. It is lined by ciliated epithelium, and its inferior angle is continuous with the central canal of the medulla oblongata; its superior angle is continuous with the cerebral aqueduct which opens above into the cavity of the third ventricle. From its middle part a narrow, curved pouch, named the *lateral recess*, is prolonged on either side between the restiform body and the flocculus, and reaches as far as the attachments of the glossopharyngeal and vagus nerves.

The fourth ventricle possesses lateral boundaries, a roof or dorsal wall, and a floor or ventral wall (rhomboid fossa).

CC-0. Prof. Satya Vrat Shastri Collection, Gurukul Kangri Collection, Haridwar

Digitized by Arya Samaj Foundation Chennai and eGangotri

Lateral boundaries.—The lower part of each lateral boundary is constituted by the clava, the fasciculus cuneatus, and the restiform body; the upper part by the brachium pontis and the brachium conjunctivum.

The roof or dorsal wall (fig. 820).—The upper portion of the roof is formed by the brachia conjunctiva and the anterior medullary velum; the lower portion, by the posterior medullary velum, the epithelial lining of the ventricle covered by the tela chorioidea inferior, the tæniæ of the ventricle, and the obex.

The *brachia conjunctiva* (p. 818), on emerging from the central white substance of the cerebellum, pass upwards and forwards, forming at first the lateral boundaries of the upper part of the ventricle; on approaching the inferior colliculi, they converge, and their medial portions overlap the ventricle and form part of its roof.

The *anterior medullary velum* (p. 817) fills the angular interval between the brachia conjunctiva, and is continuous behind with the central white substance of the cerebellum; it is covered on its dorsal surface by the lingula of the superior vermis.

The *posterior medullary velum* (p. 817) is continued downwards and forwards from the central white substance of the cerebellum in front of the nodule and tænsillæ, and ends inferiorly in a thin, concave, somewhat ragged margin. Below this margin the roof of the ventricle is devoid of nervous matter except in the immediate vicinity of the lower lateral boundaries of the ventricle, where two narrow white bands, the *tæniæ of the fourth ventricle*, appear; these bands meet over the inferior angle of the ventricle in a thin triangular lamina, the *obex*. The non-nervous part of the roof is formed by the *epithelial lining of the ventricle*, which is prolonged downwards as a thin membrane, from the deep surface of the posterior medullary velum to the corresponding surface of the obex and tæniæ, and thence on to the floor of the ventricular cavity; it is covered and strengthened by a portion of the pia mater which is named the *tela chorioidea of the fourth ventricle*.

The *tæniæ of the fourth ventricle* (ligulæ) (fig. 821) are two narrow bands of white matter, one on either side, which complete the lower part of the roof of the ventricle. Each consists of a vertical and a horizontal part. The vertical part is continuous with the clava, to which it is adherent by its lateral border. The horizontal portion extends transversely across the restiform body, below the striæ medullares, and forms the roof of the lower and posterior part of the lateral recess; it is attached by its lower margin to the restiform body, and partly encloses the chorioid plexus, which, however, projects beyond it like a cluster of grapes. The *obex* is a thin, triangular, grey lamina, which covers the lower angle of the ventricle and is attached by its lateral margins to the clavæ. The *tela chorioidea of the fourth ventricle* is the name applied to the triangular fold of pia mater which is carried upwards between the cerebellum and the medulla oblongata. It consists of two layers, which are continuous with each other in front, and are more or less adherent throughout. The posterior layer covers the antero-inferior surface of the cerebellum, while the anterior is applied to the structures which form the lower part of the roof of the ventricle, and is continuous inferiorly with the pia mater on the restiform bodies and the closed part of the medulla.

The openings in the roof.—In the roof of the fourth ventricle there are three openings, a median and two lateral: the median aperture (*foramen Majendii*) is situated immediately above the inferior angle of the ventricle; the lateral apertures are found at the ends of the lateral recesses. Through these openings the ventricular cavity communicates with the subarachnoid cavity, and the cerebrospinal fluid can circulate from the one cavity to the other.

The chorioid plexuses.—Two highly vascular fringe-like processes of the tela chorioidea are named the chorioid plexuses of the fourth ventricle; they invaginate the lower part of the roof of the ventricle and are everywhere covered by the epithelial lining of the cavity. Each consists of a vertical and a horizontal portion: the former lies close to the middle line, and the latter passes into the lateral recess and projects through the lateral aperture. The vertical parts of the plexuses are distinct from each other, but the horizontal portions are joined in the middle line; and hence the entire structure presents the form of the letter T, the vertical limb of which, however, is double.

CC-0. In Public Domain. Gurukul Kangri Collection, Haridwar

Digitized by Arya Samaj Foundation Chennai and eGangotri

The **rhomboid fossa** (fig. 821).—The anterior wall or floor of the fourth ventricle is named, from its shape, the rhomboid fossa; it is formed by the posterior surfaces of the pons and medulla oblongata. It is covered by a layer of grey substance continuous with that of the medulla spinalis; superficial to this is a thin lamina of neuroglia which constitutes the ependyma of the ventricle and supports a layer of ciliated epithelium. The fossa consists of three parts, superior, intermediate, and inferior. The *superior* part is triangular in shape and limited laterally by the brachia conjunctiva cerebelli; its apex, directed upwards, is continuous with the cerebral aqueduct; its base is represented by an imaginary line at the level of the upper ends of two small depressions, named the superior foveæ. The *intermediate* part extends from this level to that of the horizontal portions of the tæniæ of the ventricle and

Fig. 821.—The rhomboid fossa.

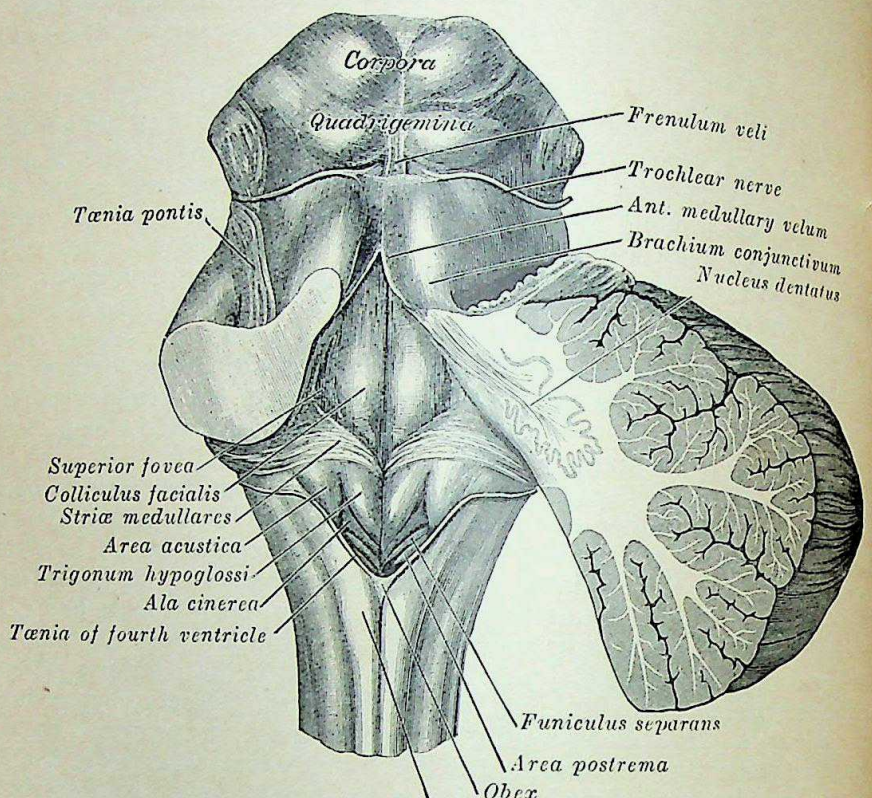

is prolonged into the lateral recesses. The *inferior* part is triangular, and its downwardly directed apex, named the *calamus scriptorius*, is continuous with the wall of the central canal of the closed part of the medulla oblongata.

The rhomboid fossa is divided into symmetrical halves by a *median sulcus* which reaches from the upper to the lower angle of the fossa and is deeper below than above. On either side of this sulcus is an elevation, the *medial eminence*, bounded laterally by a sulcus, the *sulcus limitans*. In the superior part of the fossa the medial eminence has a width equal to that of the corresponding half of the fossa, but opposite the superior fovea it forms an elongated swelling, the *colliculus facialis*, which overlies the nucleus of the abducent nerve, and is in part produced by the ascending portion of the root of the facial nerve. In the inferior part of the fossa the medial eminence assumes the form of a triangular area, the *trigonum hypoglossi*. When examined under water with a lens the trigonum hypoglossi is seen to consist of a medial and a lateral area separated by a series of oblique furrows; the medial area corresponds with the upper part of the nucleus of the hypoglossal nerve, the lateral with a small nucleus, the *nucleus intercalatus*.

The *sulcus limitans* forms the lateral boundary of the medial eminence. Its superior part corresponds with the lateral limit of the fossa and presents a bluish-grey area, the *locus ceruleus*, which owes its colour to a patch of deeply

CC-0. In Public Domain. Gurukul Kangri Collection, Haridwar

Digitized by Arya Samaj Foundation Chennai and eGangotri

pigmented nerve-cells, termed the *substantia ferruginea*. At the level of the colliculus facialis the sulcus limitans widens into a flattened depression, the *superior fovea*, and in the inferior part of the fossa appears as a distinct triple, the *inferior fovea*. Lateral to the foveæ is a rounded elevation named the *area acustica*, which extends into the lateral recess. Winding round the restiform body and crossing the area acustica and the medial eminence are a number of white strands, the *striæ medullares* (striæ acusticæ), which form a portion of the cochlear division of the acoustic nerve and disappear into the median sulcus. Below the inferior fovea, and between the trigonum hypoglossi and the lower part of the area acustica, is a triangular dark field, the *ala cinerea*, in which the sensory fibres of the vagus and glossopharyngeal nerves end. The lower part of the ala cinerea is crossed by a narrow translucent ridge, the *funiculus separans*, and between this funiculus and the clava is a small tongue-shaped area, the *area postrema*. On section it is seen that the funiculus separans is formed by a strip of thickened ependyma, and the area postrema by loose, highly vascular, neuroglial tissue containing nerve-cells of moderate size.

THE MESENCEPHALON OR MID-BRAIN

The **mesencephalon** or **mid-brain** is the short, constricted portion which connects the pons and cerebellum with the thalamencephalon and cerebral hemispheres. It is directed upwards and forwards, and consists of (1) a ventrolateral portion, composed of a pair of cylindrical bodies, named the *cerebral peduncles*; (2) a dorsal portion, consisting of four rounded eminences, named the *corpora quadrigemina*; and (3) an intervening passage or tunnel, the *cerebral aqueduct*, which represents the original cavity of the mid-brain, and connects the third and fourth ventricles (fig. 822).

FIG. 822.—A transverse section through the mid-brain. Schematic. (Testut.)

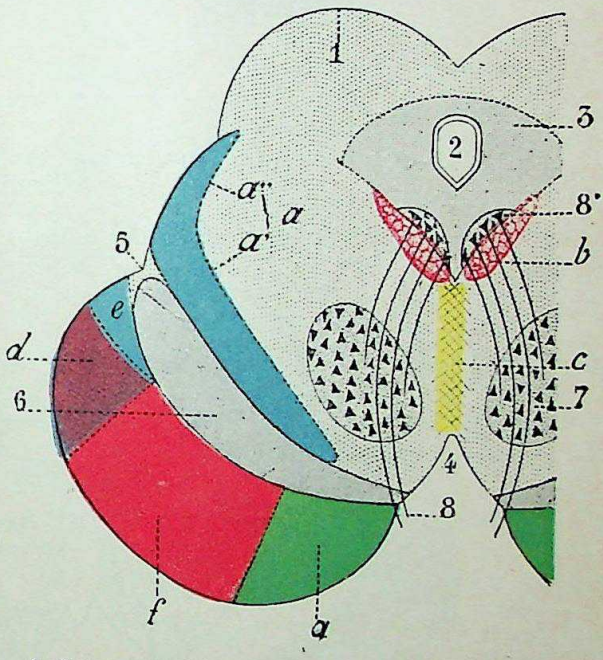

1. Corpora quadrigemina. 2. Cerebral aqueduct. 3. Central grey stratum. 4. Interpeduncular space. 5. Sulcus lateralis. 6. Substantia nigra. 7. Red nucleus of tegmentum. 8. Oculomotor nerve, with 8′, its nucleus of origin. *a*. Lemniscus (in blue), with *a′* the medial lemniscus and *a″* the lateral lemniscus. *b*. Medial longitudinal fasciculus. *c*. Raphe. *d*. Temporopontine fibres. *e*. Portion of medial lemniscus which runs to the lentiform nucleus and insula. *f*. Cerebrospinal fibres. *g*. Frontopontine fibres.

The **cerebral peduncles** (crura cerebri) (fig. 798) are two cylindrical masses situated at the base of the brain, and largely hidden by the temporal lobes of the cerebrum, which must be drawn aside or removed in order to expose them. They emerge from the upper surface of the pons, one on either side of the middle line, and, diverging as they pass upwards and forwards, disappear into the substance of the cerebral hemispheres. Curving round each peduncle, close to the upper surface of the pons, a thin white band, the *tænia pontis*, is frequently seen; it enters the cerebellum between the brachium pontis and brachium conjunctivum. The depressed area between the diverging cerebral peduncles is termed the *interpeduncular fossa*, and consists of a layer of greyish substance, the *posterior perforated substance*, which is pierced by small apertures for the transmission of blood-vessels. The lower part of the posterior perforated substance lies on the ventral aspect of the tegmenta, and contains a nucleus named the *interpeduncular ganglion* (p. 827); its upper part assists in forming the floor of the third ventricle.

CC-0. In Public Domain. Gurukul Kangri Collection, Haridwar

Digitized by Arya Samaj Foundation Chennai and eGangotri

The ventral surface of each peduncle is crossed behind, from the medial to the lateral side, by the superior cerebellar and posterior cerebral arteries, while close to the point of disappearance of the peduncle into the cerebral hemisphere the optic tract winds forwards around it. The medial surface of the peduncle forms the lateral boundary of the interpeduncular fossa, and is marked by a

FIG. 823.—A transverse section through the mid-brain at the level of the inferior colliculi.

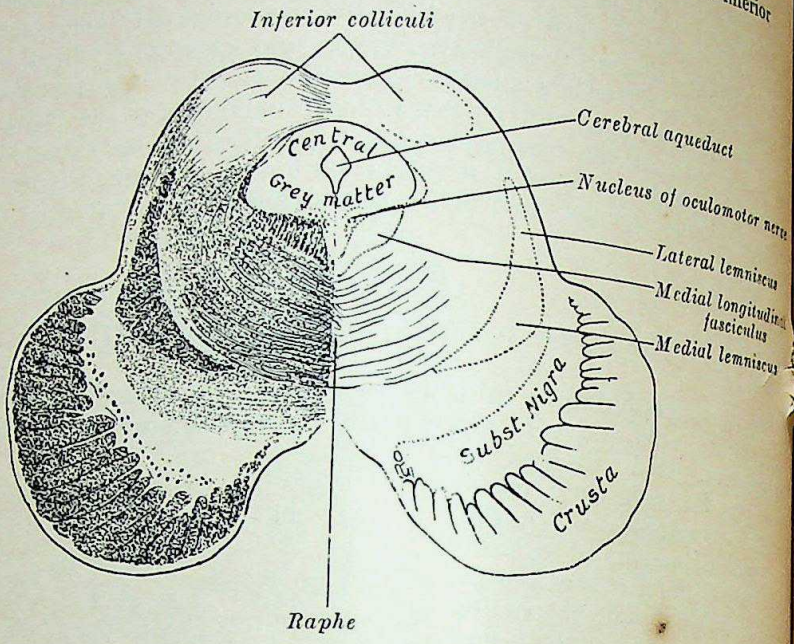

FIG. 824.—A transverse section through the mid-brain at the level of the superior colliculi.

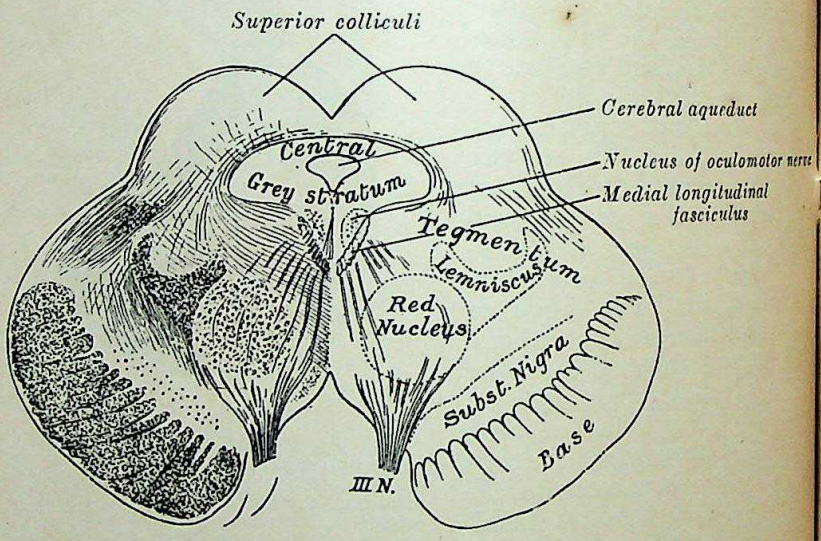

longitudinal furrow, the *oculomotor sulcus*, from which the roots of the oculomotor nerve emerge (fig. 824). The lateral surface of the peduncle is in relation with the gyrus hippocampi of the cerebral hemisphere and is crossed from behind forwards by the trochlear nerve (fig. 789). Running along this surface is a longitudinal furrow, termed the *lateral sulcus*; the fibres of the lateral lemniscus come to the surface in this sulcus, and pass backwards and upwards, to disappear under the inferior colliculus.

Structure of the cerebral peduncles (figs. 823, 824).—On transverse section, each peduncle is seen to consist of a dorsal and a ventral part, separated by a deeply pigmented lamina of grey substance, termed the *substantia nigra*

CC-0. In Public Domain. Gurukul Kangri Collection, Haridwar

Digitized by Arya Samaj Foundation Chennai and eGangotri

The dorsal part is named the *tegmentum*; the ventral, the *base* or *crusta*. The bases of the peduncles are separated from each other, but the tegmenta are joined in the median plane by a forward prolongation of the raphe of the pons. Laterally, the tegmenta are free; dorsally, they blend with the corpora quadrigemina.

The **base** (crusta or pes) is semilunar on transverse section, and consists almost entirely of longitudinal bundles of efferent fibres which arise from the cells of the cerebral cortex and are grouped into three principal sets, viz. cerebrospinal, frontopontine, and temporopontine (fig. 822). The *cerebrospinal* fibres are derived from the cells of the motor area of the cerebral cortex and occupy the middle three-fifths of the base; some of them end in the nuclei of the motor cerebral nerves of the opposite side, but most of them pass into the pyramids of the medulla oblongata. The *frontopontine* fibres are situated in the medial fifth of the base; they arise from the cells of the frontal lobe and end in the nuclei of the pons. The *temporopontine* fibres are lateral to the cerebrospinal fibres; they originate in the temporal lobe and end in the nuclei of the pons.*

The **substantia nigra** is a layer of grey substance containing numerous deeply pigmented, multipolar nerve-cells. It is semilunar on transverse section, its concavity being directed towards the tegmentum; from its convex surface, processes extend between the fibres of the base of the peduncle. Thicker medially than laterally, it reaches from the oculomotor sulcus to the lateral sulcus, and extends from the upper surface of the pons to the subthalamic region; its medial part is traversed by the fibres of the oculomotor nerve as these stream forwards to reach the oculomotor sulcus. The substantia nigra receives afferent fibres from the corpus striatum of the same, and of the opposite side, and sends efferent fibres to the reticular formation of the tegmentum.

The **tegmentum** is continuous below with the reticular formation of the pons, and, like the latter, consists of a considerable amount of grey substance together with longitudinal and transverse fibres. The principal grey masses of the tegmentum are the red nucleus and the interpeduncular ganglion; of its fibres the chief longitudinal tracts are the brachium conjunctivum, the medial longitudinal fasciculus, and the lemniscus.

Grey substance.—The *red nucleus* is situated in the anterior part of the tegmentum, and is continued upwards into the posterior part of the subthalamic region. In sections at the level of the superior colliculus it appears as a circular mass which is traversed by the fibres of the oculomotor nerve. Most of the ascending branches of the opposite brachium conjunctivum (p. 818) end in this nucleus; it also receives fibres from the corpus striatum and the frontal lobe. The axons of some of its cells cross the middle line and are continued downwards into the lateral funiculus of the medulla spinalis as the rubrospinal tract (p. 794); those of other cells end in the thalamus, the nucleus of the lateral lemniscus, and in the reticular formation of the medulla oblongata.

The *interpeduncular ganglion* is a median collection of nerve-cells situated in the ventral part of the tegmentum. The fibres of the fasciculus retroflexus of Meynert, which have their origin in the cells of the ganglion habenulæ (p. 836), end in the interpeduncular ganglion.

Besides the two nuclei mentioned, there are small collections of nerve-cells which form the dorsal and ventral nuclei and the central nucleus or nucleus of the raphe.

White substance.—(1) The origin and course of the *brachium conjunctivum* have already been described (p. 818).

(2) The *medial (posterior) longitudinal fasciculus* (fig. 825) is continuous below with the fasciculi proprii of the anterior and lateral funiculi of the medulla spinalis; and has been traced by Edinger as far as a nucleus, the *nucleus of the medial longitudinal fasciculus*, situated in the hypothalamus, immediately in front of the cerebral aqueduct. In the medulla oblongata and pons, it runs close to the middle line, near the floor of the fourth ventricle; in the mesen-

* A band of fibres, the *tractus peduncularis transversus*, is sometimes seen emerging from in front of the superior colliculus; it passes round the ventral surface of the peduncle about midway between the pons and the optic tract, and dips into the oculomotor sulcus. This band is a constant structure in many mammals, but is only present in about thirty per cent. of human brains. Since it undergoes atrophy after enucleation of the eyeballs, it may be considered as forming a path for visual sensations.

CC-0. In Public Domain. Gurukul Kangri Collection, Haridwar

Digitized by Arya Samaj Foundation Chennai and eGangotri

cephalon, it is situated on the ventral aspect of the cerebral aqueduct, below the nuclei of the oculomotor and trochlear nerves. Its connexions are imperfectly known, but it consists largely of ascending and descending intersegmental or association fibres, which connect the nuclei of the rhombencephalon and mesencephalon to each other. It forms an important link between the nuclei of the oculomotor, trochlear, and abducent nerves, and conveys fibres from the nucleus of the abducent nerve into the trochlear nerve of the opposite side and through this nerve to the Rectus medialis oculi. Many fibres enter it from the lateral nucleus (Deiters' nucleus) of the vestibular nerve, and divide into

FIG. 825.—A scheme of the medial longitudinal fasciculus; motor fibres in red, sensory fibres in blue.

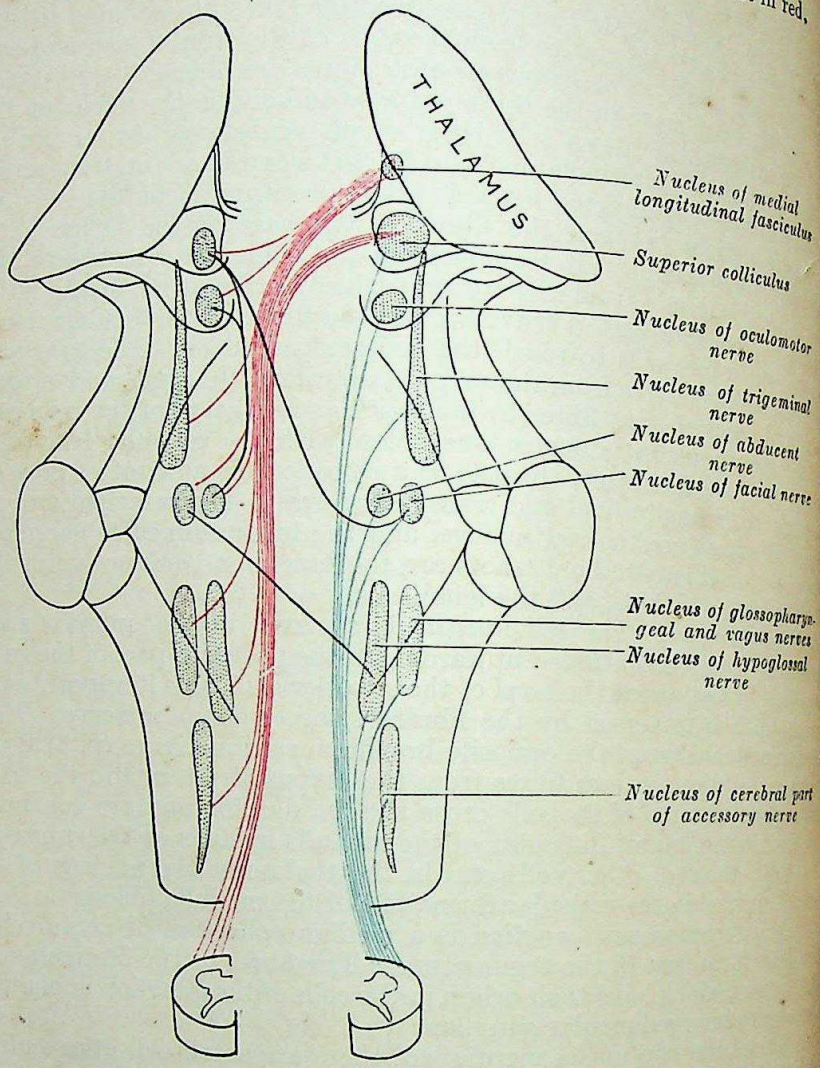

ascending and descending branches; the former ending in the nuclei of the oculomotor, trochlear, and abducent nerves, the latter passing into the anterior funiculus of the spinal medulla. Fibres arise in the superior colliculus and in the nucleus of the medial longitudinal fasciculus and, after decussating in the middle line, end in the motor nuclei of the pons and medulla oblongata. Other fibres ascend from the grey matter of the spinal medulla and from the nuclei in the medulla oblongata to the nuclei in the pons and mid-brain. Fibres are said to be prolonged through this fasciculus from the nucleus of the oculomotor nerve into the facial nerve, and through the latter nerve to the Orbicularis oculi, the Corrugator, and the Frontalis.*

The fibres of the *lemniscus* or *fillet* (fig. 827) take origin in the nucleus gracilis and nucleus cuneatus of the medulla oblongata, and cross to the opposite side

* Bruce and Pirie ('On the Origin of the Facial Nerve,' *Review of Neurology and Psychiatry*, vol. vi. No. 12, December 1908) produce weighty evidence against the view that the facial nerve derives fibres from the nucleus of the oculomotor nerve.

CC-0. In Public Domain. Gurukul Kangri Collection, Haridwar

Digitized by Arya Samaj Foundation Chennai and eGangotri

the sensory decussation (p. 805). They then pass upwards through the medulla oblongata, in which they are situated behind the cerebrospinal fibres. Here they are joined by the fibres of the spinothalamic fasciculi, these having partly undergone decussation in the medulla spinalis. As the lemniscus ascends, it receives additional fibres from the terminal nuclei of the sensory cerebral nerves of the opposite side. In the pons, it assumes a flattened, ribbon-like appearance, and is placed dorsal to the trapezium. In the mesencephalon, the lateral part is folded backwards and forms nearly a right angle with its medial portion; and hence it is customary to speak of a lateral and a medial lemniscus.

The *lateral lemniscus* comes to the surface in the lateral sulcus of the midbrain, and disappears under the inferior colliculus. It consists of fibres from the terminal nuclei of the cochlear division of the acoustic nerve, together with others from the superior olivary and trapezoid nuclei. Most of the fibres of the lateral lemniscus end in the inferior colliculus but some reach the medial geniculate body through the inferior quadrigeminal brachium.

The *medial lemniscus* begins in the nucleus gracilis and nucleus cuneatus of the opposite side, and is joined by the spinothalamic fasciculi of the medulla spinalis, and by fibres from the terminal nuclei of the sensory cerebral nerves of the opposite side, excepting the cochlear division of the acoustic nerve. In the cerebral peduncle, a few of its fibres pass upwards in the lateral part of the base of the peduncle on the dorsal aspect of the temporopontine fibres, and reach the lentiform nucleus and the insula. With this exception the fibres of the medial lemniscus are prolonged through the tegmentum into the thalamus, around the cells of which they form arborisations. From the cells of the thalamus a relay of fibres is prolonged to the cerebral cortex.

Fig. 826.—A transverse section through the sensory decussation (decussation of the lemniscus). Schematic. (Testut.)

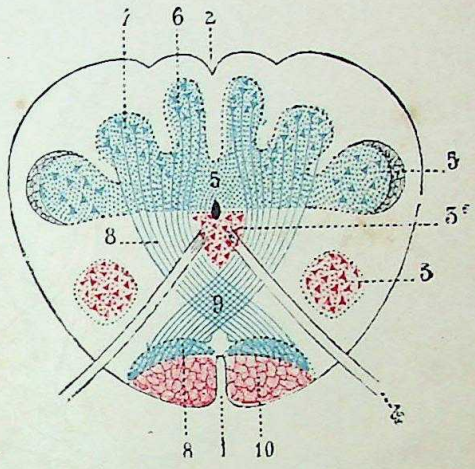

1. Anterior median fissure. 2. Posterior median sulcus. 3, 3'. Head and base of the anterior column (in red). 4. Hypoglossal nerve. 5. Bases of the posterior columns. 5'. Tuberculum cinereum (tubercle of Rolando). 6. Nucleus gracilis. 7. Nucleus cuneatus. 8, 8. Lemniscus. 9. Sensory decussation. 10. Pyramid.

The **corpora quadrigemina** (fig. 831) are four rounded eminences which form the dorsal part of the mesencephalon. They are situated above and in front of the anterior medullary velum and brachia conjunctiva, and below and behind the third ventricle and posterior commissure. They are covered by the splenium of the corpus callosum, and are partly overlapped on either side by the medial angle, or pulvinar, of the posterior end of the thalamus. The corpora quadrigemina are arranged in pairs (superior and inferior colliculi), and are separated from one another by a crucial sulcus. The longitudinal part of this sulcus expands superiorly to form a slight depression which supports the *pineal body*, a cone-like structure which projects backwards from the thalamencephalon and partly obscures the superior colliculi. From the inferior end of the longitudinal sulcus a white band, termed the *frenulum veli*, is prolonged downwards to the anterior medullary velum; on either side of this band the trochlear nerve emerges, and passes forwards on the lateral aspect of the cerebral peduncle to reach the base of the brain. The *superior colliculi* are larger and darker in colour than the inferior, and are oval in shape. The *inferior colliculi* are hemispherical, and somewhat more prominent than the superior. The superior colliculi are associated with the sense of sight, the inferior with that of hearing.

From the lateral aspect of each colliculus a white band, termed the *brachium*, is prolonged, upwards and forwards. The *superior brachium* extends laterally from the superior colliculus, and, passing between the pulvinar and medial geniculate body, is partly continued into an eminence called the lateral geniculate body, and partly into the optic tract. The *inferior brachium* passes

CC-0. In Public Domain. Gurukul Kangri Collection, Haridwar

Digitized by Arya Samaj Foundation Chennai and eGangotri

forwards and upwards from the inferior colliculus to which it conveys fi from the lateral lemniscus to the medial geniculate body.

In close relationship with the corpora quadrigemina are the brachia junctiva, which emerge from the upper and medial parts of the cerebe hemispheres. They run upwards and forwards, and, passing under the m colliculi, enter the tegmenta as already described (p. 818).

Structure of the corpora quadrigemina.—The *inferior colli* consists of a compact nucleus of grey substance which contains large and s

FIG. 827.—A scheme showing the course of the fibres of the lemniscus; medial lemniscus in blue, lateral in red.

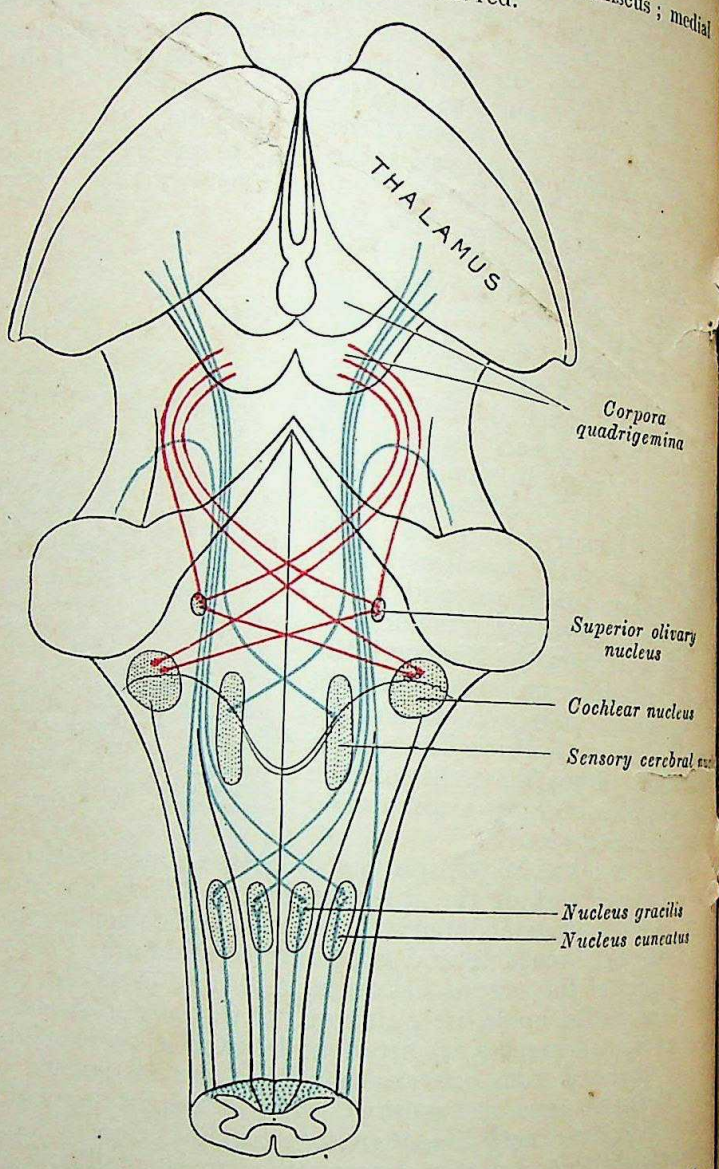

multipolar nerve-cells, and is more or less completely surrounded by fibres derived from the lateral lemniscus; most of these fibres end in the grey nucleus of the same side, but some cross to that of the opposite side. From the cells of the grey nucleus, fibres are prolonged through the inferior brachium into the tegmentum of the cerebral peduncle, and are carried to the thalamus and the cortex of the temporal lobe; other fibres cross the middle line and end in the opposite colliculus.

The *superior colliculus* is covered by a thin stratum (*stratum zonale*) of white fibres, the majority of which are derived from the optic tract. Beneath this is the *stratum cinereum*, a cap-like layer of grey substance, thicker in the centre than at the circumference, and consisting of numerous small multipolar nerve-cells imbedded in a fine network of nerve-fibres. Still deeper is the *stratum opticum*, containing large multipolar nerve-cells separated by

CC-0. In Public Domain. Gurukul Kangri Collection, Haridwar

Digitized by Arya Samaj Foundation Chennai and eGangotri

r forms a portion of the floor of the lateral ventricle, and is covered with ependyma and epithelium of that cavity; the medial part is covered with ela chorioidea of the third ventricle. In front, the superior surface is ated from the medial surface by a salient margin, the *tænia thalami*, from ith the epithelial lining of the third ventricle is reflected to the under rface of the tela chorioidea. Behind, it is limited medially by a groove, e *sulcus habenulæ* which intervenes between it and a small triangular area rmed the *trigonum habenulæ*.

FIG. 829.—A coronal section through the brain at the anterior part of the pons. Anterior aspect.

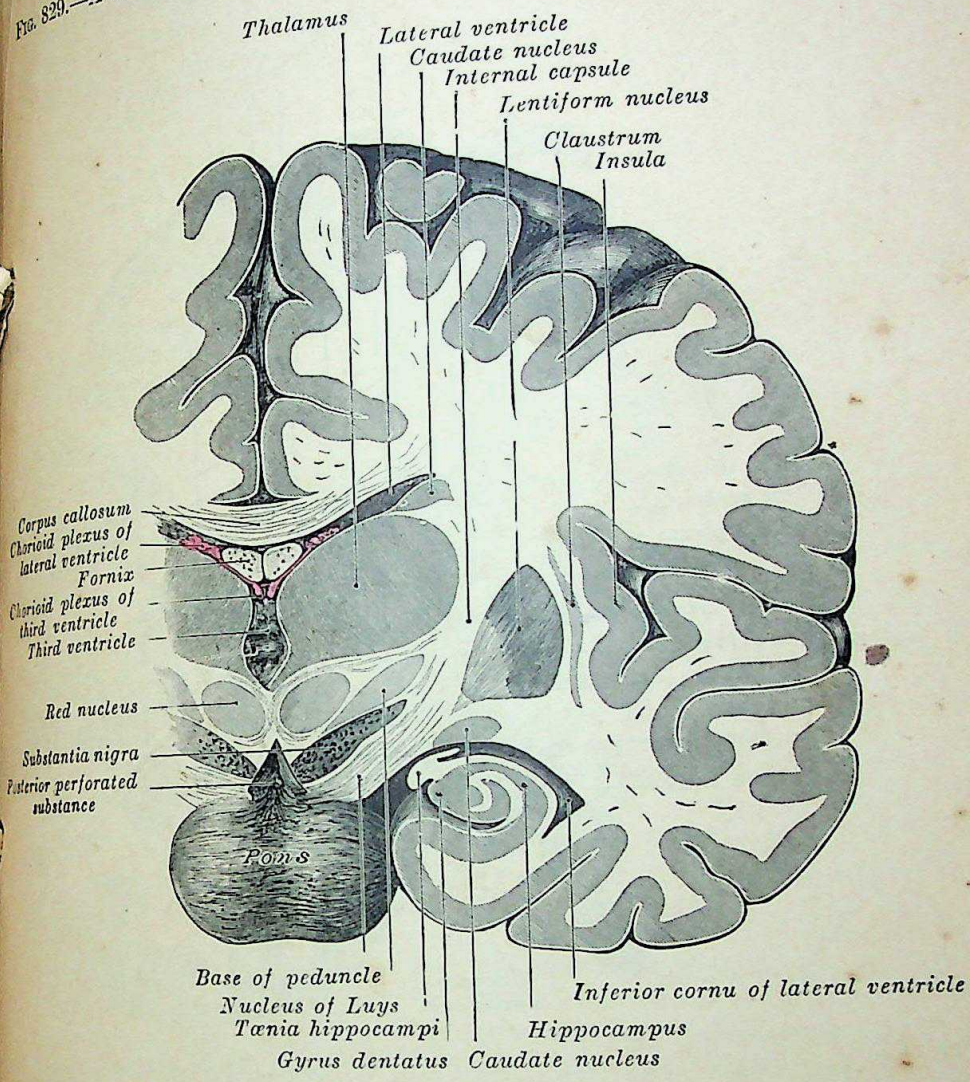

The *inferior surface* rests upon and is continuous with the upward prolongation of the tegmentum (*subthalamic tegmental region*), in front of which it is related to the *substantia innominata of Meynert* (p. 860).

The *medial surface* constitutes the upper part of the lateral wall of the third ventricle; it is covered by a thin layer of grey substance, and is connected to the corresponding surface of the opposite thalamus by a flattened grey band, the *massa intermedia* (middle or grey commissure). This band lies close behind the interventricular foramen, and averages about 1 cm. in its anteroposterior diameter: it sometimes consists of two parts, and occasionally is absent. It contains nerve-cells and nerve-fibres; a few of the latter may cross the middle line, but most of them pass towards the middle line and then curve lateralwards on the same side.

The *lateral surface* is in contact with a thick band of white substance which forms the occipital part of the internal capsule and separates the thalamus from the lentiform nucleus of the corpus striatum.

CC-0. In Public Domain. Gurukul Kangri Collection, Haridwar

Digitized by Arya Samaj Foundation Chennai and eGangotri

Structure.—The thalamus consists chiefly of grey substance, but its surface is covered by a layer of white substance, named the *stratum zonale*, and its lateral surface by a similar layer termed the *lateral medullary lamina*. Its grey substance is incompletely subdivided into three parts—anterior, medial, and lateral—by a white layer, the *medial medullary lamina*. The anterior part comprises the anterior tubercle, the medial part lies next the lateral wall of the third ventricle, while the lateral and largest part is interposed between the medial and lateral medullary laminæ and includes the pulvinar.

FIG. 830.—A coronal section through the brain, passing through the intermediate mass of the third ventricle. Anterior aspect.

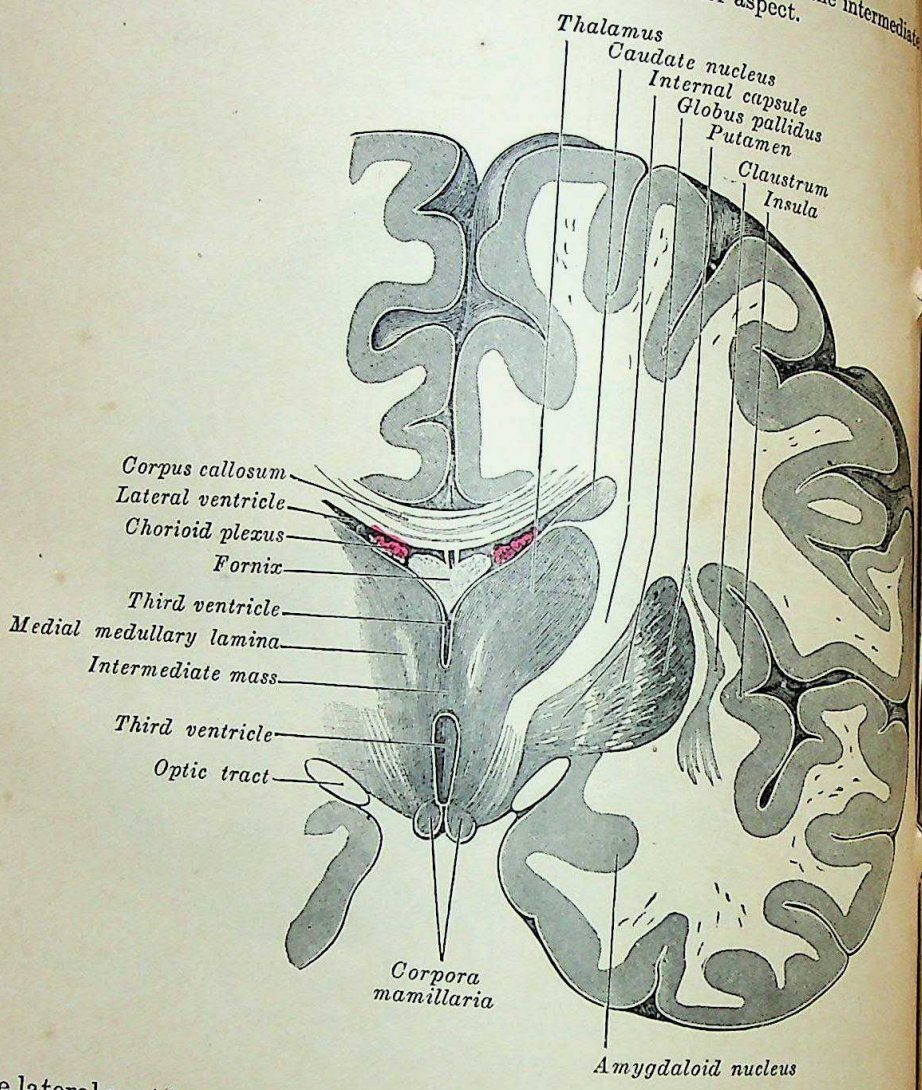

The lateral part is traversed by numerous fibres which radiate from the thalamus into the internal capsule, and pass through the latter to the cerebral cortex. These three parts are built up of numerous nuclei, the connexions of many of which are imperfectly known.

Connexions.—The thalamus may be regarded as a large, ganglionic mass in which the ascending tracts of the tegmentum and a considerable proportion of the fibres of the optic tract end, and from the cells of which numerous fibres (thalamocortical) take origin, and radiate to almost every part of the cerebral cortex. The lemniscus, together with the other longitudinal strands of the tegmentum, enters its ventral part: the thalamomamillary fasciculus (bundle of Vicq d'Azyr), from the corpus mamillare, enters its anterior tubercle, while many of the fibres of the optic tract terminate in its posterior end. The thalamus also receives fibres (corticothalamic) from the cells of the cerebral cortex and others from the red nucleus and the brachium conjunctivum. The fibres arising from the cells of the thalamus form four principal groups or

CC-0. In Public Domain. Gurukul Kangri Collection, Haridwar

Digitized by Arya Samaj Foundation Chennai and eGangotri

stalks: (*a*) those of the *anterior stalk* pass from the lateral part of the thalamus through the frontal part of the internal capsule to the frontal lobe; (*b*) the fibres of the *posterior stalk* (*optic radiations*) arise in the pulvinar and lateral geniculate body, and are conveyed through the occipital part of the internal capsule to the occipital lobe; (*c*) the fibres of the *inferior stalk* leave the under and medial surfaces of the thalamus, and pass beneath the lentiform nucleus to the temporal lobe and insula; (*d*) those of the *parietal stalk* pass from the lateral surface of the thalamus to the parietal lobe. Fibres also extend from the thalamus into the caudate and lentiform nuclei of the corpus striatum—those destined for the caudate nucleus leave the lateral surface, and those for the lentiform nucleus the inferior surface, of the thalamus. A large descending fasciculus (thalamo-olivary) ends in the inferior olivary nucleus.

FIG. 831.—The hind-brain and the mid-brain. Posterolateral aspect.

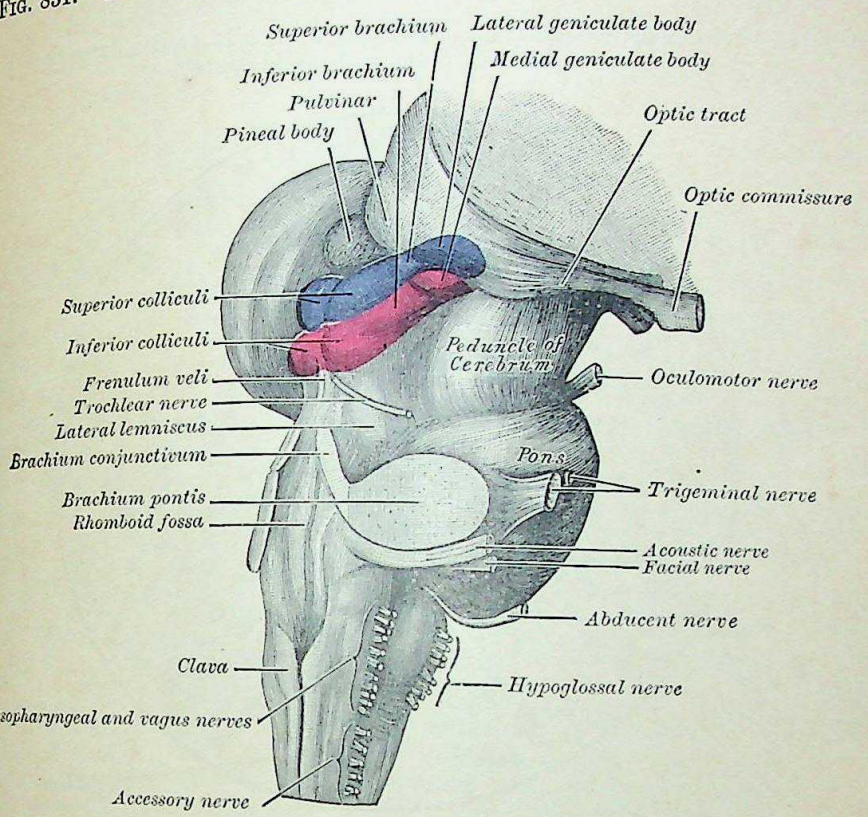

The **metathalamus** (fig. 831) comprises the geniculate bodies, which are two in number—a medial and a lateral—on either side.

The *medial geniculate body* lies under cover of the pulvinar of the thalamus and on the lateral aspect of the corpora quadrigemina. Oval in shape, with its long axis directed forwards and lateralwards, it is lighter in colour and smaller in size than the lateral geniculate body. The inferior brachium from the inferior colliculus disappears under cover of it, while from its lateral extremity a strand of fibres passes to join the optic tract. It receives many acoustic fibres from the lateral lemniscus, and its cells send a relay of similar fibres to the cortex of the temporal lobe. The medial geniculate body is connected with the inferior colliculus of the opposite side by the commissure of Gudden, the fibres of which pass through the posterior part of the optic chiasma and run in the medial parts of the optic tracts.

The *lateral geniculate body* is an oval elevation on the lateral part of the posterior end of the thalamus, and is connected with the superior colliculus by the superior brachium. It is of a dark colour, and presents a laminated arrangement consisting of alternate layers of grey and white substance. It receives most of the fibres of the optic tract, but some fibres of this tract pass over or through it into the pulvinar. Its cells are large and pigmented; their axons pass to the visual area in the occipital part of the cerebral cortex.

CC-0. In Public Domain. Gurukul Kangri Collection, Haridwar

Digitized by Arya Samaj Foundation Chennai and eGangotri

The superior colliculus, the pulvinar, and the lateral geniculate body are termed the *lower visual centres*. Extirpation of the eyes in new-born animals entails an arrest of the development of these centres, but has no effect on the medial geniculate bodies or on the inferior colliculi. Moreover, the latter are well developed in the mole, an animal in which the superior colliculi are rudimentary.

The **epithalamus** comprises the trigonum habenulæ, the pineal body, and the posterior commissure.

The *trigonum habenulæ* is a small depressed triangular area situated in front of the superior colliculus and on the lateral aspect of the posterior part of the tænia thalami. It contains a group of nerve-cells termed the *ganglion habenulæ*. Fibres reach this ganglion from the anterior perforated substance through the medullary stria which runs along the junction of the medial with the upper surface of the thalamus; some fibres, forming what is termed the *habenular*

Fig. 832.—A section through the pineal body of a child aged 13 months. Stained with hæmatoxylin and eosin. × 400.

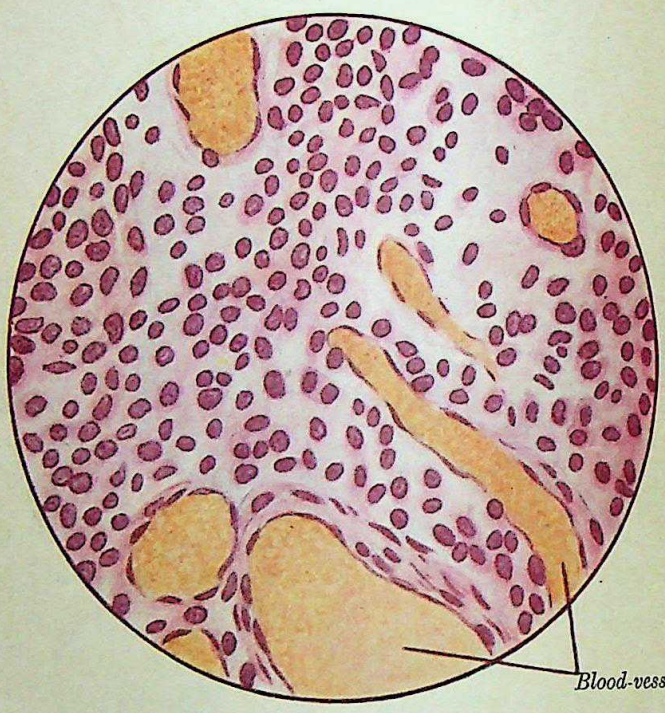

commissure, cross to the ganglion of the opposite side. Most of its fibres are, however, directed downwards and form the *fasciculus retroflexus of Meynert*, which passes medially to the red nucleus, and, after decussating with the corresponding fasciculus of the opposite side, ends in the interpeduncular ganglion.

The *pineal body* (fig. 828) is a small, conical, reddish-grey body which lies in the depression between the superior colliculi. It is placed beneath the splenium of the corpus callosum, but is separated from this by the tela chorioidea of the third ventricle, the lower layer of which envelops it. It measures about 8 mm. in length, and its base, directed forwards, is attached by a stalk or peduncle of white substance. The *stalk* divides anteriorly into two laminæ, a dorsal and a ventral, which are separated from one another by the pineal recess of the third ventricle. The ventral lamina is continuous with the posterior commissure; the dorsal lamina is continuous with the habenular commissure, and divides into two strands, termed the medullary striæ, which run forwards, one on either side, along the junction of the medial and upper surfaces of the thalamus to blend in front with the columns of the fornix.

Structure (fig. 832).—The bulk of the parenchyma of the pineal gland consists of rounded cells, the so-called *pineal* cells, with irregular nuclei poor in chromatin. At birth a few neuroglia-cells and nerve-cells are present; the latter have scanty protoplasm and angular nuclei rich in chromatin. Connective tissue cells and fibrils appear during the first year,

CC-0. In Public Domain. Gurukul Kangri Collection, Haridwar

Digitized by Arya Samaj Foundation Chennai and eGangotri

and gradually increase in quantity; the rate at which fibrosis takes place is very variable. Calcareous concretions are constantly present in the pineal body after the seventeenth year; spaces or cysts may also be present.*

The human pineal body is phylogenetically homologous with the parietal eye of cyclostome fishes. Creutzfeldt has pointed out that it is best developed in ruminants and horses, but absent in the elephant, seal, dasypus, mole, and many other animals, and he connects its presence with the possession of a relatively thin skin.

Applied Anatomy.—The function of the pineal body in the human body is very uncertain. Probably it has an internal secretion, though this is not proved. Possibly its function is to regulate the pressure of the cerebrospinal fluid. The growth of a tumour in the pineal body, itself of rare occurrence, has led in a few instances to sexual precocity or to obesity. The operative removal of the pineal body from puppies produces no abnormality in their subsequent development.

FIG. 833.—A median sagittal section through the brain. The relations of the pia mater are indicated by the red colour.

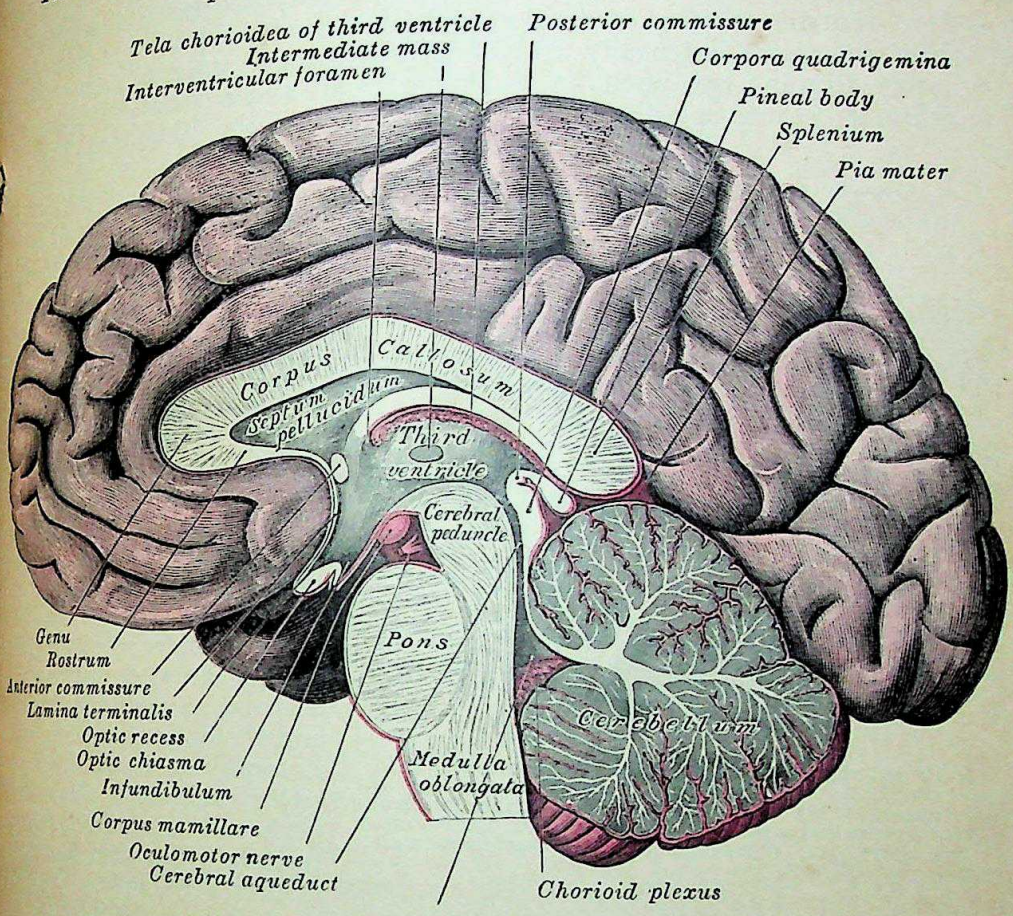

The *posterior commissure* is a rounded band of fibres crossing the middle line on the dorsal aspect of the upper end of the cerebral aqueduct. Its fibres acquire their medullary sheaths early, but their connexions have not been definitely determined. Most of them have their origin in a nucleus, the *nucleus of the posterior commissure*, which lies in the central grey substance of the upper end of the cerebral aqueduct, in front of the nucleus of the oculomotor nerve; some are probably derived from the posterior part of the thalamus and from the superior colliculus; others are believed to be continued downwards into the medial longitudinal fasciculus.

The **hypothalamus** (fig. 833) includes the subthalamic tegmental region and the structures forming the greater part of the floor of the third ventricle, viz. the corpora mamillaria, tuber cinereum, infundibulum, hypophysis, and optic chiasma.

* Consult an abstract of an article by K. H. Krabbe in the *Review of Neurology and Psychiatry*, Edinburgh, 1915, xiii. 300.

CC-0. In Public Domain. Gurukul Kangri Collection, Haridwar

Digitized by Arya Samaj Foundation Chennai and eGangotri

The *subthalamic tegmental region* consists of the upward continuation of the tegmentum; it lies on the ventrolateral surface of the thalamus and separates it from the fibres of the internal capsule. The red nucleus and the substantia nigra are prolonged into its lower part; in front it is continuous with the substantia innominata of Meynert (p. 860), medially with the grey substance of the floor of the third ventricle. It consists from above downwards of three strata: (1) *stratum dorsale*, directly applied to the under surface of the thalamus and consisting of fine longitudinal fibres; (2) *zona incerta*, a continuation forwards of the formatio reticularis of the tegmentum; and (3) the *corpus subthalamicum* or *nucleus of Luys*, a brownish mass presenting a lenticular shape on transverse section, and situated on the dorsal aspect of the fibres of the base of the cerebral peduncle; it is encapsuled by a lamina of nerve-fibres and contains numerous medium-sized nerve-cells the connexions of which are as yet not fully determined.

The *corpora mamillaria* are two round white masses, each about the size of a small pea, placed side by side below the grey substance of the floor of the third ventricle in front of the posterior perforated substance. Each consists of white substance externally and of grey substance internally, the cells of the latter forming two nuclei, a *medial* of small and a *lateral* of large cells. The white substance is mainly formed by the fibres of the columns of the fornix which descend to the base of the brain and end partly in the corpora mamillaria. From the cells of the medial nucleus a bundle of fibres arises and divides into a *mamillothalamic fasciculus* (bundle of Vicq d'Azyr) which passes upwards into the anterior nucleus of the thalamus, and a *mamillotegmental fasciculus* which is directed downwards into the tegmentum. Afferent fibres are conveyed to the lateral nucleus from the tegmentum.

Fig. 834.—A sagittal section through the hypophysis cerebri, in situ. Schematic. (Testut.)

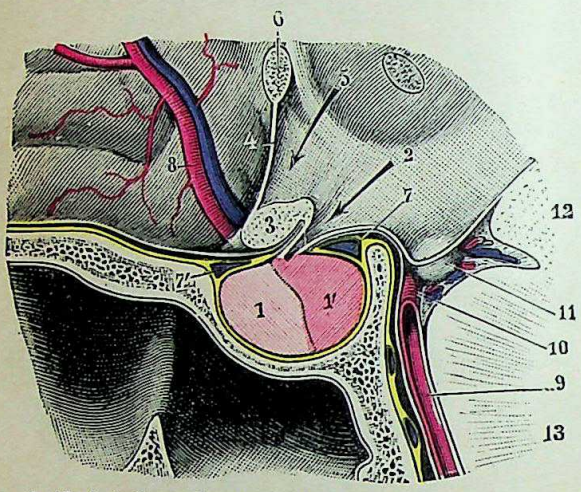

1, 1'. Anterior and posterior lobes of hypophysis. 2. Infundibulum. 3. Optic chiasma. 4. Lamina terminalis. 5. Optic recess. 6. Anterior commissure. 7, 7'. Circular sinus. 8. Anterior cerebral artery. 9. Basilar artery. 10. Posterior cerebral artery. 11. Corpus mamillare. 12. Cerebral peduncle. 13. Pons.

The *tuber cinereum* is a hollow eminence of grey substance situated between the corpora mamillaria behind, and the optic chiasma in front. Laterally it is continuous on either side with the anterior perforated substance, and anteriorly with a thin lamina, the *lamina terminalis*. From the under surface of the tuber cinereum a hollow conical process, the *infundibulum*, projects downwards and forwards and is attached to the posterior lobe of the hypophysis.

In the lateral part of the tuber cinereum is a nucleus of nerve-cells, the *basal optic nucleus of Meynert*, and close to the cavity of the third ventricle are three additional nuclei.

Between the tuber cinereum and the corpora mamillaria a small elevation, with a corresponding depression in the third ventricle, is sometimes seen. Retzius has named it the *eminentia saccularis* and regards it as a representative of the saccus vasculosus found in some of the lower vertebrates.

The *hypophysis* (pituitary body) (fig. 834) is a reddish-grey, somewhat ovoid mass, measuring about 12 mm. in its transverse, and 8 mm. in its antero-posterior, diameter. It is attached to the end of the infundibulum, and is situated in the fossa hypophyseos of the sphenoidal bone, where it is retained by a circular fold of dura mater, the *diaphragma sellæ*; this fold almost completely roofs in the fossa, leaving only a small central aperture through which the infundibulum passes.

CC-0. In Public Domain. Gurukul Kangri Collection, Haridwar

Digitized by Arya Samaj Foundation Chennai and eGangotri

The hypophysis consists of an anterior and a posterior lobe, which differ in their development and structure (fig. 835). The *anterior lobe* is the larger, and is somewhat kidney-shaped, the concavity being directed backwards and embracing the posterior lobe. It is developed from a diverticulum of

FIG. 835.—A median sagittal section through the hypophysis of an adult monkey. Semidiagrammatic. (Herring.)

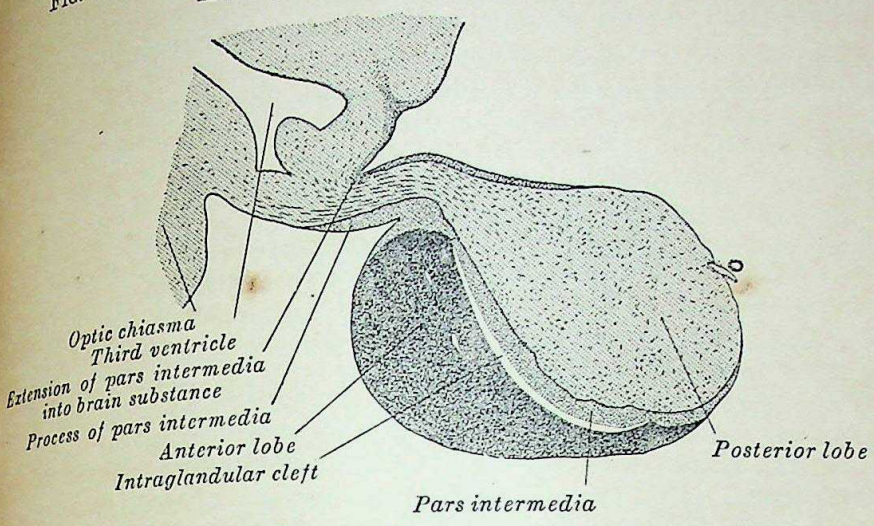

the ectoderm of the primitive buccal cavity or stomodæum (p. 135), and consists of a pars anterior and a pars intermedia, separated from each other by a narrow cleft, the remnant of the diverticulum. The *pars anterior* is extremely vascular and consists of granular epithelial cells of varying

FIG. 836.—A section of the hypophysis. ×100.

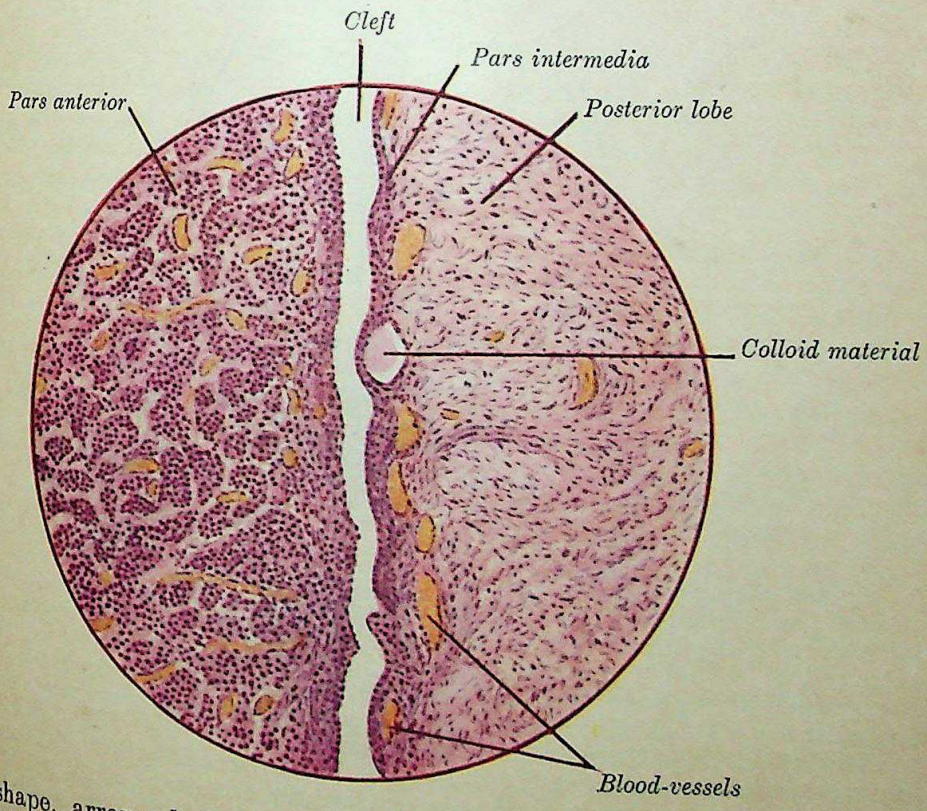

size and shape, arranged in cord-like trabeculæ or alveoli and separated by large, thin-walled blood-vessels. The *pars intermedia* is a thin lamina closely applied to the body and neck of the posterior lobe; it contains a few blood-vessels and consists of finely granular cells between which are small

CC-0. In Public Domain. Gurukul Kangri Collection, Haridwar

Digitized by Arya Samaj Foundation Chennai and eGangotri

masses of colloid material. The *posterior lobe* is developed as a downgrowth from the floor of the embryonic brain, and during early fœtal life contains a cavity continuous with that of the third ventricle. In some animals (e.g. cat) this cavity persists throughout life. Although of nervous origin the posterior lobe contains no nerve-cells or fibres. It consists of neuroglia-cells and fibres and is invaded by cell-columns which grow into it from the pars intermedia; imbedded in it are scattered masses of a colloid substance histologically similar to that found in the thyreoid gland. In certain of the lower vertebrates (e.g. fishes) nervous structures are present, and the lobe is of large size.

FIG. 837.—A scheme showing the central connexions of the optic nerves and optic tracts.

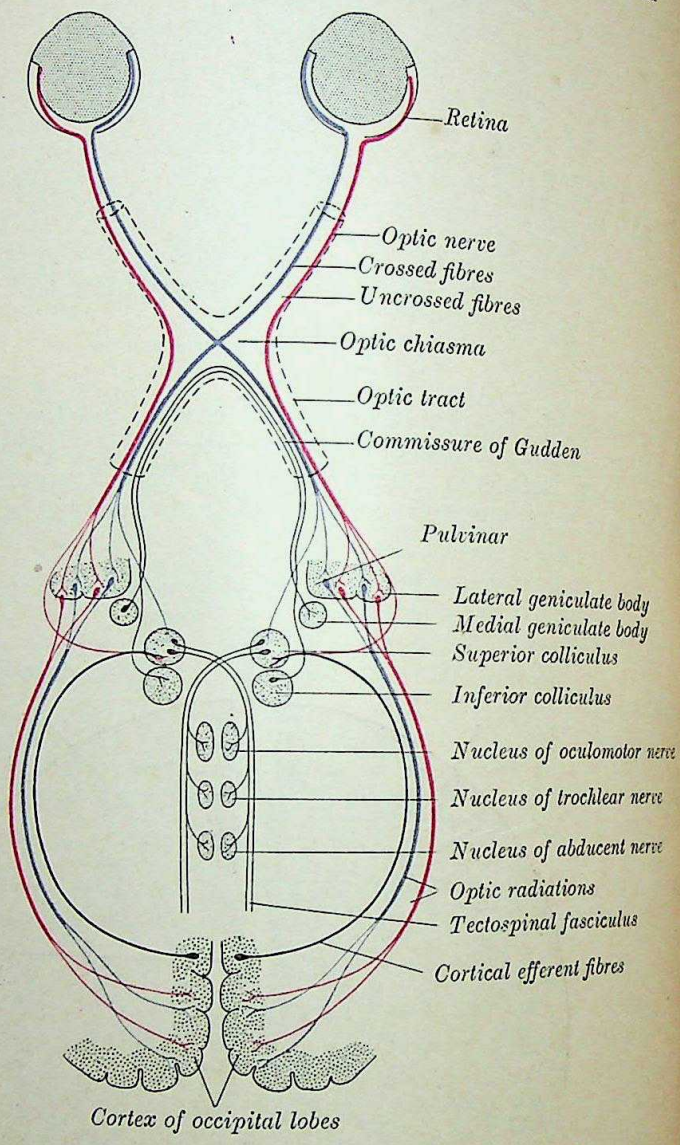

Applied Anatomy.—Sharpey Schafer has isolated from the pars intermedia a substance, no doubt an internal secretion, that causes constriction of the blood-vessels, rise of arterial blood-pressure, and increased secretion of urine, when injected subcutaneously. The anterior lobe is said "to control calcium metabolism and the growth of the skeleton." Enlargement of the hypophysis and of the cavity of the sella turcica is found in the rare disease *acromegaly*, which is characterised by gradual increase of the size of the face, hands, and feet, with headache and often a peculiar type of blindness. This blindness is due to the pressure of the enlarging hypophysis on the optic chiasma (fig. 834). The pressure causes atrophy of the nerve-fibres coming from the nasal sides of the retinæ; with the result that the patient loses his two temporal fields of vision while retaining his nasal fields (bitemporal hemianopsia).

Optic chiasma.—The optic chiasma (fig. 798) is a flattened, somewhat quadrilateral band of fibres, situated at the junction of the floor and anterior wall of

CC-0. Panini Kanya Maha Vidyalaya Collection. Gurukul Kangri Collection, Haridwar

Digitized by Arya Samaj Foundation Chennai and eGangotri

the third ventricle. Most of its fibres have their origins in the retinæ, and reach the chiasma through the optic nerves, which are continuous with its antero-lateral angles. In the chiasma the fibres from the nasal half of the retina cross the middle line and enter the optic tract of the opposite side, while the fibres from the temporal half of the retina do not cross, but pass back into the optic tract of the same side. In the posterior part of the commissure there is a strand of fibres, the *commissure of Gudden*, which is not derived from the optic nerves; it forms a connecting link between the medial geniculate body and the inferior colliculus of the opposite side.

Optic tracts.—The optic tracts (figs. 798, 837) are continued backwards and lateralwards from the posterolateral angles of the optic chiasma. Each passes between the anterior perforated substance and the tuber cinereum, and, winding round the ventrolateral aspect of the cerebral peduncle, divides into a medial and a lateral root. The medial root comprises the fibres of Gudden's commissure. The lateral root consists mainly of afferent fibres which arise in the retina and undergo partial decussation in the optic chiasma, as described; but it also contains a few fine efferent fibres which have their origins in the brain and their terminations in the retina. When traced backwards, the afferent fibres of the lateral root are found to end in the lateral geniculate body and pulvinar of the thalamus, and in the superior colliculus; and these three structures constitute the *lower visual centres*. Fibres arise from the nerve-cells in the lateral geniculate body and pulvinar, and pass through the occipital part of the internal capsule, under the name of the *optic radiations*, to the cortex of the occipital lobe of the cerebrum, where the *higher or cortical visual centre* is situated. Some of the fibres of the optic radiations take an opposite course, arising from the cells of the occipital cortex and passing to the superior colliculus. Some fibres from the superior colliculus cross the median plane and then pass to the nuclei of the oculomotor, trochlear, and abducent nerves. Some fibres reach the cerebellum through the brachia conjunctiva; others (tectospinal) descend into the spinal medulla.

The Third Ventricle

The **third ventricle** (figs. 828, 833, 838) is a median cleft between the two thalami. Behind, it communicates with the fourth ventricle through the cerebral aqueduct, and in front with the lateral ventricles through the inter-ventricular foramen. Somewhat triangular in shape with the apex directed backwards, it has a roof, a floor, an anterior and a posterior boundary, and two lateral walls.

The *roof* (fig. 838) is formed by a layer of epithelium, which stretches between the upper edges of the lateral walls of the cavity and is continuous with the epithelial lining of the ventricle. It is covered by and adherent to a fold of pia mater, named the tela chorioidea of the third ventricle, from the under surface of which a pair of vascular fringed processes, the *chorioid plexuses of the third ventricle*, project downwards, one on either side of the middle line, and invaginate the epithelial roof into the ventricular cavity.

The *floor* slopes downwards and forwards and is formed mainly by the structures which constitute the hypothalamus: from before backwards these are: the optic chiasma, the infundibulum and tuber cinereum, and the corpora mamillaria. Behind the last, the floor is formed by the posterior perforated substance and by the tegmenta of the cerebral peduncles. The ventricle is prolonged downwards as a funnel-shaped recess, the *recessus infundibuli*, into the infundibulum, to the apex of which the hypophysis is attached.

The *anterior boundary* is constituted below by the *lamina terminalis*, a thin layer of grey substance stretching from the upper surface of the optic chiasma to the rostrum of the corpus callosum; above by the columns of the fornix and the anterior commissure. At the junction of the floor and anterior wall, immediately above the optic chiasma, the ventricle presents a small angular recess or diverticulum, the *optic recess*. Between the columns of the fornix, and above the anterior commissure, is a second recess termed the *vulva*. At the junction of the roof with the anterior and lateral walls of the ventricle, and situated between the thalami behind and the columns of the fornix in

CC-0. In Public Domain. Gurukul Kangri Collection, Haridwar

Digitized by Arya Samaj Foundation Chennai and eGangotri

front, is the *interventricular foramen* (foramen of Monro) through which the third ventricle communicates with the lateral ventricles.

The *posterior boundary* is constituted by the pineal body, the posterior commissure and the cerebral aqueduct. A small recess, the *recessus pinealis*, projects into the stalk of the pineal body, whilst in front of and above the pineal body is a second recess, the *recessus suprapinealis*, consisting of a diverticulum of the epithelium which forms the ventricular roof.

Each *lateral wall* consists of an upper portion formed by the medial surface of the anterior two-thirds of the thalamus, and a lower consisting of an upward continuation of the grey substance of the ventricular floor. These two parts correspond to the alar and basal laminæ of the lateral wall of the

FIG. 838.—A coronal section through the lateral and third ventricles. Diagrammatic.

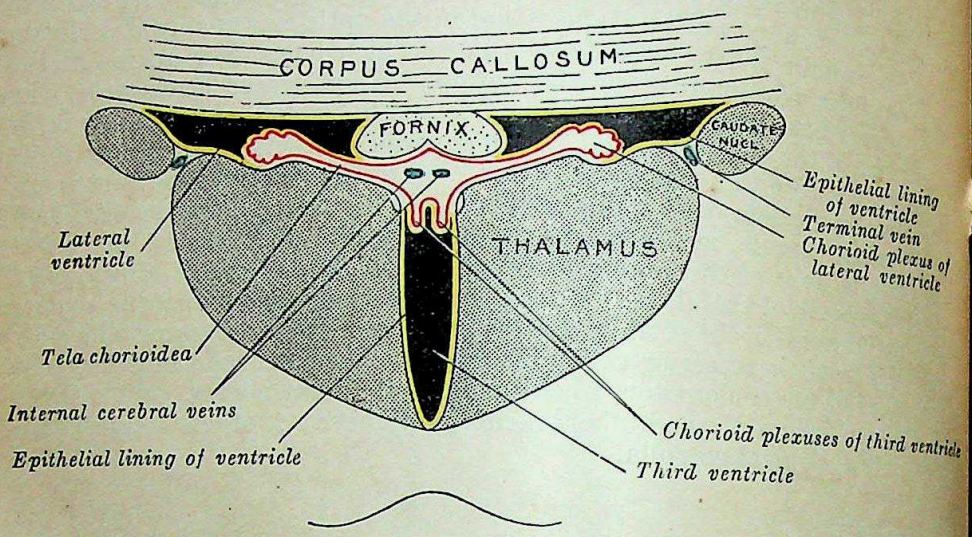

fore-brain vesicle and are separated from each other by a furrow, the *sulcus of Monro*, which extends from the interventricular foramen (p. 863) to the cerebral aqueduct. The lateral wall is limited above by the tænia thalami. The columns of the fornix curve downwards in front of the interventricular foramen, and then run in the lateral walls of the ventricle, where, at first, they form distinct prominences, but subsequently are lost to sight. The lateral walls are joined to each other across the cavity of the ventricle by a band of grey matter, the *massa intermedia* (p. 833).

The **interpeduncular fossa** (figs. 798, 839).—This is a somewhat lozenge-shaped area of the base of the brain, limited in front by the optic chiasma, behind by the anterosuperior surface of the pons, anterolaterally by the converging optic tracts and posterolaterally by the diverging cerebral peduncles. The structures contained in it have already been described; from behind forwards they are the posterior perforated substance (p. 825), corpora mamillaria tuber cinereum, infundibulum, and hypophysis (p. 838).

THE TELENCEPHALON

The **telencephalon** includes: (1) the cerebral hemispheres with their cavities, the lateral ventricles; and (2) the pars optica hypothalami and the anterior portion of the third ventricle (already described under the diencephalon). As intimated in the chapter on Embryology (p. 95), each cerebral hemisphere may be divided into three fundamental parts, viz. the rhinencephalon, the corpus striatum, and the neopallium. The rhinencephalon, associated with the sense of smell, is the oldest part of the telencephalon, and forms almost the whole of the hemisphere in some of the lower animals (e.g. fishes, amphibians, and reptiles). In man it is rudimentary, whereas the neopallium undergoes great development and forms the chief part of the hemisphere.

CC-0. In Public Domain. Gurukul Kangri Collection, Haridwar

Digitized by Arya Samaj Foundation Chennai and eGangotri

The Cerebral Hemispheres

The **cerebral hemispheres** constitute the largest part of the brain, and, when viewed together from above, assume the form of an ovoid mass broader behind than in front, the greatest transverse diameter corresponding with a line connecting the two parietal tuberosities. The hemispheres are separated by a deep median cleft, named the *longitudinal cerebral fissure*, and each possesses a central cavity, the lateral ventricle.

Fig. 839.—The base of the brain.

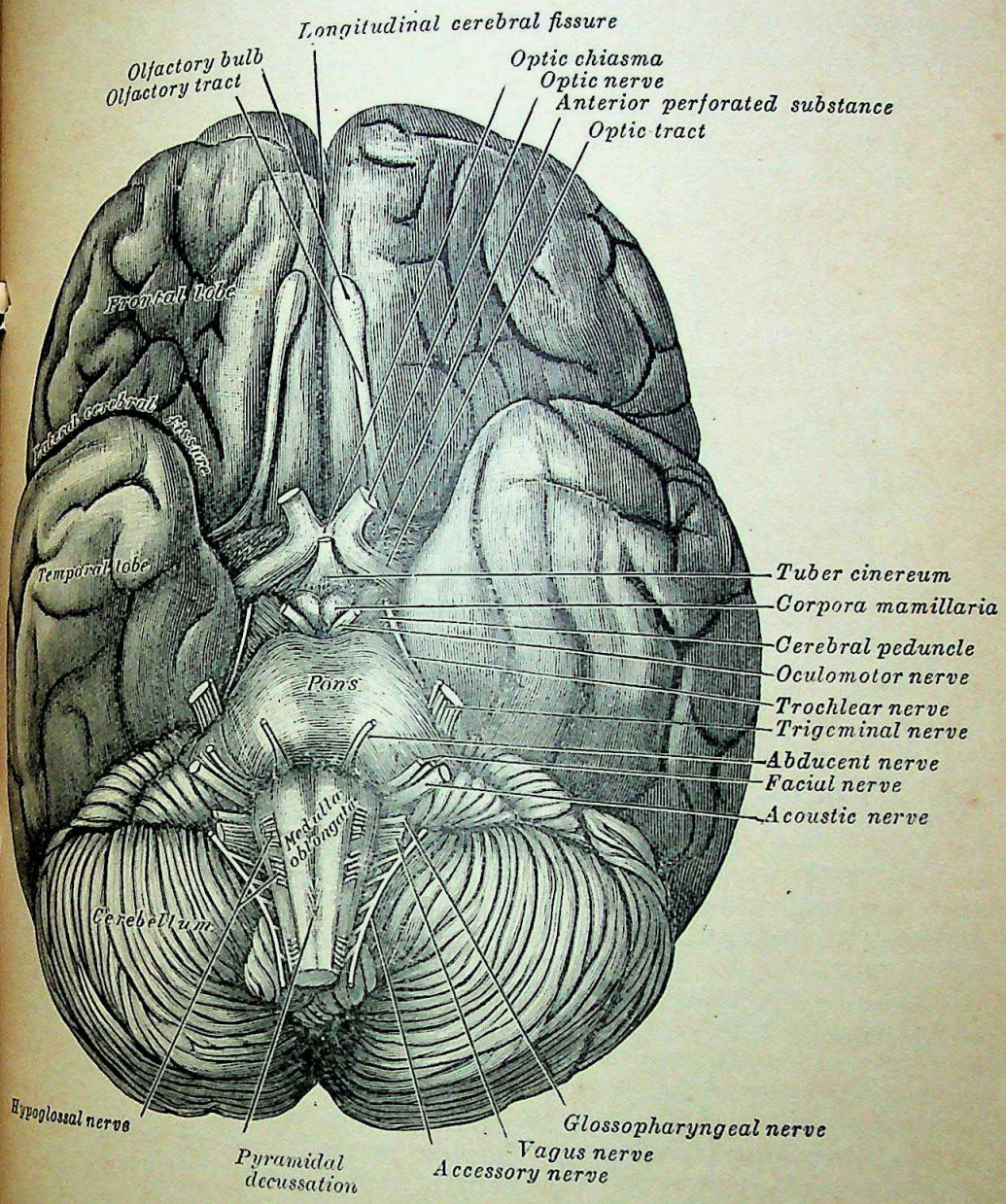

The **longitudinal cerebral fissure** contains a sickle-shaped process of dura mater, the falx cerebri. In front and behind, the fissure completely separates the cerebral hemispheres from one another; in the middle, however, it only extends down to a great central white commissure, the *corpus callosum*, which connects the hemispheres across the median plane.

In a median sagittal section (fig. 833) the cut corpus callosum presents the appearance of a broad, arched band. Its thick posterior end, termed the *splenium*, overlaps the mid-brain, but is separated from it by the tela chorioidea of the third ventricle and the pineal body. Its anterior curved end, termed the *genu*, gradually tapers into a thinner portion, the *rostrum*, which is continued

CC-0. In Public Domain. Gurukul Kangri Collection, Haridwar

Digitized by Arya Samaj Foundation Chennai and eGangotri

downwards and backwards in front of the anterior commissure to join the lamina terminalis. Arching backwards from immediately behind the anterior commissure to the under surface of the splenium is a second white band named the *fornix*; between this and the corpus callosum are the laminæ and cavity of the septum pellucidum.

The Surfaces of the Cerebral Hemispheres

Each cerebral hemisphere presents three surfaces: lateral, medial, and inferior.

The *lateral surface* is convex in adaptation to the concavity of the corresponding half of the vault of the cranium. The *medial surface* is flat and vertical and is separated from that of the opposite hemisphere by the longitudinal fissure and the falx cerebri. The *inferior surface* is of an irregular form, and may be divided into three areas: anterior, middle, and posterior. The anterior area, formed by the orbital surface of the frontal lobe, is concave, and rests on the roof of the orbit and nose; the middle area is convex, and consists of the under surface of the temporal lobe: it is adapted to the corresponding half of the middle cranial fossa. The posterior area is concave, directed medialwards and downwards, and is named the *tentorial surface*, since it rests upon the tentorium cerebelli, which intervenes between it and the upper surface of the cerebellum.

Fig. 840.—The lateral surface of the left cerebral hemisphere. Superior aspect.

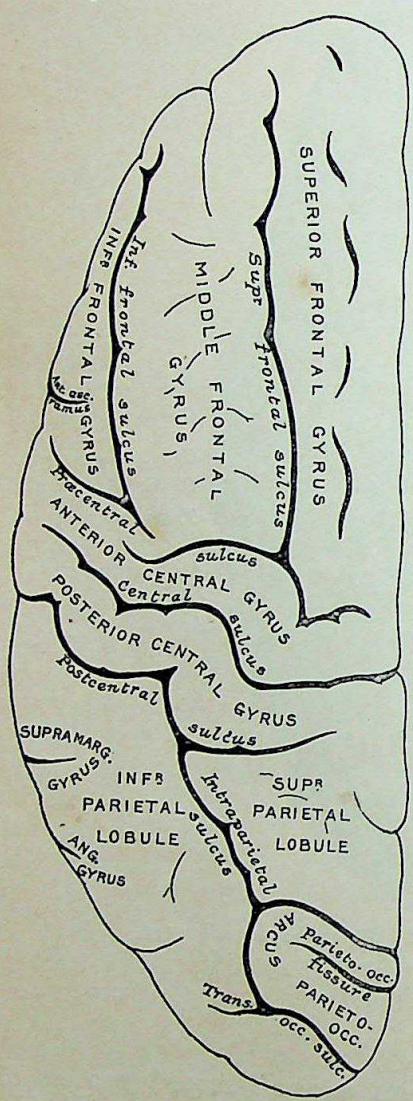

The three surfaces are separated by the following borders: (*a*) *superomedial*, between the lateral and medial surfaces; (*b*) *inferolateral*, between the lateral and inferior surfaces; the anterior part of this border separates the lateral from the orbital surface of the frontal lobe, and is known as the *superciliary* border; (*c*) *medial occipital*, between the tentorial and medial surfaces; and (*d*) *medial orbital*, separating the orbital from the medial surface. The anterior end of the hemisphere is named the *frontal pole*; the posterior, the *occipital pole*; and the anterior end of the temporal lobe, the *temporal pole*. About 5 cm. in front of the occipital pole on the inferolateral border is an indentation or notch, named the *pre-occipital notch*.

The surfaces of the hemispheres are moulded into a number of irregular eminences, named *gyri* or *convolutions*, and separated by furrows termed *fissures* and *sulci*.

The gyri and their intervening fissures and sulci are fairly constant in their arrangement; at the same time they vary within certain limits, not only in different individuals, but on the two hemispheres of the same brain. The convoluted condition of the surface permits of a great increase of the grey matter without the sacrifice of much additional space, and the number and extent of the gyri, as well as the depth of the intervening furrows, appear to bear a direct relation to the intellectual powers of the individual.

Certain of the fissures and sulci are utilised for the purpose of dividing the hemisphere into lobes, and are therefore termed *interlobar*; included under

CC-0. In Public Domain. Gurukul Kangri Collection, Haridwar

Digitized by Arya Samaj Foundation Chennai and eGangotri

this category are the lateral cerebral, parieto-occipital, calcarine and collateral fissures, and the central, cingulate, subparietal and circular sulci.

The **lateral cerebral fissure** (fissure of Sylvius) (figs. 839, 841) is a well-marked cleft on the inferior and lateral surfaces of the hemisphere, and consists of a short stem which divides into three rami. The *stem* is situated on the base of the brain (fig. 839), and commences in a depression at the lateral angle of the anterior perforated substance. From this point it extends between the anterior part of the temporal lobe and the orbital surface of the frontal lobe, and reaches the lateral surface of the hemisphere. Here it divides into three rami: an anterior horizontal, an anterior ascending, and a posterior. The *anterior horizontal ramus* passes forwards for about 2·5 cm. into the inferior frontal gyrus, while the *anterior ascending ramus* extends upwards for about an equal distance into the same convolution. The *posterior ramus* is the longest; it runs backwards and slightly upwards for about 7 cm., and ends by an upward inflexion in the parietal lobe.

Fig. 841.—The lateral surface of the left cerebral hemisphere.

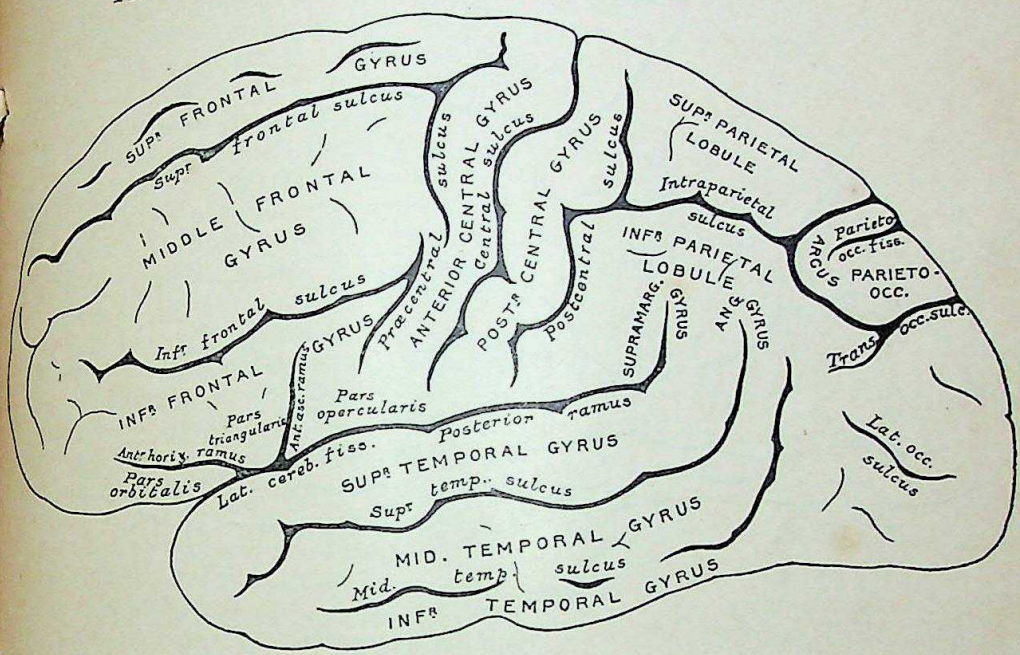

The parieto-occipital fissure.—Only a small part of this fissure is seen on the lateral surface of the hemisphere, its chief part being on the medial surface. The *lateral part* (fig. 841) is situated about 5 cm. in front of the occipital pole of the hemisphere, and is about 1·25 cm. long. The *medial part* (fig. 842) runs downwards and forwards as a deep cleft on the medial surface of the hemisphere, and joins the calcarine fissure below and behind the posterior end of the corpus callosum. In most cases it contains a submerged gyrus.

The calcarine fissure (fig. 842) is on the medial surface of the hemisphere. It begins near the occipital pole in two converging rami, and runs forward, at first with an upward, and then with a downward curve; it ends in the posterior part of the gyrus hippocampi, just below the splenium of the corpus callosum; a little behind the splenium it is joined at an acute angle by the medial part of the parieto-occipital fissure. The anterior part of the calcarine fissure gives rise to the prominence of the calcar avis in the posterior cornu of the lateral ventricle (p. 856).

The collateral fissure (fig. 842) is on the tentorial surface of the hemisphere, and extends from near the occipital pole to within a short distance of the temporal pole. Behind, it lies below and lateral to the calcarine fissure, from which it is separated by the lingual gyrus; in front, it is situated between the hippocampal gyrus and the anterior part of the fusiform gyrus.

The central sulcus (fissure of Rolando) (figs. 840, 841) is situated about the middle of the lateral surface of the hemisphere, and begins in or near the

CC-0. In Public Domain. Gurukul Kangri Collection, Haridwar

Digitized by Arya Samaj Foundation Chennai and eGangotri

longitudinal cerebral fissure, a little behind the midpoint between the frontal and occipital poles. It runs sinuously downwards and forwards, and ends a little above the posterior ramus of the lateral fissure, and about 2·5 cm. behind the anterior ascending ramus of the same fissure. It describes two chief curves: a *superior genu* with its concavity directed forwards, and an *inferior genu* with its concavity directed backwards. The central sulcus forms an angle, opening forwards, of about 70° with the median plane.

The **cingulate sulcus** (fig. 842) is on the medial surface of the hemisphere. It begins below the rostrum of the corpus callosum, curves in front of its genu, is continued backwards above its body, and finally ascends to the superomedial border of the hemisphere a short distance behind the upper end of the central sulcus. It separates the cingulate gyrus from the superior frontal gyrus and the paracentral lobule.

FIG. 842.—The medial surface of the left cerebral hemisphere.

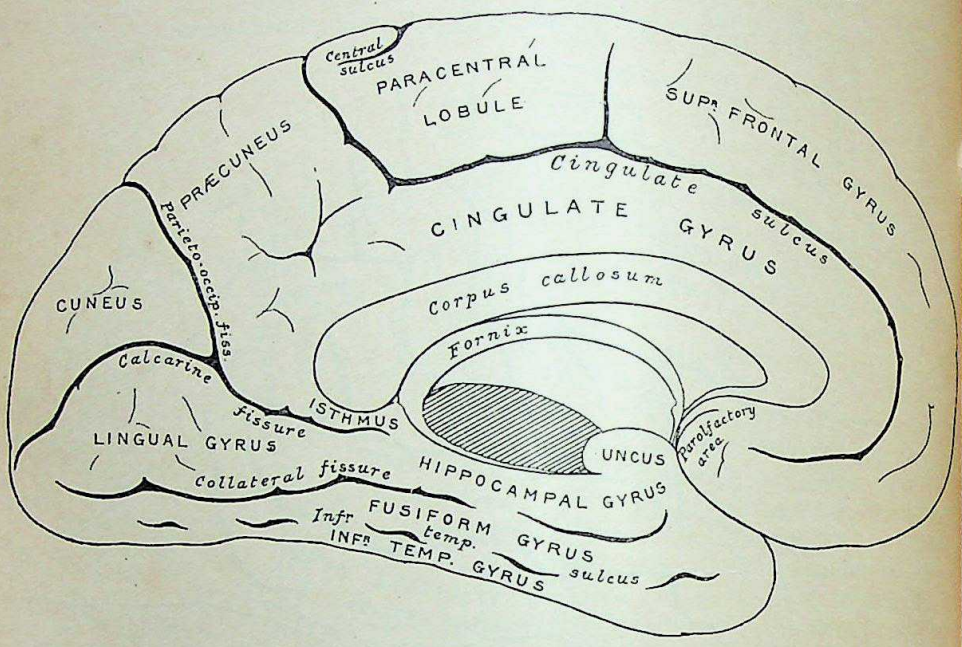

The **subparietal sulcus** is a short sulcus on the medial surface of the hemisphere, in line with but separate from the cingulate sulcus. It intervenes between the præcuneus and the cingulate gyrus.

The **circular sulcus** (sulcus limitans insulæ) (fig. 845) is on the lower and lateral surfaces of the hemisphere. It surrounds the insula (p. 849) and separates it from the frontal, parietal, and temporal lobes.

Lobes of the hemispheres.—By means of these fissures and sulci, assisted by certain arbitrary lines, each hemisphere is divided into the following lobes: *frontal*, *parietal*, *temporal*, *occipital*, *limbic*, and the *insula*.

The frontal lobe.—On the lateral surface of the hemisphere this lobe extends from the frontal pole to the central sulcus, the latter separating it from the parietal lobe; below, it is limited by the posterior ramus of the lateral fissure, which intervenes between it and the temporal lobe. On the medial surface, it is separated from the cingulate gyrus by the cingulate sulcus; and on the inferior surface, it is bounded behind by the stem of the lateral cerebral fissure.

The *lateral surface* of the frontal lobe (fig. 841) is traversed by three sulci which divide it into four gyri; the sulci are named the precentral, and the superior and inferior frontal; the gyri are the anterior central, and the superior, middle, and inferior frontal. The *precentral sulcus* runs parallel to the central sulcus, and is usually divided into an upper and a lower part; between it and the central sulcus is the anterior central gyrus. From the precentral sulcus, the *superior* and *inferior frontal sulci* run forwards and downwards, and divide the remainder of the lateral surface of the lobe into three parallel gyri, named the superior, middle, and inferior frontal gyri.

CC-0. In Public Domain. Gurukul Kangri Collection, Haridwar

Digitized by Arya Samaj Foundation Chennai and eGangotri

The *anterior central gyrus* is bounded in front by the precentral sulcus, behind by the central sulcus; it extends from the superomedial border of the hemisphere to the posterior ramus of the lateral cerebral fissure.

The *superior frontal gyrus* is situated above the superior frontal sulcus and is continued on to the medial surface of the hemisphere. The portion on the lateral surface of the hemisphere is more or less completely subdivided into an upper and a lower part by the *paramedial sulcus*, which, however, is frequently interrupted by bridging gyri.

The *middle frontal gyrus*, between the superior and inferior frontal sulci, is continuous with the anterior orbital gyrus on the inferior surface of the frontal lobe; it is frequently subdivided into two by the *medial frontal sulcus* of Eberstaller, which ends anteriorly in a wide bifurcation.

The *inferior frontal gyrus* lies below the inferior frontal sulcus, and is continuous with the lateral and posterior orbital gyri on the inferior surface of the frontal lobe. The anterior horizontal and ascending rami of the lateral cerebral fissure subdivide it into three parts, viz.: (1) *pars orbitalis*, below the anterior horizontal ramus of the fissure; (2) *pars triangularis* ('cap' of Broca), between the ascending and horizontal rami; and (3) *pars basilaris*, behind the anterior ascending ramus. The left inferior frontal gyrus is, as a rule, more highly developed than the right, and is named the *gyrus of Broca*, from the fact that Broca described it as the centre for articulate speech.

FIG. 843.—The orbital surface of the left frontal lobe.

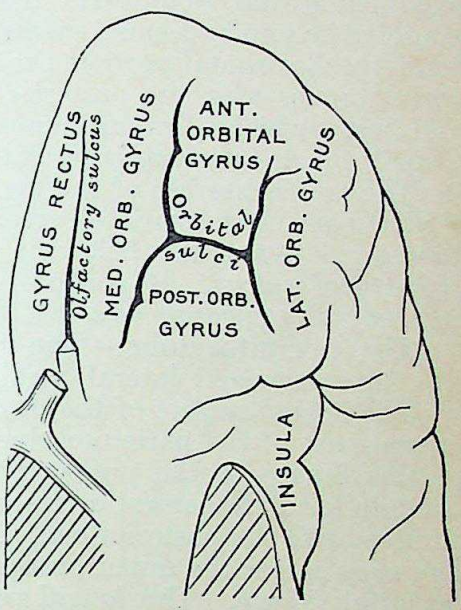

The *inferior or orbital surface* of the frontal lobe (fig. 843) is concave, and rests on the orbital plate of the frontal bone. It is divided by an H-shaped *orbital sulcus* into four gyri. These are named, from their position, the *medial*, *anterior*, *lateral*, and *posterior orbital gyri*. The medial orbital gyrus is traversed by an anteroposterior sulcus, the *olfactory sulcus*, for the olfactory tract; the portion medial to this is named the *gyrus rectus*, and is continuous with the superior frontal gyrus on the medial surface.

The *medial surface* of the frontal lobe is occupied by the medial part of the superior frontal gyrus (marginal gyrus) (fig. 842). It lies between the cingulate sulcus and the superomedial margin of the hemisphere. The posterior part of this gyrus is named the *paracentral lobule*, and is continuous, over the superomedial border of the hemisphere, with the anterior and posterior central gyri.

The **parietal lobe.**—The parietal lobe is separated from the frontal lobe by the central sulcus, but its boundaries below and behind are not so definite. Posteriorly, it is limited by the lateral part of the parieto-occipital fissure, and by a line carried across the hemisphere from the lateral end of this fissure to the pre-occipital notch. It is separated from the temporal lobe by the posterior ramus of the lateral fissure, and by a line carried backwards from this ramus to meet the line passing downwards to the pre-occipital notch. It has a lateral and a medial surface.

The *lateral surface* of the parietal lobe (fig. 841) is cleft by the *intraparietal sulcus* (Turner), which consists of an oblique and a horizontal portion. The oblique part is named the *postcentral sulcus*, and commences below, about midway between the lower end of the central sulcus and the upturned end of the lateral fissure. It runs upwards and backwards, parallel to the central sulcus, and is sometimes divided into an *upper* and a *lower* ramus. It forms the hinder limit of the posterior central gyrus.

From about the middle of the postcentral sulcus, or from the upper end of its inferior ramus, the *horizontal portion* of the intraparietal sulcus is carried backwards and slightly upwards on the parietal lobe, and is prolonged, under

CC-0. In Public Domain. Gurukul Kangri Collection, Haridwar

Digitized by Arya Samaj Foundation Chennai and eGangotri

the name of the *occipital ramus*, into the occipital lobe, where it divides into two parts, which form nearly a right angle with the main stem and constitute the *transverse occipital sulcus*. The part of the parietal lobe above the horizontal portion of the intraparietal sulcus is named the superior parietal lobule; the part below, the inferior parietal lobule.

The *posterior central gyrus* extends from the superomedial border of the hemisphere to the posterior ramus of the lateral fissure. It lies behind the central sulcus, parallel with the anterior central gyrus, with which it is continuous below, and sometimes also above, the central sulcus.

The *superior parietal lobule* is bounded in front by the upper part of the postcentral sulcus, but is usually connected with the posterior central gyrus above the end of the sulcus; behind it, is the lateral part of the parieto-occipital fissure, round the end of which it is joined to the occipital lobe by a curved gyrus, the *arcus parieto-occipitalis*; below, it is separated from the inferior parietal lobule by the horizontal portion of the intraparietal sulcus.

The *inferior parietal lobule* lies below the horizontal portion of the intraparietal sulcus, and behind the lower part of the postcentral sulcus. It is divided into two gyri. One, the *supramarginal gyrus*, arches over the upturned end of the lateral fissure; it is continuous in front with the postcentral gyrus, and behind and below with the superior temporal gyrus; it is occasionally bounded behind by a small sulcus, the *sulcus intermedius primus*, which descends from the horizontal part of the intraparietal sulcus. The other, the *angular gyrus*, arches over the posterior end of the superior temporal sulcus, behind and below which it is continuous with the middle temporal gyrus; sometimes a small *sulcus intermedius secundus* forms its posterior boundary.

The *medial surface* of the parietal lobe (fig. 842) is bounded behind by the medial part of the parieto-occipital fissure; in front, by the posterior end of the cingulate sulcus; below, it is separated from the cingulate gyrus by the *subparietal sulcus*. It consists of a square-shaped convolution, termed the *præcuneus* or *quadrate lobe*.

The **occipital lobe.**—The occipital lobe, small and pyramidal in shape, has three surfaces: lateral, medial, and tentorial.

The *lateral surface* of the occipital lobe (fig. 841) is limited in front by the lateral part of the parieto-occipital fissure, and by a line carried from the end of this fissure to the pre-occipital notch; it is traversed by the transverse occipital and the lateral occipital sulci. The *transverse occipital sulcus* is continuous with the posterior end of the occipital ramus of the intraparietal sulcus, and runs across the upper part of the lobe, a short distance behind the parieto-occipital fissure. The *lateral occipital sulcus* extends from behind forwards, and divides the lateral surface of the occipital lobe into a *superior* and an *inferior gyrus*, which are continuous in front with the parietal and temporal lobes. A vertical gyrus, which runs along the posterior border of this surface to the occipital pole, has been described as the *gyrus descendens* (Ecker).

The *medial surface* of the occipital lobe (fig. 842) is bounded in front by the medial part of the parieto-occipital fissure, and is traversed by the calcarine fissure, which subdivides it into the cuneus and the lingual gyrus. The *cuneus* is a wedge-shaped area between the calcarine fissure and the medial part of the parieto-occipital fissure. The *lingual gyrus* lies between the calcarine fissure and the posterior part of the collateral fissure; behind, it reaches the occipital pole; in front, it joins the hippocampal gyrus.

The *tentorial surface* of the occipital lobe is limited in front by an imaginary transverse line through the pre-occipital notch, and consists of the posterior part of the fusiform gyrus (p. 849), and the lower part of the lingual gyrus, which are separated from each other by the posterior segment of the collateral fissure.

The **temporal lobe.**—The temporal lobe has superior, lateral, and inferior surfaces.

The *superior surface* forms the lower limit of the lateral cerebral fissure and overlaps the insula. Three or four gyri spring from the depth of the hinder end of the fissure, and run obliquely forwards and lateralwards on the posterior part of the upper surface of the superior temporal gyrus; these are named the *transverse temporal gyri* (Heschl) (fig. 844).

The *lateral surface* (fig. 841) is bounded above by the posterior ramus of the lateral fissure, and by an imaginary line continued backwards from it; below,

CC-0. In Public Domain. Gurukul Kangri Collection, Haridwar

Digitized by Arya Samaj Foundation Chennai and eGangotri

it is limited by the inferolateral border of the hemisphere. It is divided into superior, middle, and inferior gyri by the superior and middle temporal sulci. The *superior temporal sulcus* traverses the temporal lobe, some little distance below, but parallel with, the posterior ramus of the lateral fissure; and therefore it is often termed the *parallel sulcus*. The *middle temporal sulcus* takes the same direction as the superior, but is situated at a lower level, and is usually subdivided into two or more parts. The *superior temporal gyrus* lies between the posterior ramus of the lateral cerebral fissure and the superior temporal sulcus, and is continuous behind with the supramarginal and angular gyri of the parietal lobe. The *middle temporal gyrus* is between the superior and middle temporal sulci, and is joined posteriorly with the angular gyrus. The

FIG. 844.—A section showing the upper surface of the left temporal lobe.

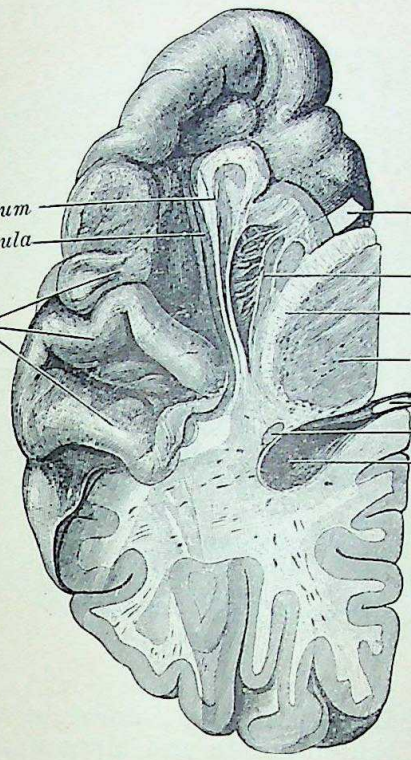

inferior temporal gyrus is placed below the middle temporal sulcus, and is connected behind with the inferior occipital gyrus; it also extends round the inferolateral border on to the inferior surface of the temporal lobe, where it is limited by the inferior temporal sulcus.

The *inferior surface* is concave, and is continuous posteriorly with the tentorial surface of the occipital lobe. It is traversed by the *inferior temporal sulcus*, which extends from near the occipital pole behind, to within a short distance of the temporal pole in front, but is frequently subdivided by bridging gyri. Lateral to this fissure is the narrow tentorial part of the inferior temporal gyrus, and medial to it the *fusiform gyrus*, which extends from the occipital to the temporal pole; this gyrus is limited medially by the collateral fissure, which separates it from the lingual gyrus behind and from the hippocampal gyrus in front.

The insula (island of Reil) (fig. 845) lies deeply in the lateral cerebral fissure, and is surrounded by the circular sulcus (p. 846); it can only be seen when the lips of the lateral cerebral fissure are widely separated, since it is overlapped and hidden by the gyri which bound the fissure. These gyri are termed the *opercula of the insula*; they are separated from each other by the three rami of the lateral fissure, and are named the orbital, frontal, fronto-parietal, and temporal opercula. The *orbital operculum* lies below the anterior horizontal ramus of the fissure, the *frontal* between this and the anterior ascending ramus, the *frontoparietal* between the anterior ascending ramus and

CC-0. In Public Domain. Gurukul Kangri Collection, Haridwar

Digitized by Arya Samaj Foundation Chennai and eGangotri

the upturned end of the posterior ramus, and the *temporal* below the posterior ramus. The frontal operculum is of small size in those cases where the anterior horizontal and ascending rami of the lateral fissure arise from a common stem. When the opercula have been removed, the insula is seen as a pyramidal eminence, the apex of which is directed towards the anterior perforated substance. It is divided into a larger anterior and a smaller posterior part by a deep sulcus (sulcus centralis insulæ) which runs backwards and upwards from the apex of the insula. The anterior part is subdivided by shallow sulci into three or four *short gyri*, while the posterior part is formed by one *long gyrus* which is often divided at its upper end. The cortical grey substance of the insula is continuous with that of the different opercula, while its deep surface corresponds with the lentiform nucleus of the corpus striatum.

FIG. 845.—The insula of the left side. Exposed by removing the opercula.

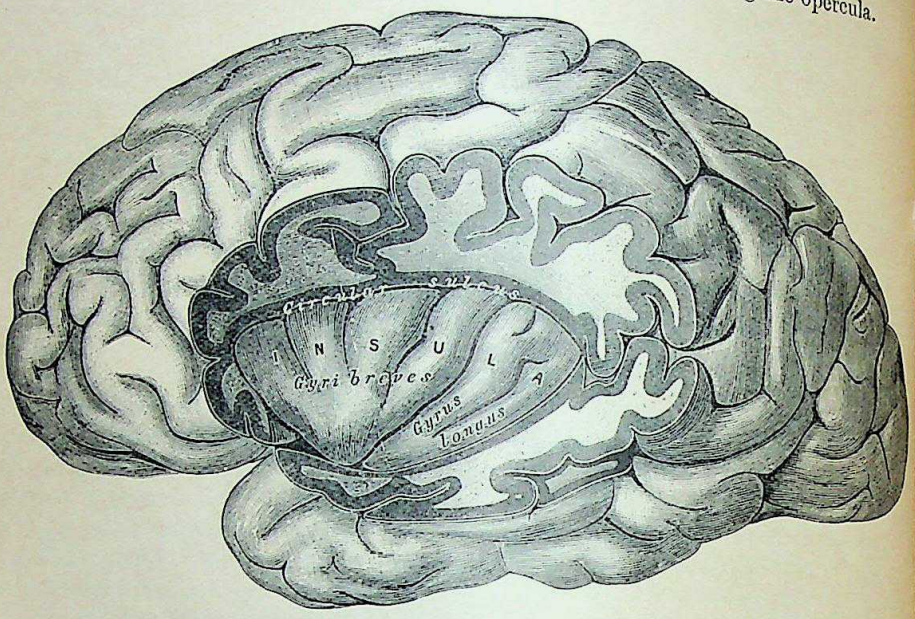

The **limbic lobe** (fig. 842).—The term limbic lobe was introduced by Broca, and under it he included the cingulate and hippocampal gyri, which together arch round the corpus callosum and the hippocampal fissure. These he separated on the morphological ground that they are well developed in animals possessing a keen sense of smell (osmatic animals), such as the dog and fox.

The *cingulate gyrus* is an arched convolution, lying in close relation to the superficial surface of the corpus callosum, from which it is separated by a slit-like fissure, the *callosal fissure*. It commences below the rostrum of the corpus callosum, curves round in front of its genu, extends along the upper surface of its body, and finally turns downwards behind the splenium, where it is connected by a narrow *isthmus* with the hippocampal gyrus. It is separated from the medial part of the superior frontal gyrus by the cingulate sulcus, and from the præcuneus by the subparietal sulcus.

The **callosal fissure** separates the cingulate gyrus from the convex surface of the corpus callosum, and, curving round the splenium, is continuous with the hippocampal fissure.

The *hippocampal gyrus* is bounded above by the hippocampal fissure, and below by the anterior part of the collateral fissure. Behind, it is continuous superiorly, through the isthmus, with the cingulate gyrus and inferiorly with the lingual gyrus. Running in the substance of the cingulate and hippocampal gyri, and connecting them together, is a tract of arched fibres, named the *cingulum* (p. 866). The anterior extremity of the hippocampal gyrus is recurved in the form of a hook (*uncus*), which is separated from the apex of the temporal lobe by a slight fissure, the *incisura temporalis*. Although superficially continuous with the hippocampal gyrus, the uncus forms morphologically a part of the rhinencephalon.

CC-0. In Public Domain. Gurukul Kangri Collection, Haridwar

Digitized by Arya Samaj Foundation Chennai and eGangotri

The **hippocampal fissure** begins immediately behind the splenium of the corpus callosum, and runs forwards between the hippocampal and dentate gyri to end in the uncus. It gives rise to the prominence of the hippocampus in the inferior cornu of the lateral ventricle.

The Rhinencephalon

The **rhinencephalon** (fig. 846) comprises the olfactory lobe, the uncus, the subcallosal and supracallosal gyri, the fascia dentata hippocampi, the septum pellucidum, the fornix, and the hippocampus.

1. The **olfactory lobe** is situated under the inferior or orbital surface of the frontal lobe. In many vertebrates it constitutes a well-marked portion

Fig. 846.—A scheme of the rhinencephalon.

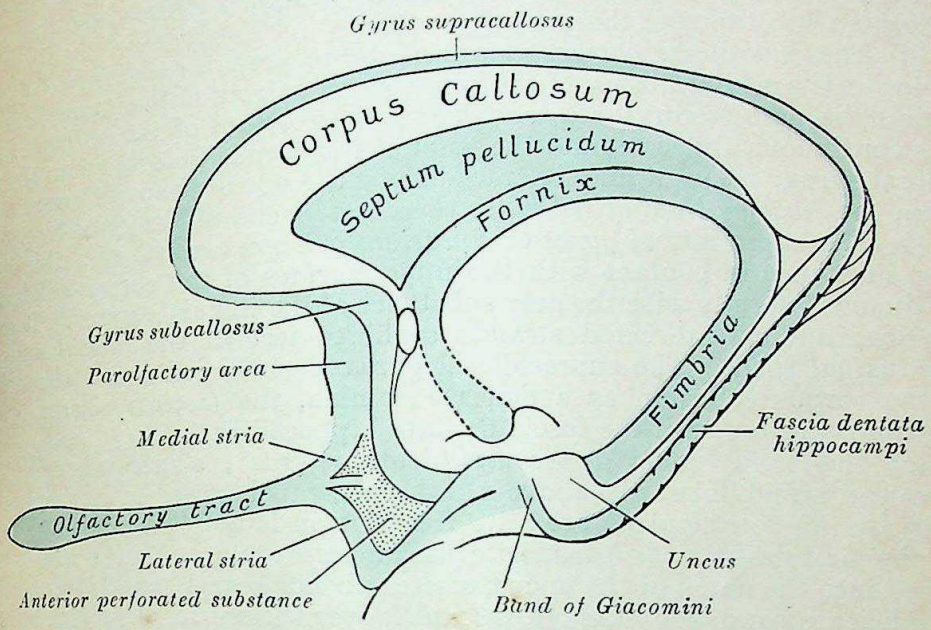

of the hemisphere and contains an extension of the lateral ventricle; but in man and some other mammals it is rudimentary. It consists of the olfactory bulb and tract, the olfactory trigone, the parolfactory area of Broca, and the anterior perforated substance.

(*a*) The *olfactory bulb* is an oval, reddish-grey mass which lies above the lamina cribrosa of the ethmoidal bone, and forms the anterior expanded extremity of the olfactory tract. The olfactory nerves pass upwards through the lamina cribrosa from the olfactory region of the nasal cavity and enter the inferior surface of the olfactory bulb. Its minute structure is described on p. 872. The two olfactory bulbs are connected by fibres which run backwards in the olfactory tracts and decussate in the anterior commissure.

(*b*) The *olfactory tract* is a narrow white band, triangular on coronal section, the apex being directed upwards. It lies in the olfactory sulcus on the inferior surface of the frontal lobe, and divides posteriorly into two striæ, a medial and a lateral. The *lateral stria* is directed across the lateral part of the anterior perforated substance and then bends abruptly medialwards towards the uncus of the hippocampal gyrus. The *medial stria* turns medialwards behind the parolfactory area and ends in the subcallosal gyrus; in some cases a small *intermediate stria* is seen running backwards to the anterior perforated substance.

(*c*) The *olfactory trigone* is a small pyramidal area at the posterior end of the olfactory tract, and in front of the anterior perforated substance. Its apex, directed forwards, occupies the posterior part of the olfactory sulcus, and is brought into view by throwing back the olfactory tract.

CC-0. In Public Domain. Gurukul Kangri Collection, Haridwar

Digitized by Arya Samaj Foundation Chennai and eGangotri

(*d*) The *parolfactory area of Broca* is a small triangular field on the medial surface of the hemisphere in front of the subcallosal gyrus, from which it is separated by the posterior parolfactory sulcus; it is continuous below with the olfactory trigone, and above and in front with the cingulate gyrus; it is limited anteriorly by the *anterior parolfactory sulcus*.

(*e*) The *anterior perforated substance* is an irregularly quadrilateral area in front of the optic tract and behind the olfactory trigone, from which it is separated by the *fissura prima*; medially and in front it is continuous with the subcallosal gyrus; laterally it is bounded by the lateral stria of the olfactory tract and is continued into the uncus. Its grey substance is confluent above with that of the corpus striatum, and is perforated anteriorly by numerous small blood-vessels.

2. The **uncus** has already been described (p. 850) as the recurved, hook-like portion of the hippocampal gyrus.

3. The **subcallosal and supracallosal gyri** and the **fascia dentata hippocampi** form a rudimentary arch-shaped lamina of grey substance, extending over the corpus callosum and above the hippocampal gyrus, from the anterior perforated substance to the uncus.

(*a*) The *subcallosal gyrus* (peduncle of the corpus callosum) is a narrow lamina on the medial surface of the hemisphere, in front of the lamina terminalis, behind the parolfactory area, and below the rostrum of the corpus callosum. It is continuous above around the genu of the corpus callosum with the supracallosal gyrus; below, it may be traced along the side of the optic tract as a white band, the *diagonal band of Broca*, to the anterior end of the gyrus hippocampi.

(*b*) The *supracallosal gyrus* or *indusium griseum* consists of a thin layer of grey substance in contact with the upper surface of the corpus callosum and continuous laterally with the grey substance of the cingulate gyrus. It contains two longitudinally directed strands of fibres termed the *medial* and *lateral longitudinal striæ*. The supracallosal gyrus is prolonged round the splenium of the corpus callosum as a delicate lamina, the *fasciola cinerea*, which is continuous below with the fascia dentata hippocampi.

(*c*) The *fascia dentata hippocampi* (dentate gyrus) is a narrow band extending downwards and forwards above the hippocampal gyrus but separated from it by the hippocampal fissure; its free margin is notched, and is overlapped by the fimbria—the *fimbriodentate fissure* intervening. Anteriorly it is continued into the notch of the uncus, where it bends sharply and is then prolonged as a delicate band, the *band of Giacomini*, over the uncus, on the lateral surface of which it is lost.

The remaining parts of the rhinencephalon, viz. the septum pellucidum, the fornix, and the hippocampus, will be described in connexion with the lateral ventricle.

The Interior of the Cerebral Hemispheres

If the upper part of either hemisphere be removed, at a level about 1·25 cm. above the corpus callosum, the central white substance will be exposed as an oval-shaped area, the *centrum ovale minus*, surrounded by a narrow convoluted margin of grey substance, and studded with numerous minute red dots (*puncta vasculosa*) produced by the escape of blood from divided blood-vessels. If the remaining portions of the hemispheres be drawn slightly apart a broad band of white substance, the *corpus callosum*, will be observed, connecting them at the bottom of the longitudinal fissure; the margins of the hemispheres which overlap the corpus callosum are called the *labia cerebri*. Each labium is part of the cingulate gyrus already described (p. 850); and the slit-like interval between it and the upper surface of the corpus callosum is termed the *callosal fissure*. If the hemispheres be sliced off until level with the upper surface of the corpus callosum, the white substance of that structure will be seen connecting them.* The large expanse of medullary matter now exposed, surrounded by the convoluted margin of grey substance, is called the *centrum ovale majus*.

* A better view of the corpus callosum, and of the way in which its fibres pass into the hemisphere, is obtained by inserting the fingers into the callosal fissure and tearing off the cingulate gyrus in a lateral direction.

CC-0. In Public Domain. Gurukul Kangri Collection, Haridwar

Digitized by Arya Samaj Foundation Chennai and eGangotri

The **corpus callosum** (fig. 847) is the great transverse commissure which unites the cerebral hemispheres and roofs in the lateral ventricles. A good conception of its position and size is obtained by examining a median sagittal section of the brain (fig. 833), when it is seen to form an arched structure about 10 cm. long. Its anterior end is about 4 cm. from the frontal pole, and its posterior end about 6 cm. from the occipital pole, of the hemisphere.

The *anterior end* is named the *genu*, and is bent downwards and backwards in front of the septum pellucidum; diminishing rapidly in thickness, it is prolonged backwards, under the name of the *rostrum*, which is connected below

FIG. 847.—The corpus callosum. Exposed from above.

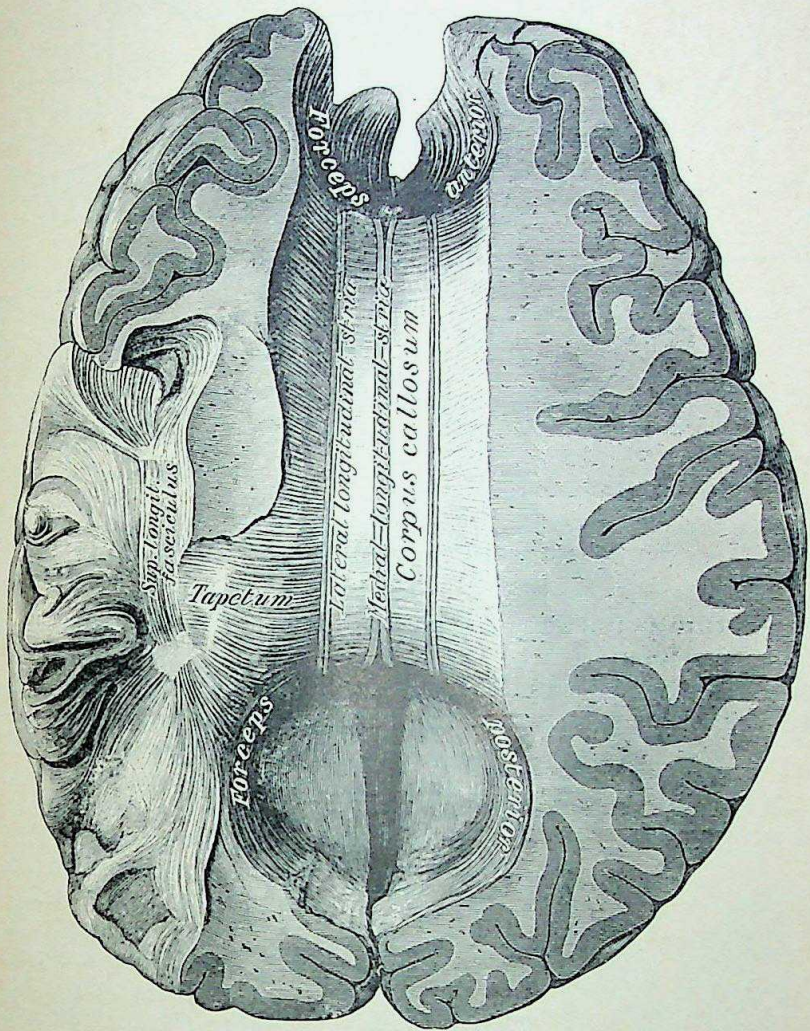

with the lamina terminalis. The anterior cerebral arteries are in contact with the under surface of the rostrum; they then arch over the front of the genu, and are carried backwards above the body of the corpus callosum.

The *posterior end* is named the *splenium*, and constitutes the thickest part of the corpus callosum. It overlaps the tela chorioidea of the third ventricle and the mesencephalon, and ends in a thick, convex free border. A sagittal section of the splenium shows that the posterior end of the corpus callosum is acutely bent forwards, the upper and lower parts being applied to each other.

The *superior surface* is convex from before backwards, and is about 2·5 cm. wide. Its median part forms the bottom of the longitudinal fissure, and is in contact posteriorly with the lower border of the falx cerebri. On either side the superior surface is overlapped by the cingulate gyrus, but is separated from it by the slit-like callosal fissure. It is traversed by numerous transverse ridges and furrows, and is covered by a thin layer of grey matter, the supracallosal gyrus, which exhibits on either side of the middle line the medial and lateral longitudinal striæ already described (p. 852).

CC-0. In Public Domain. Gurukul Kangri Collection, Haridwar

Digitized by Arya Samaj Foundation Chennai and eGangotri

The *inferior surface* is concave, and forms on either side of the middle line the roof of the lateral ventricle. The median part of the surface is attached in

FIG. 848.—A scheme showing the relations of the ventricles to the surface of the brain.

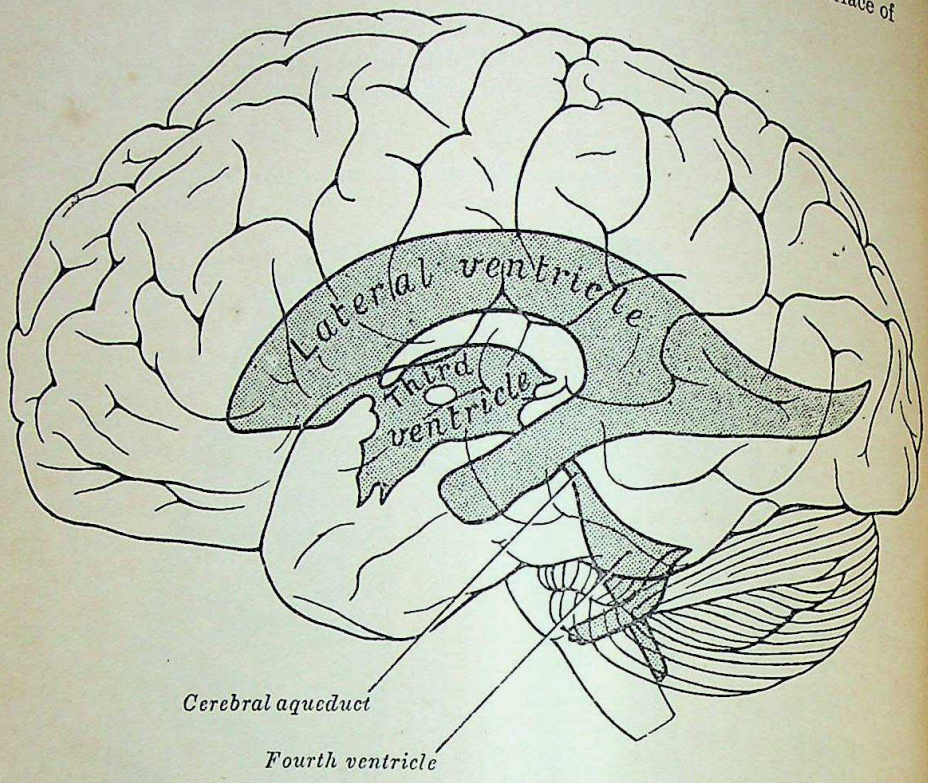

front to the septum pellucidum; behind this it is fused with the upper surface of the body of the fornix.

On either side, the fibres of the corpus callosum radiate in the white substance and pass to the various parts of the cerebral cortex; those curving forward from the genu into the frontal lobes constitute the *forceps anterior*, and those curving backwards from the splenium into the occipital lobes, the *forceps posterior*. Between these two parts is the *tapetum* constituting the main body of the fibres; these run laterally into the temporal and parietal lobes, and cover the central part of the lateral ventricle.

FIG. 849.—A drawing of a cast of the ventricular cavities. Superior aspect. (Retzius.)

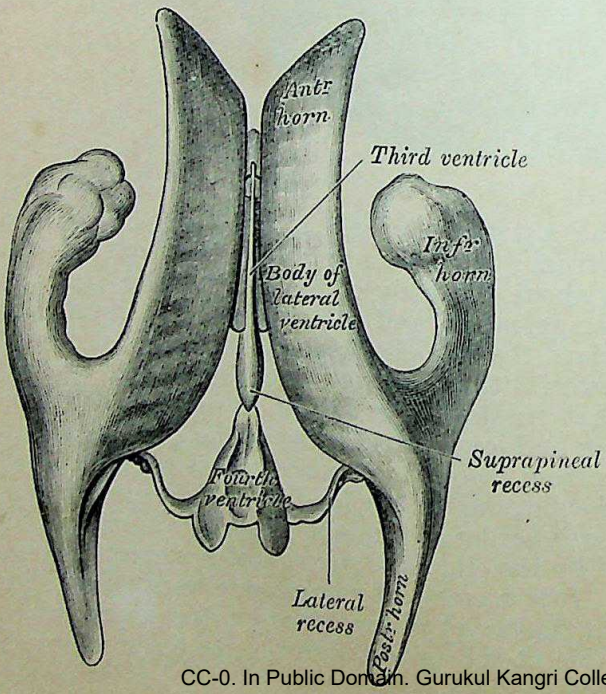

The **lateral ventricles** (fig. 848).—The two lateral ventricles are irregular cavities situated in the lower and medial parts of the cerebral hemispheres, one on either side of the middle line. They are separated from each other by a median vertical partition, the *septum pellucidum*, but communicate with the third ventricle and indirectly with each other through the *inter-ventricular foramen*. They are lined by a thin, diaphanous

CC-0. In Public Domain. Gurukul Kangri Collection, Haridwar

Digitized by Arya Samaj Foundation Chennai and eGangotri

FIG. 850.—A drawing of a cast of the ventricular cavities. Right lateral aspect. (Retzius.)

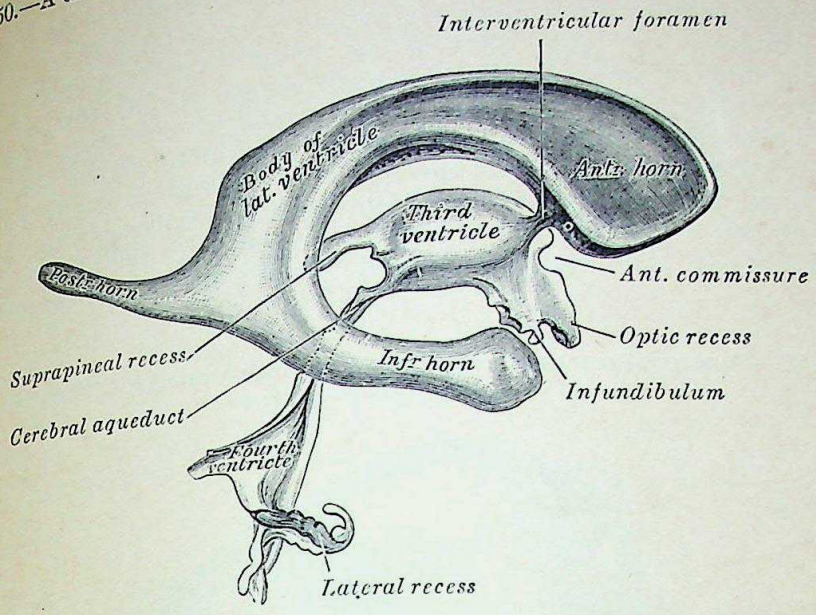

FIG. 851.—The central parts and the anterior and posterior cornua of the lateral ventricles. Exposed from above.

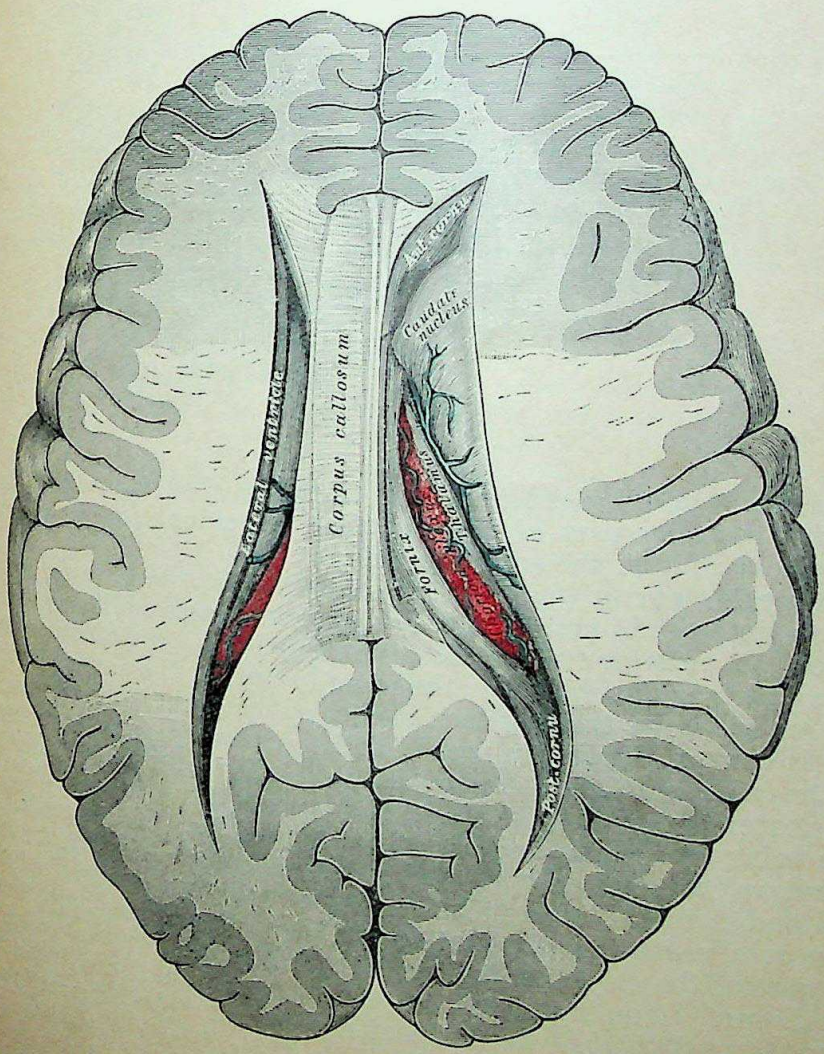

CC-0. In Public Domain. Gurukul Kangri Collection, Haridwar

Digitized by Arya Samaj Foundation Chennai and eGangotri

membrane, covered by ciliated epithelium and termed the *ependyma*, and they contain cerebrospinal fluid, which, even in health, may be secreted in considerable amount. Each lateral ventricle consists of a *central part* or *body*, and three *cornua*, an anterior, a posterior, and an inferior (figs. 849, 850).

The **central part** (fig. 851) of the lateral ventricle extends from the interventricular foramen to the splenium of the corpus callosum. It is an irregularly curved cavity, triangular on transverse section, with a roof, a floor, and a medial wall. The roof is formed by the under surface of the corpus callosum; the floor, directed upwards and medialwards, by the following parts, named in their order of position from before backwards: the caudate nucleus of the corpus striatum, the stria terminalis and the terminal vein (vein of corpus striatum), the lateral portion of the upper surface of the

FIG. 852.—A coronal section through the posterior cornu of the left lateral ventricle. Anterior aspect.

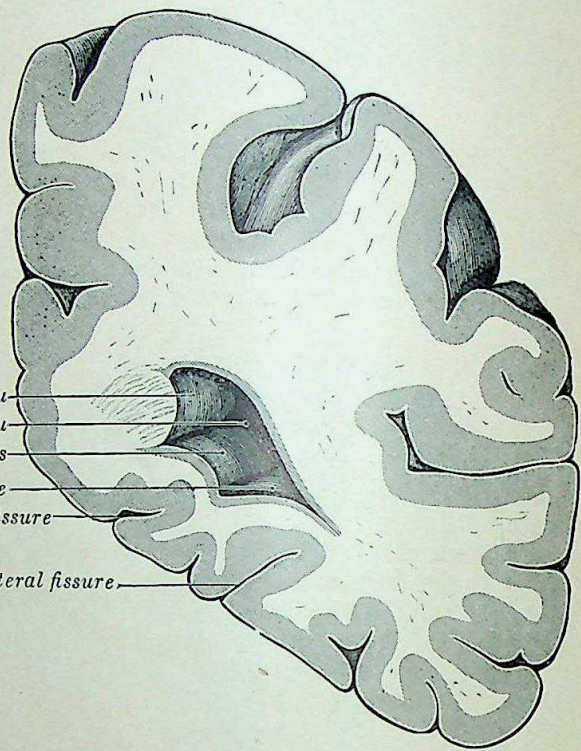

thalamus, the chorioid plexus, and the lateral part of the fornix; the medial wall is the posterior part of the septum pellucidum, which separates the ventricle from that of the opposite side.

The **anterior cornu** (fig. 851) passes forwards, lateralwards and slightly downwards, into the frontal lobe, curving round a large swelling which consists of the head or anterior end of the caudate nucleus. In a coronal section it appears as a triangular slit below the anterior part of the corpus callosum, and bounded anteriorly by the posterior surface of the genu of the corpus callosum. Its floor is convex, directed upwards and medialwards, and is formed by the head of the caudate nucleus. Its medial wall is the septum pellucidum (p. 864).

The **posterior cornu** (figs. 851, 852) passes into the occipital lobe, its direction being backwards and lateralwards, and then medialwards. Its roof and lateral wall are formed by the fibres of the corpus callosum passing to the temporal and occipital lobes. On its medial wall is a longitudinal eminence, the *calcar avis*, which is an involution of the ventricular wall produced by the anterior part of the calcarine fissure. Above this the forceps posterior of the corpus callosum, sweeping round to enter the occipital lobe, causes another projection, termed the *bulb* of the posterior cornu. The calcar avis and bulb of the posterior cornu are very variable in their degree of development; in some cases they are ill-defined, in others prominent.

CC-0. In Public Domain. Gurukul Kangri Collection, Haridwar

Digitized by Arya Samaj Foundation Chennai and eGangotri

The **inferior cornu** (fig. 853), the largest of the three, traverses the temporal lobe, forming in its course a curve round the posterior end of the thalamus. It passes at first backwards, lateralwards, and downwards, and then curves forwards to within 2·5 cm. of the apex of the temporal lobe, its position being fairly well indicated on the surface of the brain by the superior temporal sulcus. Its roof is formed chiefly by the inferior surface of the tapetum of the corpus callosum, but the tail of the caudate nucleus and the stria terminalis also extend forwards in the roof, at the extremity of which they end in a mass of grey substance, the *nucleus amygdalæ*. Its floor presents the following parts: the chorioid plexus, the fimbria hippocampi, the hippocampus and the collateral eminence. When the chorioid plexus is removed, a cleft-like opening is left along the medial wall of the inferior cornu; this cleft constitutes the lower part of the chorioidal fissure.

FIG. 853.—The posterior and inferior cornua of the left lateral ventricle. Exposed from the side.

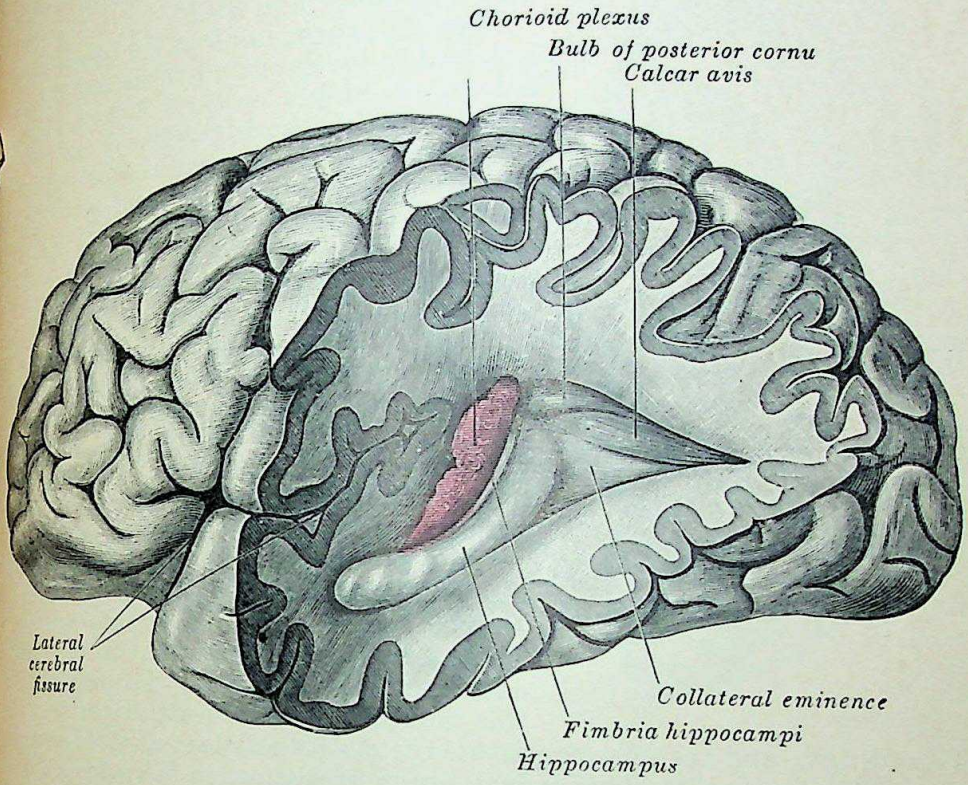

The chorioid plexus is described on p. 864, and the fimbria hippocampi on p. 863.

The **hippocampus** (figs. 853, 854) is a curved eminence, about 5 cm. long, which extends throughout the entire length of the floor of the inferior cornu. Its lower end is enlarged, and presents two or three rounded elevations or digitations, which give it a paw-like appearance, and hence it is named the *pes hippocampi*. It is separated from the hippocampal gyrus by a shallow groove, the hippocampal fissure. The main mass of the hippocampus consists of grey substance; but on its ventricular surface is a thin white layer, the *alveus*, which is continuous with the fimbria hippocampi.

The **collateral eminence** (fig. 854) is an elongated swelling lying lateral to and parallel with the hippocampus. It corresponds with the middle part of the collateral fissure, and its size depends on the depth and direction of this fissure. It is continuous behind with a flattened triangular area, the *trigonum collaterale*, situated between the posterior and inferior cornua.

The **corpus striatum** has received its name from the striped appearance which a section of its anterior part presents, in consequence of diverging white fibres being mixed with the grey substance which forms its chief mass. A part of the corpus striatum is imbedded in the white substance of the cerebral hemisphere, and is therefore external to the ventricle; it is termed the

CC-0. In Public Domain. Gurukul Kangri Collection, Haridwar

Digitized by Arya Samaj Foundation Chennai and eGangotri

extraventricular portion, or the *lentiform nucleus*; the remainder, however, projects into the ventricle, and is named the *intraventricular portion*, or the *caudate nucleus* (fig. 855).

The **caudate nucleus** (fig. 851) is a pear-shaped, highly arched grey mass; its broad extremity, or *head*, is directed forwards into the anterior cornu of the lateral ventricle, and is continuous with the anterior perforated substance and with the anterior end of the lentiform nucleus; its narrow end, or *tail*, is directed backwards on the lateral side of the thalamus, from which it is separated by the stria terminalis and the terminal vein; it is then continued downwards into the roof of the inferior cornu, and ends in the *nucleus amygdalæ*. It is covered by the ependyma of the lateral ventricle, and crossed by some veins of considerable size. It is separated from the lentiform nucleus, in the greater part of its extent, by a thick lamina of white substance, called the *internal capsule*, but the two nuclei are united in front (figs. 856, 857).

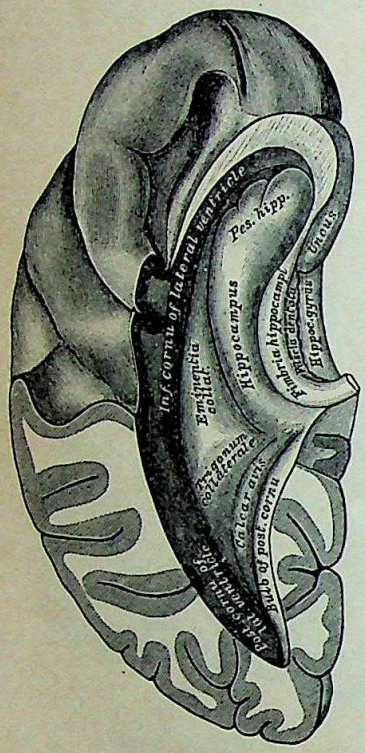

FIG. 854.—The posterior and inferior cornua of the left lateral ventricle. Exposed from above.

The **lentiform nucleus** (lenticular nucleus) is lateral to the caudate nucleus and thalamus, and is seen only in sections of the hemispheres. When divided horizontally, it exhibits, to some extent, the appearance of a biconvex lens (fig. 855), while a coronal section of its central part presents a somewhat triangular outline. It is shorter than the caudate nucleus and does not extend as far forwards. It is bounded medially by the internal capsule, and laterally by a lamina of white substance called the *external capsule*; lateral to this is a thin layer of grey substance termed the *claustrum*, which separates it from the insula. Its anterior end is continuous with the lower part of the head of the caudate nucleus and with the anterior perforated substance.

In a coronal section through the middle of the lentiform nucleus (fig. 857) two *medullary laminæ* are seen dividing it into three parts. The lateral and largest part is of a reddish colour, and is known as the *putamen*, while the medial and intermediate parts are of a yellowish tint, and together constitute the *globus pallidus*; all three are marked by fine radiating white fibres, which are most distinct in the putamen.

The grey substance of the corpus striatum is traversed by nerve-fibres, some of which originate in it. The cells are multipolar, both large and small; those of the lentiform nucleus contain yellow pigment. The caudate and lentiform nuclei are not only directly continuous with each other anteriorly, but are connected to each other by numerous fibres. The corpus striatum is also connected: (1) to the cerebral cortex, by the *corticostriate* fibres; (2) to the thalamus, by fibres which pass through the internal capsule, and by a strand named the *ansa lentiformis* (p. 860); (3) to the cerebral peduncle, by fibres which leave the lower parts of the caudate and lentiform nuclei.

The **claustrum** (figs. 855, 857) is a thin layer of grey substance, situated on the lateral surface of the external capsule. In a coronal section it is seen to be triangular in shape, with the apex directed upwards. Its medial surface, contiguous to the external capsule, is smooth, but its lateral surface presents ridges and furrows corresponding with the gyri and sulci of the insula, with which it is in close relationship. The claustrum is regarded by some as a detached portion of the grey substance of the insula, from which it is separated by a layer of white fibres, the *capsula extrema*. Its cells are small and spindle-shaped and contain yellow pigment; they are similar to those of the deepest layer of the cortex.*

* E. Landau (*Journal of Anatomy*, vol. liii.) is of opinion that the claustrum is an independent formation which is neither split off from the cortex of the insula nor from the corpus striatum.

CC-0. In Public Domain. Gurukul Kangri Collection, Haridwar

Digitized by Arya Samaj Foundation Chennai and eGangotri

The nucleus amygdalæ is an ovoid grey mass, situated above and in front of the lower end of the inferior cornu. It is merely a localised thickening of the grey cortex, confluent with that of the uncus; above, it is continuous with the putamen; behind, with the tail of the caudate nucleus.

The caudate, lentiform and amygdaloid nuclei are sometimes grouped under the term *basal ganglia*.

The internal capsule (figs. 855. 857) is a flattened band of white fibres, between the lentiform nucleus on the lateral side and the caudate nucleus and

Fig. 855.—A horizontal section through the right cerebral hemisphere. Superior aspect.

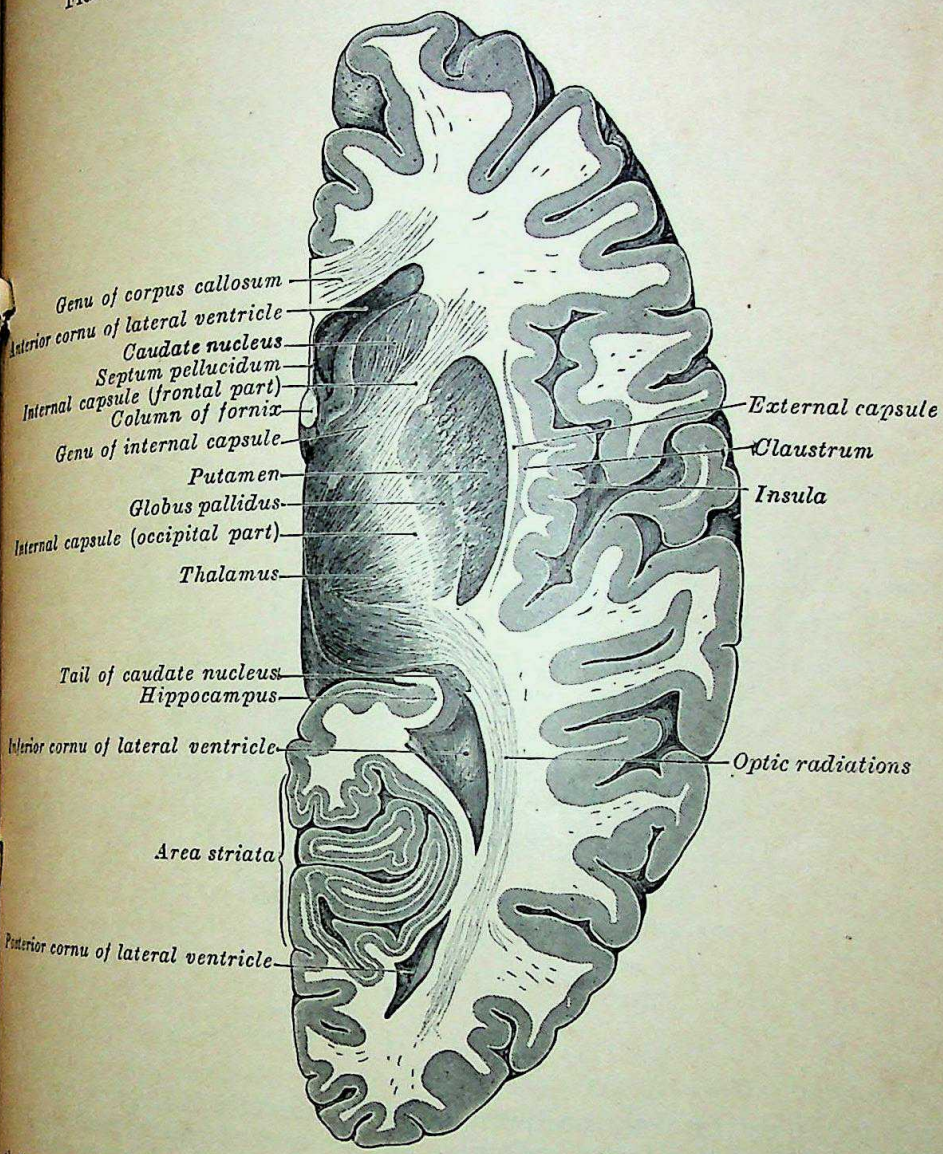

thalamus on the medial side. In horizontal section (fig. 855), it is seen to be somewhat abruptly curved, with its convexity directed medialwards; the prominence of the curve, the *genu*, projects between the caudate nucleus and the thalamus. The portion in front of the genu, separating the lentiform and caudate nuclei, is termed the frontal part; the portion behind the genu, separating the lentiform nucleus from the thalamus, is the occipital part.

The *frontal part* (anterior limb) of the internal capsule contains: (1) fibres running from the thalamus, as its anterior stalk, to the frontal lobe; (2) fibres joining the lentiform and caudate nuclei; (3) fibres connecting the cortex with the corpus striatum; and (4) fibres (frontopontine tract) passing from the frontal lobe through the medial one-fifth of the base of the cerebral peduncle to the nuclei pontis. The fibres in the region of the genu are named the *geniculate fibres*; they originate in the motor part of the cerebral cortex,

CC-0. In Public Domain. Gurukul Kangri Collection, Haridwar

Digitized by Arya Samaj Foundation Chennai and eGangotri

and, after passing downwards through the base of the cerebral peduncle with the cerebrospinal fibres, undergo decussation and end in the motor nuclei of the cerebral nerves of the opposite side. The anterior two-thirds of the occipital part of the internal capsule contains the *cerebrospinal fibres*, which arise in the motor area of the cerebral cortex, and passing downwards through the middle three-fifths of the base of the cerebral peduncle, are continued into the pyramids of the medulla oblongata. The posterior one-third of the occipital part (posterior limb) contains: (1) sensory fibres, largely derived from the thalamus, though some may be continued upwards from the medial lemniscus; (2) the fibres of the optic radiations, from the lateral geniculate body and

FIG. 856.—A coronal section through the anterior cornua of the lateral ventricles. Anterior aspect.

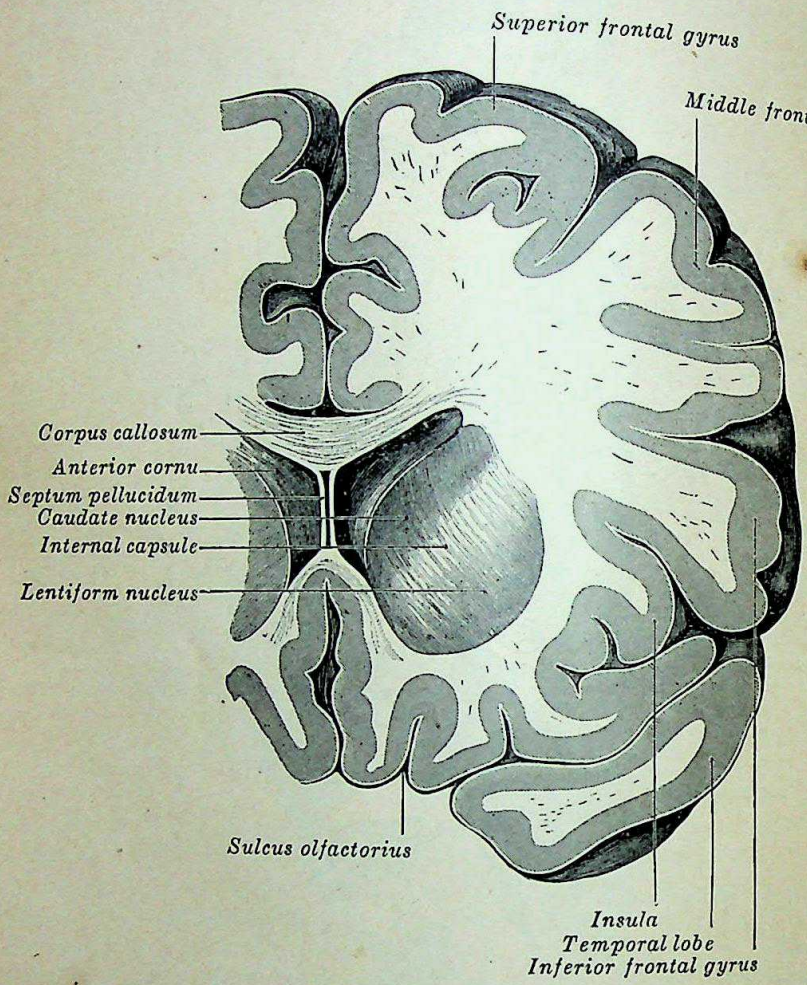

pulvinar to the cortex of the occipital lobe; (3) acoustic fibres, from the medial geniculate body and inferior colliculus to the gyri of Heschl in the temporal lobe; (4) fibres which pass from the occipital and temporal lobes to the nuclei pontis; and (5) fibres from the occipital cortex to the superior colliculus.

The fibres of the internal capsule radiate widely as they pass to and from the various parts of the cerebral cortex, forming the *corona radiata* (fig. 858) and intermingling with the fibres of the corpus callosum.

The **external capsule** (fig. 855) is a lamina of white substance, situated lateral to the lentiform nucleus, between it and the claustrum, and continuous with the internal capsule, below and behind the lentiform nucleus. It probably contains fibres derived from the thalamus, the anterior commissure, and the subthalamic region.

The **substantia innominata of Meynert** is a stratum consisting of grey and white substance, which lies below the anterior parts of the thalamus and lentiform nucleus. It consists of three layers, superior, middle, and inferior. The *superior layer* is ranked the *ansa lentiformis*, and its fibres, derived from

CC-0. In Public Domain. Gurukul Kangri Collection, Haridwar

Digitized by Arya Samaj Foundation Chennai and eGangotri

the medullary laminæ of the lentiform nucleus, pass medially to end in the thalamus and subthalamic region, while others are said to end in the tegmentum and red nucleus. The *middle* layer consists of nerve-cells and nerve-fibres: fibres enter it from the parietal lobe through the external capsule, while others are said to connect it with the medial longitudinal fasciculus. The *inferior* layer forms the main part of the inferior stalk of the thalamus, and connects this body with the temporal lobe and the insula.

The **stria terminalis** (tænia semicircularis) is a narrow band of white substance situated in the floor of the lateral ventricle between the caudate nucleus and the thalamus. Anteriorly, its fibres are partly continued into

FIG. 857.—A coronal section through the brain, passing through the anterior commissure. Anterior aspect.

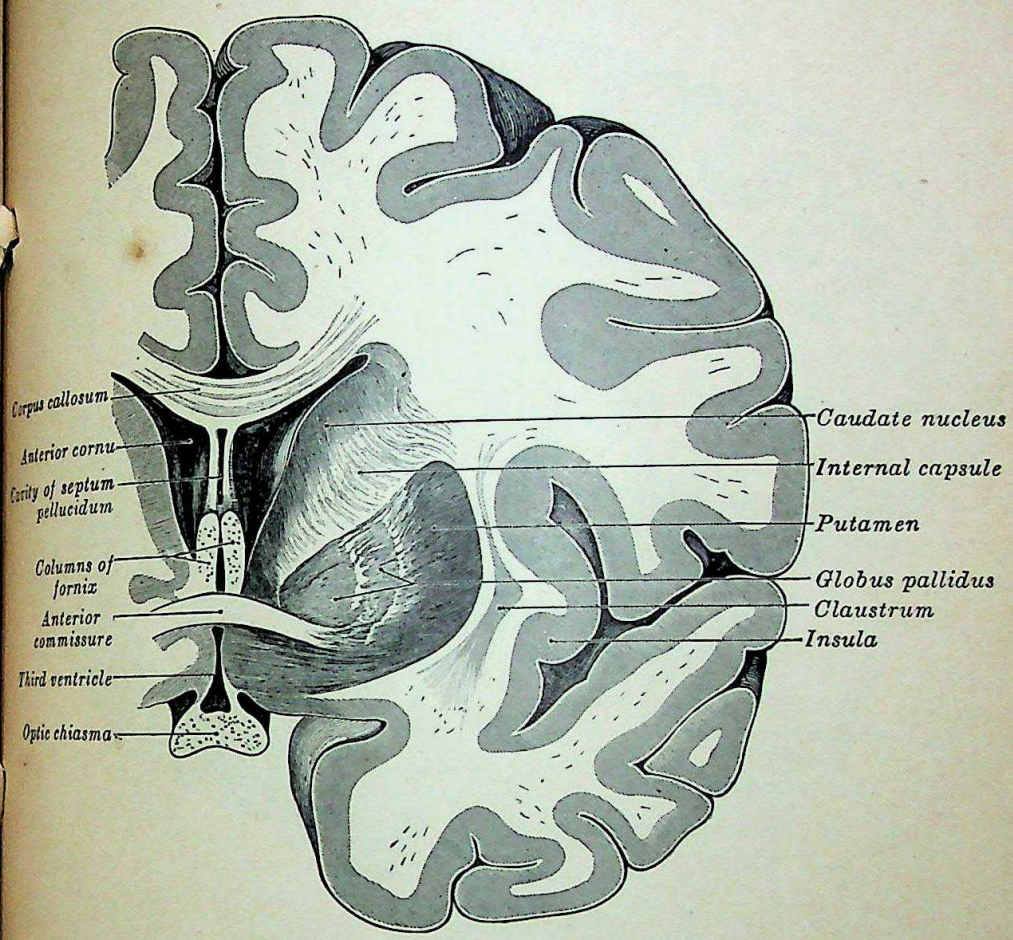

the column of the fornix; some cross in the anterior commissure to the temporal lobe of the opposite side; others are said to enter the caudate nucleus. Posteriorly, it is continued into the roof of the inferior cornu of the lateral ventricle, at the extremity of which it enters the nucleus amygdalæ. Superficial to it is the terminal vein (vein of the corpus striatum), which receives numerous tributaries from the corpus striatum and thalamus; it runs forwards to the interventricular foramen and there joins with the vein of the chorioid plexus to form the corresponding internal cerebral vein. On the surface of the terminal vein is a narrow white band, named the *lamina affixa*.

The fornix (figs. 833, 859) is a longitudinal, arch-shaped lamella of white substance, situated below the corpus callosum, and attached to its inferior surface behind, but separated from it in front by the septum pellucidum. It may be described as consisting of two symmetrical bands, one for either hemisphere. The two bands are not united to each other in front and behind, but their central parts are joined together in the middle line. The anterior parts are called the columns of the fornix; the intermediate united portions, the body; and the posterior parts, the crura.

CC-0. In Public Domain. Gurukul Kangri Collection, Haridwar

Digitized by Arya Samaj Foundation Chennai and eGangotri

The *body* of the fornix is triangular, narrow in front, and broad behind. The medial part of its upper surface is connected to the septum pellucidum in front and to the corpus callosum behind. The lateral portion of this surface forms part of the floor of the lateral ventricle, and is covered by the ventricular epithelium. Its thin lateral edge overlaps the chorioid plexus, and is continuous with the epithelial covering of the plexus. The under surface rests upon the tela chorioidea of the third ventricle (velum interpositum), which separates it from the epithelial roof of the third ventricle, and from the medial portions of the upper surfaces of the thalami. The lateral portions of the body of the fornix are joined inferiorly by a thin triangular lamina named the *psalterium or lyra*. This lamina contains some transverse fibres

FIG. 858.—A dissection showing the course of the cerebrospinal fibres. (E. B. Jamieson.)

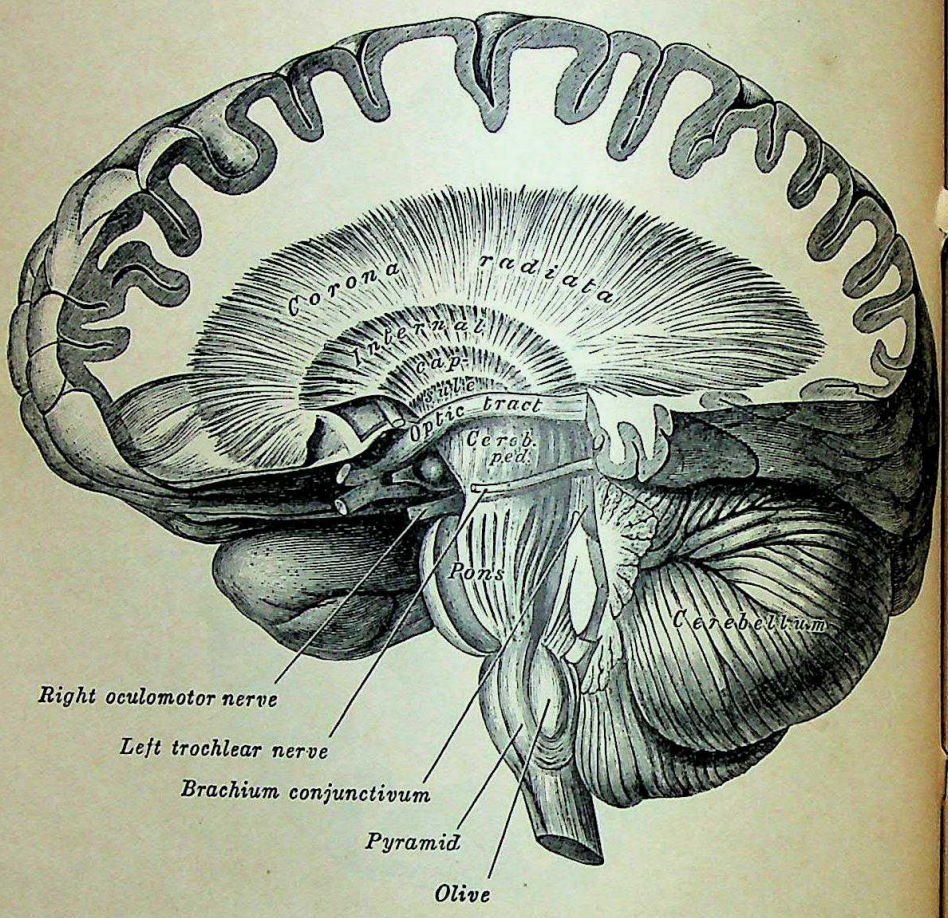

which connect the two hippocampi across the middle line and constitute the *hippocampal commissure*. Between the psalterium and the corpus callosum a horizontal cleft, the so-called *ventricle of the fornix or ventricle of Verga*, is sometimes found.

The *columns* (anterior pillars) of the fornix arch downwards in front of the thalamus and behind the anterior commissure, and form the anterior boundary of the interventricular foramen; each descends through the grey substance in the lateral wall of the third ventricle to the base of the brain, where it ends mainly in the corpus mamillare. From the cells of the corpus mamillare the *mamillothalamic fasciculus* (bundle of Vicq d'Azyr) takes origin and is prolonged into the anterior nucleus of the thalamus. The column of the fornix and the mamillothalamic fasciculus together form a loop resembling the figure 8, but the continuity of the loop is broken in the corpus mamillare. The column of the fornix is joined by the stria medullaris of the pineal body and by the superficial fibres of the stria terminalis; it is said also to receive fibres from the septum pellucidum. Zuckerkandl describes an *olfactory fasciculus* which becomes detached from the anterior portion of the column of the fornix.

CC-0. In Public Domain. Gurukul Kangri Collection, Haridwar

Digitized by Arya Samaj Foundation Chennai and eGangotri

The chorioid plexus consists of minute and highly vascular villous processes, each with an afferent and an efferent vessel. The *arteries* of the plexus are: (*a*) the anterior chorioidal, a branch of the internal carotid artery, which enters the plexus at the end of the inferior cornu; and (*b*) the posterior chorioidal, one or two small branches of the posterior cerebral artery, which pass forwards under the splenium. The *veins* of the plexus unite to form a single tortuous vessel, which courses from behind forwards to the interventricular foramen and there joins with the terminal vein (p. 717) to form the corresponding internal cerebral vein.

FIG. 861.—The tela chorioidea of the third ventricle, and the chorioid plexus of the left lateral ventricle. Exposed from above.

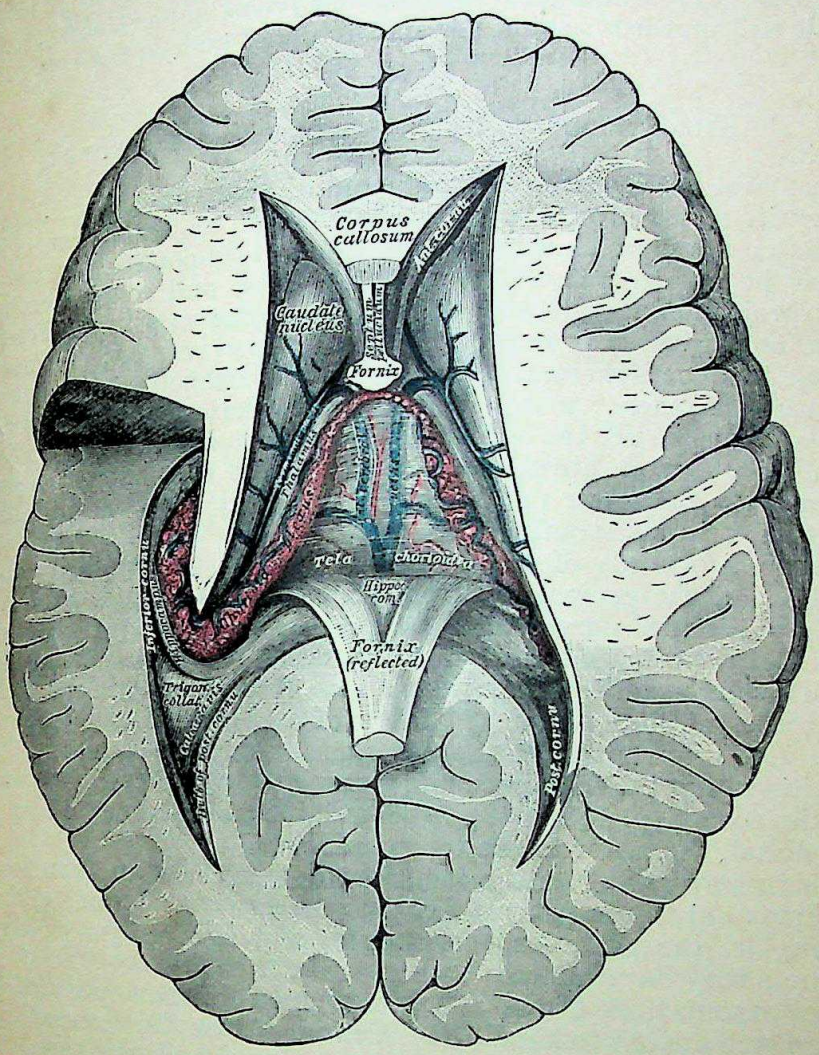

When the chorioid plexus is pulled away, the continuity between its epithelial covering and the epithelial lining of the ventricle is severed, and a cleft-like space is produced. This is named the *chorioidal fissure*; like the plexus, it extends from the interventricular foramen to the end of the inferior cornu. The upper part of the fissure, i.e. the part nearest the interventricular foramen, is situated between the lateral edge of the fornix and the upper surface of the thalamus; farther back, at the beginning of the inferior cornu, it is between the commencement of the fimbria hippocampi and the posterior end of the thalamus, while in the inferior cornu it lies between the fimbria in the floor and the stria terminalis in the roof of the cornu.

The **tela chorioidea of the third ventricle** (velum interpositum) (fig. 861) is a double fold of pia mater, triangular in shape, which lies beneath the fornix. The lateral portions of its lower surface rest upon the thalami, while the medial portion of this surface is in contact with the epithelial roof

CC-0. In Public Domain. Gurukul Kangri Collection, Haridwar

Digitized by Arya Samaj Foundation Chennai and eGangotri

of the third ventricle. Its apex is situated at the interventricular foramen; its base occupies the interval between the splenium of the corpus callosum above and the corpora quadrigemina and pineal body below. This interval, together with the lower portions of the chorioidal fissures, is sometimes spoken of as the *transverse fissure* of the brain. The two layers of the tela separate from each other at the base, and are continuous with the pia mater investing the brain in this region. Its lateral margins are modified to form the highly vascular chorioid plexuses of the lateral ventricles. It is supplied by the anterior and posterior chorioidal arteries already described. The veins of the tela chorioidea are named the internal cerebral veins (venæ Galeni); they are two in number, and run backwards between its layers, each being formed at the interventricular foramen by the union of the terminal vein with the chorioidal vein. Beneath the splenium of the corpus callosum the internal cerebral veins unite to form the great cerebral vein (vena magna Galeni), which curves backwards and upwards behind the splenium and ends in the straight sinus.

The Structure of the Cerebral Hemispheres

The cerebral hemispheres are composed of white and grey substance.

The **white substance** occupies the interior of the hemispheres; it consists of medullated fibres which vary in size, and are supported by neuroglia. The fibres may be divided, according to their course and connexions, into three systems: projection fibres connecting the hemispheres with the lower parts of the brain and with the medulla spinalis; transverse or commissural fibres uniting the two hemispheres; association fibres connecting different structures in the same hemisphere; many of the last are collateral branches of the projection fibres, but some are the axons of independent cells.

1. The **projection fibres** consist of efferent and afferent fibres uniting the cortex with the lower parts of the brain and with the medulla spinalis. The principal efferent strands are: (1) the motor tract, occupying the genu and anterior two-thirds of the occipital part of the internal capsule, and consisting of (*a*) the geniculate fibres, which decussate and end in the motor nuclei of the cerebral nerves of the opposite side; and (*b*) the cerebrospinal fibres, which are prolonged through the pyramid of the medulla oblongata into the medulla spinalis; (2) the corticopontine fibres, ending in the nuclei pontis. The chief afferent fibres are: (1) those of the brachia conjunctiva cerebelli which are not interrupted in the red nucleus and thalamus; (2) numerous fibres arising within the thalamus, and passing through its stalks to the different parts of the cortex (p. 835); (3) optic and acoustic fibres, the former passing to the occipital, the latter to the temporal lobe.

2. The **transverse or commissural fibres** connect the two hemispheres. They include: (*a*) the transverse fibres of the corpus callosum, (*b*) the anterior commissure, (*c*) the posterior commissure, and (*d*) the lyra or hippocampal commissure; they have already been described.

3. The **association fibres** (fig. 862) unite different parts of the same hemisphere, and are of two kinds: (1) *short association fibres* connecting adjacent gyri; (2) *long association fibres* passing between more distant parts.

The *short association fibres* lie immediately beneath the grey substance of the cortex of the hemispheres, and connect adjacent gyri.

The *long association fibres* include the following: (*a*) the uncinate fasciculus; (*b*) the cingulum; (*c*) the superior longitudinal fasciculus; (*d*) the inferior longitudinal fasciculus; (*e*) the perpendicular fasciculus; (*f*) the occipito-frontal fasciculus; and (*g*) the fornix.

(*a*) The *uncinate fasciculus* passes across the bottom of the lateral cerebral fissure, and unites the gyri of the frontal lobe with the anterior end of the temporal lobe.

(*b*) The *cingulum* is contained within the cingulate gyrus. Beginning in front at the anterior perforated substance, it passes forwards and upwards parallel with the rostrum and genu, runs backwards above the body of the corpus callosum, turns round the splenium, and ends in the hippocampal gyrus.

(*c*) The *superior longitudinal fasciculus* passes backwards from the frontal lobe above the lentiform nucleus and insula; some of its fibres end in the

CC-0. In Public Domain. Gurukul Kangri Collection, Haridwar

Digitized by Arya Samaj Foundation Chennai and eGangotri

ipital lobe, and others curve downwards and forwards into the temporal be.

(*d*) The *inferior longitudinal fasciculus* connects the temporal and occipital bes, running along the lateral walls of the inferior and posterior cornua of e lateral ventricle.

(*e*) The *perpendicular fasciculus* runs vertically through the front part of e occipital lobe, and connects the inferior parietal lobule with the fusiform rus.

(*f*) The *occipitofrontal fasciculus* passes backwards from the frontal lobe, ng the lateral border of the caudate nucleus, and on the medial aspect the corona radiata; its fibres radiate in a fan-like manner and pass into e occipital and temporal lobes, lateral to the posterior and inferior cornua. Dejerine regards the fibres of the tapetum as being derived from this fasciculus, nd not from the corpus callosum.

Fig. 862.—A diagram showing the principal systems of association fibres in the cerebrum.

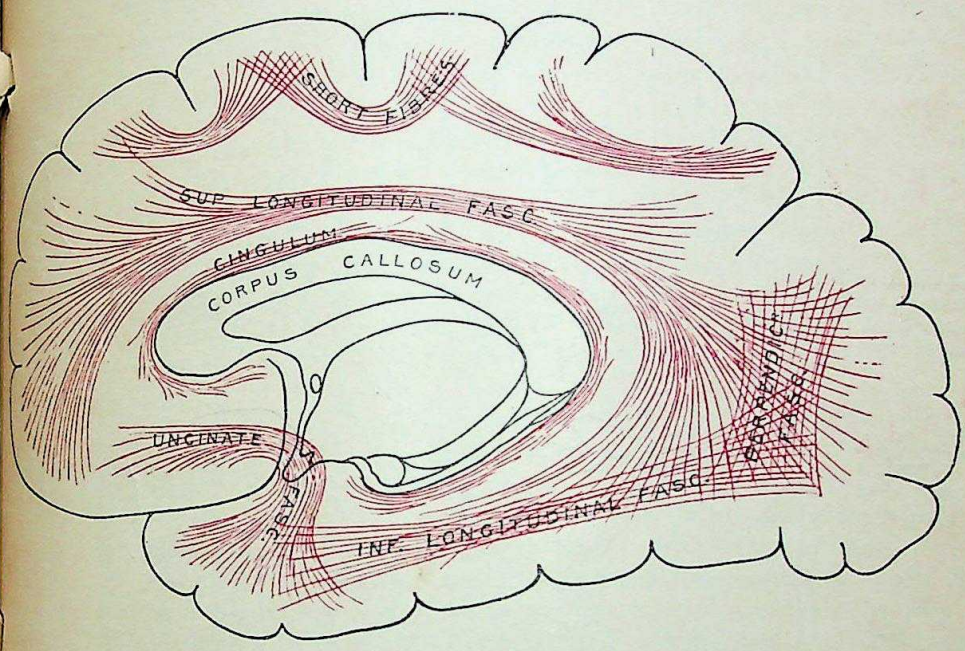

(*g*) The *fornix* connects the hippocampal gyrus with the corpus mamillare, nd, by means of the mamillothalamic fasciculus, with the thalamus (p. 838). Through the fibres of the hippocampal commissure it probably also unites the right and left hippocampal gyri.

The **grey substance of the hemisphere** is divided into: (1) that of the erebral cortex which covers the surfaces of the hemispheres, and (2) that of the caudate nucleus, the lentiform nucleus, the claustrum, and the nucleus amygdalæ.

The Structure of the Cerebral Cortex (fig. 863)

The cerebral cortex differs in thickness and structure in different parts of the hemisphere. It is thinner in the occipital region than in the anterior and posterior central gyri, and it is also much thinner in the depths of the ulci than on the summits of the gyri.

The cortex is made up of nerve-cells of varying size and shape, and of erve-fibres which are either medullated or naked axis-cylinders, imbedded in a matrix of neuroglia. According to J. S. Bolton, it exhibits five layers:

1. The outer fibre-lamina (molecular or plexiform layer).
2. The outer cell-lamina.
3. The middle cell-lamina (layer of granules and outer band of Baillarger).
4. The inner fibre-lamina (inner band of Baillarger).
5. The inner cell-lamina (polymorphous layer).

CC-0. In Public Domain. Gurukul Kangri Collection, Haridwar

Digitized by Arya Samaj Foundation Chennai and eGangotri

1. The **outer fibre-lamina.**—The superficial part of this layer consis of a stratum of medullated nerve-fibres (plexus of Exner), running paral with the surface. The deeper part is largely composed of the dendrites of cells from the subjacent laminæ. It contains also a few nerve-cells, and th

FIG. 863.—A diagram showing the layers of cells and fibres in the grey substance of the cortex of the human cerebral hemisphere, according to the histo-logical methods of Golgi, Nissl and Weigert. After Brodmann; from Luciani's Physiology (Macmillan & Co., Ltd.).

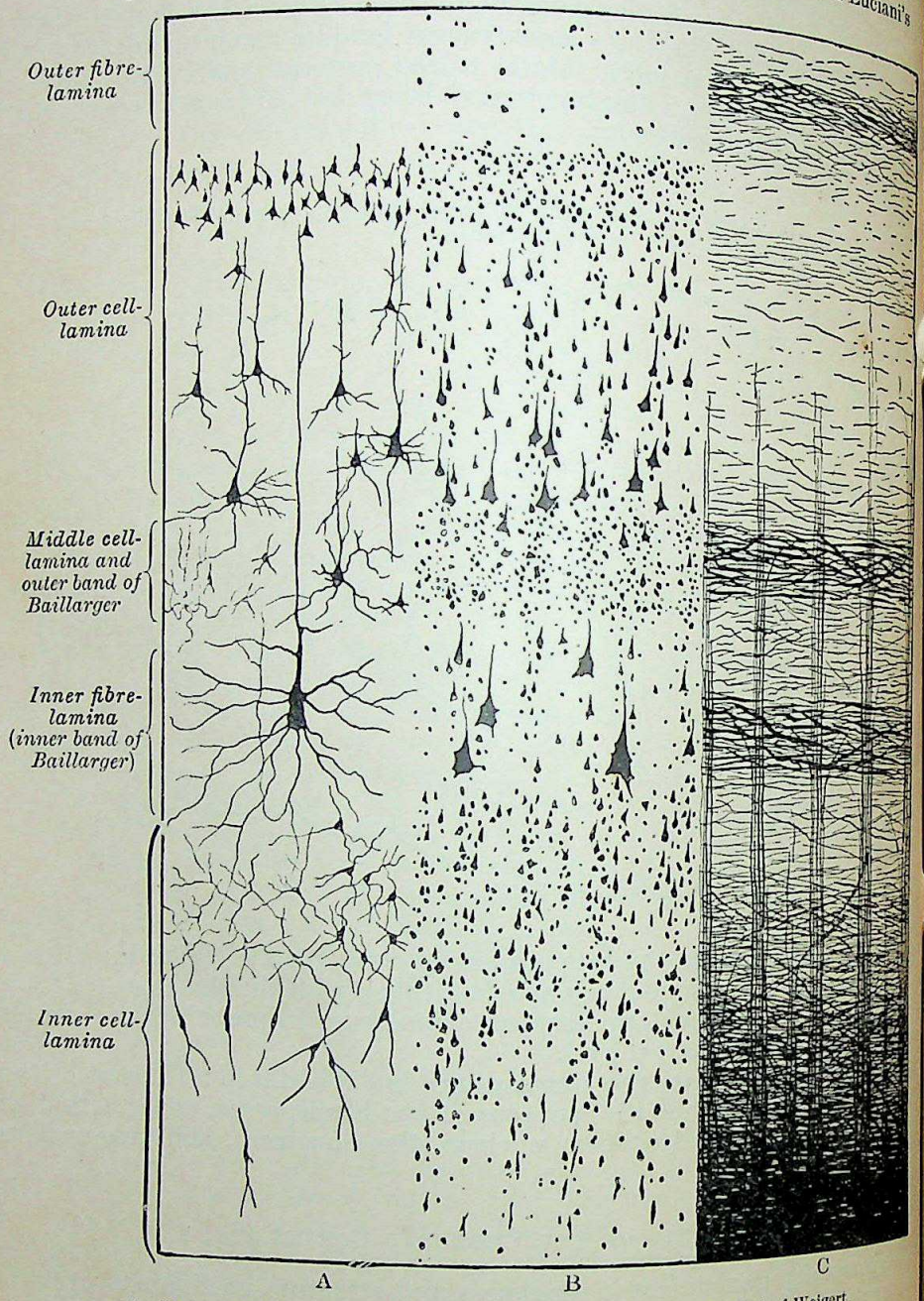

A. Stained by the method of Golgi; B. by that of Nissl; C. by that of Weigert.

terminations of fibres which run into the cortex from the white substanc of the hemisphere. The cells are of two kinds: (1) small irregular cells wit a varying number of dendrites and short axons; (2) fusiform cells with their long axes parallel with the surface; the dendrites and the axons of the latte run horizontally, and the axons give off numerous collaterals. The distributio of the axons of both types of cell is limited to the outer fibre-lamina.

2. The **outer cell-lamina** contains many pyramidal nerve-cells; these ar small (10μ to 15μ long) in the superficial, but large (20μ to 30μ) in the deep part of the lamina. Each pyramidal cell contains granular pigment and

CC-0. In Public Domain. Gurukul Kangri Collection, Haridwar

Digitized by Arya Samaj Foundation Chennai and eGangotri

large round or oval nucleus, and the apex of the cell is directed towards the surface. The axon arises from the base of the cell, and runs into the central white substance, giving off collaterals in its course, and being distributed as a projection, association, or commissural fibre. The apical and basal parts of the cell give off dendrites; the apical dendrite ends in the outer fibre-lamina by dividing into numerous branches, all of which may be seen, when stained by the silver or methylene blue method, to be studded with bristle-like processes.

3. The **middle cell-lamina** or layer of granules consists chiefly of small stellate cells, but some pyramidal cells are also present in its deepest part. The axons of the stellate cells run a short course, and terminate either in the middle or outer cell-lamina. The axons of some of the pyramidal cells descend for a short distance and then turn back and end in the outer cell-lamina; the axons of others run into the central white substance. In this lamina a well-marked stratum of nerve-fibres (*outer band of Baillarger*) runs parallel with the cortex.

In the visuosensory area of the occipital lobe (p. 871) the middle cell-lamina consists of two layers, separated by the outer band of Baillarger, which is here named the *band of Gennari*.

4. The **inner fibre-lamina** is composed of medullated nerve-fibres running parallel with the surface, and forming the *inner band of Baillarger*. In the anterior central gyrus and in the paracentral lobule it contains large pyramidal cells, the *giant-cells of Betz*, which are often solitary, but may occur in groups of three to five. These cells may be 50μ long and 40μ broad; in the paracentral lobule they attain a length of 65μ.

5. The **inner cell-lamina** or polymorphous layer contains cells of various shapes—fusiform, oval, triangular, or stellate. Their dendrites are directed outwards, but do not reach the molecular layer; most of their axons pass into the subjacent white substance. The axons of a few of these cells (cells of Golgi's second type) are short, and terminate in the adjacent grey substance. The *cells of Martinotti* in the inner cell-lamina are pyramidal in shape with their bases directed towards the surface; their dendrites are short, and their axons pass out into the outer fibre-lamina, where they form an extensive horizontal arborisation.

In addition to the bands of medullated fibres described above as running parallel with the surface (*tangential fibres*), there are many deep tangential fibres in the lower part of the inner cell-lamina. The tangential fibres consist of (*a*) the collaterals of the axons of the pyramidal and polymorphous cells, and of the cells of Martinotti; (*b*) the branching axons of Golgi's cells; (*c*) the collaterals and terminal arborisations of the projection, commissural, and association fibres. *Radial fibres* also occur in the cortex and consist of, (*a*) the axons of the pyramidal and polymorphous cells descending into the white substance, and (*b*) the terminations of projection, commissural, or association fibres, ascending to end in the cortex. The axons of the cells of Martinotti are also ascending fibres.

The development of the laminæ of the cortex. The inner cell-lamina is the first to appear in the course of development, and in the sixth month of fœtal life it has attained three-fourths of its adult depth. The inner fibre-lamina is associated with the inner cell-lamina, and although it does not appear until the sixth month of fœtal life, it reaches its full depth very quickly. The middle cell-lamina can be distinguished in the sixth month of fœtal life; at this period it is one-half, and at birth three-fourths of the depth which it finally attains. The outer cell-lamina is the last to develop, both ontogenetically and phylogenetically, and its depth varies with the intellectual capacity of the individual. The outer fibre-lamina is well developed at birth, and its further growth is associated with that of the outer cell-lamina.

SPECIAL TYPES OF CEREBRAL CORTEX

The histological investigations of Bevan Lewis, Bolton, Campbell, and Brodmann, the embryological researches of Flechsig, and the experimental work of Sherrington and many others, have shown that the cortex of the

CC-0. In Public Domain. Gurukul Kangri Collection, Haridwar

Digitized by Arya Samaj Foundation Chennai and eGangotri

cerebral hemispheres can be mapped out into areas which possess different functions, and that the minute structure of the cortex varies characteristically in these different areas. The anterior central gyrus (motor area), the convolutions

FIG. 864.—The areas of localisation on the lateral surface of the left cerebral hemisphere.

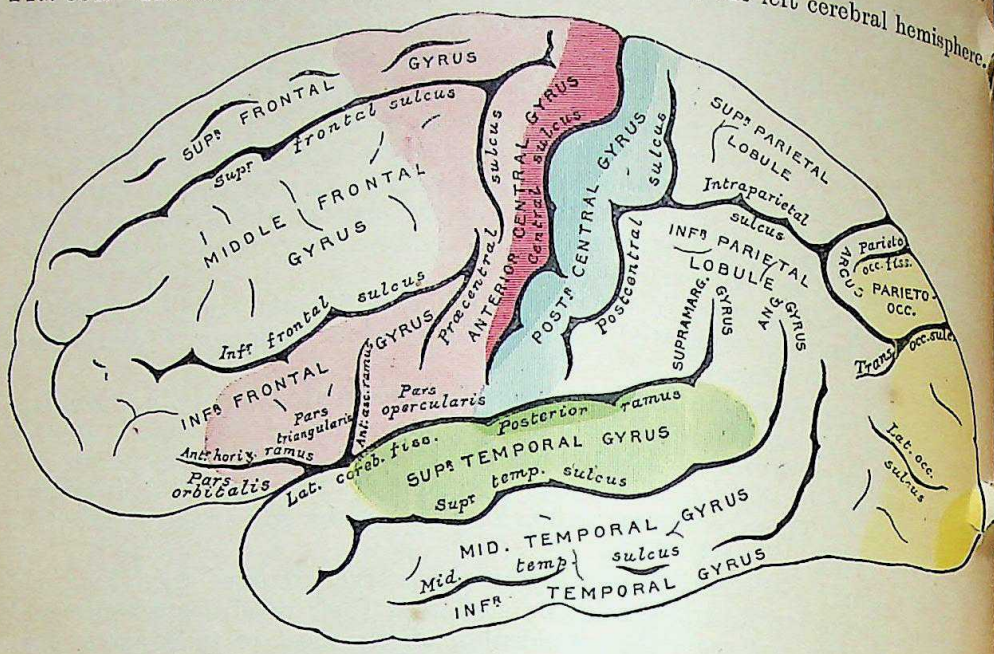

Motor area in red. Area of general sensations in blue. Auditory area in green. Visual area in yellow. The psychic portions are in lighter tints.

FIG. 865.—The areas of localisation on the medial surface of the left cerebral hemisphere.

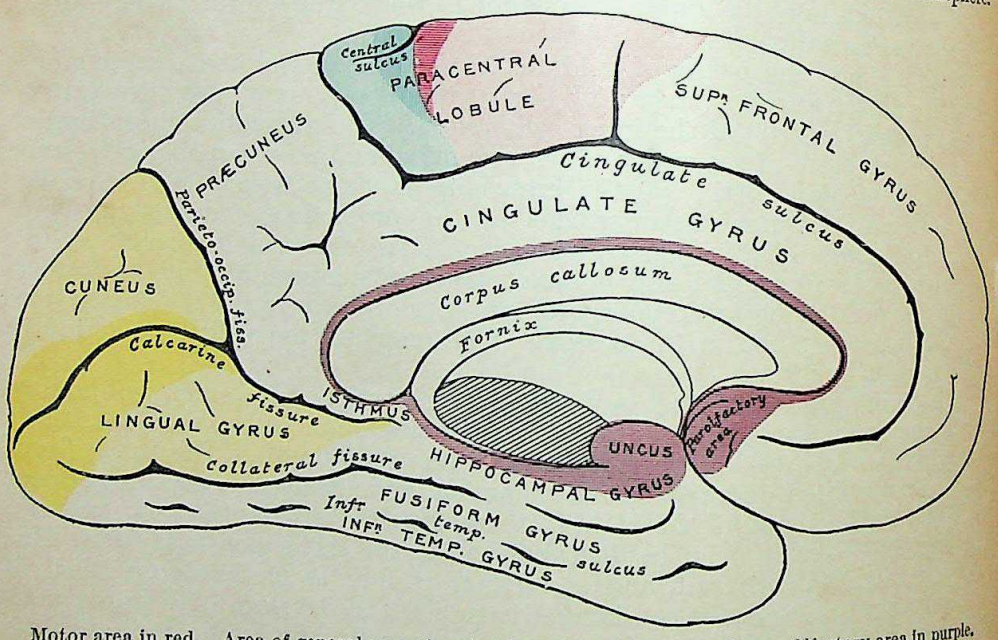

Motor area in red. Area of general sensations in blue. Visual area in yellow. Olfactory area in purple. The psychic portions are in lighter tints.

bounding the calcarine fissure (visuosensory area), the prefrontal district (associational area), and the hippocampal gyrus may be taken as types.

The **motor area** (figs. 864, 865) is characterised by the presence of the giant-cells of Betz in the inner fibre-lamina, and by the absence or very slight development of the middle cell-lamina or layer of granules. Physiological investigations show that the centres for the lower limb are located on the highest part of the anterior central gyrus and its continuation on to the paracentral lobule; those for the trunk are on the upper portion, and those for the upper

CC-0. In Public Domain. Gurukul Kangri Collection, Haridwar

Digitized by Arya Samaj Foundation Chennai and eGangotri

limb on the middle portion of the anterior central gyrus. The facial centres are situated on the lower part of the same gyrus, those for the tongue, larynx, muscles of mastication, and pharynx on the frontal operculum, while those for the eye movements occupy the posterior end of the middle frontal gyrus.

The **visuosensory area** (figs. 855, 864) is sometimes named the *area striata* because, in section, it presents a striated appearance produced by a greatly thickened outer band of Baillarger (band of Gennari); there is also a second layer of granules between this band and the outer cell-lamina. When blindness exists, the band of Gennari and the layers of granules superficial to it are diminished in depth, the former by as much as 50 per cent. in old-standing cases of optic atrophy. During development the visuosensory area matures rapidly; its outer cell-lamina develops early, but in the adult is only five-ninths of the depth of the same layer in the prefrontal region. The visuosensory area is surrounded by a zone 1 cm. or more in breadth, known as the **visuopsychic area**. In this zone the second layer of granules which is present in the visuosensory area suddenly ceases, and the outer cell-lamina is more developed.

Fig. 866.—A coronal section through the olfactory bulb. (Schwalbe.)

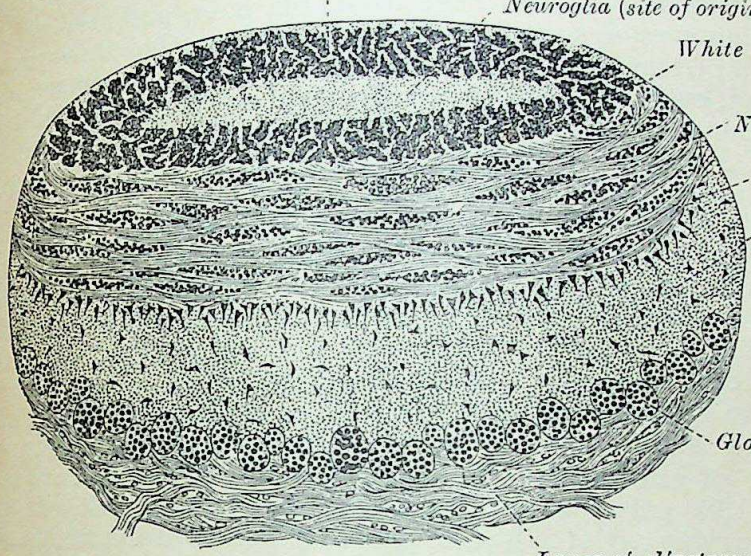

The **auditosensory area** occupies the anterior transverse temporal gyrus (p. 848) and the upper part of the middle one-third of the superior temporal gyrus; the **auditopsychic area** surrounds the auditosensory area but has not been exactly defined. The area for the *sense of taste* is probably in the uncus and hippocampal gyrus, and that for the *sense of smell* in the rhinencephalon. The area for *heat, cold*, and *pain* is somewhat diffuse, but the areas for the *tactile* and *muscular senses* are located mainly in the posterior central gyrus (fig. 864). Destruction of the cerebral cortex does not produce total loss of cutaneous sensibility; this is strikingly true of painful sensations which possibly have centres in the thalamus.

The **associational areas** are three in number: (1) the prefrontal, (2) an area occupying the posterior portions of the temporal and parietal lobes, and (3) the insula. The prefrontal associational area is especially characteristic of the human brain, and it may be taken as the type. It is distinguished by the great development of the outer cell-lamina; the cells of this lamina are undifferentiated in the sixth month of fœtal life, and the lamina is only one-fourth of its adult depth; it is the only layer which varies appreciably in depth in normal brains, and it is under-developed in idiots and imbeciles; it is the last to be evolved and the first to retrogress (Bolton).

The minute structure of the hippocampus, the fascia dentata, and the olfactory bulb calls for special description.

In the **hippocampus** the white substance is represented by a layer termed the *alveus* which lies next the ventricular ependyma; through the alveus fibres

CC-0. In Public Domain. Gurukul Kangri Collection, Haridwar

Digitized by Arya Samaj Foundation Chennai and eGangotri

pass from the hippocampus into the fimbria hippocampi and crura of the fornix. The grey substance consists of: (1) a layer of large pyramidal cells next the alveus; (2) a layer occupied by the apical dendrons of these pyramidal cells, and called the *stratum radiatum*; (3) a molecular layer, the deeper part of which, called the *stratum laciniosum*, exhibits interlacing fibres and dendrites, and contains numerous small, angular nerve-cells; near the dentate gyrus there is a layer of small cells, internal to the stratum laciniosum, known as the *stratum granulosum*.

In the **fascia dentata hippocampi** (dentate gyrus) the molecular layer contains some pyramidal cells, while the layer of pyramidal cells is almost entirely represented by small ovoid cells.

The **olfactory bulb.**—In many animals the olfactory bulb contains a cavity which communicates through the olfactory tract with the lateral ventricle. In man the original cavity is filled by neuroglia and its wall becomes thickened, but much more so on its ventral than on its dorsal aspect. Its dorsal part contains a small amount of grey and white substance, but this is scanty and ill-defined. A section through the ventral part (fig. 866) shows it to consist of the following layers from without inwards: (1) A layer of olfactory nerve-fibres.—These fibres are the non-medullated axons prolonged from the olfactory cells of the nasal cavity, and reach the bulb by passing through the lamina cribrosa of the ethmoidal bone. At first they cover the bulb, and then penetrate it to end by forming synapses with the dendrites of the mitral cells, presently to be described. (2) Glomerular layer.—This contains numerous spheroidal bodies, termed *glomeruli*, each of which is produced by the branching and interlacement of the terminations of one or more olfactory nerve-fibres with the descending dendrite of a mitral cell (fig. 876). (3) Molecular layer.—This is formed of a matrix of neuroglia, imbedded in which are the *mitral cells*. These cells are pyramidal in shape, and the basal part of each gives off a thick dendrite which descends into one of the glomeruli, where it ends as indicated above, and others which interlace with similar dendrites of neighbouring mitral cells. The axons of the mitral cells pass into the next layer, and, bending backwards, are continued into the olfactory tract. (4) Nerve-fibre layer.—This lies next the central core of neuroglia; its fibres consist of the axons of the mitral cells, and pass to the brain; some efferent fibres are, however, also present, and end in the molecular layer, but nothing is known as to their exact origin.

The **weight of the brain.**—The average weight of the brain, in the adult male, is about 1380 gms.; that of the female, about 1250 gms. In the male, the maximum weight out of 278 cases was 1840 gms. and the minimum weight 964 gms. The maximum weight of the adult female brain, out of 191 cases, was 1585 gms. and the minimum weight 879 gms. The brain increases rapidly during the first four years of life, and reaches its maximum weight by about the twentieth year. As age advances, the brain decreases slowly in weight; in old age the decrease takes place more rapidly, and may amount to about 28 gms.

Applied Anatomy.—The *internal capsule* is often the seat of hæmorrhage from the lenticulostriate and lenticulo-optic arteries (Charcot's 'arteries of cerebral hæmorrhage'), or of thrombosis, in patients whose vessels are weakened by old age or disease. A 'stroke,' or 'apoplexy,' is the result; blood is effused from the ruptured vessel and tears up the surrounding brain tissue, and also interferes with the neighbouring fibres by the compression set up by its mass. If the hæmorrhage is sudden and at all large, rapid and complete loss of consciousness follows, with paralysis of the opposite side of the body and loss of control over the sphincters. If it is the occipital part of the internal capsule that is involved, the paralysis will be more marked in the leg than in the arm, and will be associated with hemianæsthesia, and also with homonymous hemianopsia or blindness of the corresponding halves of the two retinæ, the patient being unable to see objects on the opposite side of the body. If the hæmorrhage is very extensive blood often makes its way into the ventricles, and death may follow in a few hours or days without recovery of consciousness, and with hyperpyrexia. If the hæmorrhage is small, consciousness is soon regained, and a fair degree of recovery from the paralysis follows, particularly in the leg. If the hæmorrhage takes place very slowly, the hemiplegia sets in gradually (ingravescent apoplexy), with headache and gradual clouding of the faculties. It is the upper motor neuron (p. 874) that is injured in cerebral hæmorrhage; hence the muscles on the affected side of the body become spastic, with increased reflexes, while such muscular atrophy as follows is mainly due to disuse. The cerebral arteries are liable to sudden obstruction by embolism in persons with heart disease, and by thrombosis in those with diseased arteries. The effects of either embolism or thrombosis here are comparable with those of cerebral hæmorrhage,

CC-0. In Public Domain. Gurukul Kangri Collection, Haridwar

Digitized by Arya Samaj Foundation Chennai and eGangotri

though the resulting hemiplegia or paralysis is often more gradual in its onset, and less severe in its general results.

The Chief Nerve Tracts.

The anatomy of the various parts of the central nervous system having been described, a short account will now be given of the chief ascending and descending nerve-tracts connecting the brain and the medulla spinalis. This may be effected most conveniently by grouping them as follows: (*a*) the motor (descending) tracts, (*b*) the sensory (ascending) tracts, and (*c*) the cerebellar systems (ascending and descending).

Fig. 867.—The principal motor tracts. (Modified from Poirier.)

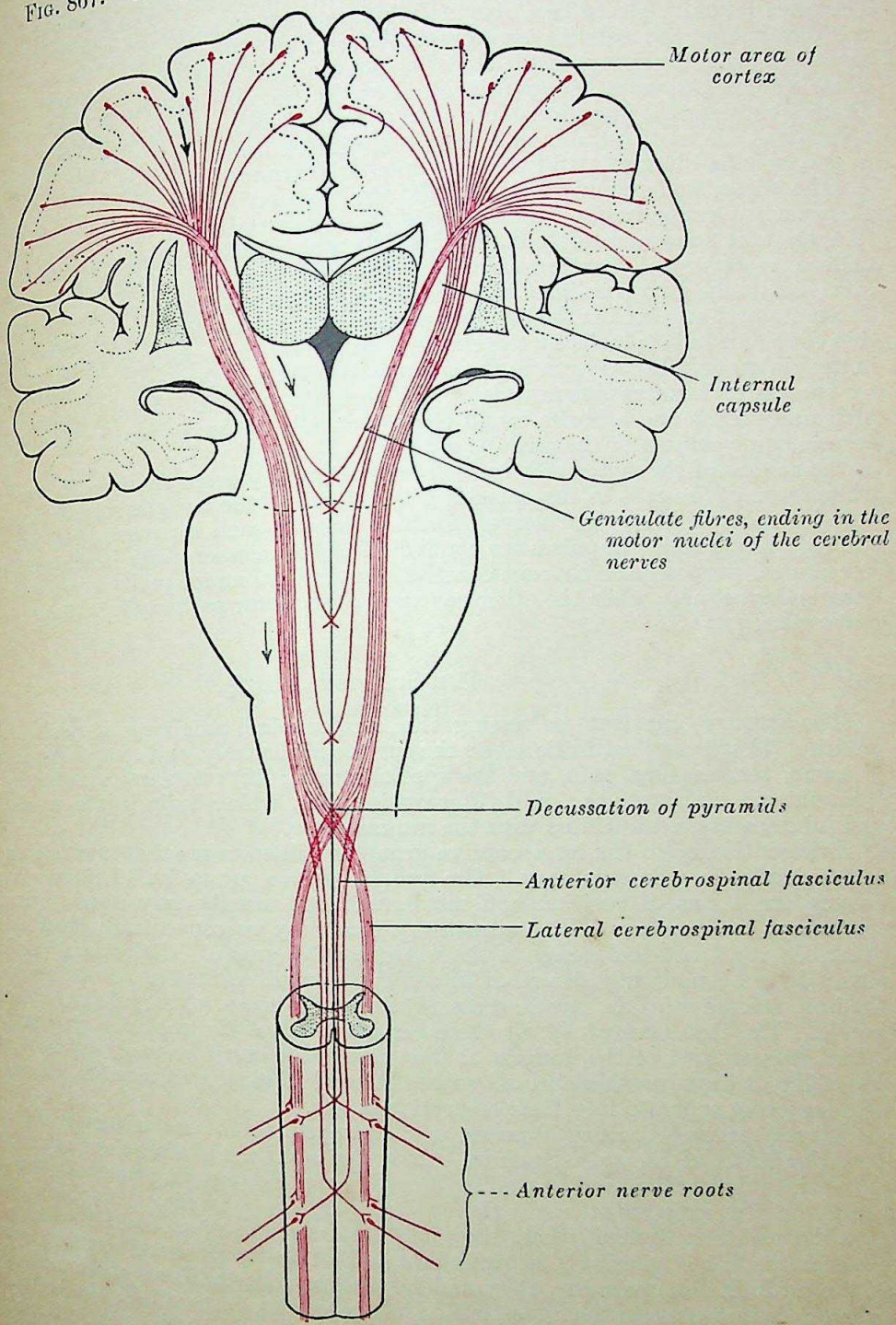

The Motor Tracts.

Included under this heading are, (*a*) the principal motor tracts, originating in the cerebral cortex, and (*b*) the secondary motor tracts originating in the basal ganglia.

The principal motor tracts (fig. 867).—The constituent fibres of these tracts are the axis-cylinder processes of the cells of Betz situated in the deep layer of the cortex. The

CC-0. In Public Domain. Gurukul Kangri Collection, Haridwar

Digitized by Arya Samaj Foundation Chennai and eGangotri

fibres converge as they descend through the corona radiata, and pass between the lentiform nucleus and thalamus, in the genu and in the anterior two-thirds of the occipital part of the internal capsule; those in the genu are named the geniculate fibres, the others the cerebrospinal fibres. Both sets of fibres proceed downwards, through the middle three-fifths of the base of the cerebral peduncle, and then the geniculate fibres cross the middle line, and end by arborising around the cells of the motor nuclei of the cerebral nerves. The cerebrospinal fibres are continued downwards into the pyramids of the medulla oblongata, and thence proceed by one of two paths. The fibres nearest to the anterior median fissure cross the middle line, forming the *decussation of the pyramids*, and descend in the opposite lateral funiculus of the medulla spinalis, as the lateral cerebrospinal fasciculus (crossed pyramidal tract). Throughout the length of the medulla spinalis, fibres from this fasciculus pass into the grey substance, to end by arborising around cells of the posterior column, the axons of which in turn make contact with the motor cells of the anterior column. The more laterally placed cerebrospinal fibres do not decussate in the medulla oblongata, but descend as the anterior cerebrospinal fasciculus (direct pyramidal tract); in each segment of the upper part of the medulla spinalis some of these fibres cross in the anterior white commissure, with the result that all end in the grey substance of the opposite side. There is considerable variation in the extent to which decussation takes place in the medulla oblongata; about two-thirds or three-fourths of the cerebrospinal fibres usually decussate in the medulla oblongata and the remainder in the medulla spinalis.

The secondary motor tracts.—While the presence of a motor path distinct from the principal motor tracts has for some time been surmised on clinical grounds, it is only recently that anatomical details of it have become available, and many of these are still under investigation. In this summary it will be sufficient to indicate that the chief nuclei involved are the globus pallidus of the corpus striatum and the red nucleus of the mid-brain. The main pathway is from the globus pallidus to the red nucleus, and thence to the opposite side of the medulla spinalis by the rubrospinal tract. Secondary pathways probably begin in the globus pallidus and run to the substantia nigra and formatio reticularis, and proceed by successive neurons downwards to the medulla spinalis. All these descending fibres ultimately reach and arborise round the motor cells of the cerebral nerve nuclei or of the anterior grey column of the medulla spinalis.

The axons of the motor cells in the cerebral nuclei proceed through the cerebral nerves, while those of the cells in the anterior grey column of the medulla spinalis pass out in the anterior roots of the spinal nerves, forming thus in each instance a *final common motor pathway*, along which impulses are conducted to the muscles of the head, trunk and limbs. For clinical purposes the neurons constituting the final motor pathway are grouped as the *lower motor neurons*, while the other neurons of the motor pathway form the group of *upper motor neurons*.

The Sensory Tracts.

The sensory impulses traversing the cerebrospinal axis may be resolved into three groups: (1) *exteroceptive*, initiated on the surface of the body, and comprising the sensations of touch, temperature, pain, and the special senses; (2) *interoceptive*, conveying impulses from the visceral systems; and (3) *proprioceptive*, which begin in the muscles, tendons and joints, and are associated with the muscle sense.

Information as to the interoceptive group is still so vague that it cannot be described satisfactorily in this summary. The proprioceptive group includes some fibres which convey sensations of position and movement, not usually very clearly defined in consciousness, but represented by a pathway that may be conveniently described with the other sensory tracts belonging to the exteroceptive group. The pathways of the special senses have been already described in sufficient detail, so that in this section are included the fibre-tracts for (*a*) the muscle sense, (*b*) the tactile sense, (*c*) the pain and (*d*) temperature senses. The first neurons of all these are the cells of the posterior root ganglia of the spinal nerves, and of the ganglia on the cerebral sensory nerves; the fibres conveying the different impulses therefore all enter the cerebrospinal axis together, but immediately after entering separate into their respective tracts.

Muscle sense.—Sensory impulses are conveyed to the medulla spinalis through the posterior roots of the spinal nerves. On entering the medulla spinalis these root-fibres divide into descending and ascending branches; the descending branches soon enter and ramify in the grey substance; the majority of the ascending branches are continued into the posterior funiculi where they join the fasciculus gracilis and fasciculus cuneatus. These fasciculi end by arborising around the cells of the nucleus gracilis and nucleus cuneatus in the medulla oblongata (fig. 868), and from these cells the fibres of the medial lemniscus take origin and cross to the opposite side in the sensory decussation. In its further course the medial lemniscus receives fibres from the terminal nuclei of the ordinary sensory cerebral nerves of the opposite side. Ascending through the cerebral peduncle the medial lemniscus gives off a few fibres to the lentiform nucleus and insula, but the greater part of it is carried into the thalamus where its fibres end. From the cells of the thalamus the fibres of the third link in the chain arise and pass to the cerebral cortex behind the central sulcus.

Tactile sense.—Sensory impulses enter the medulla spinalis by fibres of the posterior roots of the spinal nerves. Some of the [illegible] arise at once with cells in the

CC-0. In Public Domain. Gurukul Kangri Collection, Haridwar

Digitized by Arya Samaj Foundation Chennai and eGangotri

posterior column of grey matter; others ascend for varying distances, and end around the posterior column cells of higher segments; from these cells fibres arise and cross to the opposite side to run up in the anterior spinothalamic tract. A third set of longer fibres ascends as far as the nucleus gracilis and nucleus cuneatus, and ends by arborising around the cells of these nuclei; the fibres from those cells cross in the sensory decussation in

FIG. 868.—The pathway of the muscle sense. (Modified from Poirier.)

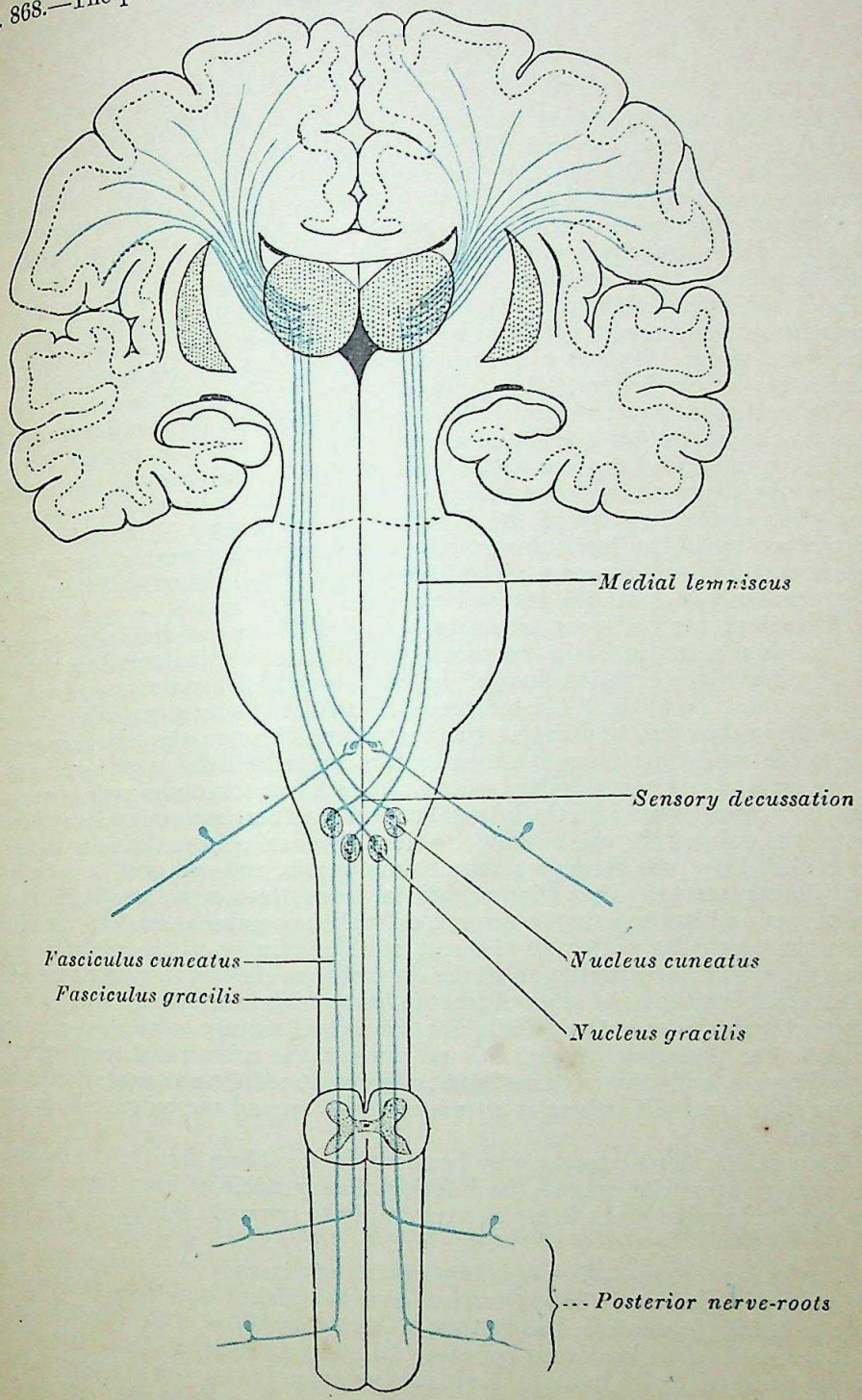

the medulla oblongata, and join the anterior spinothalamic tract, which is continued up through the pons and mid-brain to the thalamus where it ends; the impulse is finally carried by the neurons of the thalamus to the cerebral cortex behind the central sulcus.

Pain and temperature senses.—The fibres conveying these sensory impulses travel together. They enter the medulla spinalis through the posterior nerve-roots, and at once arborise around the cells of the posterior grey column. The fibres from these cells cross to the opposite side of the medulla spinalis where most of them form a long pathway, the lateral spinothalamic tract, which runs through the medulla oblongata dorsal to the inferior olive and then joins the medial lemniscus and is continued to the thalamus. Some

CC-0. In Public Domain. Gurukul Kangri Collection, Haridwar

Digitized by Arya Samaj Foundation Chennai and eGangotri

of the fibres, instead of following the long pathway, are relayed to the thalamus by shorter neurons. From the thalamus new fibres arise and convey the impulses to the cerebral cortex behind the central sulcus.

It will be observed that in most cases there are three cell-stations interposed in the course of the sensory impulses; for clinical purposes, therefore, three groups of neurons are recognised: (1) the *lowest sensory neurons* which comprise the cells of the posterior root ganglia, and their peripheral and central processes; (2) the *intermediate sensory neurons* between these and the thalamus; and (3) the highest sensory neurons which are the cells of the thalamus and the fibres passing from them to the cerebral cortex.

The Cerebellar Systems.

The cerebellum acts as a great coordinating centre for the muscles of the body generally, so that impulses reach it from all the sensory centres of the rest of the brain and of the medulla spinalis, while impulses are conveyed from it to other coordinating and motor nuclei in the cerebrospinal axis. Only the larger tracts can be summarised here.

Afferent tracts.—A considerable number of afferent impulses reach the cerebellum by way of the medulla spinalis through the fibres of the posterior nerve roots. In the medulla spinalis there are three main pathways. The entering fibres may end around the cells of the dorsal nucleus; the fibres from these cells form the direct cerebellar tract (posterior spino-cerebellar fasciculus) of the same side, and are carried up to the medulla oblongata where they enter the restiform body and are conveyed to the cortex of the vermis of the cerebellum. A second group of entering fibres arborise around the cells of the posterior grey column of the medulla spinalis; of the fibres of these cells some cross to the opposite side while others pass up the same side, in each instance forming an anterior spinocerebellar tract which traverses the medulla spinalis in the superficial antero-lateral tract, runs through the medulla oblongata and pons, and then turns in to reach the cerebellar cortex by way of the brachium conjunctivum. The third group of entering fibres runs up in the fasciculus gracilis and fasciculus cuneatus, and ends in the nucleus gracilis and nucleus cuneatus; the fibres arising from the cells of these nuclei pass in the restiform body to reach the cerebellar cortex.

Two important afferent tracts to the cerebellum run from the brain-stem, viz. the vestibulocerebellar and the tectocerebellar. The vestibulocerebellar tract arises from the vestibular nuclei in the floor of the fourth ventricle, and runs up in the restiform body to the cerebellar cortex. The tectocerebellar tract has its origin in the cells of the superior and inferior colliculi and enters the cerebellum through the brachium conjunctivum.

Of the remaining afferent fibres to the cerebellum the most important group is that of the cerebro-ponto-cerebellar tracts. These fibres arise from cells of the cerebral cortex, travel downwards through the internal capsule and cerebral peduncle, and end by arborising round the cells of the nuclei pontis. New fibres arise from the cells of these nuclei, cross the middle line, pass through the brachium pontis, and end in the cerebellar cortex.

Efferent tracts.—The efferent tracts from the cerebellum originate from cells of the cortex and run to arborise around cells of the cerebellar nuclei; no fibres pass directly from the cerebellar cortex to the rest of the brain or to the medulla spinalis. Several small groups of fibres arising from the cerebellar nuclei run to various nuclei in the cerebrospinal axis, but the chief efferent tract is that which forms the greater part of the brachium conjunctivum, crosses the middle line, and runs mainly to the red nucleus, giving some fibres to the thalamus. From the red nucleus the rubrospinal tract arises, crosses to the opposite side, and travels down in the pons and medulla oblongata to the lateral funiculus of the spinal medulla, where it ultimately ends around the motor cells in the anterior grey column.

Two other efferent tracts may be mentioned; fibres from the cerebellar nuclei run to the vestibular nuclei and to the inferior olivary nuclei; from these in turn are derived the vestibulospinal and olivospinal tracts of the opposite side of the medulla spinalis.

Applied Anatomy.—The chief symptoms of diseases of the brain and medulla spinalis depend upon the particular systems of neurons picked out for attack, and some of them may be briefly summarised as follows. *Motor paralysis* of the *spastic* type, with rigidity of the muscles and increased reflexes, follows destruction of the upper motor neurons; *flaccid* paralysis, with loss of the reflexes and rapid muscular atrophy, follows destruction of the lower motor neurons. *Sensory paralysis* follows injury to any part of the sensory path; in tabes it is due to injury of the lowest sensory neurons, in hemiplegia to destruction of the highest sensory axon as it traverses the occipital part of the internal capsule. *Dissociation of sensations*, or the loss of some forms of sensation while others remain unimpaired, is seen in a number of conditions such as tabes and syringomyelia; it shows that the paths through which various forms of sensation travel to the brain are different. *Abnormalities of reflex actions* are of very great help in the diagnosis of nervous complaints. The numerous *superficial or skin reflexes* (e.g. the scapular, irritation of the skin over the scapula produces contraction of the scapular muscles; the abdominal, stroking the abdomen causes its retraction; the cremasteric, stroking the inner side of the thigh causes retraction of the testis on that side; the plantar, tickling the sole of the

CC-0. In Public Domain. Gurukul Kangri Collection, Haridwar

Digitized by Arya Samaj Foundation Chennai and eGangotri

foot brings on plantar flexion of the toes), if present, show that the reflex arcs on whose integrity their existence depends are intact; but they often are absent in health and so cannot be trusted to indicate disease. The *deep reflexes or tendon reactions*, such as the knee-jerk, or the tendo calcaneus jerk, are increased in chronic degeneration of, or gradually increasing pressure on, the cerebrospinal fibres (upper motor neuron), in nervous or hysterical patients, and when the irritability of the cells of the anterior column (lower motor neuron) is increased, as happens in tetanus or in poisoning by strychnine. They are lost when the lower motor or lower sensory neurons are diseased, and in a few other conditions; absence of the knee-jerk is very rare in health, and suggests disease in some part of its reflex arc, in the third and fourth lumbar segments of the cord, or else, more rarely, grave intracranial or spinal disease cutting off the lower from the higher nervous centres. The *organic reflexes* of the pupil, bladder, and rectum are of the greatest practical importance. The commonest defect in the reflexes of the pupil is reflex iridoplegia, or failure to contract on exposure to light, without failure to contract on convergence or accommodation ('Argyll Robertson' pupil). The pupil is also contracted (miosis), and may or may not dilate when the skin of the neck is pinched (the ciliospinal reflex). Micturition is a spinal reflex much under the control of the brain; if the centre for micturition in the second sacral segment is destroyed the sphincter and the walls of the bladder are paralysed, the bladder becomes distended with urine, and incontinence from overflow results. If this centre escapes injury but is cut off more or less completely from impulses descending to it from above, there will be more or less interference with micturition. This varies in degree from the 'precipitate micturition' of tabetic patients, who must perforce hurry to pass water the moment the impulse seizes them, to the state of 'reflex incontinence,' when the bladder automatically empties itself from time to time, almost without the patient's knowledge. Defæcation is a very similar spinal reflex, and is liable to very similar disorders of function.

The *upper motor neuron* (p. 874) is affected in hemiplegia, the *lower motor neuron* (p. 874) in infantile spinal paralysis; both these systems of neurons are diseased together in the somewhat rare disorders known as amyotrophic lateral sclerosis and progressive muscular atrophy. The chief symptom here is wasting and weakness in certain groups of muscles; the palsy will be flaccid, with loss of the reflexes, or spastic, with increased reflexes, according as the degeneration mainly involves the lower or the upper motor neuron. The sphincters are affected only in the later stages of these diseases.

Pathological changes in the *lowest sensory neuron* are the cause of tabes dorsalis or locomotor ataxy, which occurs almost entirely in adults who have had syphilis. In the early or pre-ataxic stage the patient may exhibit the Argyll Robertson pupil (see above), and loss of knee-jerks, and complain of sharp, stabbing pains ('lightning pains') in the limbs, difficult or precipitate micturition, and sometimes of severe and painful attacks of indigestion (gastric crises). In the second or ataxic stage, coming on perhaps years later, he will complain, in addition, of interference with his powers of getting about and turning, although his muscular strength is well preserved. He is unable to stand steady with his eyes shut or in the dark, his gait becomes exaggerated and stamping in character, he has to use a stout stick to walk with, and he may suffer from painful crises in various parts of the body. Control over the sphincters is further weakened, and on examination there will be found marked incoordination of the limbs, zones of anæsthesia about the trunk or down the limbs, and marked analgesia (or insensitiveness to pain) when pressure is applied to the bones, tendons, trachea, tongue, eyeballs, mammæ, and testes.* The ataxy progresses till the third or bedridden stage is reached; control over the sphincters is still further lost, and the patient is likely to die of intercurrent disease or of general paralysis of the insane.

No nervous disease is recognised as dependent upon degeneration of either the *intermediate* or *highest sensory neuron*.

THE MENINGES OF THE BRAIN AND MEDULLA SPINALIS

The brain and the medulla spinalis are enveloped by three membranes or meniages, named from without inwards: the dura mater, the arachnoid, and the pia mater.

The Dura Mater

The **dura mater** is a thick and dense inelastic membrane. The portion of it which encloses the brain (cerebral dura mater) differs in several particulars from that which surrounds the medulla spinalis (spinal dura mater), and therefore it is necessary to describe them separately; the two parts, however, form one complete membrane, and are continuous with one another at the foramen magnum.

* J. Grasset, *Le Tabes, Maladie de la Sensibilité profonde*; Montpelier, 1909.

CC-0. In Public Domain. Gurukul Kangri Collection, Haridwar

Digitized by Arya Samaj Foundation Chennai and eGangotri

The cerebral dura mater lines the interior of the skull, and serves the two-fold purpose of an internal periosteum to the bones, and a protective membrane for the brain. It is composed of two layers, an inner or meningeal and an outer or endosteal; these are closely united, except along certain lines where they are separated by the venous sinuses which drain the blood from the brain (p. 717). The dura mater adheres to the inner surfaces of the cranial bones, and sends blood-vessels and fibrous processes into them, the adhesion being most marked at the sutures, at the base of the skull, and around the

FIG. 869.—The dura mater and its processes. Exposed by removing a part of the right half of the skull, and the brain.

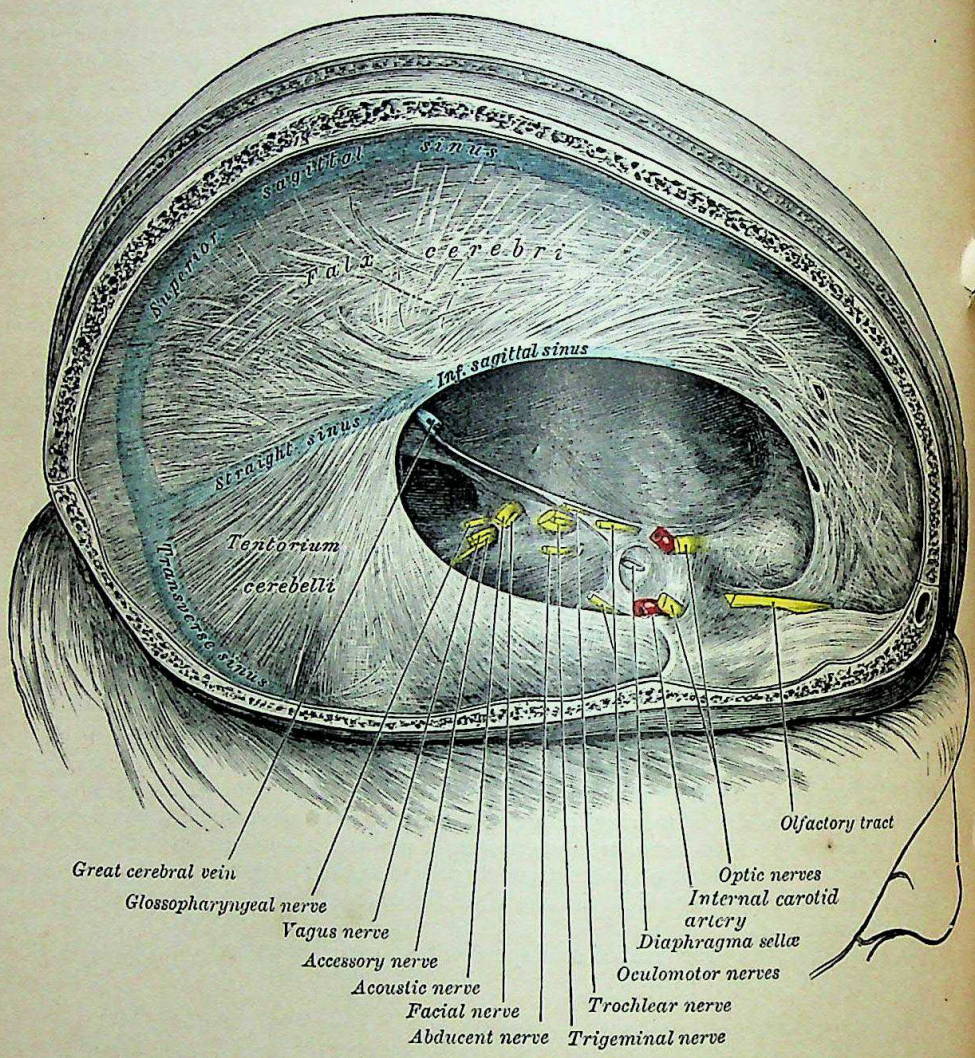

foramen magnum. The blood-vessels and fibrous processes are torn across when the dura mater is detached from the bones, and consequently the outer surface of the membrane presents a rough and fibrillated appearance; the inner surface is smooth and lined by a layer of endothelium. The dura mater is continuous through the sutures with the pericranium, and through the superior orbital fissure with the periosteal lining of the orbital cavity. It sends tubular sheaths on the cerebral nerves as the latter pass through the foramina at the base of the skull; outside the skull these sheaths fuse with the epineurium of the nerves; the sheath of the optic nerve blends anteriorly with the sclera of the bulb of the eye.

The cerebral dura mater sends inwards four processes or septa which divide the cranial cavity into a series of freely communicating spaces for the lodgment of the brain. These processes are named the falx cerebri, the tentorium cerebelli, the falx cerebelli, and the diaphragma sellæ.

CC0. In Public Domain. Gurukul Kangri Collection, Haridwar

Digitized by Arya Samaj Foundation Chennai and eGangotri

The *falx cerebri* (fig. 869), so named from its sickle-like form, is a strong, arched process of dura mater which descends vertically in the longitudinal fissure between the cerebral hemispheres. It is narrow in front, where it is fixed to the crista galli of the ethmoidal bone; and broad behind, where it is attached to the middle line of the upper surface of the tentorium cerebelli; the narrow, anterior part is thin, and is frequently perforated by numerous apertures. The upper margin of the falx cerebri is convex, and attached to the inner surface of the skull on either side of the middle line, as far back as the internal occipital protuberance; the superior sagittal sinus runs along this

Fig. 870.—The tentorium cerebelli. Superior aspect.

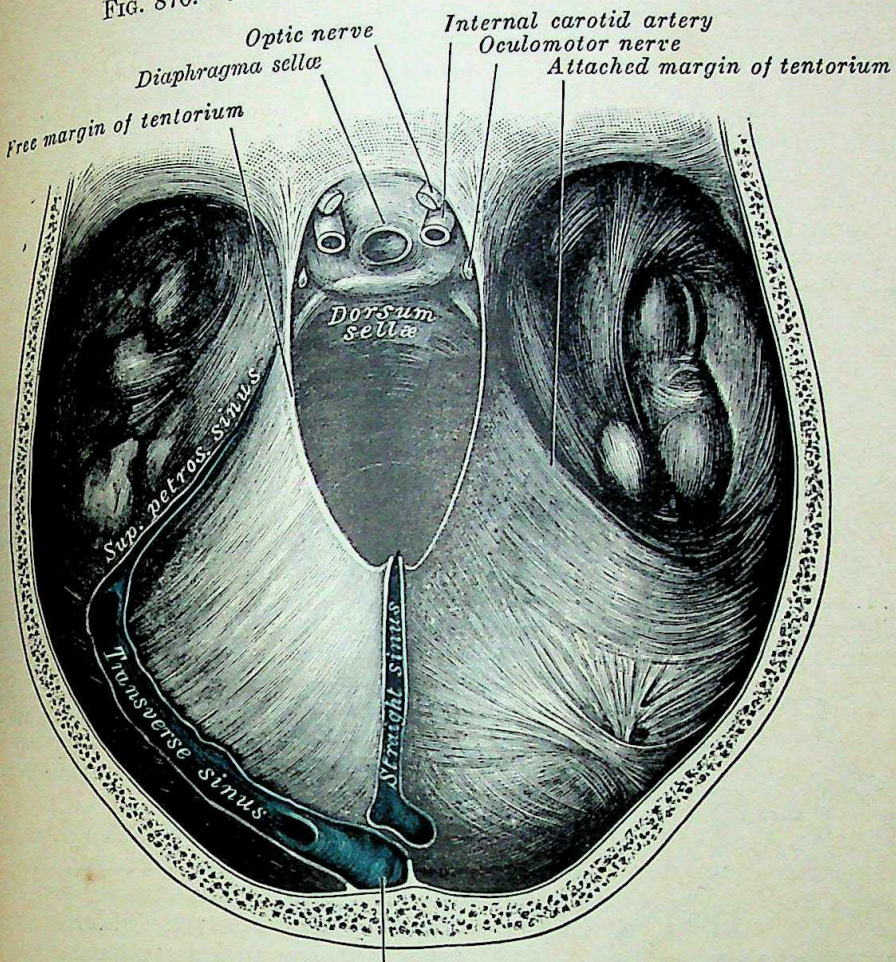

margin. Its lower margin is free and concave, and contains the inferior sagittal sinus. The straight sinus runs along its attachment to the tentorium cerebelli.

The *tentorium cerebelli* (fig. 870) is an arched lamina of dura mater which covers the superior surface of the cerebellum, and supports the occipital lobes of the brain. Its concave, anterior border is free, and bounds a large oval opening, the *incisura tentorii*, which is occupied by the mesencephalon. Its convex, posterior border is attached behind to the lips of the transverse sulci on the inner surface of the occipital bone, and there encloses the transverse sinuses; in front, the posterior border is attached to the superior angles of the petrous parts of the temporal bones, enclosing the superior petrosal sinuses. At the apex of the petrous part of the temporal bone the free and attached borders cross one another; the free borders are fixed to the anterior, and the attached borders to the posterior, clinoid processes of the sphenoidal bone. As already stated, the posterior border of the falx cerebri is attached to the median line of the upper surface of the tentorium cerebelli, and the straight sinus lies in this line of attachment.

CC-0. In Public Domain. Gurukul Kangri Collection, Haridwar

Digitized by Arya Samaj Foundation Chennai and eGangotri

The *falx cerebelli* is a small, median sagittal, triangular process of dura mater which is situated below the tentorium cerebelli, and projects forwards into the posterior cerebellar notch. Its base, directed upwards, is attached to the posterior part of the median line of the tentorium cerebelli; its posterior margin contains the occipital sinus, and is fixed to the internal occipital crest; its apex frequently divides into two small folds, which are lost on the sides of the foramen magnum.

The *diaphragma sellæ* is a small circular horizontal fold of dura mater, which roofs the sella turcica and almost completely covers the hypophysis; a small opening in its centre transmits the infundibulum.

Structure.—The cranial dura mater consists of white fibrous tissue and elastic fibres arranged in flattened laminæ which are imperfectly separated by lacunar spaces and blood-vessels into the endosteal and meningeal layers, already referred to. The endosteal layer is the internal periosteum for the cranial bones, and contains the blood-vessels for their supply. At the margin of the foramen magnum it is continuous with the periosteum lining the vertebral canal. The meningeal layer is lined on its inner surface by a layer of nucleated endothelium.

The *arteries* of the dura mater are very numerous. Those in the anterior fossa of the skull are the anterior meningeal branches of the anterior and posterior ethmoidal and internal carotid arteries, and a branch from the middle meningeal artery. Those in the middle fossa are the middle and accessory meningeal branches of the internal maxillary artery; a branch from the ascending pharyngeal artery, which enters the skull through the foramen lacerum; branches from the internal carotid artery, and a recurrent branch from the lacrimal artery. Those in the posterior fossa are meningeal branches from the occipital artery, one entering the skull through the jugular foramen, and another through the mastoid foramen; the posterior meningeal branches of the vertebral artery; occasional meningeal branches from the ascending pharyngeal artery, entering the skull through the jugular foramen and hypoglossal canal; and a branch from the middle meningeal artery.

The *veins* returning the blood from the cranial dura mater anastomose with the diploic veins and end in the cranial blood-sinuses. Many of the meningeal veins do not open directly into the sinuses, but indirectly through a series of *venus lacunæ*. These lacunæ are found on either side of the superior sagittal sinus, especially near its middle portion, and are often invaginated by arachnoideal granulations; they communicate with the diploic and emissary veins.

The *nerves* of the cerebral dura mater are filaments from the semilunar ganglion of the trigeminal nerve, from the ophthalmic, maxillary, mandibular, vagus, and hypoglossal nerves, and from the sympathetic.

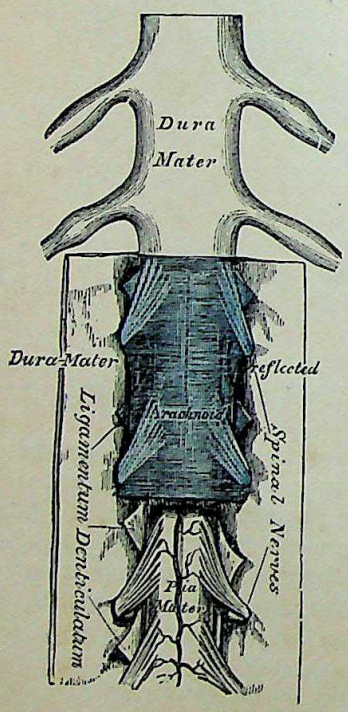

FIG. 871.—A portion of the medulla spinalis, showing its membranes.

The **spinal dura mater** (figs. 871, 874) forms a loose sheath around the medulla spinalis, and represents only the inner or meningeal layer of the cerebral dura mater; the outer or endosteal layer ceases at the foramen magnum, its place being taken by the periosteum lining the vertebral canal. The spinal dura mater is separated from the wall of the vertebral canal by a space, the *epidural space*, which contains a quantity of loose areolar tissue and a plexus of veins; the situation of these veins between the spinal dura mater and the periosteum of the vertebræ corresponds to that of the cranial sinuses between the meningeal and endosteal layers of the cerebral dura mater. The spinal dura mater is attached to the circumference of the foramen magnum, and to the second and third cervical vertebræ; it is also connected by fibrous slips to the posterior longitudinal ligament of the vertebræ, especially near the lower end of the vertebral canal. The subdural cavity ends at the lower border of the second sacral vertebræ; below this level the dura mater closely invests the filum terminale of the medulla spinalis and descends to the back of the coccyx, where it blends with the periosteum. The dura mater sends tubular prolongations on the roots of the spinal nerves and on the complete spinal nerves

CC-0. In Public Domain. Gurukul Kangri Collection, Haridwar

Digitized by Arya Samaj Foundation Chennai and eGangotri

as they pass through the intervertebral foramina. These prolongations are short in the upper part of the vertebral column, but gradually become longer below.

Structure.—The spinal dura mater resembles in structure the meningeal layer of the cranial dura mater; it consists of white fibrous and elastic tissue arranged in bands or lamellæ which, for the most part, are parallel with one another and have a longitudinal arrangement. Its internal surface is smooth and covered by a layer of endothelium. It is sparingly supplied with blood-vessels and nerves.

The Arachnoid

The **arachnoid** is a delicate membrane enveloping the brain and medulla spinalis and lying between the pia mater internally and the dura mater externally. It is separated from the dura mater by the *subdural space*, but here and there this space is traversed by isolated connective tissue trabeculæ, which are most numerous on the posterior surface of the medulla spinalis. It is separated from the pia mater by the *subarachnoid cavity* which is filled with cerebrospinal fluid.

The arachnoid surrounds the cerebral and spinal nerves, and encloses them in loose sheaths as far as their points of exit from the skull and vertebral canal.

The *cerebral part of the arachnoid* invests the brain loosely, and does not dip into the sulci between the gyri, nor into the fissures, with the exception of the longitudinal. On the upper surface of the brain it is thin and transparent; at the base it is thicker, and slightly opaque towards the central part, where it extends between the two temporal lobes in front of the pons, so as to leave a considerable interval between it and the pia mater.

The *spinal part of the arachnoid* (figs. 871, 874) is a thin, delicate, tubular membrane loosely investing the medulla spinalis. Above, it is continuous with the cerebral arachnoid; below, it widens out, invests the cauda equina, and ends at the level of the lower border of the second sacral vertebra.

Structure.—The arachnoid consists of bundles of white fibrous and elastic tissue intimately blended together. Its outer surface is covered with a layer of endothelium. Vessels of considerable size, but few in number, and, according to Bochdalek, a rich plexus of nerves derived from the motor root of the trigeminal, the facial, and the accessory nerves, are found in the cerebral part of the arachnoid.

The **subarachnoid cavity** is the interval between the arachnoid and pia mater. It contains the cerebrospinal fluid and the larger blood-vessels of the brain, and is traversed by a network of delicate connective tissue trabeculæ, which connect the arachnoid to the pia mater. The pia mater and the arachnoid are in close contact on the summits of the cerebral gyri; but where the arachnoid bridges the sulci, angular spaces are left, in which the subarachnoid trabecular tissue is found. At certain parts of the base of the brain, the arachnoid is separated from the pia mater by wide intervals, which communicate freely with each other and are named *subarachnoid cisternæ*; in these the subarachnoid tissue is less abundant.

The **subarachnoid cisternæ** (fig. 872).—The *cisterna cerebellomedullaris* (cisterna magna) is triangular on sagittal section, and is formed by the arachnoid bridging the interval between the medulla oblongata and the under surface of the cerebellum; it is continuous below with the subarachnoid cavity of the medulla spinalis. The *cisterna pontis* is a considerable space on the ventral aspect of the pons. It contains the basilar artery, and is continuous below with the subarachnoid cavity of the medulla spinalis, behind with the cisterna cerebellomedullaris, and in front of the pons with the cisterna interpeduncularis. The *cisterna interpeduncularis* (cisterna basalis) is a wide cavity where the arachnoid extends across between the two temporal lobes. Within it are the cerebral peduncles, the structures in the interpeduncular fossa, and the arterial circle of Willis. Anteriorly, the cisterna interpeduncularis is continuous with the cisterna chiasmatis which lies in front of the optic chiasma and is prolonged on the upper surface of the corpus callosum; here the arachnoid stretches between the cerebral hemispheres immediately beneath the free border of the falx cerebri, and thus leaves a space in which the anterior cerebral arteries are contained. The *cisterna fossæ cerebri lateralis* contains the middle cerebral

CC-0. In Public Domain. Gurukul Kangri Collection, Haridwar

Digitized by Arya Samaj Foundation Chennai and eGangotri

artery, and is formed in front of either temporal lobe by the arachnoid bridging the lateral cerebral fissure. The *cisterna venæ magnæ cerebri* occupies the interval between the splenium of the corpus callosum and the superior surface of the cerebellum; it extends between the layers of the tela chorioidea of the third ventricle and contains the great cerebral vein.

Fig. 872.—A diagram showing the positions of the three principal subarachnoid cisternæ.

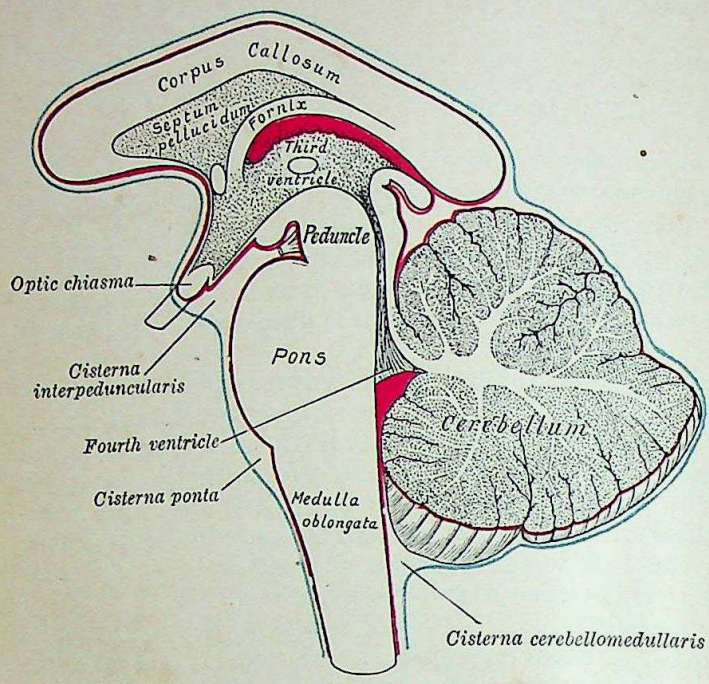

The subarachnoid cavity communicates with the general ventricular cavity of the brain by three openings: one, the *foramen of Majendie*, is in the middle line at the inferior part of the roof of the fourth ventricle; the other two are at the extremities of the lateral recesses of that ventricle, behind the upper roots of the glossopharyngeal nerves. It is stated by Meckel that the lateral ventricles also communicate with the subarachnoid cavity at the apices of their inferior cornua. There is no direct communication between the subdural and subarachnoid cavities.

The spinal part of the subarachnoid cavity is a wide interval, and is largest at the lower part of the vertebral canal, where the arachnoid encloses the nerves which form the cauda equina. Above, it is continuous with the cranial subarachnoid cavity; below, it ends at the level of the lower border of the second sacral vertebra. It is partially divided by a longitudinal septum, the *subarachnoid septum*, which connects the arachnoid with the pia mater opposite the posterior median sulcus of the medulla spinalis, and forms a partition, incomplete and cribriform above, but more complete in the thoracic region. The spinal subarachnoid cavity is further subdivided by the *ligamentum denticulatum* (p. 885).

The **arachnoideal granulations** (glandulæ Pacchionii) (fig. 873) are small fleshly-looking elevations, usually collected in clusters which are present in the vicinity of the superior sagittal, transverse, and some other sinuses. Upon laying open the sagittal sinus and the venous lacunæ on either side of it, granulations will be found protruding into their interior. On close inspection they may be seen at the age of eighteen months, "and at the age of three they are disseminated over a considerable area"; they increase in number and size as age advances. They are enlarged or distended normal villi of the arachnoid, which cause absorption of the bone, and so produce the pits or depressions on the inner wall of the calvarium.

Structure.—The growth and structure of the arachnoideal granulations have recently been studied by le Gros Clark.* Histologically each granulation appears as a diverticulum of the subarachnoid cavity, penetrating into the interstices of the dura mater, and covered by a layer of flattened cells (arachnoid mesothelium) containing large oval nuclei and lightly staining protoplasm. In the subarachnoid cavity is a reticulum of fine fibrous tissue, the density of which is as a rule greater at the periphery than at the centre of the granulation; in advanced age calcareous nodules are frequently found in it.

At the summit of the granulation the mesothelial cells proliferate and form a cap which penetrates the surrounding dura mater, and fuses with the endothelial lining of one of the intradural venous sinuses; in doing so it pulls out a little stalk of arachnoid membrane

* W. E. Le Gros Clark, *Journal of Anatomy*, vol. lv, 1920.

CC-0. In Public Domain. Gurukul Kangri Collection, Haridwar

Digitized by Arya Samaj Foundation Chennai and eGangotri

containing a diverticulum of the subarachnoid cavity. Except at the point of fusion with the endothelial lining of the sinus, the granulation is surrounded by the subdural space and the dura mater; the latter, covered on its cerebral surface by a layer of endothelium, is invaginated into the venous sinus by the protrusion of the granulation.

Fluid injected into the subarachnoid cavity passes into these granulations, and it has been found experimentally that fluid passes by osmosis from the arachnoideal villi into the venous sinuses of the dura mater.

FIG. 873.—A coronal section through the top of the skull; showing the membranes of the brain, &c. Diagrammatic. (Modified from Testut.)

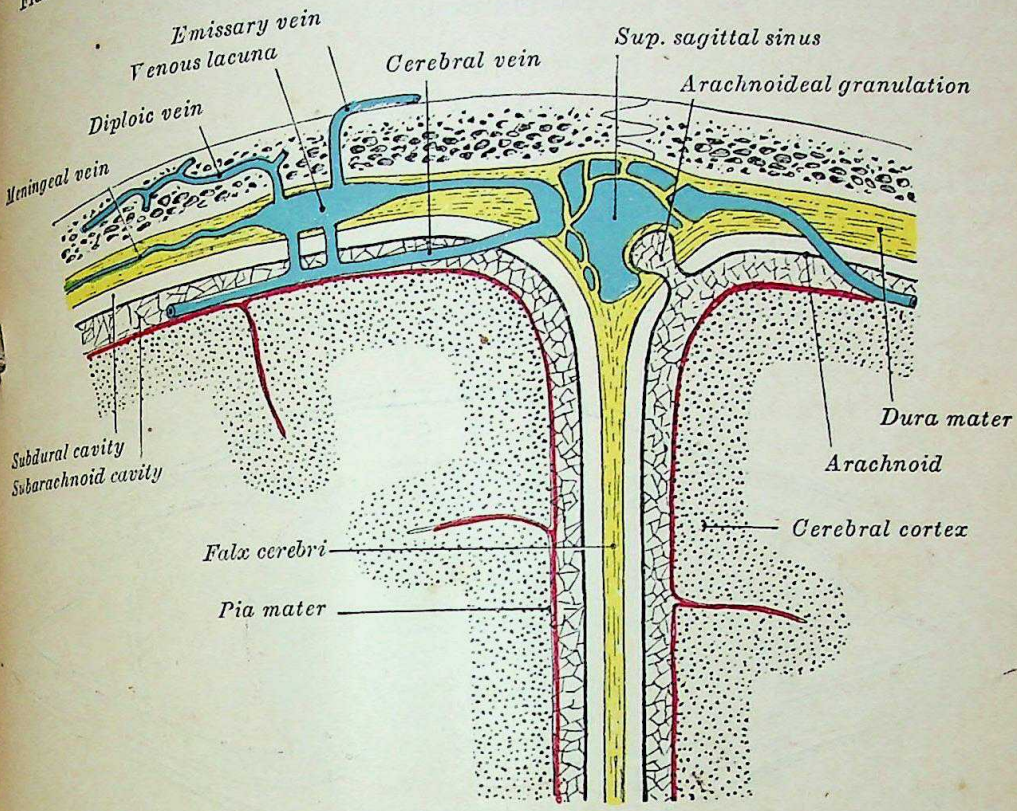

The cerebrospinal fluid is a clear, slightly alkaline fluid, with a specific gravity of about 1007. It contains in solution inorganic salts similar to those in the blood-plasma, and also traces of protein and glucose. It supports and protects the delicate structures of the brain and medulla spinalis, and maintains a uniform pressure on them. The arachnoideal villi are essential structures in the return of the cranial cerebrospinal fluid into the blood-stream (Weed *).

Applied Anatomy.—In various diseases, such as syphilis, meningitis, and infantile paralysis, changes take place in the chemical nature of the substances dissolved in the cerebrospinal fluid, or in the various cells found suspended in it; and these alterations are often of service in diagnosis.

Evidence of great value in the diagnosis of meningitis may sometimes be obtained by puncturing the spinal membranes and withdrawing some of the cerebrospinal fluid; moreover, the operation of lumbar puncture is in many cases curative, possibly because the draining of some of the cerebrospinal fluid relieves the patient by diminishing the intracranial pressure. The operation is performed by inserting a trocar, of the smallest size, between the laminæ of the third and fourth, or of the fourth and fifth lumbar vertebræ, through the ligamentum flavum. The medulla spinalis, even of a child at birth, does not reach below the third lumbar vertebra, and therefore the canal may be punctured between the third and fourth lumbar vertebra without any risk of injuring this structure. The point of puncture is indicated by laying the patient on the side and dropping a perpendicular line from the highest point of the iliac crest; this will cross the upper border of the spinous process of the fourth lumbar vertebra, and will indicate the level at which the trocar should be inserted a little to one side of the middle line. The puncture may require to be repeated more than once, and the greatest precaution must be taken not to allow septic infection of the meninges. If there be any appreciable increase of pressure, the fluid will flow through the trocar with the greatest freedom.

* Lewis H. Weed, Carnegie Institute of Washington: *Contributions to Embryology*, vol. 9, 1920.

CC-0. In Public Domain. Gurukul Kangri Collection, Haridwar

Digitized by Arya Samaj Foundation Chennai and eGangotri

In addition to the constitutional signs and symptoms of fever, *acute spinal meningitis* exhibits certain characteristic features. Pain and tenderness to pressure along the vertebral column are common, and so are pains in the limbs or round the trunk from irritation of the posterior nerve-roots by the inflammatory products. Irritation of the anterior nerve-roots is shown by the increased tone of the muscles, which may go on to the point where they pass into a state of spasm with much-increased reflexes; this is often seen in the retraction of the head and neck. Later in the disease the reflexes are often lost, when, also, the urine and fæces may be passed involuntarily.

Spinal anæsthesia can be induced by injecting certain substances, especially novocain, into the cerebrospinal fluid. It is done by means of a syringe attached to a lumbar puncture needle, and is especially valuable when, from any cause, the administration of a general anæsthetic is inadvisable; but any operation below the level of the umbilicus (10th thoracic nerve) can be performed painlessly by this method.

The Pia Mater

The **pia mater** closely invests the brain and medulla spinalis; it is a vascular membrane, consisting of a minute plexus of blood-vessels held together by an extremely fine areolar tissue. The *cerebral pia mater* invests the entire surface

Fig. 874.—A transverse section through the medulla spinalis and its membranes. Diagrammatic.

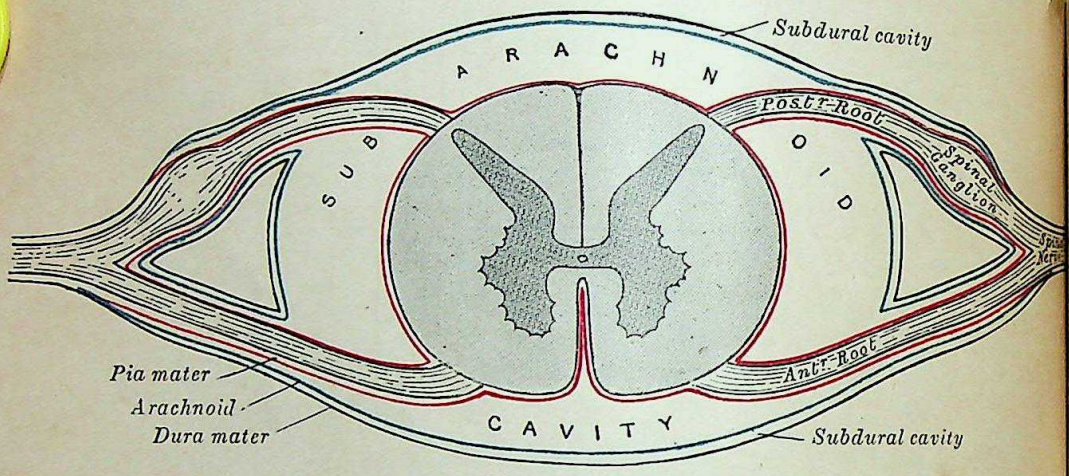

of the brain, dips between the cerebral gyri and between the cerebellar laminæ, and is invaginated to form the tela chorioidea of the third ventricle, and the chorioid plexuses of the lateral and third ventricles (pp. 865, 866); as it passes over the roof of the fourth ventricle, it forms the tela chorioidea and the chorioid plexuses of this ventricle (p. 823). Upon the surfaces of the hemispheres it gives off from its deep surface a multitude of sheaths around the minute vessels that run perpendicularly for some distance into the cerebral substance. On the cerebellum the membrane is more delicate; the vessels from its deep surface are shorter, and its relations to the cortex are not so intimate.

The *spinal pia mater* (figs. 871, 874) is thicker, firmer, and less vascular than the cerebral pia mater; this is due to the fact that it consists of two layers, the outer or additional one being composed of bundles of connective tissue fibres, arranged for the most part longitudinally. Between the layers are cleft-like spaces which communicate with the subarachnoid cavity, and a number of blood-vessels. The spinal pia mater covers the medulla spinalis, and is intimately adherent to it; in front it sends a septum into the anterior fissure. A longitudinal fibrous band, called the *linea splendens*, extends along the middle line of the anterior surface, and a somewhat similar band, the *ligamentum denticulatum*, is situated on either side. Below the conus medullaris the pia mater is continued as a long slender filament, the *filum terminale* (p. 785).

The pia mater forms sheaths for the cerebral and spinal nerves; these sheaths are closely connected with the nerves, and blend with their common membranous investments.

CC-0. In Public Domain. Gurukul Kangri Collection, Haridwar

Digitized by Arya Samaj Foundation Chennai and eGangotri

The **ligamentum denticulatum** (figs. 871, 901) is a narrow fibrous band situated on either side of the medulla spinalis, and separating the anterior from the posterior nerve-roots. Its medial border is continuous with the pia mater at the side of the medulla spinalis. Its lateral border presents a series of triangular tooth-like processes, the points of which are fixed at intervals to the dura mater. These processes are twenty-one in number, on either side. The first process crosses behind the vertebral artery at the point where that vessel pierces the dura mater, and is separated by the artery from the first cervical nerve; it is attached to the dura mater immediately above the margin of the foramen magnum, 1·25 cm. behind the hypoglossal nerve. The last process is between the exits of the twelfth thoracic and first lumbar nerves, and consists of a narrow oblique band running downwards and lateralwards from the conus medullaris (Parsons *).

THE CEREBRAL NERVES

There are twelve pairs of cerebral nerves, which are named from before backwards as follows:

1st. Olfactory.	5th. Trigeminal.	9th. Glossopharyngeal.
2nd. Optic.	6th. Abducent.	10th. Vagus.
3rd. Oculomotor.	7th. Facial.	11th. Accessory.
4th. Trochlear.	8th. Acoustic.	12th. Hypoglossal.

These nerves are attached to the brain, and are transmitted through openings in the base of the cranium. The **motor** or efferent cerebral nerves arise within the brain from groups of nerve-cells which constitute their *nuclei of origin*. They are brought into relationship with the cerebral cortex by the geniculate fibres of the internal capsule; these fibres arise from the cells of the motor area of the cortex, cross the middle line and end by arborising round the cells of the nuclei of origin of the motor cranial nerves. The **sensory** or afferent cerebral nerves arise from nerve-cells outside the brain; these nerve-cells may be grouped to form ganglia on the trunks of the nerves, or may be situated in peripheral sensory organs such as the nose, eye and ear. The centrally directed processes of the cells run into the brain, and there end by arborising around nerve-cells which are grouped to form *nuclei of termination*. Fibres arise from the cells of these nuclei and, after crossing to the opposite side, join the lemniscus, and thus connect the nuclei, directly or indirectly, with the cerebral cortex.

The Olfactory Nerves (fig. 875)

The **olfactory nerves**, or nerves of smell, are distributed to the mucous membrane of the olfactory region of the nasal cavity; this region comprises the superior nasal concha, and the opposed part of the nasal septum. The nerve-fibres originate from the central or deep processes of the olfactory cells of the nasal mucous membrane, and are collected into bundles which cross one another in various directions, and thus give rise to the appearance of a plexiform network in the mucous membrane. They are then collected into about twenty branches, which pierce the lamina cribrosa of the ethmoidal bone in lateral and medial groups, and end in the glomeruli of the olfactory bulb (fig. 876). Each branch receives tubular sheaths from the dura mater and pia mater, the former being continued into the periosteum of the nose, the latter into the neurolemma of the nerve.

The olfactory nerves are non-medullated, and consist of axis-cylinders surrounded by nucleated sheaths, in which, however, there are fewer nuclei than in the sheaths of ordinary non-medullated nerve-fibres.†

* *Proceedings of the Anatomical Society of Great Britain and Ireland*, 1915.

† Closely associated with the olfactory nerves is a pair of small nerves named the *nervi terminales*.

These nerves were first seen in the lower vertebrates, but their presence has been demonstrated in the human embryo and adult. They consist chiefly of non-medullated nerve-fibres, and on

CC-0. In Public Domain. Gurukul Kangri Collection, Haridwar

Digitized by Arya Samaj Foundation Chennai and eGangotri

The olfactory centre in the cortex is generally associated with the rhinencephalon (p. 851).

FIG. 875.—The nerves of the septum of the nose. Right side.

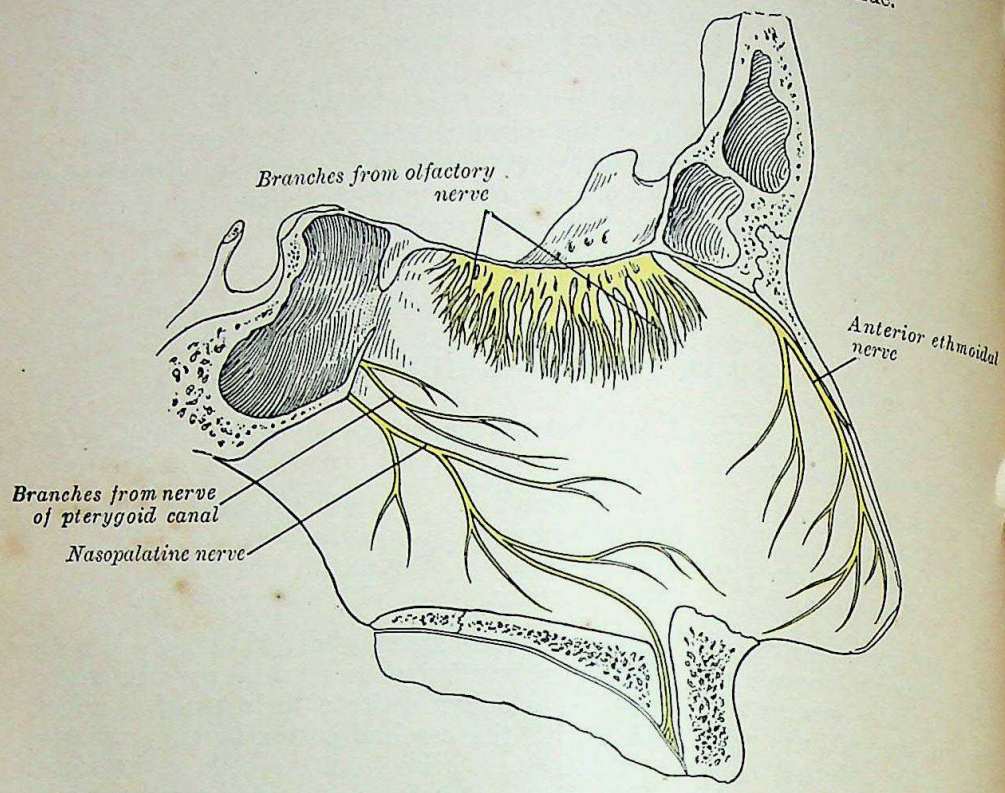

FIG. 876.—A plan of the olfactory neurons.

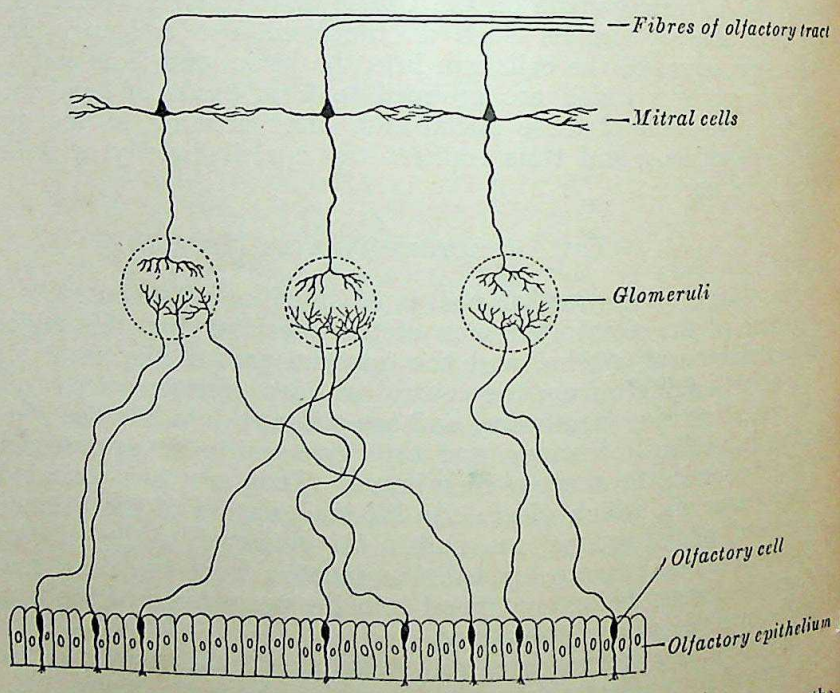

them there are small groups of bipolar and multipolar nerve-cells. Each nerve runs along the medial side of the corresponding olfactory tract, and its branches traverse the lamina cribrosa of the ethmoidal bone, and are distributed to the nasal mucous membrane. Centrally, the nerve is connected to the brain at the olfactory trigone; in some animals its fibres have been traced to the lamina terminalis; in others to the hypothalamic region. Its function is unknown; some are inclined to view it as a motor nerve of the sympathetic which is distributed to the blood-vessels and glands of the nasal cavity.

CC-0. In Public Domain. Gurukul Kangri Collection, Haridwar

Digitized by Arya Samaj Foundation Chennai and eGangotri

Applied Anatomy.—In severe injuries to the head involving the anterior fossa of the base of the skull, the olfactory bulb may become separated from the olfactory nerves or the nerves may be torn, thus producing loss of smell (*anosmia*), and with this there is a considerable loss in the sense of taste, since much of the perfection of the sense of taste is due to the substances being also odorous, and simultaneously exciting the sense of smell.

Anosmia often occurs after influenza or other acute infection of the nose. Parosmia, or a perversion of the sense of smell, may occur in lesions of the cortical olfactory centres, or in insanity.

The Optic Nerve (fig. 877)

The **optic nerve** or nerve of sight is distributed to the bulb of the eye. Most of its fibres are afferent and originate in the nerve-cells of the ganglionic layer of the retina (p. 1001), but a few are efferent and spring from nerve-cells in the lower visual centres of the brain (p. 836). Developmentally, the optic nerves and the retinæ are parts of the brain (p. 101).

Fig. 877.—The left optic nerve, the optic chiasma, and the optic tracts. Inferior aspect.

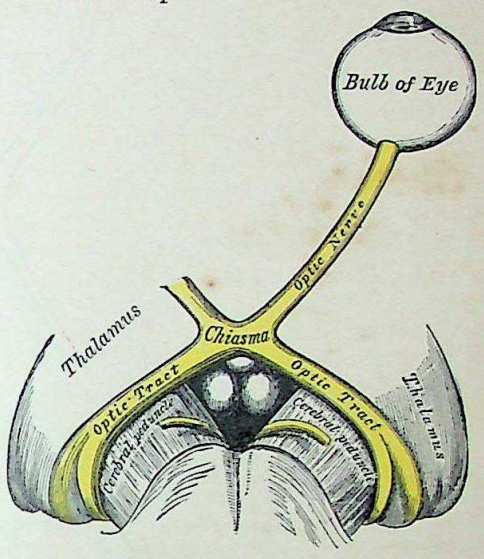

The fibres of the optic nerve form the innermost layer (stratum opticum) of the retina; they converge to the optic disc, and then pierce the chorioid coat and the lamina cribrosa of the sclera at the posterior part of the bulb of the eye, about 3 or 4 mm. to the nasal side of its centre. As the nerve-fibres traverse the lamina cribrosa they receive their medullary sheaths, and run in bundles which are collected to form the optic nerve.

The optic nerve, about 4 cm. long, is directed backwards and medialwards through the posterior part of the orbital cavity. It then runs through the optic foramen into the cranial cavity and joins the optic chiasma.

The intra-orbital part of the nerve is about 25 mm. long and has a slightly sinuous course, the length of the nerve being about 6 mm. more than the distance between the optic foramen and the eyeball. Posteriorly it is closely surrounded by the rectus muscles, but anteriorly is separated from them by a quantity of fat in which the ciliary vessels and nerves are lodged. The ciliary ganglion lies between the nerve and the Rectus lateralis muscle. The inferomedial surface of the nerve is pierced, at a distance of about 12 mm. behind the bulb of the eye, by the central artery and vein of the retina, which are then directed forwards in the centre of the nerve to the optic disc. Near the optic foramen the ophthalmic artery runs forwards and medialwards across the nerve; in the foramen the nerve lies above and medial to the artery, and is separated medially from the sphenoidal and posterior ethmoidal air-sinuses by a thin lamina of bone.

The intracranial part of the optic nerve, about 10 mm. long, runs backwards and medialwards from the optic foramen to the optic chiasma. Above it are the posterior parts of the olfactory tract and gyrus rectus, and, near the chiasma, the anterior cerebral artery. On its lateral side is the internal carotid artery.

The optic nerve consists mainly of fine medullated fibres, and is enclosed in three sheaths which are continuous with the membranes of the brain. The *outer sheath*, derived from the dura mater, is thick and fibrous, and blends anteriorly with the sclera of the bulb of the eye. The *intermediate sheath*, derived from the arachnoid membrane, is thin and delicate. It is separated from the outer sheath by the subdural space, and from the inner sheath by the subarachnoid cavity. The *inner sheath*, derived from the pia mater, is vascular and closely invests the nerve. From its deep surface septa pass into the nerve and subdivide and reunite to enclose what appear, in transverse sections of the nerve, as polygonal areas which are occupied by the bundles of nerve-fibres. From the inner sheath also, an investment is carried on the central vessels of the retina as far as the optic disc.

CC-0. In Public Domain. Gurukul Kangri Collection, Haridwar

Digitized by Arya Samaj Foundation Chennai and eGangotri

The **optic chiasma or commissure**, formed by the union of the two optic nerves, is somewhat quadrilateral in shape; it lies above the tuberculum sellæ and the anterior part of the diaphragma sellæ, some distance behind the so-called sulcus chiasmatis of the sphenoidal bone. It forms the anterior part of the floor of the third ventricle and is in relation above with the lamina terminalis, below with the cisterna chiasmatis which separates it from the anterior part

Fig. 878.—A scheme showing the central connexions of the optic nerves and optic tracts.

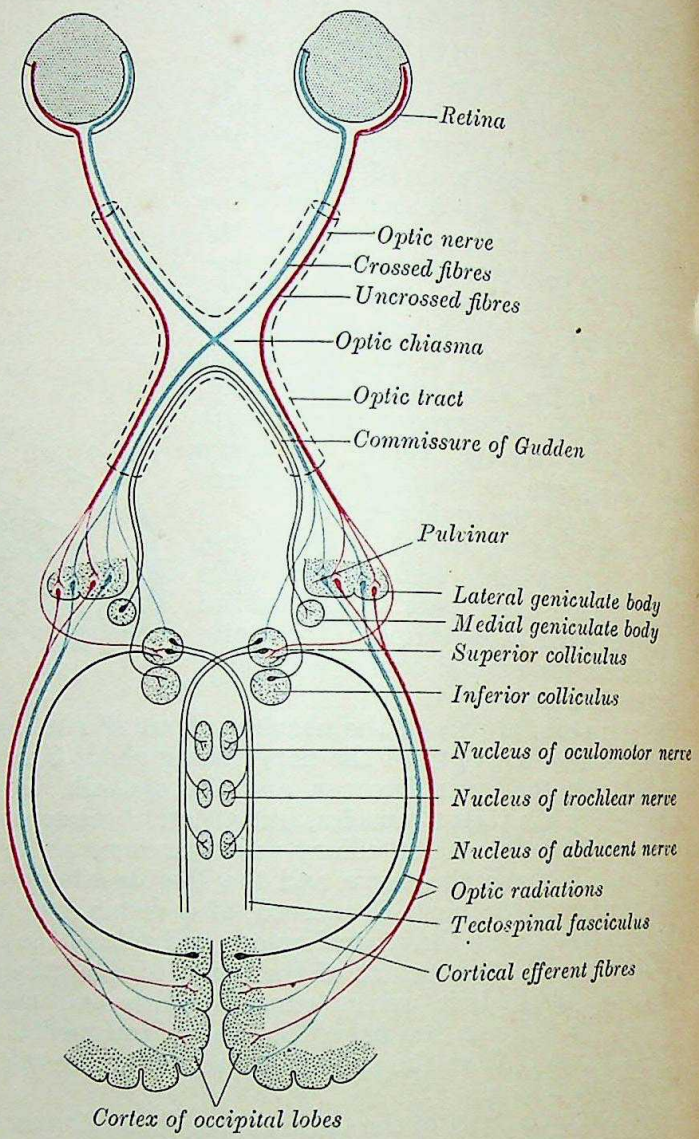

of the diaphragma sellæ, in front with the anterior cerebral and anterior communicating arteries, behind with the tuber cinereum, and laterally with the anterior perforated substance and the internal carotid artery.

The fibres of the optic nerves undergo a partial decussation in the optic chiasma (fig. 878). The fibres from the medial (nasal) half of each retina cross the middle line in the central part of the chiasma and enter the optic tract of the opposite side. The fibres from the lateral (temporal) half of each retina do not cross, but are continued backwards, through the lateral part of the chiasma, into the optic tract of the same side. The posterior part of the chiasma consists of fibres which cross the middle line, but do not form parts of the optic nerves; these fibres connect the medial geniculate body of one side with the inferior colliculus of the opposite side, and constitute what is known as the *commissure of Gudden*.

CC-0. In Public Domain. Gurukul Kangri Collection, Haridwar

Digitized by Arya Samaj Foundation Chennai and eGangotri

The **optic tract** is a cylindrical bundle of nerve-fibres which runs backwards and laterally from the optic chiasma. It passes between the anterior perforated substance and the tuber cinereum and reaches the under surface of the cerebral peduncle, where it becomes flattened. It then winds round and is adherent to the cerebral peduncle, and divides into a medial and a lateral root. The fibres of the medial root form the commissure of Gudden, already referred to; the lateral and larger root ends in the lateral geniculate body, the pulvinar of the thalamus and the superior colliculus (superior quadrigeminal body), which together constitute the *lower visual centres*. From the cells of the lateral geniculate body and the pulvinar fibres, termed the *optic radiations*, take origin, and pass through the occipital part of the internal capsule to the *higher or cortical visual centre*, which is situated in the cuneus and in the neighbourhood of the calcarine fissure. Many efferent fibres from the superior colliculus cross the middle line and descend in the medial longitudinal fasciculus, some ending in the nuclei of the oculomotor, trochlear and abducent nerves, others (tectospinal fibres) passing to the spinal medulla.

Applied Anatomy.—The optic nerve is peculiarly liable to become the seat of neuritis or undergo atrophy in affections of the central nervous system, and as a rule the pathological relationship between the two affections is exceedingly difficult to trace. There are, however, certain points in connexion with the anatomy of this nerve which tend to throw light upon the frequent association of its affections with intracranial disease. (1) From its mode of development, and from its structure, the optic nerve must be regarded as a prolongation of the brain-substance, rather than as an ordinary cerebral nerve. (2) It receives sheaths from the three cerebral membranes, and these sheaths are separated from each other by spaces which communicate with the subdural and subarachnoid cavities respectively. The innermost sheath sends a process around the arteria centralis retinæ into the interior of the nerve, and enters intimately into its structure. Thus inflammatory affections of the meninges or of the brain may readily extend along these spaces, or along the interstitial connective tissue in the nerve.

The optic neuritis or papillitis (" choked disc ") that is often seen in cases of intracranial new growth with increased intracranial tension is probably caused by increased pressure in the sheath of the optic nerve, due to excess of fluid in the general subarachnoid space with which this sheath is in direct communication. If, as is the case, for example in the internal hydrocephalus seen as a complication of cerebro-spinal fever, there is no increase in the amount of fluid in the subarachnoid space, then there will be no optic neuritis although the intracranial tension may rise until it brings about the patient's death.

The course of the fibres in the optic chiasma has an important pathological bearing and has been the subject of much controversy. Microscopic examination, experiments, and pathology all seem to point to the fact that there is a partial decussation of the fibres, each optic tract supplying the corresponding half of each eye, so that the right tract supplies the right half of each eye, and the left tract the left half of each eye. At the same time Charcot believes, and his view has met with general acceptance, that the fibres which do not decussate at the optic chiasma undergo decussation in the corpora quadrigemina, so that the lesion of the cerebral centre of one side causes complete blindness of the opposite eye, because both sets of decussating fibres are destroyed; whereas if one tract, say the right, be destroyed by disease, there will be blindness of the right half of both retinæ.

An anteroposterior section through the chiasma would divide the decussating fibres, and would therefore produce blindness of the medial half of each eye; while a section at the margin of the side of the optic chiasma would produce blindness of the lateral half of the retina of the same side. An early symptom of tumour-growth in the hypophysis is pressure on the chiasma.

The optic nerve may also be affected in injuries or diseases involving the orbit; in fractures of the anterior fossa of the base of the skull; in tumours of the orbit itself, or those invading this cavity from neighbouring parts.

The Oculomotor Nerve (figs. 880 to 882)

The **oculomotor nerve** supplies all the ocular muscles, except the Obliquus superior and Rectus lateralis; it also supplies, through its connexion with the ciliary ganglion, the Sphincter pupillæ and the Ciliaris muscles.

The fibres of the oculomotor nerve arise from a nucleus which lies in the grey substance of the upper part of the floor of the cerebral aqueduct and extends in front of the aqueduct for a short distance into the floor of the third ventricle. From this nucleus the fibres pass forwards through the tegmentum, the red nucleus, and the medial part of the substantia nigra, forming a series

CC-0. In Public Domain. Gurukul Kangri Collection, Haridwar

Digitized by Arya Samaj Foundation Chennai and eGangotri

of curves with a lateral convexity, and emerge from the oculomotor sulcus on the medial side of the cerebral peduncle (fig. 822).

The nucleus of the oculomotor nerve does not consist of a continuous column of cells, but is broken up into a number of smaller nuclei, which are arranged in two groups, anterior and posterior. Those of the posterior group are six in number, five of which are symmetrical on the two sides of the middle line, while the sixth is centrally placed and is common to the nerves of both sides. The anterior group consists of two nuclei, an anteromedial and an anterolateral (fig. 879).

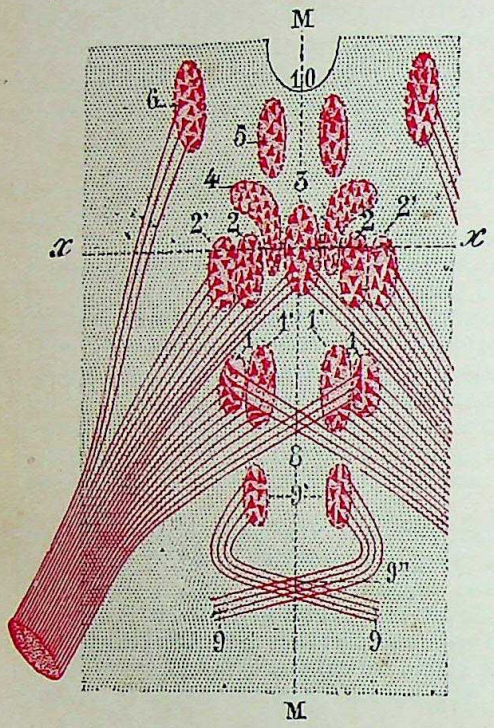

FIG. 879.—A scheme showing the different groups of cells which constitute, according to Perlia, the nucleus of origin of the oculomotor and trochlear nerves. (Testut.)

1. Posterior dorsal nucleus. 1′. Posterior ventral nucleus. 2. Anterior dorsal nucleus. 2′. Anterior ventral nucleus. 3. Central nucleus. 4. Nucleus of Edinger and Westphal. 5. Anteromedial nucleus. 6. Anterolateral nucleus. 8. Crossed fibres. 9. Trochlear nerve, with 9′, its nucleus of origin, and 9″, its decussation. 10. Third ventricle. M, M. Median line.

The nucleus of the nerve is said to send fibres through the medial longitudinal fasciculus to the facial nerve, for the supply of the Orbicularis oculi, Corrugator, and Frontalis muscles.* It is also connected with the nuclei of the trochlear and abducent nerves, with the cerebellum, the superior colliculus, and the cortex of the occipital lobe of the cerebrum.

The nucleus of the oculomotor nerve, considered from a physiological standpoint, can be subdivided into several smaller groups of cells, each group controlling a particular muscle. The nerves to the different muscles appear to take their origin from behind forwards as follows: Rectus inferior, Obliquus inferior, Rectus medialis, Rectus superior, and Levator palpebræ superioris; while from the anterior end of the nucleus the fibres for the Ciliaris, and possibly those for the Sphincter pupillæ, take their origin. Some observers are of opinion that the fibres which supply the Sphincter pupillæ are not derived from the nucleus of the third nerve.†

On emerging from the brain, the nerve is invested with a sheath of pia mater, and enclosed in a prolongation from the arachnoid. It passes between the superior cerebellar and posterior cerebral arteries, runs forward in the cisterna interpeduncularis on the lateral side of the posterior communicating artery. It then perforates the arachnoid membrane and lies in the triangular interval between the free and attached borders of the tentorium cerebelli. Piercing the dura mater on the lateral side of the posterior clinoid process the nerve traverses the lateral wall of the cavernous sinus, where it lies above the trochlear nerve, and receives one or two filaments from the cavernous plexus of the sympathetic, and a branch from the ophthalmic division of the trigeminal. It then divides into a superior and an inferior ramus, which enter the orbit through the superior orbital fissure, within the annulus tendineus which gives origin to the Recti muscles; here the nasociliary nerve is placed between the two rami.

The *superior ramus*, the smaller, ascends on the lateral side of the optic nerve, and supplies the Rectus superior and Levator palpebræ superioris. The *inferior ramus* divides into three branches (fig. 880). One passes beneath the optic nerve to the Rectus medialis; another goes to the Rectus inferior; the third and longest runs forwards between the Rectus inferior and Rectus lateralis,

* See footnote, p. 828.

† Consult an article on 'Ocular palsies' by Leslie Paton, *British Journal of Ophthalmology*, vol. v. No. 6, June, 1921.

CC-0. In Public Domain. Gurukul Kangri Collection, Haridwar

Digitized by Arya Samaj Foundation Chennai and eGangotri

to the Obliquus inferior. From the nerve to the Obliquus inferior a short thick branch is given to the lower part of the ciliary ganglion, and forms its *short* or *parasympathetic root*. The branches enter the muscles on their ocular surfaces, with the exception of that to the Obliquus inferior, which enters the posterior border of the muscle.

FIG. 880.—A plan of the oculomotor nerve.

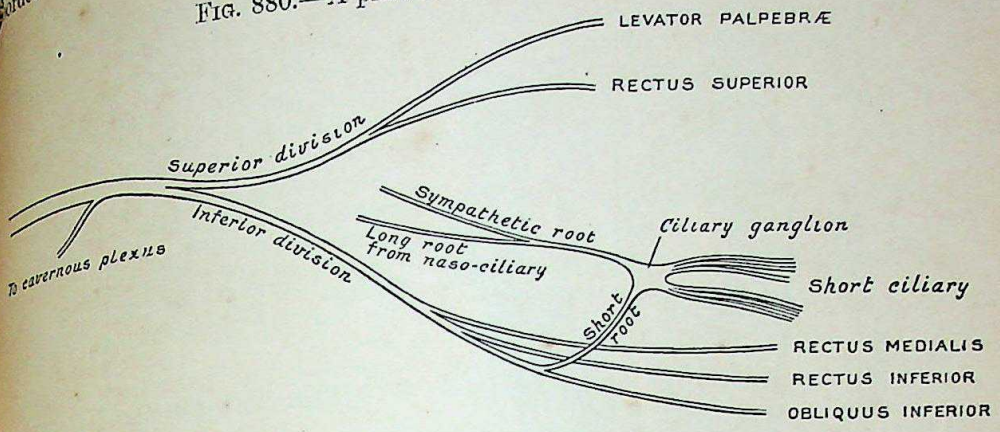

Applied Anatomy.—Paralysis of the oculomotor nerve may be the result of various causes, such as cerebral disease; or conditions causing pressure on the cavernous sinus; or periostitis of the bones entering into the formation of the superior orbital fissure. It leads, when complete, to (1) ptosis, or drooping of the upper eyelid, in consequence of the Levator palpebræ superioris being paralysed; (2) external strabismus, on account of the unopposed action of the Rectus lateralis and Obliquus superior, which are not supplied by the oculomotor nerve and are therefore not paralysed; (3) dilatation of the pupil, because the Sphincter pupillæ is paralysed; (4) loss of power of accommodation and of contraction on exposure to light, as the Sphincter pupillæ and the Ciliaris are paralysed; (5) slight prominence of the eyeball, owing to most of its muscles being relaxed; and (6) diplopia, or double vision, the false image being higher than the true, and the separation of the two images increasing with medial movements. Occasionally paralysis may affect only a part of the nerve—that is to say, there may be, for example, a dilated and fixed pupil, with ptosis, but no other signs. Irritation of the nerve causes spasm of one or other of the muscles supplied by it; thus, there may be internal strabismus from spasm of the Rectus medialis; accommodation for near objects only, from spasm of the Ciliaris; or miosis (contraction of the pupil) from irritation of the Sphincter pupillæ.

The oculomotor nerve is particularly liable to become involved in a syphilitic periarteritis, as it leaves the base of the brain, when passing between the posterior cerebral and superior cerebellar arteries.

THE TROCHLEAR NERVE (fig. 881)

The **trochlear nerve**, the smallest of the cerebral nerves, supplies the Obliquus superior oculi.

It arises from a nucleus situated in the floor of the cerebral aqueduct, opposite the upper part of the inferior colliculus. From its origin it runs downwards through the tegmentum, and then turns backwards into the upper part of the anterior medullary velum. Here it decussates with its fellow, and reaching the opposite side, emerges from the surface of the velum at the side of the frenulum veli, immediately behind the inferior colliculus.

The nerve is directed across the brachium conjunctivum cerebelli, and then winds forwards round the cerebral peduncle immediately above the pons, and between the posterior cerebral and superior cerebellar arteries. It appears between the border of the pons and the temporal lobe, and pierces the dura mater immediately below the free border of the tentorium cerebelli, a little behind the posterior clinoid process, and passes forwards in the lateral wall of the cavernous sinus, below the oculomotor nerve and above the ophthalmic division of the trigeminal nerve. Near the front of the sinus it crosses the oculomotor nerve, and enters the orbit through the superior orbital fissure, above the ocular muscles, and medial to the frontal nerve. In the orbit it passes medialwards, above the origin of the Levator palpebræ superioris, and finally enters the orbital surface of the Obliquus superior.

CC-0. In Public Domain. Gurukul Kangri Collection, Haridwar

Digitized by Arya Samaj Foundation Chennai and eGangotri

In the lateral wall of the cavernous sinus the trochlear nerve is joined by a branch from the ophthalmic division of the trigeminal nerve, and communicates with the cavernous plexus of the sympathetic. In the superior orbital fissure it occasionally gives off a branch to the lacrimal nerve.

FIG. 881.—The nerves of the right orbit. Superior aspect.

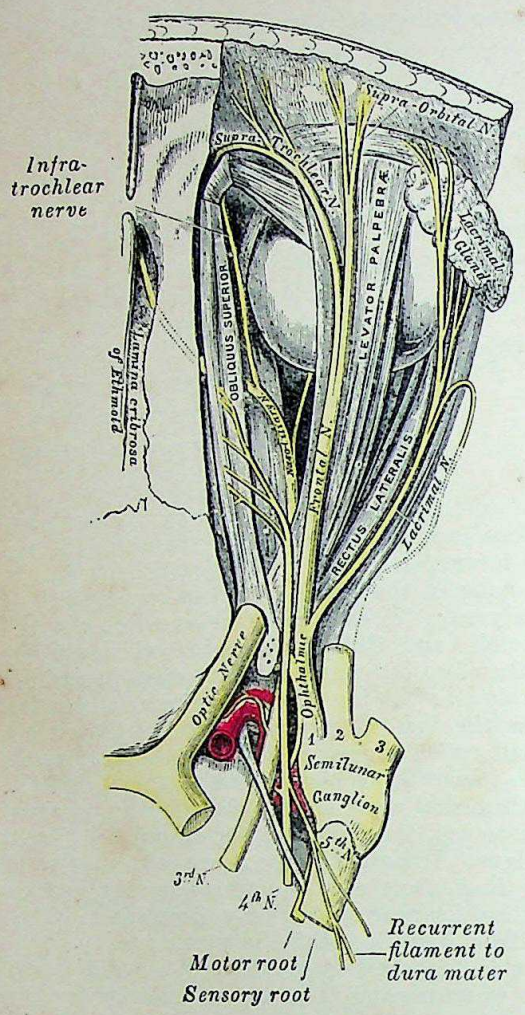

Applied Anatomy.—When the trochlear nerve is paralysed there is loss of function in the Obliquus superior, so that the patient is unable to turn his eye downwards and outwards. Should the patient attempt to do this, the eye of the affected side is rotated inwards, producing diplopia or double vision. Single vision exists in the whole of the field so long as the eyes look above the horizontal plane, diplopia occurs on looking downwards. To counteract this the patient holds his head forwards, and also inclines it to the sound side.

THE TRIGEMINAL NERVE

The **trigeminal nerve** is the largest cerebral nerve. It is the sensory nerve of the face and of the greater part of the scalp, and the motor nerve of the muscles of mastication. It divides into three nerves, viz. the ophthalmic, the maxillary, and the mandibular.

It is attached to the anterior or ventral surface of the pons, near its upper border, by a large sensory, and a small motor, root—the latter being placed medial and anterior to the former.

The fibres of the *sensory root* arise from the cells of the *semilunar ganglion* (Gasserian ganglion). This ganglion (figs. 881, 882) occupies a cavity (cavum Meckelii) in the dura mater covering the trigeminal impression near the apex of the petrous part of the temporal bone. The ganglion is somewhat crescentic in shape, with its convexity directed forwards and lateralwards. Medially, it is in relation with the internal carotid artery and the posterior part of the cavernous sinus. Beneath it are the motor root of the nerve, and the greater superficial petrosal nerve. It receives filaments from the cavernous plexus of the sympathetic, and gives twigs to the tentorium cerebelli.

The axis-cylinders of the cells of the semilunar ganglion divide into peripheral and central branches. The former are grouped to form the *ophthalmic* and *maxillary* nerves, and the sensory part of the *mandibular* nerve. The central branches constitute the fibres of the sensory root of the nerve, which leaves the concave margin of the ganglion, runs backwards and medialwards below the superior petrosal sinus and the tentorium cerebelli, and enters the pons. In the pons these fibres divide into ascending and descending branches. The ascending branches end in the upper sensory nucleus of the trigeminal nerve, which is situated in the pons, lateral to, and somewhat deeper than, the motor nucleus. The descending branches form what is named the *spinal tract* of the trigeminal nerve. This tract runs downwards through the pons into the medulla oblongata superficial to a nucleus of grey substance which is continuous inferiorly with the gelatinous substance of Rolando. As the tract descends, a succession of fibres leaves it and enters the nucleus, and the tract gradually diminishes in size, and finally ends in the upper part of the cervical portion of the medulla spinalis.

CC-0. In Public Domain. Gurukul Kangri Collection, Haridwar

Digitized by Arya Samaj Foundation Chennai and eGangotri

Medullation of the fibres of the sensory root begins about the fifth month of fœtal life, but all of its fibres are not medullated until the third month after birth.

The fibres of the *motor root* arise from two nuclei, an inferior and a superior. The *inferior or chief nucleus* is situated in the upper part of the pons, close to its dorsal surface, and along the line of the lateral margin of the rhomboid fossa. The *superior nucleus* consists of a strand of cells occupying the whole length of the lateral portion of the grey substance of the cerebral aqueduct. The fibres from this nucleus constitute the *mesencephalic root* * ; they descend through the mesencephalon, and, entering the pons, join with the fibres from the lower nucleus, and the motor root, thus formed, passes forwards through the pons to its point of emergence.

Four small ganglia are associated with the three divisions of the trigeminal nerve, viz.—the *ciliary ganglion* with the ophthalmic nerve ; the *sphenopalatine ganglion* with the maxillary nerve ; and the *otic* and *submaxillary ganglia* with the mandibular nerve.

The Ophthalmic Nerve (figs. 881, 882)

The **ophthalmic nerve**, the first division of the trigeminal nerve, is a sensory nerve. It supplies branches to the bulb of the eye, the lacrimal gland and the conjunctiva, to a part of the mucous membrane of the nasal cavity, and to the skin of the nose, eyelids, forehead, and scalp. It is the smallest division of the trigeminal nerve, and arises from the anteromedial part of the semilunar ganglion as a flattened band, about 2·5 cm. long, which passes forwards along the lateral wall of the cavernous sinus below the oculomotor and trochlear nerves ; just before entering the orbit through the superior orbital fissure, it divides into three branches, *lacrimal*, *frontal*, and *nasociliary*.

The ophthalmic nerve is joined by filaments from the cavernous plexus of the sympathetic, and gives twigs to the oculomotor, trochlear, and abducent nerves ; it supplies a recurrent branch (n. tentorii), which crosses and adheres to the trochlear nerve, and is distributed to the tentorium cerebelli.

The **lacrimal nerve** (fig. 881) is the smallest branch of the ophthalmic nerve. It sometimes receives a filament from the trochlear nerve, but possibly this filament consists of fibres which have previously passed from the ophthalmic to the trochlear nerve. The lacrimal nerve enters the orbit through the lateral part of the superior orbital fissure, runs along the upper border of the Rectus lateralis with the lacrimal artery, and sends downwards a branch to join the zygomatic branch of the maxillary nerve. It enters the lacrimal gland and gives off several filaments to the gland and the conjunctiva. Finally it pierces the orbital septum, and ends in the skin of the upper eyelid, joining with filaments of the facial nerve.

The lacrimal nerve is occasionally absent, and its place is then taken by the zygomaticotemporal branch of the maxillary nerve. Sometimes the latter branch is absent, and a continuation of the lacrimal is substituted for it.

The **frontal nerve** (figs. 881, 882) is the largest branch of the ophthalmic nerve. It enters the orbit through the superior orbital fissure above the muscles, and runs forwards between the Levator palpebræ superioris and the periosteum. About midway between the apex and base of the orbit it divides into two branches, a small supratrochlear and a larger supra-orbital.

The *supratrochlear nerve* runs medialwards and forwards, passes above the pulley of the Obliquus superior, and gives off a descending filament, to join the infratrochlear branch of the nasociliary nerve. The nerve then emerges from the orbit between the pulley of the Obliquus superior and the supra-orbital foramen, curves upwards on the forehead close to the bone in company with the frontal branch of the ophthalmic artery, and sends filaments to the conjunctiva and skin of the upper eyelid ; it then ascends under cover of the Corrugator and Frontalis, and divides into branches which pierce these muscles and supply the skin of the lower part of the forehead close to the middle line.

* Some are of opinion that the mesencephalic root of the trigeminal nerve consists of sensory fibres.

CC-0. In Public Domain. Gurukul Kangri Collection, Haridwar

Digitized by Arya Samaj Foundation Chennai and eGangotri

The *supra-orbital nerve* passes through the supra-orbital foramen, and gives off palpebral filaments to the upper eyelid. It then ascends upon the forehead with the supra-orbital artery, and divides into a smaller medial, and a larger lateral, branch, which supply the skin of the scalp, reaching nearly as far back as the lambdoid suture. These two branches are at first situated beneath the Frontalis; the medial branch perforates this muscle, the lateral branch pierces the galea aponeurotica. Both branches supply small twigs to the pericranium and to the mucous membrane of the frontal air-sinus.

The **nasociliary nerve** (figs. 881, 882) is intermediate in size between the frontal and lacrimal nerves, and is more deeply placed. It enters the orbit through the medial part of the superior orbital fissure within the annulus tendineus which gives origin to the Recti muscles of the eyeball, and here it is situated between the two rami of the oculomotor nerve. It crosses the optic nerve with the ophthalmic artery, and runs obliquely beneath the Rectus superior and Obliquus superior, to the medial wall of the orbital cavity. Here, under the name of the *anterior ethmoidal nerve* it passes through the anterior

FIG. 882.—The nerves of the right orbit, and the ciliary ganglion. Lateral aspect.

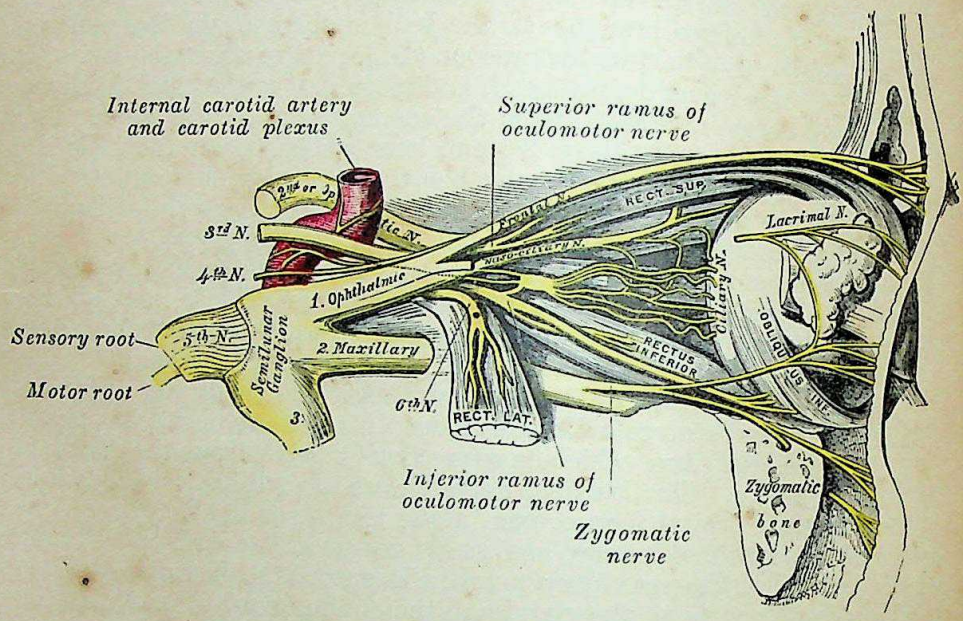

ethmoidal foramen and, entering the cavity of the cranium, traverses a shallow groove on the lateral margin of the front part of the lamina cribrosa of the ethmoidal bone, beneath the dura mater; it then descends through a slit at the side of the crista galli into the nasal cavity, and lies in a groove on the inner surface of the nasal bone. It supplies two *internal nasal branches*—a medial to the mucous membrane of the front part of the nasal septum, and a lateral to the anterior part of the lateral wall of the nasal cavity. Finally, it emerges, as the *external nasal branch*, between the lower border of the nasal bone and the lateral nasal cartilage, and, passing down beneath the Nasalis muscle, supplies the skin of the ala and apex of the nose.

The nasociliary nerve gives off the long root of the ciliary ganglion, the long ciliary, the infratrochlear, and the posterior ethmoidal nerves.

The *long* or *sensory root of the ciliary ganglion* usually arises from the nasociliary nerve as the latter enters the orbital cavity. It passes forwards on the lateral side of the optic nerve, and enters the posterosuperior angle of the ciliary ganglion; it is sometimes joined by a filament from the cavernous plexus of the sympathetic, or from the superior ramus of the oculomotor nerve.

The *long ciliary nerves*, two or three in number, are given off from the nasociliary nerve, as it crosses the optic nerve. They accompany the short ciliary nerves from the ciliary ganglion, pierce the sclera around the attachment of the optic nerve, and, running forwards between the sclera and the chorioid, are

CC-0. In Public Domain. Gurukul Kangri Collection, Haridwar

Digitized by Arya Samaj Foundation Chennai and eGangotri

distributed to the ciliary body, iris, and cornea; they contain the sympathetic fibres for the Dilatator pupillæ.

The *infratrochlear nerve* is given off from the nasociliary nerve near the anterior ethmoidal foramen. It runs forwards along the medial wall of the orbit above the upper border of the Rectus medialis, and is joined, near the pulley of the Obliquus superior, by a filament from the supratrochlear nerve. It then escapes from the orbit beneath the pulley of the Obliquus superior; it supplies branches to the skin of the eyelids and side of the nose, the conjunctiva, lacrimal sac, and caruncula lacrimalis.

The *posterior ethmoidal nerve* leaves the orbital cavity through the posterior ethmoidal foramen and gives twigs to the ethmoidal and sphenoidal air-sinuses. This nerve is absent in about thirty per cent. of subjects.

FIG. 883.—A scheme showing the roots and the branches of distribution of the ciliary ganglion.

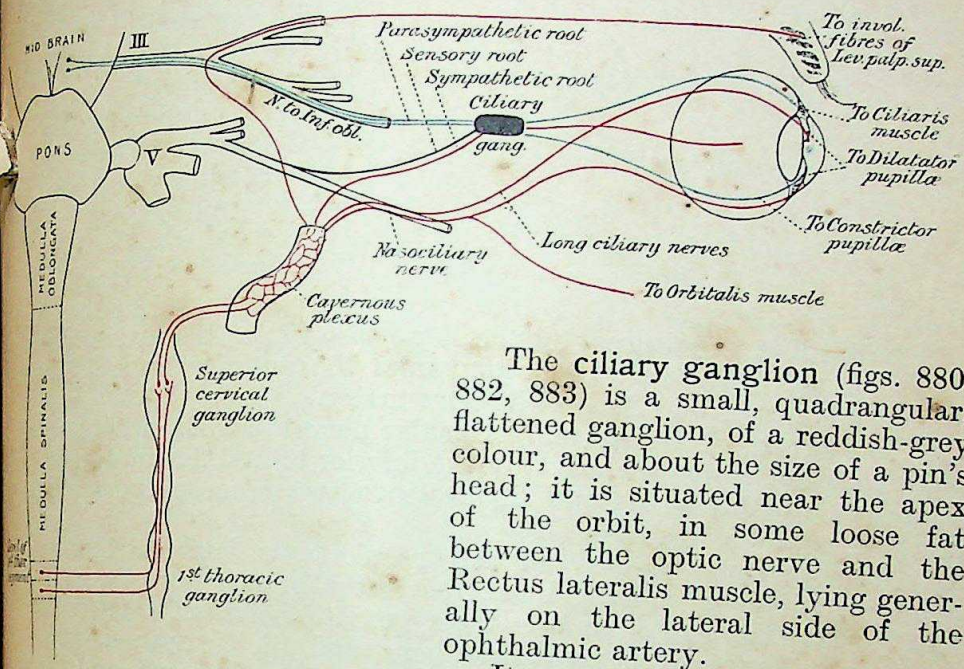

The **ciliary ganglion** (figs. 880 882, 883) is a small, quadrangular, flattened ganglion, of a reddish-grey colour, and about the size of a pin's head; it is situated near the apex of the orbit, in some loose fat between the optic nerve and the Rectus lateralis muscle, lying generally on the lateral side of the ophthalmic artery.

Its *roots* (fig. 883) are three in number, and enter its posterior ...er. One, the long or sensory root, is derived from the nasociliary nerve, ...joins the posterosuperior angle of the ganglion. The second, the short or ...sympathetic root, is a thick nerve (occasionally divided into two parts) ...ived from the branch of the oculomotor nerve to the Obliquus inferior, and ...nnected with the postero-inferior angle of the ganglion. The third, the ...mpathetic root, is a slender filament from the cavernous plexus of the ...mpathetic; it is frequently blended with the long root.

Its *branches* are the short ciliary nerves. These are delicate filaments, ...n six to ten in number, which arise from the front of the ganglion in two ...dles connected with its superior and inferior angles; the lower bundle ...the larger. They run forwards with the ciliary arteries in a wavy course, ...set above, the other below the optic nerve, and are accompanied by ...long ciliary nerves. They subdivide into about fifteen or twenty branches ...h pierce the sclera around the entrance of the optic nerve, pass forwards ...delicate grooves on the inner surface of the sclera, and are distributed to the ...ous muscle, iris, and cornea. Tiedemann described a small branch which ...ated the optic nerve with the arteria centralis retinæ.

THE MAXILLARY NERVE (fig. 884)

The **maxillary nerve**, or second division of the trigeminal nerve, is a ...ry nerve, and is intermediate in position and size between the ophthalmic ...mandibular nerves. It begins at the middle of the semilunar ganglion

CC-0. In Public Domain. Gurukul Kangri Collection, Haridwar

Digitized by Arya Samaj Foundation Chennai and eGangotri

as a flattened plexiform band, and, passing horizontally forwards in the lower part of the lateral wall of the cavernous sinus, leaves the skull through the foramen rotundum, where it becomes more cylindrical in form and firmer in texture. It then crosses the upper part of the pterygopalatine (spheno-maxillary) fossa, inclines lateralwards on the posterior surface of the orbital process of the palatine bone and on the upper part of the infratemporal surface of the maxilla, and enters the orbit through the inferior orbital fissure; it traverses the infra-orbital groove and canal in the floor of the orbit, and appears on the face through the infra-orbital foramen.* At its termination, the nerve lies beneath the Quadratus labii superioris, and divides into branches which are distributed to the side of the nose, the lower eyelid, and the upper lip, and join with filaments of the facial nerve.

The *branches* of the maxillary nerve may be divided into four groups, according as they are given off in the cranium, in the pterygopalatine fossa, in the infra-orbital canal, or on the face.

In the cranium . . .	Middle meningeal.
In the pterygopalatine fossa .	Zygomatic. Sphenopalatine. Posterior superior alveolar.
In the infra-orbital canal .	Middle superior alveolar. Anterior superior alveolar.
On the face	Inferior palpebral. External nasal. Superior labial.

The **middle meningeal nerve** is given off from the maxillary nerve near the semilunar ganglion; it accompanies the anterior branch of the middle meningeal artery and supplies the dura mater.

The **zygomatic nerve** (temporomalar nerve) (fig. 882) arises in the pterygopalatine fossa, enters the orbit by the inferior orbital fissure, courses along the lateral wall of the orbit, and divides into two branches, zygomaticotemporal and zygomaticofacial.

The *zygomaticotemporal branch* runs along the lateral wall of the orbit in a groove in the zygomatic bone, receives a branch from the lacrimal nerve, and, passing through a canal in the zygomatic bone, enters the temporal fossa. It ascends between the temporal bone and the Temporalis muscle, pierces the temporal fascia about 2 cm. above the zygomatic arch, and is distributed to the skin of the side of the forehead. It communicates with the facial nerve and with the auriculotemporal branch of the mandibular nerve. As it pierces the temporal fascia, it sends a slender twig between the two layers of the fascia to the lateral angle of the orbit.

The *zygomaticofacial branch* passes along the inferolateral angle of the orbit, emerges upon the face through a foramen in the zygomatic bone, and, perforating the Orbicularis oculi, supplies the skin on the prominence of the cheek. It joins the zygomatic branches of the facial nerve and the inferior palpebral branches of the maxillary nerve.

The **sphenopalatine branches**, two in number, descend towards the sphenopalatine ganglion, but only a few of their fibres enter the ganglion (p. 898).

The **posterior superior alveolar branches** (fig. 884) arise from the maxillary nerve just before it enters the infra-orbital groove; they are generally two in number, but sometimes they arise by a single trunk. They descend on the tuberosity of the maxilla and give off several twigs to the gums and neighboring parts of the mucous membrane of the cheek. They then enter the posterior alveolar canals on the infratemporal surface of the maxilla, and, passing forwards in the substance of the bone, communicate with the middle superior alveolar nerve, and give off branches to the lining membrane of the maxillary air-sinus and twigs to each molar tooth; these twigs enter the foramina at the apices of the roots of the teeth.

The **middle superior alveolar branch** is given off from the maxillary nerve in the posterior part of the infra-orbital canal, and runs downwards

CC-0. In Public Domain. Gurukul Kangri Collection, Haridwar

* After it enters the infra-orbital canal, the nerve is frequently called the *infra-orbital*

Digitized by Arya Samaj Foundation Chennai and eGangotri

forwards in a canal in the lateral wall of the maxillary air-sinus to supply the two premolar teeth. It forms a superior dental plexus with the anterior and posterior superior alveolar branches.

The **anterior superior alveolar branch** (fig. 884) leaves the lateral side of the maxillary nerve in the front part of the infra-orbital canal, and runs in a canal in the anterior wall of the maxillary air-sinus. At first it curves beneath the infra-orbital foramen and passes medialwards towards the nose; it then turns downwards and divides into branches which supply the incisor and canine teeth. It communicates with the middle superior alveolar branch, and gives off a *nasal branch*, which passes through a minute canal in the lateral wall of

FIG. 884.—The right maxillary and mandibular nerves, and the submaxillary ganglion.

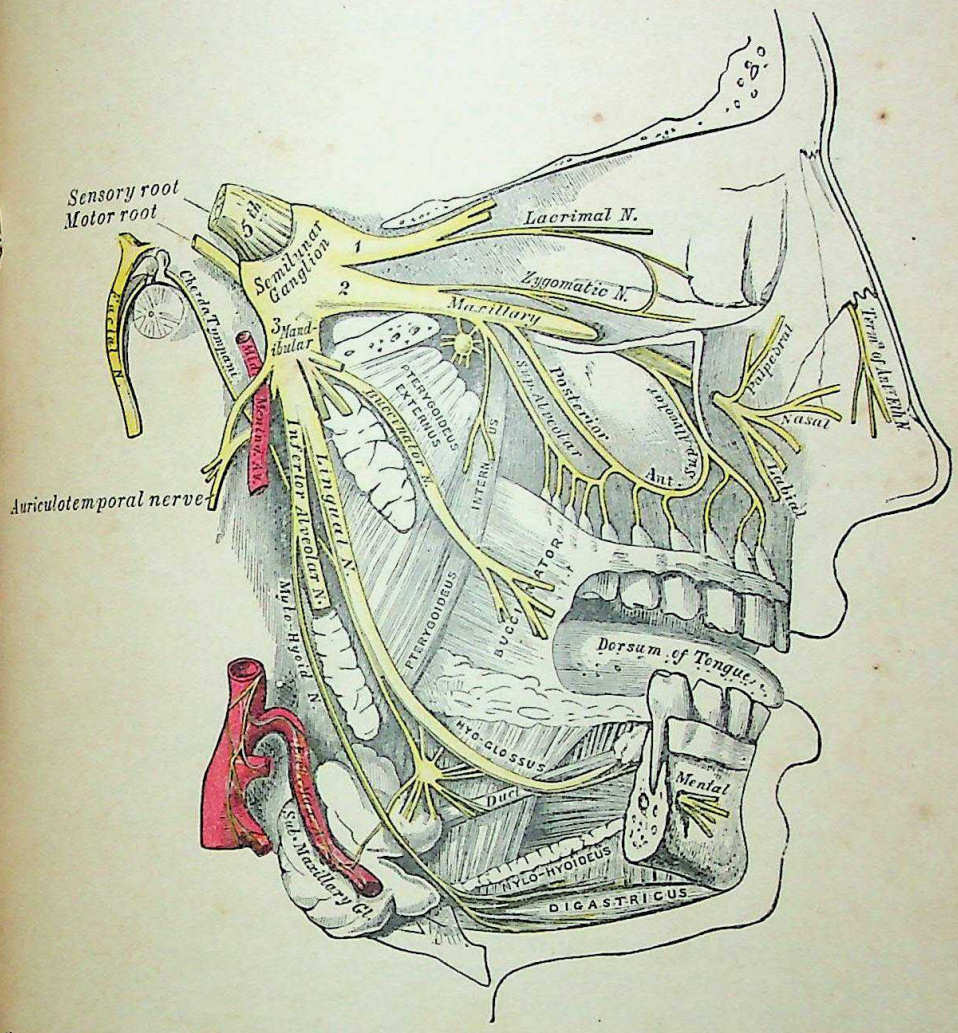

the inferior meatus, and supplies the mucous membrane of the anterior part of the inferior meatus and the floor of the nasal cavity, communicating with the nasal branches from the sphenopalatine ganglion.

The **inferior palpebral branches** ascend behind the Orbicularis oculi. They supply the skin and conjunctiva of the lower eyelid, and join with the facial and zygomaticofacial nerves at the lateral angle of the orbit.

The **external nasal branches** supply the skin of the side of the nose and of the septum mobile nasi, and join with the external nasal branch of the anterior ethmoidal nerve.

The **superior labial branches** are large and numerous; they descend behind the Quadratus labii superioris, and supply the skin of the upper lip, the mucous membrane of the mouth, and the labial glands. They are joined by branches from the facial nerve, and form with them the *infra-orbital plexus*.

CC-0. In Public Domain. Gurukul Kangri Collection, Haridwar

Digitized by Arya Samaj Foundation Chennai and eGangotri

The **sphenopalatine ganglion** (ganglion of Meckel) (fig. 885), the largest of the ganglia associated with the branches of the trigeminal nerve, is deeply placed in the pterygopalatine fossa, close to the sphenopalatine foramen and in front of the pterygoid canal. It is triangular or heart-shaped, of a reddish-grey colour, and is situated just below the maxillary nerve as it crosses the fossa. It receives sensory, parasympathetic, and sympathetic roots (fig. 886).

Its *sensory roots* are derived from the two sphenopalatine branches of the maxillary nerve; most of the fibres of these branches do not enter the ganglion but pass directly into the branches which spring from the ganglion. Its *parasympathetic root* is probably derived from the facial nerve through the greater superficial petrosal nerve, and its *sympathetic root* from the carotid plexus through the deep petrosal nerve; before entering the ganglion these two nerves join to form the nerve of the pterygoid canal.

Fig. 885.—The right sphenopalatine ganglion and its branches.

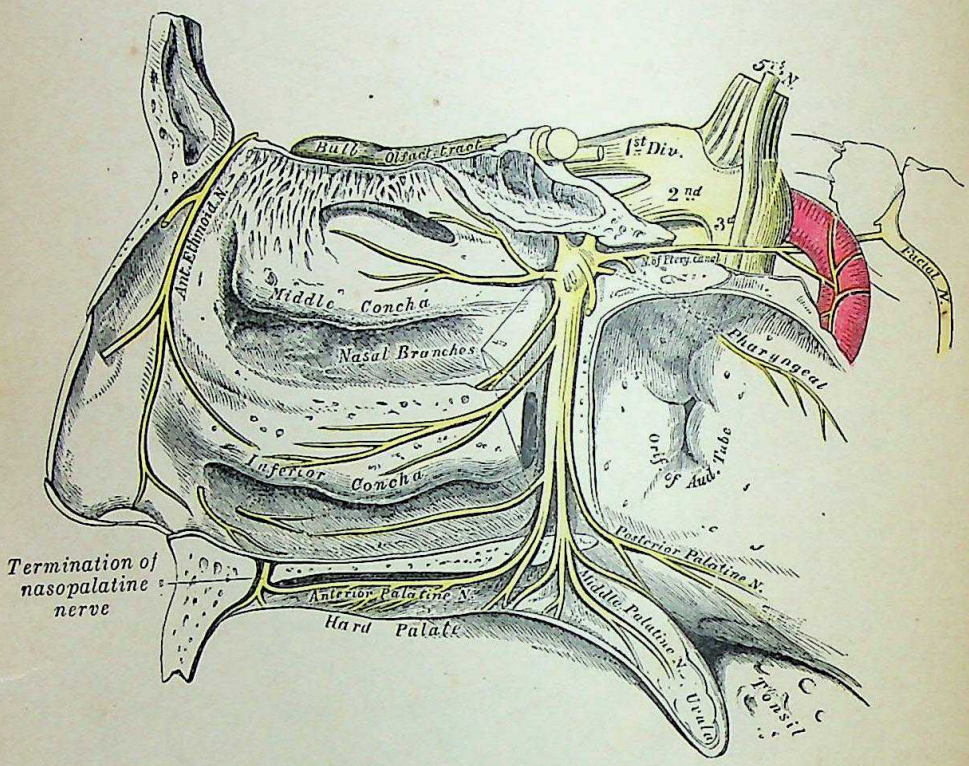

The *greater superficial petrosal nerve* is given off from the genicular ganglion of the facial nerve; it receives a branch from the tympanic plexus, passes through the hiatus of the facial canal, enters the cranial cavity, and runs forwards beneath the dura mater in a groove on the anterior surface of the petrous portion of the temporal bone. It then enters the cartilaginous substance which fills the foramen lacerum, and unites with the deep petrosal nerve to form the nerve of the pterygoid canal.

The *deep petrosal nerve* is given off from the carotid plexus, and runs through the carotid canal lateral to the internal carotid artery. It then enters the cartilaginous substance which fills the foramen lacerum, and joins with the greater superficial petrosal nerve to form the nerve of the pterygoid canal.

The *nerve of the pterygoid canal* (Vidian nerve), formed by the junction of the two preceding nerves in the cartilaginous substance which fills the foramen lacerum, is accompanied through the pterygoid canal by the corresponding artery, and is joined by a small ascending *sphenoidal branch* from the otic ganglion. Finally, it enters the pterygopalatine fossa, and joins the sphenopalatine ganglion.

The *branches* of the sphenopalatine ganglion are divisible into four groups, viz. orbital, palatine, posterior superior nasal, and pharyngeal.

CC-0. In Public Domain. Gurukul Kangri Collection, Haridwar

Digitized by Arya Samaj Foundation Chennai and eGangotri

The *orbital branches* are two or three delicate filaments, which enter the orbit by the inferior orbital fissure, and are distributed to the periosteum, the orbitalis muscle, and the lacrimal gland; twigs pass through the posterior ethmoidal foramen to the sphenoidal and ethmoidal air-sinuses.

The *palatine nerves* are distributed to the roof of the mouth, the soft palate, the tonsil, and the lining membrane of the nasal cavity. Most of their fibres are derived from the sphenopalatine branches of the maxillary nerve. They are three in number: anterior, middle, and posterior.

The *anterior palatine nerve* descends through the pterygopalatine canal, emerges upon the hard palate through the greater palatine foramen, and runs forwards in a groove on the inferior surface of the hard palate, nearly as far as the incisor teeth. It supplies the gums, and the mucous membrane and glands

Fig. 886.—A scheme showing the roots and the branches of distribution of the sphenopalatine ganglion.

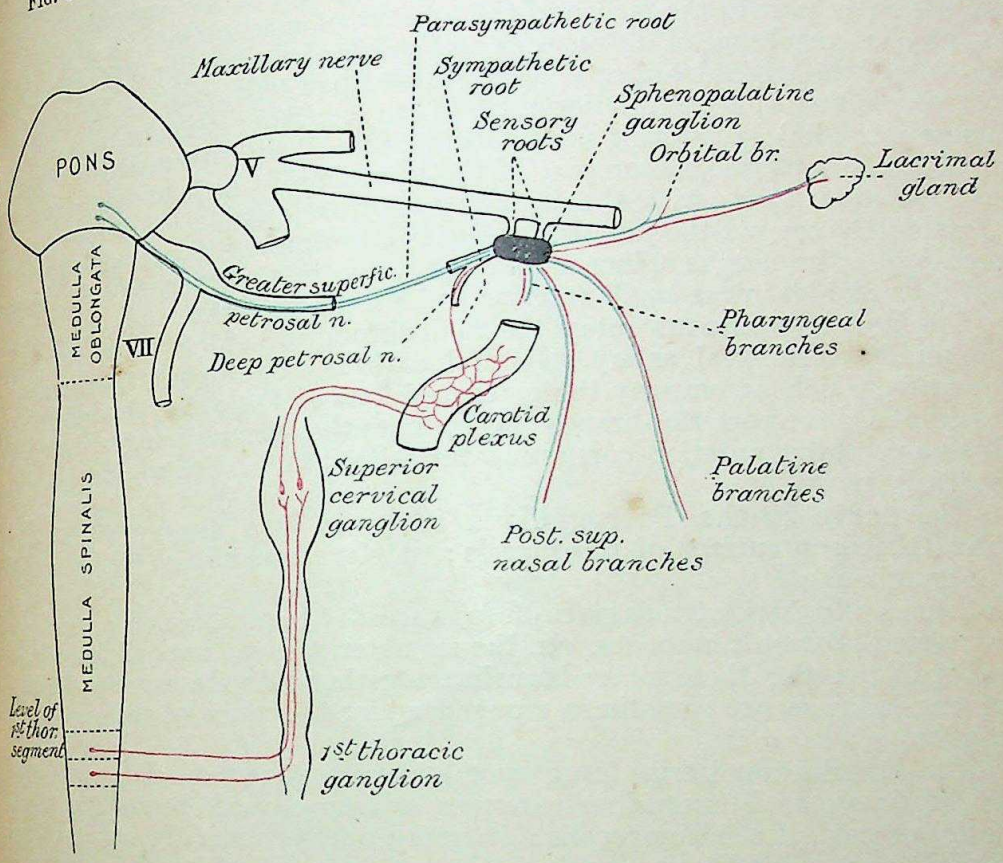

of the hard palate, and communicates in front with the terminal filaments of the nasopalatine nerve. While in the pterygopalatine canal, it gives off *posterior inferior nasal branches*, which enter the nasal cavity through openings in the vertical part of the palatine bone, and ramify over the inferior nasal concha and middle and inferior meatuses; at its exit from the canal, palatine branches are distributed to both surfaces of the soft palate.

The *middle palatine nerve* descends through the pterygopalatine canal, emerges through one of the lesser palatine foramina and supplies branches to the uvula, tonsil, and soft palate.

The *posterior palatine nerve* descends through the pterygopalatine canal and emerges through one of the lesser palatine foramina; it supplies the uvula tonsil, and soft palate. The middle and posterior palatine nerves form, with the tonsillar branches of the glossopharyngeal nerve, a plexus around the tonsil.

The *posterior superior nasal branches* enter the posterior part of the nasal cavity through the sphenopalatine foramen, and supply the mucous membrane covering the superior and middle nasal conchæ, the lining of the posterior ethmoidal air-sinuses, and the posterior part of the nasal septum. One branch, longer and larger than the others, is named the *nasopalatine nerve*. It crosses

CC-0. In Public Domain. Gurukul Kangri Collection, Haridwar

Digitized by Arya Samaj Foundation Chennai and eGangotri

the roof of the nasal cavity below the orifice of the sphenoidal air-sinus, and then runs obliquely downwards and forwards between the periosteum and mucous membrane of the lower part of the septum. It descends to the roof of the mouth through the incisive canal, and communicates with the corresponding nerve of the opposite side and with the anterior palatine nerve. It furnishes a few filaments to the mucous membrane of the nasal septum.

The *pharyngeal nerve*, a small branch, arises from the posterior part of the ganglion, passes through the pharyngeal canal with the pharyngeal branch of the internal maxillary artery, and is distributed to the mucous membrane of the nasal part of the pharynx, behind the auditory tube.

The Mandibular Nerve (figs. 884, 887)

The **mandibular nerve** (inferior maxillary nerve) supplies the teeth and gums of the mandible, the skin of the temporal region, the auricula, the lower lip, the lower part of the face, and the muscles of mastication; it also supplies the mucous membrane of the anterior two-thirds of the tongue. It is the largest division of the trigeminal nerve, and is made up of two roots: a large, sensory root proceeding from the inferior angle of the semilunar ganglion, and emerging almost immediately through the foramen ovale of the sphenoidal bone, and a small motor root (the motor part of the trigeminal) which passes beneath the ganglion, and unites with the sensory root, just outside the foramen ovale. Immediately beyond the junction of the two roots the nerve sends off from its medial side the nervus spinosus and the nerve to the Pterygoideus internus, and then divides into a small anterior and a large posterior trunk.

The **nervus spinosus** enters the skull through the foramen spinosum with the middle meningeal artery. It divides into two branches, anterior and posterior, which accompany the main divisions of the artery and supply the dura mater; the posterior branch also supplies the mucous lining of the mastoid air-sinuses; the anterior communicates with the meningeal branch of the maxillary nerve.

The **nerve to the Pterygoideus internus** is a slender branch which enters the deep surface of the muscle; it gives one or two filaments to the otic ganglion.

The small anterior trunk gives off (*a*) a sensory branch named the buccinator nerve, and (*b*) motor branches, viz. the masseteric, deep temporal, and external pterygoid nerves; these motor branches, together with the nerve to the Pterygoideus internus, are sometimes grouped under the name of the *nervus masticatorius*.

The **buccinator nerve** (long buccal nerve) passes forwards between the two heads of the Pterygoideus externus, and downwards beneath or through the lower part of the Temporalis; it emerges from under the anterior border of the Masseter, and unites with the buccal branches of the facial nerve. It furnishes a branch to the Pterygoideus externus during its passage through that muscle, and may give off the anterior deep temporal nerve. The buccinator nerve supplies the skin over the anterior part of the Buccinator, and the mucous membrane lining its inner surface.

The **masseteric nerve** passes lateralwards, above the Pterygoideus externus, in front of the mandibular articulation, and behind the tendon of the Temporalis; it crosses the posterior part of the mandibular notch with the masseteric artery, ramifies in the deep surface of the Masseter, and gives a filament to the mandibular joint.

The **deep temporal nerves** are two in number, anterior and posterior. They pass above the upper border of the Pterygoideus externus and enter the deep surface of the Temporalis. The *posterior branch*, of small size, is placed at the posterior part of the temporal fossa, and sometimes arises in common with the masseteric nerve. The *anterior branch* is frequently given off from the buccinator nerve, and then ascends over the upper head of the Pterygoideus externus. A third or intermediate branch is often present.

The **nerve to the Pterygoideus externus** enters the deep surface of the muscle. It may arise separately from the anterior division of the mandibular nerve, or in conjunction with the buccinator nerve.

CC-0. In Public Domain. Gurukul Kangri Collection, Haridwar

Digitized by Arya Samaj Foundation Chennai and eGangotri

The large posterior trunk of the mandibular nerve is for the most part sensory, but receives a few filaments from the motor root. It divides into auriculotemporal, lingual, and inferior alveolar nerves.

The **auriculotemporal nerve** generally arises by two roots, which encircle the middle meningeal artery. It runs backwards beneath the Pterygoideus externus to the medial side of the neck of the mandible. It then turns upwards with the superficial temporal artery, between the auricula and condyle of the mandible, under cover of the parotid gland; escaping from beneath the gland, it ascends over the zygomatic arch, and divides into superficial temporal branches.

FIG. 887.—The right Pterygoideus externus and the branches of the mandibular nerve in relation to it.

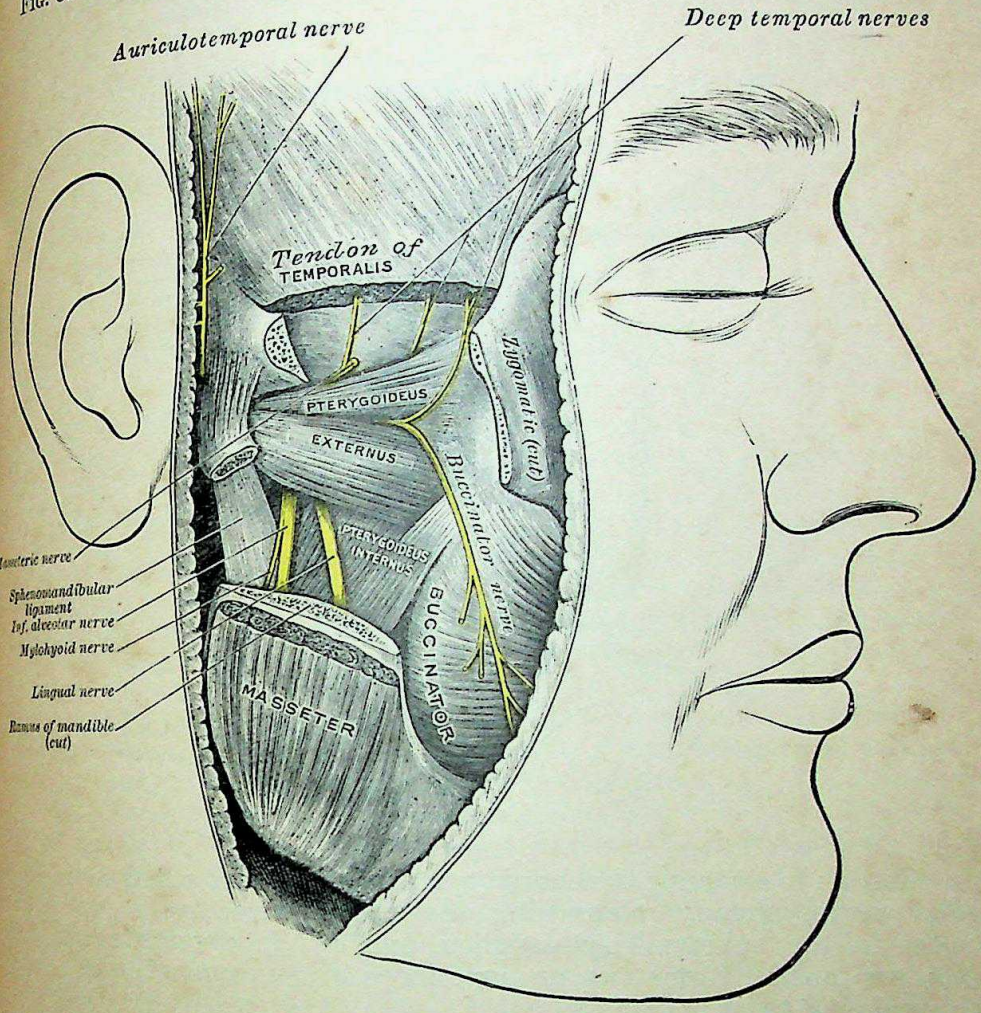

The auriculotemporal nerve communicates with the facial nerve and the otic ganglion. The branches to the facial nerve, usually two in number, pass forwards behind the neck of the mandible and join the facial nerve at the posterior border of the Masseter. The filaments to the otic ganglion are derived from the roots of the auriculotemporal nerve close to their origin.

The *branches* of the auriculotemporal nerve are the anterior auricular, branches to the external acoustic meatus, articular, parotid, and superficial temporal.

The *anterior auricular branches* are usually two in number: they supply the front of the upper part of the auricula, being distributed principally to the skin covering the front of the helix and tragus.

The *branches to the external acoustic meatus*, two in number, supply the skin lining the meatus, which they enter between its bony and cartilaginous portions; the upper one sends a filament to the tympanic membrane.

The *articular branches* consist of one or two twigs which enter the posterior part of the mandibular joint.

CC-0. In Public Domain. Gurukul Kangri Collection, Haridwar

Digitized by Arya Samaj Foundation Chennai and eGangotri

The *parotid branches* supply the parotid gland.

The *superficial temporal branches* accompany the superficial temporal artery and its terminal branches; they supply the skin of the temporal region and communicate with the facial and zygomaticotemporal nerves.

The **lingual nerve** lies at first beneath the Pterygoideus externus, medial to and in front of the inferior alveolar nerve, to which it is often joined by a branch which may cross the internal maxillary artery. The chorda tympani branch of the facial nerve also joins it at an acute angle in this situation. The nerve then runs between the Pterygoideus internus and the ramus of the mandible, and passes obliquely to the side of the tongue over the Constrictor pharyngis superior and Styloglossus, and then between the Hyoglossus and deep part of the submaxillary gland; it finally runs across the duct of the submaxillary gland, and along the tongue to its tip, lying immediately beneath the mucous membrane.

Fig. 888.—The right otic ganglion and its branches.

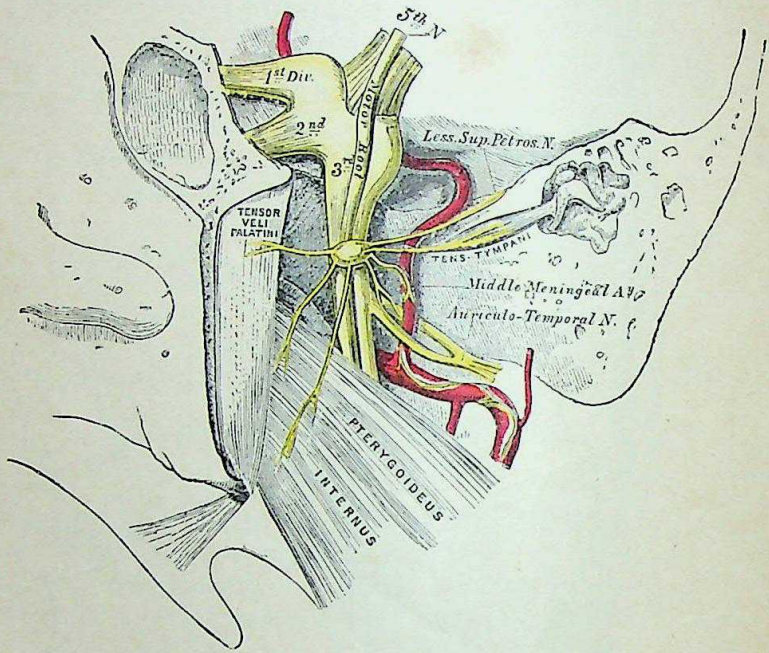

In addition to receiving the chorda tympani and the branch from the inferior alveolar nerve, already referred to, the lingual nerve sends two or three branches to the submaxillary ganglion, and, at the anterior margin of the Hyoglossus muscle, forms two or three loops of communication with twigs of the hypoglossal nerve.

The *branches* of the lingual nerve supply the sublingual gland, the mucous membrane of the mouth, the gums, and the mucous membrane of the anterior two-thirds of the tongue; the terminal filaments join, at the tip of the tongue, with those of the hypoglossal nerve.

The **inferior alveolar nerve** (inferior dental nerve) is the largest branch of the mandibular nerve. It descends with the inferior alveolar artery, at first beneath the Pterygoideus externus, and then between the sphenomandibular ligament and the ramus of the mandible to the mandibular foramen. Here it enters the mandibular canal, and runs below the teeth as far as the mental foramen, where it divides into an incisive and a mental branch.

The branches of the inferior alveolar nerve are the mylohyoid, dental, incisive, and mental.

The *mylohyoid nerve* is derived from the inferior alveolar nerve just before the latter enters the mandibular foramen. It descends in a groove on the medial surface of the ramus of the mandible, and reaching the under surface of the Mylohyoideus supplies this muscle and the anterior belly of the Digastricus.

CC-0. In Public Domain. Gurukul Kangri Collection, Haridwar

Digitized by Arya Samaj Foundation Chennai and eGangotri

The *dental branches* supply the molar and premolar teeth, and the gum. Before the branches enter the roots of the teeth they communicate with one another and form an inferior dental plexus.

The *incisive branch* is continued onwards within the bone and supplies the canine and incisor teeth.

The *mental nerve* emerges at the mental foramen, and divides beneath the Triangularis muscle into three branches; one descends to the skin of the chin, and two ascend to the skin and mucous membrane of the lower lip; these branches communicate freely with the facial nerve.

Two small ganglia, the otic and the submaxillary, are connected with the mandibular nerve.

The **otic ganglion** (fig. 888) is a small, oval-shaped, flattened ganglion of a reddish-grey colour, situated immediately below the foramen ovale; it lies on the medial surface of the mandibular nerve, and surrounds the origin of the nerve to the Pterygoideus internus. It is in relation, *laterally*, with the trunk of the mandibular nerve at the point where the motor and sensory roots join; *medially*, with the cartilaginous part of the auditory tube; *posteriorly*, with the middle meningeal artery.

It is connected by two or three short filaments with the nerve to the Pterygoideus internus, from which it may obtain a motor root (fig. 889). It communicates with the glossopharyngeal and facial nerves, through the lesser superficial petrosal nerve continued from the tympanic plexus, and through this nerve may receive sensory fibres from the glossopharyngeal nerve and a parasympathetic root from the facial nerve; its sympathetic root is a filament from the sympathetic plexus on the middle meningeal artery.

Branches.—A twig (*sphenoidal*) ascends from the otic ganglion to the nerve of the pterygoid canal, and another connects the ganglion with the chorda tympani nerve. Two or more branches run backwards and join the roots of the auriculotemporal nerve; these branches probably carry secretory fibres from the glossopharyngeal nerve to the parotid gland. A filament is supplied to the Tensor tympani muscle, and another to the Tensor veli palatini muscle. The former passes backwards, lateral to the auditory tube; the latter arises from the ganglion, near the origin of the nerve to the Pterygoideus internus, and is directed forwards. The fibres of the nerves to the Tensor tympani and Tensor veli palatini are mainly derived from the nerve to the Pterygoideus internus.

The **submaxillary ganglion** (fig. 884) is of small size, and fusiform in shape. It is situated above the deep portion of the submaxillary gland, on the Hyoglossus, near the posterior border of the Mylohyoideus. It is suspended from the lingual nerve by an anterior and a posterior filament. Through the posterior filament it receives its parasympathetic root from the chorda tympani nerve which runs in the sheath of the lingual, and its sensory root from the lingual nerve. The ganglion receives its sympathetic root from the plexus around the external maxillary (facial) artery (fig. 890).

Five or six branches arise from the lower part of the ganglion, and supply the mucous membrane of the mouth, and the submaxillary gland and its duct. Fibres pass through the filament connecting the fore part of the ganglion to the lingual nerve, and are conveyed to the sublingual gland and the tongue.

Applied Anatomy.—Paralysis of the trigeminal nerve causes anæsthesia of the corresponding anterior half of the scalp, of the face (excepting over a small area near the angle of the mandible supplied by the cervical nerves), of the cornea and conjunctiva, and of the mucous membrane of the nose, mouth, and tongue. Taste is lost (*ageusia*) on the affected side. Paralysis and atrophy follow in the Temporalis, Masseter, and Pterygoidei, possibly also in the Tensor tympani; when the mouth is opened the mandible is thrust over towards the paralysed side. Interference with the secretion of the tears, the nasal mucus, and the saliva, causes dryness of the corresponding mucous membranes. The sense of smell is gradually lost on the affected side from the trophic changes that follow in the nasal mucous membrane. Inflammation of the eyeball, under these circumstances known as neuroparalytic ophthalmia, is not rare, and is due to the dryness and insensitiveness of the conjunctiva; it is not a 'trophic' phenomenon, but depends on the occurrence and neglect of traumatic inflammation in the anæsthetic eye.

Trigeminal nerve reflexes.—Pains referred to various branches of the trigeminal nerve are of very frequent occurrence. As a general rule the diffusion of pain over the various branches of the nerve is at first confined to only one of the main divisions, although

CC-0. In Public Domain. Gurukul Kangri Collection, Haridwar

Digitized by Arya Samaj Foundation Chennai and eGangotri

FIG. 889.—A scheme showing the roots and the branches of distribution of the otic ganglion.

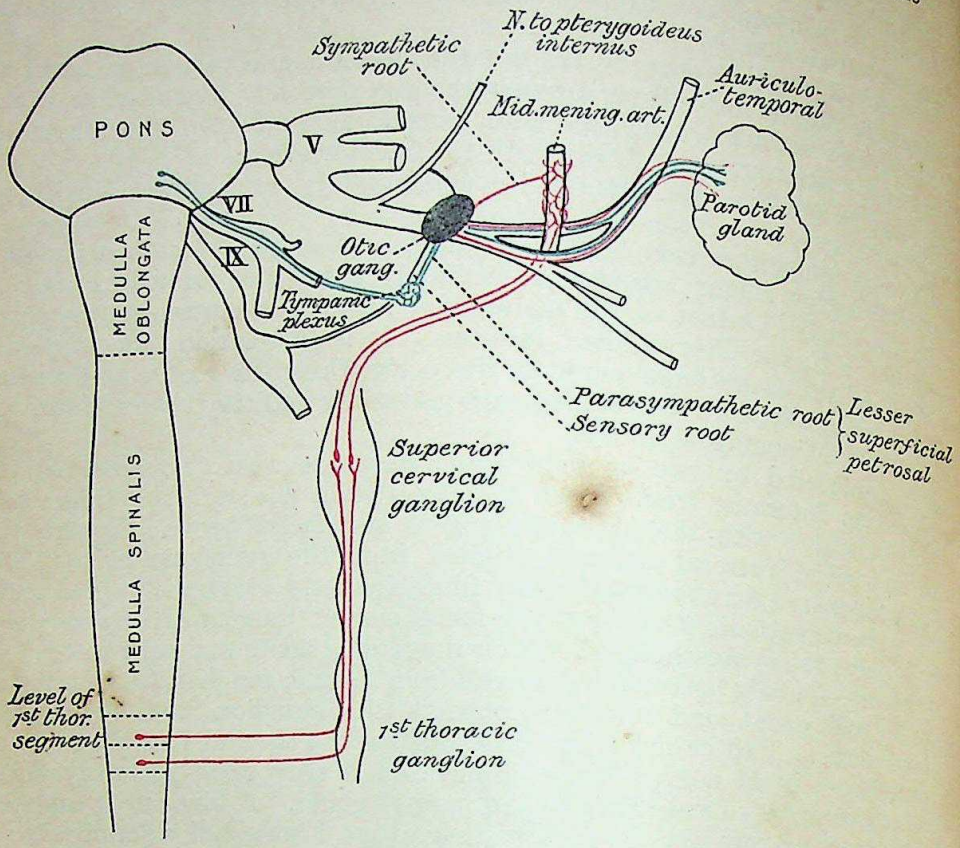

FIG. 890.—A scheme showing the roots and the branches of distribution of the submaxillary ganglion.

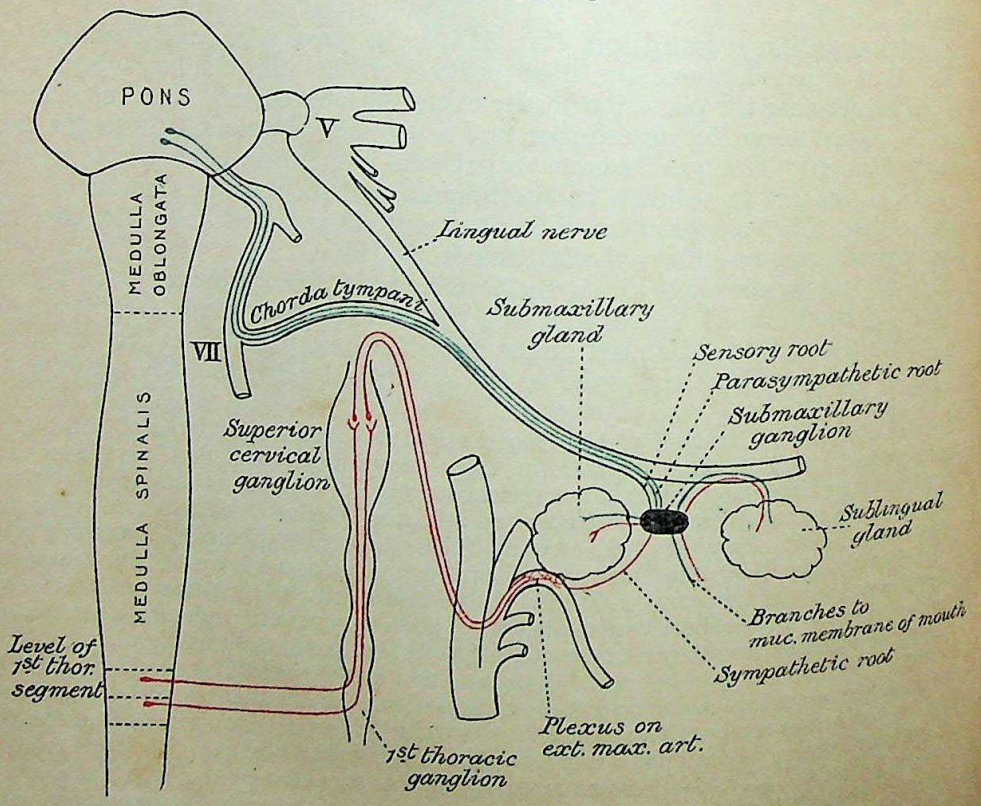

CC-0. In Public Domain. Gurukul Kangri Collection, Haridwar

Digitized by Arya Samaj Foundation Chennai and eGangotri

In severe cases pain may radiate over the branches of the other main divisions. The commonest example of this condition is the neuralgia which is so often associated with dental caries—here, although the tooth itself may not appear to be painful, the most distressing referred pains may be experienced, and these are at once relieved by treatment directed to the affected tooth.

Many other examples of trigeminal reflexes could be quoted, but it will be sufficient to mention the more common ones. In the area of the ophthalmic nerve, severe supra-orbital pain is commonly associated with acute glaucoma or with disease of the frontal or ethmoidal air-sinuses. Malignant growths or empyema of the maxillary antrum, or unhealthy conditions about the inferior conchæ or the septum of the nose, are often found giving rise to 'second division' neuralgia, and should be always looked for in the absence of dental disease in the maxilla. It is on the mandibular nerve, however, that some of the most striking reflexes are seen. It is quite common to meet with patients who complain of pain in the ear, in whom there is no sign of aural disease and the cause is usually to be

Fig. 891.—A diagram showing the cutaneous nerve-areas of the face and scalp.

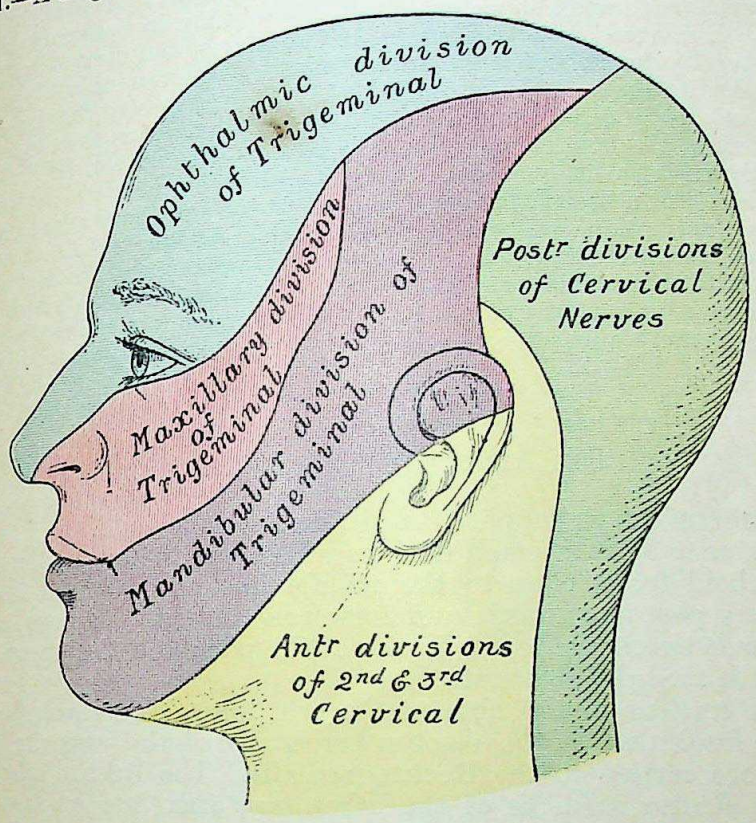

found in a carious tooth in the mandible. Moreover, with an ulcer or cancer of the tongue, often the first pain to be experienced is one which radiates to the ear and temporal fossa, over the distribution of the auriculotemporal nerve.

The trigeminal nerve is often the seat of severe neuralgia for which no local cause can be discovered; each of the three divisions has been divided, or a portion of nerve excised for this affection, usually, however, with only temporary relief. The supra-orbital nerve may be exposed by making an incision 4 cm. in length along the supra-orbital margin, below the eyebrow which is to be drawn upwards, the centre of the incision corresponding to the supra-orbital notch. The skin and Orbicularis oculi having been divided, the nerve can be easily found emerging from the notch, and lying in some loose cellular tissue.

The infra-orbital nerve has been divided at its exit by an incision on the cheek; or the infra-orbital canal can be injected with absolute alcohol; or the whole nerve, together with the sphenopalatine ganglion as far back as the foramen rotundum, may be removed, but even then a return of the neuralgia in some other branches of the trigeminal nerve is the rule. Intracranial resection of the maxillary nerve between the semilunar ganglion and the foramen rotundum is an anatomical possibility.

The inferior alveolar nerve can be reached by a transverse incision over the ramus of the mandible placed so as to avoid injury to the facial nerve; the Masseter having been divided, a small trephine is applied to the ramus immediately beneath the mandibular notch, and, when the bone has been removed, the nerve is found lying on the Pterygoideus internus just as it enters the mandibular foramen, and it can here be resected.

The lingual nerve is occasionally divided with the view of relieving the pain in cancerous disease of the tongue. This may be done in the usual course where it lies below and

CC-0. In Public Domain. Gurukul Kangri Collection, Haridwar

Digitized by Arya Samaj Foundation Chennai and eGangotri

behind the last molar tooth. If a line be drawn from the middle of the crown of the last molar tooth to the angle of the mandible it will cross the nerve, which lies about 1·25 cm. behind the tooth, parallel to the bulging alveolar ridge on the inner side of the body of the bone. The tongue should be pulled forwards and over to the opposite side, when the nerve can be seen standing out as a firm cord under the mucous membrane by the side of the tongue, and after division of the mucous membrane can be easily seized with a hook and a portion excised. This is a simple enough operation on the cadaver, but when the disease is extensive and has extended to the floor of the mouth, as is generally the case, when the division is required, the operation is not practicable.

In severe cases of neuralgia of the trigeminal nerve, the trunks of the maxillary and mandibular nerves may be injected with alcohol; if this treatment fails the semilunar ganglion may be removed in whole or in part. Rose was the first to perform this operation; and he reached the ganglion by trephining the base of the skull in the position of the foramen ovale, after dividing the zygomatic arch, in front and behind, and turning it and the Masseter downwards, and cutting through the coronoid process of the mandible, and turning it and the Temporalis upwards. A more efficient method appears to be that known as the Krause-Hartley method. The bone forming the temporal fossa having been removed to a sufficient extent, the dura mater beneath the temporal lobe of the brain is gradually raised from the middle fossa, until the foramen spinosum, with the middle meningeal artery passing through it, is exposed. This vessel is to be ligatured in two places, and divided between the ligatures; and then by further raising the dura mater, the foramina ovale and rotundum will be exposed, with the mandibular and maxillary nerves passing through them. These nerves are to be clearly defined and divided. The dura mater is then to be raised from the ganglion, when the ophthalmic nerve will be exposed and can be divided, and the ganglion, by means of a little careful dissection, raised from its bed and removed. In some cases where the neuralgia has been limited to the maxillary nerve an intracranial resection of that nerve alone has been performed with great success. In other cases where the disease has not affected the ophthalmic division, resection of the lateral half of the ganglion only, with the maxillary and mandibular nerves, has been performed, thus leaving the sensory nerve supply to the cornea intact. The motor root is usually resected with the mandibular nerve, leading to complete paralysis of the muscles of mastication on that side.

The Abducent Nerve (fig. 882)

The **abducent nerve** supplies the Rectus lateralis oculi.

Its fibres arise from a small nucleus which is situated in the upper part of the rhomboid fossa, close to the middle line and beneath the colliculus facialis. They pass downwards and forwards through the pons, and emerge in the furrow between the lower border of the pons and the upper end of the pyramid of the medulla oblongata.

From the nucleus of the abducent nerve, fibres pass through the medial longitudinal fasciculus to the oculomotor nerve of the opposite side, along which they are carried to the Rectus medialis. The Rectus lateralis of one eye and the Rectus medialis of the other may therefore be said to receive their nerves from the same nucleus (fig. 892).

The abducent nerve runs forwards and lateralwards in the cisterna pontis, in contact with the under surface of the pons, and usually dorsal to the anterior inferior cerebellar artery. It pierces the dura mater on the lateral part of the dorsum sellæ of the sphenoidal bone, and lies in a notch on the edge of this part of the bone. It next traverses the cavernous sinus, lying to the lateral side of the internal carotid artery, and runs into the orbital cavity through the medial end of the superior orbital fissure. It passes within the annulus tendineus from which the Recti muscles of the eyeball arise, beneath the oculomotor and nasociliary nerves, and finally enters the ocular surface of the Rectus lateralis.

In the cavernous sinus the abducent nerve is joined by several filaments from the carotid and cavernous plexuses, and by one from the ophthalmic nerve.

The oculomotor, trochlear, ophthalmic, and abducent nerves bear certain relations to each other in the cavernous sinus, at the superior orbital fissure, and in the cavity of the orbit, as follows.

In the *cavernous sinus* (fig. 893), the oculomotor, trochlear, and ophthalmic nerves are placed in the lateral wall of the sinus, in the order given, from above downwards; the abducent nerve lies at the lateral side of the internal carotid artery. As these nerves pass forwards to the superior orbital fissure,

CC-0. In Public Domain. Supplied by Gurukul Kangri Collection, Haridwar

Digitized by Arya Samaj Foundation Chennai and eGangotri

the oculomotor and ophthalmic nerves divide into branches, and the abducent nerve approaches the others; so that their relative positions are considerably changed.

In the *superior orbital fissure* (fig. 894), the trochlear nerve and the frontal and lacrimal divisions of the ophthalmic nerve lie in this order from the medial

FIG. 892.—A diagram showing the mode of innervation of the Rectus medialis et Rectus lateralis of the eye (after Duval and Laborde). (Testut.)

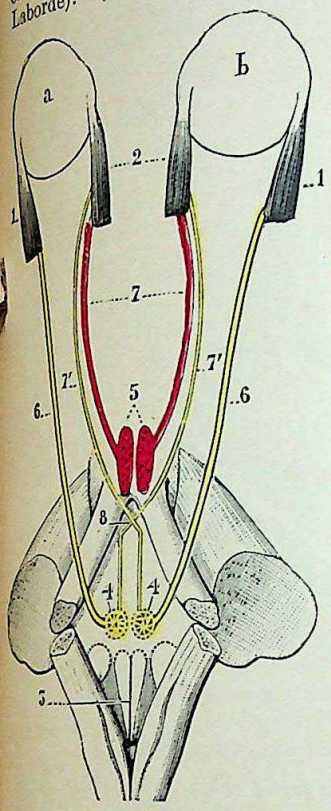

a. Left eyeball. b. Right eyeball. 1. Rectus lateralis. 2. Rectus medialis. 3. Rhomboid fossa. 4. Nucleus of abducent nerve. 5. Nucleus of oculomotor nerve. 6. Abducent nerve. 7. Nerve to Rectus medialis arising from the nucleus of the oculomotor of the same side. 7'. Nerve to Rectus medialis arising from the nucleus of the abducent of the opposite side. 8. Decussation of the fibres of the abducent nerve to the Rectus medialis.

FIG. 893.—An oblique section through the left cavernous sinus. Posterior aspect.

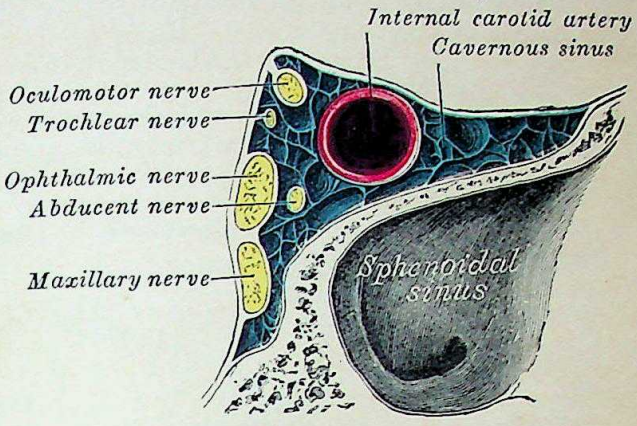

to the lateral side upon the same plane; they enter the cavity of the orbit above the muscles. The remaining nerves enter the orbit within the annulus tendineus from which the Recti muscles of the eyeball take origin. The superior division of the oculomotor nerve is the highest of these; beneath this lies the nasociliary branch of the ophthalmic nerve; then the inferior division of the oculomotor nerve; and the abducent nerve lowest of all.

In the *orbit* (fig. 881) the trochlear, frontal, and lacrimal nerves lie immediately beneath the periosteum, the trochlear nerve resting on the Obliquus superior, the frontal on the Levator palpebræ superioris, and the lacrimal on the Rectus lateralis. The superior division of the oculomotor nerve lies immediately beneath the Rectus superior, while the nasociliary nerve crosses the optic nerve to reach the medial wall of the orbit. Beneath these is the optic nerve, surrounded anteriorly by the ciliary nerves, and having the ciliary ganglion on its lateral side between it and the Rectus lateralis. Below the optic nerve are the inferior division of the oculomotor nerve, and the abducent nerve, the latter lying on the medial surface of the Rectus lateralis.

Applied Anatomy.—The abducent nerve is frequently involved in fractures of the base of the skull. The result of paralysis of this nerve is medial or convergent squint. Diplopia is also present. When injured so that its function is destroyed, there is, in addition to the paralysis of the Rectus lateralis oculi, often a certain amount of contraction of the pupil, because some of the sympathetic fibres to the Dilatator pupillæ muscle are conveyed through this nerve.

THE FACIAL NERVE (figs. 895, 897)

The facial nerve consists of a motor and a sensory part, the latter being frequently described under the name of the *nervus intermedius of Wrisberg* (fig. 798). The two parts appear at the lower border of the pons in the recess

CC-0. In Public Domain. Gurukul Kangri Collection, Haridwar

Digitized by Arya Samaj Foundation Chennai and eGangotri

between the olive and the restiform body, the motor part being the more medial; immediately to the lateral side of the sensory part is the acoustic nerve.

The motor part supplies the muscles of the face, scalp, and auricula, the Buccinator, Platysma, Stapedius, Stylohyoideus, and posterior belly of the Digastricus; it also contains some fibres which constitute the vasodilator and secretory nerves of the submaxillary and sublingual glands, and are conveyed to these glands through the chorda tympani nerve. The sensory part conveys from the chorda tympani nerve the fibres of taste for the anterior two-thirds of the tongue.

FIG. 894.—A dissection showing the origins of the right ocular muscles, and the nerves entering the orbit through the superior orbital fissure.

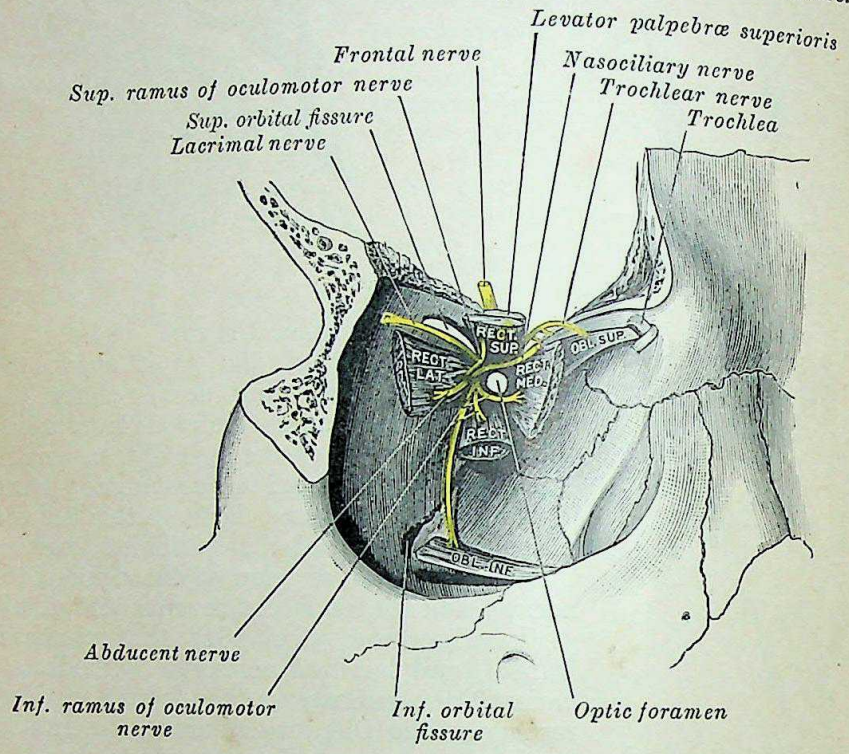

The *motor* root arises from a nucleus which lies deeply in the reticular formation of the lower part of the pons. This nucleus is situated above the nucleus ambiguus, behind the superior olivary nucleus, and medial to the spinal tract of the trigeminal nerve. From this origin the fibres pursue a curved course in the substance of the pons. They first pass backwards and medialwards, and, reaching the posterior end of the nucleus of the abducent nerve, run upwards close to the middle line beneath the colliculus facialis. At the anterior end of the nucleus of the abducent nerve they make a second bend, and run downwards and forwards through the pons to their point of emergence between the olive and the restiform body (figs. 798, 809).

Some fibres from the nucleus of the oculomotor nerve are said to descend in the medial longitudinal fasciculus and join the motor root of the facial nerve before it leaves the pons. These fibres are said to supply the Orbicularis oculi, Corrugator, and Frontalis, since these muscles have been observed to escape paralysis in lesions of the motor nucleus of the facial nerve.*

The *sensory* root arises from the genicular ganglion, which is situated on the geniculum of the facial nerve in the facial canal of the temporal bone. The cells of this ganglion are unipolar, and their single processes divide in a T-shaped manner into central and peripheral branches. The central branches leave the trunk of the facial nerve in the internal acoustic meatus, and form the sensory root of the nerve; the peripheral branches are continued into the chorda tympani and greater superficial petrosal nerves. Entering the brain at the lower border

CC-0. In Public Domain. Gurukul Kangri Collection, Haridwar

* See footnote, p. 828.

Digitized by Arya Samaj Foundation Chennai and eGangotri

of the pons, between the motor root and the acoustic nerve, the fibres of the sensory root of the facial nerve pass into the substance of the medulla oblongata and end in the upper part of the terminal nucleus of the glossopharyngeal nerve and in the nerve-cells of the fasciculus solitarius (nucleus tractus solitarii).

Fig. 895.—A plan of the facial nerve. The course of the sensory fibres is represented by the blue lines.

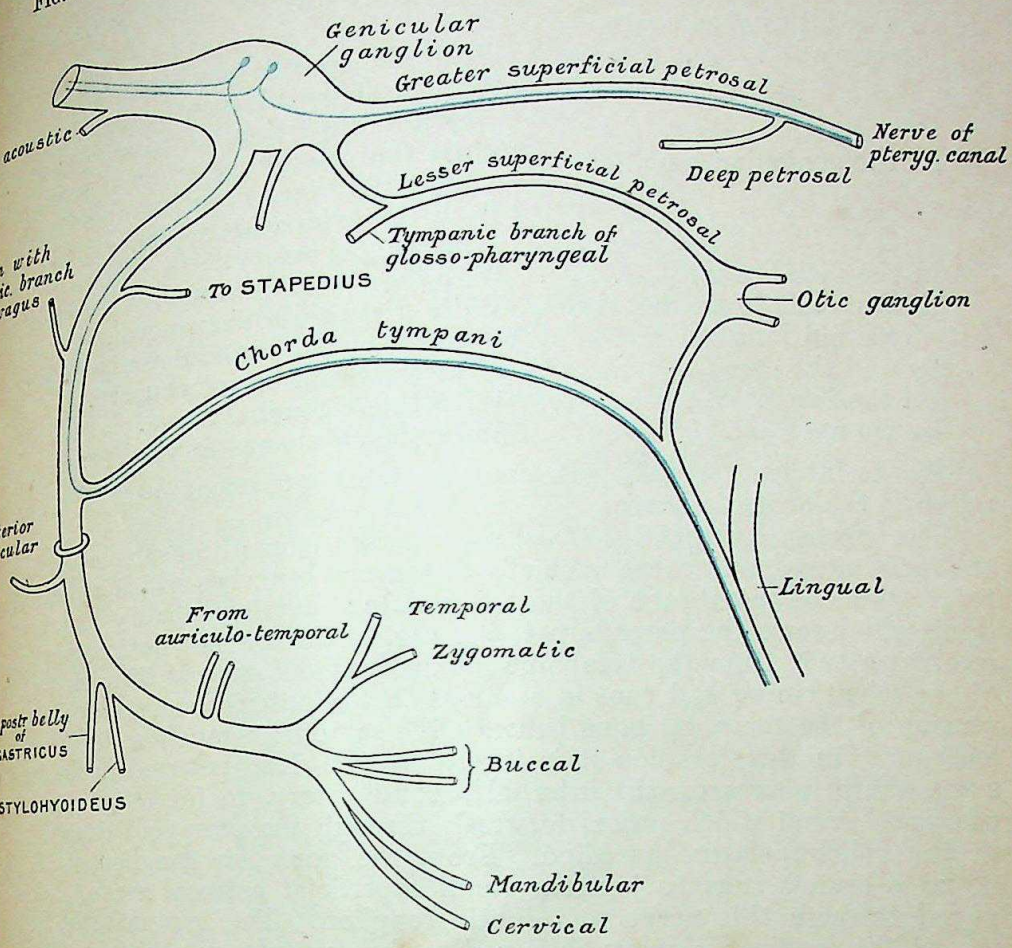

From their attachments to the brain, the two roots of the facial nerve pass lateralwards and forwards with the acoustic nerve to the opening of the internal acoustic meatus. In the meatus the motor root lies in a groove on the upper and anterior surface of the acoustic nerve, the sensory root being placed between them.

Fig. 896.—The course and connexions of the facial nerve in the temporal bone.

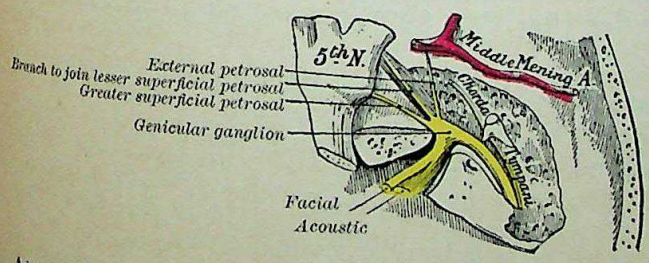

At the bottom of the meatus, the facial nerve enters the facial canal, which it traverses to its termination at the stylomastoid foramen. In this canal the nerve runs at first lateralwards over the vestibule, and reaching the medial wall of the epitympanic recess, bends suddenly backwards and arches downwards behind the tympanic cavity to the stylomastoid foramen. The point where it bends suddenly backwards is named the *geniculum*; it presents a reddish

CC-0. In Public Domain. Gurukul Kangri Collection, Haridwar

Digitized by Arya Samaj Foundation Chennai and eGangotri

gangliform swelling, the *genicular ganglion*, or nucleus of the sensory root of the nerve (fig. 896). On emerging from the stylomastoid foramen, the facial nerve runs forwards in the substance of the parotid gland, crosses the styloid process and the external carotid artery, and divides behind the ramus of the mandible into branches which form a network (*parotid plexus*) and are distributed to the superficial muscles on the side of the head, face, and upper part of the neck.

The *branches of communication* of the facial nerve may be arranged as follows:

In the internal acoustic meatus	With the acoustic nerve.
At the genicular ganglion	With sphenopalatine ganglion by the greater superficial petrosal nerve. With the otic ganglion by a branch which joins the lesser superficial petrosal nerve. With the sympathetic plexus on the middle meningeal artery.
In the facial canal	With the auricular branch of the vagus nerve.
At its exit from the stylomastoid foramen	With the glossopharyngeal, vagus, great auricular, and auriculotemporal nerves.
Behind the ear	With the lesser occipital nerve.
On the face	With the trigeminal nerve.
In the neck	With the cutaneous cervical nerve.

In the internal acoustic meatus some minute filaments pass from the facial nerve to the acoustic nerve.

The *greater superficial petrosal nerve* arises from the genicular ganglion of the facial nerve, and consists chiefly of sensory branches which are distributed to the mucous membrane of the soft palate; but it probably contains a few fibres which form the parasympathetic root of the sphenopalatine ganglion. It receives a twig from the tympanic plexus, passes forwards through the hiatus of the facial canal, and runs in a sulcus on the anterior surface of the petrous portion of the temporal bone beneath the semilunar ganglion, to the foramen lacerum. In this foramen it is joined by the deep petrosal nerve from the sympathetic plexus on the internal carotid artery, to form the nerve of the pterygoid canal which passes forwards through the pterygoid canal and ends in the sphenopalatine ganglion. From the genicular ganglion of the facial nerve a branch runs to join the small superficial petrosal nerve, and is conveyed through this nerve to the otic ganglion. The sympathetic plexus on the middle meningeal artery is joined to the genicular ganglion by the *external petrosal nerve*. According to Arnold, a twig passes back from the genicular ganglion to the acoustic nerve.

Before the facial nerve emerges from the stylomastoid foramen, it receives a twig from the auricular branch of the vagus.

After its exit from the stylomastoid foramen, the facial nerve receives a twig from the glossopharyngeal nerve, and communicates with the great auricular and auriculotemporal nerves in the parotid gland, with the lesser occipital nerve behind the ear, with the terminal branches of the trigeminal nerve on the face, and with the cutaneous cervical nerve in the neck.

The *branches of distribution* (figs. 895, 897) of the facial nerve may be grouped as follows:

Within the facial canal	Nerve to the Stapedius muscle. Chorda tympani.
At its exit from the stylomastoid foramen	Posterior auricular. Digastric. Stylohyoid.
On the face	Temporal. Zygomatic. Buccal. Mandibular. Cervical.

The **nerve to the Stapedius** arises from the facial nerve opposite the pyramidal eminence on the posterior wall of the tympanic cavity; it passes forwards through a small canal to reach the muscle.

CC-0. In Public Domain. Gurukul Kangri Collection, Haridwar

Digitized by Arya Samaj Foundation Chennai and eGangotri

The **chorda tympani nerve** is given off from the facial nerve about 6 mm. above the stylomastoid foramen. It runs upwards and forwards in a canal, and enters the tympanic cavity through an aperture (*iter chordæ posterius*) on its posterior wall, close to the posterior border of the medial surface of the tympanic membrane and on a level with the upper end of the manubrium of the malleus. It traverses the tympanic cavity, between the fibrous and mucous layers of the tympanic membrane, crosses the manubrium of the malleus, and leaves the cavity through a channel situated at the inner end of the petrotympanic fissure,

Fig. 897.—The nerves of the right side of the scalp, face, and neck.

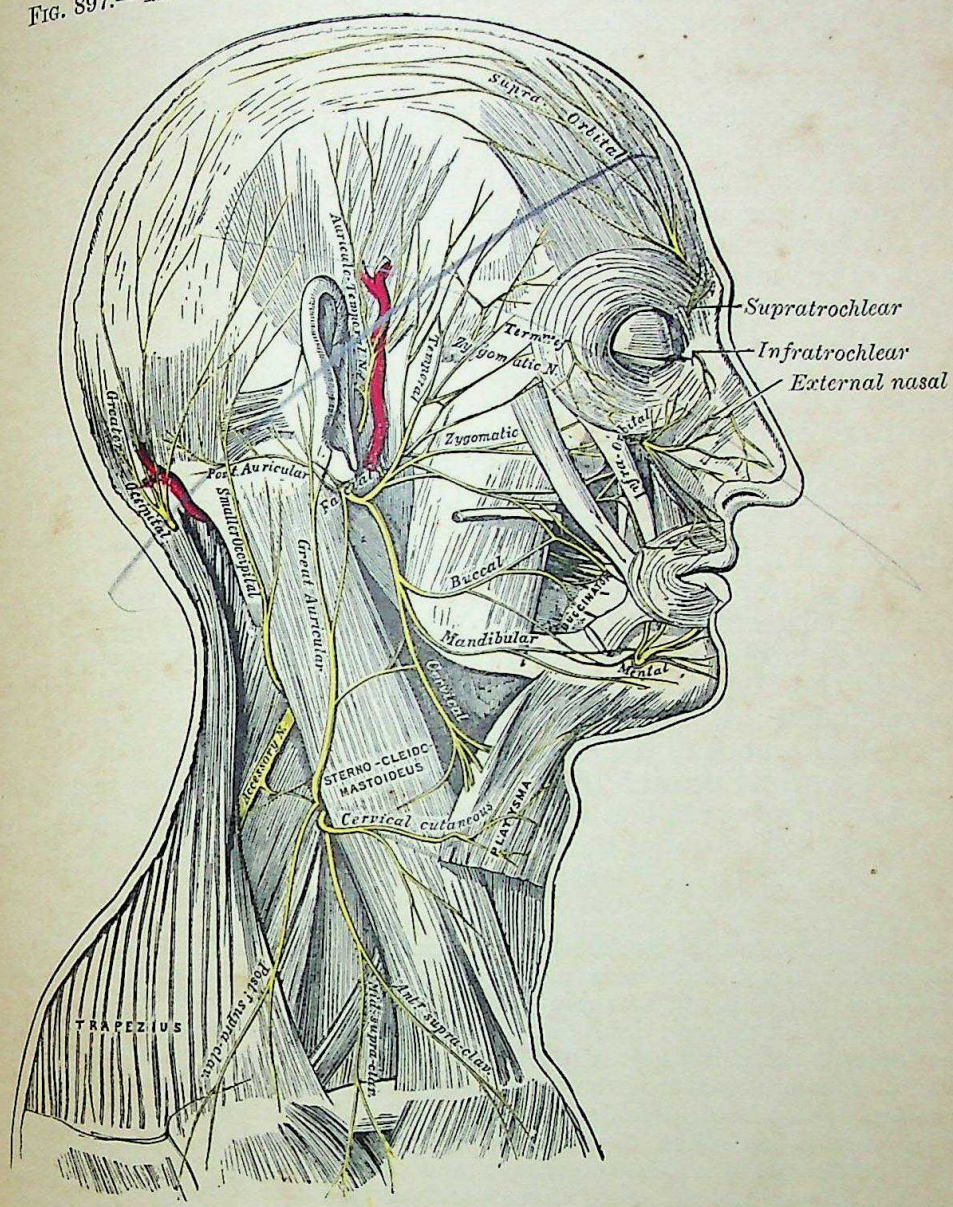

and named the *iter chordæ anterius or canal of Huguier*. The nerve now runs downwards and forwards between the Pterygoidei externus et internus on the medial surface of the spina angularis of the sphenoid (which it sometimes grooves) and on the medial surface of the Pterygoideus externus, where it joins, at an acute angle, the posterior border of the lingual nerve. It contains a few efferent fibres which enter the submaxillary ganglion, and through the latter are distributed to the submaxillary and sublingual glands; the majority of its fibres are afferent, and are continued onwards through the muscular substance of the tongue to the mucous membrane covering its anterior two-thirds; they constitute the nerve of taste for this portion of the tongue. Before uniting with the lingual nerve the chorda tympani is joined by a small branch from the otic ganglion.

The **posterior auricular nerve** arises close to the stylomastoid foramen and runs upwards in front of the mastoid process; here it is joined by a filament

CC-0. In Public Domain. Gurukul Kangri Collection, Haridwar

Digitized by Arya Samaj Foundation Chennai and eGangotri

from the auricular branch of the vagus nerve, and communicates with the posterior branch of the great auricular nerve, and with the lesser occipital nerve. As it ascends between the external acoustic meatus and mastoid process it divides into an auricular and an occipital branch. The *auricular branch* supplies the Auricularis posterior and the intrinsic muscles on the cranial surface of the auricula (pinna). The *occipital branch*, the larger, passes backwards along the superior nuchal line of the occipital bone, and supplies the Occipitalis.

The **digastric branch** arises close to the stylomastoid foramen, and divides into several filaments which supply the posterior belly of the Digastricus; one of these filaments joins the glossopharyngeal nerve.

The **stylohyoid branch** frequently arises in conjunction with the digastric branch; it is long and slender, and enters the Stylohyoideus about its middle.

The **temporal branches** cross the zygomatic arch to the temporal region. They supply the Auricularis anterior and Auricularis superior, and join with the zygomaticotemporal branch of the maxillary nerve, and with the auriculo-temporal branch of the mandibular nerve. The more anterior branches supply the Frontalis, the Orbicularis oculi, and the Corrugator, and join the supra-orbital and lacrimal branches of the ophthalmic nerve.

The **zygomatic branches** run across the zygomatic bone to the lateral angle of the orbit; they supply the Orbicularis oculi, and join with filaments of the lacrimal nerve and the zygomaticofacial branch of the maxillary nerve.

The **buccal branches** pass horizontally forwards to be distributed below the orbit and around the mouth. The *superficial branches* run between the skin and the superficial muscles of the face, and supply the latter; some are distributed to the Procerus, joining at the medial angle of the orbit with the infratrochlear and external nasal nerves. The *deep branches* pass beneath the Zygomaticus and the Quadratus labii superioris, supplying them and forming an *infra-orbital plexus* with the superior labial branches of the infra-orbital nerve; these branches also supply the small muscles of the nose. The lower deep branches supply the Buccinator and Orbicularis oris, and join with filaments of the buccinator branch of the mandibular nerve.

The **mandibular branch** (ramus marginalis mandibulæ) passes forwards beneath the Platysma and Triangularis, near the lower border of the body of the mandible; it supplies the muscles of the lower lip and chin, and joins the mental branch of the inferior alveolar nerve.

The **cervical branch** (ramus colli) issues from the lower part of the parotid gland, runs forwards below the angle of the mandible and under cover of the Platysma to the front of the neck. It supplies the Platysma and communicates with the cutaneous cervical nerve.

Applied Anatomy.—Facial palsy is commonly unilateral, and may be either: (1) *peripheral*, from lesion of the facial nerve; (2) *nuclear*, from destruction of the facial nucleus; or (3) *central*, *cerebral*, or *supranuclear*, from injury in the brain to the fibres passing from the cortex through the internal capsule to the facial nucleus, or from injury to the face-area of the motor cortex itself. In supranuclear facial paralysis, which is usually part of a hemiplegia, it is the lower part of the face that is chiefly affected, while the forehead can be freely wrinkled on the palsied side, the eye can be closed fairly well, and the eyeball is not rolled up under the upper lid; emotional movements of the face are much better executed than voluntary; and the electrical reactions of the muscles on the affected side are not altered. If the paralysis is due to lesion of the facial nucleus, the Orbicularis oris escapes, as the nuclear origin of the nerve to this muscle seems to be connected with that of the tongue-nerves; otherwise the symptoms are identical with those of the common peripheral facial palsy, of which several types may be distinguished according to the point in its course at which the facial nerve is injured. If the lesion occurs (*a*) in the pons, facial paralysis is produced as in (*d*) below; taste and hearing are not affected, but the abducent nerve also will be paralysed because the fibres of the facial nerve loop round its nucleus in the pons. When the nerve is paralysed (*b*) in the petrous bone, in addition to the paralysis of the muscles of expression, there is loss of taste in the anterior part of the tongue, and the patient is unable, from involvement of the chorda tympani, to recognise the difference between bitters and sweets, acids and salines. The mouth is dry, because the salivary glands are not secreting; and the sense of hearing is affected from paralysis of the Stapedius. When the cause of the paralysis is (*c*) fracture of the base of the skull, the acoustic and petrosal nerves are usually involved. But by far the commonest cause of facial palsy is (*d*) exposure of the nerve to cold or injury at or after its exit from the stylomastoid foramen (Bell's paralysis). In these cases the face looks asymmetrical even when at rest, and more so in the old than in the young. The

CC-0. In Public Domain. Gurukul Kangri Collection, Haridwar

Digitized by Arya Samaj Foundation Chennai and eGangotri

affected side of the face and forehead remains motionless when voluntary or emotional movement is attempted. The lines on the forehead are smoothed out, the eye can be shut only by hand, tears fail to enter the lacrimal puncta because they are no longer in contact with the conjunctiva, the conjunctival reflex is absent, and efforts to close the eye merely cause the eyeball to roll upwards until the cornea lies under the upper lid. The tip of the nose is drawn over towards the sound side; the nasolabial fold is partially obliterated on the affected side, and the ala nasi does not move properly on respiration. The lips remain in contact on the paralysed side, and cannot be put together for whistling; when a smile is attempted the angle of the mouth is drawn up on the unaffected side; on the affected side the lips remain nearly closed, and the mouth assumes a characteristic triangular form. During mastication food accumulates in the cheek, from paralysis of the Buccinator, and dribbles or is pushed out from between the paralysed lips. On protrusion the tongue seems to be thrust over towards the palsied side, but verification of its position by reference to the incisor teeth will show that this is not really so. The Platysma and the muscles of the auricula are paralysed; in severe cases the articulation of labials is impaired. The electrical reactions of the affected muscles are altered (reaction of degeneration), and the degree to which this alteration has taken place after a week or ten days gives a valuable guide to the prognosis. Most cases of Bell's palsy recover completely.

The facial nerve is at fault in cases of so-called 'histrionic spasm,' which consists in an almost constant and uncontrollable twitching of some or all of the muscles of the face. This twitching is sometimes so severe as to cause great discomfort and annoyance to the patient, and to interfere with sleep, and for its relief the facial nerve has been stretched. The operation is performed by making an incision behind the ear, from the root of the mastoid process to the angle of the mandible. The parotid is turned forwards and the dissection carried along the anterior border of the Sternocleidomastoideus and mastoid process, until the upper border of the posterior belly of the Digastricus is found. The nerve is parallel to this on about the level of the middle of the mastoid process. When found, the nerve must be stretched by passing a blunt hook beneath it and pulling it forwards and outwards. Too great force must not be used, for fear of permanent injury to the nerve.

The Acoustic Nerve

The **acoustic nerve** appears in the groove between the pons and medulla oblongata behind the facial nerve and in front of the restiform body; it is distributed to the internal ear. It consists of two sets of fibres, which, although differing in their central connexions, are both concerned in the transmission of afferent impulses from the internal ear to the medulla oblongata and pons, and from there, by means of fibres which arise from collections of grey substance in these structures, to the cerebrum and cerebellum. One set of fibres forms the vestibular nerve, and arises from the cells of the vestibular ganglion situated in the bottom of the internal acoustic meatus; the other set constitutes the cochlear nerve, and takes origin from the cells of the spiral ganglion of the cochlea. Both ganglia consist of bipolar nerve-cells, and from each cell a central fibre passes to the brain, and a peripheral fibre to the internal ear.

Fig. 898.—The terminal nuclei of the vestibular nerve. Schematic. (Testut.)

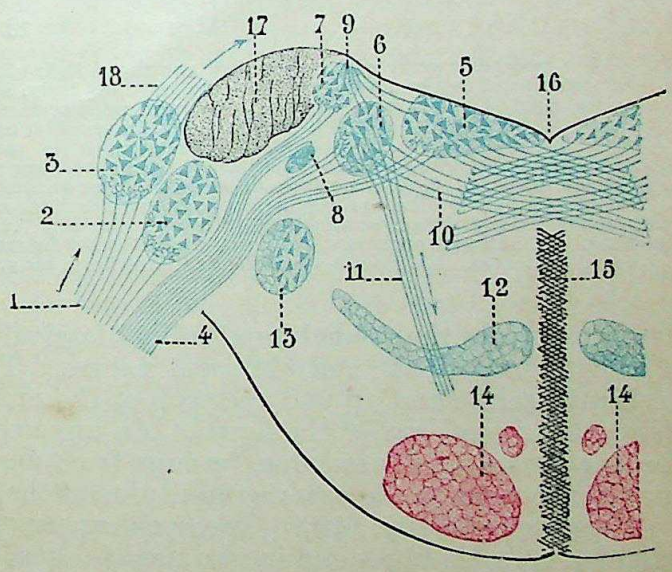

1. Cochlear nerve. 2. Accessory cochlear nucleus. 3. Lateral cochlear nucleus. 4. Vestibular nerve. 5. Medial or chief vestibular nucleus. 6. Nucleus of Deiters. 7. Nucleus of Bechterew. 8. Descending fibres of vestibular nerve. 9. Fibres passing to cerebellum. 10. Fibres going to raphe. 11. Fibres taking an oblique course. 12. Lemniscus. 13. Spinal tract of trigeminal. 14. Cerebrospinal fasciculus. 15. Raphe. 16. Fourth ventricle. 17. Restiform body. 18. Origin of striæ medullares.

Vestibular nerve (fig. 898).—The fibres of the vestibular nerve enter the brain medial to, and on a higher level than, those of the cochlear nerve. They

CC-0. In Public Domain. Gurukul Kangri Collection, Haridwar

Digitized by Arya Samaj Foundation Chennai and eGangotri

pass backwards through the pons between the restiform body and the spinal tract of the trigeminal nerve and divide into ascending and descending branches which mostly end in the vestibular nuclei. These nuclei consist of: (1) The *medial or chief vestibular nucleus*, situated in the area acustica of the rhomboid fossa, and crossed dorsally by the striæ medullares (striæ acusticæ): this nucleus is triangular on transverse section, and its lower pat constitutes (2) the *descending or spinal vestibular nucleus*. (3) The *lateral vestibular nucleus* (nucleus of Deiters), and (4) the *superior vestibular nucleus* (nucleus of Bechterew) lie close to the restiform body, and the former contains large mutipolar cells. Some of the ascending fibres of the vestibular nerve end in the vestibular nuclei, but others pass directly to the roof nucleus (nucleus fastigii) and cortex of the opposite side of the cerebellum, and are accompanied by fibres which originate in the cells of the vestibular nuclei. From the cells of the vestibular nuclei

FIG. 899.—The terminal nuclei of the cochlear nerve. Schematic. (Testut.)

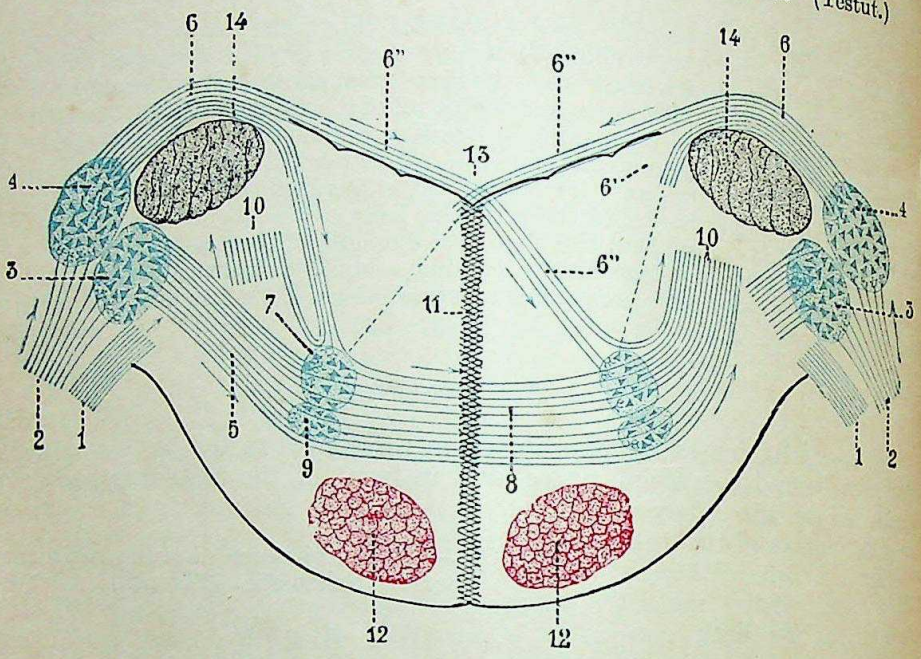

The vestibular nerve with its terminal nuclei and their efferent fibres have been suppressed. On the other hand, in order not to obscure the trapezoid body, the efferent fibres of the terminal nuclei on the right side have been resected in a considerable portion of their extent. The trapezoid body, therefore, shows only one-half of its fibres, viz. those which come from the left.

1. Vestibular nerve, divided at its entrance into the medulla oblongata. 2. Cochlear nerve. 3. Ventral or accessory cochlear nucleus. 4. Lateral cochlear nucleus. 5. Efferent fibres of accessory cochlear nucleus. 6. Efferent fibres of lateral cochlear nucleus, forming the striæ medullares, with 6', their direct bundle going to the superior olivary nucleus of the same side; 6", their decussating bundles going to the superior olivary nucleus of the opposite side. 7. Superior olivary nucleus. 8. Trapezoid body. 9. Trapezoid nucleus. 10. Central acoustic tract (lateral lemniscus). 11. Raphe. 12. Cerebrospinal fasciculus. 13. Fourth ventricle. 14. Restiform body.

fibres ascend in the medial longitudinal fasciculus and end in the nuclei of the oculomotor, trochlear and abducent nerves. The descending branches of the vestibular nerve end around the cells of the medial and spinal nuclei and constitute the *spinal root* of the nerve. An important strand of descending fibres, the vestibulospinal fasciculus, springs from the cells of Deiters' nucleus and runs downwards in the anterior funiculus of the medulla spinalis (p. 794).

Cochlear nerve (fig. 899).—The cochlear nerve is placed lateral to the vestibular nerve. Its fibres end in two nuclei: one, the *ventral or accessory cochlear nucleus*, lies on the ventral surface of the restiform body; the other, the *lateral cochlear nucleus*, lies on the lateral surface of the restiform body.

The cells of the accessory cochlear nucleus give origin to fibres which run transversely in the pons and constitute the trapezoid body; some of these fibres end around the cells of the superior olivary nucleus or of the trapezoid nucleus of the same or opposite side, but most of them ascend on the lateral side of the superior olivary nucleus under the name of the *lateral lemniscus*. The striæ medullares (striæ acusticæ) are the axons of cells of the lateral cochlear nucleus. They pass over the restiform body, and across the rhomboid fossa

CC-0. In Public Domain. Gurukul Kangri Collection, Haridwar

Digitized by Arya Samaj Foundation Chennai and eGangotri

to the median sulcus. Here they dip into the substance of the pons, where some end around the cells of the superior olivary nuclei of both sides, while others, both direct and crossed, pass into the lateral lemniscus.

The lateral lemniscus ascends through the pons, and appears on the surface in the lateral sulcus of the midbrain; its fibres end in the inferior colliculus and the medial geniculate body. In the upper part of the lateral lemniscus there is a collection of nerve-cells, the *nucleus of the lateral lemniscus*, around the cells of which some of the fibres arborise, and from the cells of which fibres originate and are continued upwards into the tract of the lateral lemniscus. From the cells of the medial geniculate body new fibres arise and run through the occipital part of the internal capsule to reach the cortical acoustic centre which is placed in the anterior part of the transverse temporal gyrus, and in the upper part of the middle one-third of the superior temporal gyrus.

The acoustic nerve is soft in texture, and destitute of neurolemma. After leaving the medulla oblongata it passes forwards across the posterior border of the brachium pontis, in company with the facial nerve, from which it is partially separated by the internal auditory artery. It then enters the internal acoustic meatus with the facial nerve. At the bottom of the meatus it receives one or two filaments from the facial nerve, and splits into its *cochlear* and *vestibular* parts, the distribution of which will be described with the anatomy of the internal ear.

Applied Anatomy.—The acoustic nerve is frequently injured, together with the facial nerve, in fracture of the middle fossa of the base of the skull implicating the internal acoustic meatus. The nerve may be either torn across, producing permanent deafness, or it may be bruised or pressed upon by extravasated blood or inflammatory exudation, when the deafness will in all probability be temporary. The nerve may also be injured by violent blows on the head without any fracture of the bones of the skull taking place, and deafness may arise from loud explosions from dynamite, &c., probably from some lesion of this nerve, which is more liable to be injured than the other cerebral nerves on account of its structure. 'Nerve-deafness,' as contrasted with deafness due to changes in the middle ear or meatus, is suggested if (1) a sounding tuning-fork placed on the middle-line of the head is heard better (Weber's test) by the unaffected ear; or if (2) the sounding tuning-fork is heard longer when held before the affected ear (=air conduction) than when it is stood on the corresponding mastoid (=bone conduction, Rinne's test); or if (3) the sounding tuning-fork applied to the vertex or mastoid is heard less well when the air in the meatus is compressed by the use of a Siegle's speculum (Gellé's test); or if (4) the tuning-fork placed on the mastoid is heard for a shorter time than its sound is perceptible to a normal individual (=evidence that bone conduction is diminished, Schwabach's test). It must be remembered that all these tests are liable to anomalies and exceptions, and are not applicable to old people. If, however, concordant results are yielded by the tests of Weber, Rinne, and Gellé, Bezold's 'triad of symptoms,' nerve-deafness rather than deafness due to disease of the conducting structures, is rendered highly probable.

Tinnitus aurium, or the hearing of sounds in the ear that have no objective cause outside the body, is said to be present in as many as sixty per cent. of cases of ear disease of all sorts, and is commonest in disease of the labyrinth or of the nerve. It is very variable in intensity; the worst forms are purely subjective and due to irritation of the nerve itself. The sounds heard are of the most varied nature—buzzing, hissing, whistling, rushing, bell-ringing, and so forth—and may occupy the patient's attention so completely that he is no longer able to attend to his business; he may even commit suicide in order to escape from them. In the insane, tinnitus is associated with delusions and hallucinations of hearing; cases of insanity have even been recorded in which cure was effected by the removal of cerumen impacted in the meatus and giving rise to persistent tinnitus.

The Glossopharyngeal Nerve (figs. 900, 901, 902)

The **glossopharyngeal nerve** contains motor and sensory fibres. It supplies motor fibres to the Stylopharyngeus, and sensory fibres to the pharynx, the palatine tonsil, and the posterior part of the tongue; it is also the nerve of taste for this part of the tongue. It is attached by three or four filaments to the upper part of the medulla oblongata, in the groove between the olive and the restiform body.

The *sensory* fibres arise from the cells of the superior and petrous ganglia, which are situated on the trunk of the nerve, and will be presently described. When traced into the medulla, some of the sensory fibres end by arborising

CC-0. In Public Domain. Gurukul Kangri Collection, Haridwar

Digitized by Arya Samaj Foundation Chennai and eGangotri

around the cells of the upper part of a nucleus which lies beneath the alae cinerea in the lower part of the rhomboid fossa. Most, however, contribute to form a strand, named the *fasciculus solitarius*, which descends in the medulla oblongata. Associated with this strand are numerous nerve-cells (nuclei tractus solitarii) and around these cells the fibres of the fasciculus end.

The *motor* fibres spring from the cells of the *nucleus ambiguus*, which also gives origin to the motor fibres of the vagus nerve, and to the cerebral part of the accessory nerve. This nucleus lies some distance from the surface of the rhomboid fossa in the lateral part of the medulla oblongata and is continuous below with the anterior grey column of the medulla spinalis. From the nucleus the fibres are first directed backwards towards the rhomboid fossa, and then forwards and lateralwards to join with the fibres of the sensory root.

From the medulla oblongata, the glossopharyngeal nerve passes forwards and lateralwards towards the triangular depression into which the aquæductus cochleæ opens, on the inferior surface of the petrous portion of the temporal bone. It lies at first under cover of the flocculus, and rests on the tuberculum jugulare of the occipital bone, which is sometimes grooved by it. It leaves the skull by bending sharply downwards through the central part of the jugular foramen, anterior and lateral to the vagus and accessory nerves, and in a separate sheath of dura mater (fig. 901). In its transit through the jugular foramen it is lodged in a deep groove leading from the triangular depression for the aquæductus cochleæ, and here it is separated by the inferior petrosal sinus from the vagus and accessory nerves. The deep groove is converted into a canal by a bridge which is usually composed of fibrous tissue, but which consists of bone in about 25 per cent. of skulls.* At its exit from the skull it passes forwards between the internal jugular vein and internal carotid artery; it descends in front of the latter vessel, and beneath the styloid process and the muscles connected with it, to the lower border of the Stylopharyngeus. It then curves forwards, forming an arch on the side of the neck and lying upon the Stylopharyngeus and Constrictor pharyngis medius. Thence it passes under cover of the Hyoglossus, and is finally distributed to the palatine tonsil, the mucous membrane of the pharynx and the posterior part of the tongue and the mucous glands of the mouth.

FIG. 900.—A plan of the upper portions of the glossopharyngeal, vagus, and accessory nerves.

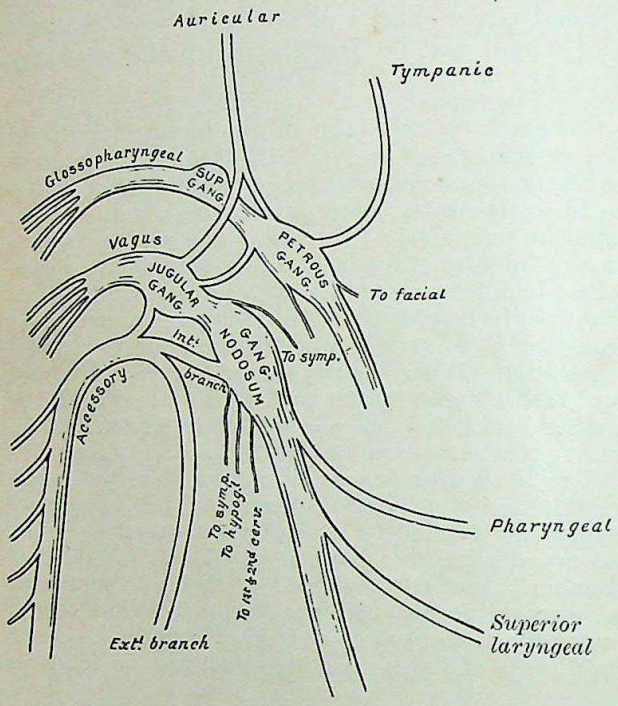

Two ganglia, the superior and the petrous, are situated on that portion of the nerve which traverses the jugular foramen (fig. 900).

The **superior ganglion** (jugular ganglion) is situated in the upper part of the groove in which the nerve is lodged during its passage through the jugular foramen. It is very small, and is usually regarded as a detached portion of the petrous ganglion.

The **petrous ganglion** is larger than the superior ganglion and is situated in a depression in the lower border of the petrous portion of the temporal bone.

The glossopharyngeal nerve communicates with the sympathetic trunk, and with the vagus and facial nerves.

The petrous ganglion is connected by a filament with the superior cervical

* E. Joyce Partridge, *Journal of Anatomy*, vol. lii.

CC-0. In Public Domain. Gurukul Kangri Collection, Haridwar

Digitized by Arya Samaj Foundation Chennai and eGangotri

ganglion of the sympathetic. The branches to the vagus consist of two filaments which arise from the petrous ganglion; one joins the auricular branch, and the other the jugular ganglion, of the vagus. The branch to the facial arises from the trunk of the glossopharyngeal nerve below the petrous ganglion; it perforates the posterior belly of the Digastricus and joins the facial nerve near the stylomastoid foramen.

The *branches of distribution* of the glossopharyngeal nerve are: tympanic, carotid, pharyngeal, muscular, tonsillar, and lingual.

The **tympanic nerve** (Jacobson's nerve) arises from the petrous ganglion of the glossopharyngeal nerve, and ascends to the tympanic cavity through the inferior tympanic canaliculus (p. 212). In the tympanic cavity it divides into branches which form the *tympanic plexus* and are contained in grooves upon the surface of the promontory. This plexus gives off: (1) the lesser superficial petrosal nerve; (2) a branch to join the greater superficial petrosal nerve; and (3) branches to the tympanic cavity, all of which are described with the anatomy of the middle ear.

The **carotid branches** descend along the trunk of the internal carotid artery as far as its origin, communicating with the pharyngeal branch of the vagus, and with branches of the sympathetic trunk.

The **pharyngeal branches** are three or four filaments which unite, opposite the Constrictor pharyngis medius, with the pharyngeal branches of the vagus nerve and the laryngopharyngeal branches of the sympathetic trunk to form the *pharyngeal plexus*; branches from this plexus perforate the muscular coat of the pharynx and are distributed to its muscles and mucous membrane.

The **muscular branch** supplies the Stylopharyngeus.

The **tonsillar branches** supply the palatine tonsil, and form around it a plexus with branches of the middle and posterior palatine nerves; from this plexus filaments are distributed to the soft palate and fauces.

The **lingual branches** are two in number: one supplies the papillæ vallatæ and the mucous membrane near the sulcus terminalis of the tongue; the other supplies the mucous membrane and follicular glands of the posterior one-third of the tongue, and communicates with the lingual nerve.

The Vagus Nerve (figs. 900, 901, 902)

The **vagus nerve** is composed of motor and sensory fibres, and has a more extensive course and distribution than any of the other cerebral nerves, since it passes through the neck and thorax to the abdomen.

The vagus nerve is attached by eight or ten filaments to the medulla oblongata in the groove between the olive and the restiform body, below the glossopharyngeal nerve. The *sensory* fibres arise from the cells of the jugular ganglion and ganglion nodosum of the nerve (see below), and, when traced into the medulla oblongata, mostly end by arborising around the cells of the inferior part of a nucleus which lies beneath the ala cinerea in the lower part of the rhomboid fossa; a few descend in the fasciculus solitarius and end around its cells. The *motor* fibres arise from the cells of the nucleus ambiguus, already referred to in connexion with the motor root of the glossopharyngeal nerve (p. 916).

The filaments of the nerve unite, and form a flat cord which passes beneath the flocculus of the cerebellum to the jugular foramen, through which it leaves the cranium. In emerging through this opening, the vagus nerve is accompanied by and contained in the same sheath of dura mater with the accessory nerve, a septum separating them from the glossopharyngeal nerve which lies in front (fig. 901). In this situation the vagus nerve presents a well-marked enlargement, the *jugular ganglion*. After its exit from the jugular foramen the vagus nerve enlarges into a second swelling, the *ganglion nodosum*.

The **jugular ganglion** (ganglion of the root) is of a greyish colour, spherical in form, about 4 mm. in diameter. It is joined by one or two delicate filaments with the cerebral portion of the accessory nerve; it is connected by a twig with the petrous ganglion of the glossopharyngeal nerve, and with the sympathetic trunk by a filament from the superior cervical ganglion; its auricular branch gives off an ascending branch which joins the facial nerve.

CC-0. In Public Domain. Gurukul Kangri Collection, Haridwar

Digitized by Arya Samaj Foundation Chennai and eGangotri

The **ganglion nodosum** (ganglion of the trunk) is cylindrical in form, of a reddish colour, and 2·5 cm. long. It is connected with the hypoglossal nerve, the superior cervical ganglion of the sympathetic trunk, and the loop between the first and second cervical nerves. The cerebral portion of the accessory nerve passes over the ganglion and is attached to it by fibrous tissue.

Beyond the ganglion nodosum the cerebral portion of the accessory nerve blends with the vagus nerve; its fibres are principally distributed to the

FIG. 901.—The upper part of the medulla spinalis, and the hind-brain and mid-brain. Exposed from behind.

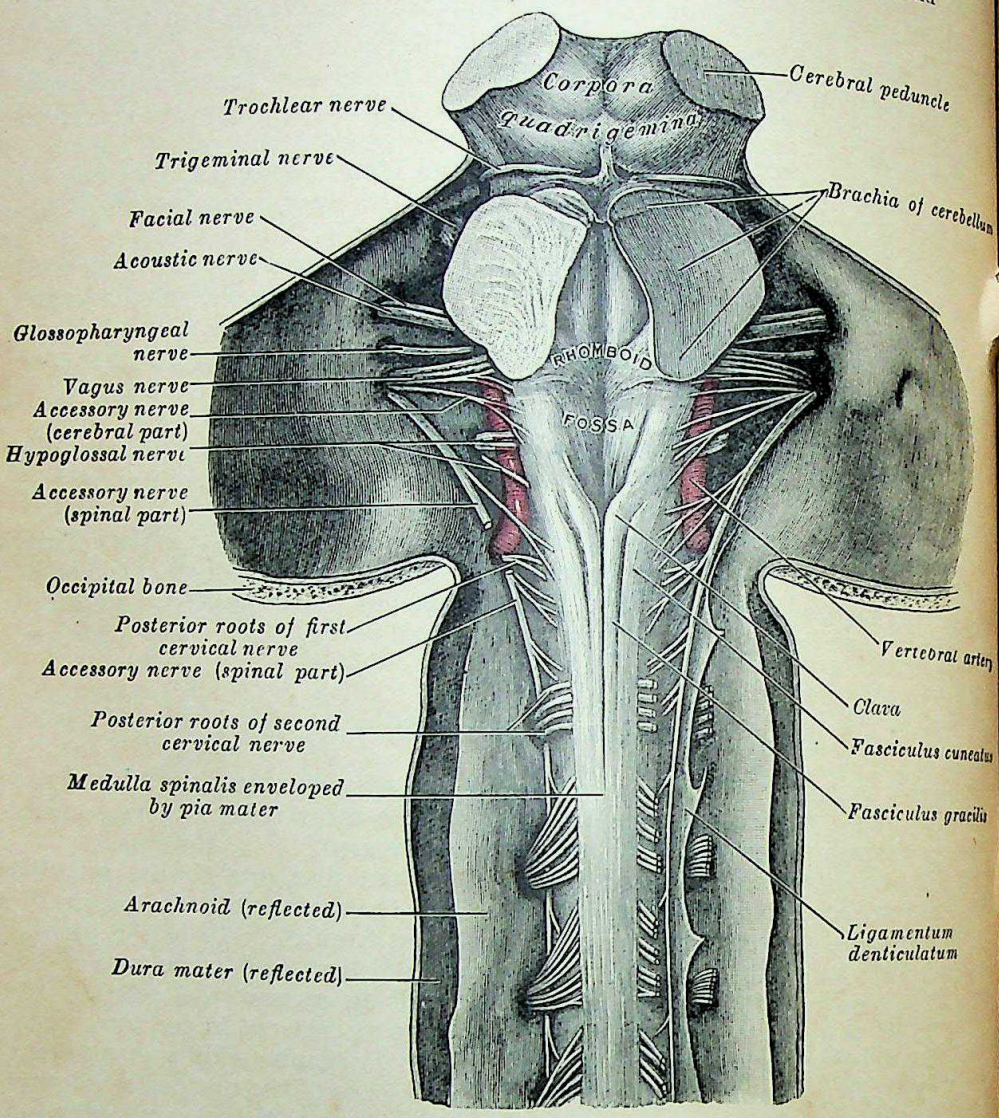

pharyngeal and superior laryngeal branches of the vagus nerve, but some descend in the trunk of the vagus nerve, to be distributed with the recurrent nerve and probably also with the cardiac nerves.

The vagus nerve passes vertically down the neck within the carotid sheath, lying between the internal jugular vein and internal carotid artery as far as the upper border of the thyreoid cartilage, and then between the same vein and the common carotid artery to the root of the neck. The further course of the nerve differs on the two sides of the body.

On the *right side*, the nerve passes across the first part of the subclavian artery, between it and the right innominate vein, and descends by the side of the trachea to the back of the root of the lung, where it spreads out in the *right posterior pulmonary plexus*. From the lower part of this plexus two cords descend on the œsophagus, and divide to form, with branches from the left nerve, the *œsophageal plexus*. Below, these branches are collected into a

CC-0. In Public Domain. Gurukul Kangri Collection, Haridwar

Digitized by Arya Samaj Foundation Chennai and eGangotri

single cord, which runs along the back of the œsophagus, enters the abdomen through the œsophageal opening in the Diaphragm, and is distributed to the posterio-inferior surface of the stomach, joining the left side of the cœliac plexus, and sending filaments to the lienal (splenic) plexus.

On the *left side*, the nerve enters the thorax between the left carotid and subclavian arteries, behind the left innominate vein. It crosses the left side of the arch of the aorta, and descends behind the root of the left lung, forming there the *left posterior pulmonary plexus*. From this it runs along the anterior surface of the œsophagus, where it unites with branches of the right nerve in the *œsophageal plexus*, and is continued to the stomach, distributing branches over its anterosuperior surface; some of these extend over the fundus, and others along the lesser curvature. Filaments from these branches enter the lesser omentum, and join the hepatic plexus.

The *branches of distribution* of the vagus nerve are:

In the jugular fossa . .	Meningeal. Auricular.
In the neck	Pharyngeal. Superior laryngeal. Right recurrent. Superior cardiac.
In the thorax . . .	Inferior cardiac. Left recurrent. Anterior bronchial. Posterior bronchial. Œsophageal.
In the abdomen . . .	Gastric. Cœliac. Hepatic.

The **meningeal branch** springs from the jugular ganglion of the vagus nerve, and is distributed to the dura mater in the posterior fossa of the skull.

The **auricular branch** (nerve of Arnold) also arises from the jugular ganglion of the vagus nerve, and is joined soon after its origin by a filament from the petrous ganglion of the glossopharyngeal; it passes behind the internal jugular vein, and enters the mastoid canaliculus on the lateral wall of the jugular fossa. Traversing the substance of the temporal bone, it crosses the facial canal about 4 mm. above the stylomastoid foramen, and here it gives off an ascending branch which joins the facial nerve. It then passes through the tympanomastoid fissure, and divides into two branches; one joins the posterior auricular nerve, the other is distributed to the skin of the back of the auricula and to the posterior part of the external acoustic meatus.

The **pharyngeal branch**, the principal motor nerve of the pharynx, arises from the upper part of the ganglion nodosum of the vagus nerve, and consists principally of filaments from the cerebral portion of the accessory nerve. It passes across the internal carotid artery to the upper border of the Constrictor pharyngis medius, where it divides into numerous filaments which join with branches from the sympathetic trunk, the glossopharyngeal and external laryngeal nerves, to form the *pharyngeal plexus*. From the plexus, branches are distributed to the muscles and mucous membrane of the pharynx, and the muscles of the soft palate, except the Tensor veli palatini. A minute filament joins the hypoglossal nerve as the latter winds round the occipital artery.

The **superior laryngeal nerve**, larger than the preceding, arises from the middle of the ganglion nodosum of the vagus nerve, and in its course receives a branch from the superior cervical ganglion of the sympathetic trunk. It descends, by the side of the pharynx, behind the internal carotid artery and divides into two branches, an internal and an external.

The *internal branch* descends to the hyothyreoid membrane; it pierces this membrane at a higher level than the superior laryngeal artery, and divides into an upper and a lower branch. The upper branch is directed horizontally, and supplies twigs to the mucous membrane of the pharynx, the epiglottis, the vallecula of the tongue and the vestibule of the larynx. The lower branch descends in the medial wall of the recessus piriformis, and gives branches to the aryepiglottic fold, and to the mucous membrane on the back of the arytænoid

CC-0. In Public Domain. Gurukul Kangri Collection, Haridwar

Digitized by Arya Samaj Foundation Chennai and eGangotri

cartilage. It also supplies one or two branches to the Arytænoideus muscle, and these branches unite with twigs from the recurrent nerve to the same muscle; the Arytænoideus has therefore a double nerve-supply. The internal branch of the superior laryngeal nerve ends by piercing the Constrictor pharyngis inferior, and joining with the recurrent nerve.*

Fig. 902.—The course and distribution of the glossopharyngeal, vagus, and accessory nerves.

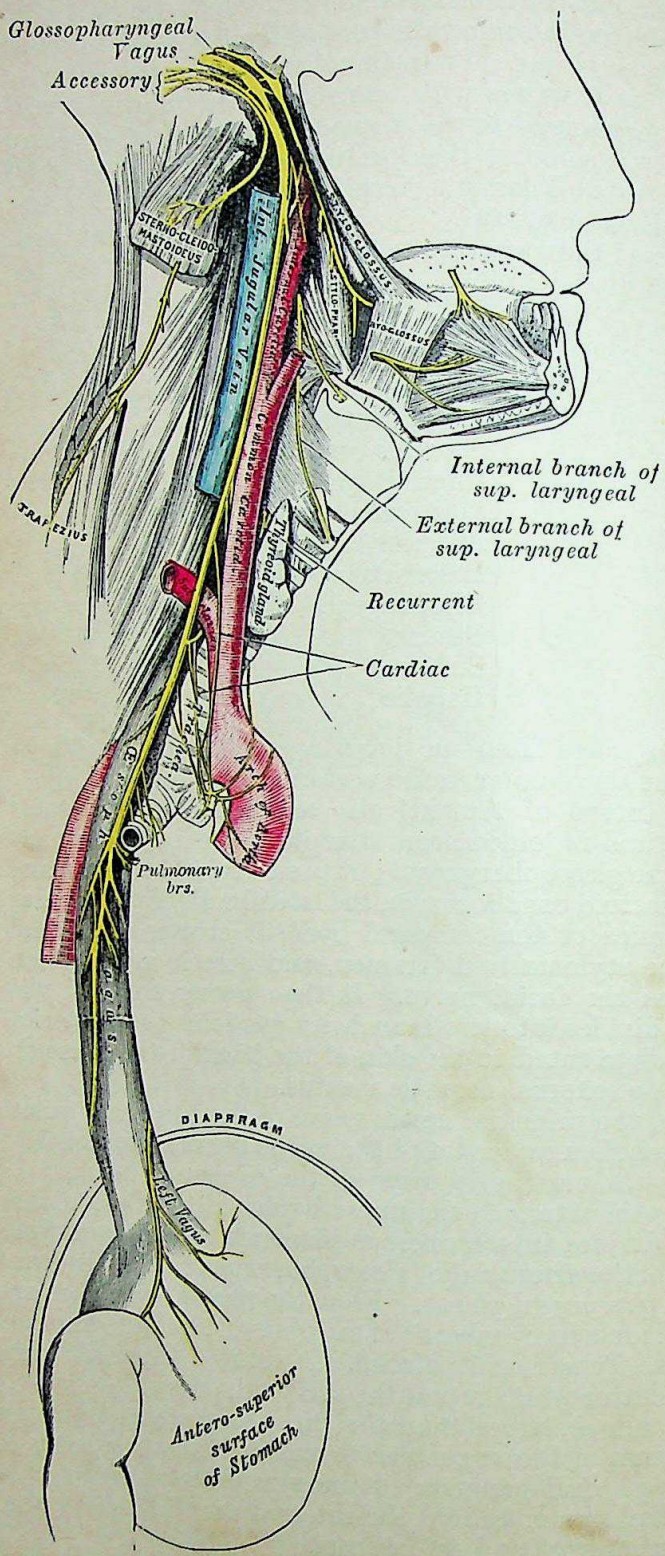

The *external branch*, the smaller, descends beneath the Sternothyreoideus: it lies at first on the Constrictor pharyngis inferior, and then passing deep to that muscle, winds round the inferior thyreoid tubercle and enters the Cricothyreoideus. It gives branches to the pharyngeal plexus and to the Constrictor pharyngis inferior; behind the common carotid artery it communicates with the superior cardiac nerve.

The **recurrent nerve** (recurrent laryngeal nerve) differs, as to its origin and course, on the two sides of the body. On the *right* side it arises from the vagus nerve in front of the first part of the subclavian artery; it winds from before backwards round that vessel, and ascends obliquely to the side of the trachea behind the common carotid artery, and either in front of or behind the inferior thyreoid artery. On the *left* side, it arises from the vagus nerve on the left of the arch of the aorta, and winds below the arch immediately behind the attachment of the ligamentum arteriosum to the concavity of the arch, and then ascends to the side of the trachea. The nerve on either side ascends in the groove between the trachea and œsophagus,† passes under the lower border of the Constrictor pharyngis inferior, and enters the larynx behind the articulation of the inferior

* Consult an article on 'The nerves of the human larynx' by T. F. M. Dilworth, *Journal of Anatomy*, vol. lvi.

† F. G. Parsons (*Journal of Anatomy*, vol. liv.) points out that the right nerve may lie at some little distance from the groove between the trachea and the œsophagus.

CC-0. In Public Domain. Gurukul Kangri Collection, Haridwar

Digitized by Arya Samaj Foundation Chennai and eGangotri

...um of the thyreoid with the cricoid cartilage; it gives branches to all the muscles of the larynx, excepting the Cricothyreoideus. It communicates with the internal branch of the superior laryngeal nerve, and gives a few filaments to the mucous membrane of the lower part of the larynx.

As the recurrent nerve hooks round the subclavian artery, or the arch of the aorta, it gives several cardiac filaments to the deep part of the cardiac plexus. As it ascends in the neck it gives branches, more numerous on the left than on the right side, to the mucous membrane and muscular coat of the œsophagus; branches to the mucous membrane and muscular fibres of the trachea; and some filaments to the Constrictor pharyngis inferior.

The **superior cardiac branches**, two or three in number, arise from the vagus nerve, at the upper and lower parts of the neck. The *upper branches* are small, and join with the cardiac branches of the sympathetic trunk. They can be traced to the deep part of the cardiac plexus.

The *lower branches* arise at the root of the neck. That from the right vagus passes in front or by the side of the innominate artery, and proceeds to the deep part of the cardiac plexus; that from the left runs down across the left side of the arch of the aorta, and joins the superficial part of the cardiac plexus.

The **inferior cardiac branches**, on the right side, arise from the trunk of the vagus nerve as it lies by the side of the trachea, and from its recurrent nerve; on the left side from the recurrent nerve only. They end in the deep part of the cardiac plexus.

The **anterior bronchial branches**, two or three in number, and of small size, are distributed on the anterior surface of the root of the lung. They join with filaments from the sympathetic, and form the *anterior pulmonary plexus*.

The **posterior bronchial branches**, more numerous and larger than the anterior, are distributed on the posterior surface of the root of the lung; they are joined by filaments from the third and fourth (sometimes also from the first and second) thoracic ganglia of the sympathetic trunk, and form the *posterior pulmonary plexus*. Branches from this plexus accompany the ramifications of the bronchi through the substance of the lung.

The **œsophageal branches** are given off both above and below the bronchial branches; the lower are more numerous and larger than the upper. They form, together with branches from the opposite nerve, the *œsophageal plexus*. From this plexus filaments are distributed to the œsophagus and to the back of the pericardium.

The **gastric branches** are distributed to the stomach. The right vagus forms the *posterior gastric plexus* on the postero-inferior surface of the stomach, and the left the *anterior gastric plexus* on the anterosuperior surface.

The **cœliac branches** are mainly derived from the right vagus: they join the cœliac plexus and through it supply branches to the pancreas, spleen, kidneys, suprarenal glands, and intestine.

The **hepatic branches** arise from the left vagus: they join the hepatic plexus and through it are conveyed to the liver.

Applied Anatomy.—The trunk of the vagus is rarely injured, but the functions of the nerve may be interfered with by damage to its nucleus of origin in the medulla; by thickening or growth from the meninges or bones, or aneurysm of the basilar artery, before it exits from the skull; injuries such as gunshot or punctured wounds in the neck, or injuries during such operations as ligature of the carotid artery, removal of tuberculous glands or other deep-seated tumours. The vagus may also be compressed by aneurysms of the carotid artery, and its deep origin becomes affected in bulbar paralysis. The symptoms produced by paralysis of the nerve are palpitation, with increased frequency of the pulse, constant vomiting, slowing of the respiration, and a sensation of suffocation.

'Reflexes' on the branches of the vagus are not at all uncommonly met with. The 'aural cough' is perhaps one of the commonest, where a plug of wax in the acoustic meatus acts, by irritating the filaments of the auricular (Arnold's) nerve, be responsible for a persistent cough. Syringing the external acoustic meatus frequently produces cough, and, in children, vomiting is not uncommon as the result of such a procedure; moreover, in people with weak hearts, syringing the ear has been responsible for a sudden fatal syncope, by reflex irritation of the cardiac branches. Another very common example is the persistent cough which is frequently due to enlarged bronchial glands in children, the irritation of which is referred to the superior laryngeal filaments.

The anatomy of the laryngeal nerves is of importance in considering some of the morbid conditions of the larynx. When the peripheral terminations of the superior laryngeal nerve are irritated by some foreign body passing over them, reflex spasm of

CC-0. In Public Domain. Gurukul Kangri Collection, Haridwar

Digitized by Arya Samaj Foundation Chennai and eGangotri

the glottis is the result. When its trunk is pressed upon by, for instance, a goitre or an aneurysm of the upper part of the carotid, there is a peculiar dry, brassy cough. When the nerve is paralysed, there is anæsthesia of the mucous membrane of the larynx so that foreign bodies can readily enter the cavity, and, as the nerve also supplies the Crico-thyreoideus muscle, the vocal folds cannot be made tense, and the voice is deep and hoarse. Paralysis may be the result of bulbar paralysis; may be a sequel to diphtheria when both nerves are usually involved; or it may, though less commonly, be caused by the pressure of tumours or aneurysms, when the paralysis is generally unilateral. Irritation of the recurrent nerves produces spasm of the muscles of the larynx. When both recurrent nerves are paralysed, the vocal folds are motionless, in the so-called 'cadaveric position'—that is to say, in the position in which they are found in ordinary tranquil respiration; neither closed as in phonation, nor widely open as in deep inspiratory efforts. When one recurrent nerve is paralysed, the vocal fold of the same side is motionless while the opposite one crosses the middle line to accommodate itself to the affected one; hence phonation is possible, but the voice is altered and weak in timbre. The nerves may be paralysed in bulbar paralysis or after diphtheria, when the paralysis usually affects both sides; or they may be affected by the pressure of aneurysms of the aorta, innominate, or subclavian arteries; by mediastinal tumours; by gummata; or by cancer of the upper part of the œsophagus, when the paralysis is often unilateral. Paralysis of the adductor muscles of the larynx on both sides is quite common, and is usually functional in nature. The voice is reduced to a whisper, but the power of coughing is preserved.

The Accessory Nerve (figs. 900, 901, 902)

The **accessory nerve** (spinal accessory nerve) consists of two parts, cerebral and a spinal.

The **cerebral part** is the smaller; its fibres arise from the cells of the nucleus ambiguus and emerge as four or five delicate rootlets from the side of the medulla oblongata, below the roots of the vagus. It runs lateralwards to the jugular foramen, where it interchanges fibres with the spinal portion or becomes united to it for a short distance; here it is also connected by one or two filaments with the jugular ganglion of the vagus. It passes through the jugular foramen, separates from the spinal portion, and is continued over the ganglion nodosum of the vagus, to the surface of which it is adherent, and is distributed principally to the pharyngeal and superior laryngeal branches of the vagus. Through the pharyngeal branch of the vagus it supplies the muscles of the soft palate, with the exception of the Tensor veli palatini. Some filaments from it are continued into the trunk of the vagus below the ganglion, to be distributed with the recurrent nerve and probably also with the cardiac nerves.

The **spinal part** is firm in texture, and its fibres arise from the motor cells in the lateral part of the anterior column of the grey substance of the medulla spinalis as low as the fifth cervical nerve. Passing through the lateral white funiculus of the medulla spinalis, they emerge on its surface and unite to form a trunk, which ascends between the ligamentum denticulatum and the posterior roots of the spinal nerves, and enters the skull through the foramen magnum, behind the vertebral artery. It is then directed upwards and lateralwards to the jugular foramen, through which it passes in the same sheath of dura mater as the vagus nerve, but separated from that nerve by a fold of the arachnoid. In the jugular foramen, it receives one or two filaments from the cerebral part of the accessory nerve, or else joins it for a short distance and then parts from it again. At its exit from the jugular foramen, it runs backwards over the internal jugular vein in about 66 per cent. of subjects, and under it in about 33 per cent. (Tandler). The nerve then descends obliquely behind the Digastricus and Stylohyoideus to the upper part of the Sternocleidomastoideus; it pierces this muscle, and courses obliquely across the posterior triangle of the neck, to end in the deep surface of the Trapezius. As it traverses the Sternocleidomastoideus it gives several filaments to the muscle, and joins with branches from the second cervical nerve. In the posterior triangle it unites with the second and third cervical nerves, while beneath the Trapezius it forms a plexus with the third and fourth cervical nerves, and from this plexus fibres are distributed to the muscle.

Applied Anatomy.—The functions of the accessory nerve may be interfered with either by central changes; in the jugular foramen, by fractures running across the jugular foramen; or in the neck, by inflamed lymph-glands, &c. The acute wry-neck in children

CC-0. In Public Domain. Gurukul Kangri Collection, Haridwar

Digitized by Arya Samaj Foundation Chennai and eGangotri

most commonly due to inflamed or suppurating glands, and rapidly subsides with appropriate treatment. Central irritation causes clonic spasm of the Sternocleidomastoideus and Trapezius muscles, or, as it is termed, spasmodic torticollis. In cases of this affection in which all previous palliative treatment has failed, and the spasms are so severe as to determine the patient's health, division or excision of a portion of the accessory nerve has been resorted to. This must be done from the anterior border of the Sternocleidomastoideus (fig. 662, p. 608). The operation consists in making an incision, 8 cm. in length, behind the apex of the mastoid process along the anterior border of the muscle, which is turned and pulled backwards so as to stretch the nerve, which is then to be sought beneath the Digastricus, about 5 cm. below the apex of the mastoid process. Unfortunately, the operation does not yield a satisfactory or permanent cure, as the spasms tend to recur after an interval, either in the same muscles or in other groups of neck muscles.

In cases where extensive dissections are undertaken for enlarged glands in the neck, it is essential that this nerve should be at once sought and isolated from the mass of inflamed glands so as to maintain its continuity.

The Hypoglossal Nerve (figs. 903, 904)

The **hypoglossal nerve** is the motor nerve of the tongue.

Its fibres arise from the cells of the hypoglossal nucleus, which is an upward prolongation of the base of the anterior column of grey substance of the medulla

Fig. 903.—The right hypoglossal nerve and cervical plexus.

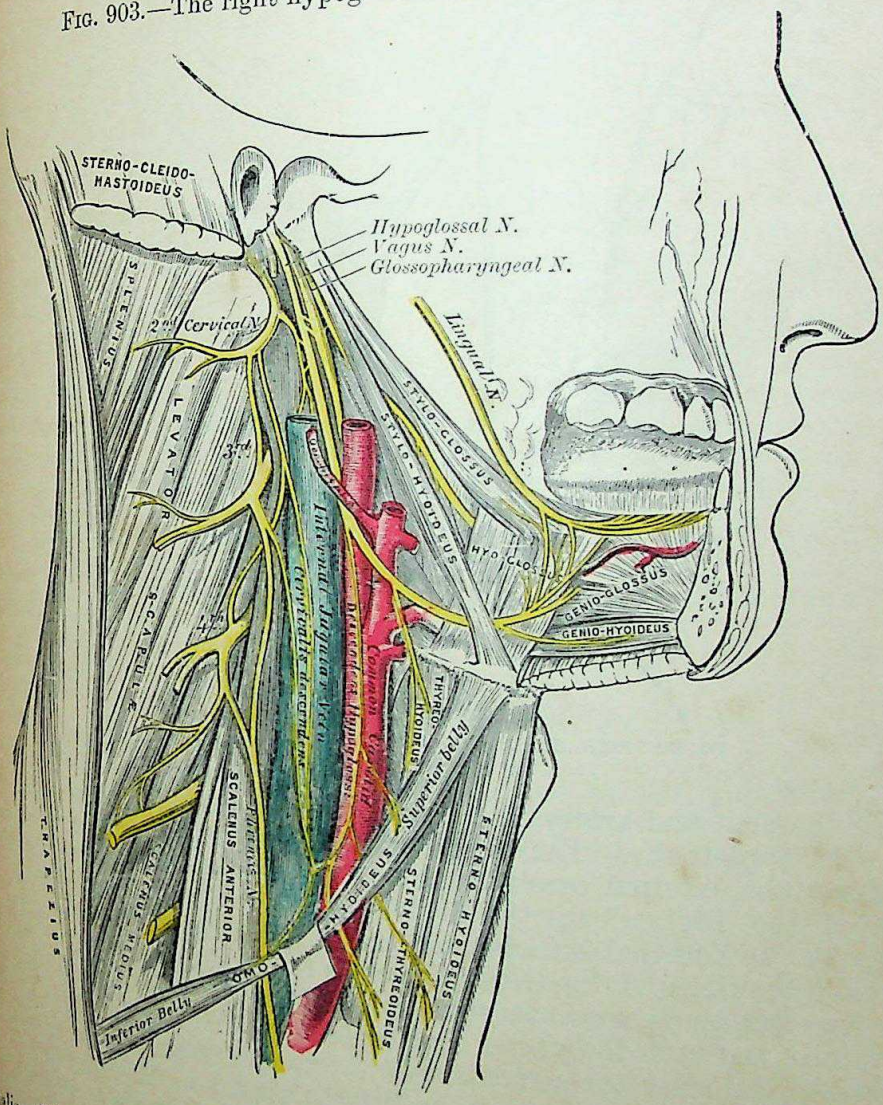

medialis. This nucleus is about 2 cm. long, and its upper part corresponds with the trigonum hypoglossi, or lower portion of the medial eminence of the rhomboid fossa (p. 824). The lower part of the nucleus extends downwards into the closed part of the medulla oblongata, and there lies in relation to the ventrolateral aspect of the central canal. The fibres run forwards through

CC-0. In Public Domain. Gurukul Kangri Collection, Haridwar

Digitized by Arya Samaj Foundation Chennai and eGangotri

the medulla oblongata, and emerge in the anterolateral sulcus between the pyramid and the olive.

The rootlets of this nerve run lateralwards behind the vertebral artery and are collected into two bundles, which perforate the dura mater separately, opposite the hypoglossal canal in the occipital bone, and unite together after their passage through it; in some cases the canal is divided into two by a small bony spicule. The nerve descends almost vertically to a point corresponding with the angle of the mandible. It is at first deeply seated beneath the internal carotid artery and internal jugular vein, and intimately connected with the vagus nerve; it then passes forwards

Fig. 904.—A plan of the hypoglossal nerve.

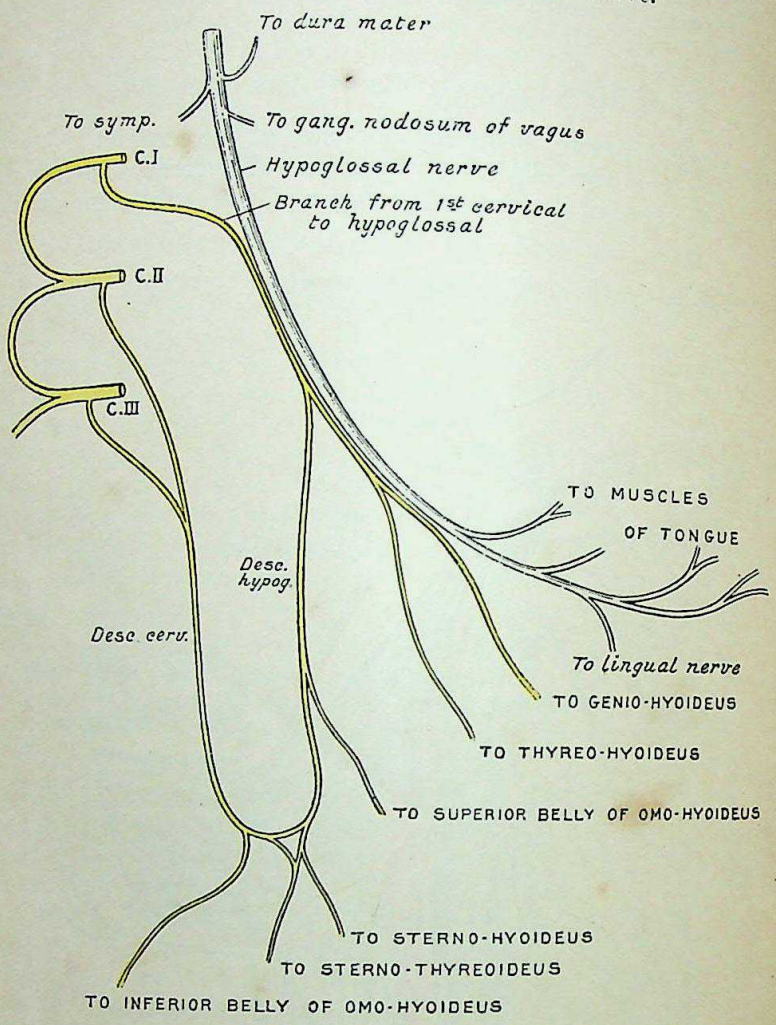

between the vein and artery, and lower down in the neck becomes superficial below the Digastricus. The nerve then loops round the occipital artery and crosses the external carotid and lingual arteries. It passes beneath the tendon of the Digastricus, the Stylohyoideus, and the Mylohyoideus, lying between the last-named muscle and the Hyoglossus, and is then continued forwards in the fibres of the Genioglossus as far as the tip of the tongue, distributing branches to its muscular substance. It communicates with the sympathetic trunk, and with the vagus, first and second cervical, and lingual nerves.

Opposite the atlas the nerve receives branches from the superior cervical ganglion of the sympathetic trunk, and at the same level is joined by a filament from the loop connecting the first and second cervical nerves.

The communications with the vagus nerve take place close to the skull, numerous filaments passing between the hypoglossal nerve and the ganglion nodosum of the vagus nerve through the mass of connective tissue which unites the two nerves. As the nerve winds round the occipital artery it gives off a filament to the pharyngeal plexus.

CC-0. In Public Domain. Gurukul Kangri Collection, Haridwar

Digitized by Arya Samaj Foundation Chennai and eGangotri

Near the anterior border of the Hyoglossus it is united to the lingual nerve by numerous filaments which ascend upon the muscle.

The *branches of distribution* of the hypoglossal nerve are :

Meningeal. Thyreohyoid.
Descending. Muscular.

Of these branches the meningeal, descending, thyreohyoid, and that to the Genihyoideus, are probably derived mainly from the branch which passes from the loop between the first and second cervical nerves to join the hypoglossal (fig. 904).

Meningeal branches.—As the hypoglossal nerve passes through the hypoglossal canal it supplies several filaments to the dura mater in the posterior fossa of the skull.

The **descending ramus**, long and slender, quits the hypoglossal nerve where the latter turns round the occipital artery, and descends in front of or within the sheath of the carotid vessels ; it gives a branch to the superior belly of the Omohyoideus, and, just below the middle of the neck, joins the communicantes cervicales from the second and third cervical nerves to form a loop, the *ansa hypoglossi*. From the convexity of this loop branches pass to supply the Sternohyoideus, the Sternothyreoideus, and the inferior belly of the Omohyoideus. According to Arnold, another filament descends in front of the vessels into the thorax, and joins the cardiac and phrenic nerves.

The **thyreohyoid branch** arises from the hypoglossal nerve near the posterior border of the Hyoglossus ; it runs obliquely across the greater cornu of the hyoid bone, and supplies the Thyreohyoideus muscle.

The **muscular branches** are distributed to the Styloglossus, Hyoglossus, Genihyoideus, and Genioglossus. Numerous slender branches pass upwards into the substance of the tongue to supply its intrinsic muscles.

Applied Anatomy.—The hypoglossal nerve is an important guide in the operation of ligature of the lingual artery (p. 612). It runs forwards on the Hyoglossus just above the greater cornu of the hyoid bone, and forms the upper boundary of the triangular space in which the artery is to be sought by cutting through the fibres of the Hyoglossus. In cases where the nerve is involved by gumma or new growth of the base of the skull, or where it has been injured on one side of the neck, or in some cases of bulbar paralysis, unilateral paralysis, together with hemiatrophy of the tongue, results; the tongue, when protruded, being directed to the paralysed side owing to the unopposed action of the Genioglossus of the opposite side. On retraction, the wasted and paralysed side of the tongue rises up higher than the other. The larynx may deviate towards the sound side on swallowing, from the unilateral paralysis of the depressors of the hyoid bone. If the paralysis is bilateral, e.g. the result of a bullet wound of the infrahyoid region, the tongue is motionless in the mouth, taste and tactile sensibility of the organ are perfect, articulation is slow and sticky; swallowing is very difficult, and the patient has to throw his head backwards and push the bolus of food back into the pharynx with his finger before he can swallow it.

THE SPINAL NERVES

The **spinal nerves** spring from the medulla spinalis, and pass through the intervertebral foramina. They number thirty-one pairs, which are grouped as follows: cervical, 8 ; thoracic, 12 ; lumbar, 5 ; sacral, 5 ; coccygeal, 1.

The first cervical nerve emerges from the vertebral canal between the occipital bone and the atlas vertebra, and is therefore called the *suboccipital nerve*; the eighth issues between the seventh cervical and first thoracic vertebræ.

Nerve-roots.—Each nerve is attached to the medulla spinalis by an anterior and a posterior root (p. 797), the latter being characterised by the presence of a ganglion, the *spinal ganglion*.

The **anterior root** emerges from the anterior surface of the medulla spinalis as a number of rootlets or filaments (fila radicularia), which coalesce to form two bundles near the intervertebral foramen.

The **posterior root** (except in the case of the first cervical nerve) is larger than the anterior ; its rootlets are attached along the posterolateral furrow of the medulla spinalis and unite to form two bundles which join the spinal ganglion.

The **spinal ganglia** are collections of nerve-cells on the posterior roots of the spinal nerves. Each ganglion is oval in shape, reddish in colour, and

CC-0. In Public Domain. Gurukul Kangri Collection, Haridwar

Digitized by Arya Samaj Foundation Chennai and eGangotri

its size bears a proportion to that of the nerve-root on which it is situated; it is bifid medially where it is joined by the two bundles of the posterior nerve-root. The ganglia are usually placed in the intervertebral foramina, immediately outside the points where the nerve-roots perforate the dura mater, but

FIG. 905.—Sketches showing the central connexions of the somatic fibres (A) and autonomic fibres (B) of a typical spinal nerve. The efferent fibres are represented by *red*, and the afferent fibres by *blue*, lines.

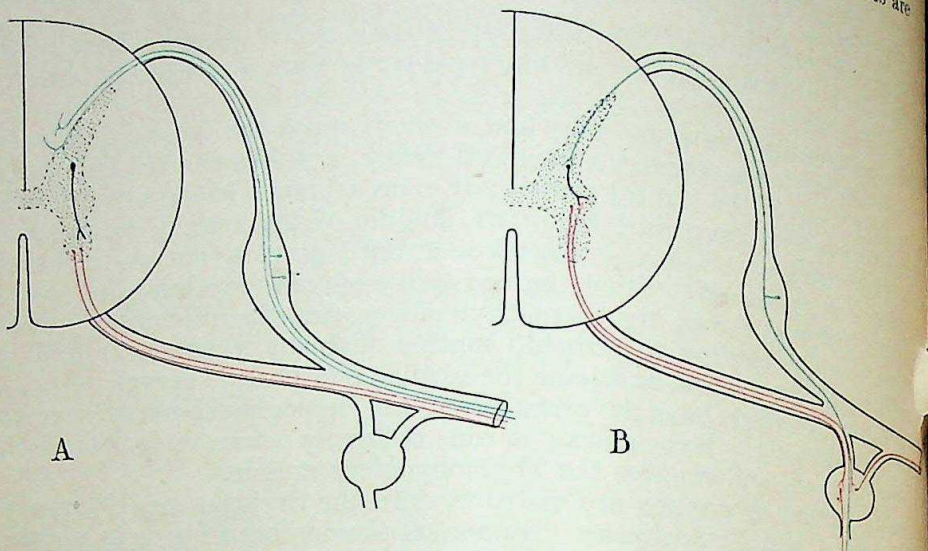

the ganglia of the first and second cervical nerves lie on the vertebral arches of the atlas and epistropheus, and those of the sacral nerves are inside the vertebral canal, and that of the coccygeal nerve is within the sheath of dura mater.

Structure.—The ganglia consist chiefly of unipolar nerve-cells, and from these the fibres of the posterior root take origin; the single process of each cell divides after a short course into a central fibre which enters the medulla spinalis and a peripheral fibre which runs into the spinal nerve (fig. 906). Two other forms of cells are said to be present, viz.: (*a*) the cells of Dogiel, whose axons ramify close to the cell (type II. of Golgi) and are distributed entirely within the ganglion; and (*b*) multipolar cells similar to those found in the sympathetic ganglia.

The ganglia of the first pair of cervical nerves may be absent, while small *aberrant ganglia* consisting of groups of nerve-cells are sometimes found on the posterior roots of the upper cervical nerves between the spinal ganglia and the medulla spinalis.

Each nerve-root receives a covering from the pia mater, and is loosely invested by the arachnoid, the latter being prolonged as far as the points where the roots pierce the dura mater. The two roots pierce the dura mater separately, each receiving a sheath from this membrane; where the roots join to form the spinal nerve this sheath is continuous with the epineurium of the nerve.

Size and direction.—The roots of the upper four *cervical* nerves are small, those of the lower four are large. The posterior roots of the cervical nerves bear a proportion to the anterior of three to one, which is greater than in the other regions; their individual filaments are also larger than those of the anterior roots. The posterior root of the first cervical is an exception to this, being smaller than the anterior root; in about eight per cent. of cases it is wanting. The roots of the first and second cervical nerves are short, and run nearly horizontally to their points of exit from the vertebral canal. From the third to the eighth cervical they are directed obliquely downwards, the obliquity and length of the roots successively increasing; the distance, however, between the level of attachment of any of these roots to the medulla spinalis and the points of exit of the corresponding nerves never exceeds the height of one vertebra.

The roots of the *thoracic* nerves, with the exception of the first, are of small size, and the posterior roots only slightly exceed the anterior in thickness. They increase successively in length, from above downwards, and, in the lower

CC-0. In Public Domain. Gurukul Kangri Collection, Haridwar

Digitized by Arya Samaj Foundation Chennai and eGangotri

the thoracic region, descend in contact with the medulla spinalis for e equal to the height of at least two vertebræ before they emerge rtebral canal.

roots of the lower *lumbar* and upper *sacral* nerves are the largest, and individual filaments the most numerous of all the spinal nerves, while s of the *coccygeal* nerve are the smallest.

roots of the lumbar, sacral, and coccygeal nerves run vertically down- to their respective exits, and as the medulla spinalis ends near the lower of the first lumbar vertebra it follows that the lengths of the successive must rapidly increase. As already mentioned (p. 784), the term *cauda* is applied to this collection of nerve-roots.

FIG. 906.—A scheme showing the structure of a typical spinal nerve.

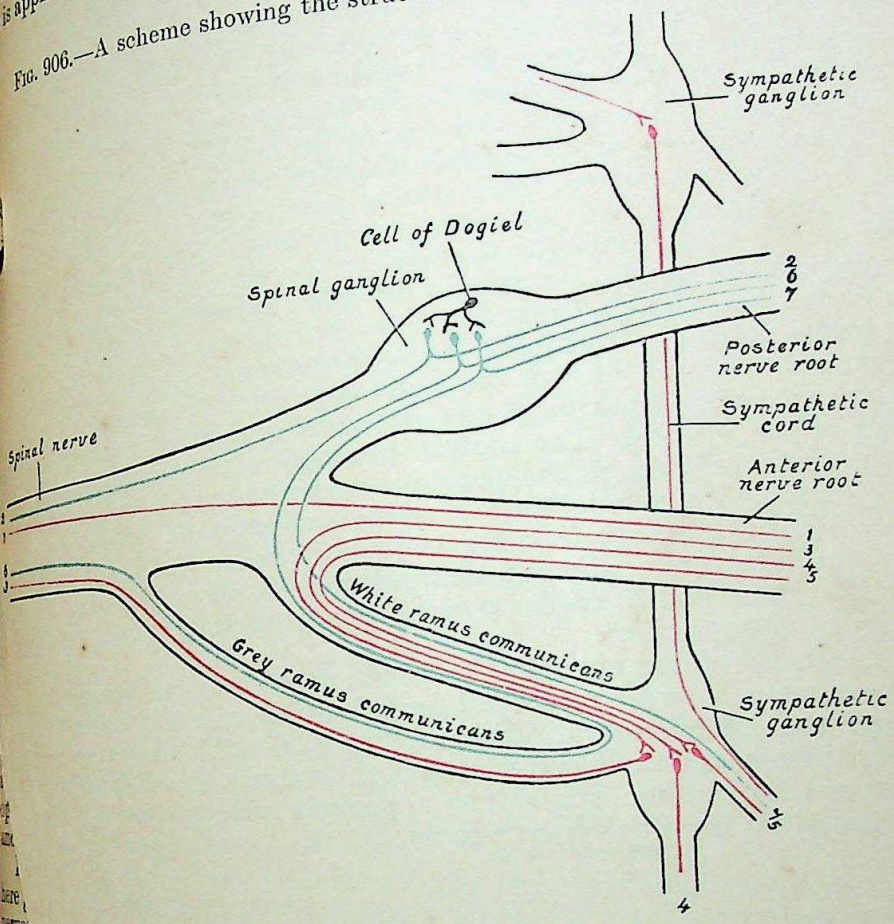

tic efferent. 2. Somatic afferent. 3, 4, 5. Autonomic efferent. 6, 7. Autonomic afferent.

the description given it will be seen that the largest nerve-roots, and ntly the largest spinal nerves, are attached to the cervical and lumbar of the medulla spinalis; these nerves are distributed to the upper r limbs.

diately beyond the spinal ganglion, the anterior and posterior nerve- te to form the *spinal nerve* which emerges through the intervertebral

xions with the sympathetic trunks.—After emerging from ertebral foramen each spinal nerve receives a branch (*grey ramus ns*) from the adjacent ganglion of the sympathetic trunk, while and the first and second lumbar nerves each contribute a branch *communicans*) to the adjoining sympathetic ganglion. The Lat and fourth sacral nerves also supply white rami; these, however, cted with the ganglia of the sympathetic trunk, but run directly lexuses.

905, 906).—Each typical spinal nerve contains fibres be- viz. the somatic and the autonomic (p. 969), as well

CC-0. In Public Domain. Gurukul Kangri Collection, Haridwar

Digitized by Arya Samaj Foundation Chennai and eGangotri

1. The *somatic efferent* fibres originate in the cells of the anterior grey of the medulla spinalis, and run outwards through the anterior nerve-roots the spinal nerve. They convey impulses to the voluntary muscles, continuous from their origin to their peripheral distribution. The *afferent* fibres convey impressions inwards from the skin, &c., and orig the unipolar nerve-cells of the spinal ganglia. The single processes of cells divide into peripheral and central fibres, and the latter enter the spinalis through the posterior nerve-roots.

2. The *autonomic* fibres are also efferent and afferent. The eff *preganglionic* fibres originate in the lateral column of the medulla spinal are conveyed through the anterior nerve-root and the white ramus comm Those issuing from the thoracic and lumbar regions of the medulla spin part of the *sympathetic* system and pass to the corresponding ganglion sympathetic trunk; here they may end by forming synapses around its or may run through the ganglion to end in another of the ganglia of the pathetic trunk, or in a more distally placed ganglion in one of the sympa plexuses. In all cases they end by forming synapses around other nerve From the cells of the ganglia of the sympathetic trunk other fibres (post *glionic*) take origin; some of these run through the grey rami communica to join the spinal nerves, while others pass to the viscera, either direc after interruption in one of the distal ganglia. The fibres issuing fro sacral region of the medulla spinalis are *parasympathetic*; they do no the sympathetic ganglia but pass as the *pelvic splanchnic nerves* of Gaskel pelvic plexuses. The *afferent* fibres are derived partly from the unipola and partly from the multipolar cells of the spinal ganglia. Their peri processes are carried through the white rami communicantes, and after without interruption through one or more sympathetic ganglia end i tissues of the viscera. The central processes of the unipolar cells ente medulla spinalis through the posterior nerve-roots and form synapses a either somatic or sympathetic efferent neurons, thus completing reflex Some authorities believe that the cells of Dogiel in the spinal ganglia (p bring the autonomic afferent neurons into relationship with those of somatic system, and so render possible the transference of an impulse from former to the sensorium.

Divisions.—After emerging from the intervertebral foramen, each sp nerve supplies a small *meningeal branch* which re-enters the vertebral c through the intervertebral foramen and is distributed to the vertebra their ligaments, and the blood-vessels of the medulla spinalis and its membr The spinal nerve then splits into a *posterior* and an *anterior* division receiving fibres from both nerve-roots.

THE POSTERIOR DIVISIONS OF THE SPINAL NERVES

The **posterior divisions** of the spinal nerves are as a rule smaller anterior. They are directed backwards, and, with the exceptions of the first cervical, the fourth and fifth sacral, and the coccygeal, div medial and lateral branches for the supply of the muscles and skin of the posterior part of the trunk.

The Posterior Divisions of the Cervical Nerves

The **posterior division of the first cervical or suboccipital** larger than the anterior division, and emerges above the posterior ar atlas and beneath the vertebral artery. It enters the suboccipital tr supplies the muscles which bound this triangle, viz. the Rectus major, and the Obliqui superior et inferior; it gives branch Rectus capitis posterior minor and the Semispinalis capitis. A the branch to the Obliquus inferior joins the posterior divisi cervical nerve.

CC-0. In Public Domain. Gurukul Kangri Collection, Haridwar

The nerve ... gth, ... which
th ... uc ... and, in the lower

Digitized by Arya Samaj Foundation Chennai and eGangotri

THE ANTERIOR DIVISIONS OF THE SPINAL NERVES

The **anterior divisions of the spinal nerves** supply the anterolateral parts of the trunk, and the limbs; they are for the most part larger than the posterior divisions. In the thoracic region they run independently of one another, but in the cervical, lumbar, and sacral regions they unite near their origins to form plexuses.

THE ANTERIOR DIVISIONS OF THE CERVICAL NERVES

The **anterior divisions of the cervical nerves**, with the exception of the first, appear between the corresponding anterior and posterior intertransverse muscles. The anterior divisions of the *upper four* nerves unite to form the *cervical plexus*; those of the *lower four*, together with the greater part of the anterior division of the first thoracic nerve, join to form the *brachial plexus*.

Each nerve receives a grey ramus communicans, the upper four from the superior cervical ganglion, the fifth and sixth from the middle cervical ganglion, and the seventh and eighth from the inferior cervical ganglion, of the sympathetic trunk.

The anterior division of the *first cervical* (*suboccipital*) *nerve* appears above the posterior arch of the atlas vertebra, and passes forwards round the lateral side of its superior articular process, medial to the vertebral artery. It supplies a branch to the Rectus lateralis, and, emerging on the medial side of that muscle, descends in front of the transverse process of the atlas and joins with the ascending branch of the second nerve.

The anterior division of the *second cervical nerve* issues between the neural arches of the atlas and epistropheus and runs forwards between the transverse processes of these two vertebræ, passing under cover of the first posterior intertransverse muscle and on the lateral side of the vertebral artery. It divides into an ascending branch which joins with the first cervical nerve, and a descending branch which unites with the ascending branch of the third cervical nerve.

The Cervical Plexus

The **cervical plexus** (fig. 908) is formed by the anterior divisions of the upper four cervical nerves; each nerve, except the first, divides into an upper and a lower branch, and these unite to form three loops. The plexus is situated opposite the upper four cervical vertebræ, in front of the Levator scapulæ and Scalenus medius, and beneath the Sternocleidomastoideus.

Its branches are divided into two groups, *superficial* and *deep*, and are here given in tabular form; the figures following the names indicate the spinal nerves from which the different branches take origin:

Superficial		Smaller occipital	2 C.
		Great auricular	2, 3 C.
		Cutaneous cervical	2, 3 C.
		Supraclavicular	3, 4 C.
Deep	Medial	Communicating	With hypoglossal — 1, 2 C.
			,, vagus — 1, 2 C.
			,, sympathetic — 1, 2, 3, 4 C.
		Muscular	Rectus capitis lateralis — 1 C.
			Rectus capitis anterior — 1, 2 C.
			Longus capitis — 1, 2, 3 C.
			Longus colli — 2, 3, 4 C.
			Communicantes cervicales — 2, 3 C.
			Phrenic — 3, 4, 5 C.
	Lateral	Communicating with accessory	2, 3, 4 C.
		Muscular	Sternocleidomastoideus — 2 C.
			Trapezius — 3, 4 C.
			Levator scapulæ — 3, 4 C.
			Scalenus medius — 3, 4 C.

CC-0. In Public Domain. Gurukul Kangri Collection, Haridwar

Digitized by Arya Samaj Foundation Chennai and eGangotri

THE SUPERFICIAL BRANCHES OF THE CERVICAL PLEXUS (figs. 908, 909)

The **smaller occipital nerve** arises from the second cervical nerve, sometimes also from the third; it hooks round the accessory nerve and ascends along the posterior border of the Sternocleidomastoideus. Near the cranium it perforates the deep fascia, and is continued upwards along the side of the head behind the auricula, supplying the skin and communicating with the great auricular and greater occipital nerves, and with the posterior auricular branch of the facial nerve. The smaller occipital nerve varies in size, and is sometimes duplicated.

FIG. 908.—A plan of the cervical plexus.

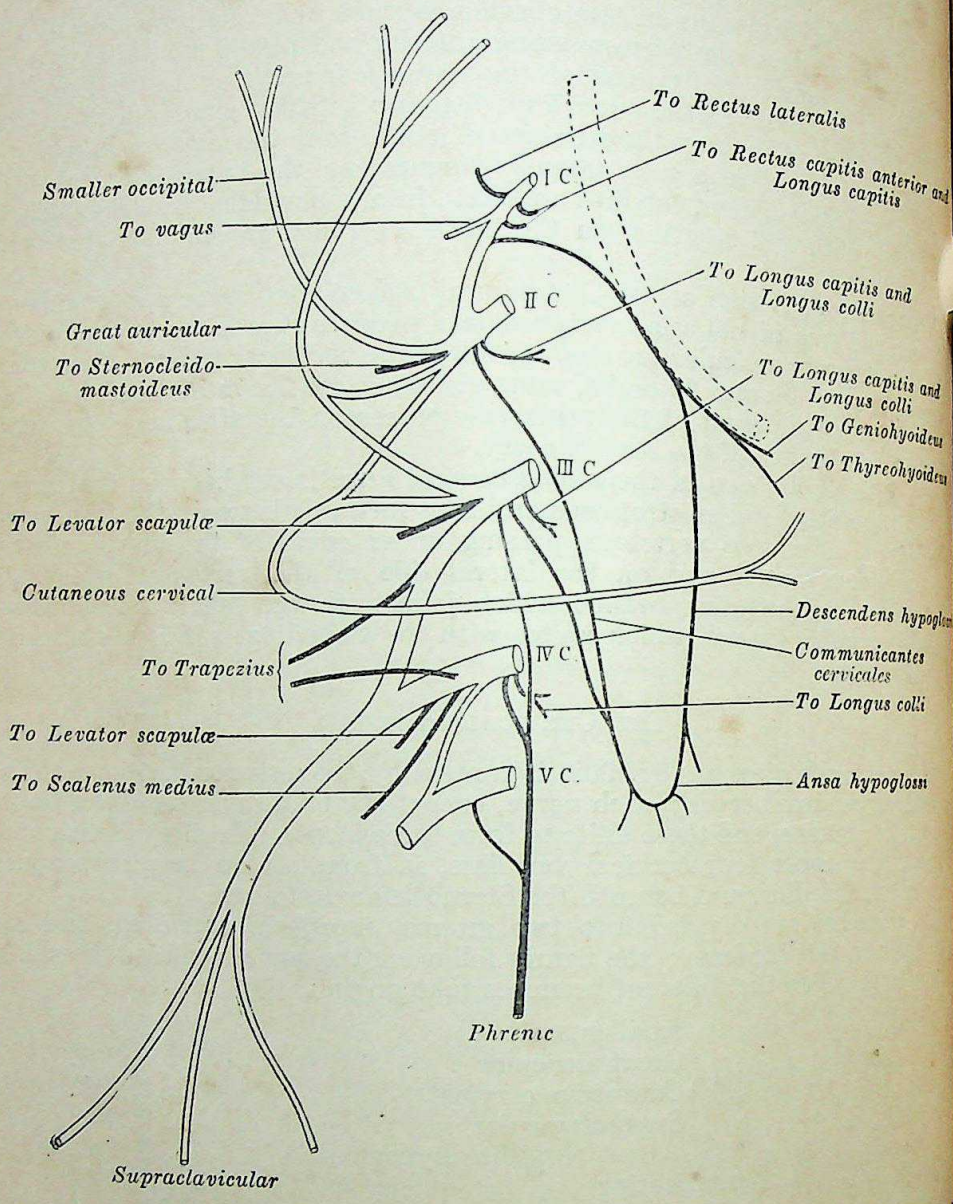

It sends off an *auricular branch* which supplies the skin of the upper third of the cranial surface of the auricula, and communicates with the mastoid branch of the great auricular nerve. The auricular branch is occasionally derived from the greater occipital nerve.

The **great auricular nerve** is the largest of the ascending branches. It arises from the second and third cervical nerves, winds round the posterior border of the Sternocleidomastoideus, and, after perforating the deep fascia, ascends upon that muscle beneath the Platysma to the parotid gland, where it divides into an anterior and a posterior branch.

The *anterior branch* is distributed to the skin of the face over the parotid gland, and communicates in the substance of the gland with the facial nerve.

CC-0. In Public Domain. Gurukul Kangri Collection, Haridwar

Digitized by Arya Samaj Foundation Chennai and eGangotri

The *posterior branch* supplies the skin over the mastoid process and on the back of the auricula, except at its upper part; a filament pierces the auricula to reach its lateral surface, where it is distributed to the lobule and lower part of the concha. The posterior branch communicates with the smaller occipital nerve, the auricular branch of the vagus nerve, and the posterior auricular branch of the facial nerve.

FIG. 909.—The nerves of the right side of the scalp, face, and side of neck.

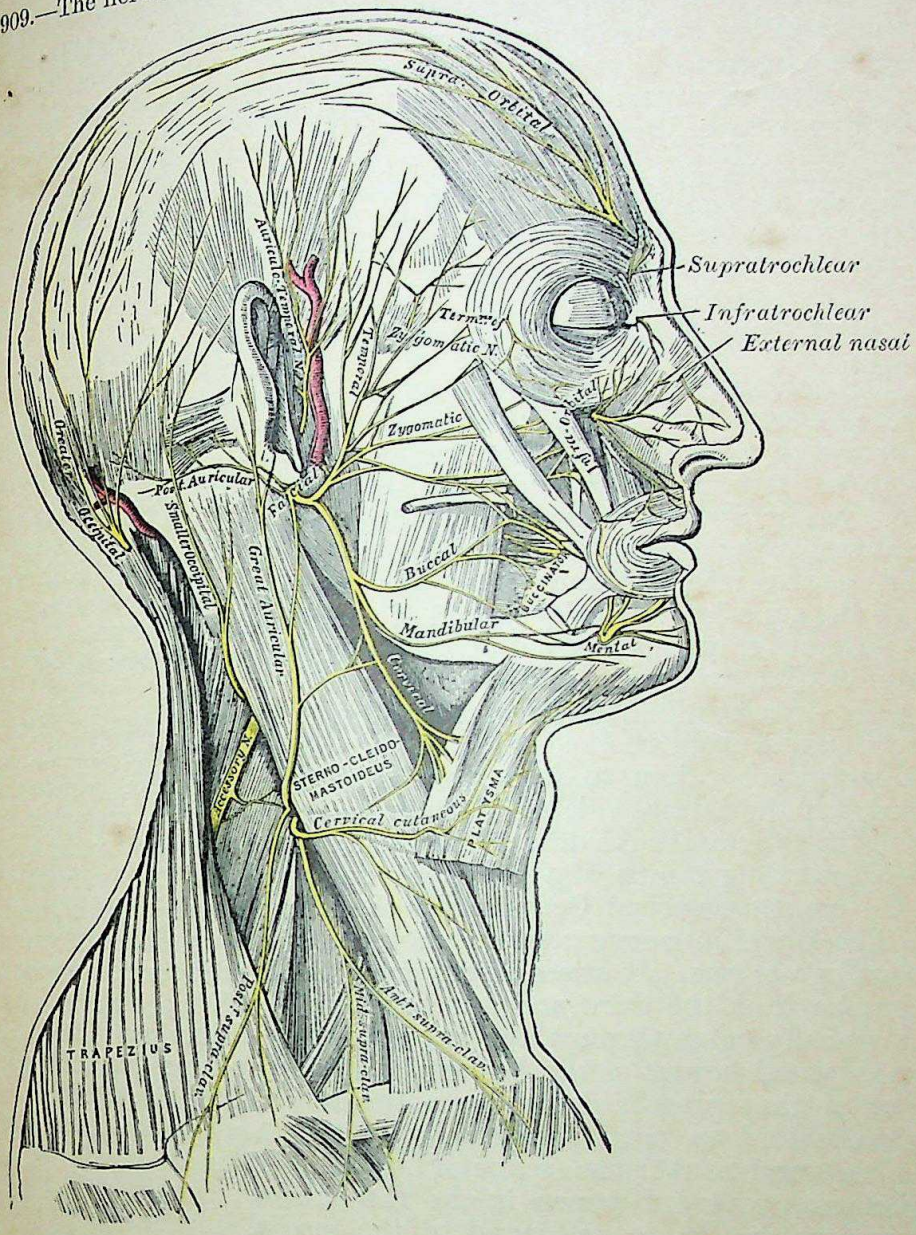

The **cutaneous cervical nerve** (transverse cervical nerve) arises from the second and third cervical nerves, turns round the posterior border of the sternocleidomastoideus about its middle, and passes obliquely forwards behind the external jugular vein to the anterior border of the muscle. It perforates the deep cervical fascia, and divides beneath the Platysma into ascending and descending branches, which are distributed to the anterolateral parts of the neck.

The *ascending branches* pass upwards to the submaxillary region, and form a plexus with the cervical branch of the facial nerve, beneath the Platysma; others pierce that muscle, and are distributed to the skin of the upper and front parts of the neck.

The *descending branches* pierce the Platysma, and are distributed to the skin of the side and front of the neck, as low as the sternum.

The **supraclavicular nerves** arise by a common trunk derived from the third and fourth cervical nerves. This trunk emerges from beneath the posterior

CC-0. In Public Domain. Gurukul Kangri Collection, Haridwar

Digitized by Arya Samaj Foundation Chennai and eGangotri

border of the Sternocleidomastoideus, descends under cover of the Platysma and deep cervical fascia, and subdivides into anterior, middle, and posterior branches which diverge from one another and pierce the deep fascia a little above the level of the clavicle.

The *anterior supraclavicular nerves* cross obliquely over the external jugular vein and the clavicular and sternal heads of the Sternocleidomastoideus, and supply the skin as far as the middle line. They furnish one or two filaments to the sternoclavicular joint.

The *middle supraclavicular nerves* cross the clavicle, and supply the skin over the Pectoralis major and Deltoideus, communicating with the cutaneous branches of the upper intercostal nerves.

The *posterior supraclavicular nerves* pass obliquely across the outer surface of the Trapezius and the acromion, and supply the skin of the upper and posterior parts of the shoulder.

Applied Anatomy.—Pains referred to the superficial terminal branches of the cervical plexus are not uncommon in caries of the cervical vertebræ, where pain may be felt radiating over the occipital bone, if the disease is situated high up in the vertebral column.

The Deep Branches of the Cervical Plexus. Medial Series

The **communicating branches** consist of several filaments, which pass from the loop between the first and second cervical nerves to the vagus, hypoglossal, and sympathetic. The branch to the hypoglossal ultimately leaves that nerve as a series of branches, viz. the meningeal, the descending ramus, the nerve to the Thyreohyoideus and the nerve to the Geniohyoideus (p. 925). A communicating branch also passes from the fourth to the fifth cervical nerve, while each of the first four cervical nerves receives a grey ramus communicans from the superior cervical ganglion of the sympathetic trunk.

Muscular branches supply the Rectus capitis lateralis, Rectus capitis anterior, Longus capitis, and Longus colli.

The **communicantes cervicales** (fig. 908) consist usually of two branches, one derived from the second and the other from the third cervical nerve. These branches join to form the *descendens cervicalis*, which passes downwards on the lateral side of the internal jugular vein, crosses in front of this vein a little below the middle of the neck, and forms a loop (*ansa hypoglossi*) with the descending ramus of the hypoglossal nerve (p. 925) in front of the sheath of the carotid vessels. Occasionally the loop is formed within the sheath.

The **phrenic nerve** contains motor and sensory fibres in the proportion of about two to one. It arises chiefly from the fourth cervical nerve, but receives a branch from the third and another from the fifth; the fibres from the fifth occasionally come through the nerve to the Subclavius (p. 937). It is formed at the lateral border of the Scalenus anterior, and running obliquely across the front of that muscle, descends to the root of the neck, beneath the Sternocleidomastoideus, the inferior belly of the Omohyoideus, and the transverse cervical and transverse scapular vessels. It next passes in front of the subclavian artery, between it and the subclavian vein, and, as it enters the thorax, crosses from the lateral to the medial side of the internal mammary artery. Within the thorax, it descends nearly vertically in front of the root of the lung, and then between the pericardium and the mediastinal pleura, to the Diaphragm, where it divides into branches which pierce that muscle, and are distributed to its under surface. In the thorax it is accompanied by the pericardiacophrenic branch of the internal mammary artery.

The two phrenic nerves differ in their length, and also in their relations at the upper part of the thorax.

The *right nerve* is situated more deeply, and is shorter and more vertical in direction than the left. It descends in front of the Scalenus anterior which separates it from the second part of the subclavian artery. It lies lateral to the right innominate vein and superior vena cava.

The *left nerve* is rather longer than the right, owing to the inclination of the heart to the left side, and from the Diaphragm being lower on this than on the right side. At the root of the neck it crosses the first part of the subclavian artery, and is crossed by the thoracic duct. In the superior mediastinal cavity

CC-0. In Public Domain. Gurukul Kangri Collection, Haridwar

Digitized by Arya Samaj Foundation Chennai and eGangotri

It lies between the left common carotid and left subclavian arteries, and crosses superficial to the vagus on the left side of the arch of the aorta.

Each nerve supplies branches to the pericardium and pleura, and at the root of the neck is joined by a filament from the sympathetic, and, occasionally, by one from the ansa hypoglossi.

From the *right nerve*, one or two filaments pass to join in a small *phrenic ganglion* with phrenic branches of the cœliac plexus; and branches from this ganglion are distributed to the falciform and coronary ligaments of the liver, the suprarenal gland, and inferior vena cava. From the *left nerve*, filaments pass to join the phrenic branches of the cœliac plexus, but without any ganglionic enlargement; and a twig is distributed to the left suprarenal gland.

Applied Anatomy.—In addition to its supply from the phrenics, the Diaphragm receives both motor and sensory nerve-fibres from the lower seven intercostal nerves at its rim. This double sensory innervation explains the varied distribution of the referred pains that may be felt in different cases of infection or inflammation of the Diaphragm, such as may occur in pleurisy or pneumonia affecting its upper surface, on the one hand, or in peritonitis attacking its lower surface on the other. For example, if it is the more central part of the Diaphragm that becomes inflamed in a case of acute peritonitis, the patient may complain of pain and tenderness in the area of distribution of the cutaneous branches of the fourth and fifth cervical nerves, with the result that disease of the shoulder-joint or supraclavicular region is erroneously suspected, and the peritonitis is missed. Contrariwise, if the periphery of the Diaphragm chances to become infected in a patient with acute pleurisy or pneumonia, he may complain of acute pain and tenderness in the area of distribution of the cutaneous branches of the lower intercostal nerves, and may also exhibit rigidity of the underlying abdominal muscles, with the result that an acute intra-abdominal infection is erroneously diagnosed and a laparotomy is performed for the relief of a supposed appendicitis, cholecystitis, or localised peritonitis.

The Deep Branches of the Cervical Plexus. Lateral Series

Communicating branches.—The lateral series of deep branches of the cervical plexus communicates with the accessory nerve, in the substance of the Sternocleidomastoideus, in the posterior triangle, and beneath the Trapezius.

Muscular branches are distributed to the Sternocleidomastoideus, Trapezius, Levator scapulæ, and Scalenus medius.

The branch for the Sternocleidomastoideus is derived from the second cervical nerve; the Trapezius and Levator scapulæ receive branches from the third and fourth cervical nerves. The Scalenus medius receives twigs either from the third or fourth cervical nerves, or occasionally from both.

The Brachial Plexus

The **brachial plexus** (fig. 910) is formed by the union of the anterior divisions of the lower four cervical nerves and the greater part of the anterior division of the first thoracic nerve; the fourth cervical nerve usually gives a branch to the fifth cervical, and the first thoracic nerve frequently receives one from the second thoracic. The plexus extends from the lower part of the side of the neck to the axilla. The nerves which form it are nearly equal in size, but their mode of communication is subject to some variation. The following is, however, the most constant arrangement. The fifth and sixth cervical nerves unite at the lateral border of the Scalenus medius to form a trunk. The eighth cervical and first thoracic nerves unite behind the Scalenus anterior to form a trunk, while the seventh cervical nerve runs alone. Three trunks—upper, middle, and lower—are thus formed, and, as they pass beneath the clavicle, each splits into an *anterior* and a *posterior* division.* The anterior divisions of the upper and middle trunks unite to form a cord, which is situated on the lateral side of the second part of the axillary artery, and is called the *lateral cord or fasciculus* of the plexus. The anterior division of the lower trunk passes down on the medial side of the second part of the axillary artery, and forms the *medial cord or fasciculus* of the brachial plexus; this cord frequently receives fibres from the seventh cervical nerve. The posterior

* The posterior division of the lower trunk is very much smaller than the others, and is frequently derived entirely from the eighth cervical nerve.

CC-0. In Public Domain. Gurukul Kangri Collection, Haridwar

Digitized by Arya Samaj Foundation Chennai and eGangotri

divisions of all three trunks unite to form the *posterior cord or fasciculus* of the plexus, which is situated behind the second portion of the axillary artery.

Relations.—*In the neck*, the brachial plexus lies in the posterior triangle, being covered by the skin, Platysma, and deep fascia; it is crossed by the supraclavicular nerves, the nerve to the Subclavius, the inferior belly of the Omohyoideus, the external jugular vein, and the transverse cervical artery. It emerges between the Scalenus anterior and Scalenus medius; its upper part lies above the third part of the subclavian artery, while the trunk formed by the union of the eighth cervical and first thoracic nerves is placed behind the artery; the plexus next passes behind the clavicle, the Subclavius, and the

Fig. 910.—A plan of the brachial plexus.

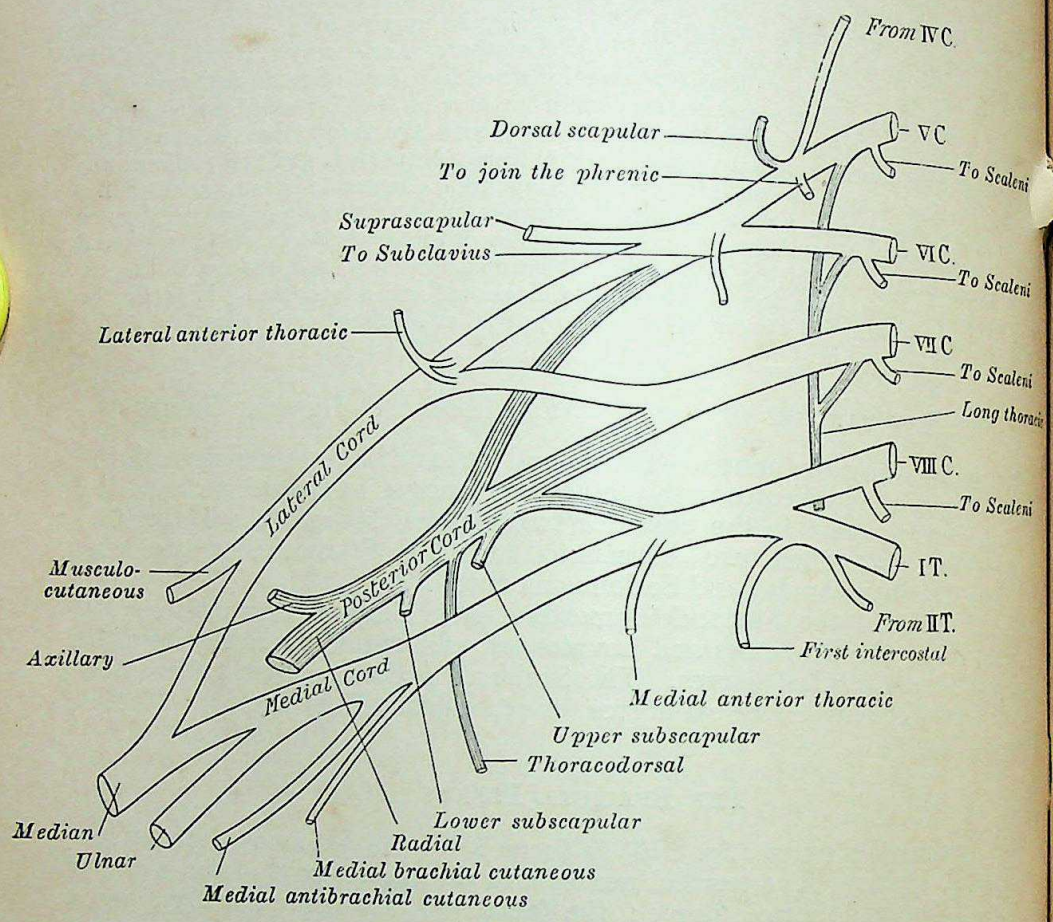

transverse scapular vessels, and lies upon the first digitation of the Serratus anterior, and the Subscapularis. *In the axilla* the lateral and posterior cords of the plexus are on the lateral side of the first part of the axillary artery, and the medial cord behind it. The cords surround the second part of the axillary artery on three sides, the medial cord lying on the medial side, the posterior cord behind, and the lateral cord on the lateral side of the artery. In the lower part of the axilla the cords split into the nerves for the upper limb.

Close to their exit from the intervertebral foramina the fifth and sixth cervical nerves each receive a grey ramus communicans from the middle cervical ganglion, and the seventh and eighth cervical similar rami from the inferior cervical ganglion, of the sympathetic trunk. The first thoracic nerve receives a grey ramus from, and contributes a white ramus to, the first thoracic ganglion of the sympathetic trunk.

The branches of the brachial plexus.—The branches of the brachial plexus are usually subdivided into two groups, viz. those arising above the clavicle (*supraclavicular*) and those below that bone (*infraclavicular*).

CC-0. In Public Domain. Gurukul Kangri Collection, Haridwar

Digitized by Arya Samaj Foundation Chennai and eGangotri

The Supraclavicular Branches

The supraclavicular branches may be grouped as follows: (*a*) those arising from the anterior divisions of the cervical nerves, and (*b*) those from the trunks of the plexus.

From the anterior divisions of the cervical nerves.	1. To Scaleni and Longus colli	5, 6, 7, 8 C.
	2. To join phrenic nerve	5 C.
	3. Dorsal scapular nerve	5 C.
	4. Long thoracic nerve	5, 6, 7 C.
From the trunks of the plexus.	1. Nerve to Subclavius	5, 6 C.
	2. Suprascapular nerve	5, 6 C.

The branches for the Scaleni and Longus colli arise from the lower four cervical nerves close to their points of exit from the intervertebral foramina.

On the Scalenus anterior the phrenic nerve is joined by a branch from the fifth cervical nerve.

The **dorsal scapular nerve** arises from the fifth cervical nerve, pierces the Scalenus medius, passes beneath the Levator scapulæ, to which it occasionally gives a twig, and runs in company with the descending branch of the transverse cervical artery on the anterior surfaces of the Rhomboidei; it ends by supplying these muscles.

The **long thoracic nerve** (nerve of Bell) (fig. 915) supplies the Serratus anterior. It usually arises by three roots from the fifth, sixth, and seventh cervical nerves, but the root from the seventh nerve may be absent. The roots from the fifth and sixth nerves pierce the Scalenus medius, while that from the seventh passes lateralwards in front of the muscle. The nerve descends behind the brachial plexus and the first part of the axillary vessels, resting on the outer surface of the Serratus anterior. It is continued down to the lower border of that muscle, supplying, in its course, filaments to each of the digitations of the muscle.

The **nerve to the subclavius** is a small nerve which arises from the point of junction of the fifth and sixth cervical nerves; it descends to the muscle in front of the third part of the subclavian artery and the lower trunk of the plexus, and is usually connected by a filament with the phrenic nerve.

The **suprascapular nerve** (fig. 916) is a large nerve which arises from the trunk formed by the union of the fifth and sixth cervical nerves. It runs lateralwards beneath the Trapezius and the Omohyoideus, and enters the supraspinatous fossa through the suprascapular notch, below the superior transverse scapular ligament; it then passes beneath the Supraspinatus, and curves round the lateral border of the spine of the scapula to the infraspinatous fossa in company with the transverse scapular artery. In the supraspinatous fossa it gives two branches to the Supraspinatus muscle, and articular filaments to the shoulder-joint and acromioclavicular joint; and in the infraspinatous fossa it gives two branches to the Infraspinatus muscle, besides some filaments to the shoulder-joint and scapula.

The Infraclavicular Branches

The infraclavicular branches are derived from the three cords of the brachial plexus, but their fibres may be traced through the plexus to the spinal nerves from which they originate. They are as follows:

Lateral cord	Lateral anterior thoracic	5, 6, 7 C.
	Musculocutaneous	5, 6, 7 C.
	Lateral head of median	6, 7 C.
	Ulnar*	7, 8, C., 1 T.
Medial cord	Medial anterior thoracic	8 C., 1 T.
	Medial antibrachial cutaneous	8 C., 1 T.
	Medial brachial cutaneous	8 C., 1 T.
	Medial head of median	8 C., 1 T.
Posterior cord	Upper subscapular	5, 6 C.
	Lower subscapular	5, 6 C.
	Axillary	5, 6 C.
	Thoracodorsal	5, 6 C.
	Radial	6, 7, 8 C.
	* See footnote on p. 942	5, 6, 7, 8 C., 1 T.

CC-0. In Public Domain. Gurukul Kangri Collection, Haridwar

Digitized by Arya Samaj Foundation Chennai and eGangotri

The **anterior thoracic nerves** (fig. 915) supply the Pectoralis major and Pectoralis minor.

The *lateral anterior thoracic nerve*, the larger of the two, may arise by two roots from the anterior divisions of the upper and middle trunks, or by a single root from the point where these divisions unite to form the lateral cord of the plexus; it receives its fibres from the fifth, sixth, and seventh cervical nerves. It crosses the axillary artery and vein, pierces the coracoclavicular fascia, and is distributed to the deep surface of the Pectoralis major. It sends a filament to join the medial anterior thoracic nerve and form with it a loop in front of the first part of the axillary artery; through this loop the lateral anterior thoracic nerve distributes some fibres to the Pectoralis minor.

The *medial anterior thoracic nerve* receives its fibres from the eighth cervical and first thoracic nerves, and arises from the medial cord of the plexus while that cord is still on the lateral side of the axillary artery. It passes behind the first part of the axillary artery, curves forwards between the axillary artery and vein, and unites in front of the artery with a filament from the lateral anterior thoracic nerve. It then enters the deep surface of the Pectoralis minor and supplies that muscle. Two or three branches pierce the Pectoralis minor, and others may pass round its inferior border, and end in the Pectoralis major.

The **subscapular nerves**, two in number, spring from the posterior cord of the plexus, and through it from the fifth and sixth cervical nerves.

The *upper subscapular nerve*, the smaller, enters the upper part of the Subscapularis, and is frequently represented by two branches.

The *lower subscapular nerve* supplies the lower part of the Subscapularis, and ends in the Teres major; the latter muscle is sometimes supplied by a separate branch.

The **thoracodorsal nerve** (long subscapular nerve), a branch of the posterior cord of the plexus, derives its fibres from the sixth, seventh and eighth cervical nerves; it accompanies the subscapular artery, along the posterior wall of the axilla and supplies the Latissimus dorsi, in which it may be traced as far as the lower border of the muscle.

The **axillary nerve** (circumflex nerve) (fig. 916) arises from the posterior cord of the brachial plexus, its fibres being derived from the fifth and sixth cervical nerves. It lies at first behind the axillary artery and in front of the Subscapularis, and at the lower border of that muscle winds backwards in close relation to the lowest part of the articular capsule of the shoulder-joint, and, in company with the posterior humeral circumflex artery, through a quadrilateral space bounded above by the Subscapularis in front and the Teres minor behind, below by the Teres major, medially by the long head of the Triceps brachii and laterally by the surgical neck of the humerus. It ends by dividing into an anterior and a posterior branch.

The *anterior branch*, accompanied by the posterior humeral circumflex vessels, winds round the surgical neck of the humerus, beneath the Deltoideus, as far as the anterior border of the muscle, supplying it, and giving a few small cutaneous branches, which pierce the muscle and ramify in the skin covering its lower part.

The *posterior branch* supplies the Teres minor and the posterior part of the Deltoideus; upon the branch to the Teres minor an oval enlargement (pseudo-ganglion) usually exists. The posterior branch then pierces the deep fascia and is continued as the *lateral brachial cutaneous nerve*, which sweeps round the posterior border of the Deltoideus and supplies the skin over the lower two-thirds of the posterior part of this muscle, as well as that covering the long head of the Triceps brachii (figs. 911, 913).

The trunk of the axillary nerve gives an articular filament which enters the shoulder-joint below the Subscapularis.

The **musculocutaneous nerve** (fig. 915) arises from the lateral cord of the brachial plexus, opposite the lower border of the Pectoralis minor, its fibres being derived from the fifth, sixth, and seventh cervical nerves. It pierces the Coracobrachialis and passes obliquely between the Biceps brachii and the Brachialis to the lateral side of the arm; a little below the elbow it pierces the deep fascia lateral to the tendon of the Biceps brachii and is continued into the forearm as the *lateral antibrachial cutaneous nerve*. In its course through the arm it supplies the Coracobrachialis, Biceps brachii,

CC-0. In Public Domain. Gurukul Kangri Collection, Haridwar

Digitized by Arya Samaj Foundation Chennai and eGangotri

and the greater part of the Brachialis. The branch to the Coracobrachialis leaves the musculocutaneous nerve before that nerve enters the muscle; it receives its fibres from the seventh cervical nerve, and in some instances arises

FIG. 911.—The cutaneous nerves of the right upper extremity. Anterior aspect.

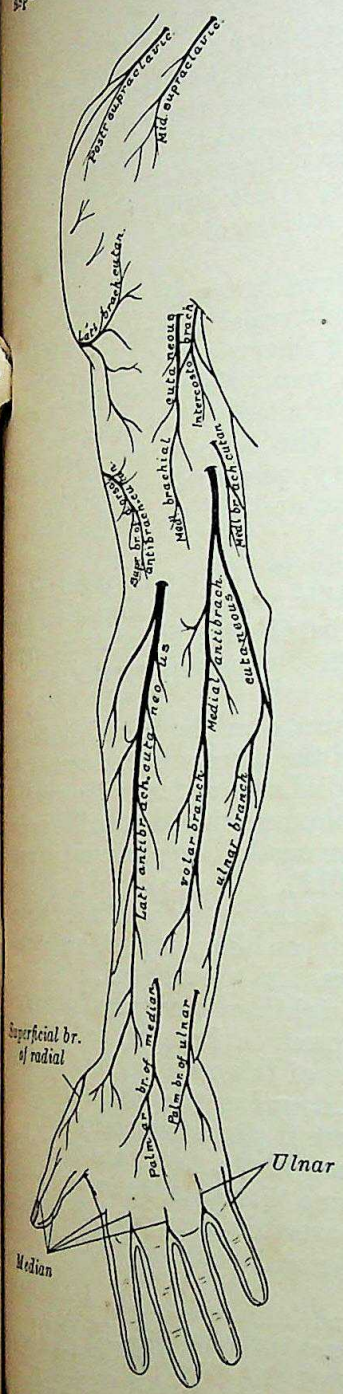

FIG. 912.—A diagram showing the segmental distribution of the cutaneous nerves of the right upper extremity. Anterior aspect.

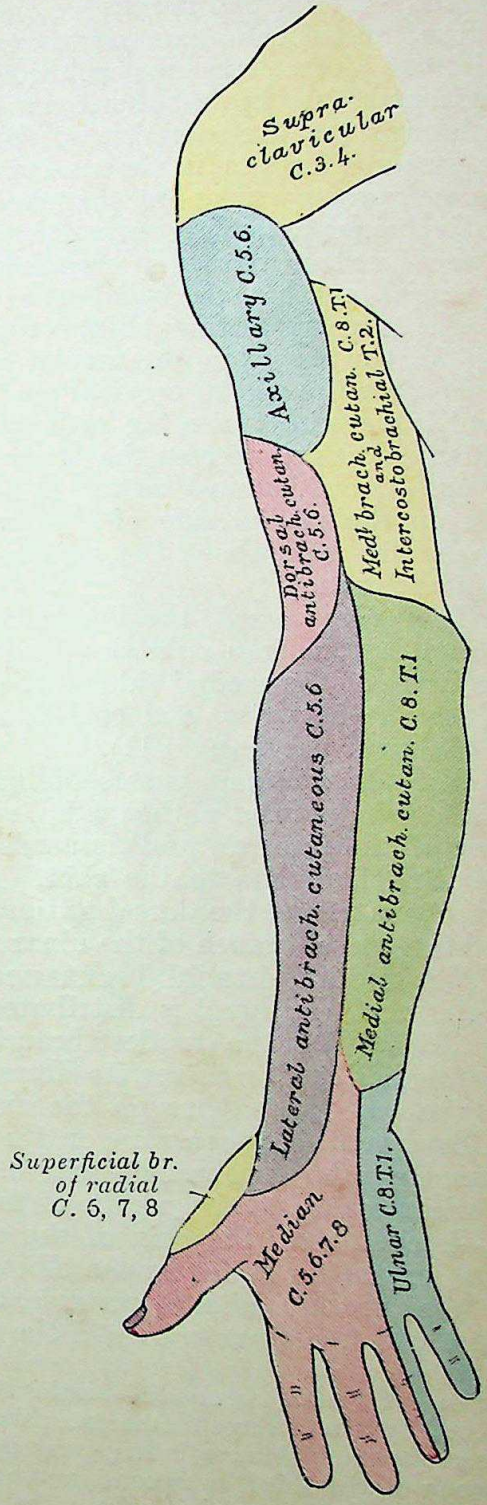

directly from the lateral cord of the brachial plexus. The branches to the Biceps brachii and Brachialis leave the musculocutaneous nerve after it has pierced the Coracobrachialis; that supplying the Brachialis gives a filament to the elbow-joint. The nerve also sends a small branch to the humerus; this branch enters the bone with the nutrient artery.

The *lateral antibrachial cutaneous nerve* (fig. 911) passes behind the cephalic vein, and descends along the radial border of the forearm to the wrist. It

CC-0. In Public Domain. Gurukul Kangri Collection, Haridwar

Digitized by Arya Samaj Foundation Chennai and eGangotri

supplies the skin over the lateral half of the volar surface of the forearm and distributes branches which turn round the radial border of the forearm to communicate with the dorsal antibrachial cutaneous nerve and the superficial branch of the radial nerve. At the wrist-joint it is placed in front of the radial artery, and some filaments, piercing the deep fascia, accompany that vessel to the dorsal surface of the carpus. The nerve then passes downwards to the ball of the thumb, where it ends in cutaneous filaments. It communicates with the superficial branch of the radial nerve, and with the palmar cutaneous branch of the median nerve.

The musculocutaneous nerve presents frequent irregularities. It may pass under the Coracobrachialis or through the Biceps brachii. It may adhere for some distance to the median nerve and then pass beneath the Biceps brachii instead of through the Coracobrachialis. Some of the fibres of the median nerve may run for some distance in the musculocutaneous nerve and then leave the latter to join their proper trunk; less frequently the reverse is the case, and the median nerve sends a branch to join the musculocutaneous nerve. Occasionally it gives a filament to the Pronator teres. It supplies the dorsal surface of the thumb when the superficial branch of the radial nerve is absent.

The **medial antibrachial cutaneous nerve** (internal cutaneous nerve) (fig. 915) arises from the medial cord of the brachial plexus. It derives its fibres from the eighth cervical and first thoracic nerves, and at its commencement is placed between the axillary artery and vein. Near the axilla it supplies a filament which pierces the fascia and is distributed to the skin covering the Biceps brachii, almost as far as the elbow. The nerve then runs down the arm on the medial side of the brachial artery, pierces the deep fascia with the basilic vein, about the middle of the arm, and divides into a volar and an ulnar branch.

The *volar branch*, the larger, passes usually in front of, but occasionally behind, the median cubital vein (median basilic vein). It then descends on the front of the medial side of the forearm, distributing filaments to the skin as far as the wrist, and communicating with the palmar cutaneous branch of the ulnar nerve (fig. 911).

The *ulnar branch* passes obliquely downwards on the medial side of the basilic vein, in front of the medial epicondyle of the humerus, winds round to the back of the forearm, and descends on its medial side as far as the wrist, distributing filaments to the skin. It communicates with the medial brachial cutaneous nerve, the dorsal antibrachial cutaneous branch of the radial nerve, and the dorsal branch of the ulnar nerve (fig. 913).

The **medial brachial cutaneous nerve** (lesser internal cutaneous nerve, or nerve of Wrisberg) is distributed to the skin on the medial side of the arm (fig. 911). It is the smallest branch of the brachial plexus, and, arising from the medial cord, receives its fibres from the eighth cervical and first thoracic nerves. It passes through the axilla and crosses in front of, or behind, the axillary vein. It then runs on the medial side of this vein, and communicates with the intercostobrachial nerve. It descends along the medial side of the brachial artery to the middle of the arm, where it pierces the deep fascia, and is distributed to the skin of the dorsal surface of the lower one-third of the arm, extending as far as the elbow, where some filaments are lost in the skin in front of the medial epicondyle, and others over the olecranon. It communicates with the ulnar branch of the medial antibrachial cutaneous nerve.

In some cases the medial brachial cutaneous and intercostobrachial nerves are connected by two or three filaments, which form a plexus in the axilla. In other cases the intercostobrachial nerve is large and may be reinforced by a part of the lateral cutaneous branch of the third intercostal nerve; it then takes the place of the medial brachial cutaneous nerve, receiving from the brachial plexus a communicating filament which represents the latter nerve; in a few cases this filament is wanting.

The **median nerve** (fig. 915) arises by two roots, one from the lateral and the other from the medial cord of the brachial plexus; these embrace the lower part of the axillary artery, uniting either in front or on the lateral side of that vessel. Its fibres are derived from the sixth, seventh, and eighth cervical and first thoracic nerves. As the median nerve descends through the arm it lies at first lateral to the brachial artery; about the level of the insertion of

CC-0. In Public Domain. Gurukul Kangri Collection, Haridwar

Digitized By Siddhanta eGangotri Gyaan Kosha Samaj Foundation Chennai and eGangotri

the Coracobrachialis it crosses in front of, occasionally behind, the artery, and lies medial to it at the bend of the elbow, where it is situated behind the bicepitus fibrosus (bicipital fascia), and is separated from the elbow-joint by the

FIG. 913.—The cutaneous nerves of the right upper extremity. Posterior aspect.

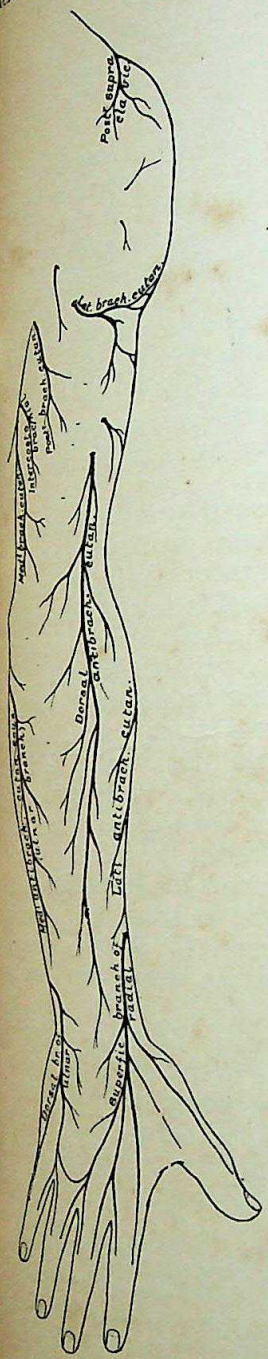

FIG. 914.—A diagram showing the segmental distribution of the cutaneous nerves of the right upper extremity. Posterior aspect.

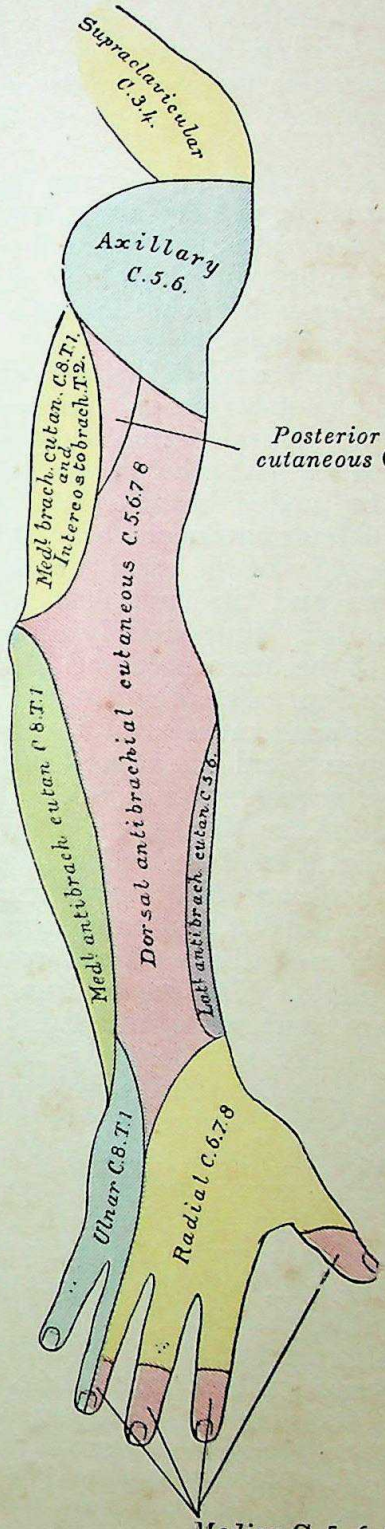

Brachialis. It enters the forearm between the two heads of the Pronator teres and then crosses the ulnar artery, but is separated from this vessel by the deep head of the Pronator teres. It descends beneath, and adheres to, the Flexor digitorum sublimis, lying on the Flexor digitorum profundus, to within 5 cm. of the transverse carpal ligament; here it becomes more superficial, and is situated between the tendons of the Flexor digitorum sublimis and Flexor

CC-0. In Public Domain. Gurukul Kangri Collection, Haridwar

Digitized by Arya Samaj Foundation Chennai and eGangotri

carpi radialis. In this situation it lies beneath, and rather to the lateral side of the tendon of the Palmaris longus, and is covered by the skin and fascia. It then passes behind the transverse carpal ligament into the palm of the hand. In its course through the forearm it is accompanied by the median artery, a branch of the volar interosseous artery.

Branches.—With the exception of the nerve to the Pronator teres, which derives its fibres from the sixth cervical nerve, and usually arises above the elbow-joint, the median nerve gives no branches in the arm. As it passes in front of the elbow, it supplies one or two twigs to the joint.

In the forearm its branches are: muscular, volar interosseous, and palmar.

The *muscular branches* are derived from the nerve near the elbow and supply all the superficial muscles on the front of the forearm, except the Flexor carpi ulnaris.

The *volar interosseous nerve* (anterior interosseous nerve) accompanies the volar interosseous artery along the front of the antibrachial interosseous membrane, in the interval between the Flexor pollicis longus and Flexor digitorum profundus, supplying the whole of the former and the lateral half of the latter muscle; it sends branches into the deep surface of the Pronator quadratus, and ends in the wrist-joint.

The *palmar branch* of the median nerve arises at the lower part of the forearm. It pierces the volar carpal ligament, and divides into a lateral and a medial branch; the lateral branch supplies the skin over the ball of the thumb, and communicates with the volar branch of the lateral antibrachial cutaneous nerve; the medial branch supplies the skin of the palm, and communicates with the palmar cutaneous branch of the ulnar nerve.

In the palm of the hand the median nerve is covered by the skin, the palmar aponeurosis and the superficial volar arch, and rests on the tendons of the flexor muscles. Immediately after emerging from under the transverse carpal ligament it becomes enlarged and flattened, and splits into a lateral and a medial portion. The *lateral* portion of the nerve supplies a short, stout branch to the following muscles of the ball of the thumb, viz. the Abductor brevis, the Opponens, and the superficial head of the Flexor brevis, and then divides into three *proper volar digital nerves*; two of these supply the sides of the thumb, while the third gives a twig to the first Lumbricalis and is distributed to the radial side of the index finger. The *medial* portion of the nerve divides into two *common volar digital nerves*. The first of these gives a twig to the second Lumbricalis and runs towards the cleft between the index and middle fingers, where it divides into two proper digital nerves for the adjoining sides of these digits. The second runs towards the cleft between the middle and ring fingers, and splits into two proper digital nerves for the adjoining sides of these digits; it receives a branch from the ulnar nerve, and sometimes sends a twig to the third Lumbricalis.

Opposite the base of the first phalanx, each proper digital nerve gives off a dorsal branch which joins the dorsal digital nerve from the superficial branch of the radial nerve, and supplies the skin on the dorsal surface of the last phalanx. At the end of the digit, each proper digital nerve divides into two branches; one supplies the pulp of the finger, the other ramifies around and beneath the nail. On the fingers the proper digital nerves are superficial to the corresponding arteries.

The **ulnar nerve** (fig. 915) arises from the medial cord of the brachial plexus, and derives its fibres from the seventh and eighth cervical and first thoracic nerves.* It lies medial to the axillary artery, and to the brachial artery as far as the middle of the arm. Here it pierces the medial intermuscular septum, and descends in front of the medial head of the Triceps brachii, to the groove between the medial epicondyle and the olecranon, accompanied by the superior ulnar collateral artery. At the elbow, it lies in the sulcus nervi ulnaris on the back of the medial epicondyle, and enters the forearm between the two

* Wilfred Harris (*Journal of Anatomy*, vol. xxxviii.) found a branch running from the seventh cervical nerve to the ulnar nerve in 86 per cent. of subjects, and believed, on clinical grounds, that the fibres of this branch were mainly motor to the Flexor carpi ulnaris.

E. A. Linell (*Journal of Anatomy*, vol. lv.) found a considerable bundle of seventh cervical nerve-fibres running from the lateral head of the median nerve to the ulnar nerve in 57 per cent. of subjects.

CC-0. In Public Domain. Gurukul Kangri Collection, Haridwar

Digitized by Arya Samaj Foundation Chennai and eGangotri

FIG. 915.—The nerves of the left upper extremity.

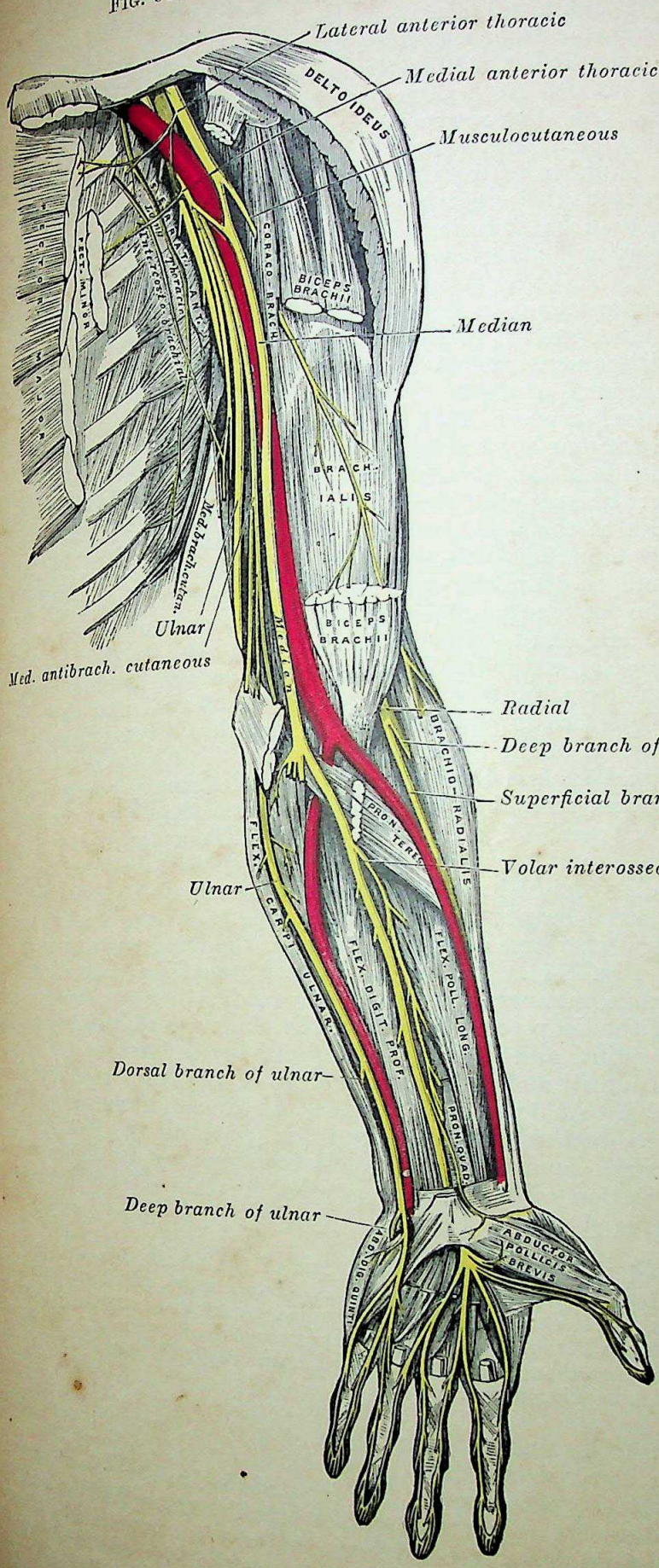

CC-0. In Public Domain. Gurukul Kangri Collection, Haridwar

Digitized by Arya Samaj Foundation Chennai and eGangotri

heads of the Flexor carpi ulnaris. It descends along the medial side of the forearm, lying upon the Flexor digitorum profundus; its upper half is covered by the Flexor carpi ulnaris; its lower half lies on the lateral side of this muscle and is covered by the skin and fascia. In the upper one-third of the forearm, the ulnar nerve is separated from the ulnar artery by a considerable interval, but in the rest of its extent it lies close to the medial side of the artery. About 5 cm. above the wrist it divides into a dorsal and a volar branch.

The branches of the ulnar nerve are: articular to the elbow-joint, muscular, palmar cutaneous, dorsal, and volar.

The *articular branches* to the elbow-joint are several small filaments which arise from the nerve as it lies between the medial epicondyle and olecranon.

The *muscular branches*, two in number, arise near the elbow; one supplies the Flexor carpi ulnaris; the other, the medial half of the Flexor digitorum profundus.

The *palmar cutaneous branch* arises about the middle of the forearm, and descends on the ulnar artery, giving some filaments to the vessel. It perforates the volar carpal ligament and ends in the skin of the palm, communicating with the palmar branch of the median nerve.

The *dorsal branch* arises about 5 cm. above the wrist; it passes backwards beneath the Flexor carpi ulnaris, perforates the deep fascia, and, running along the medial side of the back of the wrist and hand, divides into two dorsal digital branches: one supplies the medial side of the little finger; the other, the adjacent sides of the little and ring fingers. It also sends a twig to join that given by the superficial branch of the radial nerve for the adjoining sides of the middle and ring fingers, and assists in supplying them. A branch is distributed to the metacarpal region of the hand, communicating with a twig of the superficial branch of the radial nerve (fig. 913). On the little finger the dorsal digital branches extend only as far as the base of the terminal phalanx, and on the ring finger as far as the base of the second phalanx; the more distal parts of these digits are supplied by dorsal branches derived from the proper volar digital branches of the ulnar nerve.

The *volar branch* crosses the transverse carpal ligament on the lateral side of the pisiform bone, medial to and a little behind the ulnar artery. It ends by dividing into a superficial and a deep branch. The *superficial branch* supplies the Palmaris brevis and the skin on the medial side of the hand, and divides into a proper volar digital branch for the medial side of the little finger, and a common volar digital branch which sends a twig to join the median nerve and then divides into two proper digital nerves for the adjoining sides of the little and ring fingers (fig. 911). The proper digital branches are distributed to the fingers in the same manner as those of the median nerve. The *deep branch*, accompanied by the deep volar branch of the ulnar artery, passes between the Abductor digiti quinti and Flexor digiti quinti brevis; it then perforates the Opponens digiti quinti and follows the course of the deep volar arch beneath the flexor tendons. At its origin it supplies the three short muscles of the little finger. As it crosses the hand, it gives branches to all the Interossei and to the third and fourth Lumbricales; it ends by supplying the Adductor pollicis and the deep portion of the Flexor pollicis brevis. It also sends articular filaments to the wrist-joint.

It has been pointed out that the medial part of the Flexor digitorum profundus is supplied by the ulnar nerve; the third and fourth Lumbricales, which are connected with the tendons of this part of the muscle, are supplied by the same nerve. In like manner the lateral part of the Flexor digitorum profundus and the first and second Lumbricales are supplied by the median nerve. The third Lumbricalis frequently receives an additional twig from the median nerve.

The **radial nerve** (musculospiral nerve) (fig. 916), the largest branch of the brachial plexus, derives its fibres from the fifth, sixth, seventh, and eighth cervical and first thoracic nerves. It descends behind the third part of the axillary artery and the upper part of the brachial artery and in front of the tendons of the Latissimus dorsi and Teres major. Accompanied by the arteria profunda brachii it inclines backwards between the long and medial heads of the Triceps brachii, and passes obliquely across the back of the humerus in the sulcus nervi radialis, and under cover of the lateral head of the Triceps

CC-0. In Public Domain. Gurukul Kangri Collection, Haridwar

Digitized by Arya Samaj Foundation Chennai and eGangotri

brachii. On reaching the lateral side of the humerus it pierces the lateral intermuscular septum, and passes between the Brachialis and Brachioradialis to the front of the lateral epicondyle, where it divides into a superficial and a deep branch.

The branches of the radial nerve are: muscular, cutaneous, superficial, and deep.

The *muscular branches* supply the Triceps brachii, Anconæus, Brachioradialis, Extensor carpi radialis longus, and Brachialis, and are grouped as medial, posterior, and lateral.

The medial muscular branches supply the medial and long heads of the Triceps brachii; that to the medial head is a long, slender filament, which lies close to the ulnar nerve as far as the lower one-third of the arm, and is therefore frequently spoken of as the *ulnar collateral nerve*.

The posterior muscular branch, of large size, arises from the nerve as it lies in the sulcus nervi radialis. It divides into filaments which supply the medial and lateral heads of the Triceps brachii and the Anconæus. The branch for the latter muscle is a long nerve which descends in the substance of the medial head of the Triceps brachii, and gives numerous branches to it. It is accompanied by the middle collateral branch of the arteria profunda brachii, and crosses the back of the elbow-joint to end in the Anconæus.

The lateral muscular branches supply the Brachioradialis, Extensor carpi radialis longus, and the lateral part of the Brachialis.

Fig. 916.—The right suprascapular, axillary, and radial nerves.

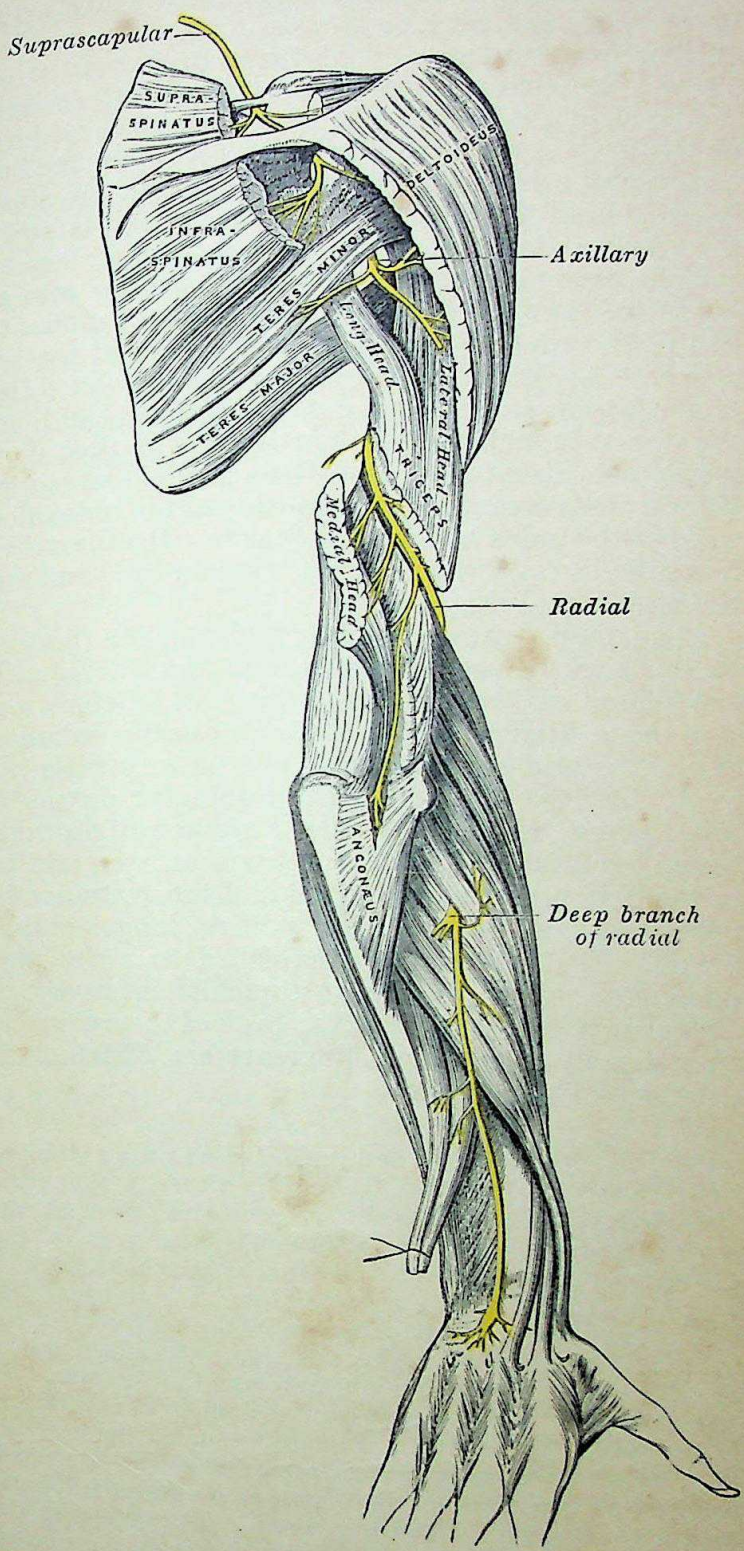

The *cutaneous branches* are two, the posterior brachial cutaneous and the dorsal antibrachial cutaneous.

The *posterior brachial cutaneous nerve* (internal cutaneous branch of the musculospiral nerve), of small size, arises in the axilla. It runs to the medial side of the arm and supplies the skin on its dorsal surface nearly as far as the olecranon. It crosses posterior to, and communicates with, the intercostobrachial nerve.

The *dorsal antibrachial cutaneous nerve* (external cutaneous branch of the

CC-0. In Public Domain. Gurukul Kangri Collection, Haridwar

Digitized by Arya Samaj Foundation Chennai and eGangotri

musculospiral nerve) consists of an upper and a lower branch, which perforate the lateral head of the Triceps brachii just below the insertion of the Deltoideus. The *upper* and smaller branch passes to the front of the elbow, lying close to the cephalic vein, and supplies the skin of the lateral part of the lower half of the arm (fig. 911). The *lower* branch descends along the lateral side of the arm and then along the back of the forearm to the wrist, supplying the skin in its course, and joining, near its termination, with dorsal branches of the lateral antibrachial cutaneous nerve (fig. 913).

The **superficial branch of the radial nerve** (radial nerve) passes along the front of the lateral side of the upper two-thirds of the forearm, and ends on the back of the hand. It lies at first upon the Supinator, lateral to the radial artery, and behind the Brachioradialis. In the middle one-third of the forearm it lies behind the latter muscle, close to the lateral side of the artery. It quits the artery about 7 cm. above the wrist, passes beneath the tendon of the Brachioradialis, and, piercing the deep fascia, divides into a lateral and a medial branch (fig. 913). The *lateral branch*, the smaller, supplies the skin of the radial side and ball of the thumb, joining with branches of the lateral antibrachial cutaneous nerve. The *medial branch* communicates, above the wrist, with dorsal branches of the lateral antibrachial cutaneous nerve, and, on the back of the hand, with the dorsal branch of the ulnar nerve. It then divides into four digital nerves, which are distributed as follows: the first supplies the medial side of the thumb; the second, the lateral side of the index finger; the third, the adjoining sides of the index and middle fingers; the fourth communicates with a filament from the dorsal branch of the ulnar nerve, and supplies the adjoining sides of the middle and ring fingers.*

The **deep branch of the radial nerve** (posterior interosseous nerve) winds to the back of the forearm round the lateral side of the radius between the two planes of fibres of the Supinator. Before reaching the back of the limb it gives a branch to the Extensor carpi radialis brevis, and another to the Supinator, and as it traverses this latter muscle it supplies additional branches to it. As it escapes from the Supinator on the back of the forearm it gives three short branches to the Extensor digitorum communis, Extensor digiti quinti proprius and Extensor carpi ulnaris, and two long branches—a medial to the Extensor pollicis longus and the Extensor indicis proprius, and a lateral which supplies the Abductor pollicis longus and ends in the Extensor pollicis brevis. The nerve, now diminished to a fine thread, descends, as the *dorsal interosseous nerve*, on the antibrachial interosseous membrane, in front of the Extensor pollicis longus, to the back of the carpus, where it presents a gangliform enlargement from which filaments are distributed to the ligaments and articulations of the carpus.

Applied Anatomy.—The brachial plexus may be injured by falls from a height on to the side of the head and shoulder, whereby the nerves of the plexus are violently stretched; the fifth cervical nerve sustains the greatest amount of injury, and the subsequent paralysis may be confined to the muscles supplied by this nerve, viz. the Deltoideus, Biceps brachii, Brachialis, and Brachioradialis, with sometimes the Supraspinatus, Infraspinatus and Supinator. The position of the limb, under such conditions, is characteristic: the arm hangs by the side and is rotated inwards; the forearm is extended and pronated. The arm cannot be raised from the side; all power of flexion of the elbow is lost, as is also supination of the forearm. This is known as Erb's paralysis, and a very similar condition is occasionally met with in new-born children, either from injury to the fifth nerve from the pressure of forceps used in effecting delivery, or from traction of the head in breech presentations. A second variety of partial palsy of the brachial plexus is known as Klumpke's paralysis. In this it is the eighth cervical and first thoracic nerves that are injured, either before or after they have joined to form the lower trunk. Atrophy follows in the intrinsic muscles of the hand, and in the flexors of the fingers and wrist; the thenar and hypothenar eminences waste and flatten; the fingers cannot be spread out or approximated, on account of the paralysis of the Interossei, and become clawed.

The brachial plexus may also be injured by direct violence or a gunshot wound, by violent traction on the arm, or by efforts at reducing a dislocation of the shoulder-joint;

* According to Hutchison, the digital nerve to the thumb reaches only as far as the root of the nail; the one to the forefinger as far as the middle of the second phalanx; and those to the middle and ring fingers reach further than the first phalangeal joints.—*London Hospital Gazette*, vol. iii. p. 319.

CC-0. In Public Domain. Gurukul Kangri Collection, Haridwar

Digitized by Arya Samaj Foundation Chennai and eGangotri

and the amount of paralysis will depend upon the amount of injury to the constituent nerves. When the entire plexus is involved, the whole of the upper extremity will be paralysed and anæsthetic. In some cases the injury appears to be rather a tearing away of the roots of the nerves from the medulla spinalis than a rupture of the nerves themselves. The brachial plexus in the axilla is often damaged from the pressure of a crutch, producing the condition known as 'crutch paralysis.' In these cases the radial (musculospiral) is the nerve most frequently implicated; the ulnar nerve suffers next in frequency. The median and radial nerves often suffer from 'sleep palsies,' paralysis from pressure coming on while the patient is profoundly asleep under the influence of alcohol or some narcotic.

Paralysis of the *long thoracic nerve* throws the Serratus anterior out of action, and may occur in porters in whom the nerve is exposed to injury as it crosses the posterior triangle of the neck. The inferior angle of the scapula is drawn towards the middle line, by the unopposed action of the Rhomboidei and Levator scapulæ, and tends to project backwards when the arm is held horizontally forwards. The arm cannot be raised above the horizontal unless the inferior angle of the scapula is pushed lateralwards for the patient.

The *axillary (circumflex) nerve*, on account of its course round the surgical neck of the humerus, is liable to be torn in fractures of this part of the bone, and in dislocations of the shoulder-joint; paralysis of the Deltoideus, and anæsthesia of the skin over the lower part of that muscle, result. According to Erb, inflammation of the shoulder-joint is liable to be followed by a neuritis of this nerve from extension of the inflammation to it. Paralysis of the Deltoideus renders abduction of the arm to the horizontal level impossible. The associated paralysis of the Teres minor is not easily demonstrated.

Hilton gave the axillary nerve as an illustration of a law which he laid down, that the same trunks of nerves whose branches supply the groups of muscles moving a joint, furnish also a distribution of nerves to the skin over the insertions of the same muscles, and the interior of the joint receives its nerves from the same source.'. In this way he explains the fact that an inflamed joint becomes rigid.

The *median nerve* is liable to injury in wounds of the forearm. In such cases there is loss of flexion of the second phalanges of all the fingers, and of the terminal phalanges of the index and middle fingers. Flexion of the terminal phalanges of the ring and little fingers is effected by that portion of the Flexor digitorum profundus which is supplied by the ulnar nerve. There is power to flex the proximal phalanges through the Interossei. The thumb cannot be flexed or opposed, and is maintained in a position of extension and abduction. There is loss in the power of pronating the forearm; the Brachioradialis has the power of bringing the forearm into a position of mid-pronation, but beyond this no further pronation can be effected. The wrist can be flexed, if the hand is first adducted by the action of the Flexor carpi ulnaris. There is loss or impairment of sensation on the volar surfaces of the thumb, index, middle, and radial half of the ring fingers, and on the dorsal surfaces of the same fingers over the last two phalanges; except in the thumb, where the loss of sensation would be limited to the back of the distal phalanx. In old cases the unopposed action of the Interossei produces backward dislocation of the interphalangeal joints. The thumb is extended and adducted to the index finger, cannot be flexed or abducted, and cannot be opposed to any one of the fingers; in consequence an 'ape-like' hand is produced. More commonly, however, the nerve is injured just above the annular ligament, when the power of flexion of the fingers and pronation of the forearm remains intact unless the flexor tendons are also divided. This injury seriously interferes with the use of the hand, as, besides the wasting of the muscles of the thenar eminence, great trouble is experienced from the trophic changes which result about the skin and nails of the fingers, which are anæsthetic. In order to expose the median nerve, for the purpose of uniting the divided ends, supposing the injury to be just above the wrist, an incision should be made along the radial side of the tendon of the Palmaris longus, which serves as a guide to the nerve.

The *ulnar nerve* is also liable to be injured in wounds of the forearm, such injury leading to impaired power of ulnar flexion, and upon an attempt being made to flex the wrist, the hand is drawn to the radial side from paralysis of the Flexor carpi ulnaris; there is inability to spread out the fingers from paralysis of the Interossei, and for the same reason the fingers, especially the ring and little fingers, cannot be flexed at the metacarpo-phalangeal joints or extended at the interphalangeal joints, and the hand assumes a claw shape from the action of the opposing muscles; there is loss of power of flexion in the little and ring fingers; and there is inability to adduct the thumb. The muscles of the hypothenar eminence become wasted. Sensation is lost, or impaired, in the skin supplied by the nerve. In order to expose the nerve in the lower part of the forearm, an incision should be made along the radial border of the tendon of the Flexor carpi ulnaris, and the nerve will be found lying on the medial side of the ulnar artery. This nerve may be also affected in cases of dislocation of the shoulder or fracture of the surgical neck of the humerus. Wasting of the muscles which it supplies is not uncommonly seen where a 'cervical rib' is present, the lower end of the plexus passing between this and the first thoracic rib.

The *radial (musculospiral) nerve* is also frequently injured. In consequence of its close relationship to the humerus, it is often torn or injured in fractures of this bone, or subsequently involved in the callus that may be thrown out around a fracture, and thus

CC-0. In Public Domain. Gurukul Kangri Collection, Haridwar

Digitized by Arya Samaj Foundation Chennai and eGangotri

pressed upon and its functions interfered with. It is also liable to be contused against the bone by kicks or blows, or to be divided in wounds of the arm. When paralysed, the hand is flexed at the wrist and lies flaccid. This is known as *wrist-drop*. The fingers are also flexed, and on an attempt being made to extend them, the last two phalanges only will be extended, through the action of the Lumbricales and Interossei; the first phalanges remaining flexed. There is no power of extending the wrist. Supination is completely lost when the forearm is extended on the arm, but is possible to a certain extent if the forearm be flexed so as to allow of the action of the Biceps brachii. The power of extension of the forearm is lost on account of paralysis of the Triceps brachii. The injury to the nerve has taken place near its origin. In cases due to pressure, sensation is hardly affected; severe injury to the nerve occasions anæsthesia over the area supplied by the superficial branch of the radial nerve, and, if the lesion be high up, on the lateral side of the upper arm and the back of the forearm (posterior brachial and dorsal antibrachial cutaneous branches) as well. The muscles supplied by the deep branch of the radial nerve are also particularly liable to be affected in chronic lead-poisoning; here the affection is probably in the cells of the anterior column of the medulla spinalis.*

The radial nerve is best exposed by making an incision along the medial border of the Brachioradialis, just above the level of the elbow-joint. The skin and superficial fascia are to be divided and the deep fascia exposed. The white line in the fascia indicating the border of the muscle is to be defined, and the deep fascia divided in this line. On raising the Brachioradialis, the nerve will be found lying between it and the Brachialis. Incisions down to the neck of the radius posteriorly or on the lateral side should never be made, as the deep branch of the radial nerve would be severed.

The distribution of the cutaneous nerves on the hand and fingers is subject to considerable variation, and a knowledge of these is of some clinical importance. Stopford,† from an investigation of 1000 cases of gunshot wounds of the upper extremity, has described and tabulated most of the variations. Speaking generally the arrangement on the volar surface is fairly constant and conforms to that described in this text. On the dorsum of the hand and fingers there is greater variability, chiefly on the radial side where the superficial radial, the dorsal antibrachial cutaneous, and the lateral antibrachial cutaneous nerves all contribute in varying amounts to the supply.

THE ANTERIOR DIVISIONS OF THE THORACIC NERVES

The **anterior divisions of the thoracic nerves** (fig. 917) are twelve in number on either side. Eleven of them are situated between the ribs, and are therefore termed *intercostal*; the twelfth lies below the last rib. Each nerve is connected with the adjoining ganglion of the sympathetic trunk by a grey and a white ramus communicans. The intercostal nerves are distributed chiefly to the parietes of the thorax and abdomen, and differ from the anterior divisions of the other spinal nerves, in that each pursues an independent course, i.e. there is no plexus formation. The first two nerves supply fibres to the upper limb in addition to their thoracic branches; the next four are limited in their distribution to the parietes of the thorax; the lower five supply the parietes of the thorax and abdomen; the lower seven supply both motor and sensory fibres to the Diaphragm; the twelfth is distributed to the abdominal wall and the skin of the buttock.

The first thoracic nerve.—The anterior division of the first thoracic nerve divides into a large and a small branch. The large branch ascends in front of the neck of the first rib on the lateral side of the arteria intercostalis suprema, and enters the brachial plexus (p. 935). The small branch is the *first intercostal nerve*; it runs along the first intercostal space, and ends on the front of the chest as the first anterior cutaneous branch of the thorax. Occasionally this anterior cutaneous branch is wanting. The first intercostal nerve as a rule gives off no lateral cutaneous branch; but sometimes it sends a small branch to communicate with the intercostobrachial. The first thoracic nerve frequently receives a connecting twig from the second nerve; this twig ascends over the neck of the second rib.

The upper thoracic nerves.—The anterior divisions of the second, third, fourth, fifth, and sixth thoracic nerves pass forwards (fig. 918) in the intercostal spaces below the intercostal vessels. At the back of the chest they lie between the pleura and the posterior intercostal membranes, but soon pierce the latter

* Consult an article on 'Voluntary movements in cases of nerve lesions,' by F. Wood Jones, *Journal of Anatomy*, vol. liv. part i.

CC-0. In Public Domain. Gurukul Kangri Collection, Haridwar

† J. S. B. Stopford, *Journal of Anatomy*, vol. liii. Oct. 1918.

Digitized by Arya Samaj Foundation Chennai and eGangotri

and run between the two planes of Intercostal muscles as far as the middle of the rib. They then enter the substance of the Intercostales interni, and, running amidst their fibres as far as the costal cartilages, they gain the inner surfaces of the muscles and lie between them and the pleura. Near the sternum, they cross in front of the internal mammary artery and Transversus thoracis muscle, pierce the Intercostales interni, the anterior intercostal membranes, and the Pectoralis major, and are now named the *anterior cutaneous nerves of the thorax*; they supply the skin of the mamma and of the front of the thorax; the branch from the second nerve unites with the anterior supraclavicular nerves of the cervical plexus.

Fig. 917.—A diagram showing the distribution of the cutaneous nerves on the front of the trunk.

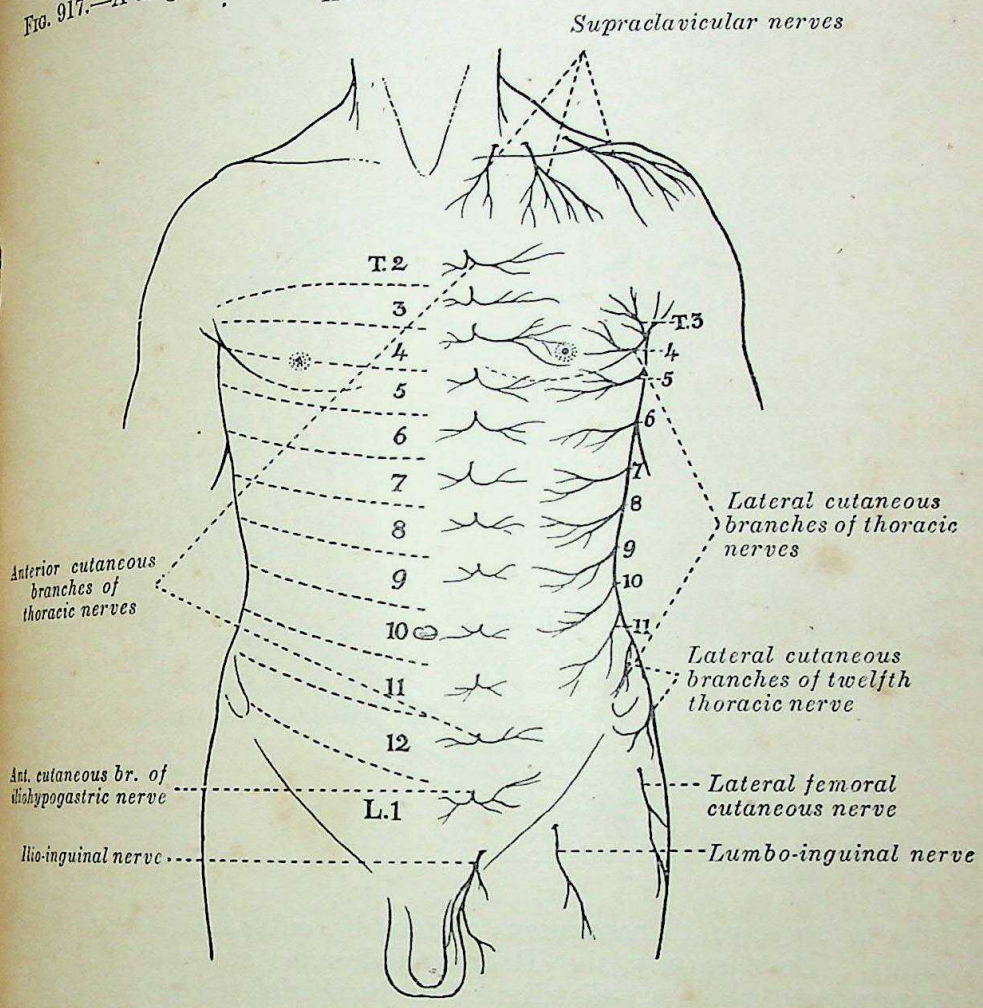

Branches.—Numerous slender muscular filaments supply the Intercostales, the Subcostales, the Levatores costarum, the Serratus posterior superior, and the Transversus thoracis. At the front of the thorax some of these branches cross the costal cartilages from one intercostal space to another.

Each of these intercostal nerves, except the first, sends off a *lateral cutaneous branch*, about midway between the vertebral column and the sternum. These branches pierce the Intercostales externi, pass between the digitations of the Serratus anterior, and, with the exception of the lateral cutaneous branch of the second intercostal nerve, divide into anterior and posterior branches. The *anterior branches* run forwards over the border of the Pectoralis major and supply twigs to the skin and the mamma; those of the fifth and sixth nerves supply twigs to the upper digitations of the Obliquus externus abdominis. The *posterior branches* run backwards, and supply the skin over the scapula and Latissimus dorsi.

The lateral cutaneous branch of the second intercostal nerve is named the *intercostobrachial nerve* (fig. 915). It crosses the axilla to the medial side of the arm, and joins with a filament from the medial brachial cutaneous nerve.

CC-0. In Public Domain. Gurukul Kangri Collection, Haridwar

Digitized by Arya Samaj Foundation Chennai and eGangotri

It then pierces the fascia brachii, and supplies the skin of the upper half of the medial and posterior parts of the arm, communicating with the posterior brachial cutaneous branch of the radial nerve. The size of the intercostobrachial nerve is in inverse proportion to that of the medial brachial cutaneous nerve. A second intercostobrachial nerve is frequently given off from the anterior part of the lateral cutaneous branch of the third intercostal nerve; it supplies filaments to the axilla and medial side of the arm.

The **lower thoracic nerves.**—The anterior divisions of the seventh, eighth, ninth, tenth, and eleventh thoracic nerves are continued anteriorly from the intercostal spaces into the abdominal wall. They have the same arrangement as the upper ones as far as the anterior ends of the intercostal spaces, where they pass between the origins of the Diaphragm and the Transversus abdominis into the abdominal wall, and running forwards between the

Fig. 918.—A diagram of the course and branches of a typical intercostal nerve.

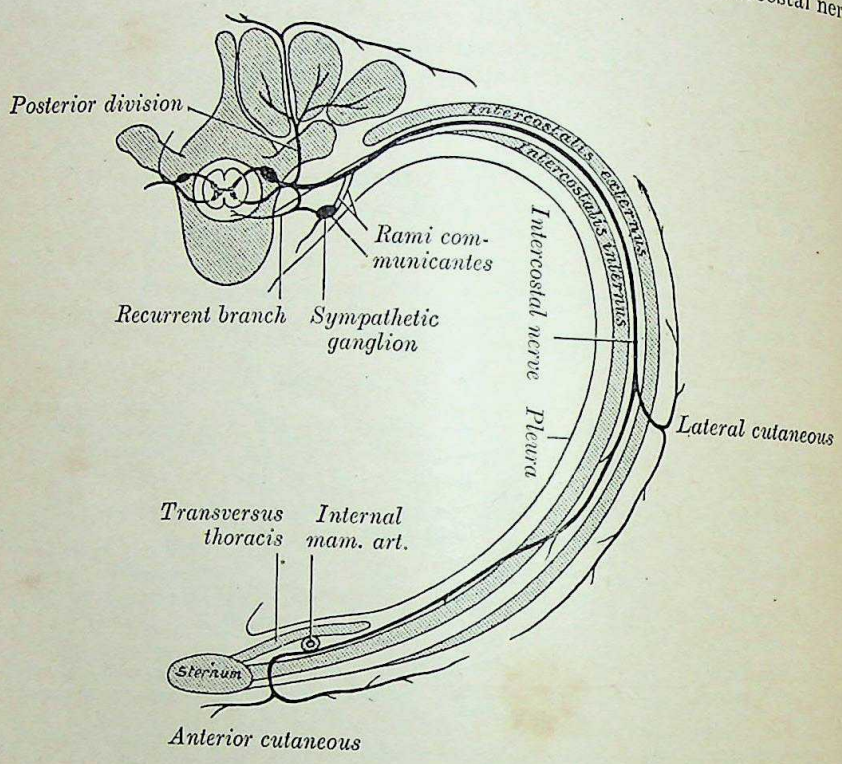

Obliquus internus and Transversus abdominis, enter the sheath of the Rectus abdominis. They supply the Rectus abdominis and end as the *anterior cutaneous nerves*, which are distributed to the skin of the front of the abdomen. The lower intercostal nerves supply the Intercostales and the abdominal muscles, and the last three send branches to the Serratus posterior inferior. About the middle of their course they give off *lateral cutaneous branches*; these pierce the Intercostales externi and the Obliquus externus abdominis, in the same line as the lateral cutaneous branches of the upper thoracic nerves, and divide into anterior and posterior branches, which are distributed to the skin of the abdomen and back respectively; the anterior branches also supply twigs to the digitations of the Obliquus externus abdominis, and extend downwards and forwards nearly as far as the margin of the Rectus abdominis; the posterior branches pass backwards to supply the skin over the Latissimus dorsi.

The anterior division of the **twelfth thoracic nerve** is larger than the others, and often gives a communicating branch to the first lumbar nerve. It accompanies the subcostal artery along the lower border of the twelfth rib, and passes under the lateral lumbocostal arch. It then runs behind the kidney, and in front of the upper part of the Quadratus lumborum, perforates the posterior aponeurosis of the Transversus, and passes forwards between that muscle and the Obliquus internus, to be distributed in the same manner as the lower intercostal nerves. It communicates with the iliohypogastric nerve of

CC-0. In Public Domain. Gurukul Kangri Collection, Haridwar

Digitized by Arya Samaj Foundation Chennai and eGangotri

the lumbar plexus, and gives a branch to the Pyramidalis. The *lateral cutaneous branch* of the twelfth thoracic nerve pierces the Obliquus internus and Obliquus externus, gives a twig to the lowest slip of the latter muscle, ascends over the iliac crest about 5 cm. behind the anterior superior iliac spine (fig. 925), and is distributed to the skin of the front part of the buttock, some of its filaments reaching as low as the greater trochanter of the femur.

Applied Anatomy.—The lower seven thoracic nerves and the iliohypogastric branch of the first lumbar nerve supply the skin of the abdominal wall. They run downwards and forwards fairly equidistant from each other. The sixth and seventh supply the skin over the 'pit of the stomach'; the eighth corresponds to about the position of the middle tendinous inscription of the Rectus abdominis; the tenth to the umbilicus; the iliohypogastric supplies the skin over the os pubis and subcutaneous inguinal ring. In many diseases affecting the nerve-trunks at or near their origins, the pain is referred to their peripheral terminations. Thus, in Pott's disease of the vertebræ, children often suffer from pain in the abdomen. When the irritation is confined to a single pair of nerves, the sensation complained of is often a feeling of constriction, as if a cord were tied round the abdomen, and in these cases the situation of the sense of constriction may serve to localise the disease in the vertebral column. Where the bone disease is more extensive and two or more nerves are involved, a more general, diffused pain in the abdomen is felt.

Again, it must be borne in mind that the nerves which supply the skin of the abdomen supply also the planes of muscle which constitute the greater part of the abdominal wall. Hence, any irritation applied to the peripheral ends of the cutaneous branches in the skin of the abdomen is immediately followed by reflex contraction of the abdominal muscles. The supply of both muscles and skin from the same source is of importance in protecting the abdominal viscera from injury. A blow on the abdomen, even of a severe character, will do no injury to the viscera if the muscles are in a condition of firm contraction; whereas in cases where the muscles have been taken unawares, and the blow has been struck while they were in a state of rest, an injury insufficient to produce any lesion of the abdominal wall has been attended with rupture of some of the abdominal contents. The importance, therefore, of immediate reflex contraction upon the receipt of an injury cannot be overestimated, and the intimate association of the cutaneous and muscular fibres in the same nerve produces a much more rapid response on the part of the muscles to any peripheral stimulation of the cutaneous filaments than would be the case if the two sets of fibres were derived from independent sources.

The nerves supplying the abdominal muscles and skin, derived from the lower intercostal nerves, are intimately connected with the sympathetic supplying the abdominal viscera through the lower thoracic ganglia from which the splanchnic nerves are derived. In consequence of this, in laceration of the abdominal viscera and in acute peritonitis, the muscles of the belly wall become firmly contracted, and thus as far as possible preserve the abdominal contents in a condition of rest.

THE ANTERIOR DIVISIONS OF THE LUMBAR NERVES

The **anterior divisions of the lumbar nerves** increase in size from the first to the last. They are joined, near their origins, by *grey rami communicantes* from the lumbar ganglia of the sympathetic trunk. These rami consist of long, slender branches which accompany the lumbar arteries round the sides of the vertebral bodies, beneath the Psoas major. Their arrangement is somewhat irregular: one ganglion may give rami to two lumbar nerves, or one lumbar nerve may receive rami from two ganglia. The first and second, and sometimes the third and fourth, lumbar nerves are each connected with the lumbar part of the sympathetic trunk by a *white ramus communicans*.

The anterior divisions of the lumbar nerves pass obliquely outwards behind the Psoas major, or between its fasciculi. The first three nerves and the greater part of the fourth, form the *lumbar plexus*. The smaller part of the fourth nerve joins with the fifth to form the *lumbosacral trunk*, which assists in the formation of the sacral plexus. The fourth nerve is named the *nervus furcalis*, from the fact that it is subdivided between the two plexuses.*

* In most cases the fourth lumbar is the *nervus furcalis*; but this arrangement is frequently departed from. The third is occasionally the lowest nerve which enters the lumbar plexus, giving at the same time some fibres to the sacral plexus, and thus forming the nervus furcalis; or both the third and fourth may be furcal nerves. When this occurs, the plexus is termed high or *prefixed*. More frequently the fifth nerve is divided between the lumbar and sacral plexuses, and constitutes the nervus furcalis; and when this takes place, the plexus is distinguished as a *low* or *postfixed* plexus. These variations necessarily produce corresponding modifications in the sacral plexus.

CC-0. In Public Domain. Gurukul Kangri Collection, Haridwar

Digitized by Arya Samaj Foundation Chennai and eGangotri

The Lumbar Plexus

The **lumbar plexus** (fig. 919) is situated in the posterior part of the Psoas major, in front of the transverse processes of the lumbar vertebræ; it is formed by the anterior divisions of the first three, and the greater part of the anterior division of the fourth, lumbar nerves; the first lumbar nerve receives a branch from the last thoracic nerve.

The mode in which it is arranged varies in different subjects, but the usual condition is the following. The first lumbar nerve, supplemented by a twig from the last thoracic, splits into an upper and a lower branch; the upper larger branch divides into the iliohypogastric and ilio-inguinal nerves; the lower, smaller branch unites with a branch of the second lumbar to form the genitofemoral nerve. The remainder of the second nerve, the third nerve, and the part of the fourth nerve which joins the plexus, divide into ventral and dorsal branches. The ventral branch of the second unites with the ventral branches of the third and fourth nerves to form the obturator nerve. The dorsal branches of the second and third nerves each divide into a smaller and larger part, the smaller parts uniting to form the lateral femoral cutaneous nerve, and the larger parts joining with the dorsal branch of the fourth nerve to form the femoral nerve. The accessory obturator, when it exists, arises from the ventral branches of the third and fourth nerves.

The branches of the lumbar plexus may therefore be arranged as follows:

Muscular.	
Iliohypogastric	1 L.
Ilio-inguinal	1 L.
Genitofemoral	1, 2 L.
	Dorsal divisions.
Lateral femoral cutaneous	2, 3 L.
Femoral	2, 3, 4 L.
	Ventral divisions.
Obturator	2, 3, 4 L.
Accessory obturator	3, 4 L.

Muscular branches are distributed to the Quadratus lumborum from the twelfth thoracic and first three or four lumbar nerves; to the Psoas minor from the first, and to the Psoas major and Iliacus from the second, third and fourth, lumbar nerves.

The **iliohypogastric nerve** arises from the first lumbar nerve. It emerges from the upper part of the lateral border of the Psoas major, and crosses obliquely behind the kidney, and in front of the Quadratus lumborum to the iliac crest. It then perforates the posterior part of the Transversus abdominis, and divides between that muscle and the Obliquus internus abdominis into a lateral and an anterior cutaneous branch.

The *lateral cutaneous branch* pierces the Obliquus internus and Obliquus externus immediately above the iliac crest at a point a little behind the iliac branch of the twelfth thoracic nerve; it is distributed to the skin of the anterior part of the side of the buttock.

The *anterior cutaneous branch* (fig. 917) runs between the Obliquus internus and Transversus, supplying twigs to both muscles. It then pierces the Obliquus internus at a point about 2 cm. on the medial side of the anterior superior iliac spine, perforates the aponeurosis of the Obliquus externus about 3 cm. above the subcutaneous inguinal ring, and is distributed to the skin of the abdomen above the os pubis.

The iliohypogastric nerve communicates with the last thoracic and ilio-inguinal nerves.

The **ilio-inguinal nerve**, smaller than the iliohypogastric nerve, arises with it from the first lumbar nerve. It emerges from the lateral border of the Psoas major just below the iliohypogastric nerve, and, passing obliquely across the Quadratus lumborum and Iliacus, perforates the Transversus abdominis near the anterior part of the iliac crest, and communicates with the iliohypogastric nerve. It then pierces the Obliquus internus, distributing filaments to it, and, accompanying the spermatic cord through the subcutaneous inguinal

CC-0. In Public Domain. Gurukul Kangri Collection, Haridwar

Digitized by Arya Samaj Foundation Chennai and eGangotri

and, is distributed to the skin of the upper and medial part of the thigh, to the skin over the root of the penis and upper part of the scrotum in the male, and to the skin covering the mons pubis (mons Veneris) and labium majus in the female.

The size of the ilio-inguinal nerve is in inverse proportion to that of the iliohypogastric. Occasionally it is very small, and ends by joining the iliohypogastric nerve; in such cases, a branch from the iliohypogastric takes the place of the ilio-inguinal, or the latter nerve may be altogether absent.

The **genitofemoral nerve** (genitocrural nerve) arises from the first and second lumbar nerves. It passes obliquely forwards and downwards through

FIG. 919.—A plan of the lumbar plexus.

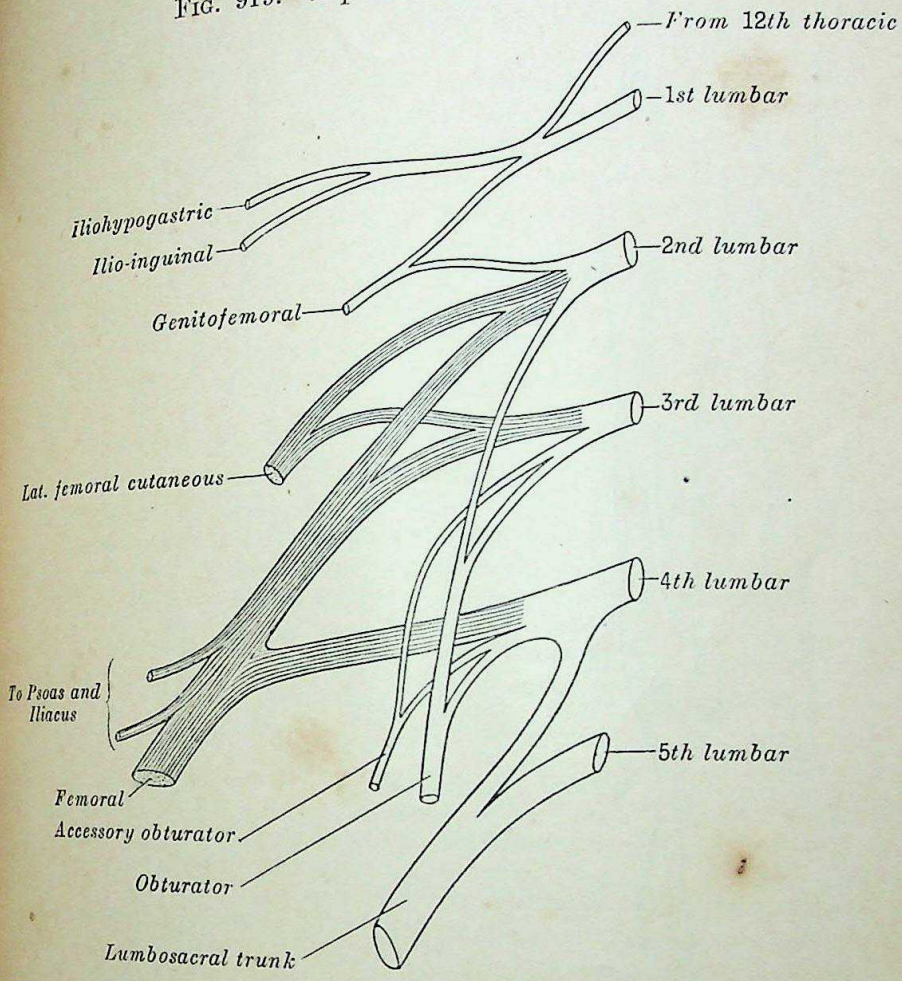

the substance of the Psoas major, and emerges near its medial border, opposite the fibrocartilage between the third and fourth lumbar vertebræ; it then descends on the surface of the Psoas major, under cover of the peritoneum, and divides into the external spermatic and lumbo-inguinal nerves. The genito-femoral nerve frequently divides close to its origin, and the external spermatic and lumbo-inguinal nerves then emerge separately through the Psoas major.

The *external spermatic nerve* (genital branch of genitocrural) passes laterally on the Psoas major, and pierces the fascia transversalis, or passes through the abdominal inguinal ring; it then descends behind the spermatic cord, supplies the Cremaster, and gives a few filaments to the skin of the scrotum. In the female, it accompanies the round ligament of the uterus and ends in the skin of the mons pubis and labium majus.

The *lumbo-inguinal nerve* (crural branch of genitocrural) descends on the external iliac artery, sending a few filaments round it, and, passing beneath the inguinal ligament, enters the femoral sheath, lying superficial and lateral to the femoral artery. It pierces the anterior layer of the femoral sheath and the fascia lata, and supplies a limited area of the skin on the anterior

CC-0. In Public Domain. Gurukul Kangri Collection, Haridwar

Digitized by Arya Samaj Foundation Chennai and eGangotri

surface of the upper part of the thigh (fig. 920). On the front of the thigh it communicates with the intermediate cutaneous branch of the femoral nerve.

FIG. 920.—The cutaneous nerves of the right lower extremity. Anterior aspect.

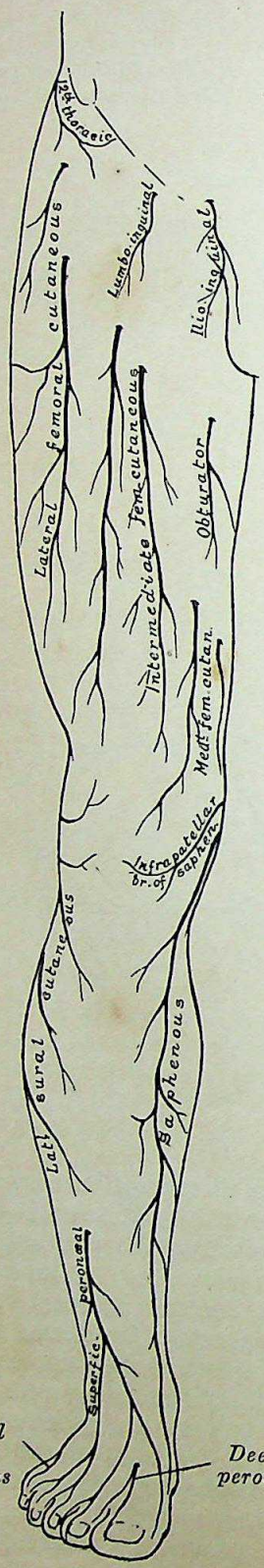

FIG. 921.—A diagram showing the segmental distribution of the cutaneous nerves of the right lower extremity. Anterior aspect.

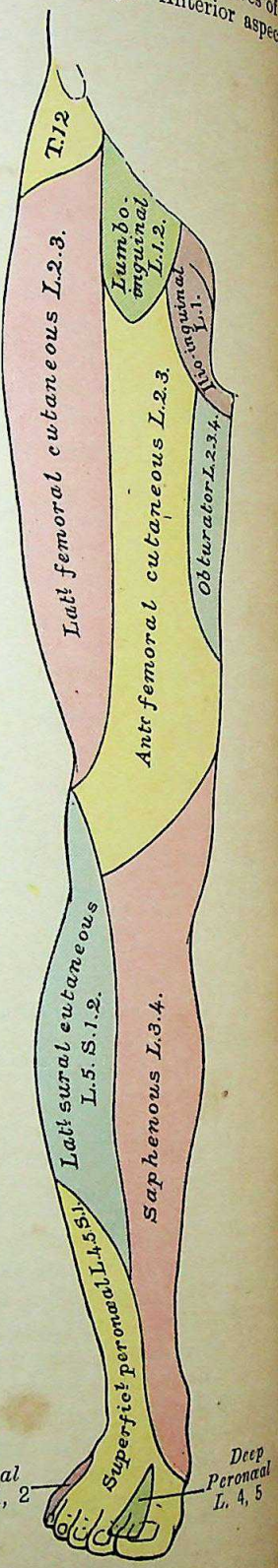

As the nerve runs beneath the inguinal ligament it gives a few twigs to the femoral artery.

CC-0. In Public Domain. Gurukul Kangri Collection, Haridwar

Digitized by Arya Samaj Foundation Chennai and eGangotri

The **lateral femoral cutaneous nerve** (external cutaneous nerve) arises from the dorsal branches of the anterior divisions of the second and third lumbar nerves. It emerges from the lateral border of the Psoas major, and crosses the Iliacus obliquely, towards the anterior superior iliac spine. It then passes under the inguinal ligament and over or through the Sartorius into the thigh, where it divides into an anterior and a posterior branch (fig. 920).

The *anterior branch* becomes superficial about 10 cm. below the anterior superior iliac spine, and is distributed to the skin of the anterior and lateral parts of the thigh, as far as the knee. Its terminal filaments frequently communicate with the anterior cutaneous branches of the femoral nerve, and with the infrapatellar branch of the saphenous nerve, forming with them the patellar plexus.

The *posterior branch* pierces the fascia lata at a higher level than the anterior branch, and subdivides into filaments which pass backwards to supply the skin on the lateral surface of the limb, from the level of the greater trochanter to about the middle of the thigh.

The **obturator nerve** arises from the ventral branches of the anterior divisions of the second, third, and fourth lumbar nerves; the branch from the third is the largest, while that from the second is often very small. It descends through the fibres of the Psoas major, and emerges from its medial border at the brim of the pelvis; it then passes behind the common iliac vessels, and on the lateral side of the hypogastric vessels, and runs along the lateral wall of the lesser pelvis, above and in front of the obturator vessels, to the upper part of the obturator foramen, through which it enters the thigh. At the foramen it divides into an anterior and a posterior branch, which are separated at first by a few fibres of the Obturator externus, and lower down by the Adductor brevis.

The *anterior branch* (fig. 922) leaves the pelvis in front of the Obturator externus and descends in front of the Adductor brevis, and behind the Pectineus and Adductor longus; at the lower border of the latter muscle it communicates with the medial cutaneous and saphenous branches of the femoral nerve, forming a kind of plexus. It then descends upon the femoral artery, to which it is finally distributed. Near the obturator foramen this branch gives an articular twig to the hip-joint. Behind the Pectineus, it distributes branches to the Adductor longus and Gracilis, and usually to the Adductor brevis, and in rare cases to the Pectineus; it receives a filament from the accessory obturator nerve when that nerve is present.

Occasionally the communicating branch to the medial cutaneous and saphenous branches of the femoral nerve is continued down, as a cutaneous branch, to the thigh and leg. When this is so, it emerges from beneath the lower border of the Adductor longus, descends along the posterior margin of the Sartorius to the medial side of the knee, where it pierces the deep fascia, communicates with the saphenous nerve, and is distributed to the skin half-way down the medial side of the leg.

The *posterior branch* pierces the anterior part of the Obturator externus, and supplies this muscle; it then passes behind the Adductor brevis on the front of the Adductor magnus, and divides into branches which are distributed to the Adductor magnus and to the Adductor brevis when the latter does not receive a branch from the anterior division of the nerve. It frequently gives a slender *articular branch* to the knee-joint; this branch perforates the lower part of the Adductor magnus or passes through the opening which transmits the femoral artery, and enters the popliteal fossa; it here descends upon the popliteal artery, to the back of the knee-joint, where it pierces the oblique popliteal ligament, and is distributed to the articular capsule. It gives filaments to the popliteal artery.

The **accessory obturator nerve** (fig. 919) is present in about 29 per cent. of subjects. It is of small size, and arises from the ventral branches of the anterior divisions of the third and fourth lumbar nerves. It descends along the medial border of the Psoas major, crosses the superior ramus of the os pubis behind the Pectineus, and divides into branches. One branch enters the deep surface of the Pectineus; another goes to the hip-joint; while a third communicates with the anterior branch of the obturator nerve. Occasionally the accessory obturator nerve is very small and supplies only the Pectineus.

CC-0. In Public Domain. Gurukul Kangri Collection, Haridwar

Digitized by Arya Samaj Foundation Chennai and eGangotri

The **femoral nerve** (anterior crural nerve) (fig. 922), the largest branch of the lumbar plexus, arises from the dorsal branches of the anterior divisions of the second, third, and fourth lumbar nerves. It descends through the fibres of the Psoas major, emerging from the muscle at the lower part of its lateral border, and passes down between it and the Iliacus, behind the iliac fascia; it then runs beneath the inguinal ligament, into the thigh, and splits into an anterior and a posterior division. Under the inguinal ligament, it is separated from the femoral artery by a portion of the Psoas major.

FIG. 922.—The nerves of the right lower extremity. Anterior aspect.

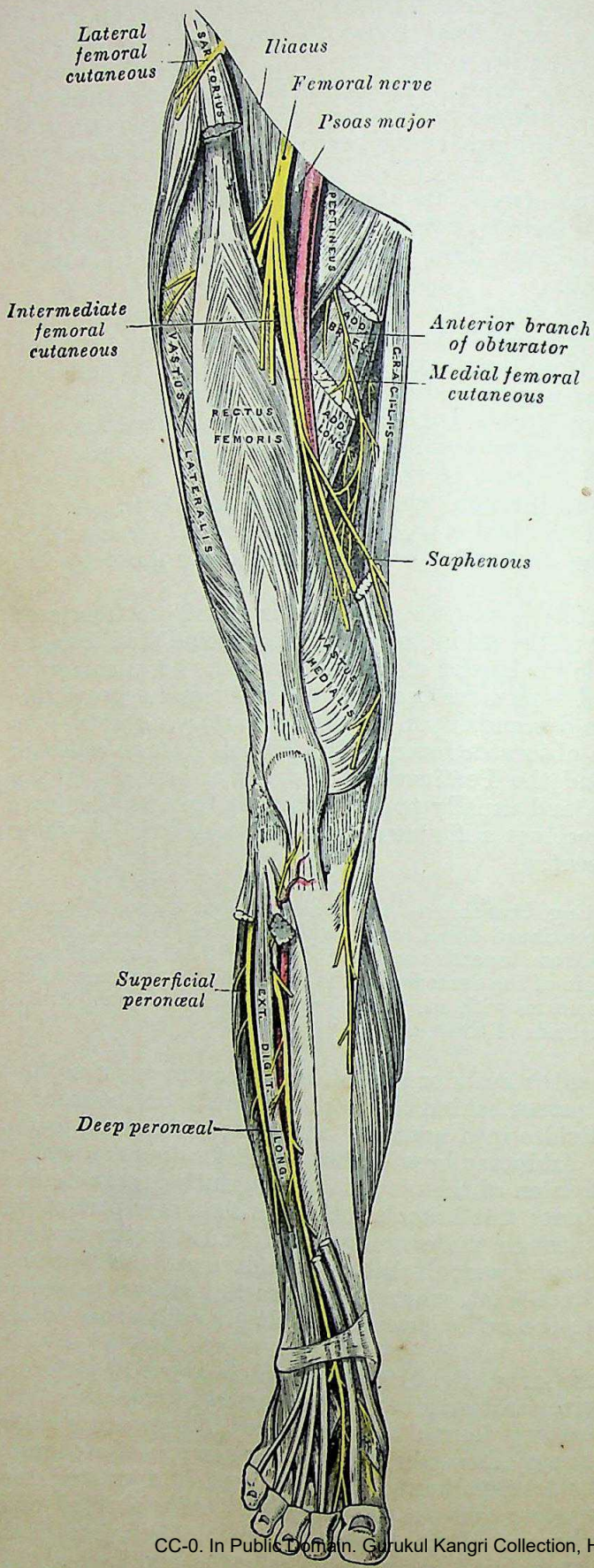

Within the abdomen the femoral nerve gives off small branches to the Iliacus, and a branch which is distributed upon the upper part of the femoral artery; the latter branch may arise in the thigh.

The anterior division of the femoral nerve gives off the intermediate and medial cutaneous nerves (fig. 920), and muscular branches to the Pectineus and Sartorius.

The *intermediate cutaneous nerve* pierces the fascia lata about 8 cm. below the inguinal ligament, either as two branches, or as a single trunk which quickly divides into two branches; these branches descend vertically along the front of the thigh, and supply the skin as low as the knee. They end in the patellar plexus (p. 957). The lateral branch of the intermediate cutaneous communicates with the lumbo-inguinal branch of the genitofemoral nerve, and frequently pierces the Sartorius.

The *medial cutaneous nerve* lies at first on the lateral side of the femoral artery, but at the apex of the femoral triangle it crosses in front of the artery and divides into an anterior and a posterior branch. Before dividing, the nerve

CC-0. In Public Domain. Gurukul Kangri Collection, Haridwar

Digitized by Arya Samaj Foundation Chennai and eGangotri

gives off a few filaments, which pierce the fascia lata, to supply the skin of the medial side of the thigh, in the neighbourhood of the great saphenous vein; one of these filaments emerges through the fossa ovalis, and a second becomes subcutaneous about the middle of the thigh. The *anterior branch* runs downwards on the Sartorius, perforates the fascia lata at the junction of the middle with the lower one-third of the thigh, and divides into two branches: one supplies the skin as low as the medial side of the knee; the other crosses to the lateral side of the patella, communicating in its course with the infrapatellar branch of the saphenous nerve. The *posterior branch* descends along the posterior border of the Sartorius to the knee, where it pierces the fascia lata, communicates with the saphenous nerve, and gives off several cutaneous branches. It then passes down to supply the skin of the medial side of the leg. Beneath the fascia lata, at the lower border of the Adductor longus, it joins to form a plexiform network (*subsartorial plexus*) with branches of the saphenous and obturator nerves. When the communicating branch from the obturator nerve is large and continued to the skin of the leg, the posterior branch of the medial cutaneous is small, and terminates in the plexus, occasionally giving off a few cutaneous filaments. The *nerve to the Pectineus* arises just below the inguinal ligament, passes behind the femoral sheath and enters the anterior surface of the muscle; it is often duplicated. The *nerve to the Sartorius* arises in common with the intermediate cutaneous nerve.

The posterior division of the femoral nerve gives off the saphenous nerve, and supplies muscular branches to the Quadriceps femoris, and articular branches to the knee-joint.

The **saphenous nerve** (long or internal saphenous nerve) (fig. 922) is the largest cutaneous branch of the femoral nerve. It descends on the lateral side of the femoral artery and enters the adductor canal (p. 690) where it crosses the artery obliquely from its lateral to its medial side. At the lower end of the canal it quits the artery, and emerges through the aponeurotic covering of the canal, accompanied by the saphenous branch of the highest genicular artery. It descends vertically along the medial side of the knee behind the Sartorius, pierces the fascia lata, between the tendons of the Sartorius and Gracilis, and becomes subcutaneous. It then passes along the tibial side of the leg, accompanied by the great saphenous vein, descends behind the medial border of the tibia, and, at the lower third of the leg, divides into two branches: one continues its course along the margin of the tibia, and ends at the ankle; the other passes in front of the ankle, and is distributed to the skin on the medial side of the foot, as far as the ball of the great toe, communicating with the medial branch of the superficial peronæal nerve.

About the middle of the thigh, the saphenous nerve gives a branch to join the subsartorial plexus.

At the medial side of the knee it gives off a large *infrapatellar branch* (fig. 920) which pierces the Sartorius and fascia lata, and is distributed to the skin in front of the patella. Above the knee this nerve unites with the medial and intermediate branches of the femoral nerve; below the knee, with other branches of the saphenous nerve; and, on the lateral side of the joint, with branches of the lateral femoral cutaneous nerve, forming a plexiform network, the *plexus patellæ*. The infrapatellar branch is occasionally small.

The *muscular branches* of the posterior division of the femoral nerve supply the Quadriceps femoris. The branch to the Rectus femoris enters the upper part of the deep surface of the muscle, and supplies a filament to the hip-joint. The branch to the Vastus lateralis, of large size, accompanies the descending branch of the lateral femoral circumflex artery to the lower part of the muscle and sends an articular filament to the knee-joint. The branch to the Vastus medialis descends through the upper part of the adductor canal, on the lateral side of the saphenous nerve and the femoral vessels. It enters the muscle about its middle, and gives off a filament, which can usually be traced downwards on the surface of the muscle, to the knee-joint. The branches to the Vastus intermedius, two or three in number, enter the anterior surface of the muscle about the middle of the thigh; a filament from one of these descends through the muscle to the Articularis genus and the knee-joint.

CC-0. In Public Domain. Gurukul Kangri Collection, Haridwar

Digitized by Arya Samaj Foundation Chennai and eGangotri

THE ANTERIOR DIVISIONS OF THE SACRAL AND COCCYGEAL NERVES

The **anterior divisions of the sacral and coccygeal nerves** form the sacral and pudendal plexuses. The anterior divisions of the upper four sacral nerves enter the pelvis through the anterior sacral foramina, that of the fifth between the sacrum and coccyx, while that of the coccygeal nerve curves forwards below the rudimentary transverse process of the first piece of the coccyx. The first and second sacral nerves are large; the third, fourth and fifth diminish progressively; the coccygeal nerve is the smallest. Each of these nerves receives a grey ramus communicans from the corresponding ganglion of the sympathetic trunk; from the second, third and fourth sacral nerves white rami communicantes are given to the pelvic plexuses of the sympathetic.

The Sacral Plexus

The **sacral plexus** (fig. 923) is formed by the lumbosacral trunk, the anterior division of the first, and portions of the anterior divisions of the second and third sacral nerves.

The lumbosacral trunk comprises a part of the anterior division of the fourth lumbar nerve, and the whole of the anterior division of the fifth lumbar nerve; it appears at the medial margin of the Psoas major and descends over the pelvic brim and in front of the sacro-iliac joint to join the first sacral nerve.

The anterior division of the third sacral nerve divides into an upper and a lower branch; the upper branch enters the sacral plexus; the lower joins the pudendal plexus.

The nerves forming the sacral plexus converge towards the lower part of the greater sciatic foramen, and unite to form a flattened band, from the anterior and posterior surfaces of which several branches arise; the band itself is continued as the sciatic nerve.

Relations.—The sacral plexus lies on the posterior wall of the pelvic cavity in front of the Piriformis (fig. 924), and behind the hypogastric vessels, the ureter and the sigmoid colon. The superior glutæal vessels run between the lumbosacral trunk and the anterior division of the first sacral nerve, and the inferior glutæal vessels between the anterior divisions of the second and third sacral nerves.

All the nerves entering the plexus, with the exception of the anterior division of the third sacral, split into ventral and dorsal divisions, and the nerves arising from these are as follows:

	Ventral divisions.	Dorsal divisions.
Nerve to Quadratus femoris and Gemellus inferior	4, 5 L., 1 S.	
Nerve to Obturator internus and Gemellus superior	5 L., 1, 2 S.	
Nerve to Piriformis		(1) 2 S.
Superior glutæal		4, 5 L., 1 S.
Inferior glutæal		5 L., 1, 2 S.
Posterior femoral cutaneous	2, 3 S.	1, 2 S.
Sciatic: Tibial	4, 5 L., 1, 2, 3 S.	
Sciatic: Common peronæal		4, 5 L., 1, 2 S.

The **nerve to the Quadratus femoris and Gemellus inferior** arises from the ventral branches of the anterior divisions of the fourth and fifth lumbar and first sacral nerves; it leaves the pelvis through the greater sciatic foramen, below the Piriformis, and, running down on the ischium in front of the sciatic nerve, the Gemelli and the tendon of the Obturator internus, supplies a twig to the Gemellus inferior, and enters the anterior surface of the Quadratus femoris; it gives an articular branch to the hip-joint.

The **nerve to the Obturator internus and Gemellus superior** arises from the ventral branches of the anterior divisions of the fifth lumbar and first and second sacral

CC-0. In Public Domain. Gurukul Kangri Collection, Haridwar

Digitized by Arya Samaj Foundation Chennai and eGangotri

nerves. It leaves the pelvis through the greater sciatic foramen below the Piriformis, and gives a branch which enters the upper part of the posterior surface of the Gemellus superior. It then crosses the ischial spine on the lateral side of the

FIG. 923.—A plan of the sacral and pudendal plexuses.

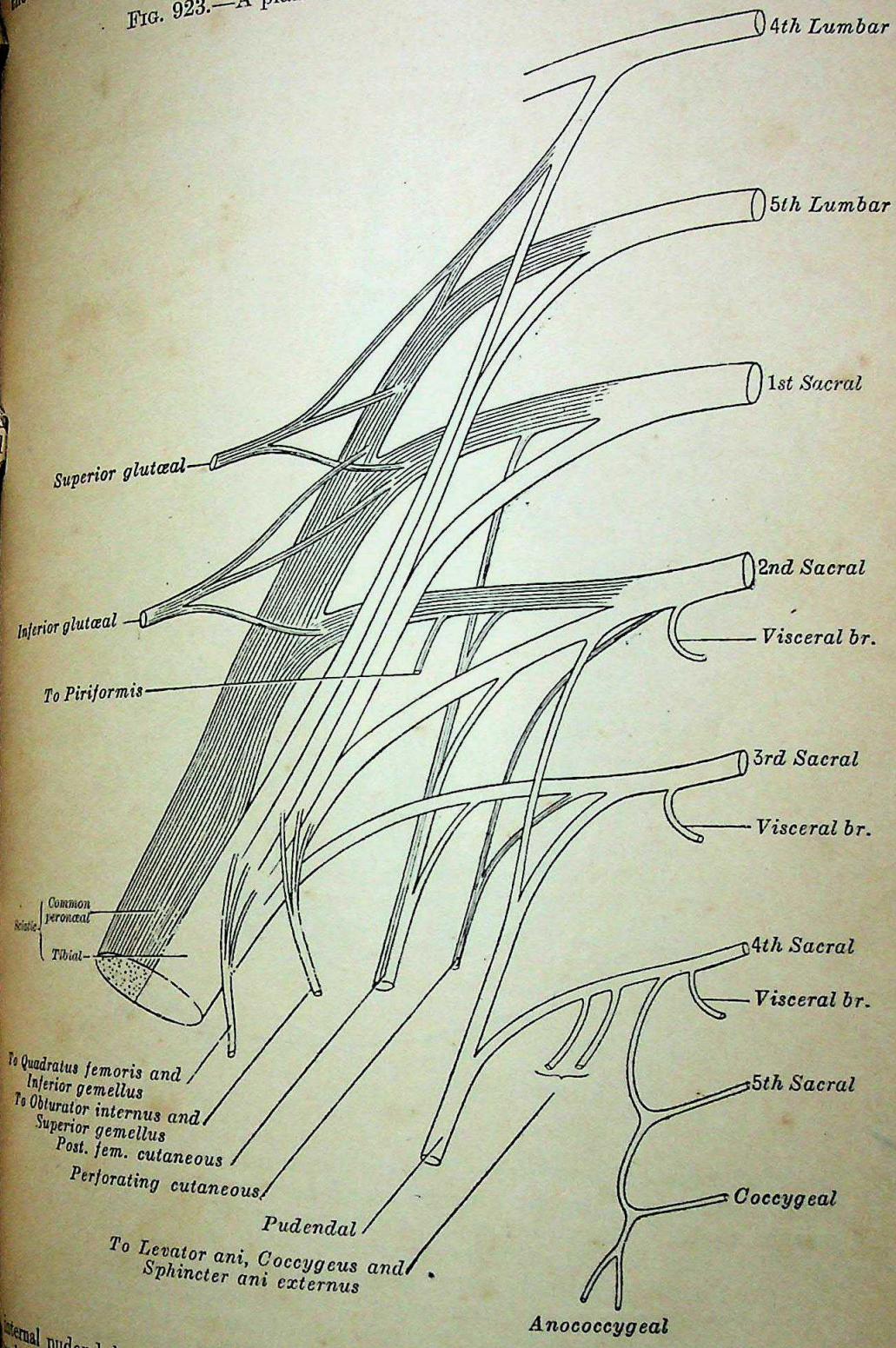

internal pudendal vessels, re-enters the pelvis through the lesser sciatic foramen, and pierces the pelvic surface of the Obturator internus.

The **nerve to the Piriformis** arises usually from the dorsal branches of the anterior divisions of the first and second sacral nerves; it enters the anterior surface of the muscle.

The **superior glutæal nerve** arises from the dorsal branches of the anterior divisions of the fourth and fifth lumbar and first sacral nerves: it leaves the pelvis through the greater sciatic foramen above the Piriformis, accompanied by the

CC-0. In Public Domain. Gurukul Kangri Collection, Haridwar

Digitized by Arya Samaj Foundation Chennai and eGangotri

superior glutæal vessels, and divides into a superior and an inferior branch. The *superior* branch accompanies the upper branch of the deep division of the superior glutæal artery and ends in the Glutæus minimus. The *inferior* branch runs with the lower branch of the deep division of the superior glutæal artery across the Glutæus minimus; it gives twigs to the Glutæus medius and Glutæus minimus, and ends in the Tensor fasciæ latæ.

Fig. 924.—A dissection of the side wall of the pelvis, showing the sacral and pudendal plexuses.

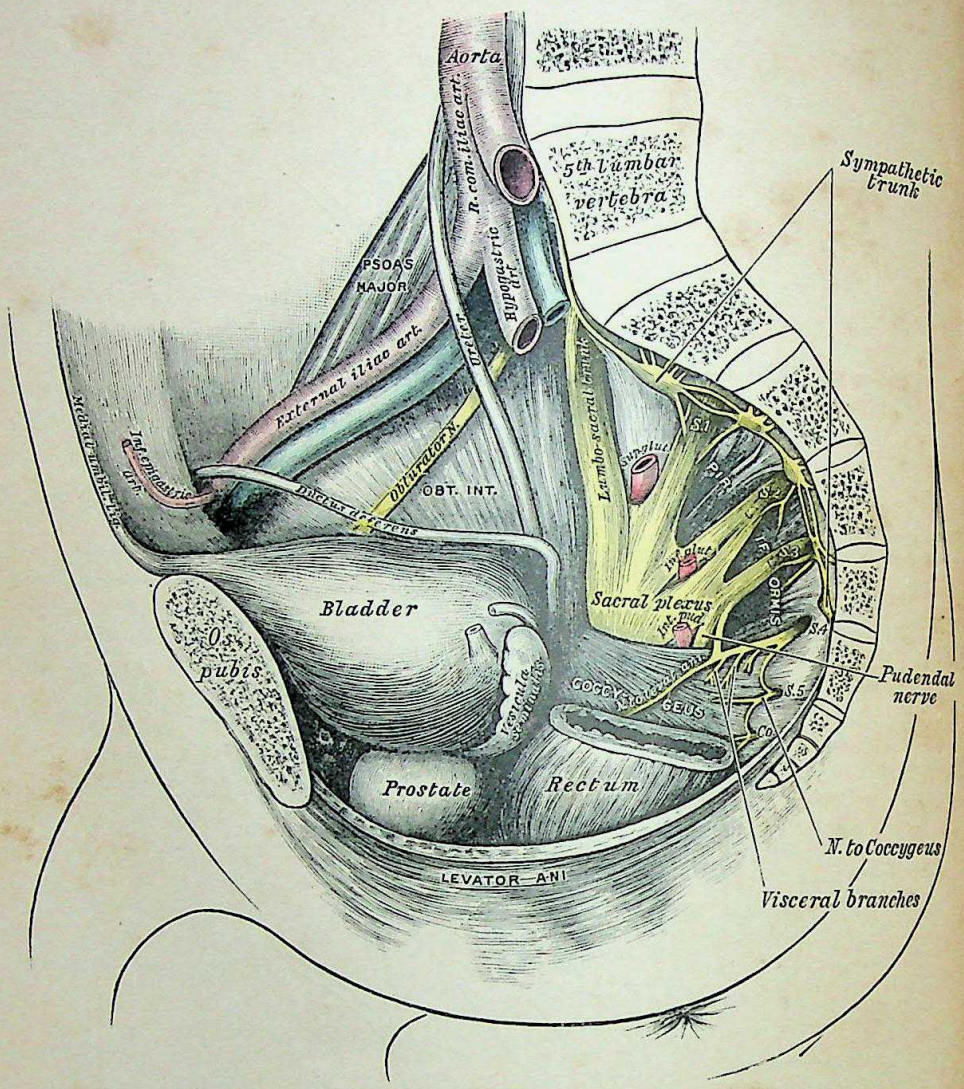

The **inferior glutæal nerve** arises from the dorsal branches of the anterior divisions of the fifth lumbar and first and second sacral nerves: it leaves the pelvis through the greater sciatic foramen, below the Piriformis, and divides into branches which enter the deep surface of the Glutæus maximus.

The **posterior femoral cutaneous nerve** (small sciatic nerve) arises from the dorsal branches of the anterior divisions of the first and second, and from the ventral branches of the anterior divisions of the second and third, sacral nerves, and issues from the pelvis through the greater sciatic foramen below the Piriformis. It then descends beneath the Glutæus maximus with the inferior glutæal artery, and runs down the back of the thigh, superficial to the long head of the Biceps femoris, and beneath the fascia lata; at the back of the knee it pierces the deep fascia and accompanies the small saphenous vein as far as the middle of the calf of the leg, its terminal twigs communicating with the sural nerve.

Its branches are all cutaneous, and are distributed to the glutæal region, the perinæum, and the back of the thigh and leg.

CC-0. In Public Domain. Gurukul Kangri Collection, Haridwar

Digitized by Arya Samaj Foundation Chennai and eGangotri

FIG. 925.—The cutaneous nerves of the right lower extremity. Posterior aspect.

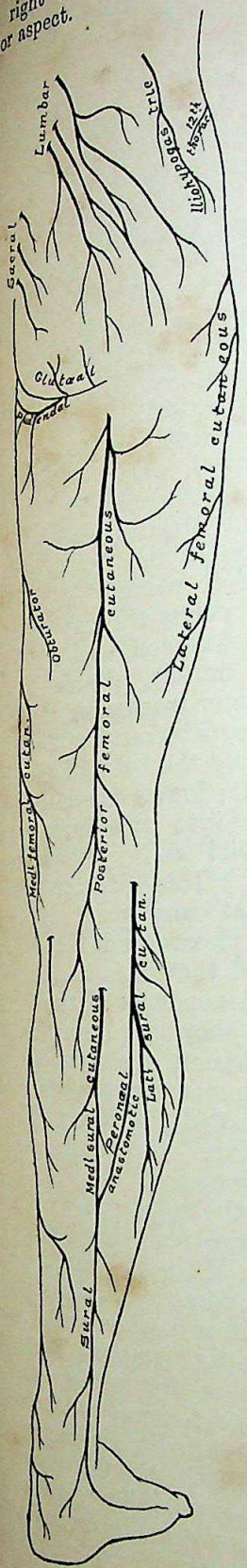

FIG. 926.—A diagram showing the segmental distribution of the cutaneous nerves of the right lower extremity. Posterior aspect.

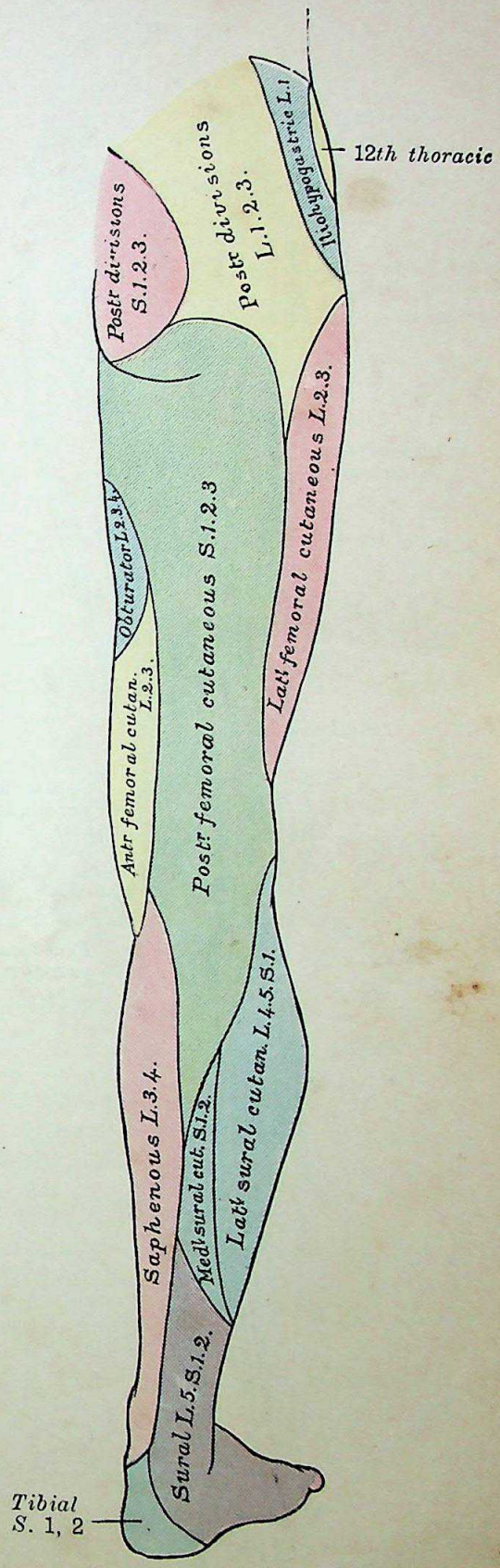

The *glutæal branches* (nn. clunium inferiores), three or four in number, turn upwards round the lower border of the Glutæus maximus, and supply the skin covering the lower and lateral part of that muscle.

The *perinæal branches* are distributed to the skin at the upper and medial side of the thigh. One long perinæal branch (inferior pudendal) curves forwards

CC-0. In Public Domain. Gurukul Kangri Collection, Haridwar

Digitized by Arya Samaj Foundation Chennai and eGangotri

Fig. 927.—The nerves of the right lower extremity.* Posterior aspect.

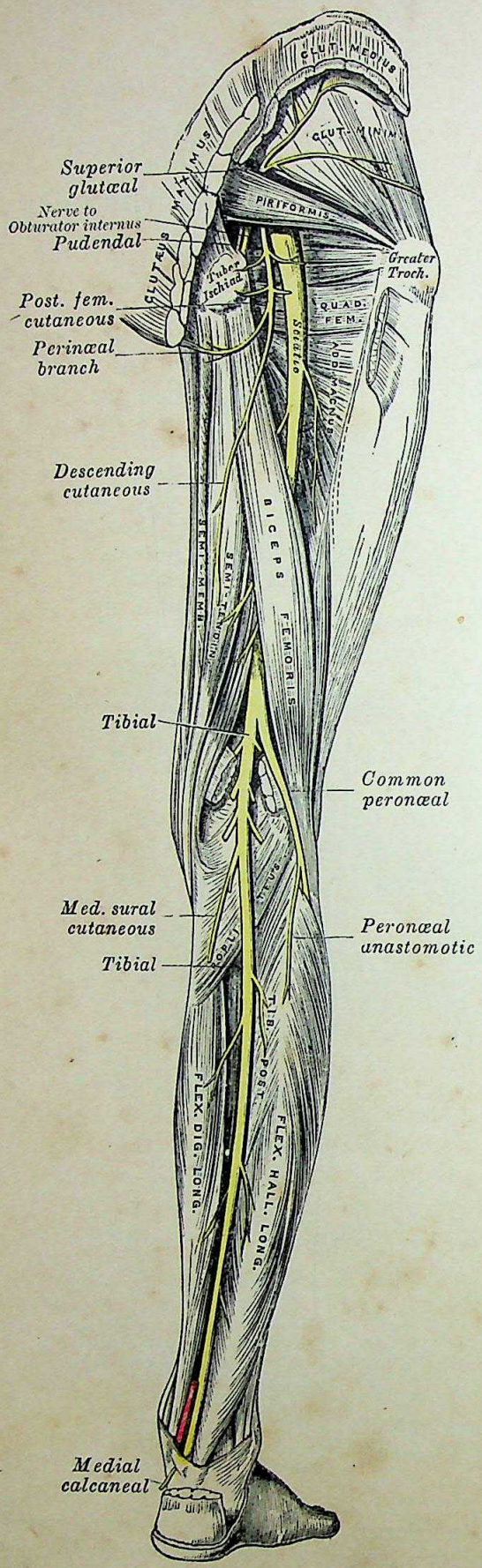

below and in front of the ischial tuberosity, pierces the fascia lata, and runs forwards beneath the superficial fascia of the perinæum to the skin of the scrotum in the male, and of the labium majus in the female. It communicates with the inferior hæmorrhoidal and posterior scrotal nerves.

The *branches to the back of the thigh and leg* consist of numerous filaments derived from both sides of the nerve, and distributed to the skin covering the back and medial side of the thigh, the popliteal fossa, and the upper part of the back of the leg (fig. 925).

The **sciatic nerve** (fig. 927) is the largest nerve in the body. At its commencement it measures 2 cm. in breadth, and is the continuation of the flattened band of the sacral plexus. It passes out of the pelvis through the greater sciatic foramen, below the Piriformis muscle, descends between the greater trochanter of the femur and the tuberosity of the ischium, and along the back of the thigh to about its lower one-third, where it divides into two large branches, the tibial and common peronæal nerves. This division may take place at any point between the sacral plexus and the lower one-third of the thigh, and in all cases the independence of the two nerves can be shown by dissection. When the division occurs at the plexus, the common peronæal nerve usually pierces the Piriformis. The nerve also gives off articular and muscular branches.

In the upper part of its course the nerve rests upon the posterior surface of the ischium, the nerve to the Quadratus femoris, the Obturator internus and Gemelli, and the Quadratus femoris; it is accompanied on its medial side by the posterior femoral cutaneous nerve and the inferior glutæal artery, and is covered by the Glutæus maximus. Lower down, it lies upon the Adductor magnus, and is crossed obliquely by the long head of the Biceps femoris.

The *articular branches* of the sciatic nerve arise from the upper part of the nerve and supply the

* N.B.—In this diagram the medial sural cutaneous and peronæal anastomotic nerves have been displaced by the removal of the superficial fascia.

CC-0. In Public Domain. Gurukul Kangri Collection, Haridwar

Digitized by Arya Samaj Foundation Chennai and eGangotri

joint, perforating the posterior part of its capsule; they are sometimes
ived from the sacral plexus.

The *muscular branches* of the sciatic nerve are distributed to the Biceps
moris, Semitendinosus, Semimembranosus, and Adductor magnus. The nerve
the short head of the Biceps femoris comes from the common peronæal part,
ile the other muscular branches arise from the tibial portion, of the sciatic
rve, as may be seen in those cases where there is a high division of the
rve.

The **tibial nerve** (internal popliteal nerve) (fig. 927), the larger terminal
anch of the sciatic nerve, arises from the ventral branches of the anterior
visions of the fourth and fifth lumbar and first, second, and third sacral
rves. It descends along the back of the thigh and through the middle of
e popliteal fossa, to the lower part of the Popliteus muscle, whence it
sses with the popliteal artery beneath the arch of the Soleus. It then runs
ng the back of the leg with the posterior tibial vessels to the interval
ween the medial malleolus and the heel, where it divides beneath the
aciniate ligament into the medial and lateral plantar nerves. In the thigh it
verlapped by the hamstring muscles above, and then becomes more super-
cial, and lies lateral to, and some distance from, the popliteal vessels; opposite
knee-joint, it is superficial to these vessels, and then crosses to the medial
of the popliteal artery. In the leg it is covered in the upper part of its
rse by the superficial muscles of the calf; lower down by the skin and
e superficial and deep fasciæ. It is placed on the deep muscles, and lies at
st on the medial side of the posterior tibial artery, but soon crosses that
sel and descends on its lateral side as far as the ankle. In the lower part
the leg it runs parallel with the medial margin of the tendo calcaneus.

The branches of this nerve are; articular, muscular, medial sural cutaneous,
ntal calcaneal, medial and lateral plantar.

Articular branches, usually three in number, supply the knee-joint; one
nch accompanies the superior, and another the inferior, medial genicular
ery; the third branch runs with the middle genicular artery. Just above
point of bifurcation the tibial nerve gives an articular branch to the ankle-
int.

Muscular branches, four or five in number, arise from the nerve as it lies
ween the two heads of the Gastrocnemius muscle; they supply that muscle,
well as the Plantaris, Soleus, and Popliteus. The branch for the Popliteus
s round the lower border of that muscle, and is distributed to its deep
face. Lower down, muscular branches arise independently or by a common
nk and supply the Soleus, Tibialis posterior, Flexor digitorum longus, and
exor hallucis longus; the branch to the last muscle accompanies the peronæal
ery; that to the Soleus enters the deep surface of the muscle.

The *medial sural cutaneous nerve* (n. communicans tibialis) descends between
e two heads of the Gastrocnemius, and, about the middle of the back of the
g, pierces the deep fascia, and unites with the peronæal anastomotic branch
the common peronæal nerve to form the sural nerve (fig. 925). The *sural*
ve (external saphenous nerve) passes downwards near the lateral margin of
e tendo calcaneus, lying close to the small saphenous vein, to the interval
ween the lateral malleolus and the calcaneus; it supplies the skin of the
teral and posterior part of the lower one-third of the leg. It runs forwards
w the lateral malleolus, and is continued as the *lateral dorsal cutaneous*
ve along the lateral side of the foot and little toe, communicating on the
rsum of the foot with the intermediate dorsal cutaneous nerve, a branch of
e superficial peronæal nerve. In the leg, its branches communicate with
se of the posterior femoral cutaneous nerve.

The *medial calcaneal branch* perforates the laciniate ligament, and supplies
e skin of the heel and medial side of the sole of the foot.

The **medial plantar nerve** (fig. 928), the larger of the two terminal divisions
the tibial nerve, accompanies the medial plantar artery. From its origin
der the laciniate ligament it passes under cover of the Abductor hallucis,
d appearing between this muscle and the Flexor digitorum brevis, gives
s a proper digital nerve to the medial side of the great toe and finally
ides opposite the bases of the metatarsal bones into three common digital
ves.

CC-0. In Public Domain. Gurukul Kangri Collection, Haridwar

Digitized by Arya Samaj Foundation Chennai and eGangotri

Branches.—*Cutaneous branches* pierce the plantar aponeurosis between the Abductor hallucis and the Flexor digitorum brevis and are distributed to the skin of the sole of the foot.

Muscular branches supply the Abductor hallucis, the Flexor digitorum brevis, the Flexor hallucis brevis, and the first Lumbricalis; those for the Abductor hallucis and Flexor digitorum brevis arise from the trunk of the nerve near its origin and enter the deep surfaces of the muscles; the branch for the Flexor hallucis brevis springs from the proper digital nerve to the medial side of the great toe, and that for the first Lumbricalis from the first common digital nerve.

Articular branches supply the articulations of the tarsus and metatarsus.

FIG. 928.—The plantar nerves of the right foot.

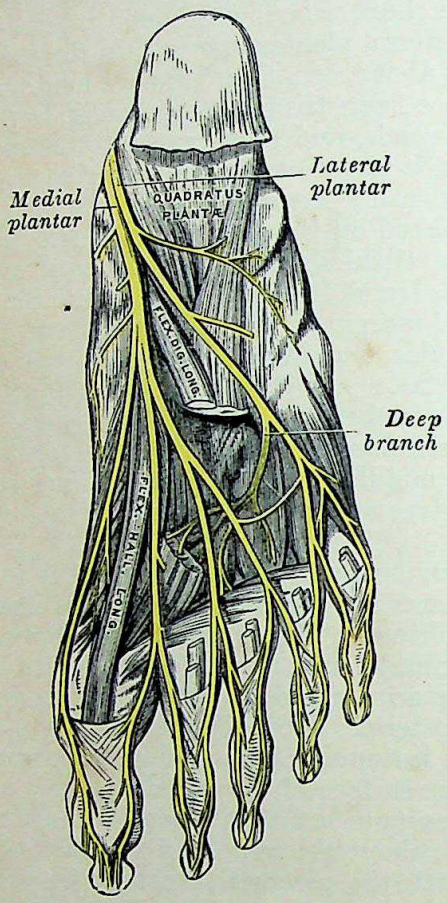

FIG. 929.—A diagram showing the segmental distribution of the cutaneous nerves of the sole of the right foot.

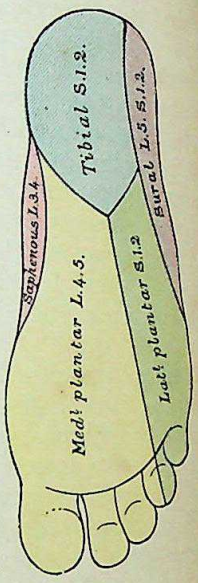

The *proper digital nerve of the great toe* supplies the Flexor hallucis brevis and the skin on the medial side of the great toe.

The *three common digital nerves* pass between the divisions of the plantar aponeurosis, and each splits into two proper digital nerves. Those of the first common digital nerve supply the adjacent sides of the great and second toes; those of the second, the adjacent sides of the second and third toes; and those of the third, the adjacent sides of the third and fourth toes. The third common digital nerve receives a communicating branch from the lateral plantar nerve; the first gives a twig to the first Lumbricalis. Each proper digital nerve gives off cutaneous and articular filaments, and opposite the last phalanx sends upwards a dorsal branch, which supplies the structures around the nail, the continuation of the nerve being distributed to the ball of the toe. It will be observed that the digital nerves of the medial plantar nerve are similar in their distribution to those of the median nerve in the hand.

The **lateral plantar nerve** (fig. 928) supplies the skin of the fifth toe and lateral half of the fourth, as well as most of the deep muscles, its distribution being similar to that of the ulnar nerve in the hand. It passes obliquely

CC-0. In Public Domain. Gurukul Kangri Collection, Haridwar

Digitized by Arya Samaj Foundation Chennai and eGangotri

forwards with the lateral plantar artery to the lateral side of the foot, lying between the Flexor digitorum brevis and Quadratus plantæ, and, in the interval between the former muscle and the Abductor digiti quinti, divides into a superficial and a deep branch. Before its division, it supplies the Quadratus plantæ and Abductor digiti quinti.

The *superficial branch* splits into a proper and a common digital nerve; the proper digital nerve supplies the lateral side of the little toe, the Flexor digiti quinti brevis, and the two Interossei of the fourth intermetatarsal space; the common digital nerve communicates with the third common digital branch of the medial plantar nerve and divides into two proper digital nerves which supply the adjoining sides of the fourth and fifth toes.

The *deep branch* accompanies the lateral plantar artery on the deep surface of the tendons of the flexor muscles and the Adductor hallucis, and supplies the second, third, and fourth Lumbricales, the Adductor hallucis, and all the Interossei (except those in the fourth metatarsal space).

The **common peronæal nerve** (external popliteal nerve) (fig. 927), about one-half the size of the tibial, is derived from the dorsal branches of the anterior divisions of the fourth and fifth lumbar and the first and second sacral nerves. It descends obliquely along the lateral side of the popliteal fossa to the head of the fibula, close to the medial margin of the Biceps femoris muscle. It lies between the tendon of the Biceps femoris and lateral head of the Gastrocnemius muscle, winds round the neck of the fibula, beneath the Peronæus longus, and divides under cover of that muscle into the superficial and deep peronæal nerves. Previous to its division it gives off articular and cutaneous branches.

The *articular branches* are three in number; two of these accompany the superior and inferior lateral genicular arteries to the knee; the upper one occasionally arises from the trunk of the sciatic nerve. The third, named the recurrent articular nerve, is given off at the point of division of the common peronæal nerve; it ascends with the anterior recurrent tibial artery through the Tibialis anterior to the front of the knee-joint.

The *cutaneous branches*, two in number, frequently spring from a common trunk; they are the lateral sural cutaneous and the peronæal anastomotic nerves.

The *lateral sural cutaneous nerve* supplies the skin on the anterior, posterior and lateral surfaces of the proximal part of the leg. The *peronæal anastomotic nerve* (n. communicans fibularis), arises near the head of the fibula, runs obliquely across the lateral head of the Gastrocnemius to the middle of the leg, and joins with the medial sural cutaneous to form the sural nerve (p. 963). The peronæal anastomotic nerve occasionally descends as a separate branch as far as the heel.

The **deep peronæal nerve** (anterior tibial nerve) (fig. 922) begins at the bifurcation of the common peronæal nerve, between the fibula and proximal part of the Peronæus longus, passes obliquely forwards beneath the Extensor digitorum longus to the front of the interosseous membrane, where it comes into relation with the anterior tibial artery in the upper one-third of the leg; it then descends with the artery to the front of the ankle-joint, where it divides into lateral and medial terminal branches. It lies at first on the lateral side of the anterior tibial artery, then in front of it, and again on its lateral side at the ankle-joint.

In the leg, the deep peronæal nerve supplies *muscular branches* to the Tibialis anterior, Extensor hallucis longus, Extensor digitorum longus and Peronæus tertius, and an *articular branch* to the ankle-joint.

The *lateral terminal branch* of the deep peronæal nerve passes across the tarsus, beneath the Extensor digitorum brevis, and, having become enlarged like the dorsal interosseous nerve at the wrist, supplies the Extensor digitorum brevis. From the enlargement three minute *interosseous branches* are given off, which supply the tarsal joints, and the metatarsophalangeal joints of the second, third, and fourth toes. The first of these sends a filament to the second Interosseus dorsalis muscle.

The *medial terminal branch* of the deep peronæal nerve runs forwards on the dorsum of the foot, on the lateral side of the dorsalis pedis artery. At the first interosseous space it communicates with the medial dorsal cutaneous branch of the superficial peronæal nerve, and divides into two dorsal digital nerves, which supply the adjacent sides of the great and second toes. Before it

CC-0. In Public Domain. Gurukul Kangri Collection, Haridwar

Digitized by Arya Samaj Foundation Chennai and eGangotri

divides it gives off an *interosseous branch* which supplies the metatarsophalangeal joint of the great toe and sends a filament to the first Interosseus dorsalis muscle.

The **superficial peronæal nerve** (musculocutaneous nerve) (fig. 922) begins at the bifurcation of the common peronæal nerve, passes forwards between the Peronæi and the Extensor digitorum longus, pierces the deep fascia at the lower one-third of the leg, and divides into a medial and an intermediate dorsal cutaneous nerve. In its course between the muscles, it gives off muscular branches to the Peronæus longus and Peronæus brevis, and filaments to the skin of the lower part of the leg.

The *medial dorsal cutaneous nerve* passes in front of the ankle-joint, and divides into two dorsal digital branches, one of which supplies the medial side of the great toe, the other, the adjacent sides of the second and third toes. It communicates with the saphenous nerve and with the deep peronæal nerve (fig. 920).

The *intermediate dorsal cutaneous nerve*, the smaller, passes along the lateral part of the dorsum of the foot, and divides into dorsal digital branches, which supply the contiguous sides of the third and fourth, and of the fourth and fifth toes. It also supplies the skin of the lateral side of the ankle, and communicates with the lateral dorsal cutaneous nerve (fig. 920).

The branches of the superficial peronæal nerve supply the skin of the dorsal surfaces of all the toes excepting the lateral side of the little toe and the adjoining sides of the great and second toes, the former being supplied by the lateral dorsal cutaneous branch of the sural nerve, and the latter by the medial branch of the deep peronæal nerve. Frequently some of the lateral branches of the superficial peronæal are absent, and their places are then taken by branches of the lateral dorsal cutaneous nerve.

The Pudendal Plexus

The **pudendal plexus** (figs. 923, 924) is not sharply marked off from the sacral plexus, and as a consequence some of its branches arise in conjunction with those of the sacral plexus. It lies on the posterior wall of the pelvic cavity and is usually formed by parts of the anterior divisions of the second, third, and fourth sacral nerves, the anterior division of the fifth sacral nerve, and the anterior division of the coccygeal nerve.

It gives off the following branches :

Perforating cutaneous	2, 3 S.
Pudendal	2, 3, 4 S.
Visceral	3, 4 S.
Muscular	4 S.
Anococcygeal	4, 5 S. and Cocc.

The **perforating cutaneous nerve** usually arises from the posterior surfaces of the second and third sacral nerves. It pierces the lower part of the sacrotuberous ligament, and, winding round the inferior border of the Glutæus maximus, supplies the skin covering the medial and lower parts of that muscle.

The perforating cutaneous nerve may arise from the pudendal nerve or it may be absent: in the latter case its place may be taken by a branch from the posterior femoral cutaneous nerve or by a branch from the third and fourth, or fourth and fifth, sacral nerves.

The **pudendal nerve** (pudic nerve) derives its fibres from the second, third, and fourth sacral nerves. It passes between the Piriformis and Coccygeus muscles and leaves the pelvis through the lower part of the greater sciatic foramen. It then crosses the spine of the ischium on the medial side of the internal pudendal vessels, and passes through the lesser sciatic foramen. It accompanies the internal pudendal vessels along the lateral wall of the ischiorectal fossa in *Alcock's canal*, and after giving off the inferior hæmorrhoidal nerve, it divides into the perinæal nerve, and the dorsal nerve of the penis or clitoris.

The *inferior hæmorrhoidal nerve* occasionally arises directly from the sacral plexus ; it crosses the ischiorectal fossa with the inferior hæmorrhoidal vessels,

CC-0. In Public Domain. Gurukul Kangri Collection, Haridwar

Digitized by Arya Samaj Foundation Chennai and eGangotri

wards the anal canal and the lower end of the rectum, and is distributed the Sphincter ani externus and to the skin round the anus. Branches of is nerve communicate with the perinæal branch of the posterior femoral utaneous and with the posterior scrotal nerves.

The *perinæal nerve*, the inferior and larger terminal branch of the pudendal is situated below the internal pudendal artery. It accompanies the rinæal artery and divides into posterior scrotal (or labial) and muscular nches.

The *posterior scrotal branches* (superficial perinæal nerves) are two, a medial d a lateral. They pierce, or pass superficial to, the fascia of the urogenital aphragm, and run forwards along the lateral part of the urethral triangle in mpany with the posterior scrotal branches of the perinæal artery; they e distributed to the skin of the scrotum, and communicate with the perinæal anch of the posterior femoral cutaneous nerve. In the female the corresponding nerves (*posterior labial branches*) supply the labium majus.

The muscular branches are distributed to the Transversus perinæi superialis, Bulbocavernosus, Ischiocavernosus, Transversus perinæi profundus, and sphincter urethræ membranaceæ. A branch, the *nerve to the urethral bulb*, is given from the nerve to the Bulbocavernosus; it pierces this muscle, and supplies corpus cavernosum urethræ, ending in the mucous membrane of the urethra.

The *dorsal nerve of the penis* is the deepest division of the pudendal nerve; accompanies the internal pudendal artery along the ramus of the ischium; then runs forwards along the margin of the inferior ramus of the os pubis, tween the superior and inferior layers of the fascia of the urogenital diaagm. It pierces the inferior layer, and gives a branch to the corpus cavernosum penis. It then passes forwards, in company with the dorsal artery of e penis, between the layers of the suspensory ligament, to the dorsum of the is, and ends on the glans penis. In the female the corresponding nerve *rsal nerve of the clitoris*) is very small, and supplies the clitoris.

The **visceral branches** arise from the second, third and fourth sacral rves, and are distributed, through the pelvic plexuses of the sympathetic, the bladder and rectum; in the female they also give branches to the vagina.

The **muscular branches** are derived from the fourth sacral, and supply e Levator ani, Coccygeus, and Sphincter ani externus. The branches to the vator ani and Coccygeus enter their pelvic surfaces; that to the Sphincter ani externus (perinæal branch of fourth sacral nerve) reaches the ischiorectal ssa by piercing the Coccygeus or by passing between it and the Levator ani. taneous filaments from this branch supply the skin between the anus and e coccyx.

The **anococcygeal nerves**.—The anterior division of the fifth sacral nerve ceives a communicating filament from the fourth, and unites with the minute terior division of the coccygeal nerve to form what is sometimes named e *coccygeal plexus*. The anococcygeal nerves arise from this plexus, and consist of a few fine filaments which pierce the sacrotuberous ligament and supply e skin in the region of the coccyx.

Applied Anatomy.—The lumbar plexus passes through the Psoas major, and therefore psoas abscess any or all of its branches may be irritated, causing severe pain in the part which the irritated nerves are distributed. The genitofemoral nerve is the one which most frequently implicated. This nerve is also of importance as it is concerned in one the principal superficial reflexes employed in the investigation of diseases of the dulla spinalis. If the skin over the medial side of the thigh just below the inguinal gument (the part supplied by the lumbo-inguinal branch of the genitofemoral nerve) be ched in the male child, the testis will be retracted, through the action of the Cremaster scle which is supplied by the external spermatic branch of the genitofemoral nerve. e same result may sometimes be noticed in adults, and can almost always be produced severe stimulation. This reflex shows that the portion of the medulla spinalis from the first and second lumbar nerves are derived is in a normal condition.

The femoral nerve is in danger of being injured in fractures of the lesser pelvis, since fracture most commonly takes place through the superior ramus of the os pubis, at or the point where this nerve crosses the bone. It is also liable to be pressed upon and functions impaired, by some tumours growing in the pelvis. Moreover, on account of superficial position, it is exposed to injury in wounds and stabs in the groin. Its ral origin is often affected in cases of infantile paralysis. When this nerve is paralysed the patient is unable to flex his hip completely, on account of the paralysis of the ing; or to extend the knee on the thigh, on account of paralysis of the Quadriceps

CC-0. In Public Domain. Gurukul Kangri Collection, Haridwar

Digitized by Arya Samaj Foundation Chennai and eGangotri

femoris; there is complete paralysis of the Sartorius, and partial paralysis of the Pectineus. There is loss of sensation down the front and medial side of the thigh, except in that part supplied by the lumbo-inguinal and ilio-inguinal nerves. There is also loss of sensation down the medial side of the leg and foot as far as the ball of the great toe.

The obturator nerve is rarely paralysed alone, but occasionally in association with the femoral. The principal interest attached to it is in connexion with its supply to the knee, pain in the knee being symptomatic of many diseases in which the trunk of this nerve, or one of its branches, is irritated. Thus it is well known that in the earlier stages of hip-joint disease the patient may not always complain of pain in that articulation, but on the medial side of the knee, or in the knee-joint itself, both of these articulations being supplied by the obturator nerve, the final distribution of the nerve being to the knee-joint. Again, the same thing may occur in sacro-iliac disease; or in cases of pathological growth of the ovary or tubal inflammation; or in cancer of the sigmoid colon; and even in cases where masses of hardened fæces are impacted in this portion of the gut, pain is complained of in the knee. Finally, pain in the knee forms an important diagnostic sign in obturator hernia. When the obturator nerve is paralysed the patient is unable to press his knees together or to cross one leg over the other on account of paralysis of the Adductor muscles. Rotation outwards of the thigh is impaired from paralysis of the Obturator externus. Sometimes there is loss of sensation in the upper half of the medial side of the leg.

FIG. 930.—Dissections to show (A, B) the sciatic nerve, (C) the upper part of the tibial nerve and (D) the common peronæal nerve.

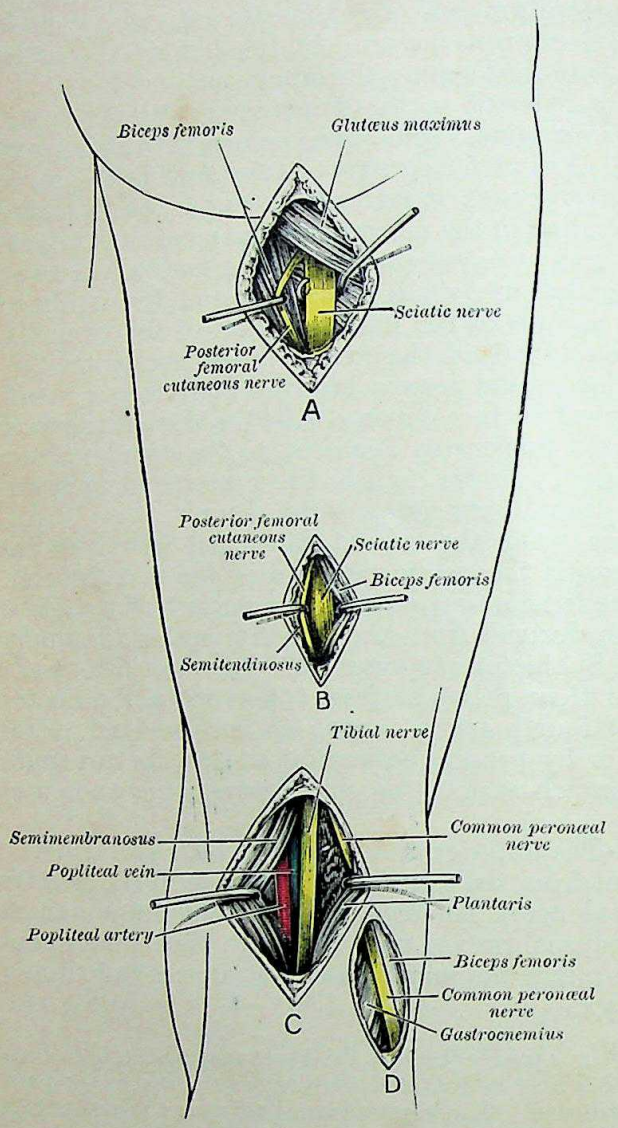

The sciatic nerve is liable to be pressed upon by various forms of pelvic tumour, giving rise to pain along its trunk, to which the term *sciatica* is applied. Tumours growing from the pelvic viscera, especially advanced cancer of the rectum, aneurysms of some of the branches of the hypogastric artery, calculus in the bladder when of large size, accumulation of fæces in the rectum, may all cause pressure on the nerve inside the pelvis, and give rise to sciatica. Outside the pelvis, exostoses or other tumours growing from the margin of the greater sciatic foramen may also give rise to the same condition. Most cases of sciatica, however, are due to neuritis of the sciatic nerve from exposure to cold, and it occurs more often in men, in the latter half of life, and often in association with rheumatism, gout, or diabetes mellitus. The inflamed nerve is often sensitive to pressure, particularly in certain 'tender spots' (e.g. near the posterior iliac spine, at the sciatic notch about the middle of the back of the thigh, in the popliteal fossa, below the head of the fibula, behind the malleoli, or on the dorsum of the foot), and pain is felt whenever extension of the leg is attempted and the nerve is stretched. Paralysis of the sciatic nerve is rarely complete; when the lesion occurs high up there is palsy of the Biceps femoris, Semimembranosus, and Semitendinosus, and of all the muscles below the knee. If the lesion be lower down, there is loss of motion in all the muscles below the knee, and loss of sensation in the same situation, except the upper half of the back of the leg, which is supplied by the posterior femoral cutaneous, and in the upper half of the medial side of the leg, where the communicating branch of the obturator is large (p. 955). Lesions of the common peronæal nerve cause paralysis of the Tibialis anterior, the Peronæi, the long Extensors of the toes, and the short Extensor on the dorsum of the foot. 'Foot-drop' follows, dorsal flexion of the toes and abduction of the foot being impossible. Later on, talipes of the

CC-0. In Public Domain. Gurukul Kangri Collection, Haridwar

Digitized by Arya Samaj Foundation Chennai and eGangotri

equinovarus type results, due to the contracture of the unopposed posterior crural group of muscles.

The sciatic nerve has been frequently cut down upon and stretched, or has been acupunctured, for the relief of sciatica. In order to define it on the surface, a point is taken at the junction of the middle with the lower third of a line stretching from the posterior superior spine of the ilium to the lateral part of the ischial tuberosity, and a line drawn from this to the middle of the upper part of the popliteal fossa. The line must be slightly curved with its convexity outwards, and, as it passes downwards to the lower border of the gluteus maximus, is slightly nearer to the ischial tuberosity than to the greater trochanter, and crosses a line drawn between these two points. The operation of stretching the sciatic nerve is performed by making an incision over the course of the nerve beneath the fold of the buttock (fig. 930, A). The skin, superficial structures, and deep fascia having been divided, the hamstrings are defined, and pulled apart with retractors. The nerve will be found lying on the Adductor magnus and covered by the Biceps femoris. It is to be separated from the surrounding structures, hooked up with the finger, and stretched by steady and continuous traction for two or three minutes. The sciatic nerve may also be stretched by what is known as the 'dry' plan. The patient is laid on his back, the foot is extended, the leg flexed on the thigh, and the thigh strongly flexed on the abdomen. While the thigh is maintained in this position. the leg is forcibly extended to its full extent, and the foot as fully flexed on the leg.

The position of the common peronæal nerve, close behind the tendon of the Biceps femoris, on the lateral side of the popliteal fossa (fig. 930, D), should be remembered in cutaneous division of the tendon. After the tendon is divided, the common peronæal nerve rises up as a cord, and might be mistaken for a small undivided portion of the tendon. Here this nerve winds round the neck of the fibula, it is also liable to be severed accidentally if its exact situation is not kept in mind, and especial care must be used when dealing with sinuses leading down to carious bone in this situation. Section of the nerve results in complete 'foot-drop' from paralysis of the anterior tibial group of muscles and inversion of the foot from the unopposed action of the Tibialis posterior, the Peronæi being paralysed, together with anæsthesia of the parts supplied by the nerve, and, owing to loss of nutrition, the limb frequently becomes blue and cold, and may develop 'trophic' sores.

THE AUTONOMIC NERVOUS SYSTEM

The autonomic nervous system (fig. 931) innervates the viscera, glands, blood-vessels, and unstriped muscle in general. Like the cerebrospinal system it has a central and a peripheral part. The central part is incorporated in the cerebrospinal axis and is represented by groups of nerve-cells, found chiefly in the mid-brain and hind-brain, and in the thoracic, lumbar, and sacral portions of the medulla spinalis. From these nerve-cells fibres pass out in certain of the cerebral and spinal nerves to form the peripheral part of the system. As already indicated (p. 779), none of these fibres reaches the zone of distribution of the autonomic system; all end round the cells of ganglia detached from the central nervous system, and from the cells of these ganglia the fibres of distribution are derived. The autonomic nerves, therefore, are composed of preganglionic and postganglionic fibres (p. 779).

The autonomic system is divisible into two secondary systems, (*a*) parasympathetic, and (*b*) sympathetic.

The **parasympathetic system** is found at the cranial and sacral ends of the autonomic system. The *cranial* parasympathetic fibres issue from the oculomotor, facial, glossopharyngeal, vagus, and accessory cerebral nerves. Those from the oculomotor and facial nerves, and some from the glossopharyngeal, run to the ciliary, sphenopalatine, otic and submaxillary ganglia, and have been described with the trigeminal nerve (pp. 892 to 903). The fibres of the glossopharyngeal, vagus and accessory nerves are largely parasympathetic; their distribution is described on pp. 915 to 922; the ganglia with which they are associated lie mainly at the periphery, i.e. in the walls of the structures they innervate. The *sacral* parasympathetic fibres emerge in the second, third and fourth sacral nerves and constitute the *pelvic splanchnic nerves* of Gaskell. They end in ganglia in the pelvic plexuses, and from the cells of these ganglia postganglionic fibres are distributed to the viscera of the pelvis.

The **sympathetic system** forms the remaining and greater part of the autonomic system. It is associated with the thoracic and lumbar parts of the medulla spinalis, and its efferent fibres emerge in the thoracic, and the first

CC-0. In Public Domain. Gurukul Kangri Collection, Haridwar

Digitized by Arya Samaj Foundation Chennai and eGangotri

FIG. 931.—A diagram of the autonomic nervous system. (After Meyer and Gottlieb.) The parasympathetic fibres are represented by *blue*, and the sympathetic fibres by *red*, lines; the interrupted red lines indicate post-ganglionic fibres to the cerebral and spinal nerves.

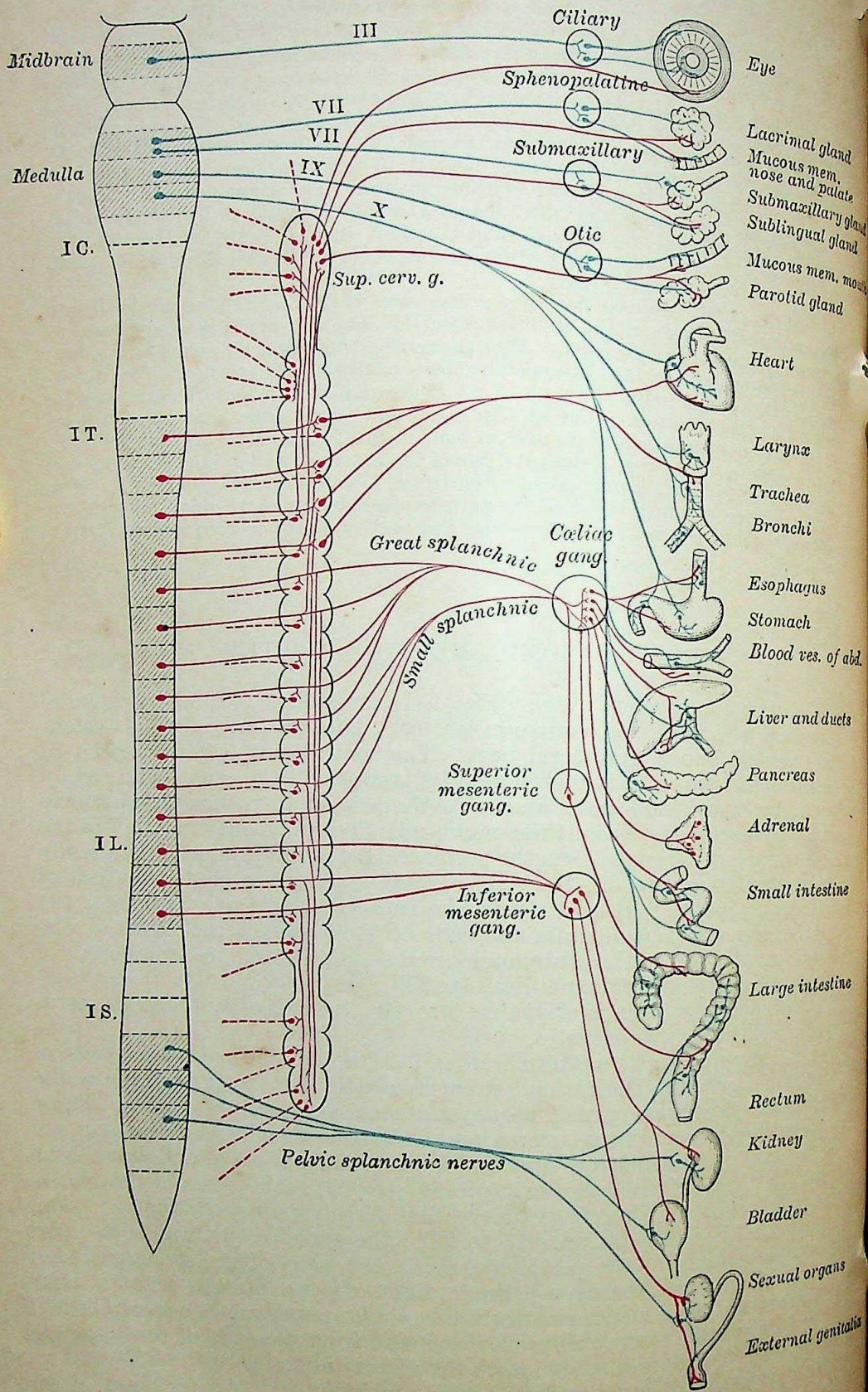

CC-0. In Public Domain. Gurukul Kangri Collection, Haridwar

Digitized by Arya Samaj Foundation Chennai and eGangotri

and second lumbar, nerves; leaving these nerves through the white rami communicantes, they run to join sympathetic ganglia. The sympathetic system, with its associated ganglia forms a complex widespread system, the communications and distribution of which are described in the following pages.

Accompanying the autonomic nerves are afferent fibres, which originate in the cells of the semilunar ganglion of the trigeminal, the genicular ganglion of the facial, the ganglia on the trunks of the glossopharyngeal and vagus nerves, and the ganglia of the spinal nerves. The peripheral branches of these fibres pass without interruption to the involuntary structures; the central branches pass into the brain and medulla spinalis to complete autonomic reflex arcs, or to form synapses with the somatic nerve-cells.

THE SYMPATHETIC NERVOUS SYSTEM

The ganglia associated with the sympathetic system may be divided into central, collateral and terminal groups. The *central* ganglia are arranged in two vertical rows, one on either side of the middle line, and situated partly

FIG. 932.—Sketches showing the central connexions of the somatic fibres (A) and sympathetic fibres (B) of a typical spinal nerve. The efferent fibres are represented by *red*, and the afferent fibres by *blue*, lines.

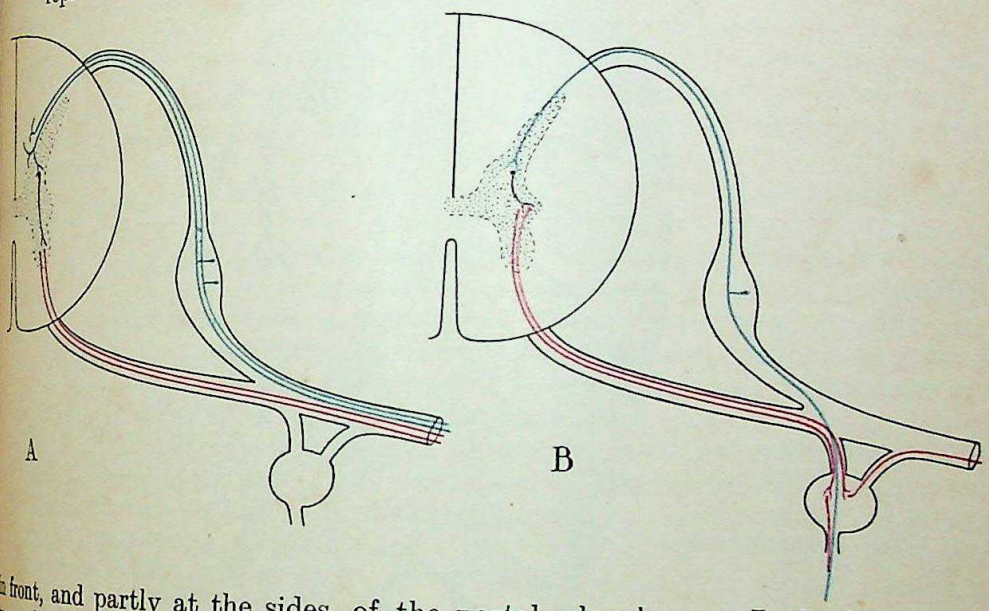

in front, and partly at the sides, of the vertebral column. In both rows the successive ganglia are connected to one another by nervous cords, so that two chains or trunks, named the *sympathetic trunks*, are formed. The *collateral* ganglia are found in connexion with three great *prevertebral plexuses* situated within the thorax, abdomen and pelvis, and named the cardiac, cœliac, and hypogastric plexuses. The *terminal* ganglia are located in the walls of the viscera.

The efferent fibres of the sympathetic nerves are the axons of nerve-cells in the lateral grey column of the medulla spinalis (fig. 932). These fibres, medullated, and mostly of small size, issue from the medulla spinalis through the anterior nerve-roots of the thoracic and first and second lumbar nerves. They leave these nerves as the white rami communicantes (p. 927), each of which joins a neighbouring ganglion of the sympathetic trunk. Some of the fibres end in the ganglion which they first enter; others pass through that ganglion and end in a collateral or a terminal ganglion; others run in the sympathetic trunk and end in higher or lower ganglia in the trunk, while others, after ascending or descending for varying distances, leave the trunk and end around the cells of collateral or terminal ganglia.

Fibres, mostly non-medullated, arise from the cells of the sympathetic ganglia. Some of these fibres go direct, or through the prevertebral plexuses,

CC-0. In Public Domain. Gurukul Kangri Collection, Haridwar

Digitized by Arya Samaj Foundation Chennai and eGangotri

to their distribution in the viscera; others leave the sympathetic trunks in the grey rami communicantes (p. 927) and join the spinal nerves, through

FIG. 933.—The right sympathetic trunk and its connexions with the thoracic, abdominal, and pelvic plexuses. (After Schwalbe.)

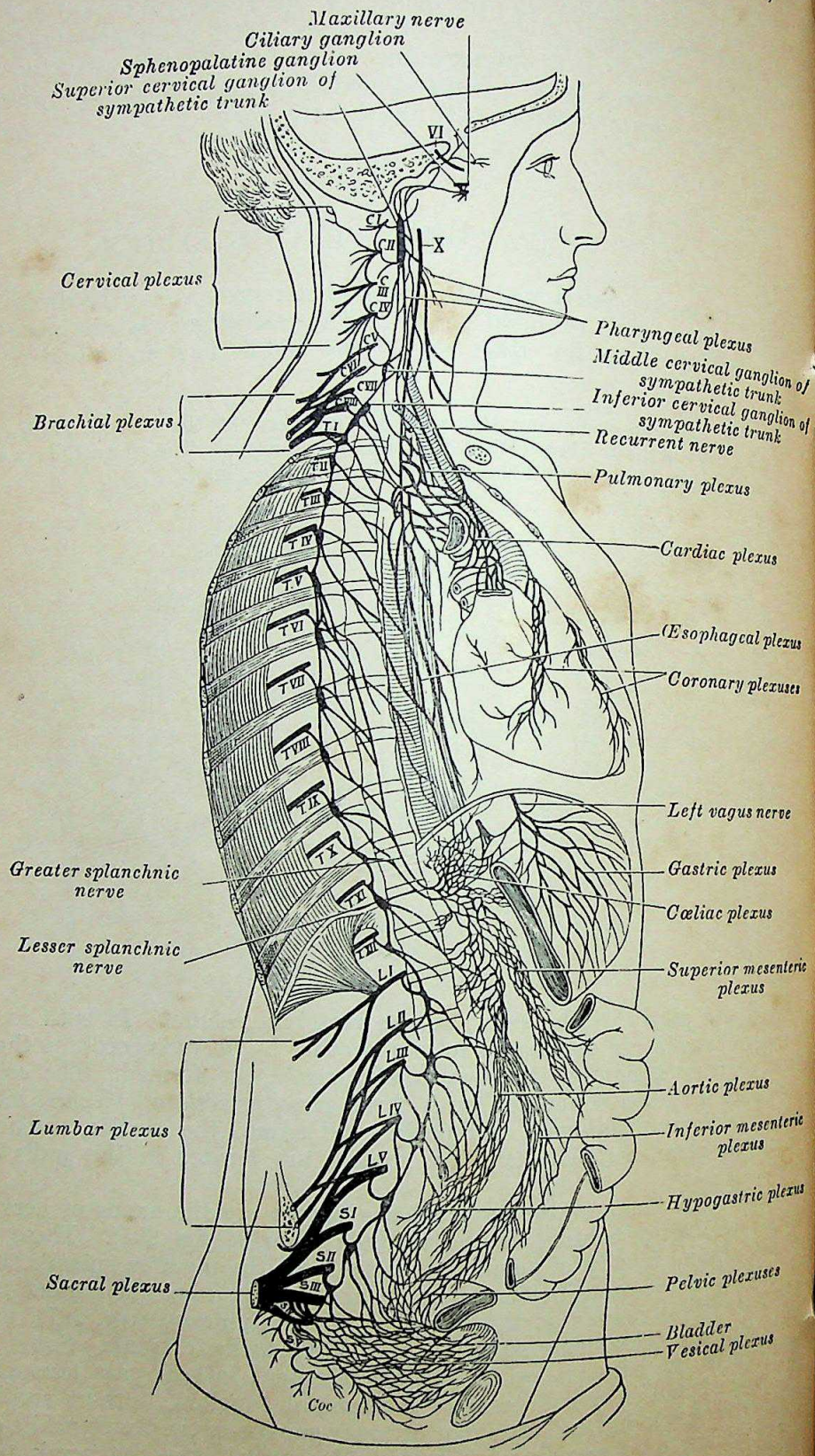

which they are conveyed to the blood-vessels, sudoriferous glands and Arrectores pilorum muscles.

CC-0. In Public Domain. Gurukul Kangri Collection, Haridwar

Digitized by Arya Samaj Foundation Chennai and eGangotri

The **sympathetic trunks** (fig. 933) extend from the base of the skull to the coccyx. Each trunk is continued upwards, under the name of the internal carotid nerve, through the carotid canal into the skull. Here it forms the carotid and cavernous plexuses which constitute the *cephalic part* of the sympathetic system. The lower ends of the sympathetic trunks converge and unite in a single ganglion, the *ganglion impar*, which is placed in front of the coccyx. The ganglia of each trunk are distinguished as cervical, thoracic, lumbar, and sacral, and, except in the neck, their number corresponds more or less closely to that of the spinal nerves. They are arranged thus :

Cervical portion	. . .	3 ganglia
Thoracic ,,	. . .	12 ,,
Abdominal ,,	. . .	4 ,,
Pelvic ,,	. .	4 or 5 ,,

In the neck the ganglia lie in front of the transverse processes of the vertebræ; in the thoracic region in front of the heads of the ribs; in the abdomen on the sides of the vertebral bodies; and in the pelvis in front of the sacrum.

The Cephalic Portion of the Sympathetic System

The **cephalic portion** of the sympathetic system on each side begins as the **internal carotid nerve**, which is continued upwards from the superior cervical ganglion of the sympathetic trunk. This nerve is soft in texture, and of a reddish colour. It ascends by the side of the internal carotid artery, and, entering the carotid canal in the temporal bone, divides into two branches, one of which lies on the lateral and the other on the medial side of the artery.

The *lateral branch*, the larger of the two, gives filaments to the internal carotid artery, and forms the *internal carotid plexus*.

The *medial branch* also supplies filaments to the internal carotid artery, and, continuing onwards, forms the *cavernous plexus*.

The **internal carotid plexus** is situated on the lateral side of the internal carotid artery, and in the plexus there occasionally exists a small gangliform swelling, the *carotid ganglion*, on the under surface of the artery. The plexus communicates with the semilunar and sphenopalatine ganglia, and with the abducent nerve and the tympanic branch of the glossopharyngeal nerve; it distributes filaments to the wall of the carotid artery.

The branches communicating with the abducent nerve consist of one or two filaments which join that nerve as it lies upon the lateral side of the internal carotid artery. The communication with the sphenopalatine ganglion is effected by a branch named the *deep petrosal*; this branch perforates the cartilage filling the foramen lacerum, and joins the greater superficial petrosal nerve to form the nerve of the pterygoid canal (Vidian nerve), which passes through the pterygoid canal to the sphenopalatine ganglion. The communication with the tympanic branch of the glossopharyngeal nerve is effected by the *superior* and *inferior caroticotympanic nerves* which traverse the wall of the carotid canal.

The **cavernous plexus**, formed chiefly by the medial division of the internal carotid nerve, is situated below and on the medial side of that part of the internal carotid artery which is placed by the side of the sella turcica, in the cavernous sinus. It gives branches to the internal carotid artery, and communicates with the oculomotor, trochlear, ophthalmic, and abducent nerves, and with the ciliary ganglion.

The branch to the oculomotor nerve joins that nerve at its point of division; the branch to the trochlear nerve joins the latter as it lies in the lateral wall of the cavernous sinus; filaments are connected with the medial side of the ophthalmic nerve; and one joins the abducent nerve. The filament to the ciliary ganglion arises from the anterior part of the cavernous plexus and enters the orbit through the superior orbital fissure; it may join the ganglion directly, or may unite with the long root of the ganglion.

The terminal filaments from the internal carotid and cavernous plexuses are prolonged as plexuses around the anterior and middle cerebral arteries

CC-0. In Public Domain. Gurukul Kangri Collection, Haridwar

Digitized by Arya Samaj Foundation Chennai and eGangotri

and the ophthalmic artery: along the anterior and middle cerebral arteries they may be traced to the pia mater; along the ophthalmic artery they pass into the orbit where they accompany each of the branches of that vessel. The filaments prolonged on the anterior communicating artery connect the sympathetic nerves of the right and left sides.

The Cervical Portion of the Sympathetic System

The **cervical portion** of each sympathetic trunk consists of three ganglia distinguished, according to their positions, as the superior, middle, and inferior, and connected by intervening cords. This portion receives no white rami communicantes from the cervical spinal nerves; its spinal fibres are derived from the white rami communicantes of the upper thoracic nerves, and enter the corresponding thoracic ganglia of the sympathetic trunk, through which they ascend into the cervical ganglia.

The **superior cervical ganglion**, the largest of the three, is placed opposite the second and third cervical vertebræ. It is of a reddish-grey colour and usually fusiform in shape, sometimes broad and flattened, and occasionally constricted at intervals; it is believed to be formed by the coalescence of four ganglia, corresponding with the upper four cervical nerves. It is in relation, in front, with the sheath of the internal carotid artery and internal jugular vein; behind, with the Longus capitis muscle. The internal carotid nerve (p. 973) ascends from the upper end of the ganglion into the cranial cavity; the lower end of the ganglion is united by the connecting trunk with the middle cervical ganglion.

Its branches may be divided into lateral, medial, and anterior.

The **lateral branches** of the superior cervical ganglion consist of grey rami communicantes to the upper four cervical nerves and to certain of the cerebral nerves. Sometimes the branch to the fourth cervical nerve comes from the trunk connecting the superior and middle cervical ganglia. Delicate filaments run to the ganglion nodosum of the vagus, and to the hypoglossal nerve; and a branch, named the *jugular nerve*, ascends to the base of the skull, and divides into two twigs, one of which joins the petrous ganglion of the glossopharyngeal, and the other the jugular ganglion of the vagus.

The **medial branches** of the superior cervical ganglion are the laryngopharyngeal branches and the superior cardiac nerve.

The *laryngopharyngeal branches* pass to the side of the pharynx, where they join with branches from the glossopharyngeal and vagus nerves to form the *pharyngeal plexus*. From this plexus branches pass to the muscles and mucous membrane of the pharynx, and communicate with the superior laryngeal nerve.

The *superior cardiac nerve* arises by two or more branches from the superior cervical ganglion, and occasionally receives a filament from the trunk connecting the superior with the middle cervical ganglion. It runs down the neck behind the common carotid artery, and in front of the Longus colli muscle; and crosses in front of the inferior thyreoid artery, and recurrent nerve. The course of the nerve of the right side then differs from that of the left. The *right nerve*, at the root of the neck, passes either in front of or behind the subclavian artery, and along the innominate artery to the back of the arch of the aorta, where it joins the deep part of the cardiac plexus. It is connected with other branches of the sympathetic; about the middle of the neck it receives filaments from the external laryngeal nerve; lower down, one or two twigs (upper cervical branches) from the vagus nerve join it; and as it enters the thorax it is joined by a filament from the recurrent nerve. Filaments from the nerve communicate with the thyreoid branches from the middle cervical ganglion. The *left nerve*, in the thorax, runs in front of the left common carotid artery and across the left side of the arch of the aorta, to the superficial part of the cardiac plexus. Sometimes it descends on the right side of the aorta and ends in the deep part of the cardiac plexus.

The **anterior branches** of the superior cervical ganglion ramify upon the common carotid artery, and upon the external carotid artery and its branches, forming around each a delicate plexus in which small ganglia are occasionally found. The plexus surrounding the external maxillary artery supplies a

CC-0. In Public Domain. Gurukul Kangri Collection, Haridwar

Digitized by Arya Samaj Foundation Chennai and eGangotri

filament to the submaxillary ganglion, and the plexus on the middle meningeal artery sends one offset to the otic ganglion, and another, the *external petrosal nerve*, to the genicular ganglion.

The **middle cervical ganglion**, the smallest of the three cervical ganglia, is occasionally wanting. It is placed opposite the sixth cervical vertebra, usually in front of, or close to, the inferior thyreoid artery. It is probably formed by the coalescence of two ganglia corresponding with the fifth and sixth cervical nerves.

The ganglion sends grey rami communicantes to the fifth and sixth cervical nerves, and gives off thyreoid branches, and the middle cardiac nerve. It is connected to the inferior cervical ganglion by two or more cords, one of which forms a loop around the subclavian artery, and supplies offsets to it. This loop is named the *ansa subclavia* (*Vieussenii*).

The *thyreoid branches* run along the inferior thyreoid artery to the thyreoid gland; they communicate with the superior cardiac, external laryngeal and recurrent nerves.

The *middle cardiac nerve*, the largest of the three cardiac nerves, arises from the middle cervical ganglion, or from the trunk connecting the middle with the inferior cervical ganglion. On the *right side* it descends behind the common carotid artery, and at the root of the neck runs either in front of or behind the subclavian artery; it then descends on the trachea, receives a few filaments from the recurrent nerve, and joins the right half of the deep part of the cardiac plexus. In the neck, it communicates with the superior cardiac and recurrent nerves. On the *left side*, the middle cardiac nerve enters the thorax between the left carotid and subclavian arteries, and joins the left half of the deep part of the cardiac plexus.

The **inferior cervical ganglion** is situated between the base of the transverse process of the last cervical vertebra and the neck of the first rib, on the medial side of the costocervical trunk. Its form is irregular; it is larger than the middle cervical ganglion, and is frequently fused with the first thoracic ganglion. It is probably formed by the coalescence of two ganglia corresponding with the seventh and eighth cervical nerves.

The ganglion sends grey rami communicantes to the seventh and eighth cervical nerves, gives off the inferior cardiac nerve, and supplies branches to blood-vessels.

The *inferior cardiac nerve* arises from either the inferior cervical or the first thoracic ganglion. It descends behind the subclavian artery and along the front of the trachea, to join the deep part of the cardiac plexus. Behind the subclavian artery it communicates with the recurrent nerve and the middle cardiac nerve.

The *offsets to blood-vessels* form plexuses on the subclavian artery and its branches. The plexus on the vertebral artery is continued on the basilar, posterior cerebral, and cerebellar arteries. The plexus on the inferior thyreoid artery accompanies the artery to the thyreoid gland, and communicates with the recurrent and external laryngeal nerves, with the superior cardiac nerve, and with the plexus on the common carotid artery.

The Thoracic Portion of the Sympathetic System (fig. 934)

The **thoracic portion** of the sympathetic trunk consists on either side of a series of ganglia, which usually correspond in number to that of the thoracic spinal nerves; but, on account of the occasional coalescence of two ganglia, their number is variable. The thoracic ganglia, with the exception of the last two, rest against the heads of the ribs, and are covered by the costal pleura; the last two are placed on the sides of the bodies of the eleventh and twelfth thoracic vertebræ. The ganglia are small, and of a greyish colour, and are connected together by the intervening portions of the trunk. The first is larger than the others, and of an elongated form; it is frequently blended with the inferior cervical ganglion.

Two rami communicantes, a white and a grey, connect each ganglion with its corresponding spinal nerve.

The *branches from the upper five ganglia* are very small; they supply filaments to the thoracic aorta and its branches. On the aorta they form, together

CC-0. In Public Domain. Gurukul Kangri Collection, Haridwar

Digitized by Arya Samaj Foundation Chennai and eGangotri

with filaments from the greater splanchnic nerve, a delicate plexus (*plexus aorticus thoracalis*). Twigs from the second, third, and fourth ganglia enter the posterior pulmonary plexus.

The *branches from the lower seven ganglia* are large, and white in colour; they distribute filaments to the aorta, and unite to form the greater, the lesser, and the lowest splanchnic nerves.

Fig. 934.—The thoracic portion of the left sympathetic trunk.

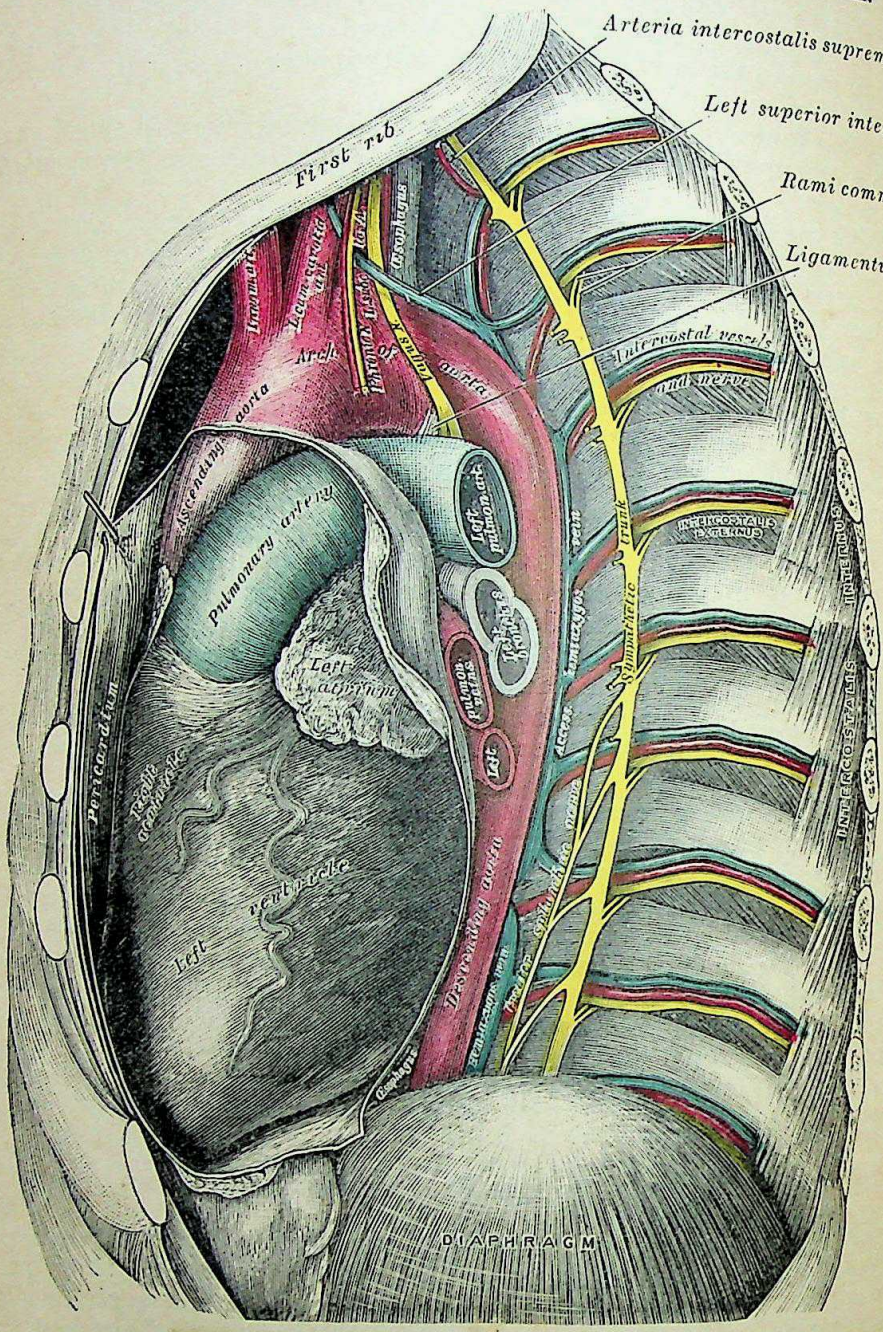

The *greater splanchnic nerve* is of a considerable size, and consists mainly of medullated fibres; it is formed by branches from the fifth to the ninth or tenth thoracic ganglia, but the fibres in the higher branches may be traced upwards in the sympathetic trunk as far as the first or second thoracic ganglion. It descends obliquely on the bodies of the vertebræ, perforates the crus of the Diaphragm, and ends in the cœliac ganglion. A ganglion (*ganglion splanchnicum*) exists on this nerve opposite the eleventh or twelfth thoracic vertebra.

The *lesser splanchnic nerve* is formed by filaments from the ninth and tenth, sometimes the tenth and eleventh, thoracic ganglia, and from the trunk between

CC-0. In Public Domain. Gurukul Kangri Collection, Haridwar

Digitized by Arya Samaj Foundation Chennai and eGangotri

the ganglia. It pierces the Diaphragm with the preceding nerve, and joins the aorticorenal ganglion.

The *lowest splanchnic nerve* arises from the last thoracic ganglion. It pierces the Diaphragm with the sympathetic trunk, and ends in the renal plexus.

A striking analogy exists between the splanchnic and the cardiac nerves. The cardiac nerves, three in number, arise from the cervical ganglia, and are distributed to a large and important organ in the thoracic cavity. The splanchnic nerves, also three in number, arise from the thoracic ganglia, and are distributed to organs in the abdominal cavity.

The Abdominal Portion of the Sympathetic System (fig. 935).

The **abdominal portion** of each sympathetic trunk is situated in front of the vertebral column, along the medial margin of the Psoas major. It consists usually

Fig. 935.—The abdominal portion of the sympathetic trunks, with the cœliac and aortic plexuses. (After Henle.)

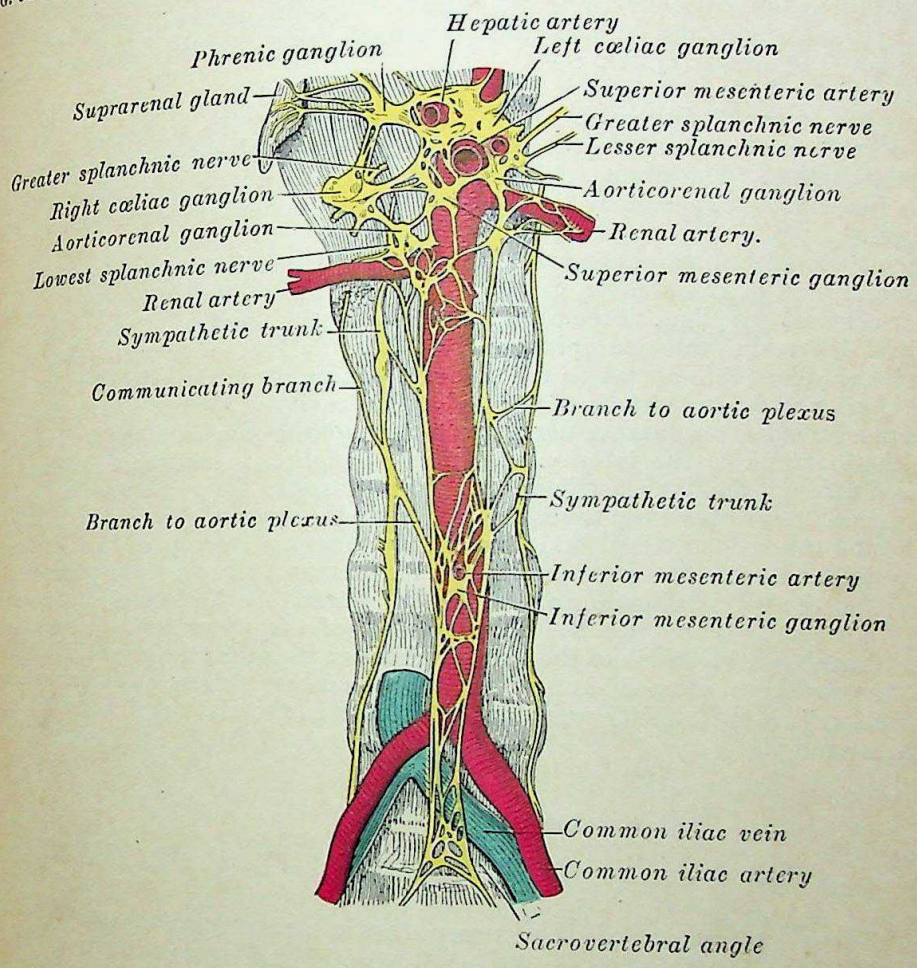

of four lumbar ganglia, connected together by the intervening portions of the trunk. It is continuous above with the thoracic portion, beneath the medial lumbocostal arch; below with the pelvic portion, behind the common iliac artery.

Grey rami communicantes pass from all the ganglia to the lumbar spinal nerves. The first and second, and sometimes the third, lumbar nerves send white rami communicantes to the corresponding ganglia. The rami communicantes are of considerable length, and accompany the lumbar arteries around the sides of the bodies of the vertebræ, beneath the fibrous arches which give origin to some of the fibres of the Psoas major.

Of the *branches of distribution*, some pass in front of the aorta, and join the abdominal aortic plexus; others descend in front of the common iliac arteries, and assist in forming the hypogastric plexus.

CC-0. In Public Domain. Gurukul Kangri Collection, Haridwar

Digitized by Arya Samaj Foundation Chennai and eGangotri

The Pelvic Portion of the Sympathetic System (fig. 933)

The **pelvic portion** of each sympathetic trunk is situated in front of the sacrum, medial to the anterior sacral foramina. It consists of four or five small sacral ganglia, connected by the intervening portions of the trunk. It is continuous above with the abdominal portion, while below, the two pelvic sympathetic trunks converge, and unite on the front of the coccyx in a small ganglion, the *ganglion impar* or *coccygeal ganglion*.

Grey rami communicantes pass from the ganglia to the sacral and coccygeal nerves. No white rami communicantes pass to this part of the sympathetic trunk, but the visceral branches (*pelvic splanchnic nerves of Gaskell*) which arise from the second, third and fourth sacral nerves (p. 969), and run through the pelvic plexuses of the sympathetic, are regarded as white rami communicantes.

The *branches of distribution* communicate on the front of the sacrum with the corresponding branches from the opposite side; twigs from the first two ganglia join the pelvic plexuses, and others form a plexus on the middle sacral artery. Filaments are distributed to the glomus coccygeum (coccygeal body) from the loop uniting the two trunks.

The following facts concerning the course of the sympathetic nerve-fibres have been arrived at by experiments on lower animals, chiefly dogs, but they probably hold good for the human sympathetic system :—

The preganglionic sympathetic fibres for the head and neck leave the medulla spinalis through the upper five thoracic nerves (chiefly through the second and third nerves). They ascend in the cervical part of the sympathetic trunk and end in the superior cervical ganglion. The fibres arising from the cells of this ganglion are vasoconstrictor for the blood-vessels, secretory for the salivary and sudoriferous glands, and dilator for the pupil.

The accelerator fibres of the heart leave mainly through the second and third thoracic nerves and pass to the *stellate* ganglion.* From the cells of this ganglion and of the inferior cervical ganglion, fibres are distributed to the heart.

Fibres leave the thoracic spinal nerves (mainly the lower six) and are conveyed through the splanchnic nerves to the cœliac ganglion, from the cells of which fibres pass to the blood-vessels and viscera of the abdominal cavity. Fibres from the lower thoracic and upper three or four lumbar nerves pass through the ganglia of the lumbar part of the sympathetic trunk to the inferior mesenteric ganglion; from this ganglion fibres are conveyed through the hypogastric and pelvic plexuses to the pelvic viscera.

No spinal fibres pass from the sacral nerves to the sympathetic trunks, but the visceral branches of the second, third and fourth sacral nerves correspond to white rami communicantes and enter the pelvic sympathetic plexuses. From these plexuses fibres are conveyed to the pelvic viscera, and vasodilator fibres (nervi erigentes) to the penis.

The constrictor fibres for the blood-vessels of the upper limbs leave the thoracic nerves from about the fourth to the tenth inclusive; those for the lower limbs through the lower two or three thoracic and upper three lumbar nerves; the former have their "cell-station" in the stellate ganglion, the latter in the sixth and seventh lumbar and first sacral ganglia.

THE GREAT PLEXUSES OF THE SYMPATHETIC

The great plexuses of the sympathetic are aggregations of nerves and ganglia, situated in the thoracic, abdominal, and pelvic cavities, and named the cardiac, cœliac, and hypogastric plexuses. They consist not only of sympathetic fibres derived from the ganglia, but of fibres from the medulla spinalis, which are conveyed through the white rami communicantes. From the plexuses branches are given to the thoracic, abdominal, and pelvic viscera.

The Cardiac Plexus (fig. 933)

The **cardiac plexus** is situated at the base of the heart, and is divided into a *superficial* and a *deep part*, which are, however, closely connected.

The **superficial part of the cardiac plexus** lies beneath the arch of the aorta, in front of the right pulmonary artery. It is formed by the superior

* In the dog the upper four thoracic ganglia of the sympathetic trunk are fused into one mass which is named the *stellate* ganglion.

CC-0. In Public Domain. Gurukul Kangri Collection, Haridwar

Digitized by Arya Samaj Foundation Chennai and eGangotri

cardiac branch of the left sympathetic trunk and the lower of the superior cardiac branches of the left vagus. A small ganglion, the *cardiac ganglion of Wrisberg*, is usually found in this plexus, and is situated immediately beneath the arch of the aorta, on the right side of the ligamentum arteriosum. The superficial part of the cardiac plexus gives branches (*a*) to the deep part of the plexus; (*b*) to the anterior coronary plexus; and (*c*) to the left anterior pulmonary plexus.

The **deep part of the cardiac plexus** is situated in front of the bifurcation of the trachea, above the point of division of the pulmonary artery, and behind the aortic arch. It is formed by the cardiac nerves derived from the cervical ganglia of the sympathetic trunk, and the cardiac branches of the vagus and recurrent nerves. The only cardiac nerves which do not join the deep part of the cardiac plexus are the superior cardiac nerve of the left sympathetic trunk, and the lower of the superior cardiac branches from the left vagus nerve, which pass to the superficial part of the plexus.

The branches from the *right half* of the deep part of the cardiac plexus pass, some in front of, and others behind, the right pulmonary artery; the former, the more numerous, transmit a few filaments to the anterior pulmonary plexus, and are then continued onwards to form part of the anterior coronary plexus; those behind the pulmonary artery distribute a few filaments to the right atrium, and are then continued onwards to form part of the posterior coronary plexus.

The *left half* of the deep part of the cardiac plexus is connected with the superficial part of the plexus, and gives filaments to the left atrium, and to the anterior pulmonary plexus, and is then continued to form the greater part of the posterior coronary plexus.

The **posterior coronary plexus** is larger than the anterior, and accompanies the left coronary artery; it is formed chiefly by filaments prolonged from the left half of the deep part of the cardiac plexus, and by a few from the right half. It gives branches to the left atrium and ventricle.

The **anterior coronary plexus** is formed partly from the superficial and partly from the deep parts of the cardiac plexus. It accompanies the right coronary artery, and gives branches to the right atrium and ventricle.

The upper cardiac nerves are distributed to the ascending aorta, the pulmonary artery and the ventricles; the lower cardiac nerves, to the atria.

The Cœliac Plexus (figs. 933, 935, 936)

The **cœliac or solar plexus**, the largest of the three great sympathetic plexuses, is situated at the level of the upper part of the first lumbar vertebra, and is composed of a pair of large ganglia, the cœliac ganglia, and a dense network of nerve-fibres uniting them together. It surrounds the cœliac artery and the root of the superior mesenteric artery. It lies behind the stomach and the omental bursa, in front of the crura of the Diaphragm and the commencement of the abdominal aorta, and between the suprarenal glands. The plexus and the ganglia receive the greater and lesser splanchnic nerves of both sides and some filaments from the right vagus, and give off numerous secondary plexuses along the neighbouring arteries.

The *cœliac or semilunar ganglia* are two large irregularly-shaped masses having the appearance of lymph-glands, and placed, one on either side of the middle line, in front of the crura of the Diaphragm close to the suprarenal glands, that on the right side being placed behind the inferior vena cava. The upper part of each ganglion is joined by the greater splanchnic nerve, while the lower part, which is more or less detached, and named the *aorticorenal* ganglion, receives the lesser splanchnic nerve and gives off the greater part of the renal plexus.

The secondary plexuses springing from or connected with the cœliac plexus are the following:

Phrenic.	Renal.
Hepatic.	Spermatic.
Lienal.	Superior mesenteric.
Superior gastric.	Abdominal aortic.
Suprarenal.	Inferior mesenteric.

CC-0. In Public Domain. Gurukul Kangri Collection, Haridwar

Digitized by Arya Samaj Foundation Chennai and eGangotri

The **phrenic plexus** accompanies the inferior phrenic artery to the Diaphragm, some filaments passing to the suprarenal gland. It arises from the upper part of the cœliac ganglion, and is larger on the right than on the left side. It receives one or two branches from the phrenic nerve. At the point of junction of the right phrenic plexus with the phrenic nerve is a small ganglion (*ganglion phrenicum*). This plexus distributes some branches to the inferior vena cava, and to the suprarenal and hepatic plexuses.

FIG. 936.—The cœliac ganglia with the sympathetic plexuses of the abdominal viscera radiating from the ganglia. (From Toldt's 'Atlas,' published by Messrs. Rebman, Ltd., London.)

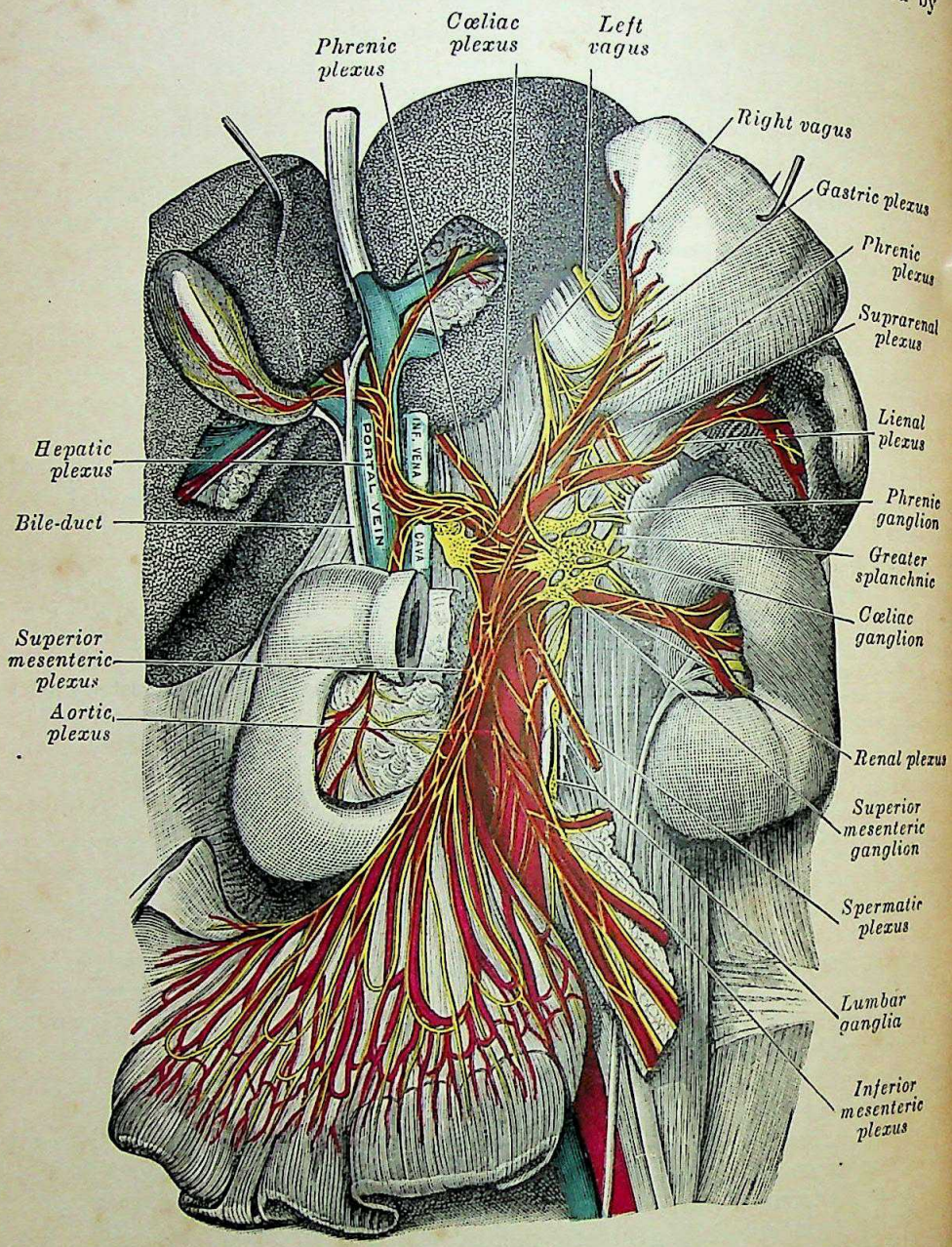

The **hepatic plexus**, the largest offset from the cœliac plexus, receives filaments from the left vagus and right phrenic nerves. It accompanies the hepatic artery, ramifying upon its branches, and upon those of the portal vein, in the substance of the liver. Branches from this plexus accompany all the branches of the hepatic artery. A considerable plexus accompanies the gastro-duodenal artery and is continued as the *inferior gastric plexus* on the right gastro-epiploic artery along the greater curvature of the stomach, where it unites with offshoots from the lienal plexus.

The **lienal or splenic plexus** is formed by branches from the cœliac

CC-0. In Public Domain. Gurukul Kangri Collection, Haridwar

Digitized by Arya Samaj Foundation Chennai and eGangotri

lexus, left cœliac ganglion, and right vagus nerve. It accompanies the lienal rtery to the spleen, giving off, in its course, subsidiary plexuses along the arious branches of the artery.

The **superior gastric plexus** accompanies the left gastric artery along the esser curvature of the stomach, and joins with branches from the left vagus.

The **suprarenal plexus** is formed by branches from the cœliac plexus, rom the cœliac ganglion, and from the phrenic and greater splanchnic nerves, a ganglion being formed at the point of junction with the latter nerve. The lexus supplies the suprarenal gland, and is distributed chiefly to its medullary ortion; its branches are remarkable for their large size in comparison with hat of the organ they supply.

The **renal plexus** is formed by filaments from the cœliac plexus, the orticorenal ganglion, and the aortic plexus. It is joined also by the smallest planchnic nerve. The nerves from these sources, fifteen or twenty in number, ave a few ganglia developed upon them. They accompany the branches of he renal artery into the kidney; some filaments are distributed to the spermatic lexus and to the ureter, and, on the right side, to the inferior vena cava.

The **spermatic plexus** is derived from the renal plexus, receiving branches rom the aortic plexus. It accompanies the testicular artery to the testis. the female, the **ovarian plexus** arises from the renal plexus, and, accomanying the ovarian artery, is distributed to the ovary, and the fundus of he uterus.

Applied Anatomy.—The intimate connexion which exists between the renal and permatic plexuses serves to explain the very frequent symptom, in renal calculus, of ain which is referred to the testis.

The **superior mesenteric plexus** is a continuation of the lower part of he cœliac plexus, and receives a branch from the junction of the right vagus erve with the latter plexus. It surrounds the superior mesenteric artery, ccompanies it into the mesentery, and divides into a number of secondary lexuses which are distributed to the parts supplied by the artery, viz. pancreatic ranches to the pancreas; jejunal and ileal branches, to the small intestine; leocolic, right colic, and middle colic branches, which supply the correponding parts of the great intestine. The nerves composing this plexus are hite in colour and firm in texture; in the upper part of the plexus close to he origin of the superior mesenteric artery is the *superior mesenteric ganglion*.

The **abdominal aortic plexus** is formed by branches derived, on either ide, from the cœliac plexus and ganglia, and receives filaments from some f the lumbar ganglia. It is situated upon the sides and front of the aorta, etween the origins of the superior and inferior mesenteric arteries. From this lexus arise parts of the spermatic, the inferior mesenteric, and the hypogastric lexuses; it also distributes filaments to the inferior vena cava.

The **inferior mesenteric plexus** is derived chiefly from the aortic plexus. t surrounds the inferior mesenteric artery, and just below the origin of this essel the *inferior mesenteric ganglion* is situated. The plexus divides into a umber of secondary plexuses, which are distributed to all the parts supplied y the artery; thus the left colic and sigmoid plexuses supply the descending nd sigmoid parts of the colon; and the superior hæmorrhoidal plexus supplies he rectum and joins in the pelvis with branches from the pelvic plexuses.

The Hypogastric Plexus (fig. 933)

The **hypogastric plexus** is situated in front of the last lumbar vertebra nd the promontory of the sacrum, between the two common iliac arteries. t is formed by the union of numerous filaments, which descend on either ide from the aortic plexus, and from the lumbar ganglia. It divides, below, nto two lateral portions which are named the *pelvic plexuses*.

The Pelvic Plexuses (fig. 933)

The **pelvic plexuses** supply the viscera of the pelvic cavity, and are situated at the sides of the rectum in the male, and at the sides of the rectum

CC-0. In Public Domain. Gurukul Kangri Collection, Haridwar

Digitized by Arya Samaj Foundation Chennai and eGangotri

and vagina in the female. They are formed on either side by a continuation of the hypogastric plexus, by the visceral branches from the second, third and fourth sacral nerves, and by a few filaments from the first two ganglia of the sacral part of the sympathetic trunk. At the points of junction of these nerves small ganglia are found. From these plexuses numerous branches are distributed to the viscera of the pelvis. They accompany the branches of the hypogastric artery.

The **middle hæmorrhoidal plexus** arises from the upper part of the pelvic plexus; it supplies the rectum, and joins with branches of the superior hæmorrhoidal plexus.

The **vesical plexus** arises from the fore part of the pelvic plexus. The nerves composing it are numerous, and contain a large proportion of spinal nerve-fibres. They accompany the vesical arteries, and are distributed to the sides and fundus of the bladder. Numerous filaments also pass to the vesiculæ seminales and ductus deferentes; those accompanying the ductus deferentes join, on the spermatic cords, with branches from the spermatic plexuses.

The **prostatic plexus** is continued from the lower part of the pelvic plexus. The nerves composing it are of large size. They are distributed to the prostate, vesiculæ seminales, and the corpora cavernosa of the penis and urethra. The nerves supplying the corpora cavernosa consist of two sets, the lesser and greater cavernous nerves, which arise from the fore part of the prostatic plexus, and, after joining with branches from the pudendal nerve, pass forwards beneath the pubic arch.

The *lesser cavernous nerves* perforate the fibrous covering of the penis, near its root, and are distributed to its erectile tissue.

The *greater cavernous nerve* passes forwards along the dorsum of the penis, joins with the dorsal nerve of the penis, and is distributed to the corpora cavernosa.

The **vaginal plexus** arises from the lower part of the pelvic plexus. It is distributed to the walls of the vagina and to the erectile tissue of the vestibule. The nerves composing this plexus contain, like the vesical, a large proportion of spinal nerve-fibres.

The **uterine plexus** accompanies the uterine artery along the side of the uterus, between the layers of the broad ligament, and communicates with the ovarian plexus. Its fibres are chiefly distributed to the neck, and the lower part of the body, of the uterus. At the side of the neck of the uterus is a collection of small ganglia which together form the *uterine cervical ganglion.*

Applied Anatomy.—Little is known as to the connexion between the numerous microscopical alterations (pigmentation, atrophy, hæmorrhage, fibrosis) that have been described in the sympathetic nervous system, and the functional changes that ensue therefrom. Grosser lesions due to stabs, bullet-wounds, or the pressure of new growths, may cause either irritative or paralytic symptoms. In *paralysis* of the cervical sympathetic on one side, the pupil is small and does not dilate when shaded or on the instillation of cocaine, although it contracts still further when brightly illuminated; it also loses the ciliospinal reflex, failing to dilate when the skin of the neck is pinched. The palpebral fissure narrows from paralysis of the involuntary muscle of the eyelid, and the eyeball sinks backwards into the orbit—enophthalmos—either from paralysis of Müller's orbital muscle in the eyelids, which surrounds the eyeball like a conical cuff and tends to produce exophthalmos when it contracts, or from wasting of the intra-orbital fat. The superficial vessels of the face and scalp are at first dilated, but later they contract. Anidrosis, or absence of sweating, is often noted on the affected side. *Irritation* of the cervical sympathetic produces signs mainly the converse of those described above. We have no definite knowledge of the signs and symptoms that follow lesions of the thoracic or abdominal sympathetic systems. It is likely, however, that a number of nervous disorders characterised by persistent vascular disturbances, such as dilatation of the vessels with throbbing, flushing, sweating, and localised œdema, or contraction of the vessels with pallor, chilliness, pain, and malnutrition of the affected parts, are due to implication of the sympathetic nervous system. It is possible, too, that the rare condition of *progressive facial hemiatrophy*, coming on between the ages of ten and twenty, and producing marked unilateral shrinkage of all the tissues on the affected side of the face, is primarily an affection of the sympathetic.

CC-0. In Public Domain. Gurukul Kangri Collection, Haridwar

Digitized by Arya Samaj Foundation Chennai and eGangotri

THE ORGANS OF THE SENSES AND THE COMMON INTEGUMENT

THE organs of the senses may be divided into (*a*) those of the special senses of taste, smell, sight, and hearing, and (*b*) those associated with the general sensations of heat, cold, pain, pressure, &c.

THE PERIPHERAL ORGANS OF THE SPECIAL SENSES

The Organ of Taste

The peripheral gustatory organs, or organs of taste, consist of certain modified epithelial cells arranged in flask-shaped groups termed *gustatory calyculi* or *taste-buds*, which are found on the tongue and adjacent parts. They occupy nests in the stratified epithelium (fig. 937), and are very numerous on the sides of the papillæ vallatæ and less so on the walls surrounding the papillæ. They are also found on the fungiform papillæ over the posterior part and sides of the tongue, and in the general epithelial covering of the same areas. They are very plentiful over the folia linguæ, just in front of the lingual attachment of the glossopalatine arch. They are also present on the under surface of the soft palate, and on the posterior surface of the epiglottis.

Fig. 937.—A vertical section through a human papilla vallata. Stained with hæmatoxylin and eosin. × 15.

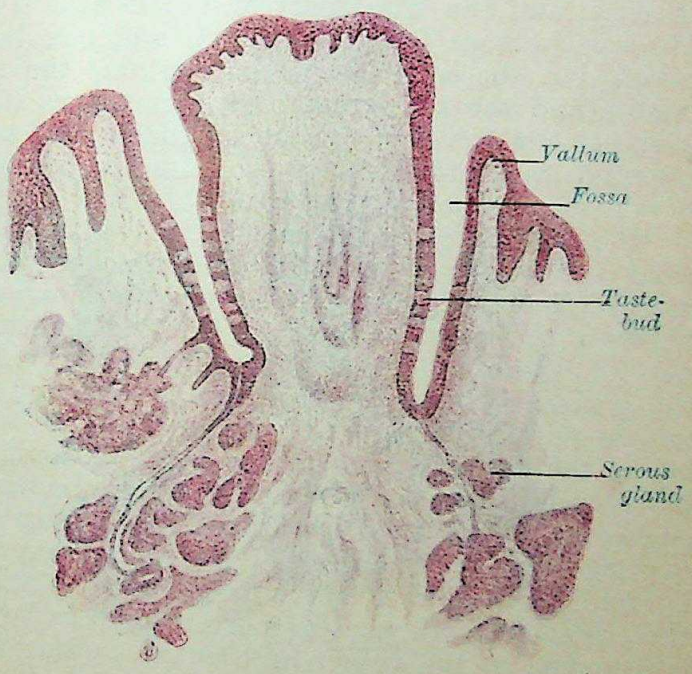

Structure.—Each taste-bud is flask-shaped (fig. 938), the broad base resting on the corium, and its neck opening by an orifice, the *gustatory pore* between the cells of the epithelium. The bud consists of supporting cells and gustatory cells. The *supporting cells* are mostly arranged like the staves of a cask, and form a complete envelope for the bud. Nuclei, however, are found in the interior of the bud between the gustatory cells. The *gustatory cells* occupy the central portion of the bud; they are spindle-shaped, and each possesses a large spherical nucleus near the middle of the cell. The peripheral process of the cell ends at the gustatory pore in a fine hair-like filament, the *gustatory hair*. The central process passes towards the deep extremity of the bud, and there ends in a single or branched extremity. The nerve-fibres, after losing their medullary sheaths, enter the

CC-0. In Public Domain. Gurukul Kangri Collection, Haridwar

Digitized by Arya Samaj Foundation Chennai and eGangotri

taste-bud, and end in fine fibrils between the gustatory cells; other nerve-fibrils end between the epithelial cells which surround the taste-bud, but these are believed to be nerves of ordinary sensation and not gustatory.

FIG. 938.—A section through a taste-bud from the human tongue. Stained with hæmatoxylin and eosin. × 450.

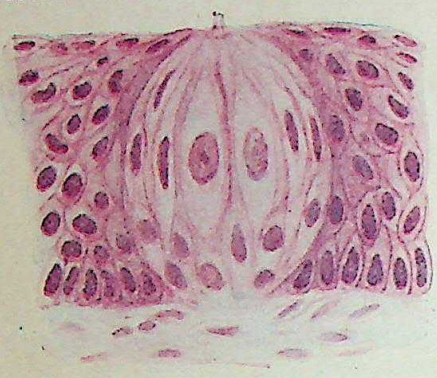

Nerves of taste.—The chorda tympani nerve derived from the sensory root of the facial nerve and distributed with the lingual nerve, is the nerve of taste for the anterior two-thirds of the tongue; the glossopharyngeal is the nerve of taste for the posterior one-third of the tongue.

THE ORGAN OF SMELL

The peripheral olfactory organ or organ of smell consists of two parts: an outer, the *external nose*, which projects from the centre of the face; and an internal, which is divided by a septum into *right* and *left nasal cavities*.

The **external nose** is pyramidal in form, and its upper angle or *root* is connected directly with the forehead; its free angle is termed the *apex*. Its *base* is perforated by two elliptical orifices, the *nares*, separated from each other by an antero-posterior septum, the *columna*. The lateral surfaces of the nose form, by their union in the middle line, the *dorsum nasi*, the direction of which varies considerably in different individuals; the upper part of the dorsum is supported by the nasal bones, and is named the *bridge*. The lateral surfaces end below in rounded eminences, the *alæ nasi*.

The framework of the external nose is composed of bones and hyaline cartilages. The *bony framework* occupies the upper part of the organ; it consists of the nasal bones, the frontal processes of the maxillæ, and the nasal part of the frontal bone. The *cartilaginous framework* consists of five large pieces, viz. the cartilage of the septum, the two lateral, and the two greater alar, cartilages (figs. 939, 940, 941). The various cartilages are connected to each other and to the bones by a tough fibrous membrane.

FIG. 939.—The cartilages of the right side of the nose. Lateral aspect.

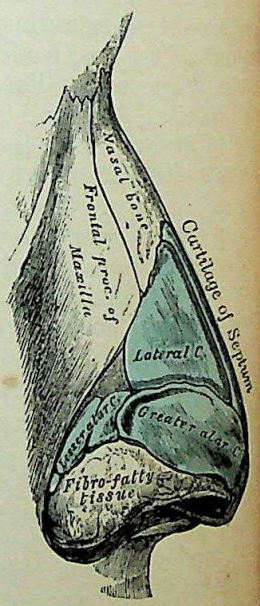

The *cartilage of the septum* (figs. 941, 942), somewhat quadrilateral in form, and thicker at its margins than at its centre, completes the separation between the nasal cavities in front. The upper part of its antero-superior margin is connected to the posterior border of the internasal suture; the middle part is continuous with the lateral cartilages; the lower part is attached to these cartilages by fibrous tissue. Its antero-inferior border is connected to the medial crura of the greater alar cartilages by fibrous tissue. Its postero-superior border is joined to the lamina perpendicularis of the ethmoidal bone, and its postero-inferior border is attached to the vomer and to the incisor crest of the maxillæ. The cartilage of the septum may extend backwards (especially in children) as a narrow process, the *sphenoidal process*, for some distance between the vomer and the lamina perpendicularis of the ethmoidal bone. The antero-inferior part of the nasal septum is freely movable, and hence is named the *septum mobile nasi*; it is not formed by the cartilage of the septum, but by the medial crura of the greater alar cartilages and by the skin.

The *lateral cartilage* (fig. 939) is situated below the inferior margin of the nasal bone, and is flattened, and triangular in shape. Its anterior margin is thicker than the posterior, and its upper part is continuous with the cartilage

CC-0. In Public Domain. Gurukul Kangri Collection, Haridwar

Digitized by Arya Samaj Foundation Chennai and eGangotri

of the septum, but its lower part is separated from this cartilage by a narrow fissure; its superior margin is attached to the nasal bone and the frontal process of the maxilla; its inferior margin is connected by fibrous tissue with the crus laterale of the greater alar cartilage.

The *greater alar cartilage* (figs. 939, 940) is a thin, flexible plate, situated immediately below the lateral cartilage, and bent upon itself anteriorly in such a manner as to form the medial, anterior, and lateral walls of the naris. The portion which forms the medial wall (*crus mediale*) is narrow, and is loosely connected with the crus mediale of the opposite cartilage and with the antero-inferior border of the cartilage of the septum; the medial crura of the greater alar cartilages constitute, together with the thickened skin and subcutaneous tissue, the septum mobile nasi. The part which forms the lateral wall (*crus laterale*) is curved to correspond with the ala of the nose; its posterior end is narrow, and is connected with the frontal process of the maxilla by a tough fibrous membrane, in which are found three or four small cartilaginous plates, the *lesser alar cartilages*. Its upper

Fig. 940.—The cartilages of the nose. Inferior aspect.

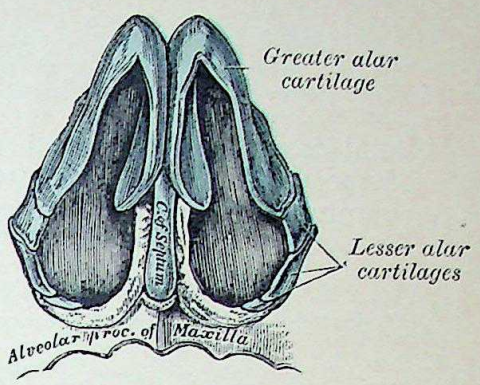

Fig. 941.—The bones and cartilages of the septum of the nose. Right lateral aspect.

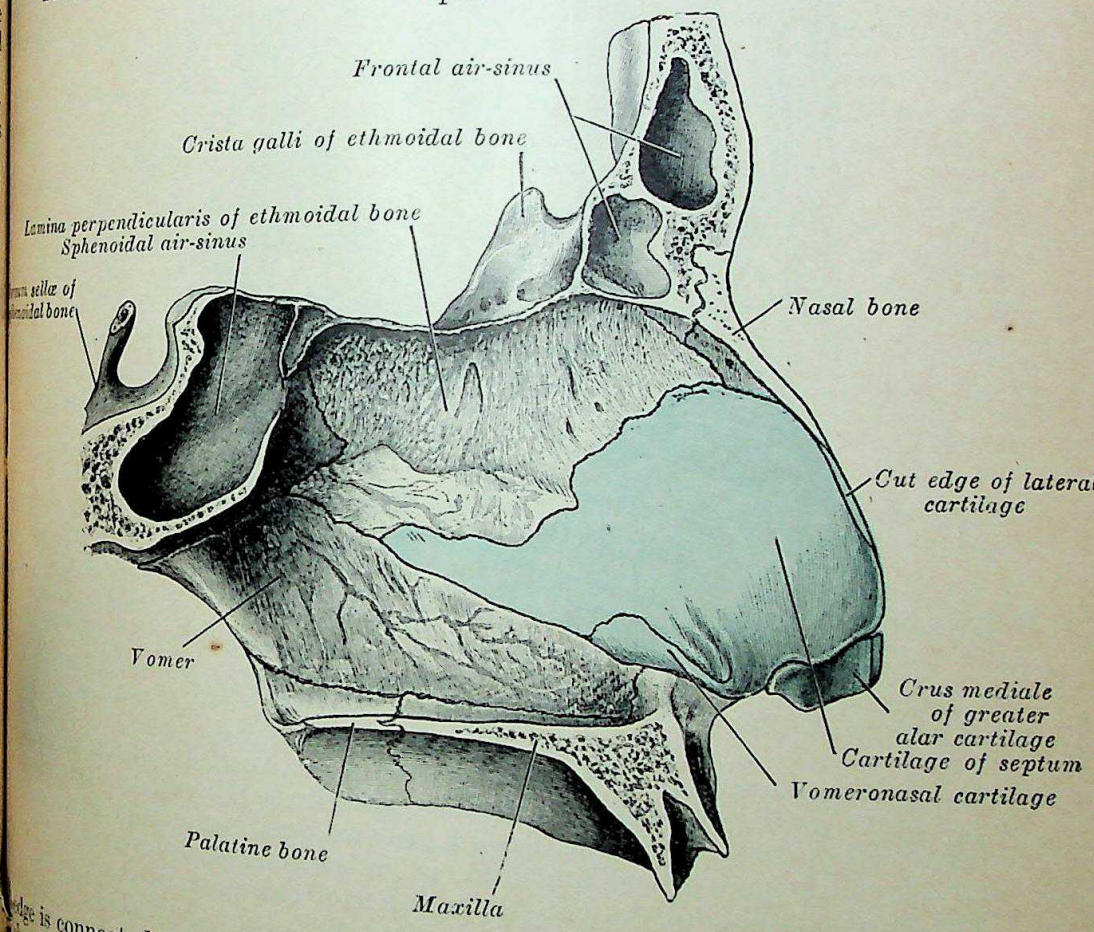

edge is connected by fibrous tissue to the lateral cartilage, its lower edge falls short of the lateral margin of the naris, the lower part of ala nasi being formed by fatty and fibrous tissue covered with skin. In front, the greater alar cartilages are separated by a notch which corresponds with the apex of the nose.

The *muscles* acting on the external nose have been described on p. 440.

The *skin* of the dorsum and sides of the nose is thin, and loosely connected with the adjacent parts; but over the tip and alæ it is thicker and more firmly adherent, and is

CC-0. In Public Domain. Gurukul Kangri Collection, Haridwar

Digitized by Arya Samaj Foundation Chennai and eGangotri

furnished with a large number of sebaceous follicles, the orifices of which are usually very distinct.

The *arteries* of the external nose are the alar and septal branches of the external maxillary artery, which supply the alæ and lower part of the septum; the dorsum and sides being supplied from the dorsal nasal branch of the ophthalmic artery and the infra-orbital branch of the internal maxillary artery. The *veins* end in the anterior facial and ophthalmic veins.

The *nerves* for the muscles of the nose are derived from the facial nerve, while the skin receives branches from the infratrochlear and anterior ethmoidal branches of the ophthalmic nerve, and from the infra-orbital branch of the maxillary nerve.

Nasal cavities.—The nasal cavities or chambers are situated one on either side of the median plane (fig. 942). They open in front through the nares, and communicate behind with the nasal part of the pharynx through the

FIG. 942.—A transverse section through the anterior part of the head at a level just below the apex of the dens (odontoid process). Viewed from below.

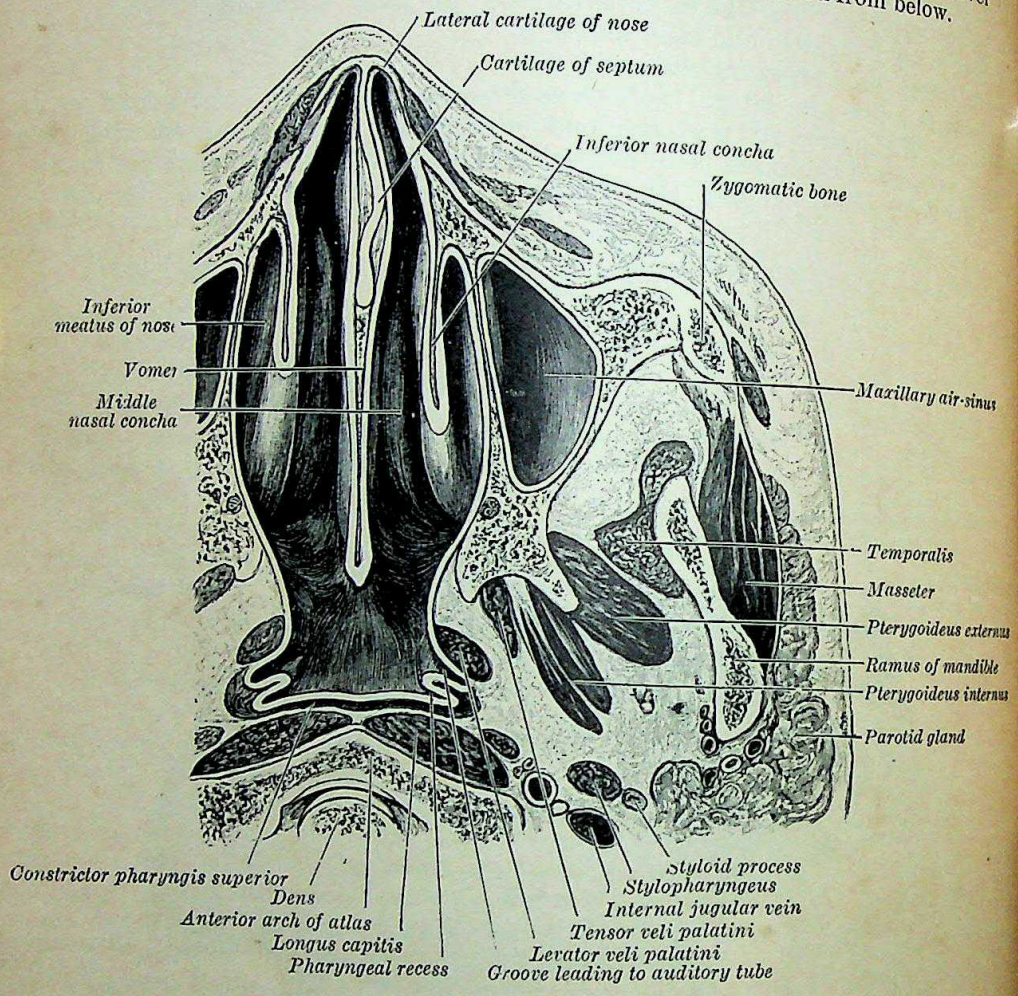

choanæ. The *nares* are somewhat pear-shaped apertures, each measuring from 1·5 cm. to 2 cm. anteroposteriorly, and from 0·5 cm. to 1 cm. transversely at its widest part. The *choanæ* are two oval openings each measuring about 2·5 cm. in the vertical, and 1·25 cm. in the transverse direction.

For the description of the bony boundaries of the nasal cavities, see p. 264.

Inside the aperture of the nostril is a slight dilatation, the *vestibule* (fig. 943), bounded laterally by the ala and the lateral crus of the greater alar cartilage, and medially by the medial crus of the same cartilage; it extends as a small recess towards the apex of the nose. The vestibule is lined by skin, and in its lower part are coarse hairs and sebaceous glands; the hairs (vibrissæ) curve downwards and forwards and tend to arrest the passage of foreign substances carried with the current of inspired air. The vestibule is limited above and behind by a curved elevation, the *limen nasi*, along which the cutaneous lining of the vestibule is continuous with the mucous membrane of the nasal cavity.

CC-0. In Public Domain. Gurukul Kangri Collection, Haridwar

Digitized by Arya Samaj Foundation Chennai and eGangotri

Each nasal cavity, above and behind the vestibule, is divided into two parts: an *olfactory* region, limited to the superior nasal concha and the opposed part of the septum, and a *respiratory* region, which comprises the rest of the cavity.

Lateral wall (figs. 943, 944).—On the lateral wall are the superior, middle, and inferior nasal conchæ, and below and lateral to each concha is the corresponding nasal passage or meatus. Above the superior concha is a triangular space, the *spheno-ethmoidal recess*, into which the sphenoidal air-sinus opens. The *superior meatus* is a short oblique passage extending about half-way along the upper border of the middle concha; the posterior ethmoidal air-sinuses open, usually by two apertures, into the front part of this meatus.

FIG. 943.—The lateral wall of the right nasal cavity. Medial aspect.

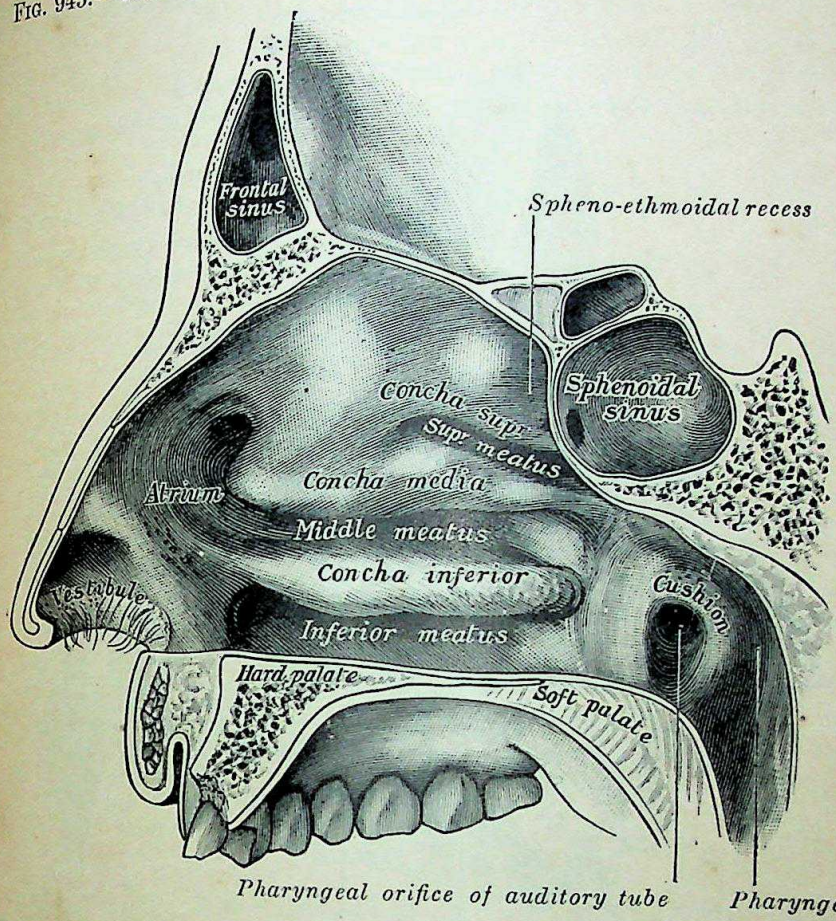

The *middle meatus*, deeper in front than behind, is below and lateral to the middle concha, and is continued anteriorly into a shallow depression, situated above the vestibule and named the *atrium* of the middle meatus. Above the atrium a flattened ridge, the *agger nasi*, runs forwards and downwards; it is better developed in the new-born child than in the adult; the furrow above it is named the *sulcus olfactorius*. On raising or removing the middle concha the lateral wall of this meatus is fully displayed. On it is a round elevation, the bulla ethmoidalis, and below and in front of this is a curved cleft, the hiatus semilunaris. The *bulla ethmoidalis* is caused by the bulging of the middle ethmoidal air-sinuses which open on or immediately above it, and the size of the bulla varies with that of its contained sinuses. The *hiatus semilunaris* is bounded inferiorly by the sharp concave margin of the uncinate process of the ethmoidal bone, and leads into a curved channel, the *infundibulum*, bounded above by the bulla ethmoidalis and below by the lateral surface of the uncinate process of the ethmoidal bone. The anterior ethmoidal air-sinuses open into the front part of the infundibulum; the latter in rather more than 50 per cent. of subjects is continuous with the frontonasal duct or passage leading from the frontal air-sinus; but in those cases where the anterior end of the uncinate process fuses with the front part of the bulla, this continuity is

CC-0. In Public Domain. Gurukul Kangri Collection, Haridwar

Digitized by Arya Samaj Foundation Chennai and eGangotri

interrupted and the frontonasal duct then opens directly into the anterior end of the middle meatus. Below the bulla ethmoidalis, and partly hidden by the inferior end of the uncinate process, is the *ostium maxillare*, or opening from the maxillary air-sinus; in a frontal section of the nose this opening is seen to be placed near the roof of the sinus. An accessory opening from the maxillary air-sinus is frequently present below and behind the infundibulum. The *inferior meatus* is below and lateral to the inferior nasal concha; the nasolacrimal duct opens into this meatus under cover of the anterior part of the inferior concha.

Medial wall (fig. 941).—The medial wall or septum is frequently more or less deflected from the median plane, thus lessening the size of one nasal cavity

Fig. 944.—The lateral wall of the right nasal cavity; the three nasal conchæ have been removed.

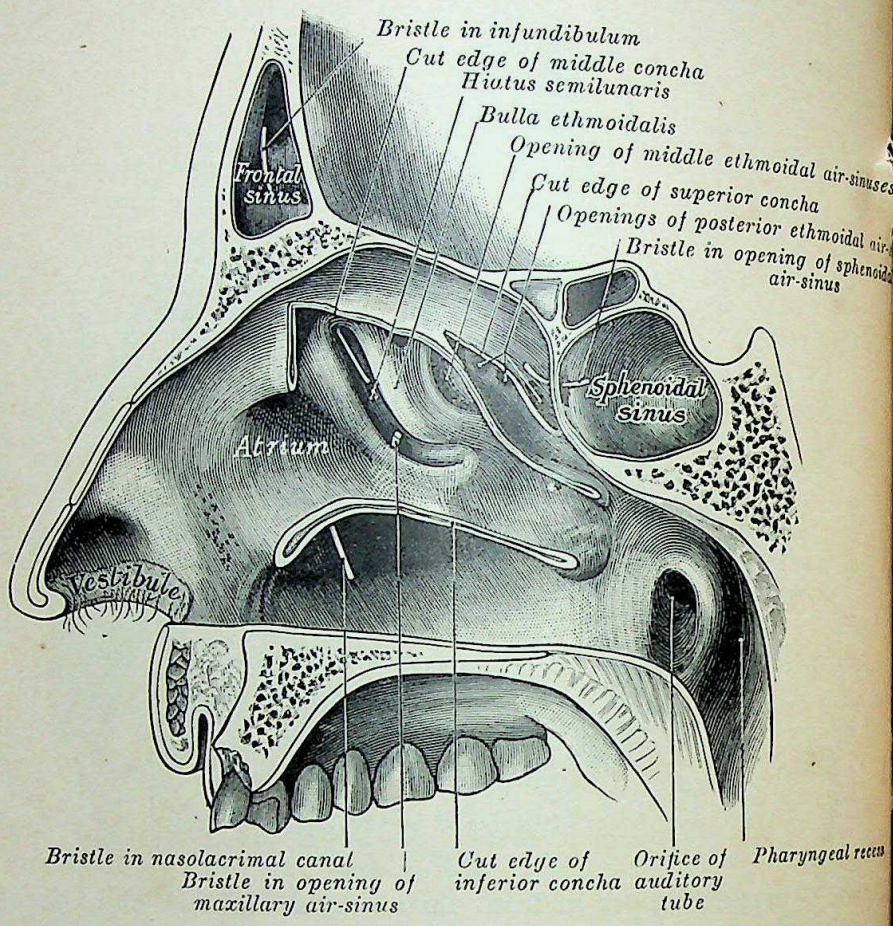

and increasing that of the other; ridges or spurs of bone sometimes project into one or other cavity from the septum. Immediately over the incisive canal at the lower edge of the cartilage of the septum a depression, the *nasopalatine recess*, is sometimes seen; it points downwards and forwards, and occupies the position of a canal which connected the nasal with the buccal cavity in early fœtal life. In the septum close to this recess a minute orifice may be discerned; it leads backwards into a blind pouch, the rudimentary *vomeronasal organ of Jacobson*, which is supported by a strip of cartilage, the *vomeronasal cartilage*. This organ is well developed in many of the lower animals, where it apparently plays a part in the sense of smell, since it is supplied by twigs of the olfactory nerve and is lined by epithelium similar to that in the olfactory region of the nose.

The *roof* of the nasal cavity is narrow from side to side, except at its posterior part, and may be divided, from behind forwards, into sphenoidal, ethmoidal, and frontonasal parts, corresponding to the bones which enter into its formation.

CC-0. In Public Domain. Gurukul Kangri Collection, Haridwar

Digitized by Arya Samaj Foundation Chennai and eGangotri

The *floor* is concave from side to side, flat and almost horizontal antero-posteriorly; its anterior three-fourths are formed by the palatine process of the maxilla, its posterior one-fourth by the horizontal part of the palatine bone.

The **nasal mucous membrane** lines the nasal cavities with the exception of the vestibules, and is intimately adherent to the periosteum or perichondrium. It is continuous with the mucous membrane of the nasal part of the pharynx, through the choanæ; with the conjunctiva, through the nasolacrimal and lacrimal ducts; and with the mucous membranes of the sphenoidal, ethmoidal, frontal, and maxillary air-sinuses, through the openings of these sinuses.

The mucous membrane is thickest and most vascular over the nasal conchæ, especially at their extremities. It is also thick over the septum nasi, but very thin in the meatuses, on the floor of the nasal cavities, and in the various air-sinuses. Owing to the thickness of the membrane, the nasal cavities are much narrower, and the middle and inferior nasal conchæ larger and more prominent than they appear in the skeleton; for the same reason the various apertures communicating with the meatuses are also considerably narrowed.

Fig. 945.—A section through the olfactory mucous membranes. (Cadiat.)

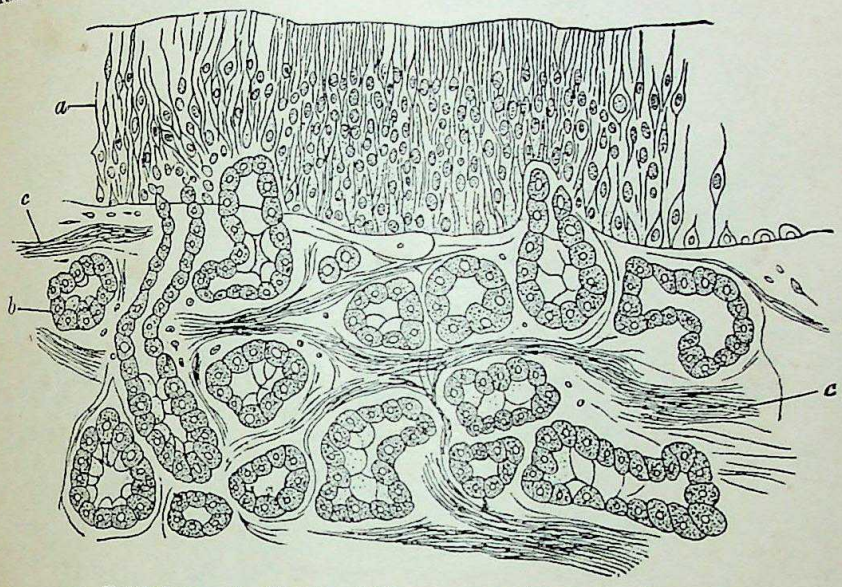

a. Epithelium. *b.* Glands of Bowman. *c.* Nerve-bundles.

Structure of the mucous membrane (fig. 945).—The epithelium of the mucous membrane differs in its characteristics according to the functions of the part of the nose in which it is found. In the *respiratory region* it is columnar and ciliated. Interspersed among the columnar cells are goblet or mucous cells, while between their bases are found smaller pyramidal cells. Beneath the epithelium and its basement-membrane is a fibrous layer infiltrated with lymph-corpuscles, forming in many parts a diffuse adenoid tissue, and under this a nearly continuous layer of mucous and serous glands, the ducts of which open upon the surface. In the *olfactory region* the mucous membrane is yellowish in colour and the epithelial cells are of two kinds, supporting cells and olfactory cells. The *supporting cells* contain oval nuclei, which are situated in the deeper parts of the cells and constitute the zone of oval nuclei; the superficial part of each cell is columnar, and contains granules of yellow pigment, while its deep part is prolonged as a delicate process which ramifies, and communicates with similar processes from neighbouring cells so as to form a network in the mucous membrane. Lying between the deep processes of the supporting cells are a number of bipolar nerve-cells, the *olfactory cells*, each consisting of a small amount of granular protoplasm with a large spherical nucleus, and possessing two processes—a superficial process which runs between the columnar epithelial cells, and ends at the surface of the mucous membrane in one or more fine, hair-like processes, the *olfactory hairs*; the deep process, runs inwards, is frequently beaded, and is continued as an olfactory nerve-fibre (p. 885). Beneath

CC-0. In Public Domain. Gurukul Kangri Collection, Haridwar

Digitized by Arya Samaj Foundation Chennai and eGangotri

the epithelium, and extending through the thickness of the mucous membrane, is a layer of tubular, often branched, glands, the *glands of Bowman*, similar in structure to serous glands.

Vessels and Nerves.—The *arteries* of the nasal cavities are the anterior and posterior ethmoidal branches of the ophthalmic artery, which supply the ethmoidal and frontal air-sinuses, and the roof of the nose; the sphenopalatine branch of the internal maxillary artery, which supplies the mucous membrane covering the conchæ, the meatuses, and septum; the septal ramus of the superior labial branch of the external maxillary artery; the infra-orbital and alveolar branches of the internal maxillary artery, which supply the lining membrane of the maxillary air-sinus; and the pharyngeal branch of the same artery, distributed to the sphenoidal air-sinus. The ramifications of these vessels form a close plexiform network, beneath and in the substance of the mucous membrane.

FIG. 946.—The nerves of the right side of the septum of the nose.

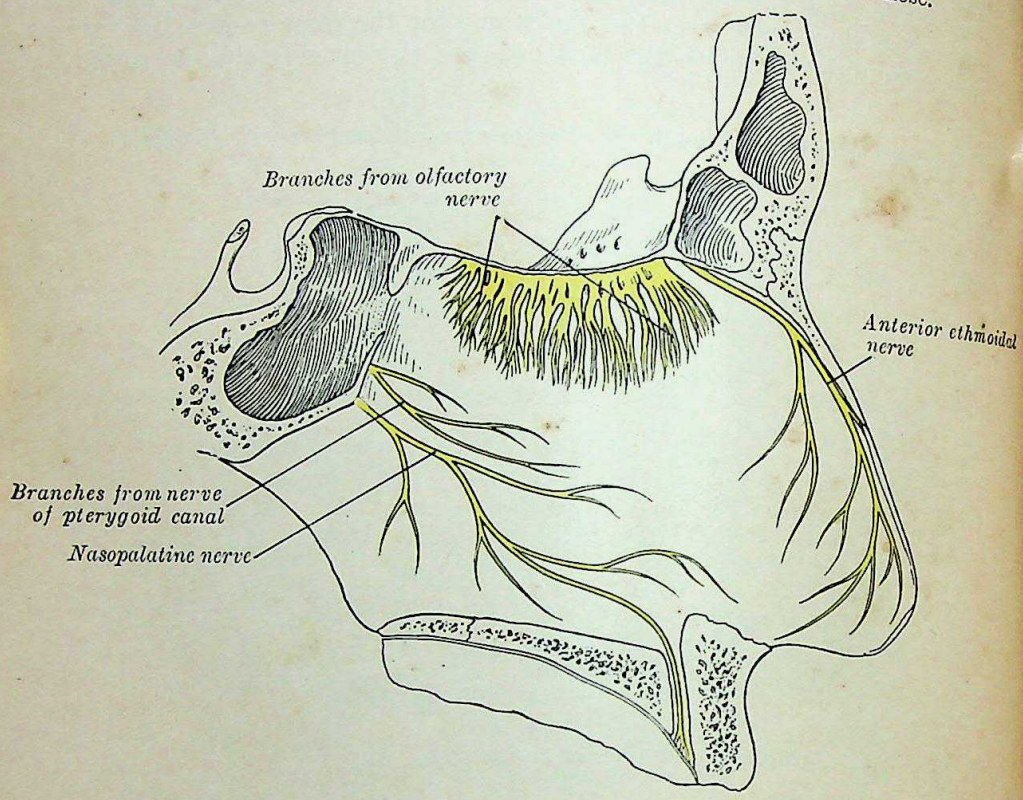

The *veins* form a close cavernous plexus beneath the mucous membrane. This plexus is especially marked over the lower part of the septum and over the middle and inferior conchæ. Some of the veins open into the sphenopalatine vein; others join the anterior facial vein; some accompany the ethmoidal arteries, and end in the ophthalmic veins; a few communicate with the veins on the orbital surface of the frontal lobe of the brain, through the foramina in the lamina cribrosa of the ethmoidal bone. When the foramen cæcum is patent it transmits a vein from the nasal cavity to the superior sagittal sinus.

The *lymphatics* are described on p. 755.

The *nerves* of ordinary sensation (figs. 885, 946) are: the anterior ethmoidal branch of the nasociliary nerve, filaments from the anterior alveolar branch of the maxillary nerve, the nerve of the pterygoid canal, the nasopalatine nerve, the anterior palatine and nasal branches of the sphenopalatine ganglion.

The anterior ethmoidal branch of the nasociliary nerve distributes filaments to the anterior parts of the septum and lateral wall. Filaments from the anterior alveolar nerve supply the inferior meatus and inferior concha. The nerve of the pterygoid canal supplies the upper and posterior parts of the septum, and superior concha; and the upper nasal branches from the sphenopalatine ganglion have a similar distribution. The nasopalatine nerve supplies the middle of the septum. The anterior palatine nerve supplies the lower nasal branches to the middle and inferior conchæ.

The *olfactory nerves* are distributed to the olfactory region. Their fibres arise from the bipolar olfactory cells and are destitute of medullary sheaths. They unite in fasciculi which cross one another in various directions, and thus give rise to the appearance of a plexus in the mucous membrane (fig. 946) and then ascend in grooves or canals in the ethmoidal bone; they pass into the skull through the foramina in the lamina cribrosa of

CC-0. In Public Domain. Gurukul Kangri Collection, Haridwar

Digitized by Arya Samaj Foundation Chennai and eGangotri

ethmoidal bone and enter the under surface of the olfactory bulbs, in which they ramify form synapses with the dendrites of the mitral cells (fig. 876). Closely associated with olfactory nerves are the *nervi terminales* (p. 885*).

The Accessory Air-sinuses of the Nose (figs. 942, 943, 944, 947)

The **accessory air-sinuses of the nose** are the frontal, ethmoidal, sphenoidal, maxillary; they vary in size and form in different individuals, and are lined mucous membrane continuous with that of the nasal cavities.

The **frontal air-sinuses,** two in number, are situated behind the superciliary ches; they are rarely symmetrical, and the septum between them frequently viates to one or other side of the middle line. Their average measurements are follows: height, 3·16 cm.; breadth, 2·58 cm.; depth from before backwards,

Fig. 947.—A coronal section through the nasal cavities.

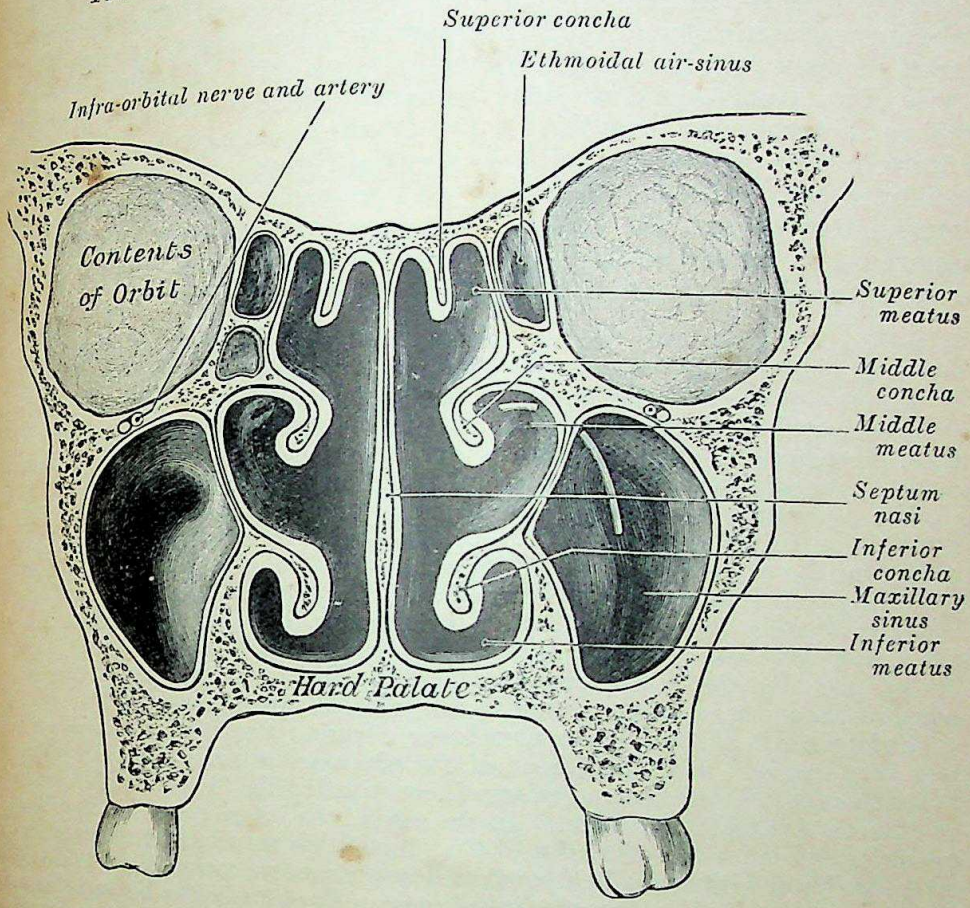

cm. Each opens into the anterior part of the corresponding middle meatus of nose through the frontonasal duct, which traverses the anterior part of the rinth of the ethmoid. Small at birth, they are generally fairly well developed ween the seventh and eighth years, but only reach their full size after puberty.

The **ethmoidal air-sinuses** consist of numerous thin-walled cavities situated in the ndal labyrinth, and completed by the frontal, maxillary, lacrimal, sphenoidal palatine bones. They lie between the upper parts of the nasal cavities and the , and are separated from the latter by the laminæ papyraceæ. On either side are arranged in three groups, anterior, middle, and posterior. The anterior middle groups open into the middle meatus of the nose, the former by way of infundibulum, the latter on or above the bulla ethmoidalis. The posterior uses open into the superior meatus under cover of the superior nasal concha; times one or more opens into the sphenoidal air-sinus. The ethmoidal air-sinuses to develop during fœtal life.

The **sphenoidal air-sinuses,** two in number, are placed behind the upper parts of nasal cavities, and are contained within the body of the sphenoidal bone. ove them are the optic chiasma and the hypophysis cerebri (pituitary body);

CC-0. In Public Domain. Gurukul Kangri Collection, Haridwar

Digitized by Arya Samaj Foundation Chennai and eGangotri

lateral to them are the internal carotid arteries and the cavernous sinuses. They vary in size and shape, and, owing to the lateral displacement of the intervening septum, are rarely symmetrical. The following are their average measurements: vertical height, 2 cm.; transverse breadth, 1·8 cm.; anterior posterior depth, 2·1 cm. When exceptionally large they may extend into the roots of the pterygoid processes or great wings, and may invade the basilar part of the occipital bone. Each air-sinus communicates with the spheno-ethmoidal recess by an aperture in the upper part of its anterior wall. They are present as minute cavities at birth, but their main development takes place after puberty.

The **maxillary air-sinuses** or **antra of Highmore,** the largest accessory air-sinuses of the nose, are pyramidal cavities in the bodies of the maxillæ. The base of each is formed by the lateral wall of the nasal cavity; the apex extends into the zygomatic process. The roof or orbital wall is frequently ridged by the infra-orbital canal, while the floor is formed by the alveolar process and is usually about 1·25 cm. below the level of the floor of the nose; projecting into the floor are several conical elevations corresponding with the roots of the first and second molar teeth, and in some cases the floor is perforated by one or more of these roots. The size of the maxillary air-sinus varies in different skulls, and even on the two sides of the same skull; when large, its apex may invade the zygomatic bone. The following measurements are those of an average-sized air-sinus: vertical height opposite the first molar tooth, 3·5 cm.; transverse breadth, 2·5 cm.; anteroposterior depth, 3·2 cm. In the anterosuperior part of its base is an opening through which it communicates with the lower part of the hiatus semilunaris; a second orifice is frequently seen in, or immediately behind, the hiatus. The maxillary air-sinus appears as a shallow groove on the medial surface of the bone about the fourth month of fœtal life, but does not reach its full size until after the second dentition.*

Applied Anatomy.—Instances of congenital deformity of the nose are occasionally met with, such as complete absence of the external nose, an aperture only being present, or perfect development on one side, and suppression or malformation on the other. Deformities which have been acquired are much more common, such as flattening of the nose, the result of syphilitic necrosis; or imperfect development of the nasal bones in cases of congenital syphilis; or a lateral deviation of the nose after fracture.

The septum of the nose may be displaced or may deviate from the middle line as a result of an injury or of some congenital defect. Sometimes the deviation may be so great that the septum may come into contact with the lateral wall of the nasal cavity, producing complete unilateral obstruction. The septum is covered by a mucous membrane intimately connected with the periosteum; in cases of deflection of the septum *submucous resection* is frequently necessary, the septal cartilage and the vomer being shelled out from the mucoperiosteum clothing them. Perforation of the septum is not uncommon, and most often results from syphilitic ulceration.

Enlargement of the mucous membrane covering the inferior or middle nasal conchæ is a very frequent accompaniment of chronic nasal catarrh. In old-standing cases the bones themselves may become enlarged, constituting the 'hypertrophied turbinals' which so often cause nasal obstruction. In the case of the inferior concha either the anterior or posterior end is usually more especially affected, giving rise to a reddened mass of tissue often confused with a nasal polypus; the appearances, however, are totally different, as the true nasal polypi appear as glistening greyish-white bodies between the conchæ.

Nasal polypi are of frequent occurrence; in the common gelatinous form they spring from the lateral wall of the nasal cavity and project down between the conchæ, giving rise to obstructed nasal respiration. They are always accompanied by purulent discharge, and are due in all instances to small areas of carious bone in the region of the *bulla ethmoidalis*, or about the ethmoidal or sphenoidal air-sinuses. In bad cases a free curetting of the ethmoidal air-sinuses may be called for after removal of the middle concha. Fibrous polypi are also more rarely met with, and these are of the nature of new growths; they most frequently spring from the base of the skull behind the choanæ and form pedunculated tumours occupying the nasopharynx. Malignant polypi also occur, most commonly originating in the maxillary air-sinus and projecting through the medial wall into the nasal cavity; for such cases removal of the maxilla offers the only hope of cure.

Suppuration in the accessory air-sinuses of the nose is of frequent occurrence, and in connexion with this the situations at which the various sinuses normally communicate with the nasal cavities, are important: thus one finds they fall into two main groups: (1) anterior, opening into the middle meatus, and draining the maxillary, the frontal and the anterior ethmoidal air-sinuses; and (2) posterior, opening into the superior meatus and spheno-ethmoidal recess, and draining the posterior ethmoidal and sphenoidal

* The measurements of the accessory air-sinuses of the nose supplied in the text are those given by A. Logan Turner, *Accessory Sinuses of the Nose*, 1901.

CC-0. In Public Domain. Gurukul Kangri Collection, Haridwar

Digitized by Arya Samaj Foundation Chennai and eGangotri

sinuses. Suppuration in the anterior group is the more common, and the pus can be running down over the anterior end of the inferior concha, whereas in the case of the posterior group, the pus does not come forwards, but runs back into the nasopharynx the posterior end of the middle concha. Again, it is of importance to notice that the le meatus is of such a form that pus running down from the frontal air-sinus is ted by the groove beneath the bulla ethmoidalis into the ostium of the maxillary sinus, so that the latter sinus may, in some cases, act as a secondary reservoir for pus rged from the frontal air-sinus. All the accessory air-sinuses can be and are ted from the nasal cavity, but it should be noted that in the case of the maxillary sinus, the infection is frequently conveyed in another way, and that is from the teeth. The air-sinus is the one most frequently the seat of chronic suppuration and it often ires drainage; this can be carried out by drilling a hole through the alveolus after oval of a tooth, preferably the first molar, or by gouging away the anterior surface of maxilla, after having reflected the gum, or by removing bone from the lateral wall the inferior meatus of the nose. Simple drainage, however, is not usually sufficient, more extensive operations have often to be performed. Distension of the walls of maxillary air-sinus occurs as the result of new growth or cyst formation within its ity. Thus the facial surface may be prominently bulged outwards, upward extension displace the eyeball, or the nasal cavity on that side may be occluded, giving rise to teral obstruction. In some cases the disease will perforate the palatine process of maxilla and a soft spot will be found under the mucoperiosteum. If the disease be gnant in nature, nothing short of excision of the maxilla is of any avail (p. 273).

The Organ of Sight

The bulb of the eye (eyeball), or organ of sight, is contained in the cavity of orbit, where it is protected from injury, and can be moved by the ocular scles. Associated with it are certain accessory structures, viz. the muscles, ae, eyebrows, eyelids, conjunctiva, and lacrimal apparatus.

The bulb of the eye is embedded in the fat of the orbit, but is separated m the fat by a thin membranous sac, the *fascia bulbi* (p. 1013). It is com- sed of segments of two hollow spheres of different sizes. The anterior ment is one of a small sphere; it is transparent, and its arc forms about -sixth of the circumference of the bulb. It is more prominent than the erior segment, which is one of a larger sphere, and is opaque, and forms ut five-sixths of the bulb. The term *anterior pole* is applied to the central nt of the anterior curvature of the bulb, and that of *posterior pole* to the ral point of its posterior curvature; a line joining the two poles forms *optic axis*. The axes of the two bulbs are nearly parallel, and there- do not correspond with the axes of the orbits, which are directed wards and lateralwards. The optic nerves follow the direction of the axes the orbits, and are therefore not parallel; each enters its eyeball 3 mm. the nasal side of the posterior pole. The vertical diameter (23·5 mm.) of bulb is rather less than the transverse and anteroposterior diameters 24 mm.); the anteroposterior diameter at birth is about 17·5 mm. and at berty from 20 to 21 mm. In the female all three diameters are rather less n in the male.

The bulb of the eye is composed of three tunics, enclosing three refracting dia.

The Tunics of the Eye (fig. 948)

From without inwards the three tunics are: (1) the fibrous tunic, consisting the *sclera* behind and the *cornea* in front; (2) the vascular, pigmented tunic, prising, from behind forwards, the *chorioid*, *ciliary body*, and *iris*; and (3) the nervous tunic, the *retina*.

I. The Fibrous Tunic

The fibrous tunic of the bulb of the eye (fig. 948) consists of an opaque, erior part, the sclera, and a transparent anterior part, the cornea.

The sclera, so named from its density and hardness, is a firm unyielding mbrane, serving to maintain the form of the bulb. It is thickest (about mm.) behind, near the entrance of the optic nerve, and thinnest (0·4 mm.) at

CC-0. In Public Domain. Gurukul Kangri Collection, Haridwar

Digitized by Arya Samaj Foundation Chennai and eGangotri

a distance of about 6 mm. behind the sclerocorneal junction. Its *external surface* is white, and is in contact with the inner surface of the fascia bulbi (p. 10[illegible]); it is smooth, except where the Recti and Obliqui muscles are inserted into it; its anterior part is covered by the conjunctival membrane. Its *inner surface* is brown and is marked by grooves, in which the ciliary nerves and vessels are lodged; it is separated from the outer surface of the chorioid by an extensive *perichorioidal lymph-space*, which is traversed by an exceedingly fine cellular tissue, the *lamina suprachorioidea*. Behind, it is pierced by the optic nerve and is continuous through the fibrous sheath of this nerve with the dura mater. Where the optic nerve pierces the sclera the latter presents the appearance of a cribriform plate, the *lamina cribrosa scleræ*; the minute orifices in the lamina serve for the transmission of the nerve-bundles, and the fibrous septa between the orifices are continuous with the supporting tissue of the nerve.

FIG. 948.—A horizontal section through the bulb of the eye.

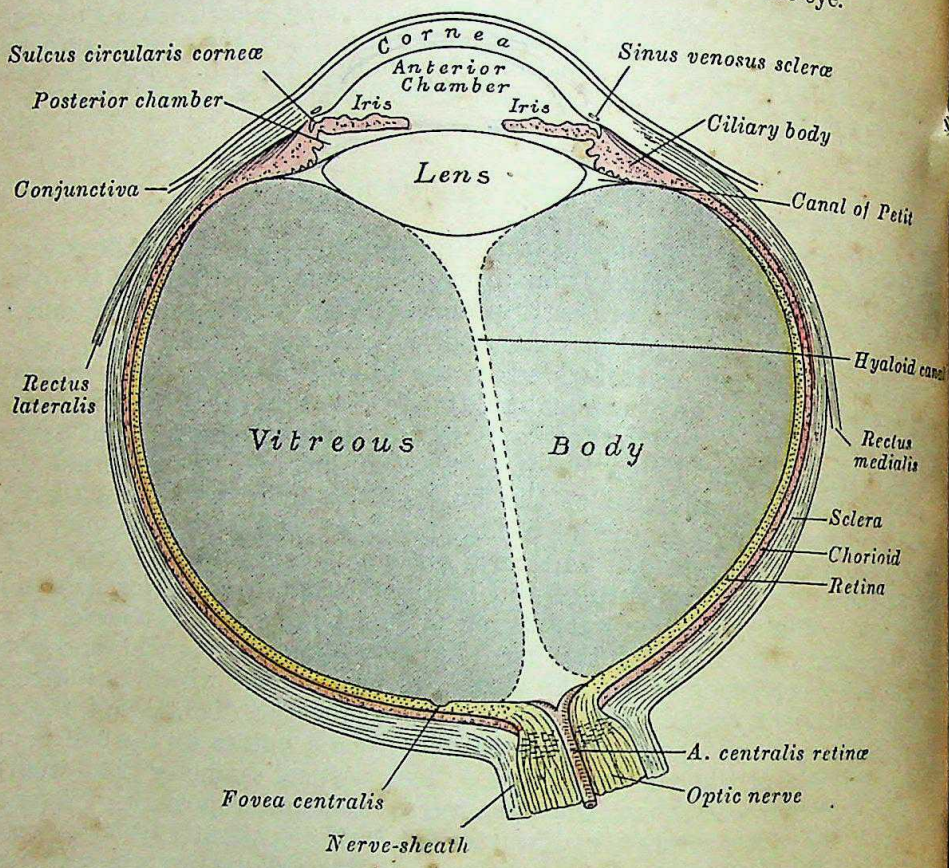

One opening, larger than the rest, and occupying the centre of the lamina, transmits the central artery and vein of the retina. Around the lamina cribrosa scleræ are numerous small apertures for the transmission of the ciliary vessels and nerves, and about midway between these and the sclerocorneal junction are four or five large apertures for the transmission of veins (*venæ vorticosæ*). In front, the sclera is directly continuous with the cornea, the line of union being termed the *sclerocorneal junction*. In the substance of the sclera close to this junction is a circular canal, the *sinus venosus scleræ* (canal of Schlemm). In a meridional section through the sclerocorneal junction, this sinus presents the appearance of a cleft, the outer wall of which consists of the firm tissue of the sclera, while its inner wall is formed by a triangular mass of trabecular tissue (fig. 949); the apex of the mass is directed forwards and is continuous with the posterior elastic lamina of the cornea. The sinus is lined by endothelium, and communicates internally with the anterior chamber of the eye, and externally with the anterior ciliary veins.

Structure.—The sclera is formed of white fibrous tissue intermixed with fine elastic fibres; flattened connective tissue corpuscles, some of which are pigmented, are contained in cell-spaces between the fibres. The fibres are aggregated into

CC-0. In Public Domain. Gurukul Kangri Collection, Haridwar

Digitized by Arya Samaj Foundation Chennai and eGangotri

...les, which are arranged chiefly in a longitudinal direction. Its *vessels* are ...numerous; its capillaries are small, and unite at long and wide intervals. ...nerves are derived from the ciliary nerves, but their exact mode of ending is ...known.

The *cornea* is the anterior projecting transparent part of the external ...; it is almost circular in outline, occasionally a little broader in the ...verse than in the vertical direction. It is convex anteriorly, and pro... like a dome in front of the sclera. Its degree of curvature varies in ...ent individuals, and in the same individual at different periods of ... being more pronounced in youth than in advanced life. The cornea is

FIG. 949.—A general view of the iridial angle. Enlarged. (After Thomson.)



...e and of uniform thickness throughout; its posterior surface is per... circular in outline, and exceeds the anterior surface slightly in ...meter. Immediately in front of the sclerocorneal junction the cornea ...es inwards as a thickened rim, and behind this rim there is a distinct ...w between the attachment of the iris and the sclerocorneal junction. ...furrow has been named by Arthur Thomson * the *sulcus circularis corneæ*; ...bounded externally by the trabecular tissue already described as forming ...inner wall of the sinus venosus scleræ. Between this tissue and the anterior ...ce of the attached margin of the iris is an angular recess, named the *iridial* ...le or *filtration angle* of the eye (fig. 949). Immediately outside the filtration ...le is a projecting rim of scleral tissue which appears in a meridional section ...a small triangular area, termed the *scleral spur*. Its base is continuous ...the inner surface of the sclera immediately to the outer side of the filtra... angle and its apex is directed forwards and inwards. The bundles of ...ecular tissue just referred to are attached to the anterior sloping margin

* *Atlas of the Eye*, Clarendon Press, Oxford, 1912.

CC-0. In Public Domain. Gurukul Kangri Collection, Haridwar

Digitized by Arya Samaj Foundation Chennai and eGangotri

of this spur; the meridional fibres of the Ciliaris muscle arise from its posterior margin.

Structure (fig. 950).—The cornea consists from before backwards of four layers, viz.: (1) the corneal epithelium, continuous with that of the conjunctiva; (2) the substantia propria; (3) the posterior elastic lamina; and (4) the endothelium of the anterior chamber.

Fig. 950.—A vertical section through the human cornea near its margin. Magnified. (Waldeyer.)

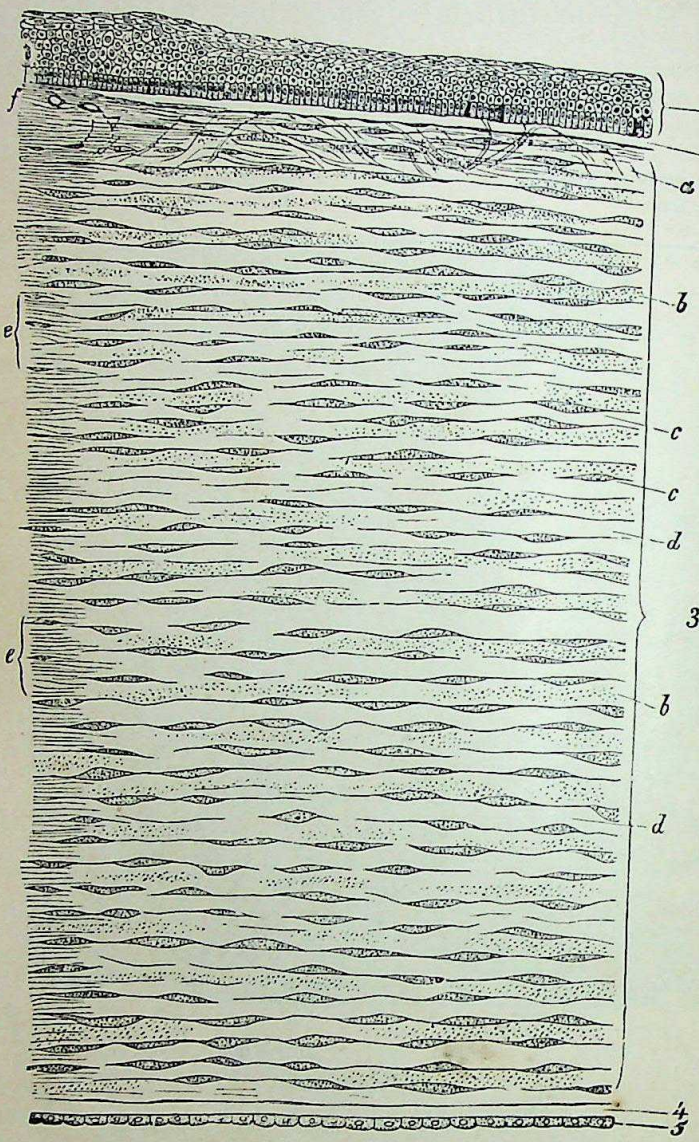

1. Epithelium. 2. Anterior elastic lamina. 3. Substantia propria. 4. Posterior elastic lamina. 5. Endothelium of the anterior chamber. *a.* Oblique fibres in the anterior layer of the substantia propria. *b.* Lamellæ the fibres of which are cut across, producing a dotted appearance. *c.* Corneal corpuscles appearing fusiform in section. *d.* Lamellæ the fibres of which are cut longitudinally. *e.* Transition to the sclera, with more distinct fibrillation, and surmounted by a thicker epithelium. *f.* Small blood-vessels cut across near the margin of the cornea.

The *corneal epithelium* covers the front of the cornea and consists of several layers of cells. The cells of the deepest layer are columnar; they follow two or three layers of polyhedral cells, the majority of which are prickle-cells similar to those found in the stratum mucosum of the cuticle (p. 105). Lastly, there are three or four layers of squamous cells, with flattened nuclei.

The *substantia propria* is fibrous, tough, unyielding, and perfectly transparent. It is composed of about sixty flattened, superimposed lamellæ. These lamellæ are made up of bundles of modified connective tissue, the fibres of which are continuous with those of the sclera. The fibres of each lamina are for the most part parallel with one another, but at right angles to those of adjacent lamellæ. Fibres, however, frequently pass from one lamella to the next.

Between the lamellæ is a small amount of ground-substance, in which are spaces, the *corneal spaces*. These are stellate in shape and communicate with one another by numerous offsets. Each contains a cell, the *corneal corpuscle*, resembling in form the space in which it is lodged, but not entirely filling it.

The layer immediately beneath the corneal epithelium presents certain characteristics which have led some anatomists to regard it as a distinct membrane, and it has been named the *anterior elastic lamina*. It consists of extremely closely interwoven fibrils, similar to those found in the substantia propria, but contains no corneal corpuscles.

The *posterior elastic lamina* covers the posterior surface of the substantia propria, and is a thin elastic, transparent homogeneous membrane, which is not rendered opaque, by water, alcohol, or acids. When stripped from the substantia propria it curls up, and rolls upon itself, with the attached surface innermost.

At the margin of the cornea the posterior elastic lamina breaks up into fibres which form the trabecular tissue on the inner wall of the sinus venosus sclerae.

CC-0. In Public Domain. Gurukul Kangri Collection, Haridwar

Digitized by Arya Samaj Foundation Chennai and eGangotri

...ght); the spaces between the trabeculæ are termed the *spaces of the angle of the iris* (spaces of Fontana); they communicate with the sinus venosus scleræ and with the anterior chamber at the filtration angle. Some of the fibres of this ...ocular tissue are continued into the substance of the iris, forming the *pectinate ...ment of the iris*; others are connected with the fore part of the sclera and ...oid.

The *endothelium of the anterior chamber* covers the posterior surface of the ...erior elastic lamina, is reflected on to the front of the iris, and also lines the ...ces of the angle of the iris; it consists of a layer of polygonal, flattened, nucleated ...

Vessels and Nerves.—The cornea is a non-vascular structure, the capillary vessels of ...conjunctiva and sclera ending in loops at its circumference. Lymphatic vessels have ...yet been demonstrated in it, but are probably represented by the channels in which ...nerves run; these channels are lined by an endothelium. The *nerves* are numerous ...are derived from the ciliary nerves. Around the periphery of the cornea they form ...*ular plexus*, from which fibres enter the substantia propria. They lose their medul... sheaths and ramify throughout the substantia propria in a delicate network, and their ...al filaments form a firm and closer plexus beneath the corneal epithelium. This is ...d the *subepithelial plexus*, and from it fine, varicose fibrils are given off which ramify ...en the epithelial cells, forming an *intra-epithelial plexus*.

II. The Vascular Tunic (figs. 951, 953, 954)

The vascular tunic of the eye is formed from behind forwards by the chorioid, ...ciliary body, and the iris.

The chorioid covers the inner surface of the sclera, and extends as far ...wards as the ora serrata of the retina. The ciliary body connects the chorioid ...h the circumference of the iris. The iris is a circular diaphragm behind ...e cornea, and presents near ...s centre a rounded aperture, ...e *pupil*.

Fig. 951.—The chorioid and iris. (Enlarged.)

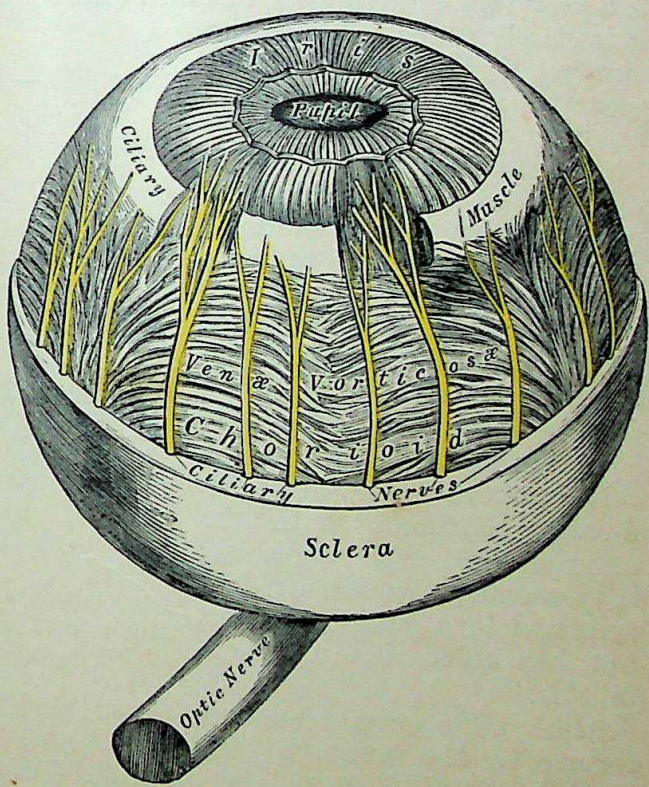

The chorioid is a thin, ...ly vascular membrane, of ...dark brown or chocolate ...ur, investing the posterior ...-sixths of the globe; it is ...ced behind by the optic ...ve, and in this situation is ...ly adherent to the sclera. ...is thicker behind than in ...nt. Its outer surface is ...ely connected with the ...a by the lamina supra-...oidea; its inner surface is ...ched to the pigmented layer ...the retina.

Structure.—The chorioid con-...s mainly of a dense capillary ...us, and of small arteries and ...s carrying blood to and from ... On its external surface is ...thin membrane, the *lamina ...chorioidea*, composed of ...ate non-vascular lamellæ, ...h lamella consisting of a ...work of fine elastic fibres ...ing which are branched pigment-cells. The spaces between the lamellæ are ...ed by endothelium, and open freely into the perichorioidal lymph-space, which, ...turn, communicates with the periscleral space at the points where the vessels ...h nerves are transmitted through the sclera.

Internal to this lamina is the *chorioid proper*, consisting of two layers: an outer, ...posed of small arteries and veins, with pigment-cells interspersed between

CC-0. In Public Domain. Gurukul Kangri Collection, Haridwar

Digitized by Arya Samaj Foundation Chennai and eGangotri

them; and an inner, consisting of a capillary plexus. The *outer layer* or *lamina vasculosa* consists, in part, of the larger branches of the short posterior ciliary arteries which run forwards between the veins before they bend inwards to end in the capillaries, but is formed principally of veins, named, from their arrangement, the *venæ vorticosæ* (fig. 953); these converge to four or five equidistant trunks which pierce the sclera about midway between the sclerocorneal junction and the entrance of the optic nerve. Interspersed between the vessels are delicate star-shaped pigment-cells, the processes of which communicate with those of neighbouring cells, and form a delicate network in the stroma, which loses its pigmentary character towards the inner surface of the chorioid. The *inner layer* or *lamina choriocapillaris* consists of an exceedingly fine capillary plexus, formed by the short ciliary vessels; the network is closer and finer in the posterior than in the anterior part of the chorioid. About 1·25 cm. behind the cornea its meshes become larger, and are continuous with those of the ciliary processes. These two laminæ are connected by a *stratum intermedium* consisting of fine elastic fibres. On the inner surface of the lamina choriocapillaris is a very thin, structureless, or faintly fibrous membrane, called the *lamina basalis*; it is closely connected with the stroma of the chorioid, and separates it from the pigmentary layer of the retina.

FIG. 952.—The arteries of the chorioid and iris. The greater part of the sclera has been removed. (Enlarged.)

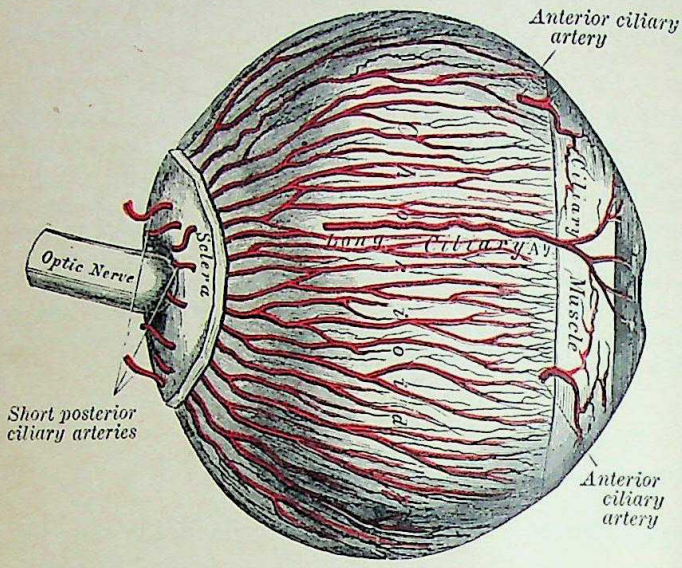

FIG. 953.—The veins of the chorioid. (Enlarged.)

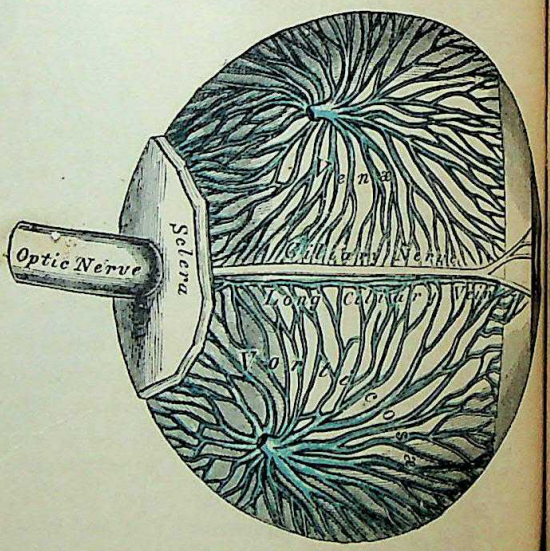

Tapetum.—This name is applied to the outer and posterior part of the chorioid, which in many animals presents an iridescent appearance.

The **ciliary body** comprises the orbicularis ciliaris, the ciliary processes, and the Ciliaris muscle.

The *orbicularis ciliaris* is a zone of about 4 mm. in width, directly continuous with the anterior part of the chorioid; it presents numerous ridges arranged in a radial manner, but has no lamina choriocapillaris.

The *ciliary processes* are formed by the inward folding of the various layers of the chorioid (i.e. the chorioid proper and the lamina basalis), and are received between corresponding foldings of the suspensory ligament of the lens. They are arranged in a circle, and form a sort of frill behind the iris, round the margin of the lens (fig. 954). They vary from sixty to eighty in number, lie side by side, and may be divided into large and small processes; the former are about 2·5 mm. long, and the latter, consisting of about one-third of the entire number, are situated in the spaces between them, but without regular alternation. Each is attached by its periphery to the

CC-0. In Public Domain. Gurukul Kangri Collection, Haridwar

Digitized by Arya Samaj Foundation Chennai and eGangotri

four of the ridges of the orbicularis ciliaris and is continuous with the layers the chorioid: their opposite extremities are free and rounded, and are rected towards the posterior chamber of the eye- and circumference of the lens. In front, they continuous with the periphery of the iris. Their posterior surfaces are connected with the suspensory ment of the lens.

The ciliary processes (figs. 954, 955) are similar structure to the chorioid, but the vessels are larger and have chiefly a longitudinal direction. Their posterior surfaces are covered by the *pars ciliaris retinæ*, continued forwards from the retina, and consisting of an outer layer of cubical pigment-cells, and an inner layer of columnar cells which are not pigmented. In the stroma of the ciliary processes there are also stellate pigment-cells, but these are not so numerous as in the chorioid itself.

Fig. 954.—The interior of the anterior half of the bulb of the eye.

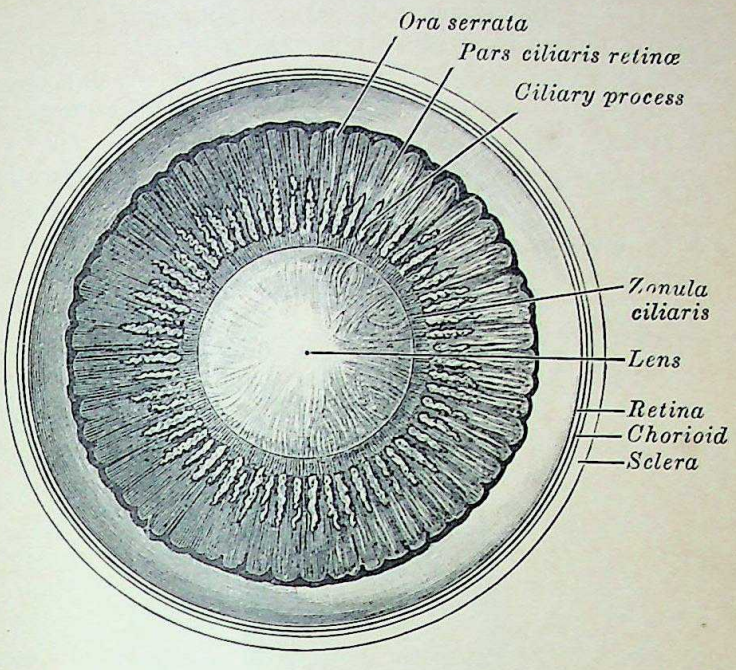

The *Ciliaris muscle* consists of unstriped fibres: it forms a greyish, semi-transparent, circular band, about 6 mm. broad, on the outer surface of the fore-part of the chorioid. It consists of meridional and circular fibres. The *meridional* fibres, much the more numerous, arise from the posterior margin of the scleral spur (p. 995); they run backwards, and are attached to the ciliary processes and orbicularis ciliaris. The *circular* fibres are internal to the meridional ones, and in a meridional section appear as a triangular zone behind the filtration angle and close to the circumference of the iris; they are well developed in hypermetropic, but are rudimentary or absent in myopic, eyes. The Ciliaris muscle is the chief agent in accommodation, i.e. in adjusting the eye to the vision of near objects. When it contracts, it draws forwards the ciliary processes, relaxes the suspensory ligament of the lens, and thus allows the lens to become more convex.

Fig. 955.—The vessels of the chorioid, ciliary processes, and iris, of a child. (Arnold.) × 10.

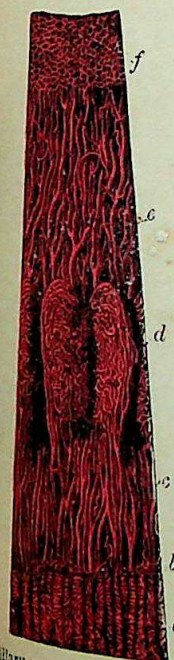

a. Capillary network of the anterior part of the chorioid, ending at *b*, the ora serrata. *c*, arteries supplying the ciliary processes *d*, and passing into the iris *e*. *f*. The capillary network close to the pupillary margin of the iris.

The iris has received its name from the various colours it presents in different individuals. It is a thin, circular, contractile disc, suspended in the aqueous humour between the cornea and the crystalline lens, and perforated a little to the nasal side of its centre by a circular aperture, the *pupil*. Its periphery is continuous with the ciliary body, and is also connected with the posterior elastic lamina of the cornea by means of the pectinate ligament; its flattened surfaces look forwards and backwards, the anterior towards the cornea, the posterior towards the ciliary processes and

CC-0. In Public Domain. Gurukul Kangri Collection, Haridwar

Digitized by Arya Samaj Foundation Chennai and eGangotri

lens. The iris divides the space between the lens and the cornea into an anterior and a posterior chamber (fig. 948). The *anterior chamber* of the eye is bounded in front by the posterior surface of the cornea, behind by the front of the iris and, opposite the pupil, by the central part of the front of the lens. The *posterior chamber* is a narrow chink behind the iris, and in front of the lens and its suspensory ligament. In the adult the two chambers communicate through the pupil, but in the fœtus up to the seventh month they are separated by the *membrana pupillaris* (p. 1001).

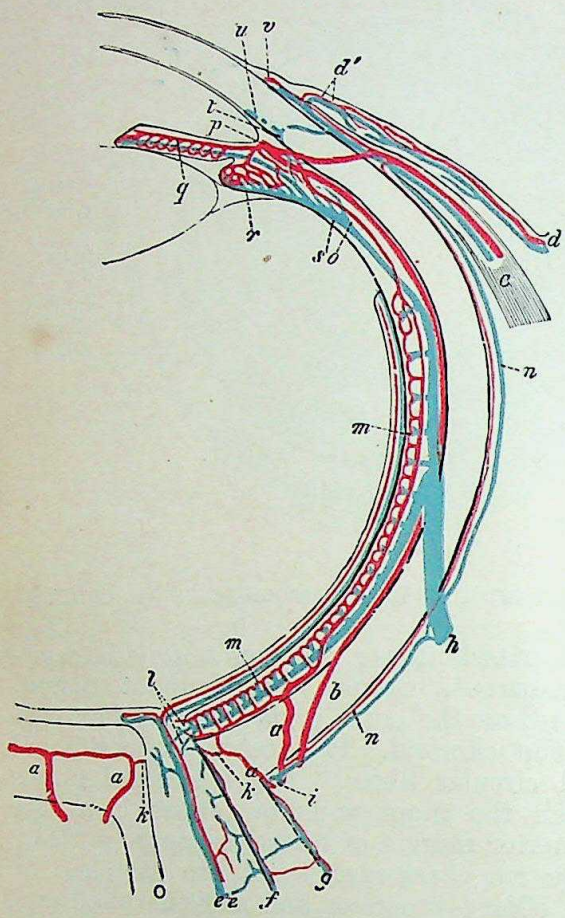

FIG. 956.—A diagrammatic representation of the course of the vessels of the eye. Horizontal section. (Leber.) Arteries and capillaries red; veins blue.

O. Entrance of optic nerve. *a*. Short posterior ciliary arteries. *b*. Long posterior ciliary arteries. *c*. Anterior ciliary vessels. *d*. Posterior conjunctival vessels. *d*. Anterior conjunctival vessels. *e*. Central vessels of the retina. *f*. Vessels of the inner sheath of the optic nerve. *g*. Vessels of the outer sheath. *h*. Vorticose veins. *i*. Short posterior ciliary vein. *k*. Branches of the short posterior ciliary arteries to the optic nerve. *l*. Anastomosis of chorioidal vessels with those of optic nerve. *m*. Choriocapillaris. *n*. Episcleral vessels. *o*. Recurrent artery of the chorioid. *p*. Circulus iridis major (in section). *q*. Vessels of iris. *r*. Vessels of ciliary process. *s*. Branch from ciliary muscle to vorticose vein. *t*. Branch from ciliary muscle to anterior ciliary vein. *u*. Sinus venosus scleræ. *v*. Capillary loop at margin of cornea.

Structure.—The iris is composed of the following structures:

1. In front is a layer of flattened endothelial cells placed on a delicate hyaline basement-membrane. This layer of cells is continuous with the endothelium covering the posterior elastic lamina of the cornea, and in individuals with dark-coloured irises the cells contain pigment-granules.

2. The *stroma* of the iris consists of connective tissue fibres and cells. A few fibres at the circumference of the iris have a circular direction; but the majority are arranged radially, forming, by their interlacement, delicate meshes, in which the vessels and nerves are contained. Interspersed between the bundles of connective tissue are numerous branched cells with fine processes. In dark eyes many of these cells contain pigment-granules, but in blue eyes and the eyes of albinos they are unpigmented.

3. The *muscular fibres* are involuntary, and consist of circular and radiating fibres. The *circular fibres* form the Sphincter pupillæ; they are arranged in a band about 1 mm. wide which surrounds the margin of the pupil, towards the posterior surface of the iris; those near the free margin of the band are closely aggregated; those near the periphery are somewhat separated and form incomplete circles. The *radiating fibres* form the Dilatator pupillæ and lie close to the posterior surface of the iris; they converge from the circumference towards the centre, and blend with the circular fibres near the margin of the pupil.

4. The posterior surface of the iris is of a deep purple tint, being covered by two layers of pigmented epithelial cells, continuous at the periphery of the iris with the pars ciliaris retinæ. This pigmented epithelium is named the *pars iridica retinæ* or, from the resemblance of its colour to that of a ripe grape, the *uvea*.

The colour of the iris is produced by the reflection of light from dark pigment-cells underlying a translucent tissue, and is therefore determined by the amount of the pigment and its distribution throughout the texture of the iris. The number and the situation of the pigment-cells differ in different irises. In the albino pigment is absent; in the various shades of blue eyes the pigment-cells are confined to the posterior surface of the iris, whereas in grey, brown, and black eyes pigment

CC-0. In Public Domain. Gurukul Kangri Collection, Haridwar

Digitized by Arya Samaj Foundation Chennai and eGangotri

found also in the cells of the stroma and in those of the endothelium on the front of the iris.

Vessels and Nerves.—The *arteries of the iris* are derived from the long posterior and the anterior ciliary arteries, and from the vessels of the ciliary processes (p. 627). Each of the two long ciliary arteries, on reaching the attached margin of the iris, divides into an upper and a lower branch; these anastomose with corresponding branches of the artery from the opposite side and with the anterior ciliary arteries and form a vascular circle (*circulus arteriosus major*). From this circle vessels converge to the free margin of the iris, and there communicate and form a second circle (*circulus arteriosus minor*) (figs. 956, 957).

FIG. 957.—The iris, viewed from in front, with its circulus arteriosus major and circulus arteriosus minor. (Testut.)

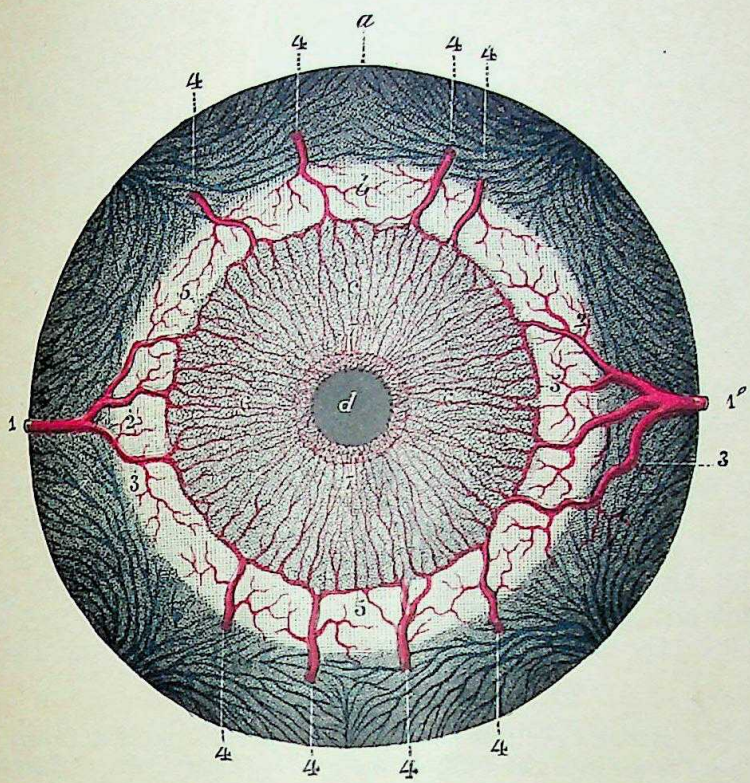

a. Chorioid. *b*. Ciliaris muscle. *c*. Iris. *d*. Pupil. 1 and 1′. The two long ciliary arteries with 2, their ascending branches of bifurcation; 3, their descending branches of bifurcation. 4. The anterior ciliary arteries. 5. Circulus major; 6, its branches radiating through the iris. 7. Circulus minor around the pupil.

The *nerves of the chorioid and iris* are the long and short ciliary nerves; the former are branches of the nasociliary nerve, the latter of the ciliary ganglion. They pierce the sclera around the entrance of the optic nerve, run forwards in the perichorioidal space, and supply the blood-vessels of the chorioid and the ciliary muscle. After reaching the iris they form a plexus around its attached margin; from this are derived non-medullated fibres which end in the Sphincter and Dilatator pupillæ. Other fibres from the plexus end in a network on the anterior surface of the iris. The fibres derived through the parasympathetic root of the ciliary ganglion from the oculomotor nerve supply the Sphincter pupillæ and the Ciliaris muscle; the sympathetic fibres in the long ciliary nerves supply the Dilatator pupillæ.

Membrana pupillaris.—In the fœtus, the pupil is closed by a delicate vascular membrane, the *membrana pupillaris*, which divides the space in which the iris is suspended into two separate chambers. The vessels of this membrane are partly derived from those of the margin of the iris and partly from those of the capsule of the lens; they end in loops a short distance from the centre of the membrane, which is thus left free from blood-vessels. About the sixth month of fœtal life the membrane begins to disappear by absorption from the centre towards the circumference, and at birth only a few fragments are present; in exceptional cases it persists.

III. THE RETINA

The retina is a delicate nervous membrane, in which the images of external objects are received. Its outer surface is in contact with the chorioid; its inner with the hyaloid membrane of the vitreous body. Posteriorly, it is

CC-0. In Public Domain. Gurukul Kangri Collection, Haridwar

Digitized by Arya Samaj Foundation Chennai and eGangotri

continuous with the optic nerve; it gradually diminishes in thickness from behind forwards, and just behind the ciliary body, it presents a jagged margin, the *ora serrata*. Here the nervous tissues of the retina end, but a thin prolongation of the membrane extends forwards over the back of the ciliary processes and iris, forming the *pars ciliaris retinæ* and *pars iridica retinæ* or *uvea*, already referred to. This forward prolongation consists of the pigmentary layer of the retina together with a stratum of columnar epithelium; in the pars iridica retinæ both layers of epithelium are cubical and pigmented. The retina is soft, translucent, and of a purple tint in the fresh state, owing to the presence of a colouring material named *rhodopsin* or *visual purple*; but it soon becomes clouded, opaque, and bleached when exposed to sunlight. Near the centre of the posterior part of the retina is an oval yellowish area the *macula lutea*, where the visual sense is most perfect; in the macula is a central depression, the *fovea centralis* (fig. 958). At the fovea centralis the retina is exceedingly thin, and the dark colour of the chorioid is distinctly seen through it. About 3 mm. to the nasal side of the macula lutea is the entrance of the optic nerve (*optic disc*) which has a diameter of about 1·5 mm. The circumference of the disc is slightly raised to form the

Fig. 958.—The interior of the posterior half of the bulb of the left eye.

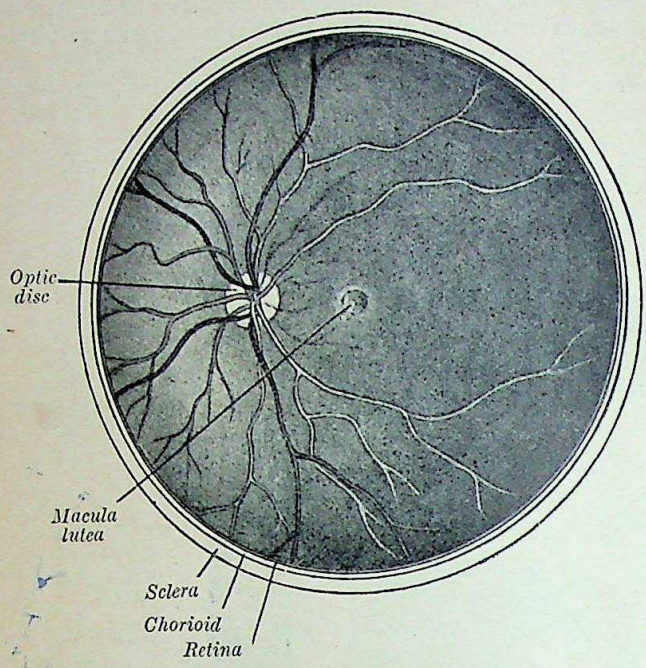

The veins are darker in appearance than the arteries.

Fig. 959.—A horizontal section through the terminal portion of the optic nerve and its entrance into the bulb of the eye. (From Toldt's 'Atlas,' published by Messrs. Rebman, Ltd., London.)

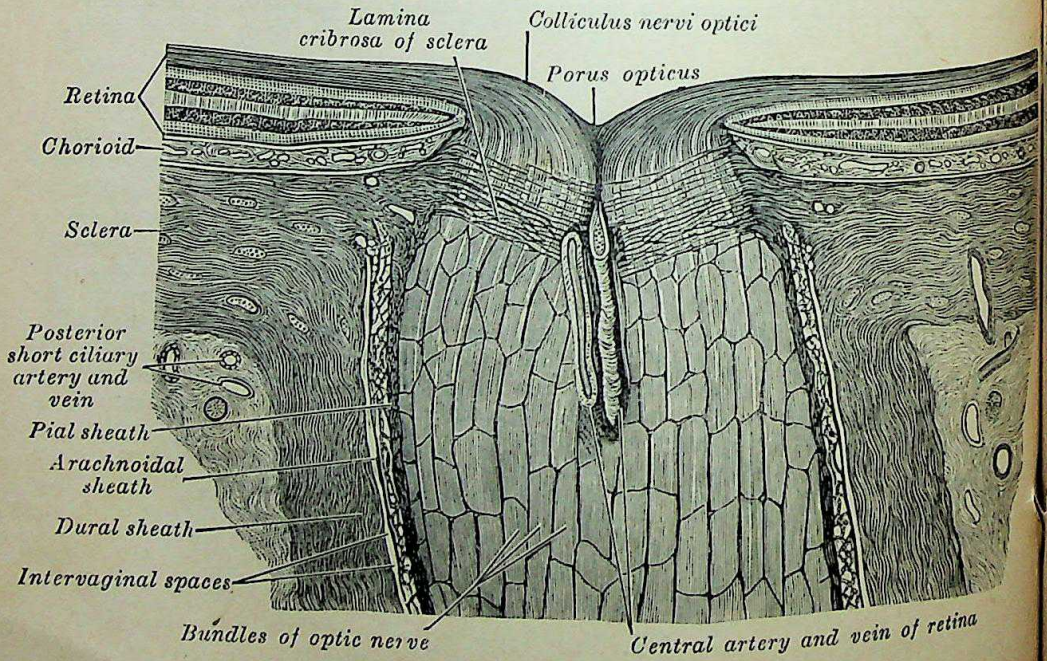

CC-0. In Public Domain. Gurukul Kangri Collection, Haridwar

Digitized by Arya Samaj Foundation Chennai and eGangotri

papilla of the optic nerve, while the central part presents a depression, named the *excavation* of the optic nerve (optic cup). The centre of the disc is pierced by the central artery and vein of the retina. The optic disc is insensitive to light, and is termed the 'blind spot.'

Structure (figs. 960, 961).—The retina consists of an outer pigmented layer and an inner nervous stratum or retina proper.

The **pigmented layer** is a single stratum of cells. When viewed from the outer surface these cells are smooth and hexagonal in shape; when seen in section each cell consists of an outer non-pigmented part containing a large oval nucleus, and an inner pigmented portion which extends as a series of straight thread-like processes between the rods (fig. 961), the amount of pigment between the rods being greater when the eye has been exposed to light. In the eyes of albinos the cells of this layer are destitute of pigment.

FIG. 960.—A section through the retina. (Magnified.)

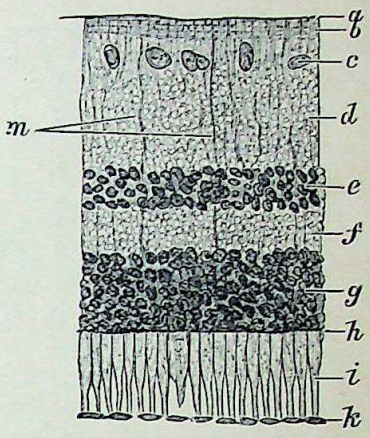

a. Membrana limitans internal *b.* Stratum opticum. *c.* Ganglionic layer. *d.* Inner plexiform layer. *e.* Inner nuclear layer. *f.* Outer plexiform layer. *g.* Outer nuclear layer. *h.* Membrana limitans externa. *i.* Layer of rods and cones. *k.* Pigmented layer. *m.* Fibres of Müller.

Retina proper.—The nervous structures of the retina proper are supported by a series of non-nervous sustentacular fibres, and, when examined microscopically by means of sections made perpendicular to the surface of the retina, are found to consist of seven layers, named from within outwards as follows:

1. Stratum opticum.
2. Ganglionic layer.
3. Inner plexiform layer.
4. Inner nuclear layer.
5. Outer plexiform layer.
6. Outer nuclear layer.
7. Layer of rods and cones.

1. The *stratum opticum* or *layer of nerve-fibres* is formed by the expansion of the fibres of the optic nerve; it is thickest near the optic disc, gradually diminishing towards the ora serrata. As the nerve-fibres pass through the lamina cribrosa scleræ (p. 994), they lose their medullary sheaths and are continued onwards through the chorioid and retina as simple axis-cylinders. When they reach the internal surface of the retina they radiate from their point of entrance over this surface, grouped in bundles which communicate with one another and form an intricate network. Most of the fibres are centripetal, and are the continuations of the axis-cylinder processes of the cells of the ganglionic layer, but a few are centrifugal; these originate in the brain and ramify in the inner plexiform and inner nuclear layers of the retina, where they end in branches.

2. The *ganglionic layer* consists of a single layer of large nerve-cells, except in the macula lutea, where there are several strata. The cells are somewhat flask-shaped, the rounded internal surface of each resting on the stratum opticum, and sending off an axon which is prolonged into it. From the opposite end numerous dendrites extend into the inner plexiform layer, where they form flattened arborisations at different levels. The ganglion-cells vary much in size, and the dendrites of the smaller ones as a rule arborise in the inner plexiform layer as soon as they enter it; while those of the larger cells ramify close to the inner nuclear layer.

3. The *inner plexiform layer* is made up of a dense reticulum of minute fibrils formed by the interlacement of the dendrites of the ganglion-cells with the processes of the cells of the inner nuclear layer; within this reticulum a few branched cells are imbedded.

4. The *inner nuclear layer* is made up of a number of closely packed cells, in which there are three varieties, viz. bipolar cells, horizontal cells, and amacrine cells.

The *bipolar cells*, by far the most numerous, are divisible into rod- and cone-bipolars. They are round or oval in shape, and each is prolonged into an inner and an outer process. The inner processes of the *rod-bipolars* run through the inner plexiform layer and arborise around the outer parts of the cell-bodies of the ganglionic layer; their outer processes end in the outer plexiform layer in tufts of fibrils around the button-like ends of the inner processes of the rod-granules. The inner processes of the *cone-bipolars* ramify in the inner plexiform layer in contact with the dendrites of the ganglionic cells; their outer processes pass into

CC-0. In Public Domain. Gurukul Kangri Collection, Haridwar

Digitized by Arya Samaj Foundation Chennai and eGangotri

the outer plexiform layer, where they divide and form arborisations with the expanded foot-plates of the inner processes of the cone-granules.

The *horizontal cells* lie in the outer part of the inner nuclear layer and possess somewhat flattened cell-bodies. Their dendrites divide into numerous branches in the outer plexiform layer, while their axons run horizontally for some distance and finally ramify in the same layer.

The *amacrine cells* are placed in the inner part of the inner nuclear layer, and were so named under the supposition that they were destitute of axons. It is now known that some, at least, possess axons. Their dendrites undergo extensive ramification in the inner plexiform layer.

FIG. 961.—A plan of the retinal neurons. (After Ramón y Cajal.)

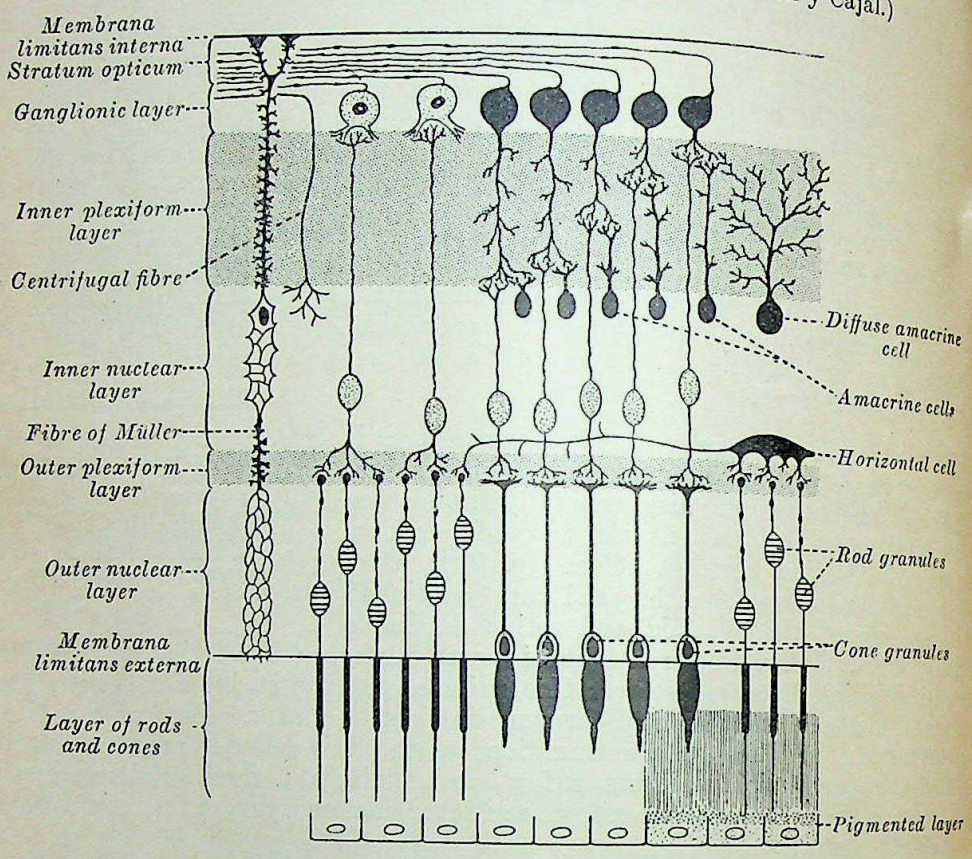

5. The *outer plexiform layer* is much thinner than the inner; but, like it, consists of a dense network of minute fibrils derived from the processes of the horizontal cells, and the outer processes of the rod- and cone-bipolar cells of the preceding layer, which arborise around the enlarged ends of the rod-fibres and the branched foot-plates of the cone-fibres.

6. The *outer nuclear layer.*—Like the inner nuclear layer, this contains several strata of oval cells; they are of two kinds, viz. rod-granules and cone-granules, the former being connected with the rods, the latter with the cones, of the next layer. The *rod-granules* are much the more numerous, and are placed at different levels throughout the layer; in some animals they present a cross-striped appearance. A fine process is prolonged from either extremity of each cell: the outer process is continuous with a rod of the layer of rods and cones; the inner process ends in the outer plexiform layer in an enlarged extremity, and is imbedded in the tuft into which the outer processes of the rod-bipolar cells break up; in its course it presents numerous varicosities. The *cone-granules*, fewer in number than the rod-granules, are placed close to the membrana limitans externa, through which they are continuous with the cones of the layer of rods and cones. Each contains a spheroidal nucleus which almost completely fills the granule. From the inner extremity of each cone-granule a thick process passes into the outer plexiform layer, and there expands into a pyramidal enlargement or foot-plate, from which are given off numerous fine fibrils that come in contact with the outer processes of the cone-bipolars.

CC-0. In Public Domain. Gurukul Kangri Collection, Haridwar

Digitized by Arya Samaj Foundation Chennai and eGangotri

7. *The layer of rods and cones.*—The elements composing this layer are of two kinds, *rods* and *cones*, the former being much more numerous than the latter except in the macula lutea. The *rods* are cylindrical, of nearly uniform thickness, and are arranged perpendicularly to the surface. Each rod consists of two segments, an outer and an inner, of about equal lengths. The segments differ from each other as regards refraction and in their behaviour towards colouring reagents; the inner segment is stained by carmine, iodine, &c.; the outer segment is not stained by these reagents, but is coloured yellowish-brown by osmic acid. The outer segment is marked by transverse striæ, and tends to break up into a number of thin superimposed discs; it also exhibits faint longitudinal markings. The inner part of the inner segment is indistinctly granular; the outer part is longitudinally striated, being composed of fine, highly refracting fibrils. The visual purple or rhodopsin is found only in the outer segments of the rods.

The *cones* are conical, their broad ends resting upon the membrana limitans externa, the pointed extremities being turned to the chorioid. Like the rods, each is made up of two segments, outer and inner; the outer segment is a short conical process, which, like the outer segment of a rod, exhibits transverse striæ. The inner segment resembles the inner segment of a rod in structure, presenting an outer striated and an inner granular part, but differs from it in size and shape, being flask-shaped. The optical characters of the two portions are identical with those of the rods.

Supporting framework of the retina.—The nervous layers of the retina are connected together by a supporting framework, formed by the *sustentacular fibres of Müller*; these fibres pass through all the nervous layers, except that of the rods and cones. Each fibre begins on the inner surface of the retina by an expanded, often forked, base, which sometimes contains a spheroidal body, staining deeply with hæmatoxylin; the edges of the bases of adjoining fibres are united to form the *membrana limitans interna*. As the sustentacular fibres pass through the stratum opticum and the ganglionic layer they send off a few lateral branches; in the inner nuclear layer they give off numerous lateral processes for the support of the bipolar cells, while in the outer nuclear layer they form a network and unite to form the *membrana limitans externa* at the bases of the rods and cones. At the level of the inner nuclear layer each sustentacular fibre contains a clear oval nucleus.

Structure of the macula lutea and fovea centralis.—At the fovea centralis there are no rods, and the cones are longer and thinner than in other parts of the retina. The nerve-fibre layer disappears at the margin of the fovea, and the other retinal layers are extremely thin. The pigment-cells are large and well-marked. At the circumference of the fovea the retina rapidly increases in thickness, so that this part of the macula lutea has a greater depth than any other part of the retina. All the layers are involved in this increase, but especially the ganglionic layer, in which the cells are six to eight deep. The yellow colour of the maculà seems to imbue all the layers except that of the rods and cones; it is deepest towards the centre of the macula, and does not appear to be due to pigment-cells, but simply to a staining of the constituent parts.

At the *ora serrata* the nervous layers of the retina end abruptly, and the retina is continued onwards as a single layer of columnar cells along with the pigmented layer. This double layer is known as the *pars ciliaris retinæ*, and can be traced forwards from the ciliary processes on to the back of the iris, where it is termed the *pars iridica retinæ* or *uvea* (p. 1002).

The *arteria centralis retinæ* (fig. 958) and its accompanying vein pierce the lower and medial aspect of the optic nerve, and enter the bulb of the eye at the centre of the optic disc. The artery immediately bifurcates into an upper and a lower branch, and each of these again divides into a medial or nasal and a lateral or temporal branch, which at first lie between the hyaloid membrane and the nervous layer; but they soon enter the latter, and pass forwards, dividing dichotomously. From these branches a minute capillary branch is given off, which does not extend beyond the inner nuclear layer. The macula receives two small branches (superior and inferior macular arteries) from the temporal branches, and small twigs directly from the central artery; these do not, however, reach as far as the fovea centralis, which has no blood-vessels. The branches of the arteria centralis retinæ do not anastomose with each other—in other words, they are terminal arteries. In the fœtus, a small vessel, the arteria hyaloidea, passes forwards as a continuation of the arteria centralis retinæ through the vitreous humour to the posterior surface of the capsule of the lens.

CC-0. In Public Domain. Gurukul Kangri Collection, Haridwar

Digitized by Arya Samaj Foundation Chennai and eGangotri

The Refracting Media of the Eye

The refracting media of the eye are the aqueous humour, the vitreous body, and the crystalline lens.

I. The Aqueous Humour

The **aqueous humour** fills the anterior and posterior chambers of the bulb of the eye (p. 1000). It is small in quantity, has an alkaline reaction, and is mainly a dilute watery solution of chloride of sodium. It is secreted by the ciliary processes into the posterior chamber, and escapes from the filtration angle of the anterior chamber through the spaces of the angle of the iris (spaces of Fontana) and the sinus venosus scleræ (canal of Schlemm) into the anterior ciliary veins.

II. The Vitreous Body

The **vitreous body** (fig. 948) occupies about four-fifths of the bulb of the eye. It fills the concavity of the retina, and is hollowed in front, forming a deep concavity, the *hyaloid fossa*, for the reception of the lens. It is transparent, of the consistence of thin jelly, and is enclosed in a delicate transparent membrane, the *hyaloid membrane*. It has been supposed by Hannover, that from the surface of the hyaloid membrane numerous thin lamellæ are prolonged inwards in a radiating manner, forming spaces in which the jelly is contained. In the adult, these lamellæ cannot be detected even after careful microscopical examination in the fresh state, but in preparations hardened in weak chromic acid it is possible to make out a distinct lamellation at the periphery of the vitreous body. Running forwards through the vitreous body from the entrance of the optic nerve to the posterior surface of the lens, is the *hyaloid canal*, filled with lymph and lined by a prolongation of the hyaloid membrane. In the embryonic vitreous body this canal conveyed the arteria hyaloidea from the central artery of the retina to the back of the lens.

The vitreous body consists of 98·6 per cent. of water, with some salts, and a little protein.

The *hyaloid membrane* envelops the vitreous body. The portion in front of the ora serrata is thickened by the accession of radial fibres and is termed the *zonula ciliaris* or *zonule of Zinn*. Here it presents a series of radially arranged furrows, in which the ciliary processes are accommodated and to which they adhere, as is shown by the fact that when they are removed some of their pigment remains attached to the zonula. The zonula ciliaris splits into two layers, one of which is thin and lines the hyaloid fossa of the vitreous body; the other, named the *suspensory ligament of the lens*, is thicker, and passes over the ciliary body to be attached to the capsule of the lens a short distance in front of its equator. Scattered and delicate fibres are also attached to the region of the equator itself. This ligament retains the lens in position, and is relaxed by the contraction of the meridional fibres of the Ciliaris muscle, so that the lens is allowed to become more convex. Behind the suspensory ligament there is a sacculated canal, the *spatia zonularia* or *canal of Petit*, which encircles the equator of the lens; it can be easily inflated through a fine blowpipe inserted under the suspensory ligament.

No blood-vessels penetrate the vitreous body; so that its nutrition must be carried on by the vessels of the retina and ciliary processes, situated upon its exterior.

III. The Crystalline Lens

The **crystalline lens** (fig. 948), enclosed in its capsule, is situated immediately behind the iris, in front of the vitreous body, and is encircled by the ciliary processes, which slightly overlap its margin.

The *capsule of the lens* is a transparent, structureless membrane which closely surrounds the lens and is thicker in front than behind. It is brittle

CC-0. In Public Domain. Gurukul Kangri Collection, Haridwar

Digitized by Arya Samaj Foundation Chennai and eGangotri

highly elastic, and when ruptured the edges roll up with the outer surface outermost. The lens rests, behind, in the hyaloid fossa on the fore-part of the vitreous body; in front, it is in contact with the free border of the iris, but recedes from it at the circumference, thus forming the posterior chamber of the eye; it is retained in its position chiefly by the suspensory ligament already described.

The *lens* is a transparent, biconvex body, the convexity of its anterior being less than that of its posterior surface. The central points of these surfaces are termed respectively the *anterior* and *posterior poles*; a line connecting the poles constitutes the *axis* of the lens, while the marginal circumference is termed the *equator*.

FIG. 962.—The crystalline lens, hardened and divided. (Enlarged.)

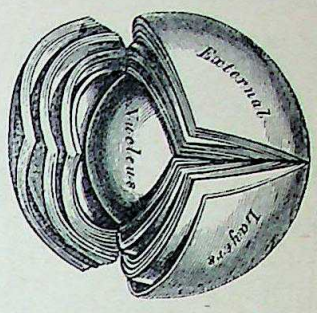

Structure.—The lens is made up of soft cortical substance and a firm, central part, the nucleus (fig. 962). Faint lines (radii lentis) radiate from the poles to the equator. In the adult there may be six or more of these lines, but in the fœtus there are only three, and these diverge from each other at angles of 120° (fig. 963); on the anterior surface one line ascends vertically and the other two diverge downwards; on the posterior surface one line descends vertically and the other two diverge upwards. These lines correspond with the free edges of an equal number of septa composed of an amorphous substance, which dip into the substance of the lens. When the lens has been hardened it is seen to consist of a series of concentrically arranged laminæ, each of which is interrupted at the septa referred to. Each lamina is built up of a number of ribbon-like lens-fibres, the edges of which are more or less serrated—the serrations fitting between those of neighbouring fibres, while the ends of the fibres come into apposition at the septa. The fibres run in a curved manner from the septa on the anterior surface to those on the posterior surface. No fibres pass from pole to pole; they are arranged in such a way that those which begin near the pole on one surface of the lens end near the peripheral extremity of the plane on the other, and vice versa. The fibres of the outer layers of the lens are nucleated, and together form a nuclear layer, most distinct towards the equator. The anterior surface of the lens is covered by a layer of transparent, nucleated columnar epithelium. At the equator the cells become elongated, and their gradual transition into lens-fibres can be traced (fig. 965).

FIG. 963.—A diagram showing the direction and arrangement of the radiating lines on the front and back of the fœtal lens. A. On the front. B. On the back.



FIG. 964.—Profile views of the lens at different periods of life.

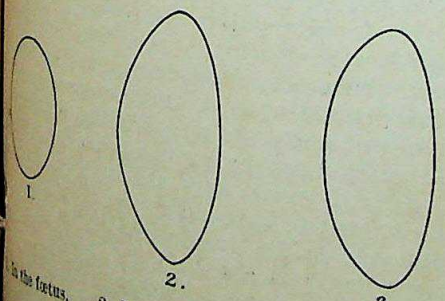

1. In the fœtus. 2. In adult life. 3. In old age.

In the fœtus, the lens is nearly spherical, and has a slightly reddish tint; it is soft, and breaks down readily on the slightest pressure. A small branch (arteria hyaloidea) from the arteria centralis retinæ runs forwards through the vitreous

CC-0. In Public Domain. Gurukul Kangri Collection, Haridwar

Digitized by Arya Samaj Foundation Chennai and eGangotri

body to the posterior part of the capsule of the lens, where its branches radiate, forming a plexiform network which covers the posterior surface of the capsule, and is continuous round the margin of the capsule with the vessels of the pupillary membrane and with those of the iris. *In the adult* the lens is colourless, transparent, firm in texture, and devoid of vessels. *In old age*, it becomes flattened on both surfaces, slightly opaque, of an amber tint, and increased in density (fig. 964).

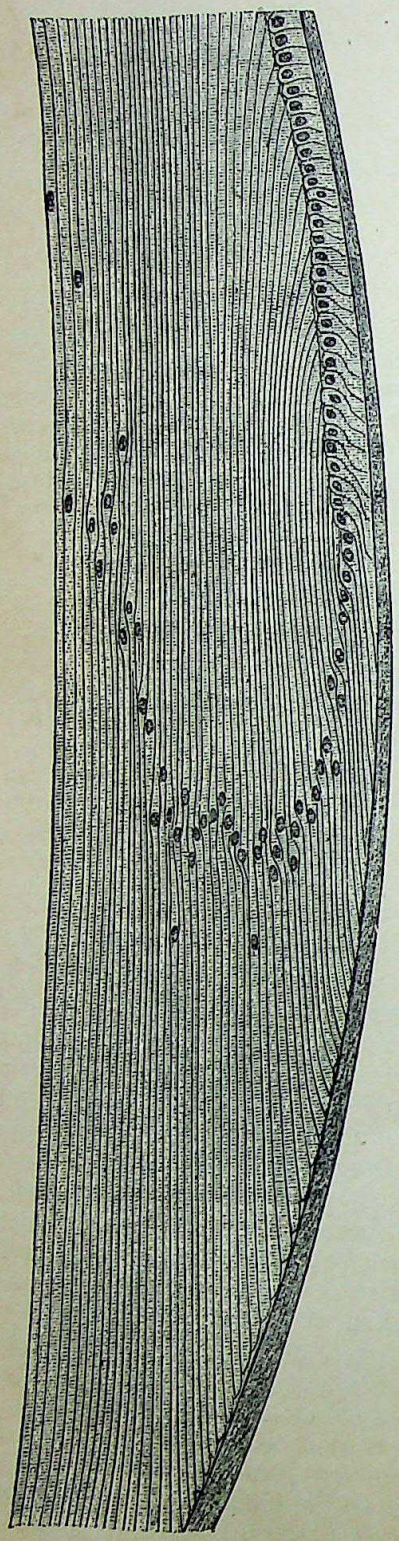

FIG. 965.—A section through the margin of the lens, showing the transition of the columnar epithelium into the lens-fibres. (Babuchin.)

Vessels and Nerves.—The *arteries* of the bulb of the eye are the long, short, and anterior ciliary arteries, and the arteria centralis retinæ. They have already been described (p. 627).

The *ciliary veins* are seen on the outer surface of the chorioid, and are named, from their arrangement, the *venæ vorticosæ*; they converge to four or five equidistant trunks which pierce the sclera midway between the sclerocorneal junction and the porus opticus. Another set of veins accompanies the anterior ciliary arteries. All these veins open into the ophthalmic veins.

The *ciliary nerves* are derived from the nasociliary nerve and from the ciliary ganglion.

Applied Anatomy.—From a surgical point of view the cornea may be regarded as consisting of three layers: (1) an external epithelial layer, developed from the ectoderm, and continuous with the epithelial covering of the rest of the body, so that its lesions resemble those of the epidermis; (2) the cornea proper, derived from the mesoderm, and associated in its diseases with the fibrovascular structures of the body; and (3) the posterior elastic lamina with its endothelium, also derived from the mesoderm and having the characters of a serous membrane, so that inflammation of it resembles inflammation of the serous and synovial membranes of the body.

The cornea contains no blood-vessels except at its periphery, where numerous delicate loops, derived from the anterior ciliary arteries, may be demonstrated on its anterior surface. The rest of the cornea is nourished by lymph, which gains access to the proper substance of the cornea and the posterior layer through the spaces of the angle of the iris. This lack of a direct blood-supply renders the cornea very apt to inflame in the cachectic and ill-nourished. In cases of *granular lids*, there is a peculiar affection of the cornea, called *pannus*, in which the anterior layers of the cornea become vascularised, and a rich network of blood-vessels may be seen upon it; and in *interstitial keratitis* new vessels extend into the cornea, giving it a pinkish hue to which the term 'salmon patch' is applied. In cases of glaucoma the ciliary nerves may be pressed upon as they course between the chorioid and sclera, the cornea becoming anæsthetic.

The sclera has very few blood-vessels and nerves. As the blood-vessels approach the corneal margin the arrangement is peculiar. Some branches pass through the sclera to the ciliary body; others become superficial and lie in the episcleral tissue, and form arches by anastomosing with each other some little distance behind the corneal margin. From these arches numerous straight vessels are given off, which run forwards to the cornea, forming its marginal plexus. In inflammation of the sclera and episcleral tissue these vessels become conspicuous, and form a pinkish zone of straight vessels radiating from the corneal margin, commonly known as the *zone of ciliary injection*. In inflammation of the iris and ciliary body this zone is present, since the sclera speedily

CC-0. In Public Domain. Gurukul Kangri Collection, Haridwar

Digitized by Arya Samaj Foundation Chennai and eGangotri

tissues involved when these structures are inflamed. But in inflammation of the cornea the sclera is seldom much affected, though the two are structurally continuous. This would appear to be due to the fact, that the nutrition of the cornea is derived from a different source than that of the sclera. The sclera may be ruptured without any laceration of the conjunctiva, and the rupture usually occurs near the corneal margin. It may be complicated with lesions of adjacent parts—laceration of the chorioid, retina, iris, or suspensory ligament of the lens—and is then often attended with hæmorrhage into the anterior chamber, which marks the nature of the injury. In some cases the lens has escaped through the rent in the sclera. Wounds of the sclera are always dangerous, and are often followed by inflammation, suppuration, and by sympathetic ophthalmia.

One of the functions of the chorioid is to provide nutrition for the retina, and to convey vessels and nerves to the ciliary body and iris. Inflammation of the chorioid is therefore followed by grave disturbances in the nutrition of the retina, and is attended with early interference with vision. Its diseases bear a considerable analogy to those which affect the skin, and it is one of the places from which melanotic sarcomata may grow. These tumours contain a large amount of pigment in their cells, and originate only in those parts where pigment is naturally present.

The iris may be absent, either in part or altogether, as a congenital condition, and in some instances the pupillary membrane may persist though rarely as a complete structure. Again, the iris may be the seat of malformation, termed *coloboma*, which consists of a deficiency or cleft, clearly due in a great number of cases to an arrest in development. In these cases the cleft is found at the lower aspect, extending directly downwards from the pupil, and the gap frequently extends through the chorioid to the porus opticus. Wounds of the iris, especially if complicated with injury to the ciliary body, may be followed by serious consequences. If septic matter is introduced, and a suppurative inflammation is set up, complete loss of vision may result; and, what is perhaps of greater consequence, similar inflammatory changes may be set up in the sound eye. The iris is abundantly supplied with blood-vessels and nerves, and is very prone to become inflamed, and when inflamed, in consequence of the intimate relationship which exists between the vessels of the iris and chorioid, this latter tunic is very liable to participate in the inflammation. The iris is covered with epithelium, and partakes of the character of a serous membrane, and like these structures, is apt to pour out a plastic exudation when inflamed, and contract adhesions, either to the cornea in front (*synechia anterior*), or to the capsule of the lens behind (*synechia posterior*). In iritis the lens may become involved, and the condition known as secondary cataract may be set up.

The retina, with the exception of its pigment layer and its vessels, is perfectly transparent. In retinitis there is more or less dense opacity of its structure, and not infrequently extravasations of blood into its substance. Hæmorrhages may also take place into the retina, from rupture of a blood-vessel without inflammation. The retina may become detached from effusion of serum between it and the chorioid, or by blows on the eyeball; but detachment of the retina may occur without apparent cause in progressive myopia. Glioma, a form of sarcoma, is occasionally met with in the retina.

The lens has no blood-vessels, nerves, or connective tissue in its structure, and therefore is not subject to those morbid changes to which tissues containing these structures are liable. Opacities may occur from injury, senile changes, or malnutrition. These opacities give rise to *cataract*, of which the senile variety is the most common. They vary as to the part of the lens in which the opacity commences, and are classified accordingly, as nuclear, cortical, lamellar, anterior and posterior polar. Senile changes may take place in the lens, impairing its elasticity and rendering it harder than in youth, so that it loses its power of altering its curvature to suit the requirements of near vision. This condition is known as *presbyopia*. The lens may be dislocated or displaced by blows upon the eyeball; and its relations to surrounding structures altered by adhesions or the pressure of new growths.

There are two particular regions of the eye which require special notice: one of these is known as the 'filtration angle,' and the other as the dangerous 'area.' The *filtration angle* is the circumcorneal zone immediately in front of the iris. Here are situated the spaces of the angle of the iris, which communicate with the sinus venosus scleræ through which the chief transudation of fluid from the eye is believed to take place. If any obstruction to this transudation occur, increased intra-ocular tension is set up, and the disease known as *glaucoma* results. The *dangerous area of the eye* is the region in the neighbourhood of the ciliary body, and wounds or injuries in this situation are peculiarly dangerous; for inflammation of the ciliary body is apt to spread to many of the other structures of the eye, especially to the iris and chorioid, which are intimately connected with it by nervous and vascular supplies.

CC-0. In Public Domain. Gurukul Kangri Collection, Haridwar

Digitized by Arya Samaj Foundation Chennai and eGangotri

The Accessory Organs of the Eye

The accessory organs of the eye include the ocular muscles, the fasciæ, the eyebrows, the eyelids, the conjunctiva, and the lacrimal apparatus.

The Ocular Muscles

The ocular muscles are the :

Levator palpebræ superioris.
Rectus superior.
Rectus inferior.
Rectus medialis.
Rectus lateralis.
Obliquus superior.
Obliquus inferior.

The **Levator palpebrae superioris** (figs. 966, 967) is thin, and triangular in shape. It arises from the under surface of the small wing of the sphenoidal bone, above and in front of the optic foramen, from which it is separated

Fig. 966.—A sagittal section through the right orbital cavity.

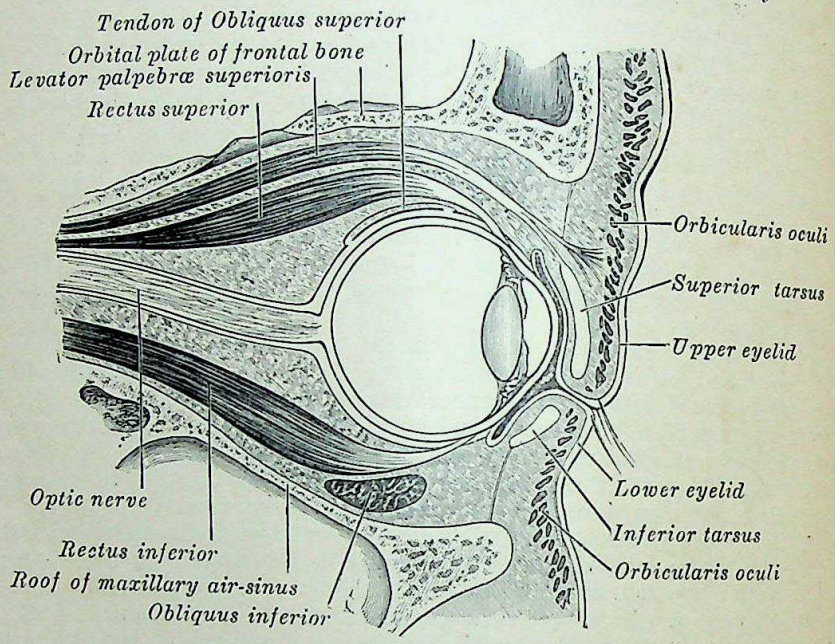

by the origin of the Rectus superior. At its origin, it is narrow and tendinous but soon becomes broad and fleshy, the medial margin of the muscle being almost straight, while the lateral margin is concave. The muscle ends anteriorly in a wide aponeurosis which splits into two lamellæ. The uppermost fibres of the superficial lamella blend with the upper part of the orbital septum ; the lowermost fibres are attached to the anterior surface of the superior tarsus, while the intermediate fibres radiate and pass through the overlying Orbicularis oculi to the skin of the upper eyelid. The deep lamella consists of non-striped muscular fibres and is known as *Müller's muscle* * ; it is attached directly to the upper margin of the superior tarsus and is covered by conjunctiva on its inferior surface. The space between the superficial and deep lamellæ is termed the *pretarsal space* (fig. 967).

The fascial sheaths of the Levator palpebræ superioris and Rectus superior fuse. Where the two muscles separate to reach their insertions, the fascia between them forms a thick mass which is fixed to the superior conjunctival fornix and is described as an additional insertion of the Levator palpebræ superioris. When traced laterally the aponeurosis of the Levator palpebræ superioris passes between the upper and lower parts of the lacrimal gland, and is fixed to a tubercle on the zygomatic bone, just within the

* H. Müller also described a layer of non-striped muscle in the lower eyelid, where it unites the inferior tarsus to the Obliquus inferior.

CC-0. In Public Domain. Gurukul Kangri Collection, Haridwar

Digitized by Arya Samaj Foundation Chennai and eGangotri

...d margin p. 240). Deep to this attachment is that of the lateral palpebral ligament ...h fixes the tarsal plates to the same tubercle. When traced medially the aponeurosis ...s its tendinous nature as it passes over and comes into close contact with the reflected ...on of the Obliquus superior, whence it can be followed with difficulty towards the ...al palpebral ligament in the form of loose strands of connective tissue. When the

FIG. 967.—A diagram of the Levator palpebræ superioris, showing its connexions. (*From Whitnall's "Anatomy of the human orbit"*; Oxford Medical Publications.)

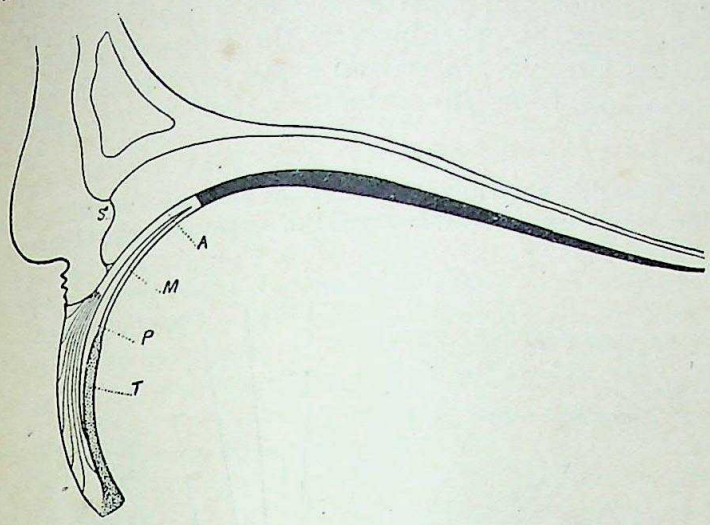

A, Superficial lamella of aponeurosis; *M*. Deep lamella (Müller's muscle); *P*, Pretarsal space; *T*, Tarsus; *S*. Orbital septum.

...vator palpebræ contracts the upper eyelid is raised, but the lateral and medial parts of ...e aponeurosis are stretched and limit the action of the muscle; the elevation of the ...per eyelid is checked also by the orbital septum.

The four **Recti** (figs. 968, 969) arise from the annulus tendineus communis, ...fibrous ring which surrounds the upper, medial, and lower margins of the

FIG. 968.—The muscles of the right orbit. Lateral aspect.

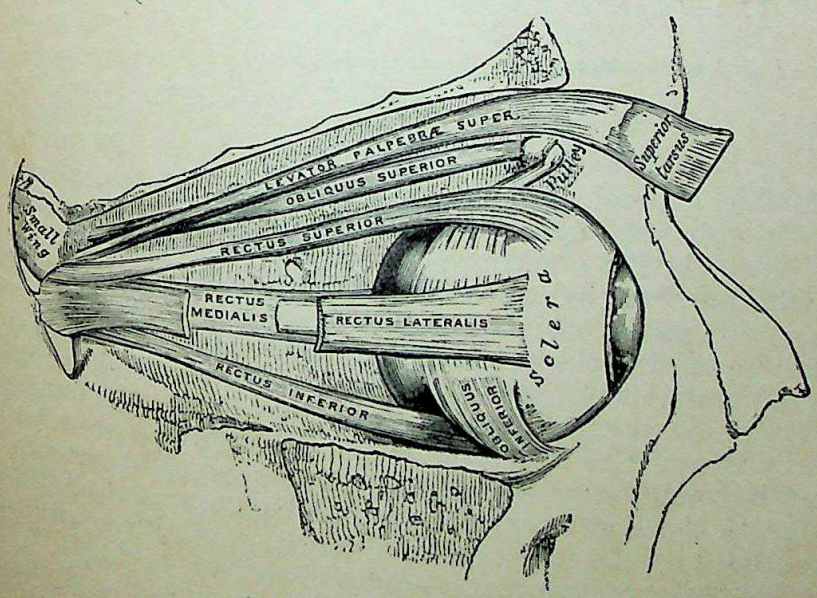

...ic foramen (fig. 969); it is completed by a tendinous band which bridges ...e lower and medial part of the superior orbital fissure and is attached to a ...bercle on the margin of the great wing of the sphenoidal bone. The ring is

CC-0. In Public Domain. Gurukul Kangri Collection, Haridwar

Digitized by Arya Samaj Foundation Chennai and eGangotri

closely adherent to the sheath of the optic nerve and to the surrounding periosteum; within it are (1) the optic foramen containing the optic nerve and ophthalmic artery, and (2) the medial end of the superior orbital fissure which transmits the two divisions of the oculomotor nerve, the nasociliary nerve, and the abducent nerve. The superior ophthalmic vein may pass through, or above, the ring; the inferior ophthalmic vein through, or below, the ring. Two specialised parts of this fibrous ring may be made out: a lower, the *ligament or tendon of Zinn*, which gives origin to the Rectus inferior, a part of the Rectus medialis, and the lower fibres of the Rectus lateralis; and an upper, sometimes termed the *superior tendon of Lockwood*, which gives origin to the Rectus superior, the other part of the Rectus medialis, and the upper fibres of the Rectus lateralis; a second small tendinous head of origin of the Rectus lateralis arises from the orbital surface of the great wing of the

Fig. 969.—A dissection showing the origins of the right ocular muscles, and the nerves entering the orbit through the superior orbital fissure. Anterior aspect.

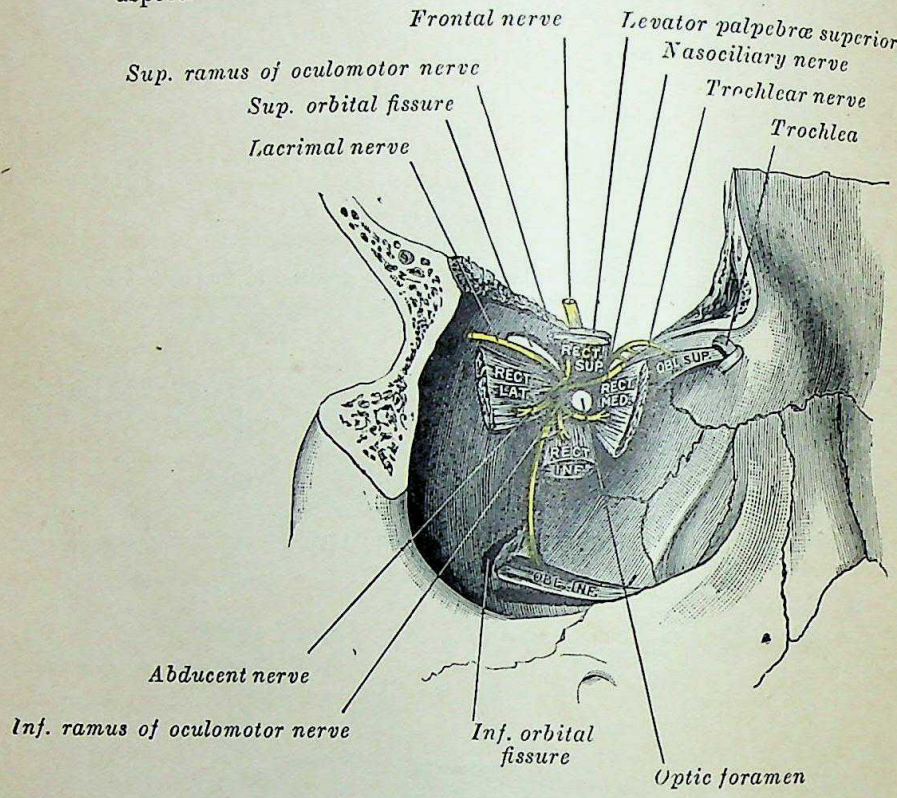

sphenoidal bone, lateral to the annulus tendineus. Each muscle passes forward in the position implied by its name, to be inserted by a tendinous expansion into the sclera, about 6 mm. from the margin of the cornea.*

The **Obliquus oculi superior** is a fusiform muscle, placed at the upper and medial side of the orbit. It arises immediately above the optic foramen, superior and medial to the origin of the Rectus superior, and, passing forwards, ends in a round tendon, which plays in a fibrocartilaginous ring or pulley attached to the fovea trochlearis of the frontal bone. The contiguous surfaces of the tendon and ring are lubricated by a delicate mucous sheath. After traversing the pulley the tendon passes backwards, lateralwards, and downwards beneath the Rectus superior, to the lateral part of the bulb of the eye, and is inserted into the sclera, behind the equator of the eyeball, and between the Rectus superior and Rectus lateralis.

The **Obliquus oculi inferior** is a thin, narrow muscle, placed near the anterior margin of the floor of the orbit. It arises from the orbital surface of

* The average distances of the insertions of the Recti from the margin of the cornea are: Rectus medialis, 5·5 mm.; Rectus inferior, 6·5 mm.; Rectus lateralis, 6·9 mm.; Rectus superior, 7·7 mm.

CC-0. In Public Domain. Gurukul Kangri Collection, Haridwar

Digitized by Arya Samaj Foundation Chennai and eGangotri

the maxilla lateral to the lacrimal groove. Passing lateralwards, backwards, and upwards, at first between the Rectus inferior and the floor of the orbit, and then between the bulb of the eye and the Rectus lateralis, it is inserted into the lateral part of the sclera between the Rectus superior and Rectus lateralis, near to, but somewhat behind, the insertion of the Obliquus superior.

Nerves.—The Levator palpebræ superioris, the Obliquus inferior, and the Recti superior, inferior, et medialis are supplied by the oculomotor nerve; the Obliquus superior, by the trochlear nerve; the Rectus lateralis, by the abducent nerve.—

Actions.—The Levator palpebræ raises the upper eyelid, and is the direct antagonist of the Orbicularis oculi. The four Recti are attached to the bulb of the eye in such a manner that, acting singly, they will turn its corneal surface either upwards, downwards, medialwards, or lateralwards, as expressed by their names. The movement produced by the Rectus superior and by the Rectus inferior is not quite a simple one, for inasmuch as each passes obliquely lateralwards and forwards to the bulb of the eye, the elevation or depression of the cornea is accompanied by a certain deviation medialwards, with a slight amount of rotation. These latter movements are corrected by the Obliqui, the Obliquus inferior correcting the medial deviation caused by the Rectus superior, and the Obliquus superior that caused by the Rectus inferior. The contraction of the Rectus lateralis or Rectus medialis, on the other hand, produces a purely horizontal movement. If any two neighbouring Recti of one eye act together they carry the globe of the eye in the diagonal of these directions, viz. upwards and medialwards, upwards and lateralwards, downwards and medialwards, or downwards and lateralwards. Sometimes the corresponding Recti of the two eyes act in unison, and at other times the opposite Recti act together. Thus, in turning the eyes to the right, the Rectus lateralis of the right eye acts in unison with the Rectus medialis of the left eye; but if both eyes are directed to an object in the middle line at a short distance, the two Recti medialis act in unison. The movement of circumduction, as in looking round a room, is performed by the successive actions of the four Recti. The Obliqui rotate the bulb of the eye on its anteroposterior axis, the superior directing the cornea downwards and lateralwards, and the inferior directing it upwards and lateralwards; these movements are required for the correct viewing of an object when the head is moved laterally, as from shoulder to shoulder, in order that the picture may fall in all respects on the same part of the retina of either eye.

A layer of non-striped muscle, the *Orbitalis muscle*, bridges the inferior orbital fissure.

The **fascia bulbi** (capsule of Tenon) (figs. 970, 971) is a thin membrane which envelops the bulb of the eye from the optic nerve to the corneoscleral junction, separating it from the orbital fat and forming a socket in which it plays. Its inner surface is smooth, and is separated from the outer surface of the sclera by the *episcleral space*; this space is traversed by delicate bands of connective tissue which extend between the fascia and the sclera. The fascia is perforated behind by the ciliary vessels and nerves, and fuses with the sheath of the optic nerve and with the sclera around the entrance of the optic nerve. In front it blends with the sclera just behind the corneoscleral junction. It is perforated anteriorly by the tendons of the ocular muscles, and is reflected backwards on each as a tubular sheath. The sheath of the Obliquus superior is carried as far as the fibrous pulley of that muscle; that on the Obliquus inferior reaches as far as the floor of the orbit, to which it gives off a slip. The sheaths on the Recti are gradually lost in the perimysium, but they give off important expansions. The expansion from the Rectus superior blends with the tendon of the Levator palpebræ superioris; that of the Rectus inferior is attached to the inferior tarsus. The expansions from the sheaths of the Recti medialis et lateralis are strong and triangular in shape, and are attached to the lacrimal and zygomatic bones respectively. As they probably check the actions of these two Recti they have been named the *medial* and *lateral check ligaments*. Lockwood * described a thickening of the lower part of the fascia bulbi, which he named the *suspensory ligament of the eye*; it is slung like a hammock below the eyeball, being expanded in the centre, and narrow at its extremities; it is formed by the union of the margins of the sheath of the Rectus inferior with the medial and lateral check ligaments.

* C. B. Lockwood, *Journal of Anatomy and Physiology*, vol. xx.

CC-0. In Public Domain. Gurukul Kangri Collection, Haridwar

Digitized by Arya Samaj Foundation Chennai and eGangotri

FIG. 970.—A scheme of the fascia of the orbit (the muscle-sheaths and the fascia bulbi) in sagittal section. (*From Whitnall's "Anatomy of the human orbit"*; Oxford Medical Publications.)

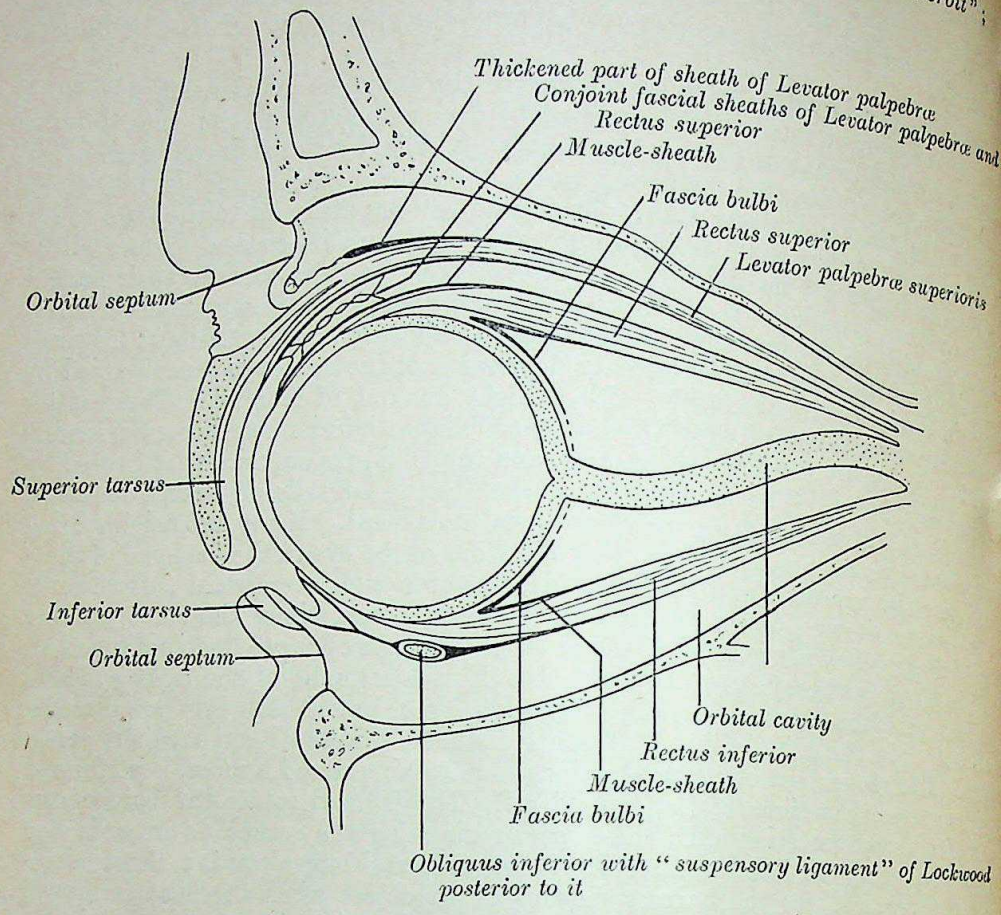

FIG. 971.—A schematic view of a horizontal section through the right orbit to illustrate the fascia of the orbit. (*From Whitnall's "Anatomy of the human orbit"*; Oxford Medical Publications.)

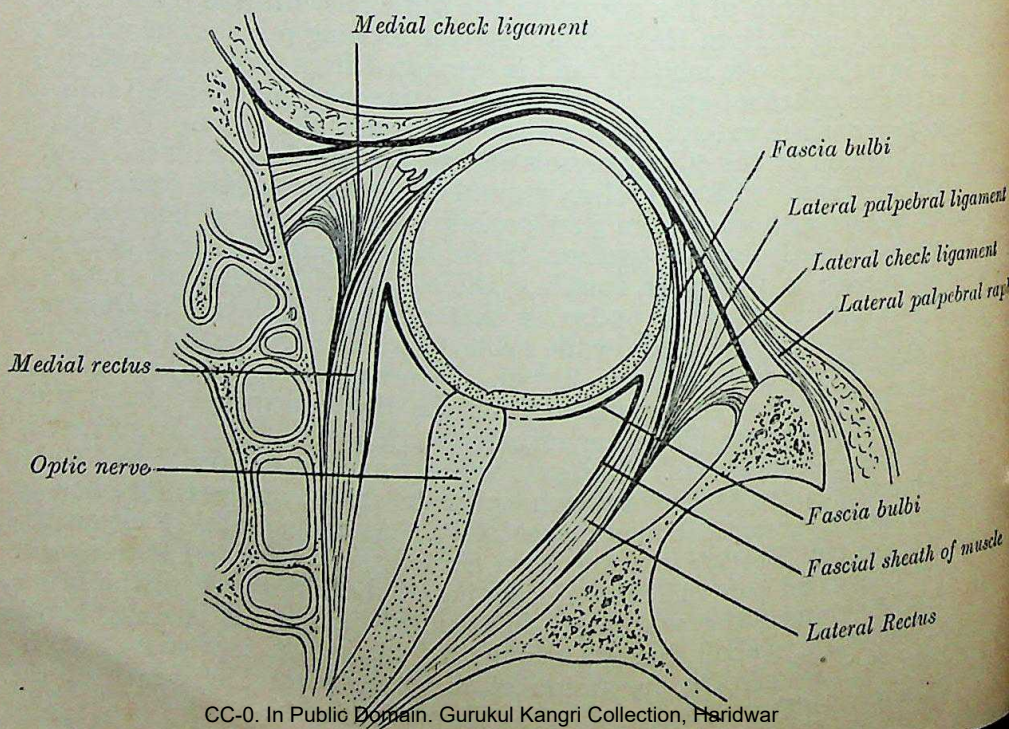

CC-0. In Public Domain. Gurukul Kangri Collection, Haridwar

Digitized by Arya Samaj Foundation Chennai and eGangotri

The **orbital fascia** forms the periosteum of the orbit, but is loosely con-
ed to the bones. Behind, it is united with the dura mater and with the
ath of the optic nerve. In front, it is connected with the periosteum at the
rgin of the orbit, and sends off a stratum which assists in forming the orbital
um. From it two processes are given off: one holds the pulley of the
liquus superior in position, the other, named the *lacrimal fascia*, forms the
d and lateral wall of the fossa in which the lacrimal sac is lodged (p. 1020).

Applied Anatomy.—The positions and exact areas of insertion of the tendons of the
is medialis and lateralis into the bulb of the eye should be carefully examined from
front, as the surgeon is often required to divide one or other of the muscles for the
of strabismus. In convergent strabismus, which is the more common form of the
ase, the eye is turned medialwards, which may require the division of the Rectus
alis. In the divergent form, which is more rare, the eye is turned lateralwards, the
us lateralis being especially implicated. If the deformity produced in either case
marked, it may be remedied
division of one or the other
cle. The operation is thus
rmed: the lids are to be
separated; the eyeball is
ed lateralwards or medial-
, and the conjunctiva
d by a pair of forceps, and
d immediately beneath the
r border of the tendon of the
cle to be divided, a little
d its insertion into the
; the submucous areolar
ue is then divided, and into
small aperture thus made,
nt hook is passed upwards
ween the muscle and the
, and the tendon of the
cle divided by a pair of
t-pointed scissors passed
ween the hook and the bulb.
The converse operation is
t of *advancement*, in which
her the Rectus medialis or
us lateralis (depending on
e form of strabismus) is
ened. The muscle is exposed in a similar manner; its tendon is divided, and
ned to the globe of the eye in front of its previous site of attachment.

Fig. 972.—The front of the left eye with the eyelids separated to show the plica semilunaris, caruncula lacrimalis and puncta lacrimalia.

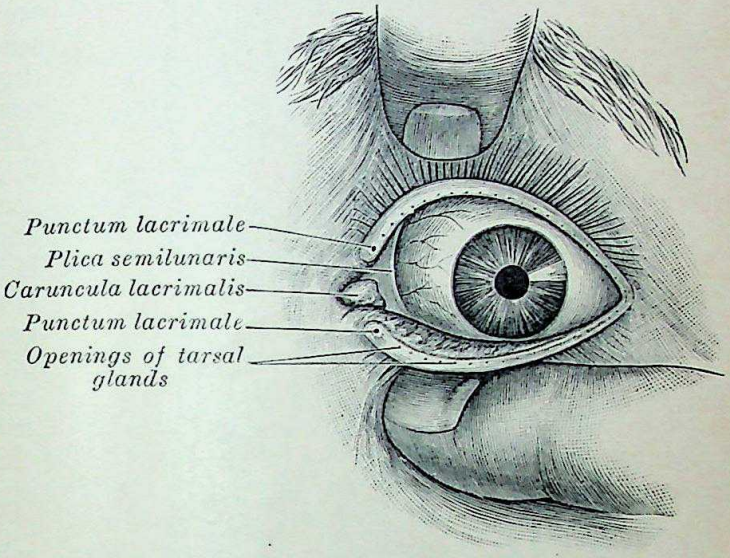

Removal of the eyeball is effected by dividing the conjunctiva all round with scissors
its attachment to the cornea, after which each ocular muscle in turn is picked up on a
nt hook and divided close to the sclera. The optic nerve is then divided with curved
ors passed to the back of the orbit; it should be remembered that the perineural
ths from the meninges are opened by this manœuvre.

Exophthalmos, or abnormal protrusion of the eyeball, is usually bilateral. It is
most always present in exophthalmic goitre or Graves' disease, in which it is due to
rmal stimulation of the cervical sympathetic nerves producing spasm of Müller's
cle, which passes between the eyeball and the eyelids. Less often it results from
ous congestion of the orbital veins due to thrombosis of the cavernous sinuses.
lateral exophthalmos is rare, and is caused by orbital cellulitis, periostitis, or new
wth, or by traumatic arterial or arteriovenous aneurysm of the carotid artery behind
e orbit. Intermittent exophthalmos, occurring only when the head is depressed, is very
e, and is due to the presence of varicose veins in the orbit.

In hydrocephalus the eyeball may be forced down so low in the orbit, through depres-
n of the orbital plate of the frontal bone by the accumulation of fluid within the brain,
the patient, usually an infant, loses his sight because the pupil comes to lie below the
er eyelid even when the eye is open.

The **eyebrows** are two arched eminences of skin, which surmount the orbits,
support numerous short, thick hairs directed obliquely on the surface.
ons of the Orbicularis oculi, Corrugator, and Frontalis muscles are inserted
the skin of the eyebrows.

The **eyelids or palpebrae** are two thin, movable folds, placed in front
the eye, and protecting it, by their closure, from injury. The upper eyelid
e larger and more movable, and is furnished with an elevator muscle, the
tor palpebræ superioris (p. 1010); the two eyelids unite with one another
their extremities to form the medial and lateral *palpebral commissures*.

CC-0. In Public Domain. Gurukul Kangri Collection, Haridwar

Digitized by Arya Samaj Foundation Chennai and eGangotri

When the eyelids are open, an elliptical space, the palpebral fissure (*rima palpebrarum*) is left between their margins; the extremities of the fissure are called the angles or canthi.

The *lateral angle* or *canthus* is more acute than the medial, and lies in closer contact with the bulb of the eye. The *medial angle* is prolonged for a short distance towards the nose, and is about 6 mm. away from the bulb of the eye; the two eyelids are here separated by a triangular space, the *lacus lacrimalis*, in which is situated a small reddish body, the *caruncula lacrimalis* (fig. 972). On the margin of each eyelid, at the basal angles of the lacus lacrimalis, is a small conical elevation, the *lacrimal papilla*, the apex of which is pierced by a minute orifice, the *punctum lacrimale*, the commencement of the lacrimal duct.

Fig. 973.—A sagittal section through the upper eyelid. (After Waldeyer.)

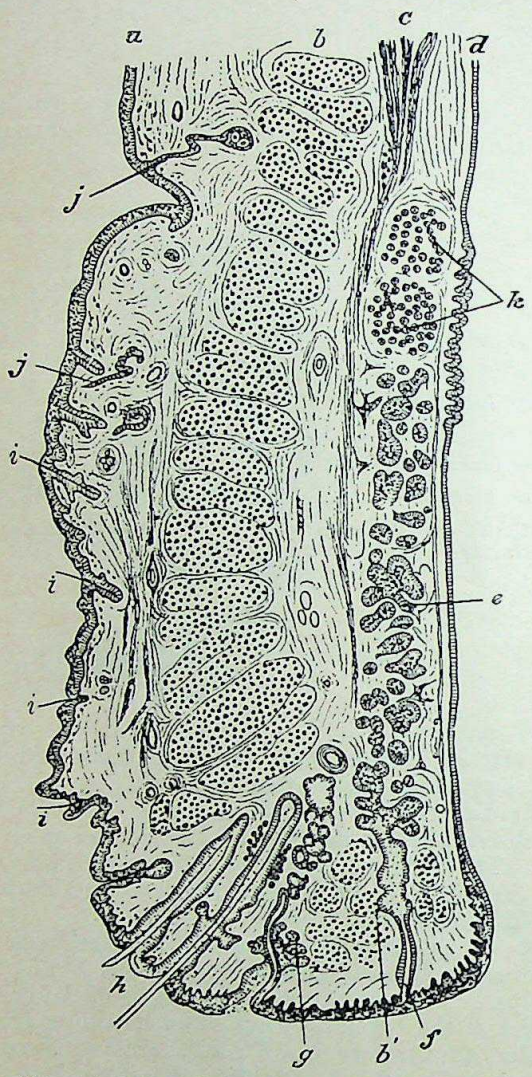

a. Skin. *b*. Orbicularis oculi. *b'*. Marginal fasciculus of the Orbicularis oculi (ciliary bundle). *c*. Levator palpebræ superioris. *d*. Conjunctiva. *e*. Tarsal glands. *f*. Opening of a tarsal gland. *g*. Sebaceous gland. *h*. Eyelashes. *i*. Small hairs of the skin. *j*. Sweat-gland. *k*. Posterior tarsal glands.

The *eyelashes* are attached to the free edges of the eyelids from the lateral palpebral commissure to the lacrimal papillæ. They are short, thick, curved hairs arranged in double or triple rows; those of the upper eyelid, more numerous and longer than those of the lower, curve upwards; those of the lower eyelid curve downwards, so that the upper and lower eyelashes do not interlace in closing the lids. Near the attachments of the eyelashes are the openings of a number of glands, the *ciliary glands*, arranged in several rows close to the free margin of each lid; they are enlarged and modified sudoriferous glands.

Structure of the eyelids.—From without inwards, each eyelid consists of: skin, subcutaneous areolar tissue, fibres of the Orbicularis oculi, tarsus, orbital septum, tarsal glands and conjunctiva. The upper eyelid has, in addition, the aponeurosis of the Levator palpebræ superioris (fig. 973).

The *skin* is extremely thin, and continuous at the margins of the eyelids with the conjunctiva.

The *subcutaneous areolar tissue* is very lax and delicate, and seldom contains any fat.

The *palpebral fibres of the Orbicularis oculi* are thin, pale in colour, and parallel to the palpebral fissure.

The *tarsi* (fig. 974) are two thin elongated plates of dense connective tissue, about 2·5 cm. long; one is placed in each eyelid, and contributes to its form and support. The *superior tarsus*, the larger, is of a semilunar form about 10 mm. in height at the centre, and gradually narrowing towards its extremities. The lowest fibres of the superficial lamella of the aponeurosis of the Levator palpebræ superioris are attached to the anterior surface, and the deep lamella of the same aponeurosis is inserted into the upper margin of the superior tarsus (p. 1010). The *inferior tarsus*, the smaller, is a narrow plate, the vertical diameter of which is about 5 mm. The free or ciliary margins of the tarsi are thick and straight. The attached or orbital margins are connected to the circumference of the orbit by the orbital septum. The lateral ends of the tarsi are attached

CC-0. In Public Domain. Gurukul Kangri Collection, Haridwar

Digitized by Arya Samaj Foundation Chennai and eGangotri

a hand, named the *lateral palpebral ligament*, to a tubercle on the zygomatic ce, just within the orbital margin; this ligament is separated from the more perficially placed lateral palpebral raphe (p. 439) by a few lobules of the rimal gland. The medial ends of the tarsi are attached by a strong tendinous d, named the *medial palpebral ligament* (tendo oculi) to the upper part of the erior lacrimal crest, and to the adjoining part of the frontal process of the

Fig. 974.—The tarsi and their ligaments. Anterior aspect. (Testut.)

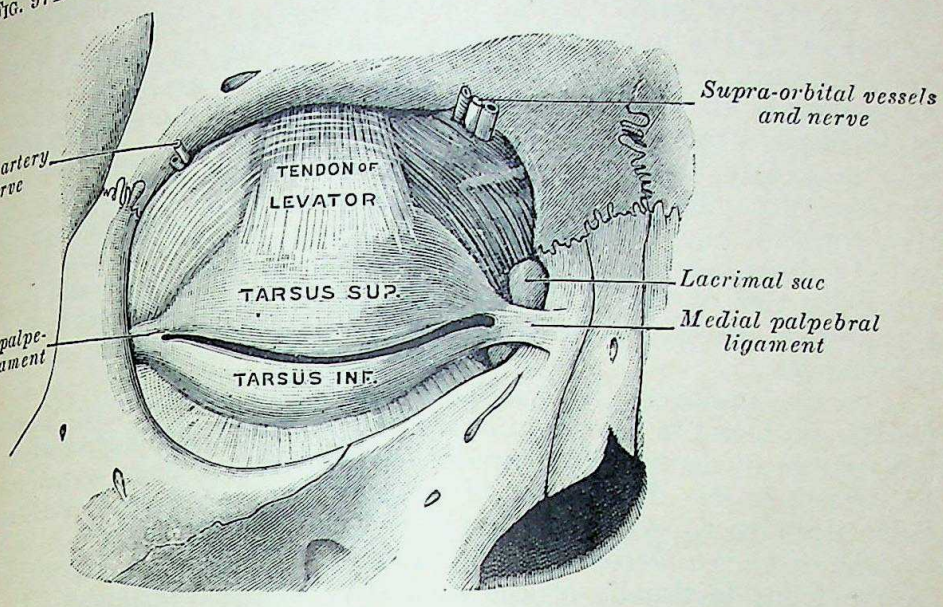

rilla in front of this crest; the lower edge of this ligament is separated from lacrimal sac by some fibres of the Orbicularis oculi.

The *orbital septum* is a membranous sheet, attached to the edge of the orbit, ere it is continuous with the periosteum. In the upper eyelid it blends with superficial lamella of the aponeurosis of the Levator palpebræ superioris, and the lower eyelid with the anterior surface of the inferior tarsus. It is perforated the vessels and nerves ich pass from the orbital ity to the face and lp.

The *tarsal glands* (Meibomian glands) (fig. 975) e situated between the si and conjunctiva, and y be distinctly seen ough the latter on ering the eyelids, presenting an appearance like rallel strings of pearls. ere are about thirty in upper eyelid, and ewhat fewer in the er. They are imbedded grooves in the inner ces of the tarsi and espond in length with breadth of these plates; y are, consequently, longer in the upper than in the lower eyelid. Their ducts en on the free margins of the lids by minute foramina.

Fig. 975.—The tarsal glands of the eyelids. Posterior aspect.

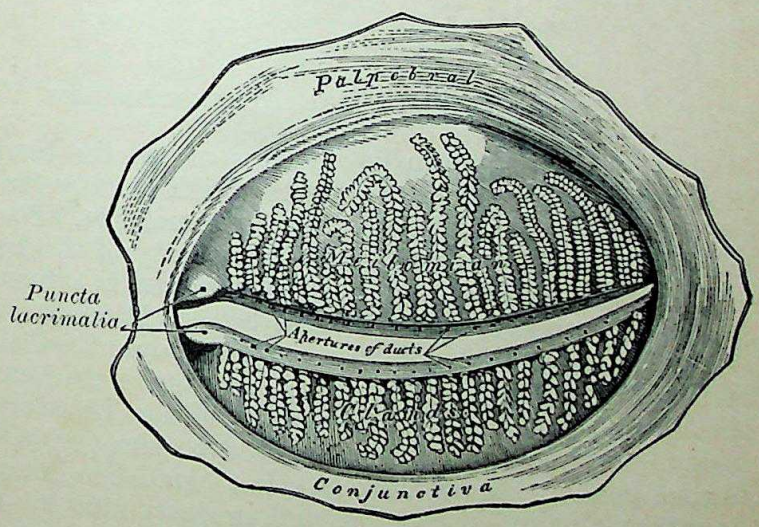

Structure.—The tarsal glands are modified sebaceous glands, each consisting a straight tube or follicle, with numerous small lateral diverticula. The tubes supported by a basement-membrane, and are lined at their mouths by stratified thelium; the deeper parts of the tubes and the lateral offshoots are lined by yer of polyhedral cells.

CC-0. In Public Domain. Gurukul Kangri Collection, Haridwar

Digitized by Arya Samaj Foundation Chennai and eGangotri

The **conjunctiva** is the mucous membrane of the eye. It lines the inner surfaces of the eyelids or palpebræ, and is reflected over the fore part of the sclera and the cornea.

The *palpebral portion* is thick, opaque, highly vascular, and has numerous subepithelial connective tissue papillæ, its deeper part containing a considerable amount of lymphoid tissue. At the margins of the lids it is continuous with the lining membranes of the ducts of the tarsal glands, and, through the lacrimal ducts, with the lining membrane of the lacrimal sac and nasolacrimal duct. Beneath the lateral part of the upper eyelid the ducts of the lacrimal gland open on its free surface. The line of reflection of the conjunctiva from the eyelids on to the bulb of the eye is named the *conjunctival fornix*, and its different parts are known as the superior, inferior, medial and lateral fornices; on account of the greater size of the upper eyelid the superior fornix appears to be situated further back than the inferior. Upon the *sclera* the conjunctiva is loosely connected to the bulb of the eye; it is thin, transparent, destitute of papillæ, and only slightly vascular. Upon the *cornea*, the conjunctiva consists only of epithelium, constituting the epithelium of the cornea already described (p. 996). The epithelium of the palpebral conjunctiva is columnar, that of the ocular conjunctiva and the cornea is stratified squamous. *Lymphatics* arise in a delicate zone around the cornea, and run to the ocular conjunctiva.

Glands, analogous to lymphoid follicles, and called by Henle *trachoma glands*, are found in the conjunctiva, and, according to Strohmeyer, are chiefly situated near the medial palpebral commissure. They were first described by Brush, in his description of Peyer's patches of the small intestine, as 'identical structures existing in the under eyelid of the ox.'

The *caruncula lacrimalis* (fig. 972) is a small, reddish, conical body situated in the lacus lacrimalis at the medial palpebral commissure. It consists of a small island of skin containing sebaceous and sudoriferous glands, and is the source of the whitish secretion which collects in this region. A few slender hairs are attached to its surface. Lateral to the caruncula is a semilunar fold of conjunctiva, the *plica semilunaris*, the concavity of which is directed towards the cornea. Müller found unstriped muscular fibres in this fold; in some of the domesticated animals it contains a thin plate of cartilage.

The nerves of the conjunctiva are numerous; many of them end in terminal bulbs, first described by Krause (p. 1048).

The lymphatic vessels of the eyelids and the conjunctiva are described on p. 754.

The Lacrimal Apparatus (figs. 976 to 979)

The lacrimal apparatus consists of (a) the lacrimal gland which secretes the tears, and its excretory ducts which convey the fluid to the surface of the eye; (b) the lacrimal ducts, the lacrimal sac, and the nasolacrimal duct, by which the fluid is conveyed into the cavity of the nose.

The **lacrimal gland** (fig. 976) is lodged in a fossa, on the medial side of the zygomatic process of the frontal bone. It is about the size and shape of an almond, and consists of two portions, described as the superior and inferior lacrimal glands; the two parts are, however, joined to one another around the lateral edge of the aponeurosis of the Levator palpebræ superioris. The *superior lacrimal gland* is connected to the periosteum of the orbit by a few fibrous bands; the *inferior lacrimal gland* lies beneath the aponeurosis of the Levator palpebræ superioris, and projects into the posterior part of the upper eyelid, where it lies upon and is adherent to the conjunctiva. The ducts of the glands, from six to twelve in number, run obliquely beneath the conjunctiva for a short distance, and open along the lateral part of the superior conjunctival fornix.

In and near the conjunctival fornices, but more plentiful in the upper than in the lower lid, are many small *accessory lacrimal glands*; the presence of these may explain why the conjunctiva does not dry up after extirpation of the lacrimal gland proper.

CC-0. In Public Domain. Gurukul Kangri Collection, Haridwar

Digitized by Arya Samaj Foundation Chennai and eGangotri

Structure of the lacrimal gland (fig. 977).—In structure the lacrimal resembles the salivary glands (p. 1100), but there are no crescents of Guianuzzi. It is a compound racemose gland, the alveoli of which are lined with columnar cells resting

FIG. 976.—The left lacrimal apparatus. Exposed from the front.

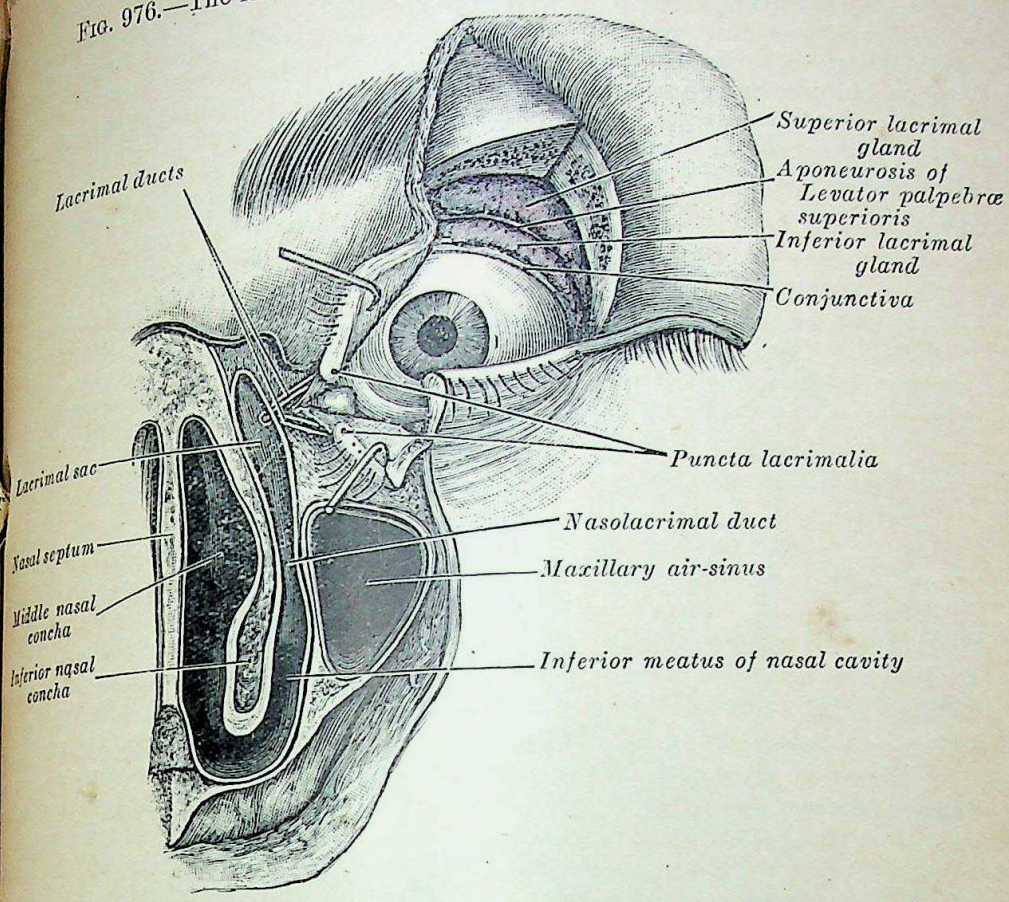

on a basement-membrane. The cells contain oval nuclei, and in the resting condition are crowded with small clear vacuoles, which disappear when the gland secretes actively; protoplasmic granules are also present. The excretory ducts are lined with columnar epithelial cells, but these cells do not show the rod-like structures of the corresponding cells in the salivary glands.

FIG. 977.—A transverse section through a portion of the lacrimal gland of a cat. × 250.

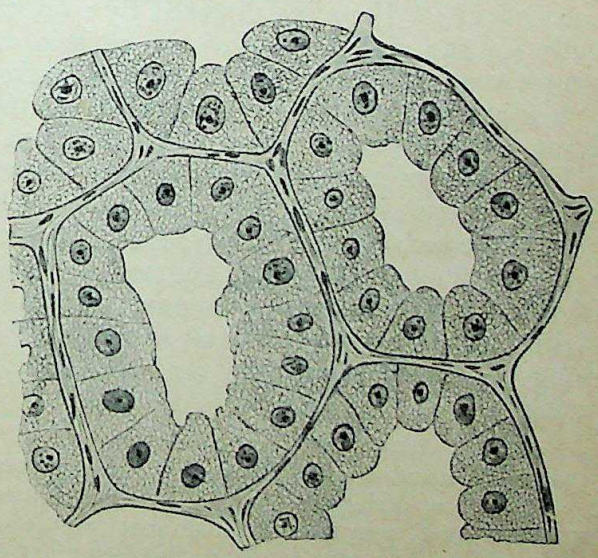

The lacrimal ducts or canals, one in each eyelid, are about 10 mm. long; they commence at minute orifices, the *puncta lacrimalia* (figs. 972, 976, 978), situated on the summits of the *papillæ lacrimales*, which are seen on the margins of the lids at the basal angles of the lacus lacrimalis. The *superior duct*, smaller and shorter than the inferior, at first ascends, and then bends at an acute angle, and passes medialwards and downwards to the lacrimal sac. The *inferior duct* at first descends, and then runs almost horizontally to the lacrimal sac. At the angles they are dilated into ampullæ. The mucous lining of the ducts is covered with stratified squamous epithelium, placed on a basement-membrane, and outside the latter is a layer of striped muscular fibres, continuous with the lacrimal part of the Orbicularis

CC-0. In Public Domain. Gurukul Kangri Collection, Haridwar

Digitized by Arya Samaj Foundation Chennai and eGangotri

oculi; at the base of each lacrimal papilla the muscular fibres are circularly arranged and form a kind of sphincter.

The **lacrimal sac** (fig. 978) is the upper end of the nasolacrimal duct, and is lodged in a fossa formed by the lacrimal bone, the frontal process of the maxilla and the lacrimal fascia. It measures about 12 mm. in length; its upper, closed end is flattened from side to side, but its lower part is rounded, and is continued into the nasolacrimal duct; in its lateral wall are the openings of the lacrimal ducts.

FIG. 978.—Sketch from a frontal section through the right nasal cavity, viewed from the front, to show the relation of the lacrimal passages to the maxillary and ethmoidal sinuses and the inferior nasal concha. The mucous membrane is coloured. (After Gerard, 1907; *From Whitnall's "Anatomy of the human orbit"*; Oxford Medical Publications.)

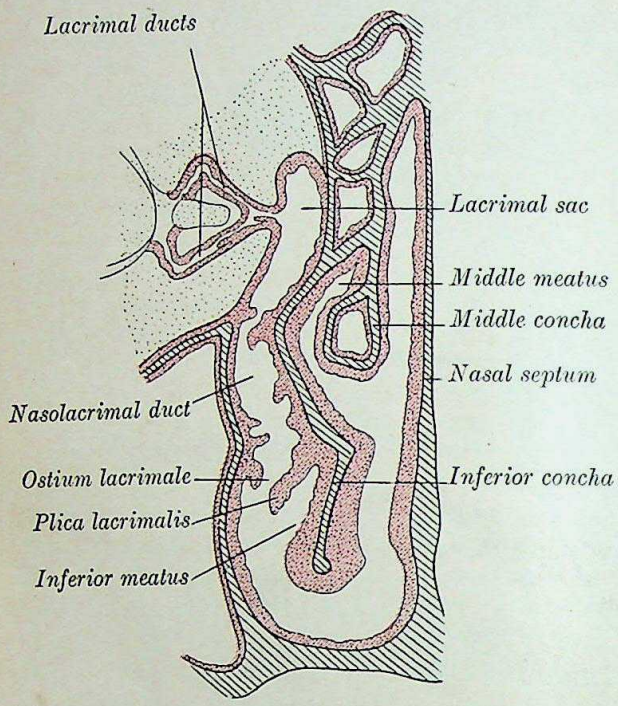

Relations.—A fascia, continuous with the periosteum of the orbit, and named the *lacrimal fascia*, passes from the anterior to the posterior lacrimal crest, and forms the roof and lateral wall of the fossa in which the lacrimal sac is lodged; between the fascia and the lacrimal sac there is a minute plexus of veins. The lacrimal fascia separates the sac from the medial palpebral ligament (tendo oculi) in front, and from the lacrimal part of the Orbicularis oculi (Tensor tarsi) behind. The lower half of the fossa which lodges the lacrimal sac is related medially with the anterior part of the middle meatus of the nasal cavity; the upper half with the anterior ethmoidal air-sinuses.*

Structure.—The lacrimal sac consists of a fibro-elastic coat, lined internally by mucous membrane; the latter is continuous, through the lacrimal ducts, with the conjunctiva, and through the nasolacrimal duct with the mucous membrane of the nasal cavity.

The tears pass from the superolateral to the inferomedial angle of the conjunctival sac. They are directed by: (*a*) the medialward pull of the Orbicularis oculi; (*b*) the contractions of the muscle around the lacrimal ducts; and (*c*) the compression of the lacrimal sac by the lacrimal part of the Orbicularis oculi.

The **nasolacrimal duct** (nasal duct) (figs. 978, 979) is a membranous canal, about 18 mm. long, which extends from the lower part of the lacrimal sac to the anterior part of the inferior meatus of the nose, where it ends in a somewhat expanded orifice, provided with an imperfect valve, the *plica lacrimalis* (*Hasneri*), formed by a fold of the mucous membrane. The duct is contained in an osseous canal, formed by the maxilla, the lacrimal bone, and the inferior nasal concha; it is narrower in the middle than at either end, and is directed downwards, backwards, and a little lateralwards. The mucous lining of the lacrimal sac and nasolacrimal duct is covered with columnar epithelium which in places is ciliated.

Applied Anatomy.—The eyelids are composed of various tissues, and consequently are liable to a variety of diseases. The skin covering them is thin and delicate, and is supported on a quantity of loose areolar subcutaneous tissue, devoid of fat. In consequence of this it is very freely movable, and is liable to be drawn down by the contraction

* S. E. Whitnall (*Ophthalmic Review*, Nov. 1911) examined 100 skulls and found that in 14 the anterior ethmoidal air-sinuses came into relation only with the posterior wall of the fossa; in 32 they reached as far forward as the suture between the lacrimal bone and the maxilla; while in 54 one large irregular air-sinus extended forward as far as the anterior lacrimal crest.

CC-0. In Public Domain. Gurukul Kangri Collection, Haridwar

Digitized by Arya Samaj Foundation Chennai and eGangotri

neighbouring cicatrices, and thus produce an eversion of the lid, known as *ectropion*. Inversion of the lids (*entropion*) from spasm of the Orbicularis oculi or from chronic inflammation of the palpebral conjunctiva may also occur. The loose cellular tissue beneath the skin is liable to become extensively infiltrated either with blood or inflammatory products, producing very great swelling. Even from very slight injuries to this tissue, the extravasation of blood may be so great as to produce considerable swelling of the eyelids and complete closure of the eye, and the same is the case when inflammatory products are poured out. The follicles of the eyelashes, or the sebaceous glands associated with these follicles, may be the seat of inflammation, constituting the ordinary 'stye.' Irregular or disorderly growth of the eyelashes not infrequently occurs, some of them being turned towards the eyeball and producing inflammation and ulceration of the cornea, and possibly eventually complete destruction of the eye. The Orbicularis oculi may be the seat of spasm, either in the form of slight quivering of the lids; or repeated twitchings, most commonly due to errors of refraction in children; or more continuous spasms, due to some irritation of the trigeminal or of the facial nerve. The Orbicularis

FIG. 979.—A sagittal section through the anterior part of the head of an adult female. Left half viewed from within to show the left lateral nasal wall. The relative positions of the fossa for the lacrimal sac and the naso-lacrimal duct are indicated by the white line. × about $\frac{2}{3}$. (*From Whitnall's "Anatomy of the human orbit"*; Oxford Medical Publications.)

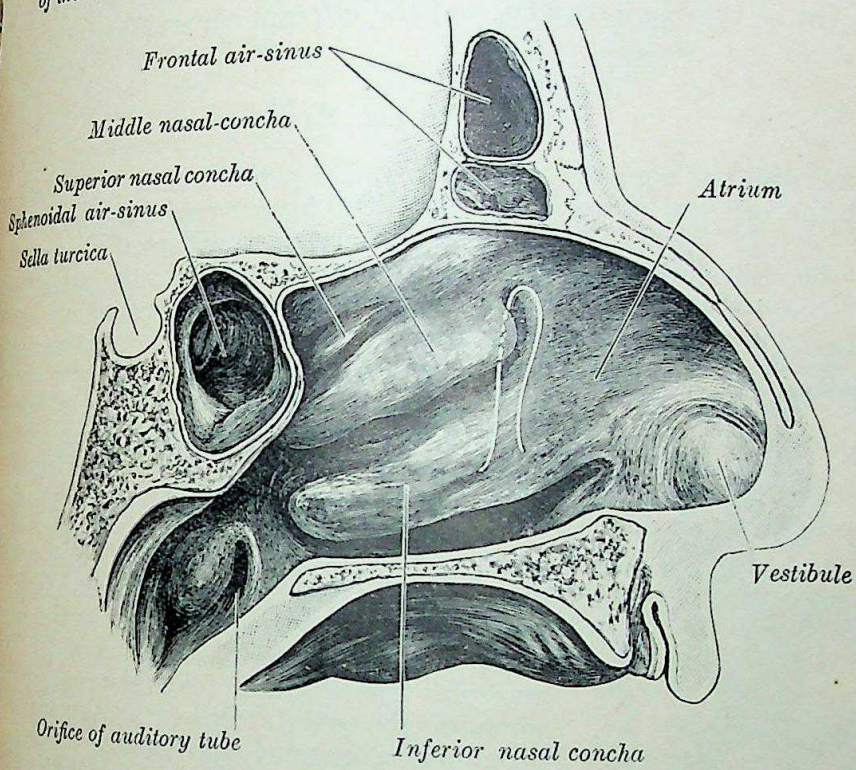

oculi may be paralysed with the other facial muscles. Under these circumstances the patient is unable to close the lids, and, if he attempts to do so, rolls the eyeball upwards under the upper eyelid. The tears overflow from displacement of the lower eyelid, and the conjunctiva and cornea, being constantly exposed and the patient being unable to wink, become irritated from dust and foreign bodies. Ptosis, or drooping of the upper eyelid, may be congenital, or may be due to paralysis of the Levator palpebræ superioris, in which case there will probably be other symptoms of implication of the oculomotor nerve. The eyelids may be the seat of bruises, wounds, or burns. Following burns, adhesion of the margins of the lids to each other, or adhesion of the lids to the bulb of the eye may take place. They are sometimes the seat of emphysema, after fracture of some of the thin bones forming the medial wall of the orbit. If shortly after such an injury the patient blows his nose, air is forced from the nostril through the lacerated tissues into the connective tissue of the eyelids, which suddenly swell up and present the peculiar crackling characteristic of this affection.

Foreign bodies frequently get into the conjunctival sac and cause great pain, especially when they come in contact with the corneal surface, during the movements of the eyelids. The conjunctiva is often involved in severe injuries of the eyeball, but is seldom ruptured alone; the most common form of injury to the conjunctiva alone is from a burn, either from fire, strong acids, or lime. In these cases union is liable to take place between the lids and the eyeball. The conjunctiva is often the seat of inflammation arising from

CC-0. In Public Domain. Gurukul Kangri Collection, Haridwar

Digitized by Arya Samaj Foundation Chennai and eGangotri

many different causes, and the arrangement of the conjunctival vessels should be remembered as affording a means of diagnosis between this condition and injection of the sclera, which is present in inflammation of the deeper structures of the bulb of the eye. The inflamed conjunctiva is bright red; the vessels are large and tortuous, and greatest at the circumference, shading off towards the corneal margin; they anastomose freely and form a dense network, and they can be emptied or displaced by gentle pressure. Inflammation of the underlying sclera, ciliary body, or iris, is a far more serious condition; the injection is in the deeper vessels of the eye, and as seen through the sclera presents a diffuse and dull purplish or violet zone of circumcorneal discoloration.

The lacrimal ducts may become occluded as a result of burns or injury; overflow of the tears may also result from deviation of the puncta, or from chronic inflammation of the lacrimal sac. This latter condition is set up by some obstruction to the nasolacrimal duct, frequently associated with some infection from the nasal cavity. In consequence of this the tears and mucus accumulate in the lacrimal sac and distend it. Suppuration in the lacrimal sac is sometimes met with; this may be the sequel of a chronic inflammation. It may lead to lacrimal fistula from an abscess forming in the sac, which bursts or is opened on the surface; the condition is often seen in badly nourished, tuberculous children.

The Organ of Hearing

The ear or organ of hearing is divisible into three parts: the external ear, the middle ear or tympanic cavity, and the internal ear or labyrinth.

The External Ear

The **external ear** consists of the expanded portion named the *auricula* or *pinna*, and the *external acoustic meatus*. The former projects from the side of the head and serves to collect the air-vibrations by which sound is produced; the latter leads inwards from the bottom of the auricula and conducts the vibrations to the tympanic cavity.

Fig. 980.—The right auricula. Lateral surface.

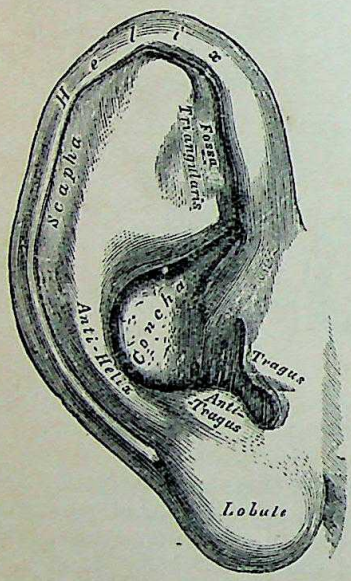

The **auricula or pinna** (fig. 980) is of an oval form, with its larger end directed upwards. Its lateral surface is irregularly concave, looks slightly forwards, and presents numerous eminences and depressions. The prominent rim of the auricula is called the *helix*; where the helix turns downwards posteriorly, a small tubercle, the *auricular tubercle of Darwin*, is frequently seen; this tubercle is very evident about the sixth month of fœtal life, when the whole auricula has a close resemblance to that of some of the adult monkeys. Another curved prominence, parallel with and in front of the helix, is called the *antihelix*; this divides above into two crura, between which is a triangular depression, the *fossa triangularis*. The narrow curved depression between the helix and the antihelix is called the *scapha*; the antihelix partly encircles a deep, capacious cavity, the *concha*, which is incompletely divided into two parts by the *crus* or anterior end of the helix; the upper part is termed the *cymba conchæ*, the lower part the *cavum conchæ*. In front of the concha, and projecting backwards over the meatus, is a small eminence, the *tragus*. Opposite the tragus, and separated from it by the *intertragic notch*, is a small tubercle, the *antitragus*. Below the antitragus is the *lobule*, composed of fibrous and adipose tissues, and devoid of the firmness and elasticity of the rest of the auricula.

The cranial surface of the auricula presents elevations which correspond to the depressions on its lateral surface, and after which they are named, e.g. eminentia conchæ, eminentia triangularis, &c.

Structure.—The auricula is composed of a thin plate of yellow fibrocartilage, covered with skin, and connected to the surrounding parts by ligaments and muscles; it is continuous with the cartilaginous portion of the external acoustic

CC-0. In Public Domain. Gurukul Kangri Collection, Haridwar

Digitized by Arya Samaj Foundation Chennai and eGangotri

meatus, and the latter is joined to the circumference of the porus acusticus internus by fibrous tissue.

The *skin of the auricula* is thin, closely adherent to the cartilage, and covered with fine hairs which are furnished with sebaceous glands; these glands are most numerous in the concha and scaphoid fossa. On the tragus and antitragus, and in the intertragic notch the hairs are strong and numerous. The skin of the auricula is continuous with that lining the external acoustic meatus.

FIG. 981.—The cranial surface of the cartilage of the right auricula.

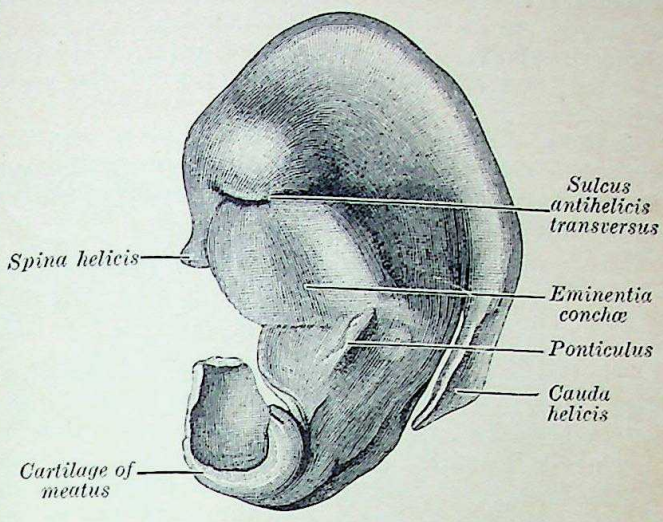

The *cartilage of the auricula* (figs. 981, 982) consists of a single piece; upon its surface are found the eminences and depressions above described. It is absent from the lobule; it is deficient, also, between the tragus and beginning of the helix, the gap being filled up by dense fibrous tissue. At the upper part of the auricula, where the helix bends upwards, a small projection of the cartilage, called the *spina helicis*, while in the lower part of the helix the cartilage is prolonged downwards as a tail-like process, the *cauda helicis*; the latter is separated from the antihelix by a fissure, the *fissura antitragohelicina*. The cranial surface of the cartilage exhibits a transverse furrow, the *sulcus antihelicis transversus*, which corresponds with the inferior crus of the antihelix and separates the eminentia conchæ from the eminentia triangularis. The eminentia conchæ is crossed by a vertical ridge (*ponticulus*) which gives attachment to the Auricularis posterior muscle. In the cartilage of the auricula are two fissures, one behind the crus helicis and another in the tragus.

FIG. 982.—The muscles of the right auricula.

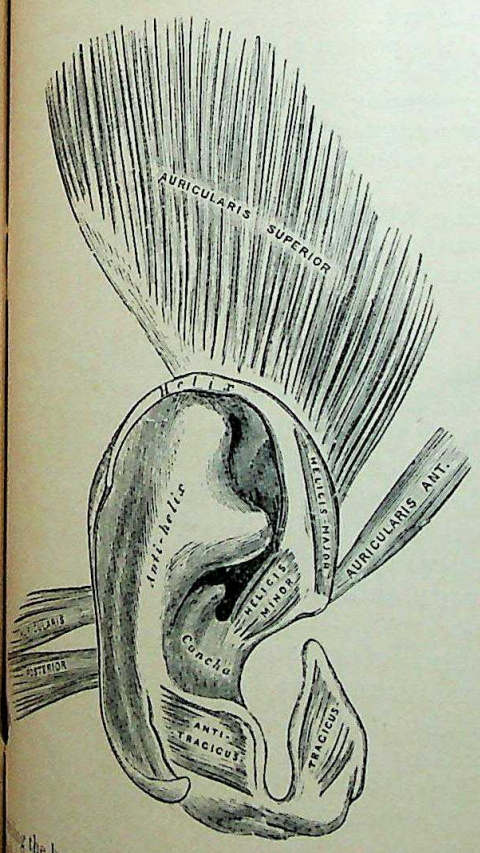

The *ligaments of the auricula* consist of two sets: (1) extrinsic, connecting it to the temporal bone; (2) intrinsic, connecting various parts of its cartilage together.

The *extrinsic ligaments* are two in number, anterior and posterior. The *anterior ligament* extends from the tragus and spina helicis to the root of the zygomatic process of the temporal bone. The *posterior ligament* passes from the posterior surface of the concha to the outer surface of the mastoid process.

The chief *intrinsic ligaments* are: (*a*) a strong fibrous band, stretching from the tragus to the helix, completing the boundary of the concha; and (*b*) a band between the antihelix and the cauda helicis. Other less important bands are found on the cranial surface of the pinna.

The *muscles of the auricula* (fig. 982) consist of two sets: (1) the extrinsic, which connect it with the skull and scalp and move the auricula as a whole; and (2) the intrinsic, which extend from one part of the auricula to another.

CC-0. In Public Domain. Gurukul Kangri Collection, Haridwar

Digitized by Arya Samaj Foundation Chennai and eGangotri

The **extrinsic muscles** are the Auriculares anterior, superior, et posterior.

The *Auricularis anterior*, the smallest of the three, is thin, fan-shaped, and its fibres are pale and indistinct. It arises from the lateral edge of the galea aponeurotica, and its fibres converge to be inserted into the spina helicis.

The *Auricularis superior*, the largest of the three, is thin and fan-shaped. Its fibres arise from the galea aponeurotica, and converge to be inserted by a thin, flattened tendon into the upper part of the cranial surface of the auricula.

The *Auricularis posterior* consists of two or three fleshy fasciculi, which arise by short aponeurotic fibres from the mastoid portion of the temporal bone, and are inserted into the ponticulus on the eminentia conchæ.

Nerve-supply.—The Auriculares anterior et superior are supplied by the temporal branches, and the Auricularis posterior by the posterior auricular branch, of the facial nerve.

Actions.—In man, these muscles possess very little action: the Auricularis anterior draws the auricula forwards and upwards; the Auricularis superior slightly raises it; and the Auricularis posterior draws it backwards.

The **intrinsic muscles** are the:

Helicis major.	Antitragicus.
Helicis minor.	Transversus auriculæ.
Tragicus.	Obliquus auriculæ.

The *Helicis major* is a narrow vertical band situated upon the anterior margin of the helix. It arises from the spina helicis, and is inserted into the anterior border of the helix, where the latter is about to curve backwards.

The *Helicis minor* is an oblique fasciculus, covering the crus helicis.

The *Tragicus* is a short, flattened vertical band on the lateral surface of the tragus.

The *Antitragicus* arises from the outer part of the antitragus, and is inserted into the cauda helicis and antihelix.

The *Transversus auriculæ* is placed on the cranial surface of the pinna. It consists of scattered fibres, partly tendinous and partly muscular, extending from the eminentia conchæ to the eminentia scaphæ.

The *Obliquus auriculæ*, also on the cranial surface, consists of a few fibres extending from the upper and posterior parts of the eminentia conchæ to the eminentia triangularis.

Nerve-supply.—The intrinsic muscles on the lateral surface are supplied by the temporal branches of the facial nerve, the intrinsic muscles on the cranial surface by the posterior auricular branch of the same nerve.

The *arteries of the auricula* are: (*a*) the posterior auricular branch of the external carotid artery, which supplies three or four branches to the cranial surface; twigs from these reach the lateral surface, some by passing through the fissures of the auricular cartilage, and others by turning round the margin of the helix; (*b*) the anterior auricular branches of the superficial temporal artery, which are distributed to the lateral surface; and (*c*) a branch from the occipital artery.

The *veins* accompany the corresponding arteries.

The *sensory nerves* are: the great auricular and lesser occipital nerves, from the cervical plexus; the auriculotemporal branch of the mandibular nerve; and the auricular branch of the vagus nerve.

The **external acoustic meatus** extends from the bottom of the concha to the tympanic membrane (figs. 983, 984). It is about 4 cm. long if measured from the tragus; from the bottom of the concha its length is about 2·5 cm. It forms an S-shaped curve, and is directed at first inwards, forwards, and slightly upwards (*pars externa*); it then passes inwards, backwards, and upwards (*pars media*), and lastly is carried inwards, forwards, and slightly downwards (*pars interna*). It is an oval cylindrical canal, the greatest diameter of the oval being directed downwards and backwards at the external orifice, but nearly horizontally at the inner end. It presents two constrictions, one near the inner end of the cartilaginous portion, and another, named the *isthmus*, in the osseous portion, about 2 cm. from the bottom of the concha. The tympanic membrane, which closes the inner end of the meatus, is obliquely directed; in consequence of this obliquity the floor and anterior wall of the meatus are longer than the roof and posterior wall.

The external acoustic meatus is formed partly by cartilage and membrane, and partly by bone, and is lined by skin.

The *cartilaginous portion* is about 8 mm. long; it is continuous with the cartilage of the auricula, and is fixed to the circumference of the porus acusticus externus of the temporal bone. The cartilage is deficient at the upper and posterior parts of the meatus, its place being supplied by fibrous membrane; two or three deep fissures are present in the anterior part of the cartilage.

CC-0. In Public Domain. Gurukul Kangri Collection, Haridwar

Digitized by Arya Samaj Foundation Chennai and eGangotri

The osseous portion is about 16 mm. long, and is narrower than the cartilaginous portion. It is directed inwards, forwards, and slightly downwards,

FIG. 983.—The external and middle portions of the right ear, from the front.

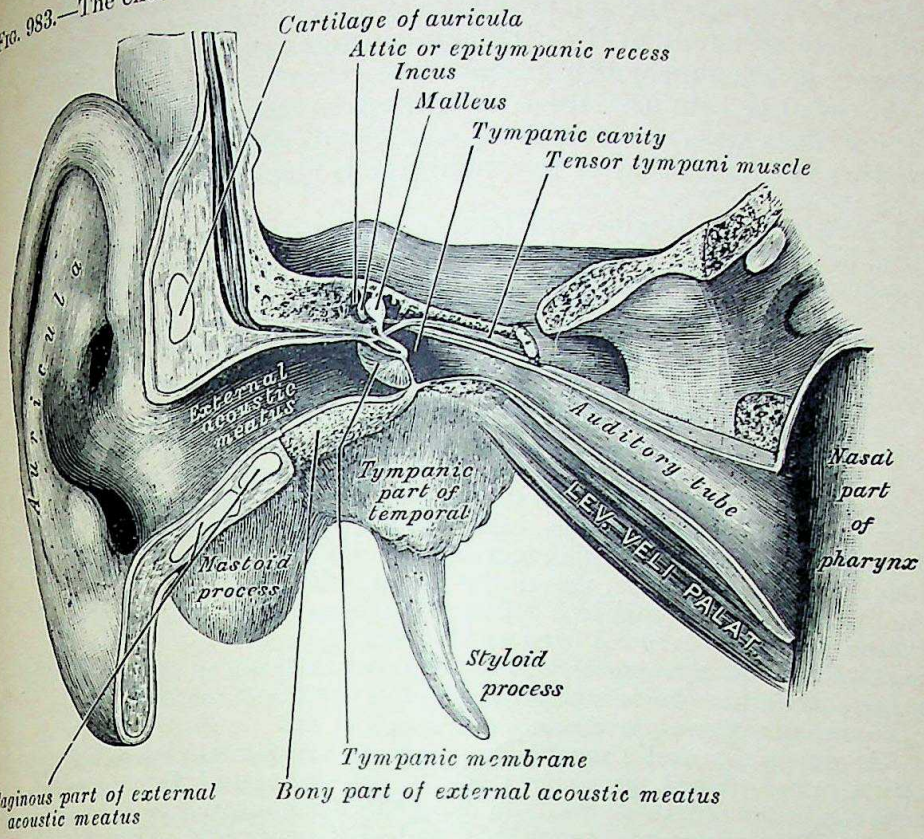

ing in its course a slight curve the convexity of which is upwards and wards. Its inner end is smaller than the outer, and sloped, the anterior projecting beyond the posterior for about 4 mm.; this end is marked,

FIG. 984.—A horizontal section through the left ear. Upper half of the section.

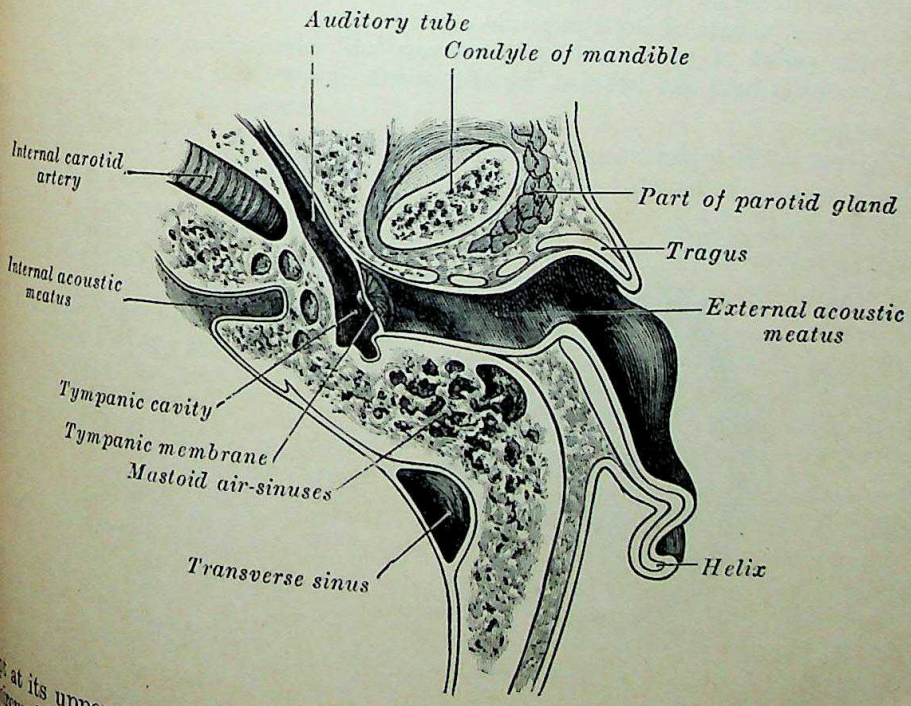

at its upper part, by a narrow groove, the *tympanic sulcus*, in which circumference of the tympanic membrane is attached. Its outer end

CC-0. In Public Domain. Gurukul Kangri Collection, Haridwar

Digitized by Arya Samaj Foundation Chennai and eGangotri

(porus acusticus externus) is dilated and rough in the greater part of its circumference, for the attachment of the cartilaginous portion. The anterior and inferior parts of the osseous portion are formed by the tympanic part of the temporal bone, which, in the fœtus, exists as the tympanic ring (p. 213).

The skin which envelops the auricula is continued into the external acoustic meatus and covers the outer surface of the tympanic membrane. It is thin and closely adherent to the cartilaginous and osseous parts of the tube. After maceration, the thin pouch of epidermis, when withdrawn, preserves the form of the meatus. In the thick subcutaneous tissue of the cartilaginous part of the meatus are numerous *ceruminous glands* which secrete the ear-wax; their structure resembles that of the sudoriferous glands (p. 1057).

Relations of the meatus.—In front of the meatus is the condyle of the mandible, which, however, is sometimes separated from the cartilaginous part by a small portion of the parotid gland. The movements of the mandible influence to some extent the lumen of the cartilaginous portion. Above the osseous part is the middle cranial fossa; behind it are the mastoid air-sinuses, separated from the meatus by a thin layer of bone.

The *arteries* supplying the meatus are branches from the posterior auricular, internal maxillary, and temporal arteries.

The *nerves* are chiefly derived from the auriculotemporal branch of the mandibular nerve and the auricular branch of the vagus nerve.

Applied Anatomy.—Malformations, such as imperfect development of the external parts, supernumerary auriculæ, or absence of the meatus, are occasionally met with. The skin of the auricula is thin and richly supplied with blood, but in spite of this it is often the seat of frost-bite, due to the fact that it is much exposed to cold, and lacks the usual underlying subcutaneous fat found in most other parts of the body. A collection of blood is sometimes found between the cartilage and perichondrium (*hæmatoma auris*), usually the result of traumatism, but not necessarily due to this cause; it is said to occur most frequently in the ears of the insane. Deposits of urate of soda are often met with in the auriculæ of gouty subjects.

The external acoustic meatus can be most satisfactorily examined by light reflected down a funnel-shaped speculum, when the greater part of the canal and tympanic membrane can be brought into view. In using this instrument, it is advisable that the auricula should be drawn upwards, backwards, and a little outwards, so as to render the meatus as straight as possible. The points to be noted are: the presence of wax or foreign bodies; the size of the meatus; and the condition of the tympanic membrane. Accumulation of wax is often a cause of deafness; it is best removed by syringing. Foreign bodies are not infrequently introduced into the ear by children, and, when situated in the first portion of the meatus, may be removed with tolerable facility by means of a minute hook or loop of fine wire, aided by reflected light; but when they have slipped beyond the narrow middle part of the meatus, their removal is in no wise easy, and attempts to effect it, in inexperienced hands, may be followed by destruction of the tympanic membrane and possibly the contents of the tympanic cavity.

At the point of junction of the osseous and cartilaginous portions an obtuse angle, which projects into the tube at its antero-inferior wall, is formed; this produces a sort of constriction, and renders it a narrow portion of the meatus—an important point to be remembered in connexion with the presence of foreign bodies in the meatus. The shortness of the meatus in children should be borne in mind in introducing the aural speculum, so that it be not pushed in too far, at the risk of injuring the tympanic membrane; indeed, even in the adult the speculum should never be introduced beyond the constriction which marks the junction of the osseous and cartilaginous portions. Just in front of the membrane is a well-marked depression, situated on the floor of the meatus, and bounded by a somewhat prominent ridge; in this fossa

FIG. 985.—The right tympanic membrane, as seen through a speculum.

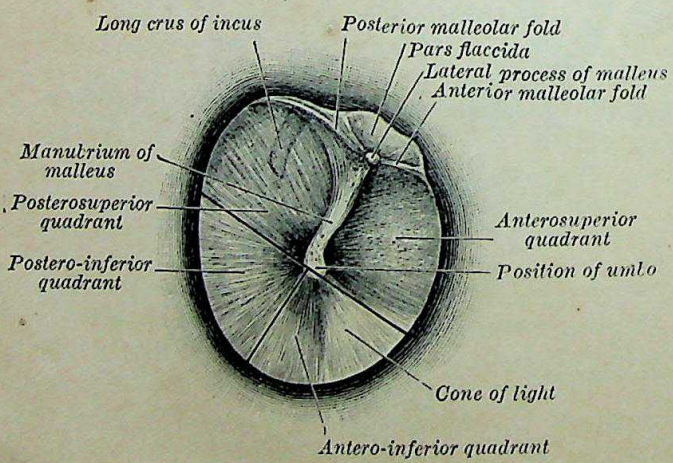

bodies may become lodged. By aid of the speculum, combined with traction of the auricula upwards and backwards, the greater part of the tympanic membrane is rendered visible (fig. 985). It is a pearly-grey membrane, slightly glistening in the adult, placed obliquely

CC-0. In Public Domain. Gurukul Kangri Collection, Haridwar

Digitized by Arya Samaj Foundation Chennai and eGangotri

so as to form with the floor of the meatus a very acute angle (about fifty-five degrees), while with the roof it forms an obtuse angle. At birth it is more horizontal, situated in almost the same plane as the base of the skull. About midway between the anterior and posterior margins of the membrane, and extending from the centre obliquely upwards and forwards, is a reddish-yellow streak; this is the handle of the malleus, which is inserted into the membrane. At the upper part of this streak, close to the roof of the meatus, a little white, round prominence is plainly to be seen; this is the lateral or short process of the malleus, projecting against the membrane. The tympanic membrane does not present a plane surface; on the contrary, its centre is drawn inwards, on account of its connexion with the manubrium of the malleus.

The connexions of the nerves of the meatus explain the occurrence of constant cough-ing and sneezing, from implication of the vagus, when there exists any source of irritation in the meatus; and the vomiting which may follow syringing the ears of children, and the occasional heart failure similarly induced in elderly people. No doubt also the associa-tion of earache with toothache or with cancer of the tongue is due to implication of the mandibular branch of the trigeminal nerve, which supplies also the teeth and the tongue. The upper half of the tympanic membrane is much more vascular than the lower half; for this reason, and also to avoid the chorda tympani nerve and ossicles, incisions through the membrane should be made at the lower and posterior part.

The Middle Ear, or Tympanic Cavity

The **middle ear or tympanic cavity**, is an irregular, laterally compressed space within the temporal bone. It is filled with air, which is conveyed to it from the nasal part of the pharynx through the auditory tube. It contains a chain of movable bones which connect its lateral to its medial wall, and transmit the vibrations of the tympanic membrane across the cavity to the internal ear.

The tympanic cavity consists of two parts: the *tympanic cavity proper*, opposite the tympanic membrane, and the *attic* or *epitympanic recess*, above the level of the membrane; the latter contains the upper half of the malleus and the greater part of the incus. Including the attic, the vertical and antero-posterior diameters of the cavity are each about 15 mm. The transverse diameter measures about 6 mm. above and 4 mm. below; opposite the centre of the tympanic membrane it is only about 2 mm. The tympanic cavity is bounded laterally by the tympanic membrane; medially, by the lateral wall of the internal ear; it communicates, behind, with the tympanic antrum and through it with the mastoid air-sinuses, and in front with the auditory tube (fig. 983).

The **tegmental wall or roof** of the tympanic cavity is formed by a thin plate of bone, the *tegmen tympani*, which separates the cranial and tympanic cavities, and forms the greater part of the anterior surface of the petrous portion of the temporal bone; it is prolonged backwards so as to roof the tympanic antrum, and forwards to cover the semicanal for the Tensor tympani.

The **jugular wall or floor** is narrow, and consists of a thin, convex plate of bone (*fundus tympani*) which separates the tympanic cavity from the superior bulb of the internal jugular vein; in places this bony wall may be deficient, and then the tympanic cavity is separated from the vein by mucous membrane and fibrous tissue only. In the floor of the tympanic cavity, near the labyrinthic wall, is a small aperture for the passage of the tympanic branch of the glossopharyngeal nerve.

The **membranous or lateral wall** of the tympanic cavity (fig. 986) is formed mainly by the tympanic membrane, but partly by the ring of bone in which this membrane is attached. There is a deficiency or notch in the upper part of the ring (*notch of Rivinus*), close to which are three small apertures, viz.: the iter chordæ posterius, the petrotympanic fissure, and the iter chordæ anterius.

The *iter chordæ posterius* (apertura tympanica canaliculi chordæ) is situ-ated in the angle of junction between the mastoid and membranous walls of the tympanic cavity immediately behind the tympanic membrane and on a level with the upper end of the manubrium mallei; it leads into a minute canal, which descends in front of the canal for the facial nerve, and ends in the chorda tympani nerve about 6 mm. above the stylomastoid foramen. Through it the chorda tympani nerve and a branch of the stylomastoid artery enter the tympanic cavity.

CC-0. In Public Domain. Gurukul Kangri Collection, Haridwar

Digitized by Arya Samaj Foundation Chennai and eGangotri

The *petrotympanic fissure* (Glaserian fissure) opens just above and in front of the ring of bone into which the tympanic membrane is inserted; in this situation it is a mere slit about 2 mm. in length. It lodges the anterior process and anterior ligament of the malleus, and transmits to the tympanic cavity the anterior tympanic branch of the internal maxillary artery.

The *iter chordæ anterius* (canal of Huguier) is placed at the medial end of the petrotympanic fissure; through it the chorda tympani nerve leaves the tympanic cavity.

The **tympanic membrane** (figs. 985, 986) separates the tympanic cavity from the external acoustic meatus. It is thin and semitransparent, nearly oval in form, somewhat broader above than below, and placed very obliquely, forming an angle of about fifty-five degrees with the floor of the meatus. Its longest diameter is downwards and forwards, and measures from 9 to 10 mm.; its shortest diameter from 8 to 9 mm. The greater part of its circumference is thickened, and forms a *fibrocartilaginous ring* which is fixed in the *tympanic sulcus* at the inner end of the meatus. This sulcus is deficient superiorly at the notch of Rivinus, and from the ends of this notch two bands, the *anterior* and *posterior malleolar folds*, are prolonged to the lateral process of the malleus. The small, somewhat triangular part of the membrane situated above these folds is lax and thin, and is named the *pars flaccida* (membrane of Shrapnell); a small orifice is sometimes seen in it. The chief part of the membrane is taut and is named the *pars tensa*. The manubrium of the malleus is firmly attached to the medial surface of the tympanic membrane as far as its centre, which projects towards the tympanic cavity; the medial surface of the membrane is thus convex, and the point of greatest convexity is named the *umbo*. Although the membrane as a whole is convex on its inner surface, its radiating fibres (vide infra) are curved with their concavities directed inwards, and the membrane has a shape somewhat resembling that of a convolvulus flower.

Fig. 986.—The membranous wall of the right tympanic cavity. (Testut.)

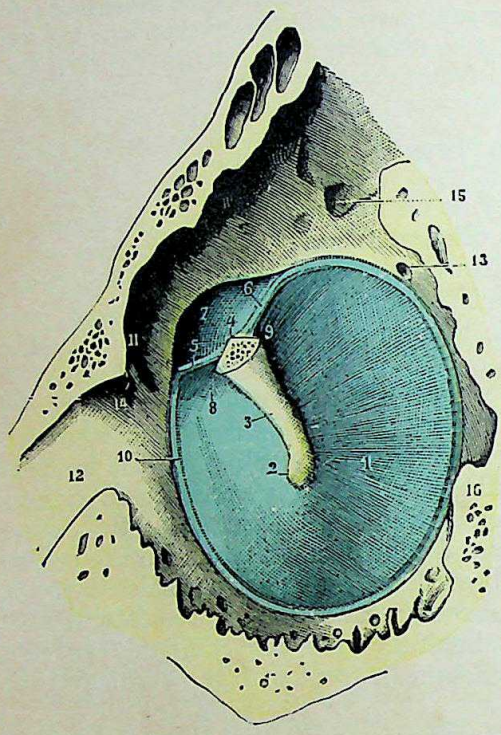

The malleus has been resected immediately below its lateral process, in order to show the malleolar folds and the pars flaccida.
1. Tympanic membrane. 2. Umbo. 3. Manubrium mallei; 4. its cut surface. 5. Anterior malleolar fold. 6. Posterior malleolar fold. 7. Pars flaccida. 8, 9. Anterior and posterior pouches of Tröltsch. 10. Fibrocartilaginous ring. 11. Petrotympanic fissure. 12. Auditory tube. 13. Iter chordæ posterius. 14. Iter chordæ anterius. 15. Fossa incudis for short crus of the incus. 16. Prominentia styloidea.

Structure.—The tympanic membrane is composed of three strata: a lateral (epidermal), an intermediate (fibrous), and a medial (mucous). The *epidermal stratum* is derived from the skin which lines the external acoustic meatus, and consists of stratified epithelium. The *fibrous stratum* consists of two layers: a superficial radiate stratum, the fibres of which diverge from the manubrium of the malleus, and a deep circular stratum, the fibres of which are plentiful around the circumference, but sparse and scattered near the centre, of the membrane. Branched or dendritic fibres (Grüber) are also present, especially in the posterior half of the membrane. The *mucous stratum* is a part of the mucous membrane of the tympanic cavity; it is thickest towards the upper part of the membrane, and is covered by a single layer of flattened cells. In the pars flaccida of the membrana tympani the fibrous stratum is replaced by loose connective tissue.

Vessels and Nerves.—The *arteries* of the tympanic membrane are derived from the deep auricular branch of the internal maxillary artery, which ramifies beneath the cutaneous stratum; and from the stylomastoid branch of the posterior auricular artery, and tympanic branch of the internal maxillary artery, which are distributed to the mucous

CC-0. In Public Domain. Gurukul Kangri Collection, Haridwar

Digitized by Arya Samaj Foundation Chennai and eGangotri

The superficial *veins* open into the external jugular vein; those on the deep surface drain partly into the transverse sinus and veins of the dura mater, and partly into the plexus of veins on the auditory tube. The membrane receives its *nerve-supply* from the auriculotemporal branch of the mandibular nerve, the auricular branch of the vagus nerve, and the tympanic branch of the glossopharyngeal nerve.

The **labyrinthic or medial wall** (fig. 987) of the tympanic cavity is formed by the lateral wall of the internal ear. It presents for examination the fenestra vestibuli, the fenestra cochleæ, the promontory, and the prominence of the facial canal.

The *fenestra vestibuli* (fenestra ovalis) is a reniform opening, situated above and behind the promontory, and leading from the tympanic cavity into the vestibule of the internal ear; its long diameter is horizontal, and its convex

Fig. 987.—A coronal section through the right temporal bone. Anterior aspect.

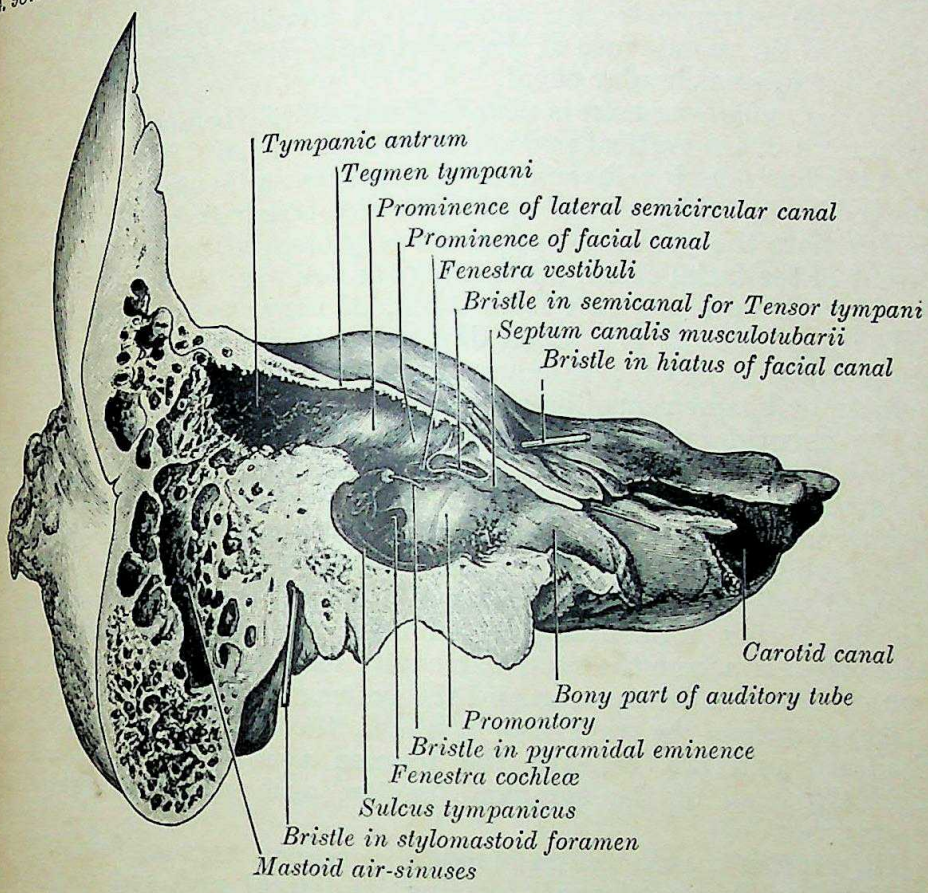

border is upwards. In the recent state it is occupied by the base of the stapes, the circumference of which is fixed to the margin of the fenestra by the ligamentum annulare baseos stapedis.

The *fenestra cochleæ* (fenestra rotunda) is situated below and a little behind the fenestra vestibuli, from which it is separated by the promontory. It lies completely under cover of the overhanging edge of the promontory, in a deep hollow or niche. It is placed very obliquely, and, in the macerated bone, opens upwards and forwards from the tympanic cavity into the scala tympani of the cochlea. In the recent state it is closed by the *secondary tympanic membrane*, which is somewhat concave towards the tympanic cavity, and convex towards the cochlea, the membrane being bent so that its posterior one-third forms an angle with its antero-inferior two-thirds. This membrane consists of three layers: an external, derived from the mucous lining of the tympanic cavity; an internal, from the lining membrane of the cochlea; and an intermediate, fibrous layer.

The *promontory* is a rounded prominence, formed by the projection outwards of the first turn of the cochlea; it is placed between the fenestra vestibuli and fenestra cochleæ, and its surface is furrowed by small grooves which lodge

CC-0. In Public Domain. Gurukul Kangri Collection, Haridwar

Digitized by Arya Samaj Foundation Chennai and eGangotri

the nerves of the tympanic plexus. A minute spicule of bone frequently connects the promontory to the pyramidal eminence.

The *prominence of the facial canal* indicates the position of the upper part of the bony canal (aquæductus Fallopii), in which the facial nerve is contained; this canal, the wall of which may be partly deficient, traverses the labyrinthic wall of the tympanic cavity from before backwards, immediately above the fenestra vestibuli, and then curves downwards in the mastoid wall.

The **mastoid or posterior wall** of the tympanic cavity is wider above than below, and presents for examination the entrance to the tympanic antrum, the pyramidal eminence, and the fossa incudis.

The *entrance to the antrum* (aditus ad antrum) is a large irregular aperture which leads backwards from the epitympanic recess into an air-sinus, named the *tympanic or mastoid antrum* (p. 209). The antrum communicates behind and below with the *mastoid air-sinuses*, which vary considerably in number, size, and form; the antrum and mastoid air-sinuses are lined by mucous membrane, continuous with that lining the tympanic cavity. On the medial wall of the entrance to the antrum is a rounded eminence, situated above and behind the prominence of the facial canal; it corresponds with the position of the lateral semicircular canal.

The *pyramidal eminence* is situated immediately behind the fenestra vestibuli, and in front of the vertical portion of the facial canal; it is hollow, and contains the Stapedius muscle; its summit projects forwards towards the fenestra vestibuli, and is pierced by a small aperture which transmits the tendon of the muscle. The cavity in the pyramidal eminence is prolonged downwards and backwards in front of the facial canal, and communicates with the latter by a minute aperture which transmits a twig from the facial nerve to the Stapedius muscle.

The *fossa incudis* is a small depression in the lower and posterior part of the epitympanic recess; it lodges the short crus of the incus, which is fixed to the fossa by ligamentous fibres.

The **carotid or anterior wall** of the tympanic cavity is narrowed in its vertical diameter by the descent of the tegmen tympani; it is separated from the carotid canal by a thin plate of bone perforated by the tympanic branch of the internal carotid artery, and by the caroticotympanic nerves. At the upper part of the anterior wall are the orifice of the semicanal for the Tensor tympani, and the tympanic orifice of the auditory tube, separated from each other by a thin horizontal plate of bone, the septum canalis musculotubarii. These canals run from the tympanic cavity forwards and downwards to the angle of union between the squama and the petrous portion of the temporal bone.

The *semicanal for the Tensor tympani*, the higher and smaller semicanal, is cylindrical and lies beneath the tegmen tympani. It extends on to the labyrinthic wall of the tympanic cavity, and ends immediately above the fenestra vestibuli.

The *septum canalis musculotubarii* (processus cochleariformis) passes backwards below this semicanal, forming its lateral wall and floor; it expands above the anterior end of the fenestra vestibuli, and terminates there by curving laterally so as to form a pulley over which the tendon of the muscle passes.

The **auditory tube** (Eustachian tube) is the channel through which the tympanic cavity communicates with the nasal part of the pharynx. Its length is about 36 mm., and its direction is downwards, forwards, and medialwards, forming an angle of about 45° with the sagittal plane and one of about 30° with the horizontal plane. It is formed partly of bone, partly of cartilage and fibrous tissue (fig. 983).

The *osseous portion* is about 12 mm. long. It begins in the carotid or anterior wall of the tympanic cavity, below the septum canalis musculotubarii, and, gradually narrowing, ends at the angle of junction of the squama and the petrous portion of the temporal bone, its extremity presenting a jagged margin, which serves for the attachment of the cartilaginous portion. It is oblong in transverse section with its greater diameter from side to side. It lies immediately above the carotid canal, from which it is separated by a very thin plate of bone.

The *cartilaginous portion*, about 24 mm. long, is formed of a triangular plate of elastic fibrocartilage, the greater part of which is situated in the medial wall of the tube. The apex of the fibrocartilage is attached by fibrous tissue to the circumference of the medial end of the osseous portion of the tube, while

CC-0. In Public Domain. Gurukul Kangri Collection, Haridwar

Digitized by Arya Samaj Foundation Chennai and eGangotri

base lies directly under the mucous membrane of the lateral wall of the al part of the pharynx, where it forms an elevation, the *torus tubarius* or ion, behind the pharyngeal orifice of the tube. The upper part of the tilage is bent lateralwards and downwards, and the cartilage therefore sists of a broad *lamina medialis*, and a narrow *lamina lateralis*. On verse section the cartilage has the appearance of a hook; a groove or ow is thus produced, which is open below and laterally, and this part of wall of the canal is completed by fibrous membrane. The cartilage is d to the base of the skull in a groove between the petrous part of the tem- l bone and the great wing of the sphenoidal bone; this groove ends opposite middle of the medial pterygoid lamina. The cartilaginous and bony portions the tube are not in the same plane, the former inclining downwards a little r than the latter. The diameter of the tube is not uniform throughout, being test at the pharyngeal orifice, least at the junction of the bony and cartila- us portions, and again increased towards the tympanic cavity; the rowest part of the tube is termed the *isthmus*. The position and relations the pharyngeal orifice are described with the nasal part of the pharynx 1122). The mucous membrane of the tube is continuous in front with that e nasal part of the pharynx, and behind with that of the tympanic cavity; covered with ciliated columnar epithelium and is thin in the osseous portion. e in the cartilaginous portion it contains many mucous glands, and near pharyngeal orifice a considerable amount of adenoid tissue, named by ich the *tube-tonsil*. The tube is opened during deglutition by the Salpingo- yngeus and Dilatator tubæ. The latter arises from the lateral lamina of cartilage and from the membranous part of the tube, and blends below with Tensor veli palatini. H. Blakeway * is of opinion that contraction of the sor veli palatini is more likely to produce closure than opening of the tube.

In the new-born child the auditory tube is about half as long as that of the adult. Its ction is more horizontal, and its osseous portion is relatively shorter but much wider n in the adult. Its pharyngeal orifice is a narrow slit which is on a level with the e, and is devoid of a torus tubarius.

Vessels and Nerves.—The *arteries* of the auditory tube are derived from the ascending ryngeal branch of the external carotid artery and from two branches of the internal ilary artery, viz.:—the middle meningeal artery and the artery of the pterygoid al. The *veins* open into the pterygoid venous plexus. The *nerves* of the tube spring m the pharyngeal plexus and from the pharyngeal branch of the sphenopalatine ion.

The Auditory Ossicles

The tympanic cavity contains a chain of three movable ossicles, the *malleus*, *incus*, and *stapes*. The malleus is attached to the tympanic membrane, the ges to the circumference of the nestra vestibuli, while the incus laced between the malleus and ges and connected to them by ate articulations.

The malleus (fig. 988), so named m its fancied resemblance to a mmer, is from 8 to 9 mm. long, d is the largest of the auditory les. It consists of a head, neck, d three processes, viz. the manu- rium, and the anterior and lateral cesses.

Fig. 988.—The left malleus.
A. From behind. B. From within.

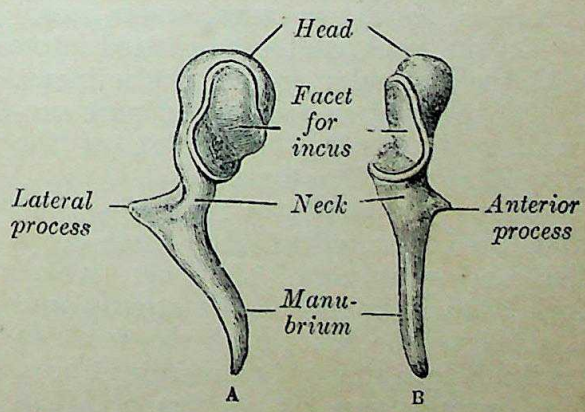

The *head*, the large upper end of bone, is situated within the mpanic recess; it is ovoid in e and articulates posteriorly with incus, being free in the rest of its extent. The facet for articulation the incus is constricted near the middle, and consists of an upper larger lower smaller part, situated nearly at right angles to one another.

* *Journal of Anatomy and Physiology*, Vol. xlviii.

CC-0. In Public Domain. Gurukul Kangri Collection, Haridwar

Digitized by Arya Samaj Foundation Chennai and eGangotri

Opposite the constriction the lower margin of the facet projects in the form of a process, the *cog-tooth* or *spur* of the malleus.

The *neck* is the contracted part just beneath the head; below the neck is an enlargement to which the various processes are attached.

The *manubrium mallei* is connected by its lateral margin with the tympanic membrane. It is directed downwards, medialwards, and backwards; it decreases in size towards its free end, which is curved slightly forwards and flattened transversely. Near the upper end of its medial surface is a slight projection, into which the tendon of the Tensor tympani is inserted.

Fig. 989.—The left incus. A. From within. B. From the front.

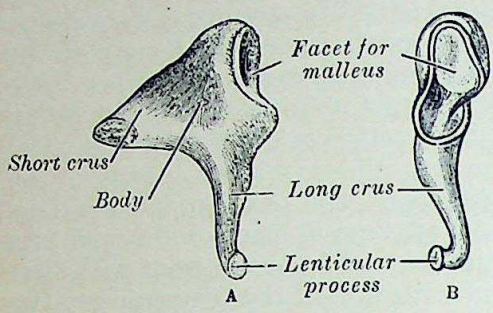

The *anterior process* (processus gracilis) is a delicate spicule, directed forwards from the enlargement below the neck; it is connected to the petrotympanic fissure by ligamentous fibres. In the fœtus this is the longest process of the malleus, and is continuous in front with the cartilage of Meckel (p. 77).

The *lateral process* (processus brevis) is a conical projection, which springs from the root of the manubrium; it is directed laterally, and is attached to the upper part of the tympanic membrane and, by means of the anterior and posterior malleolar folds, to the extremities of the notch of Rivinus.

Ossification.—The malleus, with the exception of its anterior process, is ossified from a single centre which appears near the neck of the bone. The anterior process is ossified separately, in membrane, and joins the main part of the bone about the sixth month of fœtal life.

The **incus** (fig. 989) has received its name from its supposed resemblance to an anvil, but its shape is more like that of a premolar tooth, with two widely diverging roots. It consists of a body and two crura.

The *body* is somewhat cubical, but compressed transversely. On its anterior surface is a saddle-shaped facet, for articulation with the head of the malleus.

The two crura diverge from one another nearly at right angles.

The *short crus*, somewhat conical in shape, projects backwards, and is attached by ligamentous fibres to the fossa incudis, in the lower and posterior part of the epitympanic recess.

The *long crus*, rather more than half the length of the manubrium mallei, descends nearly vertically behind and parallel to that process; its lower end bends medialwards, and terminates in a rounded projection, the *lenticular process*, the inner surface of which is covered with cartilage, and articulates with the head of the stapes.

Ossification.—The incus is ossified from one centre which appears in the upper part of its long crus.

The **stapes** (fig. 990), so called from its resemblance to a stirrup, consists of a head, neck, two crura, and a base.

On the *head*, which is directed lateralwards, is a depression for articulation with the lenticular process of the incus.

On the *neck* or constricted part succeeding the head, the tendon of the Stapedius muscle is inserted.

Fig. 990.—A. The left stapes. B. Medial surface of the base of the stapes.

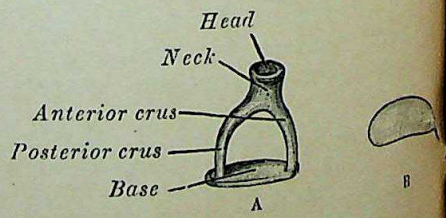

The *crura* diverge from the neck and are connected at their ends by a flattened oval plate, the *base*, which forms the footplate of the stirrup and is fixed to the margin of the fenestra vestibuli by a ring of ligamentous fibres. The anterior crus is shorter and less curved than the posterior.

Ossification.—The stapes is ossified from a single centre which appears in the base of the bone.

The articulations of the auditory ossicles.—The incudomalleolar joint is a saddle-shaped diarthrosis; it is surrounded by an articular capsule,

CC-0. In Public Domain. Gurukul Kangri Collection, Haridwar

Digitized by Arya Samaj Foundation Chennai and eGangotri

and the joint-cavity is incompletely divided by a wedge-shaped articular disc or meniscus. The incudostapedial joint is an enarthrosis, surrounded by an articular capsule; some observers have described an articular disc or meniscus in this joint; others regard the joint as a syndesmosis.

The ligaments of the ossicles.—The ossicles are connected to the walls of the tympanic cavity by ligaments: three for the malleus, and one each for the incus and stapes.

The *anterior ligament of the malleus* is attached by one end to the neck of the malleus, just above the anterior process, and by the other to the anterior wall of the tympanic cavity, close to the petrotympanic fissure, some of its fibres being prolonged through the fissure, to reach the spina angularis of the sphenoidal bone.

The *lateral ligament of the malleus* is a triangular band passing from the posterior part of the border of the notch of Rivinus to the head of the malleus. Helmholtz described the anterior ligament and the posterior part of the lateral ligament as forming together the 'axis ligament' around which the malleus rotates.

The *superior ligament of the malleus* connects the head of the malleus to the roof of the epitympanic recess.

The *posterior ligament of the incus* connects the end of the short crus of the incus to the fossa incudis.

A *superior ligament of the incus* has been described, but it is little more than a fold of mucous membrane.

The vestibular surface and the circumference of the base of the stapes are covered with hyaline cartilage; that encircling the base is attached to the margin of the fenestra vestibuli by a ring of elastic fibres, the *ligamentum annulare baseos stapedis*. The posterior part of this ligament is much narrower than the anterior part, and acts as a kind of hinge on which the base of the stapes moves when the Stapedius muscle contracts.

Movements of the auditory ossicles.—The manubrium mallei follows all the movements of the tympanic membrane, while the malleus and incus rotate together around an axis which runs through the short crus of the incus and the anterior ligament of the malleus. When the tympanic membrane and manubrium mallei are propelled inwards the long crus of the incus also moves in the same direction and pushes the base of the stapes towards the labyrinth. This motion is communicated to the fluid (perilymph) contained within the labyrinth and the movement of the perilymph causes an outward bulging of the secondary tympanic membrane which closes the fenestra cochleæ. The conditions are reversed when the tympanic membrane moves in a lateral direction, but if this movement of the membrane be exaggerated the incus does not follow the full outward excursion of the malleus, but merely glides on this bone at the incudomalleolar joint, and thus the danger of pulling the foot of the stapes out of the fenestra vestibuli is prevented. When the manubrium mallei is carried inwards the cog-tooth or spur on the lower margin of the head of the malleus locks the incudomalleolar joint, and this necessitates an inward movement of the long crus of the incus; the joint is unlocked when the manubrium mallei is carried outwards.

The **muscles of the tympanic cavity** are the Tensor tympani and Stapedius.

The **Tensor tympani** is contained in the bony canal above the osseous portion of the auditory tube, from which it is separated by the septum canalis musculotubarii. It arises from the cartilaginous portion of the auditory tube and the adjoining part of the great wing of the sphenoidal bone, as well as from the osseous canal in which it is contained. Passing backwards through the canal, it ends in a slender tendon which bends lateralwards round the pulley-like posterior end of the septum, and is inserted into the manubrium mallei, near its root.

Nerve-supply.—The Tensor tympani is supplied by a branch of the mandibular nerve through the otic ganglion.

Action.—The Tensor tympani draws the manubrium mallei medialwards, and as a consequence the base of the stapes is pushed inwards, thus increasing the pressure of the fluid in the labyrinth.

The **Stapedius** arises from the wall of a conical cavity in the pyramidal eminence; its tendon emerges from the orifice at the apex of the eminence, and, passing forwards, is inserted into the posterior surface of the neck of the stapes.

Nerve-supply.—The Stapedius is supplied by a branch of the facial nerve.

CC-0. In Public Domain. Gurukul Kangri Collection, Haridwar.

Digitized by Arya Samaj Foundation Chennai and eGangotri

Action.—The Stapedius pulls the head of the stapes backwards, and tilts the anterior end of the base towards the tympanic cavity, thus diminishing the pressure of the fluid in the labyrinth. The Stapedius, therefore, counteracts the action of the Tensor tympani.

The **mucous membrane of the tympanic cavity** is continuous with that of the pharynx, through the auditory tube. It invests the auditory ossicles and the muscles and nerves contained in the tympanic cavity, forms the medial layer of the tympanic membrane, and the lateral layer of the secondary tympanic membrane, and lines the tympanic antrum and mastoid air-sinuses. It forms several vascular folds, which extend from the walls of the tympanic cavity to the ossicles; of these, one descends from the roof of the cavity to the head of the malleus and upper margin of the body of the incus, a second invests the Stapedius muscle; other folds invest the chorda tympani nerve and the Tensor tympani muscle. These folds separate off pouch-like cavities and give the interior of the tympanum a somewhat honeycombed appearance. One of these pouches, the *pouch of Prussak*, lies between the neck of the malleus and the membrana flaccida. Two other recesses, the *anterior and posterior recesses of Tröltsch*. may be mentioned: they are formed by the mucous membrane which envelops the chorda tympani nerve, and are situated, one in front of, and the other behind, the manubrium mallei. In the tympanic cavity the mucous membrane is pale, thin, slightly vascular, and covered with cubical epithelial cells, except around the orifice of the auditory tube, where the cells are ciliated. There are no mucous glands in the tympanic cavity. The tympanic antrum and the mastoid air-sinuses are lined by squamous, non-ciliated epithelium.

Vessels and Nerves.—The *arteries* are six in number. Two of them are larger than the others, viz. the anterior tympanic branch of the internal maxillary artery, which supplies the tympanic membrane, and the stylomastoid branch of the posterior auricular artery, which supplies the posterior part of the tympanic cavity and mastoid air-sinuses. The smaller arteries are—the petrosal branch of the middle meningeal artery, which enters through the hiatus of the facial canal; a branch from the ascending pharyngeal artery, and another from the artery of the pterygoid canal, which accompany the auditory tube; and the tympanic branch from the internal carotid artery, given off in the carotid canal and perforating the thin anterior wall of the tympanic cavity. The *veins* terminate in the pterygoid venous plexus and in the superior petrosal sinus. From the mucous membrane of the tympanic antrum a small group of veins runs medialwards through the arch formed by the superior semicircular canal. They emerge on the posterior surface of the petrous part of the temporal bone through the subarcuate fossa, and open into the superior petrosal sinus. These small veins are the remains of the large subarcuate veins of the child, and constitute a pathway of infection from the tympanic antrum to the meninges of the brain. The *nerves* constitute the tympanic plexus, which ramifies upon the surface of the promontory. The plexus is formed by (1) the tympanic branch of the glossopharyngeal nerve, and (2) the caroticotympanic nerves.

The *tympanic branch of the glossopharyngeal* (Jacobson's nerve) enters the tympanic cavity by the inferior tympanic canaliculus, and divides into branches which ramify on the promontory and enter into the formation of the tympanic plexus. The *superior and inferior caroticotympanic nerves*, from the carotid plexus of the sympathetic, pass through the wall of the carotid canal, and join the plexus. The tympanic plexus supplies, (*a*) branches to the mucous lining of the tympanic cavity, auditory tube, and mastoid air-sinuses; (*b*) a branch which goes through an opening in front of the fenestra vestibuli and joins the greater superficial petrosal nerve; and (*c*) the *lesser superficial petrosal nerve*, which may be looked upon as the continuation of the tympanic branch of the glossopharyngeal nerve through the tympanic plexus. The lesser superficial petrosal nerve traverses a small canal beneath the semicanal for the Tensor tympani, runs past, and receives a connecting branch from, the genicular ganglion of the facial nerve, and reaches the anterior surface of the temporal bone through a small opening on the lateral side of the hiatus of the facial canal. It then passes through the foramen ovale or the canaliculus innominatus of Arnold (p. 203 *) and joins the otic ganglion (p. 903).

The *chorda tympani nerve* crosses the tympanic cavity. It is given off from the sensory part of the facial nerve, about 6 mm. before that nerve emerges from the stylomastoid foramen. It runs upwards and forwards in a canal, and enters the tympanic cavity through the *iter chordæ posterius*, and becomes invested with mucous membrane. It traverses the tympanic cavity, crossing medial to the tympanic membrane and the upper part of the manubrium mallei to the carotid wall, where it emerges through the *iter chordæ anterius*, or *canal of Huguier*.

Applied Anatomy.—Fractures of the middle fossa of the base of the skull almost invariably involve the tympanic roof, and are accompanied by a rupture of the tympanic

CC-0. In Public Domain. Gurukul Kangri Collection, Haridwar

Digitized by Arya Samaj Foundation Chennai and eGangotri

brane or fracture through the roof of the bony meatus. They are associated with ase continued bleeding from the ear, and, if the dura mater has also been torn, with harge of copious amounts of cerebrospinal fluid. Here the avoidance of infection the outside is of the utmost importance, as should it occur septic meningitis must ably follow with a fatal issue.

The tympanic cavity is very frequently the seat of disease, both suppurative and non-urative, and in practically every case the inflammation spreads upwards from the e or throat along the auditory tube. Acute inflammatory troubles spreading up to tympanic cavity are usually associated with so much inflammatory swelling of the ous membrane of the auditory tube as to occlude it, and thus the products of inflam-tion are pent up in the tympanic cavity and directly involve the tympanic antrum. ter such circumstances the only means of escape for the products is by rupture of the panic membrane, which usually occurs spontaneously and is followed by a free dis-rge of pus, with relief from the acute pain which exists in this condition. Should the ing of the walls of the auditory tube then subside, the normal drainage of the cavity be established and the perforation in the drum will heal, but if not—as is often the because the opening of the tube may be occluded by adenoid growths in the naso-nx or other cause—the pus will continue to accumulate in the middle ear and will low through the perforation as a chronic otorrhœa. In the course of time the disease ds beyond the mucous membrane to the walls of the tympanic cavity, to the ossicles, the mastoid process, and when this has occurred the condition is incurable except e removal of the carious bone. Further, severe intracranial complications are at ime often produced owing to purulent material being retained; thus an abscess may between the bone and dura mater, (*a*) about the roof of the tympanic cavity, and diately beneath the dura covering the temporal lobe, or (*b*) between the deep aspect e mastoid process and the sigmoid bend of the transverse sinus, possibly extending ly and surrounding the sinus. In this latter type of case thrombosis of the transverse s readily occurs, and the clot being also infected tends to disintegrate and be carried the general circulation, particles becoming lodged in the capillaries of the lungs and g up abscesses therein. Pyæmia from transverse sinus thrombosis is more common from any other focus of origin. In addition, bone disease of the tympanic cavity or m may be associated with severe and fatal septic meningitis, or with the formation bscess in the brain, the most common sites being the temporal lobe and the hemisphere e cerebellum.

Less serious, but more common, is the formation of a subperiosteal mastoid abscess h great swelling behind the ear, and protrusion outwards of the auricula; such a con-n demands an early incision through all the structures, including the periosteum, r the whole length of the mastoid process, and then it will frequently be found that underlying bone is carious or that a track leads through the bone into the tympanic um. In such conditions extensive operations for the removal of bone are often re-ed. In many cases of chronic bone disease in the tympanic cavity, the facial nerve mes exposed as it lies in its canal, and an inflammatory process is set up in the nerve, ing to facial paralysis of the infranuclear type (p. 912). In other cases localised areas bone disease, most often in the region of the epitympanic recess, form the points from h aural polypi grow, and the ear polypus, like the nasal polypus, must be considered have originated in a spot of carious bone, the removal of which is necessary if a cure be established.

In dealing with suppuration in the tympanum by operation, the tympanic antrum is reached through the suprameatal triangle of Macewen (page 206), the posterior wall the external acoustic meatus being the direction which is taken. In enlarging the ing from the antrum to the tympanum, the facial nerve is protected by passing a al probe through the passage, and only removing the bone from the lateral side. In child the tympanic antrum is close to the surface, and the facial nerve is not covered the mastoid process.

Of the non-suppurative conditions which affect the middle ear, chronic catarrh, leading sclerosis of the whole of the tympanic contents, is again due to spread of inflammation some nasal or pharyngeal condition. The progress is very slow, but leads to ever-asing deafness—this deafness in the first instance is in no way connected with any ect in the acoustic nerve, and this can be shown by the fact that the hearing by bone duction over the mastoid process remains normal or is increased. In chronic non-purative otitis media, treatment must be especially directed towards placing the nose pharynx in a healthy condition; when this has been accomplished, the aural con-n often improves of itself; if not, improvement may be induced by forcing air up the ditory tube by means of the Politzer bag, or directly into the orifice of the tube by means catheter.

Internal Ear, or Labyrinth

The **internal ear or labyrinth** is the essential part of the organ of hearing. consists of two parts: (*a*) the *osseous labyrinth*, a series of cavities within e petrous part of the temporal bone, and (*b*) the *membranous labyrinth*, a

CC-0. In Public Domain. Gurukul Kangri Collection, Haridwar

Digitized by Arya Samaj Foundation Chennai and eGangotri

series of communicating membranous sacs and ducts, contained within the bony cavities.

The Osseous Labyrinth (figs. 991, 992)

The **osseous labyrinth** consists of three parts: the *vestibule*, the semicircular canals, and the *cochlea*. These are cavities hollowed out of the substance of the bone, and lined by periosteum; they contain a clear fluid, the perilymph, in which the membranous labyrinth is placed.

Fig. 991.—The right osseous labyrinth. Lateral aspect.

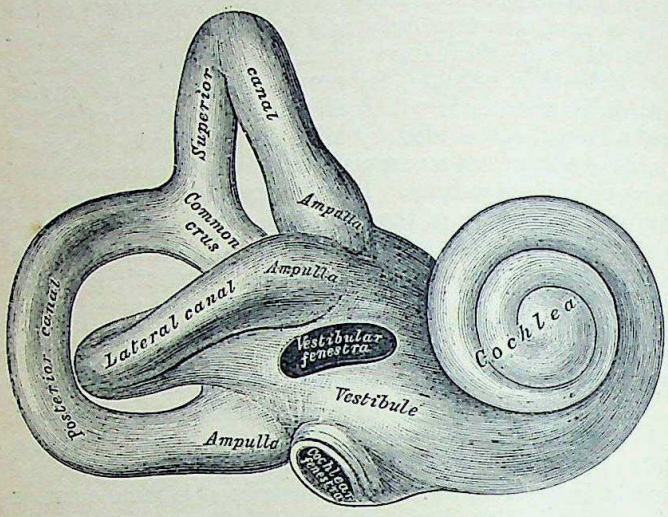

The **vestibule** is the central part of the osseous labyrinth, and is situated medial to the tympanic cavity, behind the cochlea, and in front of the semicircular canals. It is somewhat ovoid in shape, but flattened transversely; it measures about 5 mm. from before backwards, the same from above downwards, and about 3 mm. across. In its *lateral or tympanic wall* is the fenestra vestibuli, closed in the recent state by the base of the stapes and its annular ligament. On the front part of the *medial wall* is a small circular depression, the *recessus sphæricus*, which lodges the saccule, and is perforated by several minute holes (*macula cribrosa media*) for the passage of filaments of the acoustic nerve to the saccule. Behind this recess is an oblique ridge, the *crista vestibuli*, the anterior end of which is named the *pyramid of the vestibule*; this ridge divides below to enclose a small depression, the *fossa cochlearis*, which is perforated by a number of holes for the passage of filaments of the acoustic nerve to the vestibular end of the ductus cochlearis. At the hinder part of the medial wall is the orifice of the *aquæductus vestibuli*. This aqueduct extends to the posterior surface of the petrous portion of the temporal bone; it transmits a small vein, and contains a tubular prolongation of the membranous labyrinth, the *ductus endolymphaticus*. Above and behind the crista vestibuli, and situated in the *roof* and medial wall of the vestibule is an elliptical depression, the *recessus ellipticus*, which lodges the utricle. The pyramid and adjoining part of the recessus ellipticus are perforated by a number of holes (*macula cribrosa superior*); the holes in the pyramid transmit the nerves to the utricle, and those in the recessus ellipticus the nerves to the ampullæ of the superior and lateral semicircular ducts. At the *posterior part* of the vestibule there are

Fig. 992.—The interior of the right osseous labyrinth.

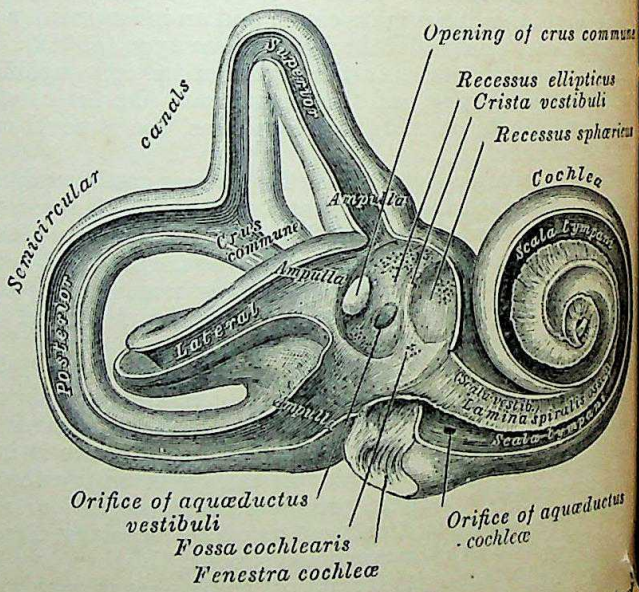

CC-0. In Public Domain. Gurukul Kangri Collection, Haridwar

Digitized by Arya Samaj Foundation Chennai and eGangotri

the five orifices of the semicircular canals; at the *anterior part* is an elliptical opening leading into the scala vestibuli of the cochlea.

The **bony semicircular canals** are three in number, superior, posterior and lateral, and are situated above and behind the vestibule. They are compressed from side to side, and each describes about two-thirds of a circle They are unequal in length, but are about 0·8 mm. in diameter and each presents a dilatation at one end, called the *ampulla*, the diameter of which is nearly twice that of the canal. They open into the vestibule by five orifices, one of which is common to two of the canals.

The *superior semicircular canal*, 15 to 20 mm. in length, is vertical in direction, and is placed transversely to the long axis of the petrous portion of the temporal bone, on the anterior surface of which its arch forms a round projection. Its antero-lateral end is ampullated, and opens into the upper and lateral part of the vestibule; the opposite end unites with the upper end of the posterior canal to form the *crus commune*, which is about 4 mm. long, and opens into the medial part of the vestibule.

The *posterior semicircular canal*, also vertical, is directed backwards, nearly parallel to the posterior surface of the petrous bone; it is from 18 mm. to 22 mm. long; its ampullated end opens into the lower part of the vestibule, where there are several small holes (*macula cribrosa inferior*) for the transmission of the nerves to this ampulla. Its upper end opens into the crus commune.

The *lateral or horizontal canal* is from 12 mm. to 15 mm. long, and its arch is directed horizontally backwards and lateralwards. Its anterior or ampullated end opens into the upper and lateral angle of the vestibule, just above the fenestra vestibuli and close to the ampullated end of the superior canal; its posterior end opens below the orifice of the crus commune.

The lateral semicircular canal of one ear is in the same plane as that of the other ear; while the superior canal of one ear is in a plane parallel with that of the posterior canal of the other ear.

The **cochlea** (figs. 992, 993) bears a resemblance to the shell of the common snail; it forms the anterior part of the labyrinth, is conical in form, and placed in front of the vestibule; it measures about 5 mm. from base to apex, and its breadth across the base is about 9 mm. Its apex (*cupula*) is directed forwards and lateralwards, with a slight inclination downwards, towards the upper and front part of the labyrinthic wall of the tympanic cavity; its base corresponds with the bottom of the internal acoustic meatus, and is perforated by numerous apertures for the passage of the cochlear nerve. The cochlea * consists of a conical-shaped central axis, the *modiolus*; of a canal, wound spirally around the central axis for two turns and three-quarters; and of a delicate lamina, the *osseous spiral lamina*, which projects from the modiolus into the canal, and partially subdivides it. In the recent state the subdivision of the canal is completed by the *basilar membrane* which stretches from the free border of the osseous spiral lamina to the outer wall of the bony cochlea; the two passages into which the cochlear canal is thus divided communicate with each other at the apex of the modiolus by a small opening, named the *helicotrema*.

The *modiolus* is the conical central axis or pillar of the cochlea. Its base is broad, and appears at the bottom of the internal acoustic meatus, where it corresponds with the tractus spiralis foraminosus which is perforated by numerous orifices, for the transmission of the branches of the cochlear nerve; the nerves for the first turn and a half of the cochlea pass through the foramina of the tractus spiralis foraminosus; those for the apical turn, through the foramen centrale. The canals of the tractus spiralis foraminosus pass up through the modiolus and successively bend outwards to reach the attached margin of the osseous spiral lamina. Here they become enlarged, and by their apposition form the *spiral canal of the modiolus*, which follows the course of the attached margin of the osseous spiral lamina and lodges the spiral ganglion (ganglion of Corti). The foramen centrale is continued into a canal which runs up the middle of the modiolus to its apex. The modiolus diminishes rapidly in size in the second and succeeding coil.

The bony canal of the cochlea takes two turns and three-quarters round the modiolus. It is about 30 mm. long, and diminishes gradually in diameter

* In the description which follows, the cochlea is supposed to be resting on its base.

CC-0. In Public Domain. Gurukul Kangri Collection, Haridwar

Digitized by Arya Samaj Foundation Chennai and eGangotri

from the base to the summit, where it ends in the *cupula*, which forms the apex of the cochlea. The beginning of this canal is about 3 mm. in diameter; it diverges from the modiolus towards the tympanic cavity and vestibule, and presents three openings. One, the *fenestra cochleæ*, communicates with the tympanic cavity and in the recent state is closed by the *secondary tympanic membrane*; another, of an elliptical form, opens into the vestibule. The third is the aperture of the aquæductus cochleæ, leading to a minute funnel-shaped canal which opens on the inferior surface of the petrous part of the temporal bone, transmits a small vein to join the inferior petrosal sinus, and establishes a communication between the subarachnoid cavity and the scala tympani.

FIG. 993.—The cochlea and vestibule. Exposed from above. (Testut.)

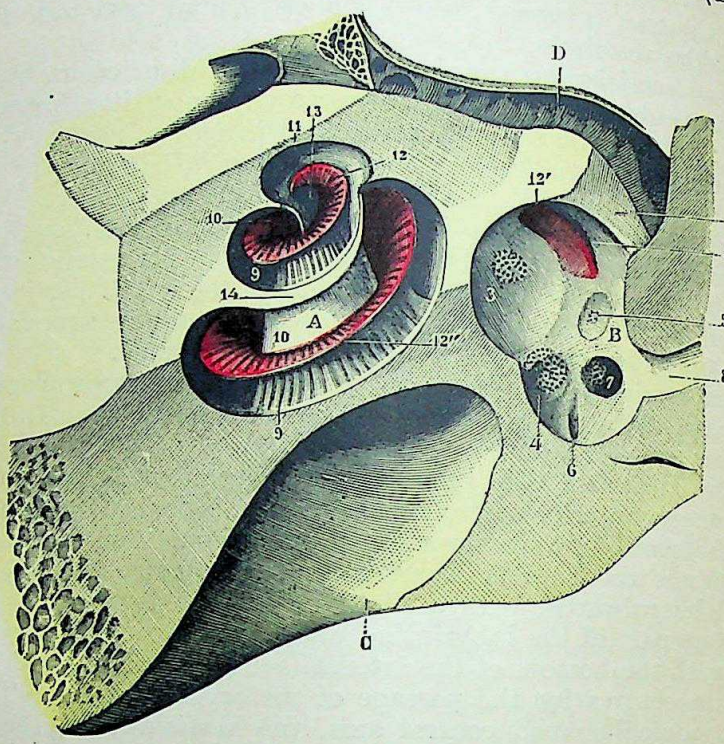

All the hard parts which form the roof of the internal ear have been removed with the saw. A. Cochlea. B. Vestibule. C. Internal acoustic meatus. D. Tympanic cavity. 1. Section of promontory. 2. Fissura vestibuli. 3. Recessus sphæricus. 4. Recessus ellipticus. 5. Fossa cochlearis. 6. Orifice of the aquæductus vestibuli. 7. Inferior opening of the posterior semicircular canal. 8. Non-ampullated end of lateral semicircular canal. 9. Scala tympani of the cochlea. 10. Scala vestibuli. 11. Cupula. 12. Osseous spiral lamina, with 12′, its vestibular origin; 12″, its external border. 13. Helicotrema. 14. Bony wall of cochlea.

The *osseous spiral lamina* is a bony shelf or ledge which winds round and projects from the modiolus into the interior of the canal, like the thread of a screw. It reaches about halfway across the canal, and incompletely divides it into two passages or scalæ: an upper, named the *scala vestibuli*, and a lower, the *scala tympani*. The width of the osseous spiral lamina gradually decreases from the basal to the apical coil of the cochlea, and near the summit of the cochlea the lamina ends in a hook-shaped process, the *hamulus laminæ spiralis*; this assists in forming the boundary of a small opening, the *helicotrema*, through which the two scalæ communicate with each other. From the spiral canal of the modiolus numerous canals pass outwards through the osseous spiral lamina as far as its free edge and transmit branches of the cochlear nerve. In the lower part of the first turn of the cochlea a *secondary spiral lamina* projects inwards from the outer wall of the bony tube; it does not, however, reach the osseous spiral lamina, so that if the laminæ be viewed from the vestibule a narrow fissure, the *fissura vestibuli*, is seen between them.

The *osseous labyrinth* is lined by a thin fibroserous membrane which is closely adherent to the bone; the free surface of the membrane is smooth, and covered with a layer of epithelium. The osseous labyrinth is filled with

CC-0. In Public Domain. Gurukul Kangri Collection, Haridwar

Digitized by Arya Samaj Foundation Chennai and eGangotri

perilymph, a fluid identical in composition, and confluent with, the cerebro-spinal fluid. The part of the petrous bone which immediately surrounds the labyrinth is developed from the cartilaginous ear-capsule; it is denser than the rest of the petrous bone, and exhibits interglobular spaces, which contain cartilage cells (fig. 997). The modiolus of the cochlea, on the other hand, is formed of spongy membrane-bone (Fraser and Dickie *). A tubular process of the lining membrane is prolonged through the aquæductus cochleæ to the inner surface of the dura mater.

The Membranous Labyrinth (figs. 994, 995, 996)

The membranous labyrinth is lodged within the bony labyrinth; it is filled with fluid named *endolymph*, and in its walls the branches of the acoustic nerve are distributed. It consists of: (*a*) two small sacs, the *utricle* and *saccule*, lodged in the vestibule; (*b*) three *semicircular ducts*, enclosed within the semicircular canals; and (*c*) the *ductus cochlearis*, contained within the bony cochlea.

Fig. 994.—A schematic representation of the membranous labyrinth. (J. K. Milne Dickie.)

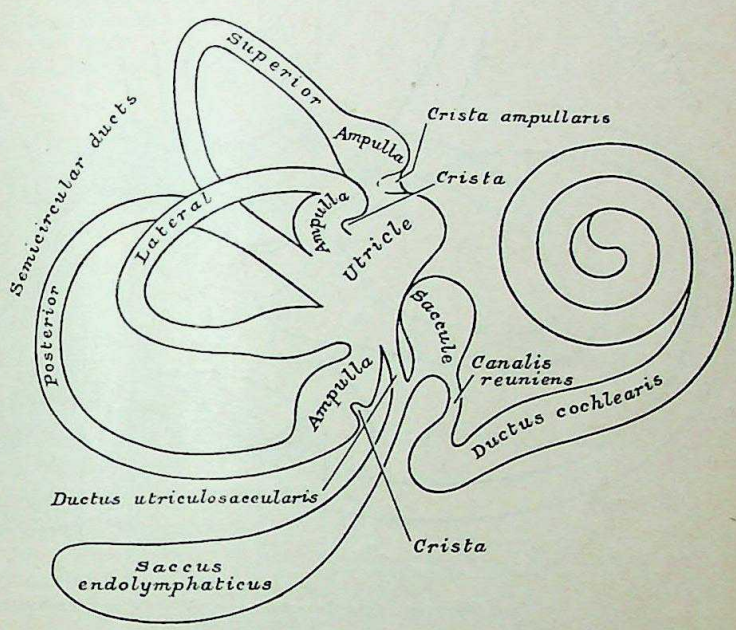

The various parts of the membranous labyrinth form a closed system of channels which, however, communicate freely with one another; the semicircular ducts open into the utricle, the utricle into the saccule through the ductus endolymphaticus, and the saccule into the ductus cochlearis through the canalis reuniens of Hensen.

The membranous labyrinth is fixed at certain points to the wall of the bony labyrinth, but is separated from the greater part of the bony labyrinth by a space which contains the *perilymph*. The perilymphatic space of the vestibule communicates behind with that of the semicircular canals, and opens anteriorly into the scala vestibuli of the cochlea, which in turn opens into the scala tympani through the helicotrema, at the apex of the cochlea. The scala tympani is separated from the tympanic cavity by the secondary tympanic membrane, but is continuous with the subarachnoid cavity through the aquæductus cochleæ.

The utricle, the larger of the two vestibular sacs, is irregularly oblong in shape, and occupies the upper and posterior part of the vestibule, lying in contact with the recessus ellipticus and the part below it. That portion which is lodged in the recessus ellipticus forms a sort of pouch or cul-de-sac; the lateral half of the floor of this is thickened, and forms the *macula acustica utriculi*, which receives the utricular filaments of the acoustic nerve. The ampullæ of the superior and lateral semicircular ducts open into the lateral part of the utricle, while the ampulla of the posterior duct, the crus commune, and the posterior end of the lateral duct open into the medial part of the utricle. The posterior end of the lateral duct widens into a flattened cone which joins the medial end of the utricle at a right angle (Milne Dickie †). From its anteromedial part a fine canal, the *ductus utriculosaccularis*, is given off, and opens into the ductus endolymphaticus.

*J. S. Fraser and J. K. Milne Dickie, *Journal of Anatomy and Physiology*, vol. xlix.
†J. K. Milne Dickie, *Journal of Laryngology, Rhinology and Otology*, vol. xxxv.

CC-0. In Public Domain. Gurukul Kangri Collection, Haridwar

Digitized by Arya Samaj Foundation Chennai and eGangotri

The **saccule** lies in the recessus sphæricus near the opening of the scala vestibuli of the cochlea. When seen from the front it presents a nearly globular form, but it is prolonged backwards in the form of a cone, the upper surface of which is in contact with the under surface of the utricle, and utricle and saccule have here a common wall (Milne Dickie *). On its anterior wall is an oval thickening, the *macula acustica sacculi* (fig. 998), to which the saccular filaments of the acoustic nerve are distributed. Its cavity communicates indirectly through a Y-shaped tube with that of the utricle. From its posterior part a duct, the *ductus endolymphaticus*, is given off, and is joined by the ductus utriculosaccularis; the ductus endolymphaticus passes inwards and then downwards along the aquæductus vestibuli and ends in a blind pouch

Fig. 995.—The right membranous labyrinth of a fifth-month human embryo. Anterolateral aspect. (G. Retzius.) × 10.

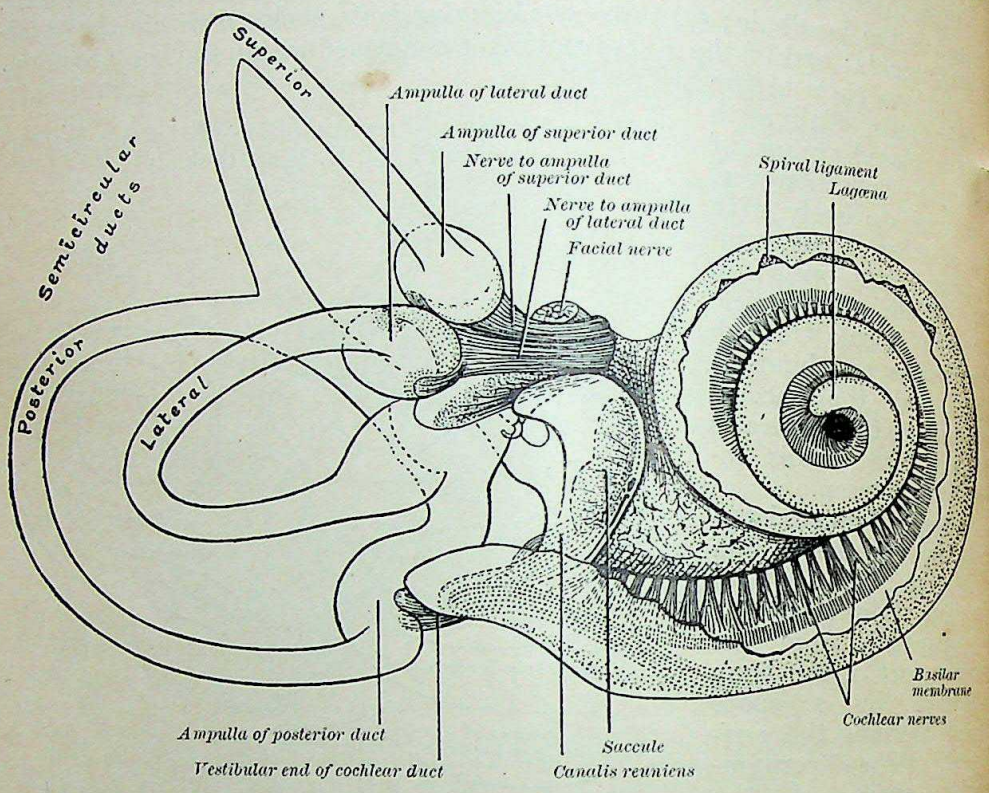

(*saccus endolymphaticus*) under the dura mater on the posterior surface of the petrous portion of the temporal bone. From the lower part of the saccule a short tube, the *canalis reuniens* of Hensen, passes downwards and gradually widens into the vestibular or lower end of the ductus cochlearis (fig. 994).

The **semicircular ducts** (fig. 997) are about one-fourth of the diameter of the osseous semicircular canals, but are similar to them in shape and general form. Each has an ampulla at one end, viz.: the end which lies within the ampulla of the corresponding bony canal. The semicircular ducts open by five orifices into the utricle, one opening being common to the medial end of the superior and the upper end of the posterior duct. In each of the ampullæ the wall is thickened, and projects into the cavity as a transverse elevation shaped somewhat like the figure 8, and named the *septum transversum*; the most prominent part of this septum is termed the *crista ampullaris*.

The utricle, saccule, and semicircular ducts are held in position by fibrous bands which stretch across the perilymphatic space to the bony walls.

Structure (fig. 997).—The walls of the utricle, saccule, and semicircular ducts consist of three layers. The *outer layer* is composed of ordinary fibrous tissue containing blood-vessels and some pigment-cells. The *middle layer*, thicker and more transparent, is named the *tunica propria*, and presents on its internal surface, especially in the semicircular ducts (fig. 997), numerous papilliform projections,

* Loc. cit.

CC-0. In Public Domain. Gurukul Kangri Collection, Haridwar

Digitized by Arya Samaj Foundation Chennai and eGangotri

which, on the addition of acetic acid, exhibit an appearance of longitudinal fibrillation. The *inner layer* is formed of polygonal nucleated epithelial cells. In the maculæ of the utricle and saccule (fig. 998), and in the cristæ ampullares of the semicircular ducts, the middle coat is thickened and the epithelium is columnar, and consists of *supporting cells* and *hair-cells*. The supporting cells are fusiform, and their deep ends are attached to the tunica propria, while their free extremities are united to form a thin cuticle. The hair-cells are flask-shaped, and their deep, rounded ends do not reach the tunica propria, but lie between the supporting cells. The deep part of each hair-cell contains a large nucleus, while its more superficial part is granular and pigmented. The free end of the cell is surmounted by a long, tapering, hair-like filament, which projects into the cavity. The filaments

Fig. 996.—The right membranous labyrinth of a fifth-month human embryo. × 10. Posteromedial aspect. (G. Retzius.)

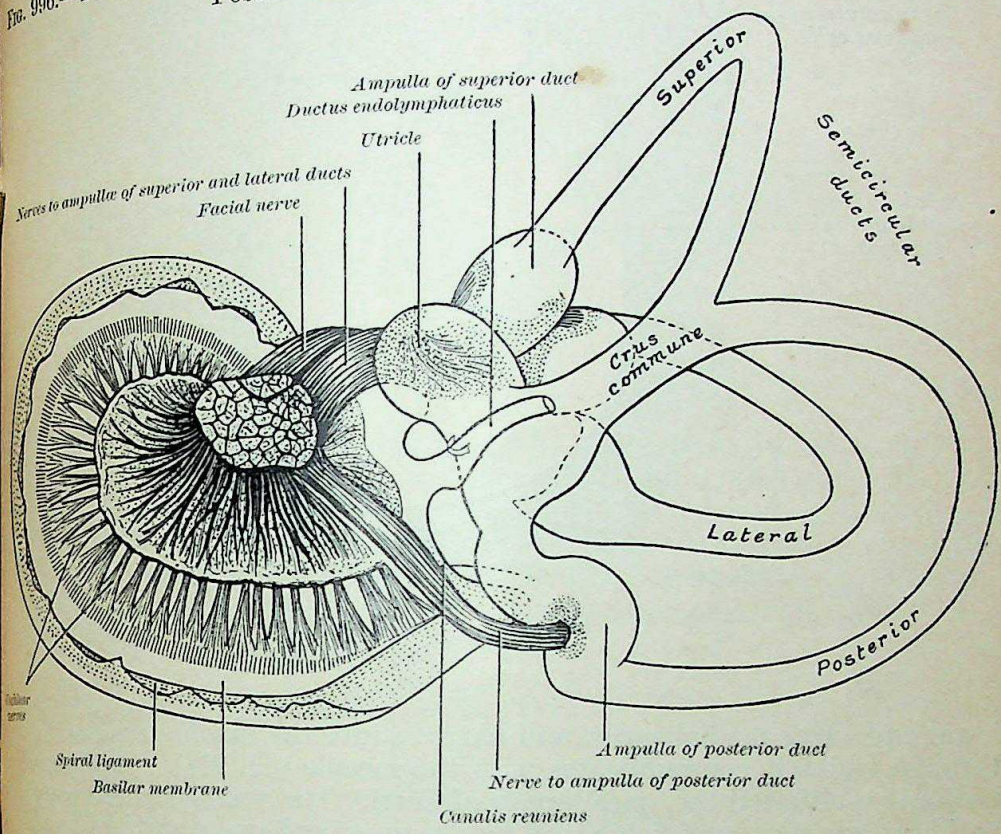

of the vestibular nerve, having pierced the tunica propria, lose their medullary sheaths, and their axis-cylinders split up into fine fibrils which end between the hair-cells.

Two small rounded bodies termed *otoconia*, consisting of crystals of carbonate of lime, are suspended in the endolymph in contact with the free ends of the hairs projecting from the maculæ.

A ridge, named the *crista quarta*, projects into the posterior end of the lateral canal; nerves have been traced to this crista, which is present in most mammals, but exists only in a rudimentary condition in the higher vertebrates.

The **ductus cochlearis** or **scala media** consists of a spirally arranged tube enclosed in the bony canal of the cochlea and lying along its outer wall.

As already stated (p. 1038) the osseous spiral lamina extends only part of the distance between the modiolus and the outer wall of the cochlea, while the *basilar membrane* stretches from the free edge of the lamina to the outer wall of the cochlea, and completes the roof of the scala tympani. A second and more delicate membrane, the *vestibular membrane* (*Reissneri*) extends from the thickened periosteum covering the osseous spiral lamina to the outer wall of the cochlea, where it is attached at some distance above the outer edge of the basilar membrane. A canal is thus shut off between the scala tympani below and the scala vestibuli above; this is the *ductus cochlearis* or *scala media* (figs. 999, 1000). It is triangular on transverse section, its roof

CC-0. In Public Domain. Gurukul Kangri Collection, Haridwar

Digitized by Arya Samaj Foundation Chennai and eGangotri

being formed by the vestibular membrane, its outer wall by the periosteum lining the bony canal, and its floor by the membrana basilaris and the outer part of the osseous spiral lamina. The upper extremity of the ductus cochlearis is closed, and is named the *lagœna*; it is attached to the cupula cochleæ. The

Fig. 997.—A transverse section through the right posterior semicircular canal and duct of an adult man. × 51. (J. K. Milne Dickie.)

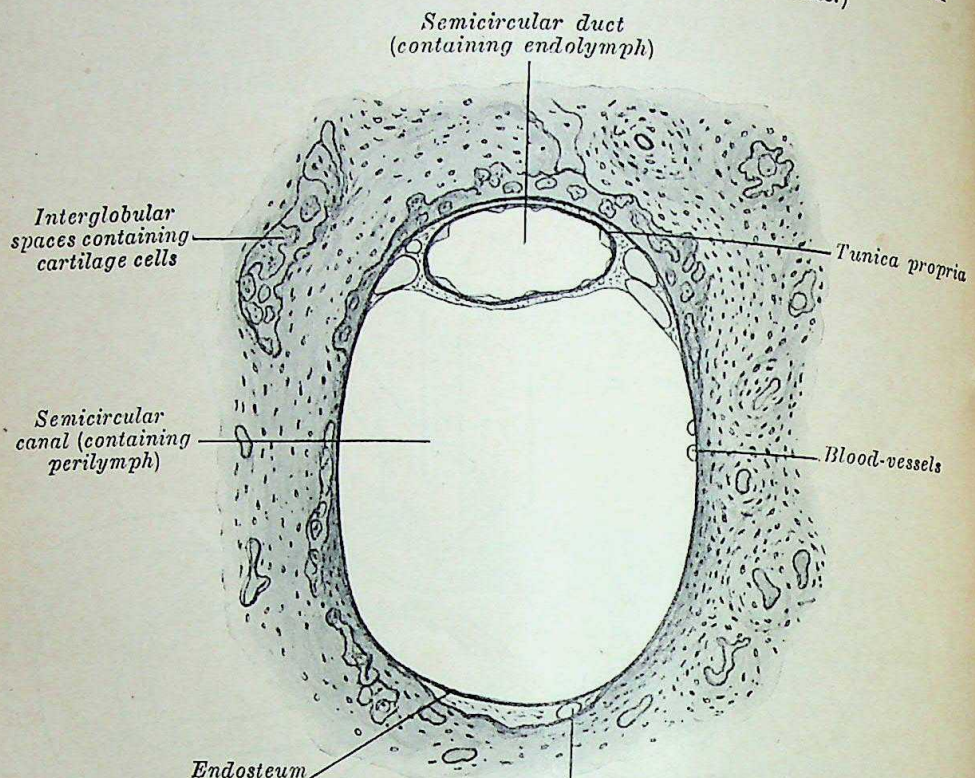

lower end turns medialwards, and narrows into the *canalis reuniens* of Hensen, through which it communicates with the saccule (fig. 994). On the membrana basilaris is situated the spiral organ of Corti. The vestibular membrane is thin and homogeneous, and is covered on its upper and under surfaces by a layer of flattened epithelium. The periosteum forming the outer wall of the ductus cochlearis is greatly thickened and altered in character. It projects inwards inferiorly as a triangular prominence, the *crista basilaris*, to which the outer edge of the basilar membrane is fixed; immediately above this is a concavity, the *sulcus spiralis externus*, above which the periosteum contains numerous blood-vessels, and is termed the *stria vascularis*.

Fig. 998.—A transverse section of the macula acustica sacculi. (Retzius.)

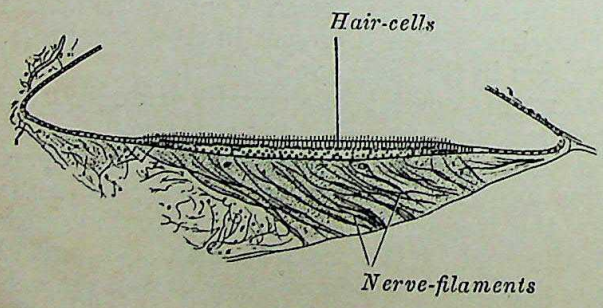

The osseous spiral lamina consists of two plates of bone, and between these are the canals for the transmission of the filaments of the acoustic nerve. On the upper plate of that part of the lamina which is contained within the ductus cochlearis the periosteum is thickened to form the *limbus laminæ spiralis* (fig. 1001); this ends externally in a concavity, the *sulcus spiralis internus*, which presents, on section, the form of the letter C; the upper part formed by the overhanging edge of the limbus, is named the *vestibular lip*; the lower part, prolonged and tapering, is called the *tympanic lip*, and is

CC-0. In Public Domain. Gurukul Kangri Collection, Haridwar

Digitized by Arya Samaj Foundation Chennai and eGangotri

perforated by numerous foramina for the passage of the branches of the cochlear nerve. The upper surface of the vestibular lip is intersected at right angles by a number of furrows, between which are numerous elevations; these present the appearance of teeth on the free surface and margin of the lip, and

FIG. 999.—A longitudinal section through the cochlea. Diagrammatic.

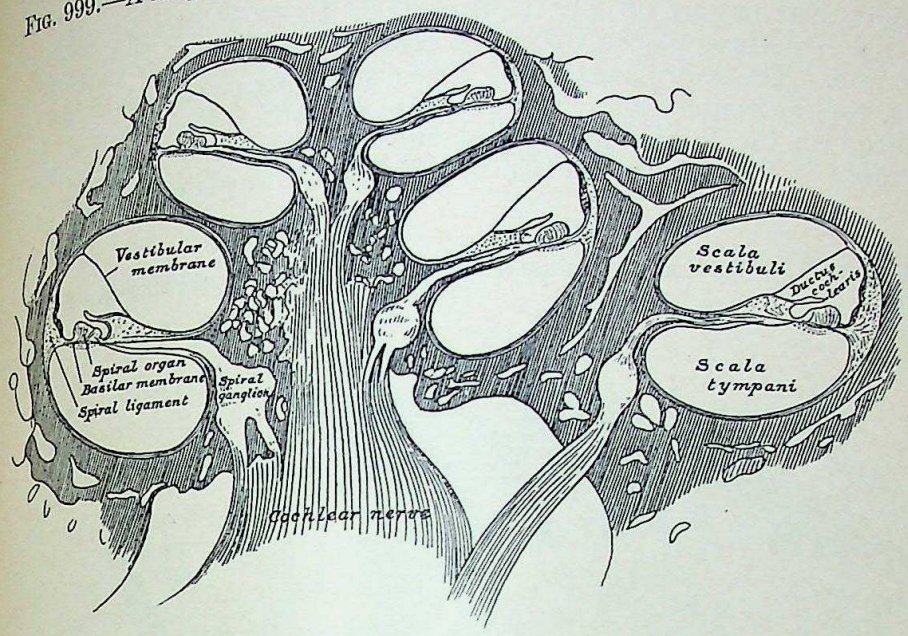

are named by Huschke the *auditory teeth* (fig. 1001). The limbus is covered by a layer of what appears to be squamous epithelium, but only the cells covering the teeth are flattened, those in the furrows being columnar, and occupying the intervals between the elevations. This epithelium is continuous on the one hand with that lining the sulcus spiralis internus, and on the other with that covering the under surface of the vestibular membrane.

FIG. 1000.—A transverse section through the middle coil of the ductus cochlearis. (Retzius.)

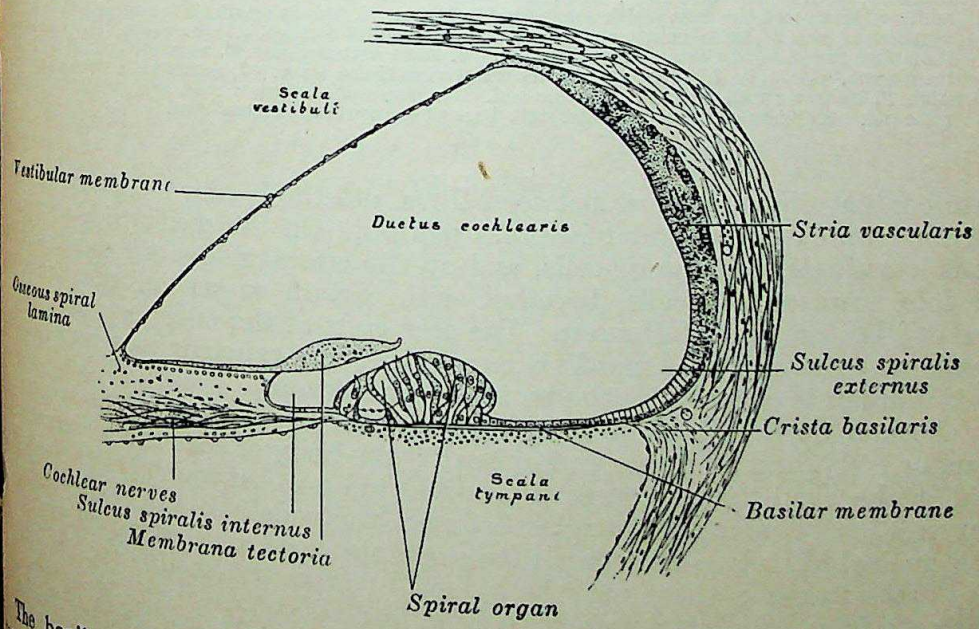

The basilar membrane.—The basilar membrane stretches from the tympanic lip of the osseous spiral lamina to the crista basilaris. Its inner part is thin, and is named the *zona arcuata*; it supports the spiral organ of Corti; the outer part is thicker and striated, and is termed the *zona pectinata*.

CC-0. In Public Domain. Gurukul Kangri Collection, Haridwar

Digitized by Arya Samaj Foundation Chennai and eGangotri

Its width increases from 0·21 mm. in the basal turn to 0·36 mm. in the apical turn of the cochlea. The gradual increase in the width of the basilar membrane is accompanied by a corresponding narrowing of the osseous spiral lamina, and a decrease in the size and density of the crista basilaris. The under-surface of the membrane is covered by a layer of vascular connective tissue; one of the vessels in this tissue is somewhat larger than the rest, and is named the *vas spirale*; it lies below Corti's tunnel.

The **spiral organ of Corti** (figs. 1000, 1002) is composed of a series of epithelial structures placed upon the zona arcuata or inner part of the basilar membrane. The more central of these structures are two rows of rod-like bodies, the *inner and outer rods or pillars of Corti*. The bases of the rods are supported on the basilar membrane, those of the inner row at some distance from those of the outer; the two rows incline towards each other and, coming

Fig. 1001.—The limbus laminæ spiralis and the basilar membrane. Schematic. (Testut.)

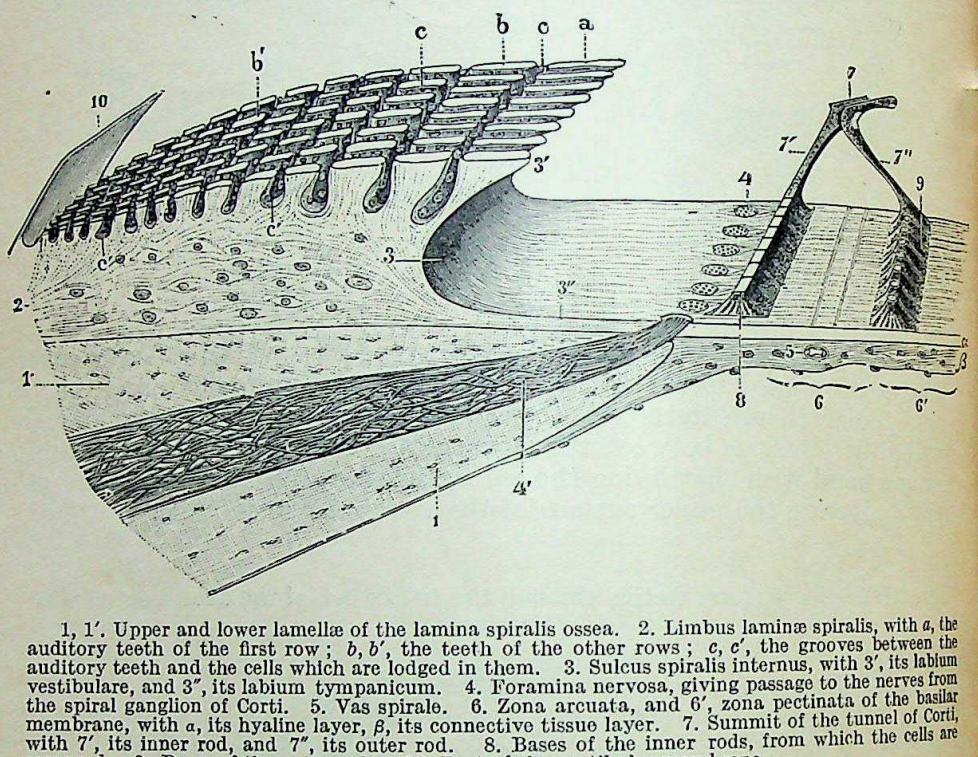

1, 1'. Upper and lower lamellæ of the lamina spiralis ossea. 2. Limbus laminæ spiralis, with *a*, the auditory teeth of the first row; *b*, *b'*, the teeth of the other rows; *c*, *c'*, the grooves between the auditory teeth and the cells which are lodged in them. 3. Sulcus spiralis internus, with 3', its labium vestibulare, and 3'', its labium tympanicum. 4. Foramina nervosa, giving passage to the nerves from the spiral ganglion of Corti. 5. Vas spirale. 6. Zona arcuata, and 6', zona pectinata of the basilar membrane, with α, its hyaline layer, β, its connective tissue layer. 7. Summit of the tunnel of Corti, with 7', its inner rod, and 7'', its outer rod. 8. Bases of the inner rods, from which the cells are removed. 9. Bases of the outer rods. 10. Part of the vestibular membrane.

into contact above, enclose between them and the basilar membrane the *tunnel of Corti* which is triangular in cross section. On the medial side of the inner rods is a single row of hair-cells, and on the lateral side of the outer rods three or four rows of hair-cells, together with certain supporting cells termed the cells of Deiters and of Hensen. The free ends of the outer hair-cells occupy a series of apertures in a net-like membrane, the reticular membrane, and the entire organ is covered by the tectorial membrane.

Rods of Corti.—Each of these consists of a base or foot-plate, an elongated part or body, and an upper end or head; the body of each rod is finely striated, but in the head there is an oval non-striated portion which stains deeply with carmine. Occupying the angles between the rods and the basilar membrane are nucleated cells which partly envelop the rods and extend on to the floor of Corti's tunnel; these may be looked upon as the undifferentiated parts of the cells from which the rods have been formed.

The *inner rods* number nearly 6000, and their bases rest on the basilar membrane close to the tympanic lip of the sulcus spiralis internus. The shaft or body of each is sinuously curved and forms an angle of about 60° with the basilar membrane. The head resembles the proximal end of the ulna, and presents a deep concavity which accommodates a convexity on the head of

CC-0. In Public Domain. Gurukul Kangri Collection, Haridwar

Digitized by Arya Samaj Foundation Chennai and eGangotri

the outer rod. The head-plate, or portion overhanging the concavity, overlaps the head-plate of the outer rod.

The *outer rods*, nearly 4000 in number, are longer and more obliquely set than the inner, forming with the basilar membrane an angle of about 40°. Their heads are convex internally; they fit into the concavities on the heads of the inner rods, and are continued outwards as thin flattened plates, termed the *phalangeal processes*, which unite with the phalangeal processes of Deiters' cells to form the reticular membrane.

The distances between the bases of the inner and outer rods increase from the base to the apex of the cochlea, while the angles between the rods and the basilar membrane diminish.

Hair-cells.—The hair-cells are short columnar cells; their free ends are on a level with the heads of Corti's rods, and each is surmounted by about

Fig. 1002.—A transverse section through the spiral organ of Corti. Magnified. (G. Retzius.)

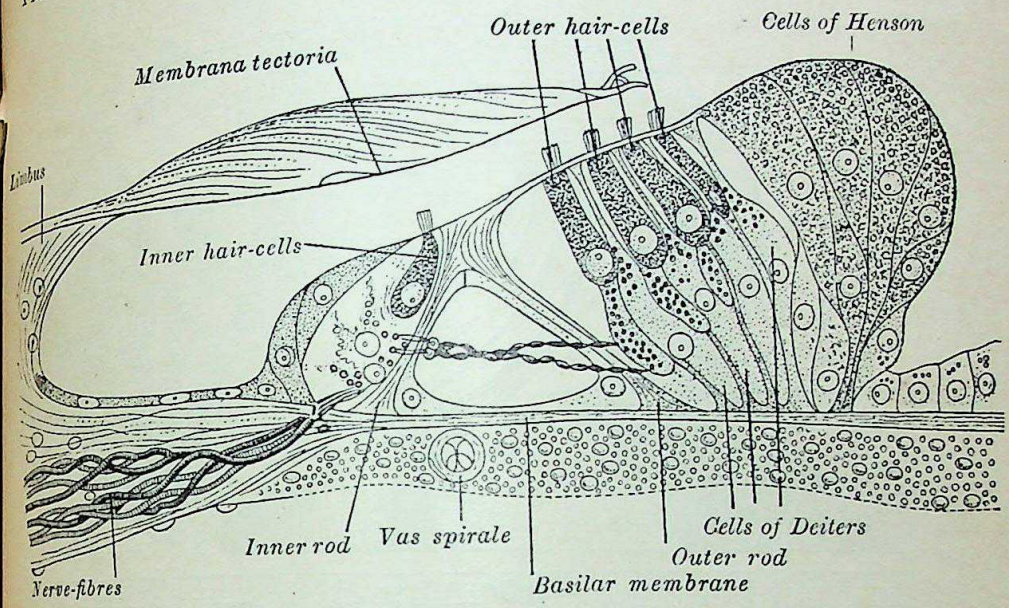

twenty hair-like processes arranged in the form of a crescent with its concavity directed inwards. The deep ends of the cells reach about halfway along Corti's rods, and each contains a large nucleus; in contact with the deep ends of the hair-cells are the terminal filaments of the cochlear nerve. The inner hair-cells, about 3500 in number, are arranged in a single row on the medial (axial) side of the inner rods, and, their diameters being greater than those of the rods, each is supported by more than one rod. The free ends of the inner hair-cells are encircled by a cuticular membrane which is fixed to the heads of the inner rods. Adjoining the inner hair-cells are one or two rows of columnar supporting cells, which, in turn, are continuous with the cubical cells lining the sulcus spiralis internus. The *outer* hair-cells number about 12,000, and are nearly twice as long as the inner. In the basal coil of the cochlea they are arranged in three regular rows; in the apical coil, in four somewhat irregular rows.

Between the rows of the outer hair-cells are rows of supporting cells, called the *cells of Deiters*; their expanded bases are planted on the basilar membrane, while the opposite end of each presents a clubbed extremity or *phalangeal process*. Immediately to the outer side of Deiters' cells are five or six rows of columnar cells, the *supporting cells of Hensen*. Their bases are narrow, while their upper parts are expanded and form a rounded elevation on the floor of the ductus cochlearis. The columnar cells lying outside Hensen's cells are termed the *cells of Claudius*. A space exists between the outer rods of Corti and the adjacent hair-cells; this is called the *space of Nuel*.

The *reticular lamina* (fig. 1003) is a delicate framework perforated by circular holes which are occupied by the free ends of the outer hair-cells. It extends

CC-0. In Public Domain. Gurukul Kangri Collection, Haridwar

Digitized by Arya Samaj Foundation Chennai and eGangotri

from the heads of the outer rods of Corti to the external row of the outer hair-cells, and is formed by several rows of minute fiddle-shaped cuticular structures, called *phalanges*, between which are circular apertures containing the free ends of the hair-cells. The innermost row of phalanges consists of the phalangeal processes of the outer rods of Corti; the outer rows are formed by the modified free ends of Deiters' cells.

The *tectorial membrane* overlies the sulcus spiralis internus and the spiral organ of Corti. It is wider and thicker in the apical than in the basal part of the cochlea. Its inner part is thin and is attached to the vestibular lip of the limbus laminæ spiralis, the attachment reaching as far as the vestibular membrane. The outer part is thick and padlike, the thickness being greatest over, or slightly to the inner side of, the upper ends of Corti's rods. Retzius

FIG. 1003.—The reticular lamina and subjacent structures. Schematic. (Testut.)

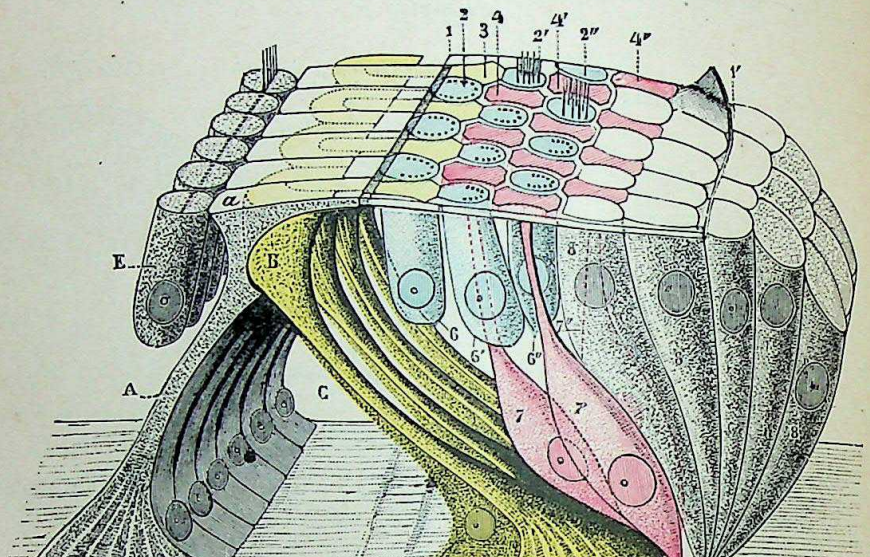

A. Inner rod of Corti, with *a*, its head. B. Outer rod (in yellow). C. Tunnel of Corti. D. Basilar membrane. E. Inner hair-cells. 1, 1′. Internal and external borders of the reticular lamina. 2, 2′, 2″. The three rows of circular holes (in blue). 3. First row of phalanges (in yellow). 4, 4′, 4″. Second, third, and fourth rows of phalanges (in red). 6, 6′, 6″. The three rows of outer hair-cells (in blue). 7, 7′, 7″. Cells of Deiters. 8. Cells of Hensen and Claudius.

described the outer edge as being attached to the outer row of Deiters' cells, while others maintain that it forms a ragged or frayed margin. Hardesty,* who has examined the membrane in the pig, states that this edge is free and bluntly rounded, but finely and irregularly scalloped. The hairs of the hair-cells project into the under surface of the membrane, and on this surface, opposite the interval between the inner and outer rows of hair-cells, is a band, named *Hensen's stripe*.

Hardesty has shown that the membrane "consists of multitudes of delicate fibrils embedded in a transparent matrix of a soft, collagenous, semi-solid character with marked adhesiveness." The prevailing course of the fibres is obliquely transverse, slanting from the vestibular lip towards the apex of the cochlea. The fibres pass in curves from the vestibular lip and upper surface of the membrane to its under surface, where by their interlacement they produce the appearance known as Hensen's stripe. He also describes a thin, exceedingly delicate *accessory tectorial membrane*, lying along the under surface of the outer zone of the main membrane, and lightly attached to the latter by its outer edge.

The **acoustic nerve**, or nerve of hearing, divides near the bottom of the internal acoustic meatus into an anterior or cochlear, and a posterior or vestibular portion. The deep connexions of these nerves are described on pp. 913 to 915.

* Irving Hardesty, *American Journal of Anatomy*, vol. viii.

CC-0. In Public Domain. Gurukul Kangri Collection, Haridwar

Digitized by Arya Samaj Foundation Chennai and eGangotri

The *vestibular nerve* supplies the utricle, the saccule, and the ampullæ of the semicircular ducts. On the trunk of the nerve, within the internal acoustic meatus, is the *vestibular ganglion* (ganglion of Scarpa), from the bipolar nerve-cells which the fibres of the nerve take origin. On the distal side of the ganglion the nerve splits into a superior, an inferior, and a posterior branch.* The filaments of the *superior branch* are transmitted through the foramina in the

Fig. 1004.—A diagrammatic view of the lateral end of the right internal acoustic meatus. (Testut.)

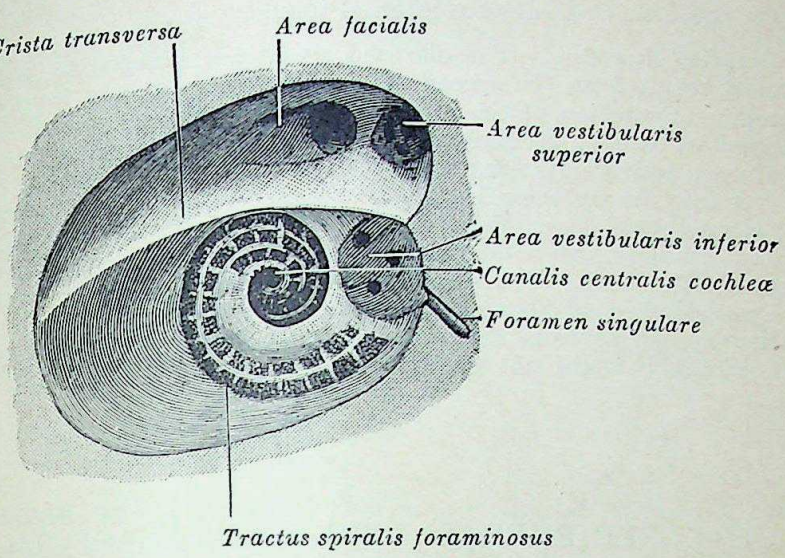

area vestibularis superior, and end in the macula of the utricle and in the cristæ ampullares of the superior and lateral semicircular ducts; those of the *inferior branch* traverse the foramina in the area vestibularis inferior, and end in the macula of the saccule. The *posterior branch* runs through the foramen singulare in the postero-inferior part of the bottom of the meatus and divides into filaments for the supply of the crista ampullaris of the posterior semicircular duct (fig. 1004).

The *cochlear nerve*, the nerve of hearing, divides into numerous filaments at the base of the modiolus; those for the basal and middle coils pass through the foramina in the tractus spiralis foraminosus, those for the apical coil through the canalis centralis, and the nerves bend outwards and pass between the lamellæ of the osseous spiral lamina. Occupying the spiral canal of the modiolus is the *spiral ganglion of the cochlea* (ganglion of Corti) (fig. 1005), consisting of bipolar nerve-cells from which the fibres of the nerve take origin. Reaching the outer edge of the osseous spiral lamina, the nerve-fibres pass through the foramina in the tympanic lip; some end by arborising around the deep ends of the inner hair-cells, while others pass between Corti's rods and across Corti's tunnel, and end in a similar manner in relation to the outer hair-cells. The hair-cells in the basal and middle coils are more richly supplied with nerves than the hair-cells in the apical coil. The cochlear nerve gives off a vestibular branch to supply the vestibular end of the ductus cochlearis; the filaments of this branch traverse the foramina in the fossa cochlearis (p. 1036).

Fig. 1005.—Part of the cochlear division of the acoustic nerve. Highly magnified. (Henle.)

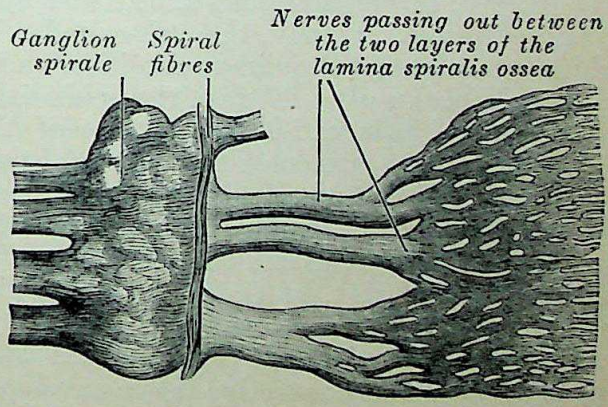

* The nerve sometimes splits on the proximal side of the ganglion, which is then divided into three parts, one on each branch of the nerve. When this occurs the ganglion of the posterior division is placed in the foramen singulare.

CC-0. In Public Domain. Gurukul Kangri Collection, Haridwar

Digitized by Arya Samaj Foundation Chennai and eGangotri

Vessels. The *arteries of the labyrinth* are the internal auditory branch of the basilar artery, and the stylomastoid branch of the posterior auricular artery. The internal auditory artery divides at the bottom of the internal acoustic meatus into two branches, cochlear and vestibular. The cochlear branch subdivides into twelve or fourteen twigs, which traverse the canals in the modiolus, and are distributed, in the form of a capillary network, in the lamina spiralis and basilar membrane. The vestibular branches are distributed to the utricle, saccule, and semicircular ducts.

The *veins* of the vestibule and semicircular canals accompany the arteries, and receiving the veins of the cochlea at the base of the modiolus, unite to form the internal auditory veins which end in the posterior part of the superior petrosal sinus or in the transverse sinus. A small vein, from the basal turn of the cochlea, traverses the aqueductus cochleæ and joins the internal jugular vein.

Applied Anatomy.—The diseased conditions which may be found in the internal ear usually result from the spread of a suppurative process from the middle ear—thus in chronic suppuration of the latter, destruction of the internal ear may take place, with necrosis of parts of the cochlea or vestibule. Such cases will be associated with 'nerve-deafness,' and the disease may spread by means of the sheaths of the facial and acoustic nerves into the posterior fossa of the skull.

Hæmorrhage occasionally occurs into the labyrinth in certain blood disorders, resulting in complete 'nerve-deafness,' and such conditions may be associated with symptoms known as 'Menière's disease,' vertigo, giddiness, and tinnitus. Nerve-deafness is diagnosed when all 'bone-conduction' of sound is lost, and is most commonly seen in patients suffering from congenital syphilis, many deaf-mutes being the subjects of this condition. It is also not rare after mumps.

THE PERIPHERAL TERMINATIONS OF THE NERVES OF GENERAL SENSATIONS

The peripheral terminations of the nerves associated with general sensations (i.e. the muscular sense and the senses of heat, cold, pain, and pressure) are widely distributed throughout the body. These nerves may end (*a*) as *free fibrils* amongst the tissue elements, or (*b*) in *special end-organs* where the terminal nerve-filaments are enclosed in capsules.

Free nerve-endings occur chiefly in the epidermis and in the epithelium covering certain mucous membranes; they occur in the stratified squamous epithelium of the cornea, in the root-sheaths and papillæ of the hairs, and around the bodies of the sudoriferous glands.

When the nerve-fibre approaches its termination, the medullary sheath suddenly disappears, leaving the axis-cylinder surrounded by the neurolemma. After a time the fibre loses its neurolemma, and consists only of an axis-cylinder, which can be seen, in preparations stained with chloride of gold, to be made up of fine varicose fibrillæ. Finally, the axis-cylinder breaks up into its constituent fibrillæ, which often present regular varicosities, and anastomosing with one another, end in small knobs or discs between the epithelial cells.

Peripheral pain end-organs consist of the free arborisations of naked axis-cylinders; end-organs other than those of pain are enveloped by capsules.

The **special end-organs** exhibit great variety in size and shape, but have one feature in common, viz. the terminal fibrils of the nerve are enveloped by a capsule. Included in this group are the end-bulbs of Krause; the corpuscles of Grandry, of Pacini, of Herbst, of Golgi and Mazzoni, of Wagner and Meissner; and the neurotendinous and neuromuscular spindles.

The *end-bulbs of Krause* (fig. 1006) are minute cylindrical or oval bodies, consisting of a capsule of connective tissue enveloping a soft semi-fluid core in which the axis-cylinder terminates either in a bulbous extremity or in a coiled-up plexiform mass. End-bulbs are found in the conjunctiva of the eye (where they are spheroidal in shape in man, but cylindrical in most other animals), in the mucous membrane of the lips and tongue, and in the epineurium of nerve-trunks. They are also found in the penis and clitoris, and have there received the name of *genital corpuscles*; in these situations they have a mulberry-like appearance, being constricted by connective tissue septa into from two to six knob-like masses. In the synovial strata of certain joints (e.g. those of the fingers), rounded or oval end-bulbs occur, and are designated *articular end-bulbs*.

CC-0. In Public Domain. Gurukul Kangri Collection, Haridwar

Digitized by Arya Samaj Foundation Chennai and eGangotri

The *tactile corpuscles of Grandry* (fig. 1007*a*) occur in the papillæ of the beaks and tongues of ducks and geese. Each has a capsule composed of a delicate,

Fig. 1006.—An end-bulb of Krause. (From Klein's Elements of Histology.)

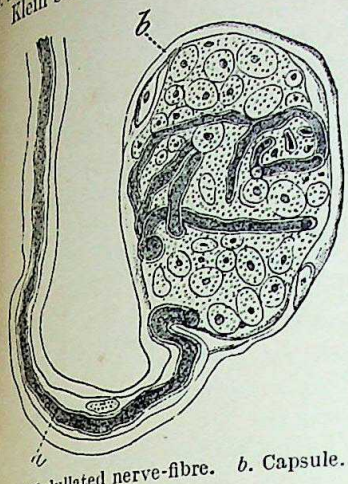

a. Medullated nerve-fibre. *b*. Capsule.

Fig. 1007.—Tactile corpuscles; (*a*) of Grandry, (*b*) of Herbst.

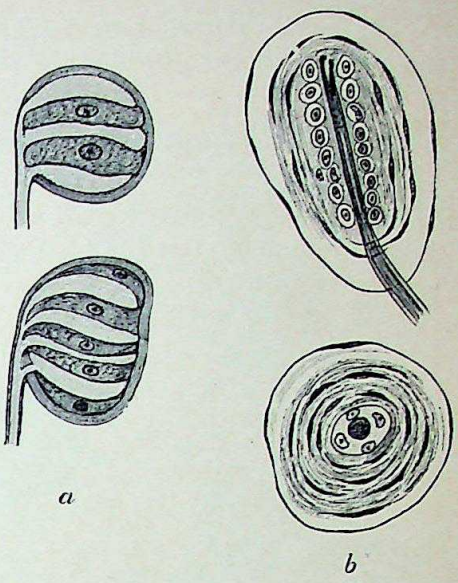

nucleated membrane, within which are two or more granular, somewhat flattened cells between which the axis-cylinder ends in flattened discs.

The *Pacinian corpuscles* (fig. 1008) are found in the subcutaneous tissue on the nerves of the palm of the hand and sole of the foot, and in the genital organs of both sexes; they also occur on the nerves of the joints, and in some other situations, as in the mesentery and pancreas of the cat and along the tibia of the rabbit. Each of these corpuscles is attached to and encloses the termination of a single nerve-fibre. The corpuscle (which is visible to the naked eye and can be most easily demonstrated in the mesentery of a cat) consists of a number of concentric lamellæ or capsules arranged around a central space, in which the nerve-fibre is contained. Each lamella is composed of bundles of fine connective tissue fibres, and is lined on its inner surface by a single layer of flattened cells. The central space is elongated or cylindrical in shape, and filled with a transparent core, in the middle of which the axis-cylinder traverses the space to near its distal extremity, where it ends in one or more small knobs. Todd and Bowman have described minute arteries as entering by the sides of the nerves, and forming capillary loops in the intercapsular spaces, and even penetrating into the central space.

Fig. 1008.—A Pacinian corpuscle, with its system of capsules and its central cavity.

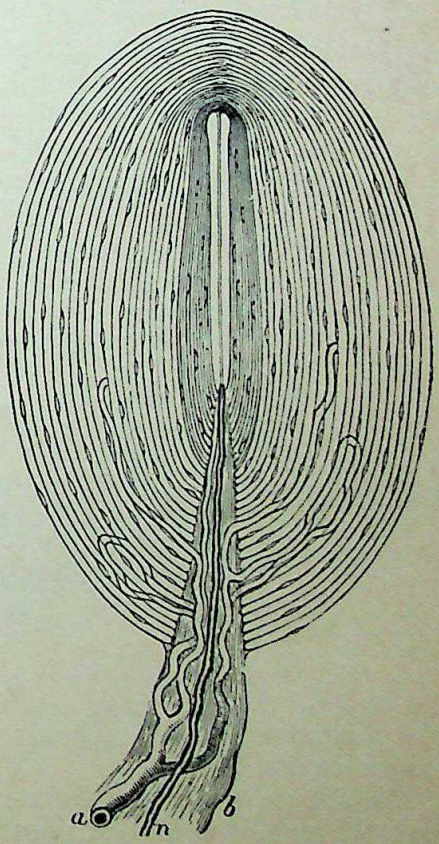

a. Arterial twig, ending in capillaries, which form loops in some of the intercapsular spaces; one penetrates to the central capsule. *b*. The fibrous tissue of the stalk. *n*. Nerve-fibre advancing to the central capsule, there losing its medullary sheath, and passing along the core to the central cavity, where it terminates in a tuberculated enlargement.

Herbst has described a nerve-ending somewhat similar to the Pacinian corpuscle, in the mucous membrane of the tongue of the duck, and in some other situations. It differs, however, from the Pacinian corpuscle in being smaller, in its capsules being more closely approximated, and especially in the fact that the axis-cylinder

CC-0. In Public Domain. Gurukul Kangri Collection, Haridwar

Digitized by Arya Samaj Foundation Chennai and eGangotri

in the central clear space is coated with a continuous row of nuclei. These nerve-endings are known as the *corpuscles of Herbst* (fig. 1007*b*).

The *corpuscles of Golgi and Mazzoni* are found in the subcutaneous tissue of the pulp of the fingers. They differ from Pacinian corpuscles in that their capsules are thinner, their contained cores thicker, and in the latter the axis-cylinders ramify more extensively and end in flat expansions.

The *tactile corpuscles of Wagner and Meissner* (fig. 1009) are oval-shaped bodies which occur in the papillæ of the corium of the hand and foot, the front of the forearm, the skin of the lips, the mucous membrane of the tip of the tongue, the palpebral conjunctiva, and the skin of the mammary papilla. Each is enveloped by a connective tissue capsule, which sends membranous septa into the interior. The axis-cylinder passes through the capsule, and after making several spiral turns round the body of the corpuscle ends in small globular or pear-shaped enlargements.

Fig. 1009.—A papilla of the hand, containing a tactile corpuscle of Wagner and Meissner. × 350.

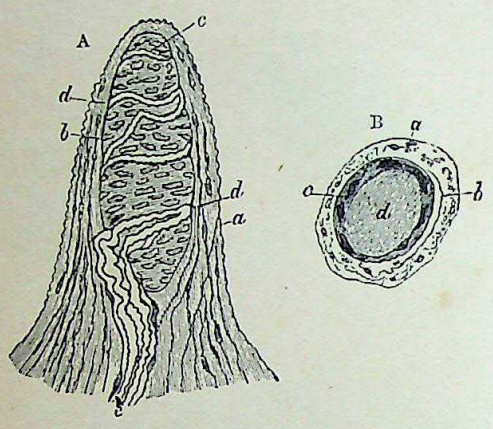

A. Side view of a papilla. *a*. Capsule. *b*. Tactile corpuscle. *c*. Small nerve of the papilla, with neurolemma. *d*. Its two nerve-fibres running with spiral coils round the tactile corpuscle *e*. Apparent termination of one of these fibres. B. Transverse section of a tactile papilla. *a*. Capsule. *b*. Nerve-fibre. *c*. Outer layer of the tactile corpuscle, with nuclei. *d*. Clear internal substance.

Corpuscles of Ruffini.—Ruffini described a special variety of nerve-ending in the subcutaneous tissue of the human finger (fig. 1010), and mostly situated at the junction of the corium with the subcutaneous tissue. They are oval in shape, and consist of strong connective tissue sheaths; inside these the nerve-fibres divide into numerous branches, which show varicosities and end in small free knobs.

The *neurotendinous spindles* or *organs of Golgi* are chiefly found near the junctions of tendons with muscles. Each is enclosed in a capsule which contains a number of enlarged tendon-fasciculi (*intrafusal fasciculi*). One or more nerve-fibres perforate the side of the capsule and lose their medullary sheaths; the

Fig. 1010.—A nerve-ending of Ruffini.

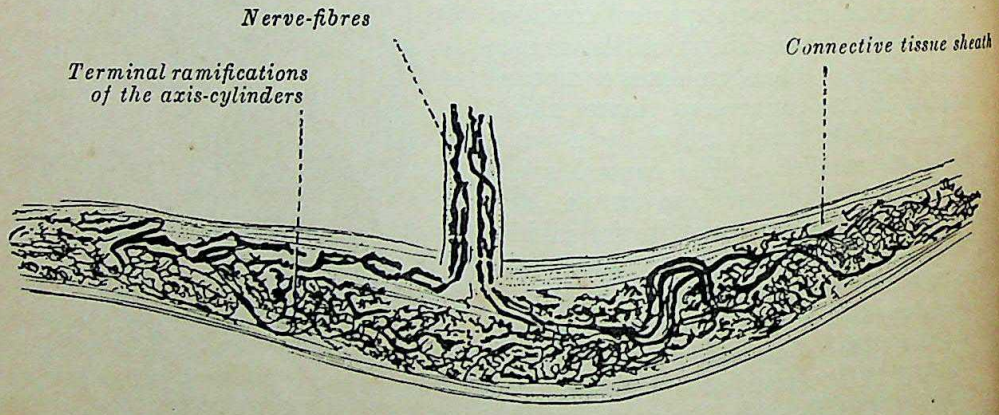

axis-cylinders subdivide and end between the tendon-fibres in irregular discs or varicosities (fig. 1011).

The *neuromuscular spindles* are present in the majority of voluntary muscles, and consist of small bundles of peculiar muscular fibres (*intrafusal fibres*), embryonic in type, invested by capsules, within which nerve-fibres, experimentally shown to be sensory, terminate. These neuromuscular spindles vary in length from 0·8 mm. to 5 mm. and have a fusiform appearance. The large medullated nerve-fibres passing to the end-organ are from one to three or four in number; entering the fibrous capsule, they divide several times, and, losing their medullary sheaths,

CC-0. In Public Domain. Gurukul Kangri Collection, Haridwar

Digitized by Arya Samaj Foundation Chennai and eGangotri

...mately end in naked axis-cylinders encircling the intrafusal fibres by flattened ...pansions, or irregular ovoid or rounded discs (fig. 1012). Neuromuscular spindles

FIG. 1011.—A neurotendinous spindle or organ of Golgi from the human tendo calcaneus. (After Ciaccio.)

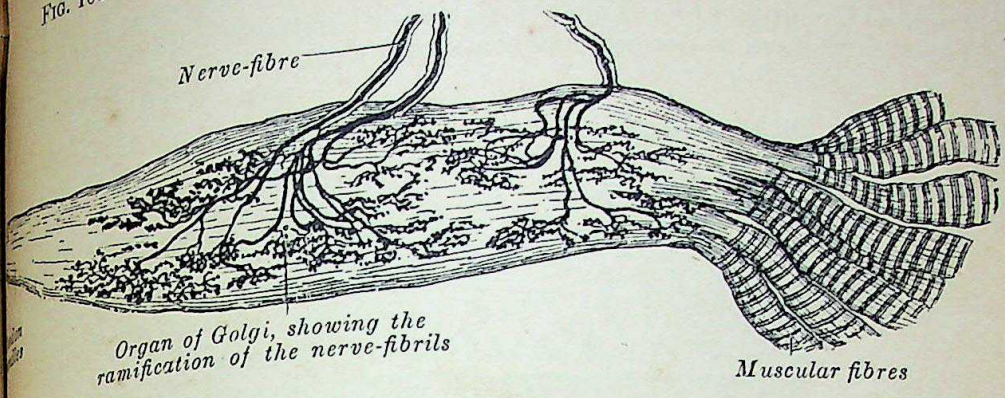

...e not yet been demonstrated in the muscles of the tongue, and only a few exist ...the ocular muscles.

FIG. 1012.—The middle third of a terminal plaque in the muscle-spindle of an adult cat. (After Ruffini.)

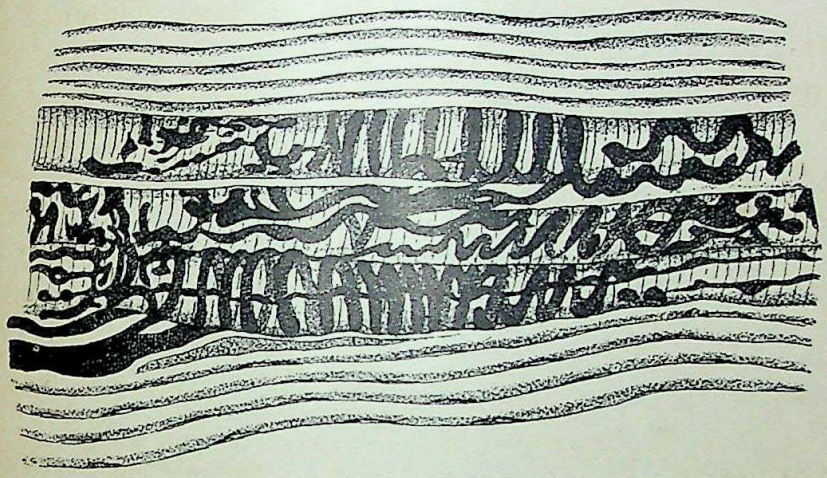

THE COMMON INTEGUMENT

The **integument** or **skin** (fig. 1013) covers the body and protects the deeper tissues. ...contains the peripheral endings of many of the sensory nerves, plays an important ...rt in the regulation of the body temperature, and possesses limited excretory ...d absorbing powers. It consists principally of a layer of vascular connective ...ue, named the *corium* or *cutis vera*, and an external covering of epithelium, ...med the *epidermis* or *cuticle*. On the surface of the former layer are sensitive ...d vascular *papillæ*; and within, or beneath it, are certain organs with special ...ctions: namely, the *sudoriferous* and *sebaceous glands*, and the *hair-follicles*.

The **epidermis** or **cuticle** is non-vascular, and consists of stratified epithelium ...g. 1014). It varies in thickness in different parts. In some situations, as in the palms ...the hands and soles of the feet, it is thick, hard, and horny in texture. This may ...in a measure due to the fact that these parts are exposed to intermittent pressure, ...that this is not the only cause is proved by the fact that the condition exists ...a very considerable extent at birth. The more superficial layers of cells form ...horny layer (*stratum corneum*), which may be separated by maceration from a ...ger stratum, the *stratum mucosum*, consisting of several layers of differently ...ped cells. The free surface of the epidermis is marked by a network of linear ...rrows of variable size, dividing the surface into a number of polygonal or lozenge-...ped areas. These furrows are large opposite the flexures of the joints, and

CC-0. In Public Domain. Gurukul Kangri Collection, Haridwar

Digitized by Arya Samaj Foundation Chennai and eGangotri

correspond with the folds in the corium produced by the joint-movements. In other situations, as upon the back of the hand, they are small, and intersect one another at various angles. Upon the palmar surfaces of the hands and fingers, and upon the soles of the feet, these lines are fine but very distinct, and are disposed in more or less parallel curves; they depend upon the large size and peculiar arrangement of the papillæ upon which the epidermis is placed. In each individual the lines on the tips of the fingers and thumbs form distinct patterns unlike those of any other person. A method of determining the identity of a criminal is based on this fact.

FIG. 1013.—A section through the skin. Magnified. Diagrammatic.

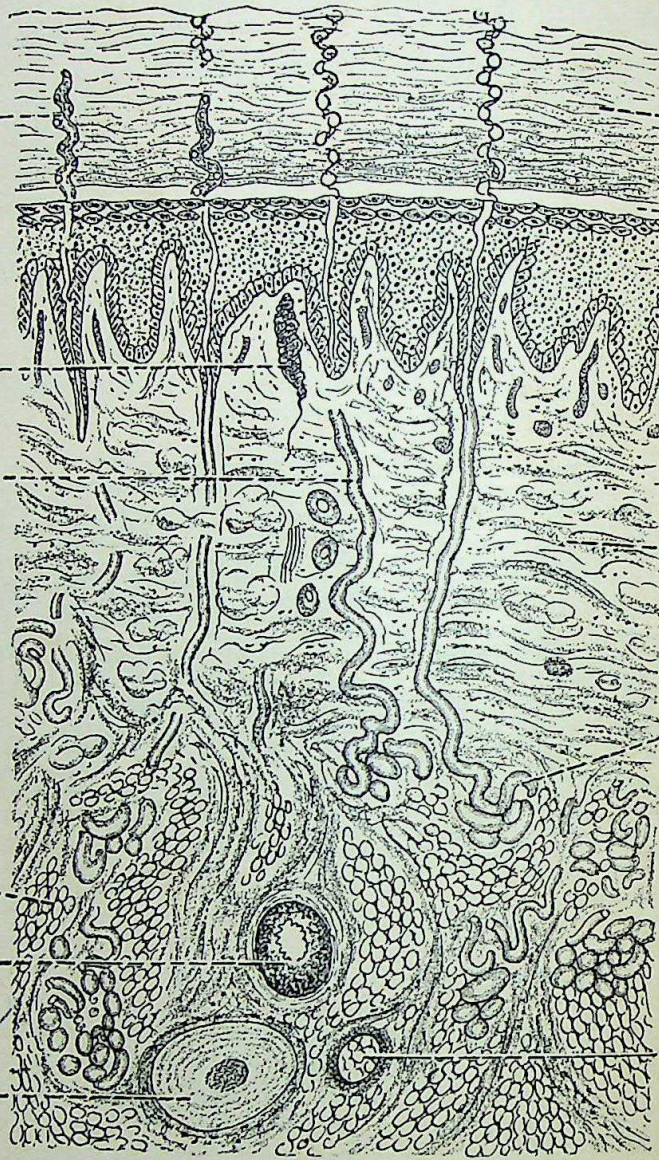

impressions ('finger-prints') of these lines being made on paper covered with soot, or on white paper after first covering the fingers with ink. The deep surface of the epidermis is accurately moulded upon the papillary layer of the corium, the papillæ being covered by a basement-membrane; so that when the epidermis is removed by maceration, its under surface presents a number of pits or depressions corresponding with the papillæ, and ridges corresponding with the intervals between them.

The epidermis consists of stratified epithelium which is arranged in five layers named from within outwards: (*a*) stratum germinativum, (*b*) stratum mucosum, (*c*) stratum granulosum, (*d*) stratum lucidum, and (*e*) stratum corneum.

The *stratum germinativum* consists of a layer of columnar cells with oblong nuclei. The cells are placed perpendicularly on the basement-membrane and attached to it by denticulated extremities.

CC-0. In Public Domain. Gurukul Kangri Collection, Haridwar

Digitized by Arya Samaj Foundation Chennai and eGangotri

On the *outer surface* of each lamina an *oblique line* runs downwards and rwards from the superior thyreoid tubercle which is situated a little in front the root of the superior cornu, to the inferior thyreoid tubercle on the wer border of the lamina. To this line are attached the Sternothyreoideus, yreohyoideus, and Constrictor pharyngis inferior. The *inner surface* is oth: above and behind, it is ightly concave and covered with cous membrane. In front, in e angle formed by the junction f the laminæ, are attached the yreo-epiglottic, ventricular, and cal ligaments, the Thyreoary-noidei, Thyreoepiglottici and ales muscles.

The *upper border* of each mina is concave behind and vex in front; it gives attach-nt to the corresponding half the hyothyreoid membrane. *lower border* is concave nd, and nearly straight in , the two parts being rated by the inferior thy-d tubercle. A small part of n and near the middle line connected to the cricoid rtilage by the middle crico-yroid ligament.

The *anterior* border is fused h that of the opposite lamina, ming with it an angle of about in the male, and about 120° the female. The *posterior* der, thick and rounded, re-ves the insertions of fibres the Stylopharyngeus and ryngopalatinus muscles. It s in the superior and inferior ma. The *superior cornu*, g and narrow, is directed wards, backwards and medial-ds, and ends in a conical mity, which gives attach-nt to the lateral hyothyreoid ment. The *inferior cornu*, r and thick, is directed wards, with a slight in-ation forwards and medial-ds; on the medial surface of wer end there is a small oval for articulation with the side the cricoid cartilage.

Fig. 1021.—The cartilages of the larynx. Posterior aspect.

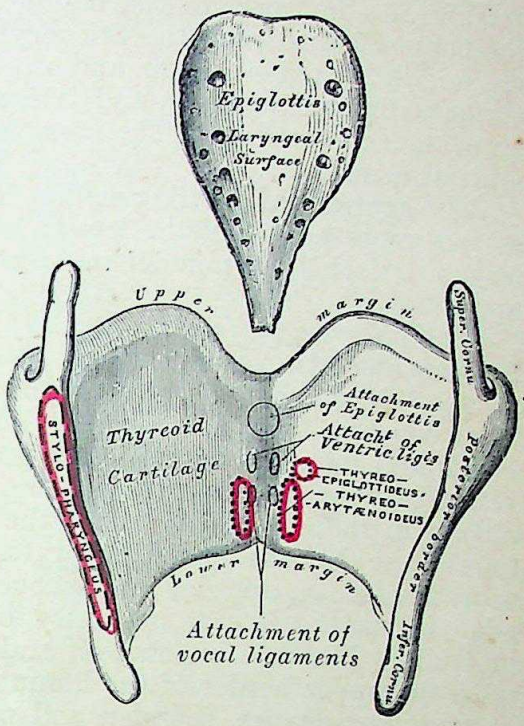

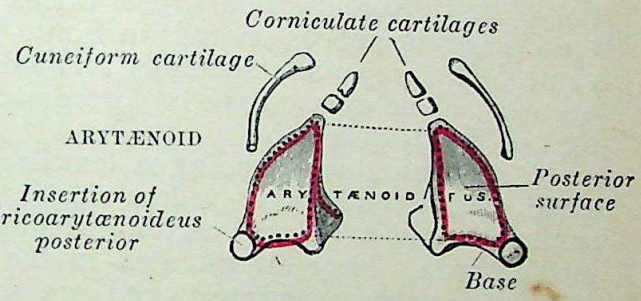

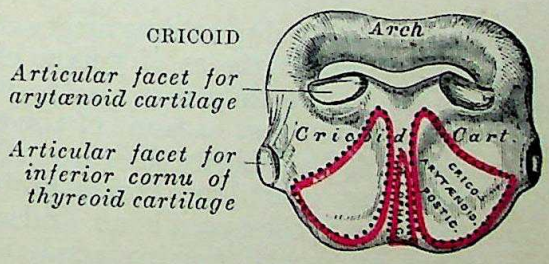

During infancy the laminæ of the thyreoid cartilage are joined to each other a narrow, lozenge-shaped, flexible strip, named the *intrathyreoid cartilage*.

The **cricoid cartilage** (figs. 1021, 1023, 1024) is smaller, but thicker and ger than the thyreoid cartilage. It is shaped like a signet-ring, and forms wer and posterior parts of the wall of the larynx. It consists of a ior quadrate lamina, and an anterior narrow arch.

The *lamina* of the cricoid cartilage is deep and broad, and measures verti-y from 2 cm. to 3 cm.; on the middle of its posterior surface is a vertical to the upper part of which the two fasciculi of the longitudinal fibres of phagus are attached by a tendon (p. 1129); and on either side of the is a shallow depression for the origin of the Cricoarytænoideus posterior.

CC-0. In Public Domain. Gurukul Kangri Collection, Haridwar

Digitized by Arya Samaj Foundation Chennai and eGangotri

The *arch* is narrow in front, measuring vertically from 5 mm. to 7 mm., but widens posteriorly as it approaches the lamina; it affords attachment in front and at the sides to the Cricothyreoidei, and behind, to part of the Constrictor pharyngis inferior. On either side, at the junction of the lamina with the arch, there is a prominent circular facet, directed lateralwards and backwards for articulation with the inferior cornu of the thyreoid cartilage. The *lower border* of the cricoid cartilage is horizontal, and connected to the highest ring of the trachea by the cricotracheal ligament. The *upper border* runs obliquely upwards and backwards, owing to the great depth of the lamina. It gives attachment, in front, to the middle cricothyreoid ligament; at the sides, to the conus elasticus and the Cricoarytænoidei laterales; behind, it presents, in the middle, a shallow notch, and on either side of this is a smooth, oval, convex surface, directed upwards and lateralwards, for articulation with the base of an arytænoid cartilage. The *inner surface* of the cricoid cartilage is lined with mucous membrane.

The **arytænoid cartilages** (figs. 1023, 1024), a right and a left, are situated at the upper border of the lamina of the cricoid cartilage, at the back of the larynx. Each is pyramidal in form, and has three surfaces, a base, and an apex.

The *posterior surface*, triangular, smooth, and concave, is covered with the Arytænoideus transversus. The *anterolateral surface* is somewhat convex and rough. On it, near the apex of the cartilage, there is an elevation (*colliculus*), from which a crest (*crista arcuata*) curves at first backwards and then downwards and forwards to the vocal process. The lower part of this crest intervenes between two depressions or foveæ, an upper, triangular, and a lower, oblong in shape; to the upper the ventricular ligament is attached; to the lower, the Vocalis and Cricoarytænoideus lateralis. The *medial surface* is narrow, smooth, and flat; it is covered with mucous membrane, and its lower edge forms the lateral boundary of the intercartilaginous part of the rima glottidis. The *base* is concave, and on it is a smooth surface for articulation with the upper border of the lamina of the cricoid cartilage. Its lateral angle or *muscular process*, rounded and prominent, projects backwards and lateralwards, and gives insertion to the Cricoarytænoideus posterior behind, and to the Cricoarytænoideus lateralis in front. Its anterior angle or *vocal process* is pointed; it projects horizontally forwards and gives attachment to the vocal ligament. The *apex* curves backwards and medialwards, and articulates with the *corniculate cartilage*.

The **corniculate cartilages** (cartilages of Santorini) (fig. 1024) are two small conical nodules of yellow elastic cartilage, which articulate with the summits of the arytænoid cartilages and serve to prolong them backwards and medialwards. They are situated in the posterior parts of the aryepiglottic folds of mucous membrane, and are sometimes fused with the arytænoid cartilages.

The **cuneiform cartilages** (cartilages of Wrisberg) (figs. 1021, 1024, 1025) are two small, elongated pieces of yellow elastic cartilage, placed one in each aryepiglottic fold, where they give rise to whitish elevations on the surface of the mucous membrane, just in front of the corniculate cartilages.

The cartilage of the **epiglottis** (figs. 1021, 1023, 1024) is a thin leaf-like lamella of yellow fibrocartilage, which projects obliquely upwards behind the tongue and the body of the hyoid bone, and in front of the entrance to the larynx. The free extremity, broad and rounded, is directed upwards; the attached part or stem is long, narrow, and connected by an elastic ligament, the *thyreo-epiglottic ligament*, to the angle formed by the two laminæ of the thyreoid cartilage, a short distance below the superior thyreoid notch. The sides of the epiglottis are attached to the arytænoid cartilages by the aryepiglottic folds of mucous membrane (p. 1066).

The upper part of the *anterior surface* of the epiglottis is free, and covered with mucous membrane, which is reflected on to the back of the tongue, forming a median and two lateral *glosso-epiglottic folds*; the lateral glosso-epiglottic folds are also attached to the wall of the pharynx, and on this account are frequently named the *pharyngo-epiglottic folds*. The depression on either side of the median glosso-epiglottic fold is named the *vallecula* (fig. 1026). The lower part of the anterior surface lies behind the hyoid bone and the hyothyreoid

CC-0. In Public Domain. Gurukul Kangri Collection, Haridwar

Digitized by Arya Samaj Foundation Chennai and eGangotri

membrane, and is connected to the upper border of the hyoid bone by an elastic ligament, the *hyo-epiglottic ligament*; it is separated from the hyothyreoid membrane by a mass of fatty tissue.

The *posterior surface* of the epiglottis is smooth, concave from side to side, concavoconvex from above downwards, and covered with mucous membrane; the lower part projects backwards as an elevation, the *tubercle* or *cushion*. When the mucous membrane is removed, the cartilage is seen to be indented by a number of small pits, in which mucous glands are lodged.

FIG. 1022.—The ligaments of the larynx. Anterolateral aspect.

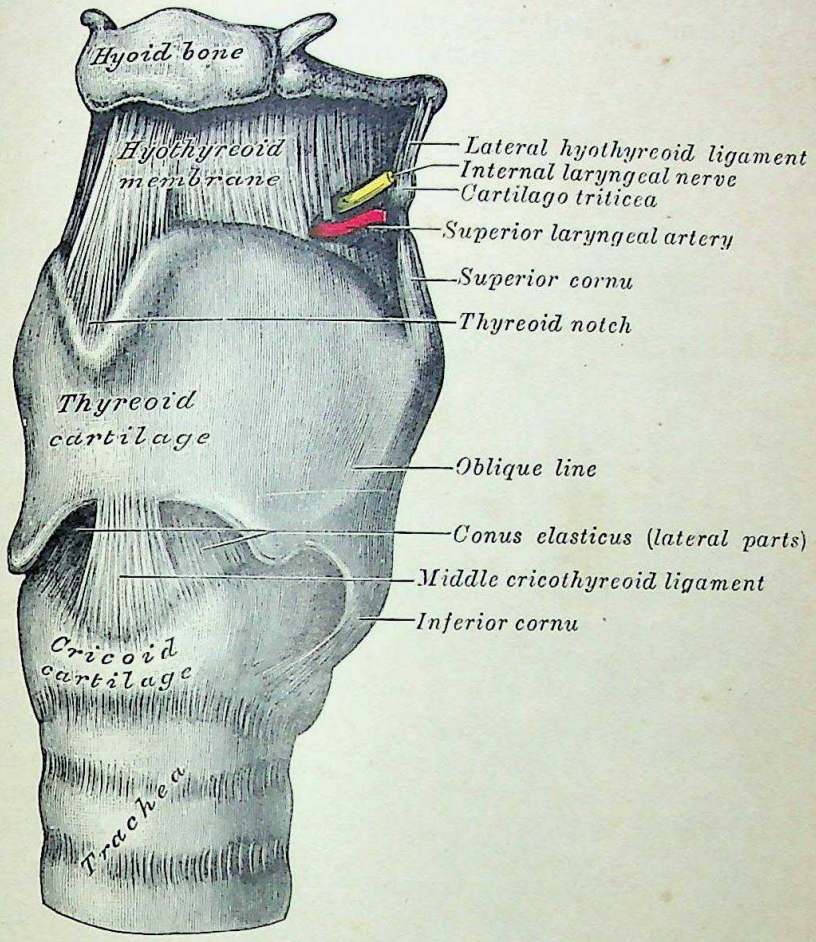

Structure.—The corniculate and cuneiform cartilages, the epiglottis, and the apices of the arytænoids consist of yellow fibrocartilage, which shows little tendency to calcification. The thyreoid, cricoid, and the greater part of the arytænoids consist of hyaline cartilage, which become more or less ossified as age advances. Ossification commences about the sixty-fifth year in the thyreoid cartilage, and somewhat later in the cricoid and the arytænoids; by the sixty-fifth year these cartilages may be completely converted into bone.

Joints.—The joints between the inferior cornua of the thyreoid cartilage and the sides of the cricoid cartilage are diarthrodial, and each is enveloped by an articular capsule, which is strengthened posteriorly by a fibrous band. Rotatory and gliding movements occur at these joints. The rotatory movement is one in which the cricoid cartilage rotates upon the inferior cornua of the thyreoid cartilage around an axis passing transversely through both joints. The gliding movement consists in a limited shifting of the cricoid on the thyreoid in different directions.

A pair of diarthrodial joints exist between the facets on the upper border of the lamina of the cricoid cartilage and the bases of the arytænoid cartilages; each joint is enclosed by an articular capsule, and a strong posterior *crico-arytænoid ligament* connects the cricoid cartilage with the lateral and posterior part of the base of the arytænoid cartilage. These joints permit of two varieties of movement: one is a rotation of the arytænoid on a vertical axis, whereby the vocal process is moved lateralwards or medialwards, and the rima glottidis increased or diminished; the

CC-0. In Public Domain. Gurukul Kangri Collection, Haridwar

Digitized by Arya Samaj Foundation Chennai and eGangotri

other is a gliding movement, and allows the arytænoid cartilages to approach or recede from each other; from the direction and slope of the articular surfaces lateral gliding is accompanied by a forward and downward movement. The two movements of gliding and rotation are associated, the medial gliding being connected with medialward rotation, and the lateral gliding with lateralward rotation. The posterior crico-arytænoid ligaments limit the forward movements of the arytænoid cartilages on the cricoid cartilage.

A synchondrosis, sometimes a diarthrosis, exists between the apex of each arytænoid cartilage and the corresponding corniculate cartilage, and a Y-shaped ligament, the *ligamentum corniculopharyngeum*, unites the apices of the corniculate cartilages to the upper border of the lamina of the cricoid cartilage.

Ligaments and membranes.—The ligaments of the larynx (figs. 1022, 1023) are (*a*) *extrinsic*, those connecting the thyreoid cartilage and epiglottis with the hyoid bone, and the cricoid cartilage with the trachea; and (*b*) *intrinsic*, those uniting the cartilages of the larynx to each other.

Fig. 1023.—The ligaments of the larynx. Posterior aspect.

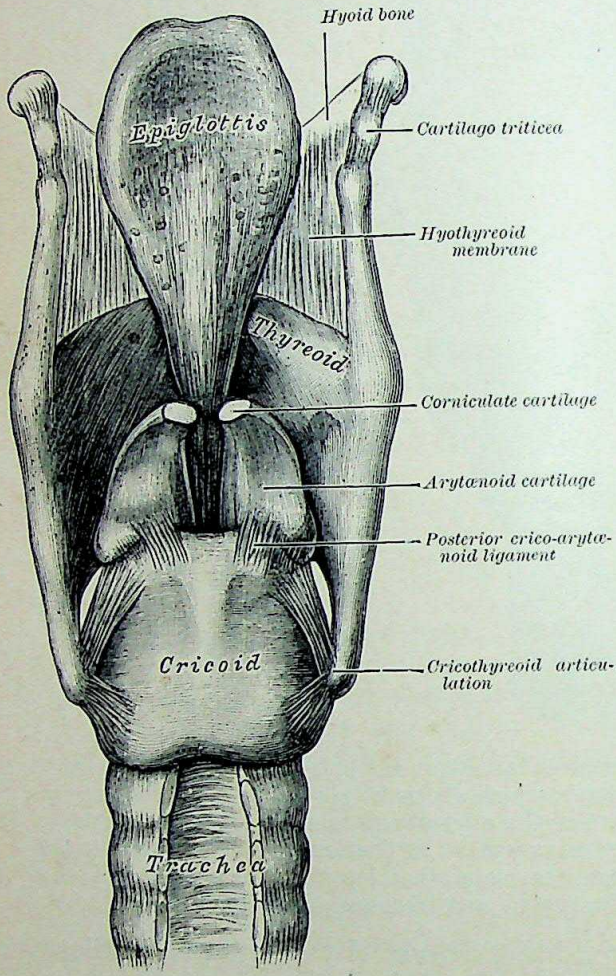

Extrinsic ligaments.—The thyreoid cartilage is connected to the hyoid bone by the hyothyreoid membrane, and by a middle and two lateral hyothyreoid ligaments.

The *hyothyreoid membrane* is a broad, fibro-elastic layer, attached below to the upper border of the thyreoid cartilage and to the front of its superior cornua, and above to the upper margin of the posterior surface of the body and greater cornua of the hyoid bone, thus passing behind the posterior surface of the body of the hyoid bone, and being separated from it by a bursa mucosa, which facilitates the upward movement of the larynx during deglutition. The middle, thicker, part of the membrane is termed the *middle hyothyreoid ligament*; each of the lateral thinner portions is pierced by the superior laryngeal vessels and the internal branch of the superior laryngeal nerve. Its outer surface is in relation with the Thyreohyoideus, Sternohyoideus, and Omohyoideus, and with the body of the hyoid bone.

The *lateral hyothyreoid ligaments* are round elastic cords which form the posterior borders of the hyothyreoid membrane and connect the tips of the superior cornua of the thyreoid cartilage to the posterior ends of the greater cornua of the hyoid bone. A small cartilaginous nodule, the *cartilago triticea*, is frequently found in each ligament.

The epiglottis is attached to the hyoid bone by the hyo-epiglottic ligament and to the thyreoid cartilage by the thyreo-epiglottic ligament (p. 1062).

The *cricotracheal ligament* unites the lower border of the cricoid cartilage with the first ring of the trachea. It is continuous below with the fibrous membrane which invests the rings of the trachea.

Intrinsic ligaments.—Beneath the mucous membrane of the larynx is a broad sheet of fibrous tissue containing many elastic fibres, and termed the *elastic membrane of the larynx*. It is subdivided on either side by the interval between the ventricular and vocal ligaments; the upper portion extends between the arytænoid cartilage and the cartilage of the epiglottis, and is often

CC-0 In Public Domain. Gurukul Kangri Collection, Haridwar

Digitized by Arya Samaj Foundation Chennai and eGangotri

ly defined; the lower part is a well-marked membrane forming, with its llow of the opposite side, the conus elasticus, which connects the thyreoid, ricoid, and arytænoid cartilages one to another. The joints between the dividual cartilages are also provided with ligaments, already described.

The *conus elasticus* (cricothyreoid membrane) (fig. 1024) is composed mainly yellow elastic tissue. It consists of an anterior and two lateral parts. The terior part or *middle cricothyreoid ligament* is thick and strong, narrow above d broad below. It connects the front parts of the contiguous margins of the yreoid and cricoid cartilages. It is overlapped on either side by the Crico-yreoideus, but between these muscles is subcutaneous; its upper part is

FIG. 1024.—A dissection to show the right half of the conus elasticus. The right lamina of the thyreoid cartilage and the subjacent muscles have been removed.

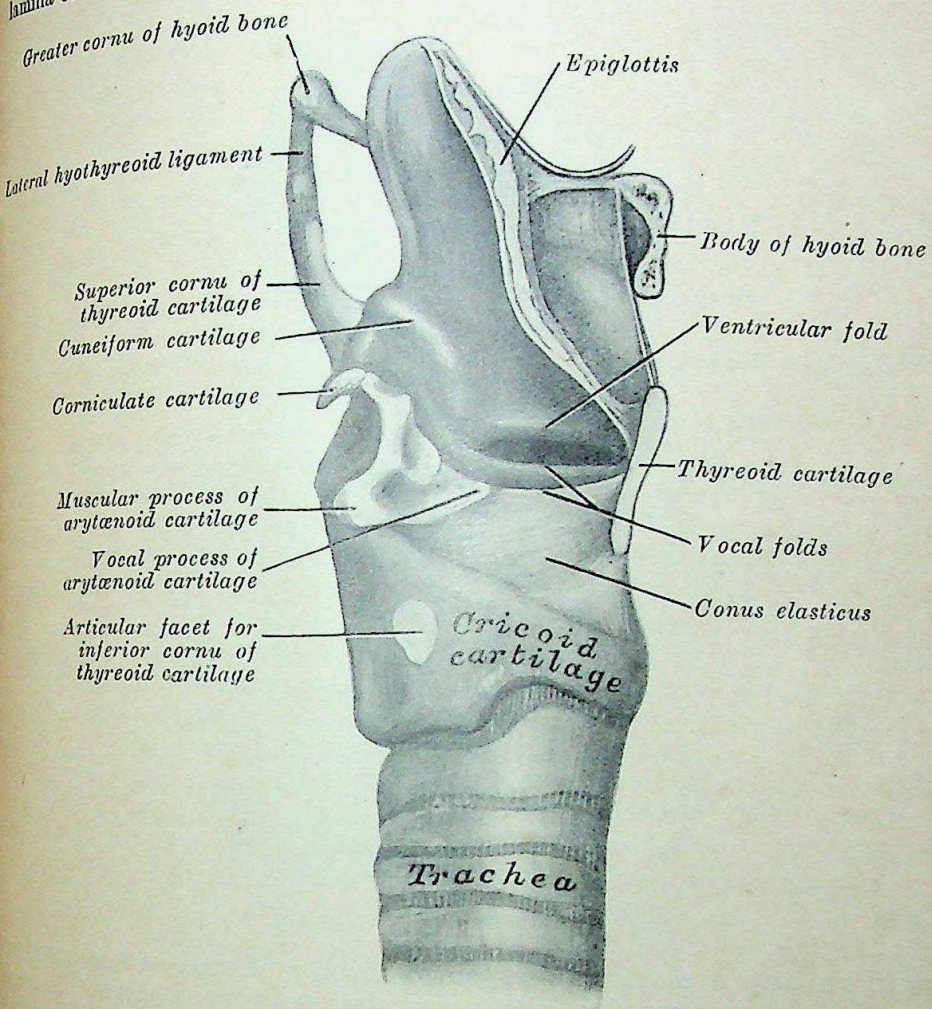

rossed by a small arterial arch, formed by the junction of the two cricothyreoid teries; branches of this arch pierce the ligament. The *lateral* parts of the nus elasticus are thinner; they are lined with the mucous membrane of the rynx, and are covered by the Cricoarytænoidei laterales and Thyreoarytæ-dei. They extend upwards and medialwards from the inner edge of the perior border of the cricoid cartilage, and end above in free, slightly thickened ges which form the vocal ligaments; these ligaments stretch from the vocal ocesses of the arytænoid cartilages to the angle of the thyreoid cartilage about way between the upper and lower borders of the cartilage.

Cavum laryngis (figs. 1025, 1026).—The *cavity of the larynx* extends from laryngeal entrance, by which it communicates with the pharynx, to the of the lower border of the cricoid cartilage, where it is continuous with cavity of the trachea. It is divided into three parts by an upper and a pair of folds of mucous membrane which project from the sides of the into its interior. The upper folds are named the *ventricular folds* (false cords), and the fissure between them is called the *rima vestibuli*. The

CC-0. In Public Domain. Gurukul Kangri Collection, Haridwar

Digitized by Arya Samaj Foundation Chennai and eGangotri

lower folds are concerned in the production of voice, and are therefore named the *vocal folds* (true vocal cords), and the fissure between them is called the *rima glottidis*.

The *entrance to the larynx* (aditus laryngis) (fig. 1026) is the aperture through which the laryngeal cavity opens into the pharynx. It slopes downwards and backwards, and is triangular in shape, with its base in front. It is bounded anteriorly by the upper edge of the epiglottis, posteriorly by the mucous membrane stretching between the arytænoid cartilages, and on either side by the free edge of a fold of mucous membrane, enclosing ligamentous and muscular fibres, stretched between the side of the epiglottis and the apex of the arytænoid cartilage; this is the *aryepiglottic fold*, and on the posterior part of its free

Fig. 1025.—A sagittal section through the larynx.

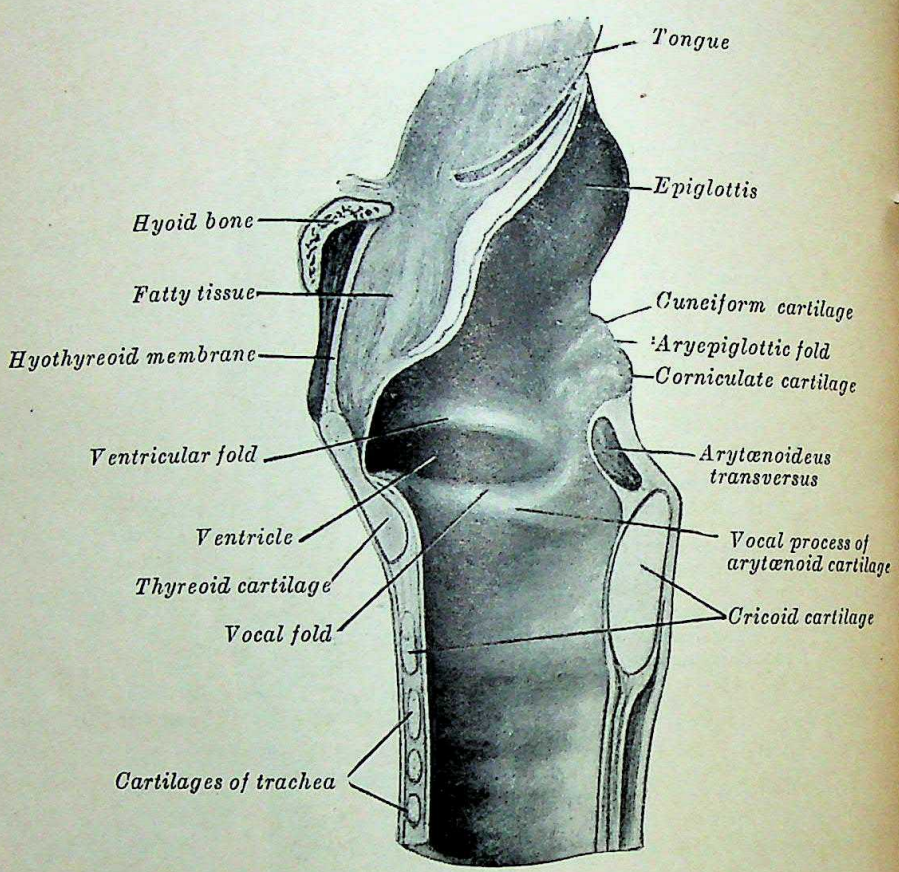

margin are two oval elevations, an anterior produced by the cuneiform cartilage, and a posterior by the corniculate cartilage. These elevations are separated by a shallow vertical furrow, which is continuous below with the opening into the ventricle of the larynx.

The *vestibule of the larynx* (figs. 1025, 1026) is the part between the laryngeal entrance and the level of the ventricular folds; it is wide above, and narrow below. Its anterior wall consists of the posterior surface of the epiglottis, the lower part of which projects backwards as the tubercle or cushion (p. 1063). Its lateral walls, deep in front and shallow behind, are formed by the medial surfaces of the aryepiglottic folds; its posterior wall consists of the mucous membrane connecting the arytænoid cartilages, above the level of the ventricular folds.

The *middle part* of the laryngeal cavity is the smallest. It reaches from the level of the rima vestibuli to that of the rima glottidis. On either side it opens through a slit between the ventricular and vocal folds, into a recess which is named the ventricle of the larynx.

The *ventricular folds* (false vocal cords) (figs. 1024, 1025, 1027) are two thick folds of mucous membrane, each enclosing a narrow band of fibrous tissue, the *ventricular ligament*, which is fixed in front to the angle of the thyreoid cartilage

CC-0. In Public Domain. Gurukul Kangri Collection, Haridwar

Digitized by Arya Samaj Foundation Chennai and eGangotri

immediately below the attachment of the epiglottic cartilage, and behind to the anterolateral surface of the arytænoid cartilage, a short distance above the vocal process.

The *vocal folds* (true vocal cords) (figs. 1024, 1025, 1027) are concerned in the production of sound, and enclose the vocal ligaments. Each *vocal ligament* consists of a band of yellow elastic tissue, attached in front to the angle of the thyreoid cartilage below the ventricular ligament, and behind to the vocal process of the arytænoid cartilage. It is continuous below with the lateral part of the conus elasticus. It is covered medially with mucous membrane, which is thin, and closely adherent to it. The Vocalis muscle lies lateral to and parallel with the vocal ligament.

FIG. 1026.—The tongue and the entrance to the larynx. Posterior aspect.

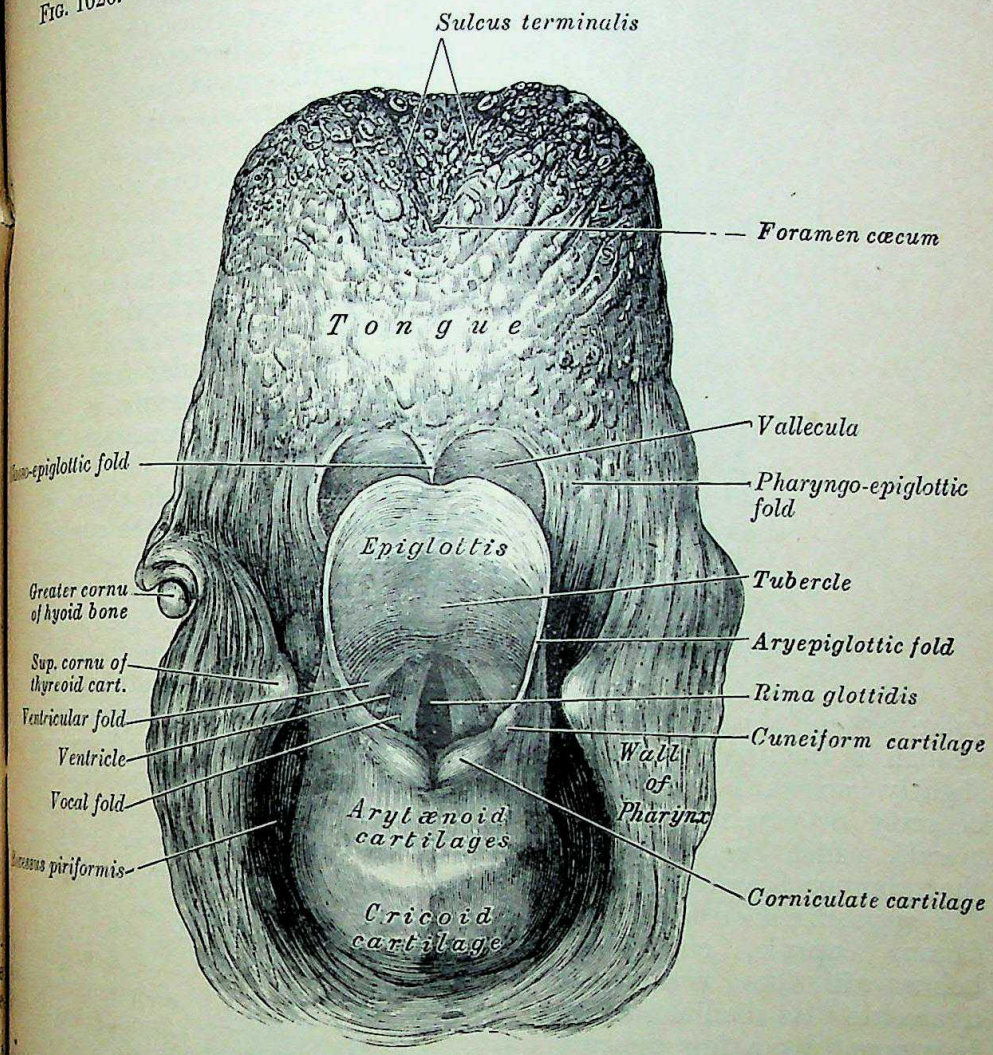

The *rima glottidis* (figs. 1026, 1028) is a fissure situated between the vocal folds anteriorly, and between the bases and vocal processes of the arytænoid cartilages posteriorly; it is limited behind by the mucous membrane passing between the arytænoid cartilages, at the level of the vocal folds. The portion between the vocal folds is named the *intermembranous part* (glottis vocalis), and measures about three-fifths of the length of the entire aperture; that between the arytænoid cartilages is named the *intercartilaginous part* (glottis respiratoria). The average length of the rima glottidis, in the male, is 23 mm.; in the female, 18 mm. Its width and shape vary with the movements of the vocal folds and arytænoid cartilages during respiration and phonation. In the condition of rest, as in quiet respiration, the intermembranous part is triangular, with its apex in front and its base behind—the latter being represented by a line, about 3 mm. long, connecting the anterior ends of the vocal processes—while the medial surfaces of the arytænoid cartilages are parallel to each other and hence the intercartilaginous part is rectangular. During extreme adduction of the

CC-0. In Public Domain. Gurukul Kangri Collection, Haridwar

Digitized by Arya Samaj Foundation Chennai and eGangotri

vocal folds, as in the production of a high note, the intermembranous part of the rima glottidis is reduced to a linear slit by the apposition of the vocal folds, while the intercartilaginous part is triangular, its apex corresponding to the anterior ends of the vocal processes of the arytænoid cartilages, which are approximated by the medial rotation of the cartilages. Conversely in extreme abduction of the vocal folds, as in forced inspiration, the arytænoid cartilages and their vocal processes are rotated lateralwards, and the intercartilaginous part is triangular in shape but with its apex directed backwards. In this condition the rima glottidis is somewhat lozenge-shaped, the sides of the intermembranous part diverging from before backwards, those of the intercartilaginous part diverging from behind forwards—the widest part of the aperture corresponding with the attachments of the vocal folds to the vocal processes.

Fig. 1027.—A coronal section through the larynx and the upper part of the trachea.

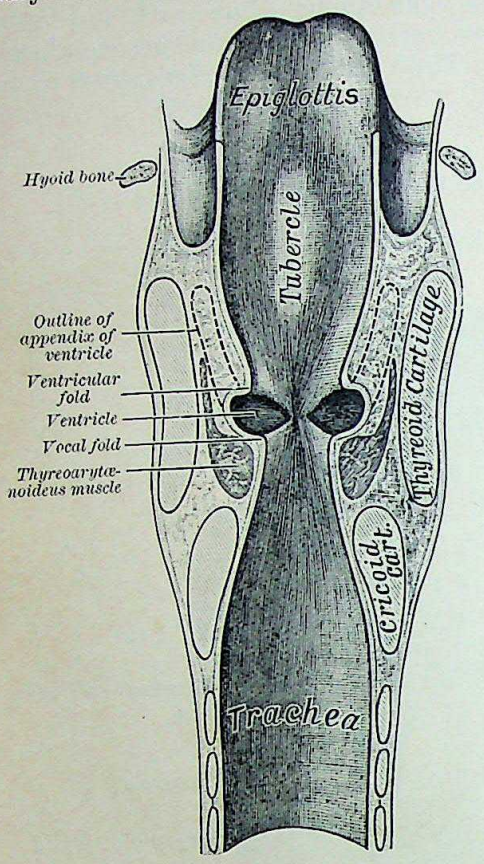

The *ventricle of the larynx* (fig. 1025) is a fusiform recess on either side between the ventricular and vocal folds and ascending for a short distance outside the ventricular fold. It is lined with mucous membrane, lateral to which is the corresponding Thyreoarytænoideus muscle. From the anterior part of the ventricle a narrow opening leads upwards into the appendix of the ventricle.

The *appendix of the ventricle* (laryngeal saccule) (fig. 1027) is a pouch which ascends from the anterior part of the ventricle, between the ventricular fold and the inner surface of the thyreoid cartilage, occasionally extending as high as the upper border of the cartilage; it is conical in form, and curved slightly backwards. On the surface of its mucous membrane are the openings of sixty or seventy mucous glands, which are lodged in the submucous areolar tissue. The appendix is enclosed in a fibrous capsule, continuous below with the ventricular ligament. Its medial surface is covered by a few delicate muscular fasciculi, which arise from the apex of the arytænoid cartilage and become lost in the aryepiglottic fold of mucous membrane; laterally it is separated from the thyreoid cartilage by the Thyreoepiglotticus. These muscles compress the sac, and express the secretion of its glands upon the vocal fold to lubricate its surfaces.

Fig. 1028.—A laryngoscopic view of the interior of the larynx.

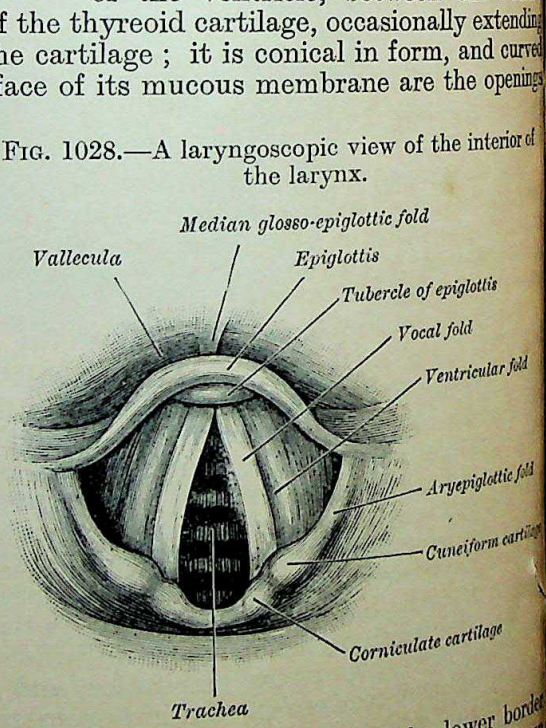

The *lower part* of the laryngeal cavity extends from the level of the vocal folds to the lower border of the cricoid cartilage. Its upper part is elliptical in form, but lower down it widens, assumes a circular shape, and is continuous with the cavity of the

CC-0. In Public Domain. Gurukul Kangri Collection, Haridwar

Digitized by Arya Samaj Foundation Chennai and eGangotri

trachea. It is lined with mucous membrane, and its walls consist of the conus elasticus above, and the inner surface of the cricoid cartilage below.

Muscles.—The muscles of the larynx are *extrinsic* and *intrinsic*. The extrinsic muscles pass between the larynx and neighbouring structures, and are described in the section on Myology. The intrinsic muscles are :

Cricothyreoideus,	Arytænoideus obliquus.
pars obliqua,	Aryepiglotticus.
pars recta.	Thyreoarytænoideus.
Cricoarytænoideus posterior.	Vocalis.
Cricoarytænoideus lateralis.	Thyreoepiglotticus.
Arytænoideus transversus.	Ventricularis.

With the exception of the Arytænoideus transversus these muscles are paired.

The *Cricothyreoideus* (fig. 1029), triangular in form, arises from the front and lateral part of the outer surface of the cricoid cartilage; its fibres diverge, and are arranged in two groups. The lower fibres constitute the *pars obliqua* and slant upwards and lateralwards to the anterior tubercle of the inferior cornu, while the superior fibres form the *pars recta* and run upwards and backwards to the posterior part of the lower border of the lamina, of the thyreoid cartilage.

FIG. 1029.—A side view of the larynx, showing the muscular attachments.

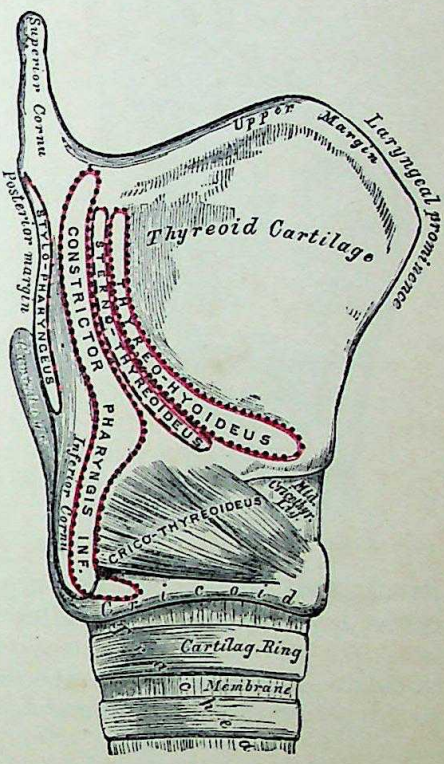

The medial borders of the two muscles are separated by a triangular interval occupied by the subcutaneous part of the middle cricothyreoid ligament.

The *Cricoarytænoideus posterior* (fig. 1030) arises from the lower and medial part of the broad depression on the corresponding half of the posterior surface of the lamina of the cricoid cartilage; its fibres, directed upwards and lateralwards, converge to be inserted into the back of the muscular process of the arytænoid cartilage. The highest fibres are nearly horizontal, the middle oblique, and the lowest almost vertical.

The *Cricoarytænoideus lateralis* (fig. 1031) is smaller than the preceding muscle; it arises from the upper border of the arch of the cricoid cartilage, and, passing obliquely upwards and backwards, is inserted into the front of the muscular process of the arytænoid cartilage.

The *Arytænoideus transversus* (fig. 1030) is a single muscle which bridges the interval between the arytænoid cartilages and fills the posterior concave surfaces of these cartilages. It arises from the back of the muscular process and lateral border of the arytænoid cartilage of one side, and is inserted into the corresponding parts of the cartilage on the opposite side.

The *Arytænoideus obliquus* (fig. 1030), superficial to the Arytænoideus transversus, consists of two fasciculi, which cross each other like the limbs of the letter X. Each passes from the back of the muscular process of one arytænoid cartilage to the apex of the opposite cartilage. A few fibres are continued round the lateral margin of the apex of the arytænoid cartilage, and prolonged into the aryepiglottic fold; they constitute the *Aryepiglotticus* muscle.

The *Thyreoarytænoideus* (figs. 1031, 1032) is a broad, thin muscle, which is placed lateral to the vocal fold, the conus elasticus, the ventricle and the ventricular appendix. It arises in front from the lower half of the angle of the thyreoid cartilage, and from the middle cricothyreoid ligament. Its fibres run backwards and lateralwards, to be inserted into the anterolateral surface

CC-0.In Public Domain. Gurukul Kangri Collection, Haridwar

Digitized by Arya Samaj Foundation Chennai and eGangotri

of the arytænoid cartilage. The lower and deeper fibres of the muscle form a band which, in a coronal section, appears as a triangular bundle, and is attached to the lateral surface of the vocal process and to the inferior fovea on the

Fig. 1030.—The muscles of the larynx. Posterior aspect.

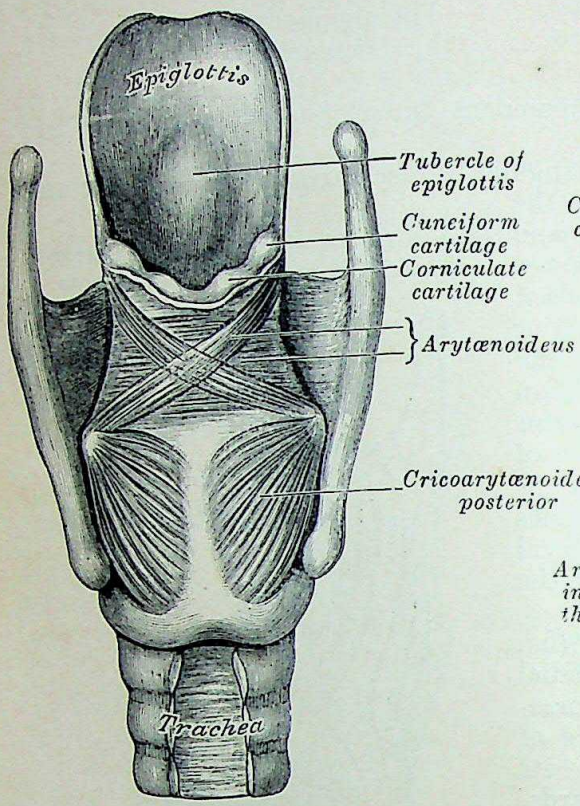

Fig. 1031.—The muscles of the larynx. Lateral aspect. The right lamina of the thyreoid cartilage has been removed.

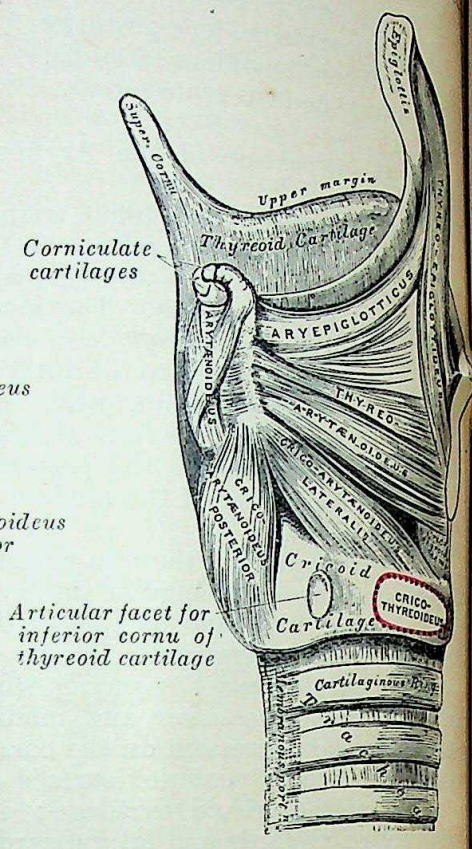

anterolateral surface of the arytænoid cartilage. This bundle is named the *Vocalis* muscle, and is parallel with, and just lateral to, the vocal ligament. The Vocalis is thicker behind than in front, because some of its fibres are inserted into the vocal ligament, and so fail to reach the thyreoid cartilage. A considerable number of the fibres of the Thyreoarytænoideus are prolonged into the aryepiglottic fold, where some of them are lost, while others are continued to the margin of the epiglottis, forming the *Thyreoepiglotticus*. A few fibres extend along the wall of the ventricle from the lateral margin of the arytænoid cartilage to the side of the epiglottis, and constitute the *Ventricularis* muscle.

Fig. 1032.—The muscles of the larynx. Superior aspect. (Enlarged.)

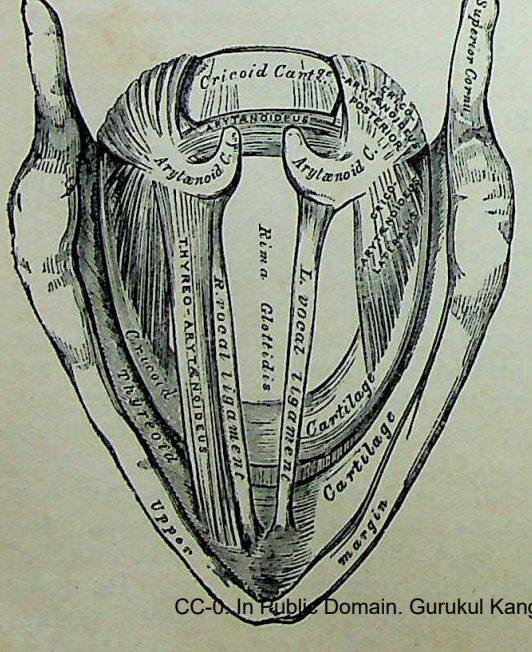

Actions.—The muscles of the larynx may be conveniently divided into two groups, (1) those which open and close the glottis, viz. the Cricoarytænoidei posteriores et laterales and the Arytænoidei; (2) those which regulate the degree of tension of the vocal ligaments, viz. the Cricothyreoidei, the Thyreoarytænoidei, and the Vocales.

CC-0. In Public Domain. Gurukul Kangri Collection, Haridwar

Digitized by Arya Samaj Foundation Chennai and eGangotri

The *Cricoarytænoidei posteriores* open the glottis, by rotating the arytænoid cartilages outwards around a vertical axis passing through the crico-arytænoid joints, so that the vocal processes and the attached vocal folds are separated.

The *Cricoarytænoidei laterales* close the glottis, by rotating the arytænoid cartilages inwards so as to approximate the vocal processes.

The *Arytænoideus transversus* approximates the arytænoid cartilages, and thus closes the opening of the glottis, especially at its posterior part.

The *Arytænoidei obliqui* and the *Aryepiglottici* act as a sphincter of the entrance of the larynx, by bringing the aryepiglottic folds together, and by approximating the arytænoid cartilages to the tubercle or cushion of the epiglottis.

The *Cricothyreoidei* produce tension and elongation of the vocal ligaments by drawing up the arch of the cricoid cartilage and tilting back the upper border of its lamina; the distance between the vocal processes and the angle of the thyreoid is thus increased, and the vocal ligaments are consequently elongated.

The *Thyreoarytænoidei* draw the arytænoid cartilages forwards towards the thyreoid, and thus shorten and relax the vocal ligaments. At the same time they rotate the arytænoid cartilages inwards and approximate the vocal folds. The deeper fibres, forming the *Vocales*, produce relaxation of the vocal ligaments.

The manner in which the entrance of the larynx is closed during deglutition is referred to on p. 1122.

Mucous Membrane.—The mucous membrane of the larynx is continuous above with that of the mouth and pharynx, below with that of the trachea. It is loosely attached to the anterior surface of the epiglottis, and to the underlying tissues in the valleculæ. It covers the aryepiglottic folds which bound the entrance of the larynx; in these folds there is a considerable amount of areolar tissue. It lines the cavity of the larynx; forms, by its reduplication, the chief parts of the ventricular folds, and is continued from the ventricle into the ventricular appendix. It is firmly attached to the posterior surface of the epiglottis and to the laryngeal surfaces of the cuneiform and arytænoid cartilages. The parts covering the vocal ligaments are thin and intimately adherent to them. On the anterior surface, and the upper half of the posterior surface, of the epiglottis, the upper part of the aryepiglottic folds, and the vocal folds, the epithelium of the mucous membrane is of the stratified squamous type; patches of stratified squamous epithelium are also found above the glottis. The rest of the laryngeal mucous membrane is covered by columnar ciliated epithelium.

Glands.—The mucous membrane of the larynx is furnished with numerous mucous glands; they are very plentiful upon the epiglottis, where they are lodged in little pits; they are present in the margins of the aryepiglottic folds in front of the arytænoid cartilages, where they are termed the *arytænoid glands*. They are large and numerous in the ventricular appendices. The free edges of the vocal folds are devoid of glands.

Taste-buds, similar to those in the tongue, are scattered over the posterior surface of the epiglottis, in the aryepiglottic folds, and less regularly in some other parts of the larynx.

Vessels and Nerves.—The chief *arteries* of the larynx are the laryngeal branches of the superior and inferior thyreoid arteries. The *veins* accompanying the superior laryngeal artery join the superior thyreoid vein which opens into the internal jugular vein; those accompanying the inferior laryngeal artery join the inferior thyreoid vein which opens into the innominate vein. The *lymphatic vessels* are divisible into two sets, a superior above, and an inferior below, the vocal folds; the superior vessels accompany the superior laryngeal artery, pierce the hyothyreoid membrane, and end in the deep cervical lymph-glands situated near the bifurcation of the common carotid artery; some of the inferior lymphatic vessels pierce the middle cricothyreoid ligament and open into a lymph-gland lying in front of that ligament or in front of the upper part of the trachea, the others emerge below the cricoid cartilage and pass to the deep cervical lymph-glands and to the lymph-glands alongside of the inferior thyreoid artery. The *nerves* are derived from the internal and external branches of the superior laryngeal nerve, from the recurrent nerve and from the sympathetic. The internal laryngeal branch is almost entirely sensory, but some motor filaments are said to be carried by it to the Arytænoideus. It pierces the larynx through the postero-inferior part of the hyothyreoid membrane above the superior laryngeal artery, and divides into three branches; one is distributed to both surfaces of the epiglottis, a second to the aryepiglottic fold, and a third, the largest, supplies the mucous membrane over the back of the larynx and communicates with the recurrent nerve. The external laryngeal branch supplies the Cricothyreoideus by entering its lateral surface. The recurrent nerve accompanies the laryngeal branch of the inferior thyreoid artery, and passes upwards beneath the lower border of the Constrictor pharyngis inferior, immediately behind the cricothyreoid joint. It supplies all the intrinsic muscles of the larynx except the Cricothyreoideus, and a part of the Arytænoideus (pp. 919, 920). The sensory branches of the laryngeal nerves form subepithelial plexuses, from which fibres pass to end between the cells covering the mucous membrane.*

* Consult an article 'On the nerves of the human larynx' by T. F. M. Dilworth, *Journal of Anatomy*, vol. lvi. 1921.

CC-0. In Public Domain. Gurukul Kangri Collection, Haridwar

Digitized by Arya Samaj Foundation Chennai and eGangotri

The Trachea and Bronchi (fig. 1033)

The **trachea**, or **windpipe**, is a cartilaginous and membranous tube, about 10 or 11 cm. long, continued downwards from the lower part of the larynx, and reaching from the level of the sixth cervical vertebra to that of the upper border

Fig. 1033.—The cartilages of the larynx, trachea, and bronchi. Anterior aspect.

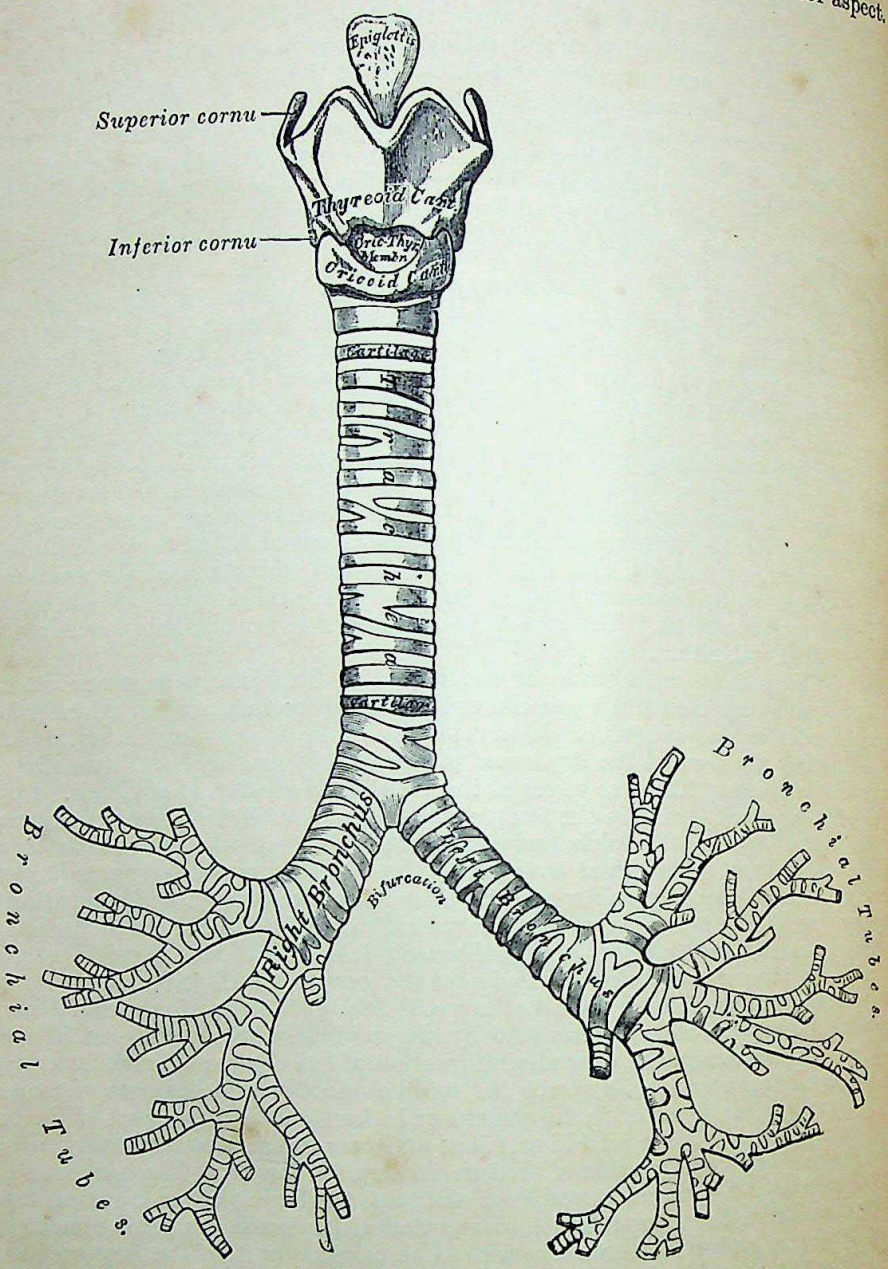

of the fifth thoracic vertebra, where it divides into two bronchi, one for each lung. It is not quite cylindrical, being flattened posteriorly; its diameter from side to side, is about 2 cm. in the male, and 1·5 in the female. In the child the trachea is smaller, more deeply placed and more movable than in the adult.

Relations of the trachea.—*In front* of the *cervical part* of the trachea (fig. 1034) are the skin, the superficial and deep fasciæ, the venous jugular arch connecting the anterior jugular veins, the Sternohyoidei and Sternothyreoidei. The second, third and fourth rings of the trachea are crossed by the isthmus of the thyreoid gland, and immediately above the isthmus is an anastomosis between the two superior thyreoid arteries; below the isthmus are the pre-tracheal fascia, the inferior thyreoid veins, the remains of the thymus, and the

CC-0. In Public Domain. Gurukul Kangri Collection, Haridwar

Digitized by Arya Samaj Foundation Chennai and eGangotri

arteria thyreoidea ima (when that vessel exists). In the child, the innominate artery crosses obliquely in front of the trachea at, or a little above, the level

Fig. 1034.—A transverse section through the anterior part of the neck at the level of the body of the first thoracic vertebra.

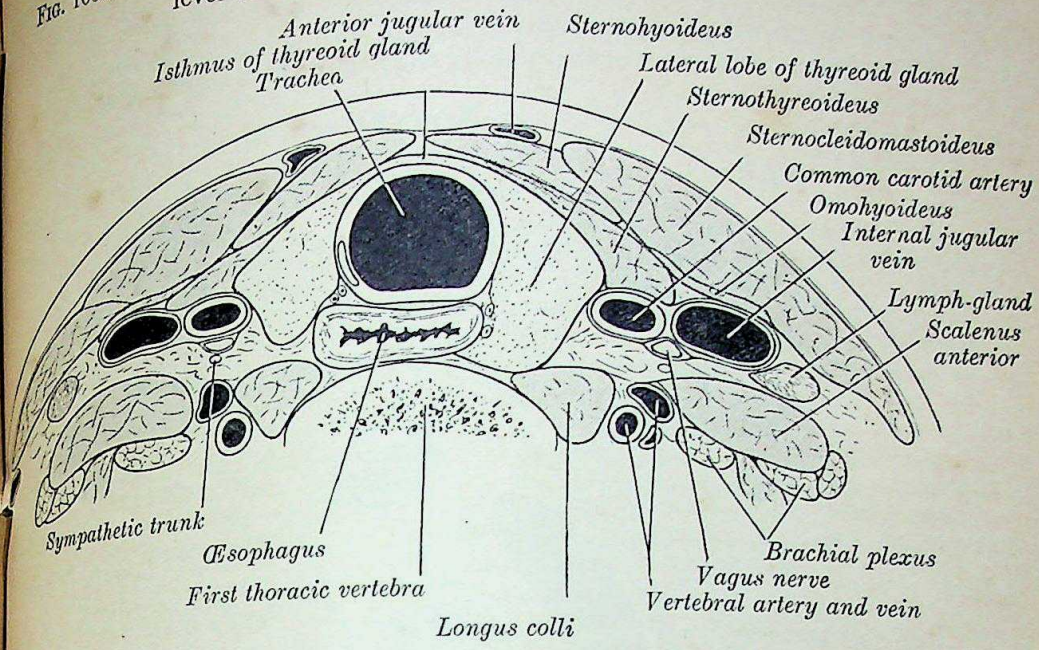

of the upper border of the manubrium sterni. *Behind* the trachea is the œsophagus, which separates the trachea from the vertebral column; the recurrent nerves ascend, one on either side, in the grooves between the sides of the trachea

Fig. 1035.—A transverse section through the mediastinal cavity at the level of the body of the third thoracic vertebra.

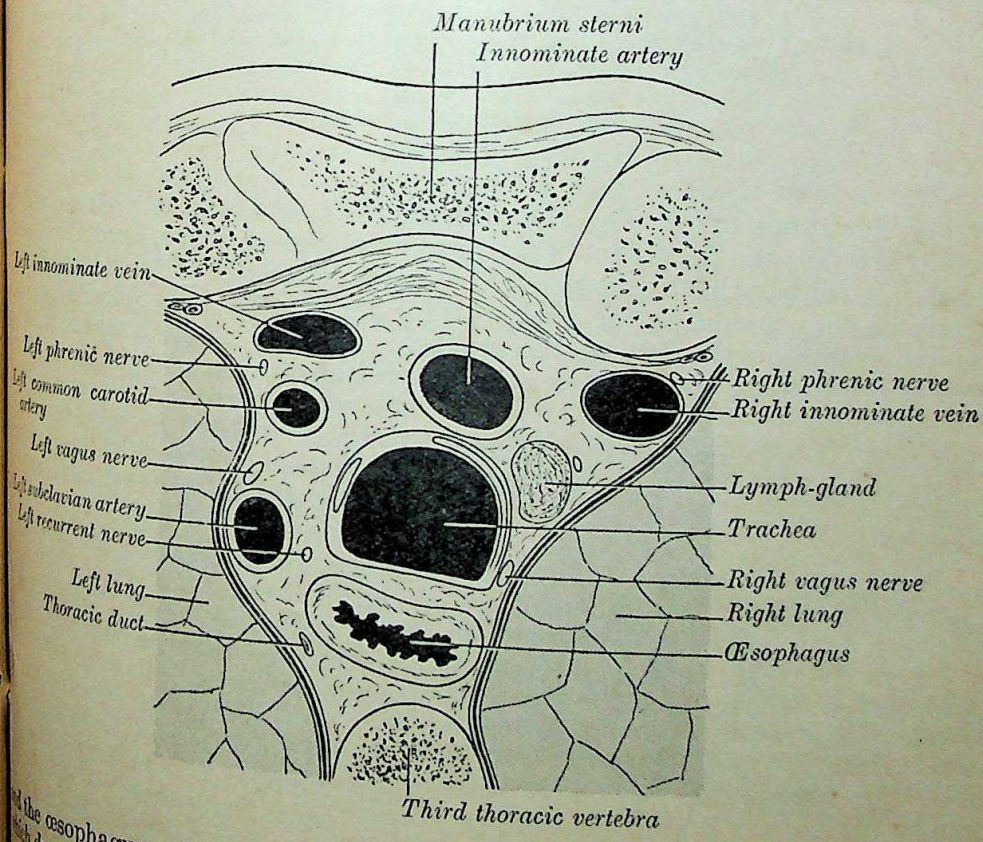

and the œsophagus. *Lateral* to the trachea are the lobes of the thyreoid gland, which descend to the level of the fifth or sixth tracheal ring, the common carotid and inferior thyreoid arteries.

CC-0. In Public Domain. Gurukul Kangri Collection, Haridwar

Digitized by Arya Samaj Foundation Chennai and eGangotri

The *thoracic part* of the trachea (figs. 1035, 1036) descends through the posterior part of the superior mediastinal cavity. *In front* of its *upper* portion are the manubrium sterni, the origins of the Sternothyreoidei, the remains of the thymus, and the inferior thyreoid veins; and in front of its *lower* portion

Fig. 1036.—A transverse section through the mediastinal cavity at the level of the upper part of the body of the fourth thoracic vertebra.

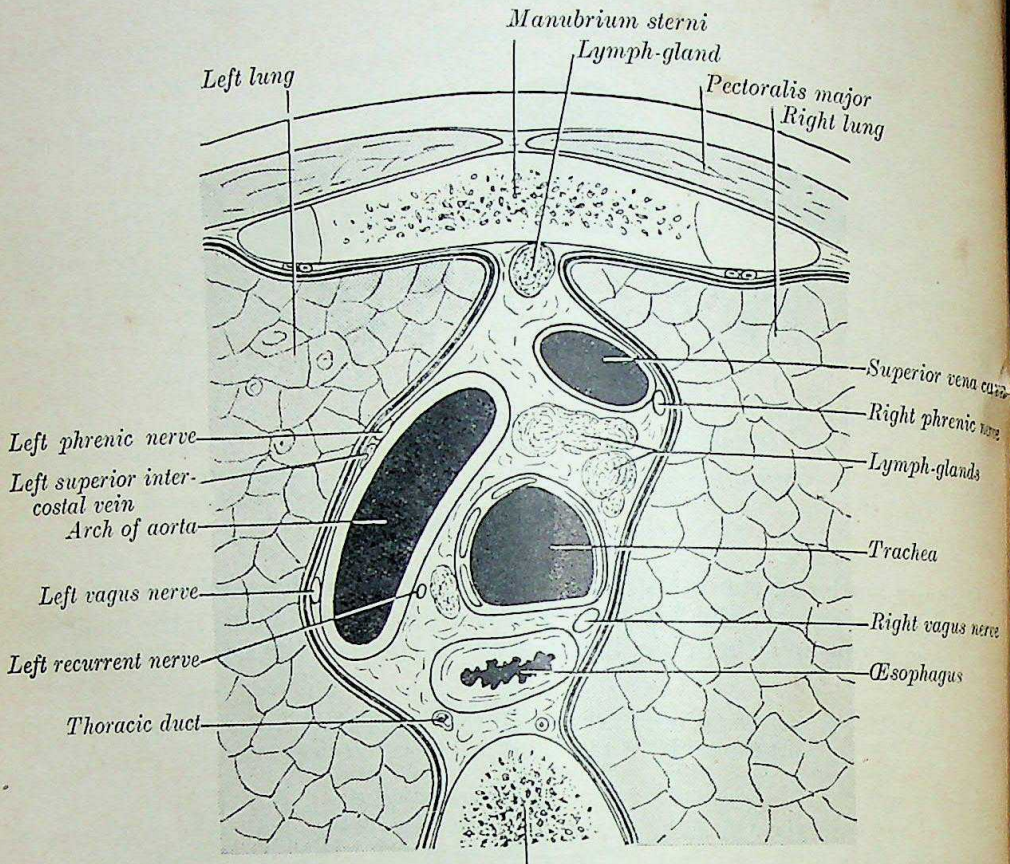

are the left innominate vein, the arch of the aorta, the innominate and left carotid arteries, the deep part of the cardiac plexus of nerves, and some lymph-glands. Owing to the divergence of the innominate artery from the left common carotid as they ascend in the neck, the former vessel comes to lie on the right, and the latter on the left of the trachea. *Behind* is the œsophagus, which intervenes between the trachea and the vertebral column. On the *right* are the right lung and pleura, the right vagus nerve, and the azygos vein. On the *left* are the arch of the aorta, the left common carotid and left subclavian arteries. The left recurrent nerve, in its upward course, lies at first between the trachea and the arch of the aorta, and then in the groove between the trachea and the œsophagus.

Fig. 1037.—A transverse section through the trachea, just above its bifurcation. Superior aspect.

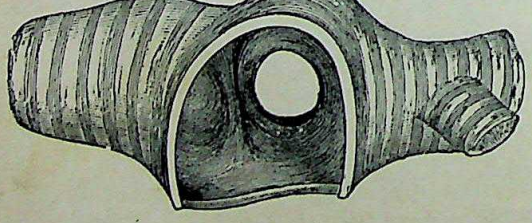

The **right bronchus**, wider, shorter, and more vertical than the left, is about 2·5 cm. long, and enters the right lung nearly opposite the fifth thoracic vertebra. The azygos vein arches over it from behind; and the right pulmonary artery lies at first below and then in front of it. It gives off a branch to the upper lobe of the right lung; this is termed the *eparterial branch*, because it arises above the right pulmonary artery. The bronchus now

CC-0. In Public Domain. Gurukul Kangri Collection, Haridwar

Digitized by Arya Samaj Foundation Chennai and eGangotri

passes below the artery, and is known as the *hyparterial branch*; this divides into two branches for the middle and lower lobes of the lung.

The **left bronchus**, narrower than the right, is nearly 5 cm. long, and enters the root of the left lung opposite the sixth thoracic vertebra. It passes beneath the aortic arch, and crosses in front of the œsophagus, the thoracic duct, and the descending aorta; the left pulmonary artery lies at first above, and then in front of it. The left bronchus has no eparterial branch, and therefore it has been supposed by some anatomists that there is no upper lobe to the left lung, and that the so-called upper lobe of the left lung corresponds to the middle lobe of the right lung.

The further subdivision of the bronchi will be considered with the structure of the lung.

If the trachea be cut across a short distance above its bifurcation, and the interior of the lower part viewed from above (fig. 1037), it will be seen that the septum between the two bronchi lies on the left of the median plane, and that the right bronchus is a more direct continuation of the trachea than the left.

Fig. 1038.—A transverse section through a part of the wall of the trachea.

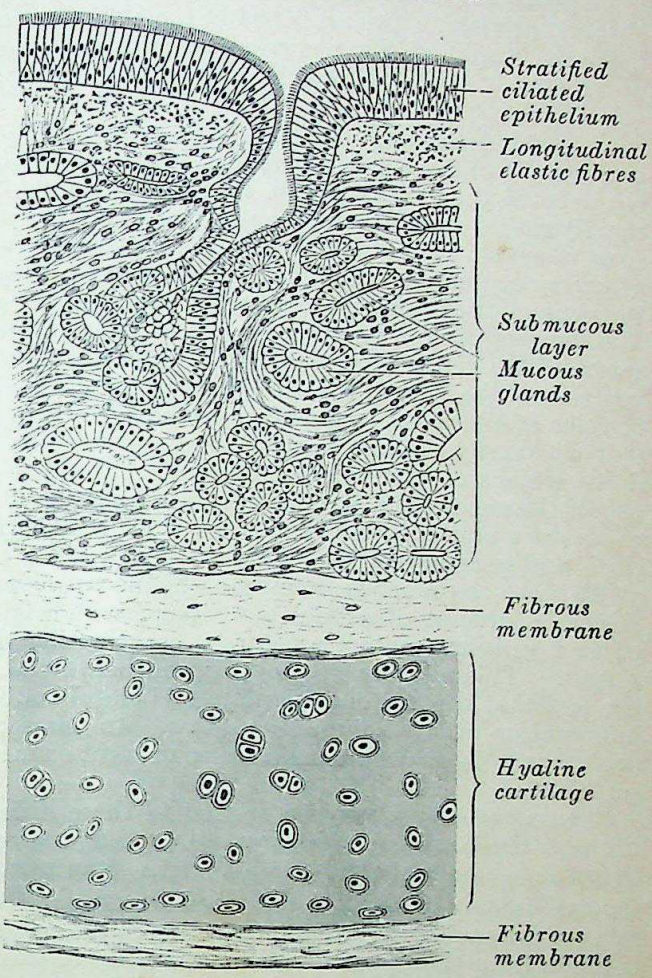

Structure (fig. 1038).—The trachea and extrapulmonary bronchi consist of a framework of imperfect rings of hyaline cartilage, united by fibrous and unstriped muscular tissue. They are lined by mucous membrane.

The *cartilages* of the trachea vary from sixteen to twenty in number. Each is in an imperfect ring which occupies the anterior two-thirds or more of the circumference of the trachea; behind, where the rings are deficient, the tube is flat, and is completed by fibrous tissue and unstriped muscular fibres. The cartilages are placed horizontally above one another, and are separated by narrow intervals. They measure about 4 mm. in length and 1 mm. in thickness; their external surfaces are flattened in a vertical direction, but their internal are convex. Two or more of the cartilages often unite, partially or completely, and are sometimes bifurcated at their extremities. They are highly elastic, but may become calcified in advanced life. In the bronchi the cartilages are shorter and narrower than those of the trachea, but have the same shape and arrangement.

The first and the last tracheal cartilages differ from the others (fig. 1033). The *first cartilage* is broader than the rest, and often divided at one end; it is connected by the crico-tracheal ligament with the lower border of the cricoid cartilage, with which, or with the succeeding cartilage, it is sometimes blended. The *last cartilage* is thick and broad in the middle, in consequence of its lower border being prolonged into a triangular hook-shaped process which curves downwards and backwards between the two bronchi. It forms on each side an imperfect ring which encloses the commencement of the bronchus. The cartilage above the last is somewhat broader at its centre than the others.

The *fibrous membrane*.—The cartilages are enclosed in an elastic fibrous membrane, which consists of two layers, one, the thicker, passing over the outer surfaces of the rings, the other over the inner surfaces: at the upper and lower margins of the cartilages the two layers blend and form a stout membrane which connects the rings one with another. Where the cartilages are deficient posteriorly, the membrane forms a single layer.

The *muscular tissue* is placed within the fibrous membrane at the posterior part of the tube, and consists of two layers of non-striped muscle, longitudinal and transverse. The *longitudinal fibres* are external, and consist of a few scattered bundles. The *transverse fibres* (Trachealis muscle) are internal, and form a thin layer which not only extends

CC-0. In Public Domain. Gurukul Kangri Collection, Haridwar

Digitized by Arya Samaj Foundation Chennai and eGangotri

between the ends of the cartilages but also passes across in the intervals between the cartilages.

Mucous Membrane.—The mucous membrane is continuous above with that of the larynx, and below with that of the bronchi. It consists of areolar and lymphoid tissue, and presents a well-marked basement-membrane, supporting a stratified epithelium, the surface cells of which are columnar and ciliated, while those of the deeper layers are oval or round. Beneath the basement-membrane there is a layer of longitudinal elastic fibres with a small amount of intervening areolar tissue. The *submucous layer* is composed of a loose meshwork of connective tissue, containing large blood-vessels, nerves, and mucous glands; the ducts of the latter pierce the overlying layers and open into the trachea (fig. 1038).

Vessels and Nerves.—The trachea is supplied with blood mainly by the inferior thyreoid *arteries*. The *veins* end in the thyreoid venous plexus. The *nerves* are derived from the vagi and the recurrent nerves, and from the sympathetic trunks; they are distributed to the Trachealis muscle and between the epithelial cells.

Applied Anatomy.—Foreign bodies often find their way into the air-passages, and may consist of large soft substances, as pieces of meat, which may become lodged in the entrance of the larynx, or in the rima glottidis, and cause speedy suffocation unless rapidly got rid of, or unless an opening is made into the air-passages below the obstruction, so as to enable the patient to breathe. Smaller bodies, frequently of a hard nature, such as cherry or plum stones, small pieces of bone, buttons, &c., may find their way through the rima glottidis into the trachea or bronchi, or may lodge in the ventricle of the larynx. The dangers then depend not so much upon the mechanical obstruction as upon reflex spasm of the glottis produced by the irritation of the foreign body. When lodged in the ventricle of the larynx, the foreign body may produce few symptoms, beyond sudden loss of voice or alteration in the voice sounds. When, however, it is situated in the trachea, it is constantly striking against the vocal folds during expiratory efforts, and thus produces attacks of dyspnœa from spasm of the glottis. When lodged in the bronchus, it usually becomes fixed there, and, occluding the lumen of the tube, causes a loss of the respiratory murmur on the affected side, and may subsequently lead to purulent bronchitis and gangrene of the lung.

Beneath the mucous membrane of the upper part of the air-passages there is a considerable amount of submucous tissue, which is liable to become much swollen from effusion in inflammatory affections, constituting the condition known as 'œdema of the glottis.' This effusion does not extend below the level of the vocal folds, on account of the fact that the mucous membrane is closely adherent to these structures without the intervention of any submucous tissue. In cases of œdema of the glottis, in which it is necessary to open the air-passages to prevent suffocation, the operation of laryngotomy is sufficient.

The air-passages may be opened in three different situations: by a vertical incision through the centre of the thyreoid cartilage (*thyreotomy*); through the middle cricothyreoid ligament (*laryngotomy*); or in some part of the trachea (*tracheotomy*).

Thyreotomy is usually performed for the purpose of removing growths from the vocal folds or for extracting foreign bodies from the ventricle of the larynx. A median incision is made from the upper border of the body of the hyoid bone to the lower border of the cricoid cartilage, and is carried through the subcutaneous tissues and deep fascia between the margins of the Sternohyoidei. An incision is then made in the middle cricothyreoid ligament, and one blade of a stout, sharp-pointed pair of scissors is introduced beneath the lower border of the thyreoid cartilage, and this structure is divided from below upwards. Great care must be taken to cut exactly in the middle line to avoid wounding the vocal folds. If the halves of the cartilage are now drawn apart, a very good view of the interior of the larynx will be obtained.

Laryngotomy is a simple operation, and should be performed in those cases where the air-passages require to be opened in an emergency for the relief of some sudden obstruction to respiration. The middle cricothyreoid ligament is very superficial, being covered only by the skin, superficial fascia, and the deep fascia in the middle line. On either side it is also covered by the Sternohyoideus and Sternothyreoideus, which diverge from each other at their upper parts, leaving a slight interval between them. On these muscles rest the anterior jugular veins. The cricothyreoid artery crosses the middle cricothyreoid ligament, and may be wounded, but rarely gives rise to any trouble. The operation is performed thus: the head being thrown back and steadied by an assistant, the finger is passed over the front of the neck, and the cricothyreoid depression felt for. A vertical incision is then made through the skin in the middle line over this spot, and carried down through the fascia until the middle cricothyreoid ligament is exposed. A cross-cut is then made through the ligament close to the upper border of the cricoid cartilage, so as to avoid, if possible, the cricothyreoid artery, and a laryngotomy tube inserted. It has been recommended, as a more rapid way of performing the operation, to make a transverse instead of a longitudinal cut through the superficial structures, and thus to open at once the air-passages. It will be seen, however, that in operating in this way the anterior jugular veins are liable to be wounded.

CC-0. In Public Domain. Gurukul Kangri Collection, Haridwar

Digitized by Arya Samaj Foundation Chennai and eGangotri

Tracheotomy may be performed either above or below the isthmus of the thyreoid gland, or this structure may be divided and the trachea opened behind it. From the relations already described it must be evident that the trachea can be more readily opened above than below the isthmus.

Tracheotomy above the isthmus is performed thus: the patient should, if possible, be laid on his back on a table in a good light. A pillow is to be placed under the shoulders and the head thrown back and steadied by an assistant. The surgeon standing on the right side of his patient makes an incision from 4 cm. to 5 cm. long in the median line of the neck from the top of the cricoid cartilage. After the superficial structures have been divided, the interval between the Sternohyoidei must be found, the fascia divided, and the muscles drawn apart. The lower border of the cricoid cartilage must now be felt for, and the upper part of the trachea exposed from this point downwards in the middle line. It has been recommended that the layer of fascia in front of the trachea should be divided transversely at the level of the lower border of the cricoid cartilage, and, having been seized with a pair of forceps, pressed downwards with the handle of the scalpel. By this means the isthmus of the thyreoid gland is depressed, and is saved from all danger of being wounded, and the trachea cleanly exposed. The trachea is now transfixed with a sharp hook and drawn forwards in order to steady it, and is then opened by inserting the knife into it and dividing the upper two or three rings by cutting upwards. If the trachea is to be opened beneath the isthmus of the thyreoid gland, the incision must be made from a little below the cricoid cartilage to the top of the sternum; in this situation the trachea is situated more deeply.

A portion or the whole of the larynx may be removed for malignant disease. It may be removed by a median incision through the soft parts, freeing the cartilages from the muscles and other structures in front, separating the larynx from the trachea below, and dissecting it off from the deeper structures from below upwards.

The Pleuræ

Each lung is invested by a delicate serous membrane, the **pleura**, which is arranged in the form of a closed invaginated sac. A portion of the serous membrane covers the surface of the lung and dips into the fissures between its lobes; it is called the *pulmonary pleura*. The rest of the membrane lines the inner surface of the corresponding half of the chest-wall, covers the Diaphragm, and is reflected over the structures occupying the middle part of the thorax; this portion is termed the *parietal pleura*. The pulmonary and parietal pleuræ are continuous with one another around and below the root of the lung; in health they are in actual contact, but the potential space between them is known as the *pleural cavity*. When the lung collapses or when air or fluid collects between the pulmonary and parietal pleuræ, the pleural cavity becomes apparent. The right and left pleural sacs are distinct from one another, and only touch each other for a short distance behind the second and third pieces of the sternum. The interval between the two sacs is termed the mediastinal cavity. The right pleural sac is shorter, wider, and reaches higher in the neck than the left.

The **pulmonary pleura** is inseparably connected with the lung. It covers the surfaces of the lung, including those which bound the fissures between the lobes of the lung; it is wanting, however, over an area where the lung root and along a line extending downwards from this and marking the attachment of the pulmonary ligament.

The **parietal pleura.**—Different portions of the parietal pleura have received distinctive names; the part lining the inner surfaces of the ribs and intercostales is the *costal pleura*; that clothing the thoracic surface of the diaphragm is the *diaphragmatic pleura*; that ascending into the neck over the summit of the lung is the *cupula of the pleura*; and that applied to the structures in the middle of the thorax is the *mediastinal pleura*.

The *costal pleura* (figs. 1039, 1040) lines the ribs and intercostal muscles, and is easily separated from them. In front it begins behind the sternum where it is continuous with the mediastinal pleura. The line of junction of the mediastinal with the costal pleura extends from behind the sternoclavicular joint downwards and medialwards to a point in the middle line behind the vertical angle. From this point the right and left costal pleuræ descend in contact with each other as far as the level of the fourth costal cartilages, below which the line differs on the two sides. On the right side it is continued down the posterior surface of the xiphoid process. On the left it diverges laterally and descends close to or a short distance from the lateral margin of the

CC-0. In Public Domain. Gurukul Kangri Collection, Haridwar

Digitized by Arya Samaj Foundation Chennai and eGangotri

sternum, to the level of the sixth costal cartilage. On either side the costal pleura sweeps lateralwards, lining the inner surfaces of the costal cartilages, ribs and intercostales, and at the back of the thorax passes over the sympathetic trunk and its branches, and on to the sides of the bodies of the vertebræ, where it again becomes continuous with the mediastinal pleura. Above, the costal pleura is continuous with the cupula of the pleura at the inner margin of the first rib. Below, it is continuous with the diaphragmatic pleura along a line which differs slightly on the two sides. On the right side the line begins behind the xiphoid process, and runs downwards and backwards behind the seventh costal cartilage, and reaches the midaxillary line at the

Fig. 1039.—The relations of the pleuræ and lungs to the chest wall. Anterior aspect.

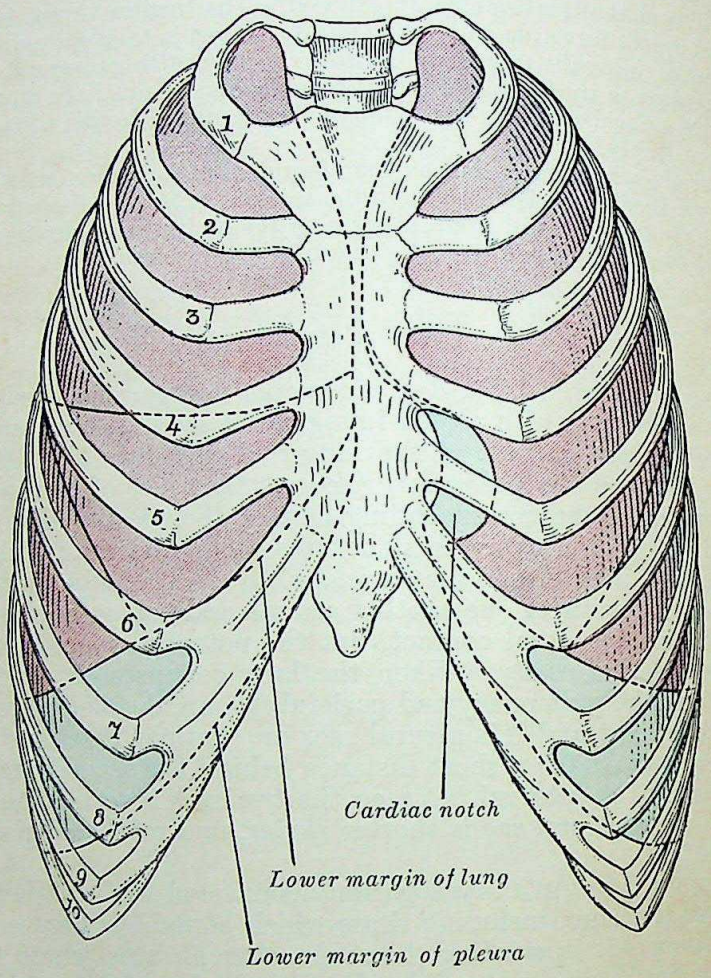

Pleuræ in blue ; lungs in purple.

level of the tenth rib ; from here the line ascends slightly, and crossing the twelfth rib, reaches the level of the spinous process of the twelfth thoracic vertebra. On the left side the line follows at first the ascending part of the sixth costal cartilage, but in the rest of its course is slightly lower than that on the right side.

The *diaphragmatic pleura* is thin, and covers the upper surface of its corresponding side of the Diaphragm. The outer part of its circumference is the line described above, along which it is continuous with the costal pleura. Medially it is continuous with the mediastinal pleura along the line of attachment of the pericardium to the Diaphragm.

The *cupula of the pleura*, i.e. the cervical portion of the pleura, is the continuation of the costal pleura over the apex of the lung. It extends from the inner border of the first rib medialwards and upwards to the apex of the lung, its summit reaching as high as the lower edge of the neck of the first rib; it then descends along the side of the trachea to become continuous with the

CC-0. In Public Domain. Gurukul Kangri Collection, Haridwar

Digitized by Arya Samaj Foundation Chennai and eGangotri

The cupula of the pleura is strengthened by a dome-like expansion of fascia (*Sibson's fascia*) attached in front to the inner border of the first rib and behind to the anterior border of the transverse process of the seventh cervical vertebra; it is covered and strengthened by a few spreading muscular fibres derived from the Scaleni. The subclavian artery, directed upwards and lateralwards, occupies a furrow a little below the summit of the cupula.

The mediastinal pleura. The space between the pleuræ is named the mediastinal cavity or interpleural space. It contains the heart, enclosed in its pericardium, the great vessels entering and leaving the heart, and the œsophagus, together with other structures described on pp. 1030 to 1083. These are partly covered with the mediastinal pleura which consists of a right and a left portion (figs. 1036, 1041). Above the root of the lung each portion is a continuous sheet between the sternum and the vertebral column. That of the right side is in contact with the right innominate vein, the upper part of the superior vena cava, the terminal part of the azygos vein, the right phrenic and right vagus nerves, the trachea, and the œsophagus. That of the left side is in relation with the arch of the aorta, the left phrenic and left vagus nerves, the left innominate and superior intercostal veins, the left common carotid and subclavian arteries, the thoracic duct and the œsophagus. At the root of the lung the mediastinal pleura is carried lateralwards as a tube of serous membrane enclosing the structures of the lung-root and passing into continuity with the pulmonary pleura. Below the lung-root the mediastinal pleura extends as a bilaminar layer from the side of the pericardium to the mediastinal surface of the lung, where it is also continuous with the pulmonary pleura. This bilaminar layer is named the *pulmonary ligament* (fig. 1045), and serves to retain the lower part of the lung in position. It is continuous above with the tube investing the lung root; below it ends in a free falciform border.

FIG. 1040.—The relations of the pleuræ and lungs to the chest wall. Lateral aspect.

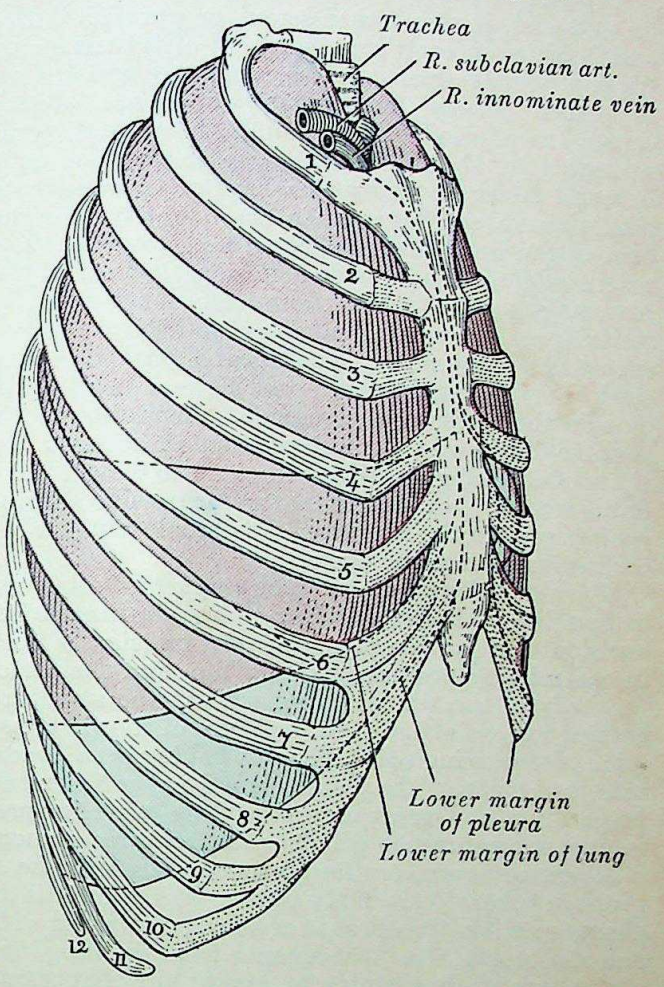

Pleuræ in blue; lungs in purple.

The inferior limit of the pleura is on a considerably lower level than the corresponding border of the lung (figs. 1039, 1040), but does not extend to the attachment of the Diaphragm, so that below the line of reflection of the pleura from the chest-wall to the Diaphragm, the latter is in direct contact with the costal cartilages and the Intercostales interni. Moreover, in ordinary inspiration the thin inferior margin of the lung does not extend as low as the line of the pleural reflection, with the result that the costal and diaphragmatic pleuræ are not in contact, the intervening narrow slit being termed the *phrenicocostal sinus*. A similar condition exists behind the sternum and rib cartilages, where the anterior thin margin of the lung falls short of the line of pleural reflection, and where the slit-like cavity between the two layers of pleura forms what is called the *costomediastinal sinus*.

CC-0. In Public Domain. Gurukul Kangri Collection, Haridwar

Digitized by Arya Samaj Foundation Chennai and eGangotri

Structure.—The free surface of the pleura is smooth, and moistened by serous fluid. Like other serous membranes, it is covered by a single layer of flattened nucleated cells, united at their edges by cement-substance. These cells are modified connective tissue corpuscles, and rest on a basement-membrane. Beneath the basement-membrane there are networks of yellow elastic and white fibres, imbedded in ground-substance which also contains connective tissue cells. Blood-vessels, lymphatic vessels, and nerves are distributed in the substance of the pleura, and the lymphatic vessels communicate with the pleural cavity by means of stomata or openings between the flattened cells.

Vessels and Nerves.—The *arteries* of the pleura are derived from the intercostal, internal mammary, musculophrenic, thymic, pericardiac, and bronchial vessels. The *veins* correspond to the arteries. The *lymphatics* are described on p. 778. The *nerves* are derived from the phrenic nerve and from the sympathetic trunk. Kölliker states that nerves accompany the ramifications of the bronchial arteries in the pulmonary pleura.

Applied Anatomy.—Acute inflammation of the pleura, or *pleurisy*, may be either dry or wet, and, if wet, either serous or purulent. *Dry pleurisy* is common in pneumonia, and is often an early manifestation of tuberculosis. It gives rise to much pain, and to friction sounds due to the scraping to and fro over one another of the inflamed and roughened parietal and pulmonary pleuræ. *Wet pleurisy* occurs if the inflammation causes the effusion of serum into the pleural cavity. The two pleural layers are now separated by the fluid effusion, so the friction sounds are no longer produced. Room is found for the fluid by shrinkage of the supernatant lung due to the retraction of its elastic tissue, and later, when the quantity of serum exceeds about 1·5 litre, by shifting over of the heart and unaffected lung towards the sound side. This shifting may be so extensive that, in a left-sided effusion, the apex of the heart may come to lie under the right mammary papilla. Any pleural effusion that is large enough to embarrass respiration seriously, or has remained unabsorbed for two or three weeks, should be removed by tapping (paracentesis thoracis). The trocar is pushed through the chest-wall into the fluid, in the sixth or seventh intercostal space in the midaxillary line, or in the eighth or ninth space just outside the angle of the scapula. Aspiration is then performed, and as much fluid as possible drawn off: it must be stopped, however, if the patient shows signs of collapse, or if fits of coughing occur and threaten to wound the expanding lung against the sharp end of the trocar. Non-inflammatory or passive effusion into the pleura, called *hydrothorax*, is often seen in the later stages of chronic renal or cardiac disease, and demands treatment on lines similar to the above.

Purulent pleural effusion, or *empyema*, often occurs after such diseases as pneumonia or measles. This condition requires drainage of the cavity, which usually necessitates excision of a portion of a rib. An incision is made down to the seventh or eighth rib in the mid- or posterior axillary line and the periosteum is incised, and separated from the body of the rib, carrying with it the structures in the costal groove. With bone-cutting forceps about 4 cm. or 5 cm. of the rib are separated and removed, and the underlying pleura is incised. The pus having been evacuated, a large drainage tube is inserted into the cavity. The pleura should never be irrigated, as sudden death has followed this proceeding, and great care should be taken to prevent the tube from slipping into the cavity, an occurrence which is far from uncommon.

Pneumothorax, or the presence of gas in the pleural cavity, is a common terminal event in tuberculosis of the lungs; less often it is due to trauma—rupture of the lung, for example, when the chest is crushed, or tearing of the lung-tissue by the sharp projecting end of a broken rib. Air escapes from the lung into the pleural cavity; the elastic tissue of the lung at once contracts, and finally that organ shrinks away to a dark rounded mass the size of a fist, lying close against the vertebral column. The symptoms of pneumothorax are often very severe; cyanosis, intense dyspnœa, great pain on the affected side, and cardiac failure. Their severity is increased by the fact that the blood-vessels of the collapsed lung offer less resistance to the circulation of the blood than do those of the other lung. Not only, therefore, does the sound lung suddenly have to take over the work—the aeration of the blood—normally performed by both lungs, but it has to do so at the moment when the circulation of blood through it is partially short-circuited by the collapsed lung. If the patient survives for a few days, empyema often complicates the pneumothorax, setting up the condition called *pyopneumothorax*. During the last few years a valuable method of treating selected cases of pulmonary tuberculosis by the establishment and maintenance of an artificial pneumothorax on the affected side, causing collapse of the diseased lung, has been employed.

In operations upon the kidney, it must be borne in mind that the pleural cavity usually extends below the level of the medial portion of the last rib, and may therefore be opened in these operations, especially when the last rib is removed in order to give more room.

The Mediastinal Cavity

The **mediastinal cavity**, or space between the right and left pleuræ, extends from the sternum in front to the vertebral column behind (fig. 1041).

CC-0. In Public Domain. Gurukul Kangri Collection, Haridwar

Digitized by Arya Samaj Foundation Chennai and eGangotri

FIG. 1041.—A transverse section through the thorax, showing the contents of the middle and posterior mediastinal cavities. Diagrammatic.

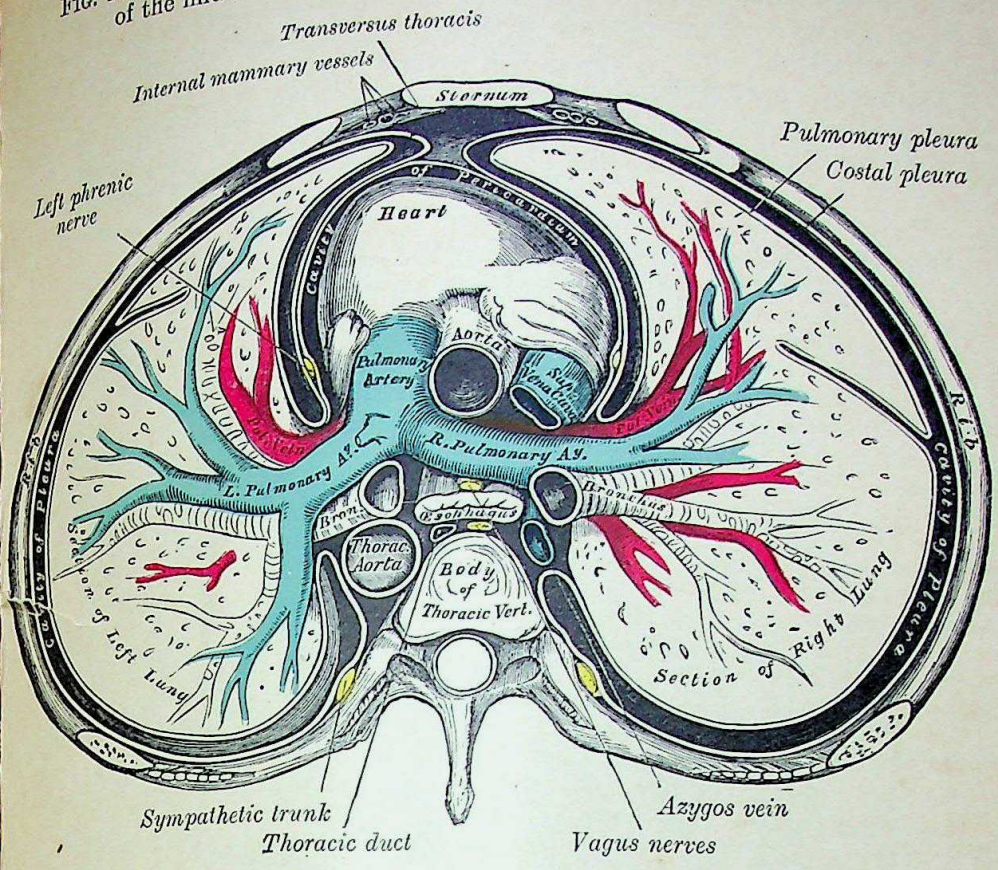

FIG. 1042.—A transverse section through the mediastinal cavity at the level of the upper part of the body of the sixth thoracic vertebra.

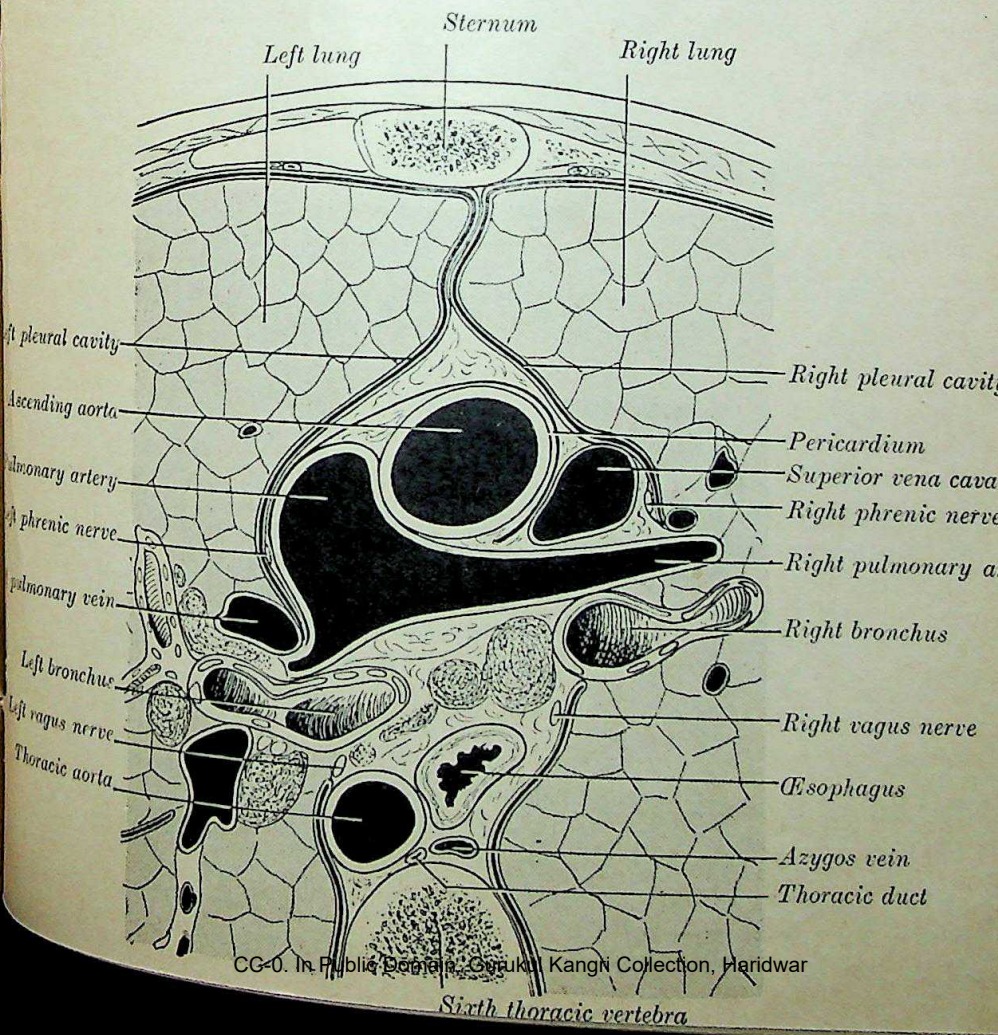

CC-0. In Public Domain. Gurukul Kangri Collection, Haridwar

Digitized by Arya Samaj Foundation Chennai and eGangotri

It is divided, for purposes of description, into two parts, an *upper*, which is named the superior mediastinal cavity, and a *lower*, which is subdivided into (*a*) the anterior mediastinal cavity, in front of the pericardium, (*b*) the middle mediastinal cavity, containing the pericardium and its contents, and (*c*) the posterior mediastinal cavity, behind the pericardium.

The **superior mediastinal cavity** (figs. 1035, 1036) lies between the manubrium sterni in front, and the upper four thoracic vertebræ behind. It is bounded below by a slightly oblique plane passing from the junction of the

Fig. 1043.—A transverse section through the mediastinal cavity at the level of the lower part of the body of the sixth thoracic vertebra.

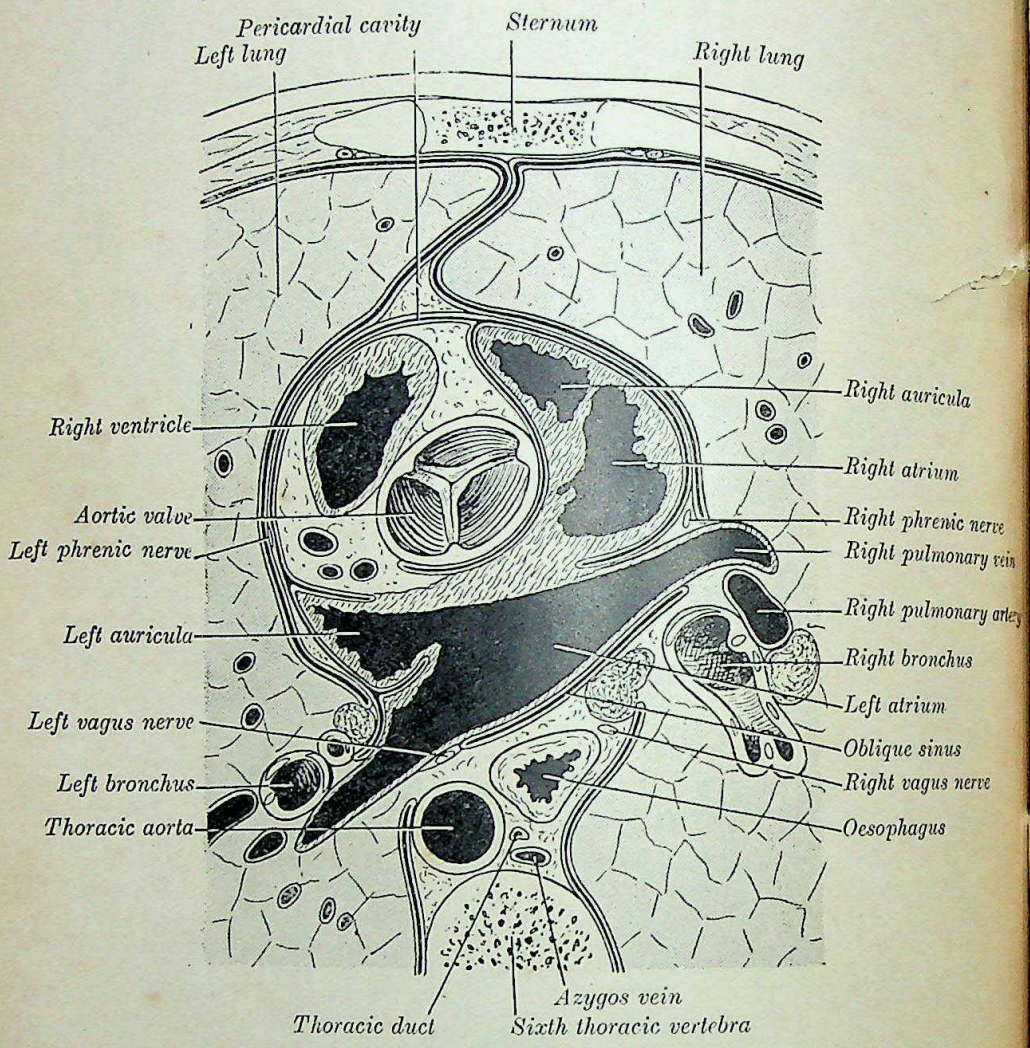

manubrium and body of the sternum to the lower part of the body of the fourth thoracic vertebra, and laterally by the pleuræ; above, by the plane of the thoracic inlet. It contains the origins of the Sternohyoidei and Sternothyreoidei and the lower ends of the Longi colli; the aortic arch; the innominate, left common carotid and left subclavian arteries; the innominate veins and the upper half of the superior vena cava; the left superior intercostal vein; the vagus, cardiac, phrenic, and left recurrent nerves; the trachea œsophagus, and thoracic duct; the remains of the thymus, and some lymph-glands.

The **anterior mediastinal cavity** lies between the sternum in front and the pericardium behind (fig. 1041); it exists only below the level of the fourth costal cartilages, where the left pleura diverges from the mid-sternal line. It contains a quantity of loose areolar tissue, some lymphatic vessels which ascend from the convex surface of the liver, two or three lymph-glands, and a few small mediastinal branches of the internal mammary artery.

CC-0. In Public Domain. Gurukul Kangri Collection, Haridwar

Digitized by Arya Samaj Foundation Chennai and eGangotri

The **middle mediastinal cavity** (figs. 1042, 1043) is the broadest part of the interpleural space. It contains the heart enclosed in the pericardium, the ascending aorta, the lower half of the superior vena cava, the terminal part of the azygos vein, the bifurcation of the trachea, the two bronchi, the

FIG. 1044.—The superior, middle and posterior mediastinal cavities. Left lateral aspect.

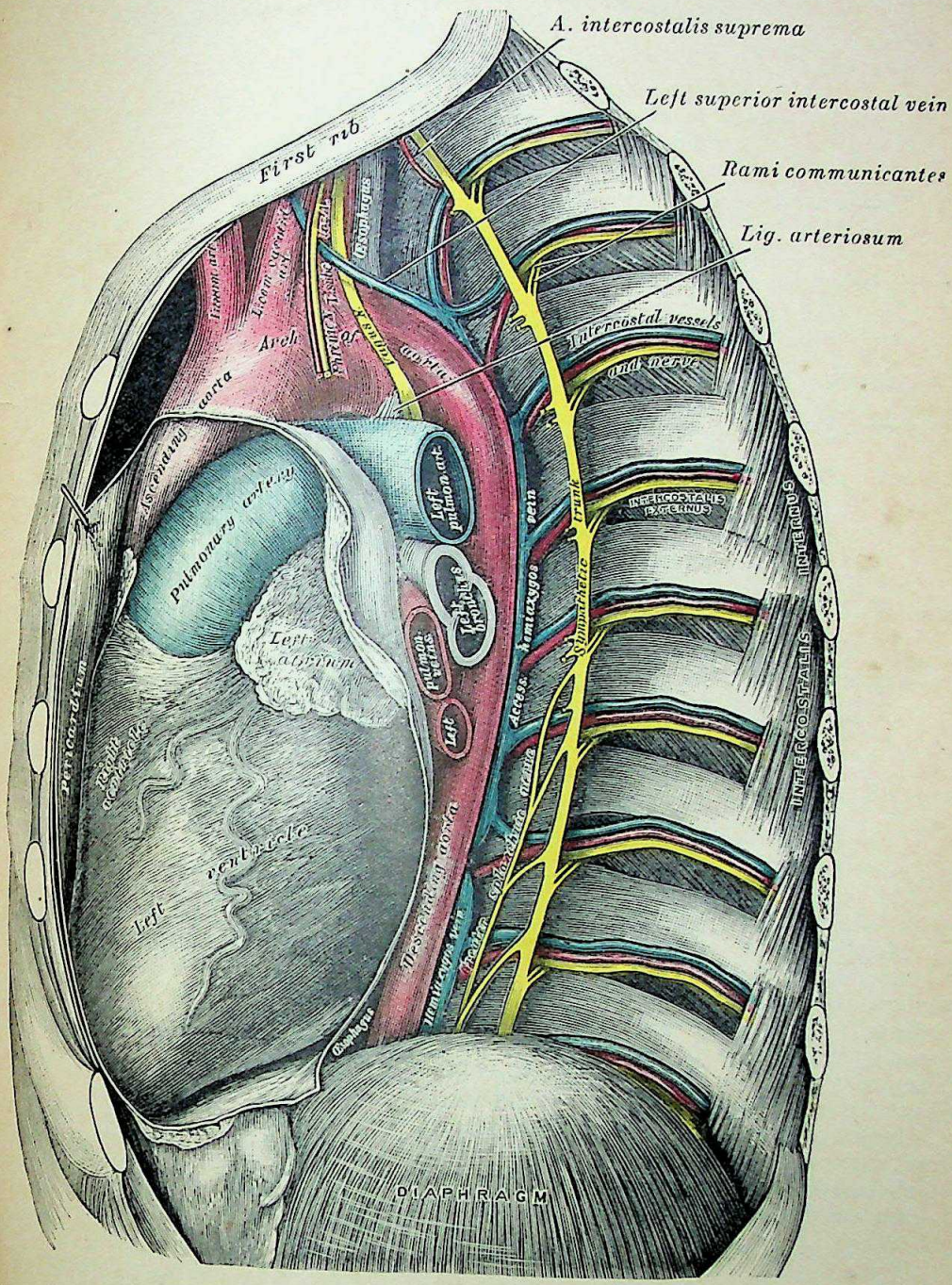

pulmonary artery dividing into its right and left branches, the right and left pulmonary veins, the phrenic nerves, and some tracheobronchial lymph-glands.

The **posterior mediastinal cavity** (figs. 1041, 1043) is an irregularly shaped space running parallel with the vertebral column; it is bounded in front by the pericardium above, and by the posterior surface of the Diaphragm below, behind by the vertebral column from the lower border of the fourth to the twelfth thoracic vertebra, and on either side by the mediastinal pleura. It contains the thoracic part of the descending aorta, the azygos, hemiazygos, and accessory hemiazygos veins, the vagus and splanchnic nerves, the oesophagus, the thoracic duct, and some lymph-glands.

CC-0. In Public Domain. Gurukul Kangri Collection, Haridwar

Digitized by Arya Samaj Foundation Chennai and eGangotri

FIG. 1045.—A transverse section through the mediastinal cavity at the level of the body of the seventh thoracic vertebra.

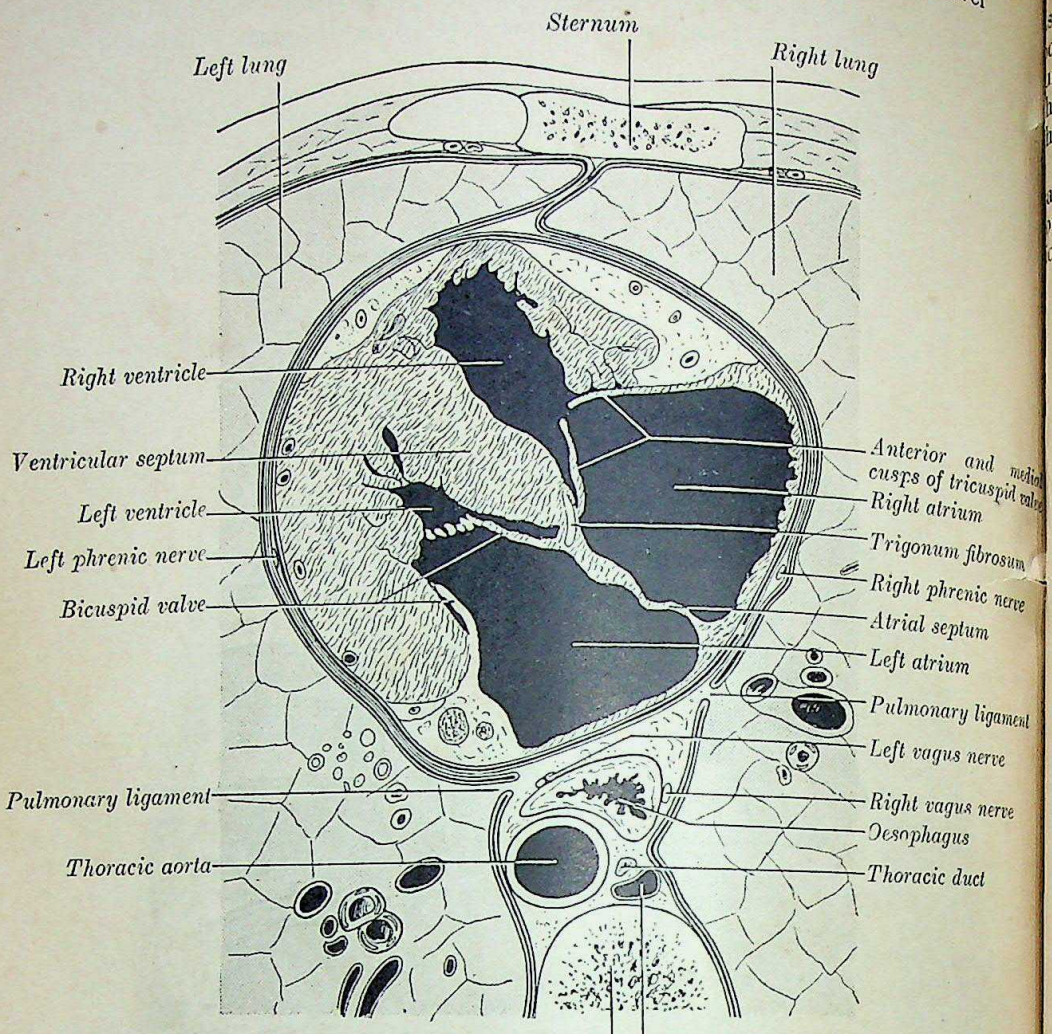

Applied Anatomy.—Primary tumours of the mediastinum are usually sarcoma or carcinoma arising from the thymus or the mediastinal lymph-glands. Lymphosarcoma, embryoma, and dermoid cysts occur more rarely. These tumours give rise to pain, deformity of the chest, and symptoms of pressure on the nerves, blood-vessels, air-passages, lymphatics, and on the œsophagus, as these various structures pass through the thorax. They may produce physical signs very much like those of an aortic aneurysm, so that diagnosis between the two is often difficult.

Inflammation of the mediastinum due to wounds, or to the spread of inflammation from adjacent parts (e.g. the œsophagus, the pericardium), is sometimes acute, leading to abscess-formation; there is also a chronic form—chronic adhesive mediastinopericarditis—associated with adhesions and inflammation of the pericardium.

THE LUNGS (PULMONES)

The **lungs** are the essential organs of respiration; they are two in number, placed one on either side within the thorax, and separated from each other by the heart and other contents of the mediastinal cavity (fig. 1046). The substance of the lung is of a light, porous, spongy texture; it floats in water, and crepitates when handled, owing to the presence of air in its alveoli; it is also highly elastic; hence the retracted state of the lungs when they are removed from the closed cavity of the thorax. The surface is smooth, shining, and marked out into numerous polyhedral areas, indicating the lobules of the lung; each of these areas is crossed by numerous lighter lines.

At birth the lungs are pinkish-white in colour; in adult life the colour is a dark slaty-grey, mottled in patches, and as age advances, this mottling

CC-0. In Public Domain. Gurukul Kangri Collection, Haridwar

Digitized by Arya Samaj Foundation Chennai and eGangotri

ssumes a black colour. The colouring matter consists of granules of a carbonaceous substance deposited in the areolar tissue near the surface of the ung; it increases in quantity as age advances, and is more abundant in males han in females. As a rule, the posterior border of the lung is darker than he anterior.

The right lung usually weighs about 625 gm., the left 567 gm., but much ariation is met with according to the amount of blood or serous fluid they ontain. The lungs are heavier in the male than in the female; their proporon to the body is, in the former, as 1 to 37, in the latter as 1 to 43.

Fig. 1046.—The heart and lungs. Anterior aspect.

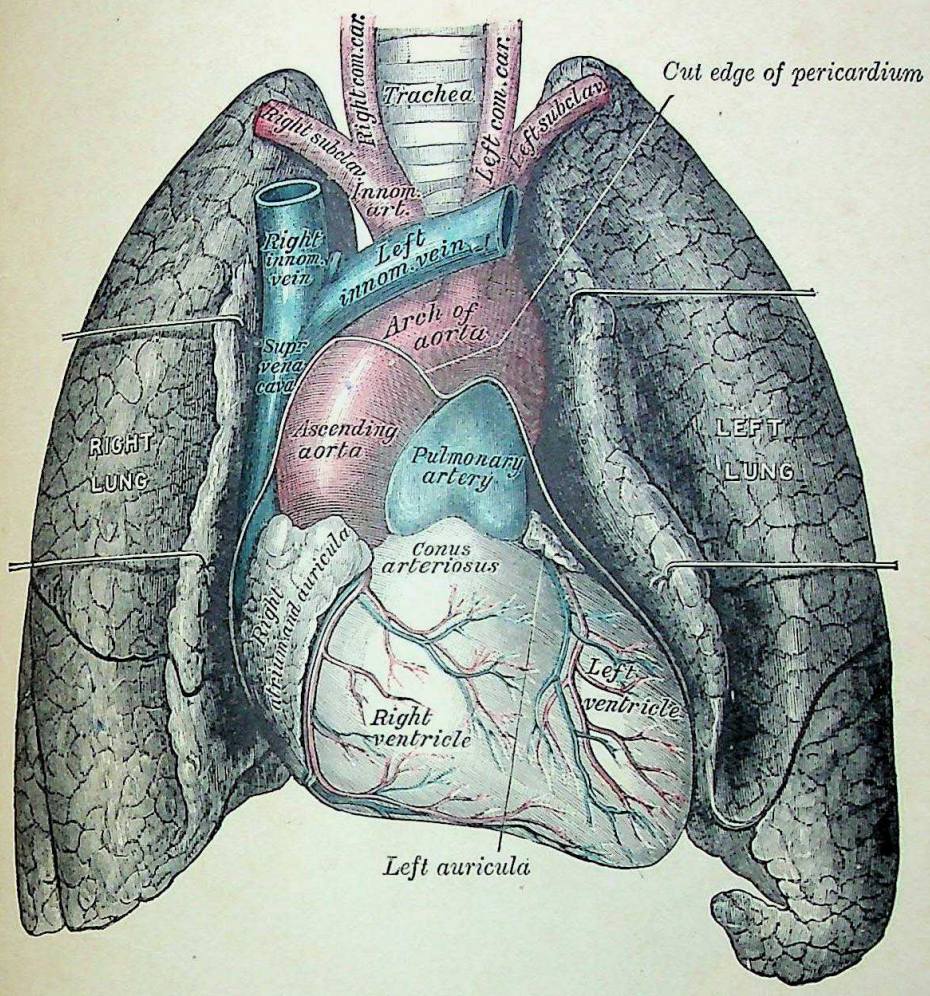

Each lung is conical in shape, and has an apex, a base, three borders, and wo surfaces.

The *apex* is rounded, and extends into the root of the neck, reaching from cm. to 4 cm. above the level of the sternal end of the first rib. A sulcus uns upwards and lateralwards immediately below the apex, and is produced y the subclavian artery.

The *base* is semilunar in shape, and concave; it rests upon the convex urface of the Diaphragm, which separates the right lung from the right lobe f the liver, and the left lung from the left lobe of the liver, the stomach, and he spleen. Since the Diaphragm extends higher on the right than on the left ide, the concavity on the base of the right lung is deeper than that on the eft. Laterally and behind, the base is bounded by a thin, sharp margin which rojects for some distance into the phrenicocostal sinus of the pleura, between he lower ribs and the costal attachment of the Diaphragm.

The *costal surface* is smooth, convex, of considerable extent, and corresponds o the form of the cavity of the chest, which is deeper behind than in front. t is in contact with the costal pleura, and exhibits, in specimens which have een hardened *in situ*, slight grooves corresponding with the overlying ribs.

CC-0. In Public Domain. Gurukul Kangri Collection, Haridwar

Digitized by Arya Samaj Foundation Chennai and eGangotri

The *medial surface* is divided into a posterior or *vertebral* part, in contact with the sides of the bodies of the thoracic vertebræ, and an anterior or *mediastinal* part, in contact with the mediastinal pleura. On the mediastinal part is a deep concavity, the *cardiac impression*, which accommodates the pericardium; this concavity is larger and deeper on the left than on the right lung, because the heart projects more to the left than to the right side of the median plane. Above and behind this concavity is a triangular depression named the *hilum*, where the structures which form the root of the lung (p. 1088) enter and leave the viscus. These structures are invested by pleura, which, below the hilum and behind the pericardial impression, forms the pulmonary ligament. On the *right* lung (fig. 1047), immediately above the hilum, is an arched furrow which accommodates the azygos vein; while running upwards

Fig. 1047.—The mediastinal surface of the right lung.

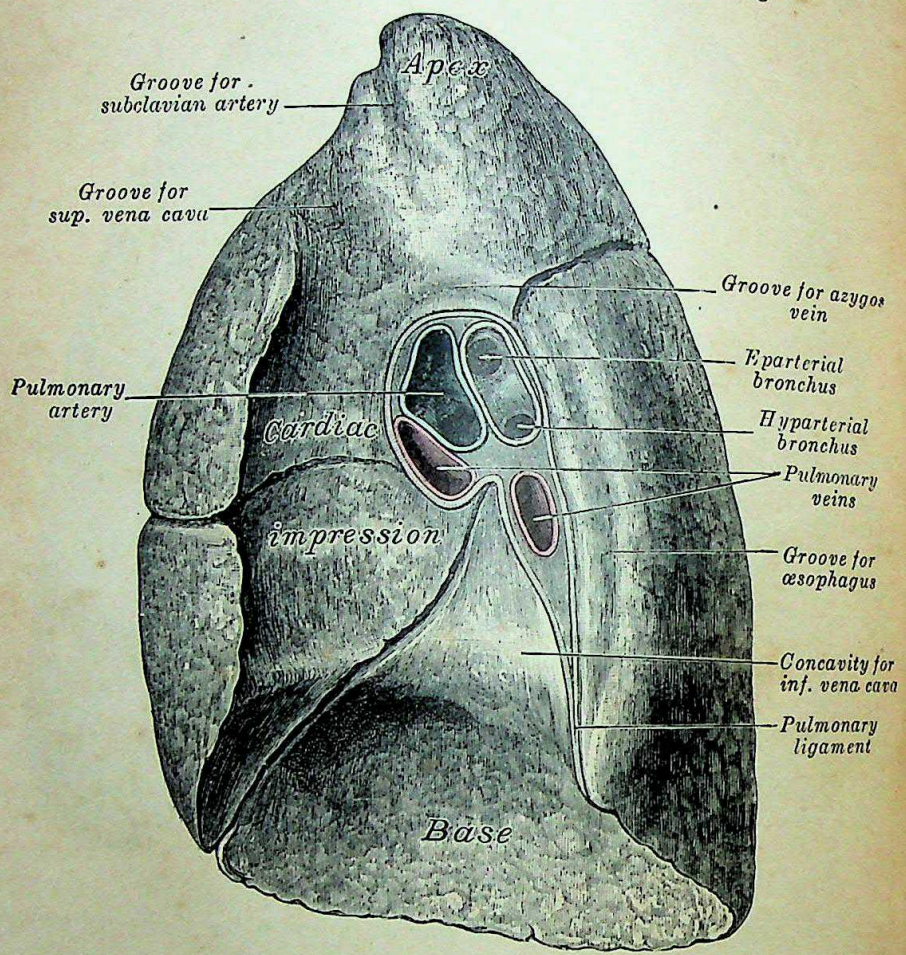

and then arching lateralwards a short distance below the apex, is a wide groove for the superior vena cava and right innominate vein. Behind the hilum and the attachment of the pulmonary ligament is a vertical groove for the œsophagus; this groove becomes less distinct below, owing to the inclination of the lower part of the œsophagus to the left of the middle line. In front and to the right of the lower part of the œsophageal groove is a concavity for the extrapericardiac portion of the thoracic part of the inferior vena cava. On the *left* lung (fig. 1048), immediately above the hilum, is a well-marked curved furrow produced by the aortic arch, and running upwards from this towards the apex is a groove accommodating the left subclavian artery; a slight impression in front of the latter and close to the margin of the lung lodges the left innominate vein. Behind the hilum and pulmonary ligament is a vertical furrow produced by the descending aorta; and in front of this, near the base of the lung, the lower part of the œsophagus causes a shallow impression.

CC-0. In Public Domain. Gurukul Kangri Collection, Haridwar

Digitized by Arya Samaj Foundation Chennai and eGangotri

The *inferior border* is thin and sharp where it separates the base from the costal surface, and extends into the phrenicocostal sinus; medially, where it divides the base from the mediastinal surface, it is blunt and rounded. The *posterior border* is broad and rounded, and is received into the deep concavity on either side of the vertebral column. It is much longer than the anterior border, and projects, below, into the phrenicocostal sinus.

The *anterior border* is thin and sharp, and overlaps the front of the pericardium; that of the *right* lung is almost vertical, and projects into the costomediastinal sinus; that of the *left* presents, below, an angular notch, the *cardiac notch*, in which a small part of the pericardium is exposed.

The fissures and lobes of the lungs.—The *left lung* is divided into two lobes (fig. 1048), superior and inferior, by a fissure which extends from

Fig. 1048.—The mediastinal surface of the left lung.

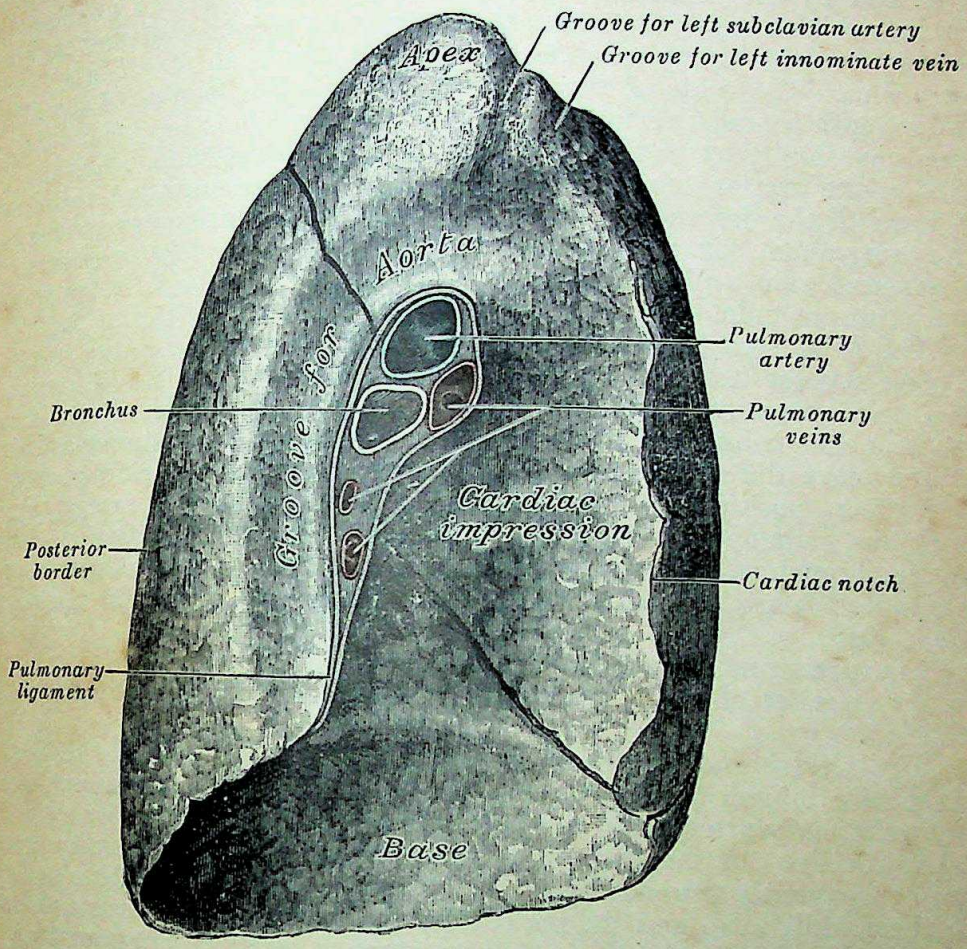

the costal to the mediastinal surface of the lung both above and below the hilum. As seen on the surface, this fissure begins on the mediastinal surface of the lung at the upper and posterior part of the hilum, and runs backwards and upwards to the posterior border, which it crosses at a point about 6 cm. below the apex. It then extends downwards and forwards over the costal surface, and reaches the lower border a little behind its anterior extremity, and its further course can be followed upwards and backwards across the mediastinal surface as far as the lower part of the hilum. The *superior lobe* lies above and in front of this fissure, and includes the apex, the anterior border, a considerable part of the costal surface, and the greater part of the mediastinal surface of the lung. The *inferior lobe*, the larger of the two, is situated below and behind the fissure, and comprises almost the whole of the base, a large portion of the costal surface, and the greater part of the posterior border.

The *right lung* is divided into three lobes, superior, middle, and inferior, by two fissures (fig. 1047). One of these separates the inferior from the middle and superior lobes, and corresponds closely with the fissure in the left lung.

CC-0. In Public Domain. Gurukul Kangri Collection, Haridwar

Digitized by Arya Samaj Foundation Chennai and eGangotri

Its direction is, however, more vertical, and it cuts the lower border about 7·5 cm. behind its anterior extremity. The other fissure is short, and separates the superior from the middle lobe. It begins in the previous fissure near the posterior border of the lung, and, running horizontally forwards, cuts the anterior border on a level with the sternal end of the fourth costal cartilage; on the mediastinal surface it may be traced backwards to the hilum. The *middle lobe* of the right lung is small and wedge-shaped, and includes the lower part of the anterior border and the anterior part of the base of the lung.

The right lung, although shorter by 2·5 cm. than the left, in consequence of the Diaphragm rising higher on the right side to accommodate the liver, is broader, owing to the inclination of the heart to the left side; its total capacity and weight are greater than those of the left lung.

The roots of the lungs.—A little above the middle of the mediastinal surface of each lung, and nearer its posterior than its anterior border, is the root of the lung, by which the lung is united to the heart and the trachea. The root is formed by the bronchus, the pulmonary artery, the two pulmonary veins, the bronchial arteries and veins, the pulmonary plexuses of nerves, lymphatic vessels, bronchial lymph-glands, and areolar tissue, all of which are enveloped by pleura. The roots of the lungs lie opposite the bodies of the fifth, sixth and seventh thoracic vertebræ. That of the right lung lies behind the superior vena cava and part of the right atrium of the heart, and below the terminal part of the azygos vein. That of the left lung is below the aortic arch and in front of the descending aorta. The following relations are common to the two lung-roots, viz.: in front, the phrenic nerve, the pericardiacophrenic artery and vein, and the anterior pulmonary plexus; behind, the vagus nerve and posterior pulmonary plexus; below, the pulmonary ligament.

The chief structures composing the root of each lung are arranged in a similar manner from before backwards on both sides, viz.: the upper of the two pulmonary veins in front; the pulmonary artery in the middle; and the bronchus behind, with the bronchial vessels on its posterior aspect. Their arrangement differs from above downwards on the two sides; on the right side their position is—eparterial bronchus, pulmonary artery, hyparterial bronchus, pulmonary veins; but on the left side their position is—pulmonary artery, bronchus, pulmonary veins. The lower of the two pulmonary veins is situated below the bronchus, at the apex or lowest part of the hilum (figs. 1047, 1048).

The divisions of the bronchi.—Just as the lungs differ from each other in the number of their lobules, so the bronchi differ in their mode of subdivision.

The *right* bronchus gives off, less than 2·5 cm. from the division of the trachea, a branch for the superior lobe; this branch arises above the level of the pulmonary artery, and is therefore named the *eparterial bronchus*. All the other divisions of the main stem come off below the pulmonary artery, and are consequently termed *hyparterial bronchi*. The first of these is distributed to the middle lobe, and the main tube then passes downwards and backwards into the inferior lobe, giving off in its course a series of large ventral and small dorsal branches. The ventral and dorsal branches arise alternately, and there are usually four of each. The branch to the middle lobe is the first of the ventral series.

The *left* bronchus passes below the level of the pulmonary artery before it divides, and hence all its branches are hyparterial; it may therefore be looked upon as equivalent to that portion of the right bronchus which lies on the distal side of its eparterial branch. The first branch of the left bronchus arises about 5 cm. from the bifurcation of the trachea, and is distributed to the superior lobe. The main stem then enters the inferior lobe, where it divides into ventral and dorsal branches similar to those in the right lung. The branch to the superior lobe of the left lung is the first of the ventral series.

Structure.—The lungs are composed of a serous coat, a subserous areolar tissue, and the pulmonary substance.

The *serous* coat is the pulmonary pleura (p. 1077); it is thin, transparent, and invests the entire organ as far as the root.

The *subserous areolar tissue* contains a large proportion of elastic fibres; it invests the entire surface of the lung, and extends inwards between the lobules.

CC-0. In Public Domain. Gurukul Kangri Collection, Haridwar

Digitized by Arya Samaj Foundation Chennai and eGangotri

The *pulmonary substance* is composed of lobules, which although closely connected interlobular areolar tissue, are quite distinct from one another, and in the fœtus may teased asunder without much difficulty. The lobules vary in size; those on the surface large and of pyramidal form with the bases turned towards the surface; those in interior are smaller, and of various forms. Each lobule is composed of a lobular nchiole and its terminal air-cells, and of the ramifications of the pulmonary and bronchial ssels, lymphatics, and nerves; all of these structures being connected together by olar tissue.

The *intrapulmonary bronchi* divide and subdivide throughout the entire organ, the allest branches constituting the lobular bronchioles. The *larger branches* consist of: an outer coat of fibrous tissue in which are found at intervals irregular plates of hyaline tilage, most developed at the points of division; (2) internal to the fibrous coat, a er of circularly disposed smooth muscular fibres, the *bronchial muscle*; and (3) most ernally, the mucous membrane, lined by columnar ciliated epithelium resting on a ement-membrane. The mucous membrane contains numerous elastic fibres running gitudinally, and a certain amount of lymphoid tissue; it is traversed by the ducts

FIG. 1049.—A section through the lung of a cat, showing the termination of a bronchus. × 50.

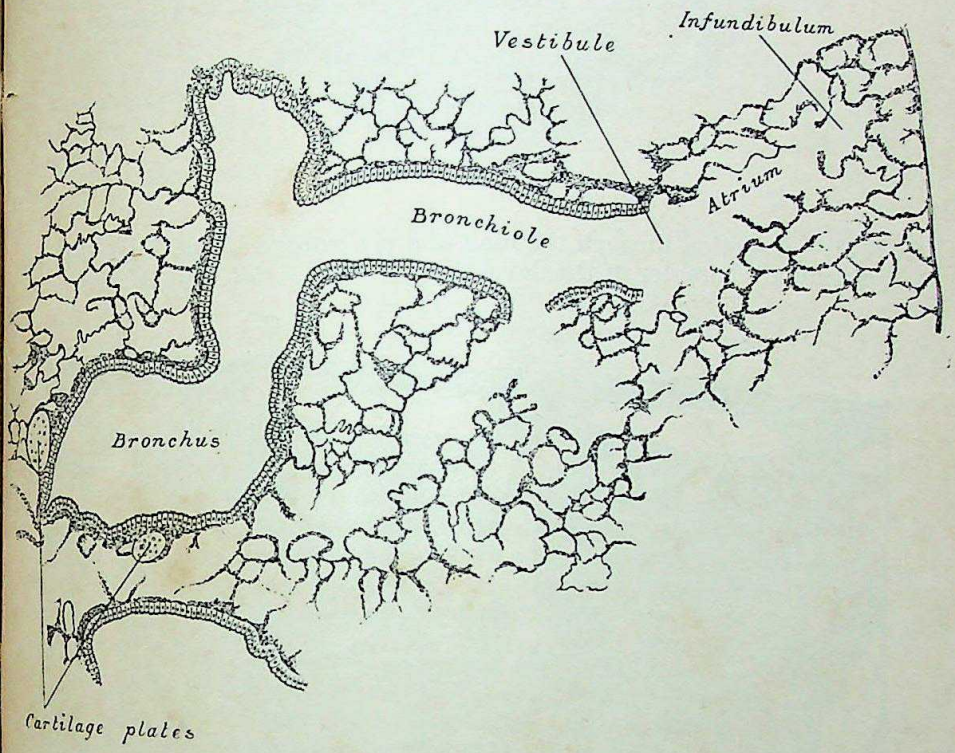

mucous glands, the acini of which lie in the fibrous coat. The *lobular bronchioles* are nt 0·2 mm. in diameter; they differ from the larger tubes in containing no cartilage in the fact that the ciliated epithelial cells are cubical in shape.

Each bronchiole ends by opening into a wider space known as the *vestibule*, the point nction of the two being marked by a circular thickening of the bronchial muscle, and a transition from the ciliated epithelium of the bronchiole to a layer of flattened non-ated cells. The vestibule divides into from three to six passages called *atria*. These lined by flattened non-ciliated epithelium. From each atrium arise two or more *ndibula*, elongated passages, lined by simple squamous epithelium and beset on all s by hemispherical alveoli or air-cells (fig. 1049).

The *alveoli* are lined by a layer of simple squamous epithelium, the cells of which are ed at their edges by cement-substance. Between the squamous cells are here and e smaller, polygonal, nucleated cells. Outside the epithelial lining is a little delicate nective tissue, containing numerous elastic fibres and a close network of blood-illaries, and forming a common wall to adjacent alveoli (fig. 1050).

The fœtal lung resembles a gland in that the alveoli have a small lumen and are lined ubical epithelium (fig. 1051). After the first respiration the alveoli become distended, the epithelium takes on the characters described above.

Vessels and Nerves.—The *pulmonary artery* conveys the venous blood to the lungs; vides into branches which accompany the bronchial tubes and end in a dense capillary work in the walls of the infundibula and alveoli. The arteries of neighbouring lobules independent of one another.

CC-0. In Public Domain. Gurukul Kangri Collection, Haridwar

Digitized by Arya Samaj Foundation Chennai and eGangotri

The *pulmonary capillaries* form plexuses which lie immediately beneath the lining epithelium, in the walls and septa of the alveoli and of the infundibula. In the septa

FIG. 1050.—A section through the lung of a kitten. Silver preparation. ×350.

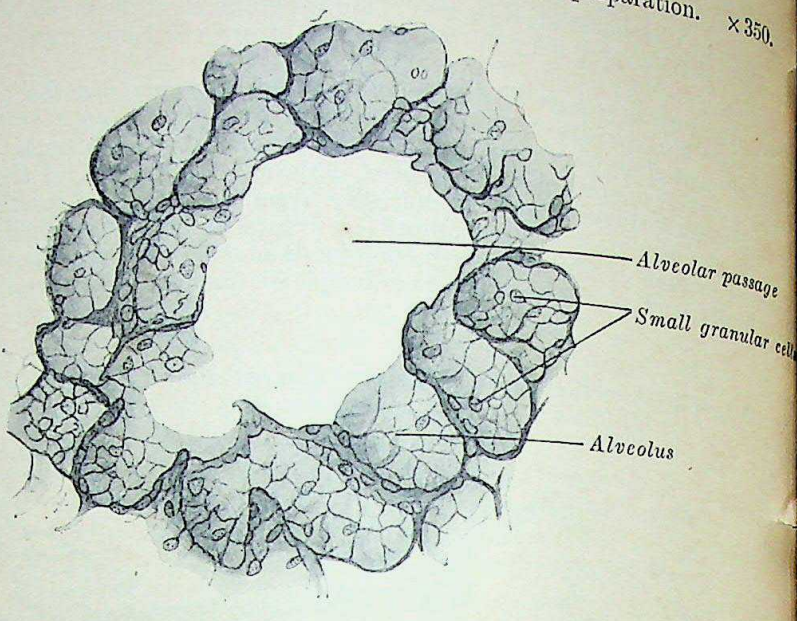

FIG. 1051.—A section through the lung of a pig-embryo 13 cm. long, showing the glandular character of the developing alveoli. ×70. (J. M. Flint.)

a. Interstitial connective tissue. *b.* A bronchial tube. *c.* An alveolus. *l.* Lymphatic clefts. *p.* Pleura.

between the alveoli the capillary network forms a single layer, the meshes of which are smaller than the vessels themselves; their walls are also exceedingly thin.

The *pulmonary veins,* two from each lung, arise from the pulmonary capillaries, the radicles coalescing into larger branches which run through the substance of the lung,

CC-0. In Public Domain. Gurukul Kangri Collection, Haridwar

Digitized by Arya Samaj Foundation Chennai and eGangotri

ndependently of the pulmonary arteries and bronchi. After freely communicating with ther branches they form large vessels, which ultimately come into relation with the rteries and bronchial tubes, and accompany them to the hilum of the lung, the artery sually being above, and the vein below, the bronchus. Finally they open into the left trium of the heart, conveying oxygenated blood to be distributed to all parts of the body y the left ventricle.

The *bronchial arteries* supply blood for the nutrition of the lung; they are derived rom the thoracic aorta or from the upper aortic intercostal arteries, and, accompanying he bronchial tubes, are distributed to the bronchial glands and upon the walls of the rger bronchial tubes and pulmonary vessels. Those supplying the bronchial tubes form, n the muscular coat, a capillary plexus from which branches are given off to form a econd plexus in the mucous coat; this plexus communicates with branches of the ulmonary artery, and empties itself into the pulmonary veins. Others are distributed the interlobular areolar tissue, and end partly in the deep, partly in the superficial, ronchial veins. Lastly, some ramify upon the surface of the lung, beneath the pleura, here they form a capillary network.

The *bronchial veins*, usually two on either side, are formed at the root of the lung, and ceive superficial and deep veins corresponding with branches of the bronchial arteries; ey do not, however, receive all the blood conveyed by the arteries, as some passes into e pulmonary veins. The right bronchial veins end in the azygos vein, the left bronchial ins in the left superior intercostal vein or the accessory hemiazygos vein.

The *lymphatics* of the lungs are described on p. 778.

Nerves.—The lungs are supplied from the anterior and posterior pulmonary plexuses, rmed chiefly by branches from the sympathetic and vagus. The filaments from these exuses accompany the bronchial tubes, supplying efferent fibres to the bronchial muscle d afferent fibres to the bronchial mucous membrane and to the alveoli of the lung. nall ganglia are found upon these nerves.

Applied Anatomy.—The lungs may be wounded or torn in three ways: (1) by com- ession of the chest, without any injury to the ribs; (2) by a fractured rib penetrating e lung; (3) by stabs, gunshot wounds, etc.

The first form, where the lung is ruptured by external compression, without any acture of the ribs, is very rare, and usually occurs in young children, and affects the root the lung, i.e. the most fixed part, and thus, implicating the great vessels, is frequently tal. It would seem *a priori* a most unusual injury, and its exact mode of causation is ficult to interpret.

In the second variety, when the wound in the lung is produced by the penetration of broken rib, both the costal pleura and pulmonary pleura must necessarily be injured, d consequently the air taken into the wounded alveoli may find its way through these unds into the cellular tissue of the parietes of the chest, producing *surgical emphy- ma.* This it may do without collecting in the pleural cavity; the two layers of the eura are so intimately in contact that the air passes straight through from the wounded g into the subcutaneous tissue. Emphysema constitutes therefore the most important n of injury to the lung in cases of fracture of the ribs. Pneumothorax, or air in the eural cavity, is much more likely to occur in injuries of the third variety—that is to say, m external wounds, from stabs, gunshot injuries, and such like—in which case air sses either from the wound of the lung or from the external wound into the cavity of the eura during the respiratory movements. In these cases there is generally no emphy- ma of the subcutaneous tissue unless the external wound is small and valvular, so that e air is drawn into the wound during inspiration, and then forced into the cellular sue during expiration because it cannot escape from the external wound. Occasion- y in wounds of the parietes of the chest no air finds its way into the cavity of the eura, because the lung at the time of the accident protrudes through the wound and cks the opening. This takes place where the wound is large, and constitutes one form *hernia* of the lung. Another form of hernia of the lung occurs, though very rarely, er wounds of the chest-wall, when the wound has healed and the cicatrix subsequently lds from the pressure of the viscus behind. It forms a globular, elastic, crepitating elling, which enlarges during expiratory efforts, falls in during inspiration, and ppears on holding the breath.

An incision into the lung is occasionally required in cases of abscess the result of eumonia or the presence of a foreign body, and from an abscess in the liver which has de its way through the Diaphragm into the lung substance, and also in cases of datid disease. In these cases there is always risk of hæmorrhage, and it has been commended that the lung tissue should be penetrated by the actual cautery rather than h the knife. Unless adhesions have formed between the two layers of the pleura, the ural cavity must necessarily be opened, and there is the further risk of pneumothorax, d possibly of septic infection. It is therefore advisable to suture the lung to the ing in the thoracic wall, and wait for adhesions to form before perforating the lung. The routine methods of physical examination—inspection, palpation, percussion, and ultation—are nowhere more important than they are in the diagnosis of disease of lungs. It is essential, too, that in every case the two sides of the chest should be pared with one another, and that the wide variations that may be met with under

CC-0. In Public Domain. Gurukul Kangri Collection, Haridwar

Digitized by Arya Samaj Foundation Chennai and eGangotri

normal conditions in different persons and at different ages should be kept in mind when the chest is being examined. On *inspection* the thorax will be seen to be enlarged and barrel-shaped in emphysema, in which the volume of the lungs is increased by dilatation of their alveoli, or in an acute attack of asthma, or when a large pleural effusion or mediastinal tumour is present. The chest-wall will be flattened or sunken, on the other hand, over an area of lung that has collapsed or become fibrosed, as often happens in chronic pulmonary tuberculosis. The respiratory movements of the chest-wall will be lessened or even absent, over a part or the whole of the affected side in such acute disorders as pleurisy, pneumonia, or pleural effusion, or in more chronic disease where the underlying lung is fibrosed, or is crushed to one side by a mediastinal tumour; and by the use of the *x*-rays a corresponding loss of movement or displacement of the Diaphragm on the affected side can often be observed. Under normal conditions the intercostal spaces are a little depressed; but when a large effusion or new growth fills up one of the pleural cavities they may be obliterated or even bulging on that side.

On *palpation* the hand can be used to verify the eye's impressions as to the degree of movement, on respiration, of any part of the chest-wall. The facility with which the vibrations produced by the voice are conducted from the larynx by the underlying lung to the hand (in the form of *vocal fremitus*) can also be tested. The vocal fremitus is commonly much increased over the consolidated area in pneumonia or in fibrosis of the lung, and much diminished over a pleural effusion when the lung is pushed up by the fluid towards the top of the pleural cavity. It is also diminished, but to a less extent, in emphysema, and in bronchitis when the bronchi are blocked by secretion. In bronchitis the bubbling of the secretion in the tubes can often be felt by a hand placed on the chest-wall as the patient breathes; and in chronic pleurisy the friction of the two roughened pleural surfaces against one another can sometimes be felt in the same way. It must be remembered that the vocal fremitus in front and behind is normally greater at the right apex than the left. This is because the apex of the right lung lies in close contact with the trachea, while the apex of the left lung is separated from it by the œsophagus and other structures.

On *percussion*, the normal resonance of the pulmonary tissue is found to be increased in emphysema, and in pneumothorax (p. 1080) this hyper-resonance may be still further increased. The resonance is lessened in any condition causing collapse or solidification of the lung-tissue, or when its place is taken by fluid (pleural effusion) or some solid growth (mediastinal tumour). Thus dulness on percussion at the bases of the lungs is common in the hypostatic congestion of the bases seen in heart-failure; dulness at the right base is often due to compression of the lung by enlargement of the liver; some dulness at the apex of a lung is frequently met with in tuberculosis of that part, before the disease has progressed very far. Complete dulness over one side of the chest, back and front alike, except at the apex, is common when a large pleural effusion has taken the lung's place. Von Korányi, Grocco, and others have drawn attention to a triangular patch of dulness along the vertebral column (the paravertebral triangle of dulness) on the unaffected side in pleural effusion; this triangle of dulness is said to be absent in other conditions causing loss of pulmonary resonance on percussion, and is due to shifting over of the contents of the posterior mediastinal cavity towards the sound side. The apex of this triangle is in the middle line at the upper level of the fluid effusion; its base, some 5 cm. to 10 cm. in length, runs horizontally outwards from the middle line at the level where the pulmonary resonance normally comes to an end.

On *auscultation* of the lungs, both in health and disease, the variety of sounds to be heard is very great. It is impossible to give adequate consideration to them here, and for further information reference should be made to the text-books dealing with the subject.

THE DIGESTIVE APPARATUS

The apparatus for the digestion of the food consists of the digestive tube and of certain accessory organs.

The **digestive tube** (alimentary canal), about 9 metres long, extends from the mouth to the anus, and is lined throughout by mucous membrane. It consists of the following parts: at its commencement is the *mouth*, where provision is made for the mechanical division of the food (*mastication*), and for its admixture with a fluid secreted by the salivary glands (*insalivation*); beyond this are the organs of deglutition, the *pharynx* and the *œsophagus*, which convey the food into the *stomach*, where the first stages of the digestive process take place; the stomach is followed by the *small intestine*, which consists of three parts, the *duodenum*, the *jejunum*, and *ileum*. In the small intestine the process of digestion is completed and the resulting products are absorbed into the blood- and lymph-vessels. Finally the small intestine

CC-0. In Public Domain. Gurukul Kangri Collection, Haridwar

Digitized by Arya Samaj Foundation Chennai and eGangotri

ends in the *large intestine*, which is made up of the *cæcum*, the *colon*, the *rectum*, and the *anal canal*, the last ending on the surface of the body at the *anus*.

The **accessory organs** are the *teeth*, for purposes of mastication; the three pairs of *salivary glands*—the *parotid*, *submaxillary* and *sublingual*—the secretion from which mixes with the food in the mouth and acts chemically on one of its constituents; the *liver* and the *pancreas*, two large glands in the abdomen, the secretions of which, in addition to that of numerous minute glands in the walls of the alimentary canal, take part in the process of digestion.

The Mouth Cavity (Cavum oris)

The **cavity of the mouth** is placed at the commencement of the digestive tube (fig. 1052); it consists of an outer, smaller portion, the vestibule, and an inner, larger part, the mouth cavity proper.

Fig. 1052.—A sagittal section through the nose, mouth, pharynx, and larynx.

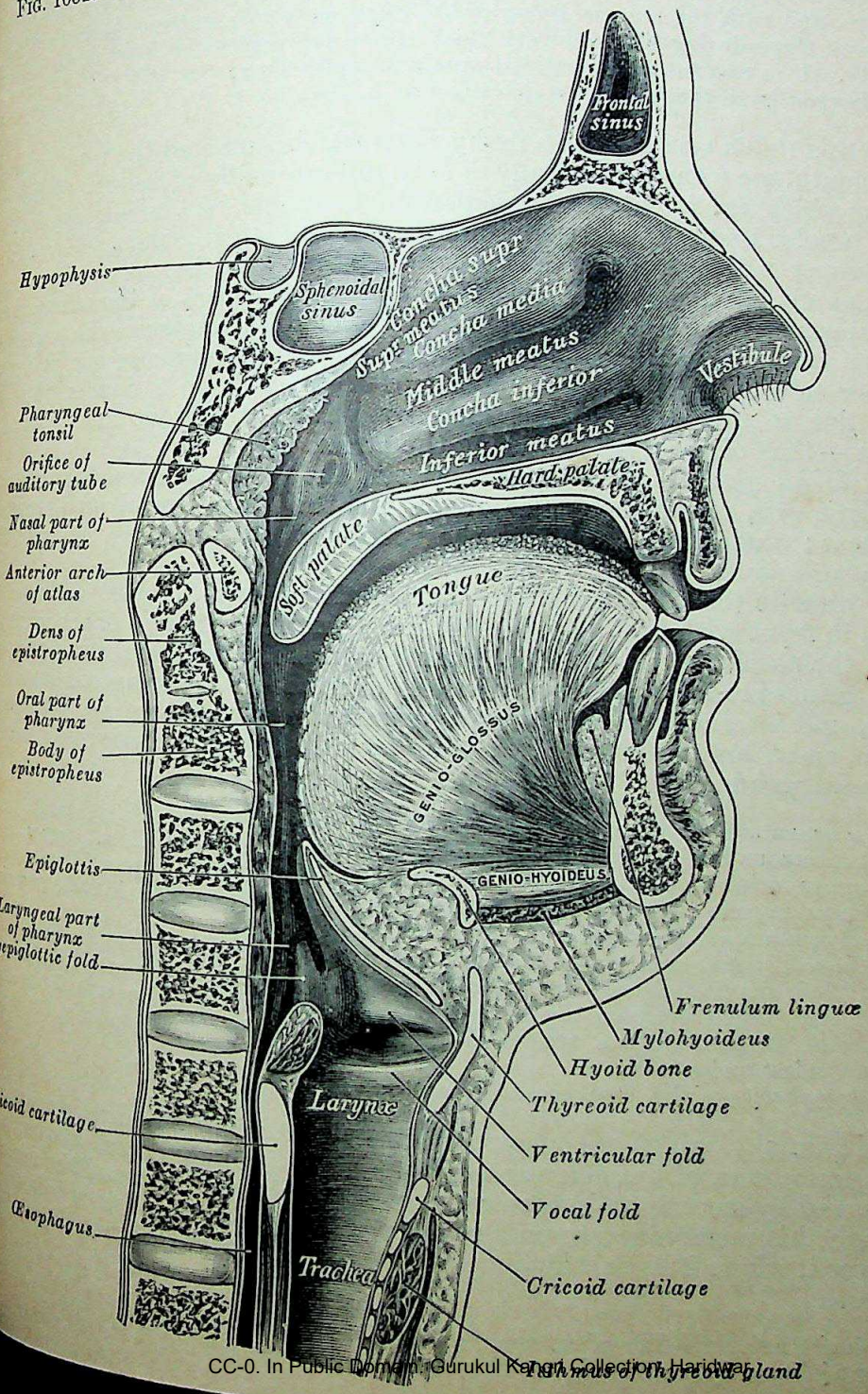

CC-0. In Public Domain. Gurukul Kangri Collection, Haridwar

Digitized by Arya Samaj Foundation Chennai and eGangotri

The *vestibule of the mouth* is a slit-like space, bounded externally by the lips and cheeks; internally by the gums and teeth. It communicates with the surface of the body by the *orifice of the mouth* (rima oris). Above and below, it is limited by the reflection of the mucous membrane from the lips and cheeks to the gums covering the upper and lower alveolar arches. The ducts of the parotid salivary glands open into it, and it communicates, when the jaws are closed, with the mouth cavity proper by an aperture on either side behind the wisdom teeth, and by narrow clefts between opposing teeth.

The *mouth cavity proper* (fig. 1074) is bounded laterally and in front by the alveolar arches with their contained teeth; behind, it communicates with the pharynx by a constricted aperture termed the *isthmus faucium*. Its roof consists of the hard palate and soft palate, while the greater part of the floor is formed by the tongue, the remainder by the reflection of the mucous membrane from the sides and under surface of the tongue to the gum on the inner surface of the mandible. The ducts of the submaxillary and sublingual salivary glands open into it.

The *mucous membrane* lining the mouth is continuous with the skin at the free margins of the lips, and with the mucous lining of the pharynx at the isthmus faucium; it is of a rose pink tinge during life, and very thick where it overlies the hard parts bounding the cavity. It is covered with stratified squamous epithelium.

The *lymphatics* of the mouth are described on p. 755.

The **lips** (labia oris), the two fleshy folds which surround the rima or orifice of the mouth, are formed externally of skin and internally of mucous membrane, between which are found the Orbicularis oris muscle, the labial vessels, some nerves, areolar tissue, and fat, and numerous small labial glands. The junction of the upper with the lower lip forms, on either side, the *labial commissure*, which bounds the *angle of the mouth*. On the middle part of the outer surface of the upper lip is a shallow vertical groove named the *philtrum* which descends from the columna nasi; it ends below in a slight prominence and is limited on either side by a ridge. The inner surface of each lip is connected in the middle line to the corresponding gum by a fold of mucous membrane, the *frenulum*—that of the upper lip being the larger.

The *labial glands* are situated between the mucous membrane and the Orbicularis oris, round the orifice of the mouth. They are about the size of small peas; their ducts open into the vestibule. In structure they resemble the salivary glands.

The **cheeks** (buccæ) form a large part of the sides of the face, and are continuous in front with the lips, the junction being indicated on either side by a groove, the *nasolabial sulcus*, which runs downwards and lateralwards from the side of the nose to the angle of the mouth. The cheeks are composed externally of skin, and internally of mucous membrane; between these are a muscular stratum, and a large quantity of fat, together with areolar tissue, vessels, nerves, and buccal glands.

The *mucous membrane* lining the cheek is reflected above and below upon the gums, and is continuous behind with the lining membrane of the soft palate. Opposite the second upper molar tooth is a papilla, on the summit of which the parotid duct opens. The principal muscle of the cheek is the Buccinator; but others enter into its formation, viz. the Zygomaticus, Risorius, and Platysma.

The *buccal glands* are placed between the mucous membrane and the Buccinator muscle; their structure is similar to that of the labial glands. Four or five, larger than the rest, and placed between the Masseter and Buccinator muscles around the distal extremity of the parotid duct, are called *molar glands*; their ducts open in the mouth opposite the last molar tooth.

The *lymphatics* of the cheeks and lips are described on p. 755.

The **gums** (gingivæ) are composed of dense fibrous tissue, closely connected to the periosteum of the alveolar processes of the mandible and maxillæ, and are covered by smooth and vascular mucous membrane. Around the necks of the teeth this membrane presents numerous fine papillæ, and is reflected into the alveoli, where it is continuous with the periosteal membrane lining these cavities.

Applied Anatomy.—The gums are occasionally the seat of considerable hypertrophy, forming a lobulated vascular fold growing up in front of and behind the teeth, so as almost

CC-0. In Public Domain. Gurukul Kangri Collection, Haridwar

Digitized by Arya Samaj Foundation Chennai and eGangotri

to bury them. They may also become swollen and congested, bleeding freely, and often becoming ulcerated. The condition is known as *spongy gums*, and may occur in scurvy, in stomatitis and dyspepsia, in ill-fed tuberculous children, and from the administration of mercury; the gums are very tender, mastication is painful, and there is often considerable fœtor. The dental margin of the gum presents a finely stippled blue or blue-black line in cases of *lead poisoning*, due to the local deposit of black lead sulphide. In cases of *bismuth poisoning*, such as may occur after the too generous use of insoluble bismuth salts in the surgical treatment of gunshot wounds, a very similar but more diffuse blue line due to the local deposit of black sulphide of bismuth may appear, together with patches of minute black dots about other parts of the mucous membrane of the mouth. The collection of tartar, which consists of the secretion from the gums mixed with fragments of food and salivary salts, may give rise to a condition known as *pyorrhœa alveolaris*, which is an inflammatory condition of the gums, followed by the gradual absorption of the alveolus and the falling out of the teeth. Fibrous tumours (epulis), myeloid growths, and epitheliomata are met with in the gums.

The palate forms the roof of the mouth: it consists of two portions, the hard palate in front, the soft palate behind.

The **hard palate** (palatum durum) (fig. 1060) is formed by the palatine processes of the maxillæ and the horizontal parts of the palatine bones; it is bounded in front and at the sides by the alveolar arches and gums; behind, it is continuous with the soft palate. It is covered by a dense tissue, formed by the periosteum and mucous membrane, which are intimately connected. Along the middle line is a linear raphe which ends anteriorly in a small papilla underlying the incisive canal. On either side and in front of the raphe the mucous membrane is thick, pale in colour, and corrugated; behind, it is thin, smooth, and of a redder colour: it is covered with stratified squamous epithelium, and furnished with numerous palatine glands which lie between the mucous membrane and the periosteum.

The **soft palate** (palatum molle) (fig. 1074) is a movable fold, suspended from the posterior border of the hard palate, and forming an incomplete septum between the mouth and pharynx. It consists of a fold of mucous membrane enclosing an aponeurosis, muscular fibres, vessels, nerves, adenoid tissue, and mucous glands. When occupying its usual position (i.e. relaxed and pendent) its anterior surface is concave, and marked by a median raphe. Its posterior surface is convex, and continuous with the floor of the nasal cavities. Its superior border is attached to the posterior margin of the hard palate, and its sides are blended with the pharynx. Its inferior border is free. The lower portion of the soft palate hangs like a curtain between the mouth and the pharynx, and is termed the *palatine velum*.

Hanging from the middle of its lower border is a small, conical process, the *palatine uvula*; and arching lateralwards and downwards from the base of the uvula on either side are two curved folds of mucous membrane, containing muscular fibres, called the *arches* or *pillars of the fauces* (p. 1118).

The *mucous membrane of the soft palate* is thin, and covered with stratified squamous epithelium, excepting near the pharyngeal ostium of the auditory tube, where it is columnar and ciliated. Beneath the mucous membrane on the oral surface of the soft palate is a considerable amount of adenoid tissue. The palatine glands form a continuous layer on its posterior surface and round the uvula.

Vessels and Nerves.—The *arteries* supplying the palate are the ascending palatine branch of the external maxillary artery, the descending palatine branch of the internal maxillary artery, and the palatine branch of the ascending pharyngeal artery. The *veins* end chiefly in the pterygoid and tonsillar plexuses. The *lymphatic vessels* pass to the deep cervical lymph-glands. The *sensory nerves* are derived from the palatine, nasopalatine and glossopharyngeal nerves.

Applied Anatomy.—The occurrence of a congenital cleft in the palate has been already referred to as a defect in development (p. 82). After the operation for the closure of a cleft in the palate, the palatine muscles, especially the Tensor and Levator veli palatini, give a tendency to retard the healing process by active traction upon the line of suture. To obviate this, it is necessary to divide them. This is best done by making longitudinal incisions, on either side, parallel to the cleft and just medial to the pterygoid hamulus, in such a position as to avoid the descending palatine artery. Acquired perforations of the palate are almost invariably the result of the breaking down of syphilitic gummata. The ensuing ulceration may continue until practically the whole palate, both hard and soft, has been destroyed. Tumours of the palate, both innocent and malignant, are occasionally seen.

CC-0. In Public Domain. Gurukul Kangri Collection, Haridwar

Digitized by Arya Samaj Foundation Chennai and eGangotri

Paralysis of the soft palate often occurs after diphtheria. It gives rise to a change in the voice, which becomes nasal, and to the regurgitation of fluids down the nose when their swallowing is attempted. On inspection, the palate is seen to hang flaccid and motionless when phonation or deglutition is attempted; it is also anæsthetic.

The Salivary Glands (fig. 1055)

Three pairs of salivary glands pour their secretion into the mouth: they are named the parotid, the submaxillary, and the sublingual glands.

The **parotid gland** (figs. 1053, 1054), the largest of the three, has an average weight of about 25 gm. It lies upon the side of the face, immediately below and in front of the external ear. The main portion of the gland is superficial, somewhat flattened and quadrilateral in form, and is placed between

Fig. 1053.—The right parotid gland. Posterior aspect.

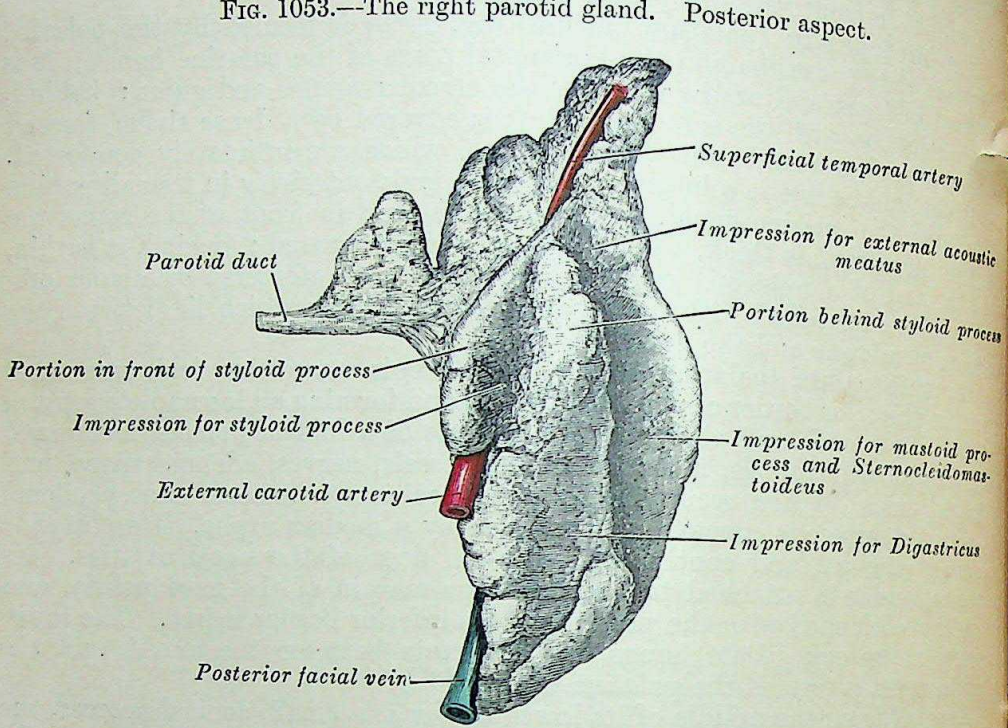

the ramus of the mandible in front and the mastoid process and Sternocleidomastoideus behind, overlapping, however, both boundaries. Above, it is broad and reaches nearly to the zygomatic arch; below, it tapers somewhat to about the level of a line joining the tip of the mastoid process to the angle of the mandible. The remainder of the gland (retromandibular process) is irregularly wedge-shaped and extends deeply inwards towards the pharyngeal wall.

The gland is enclosed within a capsule continuous with the fascia colli (deep cervical fascia); the part covering the superficial surface of the gland is dense, closely adherent to the gland, and attached to the zygomatic arch; a portion of the fascia, attached to the styloid process and the angle of the mandible, is thickened to form the stylomandibular ligament, which intervenes between the parotid and submaxillary glands.

The *anterior surface* of the gland is grooved, being moulded on the posterior bordèr of the ramus of the mandible, and on the posterior borders of the Pterygoideus internus and Masseter. The inner lip of the groove extends forwards for a short distance on the deep surface of the Pterygoideus internus; the outer lip extends for some distance over the superficial surface of the Masseter, and a small portion of it immediately below the zygomatic arch is usually more or less detached, and is named the *accessory part* of the gland.

The *posterior surface* is grooved longitudinally and abuts against the external acoustic meatus, the mastoid process, and the anterior border of the Sternocleidomastoideus

CC-0. In Public Domain. Gurukul Kangri Collection, Haridwar

Digitized by Arya Samaj Foundation Chennai and eGangotri

The *superficial surface*, slightly lobulated, is covered by the skin, the superficial fascia containing the facial branches of the great auricular nerve and some small lymph-glands, and by the fascia which forms the capsule of the gland.

The *deep surface* extends inwards by means of two processes, one of which lies on the Digastricus, styloid process, and the styloid group of muscles, and projects under the mastoid process and Sternocleidomastoideus; the other is situated in front of the styloid process, and sometimes passes into the posterior part of the mandibular fossa behind the mandibular joint. The deep surface is in contact with the internal carotid artery and the internal jugular vein.

Structures within the gland.—The external carotid artery lies at first on the deep surface, and then in the substance of the gland. The artery gives off its posterior auricular branch, which emerges from the gland behind; the artery then divides into the internal maxillary and superficial temporal arteries;

Fig. 1054.—The right parotid gland. Medial aspect.

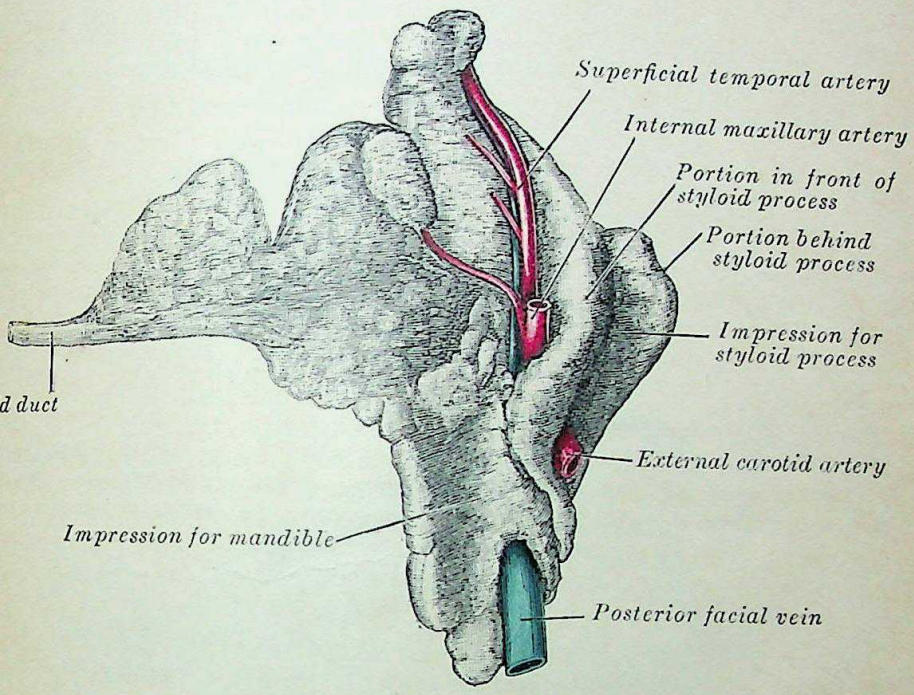

the former runs forwards deep to the neck of the mandible; the latter runs upwards across the zygomatic arch and gives off its transverse facial branch, which emerges from the front of the gland. Superficial to the arteries are the superficial temporal and internal maxillary veins, uniting to form the posterior facial vein; in the lower part of the gland this vein splits into an anterior and a posterior division. The anterior division emerges from the gland and unites with the anterior facial vein to form the common facial vein; the posterior unites in the gland with the posterior auricular vein to form the external jugular vein. On a still more superficial plane is the facial nerve, the branches of which emerge from the borders of the gland. Branches of the great auricular nerve pierce the gland to join the facial nerve, and the cutaneous part of the auriculotemporal nerve issues from the upper part of the gland.

The **parotid duct** (Stensen's duct) (fig. 1055) is about 5 cm. long. It begins by numerous branches from the anterior part of the gland, crosses the Masseter, and at the anterior border of this muscle turns inwards nearly at a right angle, passes through the corpus adiposum of the cheek and pierces the Buccinator; it then runs for a short distance obliquely forwards between the Buccinator and mucous membrane of the mouth, and opens upon a small papilla on the oral surface of the cheek opposite the second upper molar tooth. While crossing the Masseter it receives the duct of the accessory portion; in this position it lies between the branches of the facial nerve; the accessory part of the gland and the transverse facial artery are above it.

CC-0. In Public Domain. Gurukul Kangri Collection, Haridwar

Digitized by Arya Samaj Foundation Chennai and eGangotri

Structure.—The wall of the parotid duct is of considerable thickness, and consists of a thick external fibrous coat which contains unstriped muscular fibres, and an internal mucous coat which is lined with short columnar epithelium. Its canal is about the size of a crow-quill, but at its orifice on the oral surface of the cheek its lumen is greatly reduced in size.

Vessels and Nerves.—The *arteries* supplying the parotid gland are derived from the external carotid artery, and from the branches given off by that vessel in or near the gland. The *veins* empty themselves into the external jugular vein, through some of its tributaries. The *lymphatics* end in the superficial and deep cervical lymph-glands, passing in their course through two or three lymph-glands, on the surface and in the substance of the parotid gland. The *nerves* are derived from the facial, auriculotemporal and great auricular nerves and from the plexus of the sympathetic on the external carotid artery. It is probable that the branch from the auriculotemporal nerve is derived from the glossopharyngeal nerve through the otic ganglion; at all events, in some of the lower animals this has been proved experimentally to be so.

The **submaxillary gland** (fig. 1055) is irregular in form and about the size of a walnut. It consists of a larger, superficial part and a smaller deep part, which are continuous with one another around the posterior border of the Mylohyoideus.

Fig. 1055.—A dissection showing the salivary glands of the right side.

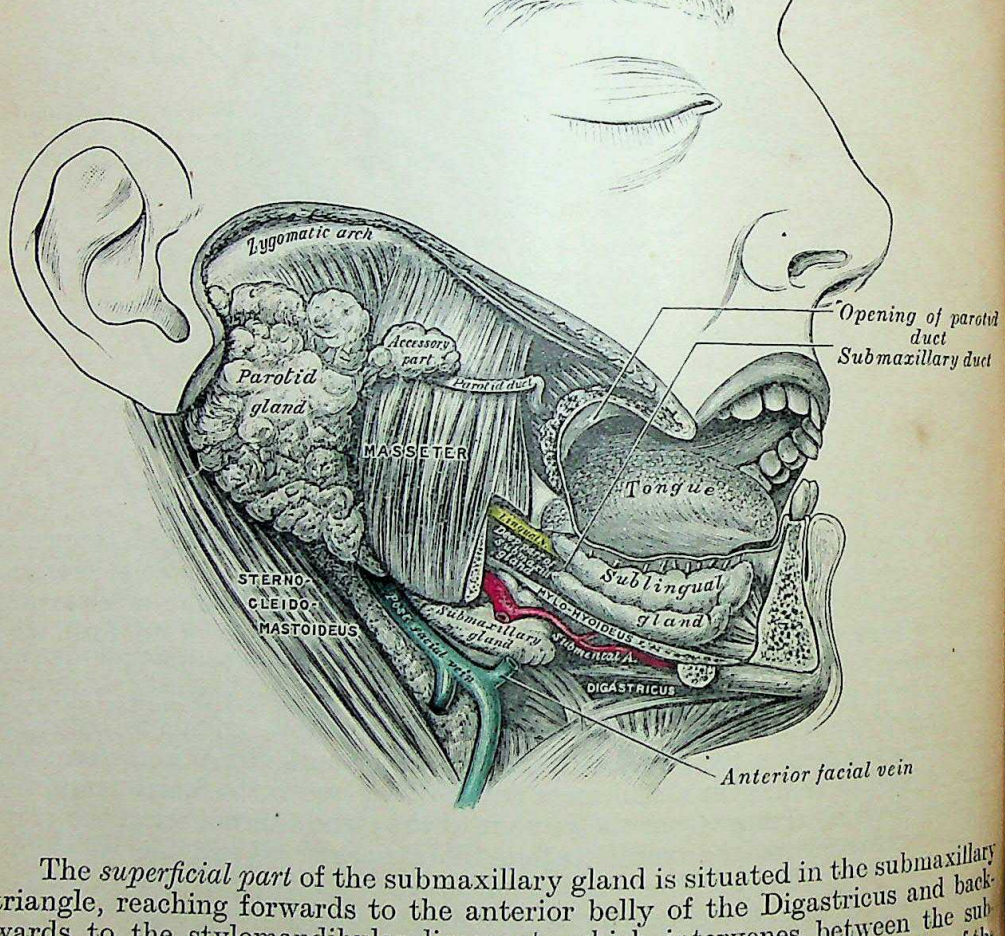

The *superficial part* of the submaxillary gland is situated in the submaxillary triangle, reaching forwards to the anterior belly of the Digastricus and backwards to the stylomandibular ligament, which intervenes between the submaxillary and parotid glands. Above, it extends under cover of the body of the mandible; below, it usually overlaps the intermediate tendon of the Digastricus and the insertion of the Stylohyoideus. It has three surfaces, an inferior, a lateral, and a medial.

The *inferior surface* is covered by the skin, Platysma, and deep cervical fascia. It is crossed by the anterior facial vein, and by some filaments of the facial nerve; in contact with it near the mandible are the submaxillary lymph-glands.

CC-0. In Public Domain. Gurukul Kangri Collection, Haridwar

Digitized by Arya Samaj Foundation Chennai and eGangotri

The *lateral surface* is in relation with the submaxillary depression on the inner surface of the body of the mandible, and with the lower part of the inner surface the Pterygoideus internus.

The *medial surface* is in relation with the Mylohyoideus, Hyoglossus, Styloglossus, Stylohyoideus, and posterior belly of the Digastricus; between it and the Mylohyoideus are the mylohyoid nerve and vessels.

The external maxillary artery is embedded in a groove in the posterior border of the gland.

The *deep part* of the submaxillary gland extends forwards as far as the posterior end of the sublingual gland, and lies between the Mylohyoideus below and externally and the Hyoglossus and Styloglossus internally; above it are the lingual nerve and submaxillary ganglion; below it, the hypoglossal nerve and its vena comitans.

The **submaxillary duct** (Wharton's duct) is about 5 cm. long, and its wall is much thinner than that of the parotid duct. It begins by numerous branches in the superficial part of the gland, and runs with the deep part of the gland forwards between the Mylohyoideus and the Hyoglossus; it then passes between the sublingual gland and the Genioglossus, and opens by a narrow orifice on the summit of a small papilla, at the side of the frenulum linguæ (fig. 1073). On the Hyoglossus it lies between the lingual and hypoglossal nerves, but at the anterior border of the muscle it is crossed laterally by the lingual nerve; the terminal branches of the lingual nerve ascend on its medial side.

Vessels and Nerves.—The *arteries* supplying the submaxillary gland are branches of the external maxillary and lingual arteries. Its *veins* follow the course of the arteries. The *nerves* are derived from the submaxillary ganglion, through which it receives filaments from the chorda tympani of the facial nerve, the lingual branch of the mandibular nerve and the sympathetic.

In the dog and cat the submaxillary gland receives its nerve-supply through Langley's ganglion (p. 1100).

The **sublingual gland** (fig. 1055) is the smallest of the three salivary glands. It is situated beneath the mucous membrane of the floor of the mouth, at the side of the frenulum linguæ, in contact with the sublingual depression on the inner surface of the mandible, close to the symphysis. It is narrow, flattened, shaped somewhat like an almond, and weighs between 3 and 4 gms. It is in relation, *above*, with the mucous membrane of the mouth which it raises in the form of a crest, named the *plica sublingualis*; *below*, with the Mylohyoideus; *in front*, with its fellow of the opposite side; *behind*, with the deep part of the submaxillary gland; *laterally*, with the mandible; and *medially*, with the Genioglossus, from which it is separated by the lingual nerve and the submaxillary duct. Its excretory ducts are from eight to twenty in number. Of the *smaller sublingual ducts* (ducts of Rivinus), some join the submaxillary duct; others open separately into the mouth, on the plica sublingualis. One or more join to form the *larger sublingual duct* (duct of Bartholin), which opens with or near to the submaxillary duct.

FIG. 1056.—A section through the submaxillary gland of a kitten. Duct semidiagrammatic. × 200.

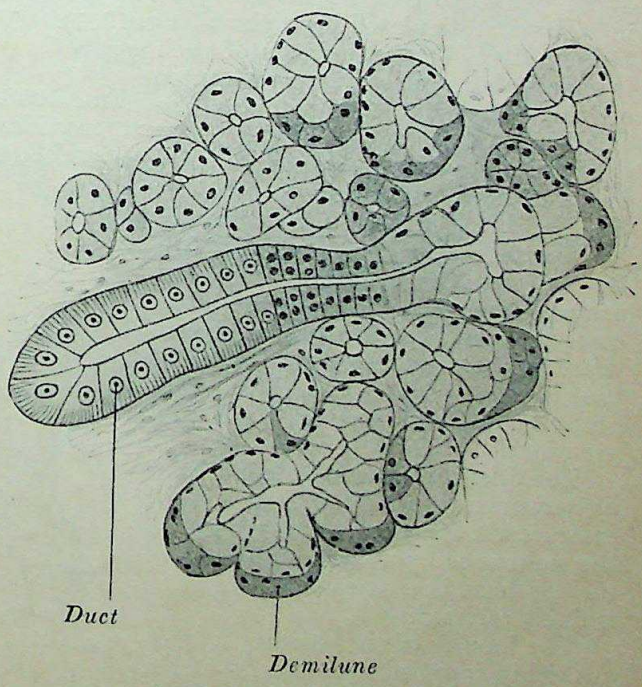

CC-0. In Public Domain. Gurukul Kangri Collection, Haridwar

Digitized by Arya Samaj Foundation Chennai and eGangotri

Vessels and Nerves.—The sublingual gland is supplied with blood by the sublingual and submental arteries. Its nerves are derived from the lingual and chorda tympani nerves, and from the sympathetic.

In the dog and cat the sublingual gland receives its nerve-supply through the submaxillary ganglion.

FIG. 1057.—A section through the parotid gland of a cat. × 200.

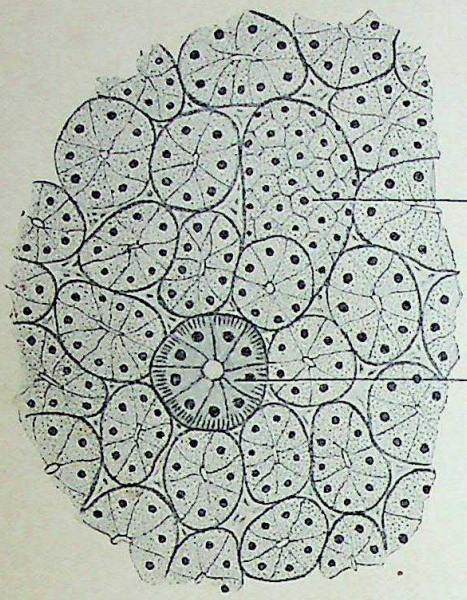

Structure of the salivary glands.—The salivary glands are compound racemose glands, consisting of numerous lobes, which are made up of lobules, connected together by dense areolar tissue, vessels and ducts. Each lobule consists of the ramification of a single duct, the branches ending in dilated ends or alveoli on which the capillaries are distributed. The alveoli are enclosed by a basement-membrane, which is continuous with the membrana propria of the duct and consists of a network of branched and flattened nucleated cells.

The alveoli of the salivary glands are of two kinds, serous and mucous, which differ in the nature of their secretion and in the appearance of their cells. (1) The mucous alveoli secrete a viscid fluid, which contains mucin; (2) the serous secrete a thinner and more watery fluid. The sublingual gland consists of mucous, and the parotid gland of serous, alveoli. The submaxillary gland contains both mucous and serous alveoli (fig. 1058).

The cells in the *mucous alveoli* are columnar in shape (fig. 1056), and in the fresh condition contain large granules of mucinogen. In hardened preparations a delicate protoplasmic network is seen, and the cells are clear and transparent. The nucleus is usually situated near the basement-membrane, and is flattened.

In some alveoli peculiar crescentic bodies are seen between the cells and the basement-membrane. They are termed the *crescents of Gianuzzi*, or the *demilunes of Heidenhain* (fig. 1056), and are composed of polyhedral granular cells. Fine canaliculi pass between the mucus-secreting cells to reach the demilunes and penetrate their cells.

In the *serous alveoli* the cells almost completely fill the cavity in the resting condition of the gland, so that the lumen is barely perceptible; they contain granules imbedded in a closely reticulated protoplasm (fig. 1057). The cells are more cubical than those of mucous alveoli; the nucleus of each is spherical and placed near the centre of the cell, and the granules are smaller.

FIG. 1058.—A section through a human submaxillary gland. Stained with hæmatoxylin and eosin. × 300.

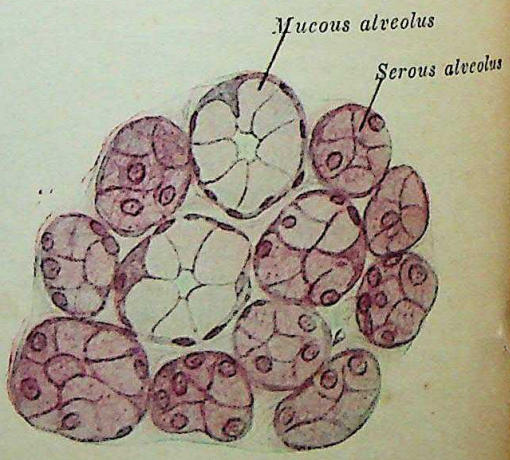

Both mucous and serous cells vary in appearance according to whether the gland is in a resting condition or has been recently active. In the former case the cells are large and contain many granules; in the latter case the cells are shrunken and contain few granules, chiefly collected at the inner ends of the cells. The granules are best seen in fresh preparations.

The ducts are lined at their origins by pavement epithelium, but as they enlarge, the epithelial cells change to the columnar type, and the part of the cell next the basement-membrane is finely striated.

The lobules of the salivary glands are richly supplied with blood-vessels, which form a dense network in the inter-alveolar spaces. Fine plexuses of nerves are also found in the interlobular tissue. The nerve-fibrils pierce the basement-membrane of the alveoli, and end in branched varicose filaments between the secreting cells. In the hilum of the submaxillary gland there is in some animals a collection of nerve cells termed *Langley's ganglion*.

CC-0. In Public Domain. Gurukul Kangri Collection, Haridwar

Digitized by Arya Samaj Foundation Chennai and eGangotri

Accessory glands.—Besides the salivary glands proper, numerous other glands are found in the mouth. Some of these occur in the tongue (p. 1117); others lie around and in the palatine tonsil between its crypts, and large numbers are present in the soft palate, the lips and cheeks. These glands are of the same structure as the larger salivary glands, and are of the mucous or mixed type.

Applied Anatomy.—The parotid glands, and much less often the other salivary glands, are liable to an acute infectious inflammation, known in the case of the parotid as *mumps*. The affected glands swell up, becoming tense, tender, and painful; much pain is felt when swallowing or mastication is attempted, and salivation may or may not occur. The inflammation goes down after a few days; suppuration in the affected glands is very rare.

The Teeth (Dentes) (figs. 1059 to 1062)

Man is provided with two sets of teeth, which make their appearance at different periods of life. Those of the first set are temporary and appear during the first and second years; they are called the *deciduous* or *milk* teeth. Those of the second set begin to replace the deciduous set about the sixth year; they are all established by the twenty-fifth year, and, since they may continue until old age, are named the *permanent* teeth.

Fig. 1059.—The teeth and jaws. Right lateral aspect.

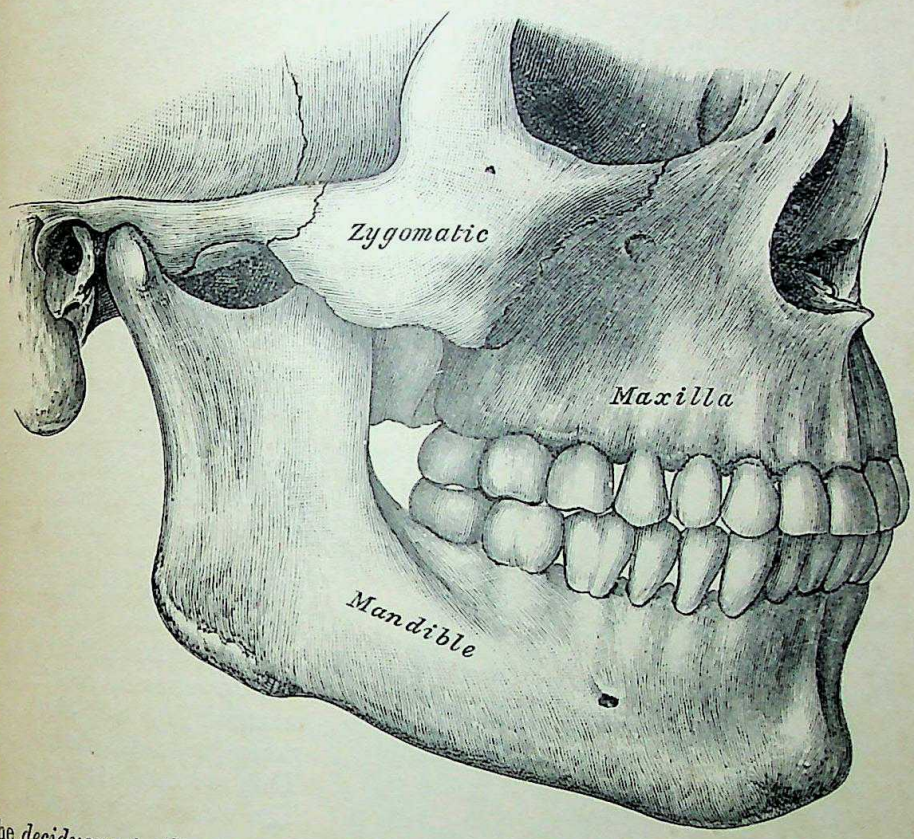

The *deciduous teeth* are twenty in number: four incisors, two canines, and four molars in each jaw.

The *permanent teeth* are thirty-two in number: four incisors, two canines, four premolars, and six molars in each jaw.

The dental formulæ may be represented as follows:

Deciduous Teeth.

	mol.	can.	in.	in.	can.	mol.	
Upper jaw . . .	2	1	2	2	1	2	Total 20
Lower jaw . . .	2	1	2	2	1	2	

Permanent Teeth.

	mol.	premol.	can.	in.	in.	can.	premol.	mol.	
Upper jaw .	3	2	1	2	2	1	2	3	Total 32
Lower jaw .	3	2	1	2	2	1	2	3	

CC-0. In Public Domain. Gurukul Kangri Collection, Haridwar

Digitized by Arya Samaj Foundation Chennai and eGangotri

General characteristics.—Each tooth consists of three portions: the *crown*, projecting beyond the gum; the *root*, imbedded in the alveolus; and the *neck*, the constricted portion between the crown and the root.

The roots of the teeth are firmly implanted in the alveoli of the maxillæ and mandible. Each alveolus is lined by periosteum which invests the tooth as far as its neck, and is continuous above with the fibrous tissue of the gums.

In consequence of the curve of the dental arch, terms such as anterior and posterior, if applied to the teeth, would be misleading and confusing. Special terms are therefore used to indicate the different surfaces of a tooth: the surface directed towards the lips or cheek is known as the *labial* or *buccal* surface; that directed towards the tongue is described as the *lingual* surface; those surfaces which touch neighbouring teeth are termed *surfaces of contact*. In the case of the incisor and canine teeth the surfaces of contact are medial and lateral; in the premolar and molar teeth they are anterior and posterior.

The superior dental arch is larger than the inferior, so that in the normal condition the teeth of the maxillæ slightly overlap those of the mandible both in front and at the sides. The upper central incisors are wider than the lower, and the teeth of the upper and lower sets do not quite correspond to each other when the mouth is closed. Thus the upper canine tooth rests partly on the lower canine and partly on the first premolar, and the cusps of the upper molar teeth lie behind the corresponding cusps of the lower molar teeth. The dental arches, however, end at nearly the same points behind because the upper molars, especially the third, are smaller than the lower.

The Permanent Teeth (figs. 1059 to 1062)

The incisor teeth are so named because they present sharp cutting edges, adapted for biting the food. They are eight in number, and form the four front teeth in each dental arch.

Fig. 1060.—The permanent teeth of the upper dental arch. Inferior aspect.

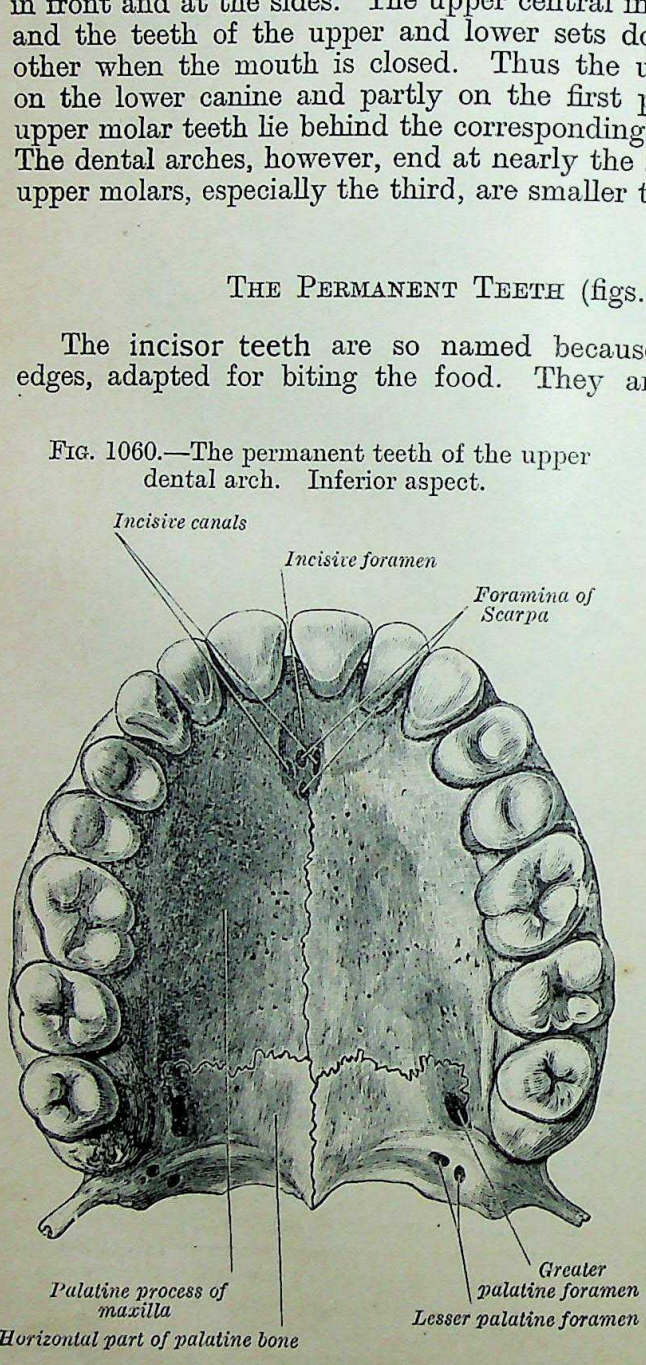

The *crown* of each is directed vertically, and is chisel-shaped, being bevelled so as to present a sharp horizontal cutting edge, which, before being subjected to attrition, presents three small prominent points separated by two notches. It is convex on its labial surface; concave on its lingual surface, where, in the teeth of the upper arch, it is frequently marked by a V-shaped eminence, situated near the gum. This is known as the *cingulum*. The *neck* is constricted. The *root* is long, single, conical, transversely flattened, thicker in front than behind, and slightly grooved on either side in the direction of its length.

The *upper incisors* are larger and stronger than the lower, and are directed obliquely downwards and forwards. They overlap the lower incisors and their free edges are consequently bevelled at the expense of their lingual surfaces. Their roots are conical and nearly cylindrical. The central upper incisors are larger than the lateral.

CC-0. In Public Domain. Gurukul Kangri Collection, Haridwar

Digitized by Arya Samaj Foundation Chennai and eGangotri

The *lower incisors* are smaller than the upper. They are placed vertically and are somewhat bevelled in front, where they have been worn down by contact with the overlapping edges of the upper teeth. Their roots are flattened at the sides. The central lower incisors are smaller than the lateral, and are the least of all the incisors.

The **canine teeth** (cuspids) are four in number, two in the upper, and two in the lower arch, one being placed lateral to each lateral incisor. They are larger and stronger than the incisors, and their roots sink deeply into the bones and cause well-marked prominences upon their surfaces.

The *crown* of each is large and conical, very convex on its labial surface, a little hollowed and uneven on its lingual surface, and tapering to a blunted point or cusp, which projects beyond the level of the other teeth. The *root* is single, but longer and thicker than that of the incisors; it is conical in form, and marked by a slight groove on either side.

The *upper canine teeth* (popularly called *eye-teeth*) are larger and longer than the lower, and usually present a distinct cingulum.

The *lower canine teeth* are placed nearer the middle line than the upper so that their summits correspond to the intervals between the upper canines and lateral incisors. The roots of the lower canines are occasionally double.

The **bicuspid teeth** or **premolars** are eight in number, four in each arch. They are situated lateral to and behind the canine teeth, and are smaller and shorter than these.

Fig. 1061.—The permanent teeth of the right half of the lower dental arch. Superior aspect.

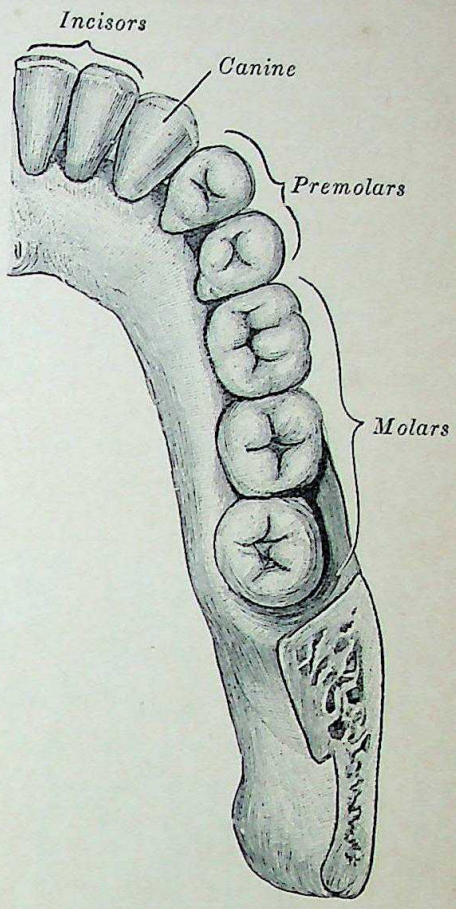

The *crown* of each is compressed from before backwards, and surmounted by two pyramidal eminences or cusps, a labial and a lingual, separated by a groove. Of the two cusps the labial is the larger and more prominent. The

Fig. 1062.—The permanent teeth of the right side. (Burchard.)

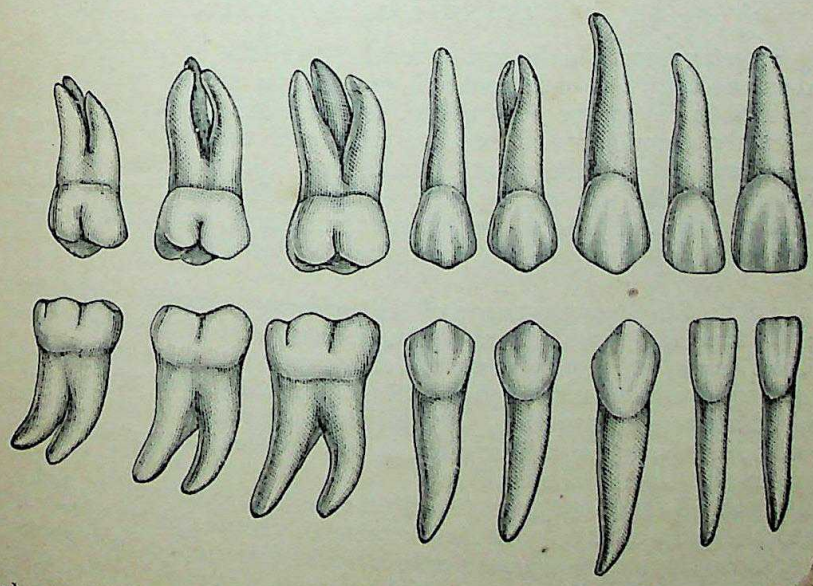

neck is oval. The *root* is generally single, but presents in front and behind a deep groove, which indicates a tendency in the root to become double.

CC-0. In Public Domain. Gurukul Kangri Collection, Haridwar

Digitized by Arya Samaj Foundation Chennai and eGangotri

The *upper premolars* are larger, and show a greater tendency to the division of their roots than the lower; this is especially the case in the first upper premolar. The roots of the *lower premolars* are nearly cylindrical.

The **molar teeth** are the largest of the permanent set, and their broad crowns are adapted for grinding the food. They are twelve in number, six in each arch, three being placed behind each second premolar.

The *crown* of each is nearly cubical in form, convex on its buccal and lingual surfaces, flattened on its surfaces of contact; it is surmounted by four or five cusps or tubercles, separated from each other by a crucial depression; hence the molars are sometimes termed *multicuspids*. The *neck* is distinct, large, and rounded.

The *upper molars*.—As a rule the first of the upper molars is the largest, and the third the smallest. The crown of the first has usually four cusps; that of the second, three or four; that of the third, three. Each upper molar has three roots, two of which are buccal, and nearly parallel to one another; the third is lingual and diverges from the others as it ascends. The roots of the third molar (dens serotinus or wisdom-tooth) are more or less fused together.

The *lower molars*.—The lower molars are larger than the upper. On the crown of the first there are usually five cusps; on the crowns of the second and third, four or five. Each lower molar has two roots, an anterior and a posterior, which are curved backwards; both roots are grooved longitudinally, indicating a tendency to division. The two roots of the third molar are more or less united.

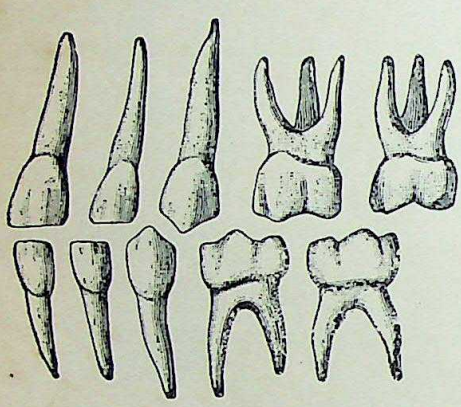

Fig. 1063.—The deciduous teeth of the left side.

The Deciduous Teeth (fig. 1063)

The **deciduous or milk-teeth** resemble in form the teeth which bear the same names in the permanent set; they are, however, smaller and their necks are more constricted. The second molar is the largest of the deciduous teeth. The first upper molar has three cusps, the second has four. The first lower molar has four cusps; the second has five. The roots of the deciduous molars are smaller than those of the permanent molars; they are also more divergent, owing to the fact that the crowns of the permanent molars are lodged between them. The deciduous molars are replaced by the permanent premolars.

The Structure of the Teeth

On making a vertical section through a tooth (figs. 1064 to 1067), a cavity is seen in the crown and in the centre of each root; it opens by a minute orifice at the extremity of the latter. This is called the *pulp cavity*, and contains the *dental pulp*, a loose connective tissue richly supplied with blood-vessels and nerves which enter the cavity through the small aperture at the point of each root. Some of the cells of the pulp are arranged as a layer on the wall of the pulp cavity; they are named *odontoblasts*, and during the development of the tooth are columnar in shape, but after the dentine is fully formed they become flattened. Each sends a fine process into a canaliculus in the dentine.

The solid portion of the tooth consists of (1) the *ivory* or *dentine*, which forms the bulk of the tooth; (2) the *enamel*, which covers the exposed part of the crown; and (3) a thin layer of bone, the *cement* or *crusta petrosa*, which covers the root or roots.

The **dentine** (substantia eburnea) (fig. 1067) is a modification of osseous tissue, from which it differs, however, in structure. On microscopic examination it is seen to consist of a number of minute wavy and branching tubes, the *dental canaliculi*, imbedded in a dense homogeneous substance, the *matrix*.

The *dental canaliculi* (fig. 1067) are placed parallel with one another, and open at their inner ends into the pulp cavity. In their course to the periphery they present two or three curves, and are twisted on themselves in a spiral direction. They vary in direction: thus in a tooth of the mandible they are vertical in the upper portion of the crown, becoming oblique and then horizontal in the neck and upper part of the root, while towards the lower part of the root they are inclined downwards. In their course they divide and subdivide, and, especially in the root, give off minute branches, which join together in loops in the

CC-0. In Public Domain. Gurukul Kangri Collection, Haridwar

Digitized by Arya Samaj Foundation Chennai and eGangotri

matrix, or end blindly. Near the periphery of the dentine, the finer ramifications of the canaliculi terminate imperceptibly by free ends. The dental canaliculi have definite walls consisting of an elastic homogeneous membrane, the *dentinal sheath of Neumann*, which resists the action of acids; they contain slender cylindrical prolongations of the odontoblasts, named *Tomes' fibres* or *dentinal fibres*.

The *matrix* is translucent, and contains the chief part of the earthy matter of the dentine. In it are a number of fine fibrils, which are continuous with the fibrils of the dental pulp. After the earthy matter has been removed by steeping a tooth in weak acid, the animal matter may be torn into laminæ which run parallel with the pulp cavity, and across the

FIG. 1064.—A vertical section through a tooth *in situ*. ×15.

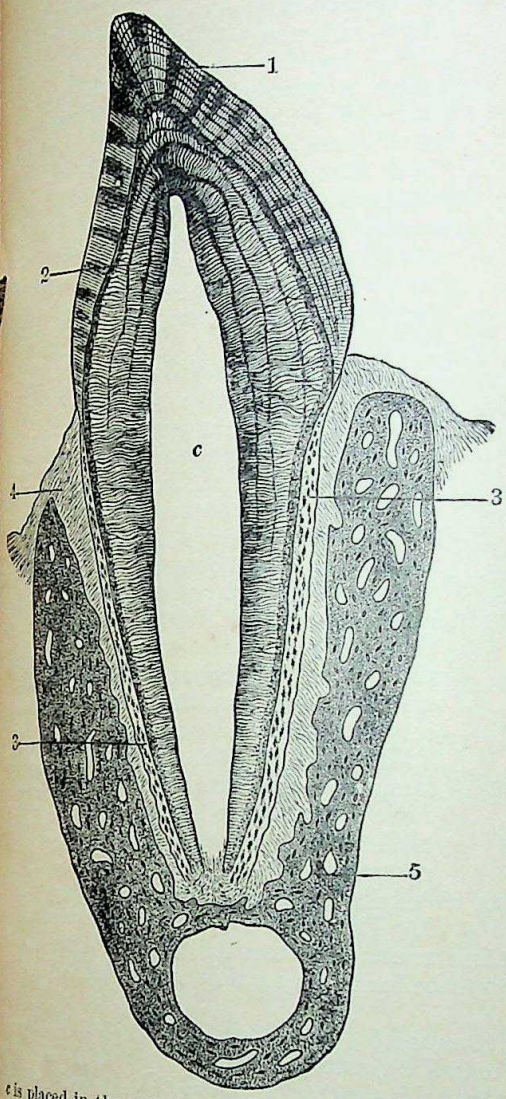

c is placed in the pulp cavity, opposite the neck of the tooth; the part above it is the crown, that below is the root. 1. Enamel with radial and concentric markings. 2. Dentine with tubules and contour lines. 3. Cement or crusta petrosa, with bone-cells. 4. Dental periosteum. 5. Mandible.

FIG. 1065.—A vertical section through a molar tooth.

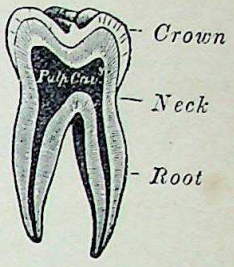

FIG. 1066.—A vertical section through a premolar tooth. (Magnified.)

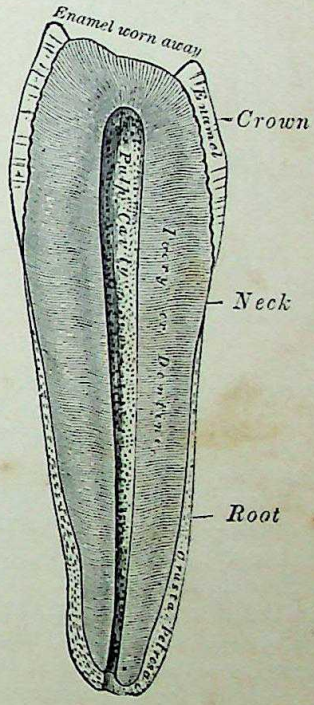

canaliculi. The planes separating these laminæ are indicated in a section of dry dentine by a series of somewhat parallel lines—the *contour lines of Owen*—composed of imperfectly calcified dentine. In consequence of the imperfection in the calcifying process, little irregular cavities are left, termed *interglobular spaces* (fig. 1067). A series of these spaces found towards the outer surface of the dentine, where they form a layer which is sometimes known as the *granular layer of Tomes*. They have received their name from the fact that they are surrounded by minute nodules or globules of dentine. Other curved lines, the *lines of Schreger*, may be seen parallel to the surface; they are due to the optical effect of simultaneous curvature of the dentinal fibres.

Chemical composition.—According to Berzelius and von Bibra, dentine consists of 28 parts of animal, and 72 parts of earthy, matter. The animal matter is converted, by boiling, into gelatin. The earthy matter consists of phosphate, carbonate, and a trace of chloride, of calcium, phosphate of magnesium, and other salts; over 80 per cent. of the earthy matter consists of calcium phosphate.

CC-0. In Public Domain. Gurukul Kangri Collection, Haridwar

Digitized by Arya Samaj Foundation Chennai and eGangotri

The enamel (substantia adamantina) is the hardest and most compact part of the tooth, and forms a thin crust over the exposed part of the crown, as far as the commencement of the root. It is thickest on the grinding surface of the crown, until worn away by attrition (fig. 1066), and becomes thinner towards the neck. The cement may overlap, or be overlapped by, the enamel, but they generally meet without overlapping. Sections usually show a series of brown lines which form acute angles with the contour of the underlying dentine. The enamel consists of minute rods termed *enamel-fibres* or *enamel-prisms* (prismata adamantina). They lie parallel with one another, their inner ends resting upon the dentine, which presents a number of minute depressions for their reception; their outer ends form the free surface of the crown. The enamel-fibres are directed vertically on the summit of the crown, and more or less horizontally at the sides; they are about 4μ in diameter, and pursue a somewhat wavy course. Each enamel-fibre is a six-sided prism and presents numerous dark transverse shadings; these shadings are probably due to the manner in which the columns are developed in successive stages, producing shallow constrictions, as will be subsequently explained. Numerous minute interstices intervene between the enamel-fibres near their dentinal ends.

Fig. 1067.—A transverse section through a portion of the root of a canine tooth. ×300. (From Stricker's Handbook of Histology.)

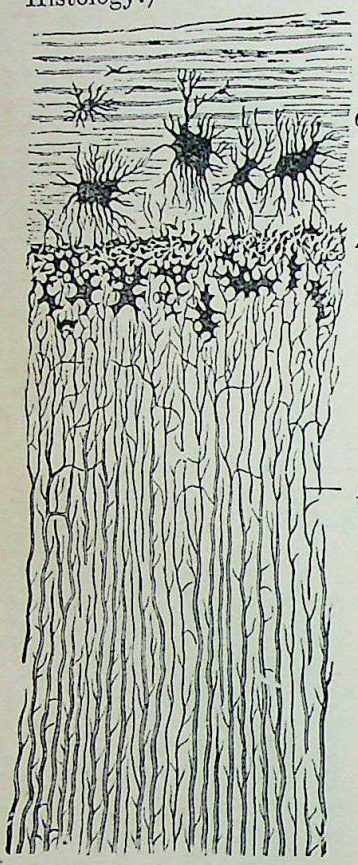

Chemical composition.—Enamel consists of from 98 to 99 per cent. of earthy matter, and from 1 to 2 per cent. of animal matter. The earthy matter consists of phosphate of lime, with traces of fluoride and carbonate of calcium, phosphate of magnesium, and other salts. Tomes asserts that there is no animal matter in properly calcified enamel.

The **crusta petrosa** or **cement** (substantia ossea) (figs. 1064, 1067), is disposed as a thin layer on the roots of the teeth, from the enamel to the apex of each root. In structure and chemical composition it resembles bone. It contains a few lacunæ and canaliculi; the canaliculi of adjacent lacunæ intercommunicate as in ordinary bone; and those more deeply placed join with the adjacent dental canaliculi. Normal cement is non-vascular.

As age advances, the cement increases in thickness, and gives rise to bony growths or exostoses, common in the teeth of the aged. The pulp cavity also becomes partially filled up by a hard substance, intermediate in structure between dentine and bone (*secondary* or *adventitious dentine*, Tomes); it appears to be formed by a slow conversion of the dental pulp, which shrinks, or disappears.

Arteries.—The upper molars and premolars receive their blood supply from the posterior superior alveolar branch of the internal maxillary artery; the upper canine and incisors from the anterior superior twigs of the infra-orbital artery. The lower teeth are supplied by the inferior alveolar branch of the internal maxillary artery.

Nerves.—The superior alveolar branches of the maxillary nerve supply the upper, and the inferior alveolar branch of the mandibular nerve the lower, teeth.

The *lymphatics* are described on p. 755.

The Development of the Teeth (figs. 1068 to 1071)

In describing the development of the teeth, the mode of formation of the deciduous teeth must first be considered, and then that of the permanent teeth.

The development of the deciduous teeth begins about the sixth week of fœtal life as a shallow *dental or labiotectal furrow* in the epithelium covering the surface of the future jaw. Along the line of this furrow the epithelium grows into the subjacent mesoderm as a band of cells which splits into a medial (dentogingival) and a lateral (labiogingival) lamina (Bolk*). The labiogingival lamina ultimately separates the alveolar processes from the lips and cheeks. In the dentogingival lamina the enamel-organs of the teeth are developed, and hence it is usually known as the *dental lamina* or *common dental germ*. Bolk has pointed

* L. Bolk, "Odontological essays," *Journal of Anatomy*, vols. lv., lvi., lvii.

CC-0. In Public Domain. Gurukul Kangri Collection, Haridwar

Digitized by Arya Samaj Foundation Chennai and eGangotri

out that the dental lamina also forms the epithelium of the gums, on the inner surface of the alveolar ridge. The common dental germ forms a flat band of cells, which grows into the substance of the embryonic jaw, at first horizontally, and then, as the teeth develop, vertically, i.e. upwards in the upper jaw, and downwards in the lower jaw. While still maintaining a horizontal direction it has two edges—an *attached edge*, continuous with the epithelium lining the mouth, and a *free edge*, imbedded in the mesodermal tissue of the embryonic jaw.

About the ninth week the dental lamina begins to develop enlargements along its free edge. These are ten in number in each jaw, and each corresponds with a future deciduous tooth. They consist of masses of epithelial cells; and the cells of the deeper parts of each mass increase rapidly and spread in all directions. Each mass thus comes to assume the shape of a club, connected with the epithelial lining of the mouth by a narrow neck, embraced by mesoderm. These masses are now known as *special dental germs*. After a time the lower expanded portion of each mass inclines outwards, so as to form an angle with the superficial constricted portion, which is sometimes known as the *neck* of the special dental germ. About the tenth week the mesodermal tissue beneath the special dental germs becomes differentiated into papillæ; these come in contact with the special dental germs, which become folded over them like a hood or cap. There is, at this stage, a

FIG. 1068.—A sagittal section through the first lower deciduous molar of a human embryo 30 mm. long. × 100. (Röse.)

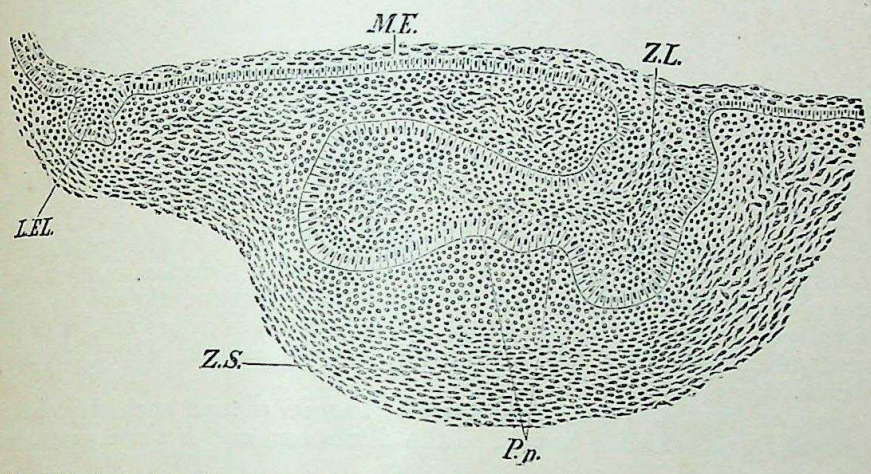

L.E.L. Labiogingival lamina, here separated from the dental lamina. *M.E.* Mouth-epithelium. *P.p.* Bicuspidate papilla, capped by the enamel germ. *Z.L.*, placed over the shallow dental furrow, points to the dental lamina, which is spread out below to form the enamel germ of the future tooth. *Z.S.* Condensed tissue forming dental sac.

papilla (or papillæ) which has already begun to assume somewhat the shape of the crown of the future tooth, and from which the dentine and pulp of the tooth are developed, surmounted by a dome or cap of epithelial cells from which the enamel is derived.

While these changes are going on, the dental lamina extends backwards behind the special dental germ of the second deciduous molar tooth, and about the seventeenth week of fœtal life, it presents an enlargement, the special dental germ for the first permanent molar, soon followed by the formation of a mesodermal papilla for the same tooth. About the fourth month after birth a further extension backwards of the dental lamina occurs, with the formation of another special dental germ and its corresponding papilla for the second molar. The process is repeated for the third molar, the papilla of which appears about the fifth year of life.

After the formation of the special dental germs, the dental lamina undergoes atrophic changes and becomes cribriform, except on the lingual aspect of each of the special germs of the temporary teeth, where it undergoes a local thickening to form the special dental germ of each of the successional permanent teeth—i.e. the ten anterior ones in each jaw. Here the same process goes on as has been described in connexion with those of the deciduous teeth: that is, they recede into the mesoderm, behind the germs of the deciduous teeth. As they recede they become club-shaped, form expansions at their distal ends, and finally meet papillæ which have been formed in the mesoderm. The apex of each papilla indents the dental germ which forms a cap for it, and becomes converted into the enamel, while the papilla forms the dentine and pulp of the permanent tooth.

The special dental germs consist at first of round or polyhedral epithelial cells. After the formation of the papillæ, these cells undergo a differentiation into three layers. Those in contact with the papilla become elongated, and form a stratum of well-marked columnar epithelium. These cells form the enamel-fibres, and are therefore termed *enamel-cells* or *ameloblasts*. The cells of the outer layer of the special dental germ are cubical in form, and are named the *external enamel epithelium*. The intermediate cells become stellate in shape

CC-0. In Public Domain. Gurukul Kangri Collection, Haridwar

Digitized by Arya Samaj Foundation Chennai and eGangotri

and form a network into which fluid is secreted; this has the appearance of a jelly, and to it the names of *stellate reticulum* or *enamel-pulp* are given. Between the stellate reticulum and the layer of ameloblasts there is a *stratum intermedium* consisting of two or three layers of round or polygonal cells. The special dental germ, thus transformed, is now named the *enamel-organ* (fig. 1070).

FIG. 1069.—A sagittal section through the canine tooth of an embryo 40 mm. long. ×100. (Röse.)

L.F. Labiodental furrow. The other lettering as in fig. 1068.

Bolk (loc. cit.) has pointed out that in mammals, with one or two exceptions, the enamel-organ is, during a certain phase of development, connected with the common dental germ by a *medial* and a *lateral enamel band*, separated by what he names the *enamel-niche*. These two bands unite and convert the niche into a short tunnel which is filled with mesoderm, and is open posteriorly. The lateral enamel-band degenerates and is broken up into epithelial islets.

While these changes are going on, a sac is formed around each enamel-organ from the mesodermal tissue. This is known as the *dental sac*, and is a vascular membrane of

FIG. 1070.—A vertical section through the mandible of an early human fœtus. ×25.

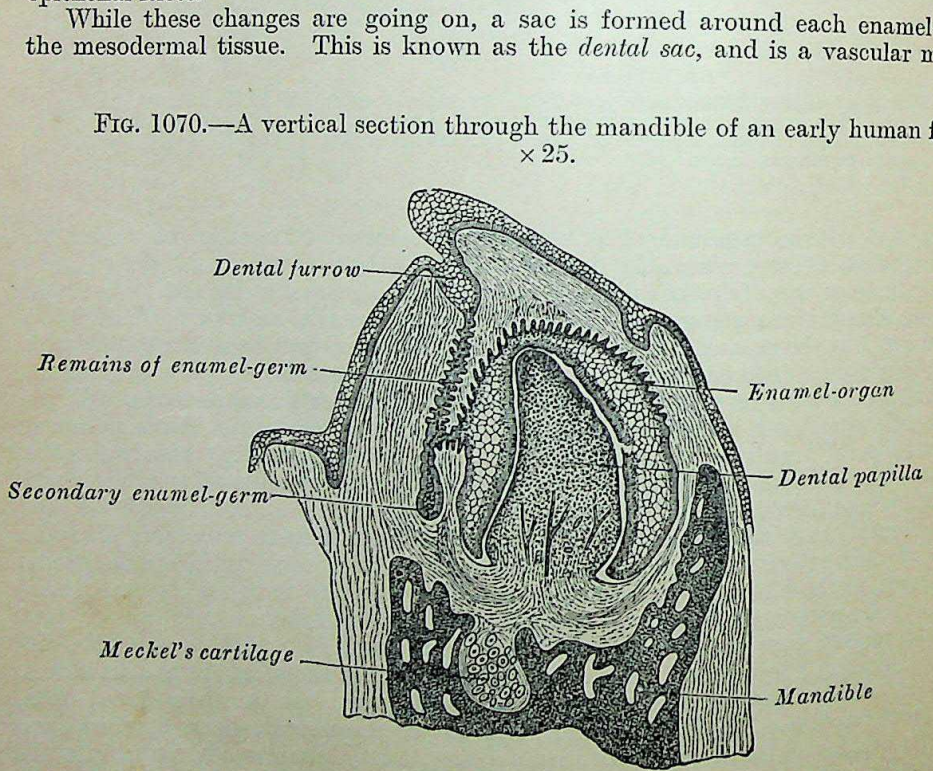

connective tissue. It encloses the whole tooth germ, and causes the neck of the enamel-organ to atrophy and disappear; so that the connexion between the enamel-organ and the superficial epithelium is severed.

The formation of the enamel.—The enamel is formed exclusively from the enamel-cells or ameloblasts of the special dental germ (fig. 1071), either by direct calcification of the

CC-0. In Public Domain. Gurukul Kangri Collection, Haridwar

Digitized by Arya Samaj Foundation Chennai and eGangotri

columnar cells, which become elongated into the enamel-fibres, or, as is more generally believed, as a secretion from the ameloblasts, within which calcareous matter is subsequently deposited.

The process begins at the ends of the enamel-cells in contact with the dental papilla. Here a fine globular deposit takes place, being apparently shed from the ends of the ameloblasts. It is known by the name of the *enamel-droplet*, and resembles keratin in its resistance to the action of mineral acids. This droplet then becomes fibrous and calcifies, and forms the first layer of the enamel; a second droplet now appears and calcifies, and so on; successive droplets of keratin-like material are shed from the ameloblasts and form successive layers of enamel, the ameloblasts gradually receding as each layer is produced, until at the termination of the process they have almost disappeared. The enamel-pulp or stellate reticulum and the stratum intermedium atrophy and disappear, so that the newly formed calcified material and the external enamel-epithelium come into apposition. The crown of the tooth is covered for a time by a distinct membrane, known as the *cuticula dentis*, or *Nasmyth's membrane*, and believed to be developed from the external enamel-epithelium. It forms a horny layer, which may be separated from the subjacent calcified mass by the action of strong acids. It is marked by the hexagonal impressions of the enamel-fibres, and when stained by nitrate of silver, shows the characteristic lines of interepithelial cement.

Fig. 1071.—A longitudinal section through the lower part of a growing tooth, showing the extension of the layer of ameloblasts beyond the crown to mark off the limit of formation of the dentine of the root. (Röse.) (From Quain's Elements of Anatomy.)

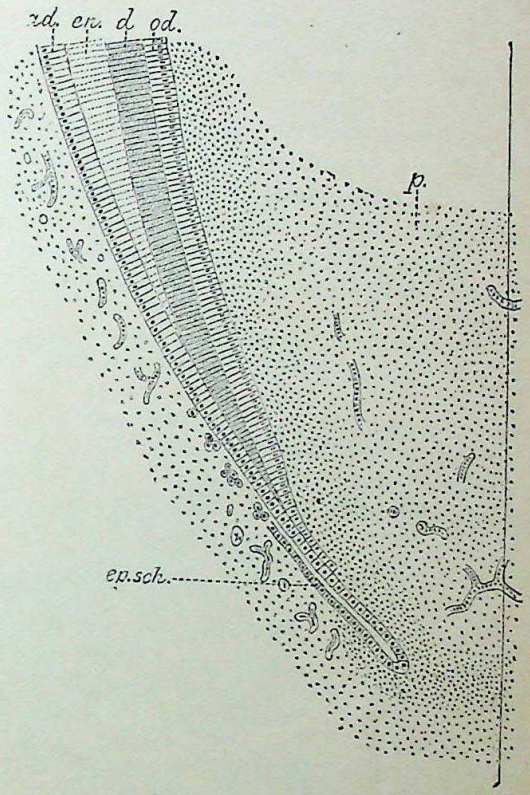

ad. Ameloblasts, continuous below with *ep. sch.*, the epithelial sheath. *d.* Dentine. *en.* Enamel. *od.* Odontoblasts. *p.* Pulp.

The formation of the dentine.—As before stated, the first germs of the dentine are the papillæ, which grow upwards into the enamel-germs and become covered by them, both being enclosed in the dental sacs, in the manner above described. Each papilla then consists of round cells, and is very vascular, and soon begins to assume the shape of the future tooth. The next step is the appearance of the *odontoblasts*, which have a relation to the development of the teeth somewhat similar to that of the osteoblasts to the formation of bone; they are formed from the superficial cells of the papilla; these cells become elongated, one end of the elongated cell resting against the epithelium of the special dental germs, the other being tapered and often branched. By the direct transformation of the peripheral ends of these cells, or by a secretion from them, a layer of uncalcified matrix (*predentine*) is formed, which caps the cusp, or cusps if there be more than one, of the papilla. This matrix becomes fibrillated, and in it islets of calcification make their appearance, and, coalescing, give rise to a continuous layer of calcified material which covers each cusp and constitutes the first layer of dentine. The odontoblasts retire towards the centre of the papilla, and, as they do so, produce successive layers of dentine—that is to say, they form the dentinal matrix in which calcification subsequently takes place. As they recede from the periphery of the papilla, they leave behind them filamentous processes of cell-protoplasm; these are surrounded by the calcified material, and thus the dental canaliculi are formed; the processes of protoplasm contained within these constitute the dentinal fibres (Tomes' fibres). The central part of the papilla does not undergo calcification, but persists as the pulp of the tooth. In certain places uncalcified portions of the matrix remain between the successive layers of dentine, and give rise to the interglobular spaces alluded to above.

The formation of the cement.—The root of the tooth begins to be formed shortly before the crown emerges through the gum, but is not completed until some time afterwards. Its form is determined by a downgrowth of the epithelium of the dental germ, which extends below the region where the enamel is to be formed, almost as far as the situation of the apex of the future root (fig. 1071); this fold of epithelium is known as the *epithelial sheath*. The vascular tissues of the dental sac then break through the epithelial sheath, and spread over the surface of the root as a layer of bone-forming material. In this layer osteoblasts make their appearance, and the process of ossification goes on as in the intramembranous ossification of bone. The remains of the epithelial sheath may sometimes be seen in the adult as isolated groups of cells in the adjacent dental periosteum.

CC-0. In Public Domain. Gurukul Kangri Collection, Haridwar

Digitized by Arya Samaj Foundation Chennai and eGangotri

The formation of the alveoli.—About the fourteenth week of embryonic life the dental lamina is enclosed in a trough or groove of mesodermal tissue, which at first is common to all the dental germs, but subsequently is divided by septa into loculi, each loculus containing the special dental germ of a deciduous tooth and its corresponding permanent tooth. After birth each cavity becomes subdivided, so as to form separate loculi for each deciduous tooth and its corresponding permanent tooth. Although at one time the whole of the growing tooth is contained in the cavity of the alveolus, the latter never completely encloses it, since there is always an aperture over the top of the crown filled by soft tissue, by which the dental sac is connected with the surface of the gum, and which in the permanent teeth is called the *gubernaculum dentis.*

The **development of the permanent teeth.**—Developmentally considered the permanent teeth may be divided into two sets: (1) the *successional permanent teeth* which replace the deciduous teeth, and, like them, are ten in number in each jaw; and (2) the *superadded permanent teeth* which have no deciduous predecessors, but are developed behind the temporary molars. The superadded permanent teeth are the three permanent molars, the molars of the deciduous set being replaced by the permanent premolars. During their development the successional permanent teeth, enclosed in their sacs, are placed on the lingual side of the deciduous teeth, but are separated from them by bony partitions. As the crown of the permanent tooth grows, absorption of the bony partition and of the root of the deciduous tooth takes place, through the agency of *osteoclasts* which appear at this time, and finally nothing but the crown of the deciduous tooth remains. This is shed or removed, and the permanent tooth takes its place.

The superadded permanent teeth are developed in the manner already described, by extensions backward of the posterior part of the dental lamina in each jaw (p. 1107).

The *eruption of the teeth.*—When the calcification of the different tissues of the tooth is sufficiently advanced to enable it to bear the pressure to which it will be subjected, eruption takes place, the tooth making its way through the gum. The eruption of the deciduous teeth commences about the seventh month after birth, and is completed about the end of the second year, the teeth of the lower jaw preceding those of the upper.

FIG. 1072.—The teeth of a child aged about seven years.

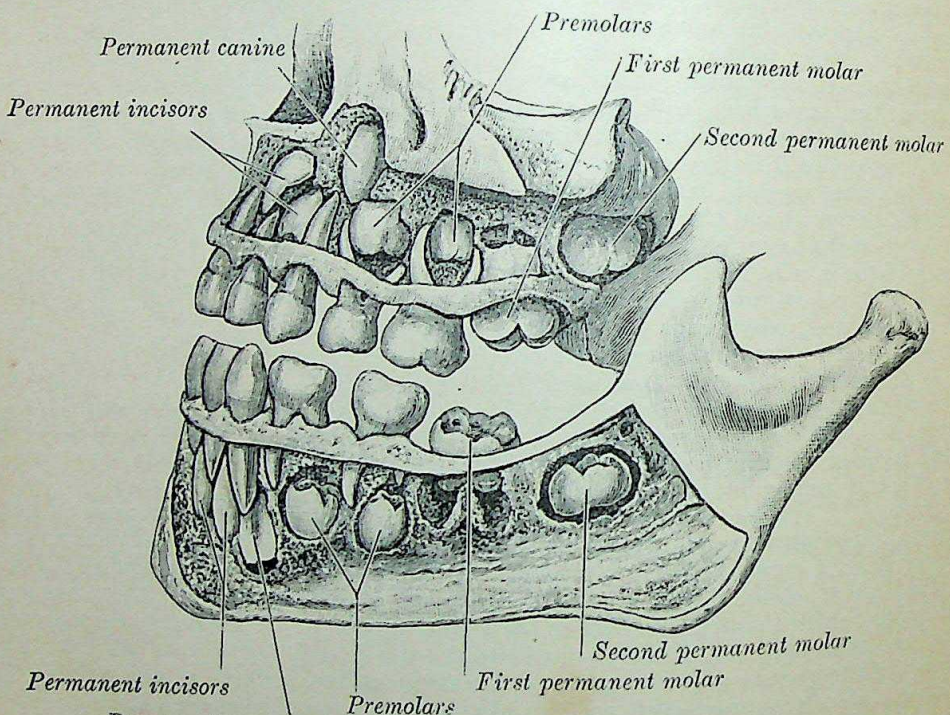

C. S. Tomes gives the following as the most usual times of eruption of the deciduous teeth:

Lower central incisors	6 to 9 months
Upper incisors	8 to 10 months
Lower lateral incisors and first molars	15 to 21 months
Canines	16 to 20 months
Second molars	20 to 24 months

CC-0. In Public Domain. Gurukul Kangri Collection, Haridwar

Digitized by Arya Samaj Foundation Chennai and eGangotri

There are, however, considerable variations in these times. According to Holt: a child at the age of one year should have six teeth; at the age of a year and half, twelve teeth; at the age of two years, sixteen teeth; and at the age of two and a half years, twenty teeth.

Calcification of the permanent teeth proceeds in the following order in the lower jaw (in the upper jaw it takes place a little later): the first molars, soon after birth; the incisors, and canines, about six months after birth; the premolars, at the second year, or a little later; the second molars, about the end of the second year; the third molars, about the twelfth year.

The eruption of the permanent teeth takes place at the following periods, the teeth of the lower jaw preceding those of the upper by short intervals:

First molars	6th year
Two central incisors	7th year
Two lateral incisors	8th year
First premolars	9th year
Second premolars	10th year
Canines	11th to 12th year
Second molars	12th to 13th year
Third molars	17th to 25th year

Towards the sixth year, before any of the deciduous teeth are shed, there are twenty-four teeth in each jaw, viz. the ten deciduous teeth and the crowns of all the permanent teeth except the third molars (fig. 1072).

Applied Anatomy.—As a consequence of local irritation or of chronic digestive disturbances occurring during their eruption, both the deciduous and the permanent teeth may show defective development or irregular transverse furrows and erosions; this is particularly the case with the incisors. A characteristic malformation of the two upper central permanent incisors is seen in patients with inherited syphilis, and was first described by Hutchinson. Here there is a crescentic notch in the anterior surface and at the cutting edge of the tooth, which is peg-shaped, stunted, and set obliquely in the gum, pointing either medialwards or lateralwards.

Numerous forms of innocent *tumour* arising from the teeth, or from their constituent layers, have been described under the general name of *odontoma*.

Infection of the pulp of a tooth by bacteria gaining access thereto in consequence of dental caries gives rise to the common and very painful *alveolar abscess*; starting in the apical space between the root of the tooth and its alveolar socket, the pus from such an abscess may make its way into the maxillary antrum, or burst through the hard palate or cheek. A more superficial abscess forming between the root of a tooth and the gum is known as a *gum-boil*.

The Tongue (Lingua)

The **tongue**, a muscular organ intimately associated with the functions of taste, speech and deglutition, is situated partly in the mouth, and partly in the pharynx. It is attached to the hyoid bone by the Hyoglossi, to the mandible by the Genioglossi, to the styloid processes by the Stylopharyngei, and to the soft palate by the Glossopalatini; it also gives origin to a few fibres of the Constrictor pharyngis superior. It possesses a root, an apex, a curved dorsum, and an inferior surface.

The *root* of the tongue is attached to the hyoid bone and the mandible, and between these bones is in contact with the Geniohyoidei and the Mylohyoidei. The *dorsum* is convex from before backwards, and from side to side, and is divided into a superior and a posterior part by a V-shaped furrow, the *sulcus terminalis*, the limbs of which run lateralwards and forwards from a median pit, the *foramen cæcum*, to the glossopalatine arches. The foramen cæcum marks the site of the upper end of the thyreoid diverticulum (p. 134), and the sulcus terminalis serves as the boundary between the oral part or anterior two-thirds, and the pharyngeal part or posterior one-third, of the tongue. These two parts differ in their development and nerve-supply.

The *oral part* of the tongue is placed in the cavity and floor of the mouth; its *apex* rests against the incisor teeth; its *borders* are free and in contact with the gums and teeth; its *superior surface* is in relation with the hard and soft palates. On each border, just in front of the Glossopalatine arch, are

CC-0. In Public Domain. Gurukul Kangri Collection, Haridwar

Digitized by Arya Samaj Foundation Chennai and eGangotri

four or five vertical folds, the *folia linguæ*, which represent the papillæ foliatæ of the rabbit's tongue. The mucous membrane on the superior surface of the oral part is marked by a median furrow (fig. 1074), is intimately adherent to the subjacent muscle, and is covered with papillæ. The mucous membrane on the inferior surface is smooth, and of a purplish colour; it is reflected from the tongue to the floor of the mouth and the gums. In the middle line it is raised into a crescentic fold, the *frenulum linguæ*, at each side of which is the opening of the submaxillary duct. Lateral to the frenulum, the lingual vein is seen shining through the mucous membrane, and at the lateral side of the vein there is a fringed fold of mucous membrane, named the *plica fimbriata*, which is directed forwards and medialwards towards the apex. The oral part

FIG. 1073.—The cavity of the mouth. The apex of the tongue is turned upwards, and on the right side a superficial dissection of its under surface has been made.

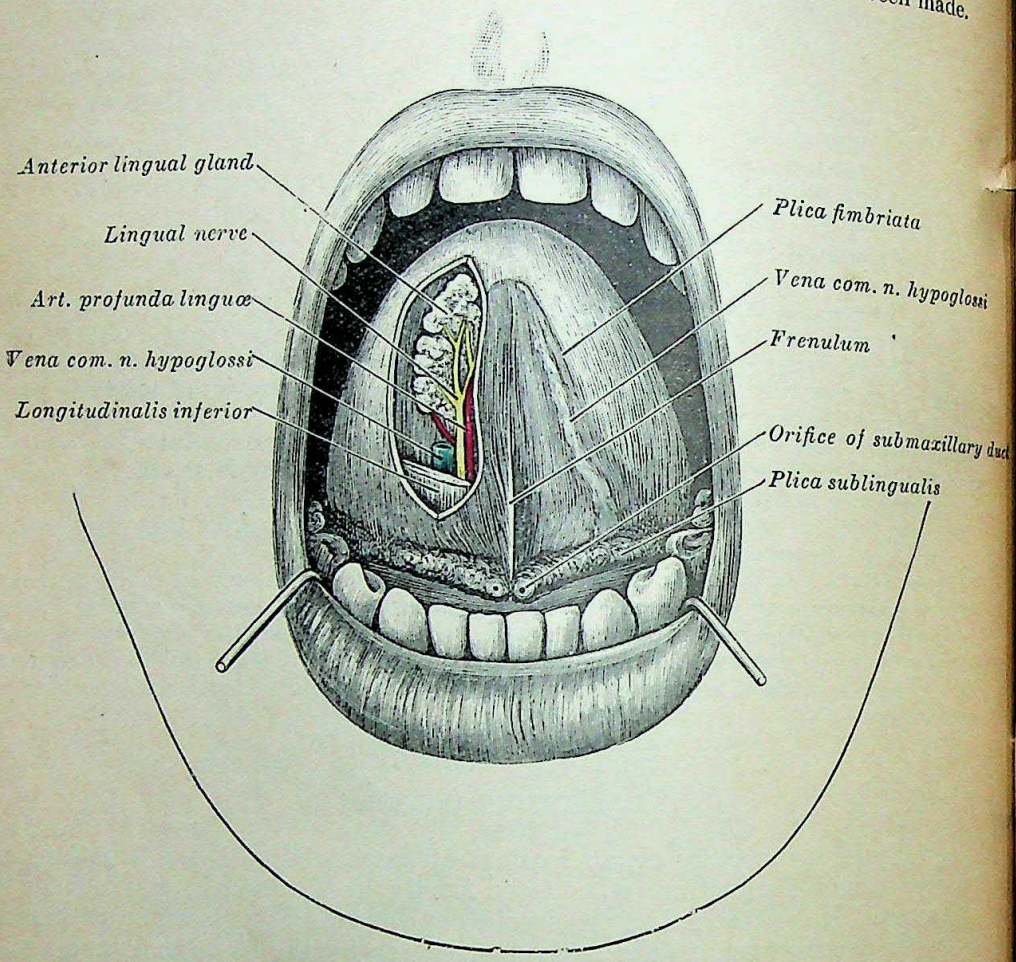

of the tongue is developed from the lingual swellings of the mandibular arch, and to a small extent from the tuberculum impar (p. 134). Its nerve of ordinary sensation is the lingual; its nerve of taste, the chorda tympani.

The *pharyngeal part* of the tongue lies behind the glosso-palatine arches and the isthmus faucium; its posterior surface (sometimes named the *base* of the tongue) forms the anterior wall of the oral part of the pharynx. The mucous membrane covering it is reflected laterally on to the tonsils and the pharyngeal wall, and posteriorly on to the epiglottis, where it forms a median (glosso-epiglottic) fold, and two lateral (pharyngo-epiglottic) folds. It is devoid of papillæ, but exhibits a number of low elevations, due to the presence of underlying nodules of lymphoid tissue, which are imbedded in the submucous tissue, and collectively constitute the *lingual tonsil*. The pharyngeal part of the tongue is developed from the copula, which is formed by the forward growth and fusion of the ventral ends of the second and third visceral arches (p. 134). Its nerves of ordinary sensation and of taste are derived from the glosso-pharyngeal.

CC-0. In Public Domain. Gurukul Kangri Collection, Haridwar

Digitized by Arya Samaj Foundation Chennai and eGangotri

The *papillæ of the tongue* (fig. 1074) are projections of the corium. They are thickly distributed over the anterior two-thirds of the dorsum, giving to this part its characteristic roughness. They are grouped under the terms papillæ vallatæ, papillæ fungiformes, papillæ conicæ, and papillæ simplices.

The *papillæ vallatæ* (fig. 1075) are of large size, and vary from eight to twelve in number. They are situated on the dorsum of the tongue, and form a V-shaped row immediately in front of and parallel with the sulcus terminalis. Each papilla is from 1 mm. to 2 mm. in diameter, and is attached within a

Fig. 1074.—The cavity of the mouth. The cheeks have been slit transversely and the tongue pulled forwards.

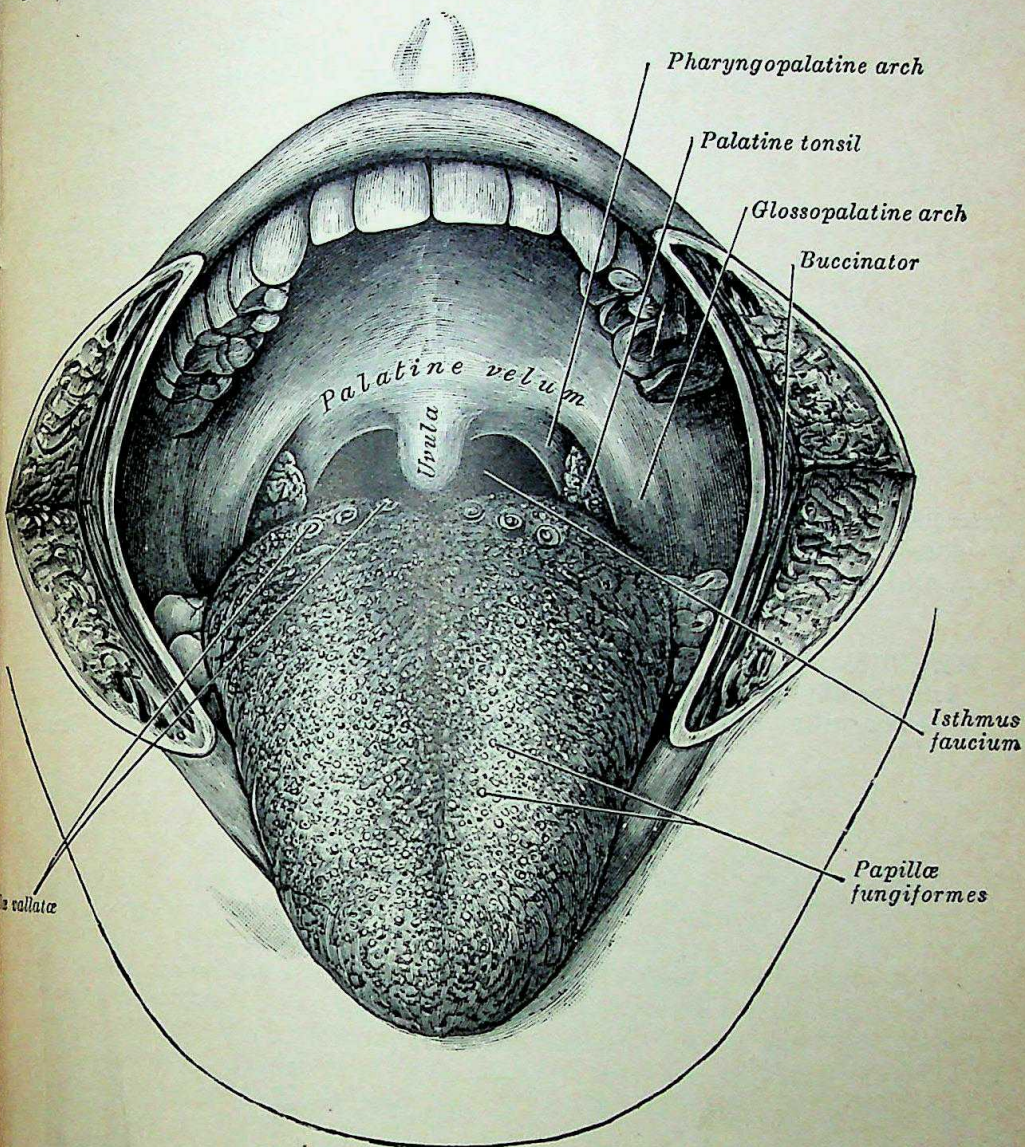

circular depression of the mucous membrane; each depression is surrounded by a wall (vallum), and between this and the papilla is a circular sulcus or fossa. The papilla is shaped like a truncated cone, the smaller end being attached to the tongue; the broader end projects a little above the surface of the tongue, and is studded with numerous small secondary papillæ subjacent to the epithelial layer. The entire papilla and the surrounding fossa and vallum are covered by stratified squamous epithelium.

The *papillæ fungiformes* (fig. 1076), more numerous than the preceding, are found chiefly at the sides and apex of the tongue, but are scattered irregularly and sparingly over the dorsum. They are easily distinguished from the papillæ conicæ by their large size, round shape, and deep red colour; each exhibits secondary papillæ beneath the epithelium. On the sides of the tongue they are somewhat flattened, and are named *papillæ lenticulares*.

CC-0. In Public Domain. Gurukul Kangri Collection, Haridwar

Digitized by Arya Samaj Foundation Chennai and eGangotri

The *papillæ conicæ* (fig. 1077) cover the anterior two-thirds of the dorsum of the tongue. They are very minute, conical or cylindrical in shape, and arranged in rows which run parallel with those of the papillæ vallatæ, excepting at the apex of the tongue, where their direction is transverse. The papillæ conicæ present numerous secondary connective tissue papillæ, but these are more pointed and contain a larger proportion of elastic fibres than the secondary papillæ vallatæ and papillæ fungiformes. The epithelium covering the papillæ conicæ may be split up into filamentous processes, each of which forms the apex of one of the secondary papillæ; these processes are of a whitish tint, owing to the thickness and density of the epithelium, the cells of which are elongated and cornified.

FIG. 1075.—A vertical section through a human papilla vallata. Stained with hæmatoxylin and eosin. × 15.

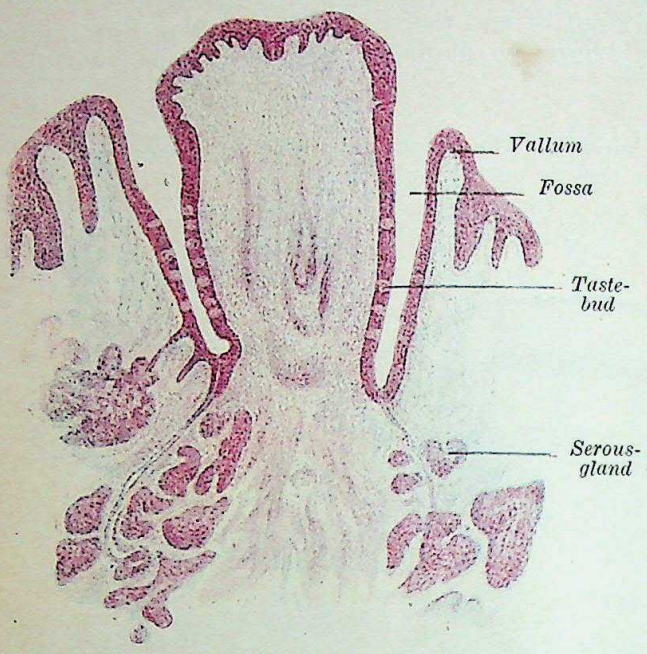

The *papillæ simplices* are similar to those of the skin, and cover the whole of the mucous membrane of the tongue, as well as the larger papillæ. They consist of closely set microscopic elevations of the corium; each contains a capillary loop, and is covered by epithelium.

FIG. 1076.—A section through a fungiform papilla from the human tongue. Stained with hæmatoxylin and eosin. × 15.

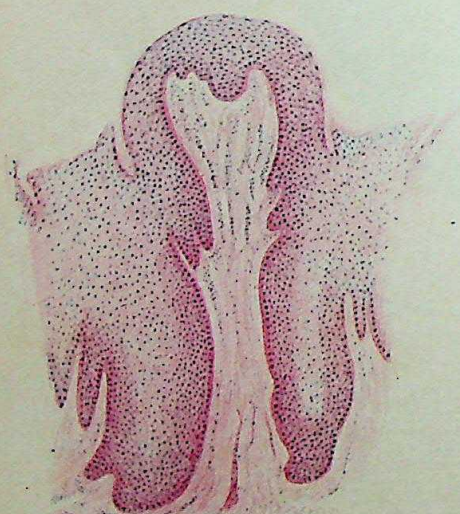

FIG. 1077.—A section through two conical papillæ from the human tongue. Stained with hæmatoxylin and eosin. × 15.

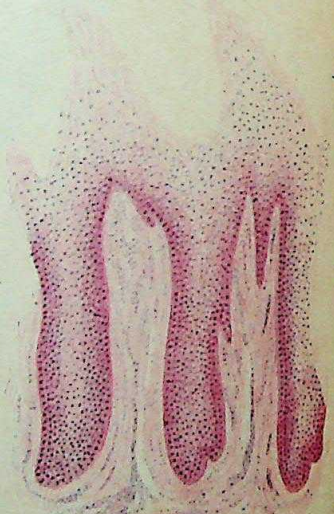

The muscles of the tongue.—The tongue is divided into right and left halves by a median fibrous septum which is fixed below to the hyoid bone. In either half there are two sets of muscles, extrinsic and intrinsic; the former have their origins outside the tongue, the latter are contained within it.

CC-0. In Public Domain. Gurukul Kangri Collection, Haridwar

Digitized by Arya Samaj Foundation Chennai and eGangotri

The *extrinsic muscles* (fig. 1078) are :

Genioglossus. Chondroglossus.
Hyoglossus. Styloglossus.
Glossopalatinus.*

The **Genioglossus** is a triangular muscle placed close to and parallel with the median plane. It arises by a short tendon from the superior mental spine on the inner surface of the symphysis of the mandible, just above the origin of

FIG. 1078.—The left extrinsic muscles of the tongue. Lateral aspect.

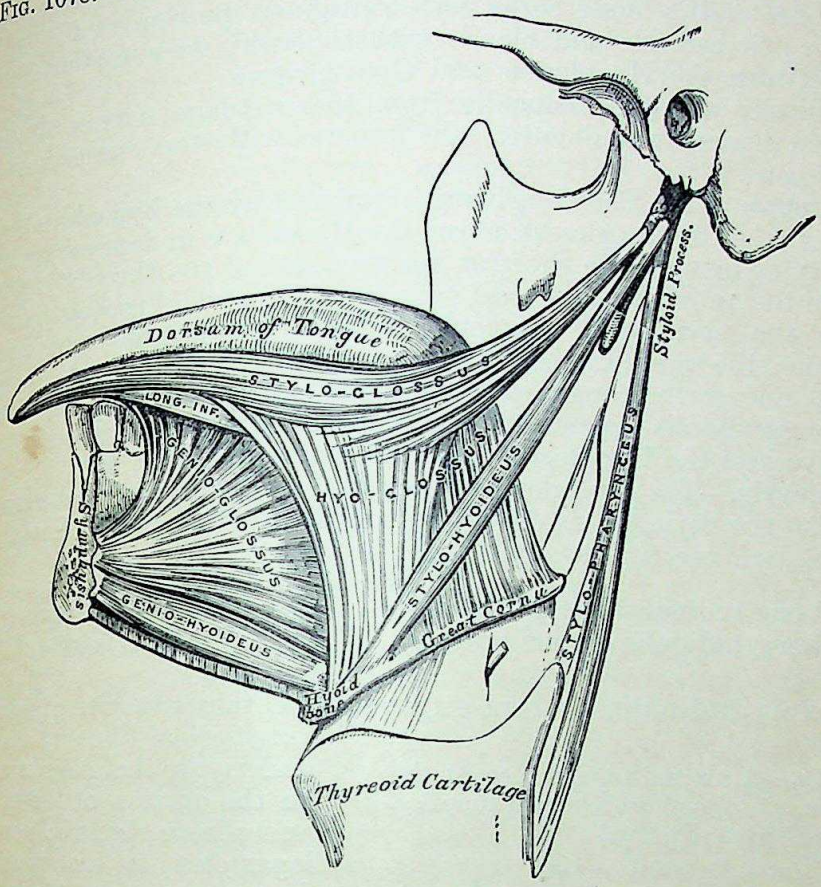

the Geniohyoideus, and spreads out in a fan-like form. The inferior fibres are attached by a thin aponeurosis to the upper part of the body of the hyoid bone, a few passing between the Hyoglossus and Chondroglossus to blend with the Constrictores pharyngis ; the middle fibres pass backwards, and the superior ones upwards and forwards, to enter the whole length of the under surface of the tongue, from the root to the apex. The muscles of opposite sides are separated posteriorly by the septum of the tongue (p. 1117) ; in front, they are more or less blended owing to the decussation of fasciculi in the median plane.

Nerve-supply.—The Genioglossus is supplied by the hypoglossal nerve.

Actions.—The Genioglossus draws the tongue forwards and protrudes the apex through the mouth. The two muscles acting in their entirety draw the median part of the tongue downwards so as to make the superior surface concave from side to side.

The **Hyoglossus**, thin and quadrilateral, arises from the whole length of the greater cornu, and from the front of the lateral part of the body, of the hyoid bone ; it passes almost vertically upwards and enters the side of the tongue, between the Styloglossus and Longitudinalis linguæ inferior. The fibres arising from the body of the hyoid bone overlap those from the greater cornu.

Relations.—The Hyoglossus is in relation by its *superficial surface* with the Digastricus, the Stylohyoideus, Styloglossus, and Mylohyoideus, the submaxillary ganglion, the lingual

* The *Glossopalatinus* (Palatoglossus), although one of the muscles of the tongue, is more closely associated with the soft palate both in situation and function ; it is consequently described with the muscles of that structure (p. 1120).

CC-0. In Public Domain. Gurukul Kangri Collection, Haridwar

Digitized by Arya Samaj Foundation Chennai and eGangotri

nerve, the hypoglossal nerve and its vena comitans, the ranine vein, the sublingual gland, the deep portion of the submaxillary gland, and the submaxillary duct. By its *deep surface* it is in relation with the stylohyoid ligament, the Genioglossus, the Longitudinalis linguæ inferior, and the Constrictor pharyngis medius, the lingual vessels, and the glossopharyngeal nerve.

Nerve-supply.—The Hyoglossus is supplied by the hypoglossal nerve.

Action.—The Hyoglossus depresses the tongue.

The **Chondroglossus** is sometimes described as a part of the Hyoglossus, but it is separated from that muscle by fibres of the Genioglossus which pass to the side of the pharynx. It is about 2 cm. long, and arises from the medial side and base of the lesser cornu and contiguous portion of the body of the hyoid bone; it ascends and blends with the intrinsic muscular fibres of the tongue, between the Hyoglossus and Genioglossus.

A small slip arises occasionally from the cartilago triticea in the lateral hyothyreoid ligament and enters the tongue with the hindermost fibres of the Hyoglossus.

Nerve-supply.—The Chondroglossus is supplied by the hypoglossal nerve.

Action.—The Chondroglossus assists the Hyoglossus in depressing the tongue.

The **Styloglossus**, the shortest and smallest of the three styloid muscles, arises from the anterior and lateral surfaces of the styloid process, near its apex, and from the stylohyoid ligament. Passing downwards and forwards, it divides upon the side of the tongue into two portions; one, longitudinal, enters the side of the tongue near its dorsal surface, blending with the fibres of the Longitudinalis linguæ inferior in front of the Hyoglossus; the other, oblique, overlaps the Hyoglossus and decussates with its fibres.

Nerve-supply.—The Styloglossus is supplied by the hypoglossal nerve.

Action.—The Styloglossus draws the tongue upwards and backwards.

The *intrinsic muscles* (fig. 1079) are:

Longitudinalis linguæ superior.	Transversus linguæ.
Longitudinalis linguæ inferior.	Verticalis linguæ.

The **Longitudinalis linguæ superior** is a thin stratum of oblique and longitudinal fibres immediately underlying the mucous membrane on the dorsum of the tongue. It arises from the submucous fibrous layer close to the epiglottis, and from the median fibrous septum, and runs forward to the edges of the tongue, some of its fibres being inserted into the mucous membrane.

FIG. 1079.—A coronal section through the tongue, showing the intrinsic muscles. (Altered from Krause.)

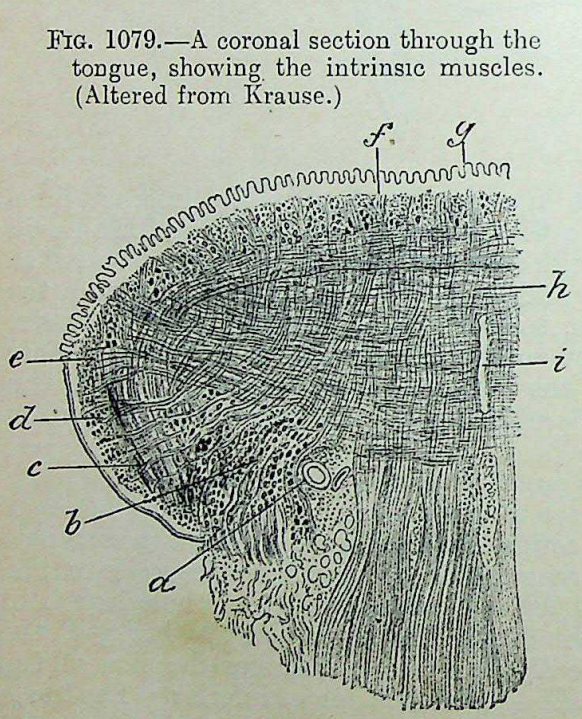

a. Lingual artery. *b.* Longitudinalis inferior. *c.* Hyoglossus. *d.* Styloglossus. *e.* Insertion of Transversus. *f.* Longitudinalis superior. *g.* Papillæ of tongue. *h.* Vertical fibres of Genioglossus intersecting Transversus. *i.* Septum.

The **Longitudinalis linguæ inferior** is a narrow band situated on the under surface of the tongue between the Genioglossus and Hyoglossus. It extends from the root to the apex of the tongue, some of its posterior fibres being connected with the body of the hyoid bone; in front it blends with the fibres of the Styloglossus.

The **Transversus linguæ** consists of fibres which arise from the median fibrous septum and pass lateralwards to be inserted into the submucous fibrous tissue at the sides of the tongue.

The **Verticalis linguæ** is found at the borders of the fore part of the tongue. Its fibres extend from the upper to the under surface of the organ.

CC-0. In Public Domain. Gurukul Kangri Collection, Haridwar

Digitized by Arya Samaj Foundation Chennai and eGangotri

Applied Anatomy.—Owing to the presence of the median fibrous septum of the tongue, the anastomosis between the two lingual arteries is not very free. This is a point of considerable importance in connexion with removal of one-half of the tongue, an operation not infrequently resorted to for malignant disease. If the mucous membrane be divided exactly in the middle line, the tongue can be split into halves, without any appreciable hæmorrhage, and the diseased half can then be removed.

Nerve-supply.—The intrinsic muscles of the tongue are supplied by the hypoglossal nerve.

Actions.—The intrinsic muscles are mainly concerned in altering the shape of the tongue; thus, the Longitudinales linguæ superior et inferior tend to shorten it, the former, in addition, turns the tip and sides upwards so as to render the dorsum concave, while the latter pulls the tip downwards and renders the dorsum convex. The Transversus linguæ narrows and elongates the tongue, and the Verticalis linguæ flattens and broadens it. The complex arrangement of the lingual muscles enables the tongue to assume the forms necessary for the production of the different consonantal sounds; and Macalister * says 'there is reason to believe that the musculature of the tongue varies in different races owing to the hereditary practice and habitual use of certain motions required for enunciating the several vernacular languages.'

Structure of the tongue.—The tongue consists chiefly of muscular tissue, but is partly covered by mucous membrane and a submucous fibrous layer.

The mucous membrane covering the under surface of the tongue is thin, smooth, and identical in structure with that lining the rest of the oral cavity. The mucous membrane of the pharyngeal part of the dorsum of the tongue is thick and freely movable over the adjacent parts. It contains a large number of follicles of lymphoid tissue; each follicle forms a rounded eminence, in the centre of which is a minute orifice leading into a funnel-shaped cavity or recess; around this recess are grouped numerous round or oval nodules of lymphoid tissue, each enveloped by a capsule derived from the submucous fibrous layer, while opening into the bottom of the recess are also seen the ducts of mucous glands. The mucous membrane on the oral part of the dorsum of the tongue is thin, intimately adherent to the muscular tissue, and covered with numerous *papillæ* (p. 1113). It consists of a layer of connective tissue, the *corium* or *mucosa*, covered with epithelium.

The epithelium is of the stratified squamous variety, similar to, but much thinner and less complex than that of the skin; it invests each papilla from root to summit.

The *corium* consists of a dense felt-work of fibrous connective tissue, with numerous elastic fibres, firmly united with the fibrous tissue between the muscular bundles of the tongue. It contains the ramifications of the numerous vessels and nerves from which the papillæ are supplied, large plexuses of lymphatic vessels, and the glands of the tongue.

Glands of the tongue.—The tongue is provided with mucous and serous glands.

The *mucous glands* are similar in structure to the labial and buccal glands. They are numerous in the posterior one-third of the tongue, i.e. behind the papillæ vallatæ, but are also present at the apex and margins. In this connexion the *anterior lingual glands* (glands of Blandin or Nuhn) require special notice. They are situated on the under surface of the apex of the tongue (fig. 1073), one on either side of the frenulum, where they are covered by the mucous membrane and by a fasciculus of muscular fibres derived from the Styloglossus and Longitudinalis inferior. They are from 12 mm. to 20 mm. long, and about 8 mm. broad; each consists of mucous and serous alveoli, and opens by three or four ducts on the under surface of the apex of the tongue.

The *serous glands* occur only at the back of the tongue in the neighbourhood of the taste-buds, their ducts opening for the most part into the fossæ of the papillæ vallatæ. These glands are racemose; the duct of each branches into several minute ducts, which end in alveoli lined by a single layer of more or less columnar epithelium. Their secretion is of a watery nature, and probably assists in distributing the substance to be tasted over the taste area (Ebner).

The *septum* of the tongue is a median fibrous partition which extends throughout the length of the organ, but does not quite reach the dorsum; it gives origin to the Transversus linguæ, and is well displayed in a coronal section of the tongue. Posteriorly it expands in a transverse direction and forms what is known as the *hyoglossal* membrane; this membrane connects the root of the tongue to the hyoid bone, and gives insertion to the inferior fibres of the Genioglossi.

Taste-buds, the end-organs of the gustatory sense, are scattered over the mucous membrane of the mouth and tongue at irregular intervals. They occur especially in the sides of the papillæ vallatæ. They are described under the organs of the senses (p. 983).

Vessels and Nerves.—The main *artery* of the tongue is the lingual branch of the external carotid artery, but the external maxillary and ascending pharyngeal arteries also give branches to it. The *veins* open into the internal jugular vein.

The *lymphatics of the tongue* are described on pp. 756, 757.

* *Text-book of Human Anatomy*, 1889.

CC-0. In Public Domain. Gurukul Kangri Collection, Haridwar

Digitized by Arya Samaj Foundation Chennai and eGangotri

The *sensory nerves of the tongue* are: (1) the lingual branch of the mandibular nerve, which is the nerve of ordinary sensibility for the anterior two-thirds of the tongue; (2) the chorda tympani branch of the facial nerve, which runs in the sheath of the lingual nerve, and is generally regarded as the nerve of taste for the anterior two-thirds; this nerve is derived from the sensory root of the facial (nervus intermedius); (3) the lingual branch of the glossopharyngeal nerve, which is distributed to the mucous membrane at the base and sides of the tongue, and to the papillæ vallatæ, and is the nerve of taste and of general sensation for this region; (4) the superior laryngeal nerve, which sends some fine branches to the part near the epiglottis.

Applied Anatomy.—Congenital cysts and fistulæ may develop from persistent remains of thyreoglossal duct (p. 134).

In the event of the lingual artery being accidentally injured, hæmorrhage can be at once controlled by passing the forefinger over the tongue until it touches the epiglottis, and then turning it towards the side on which the artery is to be compressed, and pushing it forcibly against the mandible (Heath).

It is the attachment of the Genioglossi to the mental spines on the inner surface of the symphysis menti which prevents the tongue from falling back and obstructing respiration, and, therefore, anæsthetists always pull forward the mandible and so get the full benefit of this action of these muscles. When in the course of an operation for the removal of cancer of the tongue, these attachments of the Genioglossi are divided, it is necessary to put a suture through the stump of the tongue to hold it forwards.

A consideration of the lymphatics of the tongue (pp. 756, 757) will indicate the extent of the operation necessary for the removal of cancer of the tongue.

The Fauces (fig. 1074)

The aperture by which the mouth communicates with the pharynx is called the *isthmus faucium*. Above, it is bounded by the soft palate; below, by the dorsum of the tongue; and, at the sides, by the glossopalatine arches.

The *glossopalatine arch* (anterior pillar of the fauces) runs downwards, lateralwards, and forwards on either side from the inferior surface of the soft palate to the side of the tongue, and is formed by the projection of the Glossopalatinus (p. 1120) with its covering mucous membrane.

The *pharyngopalatine arch* (posterior pillar of the fauces) lies behind and projects farther towards the middle line than the glossopalatine arch; it runs downwards, lateralwards, and backwards from the margin of the uvula to the side of the pharynx, and is formed by the projection of the Pharyngopalatinus (p. 1121), covered by mucous membrane. On either side the arches are separated below by a triangular recess, the *sinus tonsillaris*, in which the palatine tonsil is lodged.

The **palatine tonsils** (fig. 1074) are two masses of lymphoid tissue, situated in the lateral walls of the oral part of the pharynx. Each tonsil occupies the lower part of the sinus tonsillaris between the glossopalatine and pharyngopalatine arches; the upper part of the sinus is known as the *supratonsillar fossa*. A crescentic or triangular fold of mucous membrane, within which is a layer of fibrous tissue continuous with the capsule of the tonsil, passes backwards from the glossopalatine arch. The upper part of this fold, termed the *plica semilunaris* or *plica supratonsillaris*, stretches between the two arches and forms the medial wall of the supratonsillar fossa; the lower part of the fold, named the *plica triangularis*, forms the medial wall of the anterior and lower parts of the sinus tonsillaris; it overlaps, and is frequently adherent to, the tonsil. The tonsil extends forwards for a variable distance under cover of the plica triangularis and the glossopalatine arch, and upwards around the supratonsillar fossa and into the soft palate. A considerable part of the tonsil is therefore below the level of the surrounding mucous membrane (i.e. imbedded), while the remainder projects as the visible tonsil. In the child the tonsils are relatively (and often absolutely) larger than in the adult, and about one-third of the tonsil is imbedded (Hett and Butterfield *). After puberty the imbedded portion diminishes considerably in size, and the tonsil assumes a disc-like form, flattened from side to side; the shape and size of the tonsil, however, vary considerably in different persons.

The *free surface* of the tonsil presents from twelve to fifteen orifices leading into small crypts or recesses from which numerous follicles branch out into the tonsillar substance.

* G. Seccombe Hett and H. G. Butterfield, *Journal of Anatomy and Physiology*, vol. xliv.

CC-0. In Public Domain. Gurukul Kangri Collection, Haridwar

Digitized by Arya Samaj Foundation Chennai and eGangotri

The lateral or deep surface is adherent to a fibrous capsule which is continued into the plica triangularis. This surface is separated by some loose connective tissue from the Constrictor pharyngis superior; this muscle intervenes between the tonsil and the external maxillary artery with its tonsillar and ascending palatine branches. Some muscular fibres are inserted into the lower and posterior parts of the capsule. The internal carotid artery lies about 2·5 cm. behind and lateral to the tonsil.

The palatine tonsils form part of a circular band of adenoid tissue which guards the opening into the digestive and respiratory tubes. The anterior part of the ring is formed by the submucous adenoid collections (lingual tonsil) on the pharyngeal part of the tongue; the lateral portions consist of the palatine tonsils and the adenoid collections in the vicinity of the auditory tubes; the ring is completed behind by the pharyngeal tonsil on the posterior wall of the pharynx. In the intervals between these main masses are smaller collections of adenoid tissue.

Structure (fig. 1080).—The crypts of the tonsil are lined by stratified squamous epithelium, which is continuous with that of the mucous membrane of the pharynx, and is invaded by numerous lymph-corpuscles; probably some of the latter pass into the mouth and form the so-called salivary corpuscles. The tonsil consists of lymphoid tissue which is arranged in nodules or follicles. The lymphocytes are less closely packed in the centre of each nodule

Fig. 1080.—A section through a human tonsil. Stained with hæmatoxylin and eosin. ×8.

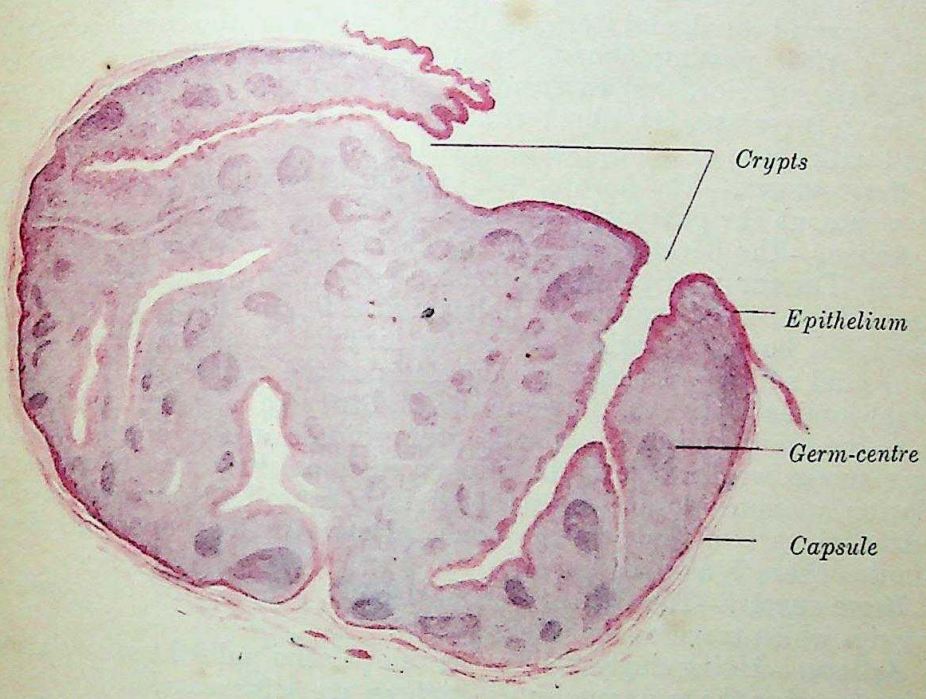

which is described as a *germ-centre*, because multiplication of the corpuscles goes on in this situation. Surrounding each follicle is a close plexus of lymphatics, from which the lymphatic vessels pass to the deep cervical lymph-glands in the neighbourhood of the greater cornu of the hyoid bone, behind and below the angle of the mandible (p. 756).

Vessels and Nerves.—The *arteries* supplying the tonsil are the dorsalis linguæ branches of the lingual artery, the ascending palatine and tonsillar branches of the external maxillary artery, the ascending pharyngeal branch of the external carotid artery, the descending palatine branch of the internal maxillary artery, and a twig from the small meningeal artery. The *veins* end in the tonsillar plexus, on the lateral side of the tonsil.

The *nerves* are derived from the sphenopalatine ganglion, and from the glossopharyngeal nerve.

Applied Anatomy.—The palatine tonsils can be easily inspected by instructing the patient to throw the head back and open his mouth widely, the tongue at the same time being depressed by a spatula or tongue-depressor. The normal tonsil should not project beyond the plane of the glossopalatine arch. They are prone to become enlarged, especially in tuberculous children; and when much increased in size they cause great trouble, owing to obstruction to respiration and deglutition. The tonsils may be the seat of acute inflammation, which may run on to suppuration, requiring evacuation of the pus. Pus

CC-0. In Public Domain. Gurukul Kangri Collection, Haridwar

Digitized by Arya Samaj Foundation Chennai and eGangotri

is best evacuated from the tonsil by Hilton's method. Another form of acute inflammation of the tonsil is follicular tonsillitis, due to the lodgment of micro-organisms in the crypts of the tonsil. The removal of enlarged tonsils from children is, as a rule, a very simple operation, and is not usually attended with much hæmorrhage, unless the patient is suffering from hæmophilia. In the operation of 'enucleation' of the tonsil, advantage is taken of the fact that its deep surface is encapsuled, the entire tonsil and the capsule being removed.

The **palatine aponeurosis.**—Attached to the posterior border of the hard palate is a thin, firm fibrous lamella, the *palatine aponeurosis*, which supports the muscles and gives strength to the soft palate. It is thick above, but very thin and difficult to define below. On each side it is continuous with the tendon of the Tensor veli palatini.

Blakeway * maintains that the palatine aponeurosis is not a separate structure, but is actually the expanded tendon of the Tensor veli palatini.

The **muscles of the palate and fauces** (fig. 1081) are:

Levator veli palatini.	Glossopalatinus.
Tensor veli palatini.	Pharyngopalatinus.
Musculus uvulæ.	

The **Levator veli palatini** (Levator palati) is a rounded muscle situated on the lateral side of the choana. It arises from the under surface of the petrous part of the temporal bone, immediately in front of the lower opening of the carotid canal, and from the medial lamina of the cartilage of the auditory tube. After passing above the upper concave margin of the Constrictor pharyngis superior, and in front of the Salpingopharyngeus, it spreads out in the soft palate, its fibres running as far as the middle line, where they blend with those of the opposite muscle.

Nerve-supply.—The Levator veli palatini is supplied by the accessory cerebral nerve through the pharyngeal plexus.

Action.—The Levator veli palatini elevates the soft palate.

The **Tensor veli palatini** (Tensor palati) is a thin muscle placed on the lateral side of the Levator veli palatini and the medial pterygoid lamina of the sphenoidal bone. It arises by a flat lamella from the scaphoid fossa, from the medial surface of the spina angularis of the sphenoidal bone, and from the lateral lamina of the cartilage of the auditory tube. Descending vertically as far as the lower end of the medial pterygoid lamina, it ends in a tendon which turns medialwards below the pterygoid hamulus, and is inserted into the palatine aponeurosis and into the surface behind the transverse ridge on the horizontal part of the palatine bone. Between the tendon and the pterygoid hamulus there is a small bursa.

Nerve-supply.—The Tensor veli palatini is supplied by the mandibular nerve by twigs which traverse the otic ganglion.

Actions.—Acting singly the Tensor veli palatini pulls the soft palate to one side; acting together the two muscles will tighten the soft palate.

The **Musculus uvulæ** (Azygos uvulæ) arises from the posterior nasal spine of the palatine bones and from the palatine aponeurosis; it descends to be inserted into the uvula.

Nerve-supply.—The Musculus uvulæ is supplied by the accessory cerebral nerve through the pharyngeal plexus.

Action.—The Musculus uvulæ pulls up the uvula on its own side.

The **Glossopalatinus** (Palatoglossus) is a small fleshy fasciculus, narrower in the middle than at the ends, forming, with the mucous membrane covering its surface, the glossopalatine arch. It arises from the anterior surface of the soft palate, where it is continuous with the muscle of the opposite side, and passing downwards, forwards, and lateralwards in front of the palatine tonsil, is inserted into the side of the tongue, some of its fibres spreading over the dorsum of the tongue, and others passing deeply into its substance to intermingle with the Transversus linguæ.

Nerve-supply.—The Glossopalatinus is supplied by the accessory cerebral nerve through the pharyngeal plexus.

* *Journal of Anatomy and Physiology*, vol. xlviii.

CC-0. In Public Domain. Gurukul Kangri Collection, Haridwar

Digitized by Arya Samaj Foundation Chennai and eGangotri

tubarius or *cushion*, caused by the pharyngeal end of the cartilage of the auditory tube which elevates the mucous membrane. A vertical fold of mucous membrane, the *salpingopharyngeal fold*, stretches from the lower part of the torus tubarius to the wall of the pharynx; it contains the Salpingopharyngeus muscle.

FIG. 1082.—A sagittal section through the nose, mouth, pharynx and larynx.

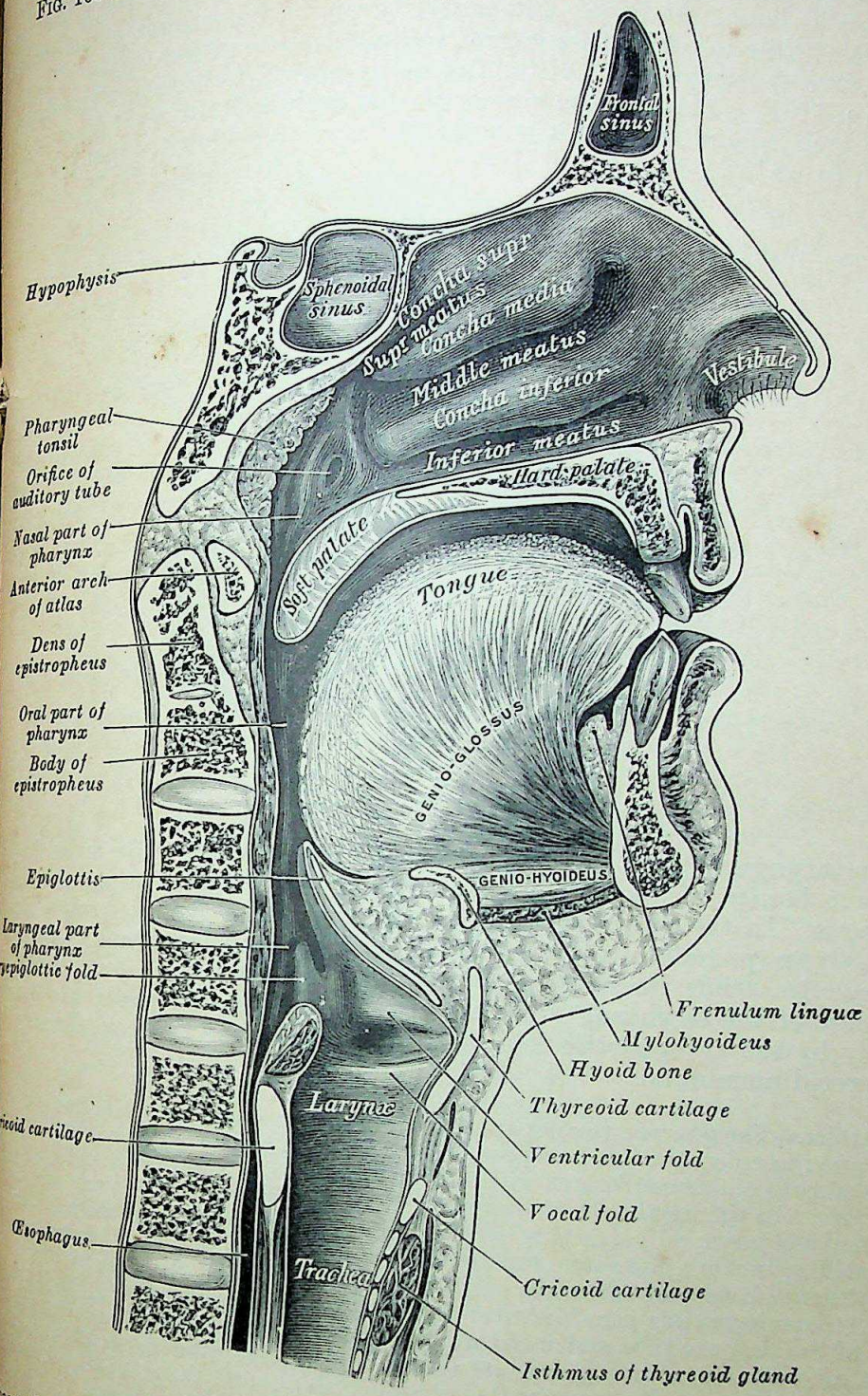

second and smaller fold, the *salpingopalatine fold*, stretches from the upper part of the torus to the palate. Behind the torus is a deep recess, the *pharyngeal recess* or *fossa of Rosenmüller*. On the posterior wall between the pharyngeal recesses is a mass of lymphoid tissue, which is known as the *pharyngeal tonsil*, and is best developed in childhood.

The pharyngeal tonsil is visible to the naked eye during the later months of fœtal life and usually increases in size up to the age of six or seven years, after which it not infrequently begins to atrophy. In a child of eighteen months it forms a triangular prominence

CC-0. In Public Domain. Gurukul Kangri Collection, Haridwar

Digitized by Arya Samaj Foundation Chennai and eGangotri

the apex of which is near the nasal septum, and the base at the junction of the roof and posterior wall of the nasal part of the pharynx. The prominence consists of a number of folds which radiate forwards and lateralwards from a median recess, the *pharyngeal bursa*. The folds consist mainly of diffuse adenoid tissue, but there are also some deeply placed mucous glands. The pharyngeal bursa lies close to the base of the tonsil and presents the appearance of a blind recess.*

The **oral part of the pharynx** reaches from the soft palate to the level of the hyoid bone. It opens anteriorly, through the isthmus faucium, into the mouth, while in each of its lateral walls is the elevation of the pharyngo-palatine arch (posterior pillar of the fauces) produced by the pharyngopalatine muscle (p. 1121). Between the glossopalatine arch in front and the pharyngo-palatine arch behind there is a triangular recess in which the palatine tonsil is lodged (p. 1118).

Fig. 1083.—The front of the nasal part of the pharynx, as seen with the laryngoscope.

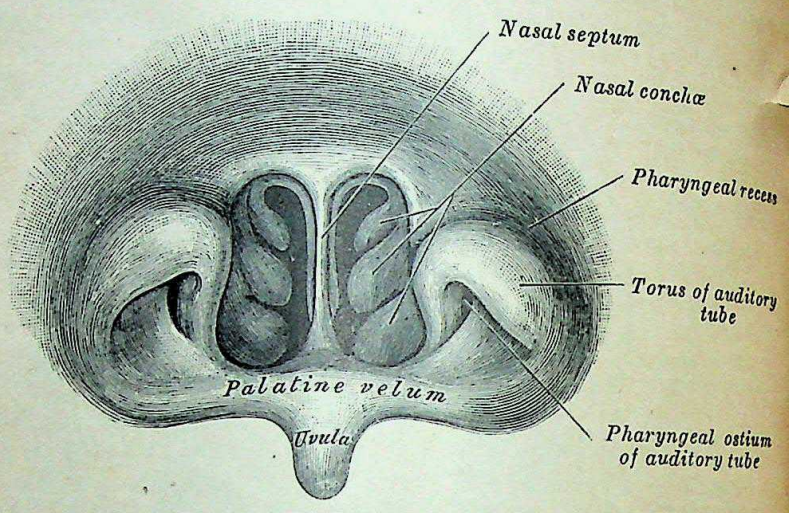

The **laryngeal part of the pharynx** reaches from the hyoid bone to the lower border of the cricoid cartilage, where it is continuous with the œsophagus. In the upper part of its anterior wall is the triangular entrance to the larynx (p. 1066); the base of the triangle is in front, and is formed by the epiglottis, while its sides are constituted by the aryepiglottic folds. On either side of the laryngeal orifice is a recess, the *recessus piriformis*, bounded medially by the aryepiglottic fold, and laterally by the thyreoid cartilage and hyothyreoid membrane.

Structure.—The pharynx is composed, from within outwards, of three coats: mucous, fibrous and muscular, the last being covered by the thin buccopharyngeal fascia (p. 448).

The *mucous coat* is continuous with that of the auditory tubes, nasal cavities, mouth, and larynx. In the nasal part of the pharynx its epithelium is columnar and ciliated; in the oral and laryngeal portions it is stratified squamous. Between the region covered by ciliated columnar epithelium and that covered by squamous epithelium, there is a narrow intermediate zone where the epithelium is cubical, and the cilia are imperfect or absent. Superiorly, this zone lies near the nasal septum: laterally it passes over the orifice of the auditory tube and inclines backwards at the union of the soft palate with the lateral wall. Racemose glands are found beneath the mucous membrane, and are especially numerous at the upper part of the pharynx around the orifices of the auditory tubes.

The *fibrous coat* is situated between the mucous and muscular layers. It is thick above (pharyngobasilar fascia) where the muscular fibres are wanting, and is firmly connected to the basilar portion of the occipital bone and the petrous portions of the temporal bones. As it descends it diminishes in thickness, and is gradually lost. It is strengthened posteriorly by a strong fibrous band, which is attached above to the pharyngeal tubercle on the under surface of the basilar portion of the occipital bone, and passes downwards as a median raphe which gives attachment to the Constrictores pharyngis.

The *muscular coat* consists of the muscles of the pharynx.

* J. Symington, *British Medical Journal*, Oct. 15, 1910.

CC-0. In Public Domain. Gurukul Kangri Collection, Haridwar

Digitized by Arya Samaj Foundation Chennai and eGangotri

The muscles of the pharynx (fig. 1084) are:

Constrictor pharyngis inferior.	Stylopharyngeus.
Constrictor pharyngis medius.	Salpingopharyngeus.
Constrictor pharyngis superior.	Pharyngopalatinus.*

The Constrictor pharyngis inferior is the thickest of the constrictors. It arises from the cricoid cartilage in the interval between the origin of the

FIG. 1084.—The Buccinator and the muscles of the pharynx.

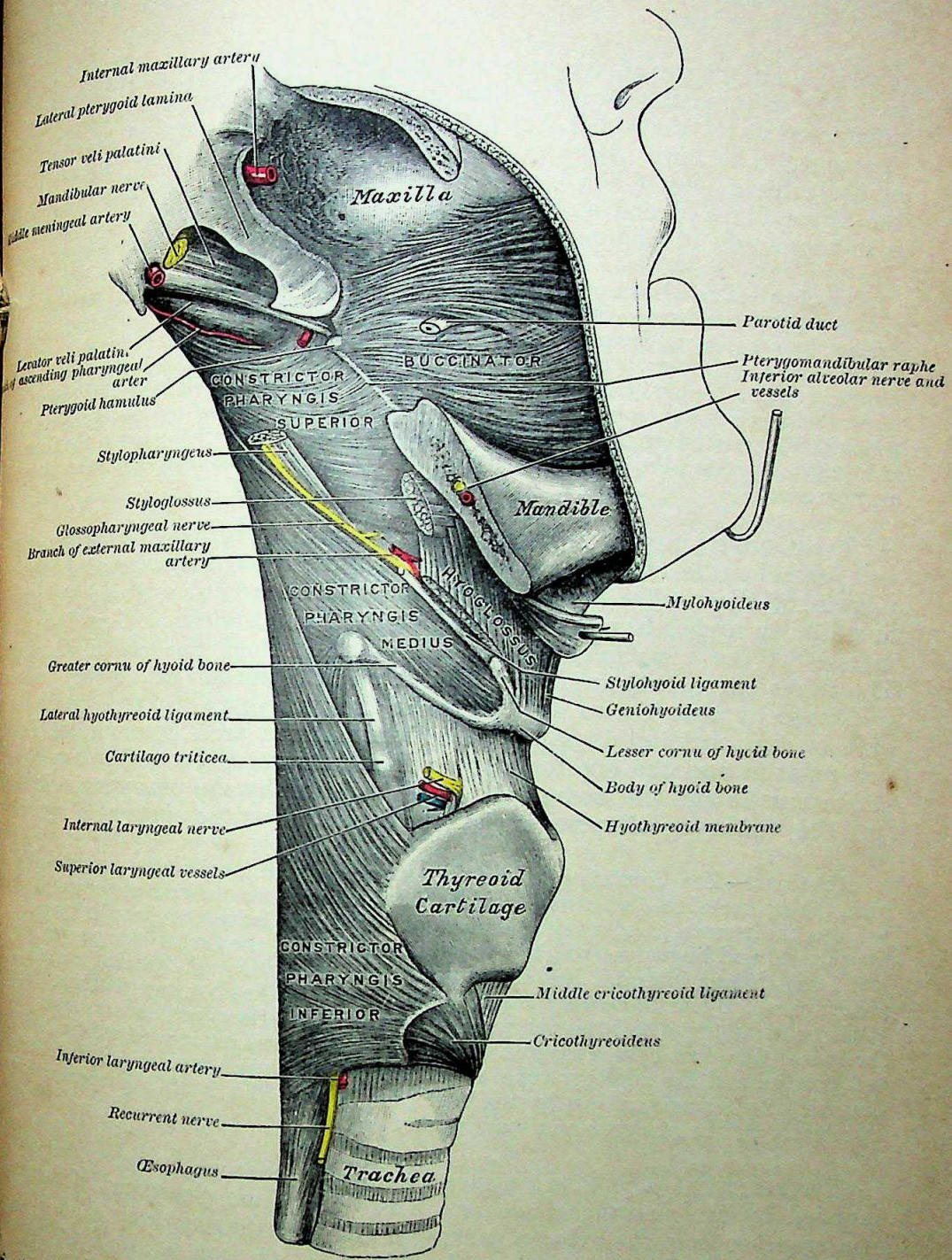

cricothyreoideus in front, and the articular facet for the inferior cornu of the thyreoid cartilage behind. It also arises from the oblique line on the lamina of the thyreoid cartilage, from the surface of the lamina behind this line nearly as far as the posterior border, and from the inferior cornu. The fibres spread backwards and medialwards, and are inserted with the muscle of the opposite side into a fibrous raphe in the posterior median line of the pharynx. The

* The Pharyngopalatinus is described with the muscles of the palate (p. 1121).

CC-0. In Public Domain. Gurukul Kangri Collection, Haridwar

Digitized by Arya Samaj Foundation Chennai and eGangotri

inferior fibres are horizontal and continuous with the circular fibres of the œsophagus; the rest ascend obliquely, and overlap the Constrictor medius.

Relations.—The Constrictor pharyngis inferior is covered by the buccopharyngeal fascia (p. 448) which surrounds the entire pharynx. *Behind*, the muscle is in relation with the prevertebral fascia and muscles; *laterally*, with the thyreoid gland, the common carotid artery, and the Sternothyreoideus; by its *internal surface*, with the Constrictor pharyngis medius, the Stylopharyngeus, the Pharyngopalatinus and the pharyngeal aponeurosis. The internal branch of the superior laryngeal nerve and the laryngeal branch of the superior thyreoid artery run near the upper border, and the recurrent nerve and the laryngeal branch of the inferior thyreoid artery ascend beneath its lower border, before they enter the larynx.

The **Constrictor pharyngis medius** is a fan-shaped muscle which arises from the lesser cornu, and from the whole length of the upper border of the greater cornu of the hyoid bone, and from the lower part of the stylohyoid ligament. The lower fibres descend beneath the Constrictor inferior, as far as the inferior end of the pharynx, the middle fibres pass transversely, and the upper fibres ascend and overlap the Constrictor superior. It is inserted, with the muscle of the opposite side, into the posterior median fibrous raphe.

Relations.—The Constrictor pharyngis medius is separated from the Constrictor pharyngis superior by the Stylopharyngeus muscle; and from the Constrictor pharyngis inferior by the internal branch of the superior laryngeal nerve and laryngeal branch of the superior thyreoid artery. *Behind* it are the prevertebral fascia, the Longus colli, and the Longus capitis. *Laterally* it is in relation with the carotid vessels, the pharyngeal plexus of nerves, and some lymph-glands. Near its origin it is covered by the Hyoglossus, from which it is separated by the lingual vessels. Its *internal surface* lies upon the Constrictor pharyngis superior, the Stylopharyngeus, the Pharyngopalatinus and the pharyngeal aponeurosis.

The **Constrictor pharyngis superior** is a quadrilateral muscle, thinner and paler than the other two. It arises from the lower one-third of the posterior margin of the medial pterygoid lamina and its hamulus, from the pterygomandibular raphe, from the posterior end of the mylohyoid line on the inner surface of the mandible, and by a few fibres from the side of the tongue. The fibres curve backwards to be inserted into the median raphe, being also prolonged by means of an aponeurosis to the pharyngeal tubercle on the basilar part of the occipital bone. The superior fibres arch beneath the Levator veli palatini and the auditory tube. The interval between the upper border of the muscle and the base of the skull is closed by the pharyngobasilar fascia (p. 1124) (pharyngeal aponeurosis), and is known as the *sinus of Morgagni*.

Relations.—The Constrictor pharyngis superior is in relation by its *external surface* with the prevertebral fascia and muscles, the internal carotid and ascending pharyngeal arteries, the internal jugular vein and pharyngeal venous plexus, the glossopharyngeal, vagus, hypoglossal and lingual nerves, the sympathetic trunks, the Constrictor pharyngis medius and Pterygoideus internus, the styloid process, the stylohyoid ligament, and the Stylopharyngeus. By its *internal surface* it is in relation with the Pharyngopalatinus, the capsule of the palatine tonsil and the pharyngeal aponeurosis. Its *upper border* is separated from the base of the skull by a crescentic interval in which the Levator veli palatini, the Tensor veli palatini and the auditory tube are situated. Its lower border is separated from the Constrictor pharyngis medius by the Stylopharyngeus. *In front* it is separated from the Buccinator by the pterygomandibular raphe.

Nerve-supply.—The Constrictores pharyngis inferior, medius et superior, are supplied by the pharyngeal plexus. The Constrictor pharyngis inferior receives also branches from the external laryngeal and recurrent nerves.

Actions.—During the process of swallowing, as soon as the bolus of food is received in the pharynx, the elevators of the pharynx relax, the pharynx descends, and the Constrictores contract upon the bolus and convey it downwards into the œsophagus.

The **Stylopharyngeus** (figs. 1078, 1084) is a long, slender muscle which is cylindrical above and flattened below. It arises from the medial side of the base of the styloid process of the temporal bone, descends along the side of the pharynx between the Constrictor pharyngis superior and the Constrictor pharyngis medius, and spreads out beneath the mucous membrane. Some of

CC-0. In Public Domain. Gurukul Kangri Collection, Haridwar

Digitized by Arya Samaj Foundation Chennai and eGangotri

ss fibres are lost in the constrictor muscles, while others are inserted with the Pharyngopalatinus into the posterior border of the thyreoid cartilage. The glossopharyngeal nerve winds round the lateral side of this muscle to reach the tongue.

Nerve-supply.—The Stylopharyngeus is supplied by a branch from the glossopharyngeal nerve.

Actions.—The Stylopharyngeus draws the side of the pharynx upwards and lateralwards, thus increasing the transverse diameter of the pharynx.

The **Salpingopharyngeus** (fig. 1081) arises from the inferior part of the cartilage of the auditory tube near its pharyngeal orifice; it passes downwards and blends with the posterior fasciculus of the Pharyngopalatinus.

Nerve-supply.—The Salpingopharyngeus is supplied by the pharyngeal plexus.

Actions.—The Salpingopharyngeus raises the upper part of the lateral wall of the pharynx, i.e. the part above the attachment of the Stylopharyngeus.

Applied Anatomy.—In young children the presence of adenoid growths in the nose and nasopharynx, with or without enlargement of the tonsils, produces a characteristic formity of the face, the "adenoid facies," by obstructing respiration through the nose and making mouth-breathing more or less obligatory. As the child has to keep its mouth open in order to breathe, the bony palate and alveolar arch are habitually out of contact with the dorsum of the tongue; lacking its pressure, they develop with an abnormally high and forward projection. Thus the hard palate becomes narrowed laterally, and the projecting alveolar processes afford insufficient room for the permanent teeth, which appear crowded, irregularly set, and overlapping as the child grows up, and overhang those in the lower jaw. The facial surfaces of the maxillæ become pinched together, with narrowing of the nasal fossæ and maxillary air-sinuses. The nose itself shows abnormality in shape of two chief types: (1) The bridge remaining normal, the apex looks thin and pinched because the alæ fall inwards from disuse of the dilator muscles, and the nares become elongated, narrow, and barely capable of voluntary dilatation; there is often a depression in the region of the lateral alar cartilage. (2) Less commonly the bones forming the bridge of the nose are pressed apart by the underlying adenoid growths, making it appear thicker and broader than normal; the Dilatatores narium atrophy from disuse, and the nares look unduly small and rounded. In all cases of adenoids the upper lip is drawn up, still further exposing the projecting front upper teeth. The face is lengthened by dropping of the lower jaw; the whole expression of the child is highly characteristic, suggesting vacuity and inattention, the latter being due to the deafness so often associated with nasal obstruction and caused by blocking of the pharyngeal orifices of the auditory tubes.

The internal carotid artery is in close relation with the pharynx, so that its pulsations can be felt through the mouth. It has been occasionally wounded by sharp-pointed instruments, introduced into the mouth and thrust through the wall of the pharynx. In aneurysm of this vessel in the neck, the tumour necessarily bulges into the pharynx, as this is the direction in which it meets with the least resistance, nothing lying between the vessel and the mucous membrane except the thin Constrictor muscles, whereas on the lateral side there are the dense cervical fascia, the muscles descending from the styloid process, and the margin of the Sternocleidomastoideus.

The mucous membrane of the pharynx is very vascular, and is often the seat of inflammation, frequently of a septic character, since the numerous recesses are prone to lodge micro-organisms. And, in addition, owing to its exposed situation, the mucous membrane is liable to be irritated by agents introduced during inspiration. The inflammation may be attended with serious consequences: it may extend up the auditory tube and involve the middle ear; it may spread to the entrance of the larynx, causing œdema and seriously interfering with respiration; or, invading the lymphatics, it may spread to the loose areolar tissue surrounding the pharyngeal wall, and may extend far and wide, sometimes into the posterior mediastinal cavity along the œsophagus. Abscess may form in the connective tissue behind the pharynx, between it and the vertebral column, constituting what is known as *retropharyngeal abscess*. Acute retropharyngeal abscesses are generally due to suppuration of the lymph-glands, and should be opened through the mouth, as the pus is in front of the prevertebral fascia. Chronic retropharyngeal abscesses are generally due to disease of the upper cervical vertebræ, and the pus is then behind the prevertebral fascia; the incision should therefore be made at the posterior border of the Sternocleidomastoideus, and the pus evacuated behind the carotid vessels.

Abscess also occurs in children, underneath the mucous membrane, between it and the pharyngeal aponeurosis. The condition usually arises from a peritonsillar inflammation, which spreads backwards. In some cases an enormous swelling may form, which bulges forwards the soft palate and gives rise to respiratory obstruction. In such cases the abscess should be opened through the mouth with the child in the inverted position, so as to prevent the first gush of pus from entering the larynx.

CC-0. In Public Domain. Gurukul Kangri Collection, Haridwar

Digitized by Arya Samaj Foundation Chennai and eGangotri

Foreign bodies not infrequently become lodged in the pharynx, and most usually at its termination at about the level of the cricoid cartilage, just beyond the reach of the finger, as the distance from the arch of the teeth to the commencement of the œsophagus is about 15 cm.

The Œsophagus (fig. 1085)

The **œsophagus, or gullet,** is a muscular canal, from 23 cm. to 25 cm. long, extending from the pharynx to the stomach. It begins in the neck at the lower border of the cricoid cartilage, opposite the sixth cervical vertebra, where it is continuous with the lower end of the pharynx. It descends along the front of the vertebral column, through the superior and posterior mediastinal cavities, pierces the Diaphragm opposite the tenth thoracic vertebra, and ends at the cardiac orifice of the stomach at the level of the eleventh thoracic vertebra. The general direction of the œsophagus is vertical; but it presents two slight curves in its course. At its commencement it is placed in the middle line; but it inclines to the left side as far as the root of the neck, gradually passes again to the middle line, which it reaches at the level of the fifth thoracic vertebra, and again deviates to the left as it passes forwards to the œsophageal hiatus in the Diaphragm. The œsophagus also presents anteroposterior flexures corresponding to the curvatures of the cervical and thoracic portions of the vertebral column. It is the narrowest part of the digestive tube, and is constricted (*a*) at its commencement, (*b*) where it is crossed by the left bronchus, and (*c*) where it pierces the Diaphragm.

Fig. 1085.—The œsophagus.

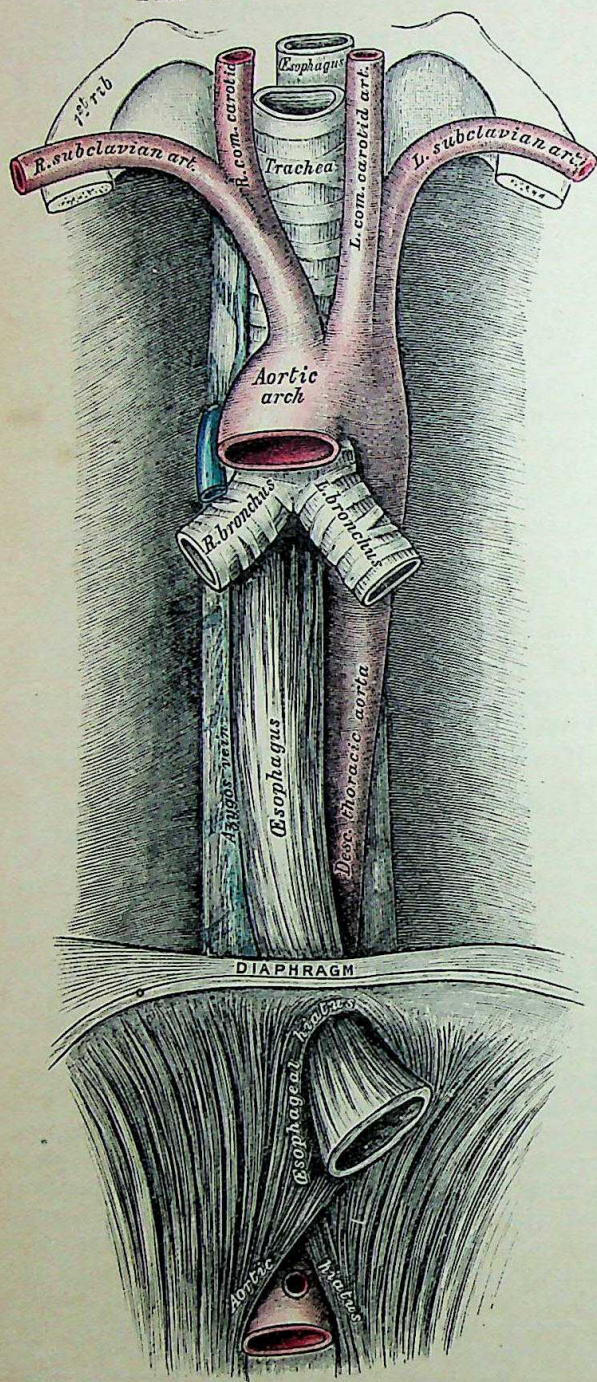

Relations.—The **cervical portion** of the œsophagus (fig. 1034) is in relation, *in front*, with the trachea, and at the lower part of the neck, where it projects to the left side, with the thyreoid gland; *behind* it are the vertebral column and Longus colli muscles; *on either side* it is in relation with the common carotid artery (especially the left), and parts of the lobes of the thyreoid gland; the recurrent nerves ascend, one on either side, in the groove between it and the trachea; to its left side is the thoracic duct.

The **thoracic portion** of the œsophagus (figs. 1035-6, 1042-3, 1045) is at first situated in the superior mediastinal cavity between the trachea and the vertebral column, a little to the left of the median line. It then passes behind and to the right of the aortic arch and descends in the posterior mediastinal

CC-0. In Public Domain. Gurukul Kangri Collection, Haridwar

Digitized by Arya Samaj Foundation Chennai and eGangotri

avity, along the right side of the descending aorta, then runs in front and a little to the left of the aorta, and enters the abdomen through the Diaphragm at the level of the tenth thoracic vertebra. It is in relation, *in front*, with the trachea, the left bronchus, the pericardium, and the Diaphragm; *behind*, it rests upon the vertebral column, the Longus colli muscles, the right aortic intercostal arteries, the thoracic duct, and the hemiazygos and accessory hemiazygos veins; and below, near the Diaphragm, upon the front of the aorta. On its *left* side, in the superior mediastinal cavity are the terminal part of the aortic arch, the left subclavian artery, the thoracic duct, and left pleura, while running upwards in the groove between it and the trachea is the left recurrent nerve; below, it is in relation with the descending thoracic aorta and the left pleura. On its *right* side are the right pleura, and the azygos vein, the latter being overlapped by the œsophagus. Below the roots of the lungs the vagus nerves descend in close contact with it, the right nerve behind, and the left in front of it; the two nerves unite to form a plexus around the tube. In the lower part of the posterior mediastinal cavity the thoracic duct lies behind and to the right of the œsophagus; higher up, it is placed behind it, and crossing to the left about the level of the fourth thoracic vertebra, is continued upwards on its left side.

The **abdominal portion** of the œsophagus is named the *antrum cardiacum*; lies in the œsophageal groove on the posterior surface of the left lobe of the liver. It measures about 1·25 cm. in length, and is covered by peritoneum in front and on its left side. It is conical in shape, and curved sharply to the left, the base of the cone being continuous with the cardiac orifice of the stomach (fig. 1085).

FIG. 1086.—A transverse section through the middle of the œsophagus. (From a drawing by V. Horsley.) Moderately magnified. (From Quain's Elements of Anatomy, Vol. II. Pt. II.)

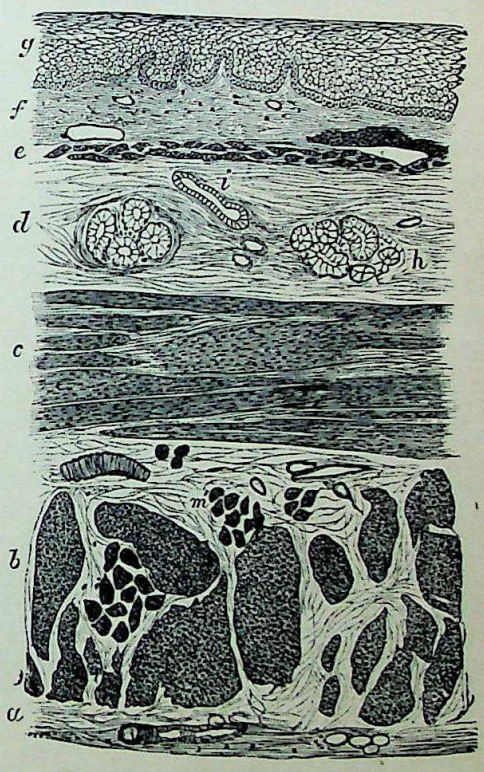

a. Fibrous covering. *b*. Divided fibres of longitudinal muscular coat. *c*. Transverse muscular fibres. *d*. Submucous or areolar layer. *e*. Muscularis mucosæ. *f*. Mucous membrane, with vessels and part of a lymphoid nodule. *g*. Stratified epithelial lining. *h*. Mucous gland. *i*. Gland duct. *m'*. Striated muscular fibres cut across.

Structure (fig. 1086).—The œsophagus has four coats: an external or fibrous, a muscular, a submucous or areolar, and an internal or mucous.

The *fibrous coat* consists of a layer of areolar tissue, containing many elastic fibres.

The *muscular coat* is composed of two layers of considerable thickness: an external of longitudinal and an internal of circular fibres.

The *longitudinal fibres* form a complete investment for nearly the whole of the œsophagus, but at the upper part of the back of the tube, at a point between 3 cm. and 4 cm. below the cricoid cartilage, they diverge from the middle line and form two longitudinal fasciculi which incline upwards and forwards to the front of the tube. Here they pass beneath the lower fibres of the Constrictor pharyngis inferior and end in a tendon, which is attached to the upper part of the ridge on the posterior surface of the lamina of the cricoid cartilage. The V-shaped interval between the diverging longitudinal fasciculi is filled by the circular fibres of the œsophagus, thinly covered below by some decussating longitudinal fibres, and above by the overlapping lower edge of the Constrictor pharyngis inferior.

Accessory slips of muscular fibres sometimes occur between the œsophagus and the left pleura, and between the œsophagus and the root of the left bronchus.

The *circular fibres* are continuous superiorly, on the posterior aspect, with the Constrictor pharyngis inferior; anteriorly, the uppermost are inserted into the lateral margins of the tendon of the two longitudinal fasciculi.*

The muscular fibres in the upper part of the œsophagus are of a red colour, and consist entirely of the striped variety; but in the lower part they consist for the most part of unstriped fibres.

* Williamina Abel, *Journal of Anatomy and Physiology*, vol. xxvii.

CC-0. In Public Domain. Gurukul Kangri Collection, Haridwar

Digitized by Arya Samaj Foundation Chennai and eGangotri

The *areolar or submucous coat* connects loosely the mucous and muscular coats. It contains the larger blood-vessels and nerves, as well as mucous glands.

The *mucous coat* is thick, of a reddish colour above, and pale below. It is disposed in longitudinal folds, which disappear on distension of the tube. It consists of (1) a layer of stratified squamous epithelium, lining the tube, (2) a layer of connective tissue, papillæ from which project into the epithelium, and (3) the muscularis mucosæ, a layer of longitudinally arranged non-striped muscular fibres. At the commencement of the œsophagus the muscularis mucosæ is absent, or only represented by a few scattered bundles; lower down it forms a considerable stratum.

The *œsophageal glands* are small compound racemose glands of the mucous type; they are lodged in the submucous tissue, and each opens upon the surface by a long duct.

Vessels and Nerves.—The *arteries* supplying the œsophagus are derived from the inferior thyreoid branch of the thyreocervical trunk, from the descending thoracic aorta, from the left gastric branch of the cœliac artery, and from the left inferior phrenic branch of the abdominal aorta. They have for the most part a longitudinal direction. The *veins* from the lower end of the œsophagus open into the left gastric vein, which is a tributary of the portal vein. The *lymphatics* are described on p. 778.

The *nerves* are derived from the vagus nerves and from the sympathetic trunks; they form a plexus, in which are groups of ganglion-cells, between the two layers of the muscular coat, and a second plexus in the submucous tissue.

Applied Anatomy.—The œsophagus may be obstructed by foreign bodies, and also by changes in its coats producing stricture, or by pressure on it from without by new growths or aneurysm, &c. The commoner forms of stricture are: (1) the fibrous, due to cicatrisation following destruction of tissue, the result of swallowing boiling or corrosive fluids—here dilatation of the stricture may be carried out; and (2) malignant, usually epitheliomatous in its nature. This may be situated either at the upper end of the tube, opposite the cricoid cartilage, or at its lower end at the cardiac orifice, but is most commonly found in that part of the tube which is crossed by the left bronchus. If, in these cases, the patient is losing weight from insufficient nourishment, the operation of gastrostomy may be performed in order to avoid death from starvation; death, however, most commonly occurs from ulceration of the growth into the mediastinal cavity or air-passages. In cases of non-malignant stricture of the œsophagus it may be necessary to dilate the canal by a bougie, when it is of importance that the direction of the œsophagus and its relations to surrounding parts should be remembered. In malignant disease of the œsophagus, where its tissues have become softened from infiltration of the growth, the passage of a bougie is a very dangerous procedure, as a false passage may easily be made, and the instrument may pass into the mediastinal cavity or into one or other pleural cavity, or even into the pericardium.

In cases of destruction of the œsophagus, and consequent symptoms of stricture, produced by an aneurysm of some part of the aorta pressing upon this tube, the passage of a bougie will only hasten the fatal issue, and therefore it is essential that the presence of an aneurysm should be excluded before such an attempt be made in any form of œsophageal obstruction.

In passing a bougie the left forefinger should be introduced into the mouth, and the epiglottis felt for, care being taken not to throw the head too far backwards. The bougie is then to be passed beyond the finger until it touches the posterior wall of the pharynx. The patient is now asked to swallow, and at the moment of swallowing, the bougie is passed gently onwards, any force being carefully avoided.

It occasionally happens that a foreign body becomes impacted in the œsophagus, and can neither be brought upwards nor moved downwards. When all ordinary means for its removal have failed, open operation by an incision in the neck is the only resource left. This, of course, can only be performed when the foreign body is not very low down. If it is allowed to remain, extensive inflammation and ulceration of the œsophagus may ensue, with the development of suppuration and cellulitis in the surrounding tissues.

THE ABDOMEN

The **abdomen** is the largest cavity in the body. The roof of the cavity is formed by the Diaphragm, which extends as a dome over the abdomen, so that the cavity ascends into the bony thorax, reaching on the right side, in the mammary line, to the upper border of the fifth rib; on the left side it falls below this level by about 2·5 cm. The floor is formed by the muscles and fasciæ of the pelvic and urogenital diaphragms (pp. 482-491).

In order to facilitate description the abdomen is artificially divided into two parts: an upper, larger part, the *abdomen proper*; and a lower, smaller part, the *pelvis*. These two parts are continuous with one another through the superior aperture of the lesser pelvis.

CC-0. In Public Domain. Gurukul Kangri Collection, Haridwar

Digitized by Arya Samaj Foundation Chennai and eGangotri

FIG. 1087.—A front view of the thoracic and abdominal viscera.

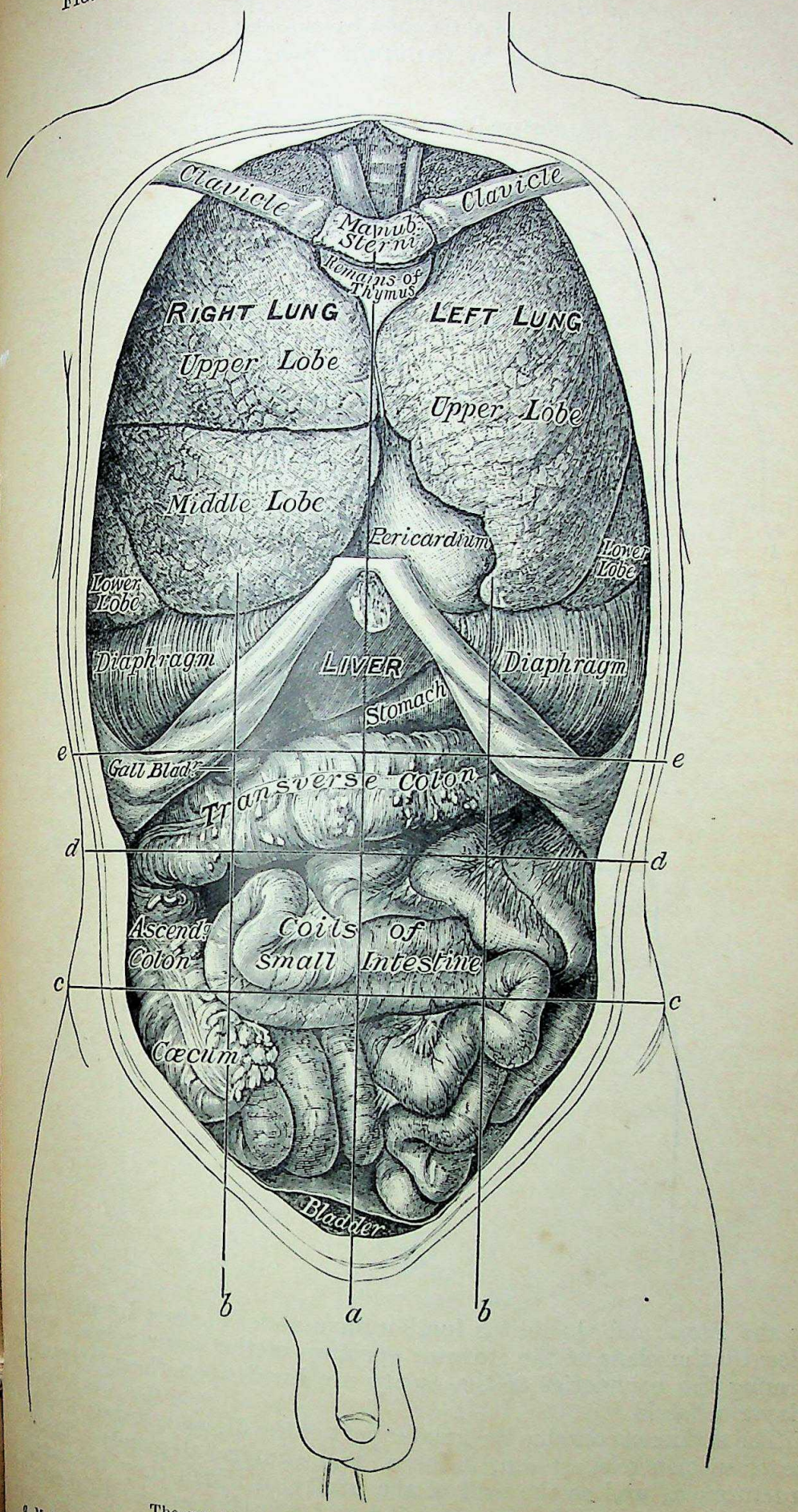

The greater omentum has been removed.

a. Median plane. *b b.* Lateral planes. *c c.* Transtubercular plane. *d d.* Subcostal plane. *e e.* Transpyloric plane.

CC-0. In Public Domain. Gurukul Kangri Collection, Haridwar

Digitized by Arya Samaj Foundation Chennai and eGangotri

The abdomen proper differs from the other cavities of the body in being bounded for the most part by muscles and fasciæ, so that its capacity and shape can vary according to the conditions of the viscera it contains.

It is bounded *in front* and *at the sides* by the abdominal and Iliacus muscles, and the iliac bones; *behind* by the lumbar part of the vertebral column and

FIG. 1088.—The surface lines on the front of the thorax and abdomen.

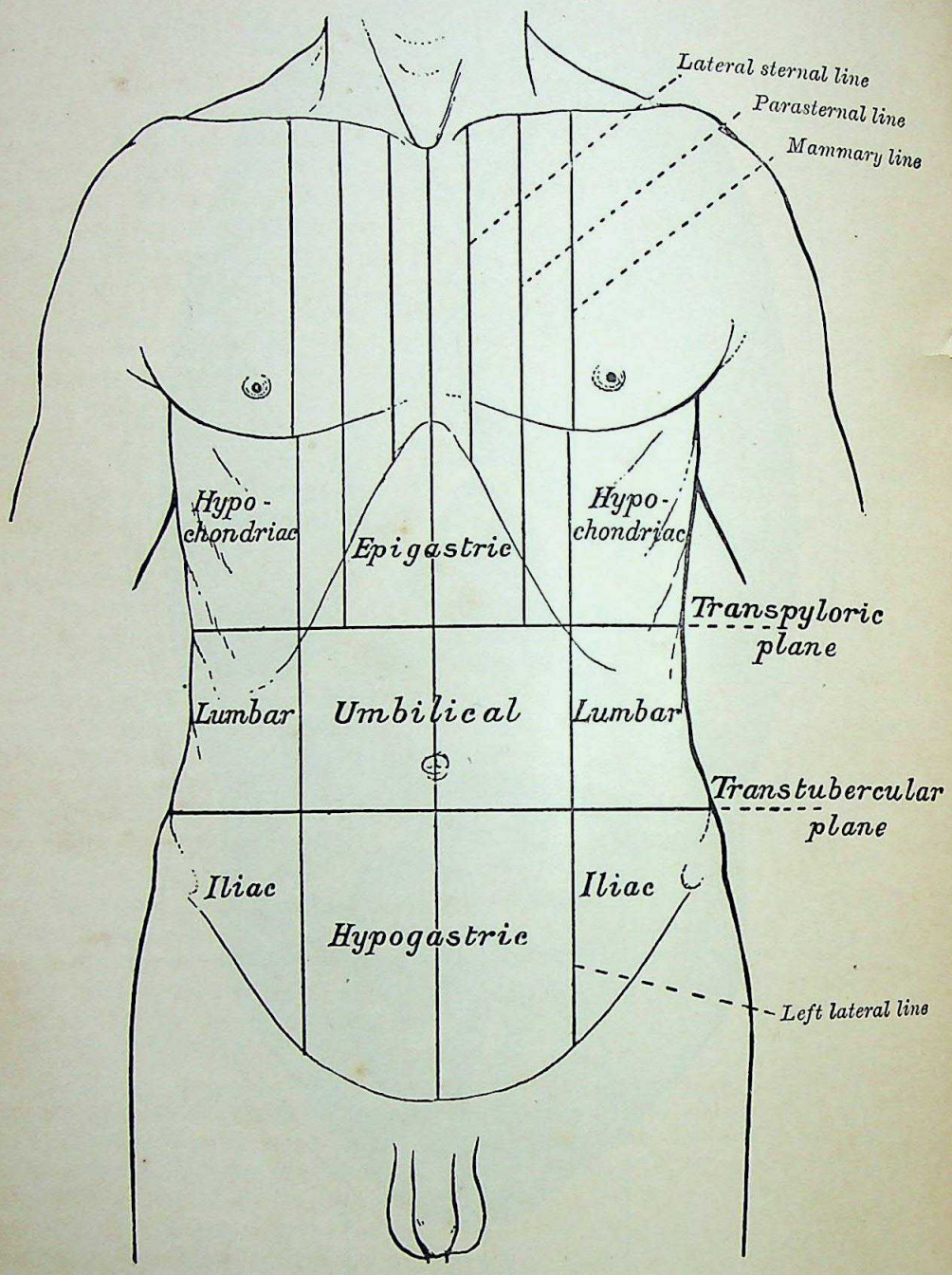

by the Psoas and Quadratus lumborum muscles; *above* by the Diaphragm; *below* by the plane of the superior aperture of the lesser pelvis. The muscles forming the boundaries of the cavity are lined upon their inner surfaces by a layer of fascia.

The abdomen contains the greater part of the digestive tube; it also contains the liver, pancreas, spleen, kidneys, and suprarenal glands. Most of these structures, as well as the wall of the cavity in which they are contained, are more or less covered by an extensive and complicated serous membrane, the *peritoneum.*

Regions.—For convenience of description of the viscera, as well as of reference to the morbid conditions of the contained parts, the abdomen is

CC-0. In Public Domain. Gurukul Kangri Collection, Haridwar

Digitized by Arya Samaj Foundation Chennai and eGangotri

divided into nine regions by imaginary planes, two horizontal and two sagittal, passing through the cavity, the edges of the planes being indicated by lines drawn on the surface of the body (fig. 1088). The upper horizontal plane, or transpyloric plane of Addison, is indicated by a line encircling the body at a level midway between the jugular notch and the symphysis pubis, the lower horizontal plane by a line carried round the trunk at a level midway between the transpyloric plane and the symphysis pubis. The latter plane is practically the same as the *transtubercular* or *intertubercular plane* of Cunningham, who pointed out * that its level corresponds with the prominent and easily defined tubercle on the iliac crest about 5 cm. behind the anterior superior iliac spine. By means of these planes the abdomen is cut into three zones; each of these is further subdivided into three regions by the two sagittal planes, which are indicated on the surface by lines drawn vertically through points halfway between the anterior superior iliac spines and the symphysis pubis.†

The middle region of the upper zone is the *epigastric*, and the lateral regions, the *right and left hypochondriac*. The central region of the middle zone is the *umbilical*, and the lateral regions are the *right and left lumbar*. The middle region of the lower zone is the *hypogastric*, and the lateral regions are the *right and left iliac or inguinal* (fig. 1088).

The pelvis is that portion of the abdominal cavity which lies below and behind a plane passing through the promontory of the sacrum, the arcuate lines of the hip-bones, and the pubic crests; it contains the urinary bladder, the sigmoid colon, the rectum, a few coils of the small intestine, and some of the generative organs.

When the anterior abdominal wall is removed, the viscera are partly exposed as follows: above and to the right side is the liver, situated chiefly under the shelter of the right ribs and their cartilages, but extending across the middle line and reaching for some distance below the level of the xiphoid process. To the left of the liver is the stomach, from the lower border of which an apron-like fold of peritoneum, the *greater omentum*, descends for a varying distance, and obscures, to a greater or lesser extent, the other viscera. Below the greater omentum, however, some of the coils of the small intestine can generally be seen, while in the right iliac region the cæcum, and in the left iliac region the iliac portion of the descending colon, are partly exposed. The urinary bladder occupies the anterior part of the pelvis, and, if distended, will project above the symphysis pubis; the rectum is placed in the concavity of the sacrum, but is usually obscured by coils of the small intestine. The sigmoid colon may be between the rectum and the bladder.

When the stomach is followed from left to right it is seen to be continuous with the first part of the small intestine (duodenum), the point of continuity being marked by a thickened ring which indicates the position of the pyloric sphincter. The duodenum passes towards the under surface of the liver, and then, curving downwards, is lost to sight. If, however, the greater omentum and transverse colon be thrown upwards over the chest, the inferior part of the duodenum will be observed passing across the vertebral column towards the right side, where it becomes continuous with the coils of the jejunum and ileum. These measure about six metres in length, and if followed downwards the ileum is seen to end in the right iliac fossa by opening into the cæcum, the commencement of the large intestine. From the cæcum the large intestine takes an arched course, passing at first upwards on the right side, then across the middle line and downwards on the left side, and forming respectively the ascending, transverse, and descending parts of the colon. In the pelvis it assumes the form of a loop, termed the sigmoid colon, and ends in the rectum.

The spleen lies behind the stomach in the left hypochondriac region, and may be in part exposed by pulling the stomach over towards the right side.

The glistening appearance of the deep surface of the abdominal wall and of the surfaces of the exposed viscera is due to the fact that the former is lined, and the latter are more or less completely covered, with a serous membrane, the *peritoneum*.

* *Journal of Anatomy and Physiology*, vol. xxvii. † *Ibid.*, vols. xxxiii., xxxiv., xxxv.

CC-0. In Public Domain. Gurukul Kangri Collection, Haridwar

Digitized by Arya Samaj Foundation Chennai and eGangotri

The Peritoneum

The **peritoneum** is the largest serous membrane in the body, and consists, in the male, of a closed sac, a part of which is applied against the abdominal parietes, while the remainder is reflected over the contained viscera. In the female the free ends of the uterine tubes open into the peritoneal cavity. The portion which lines the parietes is named the *parietal* portion of the peritoneum; that which is reflected over the contained viscera constitutes the *visceral* portion of the peritoneum. The *free surface* of the membrane is smooth, covered with a layer of flattened endothelium, and lubricated by a small quantity of serous fluid. Hence the viscera can glide on the wall of the cavity or on one another with the least possible amount of friction. The *attached surface* is rough, being connected to the viscera and inner surface of the parietes by means of areolar tissue, termed the *subserous areolar tissue*. The parietal portion is loosely connected with the fascial lining of the abdomen and pelvis, but is more closely adherent to the under surface of the Diaphragm, and also in the middle line of the anterior abdominal wall.

The parietal and visceral layers of the peritoneum are in actual contact, but the potential space between them is named the *peritoneal cavity*. The peritoneal cavity consists of (1) a main portion, and (2) a large diverticulum, the *omental bursa*, which is situated behind the stomach and adjoining structures; the neck or communication between the main cavity and the omental bursa is termed the *epiploic foramen* (foramen of Winslow). Formerly the main portion of the cavity was described as the greater sac, and the omental bursa as the lesser sac, of the peritoneum.

The peritoneum differs from the other serous membranes of the body in presenting a much more complex arrangement, and one that can only be clearly understood by following the development of the digestive tube. The student therefore is advised to preface his study of the peritoneum by reading the chapter dealing with this subject (p. 132).

To trace the membrane from one viscus to another, and from the viscera to the parietes, it is necessary to follow its continuity in the vertical and horizontal directions, and it will be found simpler to describe the main portion of the cavity and the omental bursa separately.

Vertical disposition of the main peritoneal cavity (greater sac) (fig. 1089).—It is convenient to trace this from the back of the anterior abdominal wall at the level of the umbilicus. On following the peritoneum upwards from this level it is seen to be reflected around a fibrous cord, the *ligamentum teres*, or *obliterated umbilical vein*, which reaches from the umbilicus to the under surface of the liver. This reflection forms a somewhat triangular fold, the *falciform ligament of the liver*, attaching the upper and anterior surfaces of the liver to the Diaphragm and abdominal wall. With the exception of the line of attachment of this ligament the peritoneum covers the whole of the under surface of the anterior part of the Diaphragm, and is reflected from it on to the upper surface of the right lobe of the liver as the *superior layer of the coronary ligament*, and on to the upper surface of the left lobe as the *superior layer of the left triangular ligament* of the liver. Covering the upper and anterior surfaces of the liver, it is continued round its sharp margin to the under surface, where it has the following relations: (*a*) It covers the inferior surface of the right lobe and is reflected from the posterior part of this lobe to the right suprarenal gland and the upper end of the right kidney, forming the *inferior layer of the coronary ligament*; a special fold, the *hepatorenal ligament*, is frequently present between the inferior surface of the liver and the front of the right kidney. From the right kidney it is carried downwards to the duodenum and right colic flexure and medialwards in front of the inferior vena cava, where it is continuous with the posterior wall of the omental bursa. Between the two layers of the coronary ligament there is a large triangular surface of the liver devoid of peritoneal covering: this is named the *bare area* of the liver, and is attached to the Diaphragm by areolar tissue. Towards the right margin of the liver the two layers of the coronary ligament gradually approach one another, and ultimately fuse to form a small triangular fold connecting the right lobe of the liver to the Diaphragm, and named the *right triangular ligament* of the liver. The apex of the bare area corresponds with the point of meeting

CC-0. In Public Domain. Gurukul Kangri Collection, Haridwar

Digitized by Arya Samaj Foundation Chennai and eGangotri

of the two layers of the coronary ligament, its base with the fossa for the inferior vena cava. (*b*) It covers the lower surface of the quadrate lobe of the liver, the under and lateral surfaces of the gall-bladder, and the under surface and posterior border of the left lobe of the liver; it is then reflected from the upper surface of the left lobe to the Diaphragm as the *inferior layer of the left triangular ligament*, and from the porta of the liver and the fossa for the ductus venosus to the lesser curvature of the stomach and the first 2·5 cm. of the duodenum as the anterior layer of the *hepatogastric* and *hepatoduodenal ligaments*, which together constitute the *lesser omentum*. If this layer of the lesser omentum be followed to the right it will be found to turn round the hepatic artery, bile-duct, and portal vein, and become continuous with the anterior wall of

Fig. 1089.—The vertical disposition of the peritoneum. (Main cavity, red; omental bursa, blue).

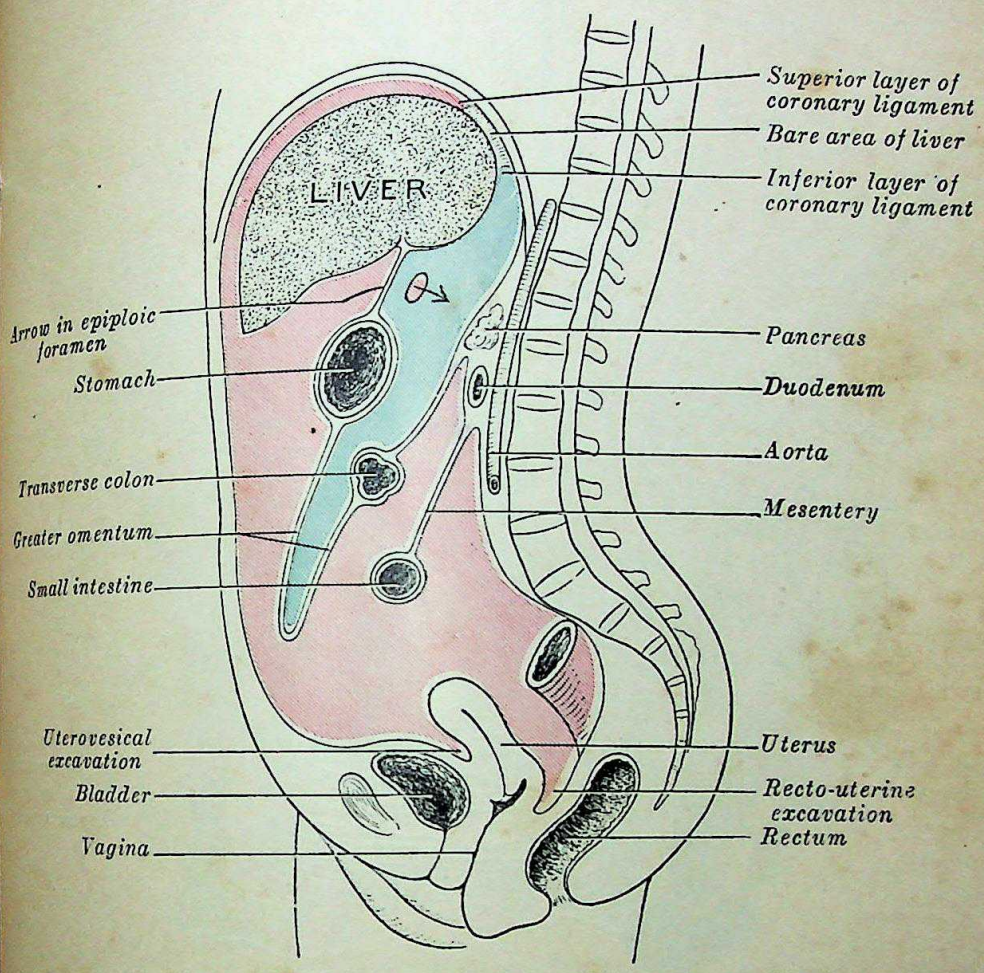

omental bursa, forming a free folded edge of peritoneum. Traced downwards, the lesser omentum covers the anterosuperior surface of the stomach and the commencement of the duodenum, and is carried down into a large free fold, known as the *gastrocolic ligament* or *greater omentum*. Reaching the free margin of this fold, it is reflected upwards to cover the under and posterior surfaces of the transverse colon, and thence to the posterior abdominal wall as the inferior layer of the *transverse mesocolon*. It reaches the abdominal wall below the head and anterior border of the pancreas, is then carried down over the lower part of the head and over the inferior surface of the pancreas on the anterior mesenteric vessels, and thence to the small intestine as the anterior layer of the *mesentery*. It encircles the intestine, and subsequently may be regarded, as the posterior layer of the mesentery, upwards and backwards to the abdominal wall. From this it sweeps down over the aorta into the pelvis, where it invests the sigmoid (pelvic) colon, and attaches it to the pelvic wall by a fold named the *sigmoid mesocolon* (pelvic mesocolon). Leaving first the sides and then the front of the rectum, it is reflected on to the seminal vesicles and fundus of the urinary bladder, and after covering the upper surface of that

CC-0. In Public Domain. Gurukul Kangri Collection, Haridwar

Digitized by Arya Samaj Foundation Chennai and eGangotri

viscus, is carried along the middle and lateral umbilical ligaments (fig. 1090) on to the back of the abdominal wall to the level from which a start was made.

Between the rectum and the bladder it forms, in the male, a pouch, the *rectovesical excavation*, the bottom of which is slightly below the level of the upper ends of the vesiculæ seminales, and about 7·5 cm. from the orifice of the anus. When the bladder is distended, the peritoneum is carried up with it so that a considerable part of the anterior surface of the bladder lies directly against the abdominal wall without the intervention of peritoneal membrane. In the female the peritoneum is reflected from the rectum over the posterior

FIG. 1090.—The lower part of the anterior abdominal wall. Posterior aspect. The peritoneum is in place, and the various cords are shining through. (After Joessel.)

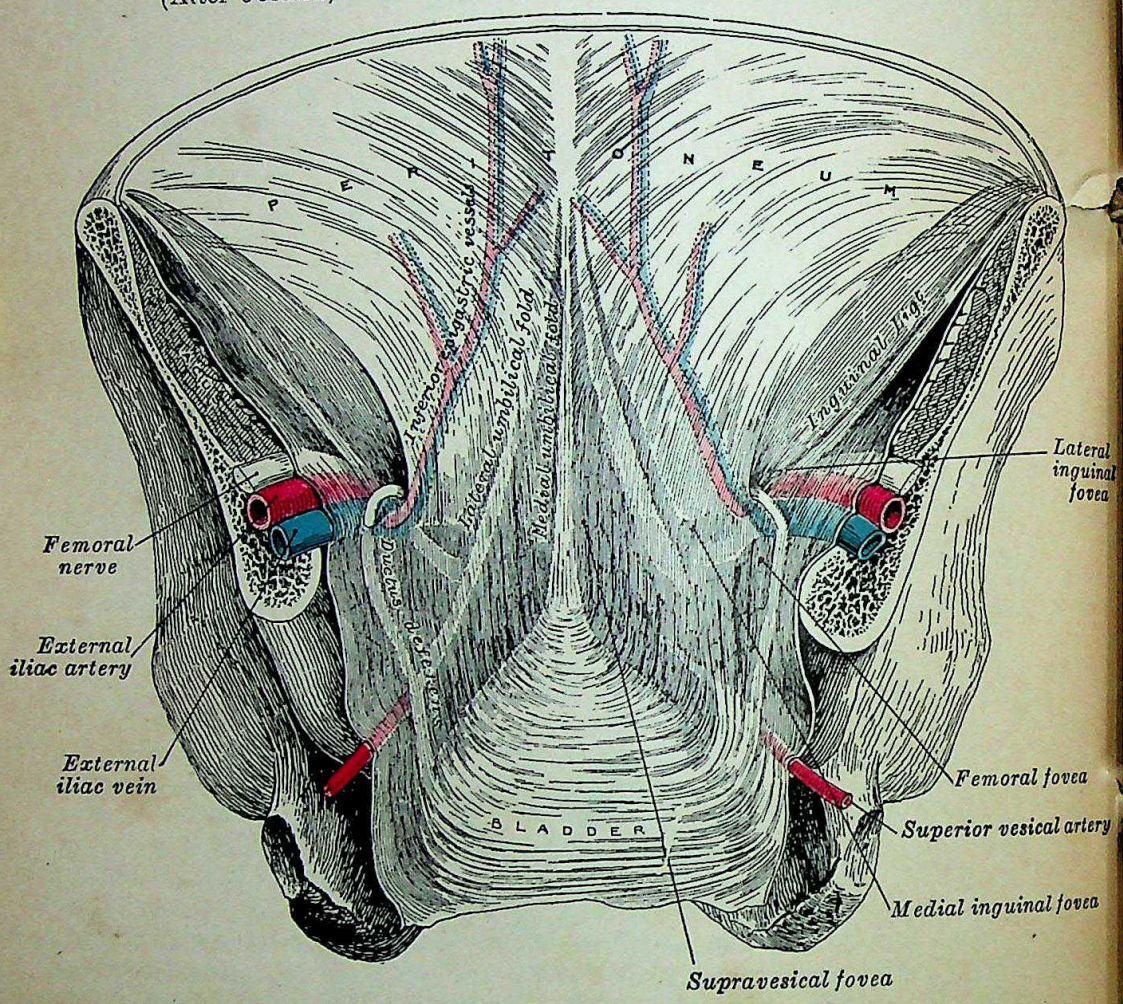

vaginal fornix to the cervix and body of the uterus, forming the *recto-uterine excavation* or *pouch of Douglas*. It is continued over the intestinal surface and fundus of the uterus on to its vesical surface, which it covers as far as the junction of the body and neck of the uterus, and then to the bladder, forming here a second, but shallower, pouch, the *vesico-uterine excavation*. It is also reflected from the sides of the uterus to the lateral walls of the pelvis as two expanded folds, the *broad ligaments of the uterus*, in the free margin of each of which is the uterine tube.

Vertical disposition of the omental bursa (lesser sac) (fig. 1089).—A start may be made in this case on the posterior abdominal wall at the anterior border of the pancreas. From this region the peritoneum may be followed upwards over the anterior surface of the pancreas to the inferior surface of the Diaphragm, and thence on the caudate lobe and caudate process of the liver to the fossa for the ductus venosus and the porta hepatis. Traced to the right, it is continuous over the inferior vena cava with the posterior wall of the main cavity. From the liver it is carried downwards to the lesser

CC-0. In Public Domain. Gurukul Kangri Collection, Haridwar

Digitized by Arya Samaj Foundation Chennai and eGangotri

curvature of the stomach and the commencement of the duodenum as the posterior layer of the lesser omentum, and is continuous on the right, round the hepatic artery, bile-duct, and portal vein, with the anterior layer of this omentum. The posterior layer of the lesser omentum is carried down as a covering for the postero-inferior surface of the stomach and commencement of the duodenum, and is continued downwards as the deep layer of the gastro-colic ligament or greater omentum. From the free margin of this fold it is reflected upwards to the anterior and superior surfaces of the transverse colon, and thence as the superior layer of the transverse mesocolon to the anterior border of the pancreas, the level from which a start was made. It will be seen that the loop formed by the wall of the omental bursa below the transverse colon follows, and is closely applied to, the deep surface of that formed by the peritoneum of the main cavity, and that the greater omentum or large fold of

Fig. 1091.—The peritoneum of the male pelvis. (Dixon and Birmingham.)

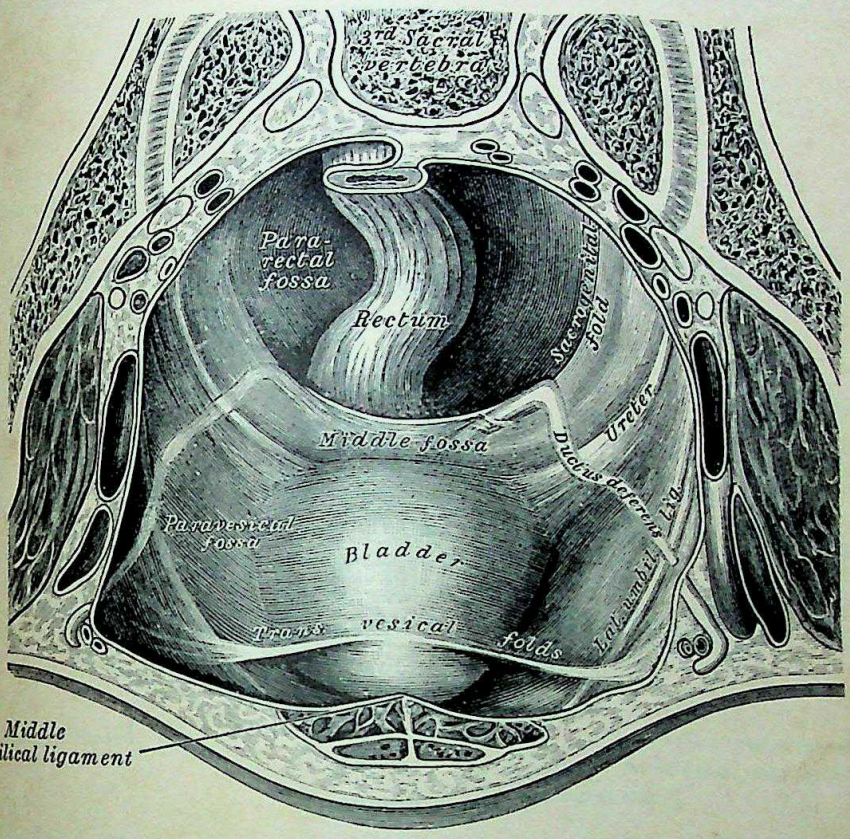

peritoneum which hangs in front of the small intestine therefore consists of four layers, two anterior and two posterior, separated by the potential cavity of the omental bursa. The transverse colon lies between the two posterior layers.

Horizontal disposition of the peritoneum.—Below the transverse colon the arrangement is simple, as it includes only the main cavity; above the level of the transverse colon it is more complicated on account of the presence of the omental bursa. Below the transverse colon it may be considered in the two regions, viz. in the pelvis and in the abdomen proper.

(1) *In the pelvis.*—The peritoneum here follows closely the surfaces of the pelvic viscera and the inequalities of the pelvic walls, and presents important differences in the two sexes. (*a*) *In the male* (fig. 1091) it encircles the sigmoid colon, from which it is reflected to the posterior wall of the pelvis as a fold, the *sigmoid mesocolon*. It leaves the sides and, finally, the front of the rectum, and is continued over the upper parts of the seminal vesicles to the upper surface of the bladder; on either side of the rectum it forms a fossa, the *para-rectal fossa*, which varies in size with the distension of the rectum. In front of the rectum the peritoneum forms the rectovesical excavation, which is bounded laterally by peritoneal folds extending from the sides of the bladder

CC-0. In Public Domain. Gurukul Kangri Collection, Haridwar

Digitized by Arya Samaj Foundation Chennai and eGangotri

to the rectum and sacrum. These folds are known, from their position, as the *rectovesical or sacrogenital folds*. The peritoneum of the anterior pelvic wall covers the superior surface of the bladder, and on either side of this viscus forms a depression, termed the *paravesical fossa*, which is limited laterally by the fold of peritoneum covering the ductus deferens. The size of this fossa is dependent on the state of distension of the bladder, and when the bladder is empty, a variable fold of peritoneum, the *plica vesicalis transversa*, divides the fossa into two portions. On the peritoneum between the paravesical and pararectal fossæ the only elevations are those produced by the ureters and the hypogastric vessels. (*b*) *In the female*, pararectal and paravesical fossæ similar to those in the male are present; the lateral limit of the paravesical fossa is the peritoneum investing the round ligament of the uterus. The rectovesical excavation is, however, divided by the uterus and vagina into a small anterior vesico-uterine and a large, deep, posterior recto-uterine

Fig. 1092.—The horizontal disposition of the peritoneum in the lower part of the abdomen.

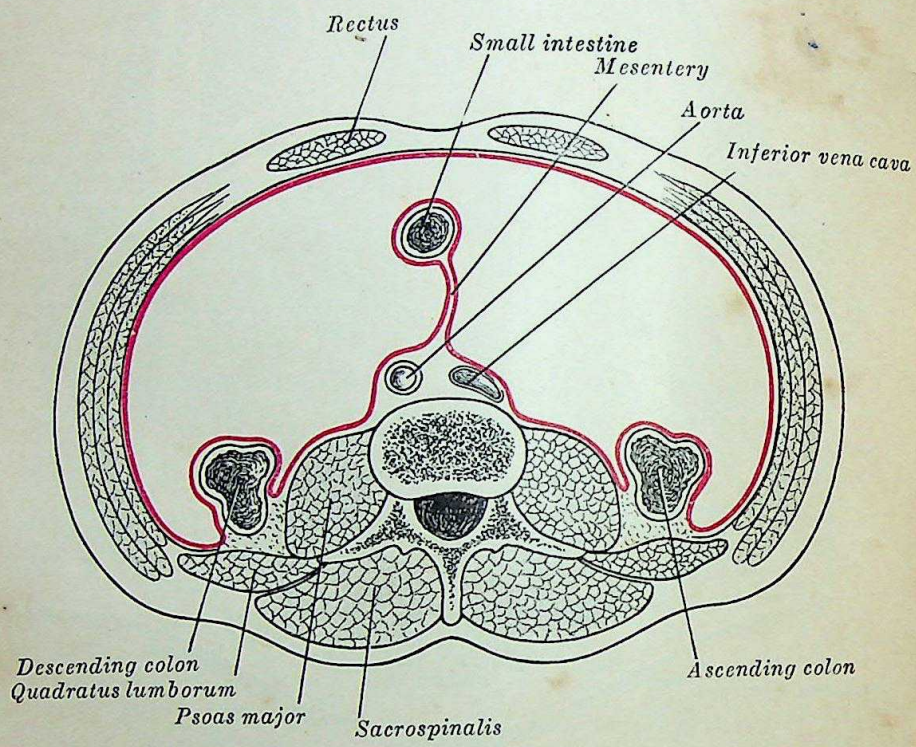

excavation. The sacrogenital folds form the margins of the latter, and are continued on to the back of the uterus and the posterior fornix of the vagina as a transverse fold, the *torus uterinus*. The *broad ligaments* extend from the sides of the uterus to the lateral walls of the pelvis; they contain in their free margins the uterine tubes, and in their posterior layers the ovaries. Below, the broad ligaments are continuous with the peritoneum on the lateral walls of the pelvis. On the lateral pelvic wall behind the attachment of the broad ligament, in the angle between the elevations produced by the obliterated hypogastric artery and the ureter, is a slight fossa, the *ovarian fossa*, in which the ovary normally lies.

(2) *In the lower abdomen* (fig. 1092).—Starting from the linea alba, below the level of the transverse colon, and tracing the continuity of the peritoneum in a horizontal direction to the right, the membrane covers the inner surface of the abdominal wall almost as far as the lateral border of the Quadratus lumborum; it encloses the cæcum and vermiform process, and is reflected over the sides and front of the ascending colon; it may then be traced over the duodenum, Psoas major, and inferior vena cava towards the middle line, whence it passes along the mesenteric vessels to invest the small intestine, and back again to the large vessels in front of the vertebral column, forming the *mesentery*, between the layers of which are contained the jejunum, ileum, the

CC-0. In Public Domain. Gurukul Kangri Collection, Haridwar

Digitized by Arya Samaj Foundation Chennai and eGangotri

mesenteric blood-vessels, nerves, lacteals, and lymph-glands. It is then continued over the left Psoas major; it covers the sides and front of the descending colon, and, reaching the abdominal wall, is carried on it to the middle line.

(3) *In the upper abdomen* (fig. 1093).—Above the transverse colon the omental bursa is superadded to the main cavity, and the communication between them through the epiploic foramen can be demonstrated.

(a) *Main cavity.*—Commencing on the posterior abdominal wall at the inferior vena cava, the peritoneum may be followed to the right over the front of the right suprarenal gland and upper part of the right kidney to the anterolateral abdominal wall. From the middle line of the anterior wall a backwardly reflected fold encircles the obliterated umbilical vein and forms the falciform ligament of the liver. Continuing to the left, the peritoneum lines the anterolateral abdominal wall and covers the lateral part of the front of the left kidney, and is reflected to the posterior border of the hilum of the spleen as the posterior

FIG. 1093.—The horizontal disposition of the peritoneum in the upper part of the abdomen.

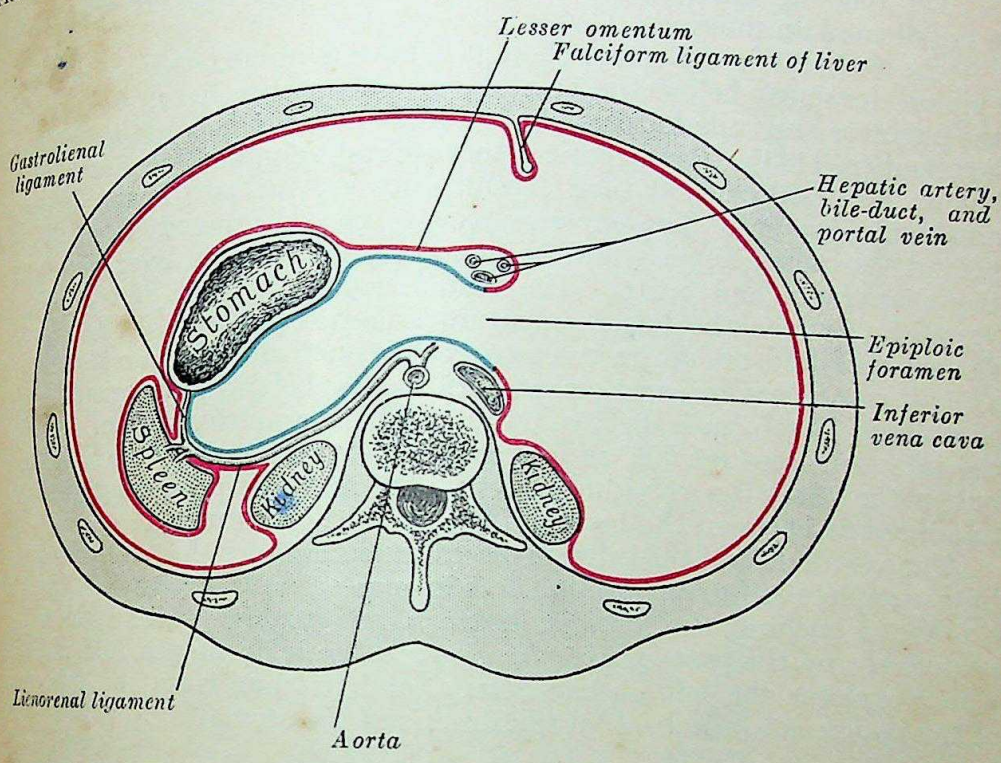

layer of the *lienorenal ligament.* It can be traced over the surfaces of the spleen to the front of the hilum, and thence to the cardiac end of the greater curvature of the stomach as the anterior layer of the *gastrolienal ligament* (gastrosplenic omentum). It covers the anterosuperior surface of the stomach and commencement of the duodenum, and ascends from the lesser curvature of the stomach to the liver as the anterior layer of the lesser omentum.

(b) *Omental bursa.*—On the posterior abdominal wall the peritoneum of the general cavity is continuous with that of the omental bursa in front of the inferior vena cava. Starting from here, the bursa may be traced across the kidney and over the medial part of the front of the left kidney to the hilum of the spleen where the peritoneum forms the anterior layer of the lienorenal ligament. From the spleen it is reflected to the stomach as the posterior layer of the gastrolienal ligament. It covers the postero-inferior surface of the stomach and commencement of the duodenum, and extends upwards to the liver as the posterior layer of the lesser omentum; the right margin of this layer is continuous round the hepatic artery, bile-duct, and portal vein with the wall of the main cavity. The lienal vessels run between the two layers of the lienorenal ligament, and the short gastric and left gastro-epiploic vessels between the two layers of the gastrolienal ligament.

The *epiploic foramen* (foramen of Winslow) (figs. 1089, 1093) is the communication between the main cavity and the omental bursa. It is bounded

CC-0. In Public Domain. Gurukul Kangri Collection, Haridwar

Digitized by Arya Samaj Foundation Chennai and eGangotri

in front by the free border of the lesser omentum, with the bile-duct, hepatic artery, and portal vein between its two layers; *behind* by the peritoneum covering the inferior vena cava; *above* by the peritoneum on the caudate process of the liver, and *below* by the peritoneum covering the commencement of the duodenum and the hepatic artery, the latter passing forwards below the foramen before ascending between the two layers of the lesser omentum.

The boundaries and the extent of the omental bursa will now be evident. It is bounded *in front*, from above downwards, by the caudate lobe of the liver, the lesser omentum, the stomach, and the two anterior layers of the greater omentum. *Behind* it is limited, from below upwards, by the two posterior layers of the greater omentum, the transverse colon, and the ascending layer of the transverse mesocolon, the anterior surface of the pancreas, the left suprarenal gland, and the upper end of the left kidney. To the right of the œsophageal opening of the stomach it is bounded by that part of the Diaphragm which supports the caudate lobe of the liver and by the aorta and the inferior vena cava. Laterally, the bursa extends from the epiploic foramen to the spleen, where it is limited by the lienorenal and gastrolienal ligaments.

The omental bursa consists of a vestibule and three recesses, a superior, a middle and an inferior.

The *vestibule* is a narrow channel situated immediately to the left of the epiploic foramen, below the caudate process of the liver, above the head of the pancreas and superior part of the duodenum, and behind the hepatoduodenal ligament (p. 1141). The hepatic artery, portal vein, and bile-duct pass forwards below the vestibule and then ascend between the two layers of the hepatoduodenal ligament. The *superior* recess extends upwards from the vestibule behind the porta hepatis and the caudate lobe of the liver, and in front of the Diaphragm and aorta. The *middle* recess, a small but variable pouch, descends between the lesser omentum and the pancreas. The vestibule and the superior and middle recesses together constitute the *bursa omenti minoris*. The *inferior* recess, or *bursa omenti majoris*, lies behind the stomach and extends as a large *lienal recess* between the stomach and the spleen. In the fœtus the inferior recess reaches as low as the free margin of the greater omentum, but in the adult the vertical extent of the recess is much more limited owing to adhesions between the layers of the greater omentum.

The vestibule and the inferior recess are sometimes shut off from one another by a complete *septum bursarum*, but in most cases they communicate through a rounded opening, the *foramen bursæ omenti majoris*. This opening is limited posteriorly by the *gastropancreatic ligament*, a sickle-shaped fold of peritoneum which encloses the left gastric artery, and extends from the tuber omentale of the pancreas to the back of the fundus of the stomach.

Crymble * states that two gastropancreatic ligaments are frequently present, viz. a *vertical* fold attaching the posterior border of the lesser curvature of the stomach to the Diaphragm and pancreas, and a *horizontal* fold between the pyloric part of the stomach and the pancreas. He gives as the boundaries of the foramen bursæ omenti majoris, the lesser curvature of the stomach, the pancreas and the gastropancreatic ligaments. He found these ligaments absent in seven out of thirty-five subjects.

During a considerable part of fœtal life the transverse colon is suspended from the posterior abdominal wall by a mesentery of its own, the two posterior layers of the greater omentum passing at this stage in front of the colon (fig. 209). This condition occasionally persists throughout life, but as a rule adhesion occurs between the mesentery of the transverse colon and the posterior layer of the greater omentum, with the result that the colon appears to receive its peritoneal covering by the splitting of the two posterior layers of the latter fold. In the adult the omental bursa intervenes between the stomach and the structures on which that viscus lies, and performs therefore the functions of a serous bursa for the stomach.

Numerous peritoneal folds extend between the various organs or connect them to the parietes; they serve to hold the viscera in position, and, at the same time, enclose the vessels and nerves proceeding to them. They are grouped as ligaments, omenta, and mesenteries.

The ligaments will be described with their respective organs.

CC-0. In Public Domain. Gurukul Kangri Collection, Haridwar

* *Journal of Anatomy and Physiology*, vol. xlvii.

Digitized by Arya Samaj Foundation Chennai and eGangotri

There are two omenta, the lesser and the greater.

The *lesser omentum* is the fold of peritoneum which extends to the liver along the lesser curvature of the stomach and the commencement of the duodenum. It is continuous with the two layers which cover the antero-superior and postero-inferior surfaces of the stomach and the first part of the duodenum. When these two layers reach the lesser curvature of the

FIG. 1094.—A diagram devised by Delépine to show the lines along which the peritoneum leaves the wall of the abdomen to invest the viscera.

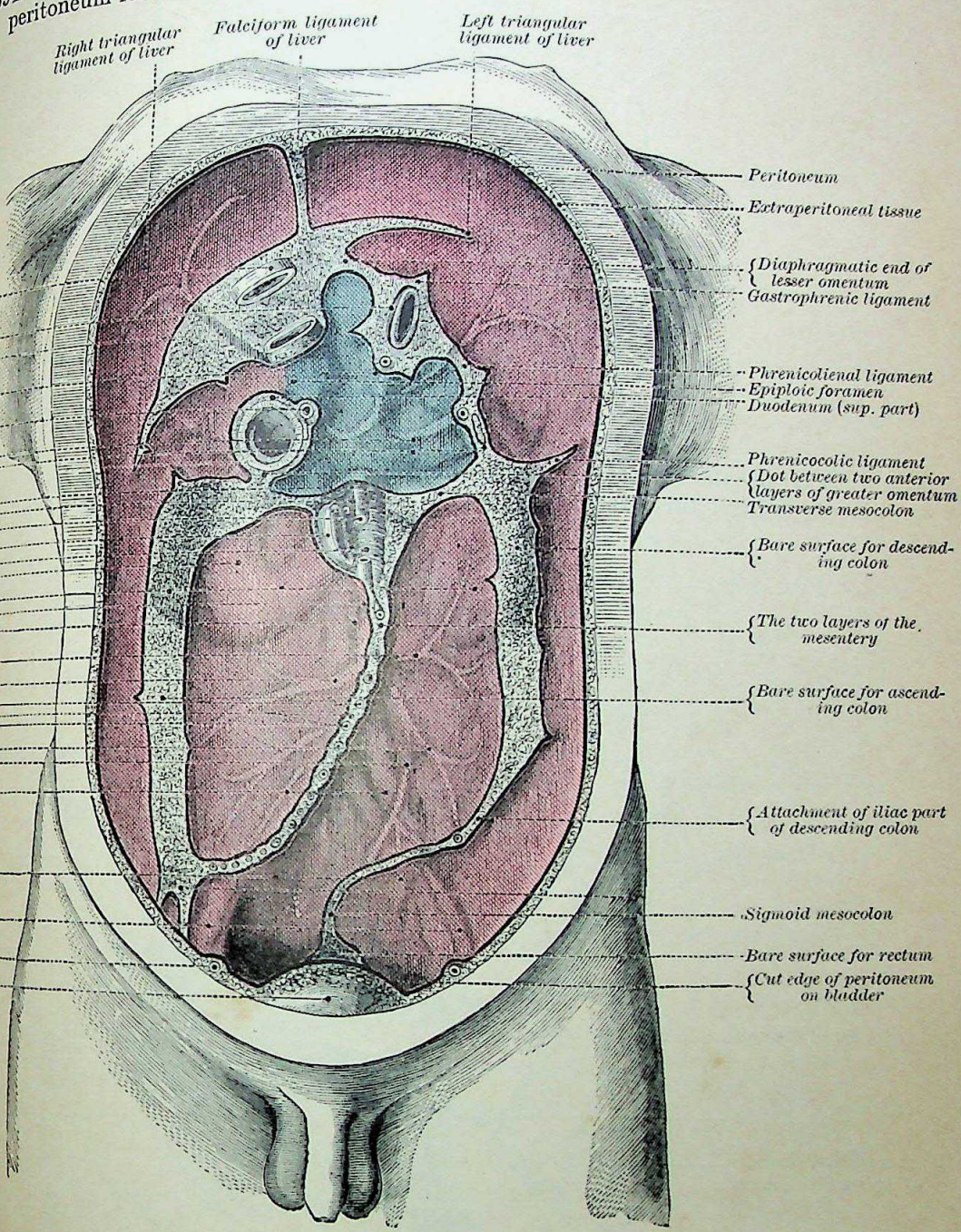

ach and the upper border of the duodenum, they unite and ascend as ble fold to the porta hepatis; to the left of the porta hepatis the fold tached to the bottom of the fossa for the ductus venosus, along which carried to the Diaphragm, where the two layers separate to embrace nd of the œsophagus. At the right border of the omentum the two layers ntinuous, and form a free margin which constitutes the anterior boundary e epiploic foramen. The portion of the lesser omentum extending between ver and stomach is named the *hepatogastric ligament*, while that between ver and duodenum is the *hepatoduodenal ligament*. Between the two s of the lesser omentum, close to the right free margin, are the hepatic portal vein and bile-duct, a few lymph glands and lymphatic vessels, and

CC-0. In Public Domain. Panini Kanya Maha Vidyalaya Collection.

Digitized by Arya Samaj Foundation Chennai and eGangotri

the hepatic plexus of nerves—all these structures being enclosed in a *fibrous capsule* (Glisson's capsule). The right and left gastric arteries run between the layers of the lesser omentum, where these are attached to the stomach.

FIG. 1095.—The superior and inferior duodenal fossæ. (After Jonnesco.) From Poirier and Charpy's Traité d'Anatomie humaine. (Masson et Cie.)

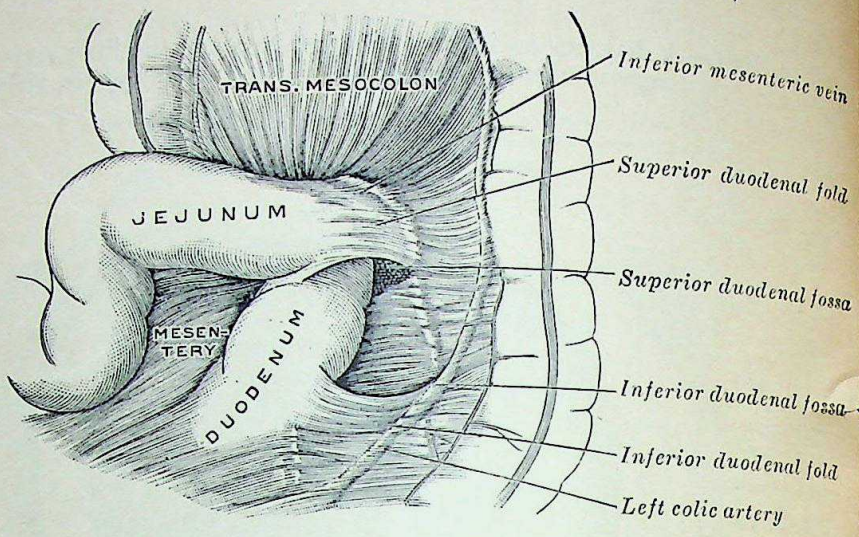

The *greater omentum* is the largest peritoneal fold. It consists of a double sheet, folded on itself so that it is made up of four layers. The two layers

FIG. 1096.—The paraduodenal fossa. (After Jonnesco.) From Poirier and Charpy's Traité d'Anatomie humaine. (Masson et Cie.)

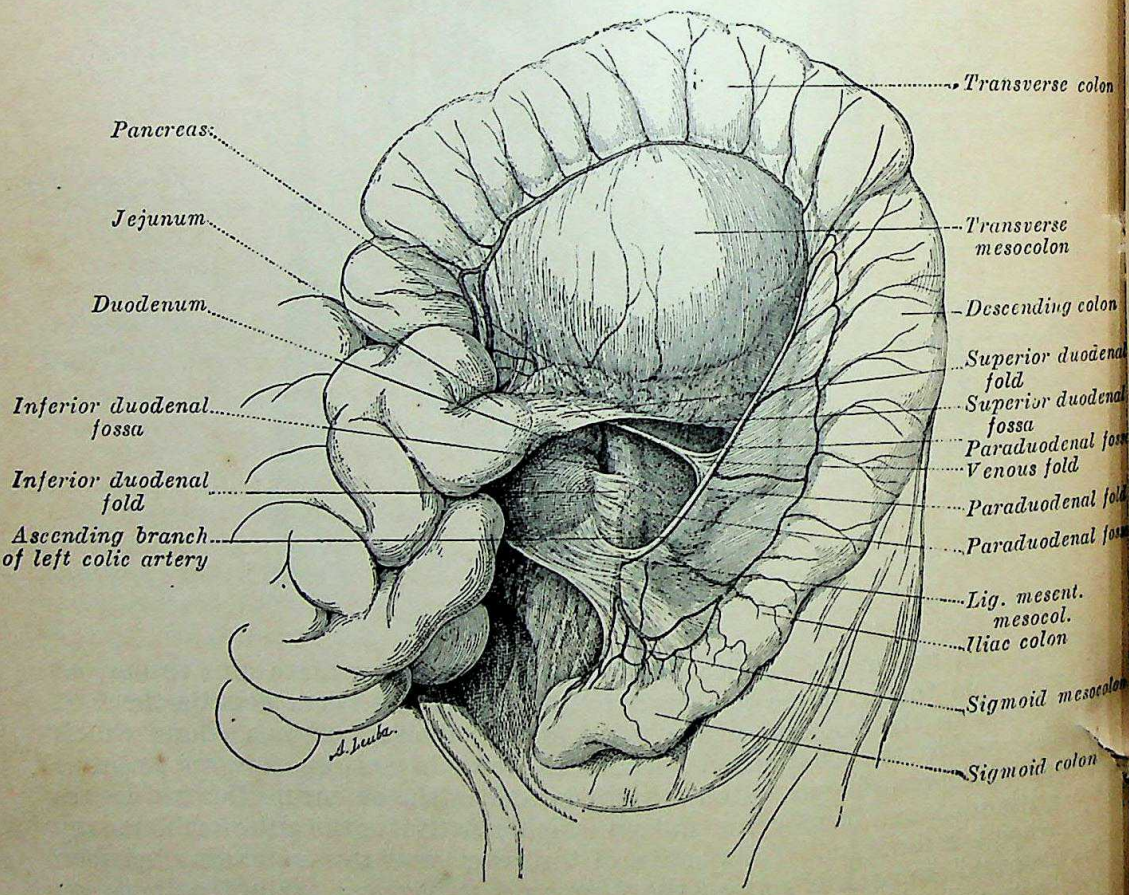

which descend from the stomach and commencement of the duodenum pass in front of the small intestines, sometimes as low down as the pelvis; they then

CC-0. In Public Domain. Gurukul Kangri Collection, Haridwar

Digitized by Arya Samaj Foundation Chennai and eGangotri

...rn upon themselves, and ascend again as far as the transverse colon, where ...y separate and enclose that part of the intestine. These individual layers ...y be easily demonstrated in the young subject, but in the adult they are ...re or less inseparably blended. The left border of the greater omentum ...continuous with the gastrolienal ligament; its right border extends as far ...the commencement of the duodenum. The greater omentum is usually ...n, presents a cribriform appearance, and always contains some adipose ...ssue, which in fat people accumulates in considerable quantity. Between ...two anterior layers, a short distance from the greater curvature of the ...omach, is the anastomosis between the right and left gastro-epiploic vessels. The mesenteries are: the mesentery (mesentery proper), the mesenteriole ...the vermiform process, the transverse mesocolon, and the sigmoid mesocolon. ...addition to these an ascending and a descending mesocolon are sometimes ...esent.

FIG. 1097.—The retroduodenal fossa. (After Jonnesco.) From Poirier and Charpy's Traité d'Anatomie humaine. (Masson et Cie.)

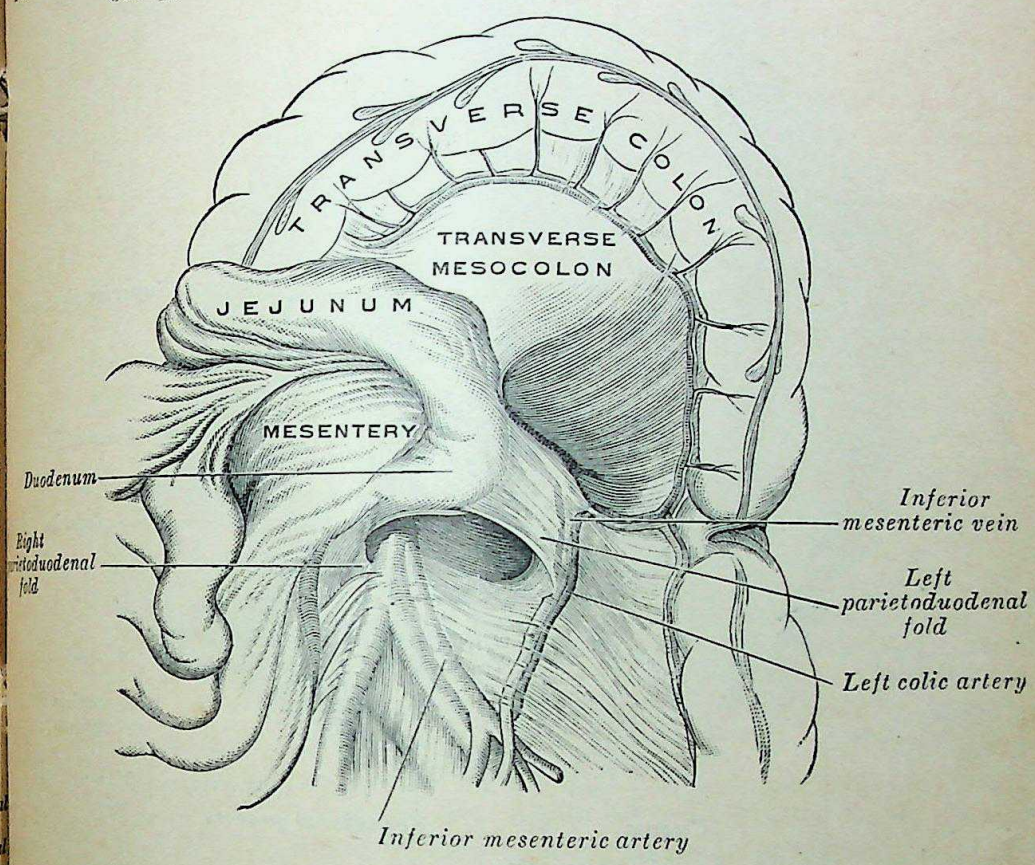

The *mesentery* is a broad, fan-shaped fold of peritoneum connecting the ...volutions of the jejunum and ileum with the posterior wall of the abdomen. ...root—the border connected with the structures in front of the vertebral ...umn—is about 15 cm. long, and is directed obliquely from the duo-...jejunal flexure at the left side of the second lumbar vertebra to the ...sacro-iliac articulation (fig. 1094). Its intestinal border is about 6 metres ...; and here the two layers separate to enclose the intestine and form ...peritoneal coat. The mesentery is short at the upper part of the jejunum, ...lengthens rapidly to about 20 cm., and is thrown into numerous pleats or folds. ...pends the jejunum and ileum, and contains between its layers the jejunal ...ileal branches of the superior mesenteric artery, with their accompanying ...s and plexuses of nerves, the lymphatic (lacteal) vessels, the mesenteric ...ph-glands, and a varying amount of fatty tissue.

The *mesenteriole of the vermiform process* (fig. 1098) is a triangular fold of ...oneum which clothes the vermiform process, and is attached to the back ...the lower end of the mesentery, close to the ileocæcal junction. Between ...yers are the blood-vessels, nerves and lymphatic vessels of the vermiform ..., together with a lymph-gland.

CC-0. In Public Domain. Gurukul Kangri Collection, Haridwar

Digitized by Arya Samaj Foundation Chennai and eGangotri

The *transverse* mesocolon is a broad fold connecting the transverse colon to the posterior wall of the abdomen. It is continuous with the two posterior layers of the greater omentum, which, after separating to surround the transverse colon, join behind it, and are continued to the vertebral column, where they diverge in front of the anterior border of the pancreas. This fold contains between its layers the blood-vessels, nerves and lymphatics of the transverse colon.

The *sigmoid mesocolon* is a fold of peritoneum which attaches the sigmoid colon to the pelvic wall. Its line of attachment forms a V-shaped curve, the apex of the curve being placed near the point of division of the left common iliac artery. The curve begins on the medial side of the left Psoas major,

Fig. 1098.—The terminal part of the ileum, the cæcum and the vermiform process. Anterior aspect.

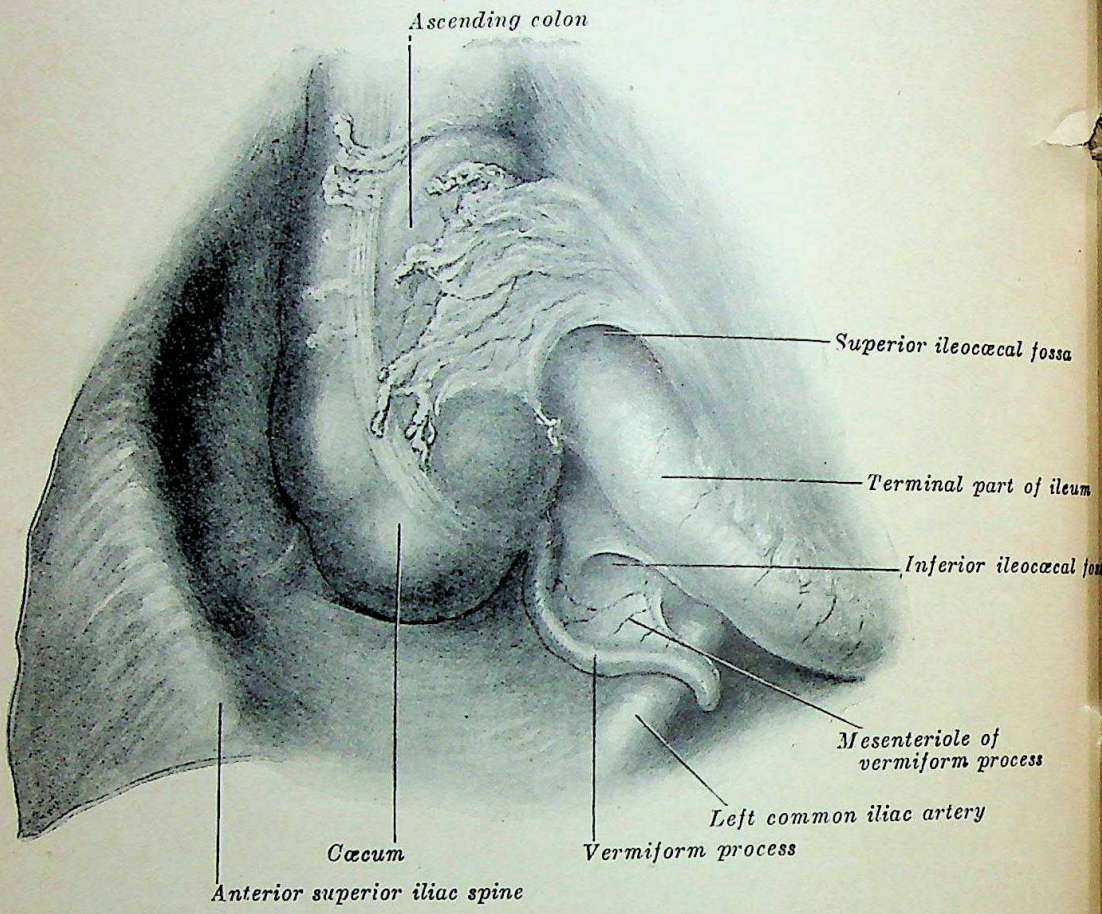

and runs upwards and backwards to the apex, from which it bends sharply downwards, and ends in the median plane at the level of the third sacral vertebra. The sigmoid and superior hæmorrhoidal vessels run between the two layers of the sigmoid mesocolon.

In most cases the peritoneum covers only the front and sides of the ascending and descending parts of the colon, but sometimes these are surrounded by peritoneum and attached to the posterior abdominal wall by an ascending and a descending mesocolon respectively (p. 1166*). A fold of peritoneum, the *phrenicocolic ligament*, is continued from the left colic flexure to the Diaphragm opposite the tenth and eleventh ribs; it passes below, and serves to support, the spleen, and therefore has received the name of *sustentaculum lienis*.

The *appendices epiploicæ* are small pouches of the peritoneum filled with fat and situated along the colon and upper part of the rectum. They are chiefly appended to the transverse and sigmoid parts of the colon.

Peritoneal recesses or fossæ.—In certain parts of the abdominal cavity there are peritoneal recesses or pouches, which are of surgical interest in connexion with the possibility of the occurrence of 'retroperitoneal'

CC-0. In Public Domain. Gurukul Kangri Collection, Haridwar

Digitized by Arya Samaj Foundation Chennai and eGangotri

rative. The largest of these is the omental bursa (p. 1139), but others of smaller size require mention, and may be divided into three groups, viz.: duodenal, cæcal, and intersigmoid.

1. *Duodenal fossæ* (figs. 1095 to 1097).—Five of these fossæ are usually described, viz. a superior and an inferior duodenal, a paraduodenal, a retroduodenal, and a duodenojejunal or mesocolic. The paraduodenal fossa may occur together with the superior and inferior duodenal fossæ, but the retroduodenal and duodenojejunal are not found in conjunction with the other varieties. (*a*) The *superior duodenal fossa* (fig. 1095) is present in about 50 per cent. of bodies. It lies on the left side of the upper segment of the ascending portion of the duodenum, behind a sickle-shaped fold of peritoneum, named

Fig. 1099.—The cæcal fossa. The ileum and cæcum are drawn backwards and upwards. (After Jonnesco.) From Poirier and Charpy's Traité d'Anatomie humaine. (Masson et Cie.)

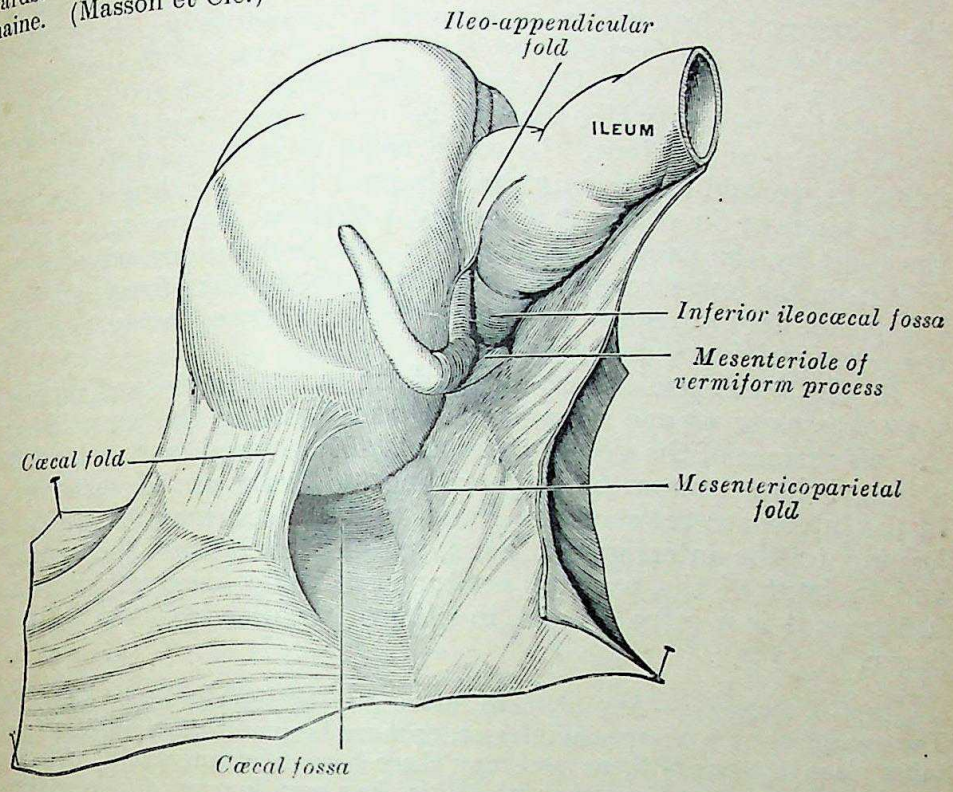

superior duodenal fold; the upper part of the inferior mesenteric vein usually runs between the layers of this fold. The fossa is about 2 cm. deep, and its orifice, directed downwards, admits a finger-tip. (*b*) The *inferior duodenal* fossa (fig. 1095) is present in about 75 per cent. of bodies. It is placed on the right side of the lower segment of the ascending portion of the duodenum behind the avascular triangular fold of peritoneum, named the inferior duodenal fold. This fossa has an average depth of 3 cm., and its orifice, which admits the tips of one or two fingers, is directed upwards and faces that of the superior duodenal fossa. In some cases the fossa extends to the left in front of the ascending branch of the left colic artery, and the inferior mesenteric vein. The *paraduodenal fossa* (fig. 1096) lies a short distance to the left of the descending portion of the duodenum, and, though frequently present in the newborn child, is rarely found in the adult. It is placed behind a falciform fold (paraduodenal fold) of peritoneum, the free edge of which contains the descending branch of the left colic artery, and frequently the inferior mesenteric vein, the fold forming a mesentery for these vessels. The free margin of the fold, and the wide orifice of the fossa, are directed towards the right. (*d*) The *retroduodenal fossa* (fig. 1097), the largest of the duodenal fossa, is only occasionally present. It lies behind the horizontal and ascending parts of the duodenum, and in front of the aorta. It extends upwards nearly as far as the duodenojejunal junction, and towards the left as far as, or beyond, the inferior mesenteric vein, which may run in its anterior wall. The orifice of the fossa faces downwards. (*e*) The *duodenojejunal or mesocolic fossa* lies on the left

CC-0. In Public Domain. Gurukul Kangri Collection, Haridwar

Digitized by Arya Samaj Foundation Chennai and eGangotri

side of the aorta, between the duodenojejunal junction and the root of the transverse mesocolon. It is present in about 20 per cent. of bodies, and has an average depth of from 2 cm. to 3 cm. Its orifice is directed forwards.

2. *Cæcal fossæ.*—There are three principal pouches or recesses in the neighbourhood of the cæcum: (*a*) The *superior ileocæcal fossa* (fig. 1098) is formed by a fold of peritoneum, the superior ileocæcal fold, arching over the branch of the ileocolic artery which supplies the ileocolic junction. The fossa is a narrow chink situated between the mesentery of the small intestine, the ileum, and the small portion of the cæcum behind. (*b*) The *inferior ileocæcal fossa* (fig. 1098) is situated behind the angle of junction of the ileum and cæcum. It is formed by the *inferior ileocæcal fold* of peritoneum (bloodless fold of Treves), the upper border of which is fixed to the ileum, opposite its mesenteric attachment, while the lower border joins the mesenteriole of the vermiform process, and sometimes the process itself. Between this fold and the mesenteriole of the vermiform process is the inferior ileocæcal fossa. It is bounded above by the posterior surface of the ileum and the mesentery; in front by the inferior ileocæcal fold, and behind by the upper part of the mesenteriole of the vermiform process. (*c*) The *cæcal fossa* (fig. 1099) is situated immediately behind the cæcum, which has to be raised to bring it into view. It varies much in size and extent. In some cases it is sufficiently large to admit the index finger, and extends upwards behind the ascending colon in the direction of the kidney; in others it is merely a shallow depression. It is bounded on the right by the cæcal fold, which is attached by one edge to the abdominal wall from the lower border of the kidney to the iliac fossa, and by the other to the posterolateral aspect of the colon. In some instances additional fossæ, the *retrocæcal fossæ*, are present.

3. The *intersigmoid fossa* is constant in the fœtus and during infancy, but may disappear as age advances. Upon drawing the sigmoid colon upwards, the left surface of the sigmoid mesocolon is exposed, and behind it will be seen a funnel-shaped recess of the peritoneum, lying on the external iliac vessels, in the interspace between the Psoas and Iliacus muscles. This is the orifice leading to the intersigmoid fossa, which lies behind the sigmoid mesocolon, and in front of the parietal peritoneum. The fossa varies in size; in some instances it is a mere dimple, in others it will admit the whole of the index finger.

Applied Anatomy.—Any of these fossæ may be the site of a 'retroperitoneal' hernia. The cæcal fossæ are of especial interest, because hernia of the vermiform process frequently takes place into one of them, and may there become strangulated. The presence of these pouches also explains the course which pus has been known to take in cases of perforation of the vermiform process, where it travels upwards behind the ascending colon as far as the Diaphragm.

The Stomach (Ventriculus)

The stomach is the most dilated part of the digestive tube, and is situated between the end of the œsophagus and the beginning of the small intestine. It lies in the epigastric, umbilical, and left hypochondriac regions of the abdomen, and occupies a recess bounded by the upper abdominal viscera, and completed in front and on the left side by the anterior abdominal wall and the Diaphragm.

The *shape and position* of the stomach are so greatly modified by changes within itself and in the surrounding viscera that no one form can be described as typical. The chief modifications are determined by (1) the amount of the stomach contents, (2) the stage which the digestive process has reached, (3) the degree of development of the gastric musculature, and (4) the condition of the adjacent intestines; but there are certain markings more or less common to all (fig. 1100).

The stomach has two openings, two borders or curvatures, and two surfaces.

Openings.—The opening by which the œsophagus communicates with the stomach is known as the *cardiac orifice*, and is situated on the left of the middle line at the level of the eleventh thoracic vertebra. The short abdominal portion of the œsophagus (*antrum cardiacum*) is conical in shape and curved

CC-0. In Public Domain. Gurukul Kangri Collection, Haridwar

Digitized by Arya Samaj Foundation Chennai and eGangotri

sharply to the left, the base of the cone being continuous with the cardiac orifice of the stomach. The right margin of the œsophagus is continuous with the lesser curvature of the stomach, while the left margin joins the greater curvature at an acute angle, termed the *incisura cardiaca*.

The opening by which the stomach communicates with the duodenum is named the *pyloric orifice*, and its position is usually indicated by a circular groove, the *duodenopyloric constriction* which indicates the position of the pyloric sphincter. The pyloric orifice lies to the right of the middle line at the level of the upper border of the first lumbar vertebra.

Curvatures.—The *lesser curvature*, extending between the cardiac and pyloric orifices, forms the right or posterior border of the stomach. It descends as a continuation of the right margin of the œsophagus in front of the fibres of the right crus of the Diaphragm, and then, turning to the right, it crosses the first lumbar vertebra and ends at the pylorus. Nearer its pyloric than its cardiac end is a notch, the *incisura angularis*, which varies somewhat in position with the state of distension of the viscus; it serves to separate the stomach into a right and a left portion. The lesser curvature gives attachment to the hepatogastric ligament, between the two layers of which are the right and left gastric arteries.

Fig. 1100.—An outline of the normal full stomach. (From a model by A. E. Barclay.)

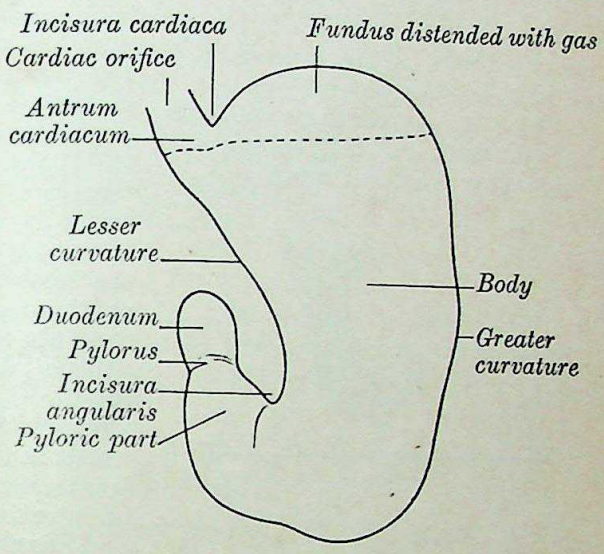

The *greater curvature* is directed mainly forwards, and is four or five times as long as the lesser curvature. Starting from the cardiac orifice at the incisura cardiaca, it forms an arch backwards, upwards, and to the left; the highest point of the convexity is on a level with the sixth left costal cartilage. From this level it may be followed downwards and forwards, with a slight convexity to the left as low as the cartilage of the ninth rib; it then turns to the right, to end at the pylorus. Directly opposite the incisura angularis of the lesser curvature the greater curvature presents a bulging, which is the left extremity of the *pyloric part* of the stomach; this is limited on the right by a slight groove, the *sulcus intermedius*, which is from 2 to 3 cm. from the duodenopyloric constriction. At its commencement the greater curvature is covered by peritoneum continuous with that on the front of the stomach. The left half of the curvature gives attachment to the gastrolienal ligament, while to its inferior portion are attached the two layers of the greater omentum, separated from each other by the gastro-epiploic vessels.

Surfaces.—When the stomach is empty and its wall contracted, its surfaces are directed upwards and downwards respectively, but when it is distended they look forwards and backwards. They may therefore be described as anterosuperior and postero-inferior.

Anterosuperior surface.—The left half of this surface is in contact with the Diaphragm, which separates it from the base of the left lung, the pericardium, and the seventh, eighth, and ninth ribs and intercostal spaces of the left side. The right half is in relation with the left and quadrate lobes of the liver and the anterior abdominal wall. When the stomach is empty, the transverse colon may lie on the front part of this surface. The whole surface is covered by peritoneum.

The *postero-inferior surface* is in relation with the Diaphragm, the gastric surface of the spleen, the left suprarenal gland, the upper part of the front of the left kidney, the anterior surface of the pancreas, the left colic flexure, and the upper layer of the transverse mesocolon. These structures form a shelf bed, the *stomach-bed*, on which the viscus rests. The transverse mesocolon separates the stomach from the duodenojejunal flexure and small intestine.

CC-0. In Public Domain. Gurukul Kangri Collection, Haridwar

Digitized by Arya Samaj Foundation Chennai and eGangotri

The postero-inferior surface is covered by peritoneum, except over a small area close to the cardiac orifice; this area is limited by the lines of attachment of the *gastrophrenic ligament*, and lies in apposition with the Diaphragm, and frequently with the upper portion of the left suprarenal gland.

FIG. 1101.—A diagram showing the shape and position of the empty stomach. Erect posture (After A. F. Hurst.)

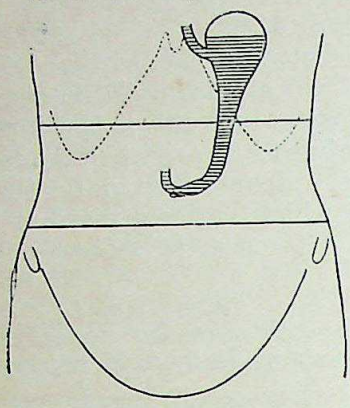

FIG. 1102.—A diagram showing the shape and position of the moderately filled stomach. Erect posture. (After A. F. Hurst.)

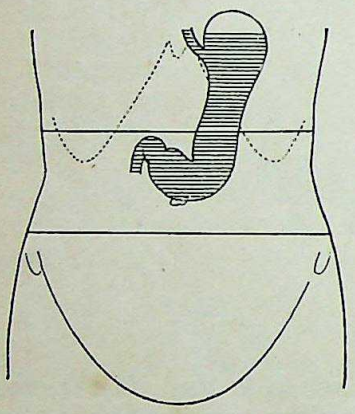

FIG. 1103.—A diagram showing the shape and position of the distended stomach. Erect posture. (After A. F. Hurst.)

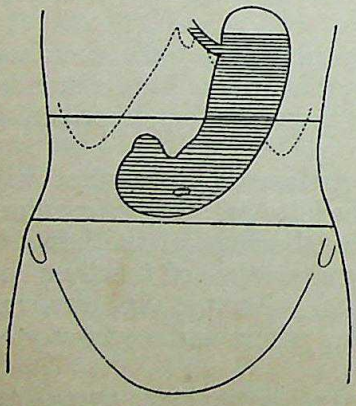

Component parts of the stomach.—A plane passing through the incisura angularis on the lesser curvature and the left limit of the opposed bulging on the greater curvature divides the stomach into a large, left portion or *body* and a small, right or *pyloric portion*. The upper portion of the body is known as the *fundus* and is marked off from the remainder of the body by a plane passing horizontally through the cardiac orifice.

By means of x-rays the form and position of the stomach can be studied in the living subject after the administration of a meal containing bismuth. During the process of digestion, it is divided by a muscular constriction into a large dilated left portion, and a narrow contracted tubular right portion. The constriction is in the body of the stomach, and does not follow any of the anatomical landmarks; indeed, it shifts gradually towards the left as digestion progresses. The position of the stomach varies with the posture, with the amount of the stomach contents, and with the condition of the intestines on which it rests (figs. 1101 to 1103). In the erect posture the empty stomach is somewhat J-shaped; the part above the cardiac orifice is usually distended with gas; the pylorus descends to the level of the second lumbar vertebra, and the most dependent part of the stomach is at the level of the umbilicus. Variation in the amount of its contents affects mainly the body of the stomach, the pyloric portion remaining in a more or less contracted condition during the process of digestion. As the stomach fills it tends to expand forwards and downwards in the direction of least resistance, but when this is interfered with by a distended condition of the colon or intestines the fundus presses upwards on the liver and Diaphragm and gives rise to the feelings of oppression and palpitation complained of in such cases. His * and Cunningham † have shown by hardening the viscera *in situ* that the contracted stomach has a sickle shape, the fundus looking directly backwards. The surfaces are directed upwards and downwards, the upper surface having, however, a gradual downward slope to the right. The greater curvature is in front and at a slightly higher level than the lesser.

The position of the full stomach depends, as already indicated, on the state of the intestines: when the latter are empty the fundus expands vertically and also forwards, the pylorus is displaced towards the right, and the whole organ assumes an oblique position, so that its surfaces are directed more forwards and backwards. The lowest part of the stomach is at the pyloric vestibule which reaches to the region of the umbilicus. Where the intestines interfere with the downward expansion of the fundus the stomach retains the horizontal position which is characteristic of the contracted viscus.

Interior of the stomach.—When examined after death, the stomach is usually fixed at some temporary stage of the digestive process. A common form is that shown in fig. 1104. If the viscus be laid open by a section through the plane of its two curvatures, it is seen to consist of two segments: (*a*) a large globular portion on the left and (*b*) a narrow tubular part on the right. To the left of the antrum cardiacum is the incisura cardiaca:

* *Archiv für Anatomie und Physiologie, anat. Abth.*, 1903.
† *Transactions of the Royal Society of Edinburgh*, vol. xlv, part i.

CC-0. In Public Domain. Gurukul Kangri Collection, Haridwar

Digitized by Arya Samaj Foundation Chennai and eGangotri

projection of this notch into the cavity of the stomach increases as the organ distends, and has been supposed to act as a valve preventing regurgitation into the œsophagus. In the pyloric portion are seen: (*a*) the elevation corresponding to the incisura angularis, and (*b*) the circular thickening of the pyloric sphincter.

FIG. 1104.—The interior of the stomach.

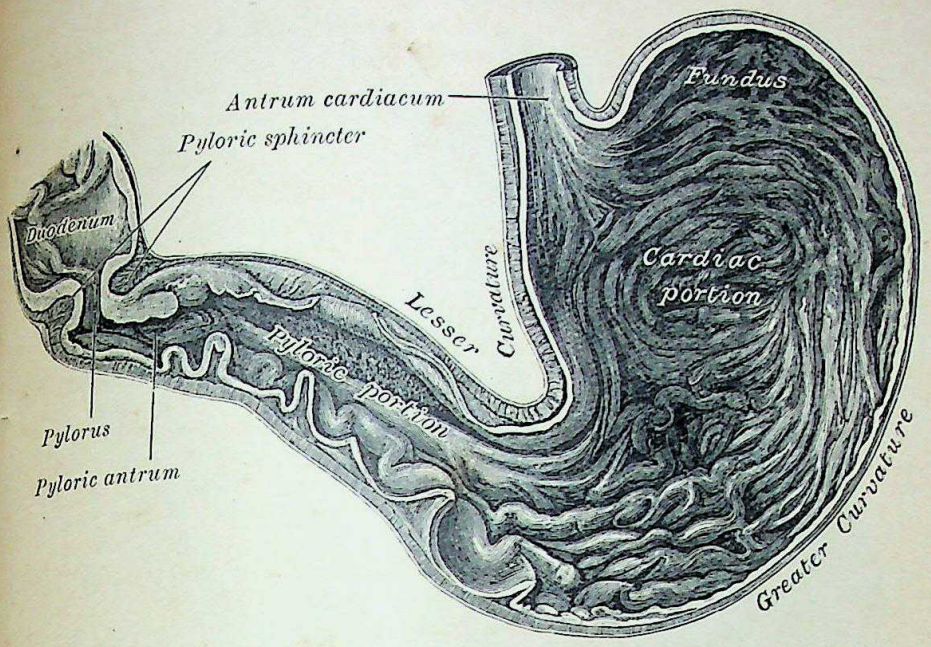

F. T. Lewis * has modelled the gastric epithelium in the human embryo, and has shown a canal (named by him the *gastric canal*) extends along the lesser curvature from the antrum cardiacum to the incisura angularis (fig. 1105), the distinctness of the canal being strikingly shown when the model is viewed from the inside. Jefferson † has brought forward radiographic evidence to show that such a canal exists in the adult. He found that in eighteen out of twenty-two cases examined whilst in the act of swallowing a mixture of oxychloride of bismuth and milk the fluid was confined to the lesser curvature. He is of the opinion that the oblique muscular coat of the stomach is so arranged that by its contraction it will cause a temporary splitting off of a canal along the lesser curvature.

FIG. 1105.—A diagram showing the subdivisions of the human stomach. (F. T. Lewis.)

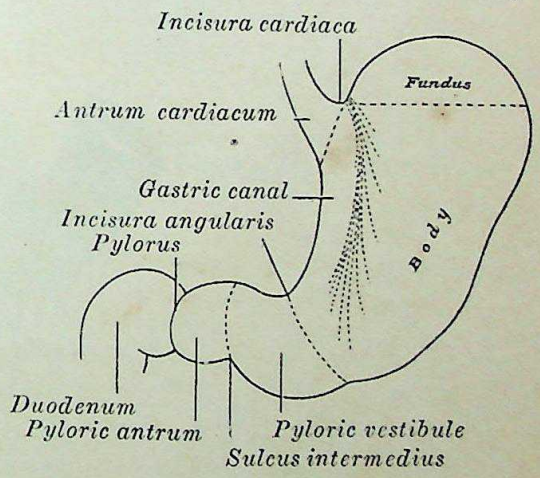

The *pyloric sphincter* is a muscular ring composed of a thickened portion of the circular layer of the muscular coat; this ring is covered by a reduplication of the mucous membrane. Some of the deeper longitudinal fibres turn in and interlace with the fibres of the sphincter.

Structure.—The wall of the stomach consists of four coats: serous, muscular, areolar, and mucous, together with vessels and nerves.

The *serous coat* is derived from the peritoneum, and covers the entire surface of the stomach, excepting (*a*) along the greater and lesser curvatures at the lines of attachment of the greater and lesser omenta, where the two layers of peritoneum leave a small space, triangular in section, in which the vessels and nerves pass; and (*b*) a small area on the postero-inferior surface of the stomach, close to the cardiac orifice, where the stomach is in contact with the under surface of the Diaphragm.

* *American Journal of Anatomy*, vol. xiii.
† *Journal of Anatomy and Physiology*, vol. xlix.

CC-0. In Public Domain. Gurukul Kangri Collection, Haridwar

Digitized by Arya Samaj Foundation Chennai and eGangotri

The *muscular coat* (figs. 1106, 1107) is situated immediately beneath the serous covering, with which it is closely connected. It consists of three layers of unstriped muscular fibres: longitudinal, circular, and oblique.

FIG. 1106.—The longitudinal and circular muscular fibres of the stomach. Anterosuperior aspect. (Spalteholz.)

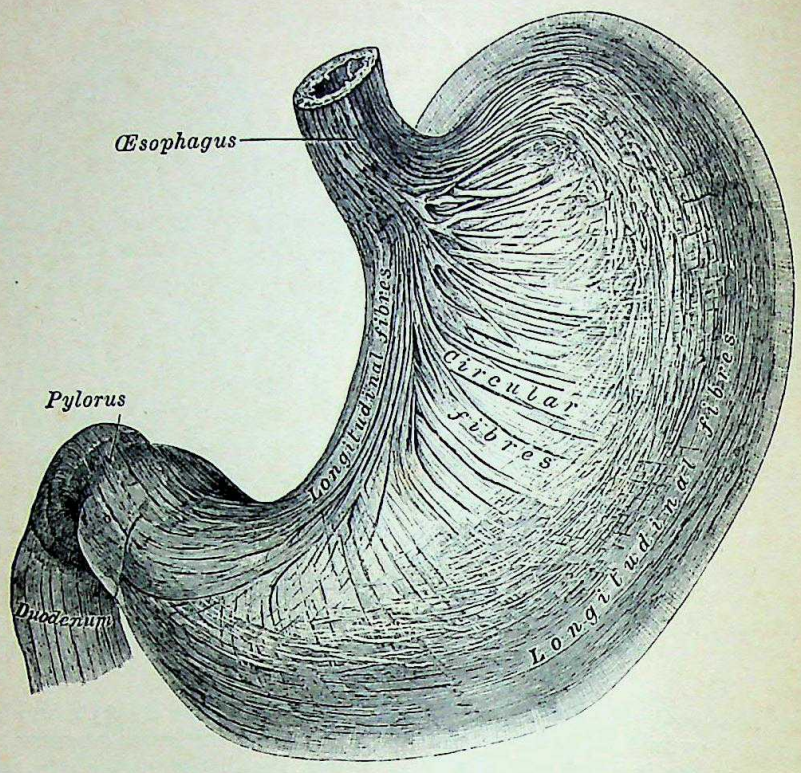

FIG. 1107.—The oblique muscular fibres of the stomach. Anterosuperior aspect. (Spalteholz.)

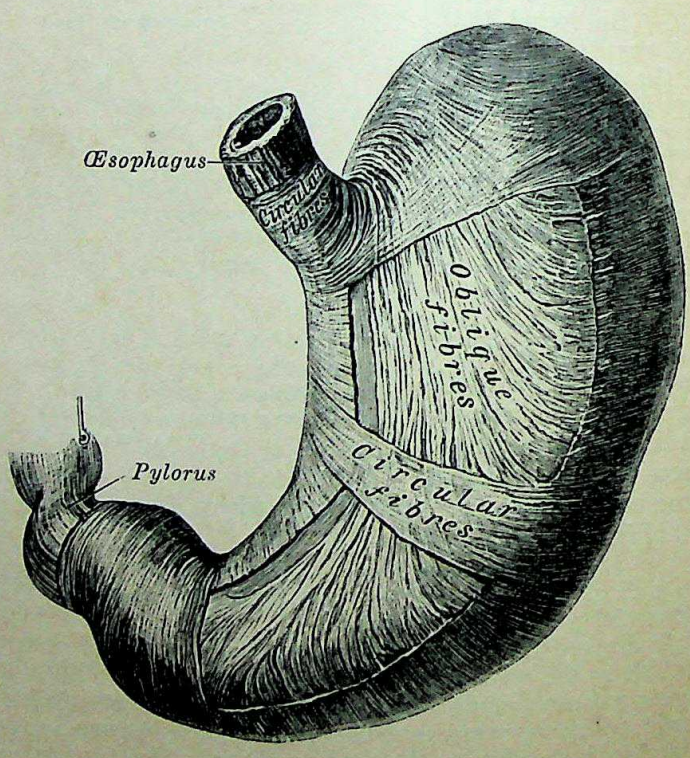

The *longitudinal fibres* are the most superficial, and are arranged in two sets. The first set consists of fibres continuous with the longitudinal fibres of the œsophagus; they radiate from the cardiac orifice and end proximal to the pyloric portion. The second set

CC-0. Public Domain. Gurukul Kangri Collection, Haridwar

Digitized by Arya Samaj Foundation Chennai and eGangotri

mences on the body of the stomach and passes to the right, its fibres becoming more ly arranged as they approach the pylorus. Some of the more superficial fibres of this pass on to the duodenum, but the deeper fibres dip inwards and interlace with the es of the pyloric sphincter.

The *circular fibres* form a uniform layer over the whole extent of the stomach beneath longitudinal fibres. At the pylorus they are most abundant, and are there aggregated a ring, which forms the *pyloric sphincter*. The circular fibres of the stomach are con- ous with the circular fibres of the œsophagus, but are sharply marked off from the ular fibres of the duodenum by a connective tissue septum.

The *oblique fibres*, internal to the circular layer, are limited chiefly to the body of the ach. They sweep downwards from the incisura cardiaca and run more or less parallel the lesser curvature. On the right they present a free and well-defined margin 1107); on the left they blend with the circular fibres.

1108.—A section through the mucous membrane of a human stomach, near the cardiac orifice. ×45. (v. Ebner, after J. Schaffer.)

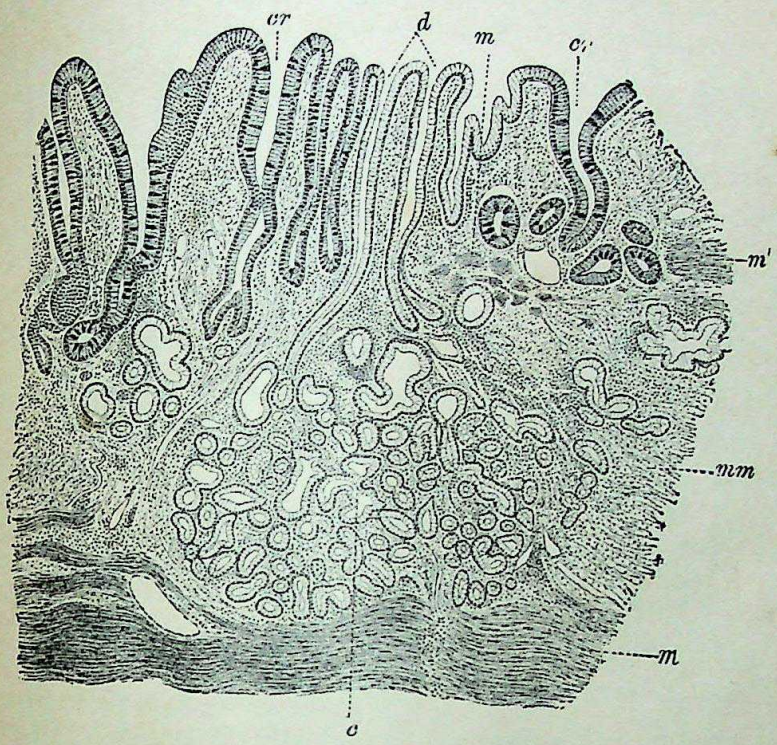

c. Cardiac glands. *d.* Their ducts. *cr.* Gland similar to the intestinal glands, with goblet-cells. *mm.* Mucous membrane. *m.* Muscularis mucosæ. *m'.* Muscular tissue within the mucous membrane.

The *areolar or submucous coat* consists of loose, areolar tissue, connecting the mucous muscular layers.

The *mucous membrane* is thick and its surface is smooth, soft, and velvety. In the state it is of a pinkish tinge at the pyloric end, and of a red or reddish-brown colour the rest of its surface. In infancy it is of a brighter hue, the vascular redness being marked. It is thin at the cardiac extremity, but thicker towards the pylorus. the contracted state of the organ it is thrown into numerous folds or rugæ, which most part have a longitudinal direction, and are best marked towards the pyloric the stomach, and along the greater curvature (fig. 1104). These folds are obliterated the organ is distended.

Structure of the mucous membrane.—When examined with a lens, the inner surface of mucous membrane presents a peculiar honeycomb appearance from being covered with shallow depressions or alveoli, of a polygonal or hexagonal form, which vary from mm. to 0·25 mm. in diameter. These are the ducts of the gastric glands, and at the of each may be seen one or more minute orifices, the openings of the gland-tubes. surface of the mucous membrane is covered by a single layer of columnar epithelium occasional goblet-cells. This epithelium commences very abruptly at the cardiac where there is a sudden transition from the stratified epithelium of the œsophagus. thelial lining of the gland-ducts is of the same character and is continuous with epithelial lining of the stomach.

gastric glands are of three kinds: (*a*) *cardiac*, (*b*) *fundus or oxyntic*, and (*c*) The *cardiac glands* (fig. 1108), few in number, occur close to the cardiac orifice. of two kinds: (1) simple tubular glands resembling those of the pyloric end of

CC-0. In Public Domain. Gurukul Kangri Collection, Haridwar

Digitized by Arya Samaj Foundation Chennai and eGangotri

the stomach, but with short ducts; (2) compound racemose glands resembling the duodenal glands. The *fundus glands* (fig. 1109) are found in the body and fundus of the stomach; they are simple tubes, two or more of which open into a single duct. The duct is short, sometimes not amounting to more othan one-sixth of the whole length of the gland. The epithelium of the fundus glands consists of (1) short columnar, granular cells, known as the *chief* or *central cells*, and (2) larger, oval cells, termed *parietal* or *oxyntic cells*. The latter lie between the chief cells and the basement-membrane, and stain deeply with eosin; they do not form a continuous layer, but occur at intervals and so give the tube a beaded appearance. They are connected with the lumen of the gland by fine channels which run in the substance of the cells. The *pyloric glands* (fig. 1110) are found in the

Fig. 1109.—A fundus gland.

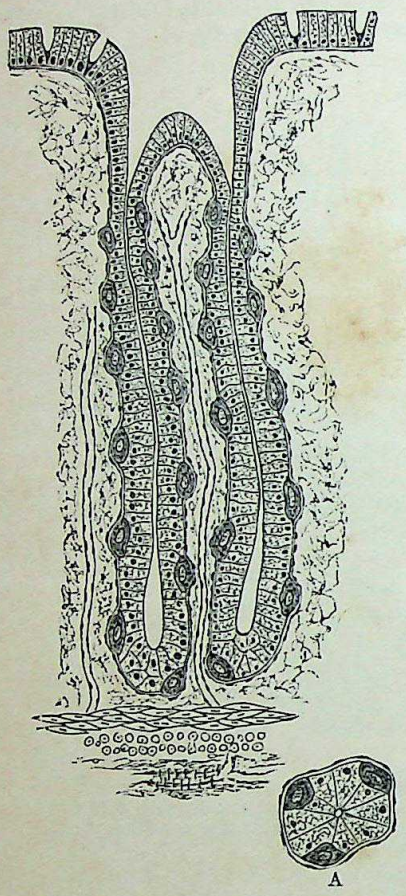

A. A transverse section through the gland.

Fig. 1110.—A pyloric gland, from a section through a dog's stomach. (Ebstein.) (From Quain's Elements of Anatomy, Vol. II. Pt. I.)

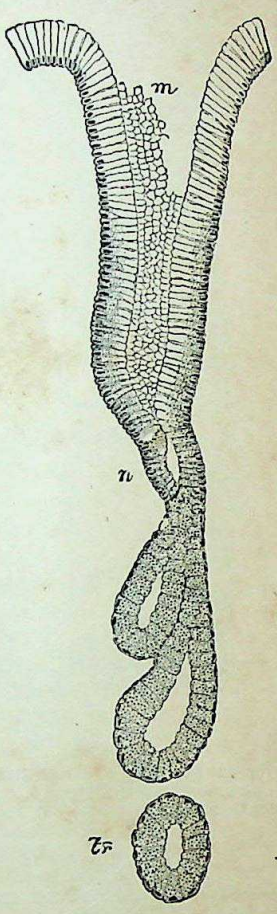

m. Mouth. *n.* Neck. *tr.* A deep portion of a tubule cut transversely.

pyloric portion of the stomach. Each consists of two or three short convoluted tubes opening into a funnel-shaped duct. The tubes are lined by cubical cells which are finely granular. Parietal or oxyntic cells are present in some of the pyloric glands. The ducts occupy about two-thirds of the depth of the mucous membrane.

Between the glands the mucous membrane consists of a connective tissue framework, with lymphoid tissue. In places, this latter tissue, especially in early life, is collected into little masses, which resemble the solitary lymphatic nodules of the intestine, and are termed the *lenticular glands* of the stomach. They are not, however, so distinctly circumscribed as the solitary nodules. The mucous membrane is bounded on its deep surface by a thin stratum of involuntary muscular fibres (muscularis mucosæ), which in some parts consists only of a single longitudinal layer; in others of two layers, an inner circular and an outer longitudinal.

Vessels and Nerves.—The *arteries* supplying the stomach are: the left gastric branch of the cœliac artery, the right gastric and right gastro-epiploic branches of the hepatic artery, and the left gastro-epiploic and short gastric branches of the lienal artery. They supply the muscular coat, ramify in the submucous coat, and are finally distributed to the mucous membrane. The arrangement of the vessels in the mucous membrane is somewhat peculiar. The arteries break up at the deep ends of the gastric glands into a

CC-0. In Public Domain. Gurukul Kangri Collection, Haridwar

Digitized by Arya Samaj Foundation Chennai and eGangotri

xus of fine capillaries which run upwards between the glands, anastomosing with each ter, and ending in a plexus of larger capillaries, which surround the mouths of the nds, and also form hexagonal meshes around the gland-ducts. From these the *veins* ose, and pursue a straight course downwards, between the glands, to the submucous ; they end either in the lienal and superior mesenteric veins, or directly in the tal vein. The *lymphatic vessels* are numerous; they consist of a superficial and a set, and pass to the lymph-glands found along the two curvatures of the organ 709). The *nerves* are the terminal branches of the right and left vagi, the former g distributed upon the back, and the latter upon the front part of the stomach. A number of branches from the cœliac plexus of the sympathetic are also distributed Nerve-plexuses are found in the submucous coat and between the layers of the ular coat, as in the intestine. From these plexuses fibrils are distributed to the ular tissue and the mucous membrane.

Applied Anatomy.—Operations on the stomach are frequently performed. By 'gas- my,' is meant an incision into the stomach for the removal of a foreign body, the ing being immediately afterwards closed—in contradistinction to 'gastrostomy,' the ng of a more or less permanent fistulous opening for purposes of feeding, when atient cannot obtain sufficient nourishment owing to some form of œsophageal ction.

cases of gastric ulcer perforation of the stomach not infrequently takes place. By ng the abdomen and closing the perforation, the vast majority of cases are cured, led the operation is done not longer than twelve or fifteen hours after the perforation aken place. The opening, which is generally situated on the anterior surface of the ach near the pylorus, is best closed by bringing the peritoneal surfaces on either side apposition by means of Lembert's sutures.

Excision of the pylorus has occasionally been performed, but the results of this opera- are by no means favourable, and, in cases of cancer of the pylorus, before operative edings are undertaken, the tumour has become so fixed and has so far implicated unding parts that removal of the pylorus is impossible and *gastro-enterostomy* has to stituted. The object of this operation is to make a fistulous communication een the stomach, on the cardiac side of the disease, and the small intestine, as high is possible. It gives great relief in any form of obstruction to the pylorus, especi- when associated with dilatation of the stomach. In this operation either the or the posterior surface of the stomach may be anastomosed to the jejunum, the for preference, in which case an opening has first to be made through the trans- mesocolon in order to reach the lesser sac. This opening must particularly avoid iddle colic vessels. In cases of cancer of the stomach involving other parts than ylorus, the question of removing the whole or greater part of the stomach has to be ered.

ypertrophy and spasm of the circumferential muscular coat of the pylorus coming ing the first few weeks or months of life, and somewhat erroneously described as *ital hypertrophic stenosis of the pylorus*, is a serious disorder of infancy. It is cterised by abdominal pains and obstinate vomiting coming on after food has been . Gastric peristalsis can be observed by inspection of the child's epigastrium after been fed and before vomiting has occurred. Progressive wasting from want of ishment, and death from exhaustion, tend to ensue. Gastro-enterostomy gives rable results in a small proportion of cases.

stomach is seldom ruptured from external violence, on account of its protected m. If it occurs, it is when the organ is distended with food. The stomach is mes injured in gunshot wounds. There is intense shock and severe pain, localised at the seat of the injury, but soon radiating over the whole abdomen. The treat- consists in opening the peritoneal cavity, clearing away all the extruded contents stomach, and repairing the rent.

The Small Intestine (Intestinum Tenue)

e small intestine is a convoluted tube, extending from the pylorus to the alve, where it joins the large intestine. It is about 6·5 metres long, and ally diminishes in diameter from its commencement to its termination. ontained in the central and lower parts of the abdominal cavity and ounded above and at the sides by the large intestine; it is in relation, t, with the greater omentum and abdominal parietes; a portion of it s below the superior aperture of the pelvis and lies in front of the rectum. all intestine consists of (1) a short, curved portion which is devoid of ntery and is named the duodenum, and (2) a long, greatly coiled part is attached to the posterior abdominal wall by the mesentery (p. 1143), named the intestinum tenue mesenteriale; the proximal two-fifths of

CC-0. In Public Domain. Gurukul Kangri Collection, Haridwar

Digitized by Arya Samaj Foundation Chennai and eGangotri

the latter constitute the jejunum (intestinum jejunum), the distal three-fifths the ileum (intestinum ileum).

The **duodenum** (fig. 1111) is so named because its length is about equal to the breadth of twelve fingers (25 cm.). It is the shortest, widest, and most fixed part of the small intestine; it has no mesentery, and is only partially covered by peritoneum. Its course presents a remarkable curve, somewhat of the shape of an imperfect circle.

It begins at the pylorus, passes backwards, upwards and to the right, beneath the quadrate lobe of the liver to the neck of the gall-bladder, varying slightly in direction according to the degree of distension of the stomach; it then makes a sharp curve (superior duodenal flexure) and descends along the right margin of the head of the pancreas, for a variable distance, generally to the level of the upper border of the body of the fourth lumbar vertebra. It now makes a second bend (inferior duodenal flexure), and passes almost horizontally from right to left across the vertebral column, having a slight

Fig. 1111.—The duodenum and pancreas. Exposed from the front.

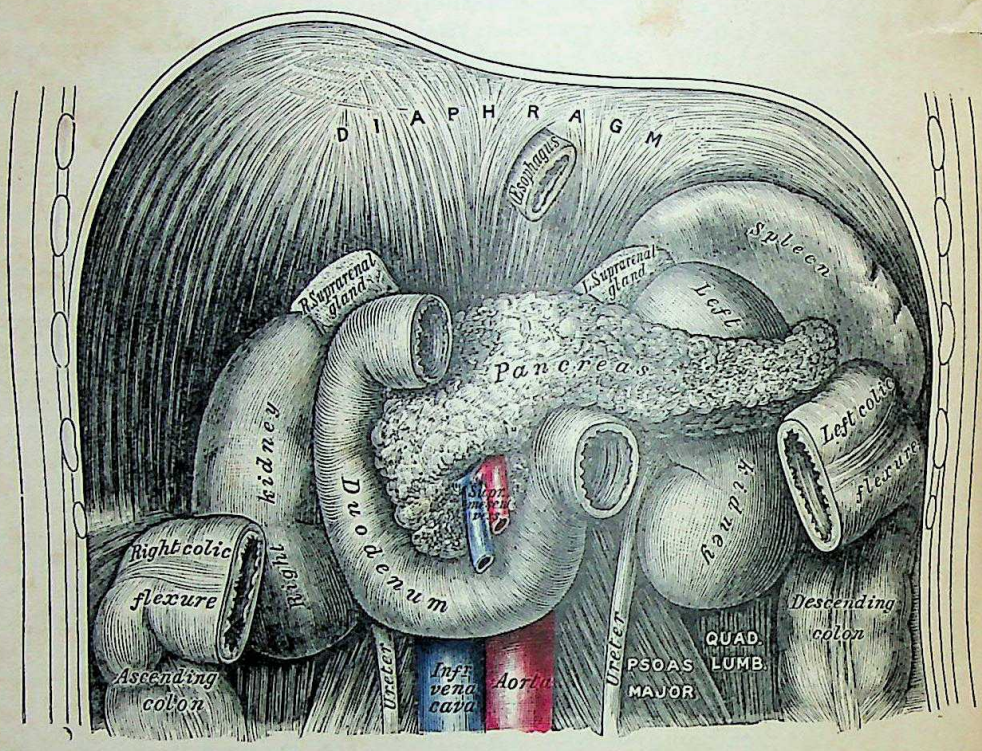

inclination upwards; it then ascends in front of the abdominal aorta for about 2·5 cm., and ends opposite the second lumbar vertebra in the jejunum. At its union with the jejunum it turns abruptly forwards, forming the *duodeno-jejunal flexure*. For descriptive purposes it is divided into superior, descending, horizontal, and ascending portions.

Relations.—The *superior portion* is about 5 cm. long, and is the most movable of the four portions; it begins at the pylorus, and ends at the neck of the gall-bladder. It is covered by peritoneum with the exception of a small part of its posterior surface near the neck of the gall-bladder and the inferior vena cava; the hepatoduodenal ligament is attached to the upper border, and the greater omentum to the lower border of the proximal half. It is in relation above and in front with the quadrate lobe of the liver and the gall-bladder; behind with the gastroduodenal artery, the bile-duct, and the portal vein; and below and behind with the head and neck of the pancreas. It is in such close relation with the gall-bladder that it is usually found to be stained by bile after death, especially on its anterior surface.

The *descending portion*, from 8 cm. to 10 cm. long, descends from the neck of the gall-bladder along the right side of the vertebral column as low as the upper border of the body of the fourth lumbar vertebra. It is crossed by the

CC-0. In Public Domain. Gurukul Kangri Collection, Haridwar

Digitized by Arya Samaj Foundation Chennai and eGangotri

transverse colon, the posterior surface of which is connected to the duodenum by a small quantity of connective tissue. The parts above and below the transverse colon are covered in front by peritoneum. It is in relation, in front, from above downwards, with the duodenal impression on the right lobe of the liver, the transverse colon, and the small intestine; behind, it has a variable relation to the front of the right kidney in the neighbourhood of its hilum, and is connected to it by loose areolar tissue; the renal vessels, the right edge of the inferior vena cava, and the Psoas major, are also behind it. At its medial side is the head of the pancreas, and the bile-duct; at its lateral side the right colic flexure. The bile-duct and the pancreatic duct together perforate the medial side of this portion of the duodenum obliquely, and open by a common orifice on the summit of a papilla (*papilla duodeni*) (figs. 1112, 1117), from 8 cm. to 10 cm. distal to the pylorus; the accessory pancreatic duct, when present, pierces it about 2 cm. proximal to and slightly in front of the papilla duodeni.

Fig. 1112.—The interior of the descending portion of the duodenum, showing the papilla duodeni.



The *horizontal portion*, about 10 cm. long, begins at the right side of the lower border of the fourth lumbar vertebra and passes from right to left, with a slight inclination upwards, in front of the inferior vena cava, and ends in the ascending portion in front of the abdominal aorta. Its anterior surface is covered by peritoneum, except near the middle line, where it is crossed by the superior mesenteric vessels. Its posterior surface is uncovered by peritoneum, except towards its left extremity, where the posterior layer of the mesentery sometimes covers it to a variable extent. This surface rests upon the right ureter, the right Psoas major, the right testicular vessels, the inferior vena cava. The upper surface is in relation with the head of the pancreas; the lower with the coils of the jejunum.

The *ascending portion*, about 2·5 cm. long, ascends on the aorta, as far as the level of the upper border of the second lumbar vertebra, where it turns sharply forwards (*duodenojejunal flexure*) and is continuous with the jejunum. It is in front of the left Psoas major, the left renal and testicular vessels, and is covered in front, and partly at the sides, by peritoneum continuous with the left portion of the mesentery.

The superior part of the duodenum, as stated above, is somewhat movable, the rest is practically fixed, and is bound down to neighbouring viscera and the posterior abdominal wall. In addition to this, the ascending part of

CC-0. In Public Domain. Gurukul Kangri Collection, Haridwar

Digitized by Arya Samaj Foundation Chennai and eGangotri

the duodenum and the duodenojejunal flexure are fixed by the *Musculus suspensorius duodeni* (muscle of Treitz) which arises from the right crus of the Diaphragm, close to the right margin of the œsophagus. It passes downwards and slightly forwards in close relation with the cœliac artery (sometimes dividing to enclose this vessel) and is attached to the posterior surface of the upper part of the duodenojejunal flexure, many fibres being continued into the mesentery.* This muscle consists of three parts, viz. an upper of striped muscular fibres, an intermediate elastic tendon, and a lower of unstriped muscular fibres.

Vessels and Nerves.—The *arteries* supplying the duodenum are the right gastric and superior pancreaticoduodenal branches of the hepatic, and the inferior pancreaticoduodenal branch of the superior mesenteric. The *veins* end in the lienal and superior mesenteric veins. The *nerves* are derived from the cœliac plexus.

The **mesenteric part** of the small intestine (intestinum tenue mesenteriale), about 6 metres long, extends from the duodenojejunal flexure to the colic valve, where it ends in the cæcum of the large intestine; it is arranged in a series of coils or loops which are attached to the posterior abdominal wall by the mesentery. It is divided into jejunum and ileum, the former name being given to the upper two-fifths and the latter to the lower three-fifths. There is no morphological line of distinction between these two parts, and the division is arbitrary; but at the same time the character of the intestine gradually undergoes a change from the beginning of the jejunum to the end of the ileum, so that portions of the bowel taken from these two situations present characteristic differences.

The **jejunum** (intestinum jejunum) has a diameter of about 4 cm., and is thicker, redder and more vascular than the ileum. The circular folds or valvulæ conniventes (p. 1158) of its mucous membrane are large and thickly set, and its villi surpass those of the ileum in size. The aggregated lymphatic-nodules (p. 1160) are almost absent in the upper part of the jejunum; in the lower part they are less frequently found than in the ileum, and are smaller and tend to assume a circular form. By grasping the jejunum between the finger and thumb the circular folds can be felt through the wall of the gut; as these folds are absent from the lower part of the ileum, it is possible in this way to distinguish the upper from the lower part of the small intestine.

The **ileum** (intestinum ileum) has a diameter of 3·5 cm., and its coats are thinner than those of the jejunum. A few circular folds are present in the upper part of the ileum, but they are small and disappear almost entirely towards its lower end; the aggregated lymphatic-nodules (Peyer's glands) are, however, larger and more numerous than in the jejunum. The jejunum for the most part occupies the umbilical and left iliac regions, while the ileum is situated chiefly in the umbilical, hypogastric, right iliac, and pelvic regions. The terminal part of the ileum usually lies in the pelvis, from which it ascends over the right Psoas major and right iliac vessels; it ends in the right iliac fossa by opening into the medial side of the cæcum.

The jejunum and ileum are attached to the posterior abdominal wall by an extensive fold of peritoneum, the *mesentery*, which allows of very free motion, so that each coil can accommodate itself to changes in form and position. The mesentery is fan-shaped; its vertebral border or root, about 15 cm. long, is attached to the posterior abdominal wall along a line running from the left side of the body of the second lumbar vertebra to the right sacro-iliac articulation, and crossing successively the horizontal part of the duodenum, the aorta, the inferior vena cava, the right ureter, and right Psoas major (fig. 1094). Its average breadth from the vertebral to the intestinal border is about 20 cm., but is greater in the middle than at its upper and lower ends; according to Lockwood the breadth of the mesentery tends to increase as age advances. Between the two layers of the mesentery are contained the jejunum, ileum, the jejunal and ileal branches of the superior mesenteric blood-vessels, nerves, lacteals, and lymph-glands, together with a variable amount of fat.

Meckel's diverticulum.—This is a pouch which projects from the lower part of the ileum in about 2 per cent. of subjects. Its average position is about 1 metre above the

* A. Low, *Journal of Anatomy and Physiology*, vol. xlii.

CC-0. In Public Domain. Gurukul Kangri Collection, Haridwar

Digitized by Arya Samaj Foundation Chennai and eGangotri

ic valve, and its average length about 5 cm. Its calibre is generally similar to that the ileum, and its blind extremity may be free or may be connected with the abdominal all or with some other portion of the intestine by a fibrous band. It represents the emains of the proximal part of the vitelline duct, the duct of communication between e yolk-sac and the primitive digestive tube in early fœtal life (p. 56).

FIG. 1113.—A section through the duodenum of a cat. ×60. (From Sharpey Schafer's Essentials of Histology.)

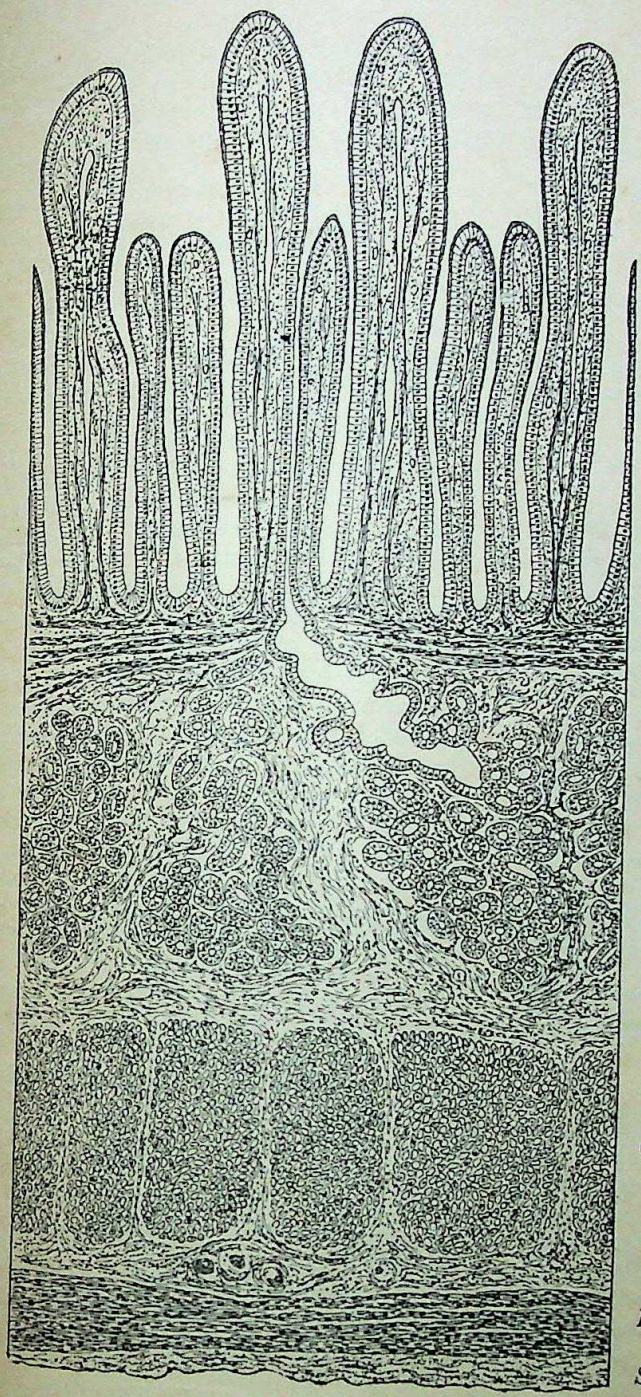

ructure.—The wall of the small intestine (fig. 1113) is composed of four coats: muscular, areolar, and mucous.

serous coat is formed of peritoneum. The superior portion of the duodenum is completely surrounded by this membrane near its pyloric end, but is only covered at the other extremity; the descending portion is covered by it in front, except it is in contact with the transverse colon; and the inferior portion lies behind the ours, which is separated from it in and near the middle line by the superior ric vessels. The rest of the small intestine is surrounded by the peritoneum, ng along its attached or mesenteric border; here a space is left for the vessels es to enter the wall of the gut.

muscular coat is thicker in the upper than in the lower part of the small intes- consists of an external longitudinal, and an internal circular layer of non-striped

CC-0. In Public Domain. Gurukul Kangri Collection, Haridwar

Digitized by Arya Samaj Foundation Chennai and eGangotri

muscular fibres. The *longitudinal layer* is thin; the *circular layer* is thick, and composed of fibres of considerable length.

The *areolar or submucous coat* unites the mucous and muscular layers. It consists of loose, areolar tissue containing blood-vessels, lymphatic vessels, and nerves.

The *mucous membrane* is thick and highly vascular in the upper part of the small intestine, but thinner and less vascular in the lower part. It consists of the following structures: next the areolar or submucous coat is the *muscularis mucosæ*, consisting of an outer longitudinal and inner circular layer of unstriped muscular fibres; internal to the muscularis mucosæ is a quantity of retiform tissue, enclosing in its meshes lymph-corpuscles, and in which the blood-vessels and nerves ramify; lastly, a basement-membrane, supporting a single layer of tall columnar cells. The cells are granular in appearance, and each possesses a clear oval nucleus. At their superficial or unattached ends is a distinct layer of highly refracting material, marked by vertical striæ (the *striated border*). Goblet-cells occur at intervals in the epithelial layer.

Contained within or belonging to the mucous membrane are the following structures:

Circular folds.	Duodenal glands.
Villi.	Solitary lymphatic nodules.
Intestinal glands.	Aggregated lymphatic nodules.

The **circular folds** or **valvulæ conniventes** (fig. 1114) are large transverse folds of mucous membrane which project into the lumen of the bowel. They are composed of reduplications of the mucous membrane, the two layers of the fold being bound together by submucous tissue; unlike the folds in the stomach, they are permanent, and are not obliterated when the intestine is distended. The majority extend transversely round the intestine for about one-half or two-thirds of its circumference, but some form complete circles, some bifurcate and join adjacent folds, and others have a spiral direction; the latter usually extend a little more than once round the bowel, but occasionally two or three times. The larger folds are about 8 mm. in depth at their broadest part; but the greater number are of smaller size. The larger and smaller folds alternate with each other. Circular folds are not found at the commencement of the duodenum, but begin to appear about 2·5 or 5 cm. beyond the pylorus. Distal to the point where the bile- and pancreatic ducts enter the duodenum, they are very large and closely approximated. In the upper one-half of the jejunum they are large and numerous, but from this point, down to the middle of the ileum, they diminish considerably in size. In the lower part of the ileum they are almost entirely absent; hence the comparative thinness of this portion of the intestine, as compared with the duodenum and jejunum. The circular folds retard the passage of the food along the intestine, and afford an increased surface for absorption.

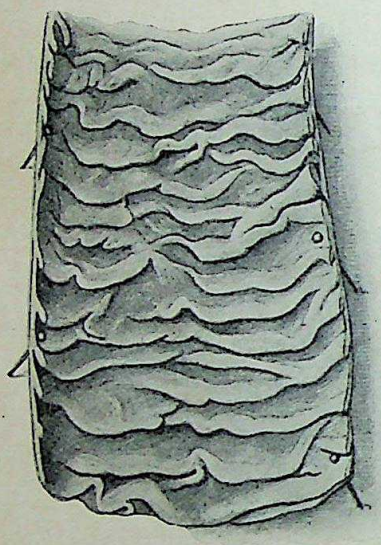

FIG. 1114.—The interior of a portion of the upper part of the jejunum, showing the circular folds.

The **intestinal villi** are highly vascular processes, just visible to the naked eye; they project from the mucous membrane of the whole of the small intestine, and give to its surface a velvety appearance. They are large and numerous in the duodenum and jejunum, but are smaller and fewer in the ileum.

Structure of the villi (figs. 1115, 1116).—The essential parts of a villus are: the lacteal vessel, the blood-vessels, the epithelium, the basement-membrane and the muscular tissue of the mucosa, all being supported and held together by retiform tissue.

The *lacteals* are in some cases double, and in some animals multiple, but usually there is a single vessel. Situated in the axis of the villus, each commences by a dilated blind extremity near to, but not quite at, the summit of the villus. The wall is composed of a single layer of endothelial cells.

The *muscular fibres* are derived from the muscularis mucosæ, and are arranged in bundles around the lacteal vessel, extending from the base to the summit of the villus, and giving off, laterally, individual muscle cells, which are enclosed by the reticulum, and by it are attached to the basement-membrane and to the lacteal.

The *blood-vessels* (fig. 1117) form a plexus under the basement-membrane, and are enclosed in the reticular tissue.

These structures are surrounded by the *basement-membrane*, which is made up of a stratum of endothelial cells and upon this is placed a layer of *columnar epithelium*, the characteristics of which have been described above. The *retiform tissue* forms a network (fig. 1116) in the meshes of which a number of leucocytes are found.

CC-0. In Public Domain. Gurukul Kangri Collection, Haridwar

Digitized by Arya Samaj Foundation Chennai and eGangotri

Fig. 1115.—A vertical section through a villus of the small intestine of a dog. × 80.

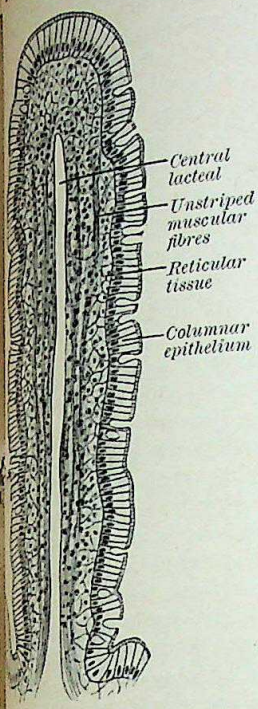

Fig. 1116.—A transverse section through a villus of the human intestine. × 350. (v. Ebner.)

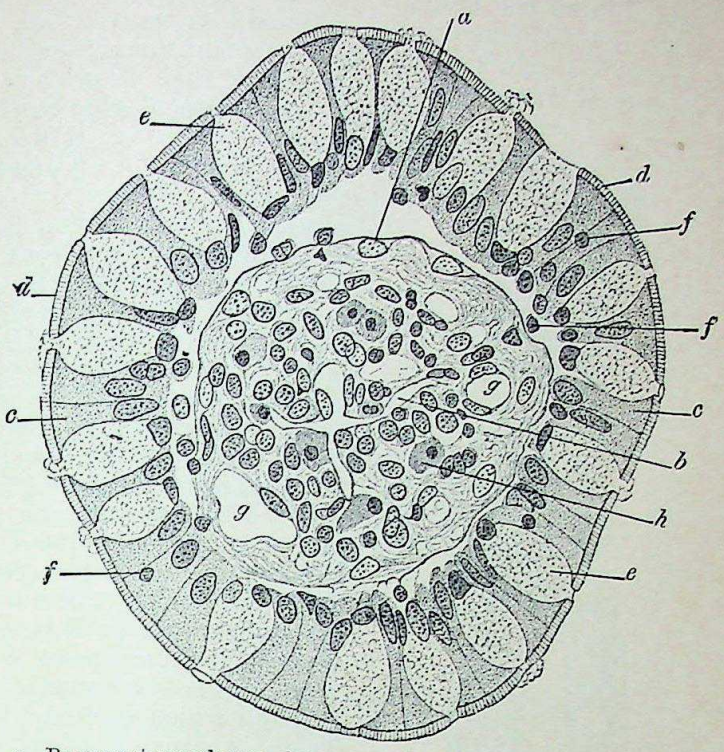

a. Basement-membrane, here somewhat shrunken away from the epithelium. *b.* Lacteal. *c.* Columnar epithelium; *d.* its striated border. *e.* Goblet-cells. *f.* Leucocytes in epithelium. *f'.* Leucocyte below epithelium. *g.* Blood-vessels. *h.* Muscle-cells cut across.

Fig. 1117.—The villi of the small intestine, showing the blood-vessels and the lymphatic vessels. (Cadiat.)

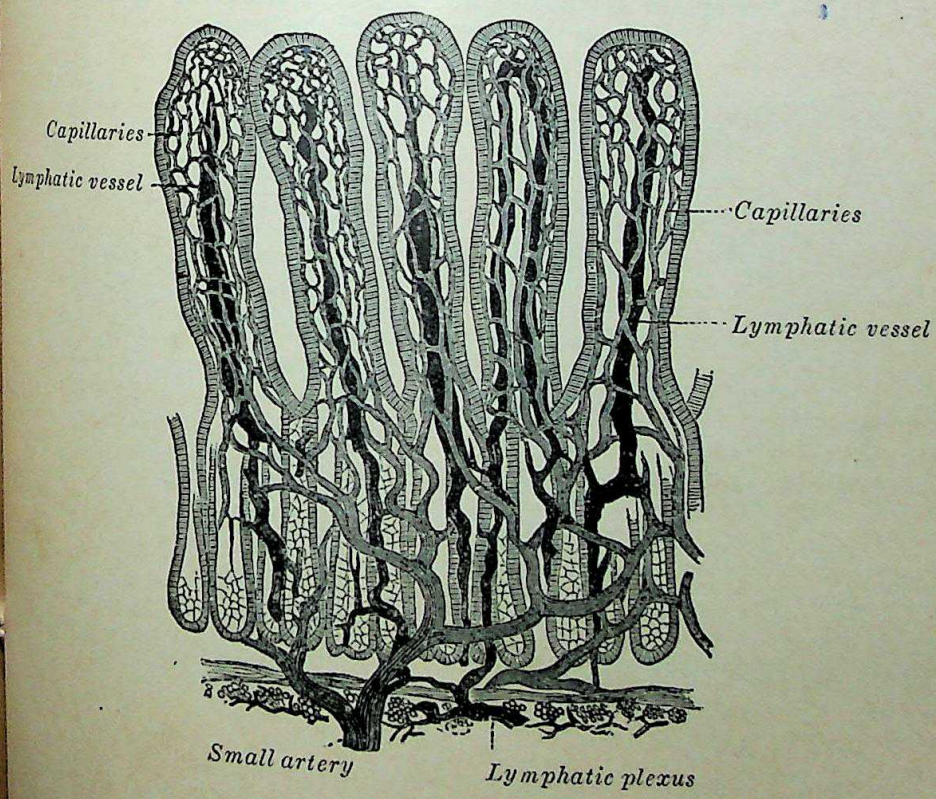

CC-0. In Public Domain. Gurukul Kangri Collection, Haridwar

Digitized by Arya Samaj Foundation Chennai and eGangotri

The **intestinal glands** (crypts of Lieberkühn) (fig. 1118) are found in considerable numbers over every part of the mucous membrane of the small intestine. They are simple tubular glands, arranged perpendicularly to the surface, upon which they open by small circular apertures. Their orifices may be seen with the aid of a lens as minute dots scattered between the villi. Their walls are thin, consisting of a basement-membrane lined by columnar epithelium, and covered on their exterior by capillary vessels.

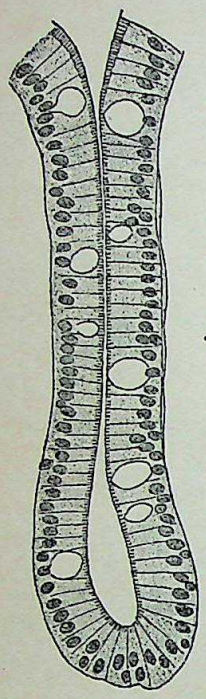

Fig. 1118.—An intestinal gland from the human intestine. (Flemming.) (From Quain's Elements of Anatomy.)

The **duodenal glands** (Brunner's glands) are limited to the duodenum (fig. 1113), and are found in the submucous areolar tissue. They are largest and most numerous near the pylorus, forming an almost complete layer in the superior portion, and upper half of the descending portion, of the duodenum; beyond this they gradually diminish in number and disappear at the junction of the duodenum and jejunum. They are small compound acinotubular glands, each consisting of a number of alveoli lined by short columnar epithelium and opening by a duct on the inner surface of the intestine.

The **solitary lymphatic nodules** are found scattered throughout the mucous membrane of the small intestine, but are most numerous in the lower part of the ileum. Their free surfaces are covered with rudimentary villi, except at the summits, and each nodule is surrounded by the openings of the intestinal glands. Each consists of a dense interlacing retiform tissue closely packed with lymph-corpuscles, and permeated by an abundant capillary network. The interspaces of the retiform tissue are continuous with larger lymph-spaces which surround the nodule, through which they communicate with the lacteal system. They are situated partly in the submucous tissue, partly in the mucous coat, where they form slight projections of its epithelial layer.

The **aggregated lymphatic nodules** (Peyer's glands) (figs. 1119, 1120) form circular or oblong patches, from twenty to thirty in number, and varying in length from 2 cm. to 10 cm. They are best marked in the young subject, become indistinct in middle age, and sometimes disappear altogether in advanced life. They are largest and most numerous in the

Fig. 1119.—Aggregated lymphatic nodules. A, from the upper part, and B, from the lower part, of the ileum.

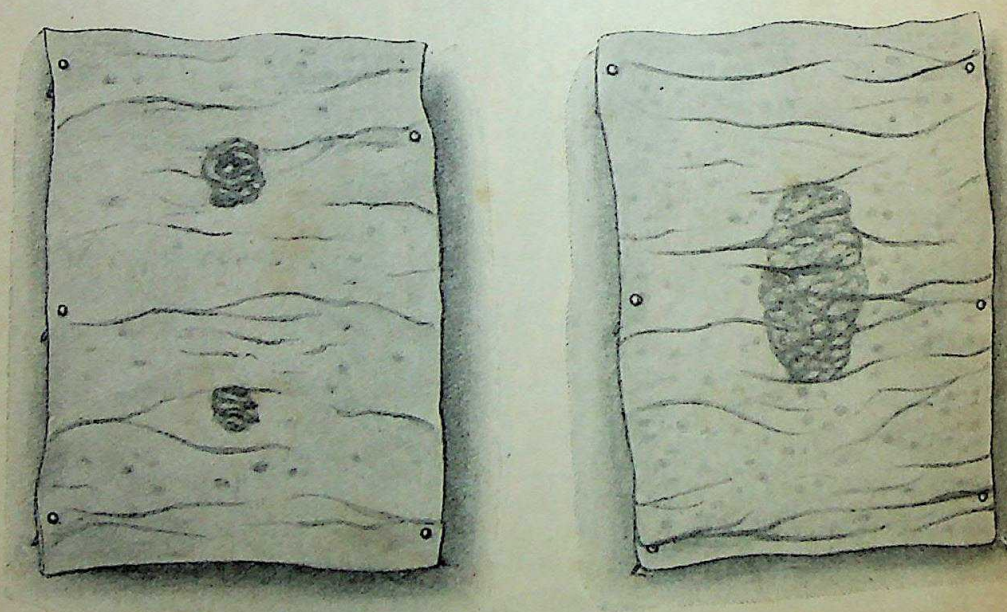

A B

ileum. In the lower part of the jejunum they are small, circular, and few in number. They are occasionally seen in the duodenum. They are placed lengthwise in the intestine, and are situated in the portion of the tube most distant from the attachment of the mesentery. Each patch is formed of a group of solitary lymphatic nodules

CC-0. In Public Domain. Gurukul Kangri Collection, Haridwar

Digitized by Arya Samaj Foundation Chennai and eGangotri

vered with columnar epithelium; the patches do not, as a rule, possess villi on their free surfaces. They are freely supplied with blood-vessels (fig. 1121), which form an

FIG. 1120.—A vertical section through a human aggregated lymphatic nodule, injected through the lymphatic vessels.

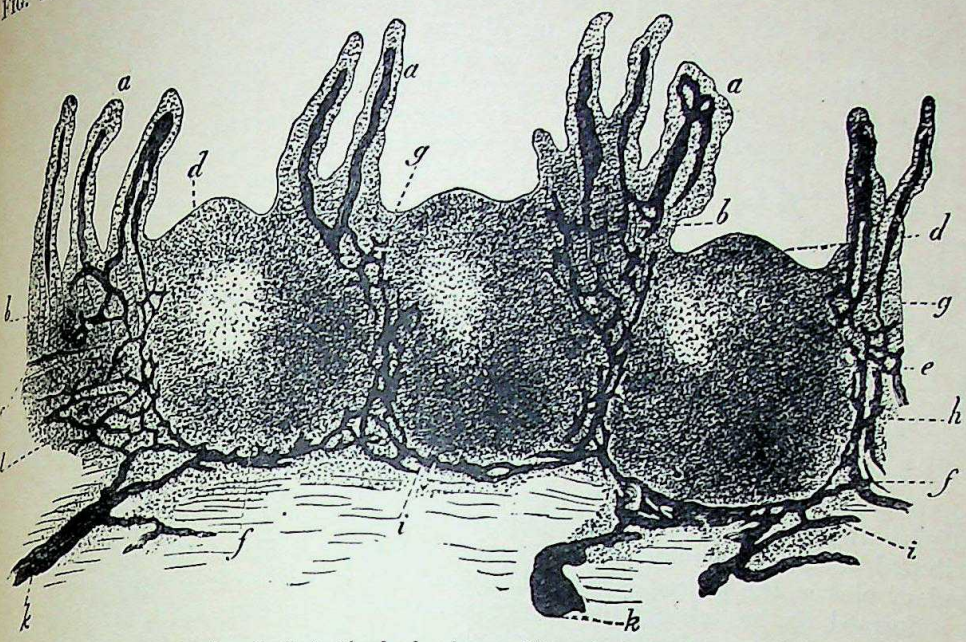

a. Villi with their lacteals. b. Intestinal glands. c. Muscularis mucosæ. d. Cupula or apex of solitary lymphatic nodule. e. Mesial zone of nodule. f. Base of nodule. g. Points of exit of the lacteals from the villi, and entrance into the true mucous membrane. h. Retiform arrangement of the lymphatic vessels in the mesial zone. i. Course of the latter at the base of the nodule. k. Confluence of the lymphatic vessels in the submucous tissue. l. Follicular tissue of the latter.

ant plexus around each nodule and give off fine branches permeating the lymphoid e in the interior of the nodule. The plexuses of lymphatic vessels are especially ant around these patches.

FIG. 1121.—A transverse section through the equatorial plane of three lymphatic nodules of the rabbit.

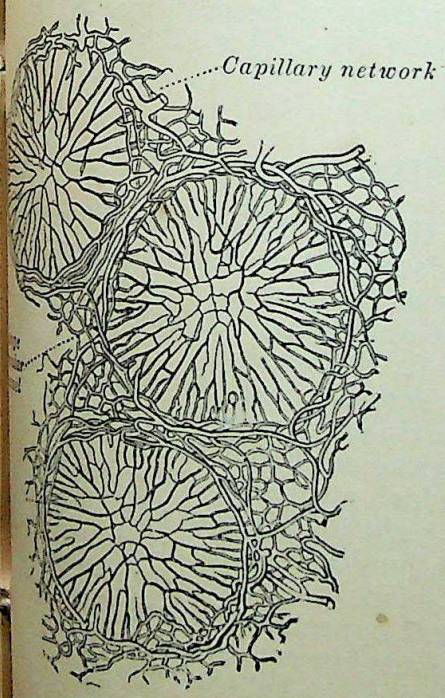

FIG. 1122.—The myenteric plexus of the rabbit. × 50.

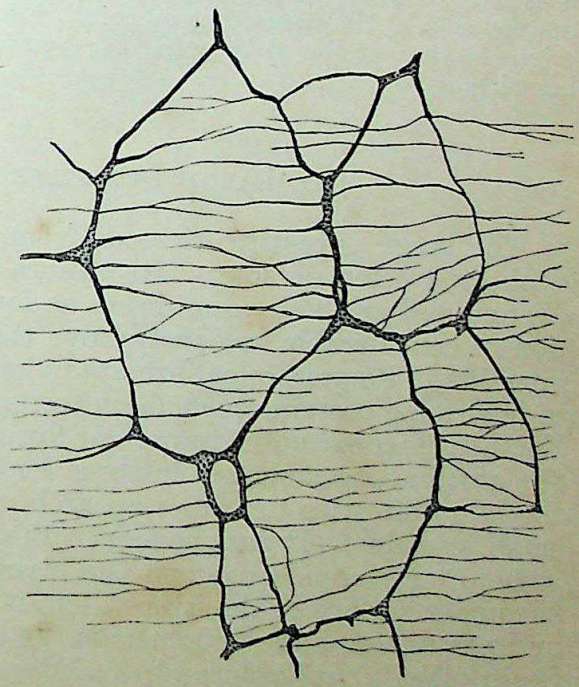

sels and Nerves.—The jejunum and ileum are supplied by the superior mesenteric the jejunal and ileal branches of which, having reached the attached border of el, run between the serous and muscular coats, with frequent inosculations, to

CC-0. In Public Domain. Gurukul Kangri Collection, Haridwar

Digitized by Arya Samaj Foundation Chennai and eGangotri

the free border, where they also anastomose with other branches running round the opposite surface of the gut. From these vessels numerous branches are given off, which pierce the muscular coat, supplying it and forming an intricate plexus in the submucous tissue. From this plexus minute vessels pass to the glands and villi of the mucous membrane. The *veins* have a course and arrangement similar to the arteries. The *lymphatic vessels* of the small intestine (lacteals) are arranged in two sets, those of the mucous membrane and those of the muscular coat. The lymphatic vessels of the villi commence in these structures in the manner described on p. 1158. They form an intricate plexus in the mucous and submucous tissue, being joined by the lymphatic vessels from the lymph-spaces at the bases of the solitary nodules, and from this pass to larger vessels at the mesenteric border of the gut. The lymphatic vessels of the muscular coat are situated to a great extent between the two layers of muscular fibres, where they form a close plexus; throughout their course they communicate freely with those from the mucous membrane, and open in the same manner as these into the origins of the lacteal vessels at the attached border of the gut.

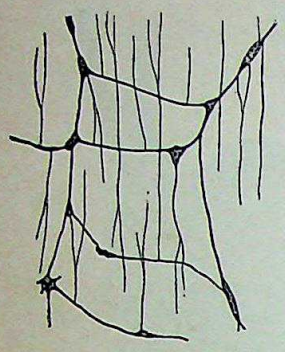

FIG. 1123.—The plexus of the submucosa of the rabbit. × 50.

The *nerves* of the small intestine are derived from the vagus and splanchnic nerves through the cœliac ganglia and the plexuses around the superior mesenteric artery. They run to the *myenteric plexus* (*Auerbach's plexus*) (fig. 1122) of nerves and ganglia, situated between the circular and longitudinal layers; from this plexus filaments are distributed to the muscular coats of the intestine. From the myenteric plexus a secondary plexus, the *plexus of the submucosa* (*Meissner's plexus*) (fig. 1123), is derived, and is formed by branches which have perforated the circular muscular layer. This plexus also contains ganglia from which the nerve-fibres pass to the muscularis mucosæ and to the mucous membrane. The nerve-bundles of the submucous plexus are finer than those of the myenteric plexus.

Keith states that 'Auerbach's plexus is not composed simply of ganglionic cells and nerve-fibres; it contains numerous other cells to which Kölliker called attention, and which may be described as Kölliker's cells. These cells have small bodies which send out numerous branched processes, and differ from pure sheath-cells in staining reaction and structure. It is through these cells that Auerbach's tissue is linked up with the musculature of the bowel. The nerve-fibres which former authors have described as distributed to the muscular and other coats of the bowel are probably sensory in nature. Sections of the developing bowel show that the outer and inner muscular coats are developed from a germinal layer situated between them. Auerbach's plexus represents the residue of the germinal or developmental intermediate layer. Probably the ganglionic cells may be of central origin, but the cells of Kölliker are apparently undifferentiated muscle-cells.' He states that in point of development Auerbach's plexus is similar in origin to that of the atrioventricular bundle of His, and is of opinion that they are homologous.*

THE LARGE INTESTINE (INTESTINUM CRASSUM)

The **large intestine** extends from the end of the ileum to the anus, and is about 1·5 metres long. Its calibre is largest at its commencement at the cæcum, and gradually diminishes as far as the rectum, where there is a dilatation of considerable size just above the anal canal. It differs from the small intestine in its greater calibre, its more fixed position, its sacculated form, and in possessing certain appendages to its external coat, the *appendices epiploicæ*. Further, its longitudinal muscular fibres do not form a continuous layer around the gut, but are arranged in three longitudinal bands or *tæniæ*. In its course the large intestine describes an arch which surrounds the convolutions of the small intestine. It commences in the right iliac region, in a dilated part, the *cæcum*. It ascends through the right lumbar and hypochondriac regions to the under surface of the liver; here it bends (the *right colic flexure*) to the left, and passes across the abdomen to the left hypochondriac region; it then bends again (the *left colic flexure*), and descends through the left lumbar and iliac regions to the pelvis, where it forms a loop called the *sigmoid flexure*: from this it is continued along the lower part of the posterior wall of the pelvis to the anus. It is divided into the cæcum, the colon, the rectum, and the anal canal.

* *Proceedings of the Anatomical Society of Great Britain and Ireland*, January 1915.

CC-0. In Public Domain. Gurukul Kangri Collection, Haridwar

Digitized by Arya Samaj Foundation Chennai and eGangotri

The **cæcum** (fig. 1124), the commencement of the large intestine, is the large pouch situated below the level of the colic valve. Its closed end is directed downwards, and its open end upwards, communicating directly with the colon, of which the cæcum appears to be the beginning or head, and hence the name *caput cæcum coli* was formerly applied to it. Its average length is about 6 cm. and its breadth about 7·5 cm. It is situated in the right iliac fossa, above the lateral half of the inguinal ligament: it rests on the Iliacus and Psoas major, and is usually in contact with the anterior abdominal wall, but the greater mentum, and, if the cæcum be empty, some coils of small intestine, may lie front of it. As a rule, it is entirely enveloped by peritoneum, but in about

FIG. 1124.—The terminal part of the ileum, the cæcum and the vermiform process. Anterior aspect.

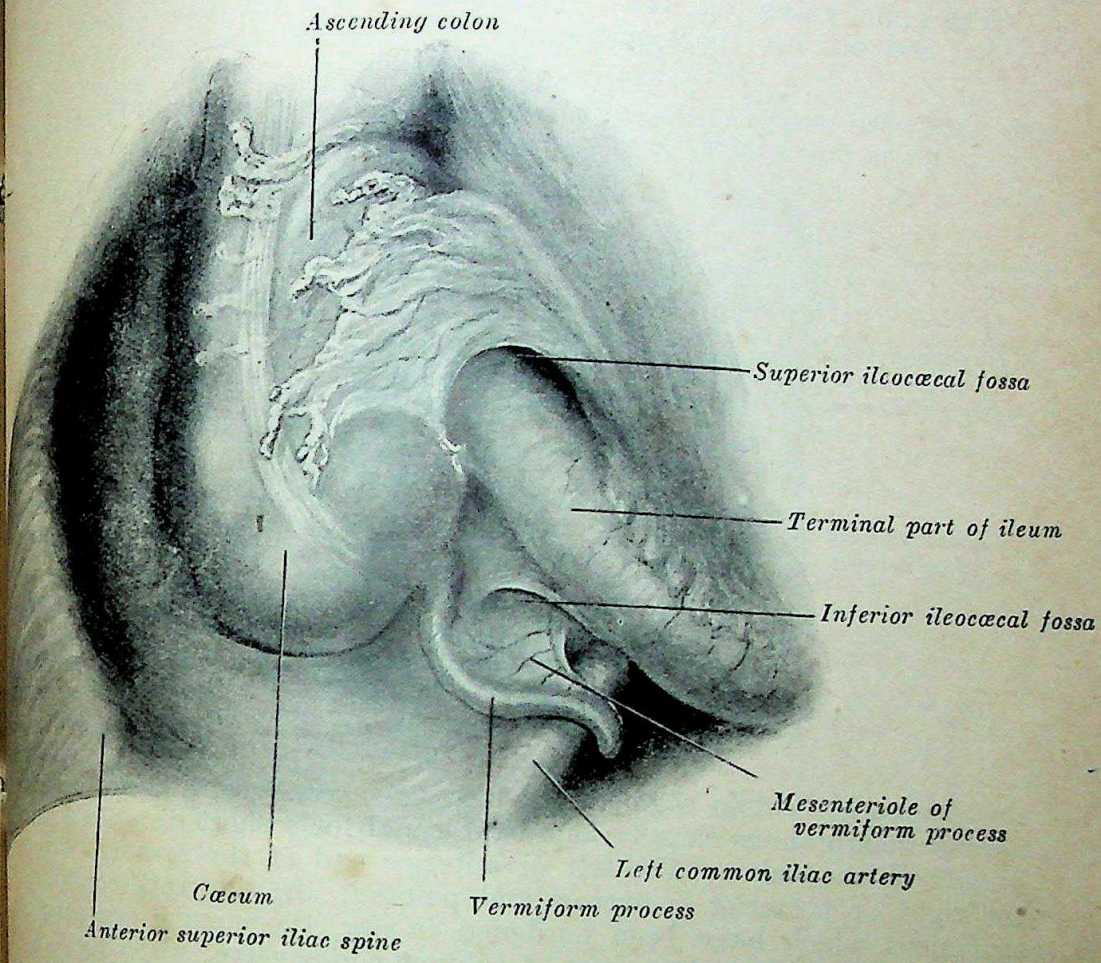

er cent. of cases (Berry) the peritoneal covering is incomplete, the upper of the posterior surface being uncovered, and connected to the iliac fascia connective tissue. The cæcum enjoys a considerable amount of movement, that it may become herniated down the right inguinal canal, and has occasion- been found in an inguinal hernia on the left side.

The cæcum varies in shape, but, according to Treves, it may be classified under one r types. In early fœtal life it is short, conical, and broad at the base, with its apex d upwards and medialwards towards the ileocolic junction. It then resembles the of the mangabey monkey. As the fœtus grows, the cæcum increases in length more in breadth, so that it forms a longer tube than in the primitive form and without the base, but with the same inclination of the apex towards the ileocolic junction. This is seen in the spider monkey. As development goes on, the lower part of the tube to grow and the upper part becomes greatly increased, so that at birth there is a w tube, the vermiform process, hanging from a conical projection, the cæcum. This infantile form, and as it persists throughout life in about 2 per cent. of subjects, it is ed by Treves as the *first* of his four types of human cæca. The cæcum is conical and ppendix rises from its apex. The three tæniæ coli (p. 1170) start from the appendix equidistant from each other. In the *second* type, the conical cæcum has become

CC-0. In Public Domain. Gurukul Kangri Collection, Haridwar

Digitized by Arya Samaj Foundation Chennai and eGangotri

quadrate by the growing out of a saccule on either side of the anterior tænia. These saccules are of equal size, and the appendix arises from between them, instead of from the apex of a cone. This type is found in about 3 per cent. of subjects. The *third* type is the normal type of man. Here the two saccules, which in the second type were uniform, have grown at unequal rates: the right with greater rapidity than the left. In consequence of this an apparently new apex has been formed by the growing downwards of the right saccule, and the original apex, with the appendix attached, is pushed over to the left towards the ileocolic junction. The three tæniæ still start from the base of the vermiform process, but they are now no longer equidistant from each other, because the right saccule has grown between the anterior and posterolateral tæniæ, pushing them over to the left. This type occurs in about 90 per cent. of subjects. The *fourth* type is merely an exaggerated condition of the third; the right saccule is still larger, and at the same time the left saccule has become atrophied, so that the original apex of the cæcum, with the vermiform process, is close to the ileocolic junction, and the anterior tænia courses medialwards to the same situation. This type is present in about 4 per cent. of subjects.

The colic valve (fig. 1125).—The lower end of the ileum opens into the medial and posterior part of the large intestine, at the point of junction of the cæcum with the colon. The opening is guarded by a valve, consisting of two segments or lips, which project into the lumen of the large intestine. If the intestine has been inflated and dried, the lips are of a semilunar shape. The upper lip, nearly horizontal in direction, is attached by its convex border to the line of junction of the ileum with the colon; the lower lip, the longer and more concave, is attached to the line of junction of the ileum with the cæcum. At the ends of the aperture the two segments of the valve coalesce, and are continued as narrow membranous ridges around the canal for a short distance, forming the *frenula* of the valve. The left or anterior end of the aperture is rounded; the right or posterior is narrow and pointed. In the fresh condition, or in specimens which have been hardened *in situ*, the circular muscular coat of the ileum is thickened to form a sphincter-like valve, while the lips of the valve project as thick folds into the lumen of the cæcum, and the opening between them may present the appearance of a slit or may be somewhat oval in shape.

Fig. 1125.—The interior of the cæcum and the lower end of the ascending colon, showing the colic valve.

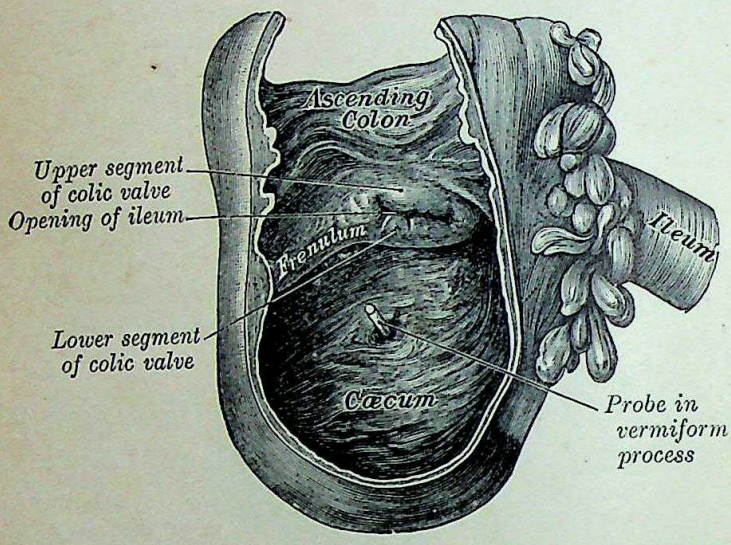

Each lip of the valve is formed by a reduplication of the mucous membrane and of the circular muscular fibres of the intestine, the longitudinal fibres and peritoneum being continued uninterruptedly from the small to the large intestine.

The surfaces of the valve directed towards the ileum are covered with villi and present the characteristic structure of the mucous membrane of the small intestine; while those turned towards the large intestine are destitute of villi and marked with the orifices of the numerous tubular glands peculiar to the mucous membrane of the large intestine. It was formerly maintained that this valve prevented reflux from the cæcum into the ileum, but in all probability it acts as a sphincter round the end of the ileum and prevents the contents of the ileum from passing too quickly into the cæcum; the valve is kept in a condition of tonic contraction by impulses which reach it through the splanchnic nerves.

The **vermiform process** or **appendix** (fig. 1124) is a long, narrow, worm-shaped tube, which starts from what was originally the apex of the cæcum,

CC-0. In Public Domain. Gurukul Kangri Collection, Haridwar

Digitized by Arya Samaj Foundation Chennai and eGangotri

and may pass in one of several directions: upwards behind the cæcum; to the left behind the ileum and mesentery; or downwards into the lesser pelvis. It varies from 2 cm. to 20 cm. in length, the average being about 9 cm. It is connected by a fold of peritoneum (mesenteriole) to the lower part of the mesentery of the ileum. This fold, in the majority of cases, is more or less triangular in shape, and as a rule extends along the entire length of the tube. Between the two layers of the mesenteriole, and close to its free margin, lies the appendicular artery. The canal of the vermiform process is small, and communicates with the cæcum by an orifice which is placed below and behind the ileocolic opening. The orifice is sometimes guarded by a semilunar valve formed by a fold of mucous membrane.

FIG. 1126.—A transverse section through the human vermiform process. ×20.

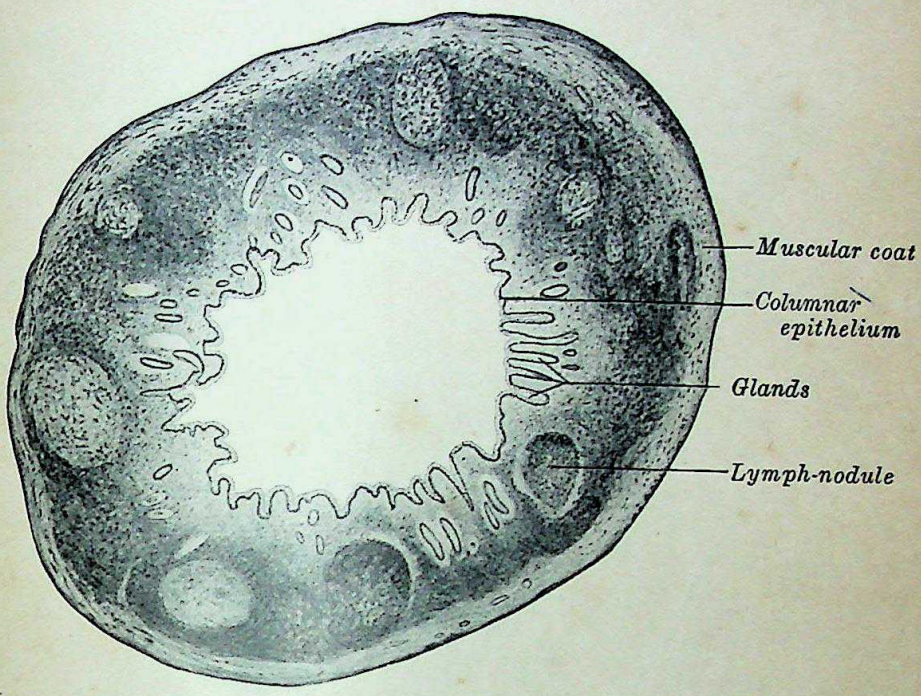

Structure.—The coats of the vermiform process are the same as those of the intestine: serous, muscular, submucous, and mucous. The *serous* coat forms a complete investment for the tube, except along the narrow line of attachment of its mesenteriole. The longitudinal *muscular fibres* do not form three bands as in the greater part of the large intestine, but invest the whole organ, except at one or two points where both the longitudinal and circular layers are deficient, so that the peritoneal and submucous coats are contiguous over small areas. The *circular muscular fibres* form a thicker layer than the longitudinal fibres, and are separated from them by a small amount of connective tissue. The *submucous* coat is well developed, and contains a large number of masses of lymphoid tissue which cause the mucous membrane to bulge into the lumen and so render the latter of small size and irregular shape. The *mucous membrane* is lined by columnar epithelium and resembles that of the rest of the large intestine, but the intestinal glands are fewer in number (fig. 1126).

The colon is divided into four parts: the ascending, transverse, descending, and sigmoid.

The **ascending colon**, about 15 cm. long, is smaller in calibre than the colon. It begins at the cæcum, and ascends to the under surface of the right lobe of the liver, where it is lodged in a shallow depression, the colic impression; then it bends abruptly forwards and to the left, forming the *right colic* (*hepatic*) flexure (fig. 1111). It is retained in contact with the posterior wall of the abdomen by the peritoneum, which covers its sides and anterior surface, its posterior surface being connected by loose areolar tissue with the Iliacus, Quadratus lumborum, aponeurotic origin of Transversus abdominis, and the front of the lower and lateral part of the right kidney. Sometimes the peritoneum completely invests it, and forms a distinct but narrow

CC-0. In Public Domain. Gurukul Kangri Collection, Haridwar

Digitized by Arya Samaj Foundation Chennai and eGangotri

mesocolon.* It is in relation, in front, with the convolutions of the ileum and the abdominal parietes.

The **transverse colon** (fig. 1087), about 50 cm. long, begins at the right colic flexure, in the right hypochondriac region, and passing across the abdomen into the left hypochondriac region, curves sharply on itself beneath the lower end of the spleen, forming the *left colic (splenic) flexure*. In its course across the abdomen it lies in umbilical and epigastric regions, and describes an arch, the concavity of which is usually directed backwards and a little upwards; towards its splenic end there is often an abrupt U-shaped curve which may descend lower than the main curve. The posterior surface of its right extremity is devoid of peritoneum, and is attached by areolar tissue to the descending

FIG. 1127.—The lower part of the descending colon, the sigmoid colon, and the rectum, seen from the front, after the removal of the pubic bones and the bladder.

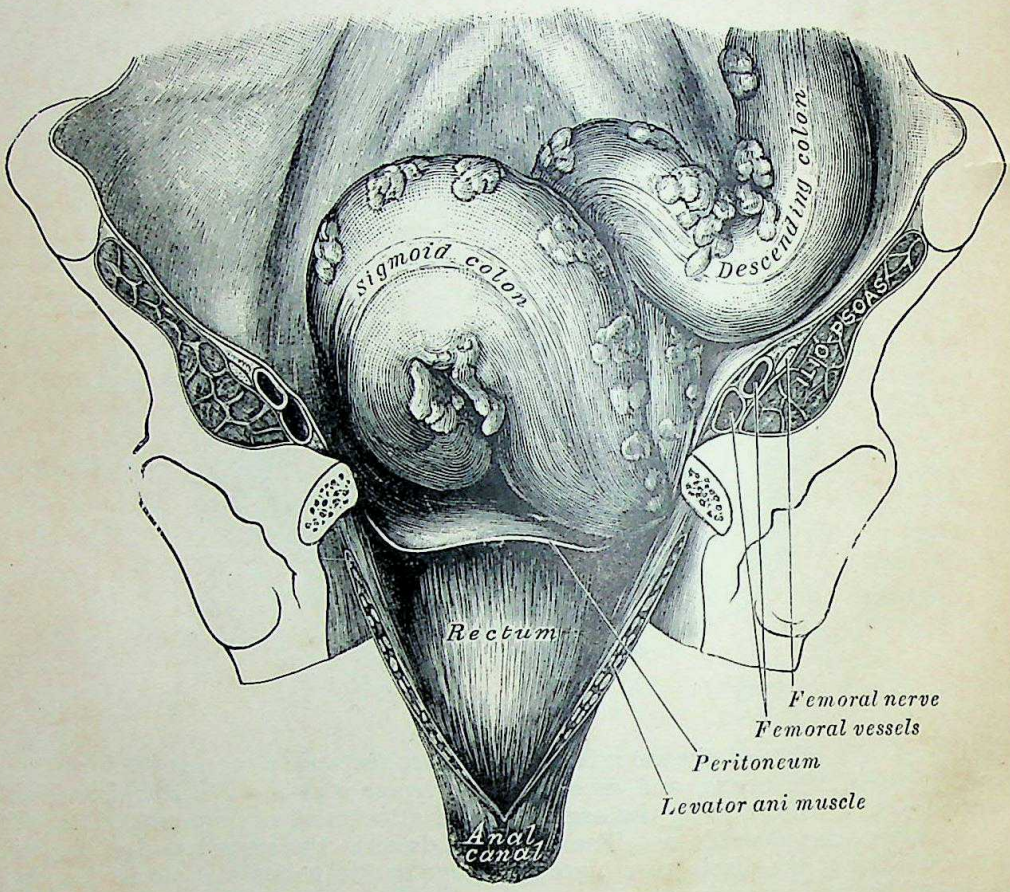

part of the duodenum and the head of the pancreas. Between the head of the pancreas and the left colic flexure the transverse colon is almost completely invested by peritoneum, and is connected to the anterior border of the pancreas by the *transverse mesocolon*. It is in relation, by its upper surface, with the liver and gall-bladder, the greater cuvature of the stomach, and the lower end of the spleen; by its under surface, with the small intestine; by its anterior surface with the anterior layers of the greater omentum and the abdominal parietes; its posterior surface is in relation with the descending portion of the duodenum, the head of the pancreas, the upper end of the mesentery, the duodenojejunal flexure and some of the coils of the jejunum and ileum.

The *left colic or splenic flexure* (fig. 1111) is situated at the junction of the transverse and descending parts of the colon in the left hypochondriac region, and is in relation with the lower end of the spleen and the tail of the pancreas; the flexure is so acute that the end of the transverse colon usually lies in

* Treves examined one hundred subjects, and found that in fifty-two there was neither an ascending nor a descending mesocolon; in fourteen both were present; while in twelve there was an ascending, and in twenty-two a descending, mesocolon. It follows, therefore, that in performing lumbar colotomy a mesocolon may be expected upon the left side in 36 per cent. of all cases, and on the right in 26 per cent.—*The Anatomy of the Intestinal Canal and Peritoneum in Man*, 1885, p. 55.

CC-0. In Public Domain. Gurukul Kangri Collection, Haridwar

Digitized by Arya Samaj Foundation Chennai and eGangotri

ontact with the front of the descending colon. The left colic flexure lies at a higher level than, and on a plane posterior to, the right colic flexure, and is attached to the Diaphragm, opposite the tenth and eleventh ribs, by a peritoneal fold, named the *phrenicocolic ligament*, which assists in supporting the lower end of the spleen (p. 1144).

The **descending colon**, about 25 cm. long, passes downwards through the left hypochondriac and lumbar regions and in front of the lower part of the left kidney. At the lower end of the kidney it turns medialwards towards the

FIG. 1128.—The posterior aspect of the rectum. Exposed by removing the lower part of the sacrum and the coccyx.

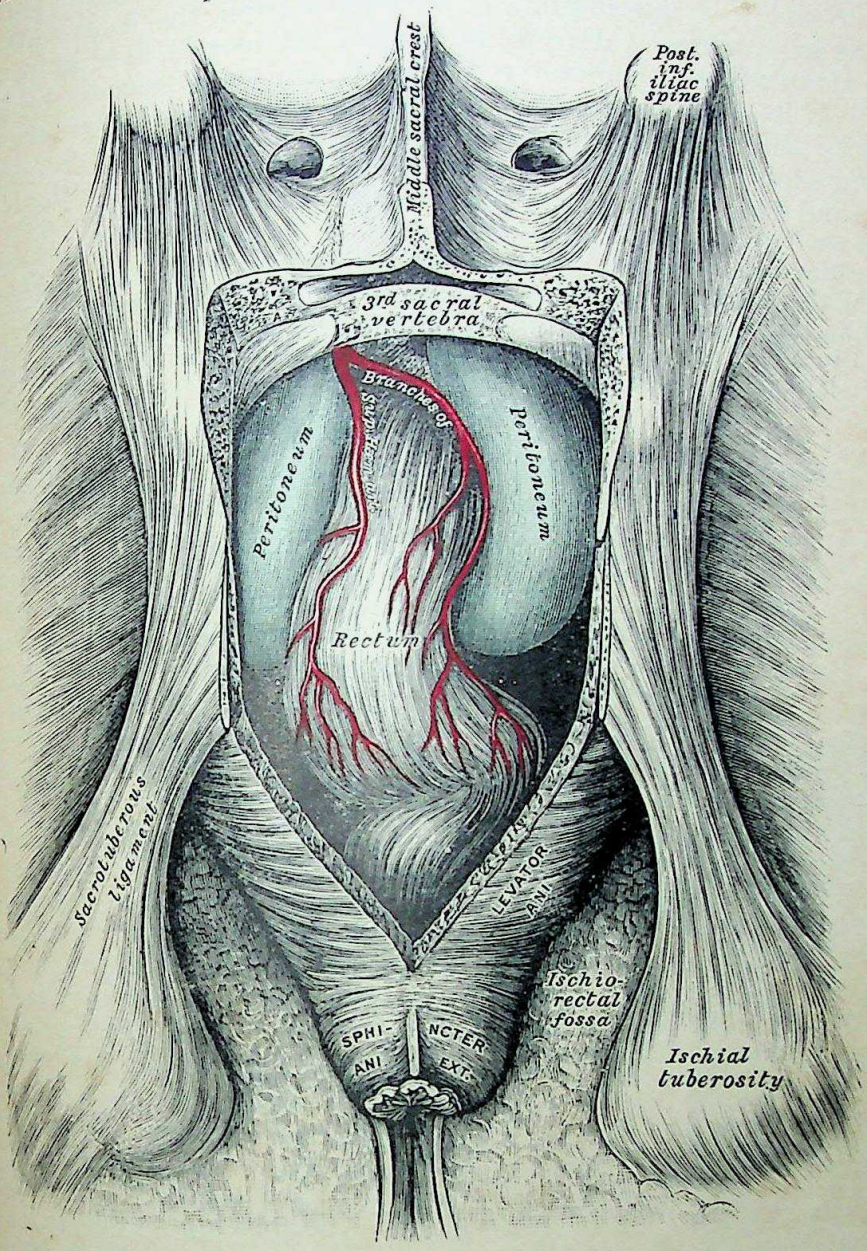

al border of the Psoas major, and descends, in the angle between Psoas or and Quadratus lumborum, to the crest of the ilium; it then curves wards and medialwards in front of the Iliacus and Psoas major, and ends the sigmoid colon at the superior aperture of the lesser pelvis.* The toneum covers its anterior surface and sides, while its posterior surface nnected by areolar tissue with the lower and lateral part of the left ney, the aponeurotic origin of the Transversus abdominis, the Quadratus orum, the Iliacus and the Psoas major (1111, 1127). It is smaller in re, more deeply placed, and more frequently covered with peritoneum on posterior surface, than the ascending colon (p. 1166 *). In front of it are coils of small intestine.

* The descending colon is sometimes described as ending at the level of the iliac crest, the between that level and the superior aperture of the lesser pelvis being named the *iliac colon.*

CC-0. In Public Domain. Gurukul Kangri Collection, Haridwar

Digitized by Arya Samaj Foundation Chennai and eGangotri

The **sigmoid colon** (sometimes called the *pelvic colon*) (fig. 1127) begins at the superior aperture of the lesser pelvis, where it is continuous with the descending colon; it forms a loop which varies greatly in length, but averages about 40 cm., and normally lies within the pelvis. The loop consists of three parts; the first part descends in contact with the left pelvic wall; the second crosses the pelvic cavity, between the rectum and bladder in the male, and the rectum and uterus in the female, and may come into contact with the right pelvic wall; the third arches backwards and reaches the middle line at the level of the third piece of the sacrum, where it bends downward and ends in the rectum. The sigmoid colon is completely surrounded by peritoneum, which forms a mesentery, the *sigmoid mesocolon* (p. 1144); this diminishes in length from the centre towards the ends of the loop, where it disappears, so that the loop is fixed at its junctions with the descending colon and rectum, but enjoys a considerable range of movement in its central portion. *Behind* the sigmoid colon are the external iliac vessels, the left Piriformis, and left sacral plexus of nerves; in *front* of it are some coils of the small intestine which separate it from the bladder in the male, and from the uterus in the female.

The position and shape of the sigmoid colon vary very much, and depend on (*a*) its length; (*b*) the length and freedom of its mesocolon; (*c*) the condition of distension; when distended it rises out of the pelvis into the abdominal cavity, and when empty it sinks again into the pelvis; (*d*) the condition of the rectum and bladder (and the uterus, in the female); when these organs are distended the sigmoid colon tends to rise, and conversely.

The **rectum** (figs. 1127, 1128) is continuous above with the sigmoid colon, whilst below it ends in the anal canal. From its origin at the level of the third sacral vertebra it passes downwards, lying in the sacrococcygeal curve, and extends for 2 or 3 cm. in front of, and a little below, the tip of the coccyx, as far as the apex of the prostate. It then bends sharply backwards into the anal canal. It therefore presents two anteroposterior flexures: an upper or *sacral flexure* with its convexity backwards, and a lower or *perinæal flexure*, with its convexity forwards. Two lateral curves are also described, one convex to the right opposite the junction of the third and fourth sacral vertebræ, and the other to the left, opposite the sacrococcygeal articulation; they are, however, of little importance. The rectum is about 12 cm. long, and at its commencement its calibre is similar to that of the sigmoid colon, but near its termination it is dilated to form the *rectal ampulla*. It has no sacculations comparable to those of the colon, but when the lower part of it is contracted its mucous membrane is thrown into a number of folds, which are longitudinal in direction and are effaced by the distension of the gut. Besides these there are certain permanent *transverse folds* (plicæ transversales recti) of a semilunar shape, known as *Houston's valves* (fig. 1129). There are usually three of these transverse folds, but sometimes four or five, and occasionally only two, are present. One is situated near the commencement of the rectum, on the right side; a second extends inwards from the left side of the tube opposite the middle of the sacrum; a third, the largest and most constant, projects backwards from the fore part of the rectum, opposite the fundus of the urinary bladder. When a fourth is present, it is

Fig. 1129.—A coronal section through the rectum and anal canal.

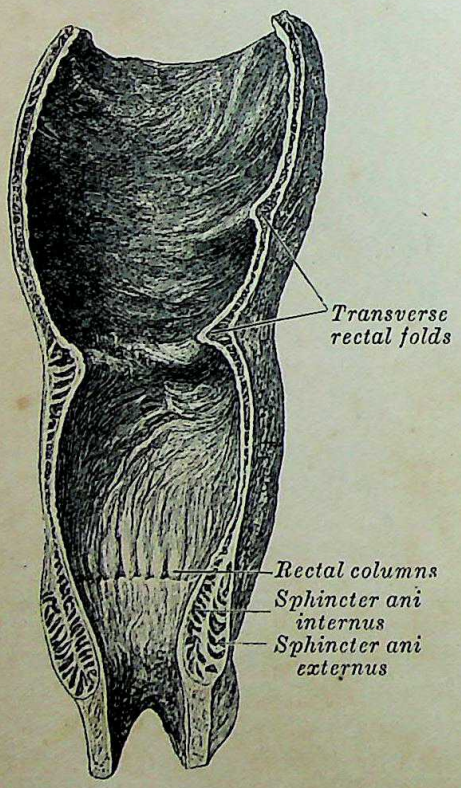

CC-0. In Public Domain. Gurukul Kangri Collection, Haridwar

Digitized by Arya Samaj Foundation Chennai and eGangotri

situated nearly 2·5 cm. above the anus on the left and posterior wall of the rectum. These folds are about 12 mm. in width and contain some of the circular fibres of the gut. In the empty state of the intestines they overlap each other, as Houston remarks, so effectually as to require considerable manœuvring to conduct a bougie or the finger along the canal. Their use seems to be 'to support the weight of fæcal matter, and prevent its urging towards the anus, where its presence always excites a sensation demanding its discharge.' *

The peritoneum is related to the upper two-thirds of the rectum, covering at first its front and sides, but lower down its front only; from the latter it is reflected on to the seminal vesicles in the male and the posterior vaginal wall in the female.

The level at which the peritoneum is reflected from the rectum to the viscus in front of it is higher in the male than in the female. In the former the height of the rectovesical excavation is about 7·5 cm. (i.e. the height to which an ordinary index finger can reach) from the anus. In the female the height of the recto-uterine excavation is about 5·5 cm. from the anal orifice. The lower part of the rectum is surrounded by a dense tube of fascia which consists of a localised thickening and compression of the extraperitoneal connective tissue; this fascial tube is loosely attached to the rectal wall by areolar tissue, in order to allow of distension of the viscus.

Relations of the rectum.—The upper part of the rectum is in relation, *behind*, with the superior hæmorrhoidal vessels, the left Piriformis and the left sacral plexus of nerves, which separate it from the pelvic surfaces of the sacral vertebræ; its lower part lies on the sacrum, coccyx, and Levatores ani; it is attached to the sacrum along the lines of the sacral foramina by connective tissue which surrounds the sacral nerves and the branches of the superior hæmorrhoidal vessels passing to the bowel. *In front* of its upper part, in the male, is the recto-vesical excavation, in the female, the recto-uterine excavation, of the peritoneum. The excavations contain some convolutions of the small intestine, and frequently the sigmoid colon. Below the recto-vesical excavation in the male the anterior surface of the rectum is in relation with the triangular portion of the fundus of the bladder, the vesiculæ seminales, and ductus deferentes, and more anteriorly with the posterior surface of the prostate; below the recto-uterine excavation in the female, it is in relation with the anterior wall of the vagina.

Fig. 1130.—A coronal section through the anal canal. (Symington.)

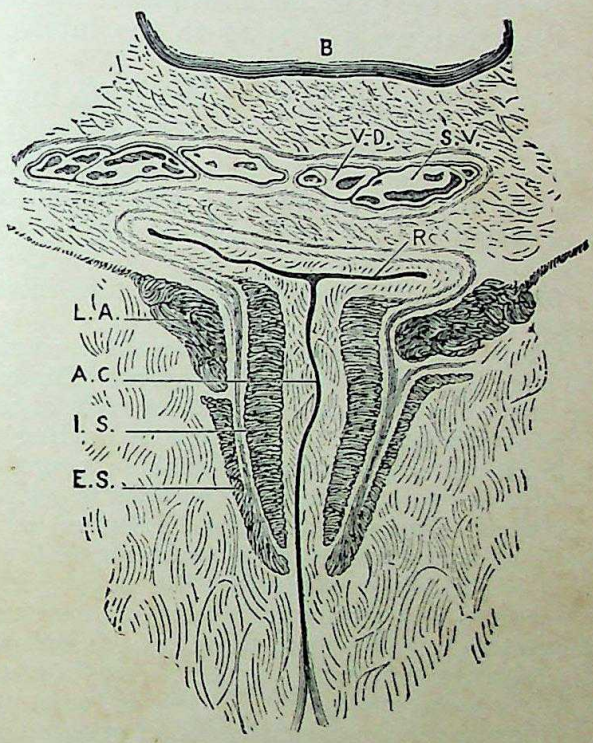

A.C. Anal canal. B. Cavity of urinary bladder. E.S. Sphincter ani externus. I.S. Sphincter ani internus. L.A. Levator ani. R. Second part of rectum. S.V. Seminal vesicle. V.D. Ductus deferens.

The **anal canal** (pars analis recti) (fig. 1130) begins at the level of the apex of the prostate, and is directed downwards and backwards, and ends at the anus. It forms an angle with the lower part of the rectum, and is from 2 to 3 cm. long. It has no peritoneal covering, but is invested by the Sphincter ani internus, supported by the Levatores ani, and surrounded at its termination by the Sphincter ani externus. In the empty condition it presents the appearance of an antero-posterior longitudinal slit. Behind it, is a mass of muscular and fibrous tissue,

* Paterson (*Journal of Anatomy and Physiology*, vol. xliii.) utilised the third fold for the purpose of dividing the rectum into an upper and a lower portion; he considered the latter 'to be as much a duct as the narrower anal canal below,' and maintained that, under normal conditions, it does not contain fæces except during the act of defæcation.

CC-0. In Public Domain. Gurukul Kangri Collection, Haridwar

Digitized by Arya Samaj Foundation Chennai and eGangotri

the *anococcygeal body* (Symington); in front of it, in the male, but separated from it by connective tissue, are the membranous portion and bulb of the urethra, and the fascia of the urogenital diaphragm; and in the female it is separated from the lower end of the vagina by a mass of muscular and fibrous tissue, named the *perinæal body*.

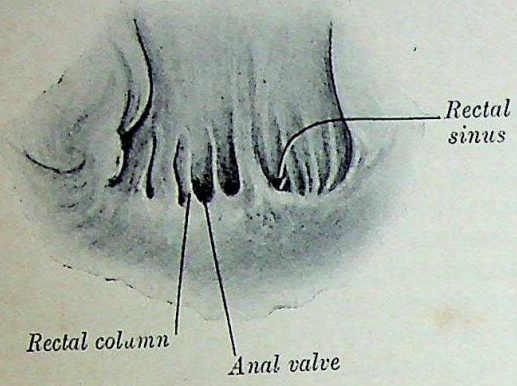

FIG. 1131.—The anterior of the anal canal of a new-born child.

The upper half of the anal canal is lined by mucous membrane which presents from six to ten vertical folds known as the *rectal columns* (*Morgagni*). These columns are usually well marked in the new-born child (fig. 1131), but are often ill-defined in the adult. They are produced by infoldings of the mucous membrane and of some of the longitudinal muscular tissue, and each contains a small artery and vein. They are separated from one another by furrows, and end below in small crescentic valve-like folds, termed *anal valves*; these valves join together the lower ends of the rectal columns, and outside each valve is a small pouch or *rectal sinus*.

The lower half of the anal canal is lined by skin which exhibits a series of folds extending upwards from the anus towards the rectal columns. The junction of the skin and mucous membrane is indicated by a white line which is somewhat wavy 'owing to the interlocking of the cutaneous and mucous folds' (Symington).

The **anus** or **anal orifice** is the lower aperture of the anal canal, and is situated in front of the apex of the coccyx in the cleft between the buttocks. The skin surrounding it is thrown into a series of folds which converge towards the orifice and are continued upwards into the lower part of the anal canal.

Structure of the colon.—The large intestine has four coats: serous, muscular, areolar, and mucous.

The *serous coat* is derived from the peritoneum, and invests the different portions of the large intestine to a variable extent. The cæcum is usually completely covered by the serous membrane, but in about 5 per cent. of cases the upper part of the posterior surface is uncovered. The ascending and descending parts of the colon are usually covered only in front and at the sides, a variable amount of the posterior surface being uncovered. The transverse colon is invested with the exception of (*a*) the posterior surface of that part which lies in front of the duodenum and the head of the pancreas, and (*b*) along the lines of attachment of the greater omentum and transverse mesocolon. The sigmoid colon is entirely surrounded. The upper part of the rectum is covered on its anterior surface and sides; the middle part on its anterior surface only; while the lower 5 cm. of the rectum, and the anal canal are devoid of any serous covering. In the course of the colon the peritoneal coat is thrown into a number of small pouches filled with fat, called *appendices epiploicæ*. They are most numerous on the transverse colon.

The *muscular coat* consists of an external longitudinal, and an internal circular layer of non-striped muscular fibres.

The *longitudinal fibres* do not form a continuous layer over the whole surface of the large intestine. In the cæcum and colon they are collected into three longitudinal bands (*tæniæ coli*), each of about 12 mm. in width; one, the *tænia mesocolica*, is placed along the attached border of the intestine; the second and largest, the *tænia omentalis*, corresponds, along the arch of the colon, with the attachment of the greater omentum, but is placed anteriorly in the ascending, descending, and sigmoid parts of the colon; the third, the *tænia libera*, is found on the medial sides of the ascending and descending parts of the colon, and on the under surface of the transverse colon. These bands are shorter than the other coats of the intestine, and serve to produce the sacculi which are characteristic of the cæcum and colon; accordingly, when they are dissected off, the tube can be lengthened, and its sacculated character becomes lost. In the sigmoid colon the longitudinal fibres become more scattered; and round the rectum they spread out and form a layer, which completely encircles this portion of the gut, but is thicker on the anterior and posterior surfaces, where it forms two bands. In addition, two fasciculi of plain muscular tissue arise from the front of the second and third coccygeal vertebræ, and

CC-0. In Public Domain. Gurukul Kangri Collection, Haridwar

Digitized by Arya Samaj Foundation Chennai and eGangotri

ass downwards and forwards to blend with the longitudinal muscular fibres on the osterior wall of the anal canal. These are known as the *Rectococcygeal muscles.*

The *circular fibres* form a thin layer over the cæcum and colon, being especially ccumulated in the intervals between the sacculi ; in the rectum they form a thick layer, nd in the anal canal they become numerous, and constitute the Sphincter ani internus.

The *areolar coat* connects the muscular and mucous layers closely together.

The *mucous membrane* of the cæcum and colon is pale, smooth, destitute of villi, nd raised into numerous crescentic folds which correspond with the intervals between he sacculi; that of the rectum is thicker, of a darker colour, more vascular, and con-ected loosely with the muscular coat.

As in the small intestine, the mucous membrane (fig. 1132) consists of a muscular yer, the muscularis mucosæ; a quantity of retiform tissue in which the vessels ramify; basement-membrane, and an epithelium which is of the columnar variety and resembles e epithelium found in the small intestine. The mucous membrane of the large intestine esents for examination glands and solitary lymphatic nodules.

FIG. 1132.—A section through the mucous membrane of the human rectum. × 60. (Sobotta.)

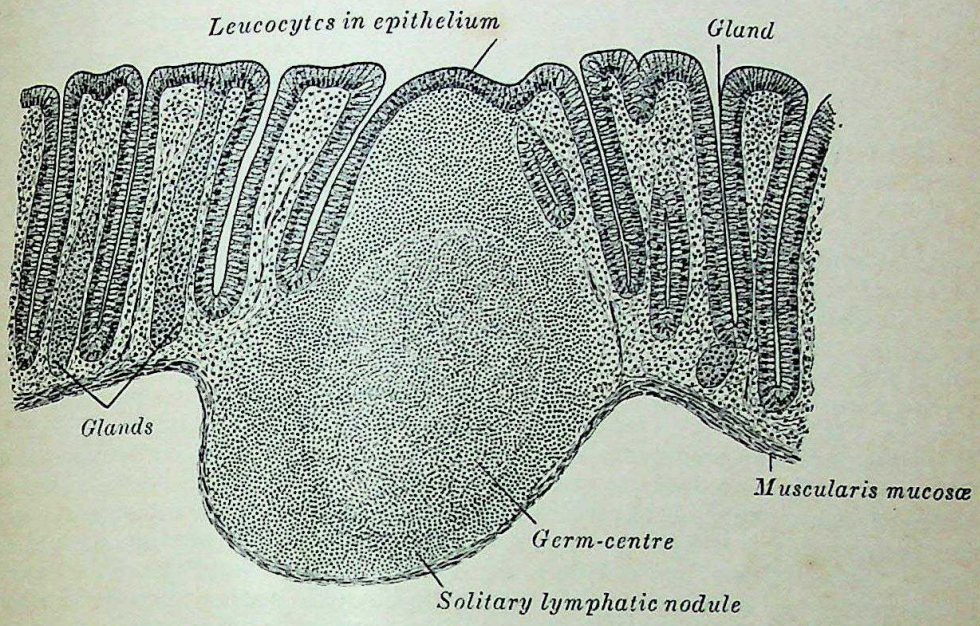

The *glands* of the great intestine are minute tubular prolongations of the mucous mbrane arranged perpendicularly to its surface; they are longer, more numerous, d placed in much closer apposition than those of the small intestine; and they open by ite rounded orifices upon the surface, giving it a cribriform appearance. Each gland ined by short columnar epithelium, the majority of the cells being goblet-cells.

The *solitary lymphatic nodules* (fig. 1132) of the large intestine are most abundant in cæcum and vermiform process, but are irregularly scattered also over the rest of the e intestine. They are similar to those of the small intestine.

Vessels and Nerves.—The *arteries* supplying the colon are derived from the colic and oid branches of the mesenteric arteries. They give off large branches, which ramify een and supply the muscular coats, and after dividing into small vessels in the sub-ous tissue, pass to the mucous membrane. The rectum is supplied by the superior orrhoidal branch of the inferior mesenteric, and the anal canal by the middle hæmor-dal from the hypogastric, and the inferior hæmorrhoidal from the internal pudendal ry. The superior hæmorrhoidal, the continuation of the inferior mesenteric, divides two branches, which run down either side of the rectum to within about 12·5 cm. of anus; they here divide into a number of branches, which pierce the muscular coat descend between it and the mucous membrane in the rectal columns as far as the nster ani internus, where they anastomose with the other hæmorrhoidal arteries and a series of loops around the anus. The *veins* of the rectum commence in a plexus vessels which surrounds the anal canal. In the vessels forming this plexus are small ular dilatations just within the margin of the anus; from the plexus about six vessels considerable size are given off. These ascend between the muscular and mucous coats about 12·5 cm., running parallel to each other; they then pierce the muscular coat, by their union, form a single trunk, the superior hæmorrhoidal vein. This arrange-is termed the *hæmorrhoidal plexus*; it communicates with the tributaries of the ile and inferior hæmorrhoidal veins, at its commencement, and thus a communication ablished between the systemic and portal circulations. The *nerves* are derived the second, third and fourth sacral nerves, and from the sympathetic, through the

CC-0. In Public Domain. Gurukul Kangri Collection, Haridwar

Digitized by Arya Samaj Foundation Chennai and eGangotri

pelvic plexuses. They are distributed in a similar way to those found in the small intestine.

The *lymphatics* of the large intestine are described on pp. 770, 771.

Applied Anatomy.—The small intestine is much exposed to injury, but, in consequence of its elasticity and the ease with which one coil glides over another, it is not so frequently ruptured as would otherwise be the case. Any part of it may be ruptured, but probably the most common situation is the horizontal portion of the duodenum, on account of its being more fixed than other portions of the bowel, and because it is situated in front of the bodies of the vertebræ, so that if this portion of the intestine is struck by a sharp blow, as from the kick of a horse, it is unable to glide out of the way, but is compressed against the bone and so lacerated. Wounds of the intestine sometimes occur. If the wound is a small puncture, under, it is said, 6 mm. in length, no extravasation of the contents of the bowel takes place; the mucous membrane becomes everted and plugs the little opening. The small intestine, and most frequently the ileum, may become strangulated by internal bands, or through apertures, normal or abnormal. The bands may be formed in several different ways; they may be old peritoneal adhesions from previous attacks of peritonitis; or an adherent omentum from the same cause; or the band may be formed by Meckel's diverticulum, which has contracted adhesions at its distal extremity; or it may be the result of the abnormal attachment of some normal structure, as the adhesion of two appendices epiploicæ, or an adherent vermiform process or uterine tube. Intussusception, most commonly an invagination of the small intestine into the large, may take place; it may attain great size, and it is possible in these cases to find the colic valve projecting from the anus. Stricture, the impaction of foreign bodies, and twisting of the gut (*volvulus*) may also lead to intestinal obstruction.

Resection of a portion of the intestine may be required in cases of gangrene; for the removal of new growth in the bowel; in dealing with artificial anus; and in cases of rupture. The operation is termed *enterectomy*, and is performed as follows: the abdomen having been opened and the amount of bowel requiring removal having been determined upon, the intestine must be clamped on either side of this portion in order to prevent the escape of any of its contents during the operation. The portion of the bowel is then separated above and below by means of scissors. If the portion resected is small, it may be simply removed from the mesentery at its attachment, and the bleeding vessels tied; but if it be large it will be necessary to take away a triangular piece of the mesentery, and, having secured the vessels, suture the cut edges of this structure together. In doing this, care must be taken not to leave any intestine projecting beyond the line of the section of the mesentery, as gangrene is very likely to occur in the projecting part if this is done. The surgeon then proceeds to unite the cut ends of the bowel by end-to-end anastomosis. There are many ways of doing this, but they may be divided into two classes, one where the anastomosis is made by means of some mechanical appliance, such as Murphy's button, or one of the forms of decalcified bone bobbin; and the other, where the operation is performed by suturing the ends of the bowel in such a manner that the peritoneum covering the two divided ends is brought into contact, so that speedy union may ensue.

The vermiform process is very liable to become inflamed, because it contains a relatively large amount of lymphoid tissue which is prone to bacterial infection. In many cases the inflammation is set up by the impaction in it of a solid mass of fæces or a foreign body, or by the inspissation of its mucous secretion in catarrhal conditions. The inflammation may result in ulceration and perforation, or if very acute in gangrene of the process. These conditions generally require immediate operative interference, and in chronic cases with recurring attacks of inflammation it is always advisable to remove this diverticulum of the bowel. In incising the abdominal wall for this operation, the muscles should be split in the direction of their fibres, rather than cut across, in order to prevent subsequent weakening of the abdominal parietes and the occurrence of a ventral hernia. After the process has been removed it is better to suture the planes of the abdominal wall separately.

In external hernia the ileum is the portion of bowel most frequently herniated. When a part of the large intestine is involved it is usually the cæcum, and this may occur even on the left side. In some few cases the vermiform process has been the part implicated in strangulated hernia.

Chronic ulcer of the duodenum is sometimes met with, probably produced by the same causes as chronic ulcer of the stomach. It may perforate and set up a rapidly fatal peritonitis, or it may open into the gastroduodenal artery and cause death from hæmorrhage. An acute ulcer sometimes, but rarely, follows extensive burns of the skin.

The calibre of the large intestine gradually diminishes from the cæcum, which has the greatest diameter of any part of the bowel, to the point of junction of the sigmoid colon with the rectum. At or a little below this point stricture most commonly occurs, and diminishes in frequency as one proceeds upwards to the cæcum. When distended by some obstruction low down, the outline of the large intestine can be defined throughout nearly the whole of its course—all, in fact, except the right and left colic flexures, which are more deeply placed; the distension is most obvious in the flanks and on the front of the abdomen just above the umbilicus. The cæcum, however, is the portion of the bowel which becomes most distended. It may assume enormous dimensions, and may give way from the distension, leading to rapidly fatal peritonitis. The right colic flexure and the

CC-0. In Public Domain. Gurukul Kangri Collection, Haridwar

Digitized by Arya Samaj Foundation Chennai and eGangotri

ght extremity of the transverse colon are in close relationship with the liver, and abscess of this viscus sometimes bursts into the gut in this situation. The gall-bladder may ecome adherent to the duodenum or colon, and gall-stones may find their way into ther, and may become impacted or may be discharged per anum. The mobility of the gmoid colon renders it more liable to become the seat of a volvulus or twist than any ther part of the intestine. This generally occurs in patients who have been the subjects f habitual constipation, and in whom, therefore, the mesocolon is elongated. This ortion of the bowel, being loaded with fæces, falls over the part below, and so gives rise o the twist.

Hernia.—The two chief sites at which external hernia may take place are the inguinal ion and the femoral canal. The description of the inguinal canal and its relations will e found on p. 481 and that of the femoral canal on p. 689. Some points in regard to the sposition of the peritoneum in these regions may, however, be recapitulated here.

Between the upper margin of the front of the pelvis and the umbilicus, the peri-neum, when viewed from behind, will be seen to be raised into five folds, with inter-ening depressions, by more or less prominent bands which converge to the umbilicus fig. 1090). The middle umbilical ligament, situated in the middle line, is covered by a ld of peritoneum known as the *middle umbilical fold*. On either side of this a fold of ritoneum round the obliterated umbilical artery forms the *lateral umbilical fold*. To ther side of these three cords is the inferior epigastric artery covered by the *epigastric ld*. Between these raised folds are depressions constituting the so-called foveæ. The ost medial, between the middle and lateral umbilical folds, is known as the *supravesical vea*. The intermediate one is on the medial side of the epigastric fold, and is termed e *medial inguinal fovea*. The third is lateral to the epigastric fold, and is known as e *lateral inguinal fovea*. Occasionally the inferior epigastric artery corresponds in sition to the obliterated hypogastric artery, and then there is but one fold on either side the middle line. In the usual position of the parts, the floor of the lateral inguinal vea corresponds to the abdominal inguinal ring, and into this fovea an oblique inguinal rnia descends. On the medial side of the epigastric fold are the medial inguinal and e supravesical foveæ, and through either of these a direct hernia may descend. The hole of the space between the inferior epigastric artery, the margin of the Rectus dominis, and the inguinal ligament, is known as Hesselbach's triangle. Below the vel of the inguinal ligament is a small depression corresponding to the position of the moral ring. It is known as the *femoral fovea*, and into it a femoral hernia descends.

Inguinal hernia.—Inguinal hernia is that form of protrusion which makes its way rough the abdominal wall in the inguinal region. There are two principal varieties: teral or oblique, and medial or direct.

In *oblique inguinal hernia* the intestine escapes from the abdominal cavity at the dominal inguinal ring, pushing before it a pouch of peritoneum which forms the hernial c. As it enters the inguinal canal it receives an investment from the extraperitoneal ssue and is enclosed in the infundibuliform fascia. In passing along the inguinal canal displaces upwards the arched fibres of the Transversus and Obliquus internus, and ceives a covering of Cremaster muscle and cremasteric fascia. It then passes along e front of the spermatic cord and escapes from the inguinal canal at the subcutaneous guinal ring, becoming invested by intercrural fascia. Lastly it descends into the rotum, receiving coverings from the superficial fascia and the skin.

The seat of stricture in oblique inguinal hernia is either the abdominal or the sub-taneous inguinal ring; most frequently at the former situation. If it is situated at e subcutaneous ring, the division of a few fibres at one point of the circumference is that is necessary for the replacement of the hernia. If at the abdominal ring, it is cessary to divide the aponeurosis of the Obliquus externus so as to lay open the inguinal nal; in dividing the aponeurosis the incision should be directed parallel to the inguinal gament, and the constriction at the abdominal ring should then be divided directly wards.

When the intestine passes along the inguinal canal and escapes from the sub-taneous ring into the scrotum, it is called a *scrotal* hernia. If the intestine does not s into the scrotum, but merely bulges through the subcutaneous ring, it is called a *bocele*.

The great majority of varieties of oblique inguinal hernia depend upon congenital ects in the saccus vaginalis, the pouch of peritoneum which precedes the descent of testis. Normally this pouch is closed before birth, closure commencing at two points, at the abdominal inguinal ring and at the top of the epididymis, and gradually extend-until the whole of the intervening portion is converted into a fibrous cord. From re in the completion of this process, variations in the relation of the hernial protru-to the testis and tunica vaginalis are produced; these constitute distinct varieties guinal hernia, viz. the hernia of the funicular process and the complete congenital ty.

Where the saccus vaginalis remains patent throughout, the cavity of the tunica vagi-communicates directly with that of the peritoneum. The intestine descends along pouch into the cavity of the tunica vaginalis, which constitutes the sac of the hernia, the gut lies in contact with the testis. Though this form of hernia is termed *complete ital* (fig. 113), the term does not imply that the hernia existed at birth,

CC-0. In Public Domain. Gurukul Kangri Collection, Haridwar

Digitized by Arya Samaj Foundation Chennai and eGangotri

but merely that a condition is present which may allow of the descent of the hernia at any moment. As a matter of fact, congenital herniæ frequently do not appear till adult life.

Where the processus vaginalis is occluded at the lower point only, i.e. just above the testis, the intestine descends into the pouch of peritoneum as far as the testis, but is prevented from entering the sac of the tunica vaginalis by the septum which has formed between it and the pouch. This is known as *hernia into the funicular process* or *incomplete congenital* hernia (fig. 1133); it differs from the former in that instead of enveloping the testis it lies above it.

Fig. 1133.—The varieties of oblique inguinal hernia.

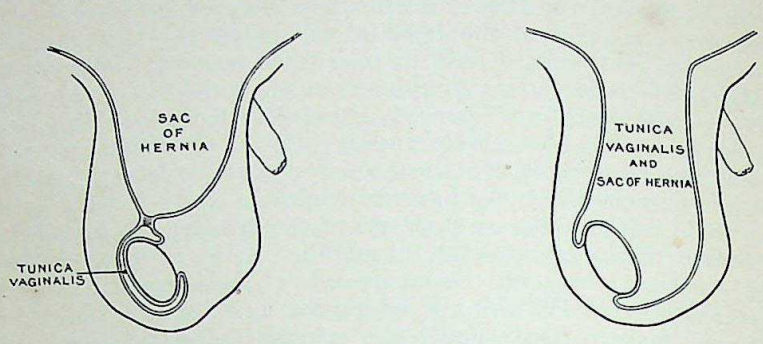

Incomplete congenital — Complete congenital

In *direct inguinal hernia* the protrusion makes its way through some part of Hesselbach's triangle, either through (*a*) the lateral part, where only extraperitoneal tissue and transversalis fascia intervene between the peritoneum and the aponeurosis of the Obliquus externus; or through (*b*) the inguinal aponeurotic falx which stretches across the medial two-thirds of the triangle between the artery and the middle line. In the former the hernial protrusion escapes from the abdomen on the lateral side of the inguinal falx, pushes before it the peritoneum, extraperitoneal tissue and transversalis fascia, and enters the inguinal canal. It passes along nearly the whole length of the canal and finally emerges from the subcutaneous ring, receiving an investment from the intercrural fascia. The coverings of this form of hernia are similar to those of the oblique form, except that a portion derived from the general layer of transversalis fascia replaces the infundibuliform fascia.

In the second form, which is the more frequent, the hernia is either forced through the fibres of the inguinal falx, or the falx is gradually distended in front of it so as to form a complete investment for it. The intestine then enters the lower end of the inguinal canal, escapes at the subcutaneous ring, lying on the medial side of the cord, and receives additional coverings from the intercrural fascia, the superficial fascia and the integument. The coverings of this form therefore differ from those of the oblique form in that the inguinal falx is substituted for the Cremaster, and the infundibuliform fascia is replaced by a portion of the general layer of the transversalis fascia.

Direct inguinal hernia is of much less frequent occurrence than oblique, and is found more often in men than in women. The main differences in position between it and the oblique form are: (*a*) it is placed over the os pubis and not in the course of the inguinal canal; (*b*) the inferior epigastric artery runs on the lateral or iliac side of the neck of the sac; and (*c*) the spermatic cord lies along its lateral and posterior sides, not directly behind it as in oblique inguinal hernia. A direct hernia is always of the acquired variety.

The seat of stricture in both varieties of direct hernia is usually found either at the neck of the sac or at the subcutaneous ring. In that form which perforates the inguinal falx it may occur at the edges of the fissure through which the gut passes. In all cases of inguinal hernia, whether direct or oblique, it is proper to divide the stricture directly upwards; by cutting in this direction the incision is made parallel to the inferior epigastric artery, and all chance of wounding the vessel is thus avoided.

Femoral hernia.—In femoral hernia the protrusion of the intestine takes place through the femoral ring. As already described (p. 689), this ring is closed by the femoral septum, a partition of modified extraperitoneal tissue; it is therefore a weak spot in the abdominal wall, and especially in the female, where the ring is larger, and where profound changes are produced in the tissues of the abdomen by pregnancy. Femoral hernia is therefore more common in women than in men.

When a portion of intestine is forced through the femoral ring, it carries before it a pouch of peritoneum, which forms the hernial sac. It receives an investment from the extraperitoneal tissue or femoral septum, and descends along the femoral canal, or inner compartment of the sheath of the femoral vessels, as far as the fossa ovalis; at this point it changes its course, being prevented from extending farther down the sheath on account of the narrowing of the latter, and its close contact with the vessels, and also the close

CC-0. In Public Domain. Gurukul Kangri Collection, Haridwar

Digitized by Arya Samaj Foundation Chennai and eGangotri

attachment of the superficial fascia and femoral sheath to the lower part of the circumference of the fossa ovalis. The tumour is consequently directed forwards, pushing before it the fascia cribrosa, and then curves upwards over the inguinal ligament and the lower part of the aponeurosis of the Obliquus externus, being covered by the superficial fascia and integument. While the hernia is contained in the femoral canal it is usually of small size, owing to the resisting nature of the surrounding parts, but when it escapes from the fossa ovalis into the loose areolar tissue of the groin it becomes considerably enlarged. The direction taken by a femoral hernia is at first downwards, then forwards and upwards; in the application of taxis for the reduction of a femoral hernia, therefore, pressure should be directed in the reverse order.

The coverings of a femoral hernia from within outwards are: peritoneum, femoral septum, femoral sheath, fascia cribrosa, superficial fascia, and integument. Sir Astley Cooper has described an investment for femoral hernia under the name of *fascia propria*, being immediately external to the peritoneal sac but frequently separated from it by some adipose tissue. Surgically it is important to remember the frequent existence of this layer on account of the ease with which an inexperienced operator may mistake the fascia for the peritoneal sac and the contained extraperitoneal fat for omentum, as there is often a great excess of subperitoneal fatty tissue enclosed in the 'fascia propria.' In many cases it resembles a fatty tumour, but on further dissection the true hernial sac will be found in the centre of the mass of fat. The fascia propria is merely a modified femoral septum which has been thickened to form a membranous sheet by the pressure of the hernia.

When the intestine descends along the femoral canal only as far as the fossa ovalis the condition is known as *incomplete* femoral hernia, in contradistinction to the *complete* hernia when it has passed through the fossa ovalis. The small size of the protrusion in the incomplete form of hernia, on account of the firm and resisting nature of the canal in which it is contained, renders it an exceedingly dangerous variety of the disease, from the extreme difficulty of detecting the existence of the swelling, especially in corpulent subjects. The coverings of an incomplete femoral hernia would be from without inwards: integument, superficial fascia, superior cornu of falciform margin of the fossa ovalis, femoral sheath, femoral septum, and peritoneum.

The seat of stricture of a femoral hernia varies: it may be in the peritoneum at the neck of the hernial sac; in the greater number of cases it is at the point of junction of the falciform margin of the fossa ovalis with the free edge of the lacunar ligament; or it may be at the margin of the fossa ovalis. The stricture should in every case be divided in a direction upwards and medialwards for a distance of about 4 mm. to 6 mm. All vessels or other structures of importance in relation to the neck of the sac will thus be avoided.

The pubic tubercle forms an important landmark in serving to differentiate the inguinal from the femoral variety of hernia. The inguinal protrusion is above and medial to the tubercle, while the femoral is below and lateral to it.

There are several details of practical interest in connexion with the mesentery which merit notice. 1. The depth of the mesentery—that is to say, the distance from its parietal to its intestinal attachment—is normally less than 20 cm., generally nearer 15 cm.; but under certain abnormal conditions it may become elongated, and this would appear to favour the occurrence of hernia of the intestine. 2. Not only may the depth of the mesentery be increased, but its point of attachment to the posterior abdominal wall may yield, and descend over the lumbar vertebræ. This condition, which is known under the name of *enteroptosis*, usually occurs in women who have borne many children, and is attended with general relaxation of the abdominal parietes. It produces a characteristic appearance, the abdomen being prominent and pendulous below, while above, it is flattened and constricted. 3. Holes are sometimes present in the mesentery, and these may be congenital, or may be the result of injury. They are of practical importance, since a knuckle of intestine may become herniated into one of them, causing acute strangulation. 4. The lymph-glands contained between the two layers of the mesentery are frequently the seat of tuberculous deposit, especially in children.

Colon.—The colon frequently requires opening in cases of intestinal obstruction, and by some surgeons this operation is performed in cases of cancer of the rectum as soon as the disease is recognised, in the hope that the symptoms may be relieved by removing the irritation produced by the passage of fæcal matter over the diseased surface. The operation of *colostomy* may be performed either in the iliac or lumbar region; but *iliac colostomy* has in the present day entirely superseded the lumbar operation. The main reasons for preferring this operation are that a spur-shaped process of the mesocolon can be formed, which prevents any fæcal matter finding its way past the artificial anus, and greater ease in maintaining cleanliness. The sigmoid colon being entirely surrounded by peritoneum, a coil can be drawn out of the wound and opened, leaving the attachment of the mesocolon to form a spur, much as it does in an artificial anus caused by sloughing of the intestine after a strangulated hernia, and this prevents any fæcal matter finding its way from the gut above the opening into that below. The operation is performed by making an incision 5 cm. to 7 cm. long through the outermost fibres of the left Rectus abdominis, opposite the anterior superior iliac spine. The peritoneum is opened; the sigmoid colon is now sought, pulled out of the wound, and fixed by passing a glass rod

CC-0. In Public Domain. Gurukul Kangri Collection, Haridwar

Digitized by Arya Samaj Foundation Chennai and eGangotri

beneath it, or by suturing the mesocolon close to the gut to the abdominal wall. Later, the protruding coil of intestine is opened, and finally, when firm adhesions have formed, it is cut completely across.

Rectum.—The surgical anatomy of the rectum is of considerable importance. There may be congenital malformations due to arrest of, or imperfection in, development. Thus, there may be no proctodæal invagination (p. 142), and consequently a complete absence of the anus; or the hind-gut may be imperfectly developed, and there may be an absence of the rectum, though the anus is developed; or the proctodæal invagination may not communicate with the termination of the hind-gut from want of solution of continuity in the septum which in early fœtal life exists between the two.

The mucous membrane of the rectum is thick and but loosely connected to the muscular coat beneath, and thus favours prolapse, especially in children. The vessels of the rectum are arranged, as mentioned above, longitudinally, and are contained in the loose cellular tissue between the mucous and muscular coats, and receive no support from surrounding tissues, and this favours varicosity. Moreover, the veins, after running upwards in a longitudinal direction for about 12·5 cm. in the submucous tissue, pierce the muscular coats, and are liable to become constricted at this spot by the contraction of the muscular wall of the gut. In addition to this there are no valves in the superior hæmorrhoidal veins, and the vessels of the rectum are placed in a dependent position, and are liable to be pressed upon and obstructed by hardened fæces. The anatomical arrangement, therefore, of the hæmorrhoidal vessels explains the great tendency to the occurrence of piles. The presence of the Sphincter ani externus is of surgical importance, since it is the constant contraction of this muscle which prevents an ischiorectal abscess from healing, and causes it to become a fistula. Also the reflex contraction of this muscle is the cause of the severe pain complained of in fissure of the anus. The relations of the peritoneum to the bowel are of importance in connexion with the operation of removal of the rectum for malignant disease. This membrane gradually leaves the rectum as it descends into the pelvis; first leaving its posterior surface, then the sides, and then the anterior surface, to become reflected, in the male on to the posterior wall of the bladder, forming the rectovesical excavation, and in the female on to the posterior wall of the vagina, forming the recto-uterine excavation. The rectovesical excavation extends to within 7·5 cm. from the anus. Within recent years much more extensive operations have been done for the removal of cancer of the rectum, and in these the peritoneal cavity has necessarily to be opened. For cases of cancer of the rectum which are too low to be reached by abdominal section, and too high to be removed by the perinæum, Kraske has devised an operation which goes by his name. The patient is placed on his right side and an incision is made from the last piece of the sacrum to the anus. The coccyx is removed, and if necessary a small piece of the sacrum, and the edges of the wound being now forcibly drawn outwards, a considerable length of the rectum is brought into view, and the diseased portion is removed.

The loose connective tissue round the rectum, above the Levator ani, is occasionally the site of an abscess, the active focus of which, however, may be located elsewhere. This form of abscess may be described as the *superior pelvirectal*; it is placed above the pelvic diaphragm but beneath the peritoneum. The acute variety is generally due to ulceration or perforation of the bowel (possibly produced by a foreign body) above the level of attachment of the Levator ani. The abscess may also occur above a stricture (simple or malignant) of the rectum; occasionally it arises from suppuration around the prostate, and more rarely follows abscess of the vesiculæ seminales. Chronic abscesses also appear in the same region either from caries of the anterior surface of the sacrum or from caseation of the presacral lymph-glands, whilst in other cases an abscess finds its way down into the pelvis from disease of the anterior surfaces of the bodies of the lumbar vertebræ. For abscess in the ischiorectal fossa, see p. 486.

The Pancreas

The **pancreas** is a compound racemose gland, analogous in its structure to the salivary glands, but softer, and less compactly arranged. It is irregularly prismoid in shape, and from 12 cm. to 15 cm. long. Its broad, right extremity is called the *head*, and is connected to the main portion, or *body*, by a slightly constricted part, the *neck*; its narrow, left extremity forms the *tail*. It is placed across the posterior wall of the abdomen, at the back of the epigastric and left hypochondriac regions.

Relations (figs. 1134 to 1136).—The **head**, flattened from before backwards, is lodged within the curve of the duodenum. Its upper border is overlapped by the superior part of the duodenum; the other borders are grooved to receive the adjacent margin of the duodenum which they overlap in front and behind to a variable extent. The angle of junction of the lower and left lateral borders forms a prolongation termed the *uncinate process*, which projects to the left behind the superior mesenteric vessels. In or near the groove between

CC-0. In Public Domain. Gurukul Kangri Collection, Haridwar

Digitized by Arya Samaj Foundation Chennai and eGangotri

the duodenum and the right lateral and lower borders anteriorly are the anastomosing superior and inferior pancreaticoduodenal arteries; the bile-duct descends behind the head, close to its right border.

FIG. 1134.—A transverse section through the abdomen at the level of the middle of the first lumbar vertebra. (Braune.)

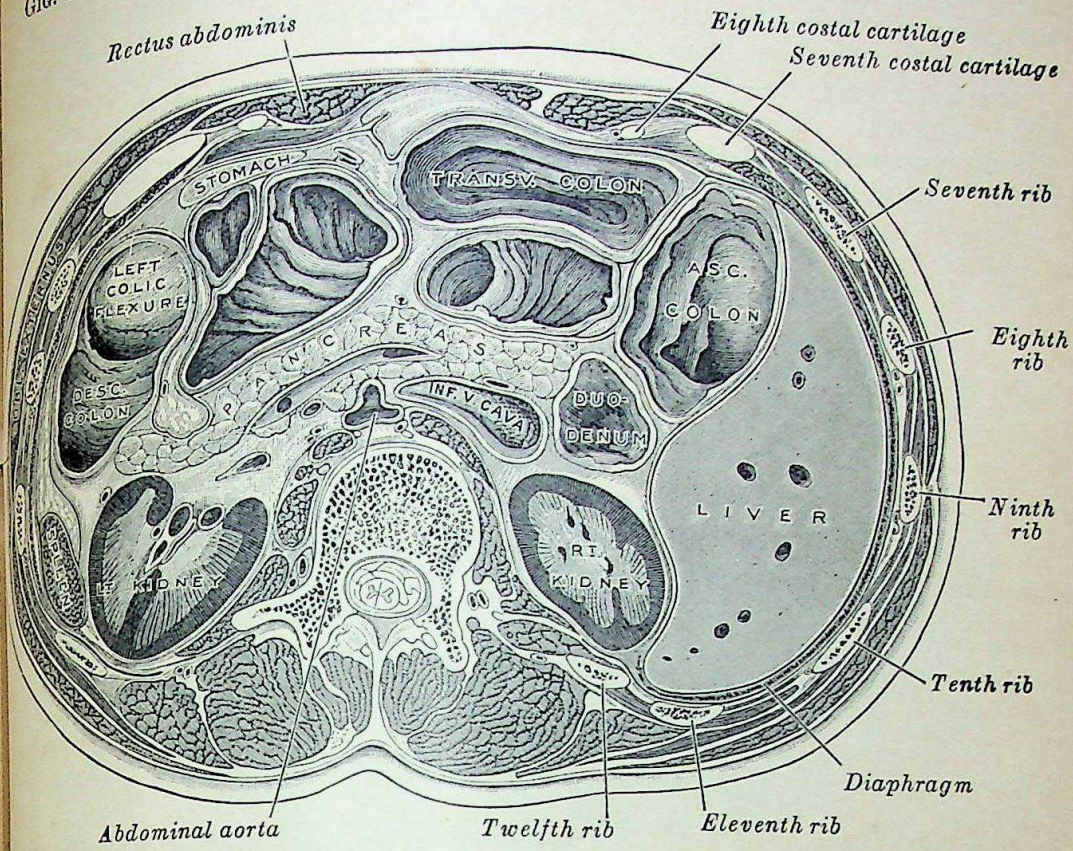

FIG. 1135.—The pancreas and duodenum. Anterior aspect.

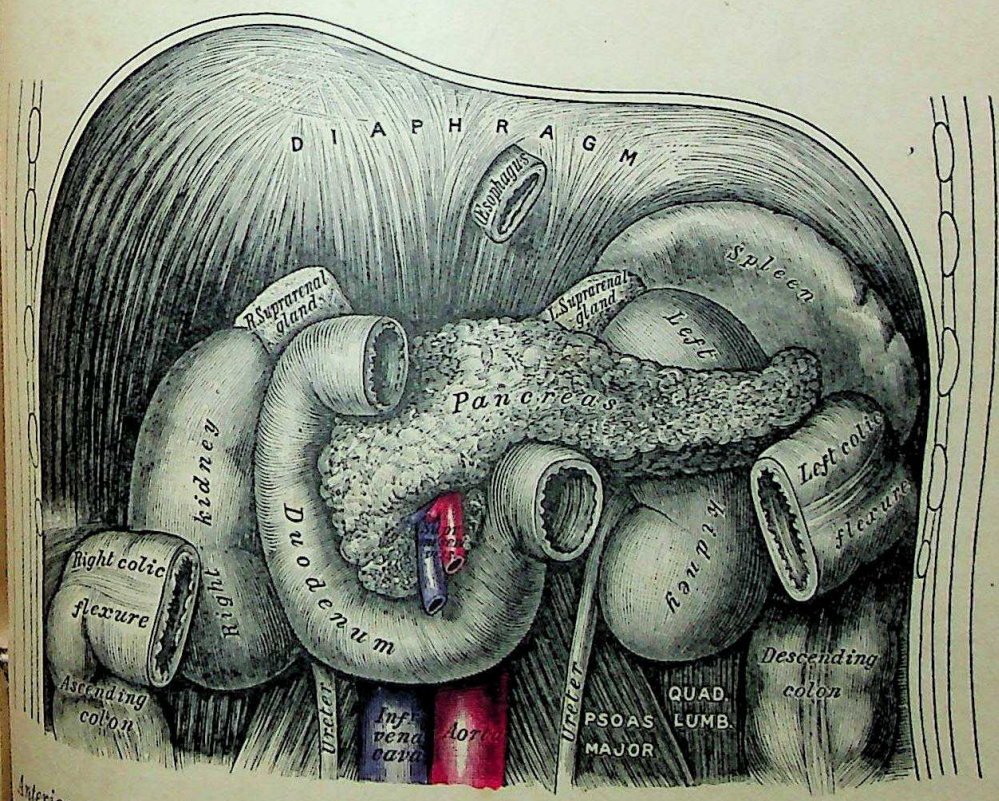

Anterior surface.—From the upper part of the front of the head of the pancreas, the neck juts forwards, upwards and towards the left, to be continued into the body of the pancreas. The boundary between the head and neck;

CC-0. In Public Domain. Gurukul Kangri Collection, Haridwar

Digitized by Arya Samaj Foundation Chennai and eGangotri

on the right side, is a groove for the gastroduodenal artery; on the left side a deep notch, *incisura pancreatis*, intervenes between the head and the neck and body, and in this notch the superior mesenteric and lienal veins unite to form the portal vein. Below and to the right of the neck the anterior surface of the head is in contact with the transverse colon, only areolar tissue intervening, while still lower the surface is covered by peritoneum continuous with the inferior layer of the transverse mesocolon, and is in contact with coils of the jejunum. Below and to the left of the neck is the uncinate process which is crossed by the superior mesenteric vessels.

Posterior surface.—The posterior surface of the head of the pancreas is in relation with the inferior vena cava, the renal veins, the right crus of the Diaphragm, and the aorta. The bile-duct either lies in a groove on the posterior surface of the head of the pancreas or in a canal in its substance (McConnell *).

FIG. 1136.—The pancreas and duodenum. Posterior aspect. (From a model by His.)

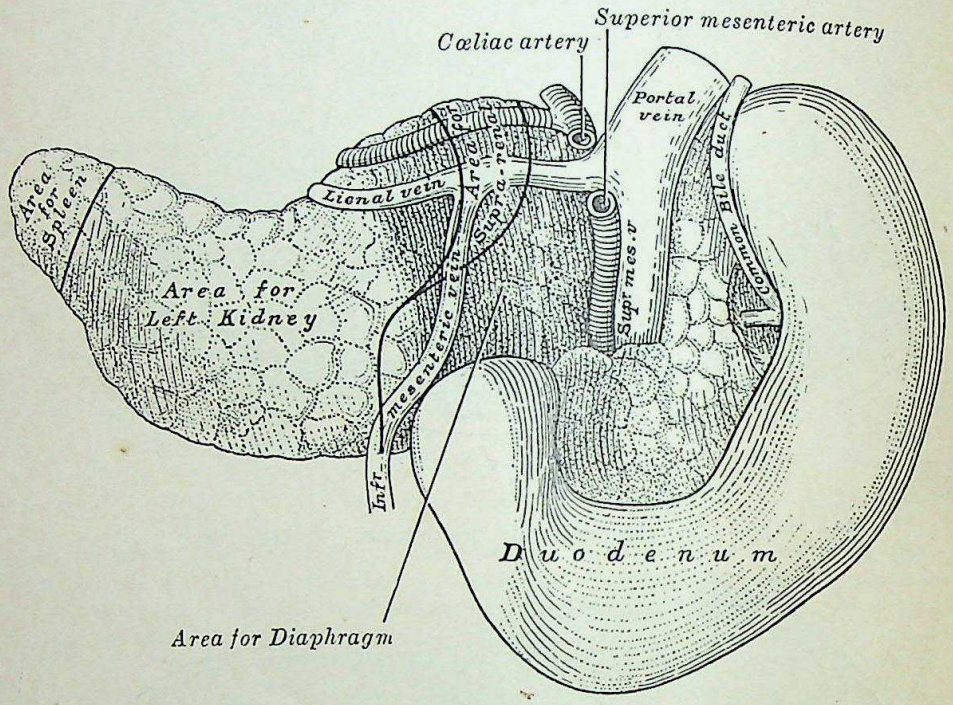

The **neck**, about 2 cm. long, is confluent below and to the right with the anterior surface of the head; it extends upwards and to the left, and merges imperceptibly with the body. It is a somewhat ridge-like part of the pancreas, accentuated by two vascular depressions; below and to the left is the deep notch containing the superior mesenteric vessels, while above and to the right is a groove in which the lower end of the gastroduodenal artery and the superior pancreaticoduodenal artery, are lodged. Its anterior surface supports the pylorus; its posterior surface is in relation with the beginning of the portal vein.

The **body** is somewhat prismoid in shape, and has three surfaces: anterior, posterior, and inferior.

The *anterior surface* is concave, and is directed forwards and upwards; it is separated from the stomach by the omental bursa.

The *posterior surface* is devoid of peritoneum, and is in contact with the aorta, the lienal vein, the left kidney and its vessels, the left suprarenal gland, the origin of the superior mesenteric artery, and the left crus of the Diaphragm.

The *inferior surface* is narrow on the right but broader on the left, and is covered by peritoneum; it lies upon the duodenojejunal flexure and on some coils of the jejunum; its left extremity rests on the left colic flexure.

* *Journal of Anatomy and Physiology*, vol. xliv.

CC-0. In Public Domain. Gurukul Kangri Collection, Haridwar

Digitized by Arya Samaj Foundation Chennai and eGangotri

The *superior border* is blunt and flat to the right; narrow and sharp to the left, near the tail. It is in relation with the cœliac artery, from which the hepatic artery courses to the right just above the gland, while the lienal artery runs towards the left in a groove along this border. A process, the *tuber omentale*, usually projects from the right end of the superior border above the level of the lesser curvature of the stomach, and is in contact with the posterior surface of the lesser omentum.

The *anterior border* separates the anterior from the inferior surface, and along this border the two layers of the transverse mesocolon diverge from one another: one passing upwards over the anterior surface, the other backwards over the inferior surface.

The *inferior border* separates the posterior from the inferior surface; the superior mesenteric vessels emerge under its right extremity.

Fig. 1137.—The pancreatic duct.

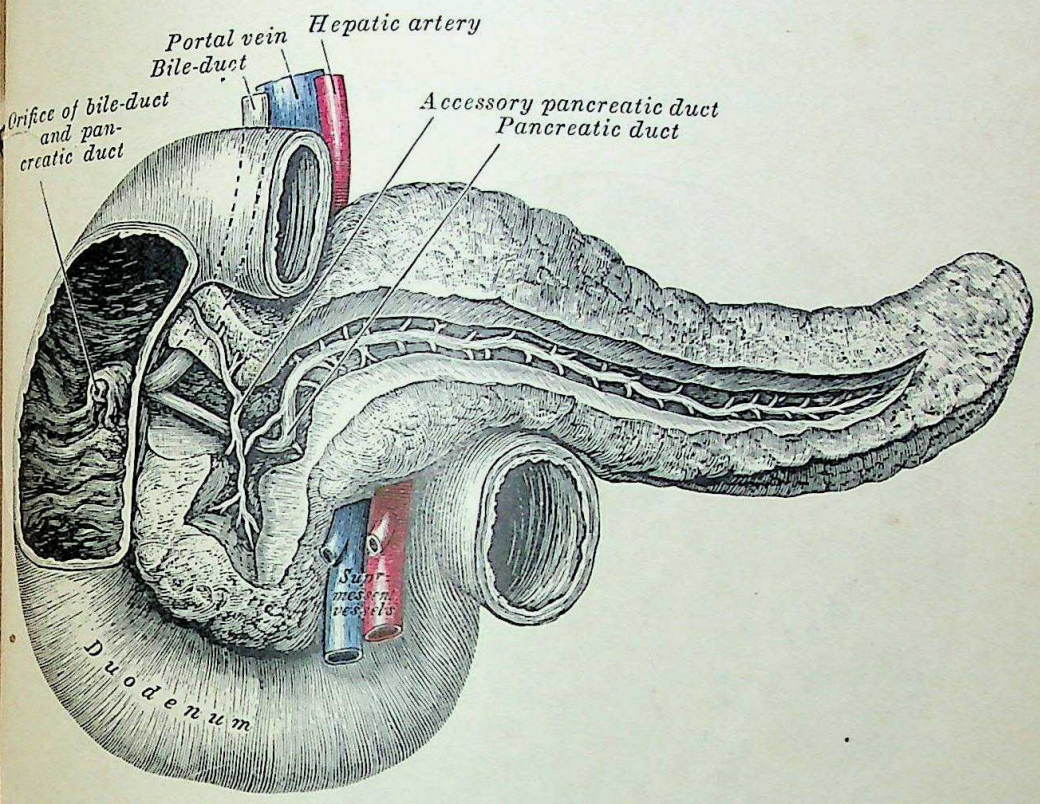

The **tail** is narrow, and usually lies in contact with the inferior part of the gastric surface of the spleen.

Birmingham described the body of the pancreas as projecting forwards as a prominent ridge into the abdominal cavity and forming part of a bed or shelf on which the stomach lies. 'The portion of the pancreas to the left of the middle line has a very considerable anteroposterior thickness; as a result the anterior surface is of considerable extent; it looks strongly upwards, and forms a large and important part of the shelf. As the pancreas extends to the left towards the spleen it crosses the upper part of the kidney, and is so moulded on to it that the top of the kidney forms an extension inwards and backwards of the upper surface of the pancreas and extends the bed in this direction. On the other hand, the extremity of the pancreas comes in contact with the spleen in such a way that the plane of its upper surface runs with little interruption upwards and backwards into the concave gastric surface of the spleen, which completes the bed behind and to the left, and, running upwards, forms a partial cap for the wide end of the stomach.' *

The **pancreatic duct** (ductus Wirsungi) traverses the pancreas from left to right, lying nearer its posterior than its anterior surface (fig. 1137). It begins by the junction of the small ducts of the lobules situated in the head of the pancreas, and, running from left to right through the body, receives the ducts of the various lobules composing the gland. Considerably augmented

* *Journal of Anatomy and Physiology*, vol. xxxi.

CC-0. In Public Domain. Gurukul Kangri Collection, Haridwar

Digitized by Arya Samaj Foundation Chennai and eGangotri

in size, it reaches the neck, and turning downwards, backwards, and to the right, comes into relation with the bile-duct, which lies to its right side; leaving the head of the gland, it passes very obliquely through the mucous and muscular coats of the duodenum, and ends by an orifice, common to it and the bile-duct upon the summit of the duodenal papilla (p. 1155), situated at the medial side of the descending portion of the duodenum, from 7 cm. to 10 cm. beyond the pylorus. The pancreatic duct, near the duodenum, is about the size of an ordinary quill. Sometimes the pancreatic duct and the bile-duct open separately into the duodenum. Frequently there is an additional duct, which communicates with the pancreatic duct in the neck of the pancreas and opens into the duodenum about 2 cm. above the duodenal papilla. It receives the ducts from the lower part of the head, and is known as the *accessory pancreatic duct* (ductus Santorini) (fig. 1137).

Structure (fig. 1138).—In structure, the pancreas resembles the salivary glands. It differs from them, however, in certain particulars, and is looser and softer in its texture. It is not enclosed in a distinct capsule, but is surrounded by areolar tissue, which dips

Fig. 1138.—A section through a part of the human pancreas. Stained with hæmatoxylin and eosin. ×400.

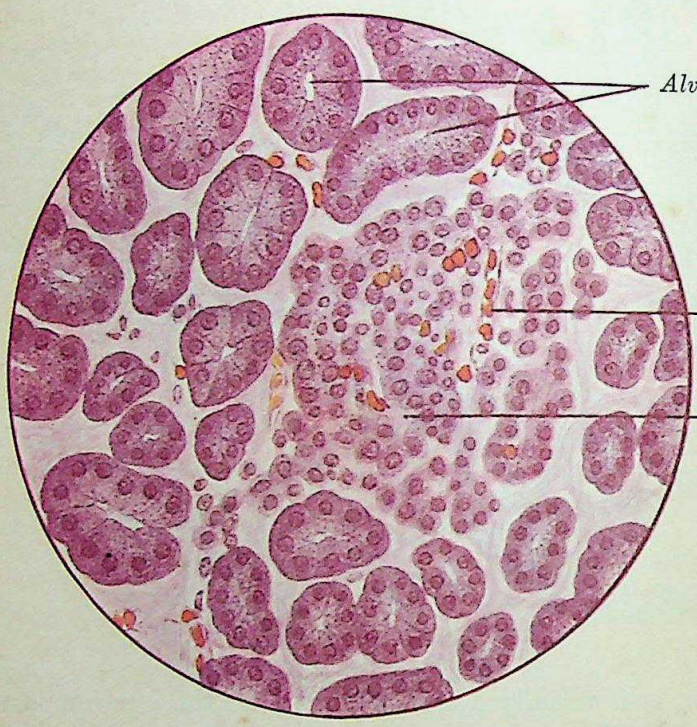

into its interior, and connects together the various lobules of which it is composed. Each lobule, like the lobules of the salivary glands, consists of one of the ultimate ramifications of the main duct, ending in a number of alveoli, which are tubular and somewhat convoluted. The minute ducts (intercalary ducts) connected with the alveoli are narrow and lined with flattened cells. In some animals spindle-shaped cells occupy the centre of the alveolus and are known as *centro-acinar cells*. The true secreting cells which line the wall of the alveolus are columnar in shape and present two zones; an outer, clear and faintly striated, next the basement-membrane, and an inner, which contains secretory granules. In hardened specimens the outer zone stains deeply with basic dyes, whereas the inner zone stains slightly. During activity the granular zone gradually diminishes in size; during the resting stages it gradually increases until it forms nearly three-fourths of the cell. In some of the secreting cells of the pancreas is a spherical mass, staining more easily than the rest of the cell; this is termed the *paranucleus*, and is believed to be derived from the nucleus. Between the alveoli are found, in certain parts, collections of cells, which are termed *interalveolar cell-islets*, or islands of Langerhans. The cells of these stain lightly with hæmatoxylin or carmine, and are more or less polyhedral in shape, forming a network in which many capillaries ramify. There are two main types of cell in the islets, distinguished as A-cells and B-cells according to the special staining reactions of the granules they contain. The cell-islets are believed to produce the internal secretion of the pancreas which is necessary for carbohydrate metabolism.

CC-0. In Public Domain. Gurukul Kangri Collection, Haridwar

Digitized by Arya Samaj Foundation Chennai and eGangotri

The wall of the pancreatic duct is thin, consisting of two coats, an external fibrous and an internal mucous; the latter is smooth, lined by columnar epithelium, and furnished near its termination with a few scattered follicles.

Vessels and Nerves.—The *arteries of the pancreas* are derived from the lienal artery, and from the pancreaticoduodenal branches of the hepatic and superior mesenteric arteries. Its *veins* open into the lienal and superior mesenteric veins. Its *lymphatic vessels* are described on p. 771. Its *nerves*, derived from the vagus and splanchnic nerves, reach it through the lienal plexus.

Applied Anatomy.—Inflammation of the pancreas has of late years received considerable attention. It appears to be due to infection of the pancreatic ducts by micro-organisms from the duodenum in cases of gastroduodenal catarrh, or from the biliary passages in which a gall-stone is lodged. Acute cases usually terminate fatally and are frequently of the hæmorrhagic type; chronic inflammation of the pancreas produces few symptoms of disease unless it is extensive, when attacks of abdominal pain, loss of appetite, progressive weakness and wasting, and the passage of whitish fatty motions, are likely to follow. Extensive fibrosis of the pancreas is also one of the commonest lesions found post-mortem in cases of diabetes mellitus. Cysts of the pancreas are sometimes met with. They may be the result of traumatism, when they generally contain blood, or they may be due to retention from obstruction of a duct, or from pressure on the main duct by a gall-stone. They may attain a large size, and cause symptoms by pressing on the stomach, Diaphragm, or common bile-duct. They generally push their way forwards between the stomach and transverse colon, and may then be felt as a definite tumour in the middle line of the upper part of the abdomen. The tumour is fixed and does not move with respiration. The treatment consists in opening the abdomen in the middle line, incising the cyst, evacuating its contents, and fixing its walls to the deeper layers of the abdominal wall. Drainage in the left loin, just below the last rib, can sometimes be established. When they are situated in the tail of the pancreas they have been removed. The pancreas is often the seat of cancer; this usually affects the head, and therefore speedily involves the bile-duct, leading to persistent jaundice; or it may press upon the portal vein, causing ascites, or involve the stomach, causing pyloric obstruction. The descending part of the duodenum is occasionally encircled by the head of the pancreas, and should the latter then be the seat of malignant disease or chronic inflammation it may cause obstruction of the duodenum. It has been said that the pancreas is the only abdominal viscus which has never been found in a hernial protrusion; but even this organ has been found in company with other viscera, in rare cases of diaphragmatic hernia.

The Liver (Hepar)

The liver, the largest gland in the body, is situated in the upper and right parts of the abdominal cavity, occupying almost the whole of the right hypochondrium, the greater part of the epigastrium, and not uncommonly extending into the left hypochondrium as far as the mammary line. In the male it weighs from 1·4 to 1·6 kilogm., in the female from 1·2 to 1·4 kilogm. It is relatively much larger in the fœtus than in the adult, constituting, in the former, about one-eighteenth, and in the latter, about one-thirty-sixth of the entire body weight. Its greatest transverse measurement is from 15 cm. to 20 cm. Vertically, near its right surface, it measures from 15 cm. to 17 cm., while its greatest anteroposterior diameter is on a level with the upper end of the right kidney, and is from 12 cm. to 15 cm.; opposite the vertebral column this diameter is reduced to about 7 cm. Its consistence is that of a soft solid; it is, however, friable and easily lacerated; its colour is a dark reddish-brown, and its specific gravity is 1·05.

When the liver has been hardened *in situ* it presents the appearance of a wedge, the base of which is directed to the right and the edge to the left. Symington describes its shape as that 'of a right-angled triangular prism with the right angles rounded off.'

The liver possesses five surfaces, viz. superior, inferior, anterior, posterior, and right. The superior, anterior, and right surfaces are united by round borders, but a sharp margin separates these surfaces from the inferior surface. A sickle-shaped fold of peritoneum, named the falciform ligament, is attached by its convex edge to the Diaphragm and the anterior abdominal wall, and by its concave edge to the anterior and superior surfaces of the liver, where it forms the boundary between the large right, and the small left, lobe of the liver (fig. 1139). In the free edge of this ligament there is a round cord, the *ligamentum teres hepatis*, which consists of the obliterated left umbilical vein.

CC-0. In Public Domain. Gurukul Kangri Collection, Haridwar

Digitized by Arya Samaj Foundation Chennai and eGangotri

Fossæ.—The inferior and posterior surfaces of the liver (figs. 1140, 1141) are traversed by five fossæ or fissures, arranged somewhat like the letter H.

Fig. 1139.—The superior, anterior, and right lateral surfaces of the liver. (From a model by His.)

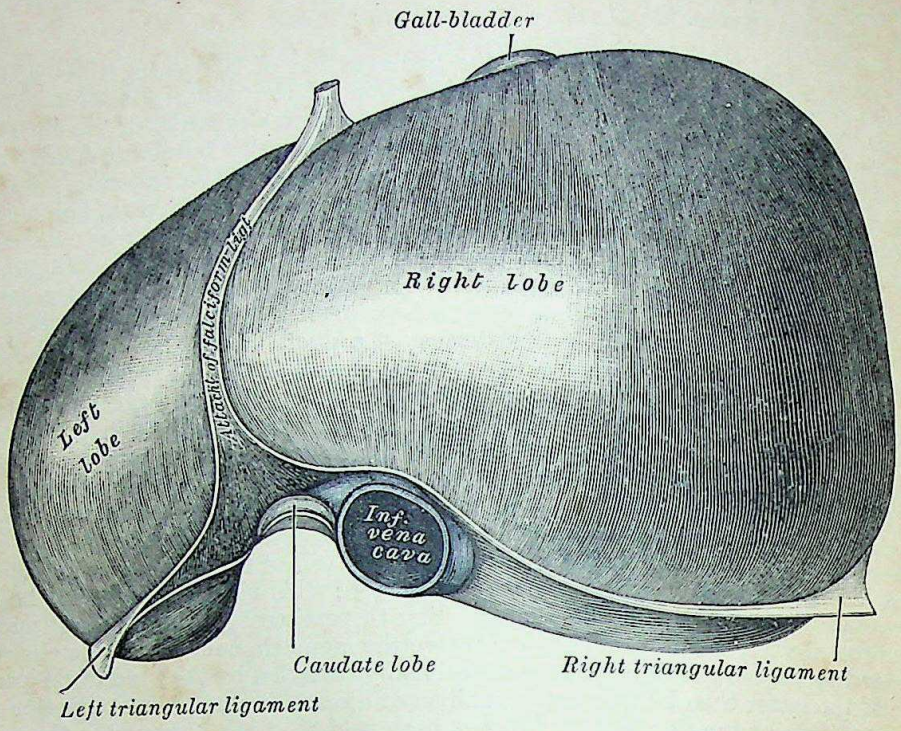

The left limb of the H is formed by the *left sagittal fossa*, which here separates the right from the left lobe; it consists of an anterior part, the fossa for the umbilical vein, and a posterior part, the fossa for the ductus venosus. The right limb of the H is formed by the *right sagittal fossæ*, the anterior of which

Fig. 1140.—The posterior and inferior surfaces of the liver. (From a model by His.)

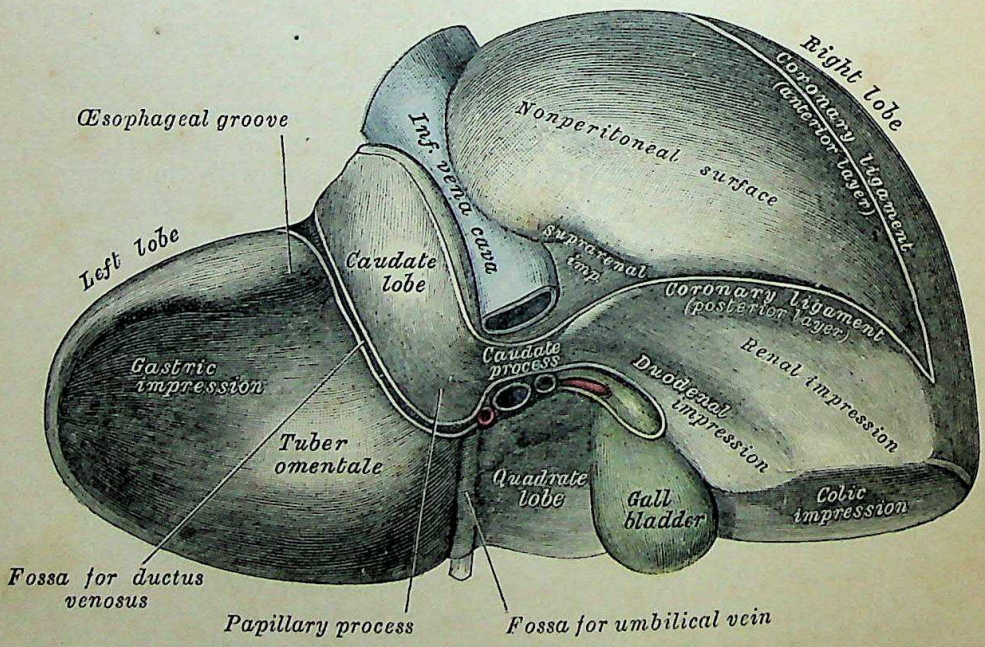

is the fossa for the gall-bladder, the posterior, the fossa for the inferior vena cava. The cross-bar of the H is represented by the porta hepatis.

CC-0. In Public Domain. Gurukul Kangri Collection, Haridwar

Digitized by Arya Samaj Foundation Chennai and eGangotri

The *fossa for the umbilical vein* (fig. 1140) is a deep cleft which runs backwards from a notch (*incisura umbilicalis*) on the anterior margin of the liver to the left end of the porta hepatis, where it joins the fossa for the ductus venosus. It forms the left boundary of a four-sided area named the quadrate lobe, and a part of the fossa is often bridged by a band of liver-substance, named the *pons hepatis*. In the fœtus it lodges the left umbilical vein, and in the adult, the obliterated remains of this vein, viz. the ligamentum teres hepatis.

The *fossa for the ductus venosus* (fig. 1140) is a deep cleft on the posterior surface of the liver, separating the left lobe from an oblong area, named the caudate lobe. In the fœtus it lodges the ductus venosus, and in the adult, a part of the lesser omentum, and a slender cord, named the *ligamentum venosum*, which represents the obliterated remains of the ductus venosus. The ligamentum venosum runs upwards and towards the right, in front of the upper end of the caudate lobe, and is attached to the wall of the inferior vena cava.

FIG. 1141.—The inferior surface of the liver. (From a model by His.)

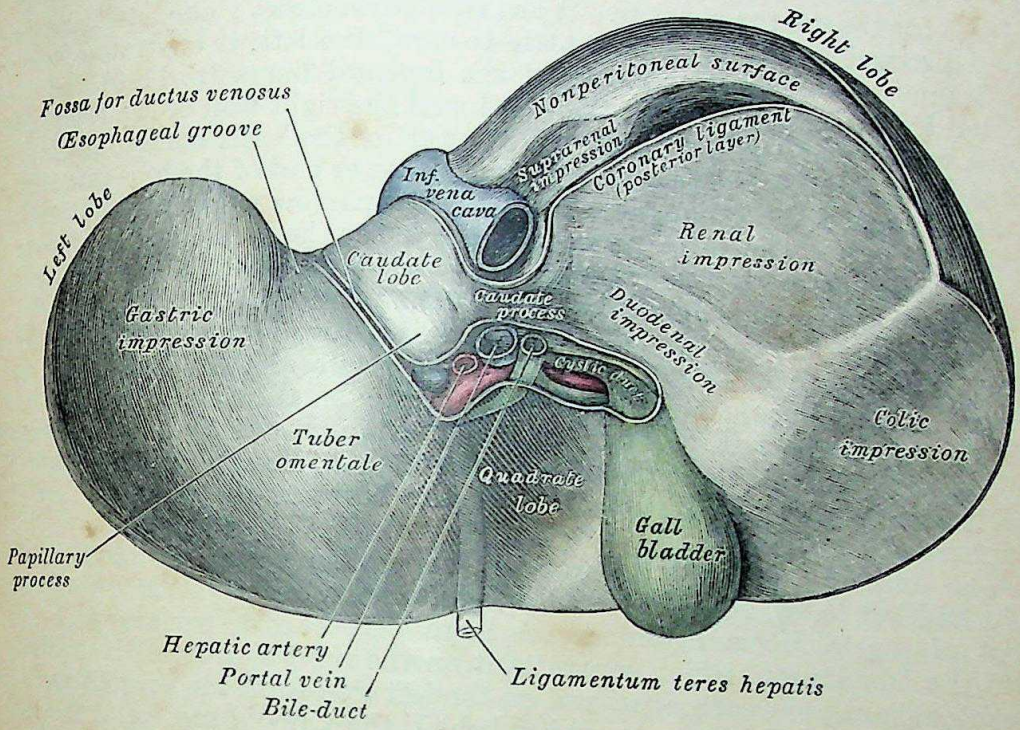

The *fossa for the gall-bladder* (fig. 1141) is a shallow depression on the inferior surface of the right lobe, parallel with, but on the right of, the fossa for the umbilical vein. It forms the right boundary of the quadrate lobe, and extends from the anterior margin of the liver, which is often notched by it, to the right extremity of the porta hepatis.

The *fossa for the inferior vena cava* (fig. 1140) is a deep depression, occasionally a complete tunnel, on the posterior surface of the liver, between the caudate lobe and what is known as the 'bare area' of the right lobe (p. 1184). It is separated from the porta hepatis by a narrow band of liver-substance, named the caudate process. If the inferior vena cava be slit open the orifices of the hepatic veins will be displayed.

The *porta hepatis* (transverse fissure) (fig. 1141) is a deep fissure about 5 cm. long. It runs transversely between the posterior ends of the fossæ for the gall-bladder and umbilical vein, and separates the quadrate from the caudate lobe. Through the porta hepatis the portal vein, the hepatic artery and a plexus of nerves enter, and the right and left hepatic ducts and some lymphatic vessels leave, the liver. Near the right end of the porta hepatis the right and left hepatic ducts unite, at an obtuse angle, to form the hepatic duct. The hepatic duct and artery are placed in front of the portal vein, the duct lying to the right side of the artery. The lesser omentum is attached to the margins of the porta hepatis.

CC-0. In Public Domain. Gurukul Kangri Collection, Haridwar

Digitized by Arya Samaj Foundation Chennai and eGangotri

Lobes.—As already stated, the falciform ligament and the left sagittal fossa serve to divide the liver into a right and a left lobe.

The *left lobe* is thin, flattened from above downwards, and only about one-sixth of the size of the right. It presents superior, inferior and posterior surfaces which are described with the surfaces of the liver.

The *right lobe* is of a somewhat quadrilateral form. The porta hepatis and the fossæ for the gall-bladder and inferior vena cava traverse its posterior and inferior surfaces and divide its left portion into two smaller lobes, named the quadrate and caudate.

The *quadrate lobe* (figs. 1141, 1142) is situated on the inferior surface of the liver. It is bounded in front by the anterior margin, behind by the porta hepatis, on the right by the fossa for the gall-bladder, and on the left by the fossa for the umbilical vein. It is oblong in shape, its anteroposterior diameter being greater than its transverse.

The *caudate lobe* (Spigelian lobe) (fig. 1141) is situated on the posterior surface of the liver, opposite the lower three thoracic vertebræ. It is bounded above by the upper part of the ligamentum venosum, below by the porta hepatis, on the right by the fossa for the inferior vena cava, and on the left by the fossa for the ductus venosus. It has two free surfaces; one, quadrilateral in shape, directed backwards and a little towards the left, is separated from the Diaphragm by the superior recess of the omental bursa (p. 1140), the other, directed forwards, and towards the left, forms the right wall of the fossa for the ductus venosus, and is in contact with the part of the lesser omentum which lies in this fossa. A notch divides the projecting lower end of the lobe into a round left part, named the *papillary process*, and a narrow right part, termed the *caudate process*. The latter separates the porta hepatis from the fossa for the inferior vena cava, and connects the caudate lobe with the inferior surface of the main part of the right lobe (fig. 1141).

Surfaces.—The *superior surface* of the liver (fig. 1139) includes portions of the right and left lobes. It fits under the vault of the Diaphragm, and is covered by peritoneum, with the exception of a small triangular area between the diverging layers of the falciform ligament. Its right and left portions are convex, but on its central part there is a shallow *cardiac impression* which corresponds with the position of the heart on the upper surface of the Diaphragm.

The *anterior surface*, triangular in shape, also comprises portions of the right and left lobes, and is covered by peritoneum except at the line of attachment of the falciform ligament. A large part of this surface is in contact with the Diaphragm, which separates it on the right side from the sixth to the tenth ribs and their cartilages, and on the left side from the seventh and eighth costal cartilages. Its central part lies behind the xiphoid process of the sternum and, in the angle between the diverging right and left costal cartilages, the anterior abdominal wall.

The *right surface* is convex from before backwards, and slightly so from above downwards. It is covered by peritoneum and lies against the right portion of the Diaphragm which separates it from the lower parts of the right lung and pleura; outside these are the right costal arches from the seventh to the eleventh inclusive.

The *posterior surface* (fig. 1140) includes portions of the right and left lobes, and is thick and convex on the right, but thin on the left. Its central part is deeply concave in adaptation to the convexity formed by the vertebral column and the crura of the Diaphragm. A large part of this surface of the right lobe is not covered by peritoneum but is attached to the Diaphragm by areolar tissue. This non-peritoneal surface, or '*bare area*' as it is termed, is triangular in shape, and is limited above and below by the superior and inferior layers of the coronary ligament. Its base is formed by the fossa for the inferior vena cava, while its apex, directed downwards and lateralwards, corresponds with the meeting-point of the two layers of the coronary ligament. Immediately to the right of the lower part of the fossa for the inferior vena cava is a small triangular pit, the greater part of which is on the bare surface; it lodges the right suprarenal gland and is named the *suprarenal impression*. Between the fossa for the inferior vena cava and that for the ductus venosus is the caudate lobe, already described. Immediately to the left of the fossa for the ductus venosus,

CC-0. In Public Domain. Gurukul Kangri Collection, Haridwar

Digitized by Arya Samaj Foundation Chennai and eGangotri

the posterior surface of the left lobe, is the *œsophageal impression* in which antrum cardiacum of the œsophagus is lodged.

The *inferior or visceral surface* (fig. 1141) is concave but uneven. It is ected downwards, backwards and towards the left, and is in contact with the mach, duodenum, lesser omentum, right colic flexure, right kidney and t suprarenal gland. It is invested by peritoneum, except at the fossa for gall-bladder and at the porta hepatis. On the inferior surface of the left , and in direct continuity with the œsophageal groove, is the *gastric impres-*, which is moulded over the stomach. On the right of this impression is a nded eminence, the *tuber omentale*, which fits into the concavity of the lesser vature of the stomach, and is in contact with the lesser omentum. On the t of the fossa for the umbilical vein is the quadrate lobe which is concave lies over the pyloric part of the stomach and the beginning of the duodenum, n these are dilated. When, on the other hand, the stomach is empty the drate lobe is in contact with the superior part of the duodenum and a portion he transverse colon. Behind the quadrate lobe are the porta hepatis and papillary and caudate processes, already described. There are three im-sions, colic, renal and duodenal, on that part of the right lobe which is ed on the right side of the fossa for the gall-bladder. The *colic impression*, ced by the right colic flexure, is shallow and is situated anteriorly. *renal impression*, posterior to and deeper than the colic impression, is pied by the upper part of the right kidney, and frequently extends for ort distance on to the lower part of the 'bare area.' The *duodenal ssion* is between the renal impression and the neck of the gall-bladder. a narrow, concave surface which comes into contact with the descending of the duodenum.

he *anterior margin* of the liver is sharp, and marked, at the attachment e falciform ligament, by the incisura umbilicalis (p. 1183), and frequently second notch at the fundus of the gall-bladder. In adult males this margin ally corresponds with the lower edge of the thorax in the right mammary but in women and children it usually projects below the ribs.

igaments.—The liver is connected to neighbouring structures by liga-s. These, except the ligamentum teres hepatis and the ligamentum um, consist of folds or reflections of the peritoneum and comprise the rm, the coronary, the right and left triangular, the hepatogastric and epatoduodenal ligaments.

e *falciform ligament* connects the liver to the Diaphragm and the anterior minal wall, and is a sickle-shaped fold consisting of two layers of peritoneum r united together. Its convex margin is fixed to the inferior surface of iaphragm, and to the posterior surface of the anterior abdominal wall 3 or 4 cm. to the right of the median plane, and extending downwards as the umbilicus. Its concave margin is attached to the anterior and or surfaces of the liver and to the fossa for the umbilical vein on its r surface. In its base or free edge are contained the ligamentum teres s and the small para-umbilical veins (p. 744). At the posterior part of perior surface of the liver the two layers of the falciform ligament separate ne another and expose a small triangular area which is uncovered by eum. The right layer of the ligament is continuous with the superior of the coronary ligament, the left with the anterior layer of the left lar ligament (fig. 1139).

coronary ligament (fig. 1140) is formed by the reflections of the peritoneum he liver to the Diaphragm at the upper and lower boundaries of the area,' and consists of a superior layer which is continuous with the right f the falciform ligament, and an inferior layer which passes to the right and suprarenal gland and is termed the *hepatorenal ligament*.

right triangular ligament (right lateral ligament) (fig. 1139) is situated ight extremity of the 'bare area,' and is a small fold which passes to the gm. It is formed by the apposition of the two layers of the coronary t.

left triangular ligament (left lateral ligament) (fig. 1139) is larger than . It connects the posterior part of the upper surface of the left lobe ver to the Diaphragm, and its anterior layer is continuous with the of the falciform ligament.

CC-0. In Public Domain. Gurukul Kangri Collection, Haridwar

Digitized by Arya Samaj Foundation Chennai and eGangotri

The *hepatogastric* and *hepatoduodenal* ligaments together constitute the lesser omentum which is attached below to the lesser curvature of the stomach and the superior part of the duodenum, and above to the liver along the margins of the porta hepatis and at the bottom of the fossa for the ductus venosus. Between the layers of the hepatoduodenal ligament are contained the bile-duct, the portal vein and the hepatic artery, together with some lymph-glands and lymphatic vessels, and a plexus of nerves.

The *ligamentum teres hepatis* (fig. 1141) is a fibrous cord resulting from the obliteration of the left umbilical vein of the fœtus. It runs from the umbilicus upwards and backwards in the free margin of the falciform ligament to the incisura umbilicalis, and above this in the fossa for the umbilical vein to the porta hepatis where it joins the left branch of the portal vein. Before birth the left umbilical vein conveyed blood from the placenta to the fœtus.

The *ligamentum venosum* (*Arantii*) is a fibrous cord resulting from the obliteration of the ductus venosus. It ascends in the fossa for the ductus venosus and unites the left branch of the portal vein to the terminal part of the inferior vena cava. Before birth the ductus venosus transmitted to the inferior vena cava some of the blood conveyed from the placenta by the left umbilical vein.

Vessels and Nerves.—The vessels connected with the liver are the portal vein, and hepatic artery and veins.

The *portal vein* and *hepatic artery*, accompanied by numerous nerves, ascend between the layers of the lesser omentum to the porta hepatis where each divides into two branches. The *bile-duct* and lymphatic vessels descend from the porta hepatis between the layers of the same omentum. They are all enveloped in a loose areolar tissue, the *fibrous capsule of Glisson*, which accompanies the vessels in their course through the portal canals in the interior of the liver (fig. 1146).

FIG. 1142.—A longitudinal section through a hepatic vein. (After Kiernan.)

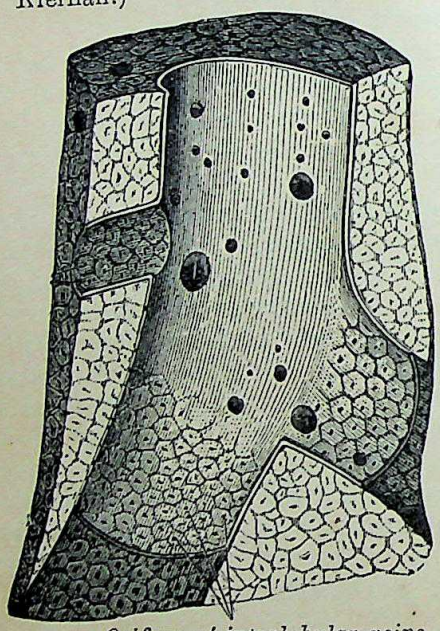

FIG. 1143.—A longitudinal section through a small portal vein and canal. (After Kiernan.)

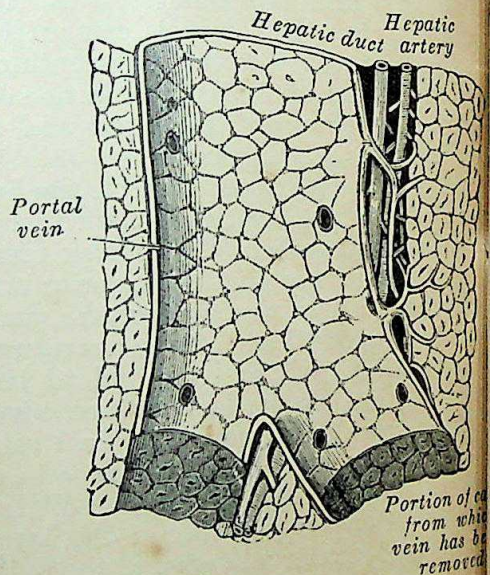

The *hepatic veins* (fig. 1142) convey the blood from the liver to the inferior vena ca and are described on p. 741. They have very little cellular investment, but what the binds them closely to the walls of the canals through which they run; so that, on sec of the liver, they remain widely open and are solitary, and may be easily distinguished f the branches of the portal vein, which are more or less collapsed, and always accompa by an artery and duct.

The *lymphatic vessels* of the liver are described on p. 771.

The *nerves* of the liver, derived from the left vagus and sympathetic, enter at the p hepatis and accompany the vessels and ducts to the interlobular spaces. Here, accor to Korolkow, the medullated fibres are distributed almost exclusively to the coats of blood-vessels; while the non-medullated enter the lobulus and ramify between the cel

Structure of the liver.—The greater part of the liver is covered with peritoneum, un neath which is a thin capsule of connective tissue. With the naked eye the liver ca

CC-0. In Public Domain. Gurukul Kangri Collection, Haridwar

Digitized by Arya Samaj Foundation Chennai and eGangotri

seen to consist of an enormous number of polyhedral lobules (fig. 1145), each of which is about 1 mm. in diameter. In the pig each lobule is sharply marked off from those adjoining it by connective tissue septa, but in the human liver there are no such definite boundaries.

FIG. 1144.—A section through the injected liver of a dog.

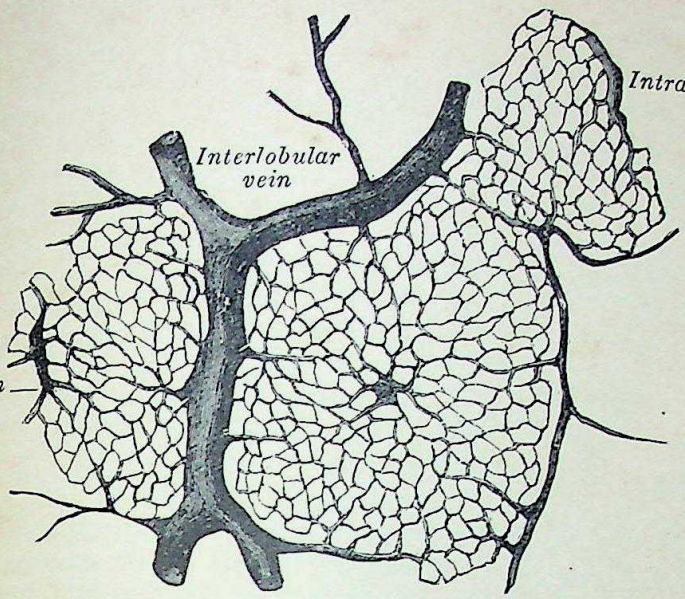

A lobule consists of a mass of cells, arranged in columns which radiate from a central n (fig. 1145). Between the columns are irregular blood-vessels (sinusoids).
A liver-cell is approximately cubical in shape, and is from 12μ to 25μ in diameter. possesses one or two spherical nuclei, and its protoplasm usually contains granules of ogen, and of a compound of iron. Fat droplets may also be present in the liver-cell. Blood is conveyed to the liver by the portal vein and hepatic artery. These vessels er the liver at the porta hepatis, and, as already stated, are enclosed together with the

FIG. 1145.—A section through a lobule of the human liver. Stained with hæmatoxylin and eosin. ×60.

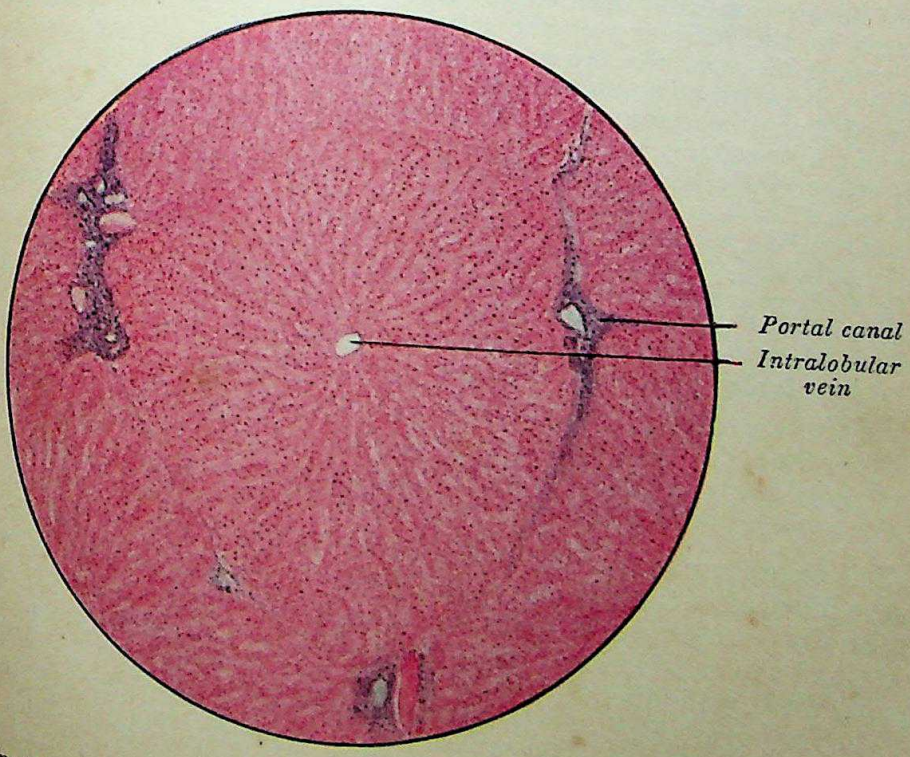

duct in a connective tissue sheath termed Glisson's capsule. In the porta the portal vein, hepatic artery and hepatic duct each divide into right and left , and these branches subsequently ramify, in their connective tissue capsule,

CC-0. In Public Domain. Gurukul Kangri Collection, Haridwar

Digitized by Arya Samaj Foundation Chennai and eGangotri

throughout the substance of the liver, and are accompanied by nerves and lymphatic vessels. The spaces occupied by these various structures are named *portal canals* (fig. 1146). The smallest branches of the portal vein form *interlobular plexuses* between the lobules, and from these plexuses capillary-like vessels, named sinusoids, run between the columns of liver-cells and open into the *intralobular* veins in the centres of the lobules. The intralobular veins join to form *sublobular veins*, and these unite to form the *hepatic veins* (fig. 1142) which drain the blood from the liver into the inferior vena cava.

Fig. 1146.—A transverse section through a portal canal of a pig. × 250.

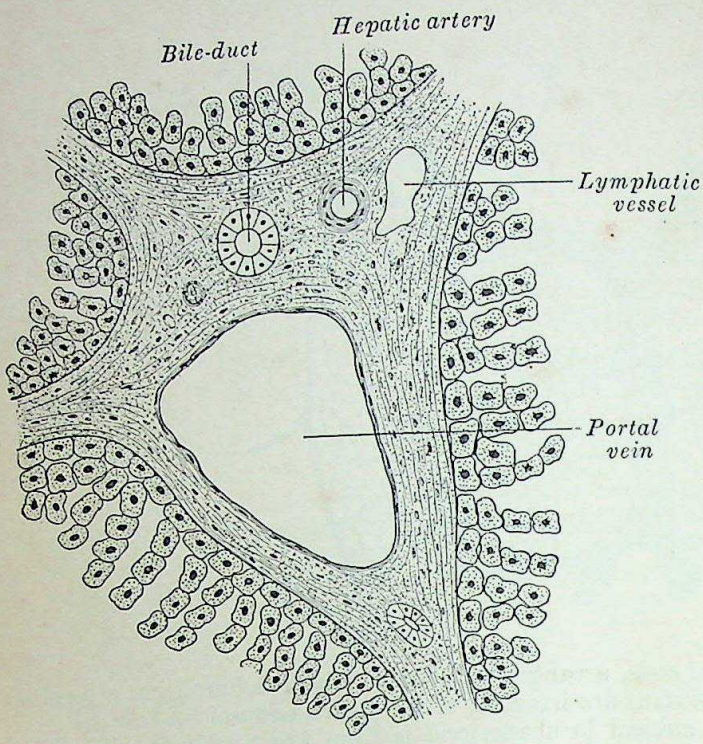

The *hepatic artery* conveys arterial blood to the connective tissue of the liver, to the walls of the subdivisions of the portal vein, and to the bile-ducts; its ultimate branches open into the interlobular plexuses and provide oxygenated blood for the liver cells.

The *sinusoids* are wider and more irregular than capillaries, and have an incomplete wall formed of branched cells (stellate cells of Kupffer). There is no lymph-space between the wall of the sinusoid and the liver-cells, and, in consequence of the gaps in the former, the blood comes into direct contact with the hepatic cells. Moreover, according to Herring and Simpson, minute channels penetrate the liver-cells, conveying the constituents of the blood into their substance.

The *bile-ducts* do not penetrate the lobules, but receive minute canaliculi which convey the bile from the cells to the periphery of the lobules. These canaliculi, or *bile-capillaries*, are merely little channels or spaces between adjacent cells, and are always separated from the sinusoids by at least half the width of a liver-cell (fig. 1147).

Fig. 1147.—The bile-capillaries of a rabbit, shown by Golgi's method. × 450.

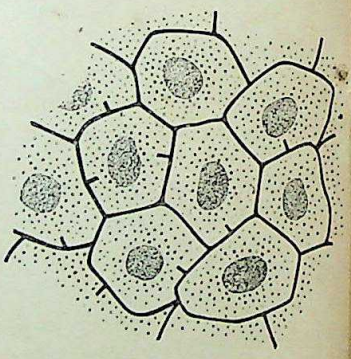

Structure of the ducts.—The walls of the biliary ducts consist of a connective tissue coat, in which are non-striped muscle-cells arranged both circularly and longitudinally, and an epithelial layer, consisting of short columnar cells resting on a basement-membrane.

Nerve-fibrils are said to be distributed between the cells of the liver, and even to enter their substance.

The Excretory Apparatus of the Liver

The excretory apparatus of the liver consists of (1) the *hepatic duct*, formed by the junction of the two main ducts, which leave the liver at the porta hepatis; (2) the *gall-bladder*, which serves as a reservoir for the bile; (3) the *cystic duct* or duct of the gall-bladder; and (4) the *bile-duct*, formed by the junction of the hepatic and cystic ducts.

The hepatic duct.—Two main ducts (right and left hepatic) issue from the liver at the porta hepatis and unite to form the hepatic duct, which passes downwards for about 3 cm., and is joined at an acute angle by the cystic duct; by the union of the hepatic with the cystic duct the bile-duct is formed. The hepatic duct is on the right of the hepatic artery and in front of the portal vein.

CC-0. In Public Domain. Gurukul Kangri Collection, Haridwar

Digitized by Arya Samaj Foundation Chennai and eGangotri

The **gall-bladder** (vesica fellea) (figs. 1141, 1148) is a conical or pear-shaped sac, lodged in a fossa on the under surface of the right lobe, and extending from near the right extremity of the porta hepatis to the anterior border of the liver. Its upper surface is attached to the liver by connective tissue; its under surface and sides are covered with peritoneum continued from the surface of the liver. Occasionally it is completely invested with peritoneum and may be connected to the liver by a short mesentery. It is from 7 cm. to 10 cm. long, 3 cm. broad at its widest part, and holds from 30 c.cm. to 50 c.cm. It is divided into a fundus, body, and neck.

FIG. 1148.—The gall-bladder and bile-ducts laid open. (Spalteholz.)

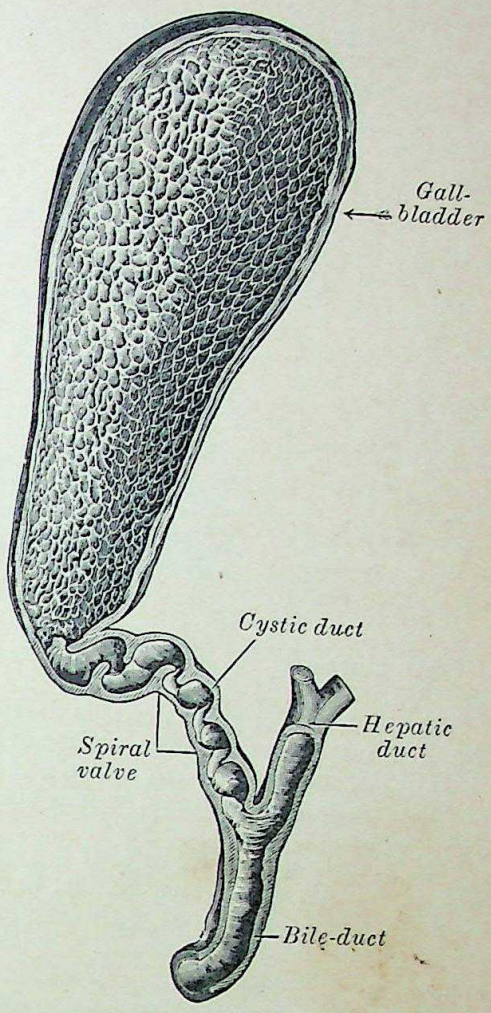

The *fundus*, or expanded end, is directed downwards, forwards and to the right. It projects beyond the anterior margin of the liver, and comes into relationship with the posterior surface of the anterior abdominal wall below the ninth right costal cartilage, and behind the point where the lateral edge of the right Rectus abdominis touches the lower margin of the thoracic wall; posteriorly the fundus is in relation with the transverse colon. The *body* is directed upwards, backwards and to the left; near the right end of the porta hepatis it is continuous with the neck. It is in relation, by its upper surface, with the liver; by its under surface, with the commencement of the transverse colon; and farther back usually with the upper end of the descending portion of the duodenum, but sometimes with the superior portion of the duodenum or pyloric end of the stomach. The *neck* is narrow; it curves upwards and forwards, and then, turning abruptly upwards and downwards, becomes continuous with the cystic duct; at its point of continuity with the cystic duct there is a constriction. The neck is attached to the liver by areolar tissue in which the cystic artery is imbedded. The mucous membrane which lines the neck projects into its lumen in the form of oblique ridges, forming a sort of spiral valve.

The **cystic duct**, from 3 cm. to 4 cm. long, passes backwards, downwards, and to the left from the neck of the gall-bladder, and joins the hepatic duct to form the bile-duct; it runs parallel with and adheres to the hepatic duct for a short distance before joining with it. The mucous membrane lining its interior is thrown into a series of crescentic folds, from five to twelve in number, similar to those found in the neck of the gall-bladder. They project into the duct in regular succession, and are directed obliquely round the tube, presenting such the appearance of a crescentic spiral valve. When the duct is distended, the spaces between the folds are dilated, and the exterior of the duct appears dented.

The **bile-duct** (common bile-duct, ductus choledochus) is formed by the junction of the cystic and hepatic ducts; it is about 7 cm. long, and of the diameter of a goose-quill.

It runs at first downwards, backwards, and to the left in the right border of the lesser omentum, in front of the portal vein, and on the right of the hepatic artery. It passes behind the superior portion of the duodenum, and then in a groove, on the posterior surface of the head of the pancreas; here situated in front of the inferior vena cava, and is sometimes completely imbedded in the pancreatic substance. Its terminal part lies for a short distance along the right side of the terminal part of the pancreatic duct and

CC-0. In Public Domain. Gurukul Kangri Collection, Haridwar

Digitized by Arya Samaj Foundation Chennai and eGangotri

passes with it obliquely through the coats of the duodenum. The two ducts unite and open by a common orifice upon the summit of a papilla (*papilla duodeni*), situated at the medial side of the descending portion of the duodenum, 7 cm. to 10 cm. from the pylorus (fig. 1137). The short tube formed by the union of the two ducts is dilated into an ampulla, the *ampulla of Vater*.

FIG. 1149.—A transverse section through the wall of the gall-bladder.

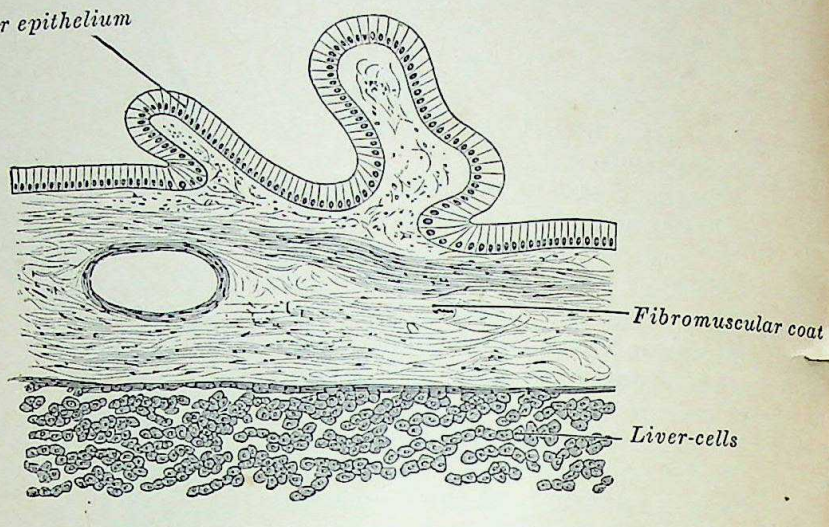

Structure (fig. 1149).—The gall-bladder has three coats: serous, fibromuscular, and mucous.

The *external or serous coat* is derived from the peritoneum; it completely invests the fundus, but covers only the under surfaces and sides of the body and neck.

The *fibromuscular coat*, a thin but strong layer, consists of dense fibrous tissue, mixed with plain muscular fibres, which are disposed chiefly in a longitudinal direction, a few running transversely.

The *internal or mucous coat* is loosely connected with the fibrous layer. It is generally of a yellowish-brown colour, and is elevated into minute rugæ. It is continuous through the hepatic duct with that of the ducts of the liver, and through the bile-duct with that of the duodenum. Its epithelium is columnar, and secretes mucin, or, in some animals, a nucleoprotein.

The coats of the large biliary ducts are an external or fibrous, and an internal or mucous. The fibrous coat is composed of strong fibro-areolar tissue, with a certain amount of muscular tissue, arranged, for the most part, in a circular manner around the ducts. The mucous coat is continuous with the lining membrane of the hepatic ducts and gall-bladder, and also with that of the duodenum; and, like the mucous membrane of these structures, its epithelium is of the columnar variety. It is provided with numerous mucous glands, which are lobulated and open by minute orifices scattered irregularly in the larger ducts.

Applied Anatomy.—On account of its large size, its fixed position, and its friability, the liver is more frequently ruptured than any of the other abdominal viscera. The rupture may vary from a slight scratch to an extensive and complete laceration of its substance, dividing it into two parts. Sometimes an internal rupture, without laceration of the peritoneal covering, takes place, and such injuries are most susceptible of repair; but small tears of the surface may also heal; when, however, the laceration is extensive, death usually takes place from hæmorrhage, on account of the fact that the hepatic veins are contained in rigid canals in the liver-substance and are unable to contract, and are moreover unprovided with valves. The liver may also be torn by the end of a broken rib perforating the Diaphragm. It may be injured by stabs or other punctured wounds, and when these are inflicted through the chest-wall, the pleural and peritoneal cavities may both be opened up, and both lung and liver wounded. In cases of laceration of the liver, when there is evidence that bleeding is going on, the abdomen must be opened, the laceration sought for, and the bleeding arrested. This may be done temporarily by introducing the forefinger into the epiploic foramen and placing the thumb on the lesser omentum, and compressing the hepatic artery and portal vein between the two. The margins of the laceration, if small, can be brought together and sutured by means of a blunt curved needle passed from one side of the wound to the other; this must be done with the greatest gentleness, as the liver substance is very friable. When the laceration is extensive it must be packed with gauze, the end of which is allowed to hang out of the external wound.

CC-0. In Public Domain. Gurukul Kangri Collection, Haridwar

Digitized by Arya Samaj Foundation Chennai and eGangotri

Abscess of the liver is of not infrequent occurrence. The so-called *tropical abscess* is to absorption, from the intestine, of the amœba of dysentery, which reaches the liver ough the portal system and causes the formation of a large chronic abscess; this may arge in many different directions on account of the relations of the liver to other ans. Thus it has been known to burst into the lungs, when the pus is coughed up; or o the stomach, when the pus is vomited; it may burst into the colon, or duodenum; by perforating the Diaphragm, it may empty itself into the pleural cavity. It often kes its way forwards, and points on the anterior abdominal wall, and finally it may st into the peritoneal or pericardial cavities. Abscesses of the liver frequently require ning, and this must be done by an incision in the abdominal wall, in the thoracic wall, n the lumbar region, according to the direction in which the abscess is tracking. The sion through the abdominal wall is to be preferred when possible. The abdominal l is incised over the swelling, and, unless the peritoneum is adherent, gauze is packed round the exposed liver surface, the abscess opened, and a large drainage tube rted.

Hydatid cysts are more often found in the liver than in any of the other viscera. The on of this is not far to seek. The embryo of the egg of the Tænia echinococcus, being rated in the stomach by the disintegration of its shell, bores its way through the ric walls and usually enters a blood-vessel, and is carried by the blood-stream to the atic capillaries, where its onward course is arrested, and where it undergoes develop- t into the fully formed hydatid.

Ptosis of the liver, or hepatoptosis, from abnormal laxity of its ligaments and failure ife support it usually receives from the subjacent viscera, is an occasional cause of ous nervous and gastro-intestinal disturbances. It has been very fully described by nard and his pupils. In women who have used very tight corsets and in men who e worn tightly buckled belts, the lower margin of the right lobe may become elongated he pressure, producing an abnormal lobe known as the *linguiform* or *Riedel's* lobe. may cause indefinite abdominal symptoms suggesting dyspepsia or disease of the bladder; and if discovered accidentally, a Riedel's lobe may be mistaken for a our of the right kidney, of the colon or pancreas, or even of the vermiform process.

The gall-bladder may become distended in cases of obstruction of the cystic duct or e bile-duct, or from a collection of gall-stones in its interior, thus forming a large our. The swelling is pear-shaped, and projects downwards and forwards towards the ilicus. It moves with respiration, since it is attached to the liver. To relieve this ition, the gall-bladder must be opened (*cholecystotomy*) and the gall-stones removed. operation is performed by an incision, 5 cm. to 7 cm. long, through the lateral part of right Rectus, commencing at the costal margin. The peritoneal cavity is opened, the tumour having been found, gauze is packed round it to protect the peritoneal y, and it is aspirated. When the contained fluid has been evacuated the flaccid ler is drawn out of the abdominal wound and its wall incised; any gall-stones in the ler are now removed. If the case is one of obstruction of the duct, an attempt must ade to dislodge the stone by manipulation through the wall of the duct. If this does ceed, the safest plan is to incise the duct, extract the stone, and close the incision e sutures in two layers. The obstruction having been removed, the edges of the on in the gall-bladder may be sutured round a drainage tube which is inserted into avity; this fistulous opening usually closes in the course of a few weeks. The bladder may be completely removed if it be quite certain that no cause for biliary ction remains: this is also done for primary malignant growth of the viscus.

Obstruction of the bile-duct apart from stone is often due to occlusion of this canal by ure of malignant growths, especially those commencing in the pylorus or pancreas. also seen following ulceration of the duct, cicatricial contraction of the scar tissue g place. Enormous distension, both of the bile-duct itself and of its radicles in the substance, may occur at times.

THE UROGENITAL APPARATUS

The urogenital apparatus consists of (*a*) the urinary organs for the secretion discharge of the urine, and (*b*) the genital organs, which are concerned the process of reproduction.

THE URINARY ORGANS

The urinary organs comprise the *kidneys*, which secrete the urine; the s, which convey it to the *urinary bladder*; and the *urethra*, through it is discharged from the urinary bladder.

CC-0. In Public Domain. Gurukul Kangri Collection, Haridwar

Digitized by Arya Samaj Foundation Chennai and eGangotri

The Kidneys (Renes)

The **kidneys** are situated in the posterior part of the abdomen, one on either side of the vertebral column, behind the peritoneum; they are surrounded by a mass of fat and some loose areolar tissue. Their upper ends are on a level with the upper border of the twelfth thoracic vertebra, their lower, with the third lumbar vertebra. The right kidney is usually slightly lower than the left, probably on account of the vicinity of the liver; the left is a little longer and narrower than the right. The long axis of each kidney is directed downwards and lateralwards; the transverse axis lateralwards and backwards.

Each kidney is about 11 cm. in length, 6 cm. in breadth, and about 3 cm. in thickness. In the adult male the weight of the kidney varies from 125 gm. to 170 gm.; in the adult female from 115 gm. to 155 gm.

The kidney has a characteristic form, and presents for examination two surfaces, two borders, and an upper and a lower end.

Fig. 1150.—The anterior surfaces of the kidneys, showing the areas of contact of the neighbouring viscera.

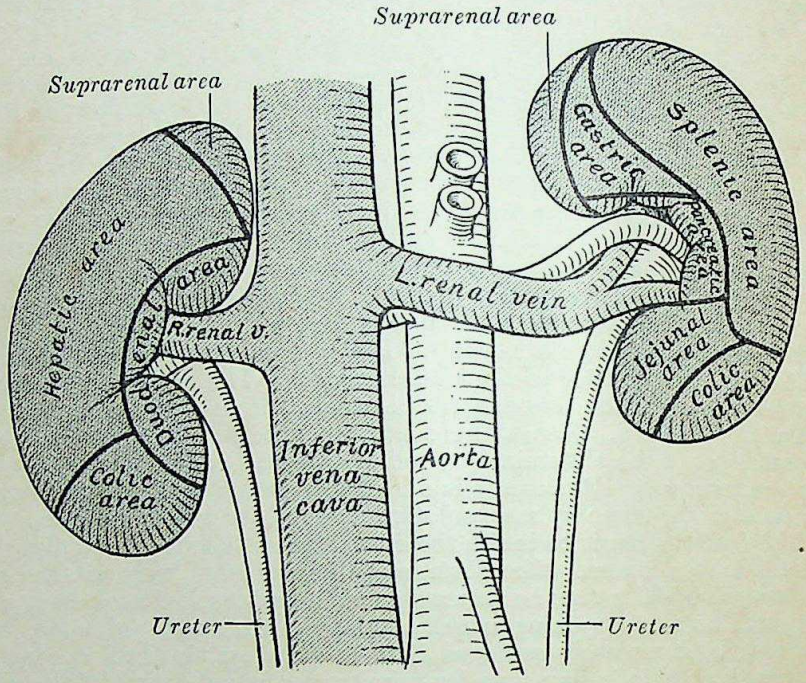

Relations.—The *anterior surface* (figs. 1135, 1150) of either kidney is convex, and looks forwards and lateralwards. Its relations to adjacent viscera differ on the two sides of the body.

(*a*) *Anterior surface of right kidney.*—A narrow portion at the upper extremity is in contact with the right suprarenal gland. A large area just below this and involving about three-fourths of the surface, lies in the renal impression on the inferior surface of the liver, and a narrow but somewhat variable area near the medial border is in contact with the descending part of the duodenum. The lower part of the anterior surface is in contact laterally with the right colic flexure, and medially, as a rule, with the small intestine. The area in relation with the small intestine and almost the whole of the area in contact with the liver are covered by peritoneum; the suprarenal, duodenal, and colic areas are devoid of peritoneum.

(*b*) *Anterior surface of left kidney.*—A small area along the upper part of the medial border is in relation with the left suprarenal gland, and the upper two-thirds of the lateral half of the anterior surface are in contact with the renal impression on the spleen. A somewhat quadrilateral field, about the middle of the anterior surface, marks the site of contact with the body of the pancreas, on the deep surface of which are the lienal vessels. Above this is a small triangular portion, between the suprarenal and splenic areas, in

CC-0. In Public Domain. Gurukul Kangri Collection, Haridwar

Digitized by Arya Samaj Foundation Chennai and eGangotri

ontact with the stomach. Below the pancreatic and splenic areas the lateral art is in relation with the left colic flexure, the medial with a small part of e jejunum. The area in contact with the stomach is covered by the peri-neum of the omental bursa, while those in relation to the spleen and the junum are covered by the peritoneum of the main cavity; behind the eritoneum of the jejunal area are some branches of the left colic vessels. e suprarenal, pancreatic, and colic areas are devoid of peritoneum.

The *posterior surface* (figs. 1151, 1153) of each kidney is directed backwards d medialwards. It is imbedded in areolar and fatty tissue, and is devoid peritoneal covering. It lies upon the Diaphragm, the medial and lateral mbocostal arches, the Psoas major, the Quadratus lumborum, and the ndon of origin of the Transversus abdominis, the subcostal vessels, and the t thoracic, iliohypogastric, and ilioinguinal nerves. The right kidney rests

FIG. 1151.—The posterior surfaces of the kidneys, showing the areas of relation to the parietes.

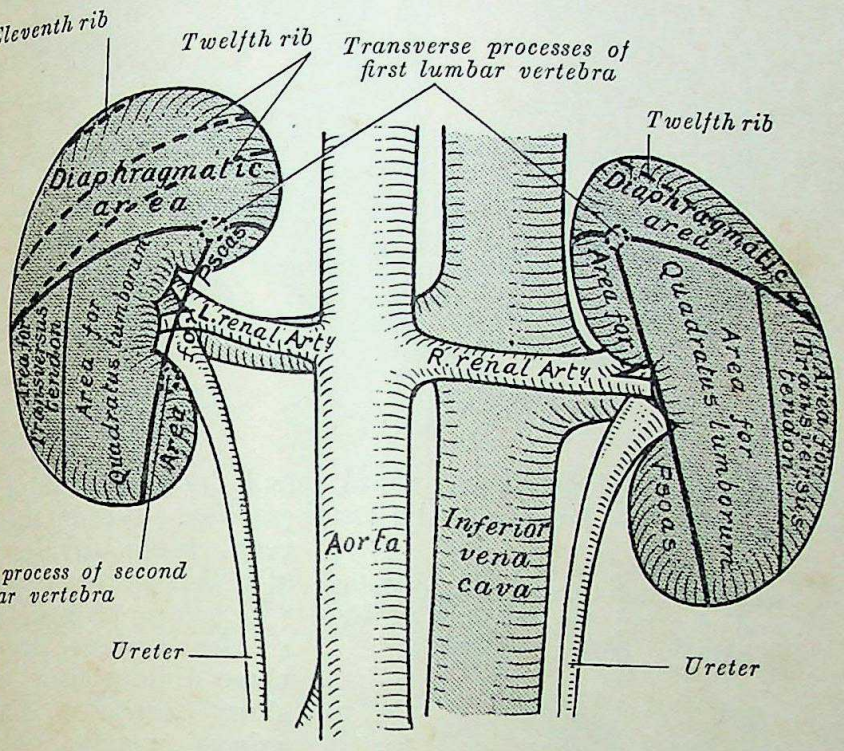

on the twelfth rib, the left usually on the eleventh and twelfth. The aphragm separates the kidney from the pleura, which dips down to form phrenicocostal sinus, but frequently the muscular fibres of the Diaphragm defective or absent over a triangular area immediately above the lateral mbocostal arch, and when this is so the perinephric areolar tissue is in contact th the diaphragmatic pleura.

The *upper end* of the kidney is thick and round, and is nearer the median line an the lower; it is surmounted by the suprarenal gland, which covers also small portion of the anterior surface. The *lower end*, smaller and thinner an the superior, extends to within 5 cm. of the iliac crest.

The *lateral border* is convex; that of the left kidney is in contact, at its per part, with the spleen.

The *medial border* is concave in the centre and convex at either end; is directed a little downwards and forwards. In its central part is a deep rtical fissure, the *hilum*, which is bounded by an anterior and a posterior and transmits the renal vessels and nerves and the funnel-shaped upper (*renal pelvis*) of the ureter. The relative positions of the main structures e hilum are as follows: the renal vein is in front, the renal artery in the ille, and the renal pelvis behind. Frequently, however, branches both rtery and vein are situated behind the renal pelvis. Above the hilum the dial border is in relation with the suprarenal gland, below with the com-cement of the ureter.

CC-0. In Public Domain. Gurukul Kangri Collection, Haridwar

Digitized by Arya Samaj Foundation Chennai and eGangotri

The hilum leads into a central recess or cavity named the *renal sinus*, which is lined by a continuation of the capsule of the kidney and is almost

Fig. 1152.—The relations of the kidneys from behind.

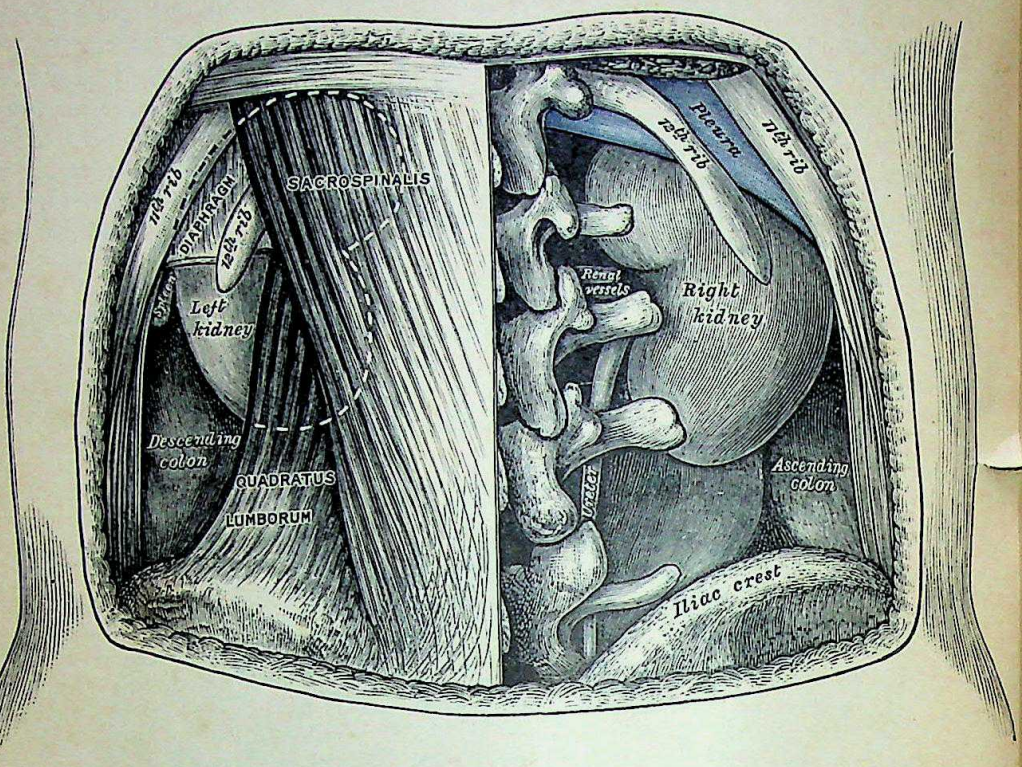

entirely filled by the renal pelvis and renal vessels; on the wall of the sinus are numerous nipple-like elevations, the *renal papillæ*. Within the sinus the renal pelvis divides into two, sometimes three, large branches which are termed the *calyces renales majores*, and each of these divides again into several short branches named the *calyces renales minores* (fig. 1156). In all, there are usually from seven to thirteen of these minor calyces; each expands as it approaches the wall of the renal sinus, and the expanded end is indented and moulded round from one to three renal papillæ. The wall of the expanded end of the calyx is firmly adherent to the capsule lining the renal sinus; it is perforated by the collecting tubes which open on the summits of the renal papillæ.

Fig. 1153.—A sagittal section through the posterior abdominal wall showing the relations of the capsule of the kidney. (After Gerota.)

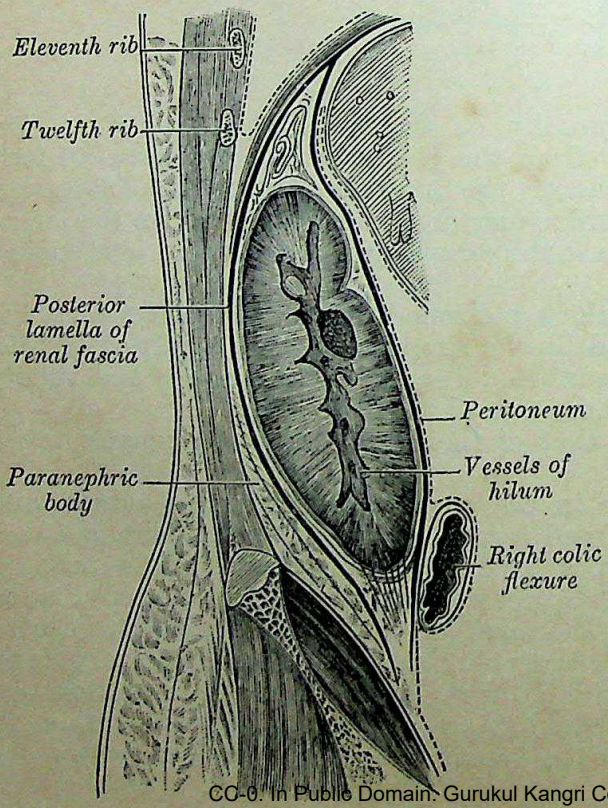

The kidney and its vessels are imbedded in a mass of fatty tissue, termed the *fatty capsule*, which is thickest at the borders of the kidney and is prolonged through the hilum into the renal sinus. The kidney and the fatty capsule are enclosed in a sheath of

CC-0. In Public Domain. Gurukul Kangri Collection, Haridwar

Digitized by Arya Samaj Foundation Chennai and eGangotri

brous tissue continuous with the subperitoneal fascia, and named the *renal* scia (figs. 1153, 1154). At the lateral border of the kidney the renal fascia plits into an anterior and posterior layer. The nterior layer is carried edialwards in front of the idney and its vessels, and continuous over the aorta ith the corresponding yer of the opposite side. he posterior layer extends edialwards behind the idney and blends with the scia on the Quadratus mborum and Psoas major, d through this fascia is tached to the vertebral lumn. Above the supranal gland the two layers the renal fascia fuse, and ite with the fascia of e Diaphragm; below the lney they remain separ-, and are gradually lost the subperitoneal fascia the iliac fossa. The renal scia is connected to the rous tunic of the kidney numerous trabeculæ, ich traverse the fatty psule, and are strongest r the lower end of the an. Behind the renal cia is a considerable quantity of fat, which constitutes the *paranephric body*. e kidney is held in position partly through the attachments of the renal cia and partly by the apposition of the neighbouring viscera.

FIG. 1154.—A transverse section, showing the relations of the capsule of the kidney. (After Gerota.)

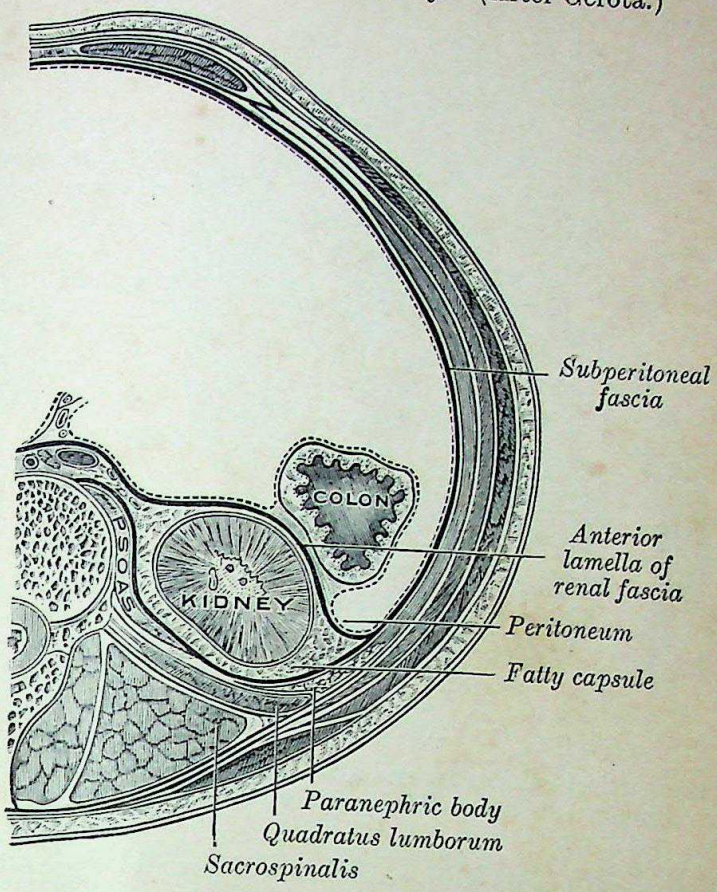

. 1155.—The kidneys and suprarenal lands of a new-born child. Anterior pect.

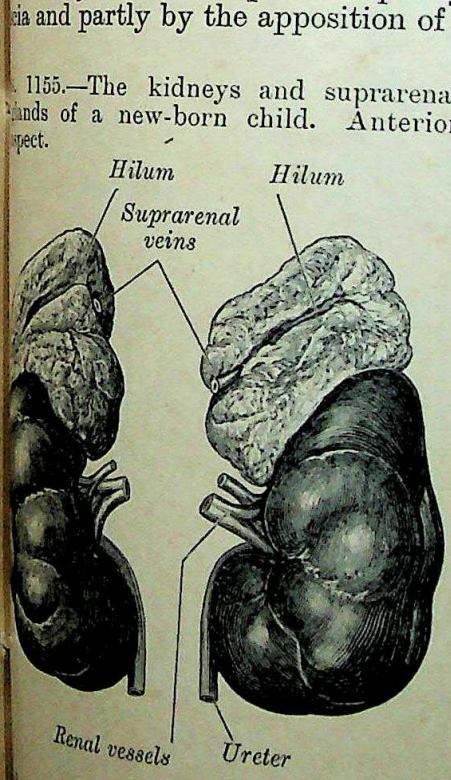

In the fœtus the kidney consists of about twelve distinct lobules (fig. 1155), but in the adult these are fused and the kidney presents a uniformly smooth surface.

General structure of the Kidney.—The kidney is invested by a fibrous capsule which is easily stripped off; beneath the fibrous capsule is an incomplete layer of smooth muscular fibres. If a vertical section be made from its lateral to its medial border, and the loose tissue and fat removed from around the vessels and the excretory duct, the *renal sinus* will be seen surrounded at all parts but one by the proper kidney-substance (fig. 1156). The fibrous capsule is prolonged into the sinus round the lips of the hilum, to become continuous with the outer coat of the renal pelvis.

The kidney is composed of an internal medullary and an external cortical substance.

The *medullary substance* consists of a series of pale striated conical masses, termed the *renal pyramids*, the bases of s are directed towards the circumference of the kidney, while their apices converge ds the renal sinus, where they form prominent papillæ projecting into the interior calyces, each calyx minor receiving from one to three papillæ.

CC-0. In Public Domain. Gurukul Kangri Collection, Haridwar

Digitized by Arya Samaj Foundation Chennai and eGangotri

The *cortical substance* is reddish-brown in colour, and soft and granular in consistence. It lies immediately beneath the fibrous tunic, arches over the bases of the pyramids, and dips in between adjacent pyramids towards the renal sinus. The parts dipping in between the pyramids are named the *renal columns* (Bertini), while the portions which connect the renal columns with each other and intervene between the bases of the pyramids and the fibrous tunic are called the *cortical arches*. If the cortex be examined with a lens, it will be seen to consist of a series of lighter-coloured, conical areas, termed *medullary rays*, and a darker-coloured intervening substance, which from the complexity of its structure is named the *convoluted part*. The rays gradually taper towards the circumference of the kidney, and consist of a series of outward prolongations from the base of each renal pyramid.

Fig. 1156.—A vertical section through a kidney.

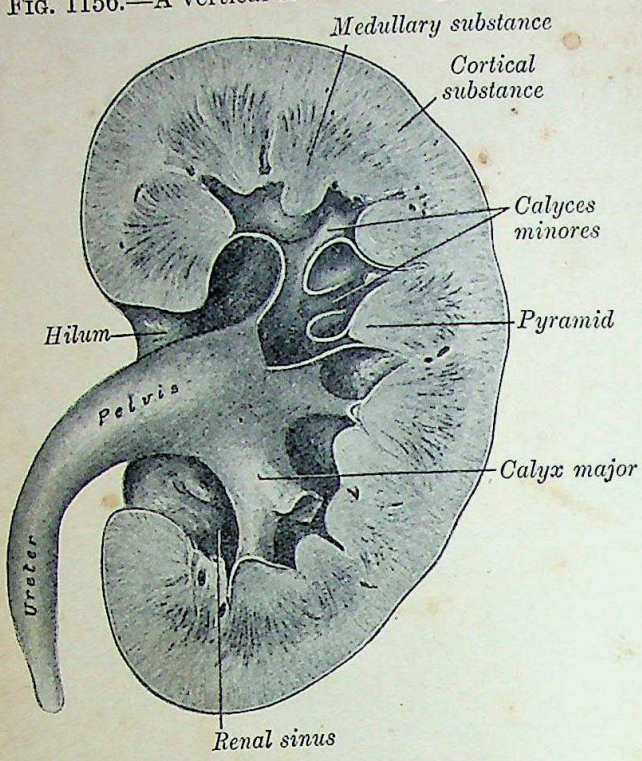

The cortical and medullary substances are made up of renal tubules and blood-vessels, united and bound together by a connecting stroma.

Minute Anatomy.—The *renal tubules* (fig. 1157) commence in the cortical substance, and after pursuing a very tortuous route through the cortical and medullary substances finally end at the apices of the renal pyramids by open mouths. If

Fig. 1157.—A scheme of a renal tubule and its vascular supply.

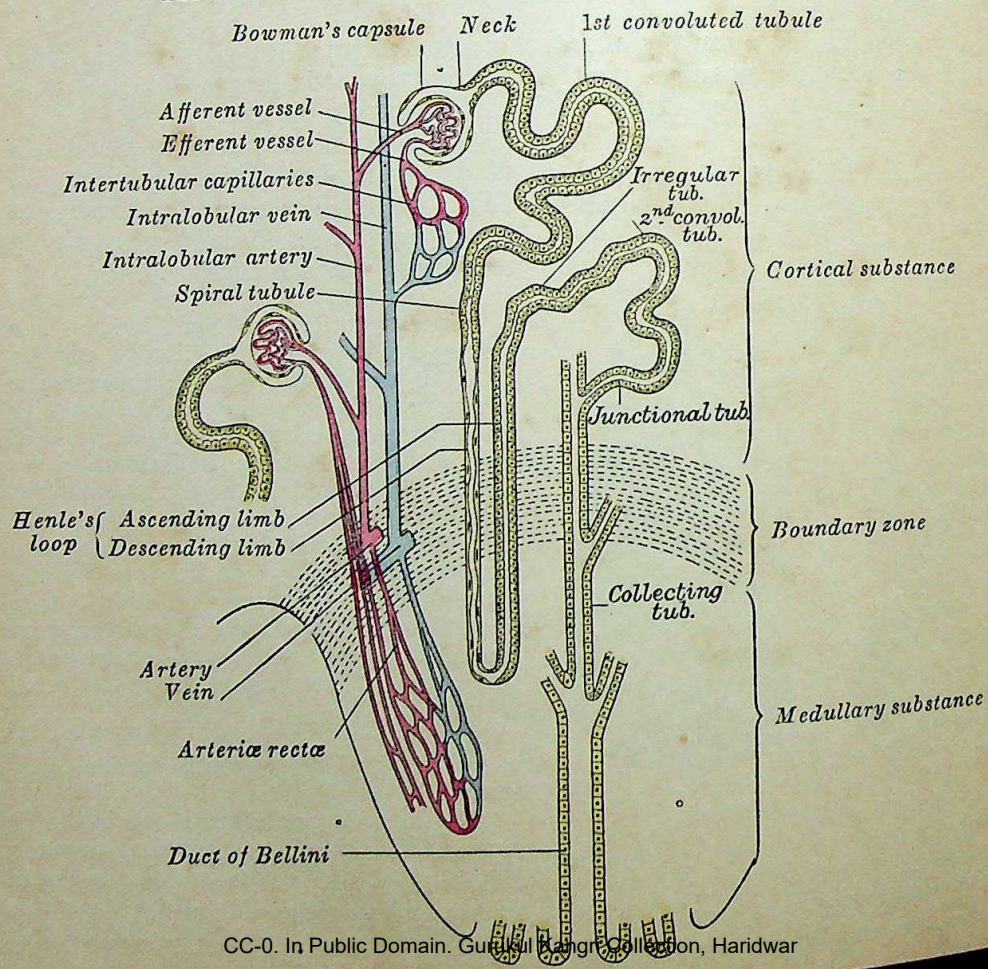

CC-0. In Public Domain. Gurukul Kangri Collection, Haridwar

Digitized by Arya Samaj Foundation Chennai and eGangotri

the surface of one of the papillæ be examined with a lens, it will be seen to be studded over with minute openings, the orifices of the renal tubules, from sixteen to twenty in number, and if pressure be made on a fresh kidney, urine will be seen to exude from these orifices. The tubules commence in the convoluted part and renal columns as the *Malpighian bodies*, which are small rounded masses of a deep red colour, averaging about

FIG. 1158.—The distribution of the blood-vessels in the cortex of kidney.

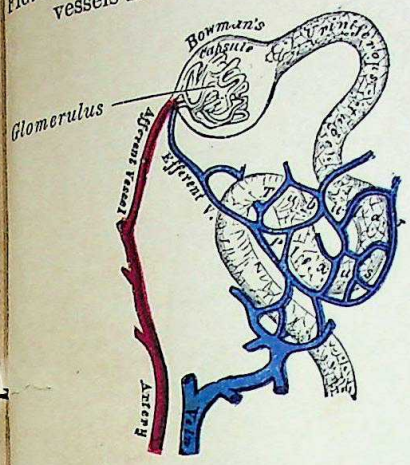

FIG. 1159.—A glomerulus.

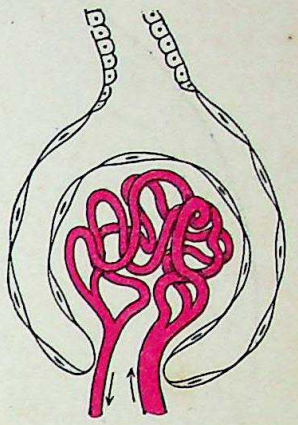

·2 mm. in diameter. Each of these bodies is composed of two parts: a central *lomerulus* of vessels, and a membranous envelope, the *capsule of Bowman*, which is the mall pouch-like commencement of a renal tubule.

The *glomerulus* is a lobulated tuft of convoluted capillary blood-vessels, held together y scanty connective tissue. This capillary network is derived from a small arterial twig, he *afferent vessel*, which enters the capsule, generally at a point opposite to that at which he latter is connected with the tubule; the *efferent vessel* emerges from the capsule at he same point. The afferent vessel is usually the larger of the two (figs. 1158, 1159).

Bowman's capsule is the blind expanded end of the renal tubule, indented for the eception of the glomerulus. It consists of a basement-membrane, lined by a single layer f flattened epithelial cells. Thus between the glomerulus and the outer layer of the apsule there is a space lined by a continuous layer of squamous cells; this cavity varies n size according to the state of secretion and the amount of fluid present in it. In the etus and young subject the lining epithelial cells are polyhedral or columnar.

Each *renal tubule* consists of the following parts: (1) *Bowman's capsule*, already escribed, (2) a constricted portion, the *neck*, (3) the *first convoluted tubule*, (4) the *spiral ubule*, which takes a course towards the medulla, (5) the *descending limb of Henle's loop*, narrower han the preceding, and running into the medullary ubstance, where it turns to form (6) the *loop of Henle*, (7) the *ascending limb of Henle's loop*, broader han the descending limb, which re-enters the ortical substance, (8) an angular segment, the *regular or zig-zag tubule*, (9) the *second convoluted ubule*, (10) the *junctional tubule*, which opens into (1), the *collecting tubule* (fig. 1157).

The *straight or collecting tubules* commence in e medullary rays of the cortex; they unite at ort intervals with one another; the terminal tubes resent a considerable increase in calibre, and are nown as the *ducts of Bellini*; they finally open on e summit of a papilla.

Structure of the renal tubules.—The renal tubules onsist of a basement-membrane lined by epithelium. the neck the epithelium is continuous with that ining Bowman's capsule, and like it consists of attened cells each containing an oval nucleus (fig. 161). The two convoluted tubules, the spiral and g-zag tubules, and the ascending limb of Henle's p are lined by a type of epithelium which is hisogically similar in all. The cells are somewhat columnar in shape and dovetail into one other on their lateral aspects. Each has a striated border next the lumen of the tube; substance is granular, the granules in the outer portion being arranged in vertical rows. nucleus is spherical and situated about the centre of the cell. In the descending b of Henle's loop the epithelium resembles that found in Bowman's capsule and the

FIG. 1160.—A longitudinal section through the descending limb of Henle's loop.

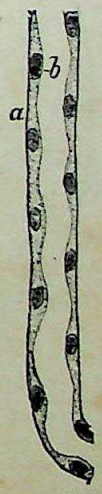

a. Membrana propria. *b*. Epithelium.

CC-0. In Public Domain. Gurukul Kangri Collection, Haridwar

Digitized by Arya Samaj Foundation Chennai and eGangotri

commencement of the tube, consisting of flat, clear epithelial plates, each with an oval nucleus (fig. 1160). The nuclei alternate on opposite surfaces of the tubule so that the lumen remains fairly constant.

FIG. 1161.—A radial section through the cortex of a human kidney. Stained with hæmatoxylin and eosin. ×100.

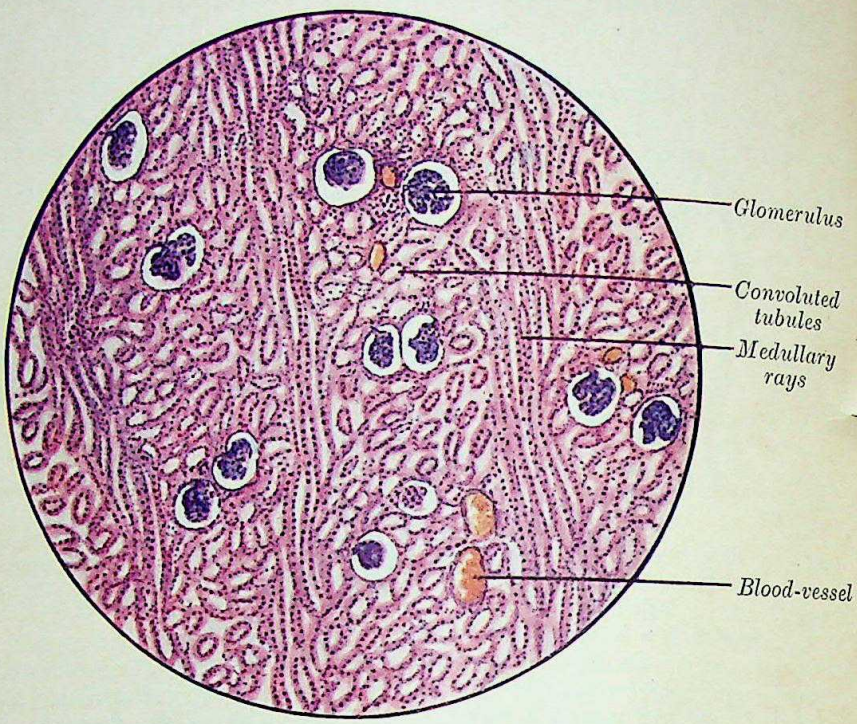

FIG. 1162.—A transverse section through a pyramid of a human kidney. Stained with hæmatoxylin and eosin. ×400.

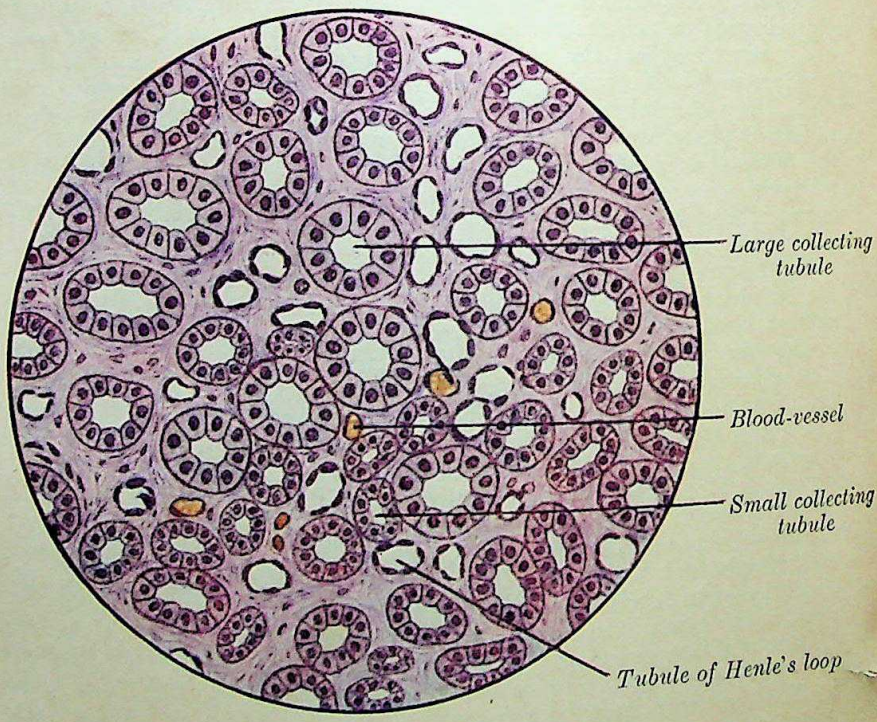

In the collecting tubule the epithelium is clear and cubical: in its papillary portion the cells are columnar and transparent (fig. 1162).

The **renal blood-vessels.**—Before entering the kidney, each artery divides into four or five branches which at the hilum lie mainly between the renal vein and renal pelvis, the vein being in front, the pelvis behind; one branch usually lies behind the pelvis. Each

CC-0. In Public Domain. Gurukul Kangri Collection, Haridwar

Digitized by Arya Samaj Foundation Chennai and eGangotri

vessel gives off some small branches to the suprarenal glands, to the ureter, and to the surrounding cellular tissue and muscles. One or two *accessory renal arteries* may arise from the abdominal aorta, either above or below the renal artery. Such vessels do not enter the hilum, but pierce the upper or lower parts of the kidney. The branches of the renal artery, while in the sinus, give off a few twigs for the nutrition of the surrounding tissues, and end in the *arteriæ propriæ renales*, which enter the kidney proper in the renal columns. These pass between the renal pyramids, and may be called *interlobar arteries* (Gross*). They run a short course, and divide and subdivide rapidly at acute angles as they penetrate the kidney substance, producing, when injected by barium sulphate and examined by means of *x*-rays, a treelike appearance. From the smallest branches of the tree, near the surface of the kidney, there spring a large number of straight arteries (*intralobular*), arranged vertically to the surface. Each of these gives off a number of lateral branches, afferent vessels of the glomeruli, or *glomerular arteries*. Each intralobular artery with its branches and associated glomeruli resembles a string of red currants.

From the capillaries of each glomerulus an efferent vessel, smaller than the afferent vessel, arises and divides to form a second set of capillaries which run between the tubules and are called *intertubular capillaries*. These unite to form *intralobular veins* which discharge into the tributaries of the *interlobar veins* running with the interlobar arteries. Each intralobular vein begins beneath the fibrous tunic of the kidney by the convergence of smaller veins, called *venæ stellatæ* because of their appearance as seen from the surface of the organ.

The vascular supply of the medulla of the kidney is relatively scanty, and is derived from branches of the interlobar arteries, and also, to a small extent, from the efferent vessels of the glomeruli adjacent to the medullary substance. The capillaries run a straight course between the collecting tubules, and open into tributaries of the interlobar veins, these finally uniting to form the renal vein.

Nerves of the kidney.—The nerves of the kidney, although small, are about fifteen in number. They have small ganglia developed upon them, and are derived from the renal plexus, which is formed by branches from the cœliac plexus, the lower and outer part of the cœliac ganglion and aortic plexus, and from the lesser and lowest splanchnic nerves. The spinal nerves which supply the kidney are derived from the tenth, eleventh, and twelfth thoracic segments of the medulla spinalis. The nerves communicate with the testicular plexus, a circumstance which may explain the occurrence of pain in the testis in affections of the kidney. They accompany the renal artery and its branches, and are distributed to the blood-vessels and to the cells of the urinary tubules.

The *lymphatics* of the kidney are described on p. 772.

Connective tissue, or intertubular stroma.—Although the tubules and vessels are closely packed, a small amount of connective tissue, continuous with the fibrous tunic, binds them firmly together and supports the blood-vessels, lymphatics, and nerves.

Applied Anatomy.—Absence of one kidney is excessively rare; a more frequent occurrence is congenital atrophy of one kidney, where the organ is very small but usually healthy in structure. One or both kidneys may be misplaced as a congenital condition; if the misplaced kidney is not fixed it is termed a floating kidney. Usually the misplaced organs are misshapen and fixed; they may be situated higher or lower or further from the middle line than usual; or they may be displaced into the iliac fossa, over the sacro-iliac joint, in to the promontory of the sacrum, or into the pelvis between the rectum and bladder, or by the side of the uterus. Occasionally the two kidneys are fused together; the union may be complete, resulting in a disc-shaped kidney from which two ureters descend; or the lower ends may be connected by a thick mass of renal tissue so that the whole structure presents the form of a horse-shoe. Fused kidneys are usually situated in the middle line of the abdomen but may be misplaced. Pulsation of the abdominal aorta may be transmitted through the part of the 'horse-shoe' kidney which crosses in front of the vessel. In the fœtus the kidney has a lobulated structure (fig. 1155), and traces of this may persist in the adult. Sometimes the pelvis of the kidney is duplicated, and a double ureter is not uncommon.

In badly nourished people or in those who have become emaciated, the perinephric fat is deficient and the kidney may become displaced; this condition, which occurs more frequently in females than in males, on account of the greater laxity of the abdominal walls, is termed movable kidney.

Injuries of the kidney are generally due to some severe crushing force, as from being run over by a heavy waggon or cart, or from the abdomen being compressed between the buffers of two railway carriages. When a laceration occurs on the posterior surface of the organ, infiltration of blood and urine takes place into the retroperitoneal connective tissue; this is often followed by suppuration, and death may ensue from septic poisoning. When the laceration is in front, the peritoneum may be torn and extravasation of blood and urine may take place into the peritoneal cavity. Death may occur from hæmorrhage or peritonitis. Occasionally, when rupture involves the pelvis of the kidney or the commencement of the ureter, this duct may become blocked, and hydronephrosis follow. Sometimes the kidney may be bruised by blows in the loin, or by being compressed

* For a method of investigating the course of the blood-vessels in the kidney, the reader is referred to an article by L. Gross, *Journal of Medical Research*, vol. xxxvi. 1917.

CC-0. In Public Domain. Gurukul Kangri Collection, Haridwar

Digitized by Arya Samaj Foundation Chennai and eGangotri

between the lower ribs and the ilium when the body is violently bent forwards. This is followed by a little transient hæmaturia, which, however, speedily passes off.

The loose cellular tissue around the kidney may be the seat of suppuration, constituting *perinephric abscess*. This may be due to injury, or to disease of the kidney itself, or to extension of inflammation from neighbouring parts. The abscess tends to point externally in the groin or loin.

Tumours of the kidney may be recognised by their position: by the resonant colon lying in front of them; and by their rounded outline not presenting a notched anterior margin like the spleen, with which they are most likely to be confounded. The *hypernephroma*, a tumour arising from suprarenal 'rests' or inclusions in the cortex or medulla of the kidney, is not infrequent. When occurring in children it is often associated with precocious growth of the body generally and of the hair and sexual organs in particular. Arising, as it often does, in the kidney, a hypernephroma is indistinguishable from a true renal tumour so far as the physical signs and symptoms go; it is really, however, a tumour of the suprarenal gland substance.

The examination of the kidney should be bimanual; that is to say, one hand should be placed in the flank and firm pressure made forwards, while the other hand is buried in the abdominal wall, over the situation of the organ. Manipulation of the kidney frequently produces a peculiar sickening sensation, sometimes with faintness.

The kidney may require exposure for exploration or the evacuation of pus (*nephrotomy*); it may be incised for the removal of stone (*nephrolithotomy*); it may be sutured when movable or floating (*nephropexy*); or it may be removed (*nephrectomy*). It may be exposed either by a lumbar or an abdominal incision; except in cases of very large tumours, a lumbar incision is best, as it has the advantages of not opening the peritoneum, and of affording admirable drainage. An oblique incision should be made, starting at the lateral border of the Sacrospinalis, 1 cm. below the last rib and directed downwards and forwards towards a point 2·5 cm. in front of the anterior superior spine of the ilium. The structures divided are the skin, the superficial fascia with the cutaneous nerves, the deep fascia, the posterior border of the Obliquus externus abdominis, and the outer border of the Latissimus dorsi; the Obliquus internus and the posterior aponeurosis of the Transversus abdominis; the lateral border of the Quadratus lumborum; the deep layer of the lumbodorsal fascia and the transversalis fascia. The fatty tissue around the kidney is now exposed to view, and must be separated by the fingers, or a director, in order to reach the kidney. The operations of nephrolithotomy, for the removal of calculi from the kidney, and nephrotomy, or incision of the kidney for abscess, &c., are generally performed by the lumbar incision. This route is also generally chosen for nephrectomy, especially if the organ is thought to contain pus. The abdominal operation is best performed by an incision through the lateral part of the Rectus abdominis on the side of the kidney to be removed; the kidney is then reached from the lateral side of the colon, ascending or descending as the case may be, and thus the vessels of the colon are not interfered with. The incision commencing just below the costal arch is made of varying length, according to the size of the kidney. The abdominal cavity having been opened, the intestines are drawn medialwards and the peritoneum covering the kidney to the lateral side of the colon is incised, so that the fingers can be introduced behind the peritoneum. The kidney must now be enucleated, and the vessels firmly ligatured and divided, the ureter being tied separately. The particular advantage of the abdominal operation is that the condition of the other kidney can be ascertained by manual examination, before the removal of the diseased kidney is finally decided upon; and, further, involvement of neighbouring structures by a new growth, rendering removal impossible, can only be discovered by the abdominal route.

Nephropexy is the name given to the operation for fixing a movable kidney. The kidney is reached by the lumbar incision, and is freely separated from its perinephric capsule. Sutures are then passed through the true capsule of the organ and are brought out above the upper end of the wound. When these sutures are tied, the kidney is tightly anchored in position; at the same time a flap of the true capsule can be separated from the parenchyma of the kidney and passed around the last rib and sutured down again, so as to form a sling for the kidney from the rib.

The Ureters

The **ureters** are the two tubes which convey the urine from the kidneys to the urinary bladder. Each measures from 25 cm. to 30 cm. in length, and is a thick-walled, narrow, cylindrical tube which is directly continuous with the tapering lower end of the renal pelvis. It runs downwards and medialwards in front of the Psoas major and, entering the pelvic cavity, finally opens into the fundus of the urinary bladder.

The *abdominal part* lies behind the peritoneum on the medial portion of the Psoas major, and is crossed obliquely by the testicular vessels. It enters the pelvic cavity by crossing either the end of the common, or the beginning of the external, iliac vessels.

CC-0. In Public Domain. Gurukul Kangri Collection, Haridwar

Digitized by Arya Samaj Foundation Chennai and eGangotri

At its origin the *right* ureter is usually covered by the descending part of the duodenum; in its course downwards it lies to the right of the inferior vena cava, and is crossed by the right colic and the ileocolic vessels, while near the superior aperture of the pelvis it passes behind the lower part of the mesentery and the terminal part of the ileum. The *left* ureter is crossed by the left colic vessels, and near the superior aperture of the pelvis passes behind the sigmoid colon and its mesentery.

The *pelvic part* runs at first downwards on the lateral wall of the pelvic cavity, under cover of the peritoneum, and along the anterior border of the greater sciatic notch. It lies in front of the hypogastric artery, and medial to the obturator nerve and the umbilical, obturator, inferior vesical, and middle hæmorrhoidal arteries. Opposite the lower part of the greater sciatic foramen it inclines medialwards, and reaches the lateral angle of the urinary bladder, where it is situated in front of the upper end of the seminal vesicle (and at a distance of about 5 cm. from the opposite ureter); here the ductus deferens crosses to its medial side, and the vesical veins surround it. Finally, the ureters run obliquely through the wall of the bladder and open by slit-like apertures into the cavity of that viscus at the lateral angles of the trigone (fig. 1169). When the bladder is distended the openings of the ureters may be about 5 cm. apart, but when it is empty and contracted the distance between them is diminished by one-half. Owing to their oblique course through the coats of the bladder, the upper and lower walls of the terminal portions of the ureters become closely applied to each other when the bladder is distended, and, acting as valves, prevent regurgitation of urine.

FIG. 1163.—A transverse section through the ureter. Stained with hæmatoxylin and eosin. ×5.

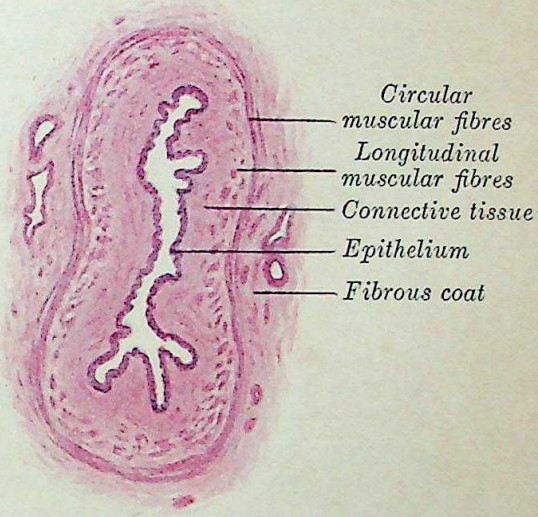

In the *female*, the ureter forms, as it lies in relation to the wall of the pelvis, the posterior boundary of a shallow depression named the *ovarian fossa*, in which the ovary is situated. It runs medialwards and forwards beneath the broad ligament of the uterus to reach the lateral aspect of the cervix uteri and upper part of the vagina. It then lies for a short distance in front of the vagina, and finally pierces the wall of the bladder obliquely. In this part of its course it is accompanied for about 2·5 cm. by the uterine artery, which then crosses in front of the ureter and ascends between the two layers of the broad ligament. The ureter is distant about 2 cm. from the side of the cervix of the uterus.*

The ureter is sometimes duplicated on one or both sides, and the two tubes may remain distinct as far as the fundus of the urinary bladder; they rarely open separately into the bladder cavity.

Structure (fig. 1163).—The ureter is composed of three coats: fibrous, muscular, and mucous.

The *fibrous coat* is continuous at one end with the fibrous tunic of the kidney on the floor of the renal sinus; while at the other it is lost in the fibrous structure of the bladder.

* J. C. Brash (*British Medical Journal*, Oct. 28, 1922) says:

"The relation of the last portion of the ureter to the vagina is variable. There is usually a portion of the ureter in front of the vagina, lying for a short distance in the connective tissue between the vagina and bladder, and then in the wall of the bladder itself.

"With the vagina and bladder symmetrically related to each other this portion of the ureter is equal on the two sides; but deviation from the symmetrical position is the rule. The result is an increase of this portion of the ureter on one side and a corresponding decrease on the other. There is frequently no ureter in front of the vagina on one side, and therefore a much longer portion than usual on the other side.

"In the majority of specimens examined, it is the left ureter that has the greatest relation to the vagina, and it is occasionally found crossing the middle line of the vagina. . . . It must be forgotten, however, that occasionally the position may be reversed."

CC-0. In Public Domain. Gurukul Kangri Collection, Haridwar.

Digitized by Arya Samaj Foundation Chennai and eGangotri

In the renal pelvis the *muscular coat* consists of two layers, longitudinal and circular: the longitudinal fibres become lost upon the sides of the papillæ at the extremities of the calyces; the circular fibres surround the medullary substance in the same situation. In the ureter proper the muscular fibres are very distinct, and are arranged in three layers: an external longitudinal, a middle circular, and an internal, less distinct than the other two, but having a general longitudinal direction.

The *mucous coat* is smooth, and presents a few longitudinal folds which become effaced by distension. It is continuous with the mucous membrane of the bladder below, while it is prolonged over the papillæ of the kidney above. It consists of fibrous tissue containing many elastic fibres, and covered by transitional epithelium. The continuation of the epithelium over the renal papillæ is columnar in type.

The *arteries* supplying the ureter are branches from the renal, testicular (or ovarian), hypogastric, and inferior vesical arteries.

The *lymphatics* of the ureter are described on p. 772.

The *nerves* are derived from the inferior mesenteric, spermatic (or ovarian), and pelvic plexuses; through these plexuses fibres are derived from the lower three thoracic and first lumbar segments of the medulla spinalis. Small ganglia and isolated ganglion-cells are found in the fibrous and muscular coats.

Applied Anatomy.—Rupture of the ureter occasionally occurs. If it be torn completely across, the urine collects in the retroperitoneal tissues; if it be not completely divided, the lumen of the tube may become strictured, and hydronephrosis or pyonephrosis result. The ureter may be accidentally wounded in some pelvic operations, such as removal of the uterus; if this should happen the divided ends must be sutured together, or failing to accomplish this an attempt may be made to implant the upper end into the bladder. If this cannot be carried out the only alternative is to remove the kidney immediately.

Stones may become impacted in any part of the ureter, but this occurs most commonly either at the point where the tube is crossing the pelvic brim or at where it is passing obliquely through the muscular wall of the bladder. In the former case, an incision with its centre opposite, and 2·5 cm. medial to, the anterior superior iliac spine dividing all the structures down to the peritoneum, enables the operator to reach the ureter by pushing the unopened peritoneum inwards; the stone can then be felt in the ureter, the wall of which is incised, and the stone extracted, free drainage being provided for the escaping urine. When the stone is impacted at the vesical end of the tube a preliminary incision into the bladder is required, and the calculus can be removed by scratching through the mucous membrane overlying it.

The Urinary Bladder (Vesica Urinaria)

The **urinary bladder** (fig. 1164) is a sac which acts as a reservoir for the urine; its size and position vary with the amount of fluid it contains, and also with the state of distension of the neighbouring viscera. "The mean capacity of the living urinary bladder in the male adult is 220 c.c., varying from 120 c.c. to 320 c.c." *

When the empty bladder is firmly contracted it presents the form of a flattened tetrahedron. It has a fundus, a vertex, a superior and an inferior surface. The *fundus* is triangular in shape, and is directed downwards and backwards towards the rectum, from which it is separated by the rectovesical fascia, the vesiculæ seminales, and the terminal portions of the ductus deferentes. The *vertex* is directed forwards towards the upper part of the symphysis pubis, and from it the middle umbilical ligament (urachus) is continued upwards on the back of the abdominal wall to the umbilicus; the peritoneum folded over this ligament forms the middle umbilical fold. The *superior surface* is triangular, covered by peritoneum, and is in relation with the sigmoid colon and some coils of the small intestine. It is bounded on either side by a lateral border which separates it from the inferior surface, and behind by a posterior border, represented by a line joining the two ureters, which intervenes between it and the fundus. The lateral borders run from the ureters to the vertex, and from these borders the peritoneum extends to the walls of the pelvis. On either side of the bladder is a peritoneal depression named the *paravesical fossa* (fig. 1091). The *inferior surface* is directed downwards, and is uncovered by peritoneum. It may be divided into a posterior or prostatic area and two inferolateral surfaces. The prostatic area, somewhat triangular, rests upon and is in direct continuity with the base of the prostate; from it the urethra emerges. The inferolateral portions of the inferior surface are separated in front from the symphysis pubis by a mass of fatty tissue named the *retropubic pad*; behind,

CC-0. In Public Domain. Gurukul Kangri Collection, Haridwar

* Ralph Thompson, *Journal of Anatomy*, vol. liii.

Digitized by Arya Samaj Foundation Chennai and eGangotri

they are in contact with the fascia covering the Levatores ani and Obturatores internii.

When the bladder is empty it is placed entirely within the pelvis, below the level of the obliterated hypogastric arteries, and of the portions of the ductus deferentes which are in contact with the lateral wall of the pelvis.

As the bladder fills, its fundus, being more or less fixed, is only slightly depressed; while its superior surface gradually rises into the abdominal cavity, carrying with it its peritoneal covering, and at the same time rounding off the posterior and lateral borders. When the bladder is distended it assumes an ovoid form, the long diameter being directed upwards and forwards. In this condition it presents a posterosuperior, an antero-inferior, and two lateral

FIG. 1164.—A median sagittal section through the male pelvis.

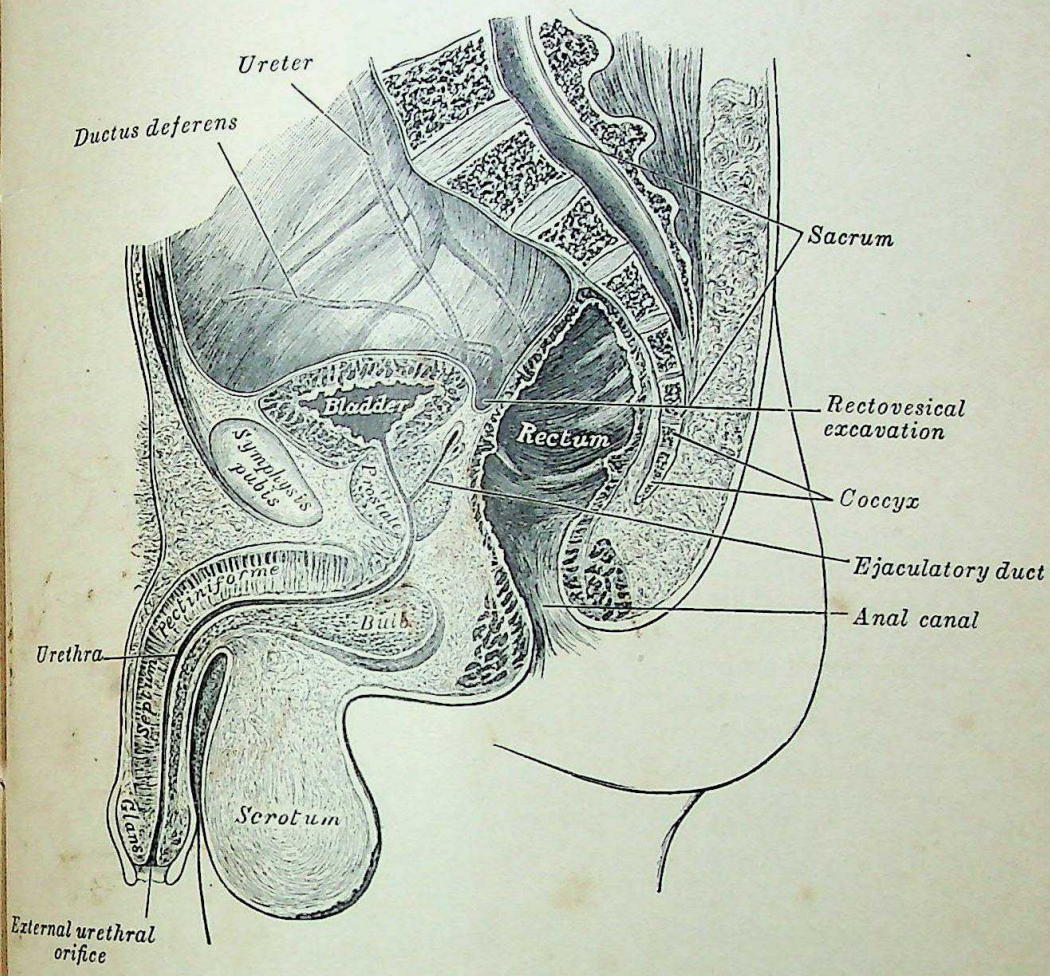

urfaces, a fundus, and a summit. The posterosuperior surface is directed pwards and backwards, and is covered by peritoneum; its posterior part separated from the rectum by the rectovesical excavation, while its anterior art is in contact with the coils of the small intestine. The antero-inferior rface is devoid of peritoneum, and rests against the pubic bones and the osterior surface of the anterior abdominal wall. The lower parts of the lateral rfaces are destitute of peritoneum, and are in contact with the lateral walls the pelvis. The line of peritoneal reflection from the lateral surfaces is raised the level of the obliterated hypogastric arteries. The fundus undergoes little teration in position, being only slightly lowered. It exhibits, however, a rrow triangular area, which is separated from the rectum merely by the ectovesical fascia. This area is bounded below by the prostate, above by e rectovesical fold of peritoneum, and laterally by the ductus deferentes. e ductus deferentes frequently come in contact with each other above the rostate, and when this occurs the lower part of the triangular area is obliterated. e line of reflection of the peritoneum from the rectum to the bladder dergoes little or no change when the latter is distended; it is situated about

CC-0. In Public Domain. Gurukul Kangri Collection, Haridwar

Digitized by Arya Samaj Foundation Chennai and eGangotri

10 cm. from the anus. The summit of the bladder is directed upwards and forwards above the point of attachment of the middle umbilical ligament, and hence the peritoneum, which follows the ligament, forms a pouch of varying depth between the summit and the anterior abdominal wall.

Fig. 1165.—The fundus of the urinary bladder, &c.

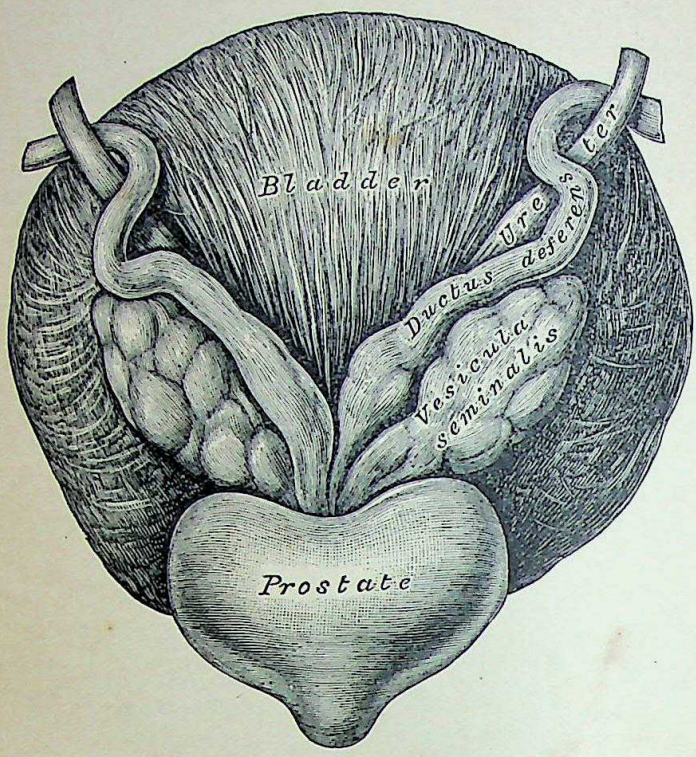

In the new-born child (figs. 1166, 1167) the internal urethral orifice is at the level of the upper border of the symphysis pubis; the bladder therefore lies relatively at a much higher level in the infant than in the adult. Its anterior surface 'is in contact with about the lower two-thirds of that part of the abdominal wall which lies between the symphysis pubis and the umbilicus' (Symington *). Its fundus is clothed with peritoneum as far as the level of the internal orifice of the urethra. Although the bladder of the infant is usually described as an abdominal organ, Symington has pointed out that only about one-half of it lies above the plane of the superior aperture of the pelvis. Disse maintains that the internal urethral orifice sinks rapidly during the first three years of life, and then more slowly until the ninth year, after which it remains stationary until puberty, when it again slowly descends and reaches its adult position.

Fig. 1166.—A sagittal section through the pelvis of a new-born male child.

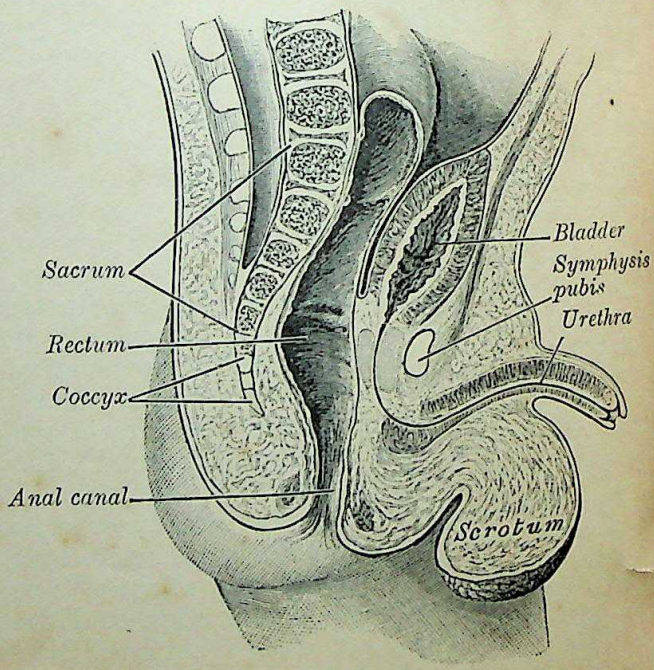

In the female, the bladder is in relation behind with the uterus and the upper part of the vagina (fig. 1168). It is separated from the anterior surface of the body of the uterus by the vesico-uterine excavation, but below the level of this excavation it is connected to the front of the cervix uteri and the upper part of the anterior wall of the vagina by areolar tissue. When the bladder is empty the uterus rests upon its superior surface.

Ligaments.—Each side of the bladder is connected to the tendinous arch or white line of the pelvic fascia (p. 484) by what is known as the vesical layer of the pelvic fascia or *lateral true ligament* of the bladder. Anteriorly the same

CC-0. In Public Domain. Gurukul Kangri Collection, Haridwar

* *The Anatomy of the Child.*

Digitized by Arya Samaj Foundation Chennai and eGangotri

fascia forms two thickened bands, one on either side of the middle line, which pass from the back of the pubic bones to the prostate gland and the front of the bladder; these bands are named the *puboprostatic ligaments*, or *anterior true ligaments* of the bladder. The vertex of the bladder is joined to the umbilicus by the remains of the urachus which forms the *middle umbilical ligament*, a fibromuscular cord, broad at its attachment to the bladder but narrowing as it ascends.

FIG. 1167.—A sagittal section through the pelvis of a new-born female child. Some coils of the small intestine separated the uterus from the bladder.

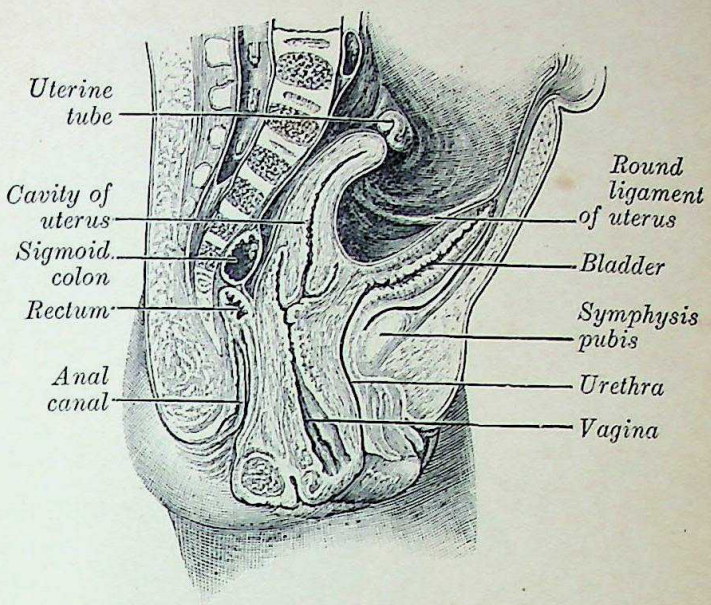

From the superior surface of the bladder the peritoneum is carried off in a series of folds which are sometimes termed the false ligaments of the bladder. Anteriorly there are three folds: the *middle umbilical fold* on the middle umbilical ligament, and two *lateral umbilical folds* on the obliterated hypogastric arteries. The reflections of the peritoneum from the bladder to the side walls of the

FIG. 1168.—A median sagittal section through the female pelvis.

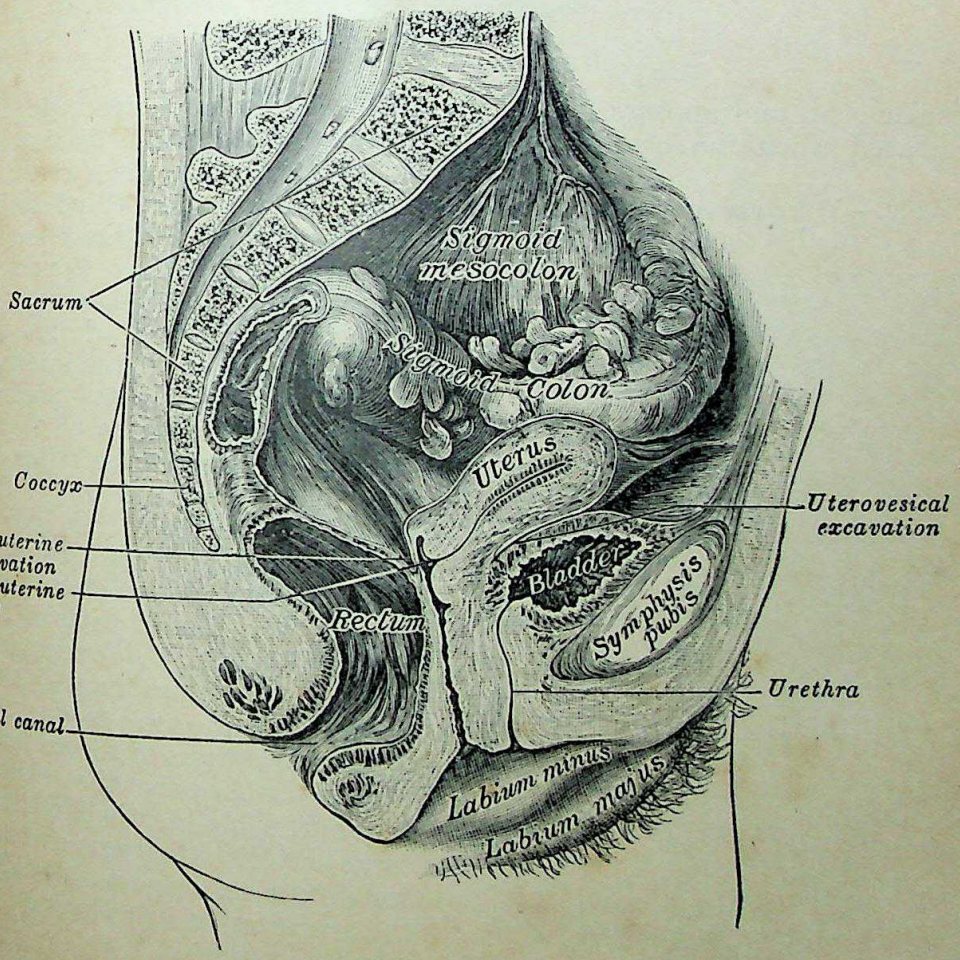

pelvis form the lateral false ligaments, while the rectovesical or sacrogenital folds (p. 1138) constitute the posterior false ligaments.

CC-0. In Public Domain. Gurukul Kangri Collection, Haridwar

Digitized by Arya Samaj Foundation Chennai and eGangotri

The interior of the bladder (fig. 1169).—The mucous membrane which lines the bladder is, over the greater part of the viscus, loosely attached to the

Fig. 1169.—The interior of the bladder.

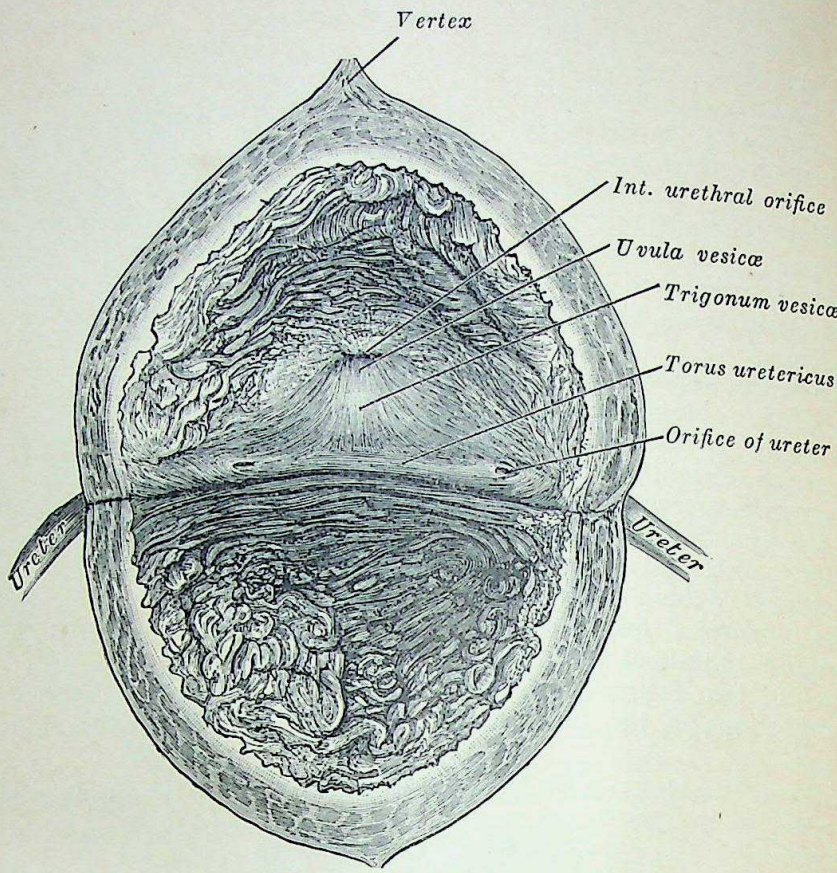

muscular coat, and appears folded when the bladder is contracted: the folds are effaced when the bladder is distended. Over a small triangular area, termed the *trigonum vesicæ*, immediately above and behind the internal orifice of the urethra, the mucous membrane is firmly bound to the muscular coat, and is always smooth. The anterior angle of the trigonum vesicæ is formed by the internal orifice of the urethra: its posterolateral angles by the orifices of the ureters. Stretching between the latter openings is a slightly curved ridge, the *torus uretericus*, forming the base of the trigone and produced by an underlying bundle of non-striped muscular fibres. The lateral parts of this ridge extend beyond the openings of the ureters; they are named the *plicæ uretericæ*, and are produced by the terminal portions of the ureters as they traverse obliquely the bladder-wall. When the bladder is illuminated the torus uretericus appears as a pale band, and forms an important guide during the operation of introducing a catheter into the ureter.

Fig. 1170.—A vertical section through the wall of the bladder.

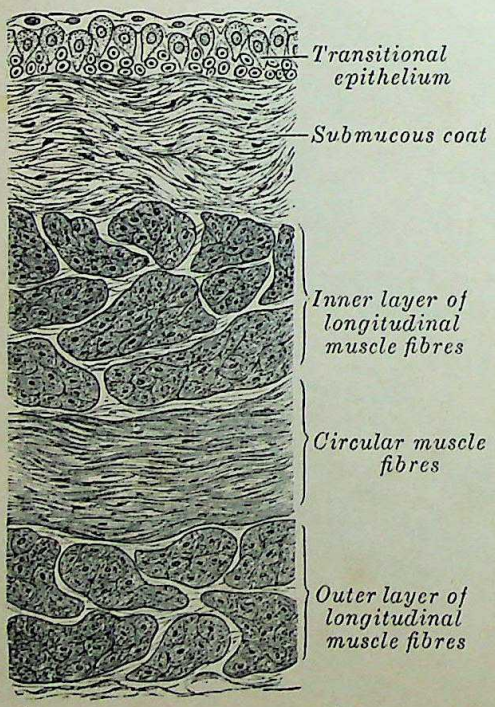

The *orifices of the ureters* are placed at the posterolateral angles of the trigonum vesicæ, and are usually slit-like in form. In the contracted bladder they are about 2·5 cm. apart and about the

CC-0. In Public Domain. Gurukul Kangri Collection, Haridwar

Digitized by Arya Samaj Foundation Chennai and eGangotri

same distance from the internal urethral orifice; in the distended bladder these measurements may be increased to about 5 cm.

The *internal urethral orifice* is placed at the apex of the trigonum vesicæ, in the most dependent part of the bladder, and is usually somewhat crescentic in form; the mucous membrane immediately behind it exhibits a slight elevation, the *uvula vesicæ*, caused by the middle lobe of the prostate.

Structure (fig. 1170).—The bladder is composed of four coats: serous, muscular, submucous, and mucous.

The *serous coat* is a partial one, and is derived from the peritoneum. It invests the superior surface and the upper parts of the lateral surfaces, and is reflected from these on to the abdominal and pelvic walls.

The *muscular coat* consists of three layers of unstriped muscular fibres: an external and an internal of longitudinal fibres, and a middle of circular fibres.

The fibres of the *external longitudinal layer* arise from the posterior surface of the body of the os pubis in both sexes (*Musculi pubovesicales*), and in the male from the adjacent part of the prostate and its capsule. They pass, in a more or less longitudinal manner, up the inferior surface of the bladder, over its vertex, and then descend along its fundus to become attached to the prostate in the male, and to the front of the vagina in the female. Some of the longitudinal fibres are carried on to the front of the rectum, and are named the *Musculus rectovesicalis*. At the sides of the bladder the fibres are arranged obliquely and intersect one another.

The fibres of the *middle circular layer* are very thinly and irregularly scattered on the body of the organ, and, although to some extent placed transverse to the long axis of the bladder, are for the most part arranged obliquely. Towards the lower part of the bladder, round the internal urethral orifice, they are disposed in a thick circular layer, forming the *Sphincter vesicæ*, which is continuous with the muscular fibres of the prostate.

The *internal longitudinal layer* is thin, and its fasciculi have a reticular arrangement, but with a tendency to assume for the most part a longitudinal direction.

Two bands of oblique fibres, originating behind the orifices of the ureters, converge to the back part of the prostate, and are inserted by means of a fibrous process into the middle lobe of that organ. They are the *muscles of the ureters*, described by Sir C. Bell, who supposed that during the contraction of the bladder they serve to retain the oblique direction of the ureters, and so prevent the reflux of the urine into them.

The *submucous coat* consists of a layer of areolar tissue, connecting together the muscular and mucous coats, and intimately united with the latter.

The *mucous coat* is thin, smooth, and of a pale rose colour. It is continuous above with that of the ureters, and below with that of the urethra; the epithelium covering it is of the transitional variety. The loose texture of the submucous layer allows the mucous coat to be thrown into folds or *rugæ* when the bladder is empty. Over the trigonum vesicæ the mucous membrane is closely attached to the muscular coat, and is not thrown into folds, but is smooth and flat. There are no true glands in the mucous membrane of the bladder, though certain mucous follicles which exist, especially near the neck of the bladder, have been regarded as such.

Vessels and Nerves.—The principal *arteries* of supply to the bladder are the superior, middle, and inferior vesical, derived from the anterior trunk of the hypogastric artery. The obturator and inferior glutæal arteries also send small branches to it, and in the female additional branches are derived from the uterine and vaginal arteries.

The *veins* form a complicated plexus on the inferior surface and fundus near the prostate, and end in the hypogastric veins.

The *lymphatics* are described on p. 772.

The *nerves* of the bladder are (1) fine medullated fibres from the second, third, and fourth sacral nerves, and (2) non-medullated fibres from the hypogastric plexus. They are connected with ganglia in the outer and submucous coats, and are finally distributed, all as non-medullated fibres, to the muscular layer and epithelial lining of the viscus.

Applied Anatomy.—A defect of development, in which the bladder is implicated, is known under the name of *extroversion of the bladder*. In this condition the lower part of the abdominal wall as high as the umbilicus, and the anterior wall of the bladder are wanting, so that the posterior wall of the bladder presents on the abdominal surface, and is pushed forwards by the pressure of the viscera within the abdomen, forming a red vascular tumour on which the openings of the ureters are visible. The penis, except the glans, is rudimentary and is cleft on its dorsal surface, exposing the floor of the urethra, a condition known as *epispadias*. The pelvic bones are also arrested in development (p. 317).

When the bladder is distended, it may be ruptured by violence applied to the abdominal wall, without any injury to the bony pelvis, or it may be torn in cases of fracture of the pelvis. The rupture may be either intraperitoneal or extraperitoneal: that is, may implicate the superior surface of the bladder in the former case, or one of the lower surfaces in the latter. Until recently intraperitoneal rupture was uniformly fatal, but now abdominal section and suturing the rent with Lembert's suture are resorted to,

CC-0. In Public Domain. Gurukul Kangri Collection, Haridwar

Digitized by Arya Samaj Foundation Chennai and eGangotri

with a very considerable amount of success. The sutures are inserted only through the peritoneal and muscular coats in such a way as to bring the serous surfaces at the margins of the wound into apposition.

The muscular coat of the bladder undergoes hypertrophy in cases in which there is any obstruction to the flow of urine. Under these circumstances the bundles of which the muscular coat consists become much increased in size, and, interlacing in all directions, give rise to what is known as the *fasciculated bladder*. Between these muscular bundles the mucous membrane may bulge out, forming sacculi, constituting the *sacculated bladder*, and in these little pouches phosphatic concretions may collect, forming *encysted calculi*.

Various forms of tumour have been found springing from the wall of the bladder. The commonest innocent tumour is the villous papilloma. Of the malignant tumours, epithelioma is the most common. In doubtful cases the cystoscope proves a valuable aid in diagnosis. This instrument consists of a tube in which is fixed a small electric light, the wires of which run through the shaft of the instrument. Upon introducing this down the urethra, the bladder can be examined with the eye, and a villous growth or other tumour, a calculus, or an ulcer can be detected; or the orifices of the ureters can be examined, and renal hæmaturia diagnosed, and it can be definitely settled from which kidney the blood comes. Again, the presence of a minute tuberculous ulceration near the mouth of the ureter on the affected side may establish the diagnosis, not only of tuberculous kidney, but also of the side in which the disease is located. The cystoscope can be used to catheterise the ureter, for the purpose of obtaining a specimen of urine from either kidney, or to ascertain the condition of both kidneys where it is proposed to remove one. Ureteric bougies opaque to *x*-rays can be passed and photographed. The pelvis of the kidney can be distended with 25 per cent. sodium bromide through the ureter and its shape photographed.

Puncture of the bladder may be performed either above the symphysis pubis or through the rectum, in both cases without wounding the peritoneum. The former plan is to be preferred, since in puncture through the rectum a permanent fistula may be left from an abscess forming between the rectum and the bladder; or pelvic cellulitis may be set up; moreover, it is exceedingly inconvenient to keep a canula in the rectum. In some cases in performing this operation the rectovesical excavation of the peritoneum has been wounded, inducing fatal peritonitis. Puncture through the rectum, therefore, has been almost completely abandoned in favour of the suprapubic route.

Access to the bladder, for the purpose of removing calculi or an enlarged prostate, is almost always effected by the suprapubic route, the old perineal operation being rarely resorted to. In the female, owing to the shortness of the urethra and its ready dilatability, calculi and foreign bodies and new growths, when of small size, may be removed by the urethral route. Over-dilatation of the female urethra may cause incontinence of urine.

Suprapubic cystotomy is performed by first injecting ten or twelve ounces of some weak antiseptic fluid into the bladder. Then, with or without distending the rectum, a vertical median incision, from 7 to 10 cm. in length, is made in the hypogastric region immediately above the symphysis, and extended between the Pyramidales and Recti until the transversalis fascia is reached. This is divided and some fatty tissue exposed (space of Retzius). Upon separating this, the inferior surface of the bladder will be exposed and will be recognised by its muscular fibres. A needle should be passed through its coat on either side of the spot selected for the opening, and two long pieces of silk inserted. The bladder is incised between these stays, which are held by an assistant and form a useful guide to the opening in the bladder when the fluid has escaped.

It is important that the bladder should be emptied by catheter as a routine measure in women, prior to operations on the lower part of the abdomen or pelvis. Neglect of this precaution has, not uncommonly, led to that viscus being opened by accident. Women especially are apt to acquire an atonic distension of the bladder, and the fact that some quantity of urine has been passed immediately before the operation is no guarantee that the viscus is not distended. If the accident should occur, the bladder wall must be carefully sutured before the peritoneum is opened.

The Male Urethra (fig. 1171)

The male urethra, from 18 cm. to 20 cm. long, extends from the internal urethral orifice in the urinary bladder to the external urethral orifice at the end of the penis. It is divided into three portions, *prostatic, membranous*, and *cavernous*, and presents a double curve in the ordinary relaxed state of the penis (fig. 1164). Except during the passage of fluid along it, the urethral canal is a mere slit or cleft; in the prostatic portion the slit is transversely arched; in the membranous portion, irregular or stellate; in the cavernous portion, transverse; while at the external orifice it is vertical.

The prostatic portion, the widest and most dilatable part of the urethra, is about 3 cm. long, and runs almost vertically through the prostate from its base to its apex; it lies nearer the anterior than the posterior surface of the prostate.

CC-0. In Public Domain. Gurukul Kangri Collection, Haridwar

Digitized by Arya Samaj Foundation Chennai and eGangotri

It is wider in the middle than at either end, and narrowest below, where it joins the membranous portion; in transverse section it is horseshoe-shaped with the convexity directed forwards.

Upon the posterior wall or floor is a narrow longitudinal ridge, the *urethral crest* (verumontanum) formed by an elevation of the mucous membrane and its subjacent tissue. It is about 15 mm. long, and about 3 mm. high. On either side of the crest is a shallow depression, the *prostatic sinus*, the floor of which is perforated by the *orifices of the prostatic ducts* from the lateral lobes of the prostate; the ducts of the middle lobe open proximal to the crest. At the fore part of the urethral crest is an elevation, the *colliculus seminalis*, on which are the orifice of the prostatic utricle and the openings of the ejaculatory ducts. The *prostatic utricle* (uterus masculinus) is a cul-de-sac about 6 mm. long, which runs upwards and backwards in the substance of the prostate behind the middle lobe. Its walls are composed of fibrous tissue, muscular fibres, and mucous membrane; and numerous small glands open into the lumen of the tube. It is developed from the united lower ends of the Müllerian ducts, and is therefore homologous with the uterus and vagina of the female. The ejaculatory ducts are described on p. 1218.

FIG. 1171.—The male urethra laid open on its anterior (upper) surface.

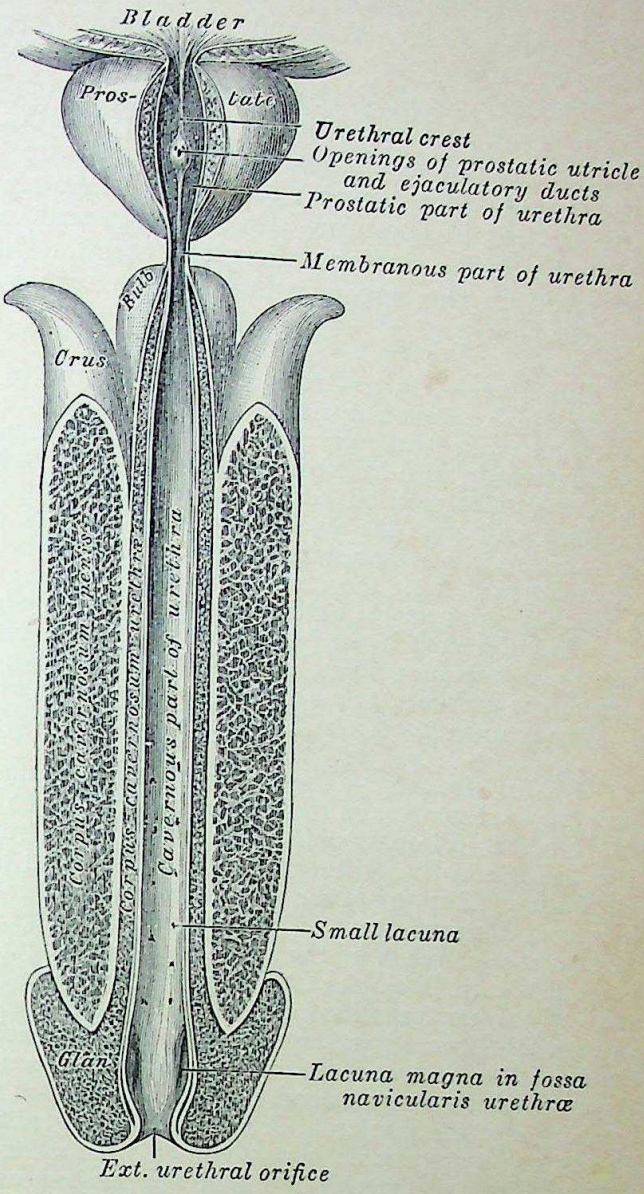

The **membranous portion** is the shortest, least dilatable, and, with the exception of the external orifice, the narrowest part of the urethra. It runs downwards and forwards, with a slight anterior concavity, from the prostate to the bulb of the urethra, perforating the urogenital diaphragm about 2·5 cm. below and behind the pubic symphysis. The hinder part of the urethral bulb lies in apposition with the inferior fascia of the urogenital diaphragm, but its upper portion diverges somewhat from this fascia; the anterior wall of the membranous urethra is thus prolonged for a short distance in front of the urogenital diaphragm, and measures about 2 cm. in length, while the posterior wall which is between the two fasciæ of the diaphragm is only 1·25 cm. long.

The membranous portion of the urethra is surrounded by the fibres of the Sphincter urethræ membranaceæ. In front of it the deep dorsal vein of the penis enters the pelvis between the transverse ligament of the pelvis and the arcuate pubic ligament; on either side near its termination are the bulbo-urethral glands.

The **cavernous portion** is contained in the corpus cavernosum urethræ. It is about 15 cm. long, and extends from the end of the membranous portion to the external urethral orifice. Commencing below the inferior fascia of the urogenital diaphragm it passes forwards and upwards to the front of the lower part of the symphysis pubis; and then, in the flaccid condition

CC-0. In Public Domain. Gurukul Kangri Collection, Haridwar

Digitized by Arya Samaj Foundation Chennai and eGangotri

of the penis, it bends downwards and forwards. It is narrow, with a uniform diameter of about 6 mm. in the body of the penis; it is dilated behind, within the bulb, and again anteriorly within the glans penis, where it forms the *fossa navicularis urethræ*. The bulbo-urethral glands open into the cavernous portion of the urethra about 2·5 cm. in front of the urogenital diaphragm.

The *external urethral orifice* is the most contracted part of the urethra: it is a vertical slit, about 6 mm. long, bounded on either side by a small labium.

The lining membrane of the urethra except in the most anterior part of the tube, presents the orifices of numerous small mucous glands and follicles situated in the submucous tissue, and named the *urethral glands* (Littré). Besides these there are a number of small pit-like recesses, or *lacunæ*, of varying sizes; the orifices of these are directed forwards, and may intercept the point of a catheter in its passage along the canal. One lacuna, larger than the rest, is situated on the upper surface of the fossa navicularis; it is called the *lacuna magna*.

Structure.—The urethra is composed of mucous membrane, supported by a submucous tissue which connects it with the various structures through which it passes.

The *mucous membrane* of the urethra is continuous internally with that of the bladder, and externally with the skin covering the glans penis; it is prolonged into the ducts of the urethral, bulbo-urethral, and prostatic glands; and into the ductus deferentes and vesiculæ seminales, through the ejaculatory ducts. In the cavernous and membranous portions of the urethra it is arranged in longitudinal folds when the tube is empty. Small papillæ are found upon it, near the external urethral orifice; its epithelial lining is of the columnar variety except near the external urethral orifice, where it is squamous and stratified.

The *submucous tissue* consists of a vascular erectile layer; outside this is a layer of unstriped muscular fibres, arranged in a circular direction, which separates the mucous membrane and submucous tissue from the tissue of the corpus cavernosum urethræ.

The lymphatic vessels of the urethra are described on p. 773.

Applied Anatomy.—The urethra may be ruptured by the patient falling astride of any hard substance and striking his perinæum, so that the urethra is crushed against the pubic arch. Bleeding will at once take place from the urethra, and this, together with the bruising in the perinæum and the history of the accident, will point to the nature of the injury. Rupture of the urethra is due in other cases to the perforation of a periurethral abscess. Extravasation of urine most frequently takes place into the perinæum in front of the inferior fascia of the urogenital diaphragm, i.e., under the fascia of Colles. Both these layers of fascia are attached firmly to the ischiopubic rami. It is clear, therefore, that when extravasation of fluid takes place between them, it cannot pass backwards, because the two layers are continuous with each other around the Transversi perinæi superficiales; it cannot extend laterally, on account of the connexion of these layers with the rami of the os pubis and ischium; it cannot find its way into the pelvis, because the opening into this cavity is closed by the urogenital diaphragm, and, therefore, so long as these two layers remain intact, the only direction in which the fluid can make its way is forwards into the areolar tissue of the scrotum and penis, and thence on to the anterior wall of the abdomen. When the pelvis is crushed the urethra may be ruptured behind the urogenital diaphragm; the extravasation of urine then takes place into the extra-peritoneal tissue of the pelvis.

Gonorrhœa is an acute and very prevalent inflammatory infection of the mucous membrane of the urethra. The causative organisms (gonococci) pass through the mucous membrane into the submucous tissue, and most serious complications and results may follow. In most cases the disease remains limited to the part of the urethra in front of the urogenital diaphragm, but in some (about 10 per cent.) the 'posterior urethra' becomes involved in the process, leading to an inflammation of the openings of the prostatic follicles. Such a condition is apt to continue as a very chronic form of prostatitis, and in many cases the infection will spread along the ductus deferentes, giving rise to epididymitis.

The anatomy of the urethra is of considerable importance in connexion with the passage of instruments into the bladder. Otis was the first to point out that the urethra is capable of great dilatation, so that, excepting through the external urethral orifice, an instrument corresponding to 18 English gauge (29 French) can usually be passed without damage. The external orifice of the urethra is not so dilatable, and therefore may require slitting. A recognition of this dilatability caused Bigelow to modify very considerably the operation for crushing a stone in the bladder. In passing catheters, especially fine ones, the point of the instrument should be kept as far as possible along the upper wall of the canal, as otherwise it is very liable to enter one of the lacunæ.

Stricture of the urethra is a disease of very common occurrence, and is generally situated in the cavernous part of the urethra, just in front of the membranous portion but in a very considerable number of cases in the anteseroal part of the canal. The

CC-0. In Public Domain. Gurukul Kangri Collection, Haridwar

Digitized by Arya Samaj Foundation Chennai and eGangotri

stricture usually results from the contraction of inflammatory products in the submucous tissue, the result, in the vast majority of all cases, of a prolonged gleet following gonorrhœa. Urethral stricture, however, follows rupture of that tube resulting from falls on the perinæum, and in this variety is very dense, and is a most unsatisfactory condition with regard to treatment. Congenital stricture is also occasionally met with, and in such cases multiple strictures may be present throughout the whole length of the cavernous portion.

Congenital defects of the urethra occur occasionally. The one most frequently met with is where there is a cleft on the floor of the urethra owing to an arrest of union in the middle line. This is known as *hypospadias*, and the cleft may vary in extent. The simplest and by far the most common form is where the deficiency is confined to the glans penis. The urethra ends at the point where the extremity of the prepuce joins the body of the penis, in a small valve-like opening. The prepuce is also cleft on its under surface and forms a sort of hood over the glans. There is a depression on the glans in the position of the normal meatus. This condition produces no disability and requires no treatment. In more severe cases the cavernous portion of the urethra is cleft throughout its entire length, and the opening of the urethra is at the point of junction of the penis and scrotum. The under surface of the penis in the middle line presents a furrow lined by a moist mucous membrane, on either side of which is often more or less dense fibrous tissue stretching from the glans to the opening of the urethra, which prevents complete erection taking place. Great discomfort is induced during micturition, and sexual connexion is impossible. The condition may be remedied by a series of plastic operations. The worst form of this condition is where the urethra is deficient as far back as the perinæum, and the scrotum is cleft. The penis is small and bound down between the two halves of the scrotum, so as to resemble a hypertrophied clitoris. The testes are often retained in the abdomen. The condition of parts, therefore, very much resembles the external organs of generation of the female, and many children the victims of this malformation have been brought up as girls. The halves of the scrotum, deficient of testes, resemble the labia, the cleft between them looks like the orifice of the vagina, and the diminutive penis is taken for an enlarged clitoris. There is no remedy for this condition.

A much more uncommon form of malformation is where there is an apparent deficiency of the upper wall of the urethra; this is named *epispadias*. The deficiency may vary in extent; when it is complete the condition is associated with extroversion of the bladder (p. 1207). In less extensive cases, where there is no extroversion, there is an infundibuliform opening into the bladder. The penis is usually dwarfed and turned upwards, so that the glans lies over the opening.

The Female Urethra (fig. 1168)

The female urethra is about 4 cm. long and 6 mm. in diameter. It begins at the internal urethral orifice of the bladder, and runs downwards and forwards behind the symphysis pubis, imbedded in the anterior wall of the vagina. It perforates the urogenital diaphragm and ends at the external urethral orifice, an anteroposterior slit with rather prominent margins, which is situated directly in front of the opening of the vagina and about 2·5 cm. behind the glans clitoridis. Except during the passage of fluid the anterior and posterior walls of the urethra are in apposition, and the lining membrane is thrown into longitudinal folds, one of which, placed on the posterior wall of the canal, is termed the *urethral crest*. Many small *urethral glands* and minute pit-like recesses or *lacunæ* open into the urethra. Near the lower end of the urethra are some small glands which are considered to be the homologues of the prostatic glands of the male; on either side they are grouped together to open into a duct, named the *ductus paraurethralis* (Skene's duct), which runs down in the submucous tissue, and ends in a small aperture on the lateral margin of the external urethral orifice.

Structure.—The urethra consists of three coats: muscular, erectile, and mucous. The *muscular coat* is continuous with that of the bladder; it extends the whole length of the tube, and consists of circular fibres. In addition to this, between the superior and inferior fasciæ of the urogenital diaphragm, the female urethra is surrounded by the sphincter urethræ membranaceæ, as in the male.

A thin layer of *spongy erectile tissue*, containing a plexus of large veins, intermixed with bundles of unstriped muscular fibres, lies immediately beneath the mucous coat.

The *mucous coat* is pale; it is continuous externally with that of the vulva, and internally with that of the bladder. It is lined by stratified squamous epithelium, which becomes transitional near the bladder. Its external orifice is surrounded by a few mucous follicles.

CC-0. In Public Domain. Gurukul Kangri Collection, Haridwar

Digitized by Arya Samaj Foundation Chennai and eGangotri

THE MALE GENITAL ORGANS

The male genital organs include the *testes* and *epididymes*, the *ductus deferentes*, the *vesiculæ seminales*, the *ejaculatory ducts*, and the *penis*, together with the following accessory structures, viz. the *prostate* and the *bulbo-urethral glands*.

The Testes

The **testes**, the reproductive glands in the male, are suspended in the scrotum by the spermatic cords, the left testis hanging somewhat lower than its fellow. The average dimensions of the testis are from 4 cm. to 5 cm. in length, 2·5 cm. in breadth, and 3 cm. in the anteroposterior diameter; its weight varies from 10·5 gm. to 14 gm. Each testis is of an oval form (fig. 1172), compressed laterally, and has an oblique position in the scrotum; the upper extremity is directed forwards and a little lateralwards; the lower, backwards and a little medialwards. The anterior border is convex, and looks forwards and downwards; the posterior border, nearly straight, looks backwards and upwards; to it the spermatic cord is attached.

Fig. 1172.—The right testis. Exposed by laying open the tunica vaginalis.

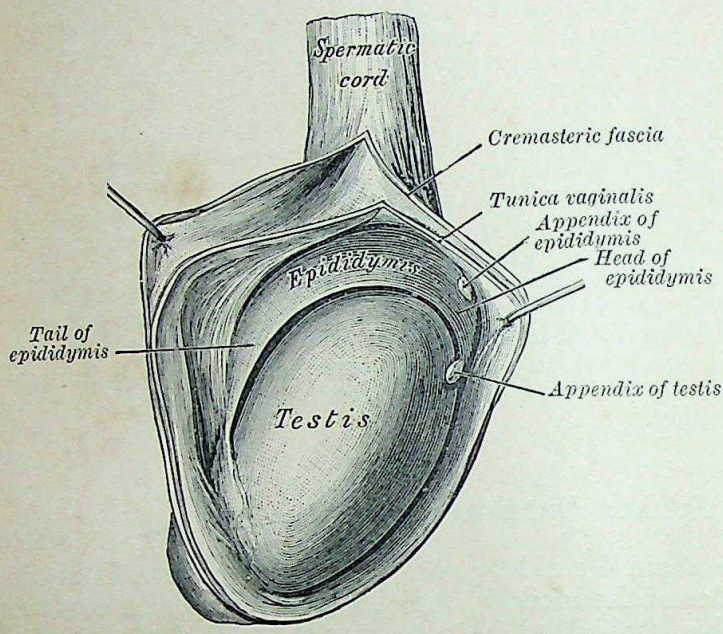

The anterior border, the medial and lateral surfaces, and the extremities of the testis, are convex, free, smooth, and invested by the visceral lamina of the tunica vaginalis (p. 1213). The posterior border receives only a partial investment from that membrane. Lying upon the lateral part of the posterior border is the *epididymis*.

The **epididymis** consists essentially of a tortuous canal which forms the first part of the efferent duct of the testis. This canal is folded on itself and tightly packed into the form of a long, narrow, flattened body attached to the lateral part of the posterior border of the testis. It consists of a central portion, or *body*; an upper enlarged end, the *head* (globus major); and a lower pointed end, the *tail* (globus minor). The head is intimately connected with the upper end of the testis by means of the efferent ductules of the gland; the tail is connected with the lower end by cellular tissue and a reflection of the tunica vaginalis. The lateral surfaces of the head and tail of the epididymis are free and covered by the tunica vaginalis; the body is also invested by it, except at its posterior border; whilst between the body of the epididymis and the lateral surface of the testis is a pouch, named the *sinus of the epididymis* (digital fossa).

The *appendages of the testis and epididymis*.—On the upper extremity of the testis, just beneath the head of the epididymis, is a minute oval, sessile body, the *appendix of the testis* (hydatid of Morgagni); it is the remnant of the upper end of the Müllerian duct. On the head of the epididymis is a small stalked appendage (sometimes duplicated); it is named the *appendix of the epididymis* (pedunculated hydatid), and is usually considered to be a detached efferent duct.

The testis is invested by three tunics: the tunica vaginalis, tunica albuginea, and tunica vasculosa.

CC-0. In Public Domain. Gurukul Kangri Collection, Haridwar

Digitized by Arya Samaj Foundation Chennai and eGangotri

The **tunica vaginalis** is the lower portion of the saccus vaginalis of the peritoneum which, in the fœtus, preceded the descent of the testis from the abdomen into the scrotum. After the testis has reached the scrotum the upper part of the saccus vaginalis, viz. from the abdominal inguinal ring to within a short distance of the testis, contracts and undergoes obliteration. The lower portion remains as a shut sac, which invests the surface of the testis, and is reflected on to the internal surface of the scrotum; hence it may be described as consisting of a visceral and a parietal lamina.

The *visceral lamina* covers the greater part of the testis and epididymis. It lines the sinus of the epididymis and passes as two folds, one from the head and the other from the tail of the epididymis, to the testis; these folds are named the *superior* and *inferior ligaments* of the epididymis. From the posterior border of the testis it is reflected on to the internal surface of the scrotum.

The *parietal lamina* is more extensive than the visceral; it reaches below the testis and extends upwards for some distance in front and on the medial side of the spermatic cord. The inner surface of the tunica vaginalis is smooth, and covered by a layer of endothelial cells. The potential space between the visceral and parietal laminæ constitutes the cavity of the tunica vaginalis.

The obliterated portion of the saccus vaginalis may frequently be seen as a fibrous thread in the areolar tissue in front of the spermatic cord; sometimes this thread may be traced from the upper end of the inguinal canal, where it is connected with the peritoneum, down to the tunica vaginalis; sometimes it is lost on the spermatic cord. In some instances the upper part of the saccus vaginalis is not obliterated, and the peritoneal cavity then communicates with the tunica vaginalis; in others the upper part of the saccus vaginalis may persist as a minute canal leading from the peritoneal cavity to that of the tunica vaginalis.

FIG. 1173.—A vertical section through the testis, to show the arrangement of the ducts. Diagrammatic.

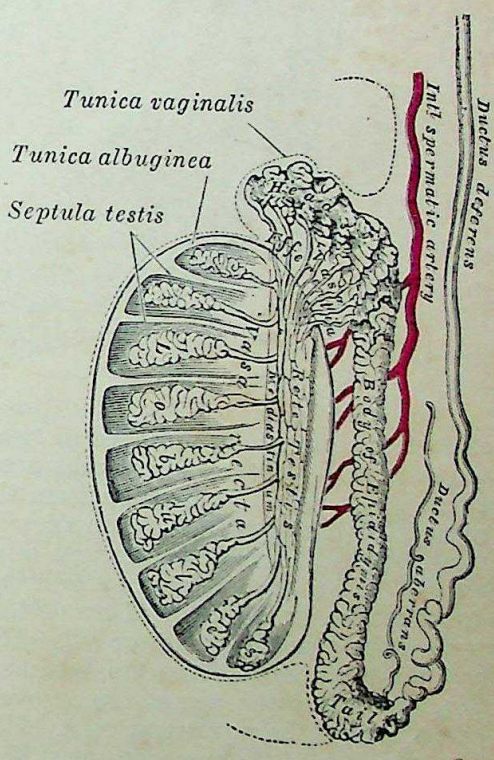

The **tunica albuginea** forms a fibrous covering for the testis. It is a dense membrane, of a bluish-white colour, composed of interlacing bundles of white fibrous tissue. It is covered by the visceral lamina of the tunica vaginalis, except at the head and tail of the epididymis, and along the posterior border of the testis, where the testicular vessels and nerves enter the gland. It is applied to the tunica vasculosa, and, at the posterior border of the testis, is projected into the interior of the gland, forming an incomplete vertical septum, called the *mediastinum testis* (corpus Highmori).

The *mediastinum testis* extends from the upper to near the lower end of the gland, and is wider above than below. From its front and sides are given off numerous imperfect septa (*septula testis*) which radiate towards the surface of the testis, and are attached to the deep aspect of the tunica albuginea. They incompletely divide the testis into a number of cone-shaped lobules (*lobuli testis*). The bases of the lobules are at the surface of the testis, and their apices converge to the mediastinum. The mediastinum supports the vessels and ducts of the testis in their passage to and from the substance of the gland.

The **tunica vasculosa** is the vascular layer of the testis, consisting of a plexus of blood-vessels held together by delicate areolar tissue. It lines the tunica albuginea and clothes the septula testis, and therefore forms an investment to all the lobules of the testis.

Structure.—The glandular structure of the testis consists of the lobuli testis (fig. 1173). Their number, in a single testis, is estimated by Berres at 250, and by Krause at 400. They differ in size according to their position, those in the middle of the testis being larger

CC-0. In Public Domain. Gurukul Kangri Collection, Haridwar

Digitized by Arya Samaj Foundation Chennai and eGangotri

and longer. Each lobule consists of from one to three, or more, minute convoluted tubes, the *tubuli seminiferi contorti*. When the tubules have been unravelled by careful dissection under water, they are seen to commence either by free cæcal ends or by anastomotic loops. They are supported by loose connective tissue which contains here and there groups of *interstitial cells* (fig. 1174) containing yellow pigment granules. The total number of tubules is estimated by Lauth at 840, and the average length of each is 70 cm. to 80 cm. Their diameter varies from 0·12 mm. to 0·3 mm. The tubules are pale in colour in early life, but in old age they acquire a deep yellow tinge from containing much fatty matter. Each tubule (fig. 1174) consists of a basement-layer formed of laminated connective tissue containing numerous elastic fibres, with flattened cells between the layers, and covered externally by a layer of flattened epithelioid cells. Within the basement-membrane are epithelial cells arranged in three irregular layers. 1. An outer layer of cubical cells, with small nuclei; some of these enlarge to become *spermatogonia*. The nuclei of some of the spermatogonia may be seen to be in process of indirect division (p. 2), and in consequence of this, daughter cells are formed which constitute the second zone. 2. Larger polyhedral

FIG. 1174.—A transverse section through a part of a human testis. Stained with hæmatoxylin and eosin. ×350.

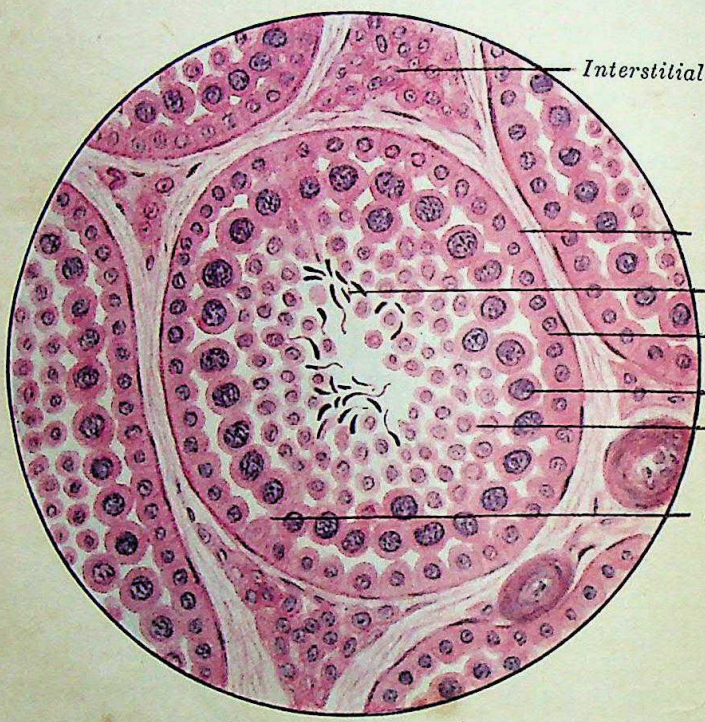

cells, with clear nuclei, arranged in two or three layers; these are the *intermediate cells* or *spermatocytes*. Most of these cells are in a condition of indirect division, and the cells which result from this division form those of the next layer. 3. The third layer of cells consists of the *spermatids*, each of which becomes a *spermatozoon*. The spermatids are small polyhedral cells, the nucleus of each containing half the usual number of chromosomes. The changes which occur during the conversion of the spermatids into spermatozoa are described and illustrated on p. 45. In addition to these three layers of cells others, termed the *supporting cells*, or *cells of Sertoli*, are seen. They are elongated and columnar, and project inwards from the basement-membrane towards the lumen of the tube. As development of the spermatozoa proceeds, the latter group themselves upon the inner extremities of the supporting cells. Ultimately the spermatozoa are liberated and set free. The structure of the spermatozoa is described on pp. 43, 44.

In the apices of the lobules, the tubules become less convoluted, assume a nearly straight course, and unite at acute angles to form from twenty to thirty larger straight ducts, of about 0·5 mm. in diameter, called tubuli seminiferi recti (fig. 1173).

The *tubuli seminiferi recti* enter the fibrous tissue of the mediastinum, and pass upwards and backwards, forming, in their ascent, a close network of anastomosing tubes which are merely channels in the fibrous stroma, lined by flattened epithelium, and having no proper walls; this network is named the *rete testis*. At the upper end of the mediastinum, the vessels of the rete testis terminate in from twelve to twenty ducts, the *ductuli efferentes testis*; they perforate the tunica albuginea, and carry the seminal fluid from the testis to the epididymis. Their course is at first straight; they then become enlarged and exceedingly convoluted, and form a series of conical masses, the *lobules of the epididymis* (coni vasculosi), which together constitute the head of the epididymis. Each lobule

CC-0. In Public Domain. Gurukul Kangri Collection, Haridwar

Digitized by Arya Samaj Foundation Chennai and eGangotri

consists of a single convoluted duct, from 15 cm. to 20 cm. in length. Opposite the bases of the lobules the canals open into a single duct, which constitutes, by its complex convolutions, the body and tail of the *epididymis*. When the convolutions are unravelled, this tube measures upwards of 6 metres in length; it increases in diameter and thickness as it approaches the tail of the epididymis where it becomes the ductus deferens. The convolutions are held together by fine areolar tissue, and by bands of fibrous tissue.

The ductuli efferentes and the tube of the epididymis have walls of considerable thickness, on account of the presence in them of muscular tissue which is principally arranged in a circular manner. These tubes are lined by columnar ciliated epithelium (fig. 1175).

Vessels and Nerves.—The *testicular artery* is a branch of the abdominal aorta. It divides into several branches, some of which ramify in the tunica vasculosa, while others traverse the mediastinum testis and, after dividing on the septula testis, supply the tubuli seminiferi. Twigs are also given to the epididymis, and anastomose with the artery of the ductus deferens. The *veins* emerge from the back of the testis and, after receiving tributaries from the epididymis, unite to form the pampiniform plexus (p. 741).

FIG. 1175.—A transverse section through the tube of the human epididymis. Stained with hæmatoxylin and eosin. ×350.

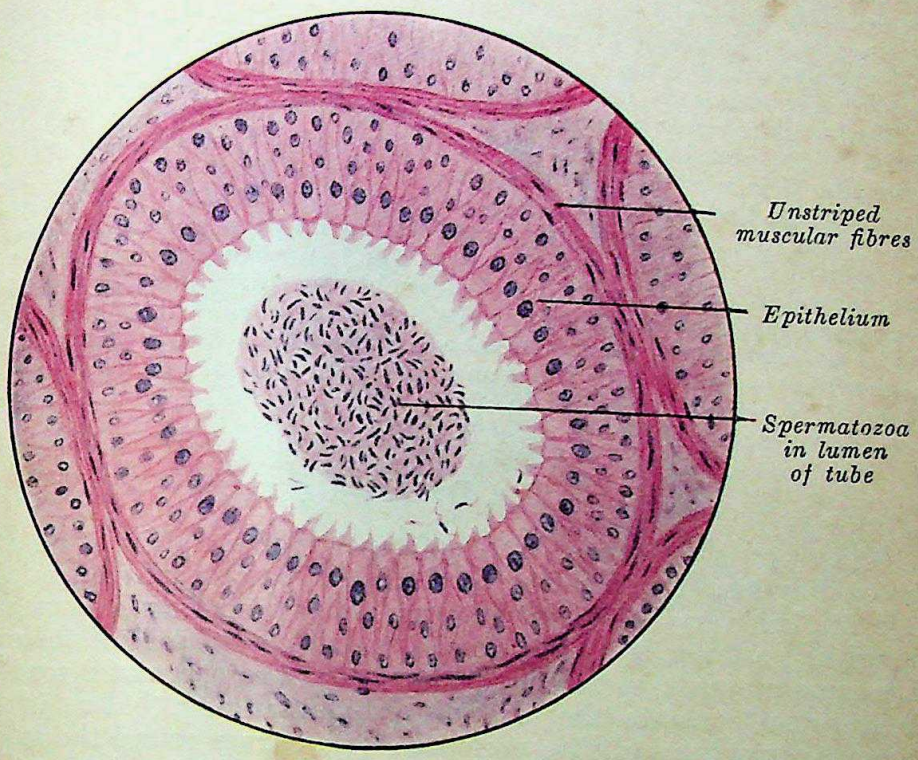

The *lymphatic vessels* of the testis end in the lateral and pre-aortic lymph-glands (p. 773). The *nerves* accompany the testicular vessels, and are derived from the renal and aortic plexuses, and from the tenth thoracic nerve.

Applied Anatomy.—The descent of the testis may be arrested. It may be retained in the abdomen; or it may be arrested at the abdominal inguinal ring, or in the inguinal canal; or it may just pass out of the subcutaneous inguinal ring without finding its way to the bottom of the scrotum. When retained in the abdomen it gives rise to no signs or symptoms, other than the absence of the testis from the scrotum. When it is retained in the inguinal canal it is subjected to pressure and may become inflamed and painful. The retained testis is probably sexually useless; so that a man in whom both testes are retained (*anorchism*) is sterile, though he may not be impotent. The absence of one testis is termed *monorchism*. When a testis is retained in the inguinal canal it is often complicated with a congenital hernia, the saccus vaginalis of the peritoneum not being obliterated. The testis may descend through the inguinal canal, but may miss the scrotum and assume some abnormal position. The most common form is where it comes to rest in the perinæum. This is known as *perinæal ectopia testis*. When the testis occupies an abnormal position it is very common to find concurrently a congenital hernia or a patent saccus vaginalis.

The testis may be inverted within the scrotum so that its posterior or attached border is directed forwards and the tunica vaginalis is situated behind. Should a hydrocele occur, and tapping be resorted to, the trocar may be thrust into the testis, if care be not taken beforehand to ascertain the position of the gland.

A number of instances of torsion of the spermatic cord, resulting in acute strangulation of the testis, have been recorded. In some it has been attributed to a strain or

CC-0. In Public Domain. Gurukul Kangri Collection, Haridwar

Digitized by Arya Samaj Foundation Chennai and eGangotri

twist, and in several patients the condition has been associated with a late descent of the organ. Symptoms of this condition closely simulate those of a strangulated hernia. In consequence of the torsion the circulation is partly arrested and the organ swells and becomes acutely painful, and the condition may be accompanied with shock and vomiting. Gangrene of the testis, however, rarely follows, and the condition if left without operation, ends in atrophy of the organ. Torsion of the body of the testis also sometimes occurs within the tunica vaginalis in those cases in which a persistent mesorchium is present.

Fluid collections of a serous character are frequently found in the scrotum. To these the term *hydrocele* is applied. The most common form is the ordinary *vaginal hydrocele*, in which the fluid is contained in the sac of the tunica vaginalis. In another form, the *congenital hydrocele*, the fluid is in the sac of the tunica vaginalis, but this sac communicates with the general peritoneal cavity owing to the non-obliteration of the upper part of the saccus vaginalis. A third variety, known as an *infantile hydrocele*, occurs in those cases where the saccus vaginalis is obliterated only at or near the abdominal inguinal ring. It resembles the vaginal hydrocele, except as regards its shape, the collection of fluid extending up the cord into the inguinal canal. Fourthly, the saccus vaginalis may be obliterated both at the abdominal inguinal ring and above the epididymis, leaving a central unobliterated portion, which may become distended with fluid, giving rise to a condition known as the *encysted hydrocele of the cord*.

Encysted hydrocele of the epididymis or *spermatocele* is the name given to a cyst found in connexion with the head of the epididymis. Among its contents are found a varying number of spermatozoa, and it is probably a retention cyst of one of the tubules.

The testis requires removal for malignant or tuberculous disease, in cases of large *hernia testis*, and in some instances of incompletely descended or misplaced testis. Castration is in most cases best carried out by the 'high' operation, an incision being made through the skin and fascia in the region of the subcutaneous inguinal ring. The testis, with its deeper coverings, is pushed up into the wound and separated from the scrotal tissues. The cord is then isolated, and an aneurysm needle, armed with a ligature, passed through it, as high as is thought necessary, and the cord tied and divided. In cases of malignant and tuberculous disease, it is desirable to open the inguinal canal and tie the cord as near the abdominal ring as possible. When removing the testis in this manner the tunica vaginalis is not opened and its folds of reflection to the scrotal tissues do not need division. The whole of the tunica vaginalis is thus removed with the cord and its coverings.

The Ductus Deferens

The **ductus deferens** (vas deferens) is the continuation of the canal of the epididymis. Commencing at the lower part of the tail of the epididymis, it is at first very tortuous, but gradually becoming less twisted it ascends along the posterior border of the testis and medial side of the epididymis, and then runs upwards in the posterior part of the spermatic cord, and traverses the inguinal canal to the abdominal inguinal ring. Here it separates from the other structures of the spermatic cord, curves round the lateral side of the inferior epigastric artery, and ascends for about 2·5 cm. in front of the external iliac artery. It is next directed backwards and slightly downwards, and, crossing the external iliac vessels obliquely, enters the pelvic cavity, where it is continued backwards between the peritoneal membrane and the lateral wall of the pelvis, and on the medial side of the obliterated umbilical artery, the obturator nerve and vessels, and the vesical vessels (fig. 1163). It then crosses in front of the ureter (fig. 1175), and, reaching the medial side of this tube, bends at an acute angle, and runs medialwards and slightly forwards between the fundus of the bladder and the upper end of the seminal vesicle. Reaching the medial side of the seminal vesicle, it is directed downwards and medialwards in contact with it, and gradually approaches the opposite ductus. Here it lies between the fundus of the bladder and the rectum, where it is enclosed, together with the seminal vesicle, in a sheath derived from what is known as the recto-vesical portion of the pelvic fascia. Lastly, it passes downwards to the base of the prostate, and is joined at an acute angle by the duct of the seminal vesicle to form the ejaculatory duct, which traverses the prostate behind its middle lobe and opens into the prostatic portion of the urethra, close to the orifice of the prostatic utricle. Owing to the thickness of its wall, the ductus deferens feels hard and cord-like when grasped by the finger and thumb. Its canal in the greater part of its extent is of extremely small calibre, but at the fundus of the bladder it becomes dilated and tortuous, and this portion is termed the *ampulla*; its terminal portion, which joins the duct of the seminal vesicle, is again greatly diminished in calibre.

CC-0. In Public Domain. Gurukul Kangri Collection, Haridwar

Digitized by Arya Samaj Foundation Chennai and eGangotri

Ductuli aberrantes.—A long narrow tube, the *ductulus aberrans inferior* (vas aberrans of Haller), is frequently found connected with the lower part of the canal of the epididymis, or with the commencement of the ductus deferens. Its length, when it is uncoiled, varies from 5 cm. to 35 cm., and it may be dilated towards its blind extremity, or may be of uniform diameter throughout. Its structure is similar to that of the ductus deferens. Occasionally it is found unconnected with the epididymis. A second tube, the *ductulus aberrans superior*, occurs in the head of the epididymis, and is connected with the rete testis.

Paradidymis (organ of Giraldès).—This term is applied to a small collection of convoluted tubules, situated in front of the lower part of the spermatic cord above the head of the epididymis. These tubes are lined with columnar ciliated epithelium, and probably represent the remains of a part of the Wolffian body.

Structure.—The ductus deferens consists of three coats: (1) an external or areolar coat; (2) a muscular coat, which in the greater part of the tube consists of two layers of unstriped muscular fibres: an outer, longitudinal in direction, and an inner, circular; but at the commencement of the ductus there is a third layer, consisting of longitudinal fibres, and placed between the circular stratum and the mucous membrane; (3) an internal, or mucous coat, which is pale, and arranged in longitudinal folds. The mucous coat is lined by columnar epithelium which is non-ciliated throughout the greater part of the tube; a variable portion of the testicular end of the tube is lined by two strata of columnar cells, those of the superficial layer being ciliated.

The Vesiculæ Seminales and Ejaculatory Ducts

The **vesiculæ seminales** (fig. 1176) are two sacculated pouches, placed between the fundus of the bladder and the rectum. Each vesicle is about 5 cm. long, and is somewhat pyramidal in form, the broad end being directed backwards, upwards, and lateralwards. It consists of a tube, coiled upon itself, and giving off several irregular diverticula (fig. 1177); the separate coils, as well as the diverticula, are connected together by fibrous tissue. When uncoiled, the tube is about the diameter of a quill, and varies in length from 10 cm. to 15 cm.; it ends above in a cul-de-sac; its lower extremity becomes constricted into a narrow straight duct, which joins with the corresponding ductus deferens to form the ejaculatory duct. The *anterior surface* is in contact with the fundus of the bladder, extending from near the termination of the ureter to the base of the prostate. The *posterior surface* rests upon the rectum, from which it is separated by the rectovesical fascia. The vesicles diverge from each other above, and are in relation with the ductus deferentes and the terminations of the ureters, and are only covered by peritoneum; each is enveloped in a dense fibromuscular sheath. Along the medial margin of each vesicle runs the ampulla of the ductus deferens.

Fig. 1176.—The fundus of the bladder with the vesiculæ seminales, &c.

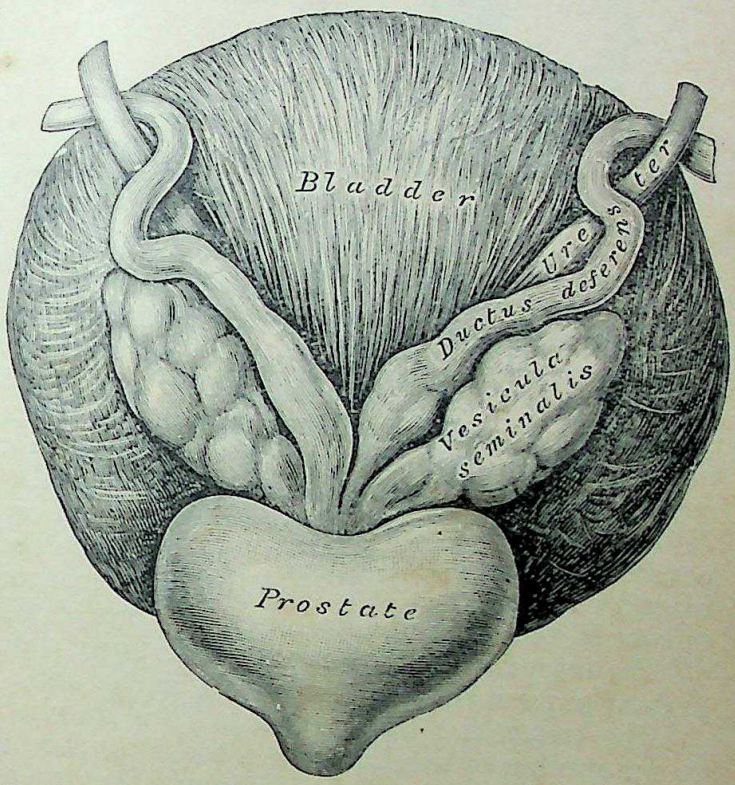

Structure.—The vesiculæ seminales are composed of three coats: an *external or areolar coat*; a *middle or muscular coat*, thinner than that of the ductus deferens and arranged in two layers, an outer longitudinal and an inner circular; an *internal or mucous coat*, which is pale, of a whitish-brown colour, and presents a delicate reticular structure. The epithelium is columnar, and in the diverticula goblet-cells are present, the secretion of which is added to the seminal fluid.

CC-0. In Public Domain. Gurukul Kangri Collection, Haridwar

Digitized by Arya Samaj Foundation Chennai and eGangotri

Vessels and Nerves.—The *arteries* supplying the vesiculæ seminales are derived from the middle and inferior vesical, and the middle hæmorrhoidal arteries. The *veins* and *lymphatics* accompany the arteries. The *nerves* are derived from the pelvic plexuses.

Applied Anatomy.—The vesiculæ seminales are often the seat of an extension of the disease in cases of tuberculosis of the testis, and should always be examined from the rectum, before deciding to perform castration in this affection. They also become affected in chronic posterior urethritis of gonorrhœal origin. An abscess of the vesicula seminalis may rupture into the peritoneal cavity and cause fatal peritonitis.

The **ejaculatory ducts** (fig. 1177) are two in number, one on either side of the middle line. Each is formed by the union of the duct of the vesicula seminalis with the terminal part of the ductus deferens, and is nearly 2 cm. long. They commence at the base of the prostate, run forwards and downwards between the middle and lateral lobes, pass along the sides of the prostatic utricle, and end on the colliculus seminalis in slit-like orifices on, or just within, the margins of the opening of the prostatic utricle (p. 1209). The ducts diminish in size, and also converge, towards their terminations.

FIG. 1177.—The vesiculæ seminales and the ampullæ of the ductus deferentes. Anterior aspect. The anterior walls of the left ampulla, left seminal vesicle, and prostatic urethra have been cut away.

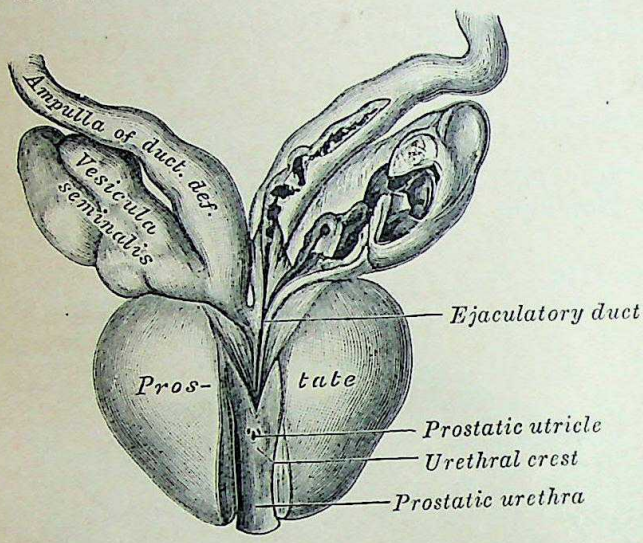

Structure.—The coats of the ejaculatory ducts are extremely thin. They are: an *outer fibrous layer*, which is almost entirely lost after the entrance of the ducts into the prostate; a *layer of muscular fibres*, consisting of a thin outer circular, and an inner longitudinal layer; and *mucous membrane*.

THE SPERMATIC CORD AND ITS COVERINGS

When the testis descends through the abdominal wall into the scrotum, it drags its vessels and nerves and the ductus deferens with it. These structures meet at the abdominal inguinal ring and together form the *spermatic cord* (*funiculus spermaticus*) which suspends the testis in the scrotum, and extends from the abdominal inguinal ring to the posterior border of the testis; the left spermatic cord is a little longer than the right.

The spermatic cord traverses the inguinal canal (p. 481) and in so doing is covered by the different layers which form the abdominal wall. These coverings extend downwards into the wall of the scrotum and are named, from within outwards, the infundibuliform, cremasteric and intercrural fasciæ.

The *infundibuliform fascia* is a thin layer which loosely invests the cord, and is derived from the transversalis fascia (p. 480).

The *cremasteric fascia* consists of a number of muscular fasciculi, united to one another by areolar tissue; the muscular fasciculi constitute the Cremaster and are continuous with the Obliquus internus abdominis (p. 475).

The *intercrural fascia* (external spermatic fascia) is a thin fibrous membrane continuous above with the tendon of the Obliquus externus abdominis, and prolonged downwards from the crura of the subcutaneous inguinal ring (p. 472).

Structure of the spermatic cord.—The spermatic cord is composed of arteries, veins, lymphatics, nerves, and the ductus deferens, connected together by areolar tissue.

The *arteries* of the spermatic cord are: the testicular artery, the external spermatic artery, and the artery of the ductus deferens.

The *testicular artery*, a branch of the abdominal aorta, escapes from the abdominal cavity at the abdominal inguinal ring, and accompanies the other constituents of the spermatic cord along the inguinal canal and through the subcutaneous inguinal ring into

CC-0. In Public Domain. Gurukul Kangri Collection, Haridwar

Digitized by Arya Samaj Foundation Chennai and eGangotri

the scrotum. It then descends to the testis, and, becoming tortuous, divides into several branches, two or three of which accompany the ductus deferens and supply the epididymis, anastomosing with the artery of the ductus deferens; the others supply the substance of the testis.

The *external spermatic artery* (cremasteric artery) is a branch of the inferior epigastric artery. It supplies the coverings of the spermatic cord, and anastomoses with the testicular artery.

The *artery of the ductus deferens*, a branch of the superior vesical artery, is a long slender vessel which accompanies the ductus deferens, ramifying upon its coats, and anastomosing with the testicular artery near the testis.

The *testicular veins* emerge from the back of the testis, and receive tributaries from the epididymis: they unite and form a convoluted plexus, the *plexus pampiniformis*, which constitutes the chief mass of the cord; the vessels composing this plexus are very numerous, and ascend in front of the ductus deferens; below the subcutaneous inguinal ring they unite to form three or four veins, which pass along the inguinal canal, and, entering the abdomen through the abdominal inguinal ring, coalesce to form two veins. These again unite to form a single vein, which opens on the right side into the inferior vena cava, at an acute angle, and on the left side into the left renal vein, at a right angle.

The *lymphatic vessels* of the testis are described on p. 773.

The *nerves* are the spermatic plexus of the sympathetic, joined by filaments from the pelvic plexus which accompany the artery of the ductus deferens.

The Scrotum

The *scrotum* is a cutaneous pouch containing the testes and the lower parts of the spermatic cords, and placed below the pubic symphysis in front of the upper parts of the thighs. It is divided on its surface into a right and

Fig. 1178.—A tranverse section through the left half of the scrotum and the left testis. The sac of the tunica vaginalis is represented in a distended condition. Diagrammatic. (Delépine.)

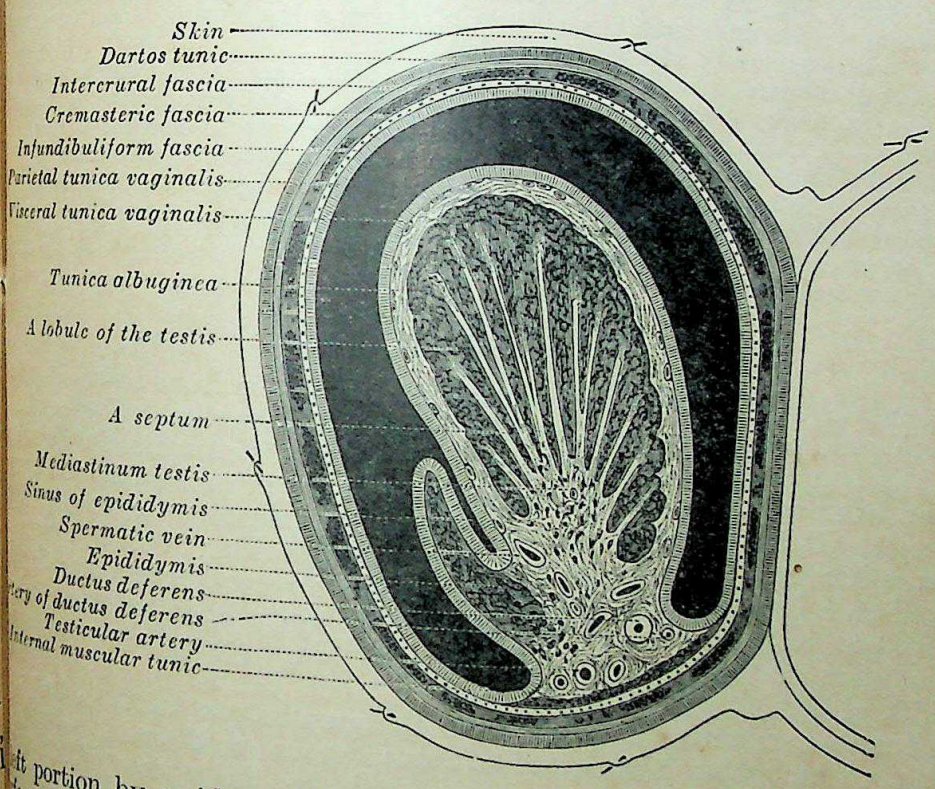

it portion by a ridge, or *raphe*, which is continued forwards to the under face of the penis, and backwards along the middle line of the perinæum the anus; the left portion hangs lower than the right, in correspondence h the greater length of the left spermatic cord. The external appearance ies under different circumstances: thus, under the influence of warmth, in old and debilitated persons, the scrotum is elongated and flaccid; but, r the influence of cold, and in the young and robust, it is short, corrugated, closely applied to the testes. It consists of the skin and the dartos tunic, ther with the intercrural, cremasteric and infundibuliform fasciæ, already

CC-0. In Public Domain. Gurukul Kangri Collection, Haridwar

Digitized by Arya Samaj Foundation Chennai and eGangotri

described in connexion with the spermatic cord. Within the infundibuliform fascia is the parietal lamina of the tunica vaginalis (fig. 1178).

The *skin* is very thin, of a brownish colour, and generally thrown into folds or rugæ. It is beset with thinly scattered, crisp hairs, the roots of which are visible through the skin; it is provided with sebaceous follicles, the secretion of which has a peculiar odour.

The *dartos tunic* is a thin layer of non-striped muscular fibres, continuous, around the base of the scrotum, with the superficial fascia of the groin and of the perinæum. It sends inwards a septum, which connects the raphe to the under surface of the root of the penis, and divides the scrotal pouch into two cavities for the testes. The dartos tunic is closely united to the skin, but is connected with the subjacent parts by delicate areolar tissue, upon which it glides with the greatest facility.

Vessels and Nerves.—The *arteries* supplying the scrotum are: the superficial and deep external pudendal branches of the femoral artery, the posterior scrotal branches of the perinæal artery, and the cremasteric branch from the inferior epigastric artery. The *veins* follow the course of the corresponding arteries. The *lymphatics* end in the inguinal lymph-glands. The *nerves* are the ilio-inguinal and lumbo-inguinal branches of the lumbar plexus, the two posterior scrotal branches of the perinæal nerve, and the pudendal branch of the posterior femoral cutaneous nerve.

Applied Anatomy.—The scrotum forms an admirable covering for the protection of the testes. These bodies, lying suspended and loose in the cavity of the scrotum and surrounded by serous membrane, are capable of great mobility, and can therefore easily slip about within the scrotum, and thus avoid injuries from blows or squeezes. The skin of the scrotum is very elastic and capable of great distension, and on account of the looseness and amount of subcutaneous tissue, the scrotum becomes greatly enlarged in cases of œdema, to which this part is especially liable as a result of its dependent position. The scrotum is occasionally the seat of epithelioma; this is no doubt due to the rugæ on its surface, which favour the lodgment of dirt, and this, producing irritation, is the exciting cause of the disease, which is especially common in chimney-sweeps from the lodgment of soot. The disease is very much less common than it used to be; this is probably due to the better hygienic conditions of the working classes. The scrotum is also the part most frequently affected by elephantiasis.

On account of the looseness of the subcutaneous tissue, large extravasations of blood may take place from very slight injuries. It is therefore generally recommended never to apply leeches to the scrotum, since they may lead to ecchymosis, but rather to puncture one or more of the superficial veins of the scrotum in cases where local blood-letting from this part is judged to be desirable. The muscular fibres in the dartos tunic cause contraction and considerable diminution in the size of a wound of the scrotum, as after the operation of castration, and are of assistance in keeping the edges together, and covering the exposed parts.

The Penis

The **penis** is a pendulous organ suspended from the front and sides of the pubic arch and containing the greater part of the urethra. In the flaccid condition it is cylindrical in shape, but when erect it assumes the form of a triangular prism with rounded angles, one side of the prism forming the dorsum of the penis. It is composed of three cylindrical masses of cavernous tissue bound together by fibrous tissue and covered with skin. Two of the masses are placed side by side, and are known as the *corpora cavernosa penis*; the third, median in position and beneath the other two, is traversed by the cavernous part of the urethra, and is termed the *corpus cavernosum urethræ* (figs. 1179, 1180).

The **corpora cavernosa penis** form the greater part of the substance of the penis. Throughout the anterior three-fourths of their extent they lie in apposition with one another, separated only by the septum of the penis; behind, they diverge in the form of two tapering processes, which are known as the *crura of the penis*, and are firmly connected to the rami of the pubic arch. Traced from behind forwards each crus begins as a blunt-pointed process in front of the tuberosity of the ischium. Just before it meets its fellow it presents a slight enlargement, named by Kobelt the *bulb of the corpus cavernosum penis*. Beyond this point the crus undergoes a constriction and merges into the corpus cavernosum proper, which retains a uniform diameter to its anterior end. Each corpus cavernosum penis ends abruptly in a round extremity a short distance from the point of the penis.

CC-0. In Public Domain. Gurukul Kangri Collection, Haridwar

Digitized by Arya Samaj Foundation Chennai and eGangotri

The corpora cavernosa penis are surrounded by a strong fibrous envelope consisting of superficial and deep fibres. The superficial fibres are longitudinal in direction, and form a single tube which encloses both corpora; the deep fibres are arranged circularly round each corpus, and form by their junction in the median plane the *septum of the penis*. This septum is thick and complete behind, but is imperfect in front, where it consists of a series of vertical bands arranged like the teeth of a comb; it is therefore named the *septum pectiniforme*.

FIG. 1179.—The constituent cavernous cylinders of the penis. The glans penis and the anterior part of the corpus cavernosum urethræ are detached from the corpora cavernosa penis and turned to one side.

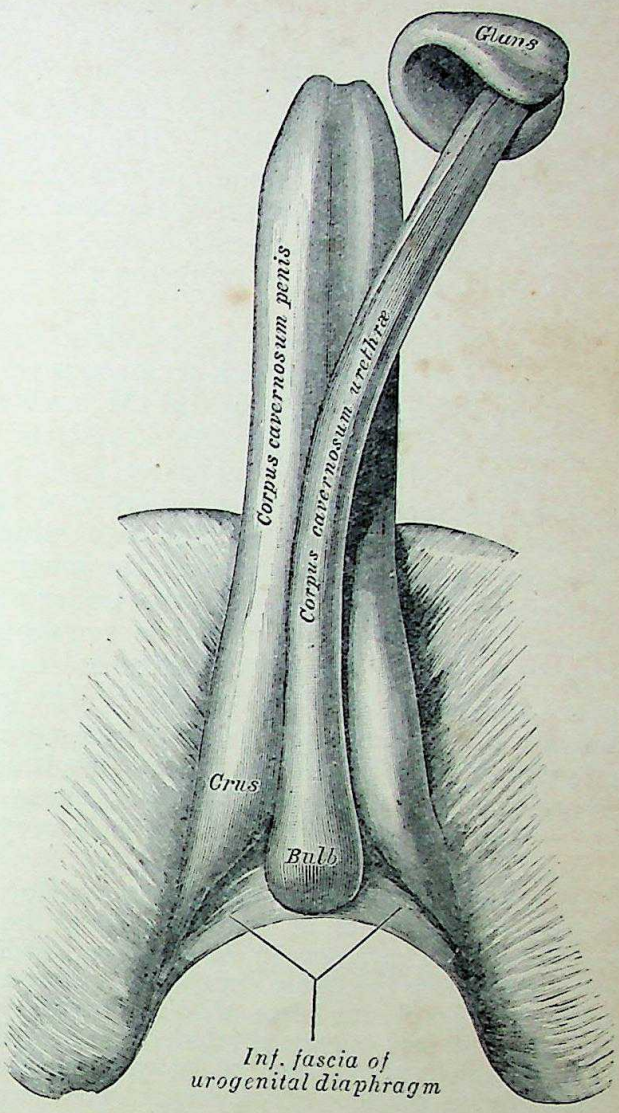

The **corpus cavernosum urethrae** (corpus spongiosum) contains the cavernous part of the urethra. Behind, it is expanded to form the urethral bulb, and lies in apposition with the inferior fascia of the urogenital diaphragm, from which it receives a fibrous investment. The urethra enters the bulb nearer to the upper than to the lower surface. On the lower surface of the bulb there is a median sulcus, from which a thin fibrous septum projects into the substance of the bulb and divides it imperfectly into two lateral lobes or *hemispheres*.

The portion of the corpus cavernosum urethræ in front of the bulb lies in a groove on the under surface of the conjoined corpora cavernosa penis. It is cylindrical in form and tapers slightly from behind forwards. His anterior end suddenly expands to form an obtuse cone, named the *glans penis*.

For descriptive purposes it is convenient to divide the penis into three regions: the root, the body, and the extremity.

The root of the penis is triradiate in form, consisting of the diverging crura, one on either side, and the median urethral bulb. Each crus is covered by the Ischiocavernosus, while the bulb is surrounded by the Bulbocavernosus. The root of the penis lies in the perinæum between the inferior fascia of the urogenital diaphragm and the fascia of Colles. In addition to being attached to the fasciæ and the pubic rami, it is bound to the front of the symphysis pubis by the fundiform and suspensory ligaments. The *fundiform ligament* springs from the front of the sheath of the Rectus abdominis and the linea alba; it splits into two fasciculi which pass one on either side

FIG. 1180.—A transverse section through the penis.

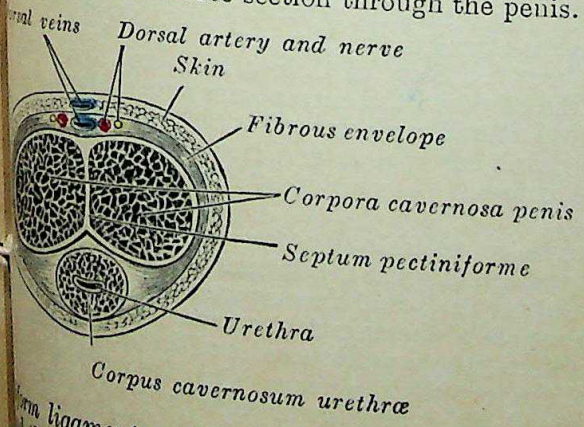

CC-0. In Public Domain. Gurukul Kangri Collection, Haridwar

Digitized by Arya Samaj Foundation Chennai and eGangotri

of the penis and unite below with the septum of the scrotum. The *suspensory ligament* is triangular in shape; it is attached above to the symphysis pubis; below, it blends with the fibrous envelope of the corpora cavernosa penis.

The **body** of the penis extends from the root to the anterior end of the corpora cavernosa penis. In the body the corpora cavernosa are intimately bound to one another; a shallow groove which marks their junction on the upper surface lodges the deep dorsal vein of the penis, while a deeper and wider groove between them on the under surface contains the corpus cavernosum urethræ. The body is ensheathed by fascia, which is continuous above with the fascia of Scarpa and below with the dartos tunic of the scrotum and the fascia of Colles.

The **extremity** is formed by the glans penis, the expanded anterior end of the corpus cavernosum urethræ. The glans penis is somewhat conical in shape and its concave base covers, and is attached to, the ends of the corpora cavernosa. The projecting margin of its base is named the *corona glandis*, and the constriction behind the latter is known as the *neck of the glans*. The terminal part of the urethra runs through the glans penis, and ends in a vertical slit on its apex.

The skin covering the penis is remarkable for its thinness, its dark colour, its looseness of connexion with the fibrous envelope of the organ, and its absence of adipose tissue. At the root of the penis it is continuous with the skin over the pubes, scrotum, and perinæum. At the neck of the glans penis it is folded upon itself to form the *prepuce* or *foreskin*, which overlaps the glans for a variable distance. The internal layer of the prepuce is confluent along the line of the neck with the thin skin which covers, and adheres firmly to, the glans, and is continuous with the mucous membrane of the urethra at the external urethral orifice. On the under surface of the glans penis a small median fold passes from the deep surface of the prepuce to a point on the glans immediately behind the external urethral orifice; this median fold is named the *frenulum* of the prepuce. The prepuce is separated from the glans penis by a potential sac—the *preputial sac*—which presents two shallow fossæ, one on either side of the frenulum. On the corona and neck of the glans there are numerous small *preputial glands*; these secrete a sebaceous material named the *smegma præputii*, which possesses a very peculiar odour.

Structure of the penis.—From the internal surface of the fibrous envelope of the corpora cavernosa penis, as well as from the sides of the septum, numerous *trabeculæ* arise, and cross the corpora cavernosa in all directions, subdividing them into a number of *cavernous spaces*, and giving the entire structure a spongy appearance (fig. 1180). These trabeculæ consist of white fibrous tissue, elastic fibres and plain muscular fibres (fig. 1181), and in them are contained numerous arteries and nerves. The cavernous spaces are filled with blood, and are lined by a layer of flattened cells similar to the endothelial lining of veins.

The fibrous envelope of the corpus cavernosum urethræ is thinner, whiter in colour, and more elastic than that of the corpora cavernosa penis. The trabeculæ are more delicate, and the meshes between them are smaller than in the corpora cavernosa penis. The envelope of the corpus cavernosum urethræ is formed partly of unstriped muscular fibres, and a layer of the same tissue surrounds the canal of the urethra.

Vessels and Nerves.—The arteries bringing the blood to the cavernous spaces are the deep arteries of the penis, and branches from the dorsal arteries of the penis, which perforate the fibrous capsule, along the upper surface, especially near the front part of the organ. On entering the cavernous structure the arteries divide into branches, which are supported and enclosed by the trabeculæ. Some of these arteries end in a capillary network, the branches of which open directly into the cavernous spaces; others assume a tendril-like appearance, and form convoluted and somewhat dilated vessels, named *helicine arteries*. They open into the cavernous spaces, and from them small capillary branches go to supply the trabecular structure. They are most abundant in the posterior parts of the corpora cavernosa.

The blood from the cavernous spaces is returned by a series of vessels, some of which emerge from the base of the glans penis and converge on the dorsum of the penis to form the deep dorsal vein; others pass out on the upper surface of the corpora cavernosa and join the same vein; some emerge from the under surface of the corpora cavernosa penis and, receiving branches from the corpus cavernosum urethræ, wind round the sides of the penis to end in the deep dorsal vein; but many pass out at the root of the penis and join the prostatic plexus.

The *nerves* are derived from the second, third and fourth sacral nerves, through the pudendal nerve and the pelvic plexuses. On the glans penis and the urethral bulb some filaments of the cutaneous nerves have Pacinian bodies connected with them, and many of them end in peculiar end-bulbs (p. 1048).

CC-0. In Public Domain. Gurukul Kangri Collection, Haridwar

Digitized by Arya Samaj Foundation Chennai and eGangotri

Applied Anatomy.—The penis occasionally requires removal for malignant disease. Removal of the antescrotal portion is usually all that is necessary, but sometimes it is requisite to remove the whole organ from its attachment to the pubic and ischial rami. The former operation is performed by cutting through the corpora cavernosa penis from the dorsum, and then separating the corpus cavernosum urethræ from them, dividing it at a level nearer the glans penis. The mucous membrane of the urethra is then slit up, and the edges of the flap attached to the external skin, in order to prevent contraction of the orifice, which might otherwise take place. The vessels which require to be ligatured are the deep and the dorsal arteries of the penis, and the artery of the septum. When the entire organ requires removal, the patient is placed in the lithotomy position, and an incision is made through the skin and subcutaneous tissue round the root of the penis, and carried down through the median line of the scrotum as far as the perinæum. The halves of the scrotum are then separated from each other, and, a catheter having been introduced into the bladder as a guide, the corpus cavernosum urethræ below the urogenital diaphragm is separated from the corpora cavernosa penis and divided, the catheter having been withdrawn. The suspensory ligament is now severed and the crura separated from the bone with a periosteum scraper. The portion of the urethra, which has not been removed, is attached to the skin at the posterior extremity of the incision in the perinæum. The remainder of the wound is closed, free drainage being provided for.

FIG. 1181.—A section through the corpus cavernosum penis in the non-distended condition. (Cadiat.)

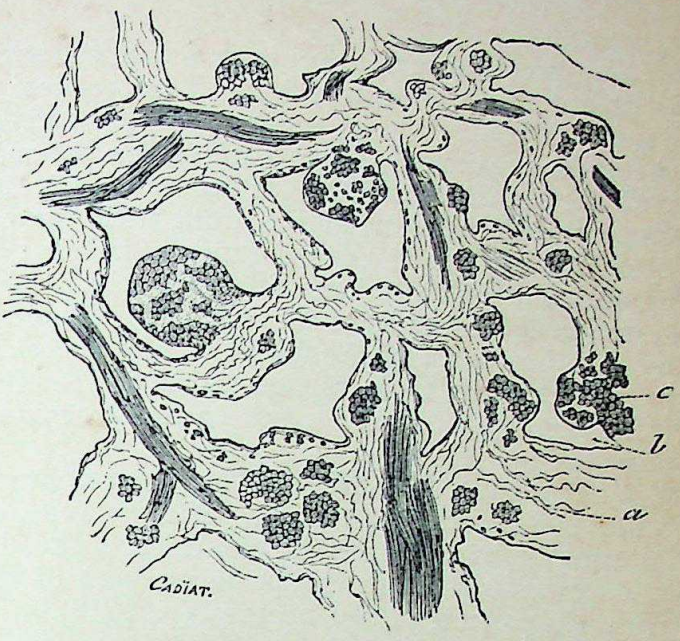

a. Trabeculæ of connective tissue, with many elastic fibres and bundles of plain muscular tissue, some of which are cut across (*c*). *b.* Blood-sinuses.

THE PROSTATE

The **prostate** (fig. 1176) is a firm, partly glandular and partly muscular body, surrounding the commencement of the urethra. It is situated in the pelvic cavity, behind the lower part of the symphysis pubis and the superior fascia of the urogenital diaphragm, and in front of the rectum. It is about the size of a chestnut and somewhat conical in shape, and presents for examination a base, an apex, a posterior, an anterior, and two lateral surfaces.

The *base* is directed upwards, and, for the greater part of its extent, is directly continuous with the wall of the urinary bladder: the urethra enters it nearer its anterior than its posterior border.

The *apex* is directed downwards, and is in contact with the superior fascia of the urogenital diaphragm.

The *posterior surface* is flattened from side to side and slightly convex from above downwards; it is separated by its sheath and some loose connective tissue from the rectum, and is distant about 4 cm. from the anus. Near its upper border is a depression through which the two ejaculatory ducts enter the prostate. This depression serves to divide the posterior surface into a lower larger and an upper smaller part. The upper smaller part constitutes the *middle lobe* of the prostate and intervenes between the ejaculatory ducts and the urethra; it varies greatly in size, and in some cases is destitute of glandular tissue. The lower larger portion sometimes presents a shallow median furrow, which imperfectly separates it into *right* and *left lateral lobes*; these form the main mass of the gland and are directly continuous with each other behind the urethra; they are connected in front of the urethra by a band which is named the *isthmus*; the latter consists of fibromuscular tissue and is devoid of glandular substance.

The *anterior surface* is narrow and convex from side to side. It lies about

CC-0. In Public Domain. Gurukul Kangri Collection, Haridwar

Digitized by Arya Samaj Foundation Chennai and eGangotri

2 cm. behind the pubic symphysis, from which it is separated by a plexus of veins and a quantity of loose fatty tissue. It is connected to the pubic bones by the puboprostatic ligaments. The urethra emerges from this surface a little above and in front of the apex of the prostate.

The *lateral surfaces* are prominent, and are covered by the anterior portions of the Levatores ani, which are, however, separated from the gland by a plexus of veins.

The prostate measures about 4 cm. transversely at the base, about 2 cm. in its anteroposterior, and 3 cm. in its vertical, diameter. Its weight is about 8 gm. It is invested by a fibrous sheath derived from the pelvic fascia. This sheath is continuous above with the rectovesical fascia which ensheathes the vesiculæ seminales and ductus deferentes, below with the superior fascia of the urogenital diaphragm, and in front with the puboprostatic ligaments. These ligaments are two thickened bands of pelvic fascia which pass backwards, one on each side of the middle line, from the pubic bones to the front of the prostate; between the ligaments is a median depression the floor of which is formed by a thinner part of the fascia.* The anterior portions of the Levatores ani pass backwards from the os pubis and embrace the sides of the prostate; from the support they afford to the prostate they are named the *Levatores prostatæ*.

The prostate is perforated by the urethra and the ejaculatory ducts and contains the prostatic utricle. The urethra usually lies along the junction of its anterior with its middle one-third. The ducts pass obliquely downwards and forwards through the posterior part of the prostate, and open into the prostatic portion of the urethra (p. 1218).

Structure (fig. 1182).—The prostate is enveloped by a thin but firm capsule, distinct from the sheath derived from the pelvic fascia, and separated from it by a plexus of veins. This capsule is firmly adherent to the prostate and is structurally continuous with the stroma of the gland, being composed of the same tissues, viz. non-striped muscle and fibrous tissue. The substance of the prostate is of a pale reddish-grey colour, of great density, and not easily torn. It consists of glandular substance and muscular tissue.

The *muscular tissue* constitutes the proper stroma of the prostate; the connective tissue being very scanty, and merely forming, between the muscular fibres, thin trabeculæ in which the vessels and nerves of the gland ramify. The muscular tissue is arranged as follows: immediately beneath the capsule is a dense layer, which forms an investing sheath for the gland; around the prostatic part of the urethra is a dense layer of circular fibres, continuous above with the internal layer of the muscular coat of the bladder, and blending below with the fibres surrounding the membranous portion of the urethra; between these two layers are strong bands of muscular tissue which decussate freely, and form meshes in which the glandular structure of the organ is imbedded. In that part of the gland which is situated in front of the urethra the muscular tissue is especially dense, and there is here little or no glandular tissue; while in that part which is behind the urethra the muscular tissue presents a wide-meshed structure, which is densest at the base of the gland—that is, near the bladder—becoming looser and more sponge-like towards the apex.

The *glandular substance* is composed of numerous follicles the lining of which frequently shows papillary elevations. The follicles open into elongated canals which join to form from twelve to twenty small excretory ducts. They are connected together by areolar tissue, supported by prolongations from the fibrous capsule and muscular stroma, and enclosed in a delicate capillary plexus. The epithelium which lines the canals and the terminal vesicles is of the columnar variety. The prostatic ducts open into the floor of the prostatic portion of the urethra, and are lined by two layers of epithelium, the inner layer consisting of columnar and the outer of small cubical cells. Small colloid masses, known as amyloid bodies, are often found in the gland tubes.

* G. Elliot Smith (*Journal of Anatomy*, vol. xlii.) pointed out that in a mesial section through the pelvis of a male fœtus of the fourth month the rectovesical excavation or recess of the peritoneum is seen to be very much deeper than it is in the adult; it extends downwards on the posterior surface of the prostate and is attached there to the upper extremity of the perinæal body.

The two layers of this recess become loosely attached to one another and their serous covering disappears, the two layers of peritoneum being transformed into or replaced by a double sheet of fibrous tissue, mixed with some unstriped muscle. This sheet he names the *rectovesical septum* and states that it is almost identical with the 'rectovesical fascia,' except that its lateral borders are either quite free or attached to the sheath of the vesical plexuses. The rectovesical septum is a triangular sheet, the superior border of which is attached to the peritoneum, while its three angles are placed respectively at the outer extremities of the vesiculæ seminales and the lower edge of the prostate. The posterior part of the capsule of the prostate is formed mainly by the rectovesical septum.

CC-0. In Public Domain. Gurukul Kangri Collection, Haridwar

Digitized by Arya Samaj Foundation Chennai and eGangotri

Vessels and Nerves.—The *arteries* supplying the prostate are derived from the internal pudendal, inferior vesical, and middle hæmorrhoidal arteries. Its *veins* form a plexus around the sides and base of the gland; they receive in front the dorsal vein of the penis, and end in the hypogastric veins. The *lymphatics* are described on p. 772. The *nerves* are derived from the pelvic plexus.

FIG. 1182.—A transverse section through a normal prostate, opposite the middle of the urethral crest. From a subject aged nineteen years. (Taylor.)

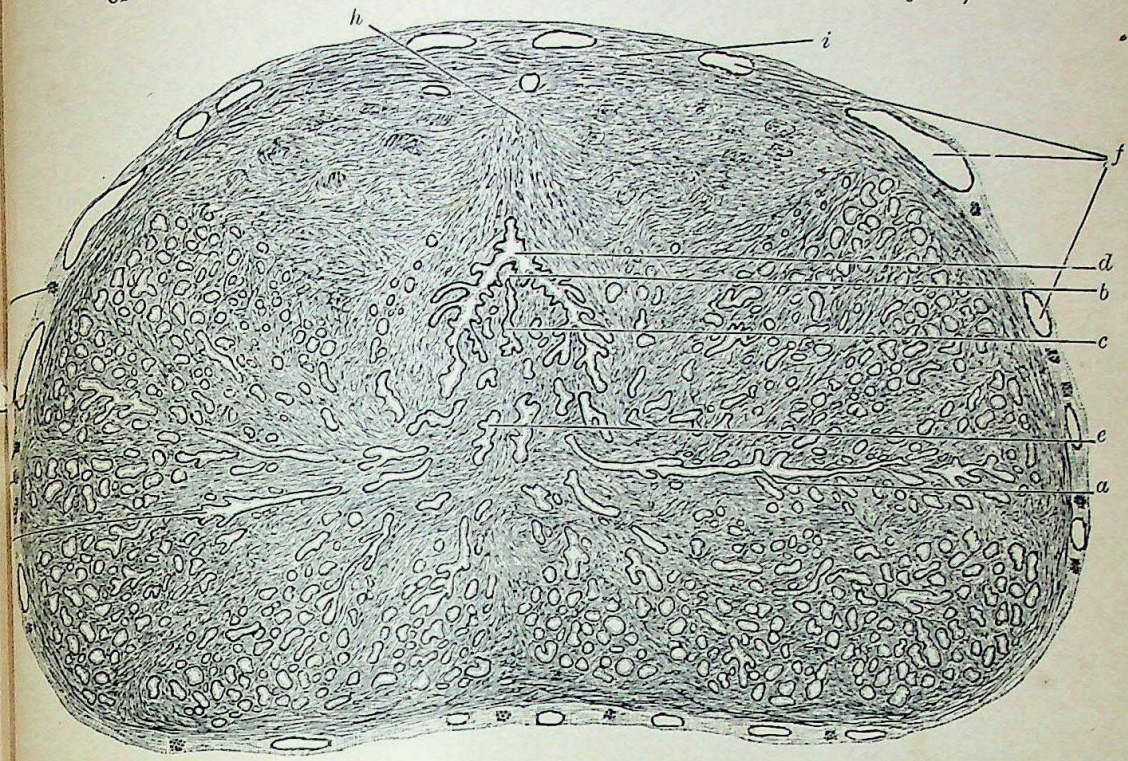

a. Longitudinal section of ducts leading from the lobules of the glands. *b.* Urethral crest. *c.* Prostatic utricle. *d.* Urethra. *e.* Ejaculatory ducts. *f.* Arteries, veins, and venous sinuses in sheath of prostate. *g.* Nerve-trunks in sheath. *h.* Point of origin of fibromuscular bands encircling urethra. *i.* Zone of striated voluntary muscle on superior surface.

Applied Anatomy.—By means of the finger introduced into the rectum, the surgeon detects enlargement or other disease of the prostate; he can feel the apex of the gland, which is the guide to Cock's operation for stricture; he is enabled also by the same means to direct the point of a catheter, when its introduction is attended with difficulty either from injury or disease of the membranous or prostatic portions of the urethra. When the finger is introduced into the bowel, the surgeon may, in some cases, especially in boys, learn the position, as well as the size, of a calculus in the bladder. If, as is not infrequently the case, the calculus be lodged behind an enlarged prostate, it may be displaced from its position by pressing it upwards towards the fundus of the bladder from the rectum. The prostate is occasionally the seat of suppuration, due to either gonorrhœa or tuberculous disease. The gland is enveloped in a dense unyielding capsule, which determines the course of the abscess, and also explains the great pain which is present in the acute form of the disease. The abscess most frequently bursts into the urethra, the direction in which there is least resistance, but may burst into the rectum, or more rarely in the perinæum. In advanced life the prostate sometimes becomes considerably enlarged and projects into the bladder so as to impede the passage of the urine. According to Messer's researches, conducted at Greenwich Hospital, it would seem that such obstruction exists in 20 per cent. of all men over sixty years of age. In some cases the condition affects principally the lateral lobes, which may undergo considerable enlargement without causing much inconvenience. In other cases it would seem that the middle lobe enlarges most, and even a small enlargement of this lobe may be injuriously, by forming a sort of valve over the internal urethral orifice, preventing the passage of the urine; and the more the patient strains, the more completely will it block the opening into the urethra. In consequence of the enlargement of the prostate, a pouch is formed at the base of the bladder behind the projection, in which urine collects, and from which it cannot be entirely expelled. For this condition *prostatectomy* is sometimes done. The bladder is opened by an incision above the symphysis pubis, the mucous membrane of the post-prostatic pouch is scratched through, and the finger is then introduced into the space between the true capsule of the prostate and outer capsule formed by the pelvic fascia. Separation in this plane is then carried out below and laterally until the apex of the gland is reached. The whole of the work is done with the finger, which is gradually swept round the sides until the anterior surface is reached and

CC-0. In Public Domain. Gurukul Kangri Collection, Haridwar

Digitized by Arya Samaj Foundation Chennai and eGangotri

freed. The gland is then, by traction, displaced into the bladder and removed, usually carrying with it the greater portion of the mucous membrane of the prostatic urethra. Hæmorrhage, which may be considerable at times, is checked by hot irrigations, and the bladder is temporarily drained. Very satisfactory results have followed this operation.

The prostate can be reached from the perinæum, and in some cases the enlarged gland has been removed by this route, but the perinæal approach is not usually employed except in the case of abscess of or about the gland.

The Bulbo-urethral Glands

The **bulbo-urethral glands** (Cowper's glands) are two small, rounded and somewhat lobulated bodies, of a yellow colour. Each is about the size of a pea, and is placed lateral to the membranous portion of the urethra, between the two layers of the fascia of the urogenital diaphragm. They lie above the urethral bulb, and are enclosed by the transverse fibres of the Sphincter urethræ membranaceæ. They gradually diminish in size as age advances.

The excretory duct of each gland is nearly 3 cm. long; it passes obliquely forwards beneath the mucous membrane, and opens by a minute orifice on the floor of the cavernous portion of the urethra about 2·5 cm. in front of the urogenital diaphragm.

Structure—Each gland is made up of several lobules which are held together by a fibrous investment. Each lobule consists of a number of acini, lined by columnar epithelial cells.

THE FEMALE GENITAL ORGANS

The female genital organs consist of an internal and an external group. The *internal organs* are situated within the pelvis, and consist of the ovaries, the uterine (Fallopian) tubes, the uterus, and the vagina. The *external organs* are placed below and in front of the pubic arch. They comprise the mons pubis, the labia majora et minora pudendi, the clitoris, the bulbus vestibuli, and the greater vestibular glands.

The Ovaries

The **ovaries**, two in number, are homologous with the testes in the male. They are situated one on either side of the uterus in relation to the lateral wall of the pelvis, and attached to the back of the broad ligament of the uterus behind and below the uterine tube (fig. 1183). They are of a greyish-pink colour, and present either a smooth or a puckered uneven surface; each is about 3 cm. long, 1·5 cm. wide, and about 10 mm. thick. In the erect posture the long axis of the ovary is vertical. Each ovary presents a lateral and a medial surface, a tubal and a uterine extremity, and a mesovarian and a free border. The ovary lies in a depression, named the *ovarian fossa*, on the lateral wall of the pelvis; this fossa is bounded in front by the obliterated hypogastric artery, and behind by the ureter and the uterine artery. The exact position of the ovary has been the subject of considerable difference of opinion, and the description here given applies to that of the nulliparous woman; the ovary is displaced during the first pregnancy, and probably never again returns to its original position. The *tubal extremity* (extremitas tubaria) is near the external iliac vein; to it are attached the ovarian fimbria of the uterine tube and a fold of peritoneum, the *suspensory ligament of the ovary*, which passes upwards over the iliac vessels and contains the ovarian vessels and nerves. The *uterine extremity* (extremitas uterina) is directed downwards towards the pelvic floor; it is usually narrower than the tubal extremity, and is attached to the lateral angle of the uterus, immediately behind and below the uterine tube, by a rounded cord termed the *ligament of the ovary*, which lies within the broad ligament and contains some non-striped muscular fibres. The *lateral surface* is in contact with the parietal peritoneum, which lines the ovarian fossa and separates the ovary from the subperitoneal connective tissue and the obturator vessels; the *medial surface* is to a large extent covered by the uterine tube. The *mesovarian border* is straight and is directed towards the obliterated hypogastric artery; it is attached to the back of the broad ligament by a short fold named the *mesovarium*. Between the two layers of this fold the

CC-0. In Public Domain. Gurukul Kangri Collection, Haridwar

Digitized by Arya Samaj Foundation Chennai and eGangotri

blood-vessels and nerves pass to the hilum of the ovary. The *free border* is convex, and is directed towards the ureter. The uterine tube arches over the ovary,

FIG. 1183.—The uterus and the right broad ligament. Posterior aspect. The broad ligament has been spread out and the ovary drawn downwards.

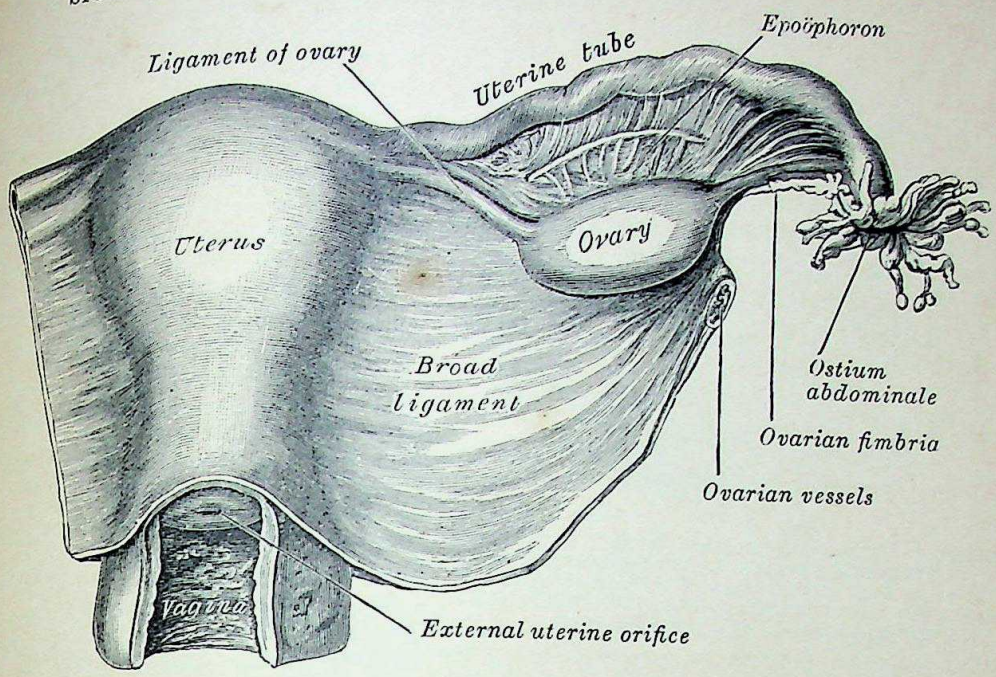

running upwards in relation to its mesovarian border, curving over its tubal extremity, and then passing downwards on its free border and medial surface.

In the fœtus, the ovaries are situated, like the testes, in the lumbar region near the kidneys, but they gradually descend into the pelvis (p. 156).

FIG. 1184.—The adult left ovary, epoöphoron, and uterine tube. Posterior aspect. (From Farre, after Kobelt.)

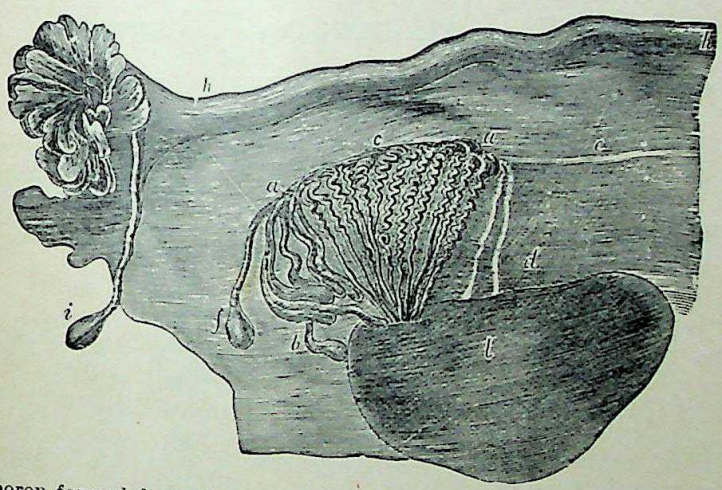

a, a. Epoöphoron formed from the upper part of the Wolffian body. *b.* Remains of the uppermost tubes sometimes forming hydatids. *c.* Middle set of tubes. *d.* Some lower atrophied tubes. *e.* Atrophied remains of the Wolffian duct. *f.* The terminal bulb or hydatid. *h.* The uterine tube. *i.* Hydatid attached to the extremity. *l.* The ovary.

Structure (fig. 1185).—The surface of the ovary is covered by a layer of cubical cells. This epithelium gives to the ovary a dull grey colour as compared with the shining smoothness of the peritoneum; the transition between the squamous epithelium of the peritoneum and the cubical cells covering the ovary is usually marked by a line around the anterior border of the ovary.

The ovary consists of a number of vesicular ovarian follicles imbedded in the meshes of a stroma or framework.

The *stroma* is abundantly supplied with blood-vessels, and consists for the most part of spindle-shaped cells with a small amount of ordinary connective tissue. Many of these cells are unstriped muscle-cells. On the surface of the organ is a condensed layer known as the *tunica albuginea*. The stroma of the ovary also contains groups of *interstitial cells* resembling those of the testis.

CC-0. In Public Domain. Gurukul Kangri Collection, Haridwar

Digitized by Arya Samaj Foundation Chennai and eGangotri

Vesicular ovarian (Graafian) follicles.—Upon making a section through an ovary, numerous vesicles of various sizes are seen; they are the follicles, or ovisacs containing the ova. Immediately beneath the tunica albuginea is a layer of stroma, called the *cortical layer*, characterised by the presence of a large number of ova in an early stage of development. At this stage each ovum is a spherical cell, and is surrounded by a single layer of smaller, cubical cells. These primitive follicles are numerous in the ovary of the child.

FIG. 1185.—A section through the ovary. (After Schrön.)

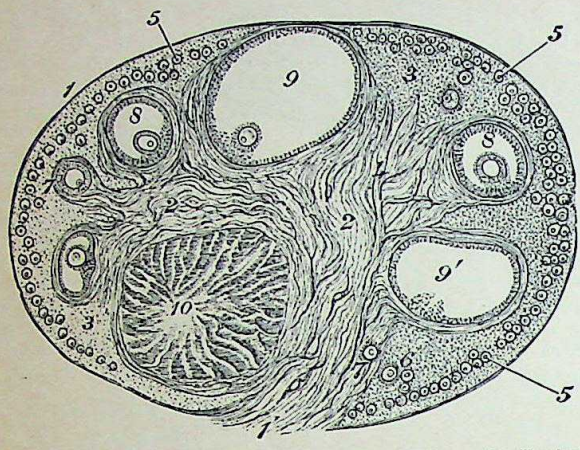

1. Outer covering. 1′. Attached border. 2. Central stroma. 3. Peripheral stroma. 4. Blood-vessels. 5. Vesicular follicles in their earliest stage. 6, 7, 8. More advanced follicles. 9. An almost mature follicle. 9′. Follicle from which the ovum has escaped. 10. Corpus luteum.

After puberty some of these primitive ovarian follicles increase in size; the cells investing the ovum multiply, and later a cavity, named the *antrum folliculi*, appears between the cells thus formed. This cavity is filled with *liquor folliculi*, a transparent, albuminous fluid which nourishes and protects the ovum. The liquor folliculi splits the investing cells into two strata, an outer named the *stratum granulosum* and an inner, the *cumulus oöphori*; the latter surrounds the ovum* and is attached at one spot to the stratum granulosum (fig. 1186). Thomson† is of opinion that the cumulus may be attached to the stratum granulosum at any part of the circumference of the follicle. In the earlier stages of the development of the follicle the stratum granulosum is made up of several layers of cubical cells, but in the matured follicle it consists of a single layer, and in some instances this may disappear.

Scattered amongst the cells of the cumulus oöphori and stratum granulosum are certain structures known as the *bodies of Call and Exner*, the cells surrounding which are radially arranged; in the advanced stages of the growth of the follicle these bodies are only found in the cumulus. Each consists of a more or less homogeneous mass of protoplasm, which, in its reactions to certain stains, resembles the coagulated liquor folliculi. These bodies become vacuolated, and tend to break down, and it is therefore probable that the liquor folliculi is formed, in the first instance, by their dissolution.

FIG. 1186.—A section through an ovarian follicle of a cat. × 50.

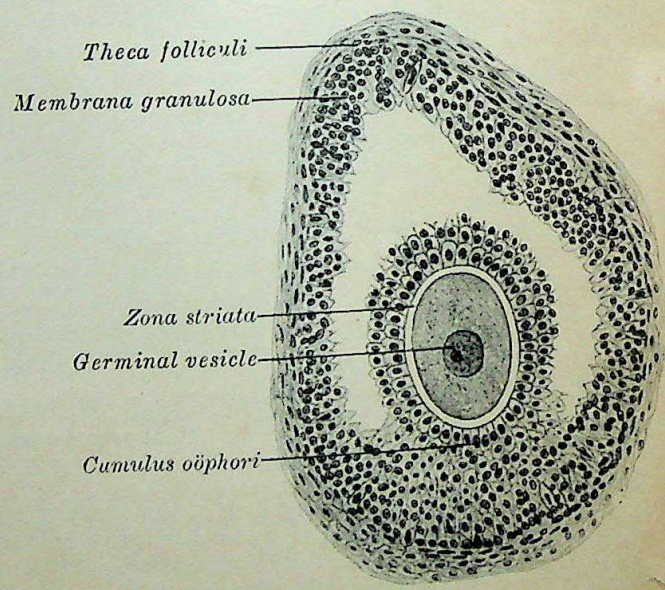

A fully developed or 'ripe' ovarian follicle is about 5 mm. in diameter (Thomson, loc. cit.) and is surrounded by a capsule (*theca folliculi*) derived from the ovarian stroma, and composed of an internal and an external tunic. The *tunica interna* consists of loosely-arranged, round or spindle-shaped cells, and is pervaded by a capillary plexus. The vascularity of this tunic increases as the follicle matures, and the capillary vessels then extend between the cells of the attached part of the cumulus. Between the tunica interna and the stratum granulosum which lines it, there is a thin *external limiting membrane* (basal membrane). The *tunica externa* consists of firmer and less vascular tissue than the tunica interna, and contains a considerable quantity of non-striped muscular fibres.

The mature follicle approaches, and ultimately bursts on, the surface of the ovary, and the escaped ovum, surrounded by the cells of the cumulus oöphori, is grasped by the

* The ovum is described on pp. 40 to 42.

†Consult, in this connection, an article by Arthur Thomson on "The ripe human Graafian follicle," *Journal of Anatomy*, vol. liv.

CC-0. In Public Domain. Gurukul Kangri Collection, Haridwar

Digitized by Arya Samaj Foundation Chennai and eGangotri

fimbriated end of the uterine tube, and is conveyed along this tube to the cavity of the uterus. The rupture of the follicle is probably brought about by the contraction of the non-striped muscular fibres of the tunica externa.

Robinson * has investigated the formation, rupture, and closure of the ovarian follicles in ferrets, and has shown that in these animals a fluid, named by him the *secondary liquor folliculi*, appears between the cells of the cumulus oöphori and takes part in the final distension of the follicle which precedes rupture.

The maturation of the follicles and ova continues uninterruptedly from puberty to the end of the reproductive period of woman's life, while their formation commences before birth.

Corpus luteum.—After the discharge of the ovum a series of changes occurs within the Graafian follicle which result in the formation of a structure named the *corpus luteum*. When fully developed this consists of large cells containing yellow pigment (*luteal cells*) separated from one another by delicate trabeculæ of vascular connective tissue which is aggregated to form a mass in the centre of the follicle devoid of luteal cells. Opinion is divided as to what is the source of the luteal cells. Many regard them as being derived from the tunica interna, a view which is supported by the fact that the stratum granulosum may be separated from the external limiting membrane before the ovarian follicle bursts. Others maintain that they are derived from the cells of the stratum granulosum, which undergo great hypertrophy, and, in the early stages of the formation of the corpus luteum, show signs of mitosis. The connective tissue trabeculæ are derived from the sheath of the follicle.

If the discharged ovum be not fertilized the corpus luteum quickly degenerates, and within two months is reduced to a small cicatrix, but if the ovum be fertilized the corpus luteum increases in size and, by the middle of pregnancy, may measure about 2·5 cm. in diameter. During the later months of pregnancy the luteal cells lose their colour, and the size of the corpus luteum diminishes, so that by the end of pregnancy its diameter is reduced to about 1 cm.†

Vessels and Nerves.—The *arteries* of the ovaries and uterine tubes are the ovarian arteries from the aorta. Each anastomoses in the mesosalpinx with the uterine artery; it gives some branches to the uterine tube, and others which traverse the mesovarium and enter the hilum of the ovary. The *veins* emerge from the hilum in the form of a plexus, the *pampiniform plexus*; the ovarian vein is formed from this plexus, and leaves the pelvis in company with the artery. The *lymphatics* are described on p. 774. The *nerves* are derived from the hypogastric or pelvic plexus, and from the ovarian plexus, the uterine tube receiving a branch from one of the uterine nerves.

Epoöphoron (figs. 1183, 1184).—The epoöphoron or organ of Rosenmüller lies in the lateral part of the mesosalpinx between the ovary and the uterine tube, and consists of a few short tubules (*ductuli transversi*) which converge towards the ovary while their opposite ends open into a rudimentary duct, the *ductus longitudinalis epoöphori* (duct of Gärtner), which runs in the broad ligament of the uterus, parallel with the lateral part of the uterine tube.

In a small proportion of subjects Gärtner's duct can be followed alongside the uterus to near the level of the internal orifice. Here it pierces the muscular wall of the uterus and descends in the cervix uteri, gradually approaching the mucous membrane, without however quite reaching it. The duct then runs downwards in the lateral wall of the vagina and ends at, or close to, the free margin of the hymen.

Paroöphoron.—The paroöphoron consists of a few scattered rudimentary tubules, best seen in the child, situated in the broad ligament between the epoöphoron and the uterus.

The ductuli transversi of the epoöphoron and the tubules of the paroöphoron are remnants of the tubules of the Wolffian body or mesonephros; the ductus longitudinalis epoöphori is a persistent portion of the Wolffian duct.

Applied Anatomy.—The inflammations which affect the ovary are merely an extension of those from the uterine tube. Ovarian new formations are of common occurrence, and are either solid or cystic; the former being the less common. The '*ovarian cysts*' in the majority of cases are cystadenomata which may spring from the ovarian follicles and assume enormous dimensions; in rarer instances they arise from the tubules at the hilum of the ovary or those of the epoöphoron; in other instances a clear watery cyst forms between the layers of the broad ligament. An ovarian cyst, once diagnosed, should always be removed, as it is liable to become affected by suppuration, torsion of its pedicle, and other serious complications. The operation for its removal, badly termed *ovariotomy*, consists in opening the abdomen and delivering the cyst through the wound; the pedicle is then clamped with forceps, and the cyst is cut free. The pedicle must be transfixed and securely ligatured by an interlocking ligature, which will not slip off. The pedicle consists of an elongated part of the broad ligament, including the uterine tube and ovarian artery, and a great number of large veins. Ovariotomy for a simple uncomplicated cyst presents no special difficulties, but, in cases where there are old adhesions implicating the small intestine, it may present very great difficulties.

* Arthur Robinson, *Transactions of the Royal Society of Edinburgh*, vol. lii. part ii.

† Consult *The Physiology of Reproduction* by F. H. A. Marshall, 1910.

CC-0. In Public Domain. Gurukul Kangri Collection, Haridwar

Digitized by Arya Samaj Foundation Chennai and eGangotri

The Uterine Tubes (figs. 1183, 1188)

The uterine tubes (Fallopian tubes), two in number, transmit the ova from the ovaries to the cavity of the uterus and are situated in the upper margins of the broad ligaments of the uterus. Each tube is about 10 cm. long, and one end of it opens into the superior angle of the cavity of the uterus, the other into the peritoneal cavity close to the ovary. The opening into the uterine cavity is very small, and only admits a fine bristle; the opening into the peritoneal cavity is named the *abdominal ostium*, and when its muscular wall is relaxed has a diameter of about 3 mm. The abdominal ostium is situated at the bottom of a trumpet-shaped expansion of the uterine tube, termed the *infundibulum*, the circumference of which is prolonged into a varying number of irregular processes, called *fimbriæ*, and therefore this ostium is sometimes called the *fimbriated end* of the tube. The inner surfaces of the fimbriæ are lined by mucous membrane, and in the larger fimbriæ this exhibits longitudinal folds which are continuous with similar folds in the mucous lining of the infundibulum. One fimbria, longer and more deeply grooved than the others, is attached to the tubal extremity of the ovary, and is named the *ovarian fimbria*. The infundibulum opens into the *ampulla* of the tube, which is thin-walled and tortuous and forms rather more than one-half the entire length of the tube. The ampulla is succeeded by the *isthmus*, which is round and cord-like and constitutes approximately the medial one-third of the tube. The part continued from the isthmus through the wall of the uterus is about 1 cm. long, and is named the *pars uterina tubæ*.

Fig. 1187.—Transverse section of a human uterine tube. Stained with hæmatoxylin and eosin. ×15.

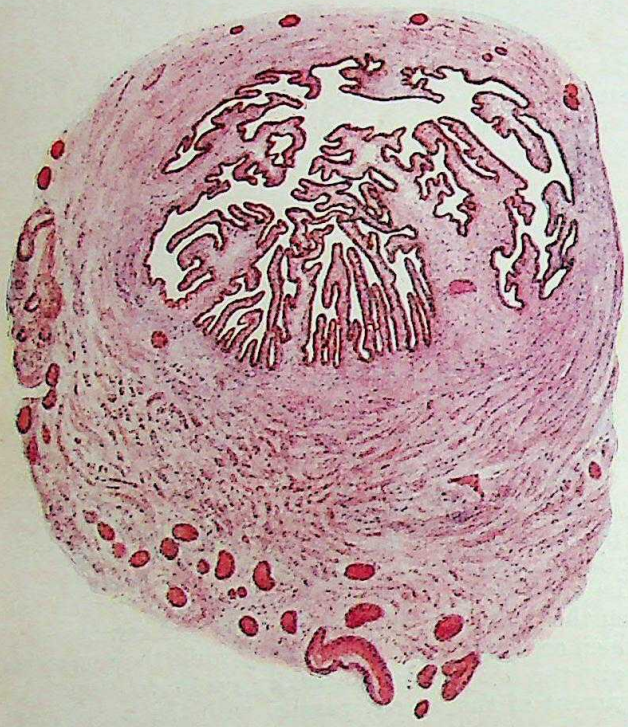

The uterine tube is directed lateralwards as far as the uterine extremity of the ovary, and then ascends along the mesovarian border of the ovary to the tubal extremity, over which it arches; finally it turns downwards and ends in relation to the free border and medial surface of the ovary. In connexion with the fimbriæ of the uterine tube, or with the broad ligament close to them, there are frequently one or more small pedunculated vesicles; these are termed the *appendices vesiculosæ* (hydatids of Morgagni).

Structure (fig. 1187).—The uterine tube consists of three coats: serous, muscular, and mucous. The *external or serous coat* is peritoneal. The *middle or muscular coat* consists of an external longitudinal and an internal circular layer of non-striped muscular fibres continuous with those of the uterus. The *internal or mucous coat* is continuous with the mucous lining of the uterus, and, at the abdominal ostium of the tube, with the peritoneum. It is thrown into longitudinal folds, which in the ampulla are much more extensive than in the isthmus. The lining epithelium is columnar and ciliated. This form of epithelium is also found on the inner surfaces of the fimbriæ; while on the outer or serous surfaces of these processes the epithelium gradually merges into the endothelium of the peritoneum.

Applied Anatomy.—The majority of the diseases of the uterine tube are due to infections which have spread by way of the vagina and uterus, and the disease often does not stop at the uterine tube, but passes on to the peritoneum, giving rise to acute general peritonitis, or a localised condition termed *perimetritis*, which may be acute or chronic.

CC-0. In Public Domain. Gurukul Kangri Collection, Haridwar

Digitized by Arya Samaj Foundation Chennai and eGangotri

Perimetritis is often followed by various painful conditions, which are due to the peritoneal adhesions resulting from the inflammation of the serous membrane, and which persist throughout life. Tubal inflammation (*salpingitis*) is usually the result of an infection either by the gonococcus, or by septic organisms implanted at the time of labour or abortion. In many cases the fimbriated ends of the tubes become closed by adhesions, pus collects in the tubes, and a *pyosalpinx* results.

Fertilisation of the ovum (p. 46) is believed to occur in the uterine tube, and the fertilised ovum is then normally passed on into the uterus; the ovum, however, may adhere to and undergo development in the tube, giving rise to the commonest variety of *ectopic gestation*. In such cases the amnion and chorion are formed, but a true decidua is never present; and the gestation usually ends by extrusion of the ovum through the abdominal ostium, although it is not uncommon for the tube to rupture into the peritoneal cavity, this being accompanied by severe hæmorrhage, and needing surgical interference.

The Uterus (figs. 1183, 1188, 1189)

The **uterus**, or **womb**, is a hollow, thick-walled, muscular organ situated in the pelvic cavity between the urinary bladder in front and the rectum behind. Into its upper part the uterine tubes open, one on either side, while below, its

Fig. 1188.—The female pelvis and its contents. Anterosuperior aspect.

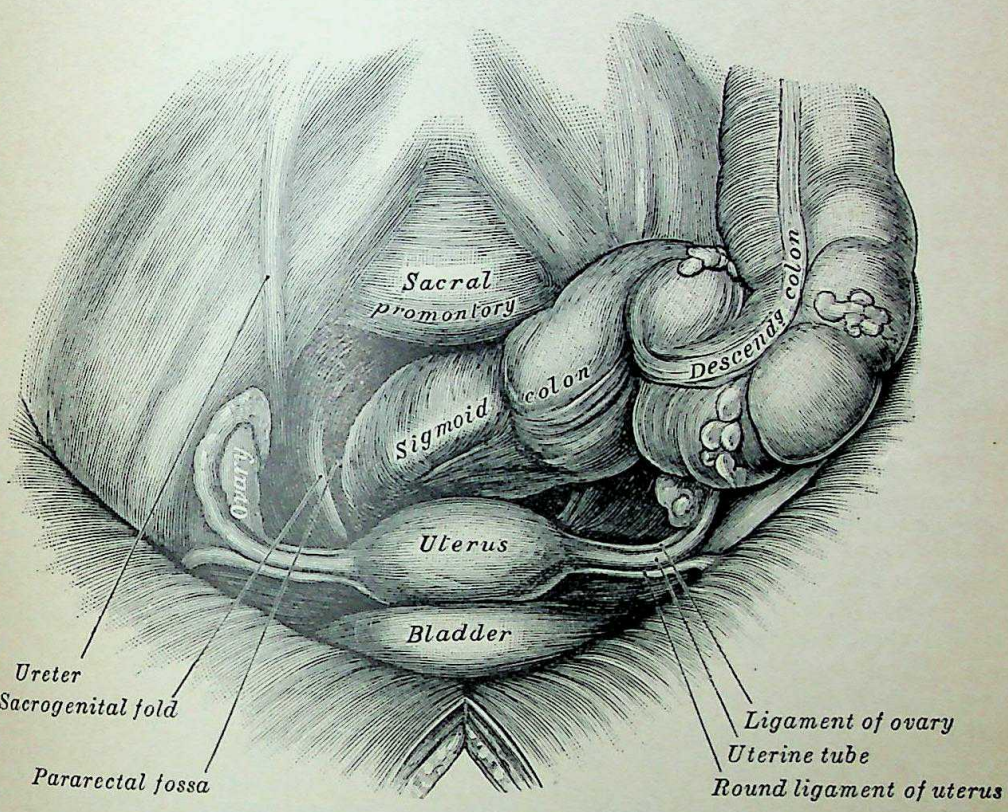

cavity communicates with that of the vagina. When the ova are discharged from the ovaries they are carried to the uterine cavity through the uterine tubes. If an ovum be fertilised it imbeds itself in the uterine wall and is normally retained in the uterus until prenatal development is completed, the uterus undergoing changes in size and structure to accommodate itself to the needs of the growing embryo. After parturition the uterus returns almost to its former condition, but traces of its enlargement remain. For general descriptive purposes the adult virgin uterus is taken as the type form.

In the virgin state the uterus is flattened from before backwards and is pyriform in shape, with the apex directed downwards and backwards. It lies between the bladder below and in front and the sigmoid colon and rectum above and behind, and is completely within the pelvis, its base being below the level of the superior pelvic aperture. Its upper part is suspended by the broad and the round ligaments, while its lower portion is imbedded in the fibrous tissue of the pelvis.

CC-0. In Public Domain. Gurukul Kangri Collection, Haridwar

Digitized by Arya Samaj Foundation Chennai and eGangotri

The long axis of the uterus usually lies approximately in the axis of the superior pelvic aperture, but as the organ is freely movable its position varies with the state of distension of the bladder and rectum. Except when much displaced by a distended bladder, it forms a forward angle with the vagina, since the axis of the vagina corresponds to the axes of the cavity and inferior aperture of the pelvis.

The uterus measures about 7·5 cm. in length, 5 cm. in breadth at its upper part, and nearly 2·5 cm. in thickness; it weighs from 30 to 40 gm. It is divisible into two portions. On the surface, a little below the middle, is a slight constriction, known as the *isthmus*, and corresponding to this in the interior is a narrowing of the uterine cavity, the *internal orifice* of the uterus. The portion above the isthmus is termed the *body*, and that below, the *cervix*.

FIG. 1189.—A median sagittal section through the female pelvis.

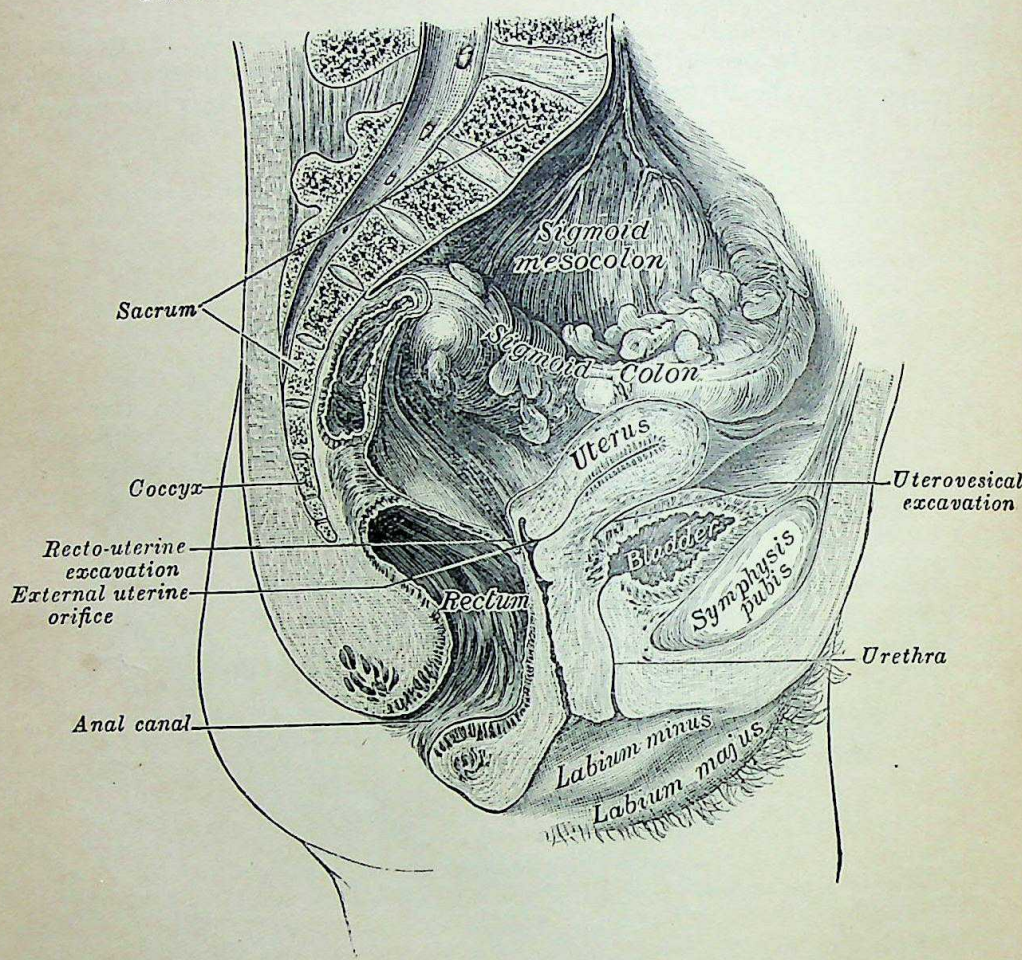

The part of the body which lies above a plane passing through the points of entrance of the uterine tubes is known as the *fundus*.

Body.—The body gradually narrows from the fundus to the isthmus.

The *vesical or anterior surface* is in apposition with the urinary bladder. It is flattened and covered by peritoneum, which is reflected on to the bladder as the vesico-uterine fold. The recess or pouch between the bladder and the uterus is named the *vesico-uterine excavation*.

The *intestinal or posterior surface* is convex transversely, and is covered by peritoneum, which is continued downwards on the cervix uteri and the upper part of the vagina. It is in relation with the sigmoid colon, from which it is usually separated by some coils of small intestine.

The *fundus* is convex in all directions, and covered by peritoneum continuous with that on the vesical and intestinal surfaces. Some coils of small intestine, and occasionally the distended sigmoid colon rest on it.

The *lateral margins* are slightly convex. At the upper end of each the uterine tube pierces the uterine wall. Below and in front of this point the round ligament of the uterus is fixed; below and behind it the ligament of

CC-0. In Public Domain. Gurukul Kangri Collection, Haridwar

Digitized by Arya Samaj Foundation Chennai and eGangotri

the ovary is attached. These three structures lie within a fold of peritoneum, named the broad ligament, which is reflected from the margin of the uterus to the wall of the pelvis.

Cervix.—The cervix is the lower constricted segment of the uterus. It is somewhat conical in shape, with its truncated apex directed downwards and backwards, but is slightly wider in the middle than above or below. Owing to its relationships it is less freely movable than the body, so that its long axis is seldom in the same straight line as that of the body. The long axis of the uterus as a whole presents the form of a curved line with its concavity forwards, or in extreme cases there may be an angular bend at the region of the isthmus uteri.

FIG. 1190.—The posterior half of the uterus and upper part of the vagina.

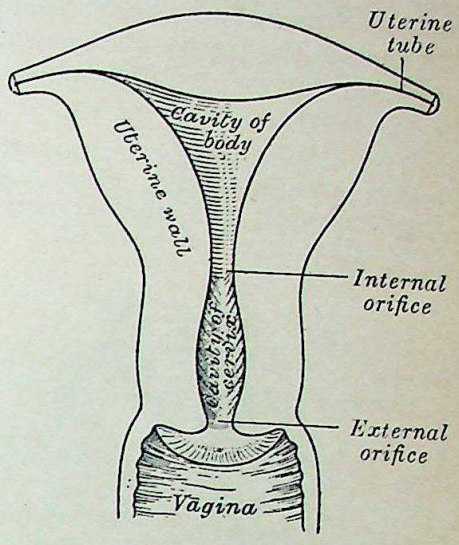

The cervix projects through the anterior wall of the vagina, which divides it into an upper, supravaginal portion, and a lower, vaginal portion.

The *supravaginal portion* is separated *in front* from the bladder by cellular tissue (*parametrium*), which extends also on to the sides of the cervix, and lateralwards between the layers of the broad ligaments. The uterine arteries reach the margins of the cervix in this fibrous tissue, while on either side the ureter runs downwards and forwards in it at a distance of about 2 cm. from the cervix. *Posteriorly*, the supravaginal cervix is covered by peritoneum, which is prolonged below on to the posterior vaginal wall, whence it is reflected to the rectum, forming the recto-uterine excavation (p. 1138). It is in relation with the rectum, from which it may be separated by coils of small intestine.

The *vaginal portion* of the cervix projects into the anterior wall of the vagina between the vaginal fornices (p. 1237). On its projecting rounded extremity is a small, depressed, somewhat circular aperture, the *external orifice of the uterus*, through which the cavity of the cervix communicates with that of the vagina. The external orifice is bounded by two lips, an anterior and a posterior, of which the anterior is the shorter and thicker, although, on account of the slope of the cervix, it projects lower than the posterior. Normally both lips are in contact with the posterior vaginal wall.

Interior of the uterus (fig. 1190).—The cavity of the uterus is small in comparison with the size of the organ.

The **cavity of the body** is a mere slit, flattened from before backwards. It is triangular in shape, the base being formed by the internal surface of the fundus between the orifices of the uterine tubes, the apex by the internal orifice of the uterus; through this orifice the cavity of the body communicates with the canal of the cervix.

The **canal of the cervix** is somewhat fusiform, flattened from before backwards, and broader at the middle than at the ends. It communicates above, through the internal orifice, with the cavity of the body, and below, through the external orifice, with the vaginal cavity. The wall of the canal presents an anterior and a posterior longitudinal ridge, from each of which a number of small oblique columns, the *palmate folds*, proceed, giving the appearance of branches from the stem of a tree; to this arrangement the name *arbor vitæ uteri* is applied. The folds on the two walls are not opposed, but fit between one another so as to close the cervical canal.

The total length of the uterine cavity from the external orifice to the fundus is about 6 cm.

Ligaments.—The ligaments of the uterus are eight in number: an anterior; a posterior; two lateral or broad; two uterosacral; and two round.

The *anterior ligament* consists of the vesico-uterine fold of peritoneum, which is reflected on to the bladder from the front of the uterus, at the junction of the cervix and body.

CC-0. In Public Domain. Gurukul Kangri Collection, Haridwar

Digitized by Arya Samaj Foundation Chennai and eGangotri

The *posterior ligament* consists of the rectovaginal fold of peritoneum, which is reflected from the back of the posterior fornix of the vagina on to the front of the rectum. It forms the bottom of a deep pouch called the *recto-uterine excavation* (pouch of Douglas), which is bounded in front by the posterior wall of the body of the uterus, the supravaginal portion of the cervix uteri, and the posterior fornix of the vagina; behind, by the rectum; and laterally by two crescentic folds of peritoneum which pass backwards from the cervix uteri, one on either side of the rectum to the posterior wall of the pelvis. These folds are named the *sacrogenital or recto-uterine folds*. They contain a considerable amount of fibrous tissue and non-striped muscular fibres which are attached to the front of the sacrum and constitute the *uterosacral ligaments*.

The *two lateral or broad ligaments* (fig. 1183) pass from the sides of the uterus to the lateral walls of the pelvis. Together with the uterus they form a septum across the female pelvis, dividing that cavity into two portions. The anterior part contains the bladder; the posterior part, the rectum, and in certain conditions some coils of the small intestine. Between the two layers of each broad ligament are: (1) the uterine tube; (2) the round ligament of the uterus; (3) the ovary and its ligament; (4) the epoöphoron and paroöphoron; (5) connective tissue; (6) unstriped muscular fibres; and (7) blood-vessels and nerves. The portion of the broad ligament which stretches from the uterine tube to the level of the ovary is named the *mesosalpinx*. Between the fimbriated extremity of the uterine tube and the lower attachment of the broad ligament is a concave rounded margin, called the *infundibulopelvic ligament*.

FIG. 1191.—A sagittal section through the pelvis of a new-born female child. Some coils of the small intestine which intervened between the uterus and the bladder have been removed.

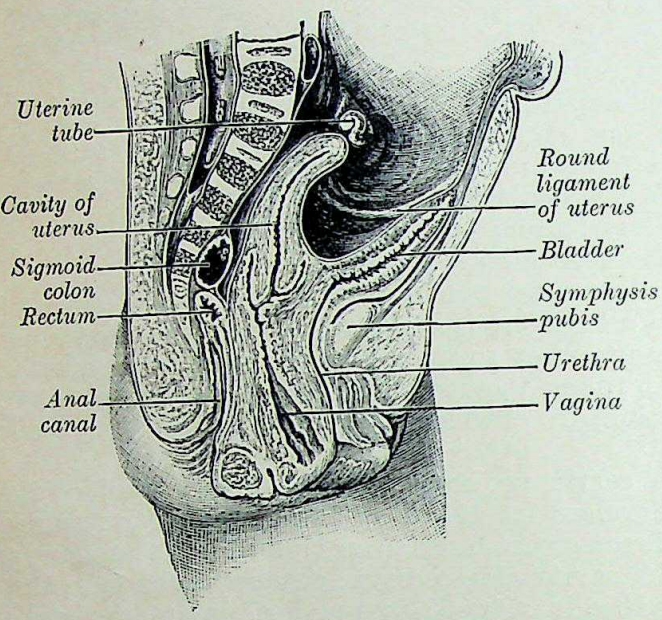

The *round ligaments* (fig. 1188) are two narrow, flat bands between 10 cm. and 12 cm. long, situated between the layers of the broad ligament in front of and below the uterine tubes. Commencing on either side at the lateral angle of the uterus, each ligament is directed forwards, upwards, and lateralwards over the external iliac vessels. It then passes through the abdominal inguinal ring and along the inguinal canal to the labium majus, in which it is lost. The round ligaments consist principally of muscular tissue prolonged from the uterus, but also contain some areolar tissue, with blood-vessels, lymphatics, and nerves, enclosed in a duplicature of peritoneum, which, in the fœtus, is prolonged in the form of a tubular process (canal of Nuck) for a short distance into the inguinal canal. The canal of Nuck is generally obliterated in the adult, but sometimes remains pervious even in advanced life. It is analogous to the saccus vaginalis which precedes the descent of the testis.

In addition to the ligaments just described, there is a band named the *ligamentum transversale colli* (Mackenrodt) on either side of the cervix uteri. It is attached to the side of the cervix uteri and to the vault and lateral fornix of the vagina, and is continuous with the fibrous tissue which surrounds the pelvic blood-vessels.

The form, size, and situation of the uterus vary at different periods of life and under different circumstances.

In the fœtus the uterus projects above the superior aperture of the pelvis (fig. 1191). The cervix is considerably larger than the body.

At puberty the uterus is pyriform in shape, and weighs from 14 to 17 gms. The fundus is just below the level of the superior aperture of the pelvis. The palmate folds are distinct, and extend to the upper part of the cavity.

CC-0. In Public Domain. Panini Kanya Maha Vidyalaya Collection, Haridwar

Digitized by Arya Samaj Foundation Chennai and eGangotri

The position of the uterus *in the adult* is liable to considerable variation, depending chiefly on the condition of the bladder and rectum. When the bladder is empty the entire uterus is directed forwards, and is at the same time bent on itself at the junction of the body and cervix, so that the body lies upon the bladder. As the latter fills, the uterus gradually becomes more and more erect, until with a fully distended bladder the fundus may be directed towards the sacrum.

During menstruation the organ is enlarged, and more vascular, and its surfaces are rounder; the external orifice is rounded, its labia swollen, and the lining membrane of the body is thicker, softer, and of a darker colour.

During pregnancy the uterus becomes enormously enlarged, and in the eighth month reaches the epigastric region. The increase in size is partly due to growth of pre-existing muscular fibres, and partly to development of new fibres.

After parturition the uterus nearly regains its usual size, weighing about 42 gm.; but its cavity is larger than in the virgin state, its vessels are tortuous, and its muscular layers are more defined; the external orifice is more marked, and its edges present one or more fissures.

FIG. 1192.—A vertical section through the mucous membrane of a human uterus. (Sobotta.)

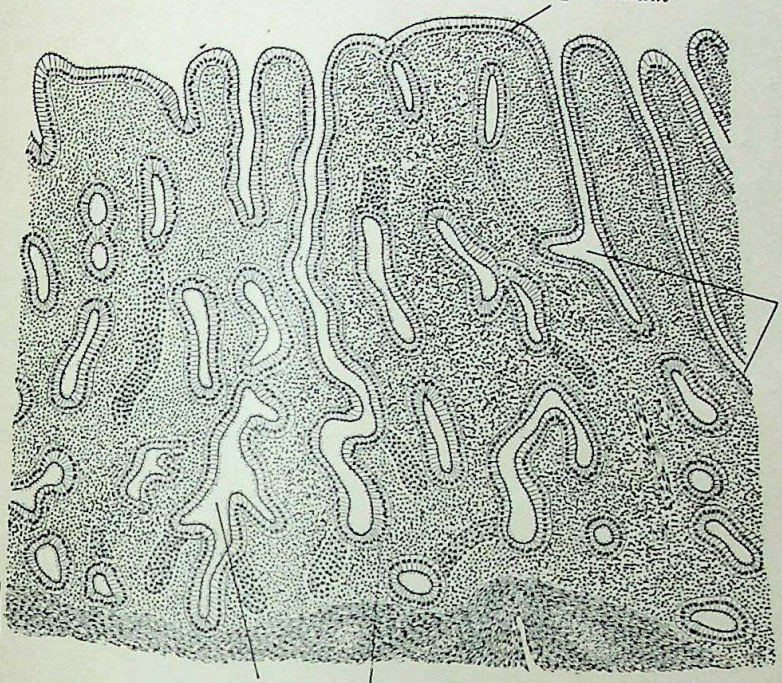

In old age the uterus becomes atrophied, and paler, and denser in texture; a more distinct constriction separates the body and cervix. The internal orifice is frequently, and the external orifice occasionally, obliterated, while the lips almost entirely disappear.

Structure.—The uterus is composed of three coats: an external or serous, a middle or muscular, and an internal or mucous.

The *serous coat* is derived from the peritoneum; it invests the fundus and the whole of the posterior or intestinal surface of the uterus; but covers the anterior or vesical surface only as far as the junction of the body and cervix. In the lower one-fourth of the intestinal surface the peritoneum is not closely connected with the uterus, being separated from it by a layer of loose cellular tissue and some large veins.

The *muscular coat* forms the chief bulk of the substance of the uterus. In the virgin it is dense, firm, of a greyish colour, and cuts almost like cartilage. It is thick opposite the middle of the body and fundus, and thin at the orifices of the uterine tubes. It consists of bundles of unstriped muscular fibres, intermixed with areolar tissue, blood-vessels, lymphatic vessels, and nerves. During pregnancy the muscular tissue becomes more prominently developed, the fibres being greatly enlarged. Although the unstriped muscular fibres interlace in all directions, they are arranged in three more or less distinct layers: external, middle and internal; the last is sometimes looked upon as a greatly hypertrophied muscularis mucosæ.

The external layer consists chiefly of longitudinal fibres which pass over the fundus, and, converging at either lateral angle of the uterus, are continued on the uterine tube, the round ligament, and the ligament of the ovary: some passing at either side into the broad ligament, and others running backwards from the cervix into the sacro-uterine ligaments. The middle layer of fibres is the thickest, but presents no regularity in its

CC-0. In Public Domain. Gurukul Kangri Collection, Haridwar

Digitized by Arya Samaj Foundation Chennai and eGangotri

arrangement, being disposed longitudinally, obliquely, and transversely; it contains the larger blood-vessels. The internal layer consists of longitudinal and circular fibres; at the internal orifice the circular fibres form a sphincter. The deep ends of the uterine glands come into close relation with the fibres of the internal layer.

The *mucous membrane*, sometimes named the *endometrium* (fig. 1192), is continuous, through the fimbriated extremities of the uterine tubes, with the peritoneum; and, through the external uterine orifice, with the lining of the vagina.

In the body of the uterus the mucous membrane is smooth, soft, of a pale red colour, and lined by columnar ciliated epithelium. The structure of the corium differs from that of ordinary mucous membranes, and consists of an embryonic nucleated and highly cellular form of connective tissue in which run numerous large lymphatics. In it are many tube-like *uterine glands*, which are lined with ciliated columnar epithelium and open into the cavity of the uterus. They are of small size in the unimpregnated uterus, but shortly after impregnation become enlarged and elongated, presenting a contorted or waved appearance.*

Fig. 1193.—The left uterine and ovarian arteries of an unmarried girl of 17½ years. Posterior aspect. (From a preparation by Hamilton Drummond.)

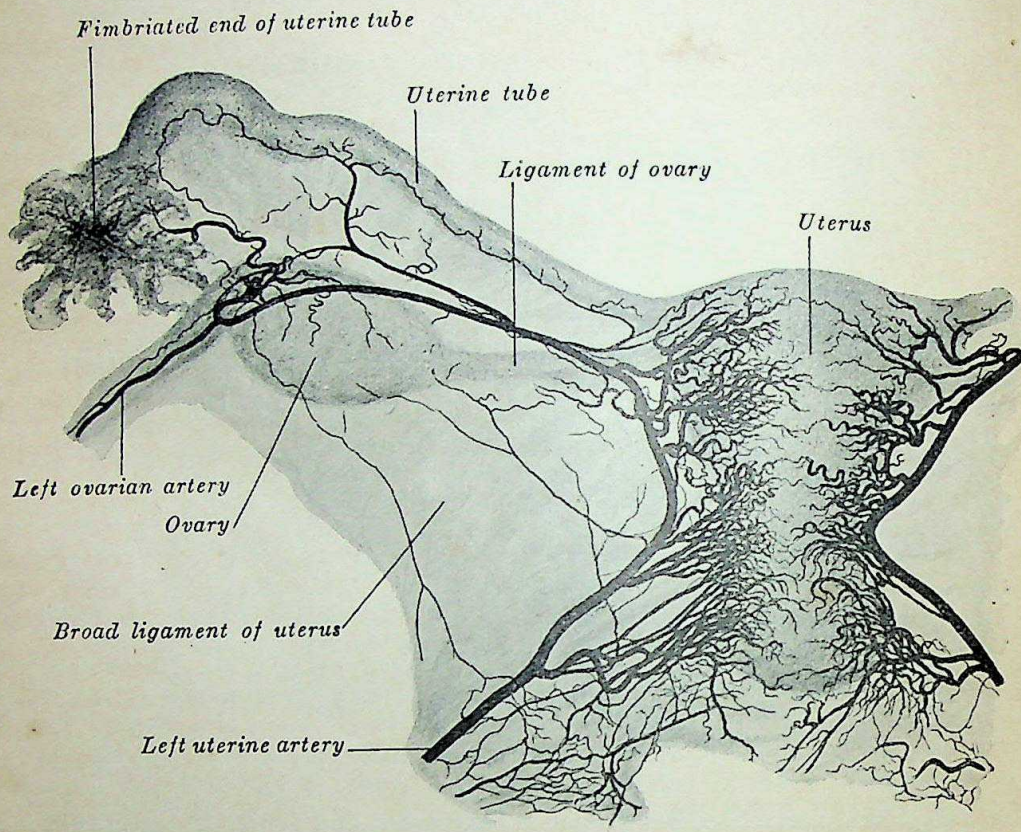

In the cervix uteri the mucous membrane is raised into two median elevations, one on the anterior, the other on the posterior, wall of the canal; from these median elevations numerous ridges (palmate folds) run upwards and lateralwards. In the upper two-thirds of the cervix, the mucous membrane is provided with numerous deep glandular follicles which secrete a clear viscid alkaline mucus; and, in addition, extending through the whole length of the canal is a variable number of little cysts, presumably follicles which have become occluded and distended with retained secretion. They are called the *ovula Nabothi*. The mucous membrane covering the lower one-half of the cervical canal presents numerous papillæ. The epithelium of the upper two-thirds is cylindrical and ciliated, but below this it loses its cilia, and, close to the external orifice, changes to stratified squamous. On the vaginal surface of the cervix the epithelium is similar to that lining the vagina, viz. stratified squamous.

Vessels and Nerves.—The *arteries* of the uterus are the uterine branch of the hypogastric artery, and the ovarian branch of the abdominal aorta (fig. 1193). They are remarkable for their tortuous course in the substance of the organ. The termination of the ovarian artery meets that of the uterine artery, and forms an anastomotic trunk from which branches are given off to supply the uterus. The *veins* are of large size, and correspond with the arteries. They end in the uterine venous plexuses. In the impregnated uterus the arteries

* Arthur Thomson (*British Medical Journal*, January 7th, 1922) discusses whether the uterine glands possess a secretory or an absorbent function.

CC-0. In Public Domain. Gurukul Kangri Collection, Haridwar

Digitized by Arya Samaj Foundation Chennai and eGangotri

carry the blood to, and the veins convey it away from, the intervillous space of the placenta (p. 66). The *lymphatics* are described on p. 774. The *nerves* are derived from the hypogastric and ovarian plexuses, and from the second, third and fourth sacral nerves.

Applied Anatomy.—A certain amount of anteversion or retroversion of the uterus can take place without the conditions being regarded as pathological, but when the degree of flexion at the junction of the body with the cervix becomes considerable it must be regarded as a morbid condition. This is especially true of retroversion combined with retroflexion. Retroversion alone is a falling back of the whole uterus, so that the cervix points forwards towards the os pubis; retroflexion is a bending backwards of the body, the cervix remaining in its normal position. The two conditions are usually combined. Prolapse of the uterus is another common infirmity. The organ sinks to an abnormally low level in the pelvis, and sometimes protrudes beyond the vulva. This is due to the supporting mechanism of the uterus being insufficient to sustain the strain thrown upon it.

In the treatment of uterine fibroids which require operative interference, removal of the whole body of the uterus, together with the tumours, with or without the cervix, through an abdominal incision, gives the most satisfactory results. After the abdomen has been opened the ovarian vessels are secured (one ovary at least being left, provided it be healthy) and the broad ligaments are divided. It will now be found that the uterus can be raised out of the pelvis, and a transverse incision is made through the peritoneum, where it is reflected from the front of the uterus on to the back of the bladder, and this viscus is separated from the surface of the uterus. The uterus is now turned forwards and the peritoneum of the recto-uterine excavation incised transversely. The uterus is now almost free, and is held only by the lower part of the broad ligament on either side, containing the uterine artery. A ligature is made to encircle this as close to the uterus as possible, the position of the ureter being always kept in mind, and, after having been tied, the structures are divided between the ligature and the uterus. The body of the uterus can now be removed by cutting it across at its junction with the cervix, or if desired the vaginal wall can be incised both front and back and the cervix removed together with the body. The peritoneum is finally sewn up carefully across the floor of the pelvis, with a transverse line of suture from one uterine tube to the other, so as to leave no raw surface to which small intestine can adhere.

Inflammation of the cellular tissue surrounding the cervix occasionally takes place. Laceration of the cervix by instruments or by the fœtal head frequently occurs, opening up the cellular planes and so exposing them to any infection that may be present. An inflammatory mass forms in the cellular tissue between the layers of the broad ligament or of the uterosacral ligaments, and the condition is termed *pelvic cellulitis*, or *parametritis*. This condition is usually confined to one side of the pelvis, forming a large inflammatory mass which pushes the uterus over to the opposite side. It does not always remain localised, however, but may spread widely, surrounding the rectum or the neck of the bladder, or mounting into the iliac fossa, or even to the perinephric cellular tissue. The condition may resolve or an abscess may form. In the former condition the cicatrisation of the inflammatory products produces displacements of the uterus towards the affected side of the pelvis, or may result in stricture of the rectum when that viscus has been surrounded by the process. When suppuration ensues, the pus may burst into the bladder, vagina, or rectum, or it may present above the inguinal ligament, or it may mount to the anterior abdominal wall in front of the bladder or to the posterior abdominal wall between the iliac crest and last rib. The abscess may, moreover, make its way into the buttock by passing out of the pelvis through the greater sciatic foramen, or it may pass down between the fibres of the Levator ani and appear as a secondary ischiorectal abscess.

The Vagina (fig. 1189)

The **vagina** is a canal which extends from the vestibule or cleft between the labia minora to the uterus, and is situated behind the bladder and in front of the rectum; it is directed upwards and backwards, its axis forming with that of the uterus an angle of over ninety degrees, opening forwards, but the angle varies with the conditions of the bladder and rectum. Its walls are ordinarily in contact, and the usual shape of its lower part on transverse section is that of an **H**, the transverse limb being slightly curved forwards or backwards, while the lateral limbs are somewhat convex towards the median line; its middle part has the appearance of a transverse slit. Its length is 7·5 cm. along its anterior wall, and 9 cm. along its posterior wall; its width gradually increases from below upwards. Its upper end surrounds the vaginal portion of the cervix uteri, a short distance from the external orifice of the uterus, its attachment extending higher on the posterior than on the anterior wall of the uterus. To the recess behind the cervix uteri the term *posterior fornix* is applied, while the smaller recesses at the sides and in front are called the *lateral* and *anterior fornices*.

CC-0. In Public Domain. Gurukul Kangri Collection, Haridwar

Digitized by Arya Samaj Foundation Chennai and eGangotri

The *anterior wall* of the vagina is in relation with the fundus of the bladder, and with the urethra. Its *posterior wall* is separated from the rectum by the recto-uterine excavation in its upper one-fourth, and by some connective tissue in its middle two-fourths; the lower one-fourth is separated from the anal canal by a mass of muscular and fibrous tissue, named the *perinœal body*. Its sides are enclosed between the Levatores ani muscles. As the terminal portions of the ureters pass forwards and medialwards to reach the fundus of the bladder, they run close to the lateral fornices of the vagina, and as they enter the bladder are usually placed in front of the vagina (p. 1201*).

Structure.—The vagina consists of an internal mucous lining and a muscular coat, separated by a layer of erectile tissue.

The *mucous membrane* is firmly fixed to the muscular coat; on its free surface there are two longitudinal ridges, one on the anterior and the other on the posterior wall of the vagina. These ridges are called the *columns of the vagina*, and from them numerous transverse ridges or rugæ extend lateralwards on either side. These rugæ are divided by furrows of variable depth, giving to the mucous membrane the appearance of being studded over with conical projections or papillæ; they are most numerous near the orifice of the vagina, especially before parturition. The epithelium of the mucous membrane is of the stratified squamous variety. The mucous coat contains a number of mucous crypts, but no true glands.

The *muscular coat* consists of two layers: an external longitudinal, which is by far the stronger, and an internal circular layer. The longitudinal fibres are continuous with the superficial muscular fibres of the uterus. The strongest fasciculi are those attached to the rectovesical fascia on either side. The two layers are not distinctly separable from each other, but are connected by oblique decussating fasciculi, which pass from the one layer to the other. In addition to this, the lower end of the vagina is surrounded by a band of striped muscular fibres, the *Bulbocavernosus* (Sphincter vaginæ) (p. 491).

External to the muscular coat is a layer of connective tissue, containing a large plexus of blood-vessels.

The *erectile tissue* is situated between the mucous membrane and the muscular coat; it consists of a layer of loose connective tissue, imbedded in which is a plexus of large veins, and numerous bundles of unstriped muscular fibres, derived from the circular muscular layer. The arrangement of the veins is similar to that found in other erectile tissues.

Vessels and Nerves.—The *arteries* of the vagina are derived from the vaginal, uterine, internal pudendal, and middle hæmorrhoidal branches of the hypogastric arteries. The *veins* form plexuses at the sides of the vagina, and these plexuses are drained through the vaginal veins into the hypogastric veins. The *lymphatics* are described on p. 774. The *nerves* are derived from the vaginal plexuses, and from the second, third and fourth sacral spinal nerves.

The External Genital Organs of the Female (fig. 1194)

The **external genital organs of the female** are: the mons pubis, the labia majora et minora pudendi, the clitoris, the vestibule of the vagina, the bulb of the vestibule, and the greater vestibular glands. The term *pudendum* or *vulva*, as generally applied, includes all these parts.

The **mons pubis** (mons Veneris), the rounded eminence in front of the pubic symphysis, is formed by a collection of fatty tissue beneath the skin. It becomes covered with hair at the time of puberty.

The **labia majora** are two prominent longitudinal cutaneous folds which extend downwards and backwards from the mons pubis, and form the lateral boundaries of a fissure or cleft, the *pudendal cleft or rima*, into which the vagina and urethra open. Each labium has two surfaces, an outer, pigmented and covered with crisp hairs; and an inner, smooth and beset with large sebaceous follicles. Between the two surfaces there is a considerable quantity of areolar tissue, fat, and a tissue resembling the dartos tunic of the scrotum, besides vessels, nerves, and glands. The labia are thicker in front, where they form by their meeting the *anterior labial commissure*. Posteriorly they are not really joined, but appear to become lost in the neighbouring integument, ending close to, and nearly parallel with, each other; together with the connecting skin between them, they form the *posterior labial commissure*, or posterior boundary of the pudendum. The interval between the posterior commissure and the anus, from 2·5 cm. to 3 cm. in length, constitutes the gynæcological perinæum.

The **labia minora** are two small cutaneous folds, situated between the labia

CC-0. In Public Domain. Gurukul Kangri Collection, Haridwar

Digitized by Arya Samaj Foundation Chennai and eGangotri

majora, and extending from the clitoris obliquely downwards, lateralwards, and backwards for about 4 cm. on either side of the orifice of the vagina, between which and the labia majora they end; in the virgin the posterior ends of the labia minora are usually joined across the middle line by a fold of skin, named the *frenulum of the labia*, or *fourchette*. Anteriorly, each labium minus divides into two portions: the upper division passes above the clitoris to meet its fellow of the opposite side, forming a fold which overhangs the glans clitoridis, and is named the *præputium clitoridis*; the lower division passes beneath the clitoris and is united to its under surface, forming, with its fellow of the opposite side, the *frenulum clitoridis*. On the opposed surfaces of the labia minora are numerous sebaceous follicles.

FIG. 1194.—The external genital organs of the female. The labia have been drawn apart.

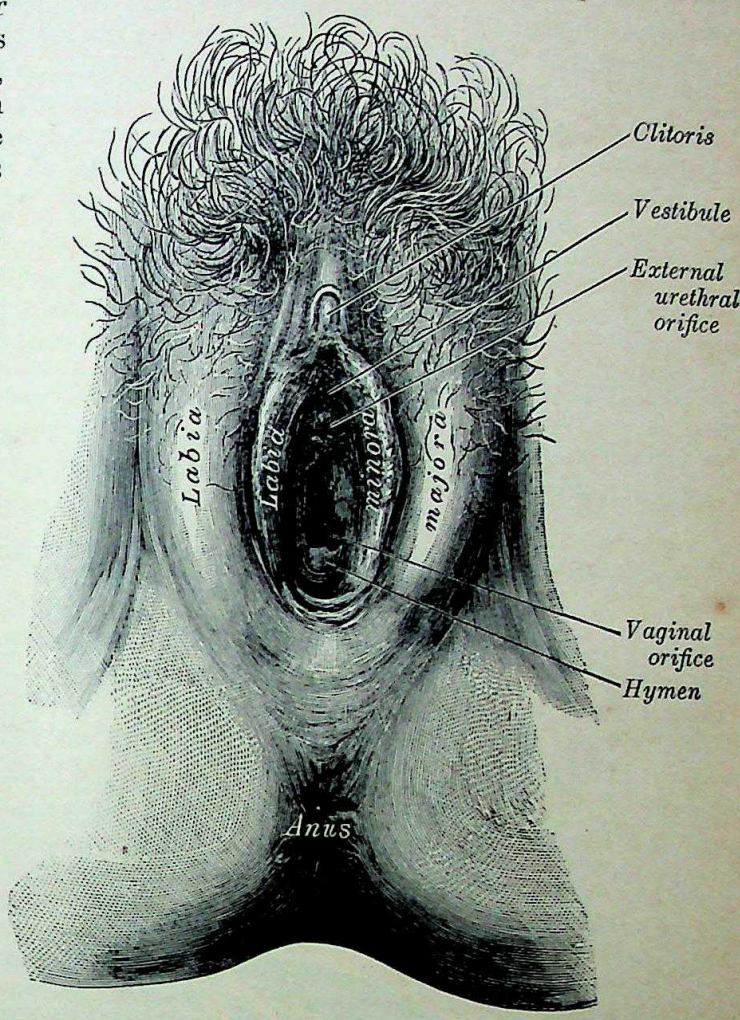

The **vestibule.**—The cleft between the labia minora is named the *vestibule of the vagina*: in it are the vaginal and external urethral orifices and the openings of the ducts of the greater vestibular glands. The part of the vestibule between the vaginal orifice and the frenulum of the labia minora consists of a shallow depression named the *navicular fossa*.

The **clitoris** is an erectile structure, homologous with the penis. It is situated beneath the anterior labial commissure, partially hidden between the anterior ends of the labia minora. The *body of the clitoris* (corpus clitoridis) consists of two corpora cavernosa, composed of erectile tissue enclosed in a dense layer of fibrous membrane, and separated along their medial surfaces by an incomplete fibrous pectiniform septum; each corpus cavernosum is connected to the pubic and ischial rami by a *crus*. The free extremity, or *glans clitoridis*, is a small rounded tubercle, consisting of spongy erectile tissue, and highly sensitive. The clitoris is provided, like the penis, with a suspensory ligament, and with two small muscles, the Ischiocavernosi, which are inserted into the crura of the clitoris.

The **vaginal orifice** is a median slit below and behind the opening of the urethra; its size varies inversely with that of the *hymen*.

The **hymen** is a thin fold of mucous membrane situated at the orifice of the vagina; the inner surfaces of the fold are normally in contact with each other, and the vaginal orifice appears as a cleft between them. The hymen varies much in shape. When stretched, its commonest form is that of a ring, generally broadest posteriorly; sometimes it is represented by a semilunar fold, with its concave margin turned towards the pubes. Occasionally it is cribriform, or its free margin forms a membranous fringe. It may be entirely absent, or may form a complete septum across the lower end of the vagina; the latter condition is known as an imperforate hymen. When the hymen has been ruptured, small rounded elevations known as the *carunculæ hymenales* are found as its remains.

CC-0. In Public Domain. Gurukul Kangri Collection, Haridwar

Digitized by Arya Samaj Foundation Chennai and eGangotri

The **external urethral orifice** is placed about 2·5 cm. behind the glans clitoridis and immediately in front of the orifice of the vagina: it usually assumes the form of a short, sagittal cleft with slightly raised margins.

The **bulb of the vestibule** is the homologue of the urethral bulb and adjoining part of the corpus cavernosum urethræ of the male, and consists of two elongated masses of erectile tissue, placed one on either side of the vaginal orifice and united to each other in front by a narrow median band termed the *pars intermedia*. Each lateral mass measures about 3 cm. in length. Their posterior ends are expanded and are in contact with the greater vestibular glands; their anterior ends are tapered and joined to one another by the pars intermedia; their deep surfaces are in contact with the inferior fascia of the urogenital diaphragm; superficially they are covered by the Bulbocavernosus.

The **greater vestibular glands** (glands of Bartholin) are the homologues of the bulbo-urethral glands in the male. They consist of two small, round or oval bodies of a reddish-yellow colour, situated one on either side of the vaginal orifice, in contact with the posterior end of each lateral mass of the bulb of the vestibule. Each gland opens by means of a duct, about 2 cm. long, immediately lateral to the hymen, in the groove between its attached border and the labium minus.

The Mammæ

The **mammæ** or **breasts** secrete the milk, and are accessory glands of the generative system. They exist in the male as well as in the female, but in the former only in the rudimentary state. In the female they are two large hemispherical eminences lying within the superficial fascia on the front and

Fig. 1195.—A dissection of the lower half of the mamma during the period of lactation. (Luschka.)

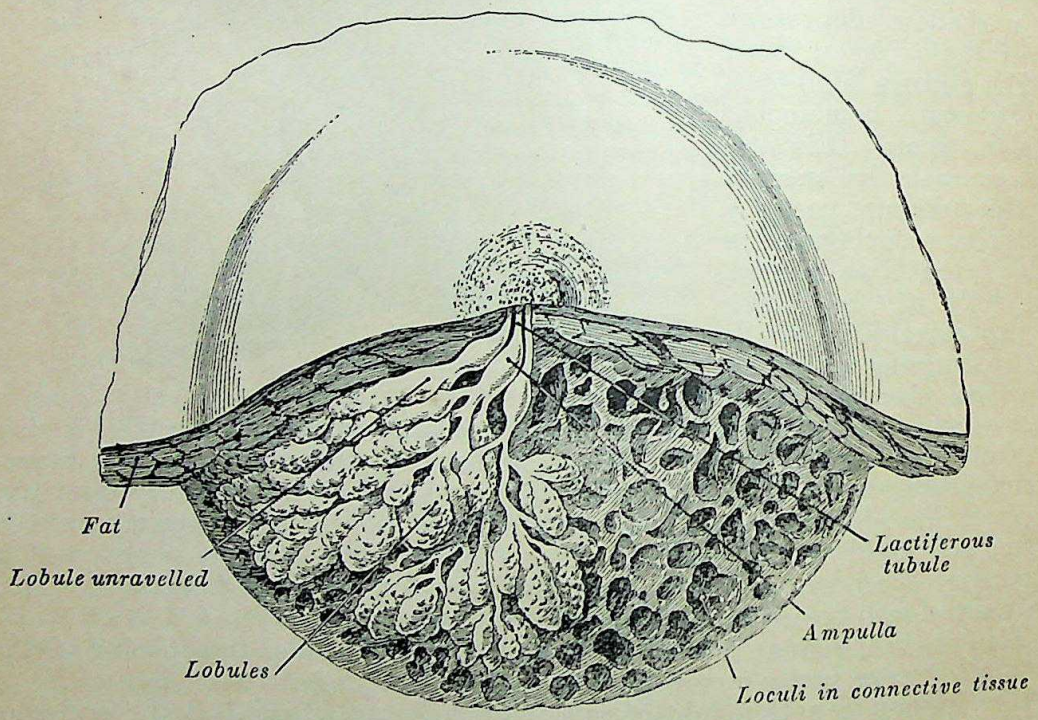

sides of the chest; each extends from the second rib above to the sixth rib below, and from the side of the sternum to near the mid-axillary line. In weight and size they differ at different periods of life, and in different individuals. Before puberty they are small, but they enlarge as the generative organs become more completely developed. They increase during pregnancy, and especially after delivery, and become atrophied in old age. The deep surface of each is nearly circular, flattened, or slightly concave, and has its long diameter directed upwards and lateralwards towards the axilla; it is separated from the fascia covering the Pectoralis major, Serratus anterior, and Obliquus externus

CC-0. Panini Kanya Maha Vidyalaya Collection. Haridwar

Digitized by Arya Samaj Foundation Chennai and eGangotri

abdominis by loose connective tissue. The subcutaneous surface of the mamma is convex, and presents, just below the centre, a small conical prominence, the papilla.

The mammary papilla or nipple is a cylindrical or conical eminence situated about the level of the fourth intercostal space. It is capable of undergoing a sort of erection from mechanical excitement, a change mainly due to the contraction of its muscular fibres. It is of a pink or brownish hue, its surface wrinkled and provided with secondary papillæ; and it is perforated by from fifteen to twenty orifices, the apertures of the lactiferous ducts. The base of the mammary papilla is encircled by a coloured area of skin called the *areola*. In the virgin the areola is of a delicate rosy hue; about the second month after impregnation it enlarges and acquires a darker tinge, and as pregnancy advances it may assume a dark brown, or even black colour. This colour diminishes as soon as lactation is over, but is never entirely lost. These changes in the colour of the areola are of importance in forming a conclusion in a case of suspected first pregnancy. Near the base of the papilla, and upon the surface of the areola, are numerous sebaceous glands, the *areolar glands*, which become much enlarged during lactation and present the appearance of small tubercles beneath the skin; they secrete a peculiar fatty substance, which serves as a protection to the skin of the papilla. The mammary papilla consists of numerous vessels, intermixed with plain muscular fibres, which are principally arranged in a circular manner around the base, but a few fibres radiate from base to apex.

Structure (figs. 1195 to 1197).—The mamma consists (*a*) of gland-tussue; (*b*) of fibrous tissue, connecting its lobes; and (*c*) of fatty tissue in the intervals between the lobes. The subcutaneous tissue encloses the mamma and sends numerous septa into it to support its various lobules. From that part of the fascia which covers the mamma fibrous processes pass forwards to the skin and the mammary papilla; these are named by Sir A. Cooper the *ligamenta suspensoria*. The gland-tissue is of a pale reddish colour, firm in texture, and forms a lobulated mass which is flattened from before backwards and thicker in the centre than at the circumference. It consists of numerous lobes, and these are composed of lobules, connected together by areolar tissue, blood-vessels, and ducts. The smallest lobules

FIG. 1196.—Horizontal section of the mammary gland at the level of the nipple in a multiparous female, aged forty years. (Stiles.) (From Quain's Anatomy, vol. iii. part iv.)

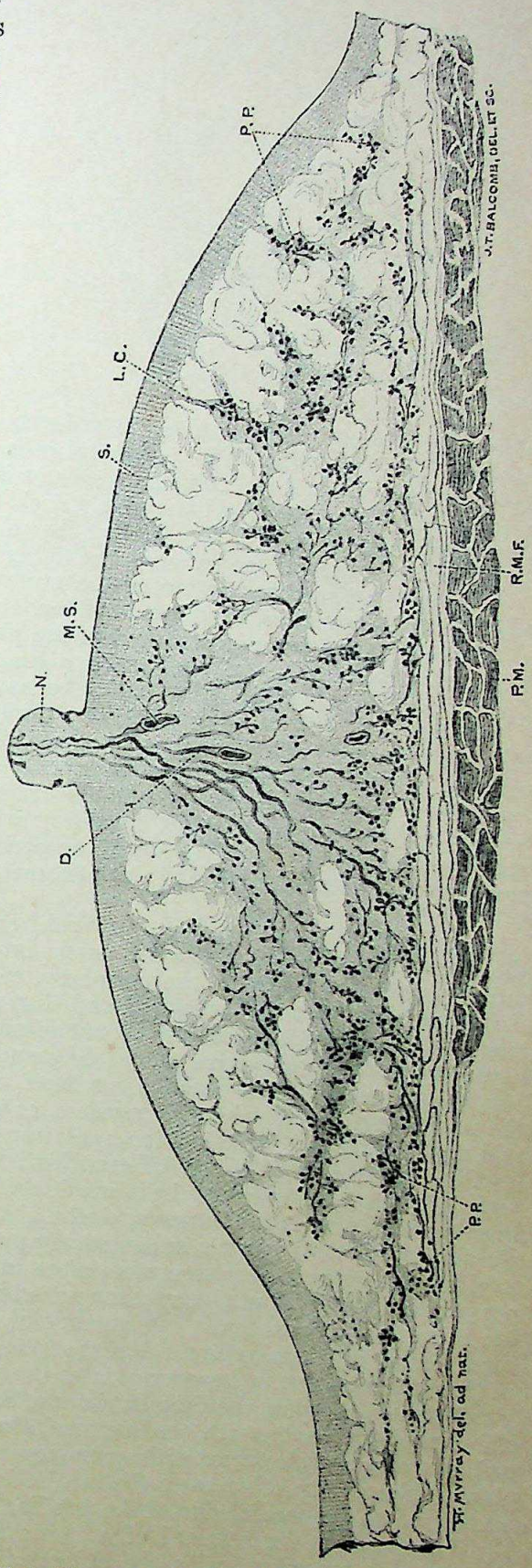

D. lactiferous tubule; L.C. ligament of Cooper; M.S. Ampulla of lactiferous tubule; N. mammary papillæ or nipple; R.M. Pectoralis major; P.P. peripheral processes; R.M.F. retromammary fat; S. skin.

CC-0. In Public Domain. Gurukul Kangri Collection, Haridwar

Digitized by Arya Samaj Foundation Chennai and eGangotri

consist of a cluster of rounded alveoli which open into the smallest branches of the lactiferous ducts; these branches unite to form larger ducts which end in the excretory ducts or *tubuli lactiferi*. The tubuli lactiferi vary from fifteen to twenty in number; they converge towards the areola, beneath which they form dilatations, or *ampullæ*, which serve as reservoirs for the milk. At the base of the papilla they become contracted, and pursue a straight course to its summit, perforating it by separate orifices considerably narrower than the ducts themselves. The ducts are composed of areolar tissue containing longitudinal and transverse elastic fibres; they are lined by columnar epithelium resting on a basement-membrane. The epithelium of the alveoli differs according to the state of activity of the organ. In the gland of a woman who is not pregnant or suckling, the alveoli are very small and solid, being filled with a mass of granular polyhedral cells. During pregnancy the alveoli enlarge, and the cells undergo rapid multiplication. At the commencement of lactation, the cells in the centre of the alveolus undergo fatty degeneration, and are eliminated in the first milk, as *colostrum corpuscles*. The peripheral cells of the alveolus remain, and form a single layer of granular, short columnar cells, with spherical nuclei, lining the basement-membrane. When the gland is active, oil globules are found in the alveolar cells and are discharged into the lumen, constituting the milk-globules. When the acini are distended by the accumulation of the secretion the lining epithelium becomes flattened.

Fig. 1197.—A section through a portion of the mamma.

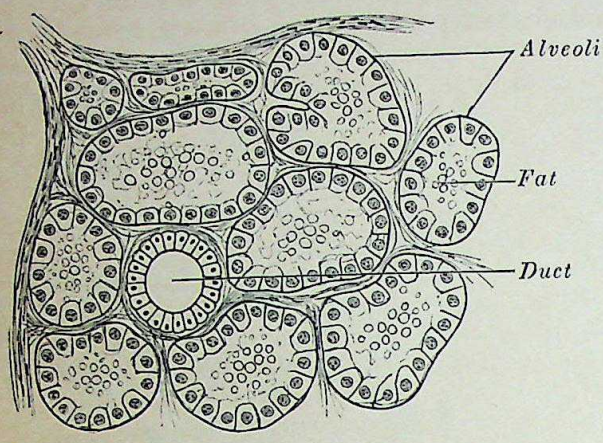

The *fibrous tissue* invests the entire surface of the mamma, and sends down septa between its lobes, connecting them together.

The *fatty tissue* covers the surface of the gland, and occupies the interval between its lobes. It usually exists in considerable abundance, and determines the form and size of the gland. There is no fat immediately beneath the areola and papilla.

Vessels and Nerves.—The *arteries* supplying the mamma are derived from the thoracic branches of the axillary artery, and from the internal mammary and intercostal arteries. The *veins* describe an anastomotic circle round the base of the papilla, called by Haller the *circulus venosus*. From this circle, branches transmit the blood to the circumference of the gland, and end in the axillary and internal mammary veins. The *lymphatics* are described on p. 777. The *nerves* are derived from the anterior and lateral cutaneous branches of the fourth, fifth, and sixth thoracic nerves.

Applied Anatomy.—The ducts descending from the mammary papilla radiate through the gland, and when an incision is made into the breast the scalpel should be directed radially, from the centre to the periphery, so that it may not pass across the ducts. A milk duct may become obstructed and distended, forming a tumour known as a *galactocele*. Abscess frequently occurs about the mamma, more often in women who are lactating, especially in those who have cracks or fissures about the papilla. The abscess may be between the septa, in the gland-tissue itself, or it may lie beneath the skin by the side of the papilla and superficial to the mamma, or it may form beneath the mamma, between it and the deep fascia. Free incision, radiating from the papilla, is required in such cases.

Cystic formation of many different kinds is commonly seen in the mamma; in some cases it is due to dilatation of the larger ducts or of the lymph-spaces throughout the gland; in others the cysts occur in new growths of the mamma, or as the result of obstruction of the smaller ducts by chronic inflammatory processes.

Malignant growths are seen more often in the mamma than in any other organ; they are of great variety, but the commonest is the spheroidal-celled cancer, the cells of which are intermingled with a varying amount of fibrous tissue. A hard contracting tumour-mass results, which drags on the fibrous septa between the lobes so that fixation or retraction of the papilla ensues, and sooner or later the malignant infiltration invades the surrounding gland-tissues, the skin, the deep fascia and Pectorales, and even the chest-wall and pleura. The lymph-glands beneath the Pectorales and those situated towards the apex of the axilla become early involved with secondary malignant deposit, and later the supraclavicular glands enlarge. In other cases the mediastinal glands may be involved, when the disease is situated on the medial side of the papilla.

The operation for removal of a mamma affected with malignant disease should be an extensive procedure, with the object of extirpating all fascial planes and lymphatic structures that may become infected. The incision commences below, over the upper part of the sheath of the Rectus, encloses the mamma by an ellipse, and is then continued on towards the apex of the axilla. The loss of blood can be diminished by planning the

CC-0. In Public Domain. Gurukul Kangri Collection, Haridwar

Digitized by Arya Samaj Foundation Chennai and eGangotri

operation so as to ligature the branches of the axillary artery near their origins, and the perforating branches of the internal mammary as they come through the intercostal muscles. This is done by first clearing the axillary vein and ligaturing the subscapular, the lateral thoracic, and the thoraco-acromial arteries as they appear. The pectoralis major and minor are divided close to their insertions, and turned medialwards so as to expose the perforating arteries as they come through the intercostal muscles before entering the pectoral muscle. The reflection of the skin, which has not yet been completed, and the removal of the pectoralis major now give rise to very little bleeding. The wound is then closed, drainage is provided, and firm pressure is applied with the dressings. It will be noted that the clavicular portion of the Pectoralis major is left intact, as it is of considerable service for the subsequent movements of the arm, the utility of which is but slightly impaired.

THE DUCTLESS GLANDS*

The **ductless glands** are distinguished from other glands by the fact that they have no ducts, the products of their activity being discharged into the blood either directly, or indirectly through the lymphatic vessels. Each of these glands produces an *internal secretion* which contains one or more active substances or *hormones*,† and is distributed to other organs and tissues by the blood-stream. In some of the other glands of the body, groups of cells are present which exhibit all the characteristics of the ductless glands, i.e. their secretions are not discharged through the gland-ducts but are carried off in the blood-vessels or lymphatics ; important examples of these are the cell-islets of the pancreas (p. 1180), the interstitial cells of the testes (p. 1212) and ovaries (p. 1226), and the glands of the stomach (p. 1151) and duodenum (p. 1160).

The products of the ductless glands differ so greatly from one another that, with the exception of the chromaffin group, it is impossible to classify them physiologically. For descriptive purposes, however, they may be grouped according to the systems from which they mainly originate, thus :

1. Developed chiefly from the digestive tube.
   - Thyreoid gland.
   - Parathyreoid glands.
   - Thymus.
2. Developed chiefly from the neural tube.
   - (*a*) From the brain.
     - Pineal body (p 836).
     - Hypophysis (p. 838).
       - Posterior lobe from neural tube.
       - Anterior lobe from buccal ectoderm.
   - (*b*) From the sympathetic system.
     - Paraganglia.
     - Suprarenal glands.
       - Medulla from sympathetic system.
       - Cortex from cœlomic epithelium.
3. Developed chiefly from the vascular system.
   - Lymph and hæmolymph glands.
   - Glomus coccygeum.
   - Spleen (partly from cœlomic epithelium).

THE THYREOID GLAND (fig. 1198)

The **thyreoid gland** is a highly vascular organ, situated at the front and sides of the lower part of the neck, opposite the fifth, sixth and seventh cervical vertebræ. It is ensheathed by the pretracheal layer of the fascia colli, and

*The term "endocrine organs" is commonly used to designate glands and tissues which produce internal secretions.

† Sharpey Schafer proposes the term "hormones" for these substances, and divides them into *hormones* excitatory secretions and *chalones* or inhibitory secretions.

CC-0. In Public Domain. Gurukul Kangri Collection, Haridwar

Digitized by Arya Samaj Foundation Chennai and eGangotri

consists of right and left lobes connected across the middle line by a narrow portion, the *isthmus*. Its weight is somewhat variable, but is usually about 30 gm. It is slightly heavier in the female, in whom it becomes enlarged during menstruation and pregnancy.

The *lobes* are conical in shape, the apex of each being directed upwards and lateralwards as far as the junction of the middle with the lower one-third of the thyreoid cartilage; the base is on a level with the fifth or

FIG. 1198.—Dissection of the lower part of the neck, and the upper part of the thorax. Anterior aspect.

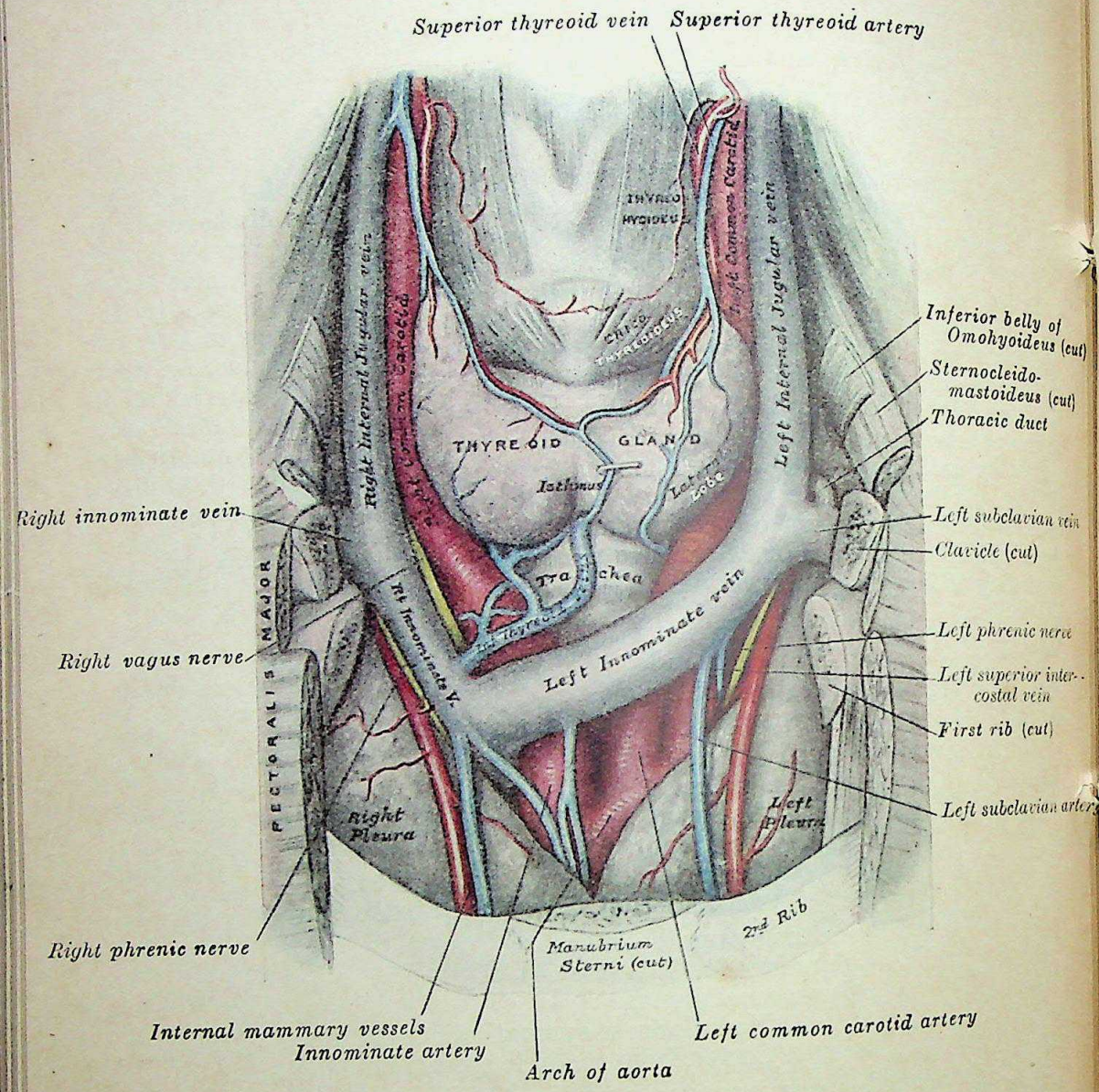

sixth tracheal ring. Each lobe is about 5 cm. long; its greatest width is about 3 cm., and its thickness about 2 cm. The *lateral or superficial surface* is convex, and covered by the skin, the superficial and deep fasciæ, the Sternocleidomastoideus, the superior belly of the Omohyoideus, the Sternohyoideus and Sternothyreoideus, and beneath the last muscle by the pretracheal layer of the deep fascia, which forms a capsule for the gland. The *medial surface* is moulded over the thyreoid and cricoid cartilages, the trachea, the Constrictor pharyngis inferior and posterior part of the Cricothyreoideus, the œsophagus (particularly on the left side of the neck), the superior and inferior thyreoid arteries, and the recurrent nerve. The *posterior surface* overlaps the common carotid artery, and, as a rule, the parathyreoid glands. The *anterior border* is thin, and inclines obliquely from above downwards towards the middle line of the neck.

CC-0. In Public Domain. Gurukul Kangri Collection, Haridwar

Digitized by Arya Samaj Foundation Chennai and eGangotri

The *isthmus* connects together the lower parts of the two lobes; it measures about 1·25 cm. transversely, and the same vertically, and usually covers the second, third and fourth rings of the trachea. Its situation and size present, however, many variations. It is covered by the skin and fascia, and close to the middle line, on either side, by the Sternothyreoideus. Across its upper border runs an anastomotic branch uniting the two superior thyreoid arteries; at its lower border are the inferior thyreoid veins. Sometimes the isthmus is altogether wanting.

A third lobe, of conical shape, called the *pyramidal lobe*, frequently extends from the upper part of the isthmus, or from the adjacent portion of either lobe, but most commonly the left, to the hyoid bone. It is occasionally quite detached, or may be divided into two or more parts.

A fibrous or muscular band is sometimes found attached, above, to the body of the hyoid bone, and below, to the isthmus of the gland, or its pyramidal lobe; when muscular, it is termed the *Levator glandulæ thyreoideæ*.

Small detached portions of thyreoid tissue are sometimes found in the vicinity of the lateral lobes or above the isthmus; they are called *accessory thyreoid glands*.

Structure.—The thyreoid gland is closely invested by a thin capsule of connective tissue, which sends incomplete septa into its substance, dividing it into masses of irregular form and size. The gland is of a brownish-red colour, and is made up of a number of closed vesicles, just visible to the naked eye, containing a yellow glairy fluid, and separated from each other by intermediate connective tissue (fig. 1198).

The vesicles of the thyreoid of the adult are generally closed spherical sacs; but in some young animals (e.g. dogs) they are more or less tubular and branched. Each is lined by a single layer of cubical epithelium. There does not appear to be a basement-membrane, so that the epithelial cells are in direct contact with the connective tissue reticulum. The vesicles are of various sizes, and contain a viscid, homogeneous, semi-fluid, slightly yellowish, colloid material; red blood-corpuscles are found in various stages of disintegration and decolorisation, the yellow tinge being probably due to hæmoglobin, which is set free from the corpuscles. The colloid material contains an iodine compound, *iodothyrin*, and, when coagulated by hardening reagents, is readily stained by eosin and other dyes. It passes out between the cubical cells and is absorbed into the blood or lymph.

Fig. 1199.—A section through the thyreoid gland of a sheep. × 160.

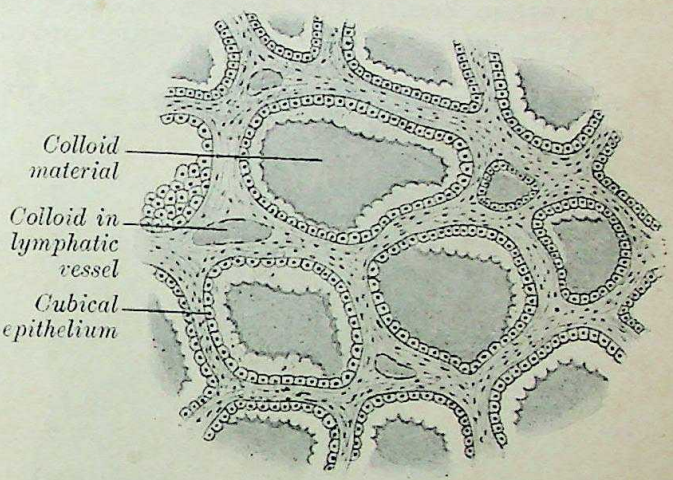

Vessels and Nerves.—The *arteries* supplying the thyreoid gland are the superior and inferior thyreoid arteries; sometimes there is an additional branch (a. thyreoidea ima) from the innominate artery or the arch of the aorta, which ascends upon the front of the trachea. The arteries are remarkable for their large size and frequent anastomoses. The *veins* form a plexus on the surface of the gland and on the front of the trachea; from this plexus the superior, middle, and inferior thyreoid veins arise; the superior and middle end in the internal jugular vein, the inferior in the innominate vein. The capillary blood-vessels form a dense plexus in the connective tissue around the vesicles, between the epithelium of the vesicles and the endothelium of the lymphatics which surround a greater or smaller part of the circumference of the vesicle. The *lymphatic vessels* run in the interlobular connective tissue, not uncommonly surrounding the arteries which they accompany and communicate with a network in the capsule of the gland; they may contain colloid material. They end in the thoracic duct and the right lymphatic trunk. The *nerves* are derived from the middle and inferior cervical ganglia of the sympathetic.

Applied Anatomy.—The secretion of the thyreoid gland has a profound influence over metabolic processes generally, and exercises its effects on the whole autonomic nervous system.

When the gland is congenitally absent, or has undergone atrophy in early life, the physical and mental development of the body is greatly interfered with, and a form of dwarfism with mental deficiency, named cretinism, results. If, during adult life, atrophy

CC-0. In Public Domain. Gurukul Kangri Collection, Haridwar

Digitized by Arya Samaj Foundation Chennai and eGangotri

of the gland occurs, or the whole gland be removed by operation the condition known as myxœdema is brought about; this is characterised by marked apathy, dulling of all the bodily and mental functions, and the deposit of mucoid material in the subcutaneous tissues.

The effects of hyperactivity of the gland are well seen in exophthalmic goitre, a condition in which the outstanding symptoms are enlargement of the thyreoid gland, persistent tachycardia, tremor, and exophthalmos (protrusion of the eyeballs). Any enlargement of the thyreoid gland is called a goitre. The swelling may take the form of a diffuse hypertrophy of the whole gland, giving rise to the *parenchymatous goitre*, this being mainly due to the hypertrophy of the thyreoid follicles themselves; in other cases a *fibroid* form of goitre is produced owing to the increase in the interstitial connective tissue; in others, again, the vascular changes may preponderate, and many large pulsating vessels may be present. Much more commonly, however, the enlargement is due to adenomatous new growth in the substance of the thyreoid; these tumours are usually innocent, and tend to destroy life only by pressure on the air-passages. A single tumour is the rule, but in some instances a very large number may be present. They tend to show marked mucoid degeneration, and so become converted into cystadenomata, and finally into what appear to be simple cysts. These tumours may attain an enormous size and may involve practically the whole gland. Malignant tumour-growth more rarely attacks the organ.

When a goitre continues to grow, and especially when there are commencing symptoms of tracheal pressure, operative interference becomes necessary. This is not difficult, if an encapsuled tumour is to be dealt with, provided the anatomical layers covering it are remembered. In such a case it is necessary to make an incision suited to the size and situation of the tumour, and having divided the deep cervical fascia, to retract the Sterno-cleidomastoideus or divide it if necessary. The Sternohyoideus and Sternothyreoideus next require division, or in some cases their fibres may be separated and drawn asunder, and beneath is found the ensheathing capsule derived from the pretracheal fascia; this requires division, and exposes the true capsule of the thyreoid gland. In the case of an adenoma or cyst, this true capsule then needs incision before the tumour can be effectually shelled out, and this is usually accomplished with very little hæmorrhage, and without any of the main vessels of the gland requiring ligature.

Partial extirpation of the thyreoid, viz. the removal of one lateral lobe with division of the isthmus, may be required in cases of parenchymatous goitre, and in the diffuse form of adenomatous disease. It is a more radical proceeding, and carries with it a much greater risk from hæmorrhage; there is also a danger of wounding the recurrent nerve. The whole gland must never be removed, as such a procedure is followed by the development of myxœdema. In hemithyreoidectomy a free incision is indicated—dividing muscles, if necessary—to expose the true gland capsule, but at the same time avoiding injury to the large vessels which lie beneath it. The superior and inferior pedicles containing the respective thyreoid arteries are then isolated and clamped on either side and divided between the clamps. The half gland is then turned over towards the middle line, and the isthmus ligatured and divided. Some venous bleeding is apt to occur from connexions with the tracheal veins, and must be stopped. The pedicles are then securely ligatured and the wound closed. In dealing with the inferior thyreoid artery, the position of the recurrent nerve must be borne in mind, so as not to ligature or divide it. Temporary aphonia not uncommonly follows from bruising of the nerve, and if nothing more serious has occurred soon passes off.

Fig. 1200.—The parathyreoid glands. Posterior aspect.

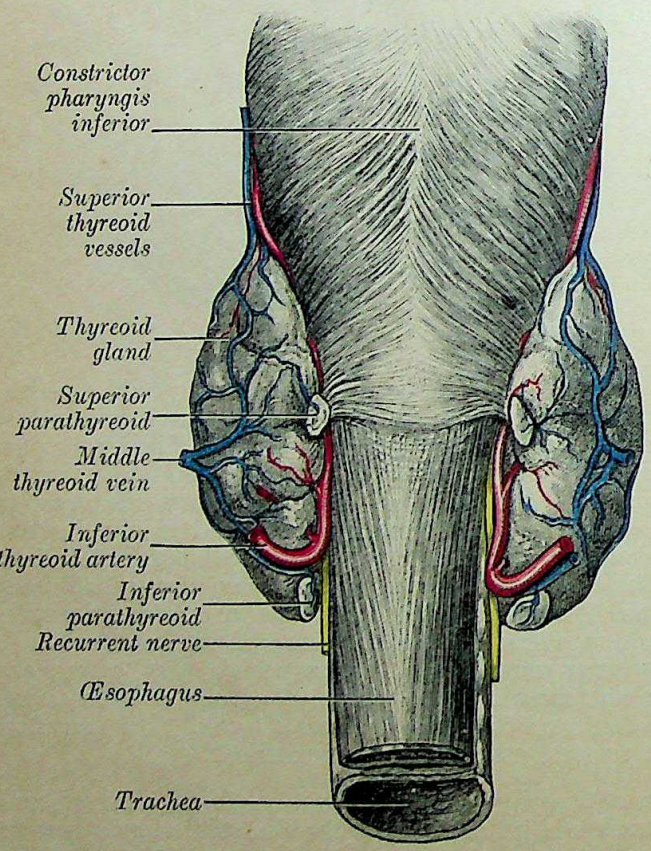

The Parathyreoid Glands

The parathyreoid glands (fig. 1200) are small brownish-red bodies, situated as a rule between the posterior borders of the lateral lobes of the thyreoid gland and its capsule. They measure on an average about 6 mm.

CC-0. In Public Domain. Gurukul Kangri Collection, Haridwar

Digitized by Arya Samaj Foundation Chennai and eGangotri

in length, and from 3 mm. to 4 mm. in breadth, and usually present the appearance of flattened oval discs. They are divided, according to their situation, into *superior* and *inferior*. The superior, usually two in number, are the more constant in position, and are situated one on either side, at the level of the lower border of the cricoid cartilage, behind the junction of the pharynx and œsophagus. The inferior, also usually two in number, may be applied to the lower edge of the lateral lobes of the thyreoid gland, or placed at some little distance below the thyreoid gland, or found in relation to one of the inferior thyreoid veins.*

In man, they number four as a rule; fewer than four were found in less than 1 per cent. of over a thousand persons (Pepere †), but more than four in over 33 per cent. of 122 bodies examined by Civalleri. In addition, numerous minute islands of parathyreoid tissue may be found scattered in the connective tissue and fat of the neck round the parathyreoid glands proper, and quite distinct from them.

Structure.—Microscopically the parathyreoid glands consist of intercommunicating columns of cells supported by connective tissue containing a rich supply of blood-capillaries (sinusoids). Most of the cells are clear, but some, larger in size, contain oxyphil granules (fig. 1201). Vesicles containing colloid are sometimes found.

Fig. 1201.—A section of a human parathyreoid gland. Stained with hæmotoxylin and eosin. ×400.

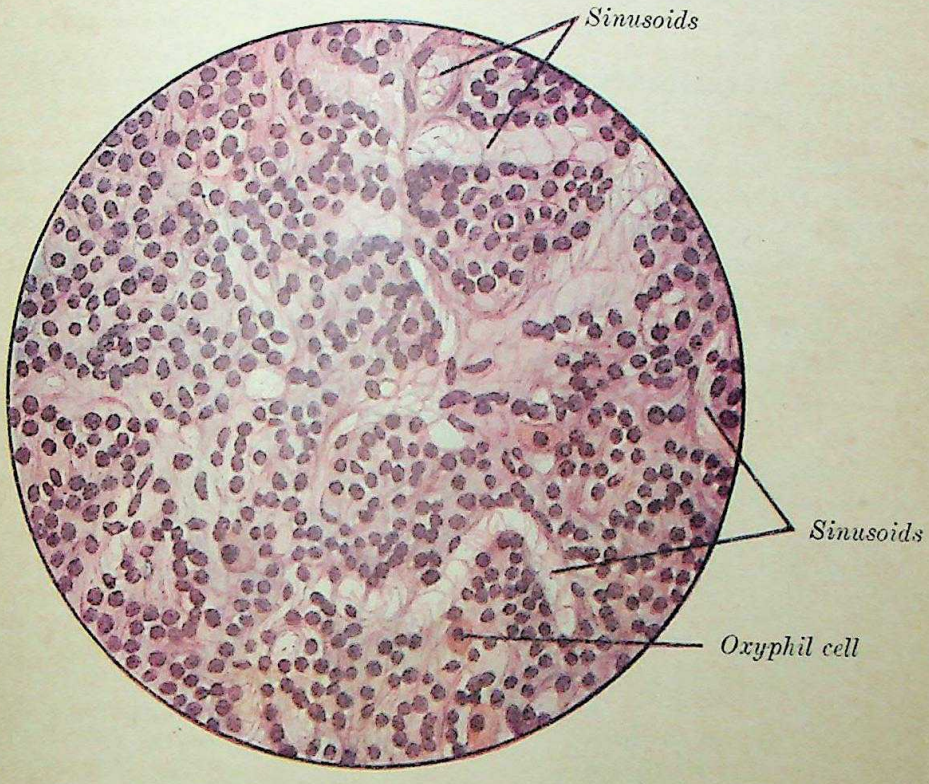

Applied Anatomy.—No doubt the parathyreoid glands produce an internal secretion essential to the well-being of the human economy; but it is still a matter of dispute what symptoms of disease are produced by their removal and suppression of their secretion. Pepere believes that they show signs of exceptional activity during pregnancy, and that parathyreoid insufficiency is a main factor in the production of tetany in infants and adults, of eclampsia, and of certain sorts of fits.

The Thymus (fig. 1202)

The **thymus** increases in size until the age of puberty, after which it dwindles and undergoes a gradual involution. Hammar maintains that it may persist and function even in advanced life. If examined when its growth is most active,

* Consult an article by D. A. Welsh, *Journal of Anatomy and Physiology*, vol. xxxii.
† Consult *Le Ghiandole paratiroidee*, by A. Pepere, Turin, 1906.

CC-0. In Public Domain. Gurukul Kangri Collection, Haridwar

Digitized by Arya Samaj Foundation Chennai and eGangotri

it will be found to consist of two lateral lobes placed in close contact along the middle line, situated partly in the thorax, partly in the neck, and extending from the fourth costal cartilage upwards, as high as the lower border of the thyreoid gland. It is covered by the sternum, and by the origins of the Sternohyoidei and Sternothyreoidei. Below, it rests upon the pericardium, being separated from the aortic arch and great vessels by a layer of fascia. In the neck it lies on the front and sides of the trachea, behind the Sternohyoidei and Sternothyreoidei. The two lobes generally differ in size; they are occasionally united by connective tissue, so as to form a single mass; sometimes they are separated by an intermediate lobe. The thymus is of a pinkish-grey colour, soft, and lobulated on its surfaces. At birth it weighs about 13 gm., and at puberty between 35 and 40 gm.; it is heavier in the male than in the female.

Fig. 1202.—The thymus of a full-time fœtus. Exposed *in situ*.

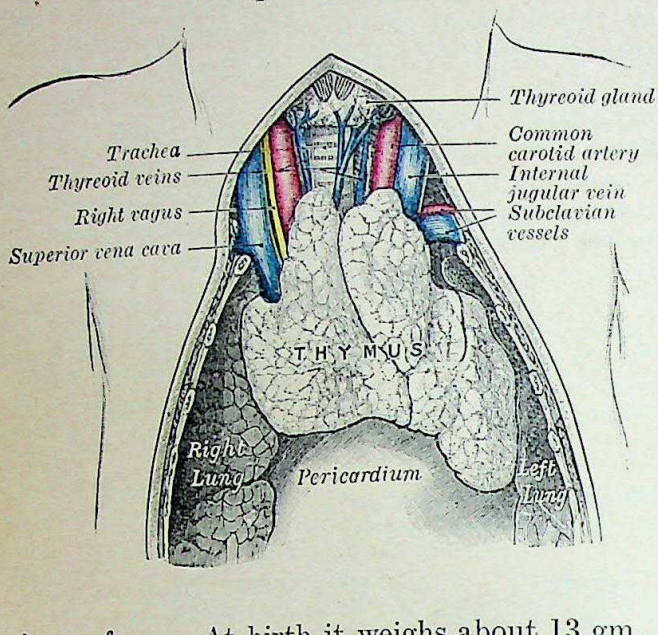

Structure.—Each lateral lobe is composed of numerous lobules held together by delicate areolar tissue; the entire gland being enclosed in an investing capsule of a similar but denser structure. The primary lobules vary in size and are made up of a number of small nodules or follicles, which are irregular in shape and are more or less fused together,

Fig. 1203.—A, A section through a follicle of the thymus of a kitten. ×60; B, a corpuscle of Hassall. ×350. Stained with picrocarmine.

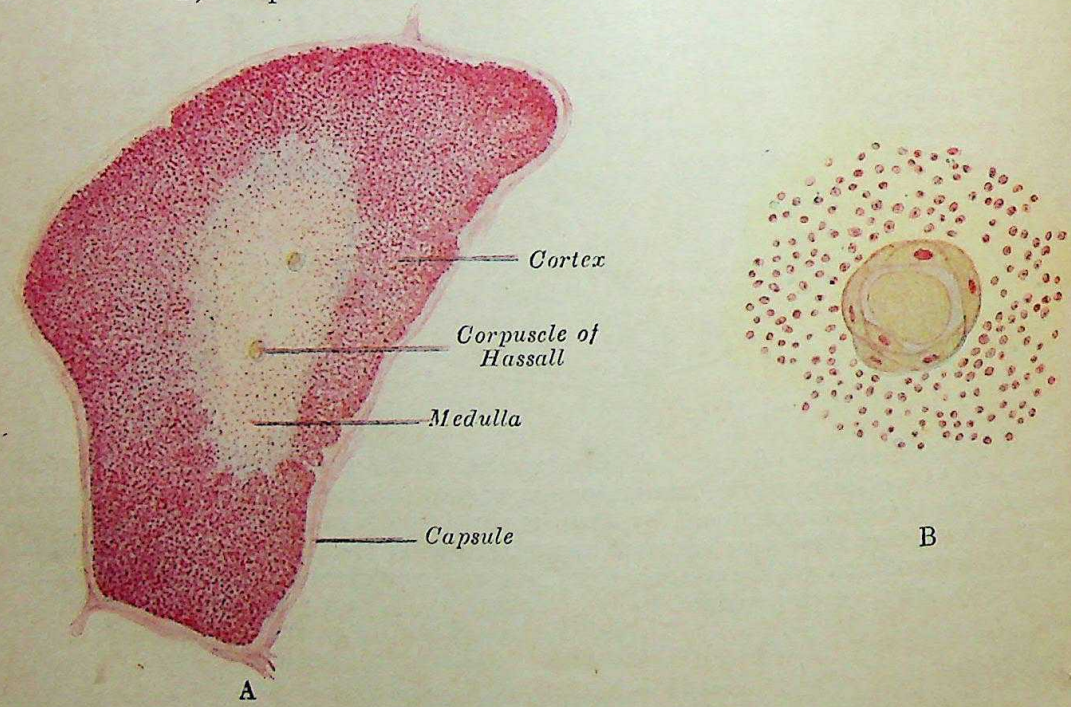

especially towards the interior of the gland. Each follicle (fig. 1203 A) is from 1 mm. to 2 mm. in diameter and consists of a cortical and a medullary portion; it is enclosed in a connective tissue capsule, from which septa pass into its substance, but do not extend as far as the medullary portion of the follicle. The *cortical portion* is mainly composed of lymphocytes, supported by a network of finely branched cells, which is continuous with a similar network in the medullary portion. This network forms an adventitia to the blood-

CC-0. In Public Domain. Gurukul Kangri Collection, Haridwar

Digitized by Arya Samaj Foundation Chennai and eGangotri

vessels. In the *medullary portion* the lymphoid cells are fewer, and the reticulum is coarser than in the cortex; it contains nest-like bodies, the *concentric corpuscles* of Hassall. These corpuscles are composed of a central mass, consisting of one or more granular cells, and of a capsule which is formed of concentrically arranged epithelioid cells (fig. 1203 B). Eosinophil and polymorphonuclear leucocytes are also found in the gland.

Each follicle is surrounded by a vascular plexus, from which vessels pass into the interior, and radiate from the periphery towards the centre, forming a second zone just within the margin of the medullary portion. In the centre of the medullary portion there are very few vessels, and they are of minute size.

The cortical part begins to atrophy before the medullary part, and its decrease in size is mainly owing to a diminution in the number of lymphocytes.

Vessels and Nerves.—The *arteries* supplying the thymus are derived from the internal mammary, and from the superior and inferior thyreoids. The *veins* end in the left innominate vein, and in the thyreoid veins. The *lymphatics* are described on p. 778. The *nerves* are exceedingly minute; they are derived from the vagi and sympathetic. Branches from the descendens hypoglossi and phrenic reach the investing capsule, but do not penetrate the substance of the gland.

Applied Anatomy.—Sudden death—'thymus death'—with heart-failure, and with or without acute respiratory embarrassment, has been recorded in a number of infants and children in whom the thymus was considerably enlarged, and the lymphatic tissues throughout the body showed general hypertrophy, but who showed no other evidence of disease. Such deaths have often occurred during the administration of anæsthetics, particularly chloroform. How far the enlarged thymus was responsible for the death of these patients, and, if it was responsible, how far its action was mechanical, are points that have been much disputed. Short of producing this sudden death, it appears that thymic enlargement may cause attacks of respiratory stridor, or noisy and difficult breathing, and spasmodic attacks of asthma—'thymic asthma'—which may be frequently repeated and may even result in death.

Primary tumours of the thymus are rare forms of mediastinal new growth, and are usually sarcomas.

The Chromaffin Organs

It was pointed out on p. 100 that the tissue from which the sympathetic ganglia are formed consists of a syncytium of sympathochromaffin cells which are soon differentiated into (*a*) small sympathetic nerve-cells, and (*b*) large *chromaffin cells*, so named because of their affinity for chromic salts, which stain them a brown colour. These chromaffin cells are subsequently grouped to form the chromaffin organs, the chief of which are the paraganglia, and the medullary portions of the suprarenal glands.

The **paraganglia** are found in two chief groupings: (1) as small masses of chromaffin cells, placed either within the capsules of the sympathetic ganglia or in close contact with them; (2) as small groups of chromaffin cells scattered throughout the sympathetic plexuses. The two largest masses in this latter group are the aortic bodies of Zuckerkandl and the glomera carotica.

The *aortic bodies of Zuckerkandl* are two small brownish-coloured bodies which lie one on either side of the abdominal aorta at the level of the origin of the inferior mesenteric artery, in intimate relationship with the abdominal aortic plexus of the sympathetic. They are of considerable size (8-10 mm. long) in the new-born child, and may be united to one another across the front of the abdominal aorta. After birth they gradually atrophy, and become invisible to the naked eye shortly after puberty.

Structure.—The aortic bodies consist of masses of polygonal or cubical epithelium, imbedded in a wide-meshed capillary plexus.

FIG. 1204.—A section through a part of a human glomus caroticum. (Schaper.) Highly magnified. (From Quain's Elements of Anatomy.)

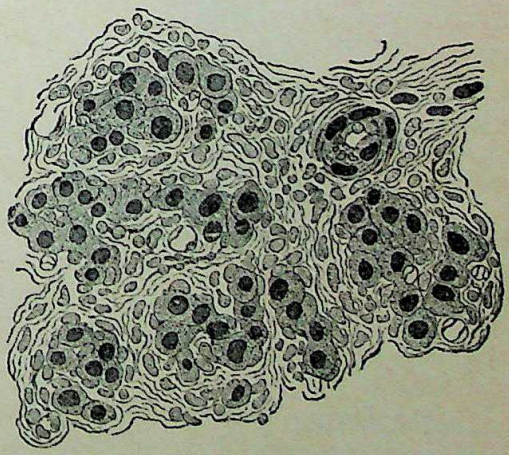

Numerous blood-vessels are seen in section among the gland-cells.

The *glomera carotica* (carotid bodies), two in number, are situated one on each side of the neck, behind the common carotid artery at its point of

CC-0. In Public Domain. Gurukul Kangri Collection, Haridwar

Digitized by Arya Samaj Foundation Chennai and eGangotri

bifurcation into the external and internal carotid trunks. They are reddish-brown in colour and oval in shape, the long diameter measuring about 5 mm.

Structure.—Each glomus is invested by a fibrous capsule and consists largely of spherical or irregular masses of chromaffin cells (fig. 1204)—the masses being more or less isolated from one another by septa which extend inwards from the deep surface of the capsule. The cells are polyhedral in shape, and each contains a large nucleus imbedded in finely granular protoplasm. Numerous nerve-fibres, derived from the sympathetic plexus on the carotid artery, are distributed throughout the organ, and a network of large sinusoidal capillaries ramifies amongst the cells.

The Suprarenal Glands (figs. 1205, 1206)

The **suprarenal glands** are two small flattened bodies of a yellowish colour, situated, one on either side of the middle line, at the posterior part of the abdomen, behind the peritoneum, and immediately above and in front of the

Fig. 1205.—The suprarenal glands. Anterior aspect.

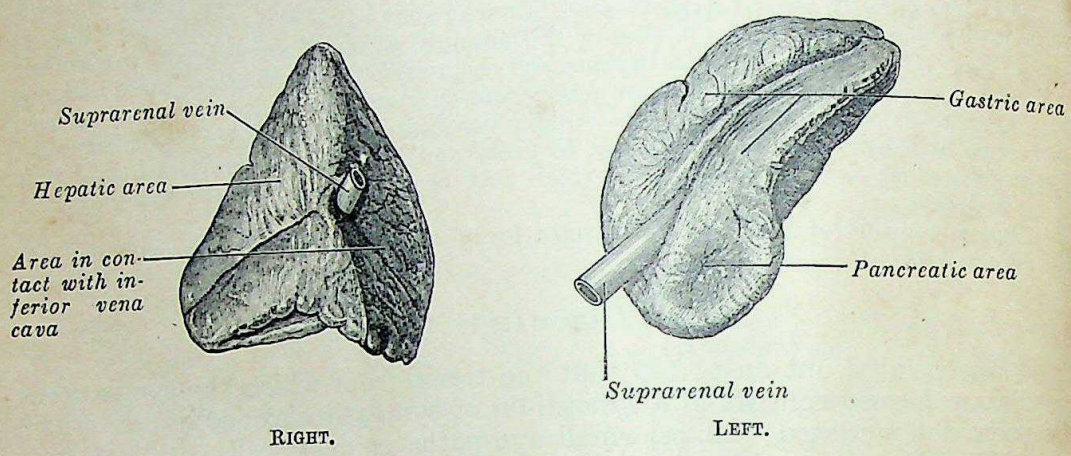

upper end of the kidney. They are surrounded by areolar tissue containing a considerable amount of fat. The right gland is somewhat pyramidal in shape, bearing a resemblance to a cocked hat; the left is semilunar, and is usually larger and placed at a higher level than the right. They measure from 30 mm. to 50 mm. in height; about 30 mm. in breadth, and from 4 mm. to 6 mm. in thickness. The average weight of each is from 3 gm. to 4 gm.

Fig. 1206.—The suprarenal glands. Posterior aspect.

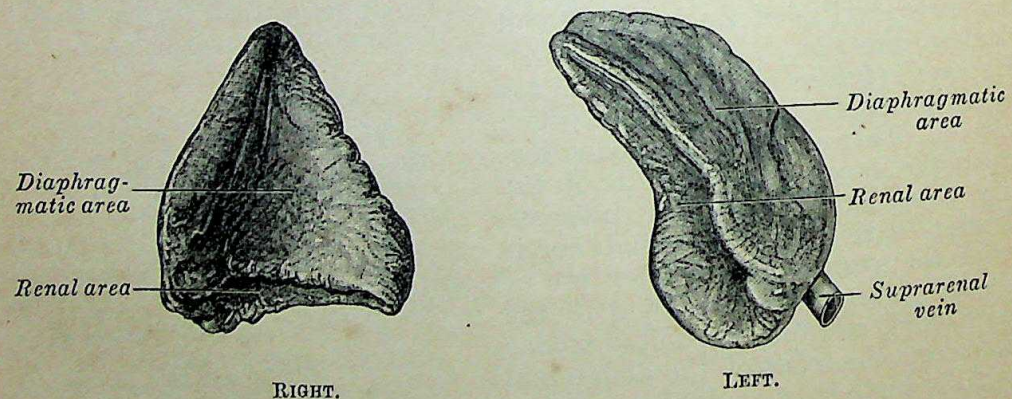

Relations.—The *right suprarenal gland* is situated behind the inferior vena cava and the right lobe of the liver, and in front of the Diaphragm and upper end of the right kidney. It is roughly triangular in shape; its base, directed downwards, is in contact with the medial and anterior surfaces of the upper end of the right kidney. Its *anterior surface* looks forwards and lateralwards, and has two areas: a medial, narrow and non-peritoneal, which lies behind the inferior vena cava; and a lateral, somewhat triangular, in contact with the

CC-0. In Public Domain. Gurukul Kangri Collection, Haridwar

Digitized by Arya Samaj Foundation Chennai and eGangotri

liver. The upper part of the latter surface is devoid of peritoneum, and is in relation with the lower and medial angle of the bare area of the liver, while its inferior portion may be covered by peritoneum, reflected on to it from the inferior layer of the coronary ligament; occasionally the duodenum overlaps the inferior portion. A little below the apex, and near the anterior border of the gland, is a short furrow termed the hilum, from which the right suprarenal vein emerges to join the inferior vena cava. Its *posterior surface* is divided into upper and lower parts by a curved ridge; the upper, slightly convex, rests upon the Diaphragm; the lower, concave, is in contact with the upper end and the adjacent part of the anterior surface of the right kidney.

The *left suprarenal gland* is crescentic in shape, its concavity being adapted to the medial border of the upper part of the left kidney. Its medial border is convex, its lateral concave; its upper end is narrow, its lower rounded. Its *anterior surface* has two areas: an upper, covered by the peritoneum of the omental bursa which separates it from the cardiac end of the stomach and sometimes from the superior extremity of the spleen; and a lower which is not covered by peritoneum, but is in contact with the pancreas and lienal artery. Near the lower part of the anterior surface is the hilum, which is directed downwards and forwards. From it the left suprarenal vein emerges to join the left renal vein. Its *posterior surface* is divided into two areas by a ridge; the lateral area rests on the kidney, the medial and smaller, on the left crus of the diaphragm.

Fig. 1207.—A section through a part of a suprarenal gland. (Magnified.)

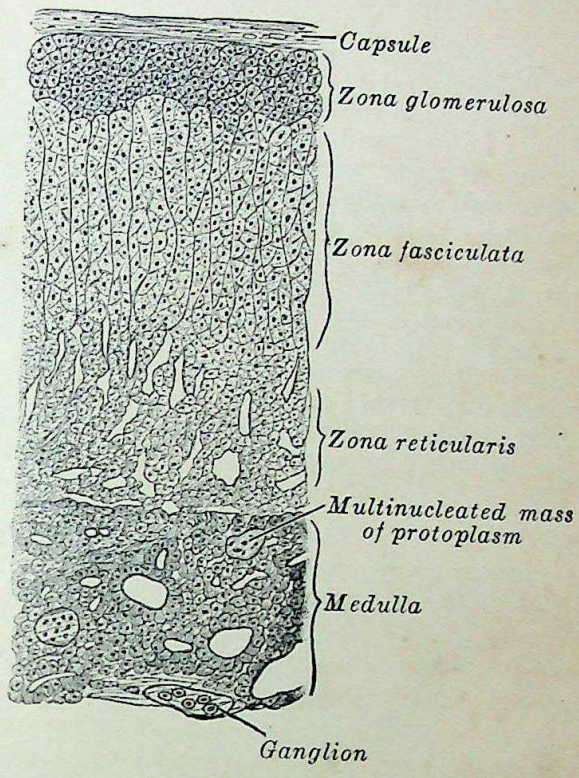

Small *accessory suprarenal* glands are often found in the connective tissue round the suprarenal glands; they are sometimes present in the spermatic cord and epididymis, and in the broad ligament of the uterus.

Structure.—The suprarenal gland is closely invested by a capsule of connective tissue from which trabeculæ pass into the substance of the gland; the capsule may contain smooth muscular fibres. On section, the gland is seen to consist of two portions (fig. 1207): an external, the cortex, and an internal, the medulla. The cortex constitutes the larger part of the organ, and is of a deep yellow colour; the medulla is soft, pulpy, and of a dark red or brown colour.

The *cortex* consists of a fine connective tissue network, in which is imbedded the glandular epithelium. The epithelial cells are polyhedral in shape and possess rounded nuclei; many of the cells contain coarse granules, others lipoid globules. Owing to the differences in the arrangement of the cells three distinct zones can be made out: (1) The *zona glomerulosa*, situated beneath the capsule, consists of cells arranged in rounded groups, with here and there indications of an alveolar structure. (2) The *zona fasciculata*, continuous with the zona glomerulosa, is composed of columns of cells arranged in a radial manner; these cells contain fine granules and in many instances globules of lipoid material. The *zona reticularis*, in contact with the medulla, consists of cylindrical columns of cells irregularly arranged; these cells often contain pigment-granules which give this zone a darker appearance than the rest of the cortex.

The *medulla* is extremely vascular, and is composed of a mass of large finely granular, chromaffin cells, permeated by venous sinusoids. This portion of the gland is richly supplied with non-medullated nerve-fibres, and here and there sympathetic ganglion cells are found.

The suprarenal gland is large in the fœtus, owing to the great development of the inner zone of the cortex. This layer has been named the *boundary zone* by Elliott and Armour. The cells contain no lipoid granules. This zone disappears soon after birth and is absent in anencephalic fœtuses.

CC-0. In Public Domain. Gurukul Kangri Collection, Haridwar

Digitized by Arya Samaj Foundation Chennai and eGangotri

In connexion with the development of the medulla from the sympathochromaffin tissue, it is to be noted that this portion of the gland secretes a substance, *adrenalin*, which has the property of stimulating all sympathetic nerve-endings.

Vessels and Nerves.—The *arteries* supplying the suprarenal glands are numerous and of comparatively large size; they are derived from the aorta, and the inferior phrenic and renal arteries. In the cortical part of the gland they break up into capillaries which end in the sinusoids of the medullary portion; the latter open into the veins near the centre of the medulla.

The *suprarenal vein* emerges from the hilum of the gland; that of the right gland opens into the inferior vena cava, that of the left into the renal vein.

The *lymphatics* end in the lumbar glands.

The *nerves* are exceedingly numerous, and are derived from the splanchnic nerves through the cœliac and renal plexuses, and, according to Bergmann, from the phrenic and vagus nerves. They enter the lower and medial part of the capsule, traverse the cortex, and end around the cells of the medulla. They have numerous small ganglia developed upon them in the medullary portion of the gland.

Applied Anatomy.—The suprarenal *cortex* is derived from the cœlomic epithelium of the Wolffian ridge, and is connected with the sexual glands; it is related to growth and development in some way, and is often found to be hypertrophied in patients with chronic kidney disease and high blood-pressure. The *medulla*, on the other hand, is neuro-ectodermal in origin, and closely connected with the sympathetic nervous system. When the suprarenal medulla is destroyed by tuberculosis, to which the glands are prone, or by the pressure of a new growth, the secretion of adrenalin becomes inadequate, and Addison's disease develops. Patients with Addison's disease become pigmented in various parts of the body, possibly from irritation of the sympathetic, and complain of great weakness, lack of energy, nausea, and severe attacks of vomiting. Their blood-pressure is low, the whole nervous system is depressed, and death follows after a period of months or years, usually from asthenia. Tumours derived from the suprarenal itself, or from misplaced suprarenal 'rests' occurring in such organs as the kidney or liver, may be either benign or malignant, and are classed together under the name 'hypernephroma.' In children the malignant hypernephroma is often associated with obesity and precocity. The benign hypernephroma, or suprarenal adenoma, appears to produce no symptoms except those due to its slow enlargement.

Fig. 1208.—A section through an irregular nodule of the glomus coccygeum. ×85. (Sertoli.) (From Quain's Elements of Anatomy.)

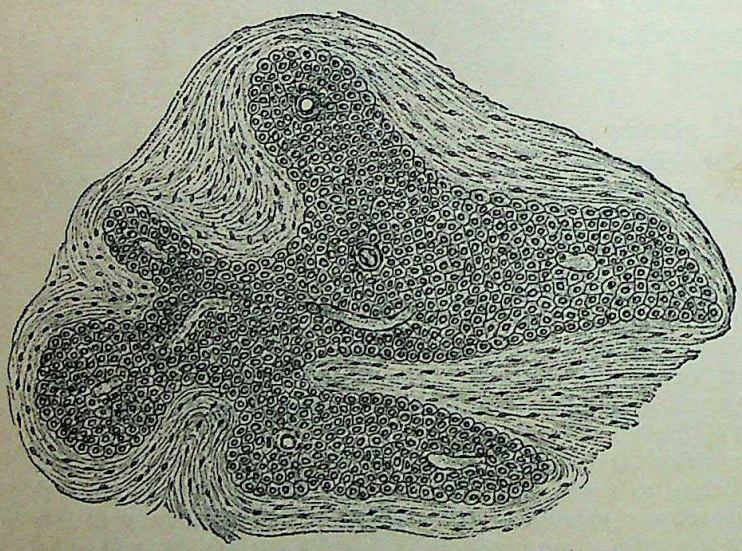

The section shows the fibrous covering of the nodule, the blood-vessels within it, and the epithelial cells of which it is constituted.

The Glomus Coccygeum

The **glomus coccygeum** (coccygeal body) is placed in front of, or immediately below, the tip of the coccyx. It is about 2·5 mm. in diameter and is irregularly oval in shape; several smaller nodules are found around or near the main mass.

Structure.—The glomus coccygeum consists of irregular masses of round or polyhedral cells (fig. 1208), the cells of each mass being grouped around a dilated sinusoidal capillary vessel. Each cell contains a large round or oval nucleus, the protoplasm surrounding which is clear and is not stained by chromic salts.*

The Spleen (Lien)

The **spleen** is situated principally in the left hypochondriac region of the abdomen, but its upper end extends into the epigastric region; it lies between the fundus of the stomach and the Diaphragm. It is the largest of the

* Consult the following article: 'Über die menschliche Steissdrüse,' von J. W. Thomson Walker, *Archiv für mikroskopische Anatomie und Entwickelungsgeschichte*, Band 64, 1904.

CC-0. In Public Domain. Gurukul Kangri Collection, Haridwar

Digitized by Arya Samaj Foundation Chennai and eGangotri

ductless glands, and is of an oblong, flattened form, soft, of very friable consistence, highly vascular, and of a dark purplish colour.

Relations.—The *diaphragmatic surface* is convex, smooth and is directed upwards, backwards, and to the left, except at its upper end, where it is directed slightly medialwards. It is in relation with the under surface of the Diaphragm, which separates it from the ninth, tenth, and eleventh ribs of the left side, and the intervening lower border of the left lung and pleura.

The *visceral surface* (fig. 1209) is divided by a ridge into an anterior or gastric, and a posterior or renal portion.

The *gastric surface*, directed forwards, upwards, and medialwards, is broad and concave. It is in contact with the posterior wall of the stomach, and below the stomach with the tail of the pancreas. It presents near its medial border a long fissure, termed the *hilum*. This is pierced by several irregular apertures for the entrance and exit of vessels and nerves.

Fig. 1209.—The visceral surface of the spleen.

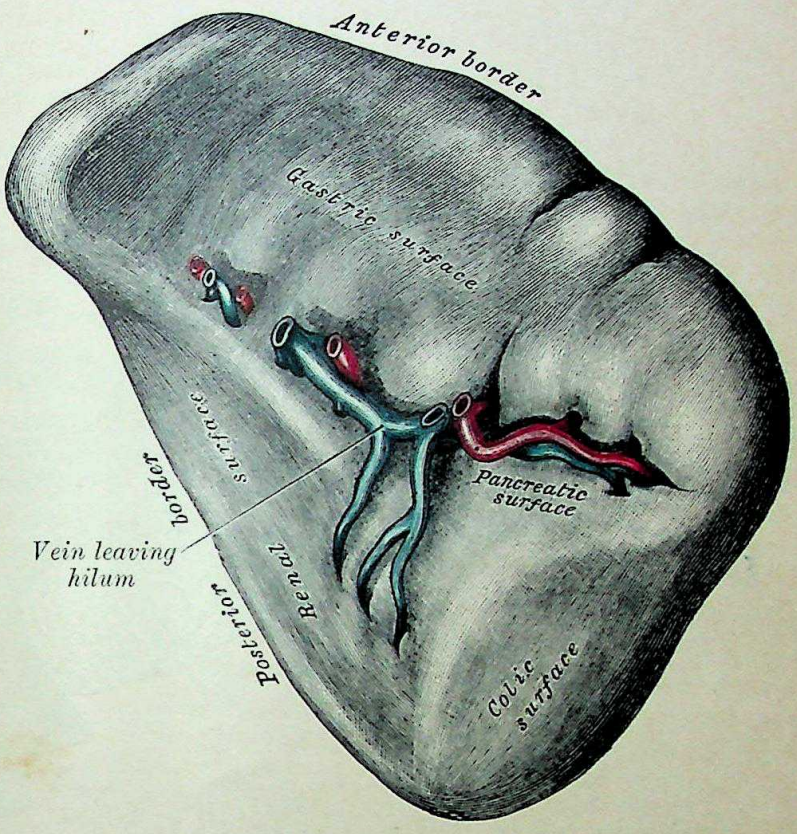

The *renal surface*, directed medialwards and downwards, is somewhat flattened. It is considerably narrower than the gastric surface, and is in relation with the upper part of the anterior surface of the left kidney and occasionally with the left suprarenal gland.

The *upper end* is directed towards the vertebral column, where it lies on a level with the eleventh thoracic vertebra. The *lower end* or *colic surface* is flat, triangular in shape, and rests upon the left flexure of the colon and the phrenicocolic ligament, and is generally in contact with the tail of the pancreas. The *anterior border*, free and thin, is often notched near its lower end; it separates the diaphragmatic from the gastric surface. The *posterior border*, blunter and more rounded than the anterior, separates the renal from the diaphragmatic surface; it corresponds to the lower border of the eleventh rib and lies between the Diaphragm and left kidney. The *inferior border* separates the diaphragmatic from the colic surface, and the *intermediate margin* intervenes between the renal and gastric surfaces.

The spleen is almost entirely surrounded by peritoneum, which is firmly adherent to its capsule. It is held in position by two folds of this membrane. One, the *lienorenal ligament*, is derived from the peritoneum where the wall of the general peritoneal cavity comes into contact with the omental bursa between the left kidney and the spleen; the lienal vessels pass between its two layers (fig. 1093). The other fold, the *gastrolienal ligament* (gastrosplenic omentum), also consists of two layers, and is formed by the meeting of the walls of the general peritoneal cavity and of the omental bursa between the spleen and stomach (fig. 1093); the short gastric and left gastro-epiploic branches of the lienal artery run between its two layers. The lower end of the spleen is supported by the phrenicocolic ligament (p. 1144).

The size and weight of the spleen vary at different periods of life, in different individuals, and in the same individual under different conditions. *In the adult*, it is usually about 12 cm. in length, 7 cm. in breadth, and 3 or 4 cm. in thickness, and weighs about 200 gm.

CC-0. In Public Domain. Gurukul Kangri Collection, Haridwar

Digitized by Arya Samaj Foundation Chennai and eGangotri

The size of the spleen slowly increases during digestion, and varies according to the state of nutrition of the body, being large in highly fed, and small in starved, animals. In malarial fever it is greatly enlarged, and may weigh as much as 9 kilos.

Frequently in the neighbourhood of the spleen, and especially in the gastrolienal ligament and greater omentum, small encapsulated nodules of splenic tissue may be found, either isolated or connected to the spleen by thin bands of splenic tissue. They are known as *accessory spleens.*

Structure.—The spleen is invested by two coats: an external serous and an internal fibro-elastic coat.

The *external or serous coat* is derived from the peritoneum; it is thin, smooth, and in the human subject intimately adherent to the fibro-elastic coat. It invests the entire organ, except at the hilum and along the lines of reflection of the lienorenal and gastrolienal ligaments.

The *fibro-elastic coat* or *tunica propria* invests the organ, and at the hilum is reflected inwards upon the vessels in the form of sheaths. From these sheaths, as well as from the

Fig. 1210.—A transverse section through the spleen, showing the trabecular tissue and the splenic vein and its tributaries.

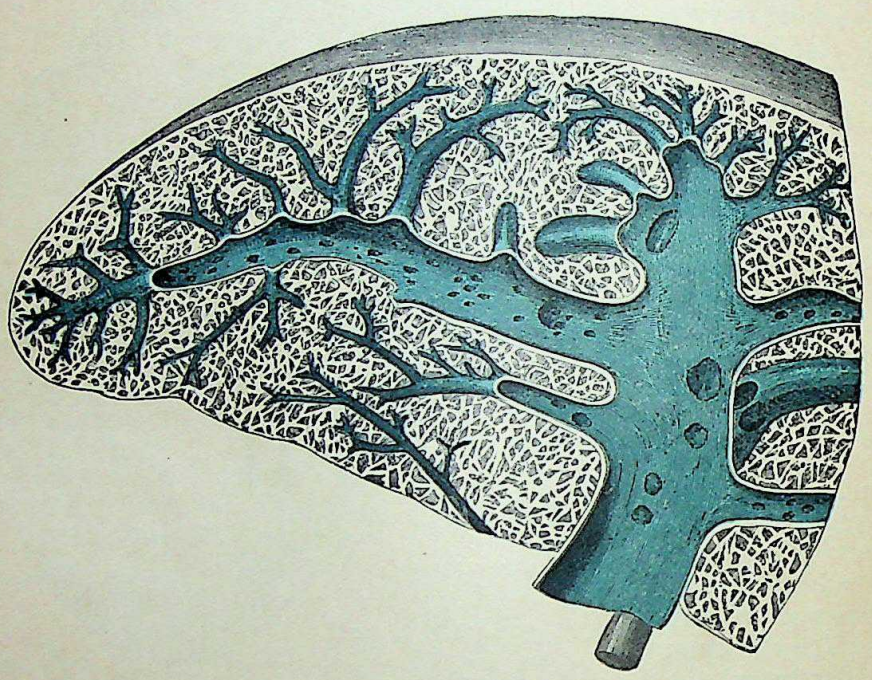

inner surface of the fibro-elastic coat, numerous small fibrous bands, *trabeculæ* (fig. 1210), are given off in all directions; these unite to form the framework of the spleen, in the interspaces of which is contained the *splenic pulp.*

The fibro-elastic coat, the sheaths of the vessels, and the trabeculæ, are composed of white, and yellow elastic, fibres, the latter predominating. It is owing to the presence of the elastic tissue that the spleen possesses a considerable amount of elasticity, which allows of the very great variations in size that it presents under certain circumstances. In addition to these constituents there is a small amount of non-striped muscular fibre. In some mammals (e.g. dog, pig, and cat) the trabeculæ consist chiefly of muscular tissue.

The *splenic pulp* is a soft mass of a dark reddish-brown colour; it consists of a fine reticulum of fibres, continuous with those of the trabeculæ, to which are applied flat, branching cells. The meshes of the reticulum are filled with blood, in which, however, the white corpuscles are found to be in larger proportion than they are in ordinary blood. Large, rounded cells, termed *splenic cells*, are also seen; these are capable of amœboid movement, and often contain pigment and red blood-corpuscles in their interior. The cells of the reticulum each possess a round or oval nucleus, and like the splenic cells they may contain pigment-granules in their cytoplasm; they do not stain deeply with carmine, and in this respect differ from the cells of the Malpighian bodies. In the young spleen giant cells may be found, each containing numerous nuclei or one compound nucleus. Nucleated red blood-corpuscles have also been found in the spleen in young animals.

Blood-vessels of the spleen.—The lienal artery is remarkable for its large calibre in proportion to the size of the organ, and also for its tortuous course. It divides into six or more branches, which enter the hilum of the spleen and ramify throughout its substance (fig. 1211) receiving sheaths from an involution of the external fibrous tissue. Similar sheaths also invest the nerves and veins.

CC-0. In Public Domain. Gurukul Kangri Collection, Haridwar

Digitized by Arya Samaj Foundation Chennai and eGangotri

Each branch runs in the transverse axis of the organ, from within outwards, diminishing in size during its transit, and giving off in its passage smaller branches, some of which pass to the anterior, others to the posterior part. These ultimately leave the trabecular sheaths, and terminate in the proper substance of the spleen in small tufts or pencils of

FIG. 1211.—A transverse section through the human spleen, showing the distribution of the splenic artery and its branches.

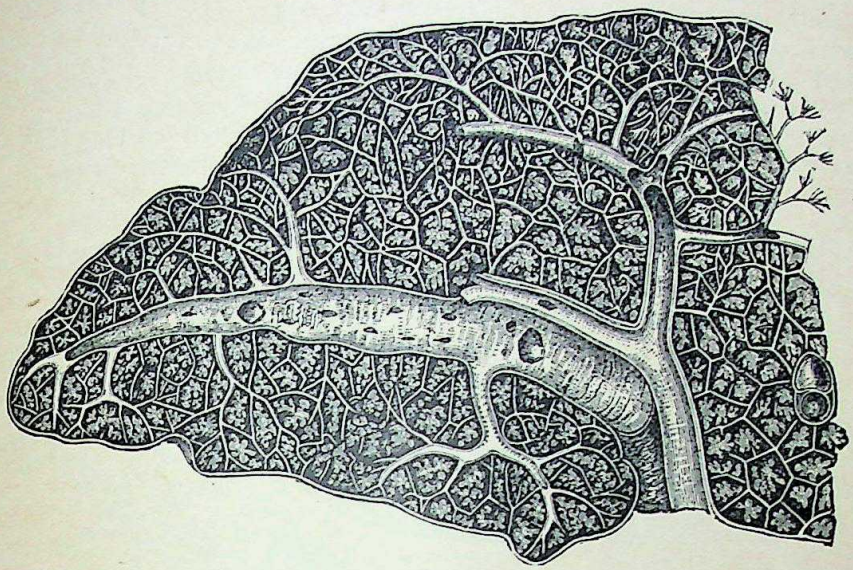

minute arterioles, which open into the interstices of the reticulum formed by the branched sustentacular cells. The branches of the splenic artery are 'end arteries' (p. 595).

The *arterioles* differ in structure from the larger arterial vessels in that their outer coat consists of lymphoid tissue. This coat exhibits localized spheroidal thickenings, termed the *Malpighian bodies* of the spleen (fig. 1212). These bodies vary in size from about 0·25 mm. to 1 mm. in diameter. In transverse sections, the artery, in the majority of cases, is found in an eccentric position. The Malpighian bodies are visible to the naked

FIG. 1212.—A section through a portion of the human spleen. Stained with hæmatoxylin and eosin. × 15.

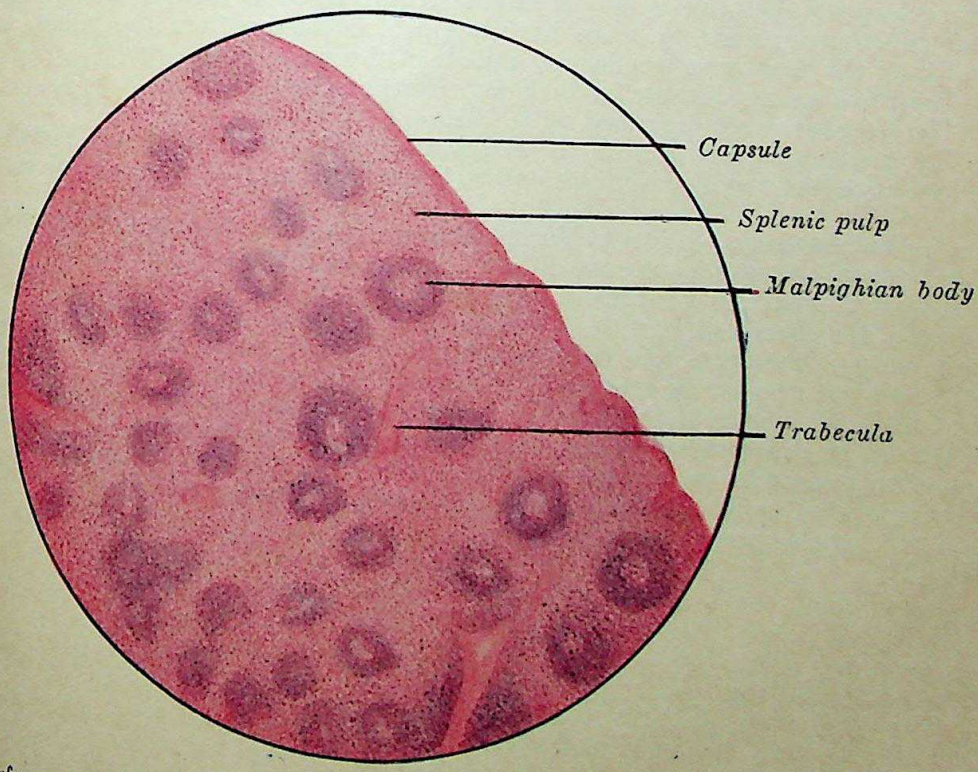

on the surface of a fresh section of the organ, appearing as minute semi-opaque dots a whitish colour in the dark substance of the pulp. The reticulum of the lymphoid is made up of extremely fine fibrils, and is comparatively open in the centre of the but closer at its periphery.

CC-0. In Public Domain. Gurukul Kangri Collection, Haridwar

Digitized by Arya Samaj Foundation Chennai and eGangotri

The arterioles end by opening freely into the splenic pulp; their walls become much attenuated, they lose their tubular character, and the endothelial cells ramify, their processes being directly connected with those of the reticular cells of the pulp (fig. 1213). The blood thus finds its way into the interstices of the reticulated tissue of the splenic pulp. It is then collected by the rootlets of the veins, which begin much in the same way as the arteries end. The connective tissue corpuscles of the pulp arrange themselves in rows, in such a way as to form an elongated space or sinus. They become elongated and spindle-shaped, and overlap each other at their extremities, and thus form a sort of endothelial lining of the path or sinus, which is the radicle of a vein. On the outer surface of these sinuses are seen delicate transverse lines or markings, which are due to minute elastic fibrils arranged in a circular manner. Thus the channel obtains an external investment, and gradually becomes converted into a small vein, which after a short course acquires a coat of ordinary connective tissue, lined by a layer of flattened epithelial cells continuous with the supporting cells of the pulp. The smaller veins unite to form larger ones; these do

Fig. 1213.—A section through the spleen, showing the termination of a small blood-vessel.

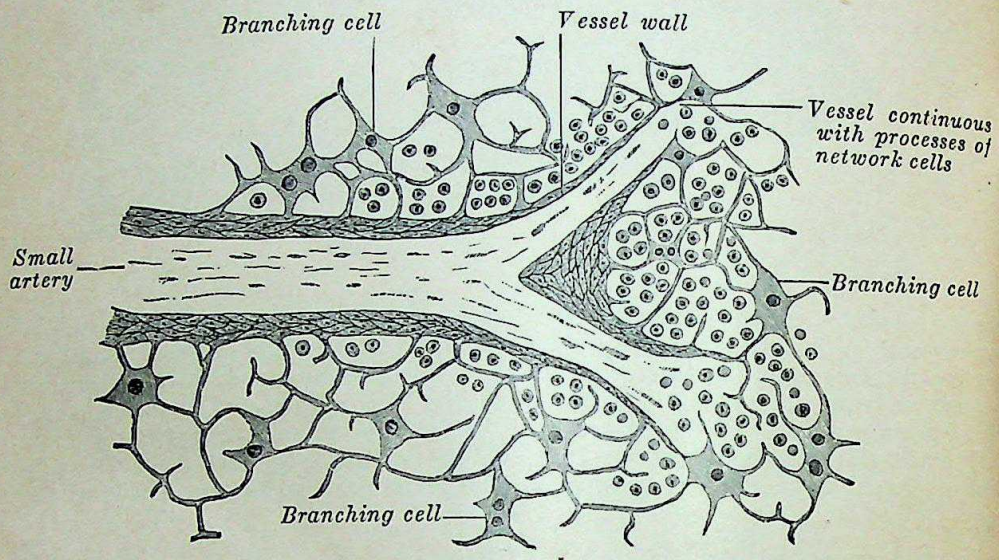

not accompany the arteries, but soon enter the trabecular sheaths of the capsule, and by their junction form six or more branches, which emerge from the hilum, and, uniting, constitute the lienal vein, the largest radicle of the portal vein.

The veins are remarkable for their numerous anastomoses.

The lymphatics are described on p. 771.

The *nerves* are derived from the cœliac plexus and are chiefly non-medullated. They are distributed to the blood-vessels and to the smooth muscle of the capsule and trabeculæ.

Applied Anatomy.—Injury of the spleen is less common than that of the liver, on account of its protected situation and connexions. It may be ruptured by direct or indirect violence; torn by a broken rib; or injured by a punctured or gunshot wound. When the organ is enlarged, the chance of rupture is increased. The great risk is hæmorrhage, owing to the vascularity of the organ and the absence of a proper system of capillaries. The injury is not, however, necessarily fatal, and this would appear to be due, in a great measure, to the contractile power of the capsule, which narrows the wound and prevents the escape of blood. In cases where the diagnosis is clear, and the symptoms indicate danger to life, laparotomy must be performed, and the spleen removed. When removing the spleen it must be remembered that the tail of the pancreas is in contact with it, and should be avoided in ligaturing the vessels.

CC-0. In Public Domain. Gurukul Kangri Collection, Haridwar

Digitized by Arya Samaj Foundation Chennai and eGangotri

SURFACE ANATOMY AND SURFACE MARKINGS

THE SURFACE ANATOMY OF THE HEAD AND THE NECK

THE bones (fig. 1214).—The *external occipital protuberance* (inion) is situated behind, in the middle line, at the upper end of the nuchal furrow, and the *superior nuchal lines* run lateralwards from it, one on either side. Above these lines the vault of the cranium is so thinly covered with soft structures that the form of

FIG. 1214.—A side view of the head, showing the surface relations of the bones.

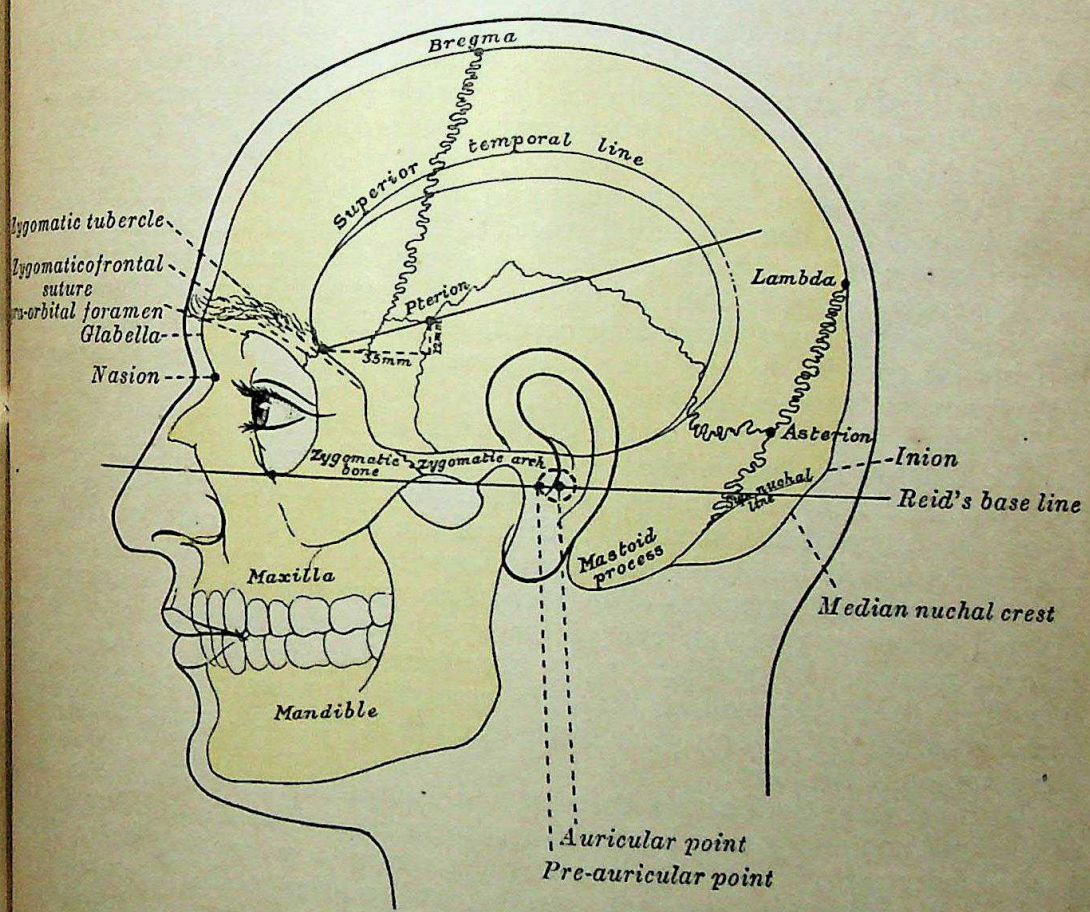

part of the head is almost that of the upper portion of the occipital, the parietal the frontal bones. The superior nuchal lines run lateralwards to the mastoid rions of the temporal bones, from which the *mastoid processes* project downwards d forwards behind the auriculæ. The anterior and posterior borders, the apex, the external surface of the mastoid process are available for surface examina- ; the anterior border lies immediately behind the concha, and the apex is ly on a level with the lobule of the auricula. In front of the ear the *zygomatic* can be felt throughout its entire length; its narrow posterior end is situated

CC-0. In Public Domain. Gurukul Kangri Collection, Haridwar

Digitized by Arya Samaj Foundation Chennai and eGangotri

a little above the level of the tragus; its broad anterior end is continued into the zygomatic bone. The upper border of the arch is less distinct than the lower, but can be followed into the *superior temporal line*. Anteriorly, this line begins at the zygomatic process of the frontal bone as a curved ridge which runs at first forwards and upwards and then backwards on the frontal bone, separating the forehead from the temporal fossa. It then crosses the parietal bone, where, though less marked, it can generally be recognised. Finally, it curves downwards and forwards, and, passing above the opening of the external acoustic meatus, ends in the posterior root of the zygomatic arch.

Near the line of the greatest transverse diameter of the head are the *parietal tuberosities*, one on either side; further forwards, on the forehead, are the *frontal tuberosities*, which vary in prominence in different individuals. Below the frontal tuberosities are the *superciliary arches*; they are absent in infancy, and are, as a rule, small in the female. In some cases the prominence of these arches is related to the size of the frontal sinuses, but frequently there is no such relationship. Between the superciliary ridges is a smooth, somewhat triangular area, the *glabella*, and below this is the *nasion* or frontonasal suture.

Below the nasion the *nasal bones*, scantily covered by soft tissues, can be traced to their junctions with the nasal cartilages, and on either side of the nasal bones the complete outline of the *orbital margin* can be made out. At the junction of the medial with the intermediate one-third of the supra-orbital margin the *supra-orbital notch*, when present, can be felt; near the medial end of the infra-orbita margin is a little tubercle which serves as a guide to the position of the lacrimal sac. Below and lateral to the orbit, on either side, the *zygomatic bone* forms the prominence of the cheek; its posterior margin is easily felt, and on it just above the level of the lateral palpebral commissure is the *zygomatic tubercle*. A slight depression, about 1 cm. above this tubercle, indicates the position of the *zygomatico-frontal suture*. Below the orbit a considerable part of the anterior surface, and the whole of the alveolar process, of the *maxilla*, can be palpated. Almost the entire outline of the *mandible* can be recognised; the condyle lies in front of the tragus and below the zygomatic arch, and from it the posterior border of the ramus descends to the angle; from the angle to the symphysis the lower rounded border of the body of the bone is readily traced; the lower part of the anterior border of the ramus and the alveolar process can be made out without difficulty. In the receding angle below the chin is the *hyoid bone*, and the finger can be carried along the bone to the tip of its greater cornu, which is most readily appreciated by pressing on one side of the bone, and thus rendering the cornu of the opposite side prominent beneath the skin.

The transverse processes of the first, sixth, and seventh cervical vertebræ can be felt. That of the first is about 1 cm. below and in front of the mastoid process of the temporal bone and can be recognised readily by pressing upwards and inwards behind the angle of the mandible; that of the sixth is opposite to, and that of the seventh a little below, the cricoid cartilage.

The **joints and muscles.**—The *mandibular articulation* is superficial and is situated below the posterior end of the zygomatic arch, in front of the external acoustic meatus. Its position can be ascertained by defining the condyle of the mandible; when the mouth opens, the condyle advances out of the mandibular fossa on to the articular tubercle of the temporal bone, and a depression is felt in the situation of the joint.

With the exceptions of the Masseter and Temporalis the outlines of the muscles of the head and face cannot be traced on the surface. The *Masseter* imparts fulness to the hinder part of the cheek; if firmly contracted, as when the teeth are clenched, its quadrilateral outline is plainly visible; its anterior border forms a prominent vertical ridge, behind which is a considerable fulness especially marked at the lower part of the muscle. The *Temporalis*, a fan-shaped muscle, fills the temporal fossa, and stands out in strong relief when in action. The muscles of the scalp are so thin that the contour of the skull is perceptible beneath them. Those of the face are small, covered by soft skin and often by a considerable layer of fat, and their outlines are therefore concealed; they serve, however, to round off and smooth prominent borders, and to fill up what would otherwise be unsightly angular depressions. Thus the *Orbicularis oculi* rounds off the prominent margin of the orbit, and the *Procerus* fills in the sharp depression below the glabella. In like manner the *labial muscles*, converging to the lips, and assisted by the superimposed

CC-0.In Public Domain. Gurukul Kangri Collection, Haridwar

Digitized by Arya Samaj Foundation Chennai and eGangotri

fat, fill up the sunken hollow of the lower part of the face. When in action the facial muscles produce the various expressions, and in addition throw the skin into numerous folds and wrinkles.

By the contraction of the *Platysma* the skin of the neck is thrown into oblique ridges parallel with the fasciculi of the muscle. The *Sternocleidomastoideus* has the most important influence on the surface form of the neck (figs. 1215, 1216). When the muscle is at rest its anterior border forms an oblique rounded edge ending below in the outline of the sternal head; the posterior border is only distinct for about 2 cm. or 3 cm. above the middle of the clavicle. When the muscle is contracted, the sternal head stands out as a sharply defined ridge, while the clavicular head is flatter and less prominent; between the two heads is a slight depression.

Fig. 1215.—An anterolateral view of the head and neck.

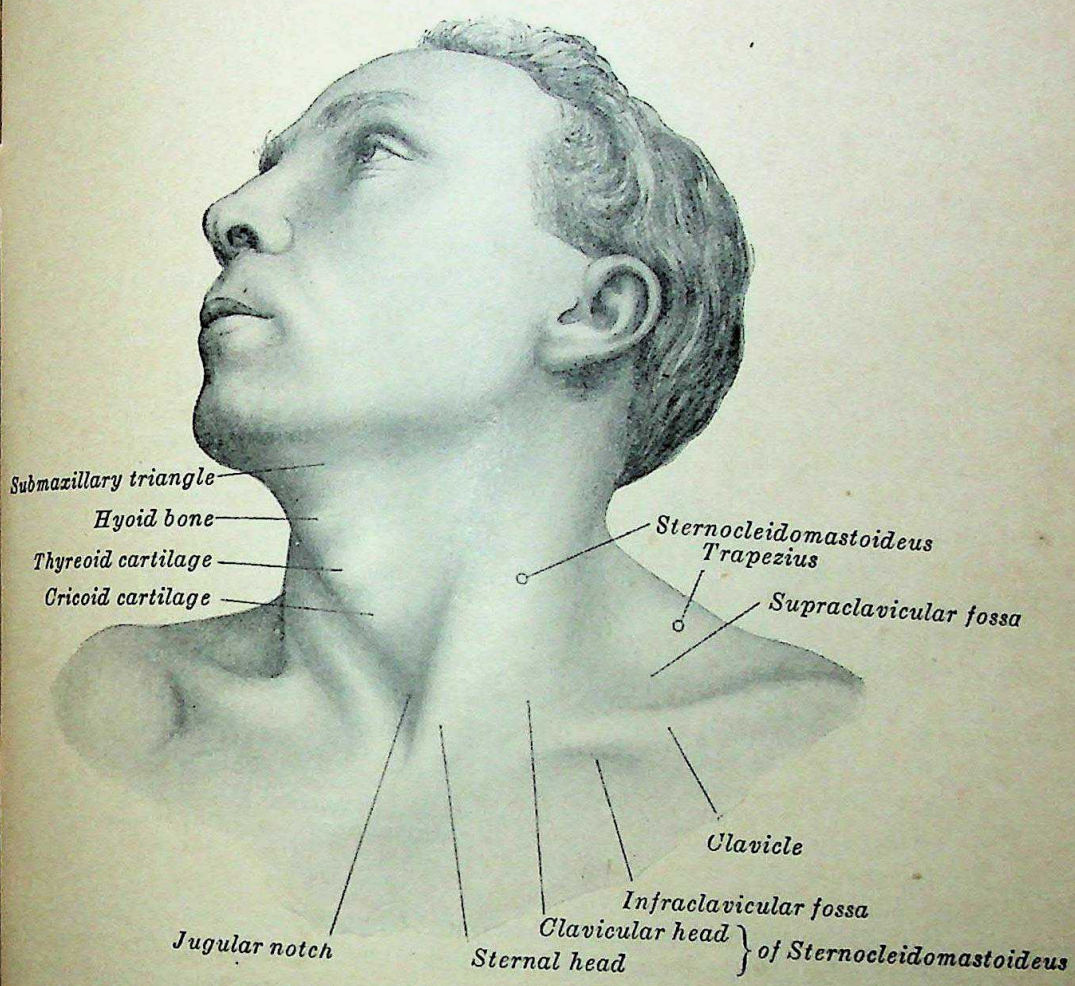

he middle portion of the muscle appears as an oblique elevation with a thick, terior border, best marked in its lower part. The sternal heads of the two muscles e separated by a V-shaped depression (jugular notch), the floor of which is formed the *Sternohyoideus* and *Sternothyreoideus*. The lateral border of the *Scalenus terior* is just under cover of and parallel with the posterior border of the Sternoidomastoideus.

Above the hyoid bone, near the middle line, the anterior belly of the *Digastricus* es rise to a slight convexity.

The anterior border of the *Trapezius* produces a faint ridge running downwards d forwards from the superior nuchal line to the junction of the intermediate th the lateral one-third of the clavicle. Between the Sternocleidomastoideus and e Trapezius is the posterior triangle of the neck, the lower part of which appears a shallow concavity—the supraclavicular fossa. In this fossa, the inferior belly the *Omohyoideus*, when in action, causes a cord-like elevation a little above d almost parallel to the clavicle.

The arteries.—The positions of several of the larger arteries can be ascertained their pulsations.

CC-0. In Public Domain. Gurukul Kangri Collection, Haridwar

Digitized by Arya Samaj Foundation Chennai and eGangotri

The *subclavian artery* is felt on making pressure downwards, backwards, and medialwards behind the lateral margin of the clavicular head of the Sternocleidomastoideus; the *transverse cervical artery* may be detected parallel to, and about a finger's breadth above, the clavicle. The *common* and *external carotid arteries* can be recognised immediately beneath the anterior edge of the Sternocleidomastoideus, and the *external maxillary artery* can be traced over the inferior border of the mandible at the anterior edge of the Masseter, about 3 cm. in front of the angle of the mandible. The pulsation of the *occipital artery* may be felt about 3 cm. or 4 cm. lateral to the external occipital protuberance, and that of the *posterior auricular artery* in the groove between the mastoid process and the auricula. The course of the *superficial temporal artery* can be readily followed upwards across the

FIG. 1216.—A front view of the neck.

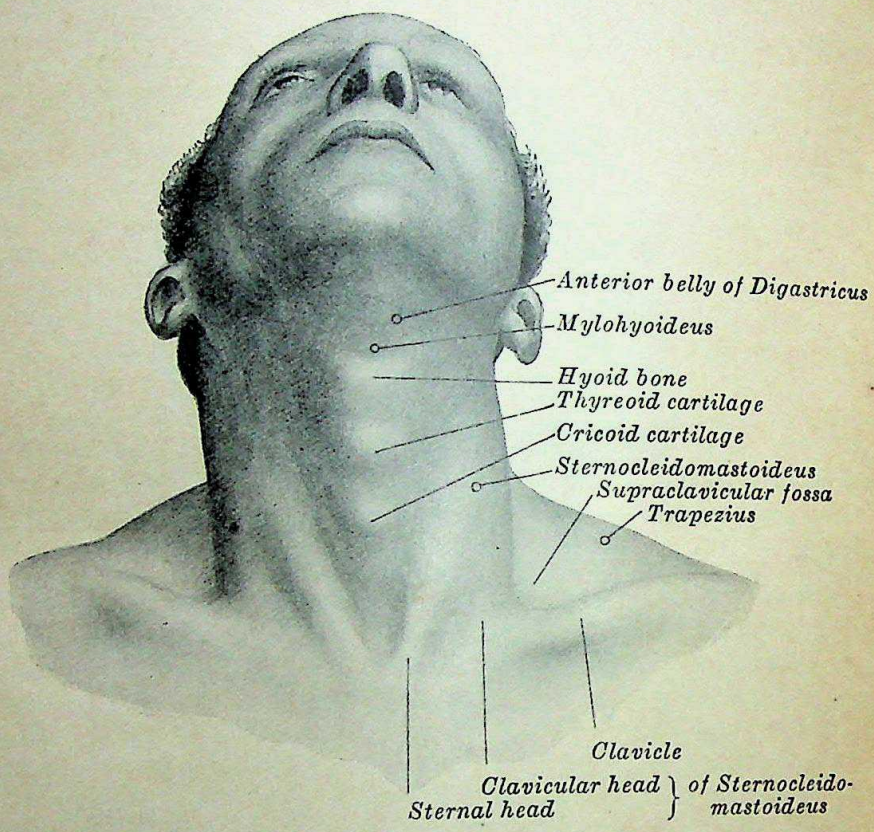

posterior end of the zygomatic arch to a point about 4 cm. above the arch, where it divides into its frontal and parietal branches; the pulsation of the frontal branch is frequently visible on the side of the forehead. The *supra-orbital artery* can usually be detected immediately above the supra-orbital notch or foramen.

The **larynx and trachea**.—In the receding angle below the chin, the hyoid bone (p. 1258), situated opposite the lower part of the third cervical vertebra, can easily be made out; when the head is erect the hyoid bone is on the same level as the lower border of the mandible. Immediately below it, is the laryngeal prominence (pomum Adami) of the thyreoid cartilage; the space between the hyoid bone and the thyreoid cartilage is occupied by the hyothyreoid membrane. The outlines of the laminæ and cornua of the thyreoid cartilage are readily palpated; below this cartilage is a depression corresponding to the middle cricothyreoid ligament. The level of the vocal folds (true vocal cords) corresponds to the middle of the anterior margin of the thyreoid cartilage. The anterior part of the cricoid cartilage forms an important landmark on the front of the neck; it lies opposite the sixth cervical vertebra, and indicates the junctions of the pharynx with the œsophagus, and of the larynx with the trachea. Below the cricoid cartilage the trachea can be felt, but only in thin subjects are its rings distinguishable; as a rule there are seven or eight rings above the jugular notch of the sternum, and of these the second, third, and fourth are covered by the isthmus of the thyreoid gland. The normal thyreoid gland cannot be felt.

CC-0. In Public Domain. Gurukul Kangri Collection, Haridwar

Digitized by Arya Samaj Foundation Chennai and eGangotri

The **submaxillary gland**.—On either side of the neck the superficial portion of the submaxillary gland, as it lies partly under cover of the body of the mandible, can be felt. To palpate the entire gland the head should be thrown forwards to relax the investing layer of the fascia colli; the index finger of one hand is placed in the digastric triangle, that of the other hand is placed on the floor of the mouth, under the tongue; the gland is easily made out between the fingers.

THE SURFACE MARKINGS OF SPECIAL REGIONS OF THE HEAD AND NECK

The Cranium

The **scalp**.—The soft parts covering the upper surface of the skull form the scalp and comprise the following layers (fig. 1217): (1) skin, (2) subcutaneous tissue, (3) Occipitalis, Frontalis, and galea aponeurotica, (4) subaponeurotic tissue, (5) pericranium. The subcutaneous tissue consists of a close meshwork of fibres, the

Fig. 1217.—A coronal section through the scalp and skull. Diagrammatic.

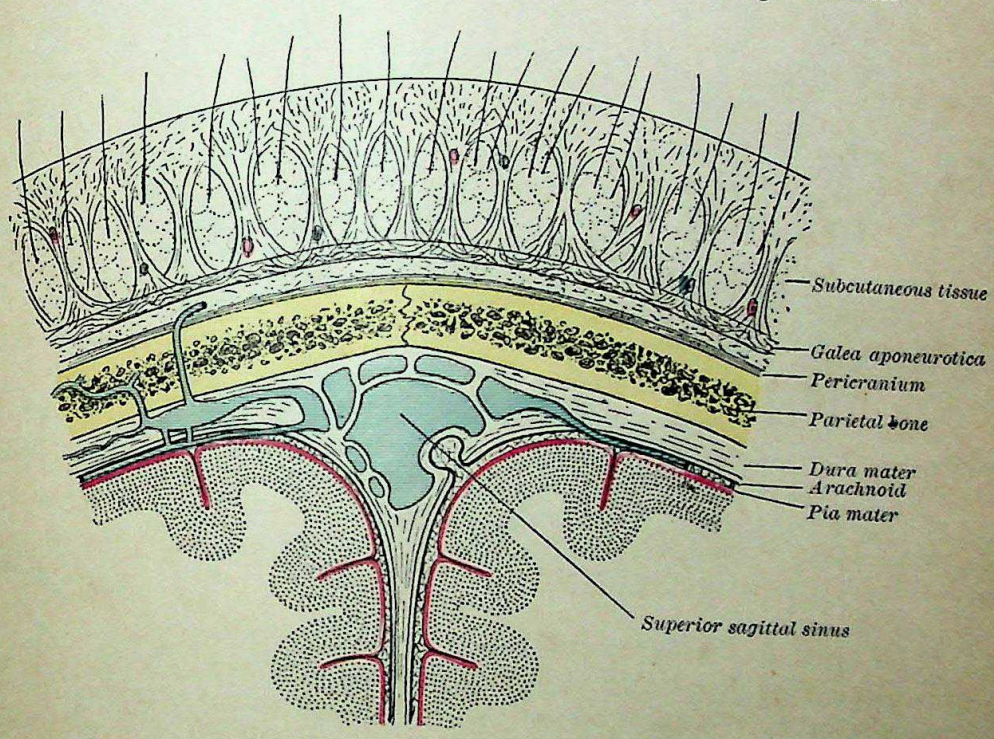

meshes of which contain fatty tissue; the fibres bind the skin and galea aponeurotica firmly together, so that when the Occipitalis or the Frontalis is in action the skin moves with the aponeurosis. The subaponeurotic tissue is much looser in texture, and permits the movement of the galea aponeurotica over the underlying pericranium.

The **bony landmarks** (fig. 1214).—In addition to the bony points already described, which can be determined by palpation, the following are utilised for surface markings:

Asterion.—The point of meeting of the lambdoid, masto-occipital, and masto-parietal sutures; it lies 4 cm. behind and 12 mm. above the level of the auricular point.

Auricular point.—The centre of the orifice of the external acoustic meatus.

Bregma.—The meeting-point of the coronal and sagittal sutures; it lies at the point of intersection of the middle line of the scalp with a line drawn vertically upwards through the pre-auricular point.

Lambda.—The point of meeting of the lambdoid and sagittal sutures; it is in the middle line about 6·5 cm. above the inion.

CC-0. In Public Domain. Gurukul Kangri Collection, Haridwar

Digitized by Arya Samaj Foundation Chennai and eGangotri

Pre-auricular point.—A point on the posterior root of the zygomatic arch immediately in front of the orifice of the external acoustic meatus.

Pterion.—The point where the great wing of the sphenoid joins the sphenoidal angle of the parietal; it is situated 35 mm. behind, and 12 mm. above, the level of the frontozygomatic suture.

A line passing through the inferior margin of the orbit and the auricular point is known as *Reid's base-line.*

The right or left half of the *lambdoid suture* is indicated by the upper two-thirds of a line uniting the lambda to the tip of the corresponding mastoid process. The

Fig. 1218.—A drawing of a cast to illustrate the relations of the brain to the skull. (Cunningham.)

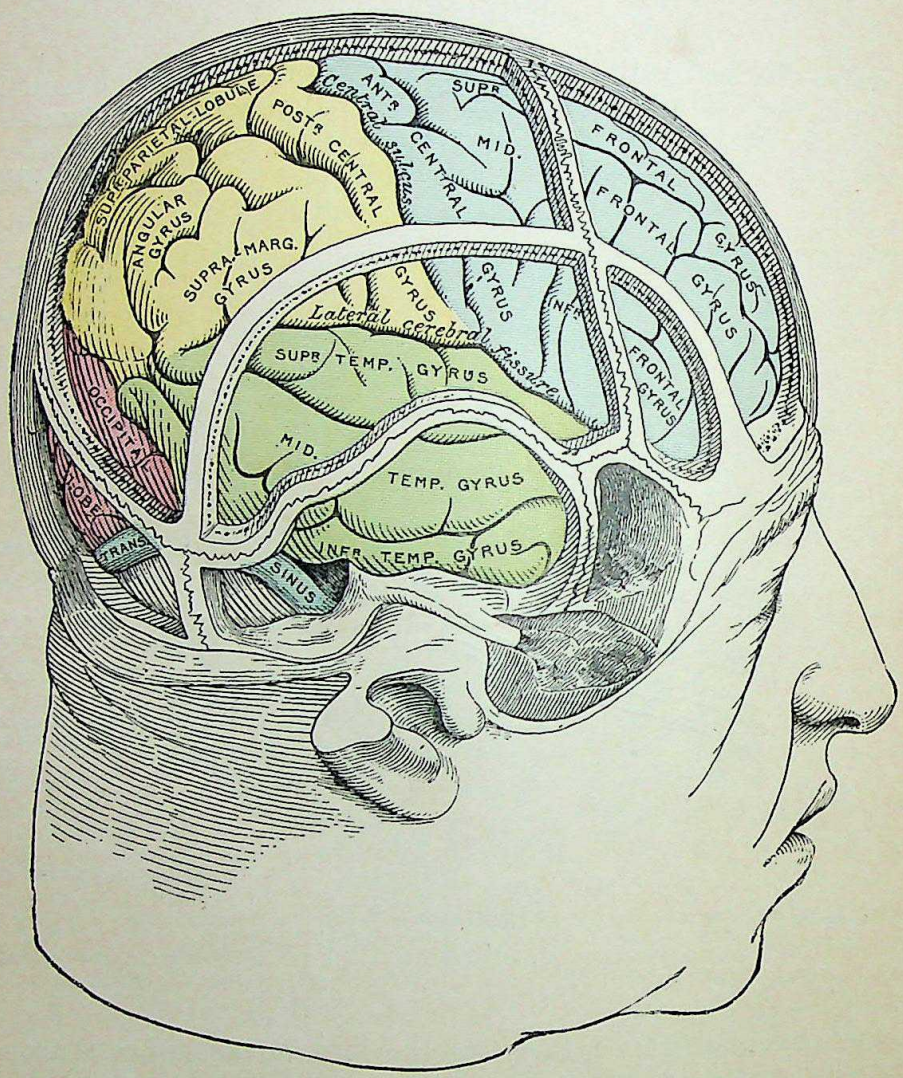

sagittal suture is in the line joining the lambda to the bregma. The position of the *coronal suture* is represented by a line connecting the bregma with the centres of the zygomatic arches.

The floor of the middle fossa of the skull is at the level of the posterior three-fourths of the upper border of the zygomatic arch; the articular tubercle of the temporal bone is opposite the foramen spinosum and the semilunar ganglion.

The **brain** (figs. 1218, 1219).—The general outline of the *cerebral hemisphere*, on either side, may be mapped out on the surface in the following manner. A line drawn from the nasion along the middle of the scalp to the inion represents the superomedial border. The line of the posterior part of the lower border is that of the transverse sinus (p. 1264), or more roughly a line convex upwards from the inion to the posterior root of the zygomatic process of the temporal bone; thence along the posterior three-fourths of the upper border of the zygomatic arch and then upwards to the pterion; the anterior part of the lower border extends from

CC-0. In Public Domain. Gurukul Kangri Collection, Haridwar

Digitized by Arya Samaj Foundation Chennai and eGangotri

the pterion to the glabella about 1 cm. above the supra-orbital margin. The *cerebellum* is so deeply situated that there is no satisfactory surface marking for it; a point 4 cm. behind and 1·5 cm. below the level of the auricular point is situated directly over it.

The relations of the principal fissures and gyri of the cerebral hemispheres to the surface of the scalp are of practical importance, and several methods of indicating them have been devised. These methods are only approximately correct, but are sufficiently accurate for surgical purposes. The *longitudinal fissure* corresponds to the median line of the scalp between the nasion and inion.

FIG. 1219.—The relations of the brain and the middle meningeal artery to the surface of the skull.

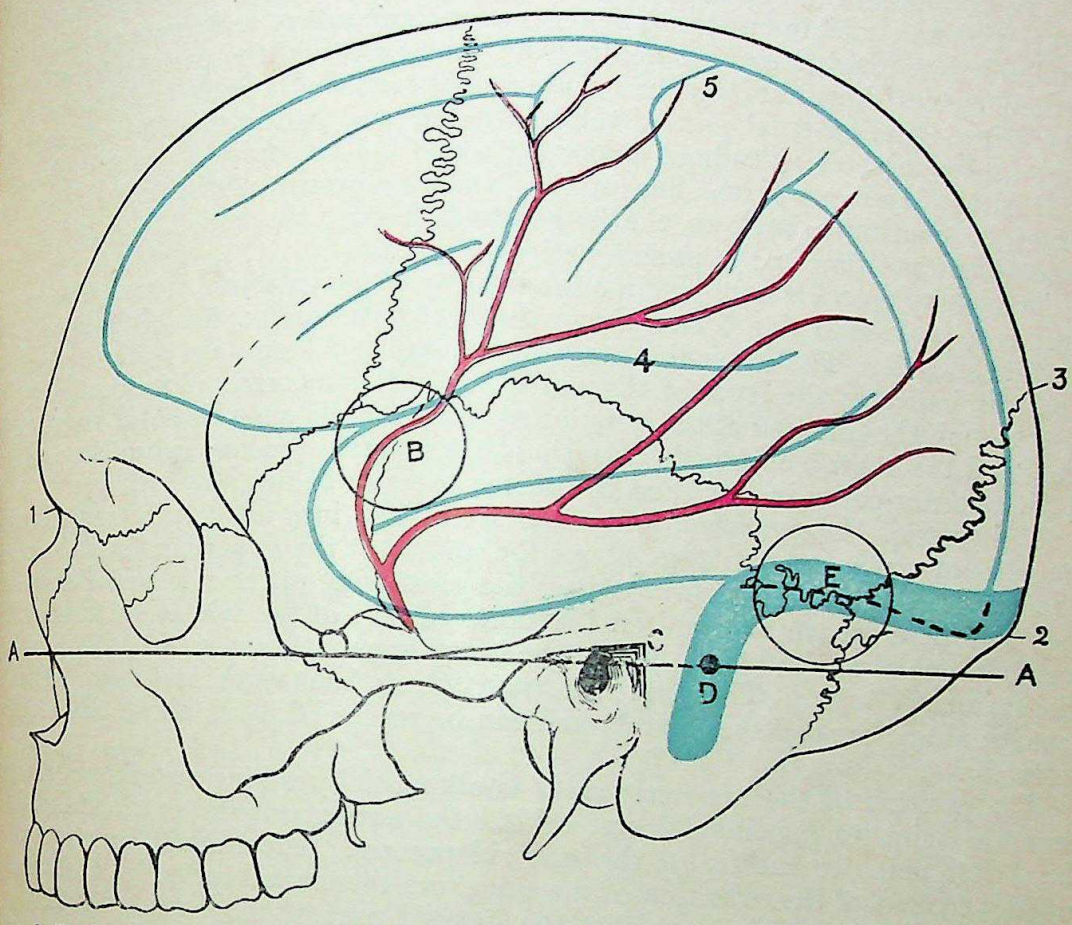

1. Nasion. 2. Inion. 3. Lambda. 4. Lateral cerebral fissure. 5. Central sulcus. AA. Reid's base-line. B. Point for trephining over the anterior branch of the middle meningeal artery. C. Supra-meatal triangle. D. Sigmoid bend of the transverse sinus. E. Point for trephining over the straight portion of the transverse sinus, exposing dura mater of both cerebrum and cerebellum. The outline of the cerebral hemisphere is indicated in blue; the course of middle meningeal artery in red.

To mark out the *lateral cerebral (Sylvian) fissure* a point, named the Sylvian point, is defined 35 mm. behind and 12 mm. above the level of the frontozygomatic suture, the latter being recognised by a notch in its posterior border; the Sylvian point marks the spot where the stem of the lateral cerebral fissure divides. Another method of defining the Sylvian point is to divide the distance between the nasion and inion into four equal parts; from the junction of the third with the fourth part (reckoning from the front) draw a line to the frontozygomatic suture; from the junction of the first with the second part another line to the auricular point. These two lines intersect at the Sylvian point, and the portion of the first line behind this point overlies the posterior ramus of the lateral cerebral fissure. The position of the posterior ramus can also be obtained by joining the Sylvian point to a point 2 cm. below the summit of the parietal tuberosity. The anterior ascending ramus is marked by drawing a line upwards at right angles to the line of the posterior ramus for 2 cm., and the anterior horizontal ramus by a line of the same length drawn horizontally forwards both from the Sylvian point. The upper end of the *central sulcus* (fissure of Rolando) is in the median line of the skull 1·25 cm. behind the middle of the line

CC-0. In Public Domain. Gurukul Kangri Collection, Haridwar

Digitized by Arya Samaj Foundation Chennai and eGangotri

joining the nasion and inion; the lower end is 5 cm. vertically above the pre-auricular point, the fissure ending just above the posterior ramus of the lateral cerebral fissure. Measured on the scalp this line is 9 cm. long and forms an angle, opening forwards, of about 70° with the median line of the scalp. The *precentral* and *postcentral sulci* are nearly parallel with the central sulcus, and are situated about 15 mm. in front of, and behind, it respectively. The *superior frontal sulcus* is indicated by a line drawn from the junction of the upper with the middle one-third of the precentral sulcus, in a direction parallel with the longitudinal sulcus, to a point midway between the middle line of the forehead and the temporal line, 4 cm. above the supra-orbital notch. The *inferior frontal sulcus* begins at the junction of the middle with the lower one-third of the precentral sulcus, and follows the course of the superior temporal line.

The horizontal limb of the *intraparietal sulcus* begins near the junction of the lower with the middle one-third of the postcentral sulcus and curves backwards parallel to the longitudinal fissure, midway between it and the parietal tuberosity; it then curves downwards to end midway between the lambda and the parietal tuberosity. The external part of the *parieto-occipital fissure* runs lateralwards at right angles to the longitudinal fissure for about 2·5 cm. from a point 5 mm. in front of the lambda. If the line of the posterior ramus of the lateral cerebral fissure be continued back to the longitudinal fissure, the last 2·5 cm. of it will indicate the position of the parieto-occipital fissure.

The *lateral ventricle* may be circumscribed by a quadrilateral figure. The upper limit is a horizontal line 5 cm. above the zygomatic arch; this defines the roof of the ventricle. The lower limit is a horizontal line 1 cm. above the zygomatic arch; it indicates the level of the end of the inferior cornu. Two vertical lines, one through the junction of the anterior with the middle one-third of the zygomatic arch, and the other 5 cm. behind the tip of the mastoid process, indicate the extent of the anterior cornu in front and the posterior cornu behind.

The **vessels.**—The *middle meningeal artery* divides into its anterior and posterior branches at a point about 2 cm. above the middle of the upper border of the zygomatic arch. Its anterior branch crosses the great wing of the sphenoidal bone, and then lies in a groove or canal on the inner surface of the sphenoidal angle of the parietal bone at a point 4 cm. behind the frontozygomatic suture and 4·5 cm. above the zygomatic arch. The posterior branch runs backwards less than a finger's breadth above the zygomatic arch, and can be reached 2·5 cm. above the auricular point.

The position of the *transverse sinus* is obtained by taking two lines: the first from the inion to a point 2·5 cm. behind the auricular point; the second from this latter point to the tip of the mastoid process. The second line corresponds roughly to that of the reflection of the skin from the cranial surface of the auricula, and its upper two-thirds represents the sigmoid part of the sinus. The first part of the sinus has a slight upward convexity, and its highest point is about 4 cm. behind and 1 cm. above the level of the auricular point. The width of the sinus is about 1 cm.

The Face

The **air-sinuses** (fig. 1220).—The frontal and maxillary air-sinuses vary so greatly in form and size that their surface markings must be regarded as only approximate. To mark out the position of the *frontal air-sinus* three points are taken: one at the nasion, a second in the middle line 3 cm. above the nasion, and a third at the junction of the lateral with the intermediate one-third of the supra-orbital margin. By joining these a triangular field is described which overlies the greater part of the air-sinus. The outline of the *maxillary air-sinus* is irregularly quadrilateral and is obtained by joining up the following points: (1) the lacrimal tubercle, (2) a point on the zygomatic bone at the junction of the inferior with the lateral margin of the orbit, (3) and (4) points on the alveolar process above the last molar and the second premolar teeth respectively.

The **external maxillary artery.**—The course of the *external maxillary artery* on the face may be indicated by a line starting from the lower border of the mandible at the anterior margin of the Masseter, and running at first forwards and upwards to a point 1 cm. lateral to the angle of the mouth, thence to a point a little behind the ala of the nose and upwards to the medial commissure of the eye (fig. 1221).

CC-0. In Public Domain. Gurukul Kangri Collection, Haridwar

Digitized by Arya Samaj Foundation Chennai and eGangotri

The **trigeminal nerve.**—The *supratrochlear nerve* crosses the supra-orbital margin about 1 cm. from the middle line. The *supra-orbital*, *infra-orbital*, and *mental nerves* emerge from the corresponding foramina on the face (fig. 1221). The supra-orbital foramen is situated at the junction of the medial with the intermediate third of the supra-orbital margin. A line drawn from this foramen to the lower border of the mandible, through the interval between the lower premolar teeth, passes over the infra-orbital and mental foramina: the former lies about 1 cm. below the margin of the orbit, while the latter varies in position according to the age of the individual; in the adult it is midway between the upper and lower borders of the mandible, in the child it is nearer the lower border, while in the edentulous jaw of old age it is close to the upper margin.

Fig. 1220.—An outline of the bones of the face, showing the positions of the frontal and maxillary air-sinuses.

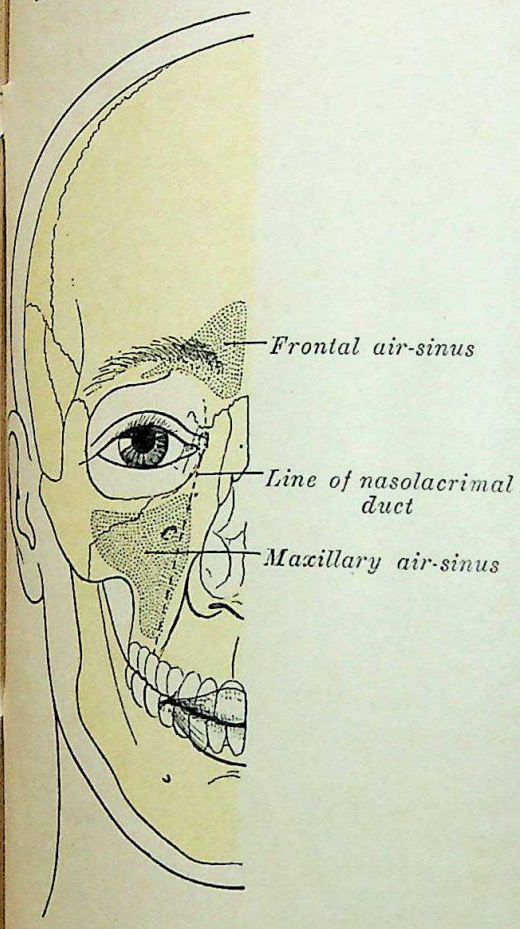

Fig. 1221.—An outline of the side of the face, showing the chief surface markings.

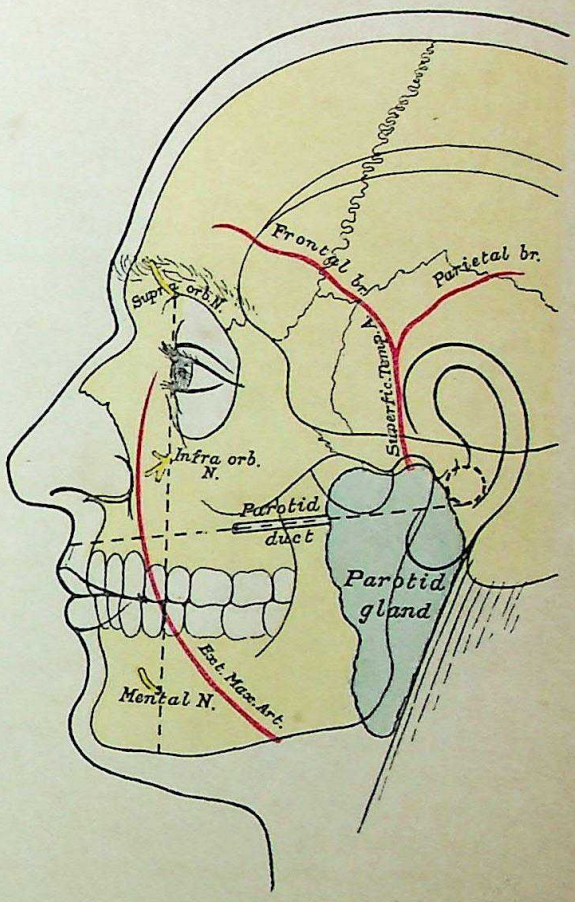

The position of the *sphenopalatine ganglion* is indicated from the side by a point on the upper border of the zygomatic arch, 6 mm. from the temporal border of the zygomatic bone. The foramen ovale, which is the guide to the *semilunar ganglion*, lies opposite the anterior border of the neck of the mandible.

The **parotid gland** (fig. 1221).—The upper border of the parotid gland corresponds to the posterior two-thirds of the lower border of the zygomatic arch; the posterior border to the front of the external acoustic meatus, the mastoid process, and the anterior border of Sternocleidomastoideus. The inferior border is indicated by a line from the tip of the mastoid process to the junction of the body and greater cornu of the hyoid bone. In front, the anterior border extends for a variable distance on the superficial surface of the Masseter. The surface marking for the *parotid duct* is the middle one-third of a line drawn across the face about a finger's breadth below the zygomatic arch, i.e. from the lower margin of the concha to midway between the red margin of the lip and the ala of the nose; the duct ends opposite the second upper molar tooth and measures about 5 cm. in length.

CC-0. In Public Domain. Gurukul Kangri Collection, Haridwar

Digitized by Arya Samaj Foundation Chennai and eGangotri

The Nose

The outlines of the nasal bones and the cartilages forming the external nose can be easily felt. The mobile portion of the nasal septum, formed by the medial crura of the greater alar cartilages and the skin, is easily distinguished between the nares. When the head is tilted back and a speculum introduced through one naris, the floor of the nasal cavity, the lower part of the nasal septum, and the anterior ends of the middle and inferior nasal conchæ can be examined. The opening of the nasolacrimal duct, which lies under cover of the front of the inferior nasal concha, is situated about 2·5 cm. behind the naris and 2 cm. above the floor of the nasal cavity.

The Mouth

The orifice of the mouth is bounded by the lips, and its angles usually correspond to the lateral borders of the canine teeth. In the middle of the outer surface of the upper lip is a shallow groove—the philtrum. When the lips are everted, a small fold

Fig. 1222.—The mouth-cavity. The cheeks have been slit transversely and the tongue pulled forwards.

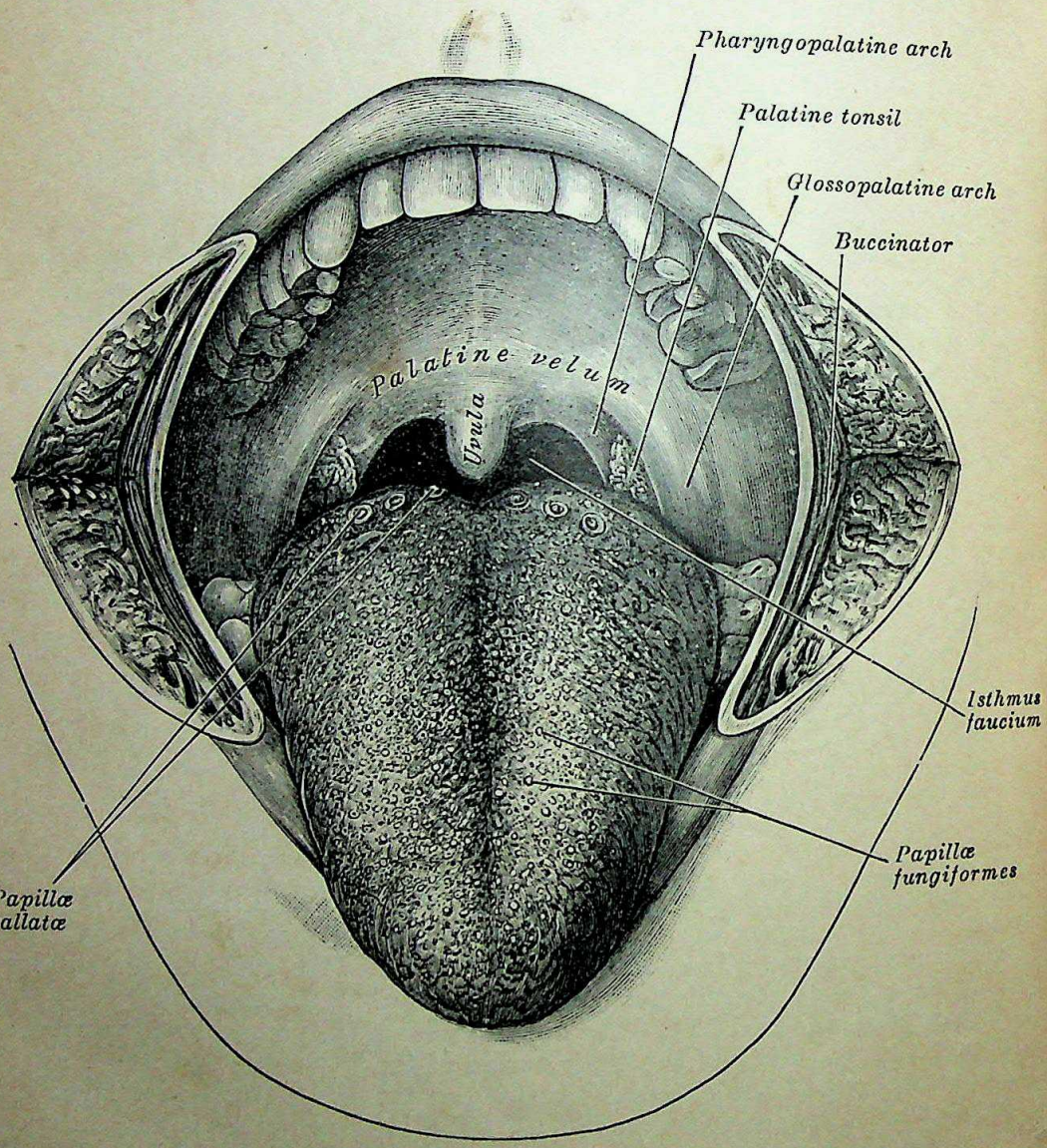

of mucous membrane, termed the frenulum, is seen in the middle line of each, passing from the lip to the gum. By pulling the angle of the mouth outwards the mucous membrane of the cheek can be inspected, and on this, opposite the second upper molar tooth, is the little papilla which marks the orifice of the parotid duct.

The upper surface of the tongue (fig. 1222) is convex and marked in the middle line by a shallow sulcus; its anterior two-thirds are rough and studded with papillæ;

CC-0. In Public Domain. Gurukul Kangri Collection, Haridwar

Digitized by Arya Samaj Foundation Chennai and eGangotri

its posterior one-third is smoother and contains many muciparous glands and lymph-follicles; it is much more sensitive than the anterior papillary part. These two parts are separated by a V-shaped furrow, the sulcus terminalis, which is situated immediately behind the papillæ vallatæ.

The mucous membrane on the under surface of the tongue (fig. 1223) is smooth and devoid of papillæ. In the middle line it extends to the floor of the mouth as a fold—the frenulum—the free edge of which runs forwards to the symphysis of the mandible. The *lingual veins* are seen immediately beneath the mucous membrane on either side of the frenulum. On either side of the attachment of the

FIG. 1223.—The mouth-cavity. The apex of the tongue is turned upwards, and on the right side a superficial dissection of its under surface has been made.

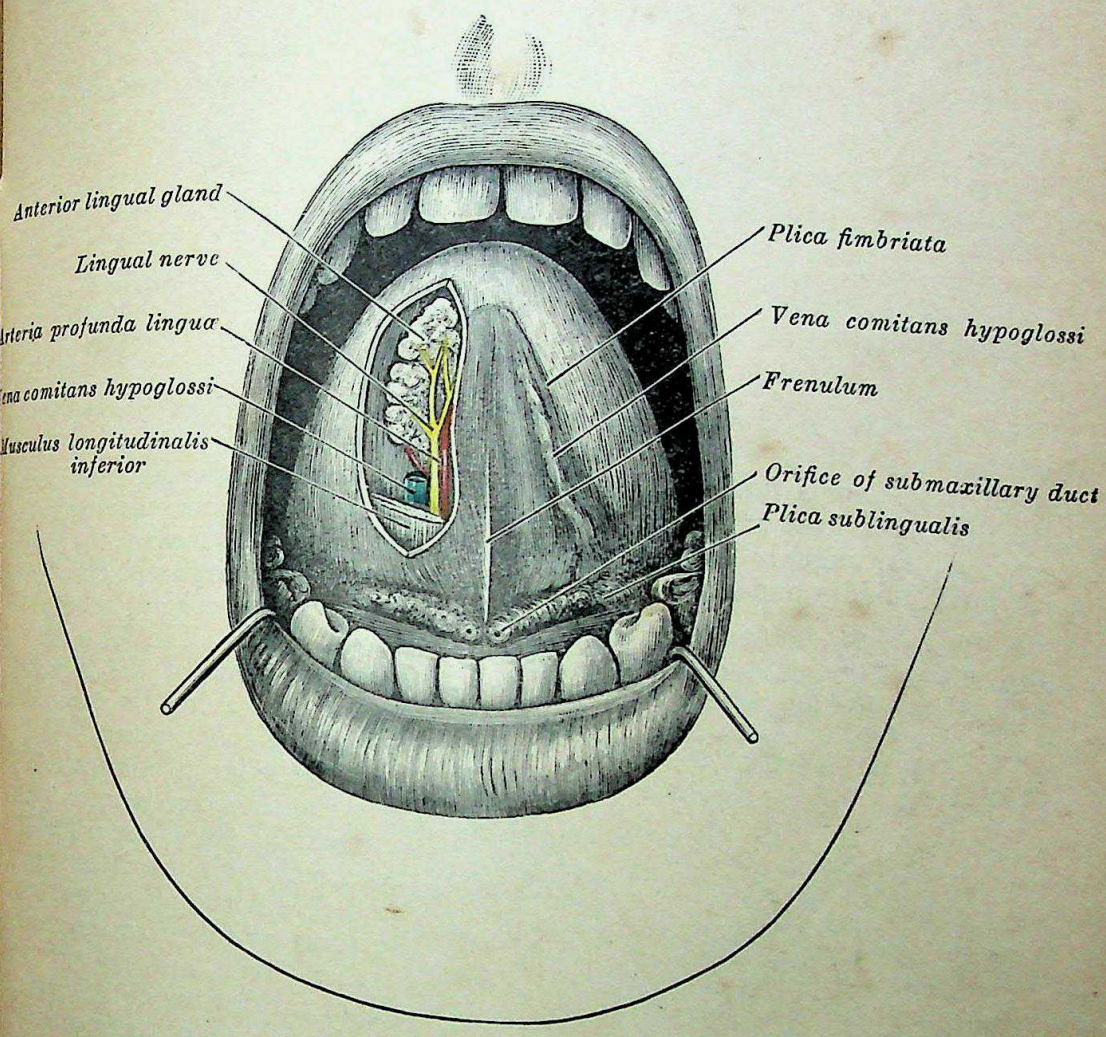

enulum to the floor of the mouth is a papilla on which the slit-like orifice of the bmaxillary duct is seen. Running backwards and lateralwards from the orifice f the submaxillary duct is the plica sublingualis, produced by the upward pro- ction of the sublingual gland which lies immediately beneath the mucous membrane. he plica sublingualis serves also to indicate the lines of the submaxillary duct nd lingual nerve; they lie on the medial side of the sublingual gland. At the ack of the mouth is the isthmus faucium, bounded above by the palatine velum, om the free margin of which the uvula projects downwards in the middle line. n either side of the isthmus are the two palatine arches, the anterior formed the Glossopalatinus and the posterior by the Pharyngopalatinus. Between e two arches of either side is the palatine tonsil, with the small supratonsillar ess above it; the position of the tonsil corresponds to the angle of the mandible. hen the mouth is opened widely, a tense band—the pterygomandibular raphe— n be seen and felt lateral to the glossopalatine arch. Its lower end is attached the mandible behind the last molar tooth, and immediately below and in front this attachment the lingual nerve can be felt; the upper end of the raphe is d to the pterygoid hamulus. About 1 cm. anterior to the hamulus and 1 cm.

CC-0. In Public Domain. Gurukul Kangri Collection, Haridwar

Digitized by Arya Samaj Foundation Chennai and eGangotri

medial to the third upper molar tooth is the greater palatine foramen through which the greater palatine vessels and the anterior palatine nerve emerge. Behind the third upper molar tooth the coronoid process of the mandible is palpable.

Fig. 1224.—The front of the nasal part of the pharynx, as seen with the laryngoscope.

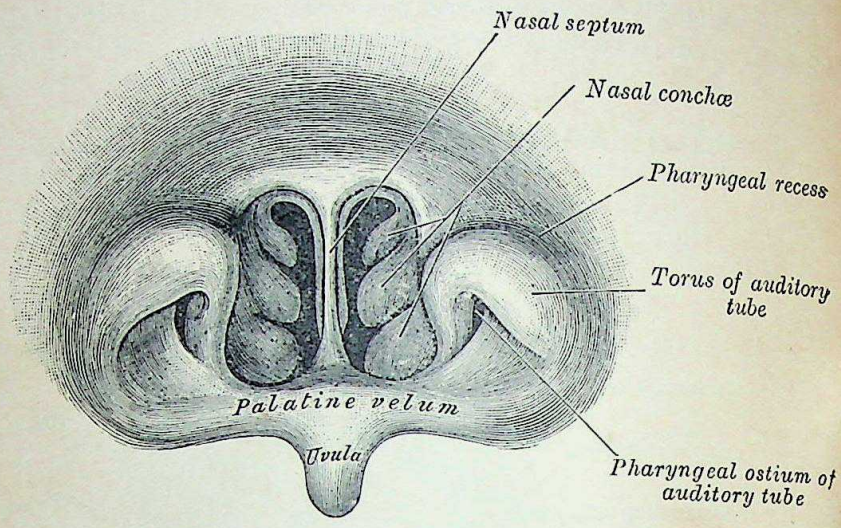

By tilting the head well back a portion of the posterior pharyngeal wall corresponding to the level of the second and third cervical vertebræ, can be seen through the isthmus faucium. On introducing the finger the anterior surfaces of the upper cervical vertebræ can be felt through the thin muscular wall of the pharynx; if the finger be hooked round the palatine velum, the choanæ, the posterior ends of the middle and inferior nasal conchæ, and the pharyngeal ostia of the auditory (Eustachian) tubes can be distinguished. The level of the choanæ is that of the atlas, while the palatine velum is opposite the body of the epistropheus.

Fig. 1225.—A laryngoscopic view of the interior of the larynx.

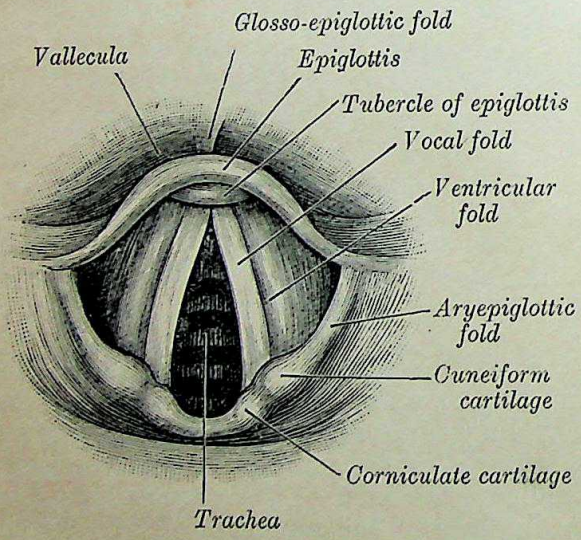

With the laryngoscope the following structures can be seen. In the nasal part of the pharynx (fig. 1224), the choanæ, the nasal septum and conchæ, and the pharyngeal ostia of the auditory tubes can be examined. Farther down are the pharyngeal part of the dorsum of the tongue, the anterior surface of the epiglottis with the glosso-epiglottic and pharyngo-epiglottic folds bounding the valleculæ, and the pyriform recesses. Beyond these is the entrance to the larynx, bounded on either side by the aryepiglottic folds, in each of which are two rounded eminences corresponding to the corniculate and cuneiform cartilages. Within the larynx (fig. 1225) on either side are the ventricular and vocal folds (false and true vocal cords) with the ventricle of the larynx between them. Still deeper, the cricoid cartilage and the anterior parts of some of the cartilaginous rings of the trachea are visible, and sometimes, during deep inspiration, the bifurcation of the trachea. Further investigation of the interior of the lower part of the trachea and the upper parts of the bronchi can be carried out with the bronchoscope.

CC-0. In Public Domain. Gurukul Kangri Collection, Haridwar

Digitized by Arya Samaj Foundation Chennai and eGangotri

THE EYE

The palpebral fissure is elliptical in shape, and varies in form and size in different individuals and in different races of mankind; normally it is oblique, in a direction upwards and lateralwards, so that the lateral commissure is on a slightly higher level than the medial. When the eyes are directed forward as in ordinary vision, the superior part of the cornea is covered by the upper eyelid and its inferior margin is on a level with the free margin of the lower eyelid.

FIG. 1226.—The front of the left eye with the eyelids separated to show the structures at the medial commissure.

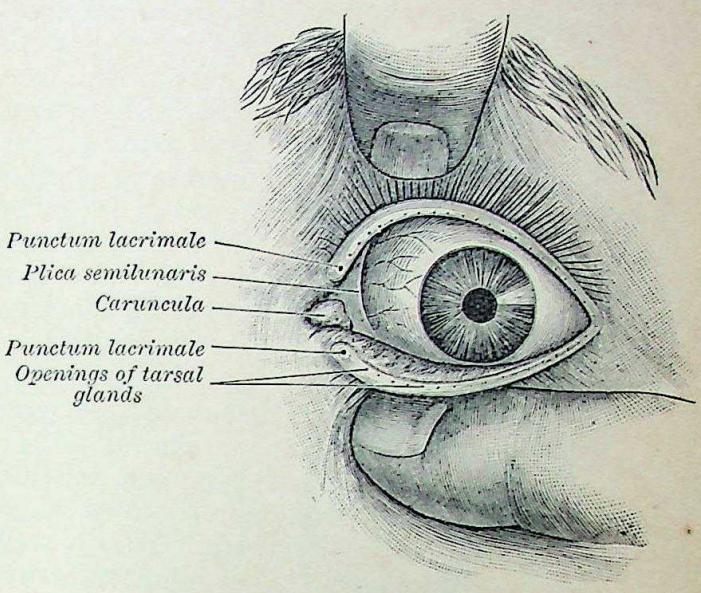

At the medial commissure (fig. 1226) are the caruncula lacrimalis and the plica semilunaris. When the lids are everted, the tarsal glands appear as a series of vertical parallel rows of light yellow granules. On the margins of the lids about 5 mm. from the medial commissure are the puncta lacrimalia; in the natural condition they are in contact with the conjunctiva of the bulb of the eye, so that it is necessary to evert the eyelids to expose them. The lacrimal sac lies immediately above and medial to a small tubercle which can be plainly felt on the inner part of the lower margin of the orbit. If the eyelids be drawn lateralwards the medial palpebral ligament (tendo oculi) can be felt beneath the tightened skin at the medial commissure; it crosses in front of and a little above the middle of the lacrimal sac, and forms a useful guide to it. The direction of the naso-lacrimal duct is indicated by a line from the lacrimal sac to the first upper molar tooth; the length of the duct is about 18 mm.

FIG. 1227.—The interior of the posterior half of the left eyeball.

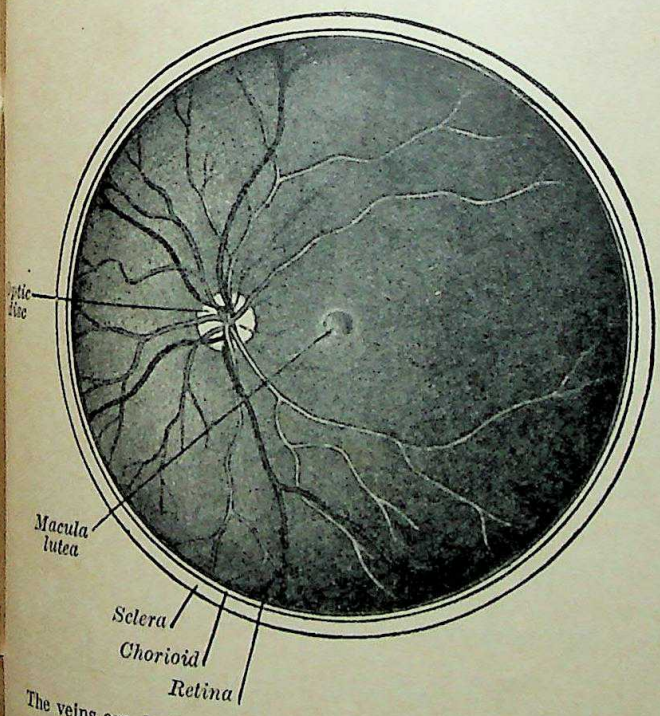

The veins are darker in appearance than the arteries.

On looking into the eye, the iris with its opening, the pupil, and the front of the lens can be examined, but for investigation of the retina an ophthalmoscope is necessary. With this instrument the lens, the vessels of the retina, the optic disc, and the macula lutea can all be inspected (fig. 1227).

On the lateral surface of the nasal part of the frontal bone the pulley of the Obliquus superior can be easily reached by pushing the finger backwards along the roof of the orbit; the tendon of the muscle can be traced for a short distance backwards and lateralwards from the pulley.

CC-0. In Public Domain. Gurukul Kangri Collection, Haridwar

Digitized by Arya Samaj Foundation Chennai and eGangotri

The Ear

The various prominences and fossæ of the auricula (pp. 1022 to 1023) are visible (fig. 1228). The orifice of the external acoustic meatus is exposed by drawing the tragus forwards; at the orifice are a few short crisp hairs which serve to prevent the entrance of dust or of small insects; beyond this the secretion of the ceruminous glands serves to catch any small particles which may find their way into the meatus. The interior of the meatus can be examined through a speculum. At the junction of its bony and cartilaginous portions is an obtuse angle which projects into the antero-inferior wall and produces a narrowing of the lumen. The cartilaginous part, however, is connected to the bony part by fibrous tissue only; this renders the outer portion of the meatus very movable. By drawing the auricula upwards, backwards, and slightly outwards, the cartilaginous portion of the canal is straightened. In children the meatus is very short, and this should be remembered in introducing a speculum.

Fig. 1228.—The auricula or pinna. Lateral surface.

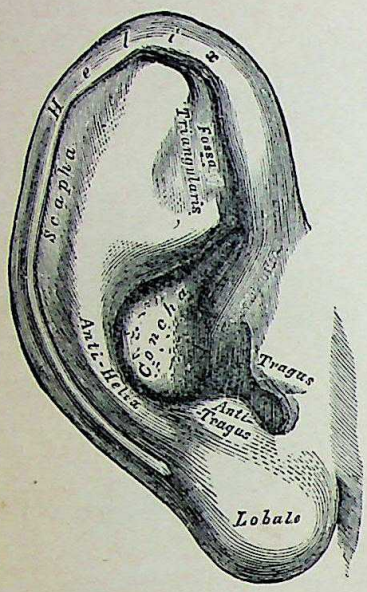

Through the speculum the greater part of the tympanic membrane (fig. 1229) is visible. It is a pearly-grey, slightly glistening membrane; in the adult it is placed obliquely so as to form an angle of about fifty-five degrees with the floor and with the anterior wall of the meatus; at birth it is more horizontal and situated in almost the same plane as the base of the skull. The membrane is concave outwards, and the point of deepest concavity is a little below the centre. Running upwards and slightly forwards from this point is a reddish-yellow streak produced by the manubrium of the malleus. This streak ends above near the roof of the meatus at a small white rounded prominence which is caused by the lateral process of the malleus projecting against the membrane. The anterior and posterior malleolar folds extend from the prominence to the circumference of the membrane and form the lower boundary of the pars flaccida of the membrane. Behind the streak caused by the manubrium of the malleus a shorter and fainter streak can sometimes be distinguished; this is the long crus of the incus. A narrow triangular patch extending downwards and forwards from the lower end of the manubrium mallei reflects the light more brightly than any other part, and is usually described as the cone of light.

Fig. 1229.—The right tympanic membrane, as seen through a speculum.

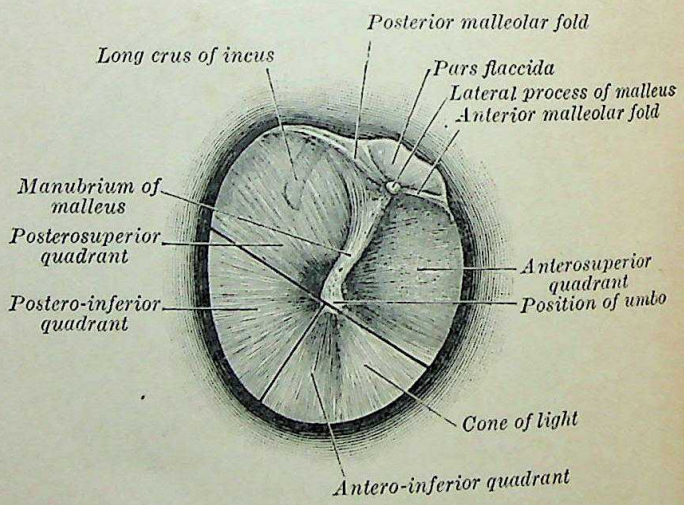

The **tympanic antrum.**—The site of the tympanic antrum is indicated by the suprameatal triangle (fig. 1230) which is bounded above by the posterior root of the zygomatic arch, behind by a vertical line from the posterior border of the orifice of the bony external acoustic meatus, in front and below by the upper margin of the orifice.

CC-0. In Public Domain. Gurukul Kangri Collection, Haridwar

Digitized by Arya Samaj Foundation Chennai and eGangotri

FIG. 1230.—The left temporal bone showing the surface markings for the tympanic antrum (red), the transverse sinus (blue), and the facial nerve (yellow).

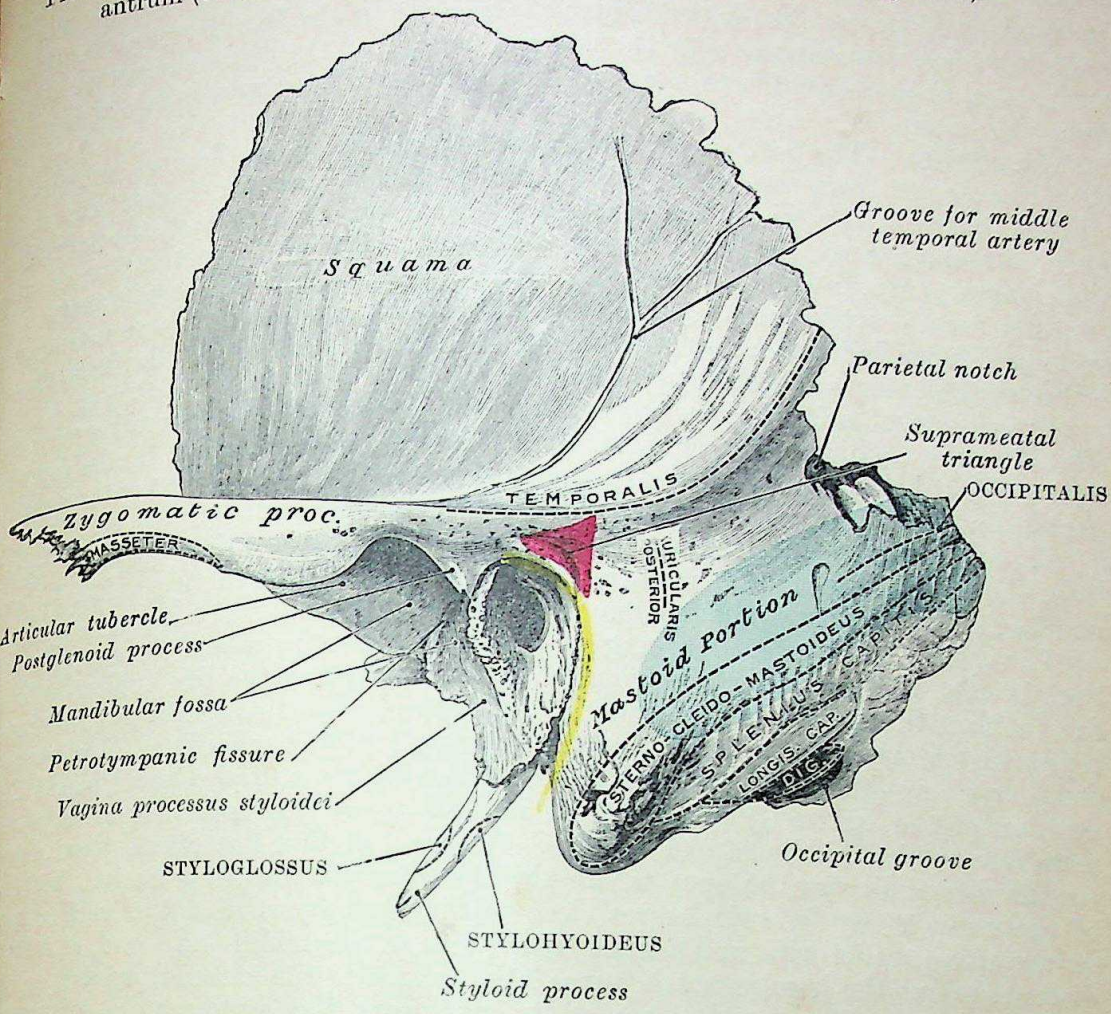

THE NECK (fig. 1231)

The **muscles.**—The posterior belly of the *Digastricus* is marked out by a line from the tip of the mastoid process to the junction of the greater cornu and body

FIG. 1231.—The side of the neck, showing the chief surface markings.

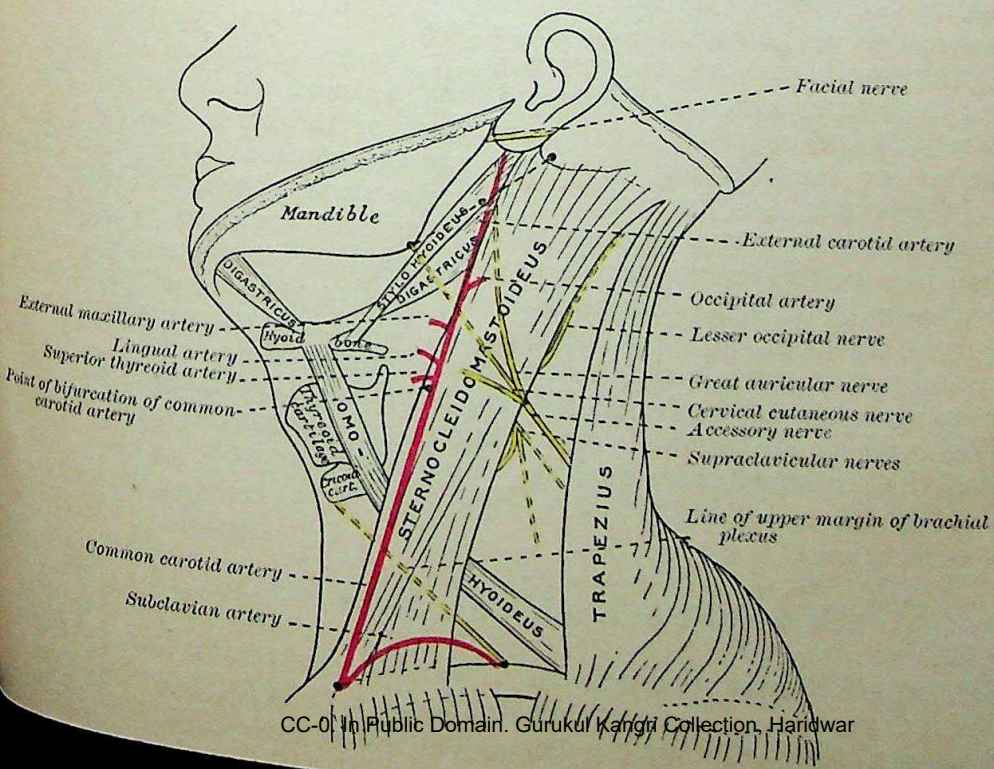

CC-0. In Public Domain. Gurukul Kangri Collection, Haridwar

Digitized by Arya Samaj Foundation Chennai and eGangotri

of the hyoid bone; a line from this latter point to one just lateral to the symphysis of the mandible indicates the position of the anterior belly. The line of the *Omohyoideus* begins at the lower border of the body of the hyoid bone, runs downwards and lateralwards to reach the anterior border of the Sternocleidomastoideus at the level of the cricoid cartilage, and then runs more horizontally to the acromial end of the clavicle.

The **arteries.**—The position of the *common carotid artery* in the neck is indicated by a line drawn from the upper part of the sternal end of the clavicle to a point midway between the tip of the mastoid process and the angle of the mandible. From the clavicle to the upper border of the thyreoid cartilage this line overlies the common carotid artery, beyond this it is over the *external carotid artery*. The external carotid artery may be otherwise marked out by the upper part of a line, arching slightly forwards, from the side of the cricoid cartilage to the front of the orifice of the external acoustic meatus.

The points of origin of the main branches of the external carotid artery are related to the tip of the greater cornu of the hyoid bone as follows: (1) the *superior thyreoid*, just below it; (2) the *lingual*, on a level with it; (3) the *external maxillary* (facial) and (4) the *occipital*, a little above and behind it.

The *subclavian artery* is indicated on the surface by a curved line, convex upwards, from the sternoclavicular articulation to the middle of the clavicle. The highest point of the convexity is about 2 cm. above the clavicle.

The **veins.**—The surface marking for the *internal jugular vein* is parallel with and slightly lateral to that for the common carotid artery; the line indicating it is drawn from the sternal end of the clavicle between the two heads of the Sternocleidomastoideus to a point just behind the angle of the mandible. The *common facial vein* joins the internal jugular vein about the level of the hyoid bone. The position of the *external jugular vein* is marked by a line from the angle of the mandible to the middle of the clavicle. A point on this line about 4 cm. above the clavicle indicates the spot where the vein pierces the deep fascia. The line of the *anterior jugular vein* begins close to the symphysis of the mandible, runs downwards parallel with and a little to one side of the middle line, and, at a short distance above the jugular notch, turns lateralwards to the external jugular.

The **nerves.**—The *facial nerve* at its exit from the stylomastoid foramen is situated, in the adult, about 2·5 cm. from the surface, opposite the middle of the anterior border of the mastoid process; a horizontal line from this point to the ramus of the mandible overlies the stem of the nerve. In the infant there is no mastoid process, and the foramen is placed superficially just behind the orifice of the external acoustic meatus. To mark the course of the *accessory nerve* a line is drawn from a point midway between the angle of the mandible and the tip of the mastoid process to a point on the anterior border of the Sternocleidomastoideus 4 cm. below the apex of the mastoid process; the line is continued across the posterior triangle of the neck to the Trapezius.

The cutaneous branches of the cervical plexus emerge from beneath the posterior border of the Sternocleidomastoideus and may be indicated as follows: the *lesser occipital nerve* appears just above the midpoint of the border and ascends along it to the scalp; the *great auricular* and *cervical cutaneous nerves* start from the middle of the border, the former running upwards towards the lobule of the auricula, the latter crossing the Sternocleidomastoideus at right angles to its long axis; the *supraclavicular nerves* emerge just below the middle of the posterior border and run down over the clavicle. The *phrenic nerve* begins at the level of the middle of the thyreoid cartilage and runs behind the clavicle about midway between the anterior and posterior borders of the Sternocleidomastoideus.

The upper border of the *brachial plexus* is indicated by a line from the side of the cricoid cartilage to the middle of the clavicle; the plexus begins a short distance in front of the posterior border of the Sternocleidomastoideus.

THE SURFACE ANATOMY OF THE BACK

The **bones.**—The only subcutaneous parts of the vertebral column are the apices of the spinous processes. These are distinguishable at the bottom of a furrow which runs down the middle line of the back from the external occipital protuberance

CC-0. In Public Domain. Gurukul Kangri Collection, Haridwar

Digitized by Arya Samaj Foundation Chennai and eGangotri

to the middle of the sacrum. In the *cervical region* the furrow is broad and ends below in a conspicuous projection caused by the spinous processes of the seventh

FIG. 1232.—The surface anatomy of the back.

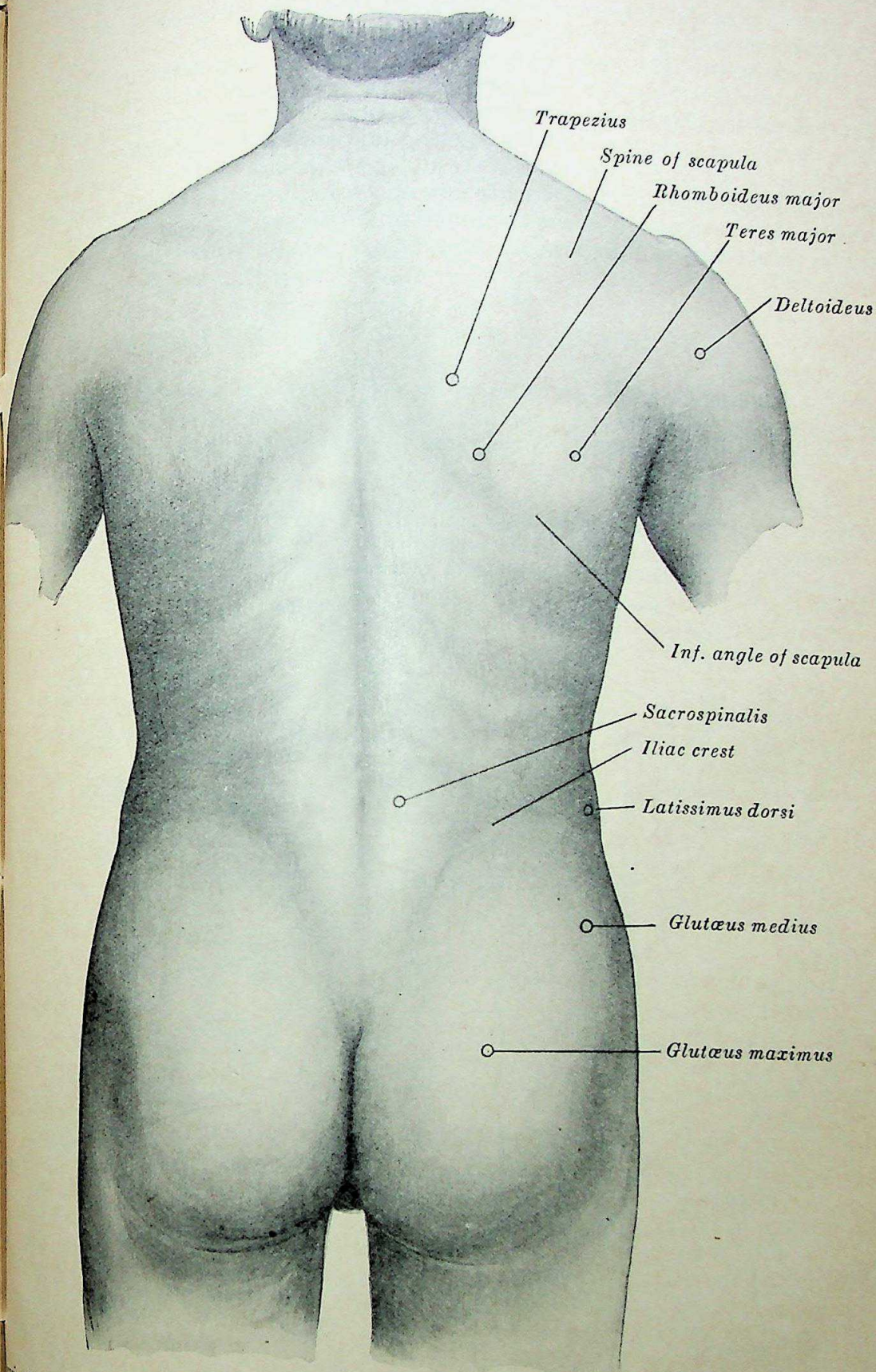

vical and first thoracic vertebræ. Above this, the spinous process of the sixth vical vertebra sometimes forms a projection; the other cervical spinous processes sunken, but that of the epistropheus can be felt. In the *thoracic region* the w is shallow and during stooping disappears, and then the spinous processes me more or less visible; the markings produced by them are small and close

CC-0. In Public Domain. Gurukul Kangri Collection, Haridwar

Digitized by Arya Samaj Foundation Chennai and eGangotri

together. In the *lumbar region* the furrow is deep and the situations of the spinous processes are frequently indicated by little pits, especially when the muscles in the loins are well developed. In the *sacral region* the furrow is shallow and flattened, and ends below at the most prominent part of the dorsal surface of the sacrum, i.e. the spinous process of the third sacral vertebra. At the bottom of the sacral furrow the irregular dorsal surface of the sacrum may be felt, and below this, in the deep groove running to the anus, the coccyx.

The **muscles.**—The deep muscles of the back are so covered by those of the upper extremity (fig. 1232) that they have very little influence on surface form. The *Splenii* by their divergence serve to broaden out the upper part of the back of the neck and produce a fulness in this situation. In the loin the *Sacrospinales*, bound down by the lumbodorsal fascia, form rounded vertical eminences which determine the depth of the spinal furrow and taper below to a point on the dorsal surface of the sacrum. The continuations of the Sacrospinales in the lower thoracic region form flattened planes which are gradually lost on passing upwards.

THE SURFACE MARKINGS OF THE BACK

The **bony landmarks.**—In order to identify any particular spinous process it is customary to count from the prominence caused by the seventh cervical and first thoracic; of these the latter is the more prominent, although the seventh cervical

Fig. 1233.—A diagram showing the relation of the medulla spinalis to the dorsal surface of the trunk. The bones are outlined in red.

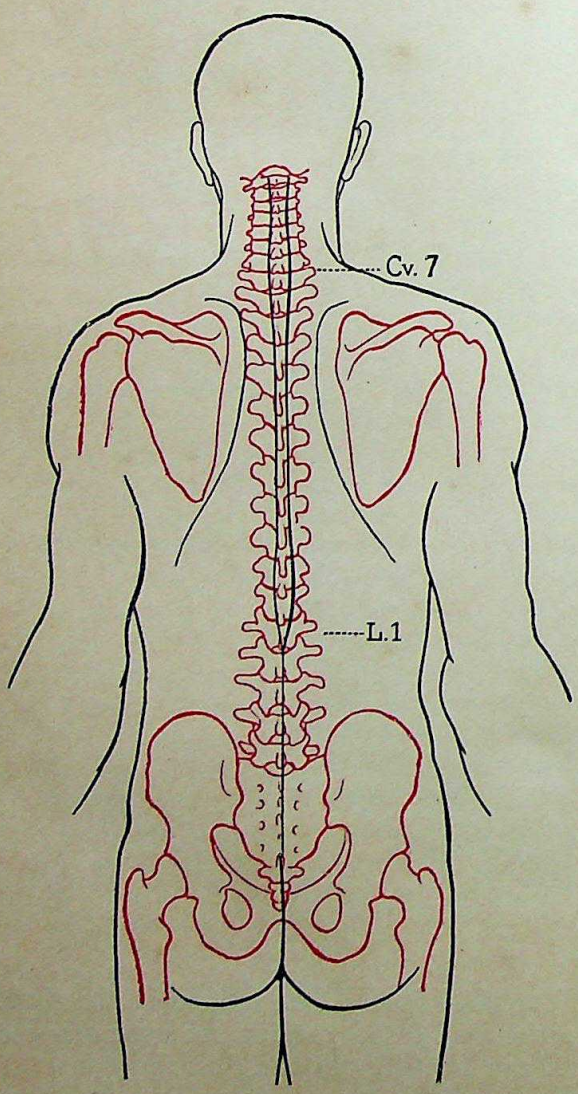

Fig. 1234.—A sagittal section through the lower part of the vertebral canal to show the lower ends of the medulla spinalis and subarachnoid cavity, and the filum terminale. (Testut.)

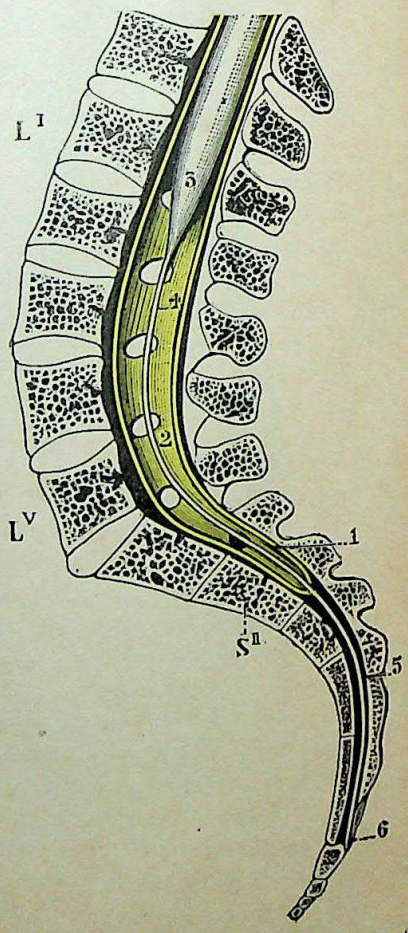

L^{I}, L^{V}. First and fifth lumbar vertebræ. S^{II}. Second sacral vertebra. 1. Dura mater. 2. Lower part of subarachnoid cavity. 3. Lower extremity of medulla spinalis. 4. Filum terminale internum. 5. Filum terminale externum. 6. Attachment of filum terminale to first segment of coccyx.

CC-0. In Public Domain. Gurukul Kangri Collection, Haridwar

Digitized by Arya Samaj Foundation Chennai and eGangotri

is known as the vertebra prominens. The root of the spine of the scapula is on a level with the tip of the spinous process of the third thoracic vertebra, and the inferior angle with that of the seventh. The highest point of the iliac crest is on a level with the spinous process of the fourth lumbar, and the posterior superior iliac spine with that of the second sacral, vertebra.

The **medulla spinalis.**—The position of the lower end of the medulla spinalis varies slightly with the movements of the vertebral column, but, in the adult, in the upright posture it is usually at the level of the spinous process of the second lumbar vertebra (fig. 1233); at birth it is at the level of the third.

The *subdural* and *subarachnoid cavities* end opposite the spinous process of the third sacral vertebra (fig. 1234).

The **spinal nerves** (fig. 1235).—The following table, after Macalister, shows the relations which the places of attachment of the nerves to the medulla spinalis bear to the bodies and spinous processes of the vertebræ :—

Level of body of	No. of nerve.	Level of tip of spine of
C. 1	C. 1	..
	2	..
2	3	1 C.
3	4	2
4	5	3
5	6	4
6	7	5
..	8	6
7	T. 1	7
T. 1	2	1 T.
2	3	..
3	4	2
4	5	3
5	6	4
6	7	5
7	8	6
8	9	7
9	10	8
10	11	9
..	12	10
11	L. 1	11
..	2	..
12	3	..
..	4	12
	5	
L. 1	S. 1	..
	2	
	3	
	4	1 L.
	5	
L. 2	C. 1	
	..	..

FIG. 1235.—A scheme showing the relations of the vertebral spinous processes to the regions of attachment of the spinal nerves. (After Reid.)

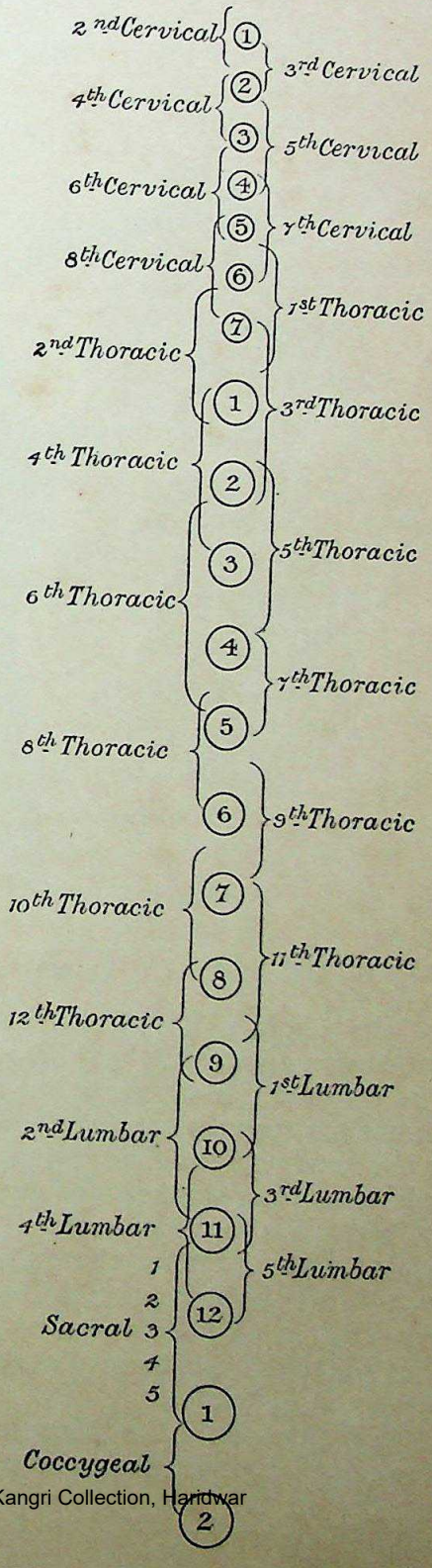

CC-0. In Public Domain. Gurukul Kangri Collection, Haridwar

Digitized by Arya Samaj Foundation Chennai and eGangotri

THE SURFACE ANATOMY OF THE THORAX

The bones.—The skeleton of the thorax is covered to a considerable extent by muscles, so that in a strongly developed muscular subject it is for the most part concealed. In thin persons the *ribs*, especially in the lower and lateral regions, stand out as prominent ridges between the sunken intercostal spaces.

In the middle line, in front, the anterior surface of the *sternum* can be felt throughout its entire length at the bottom of the sternal furrow, between the Pectorales majores. These muscles overlap the anterior surface somewhat, so

FIG. 1236.—The left side of the thorax.

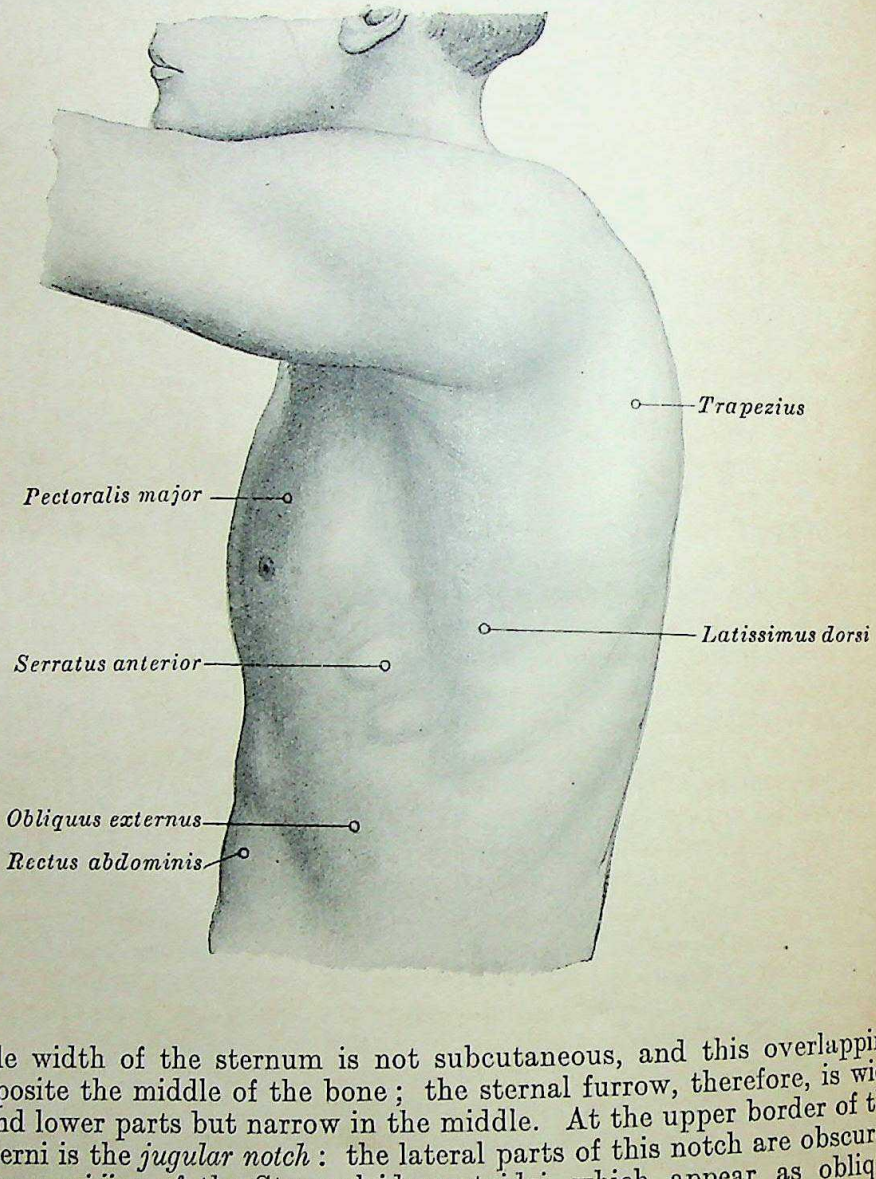

that the whole width of the sternum is not subcutaneous, and this overlapping is greatest opposite the middle of the bone; the sternal furrow, therefore, is wide at its upper and lower parts but narrow in the middle. At the upper border of the manubrium sterni is the *jugular notch*: the lateral parts of this notch are obscured by the tendinous origins of the Sternocleidomastoidei, which appear as oblique cords narrowing and deepening the notch. At the junction of the manubrium and body is a transverse ridge, the *sternal angle* (angulus Ludovici). From the middle of the sternum the sternal furrow widens, and ends at the junction of the body of the sternum with the xiphoid process. Immediately below this is the *infrasternal notch*; between the sternal ends of the seventh costal cartilages, and below the notch, is a triangular depression, the epigastric fossa, in which the *xiphoid process* can be felt.

On either side of the sternum the costal cartilages and ribs on the front of the thorax are partially obscured by the Pectoralis major, through which, however, they can be felt as ridges with yielding intervals between them corresponding to the intercostal spaces. The second space is the widest, the third and fourth

CC-0. In Public Domain. Gurukul Kangri Collection, Haridwar

Digitized by Arya Samaj Foundation Chennai and eGangotri

are somewhat narrower, and the others, with the exception of the last two, are comparatively narrow.

Below the lower border of the Pectoralis major on the front of the chest, the broad flat outlines of the ribs, and the more rounded outlines of the costal cartilages, are often visible. The lower boundary of the front of the thorax is most plainly seen when the body is bent backwards; it is formed by the xiphoid process, the cartilages of the seventh, eighth, ninth, and tenth ribs, and the ends of the cartilages of the eleventh and twelfth ribs.

On either side of the thorax, from the axilla downwards, the external surfaces of the ribs may be defined. Although covered by muscles, all the ribs, with the exception of the first, can generally be followed without difficulty over the front and sides of the thorax. The first rib, being almost completely covered by the clavicle, can only be distinguished in a small portion of its extent.

At the back, the angles of the ribs lie on slightly marked oblique lines some distance from the spinous processes of the vertebræ. The lines diverge somewhat as they descend, and lateral to each line is a broad convex surface caused by the projection of the ribs beyond their angles. Over this surface, except where covered by the scapula, the individual ribs can be distinguished.

FIG. 1237.—The side of the thorax, showing the surface markings for the bones, lung (purple), pleura (blue), and spleen (green).

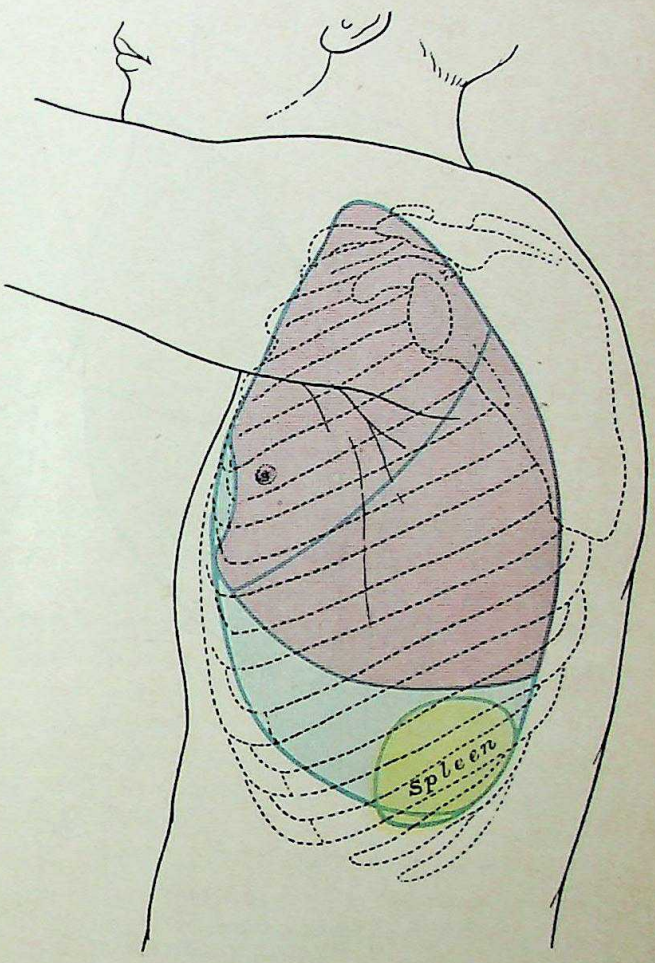

The **muscles**.—The surface muscles covering the thorax belong to the musculature of the upper extremity (figs. 1236, 1240), and will be described in that section (p. 1295). There is, however, an area of practical importance bounded by these muscles. It is limited above by the lower border of the Trapezius, below by the upper border of the Latissimus dorsi, and laterally by the vertebral border of the scapula; the floor is partly formed by the Rhomboideus major. If the trunk be flexed, and the scapula drawn forwards by folding the arms across the chest, parts of the sixth and seventh ribs and the interspace between them become subcutaneous and available for auscultation. The space is therefore known as the *triangle of auscultation*.

The **mamma**.—The size of the mamma is subject to great variations. In the adult nulliparous female it extends vertically from the second to the sixth rib, and transversely from the side of the sternum to the midaxillary line. In the male and in the nulliparous female the *mammary papilla* or *nipple* is situated in the fourth interspace about 9 or 10 cm. from the middle line.

THE SURFACE MARKINGS OF THE THORAX

The **bony landmarks**.—The second costal cartilage is on a level with the sternal angle, and is so readily found that it is used as a starting-point from which to count the ribs. The lower border of the Pectoralis major at its origin corresponds to the 6th rib; the uppermost visible digitation of the Serratus anterior indicates the 8th rib.

CC-0. In Public Domain. Gurukul Kangri Collection, Haridwar

Digitized by Arya Samaj Foundation Chennai and eGangotri

The jugular notch is at the level of the lower border of the body of the second thoracic vertebra, and the sternal angle at the level of the fibrocartilage between the fourth and fifth; the junction between the body and xiphoid process of the sternum corresponds to the fibrocartilage between the ninth and tenth thoracic vertebræ.

The degree of obliquity of the ribs is such that 'if a horizontal line be drawn round the body at the level of the inferior angle of the scapula, while the arms are at the sides, the line would cut the sternum in front between the fourth and fifth ribs, the fifth rib in the nipple line and the ninth rib at the vertebral column.' (Treves.)

The **Diaphragm.**—The shape and variations of the Diaphragm as seen by skiagraphy have already been described (p. 467).

FIG. 1238.—The front of the thorax, showing the surface relations of the bones, lungs (purple), pleuræ (blue), and heart (red outline).

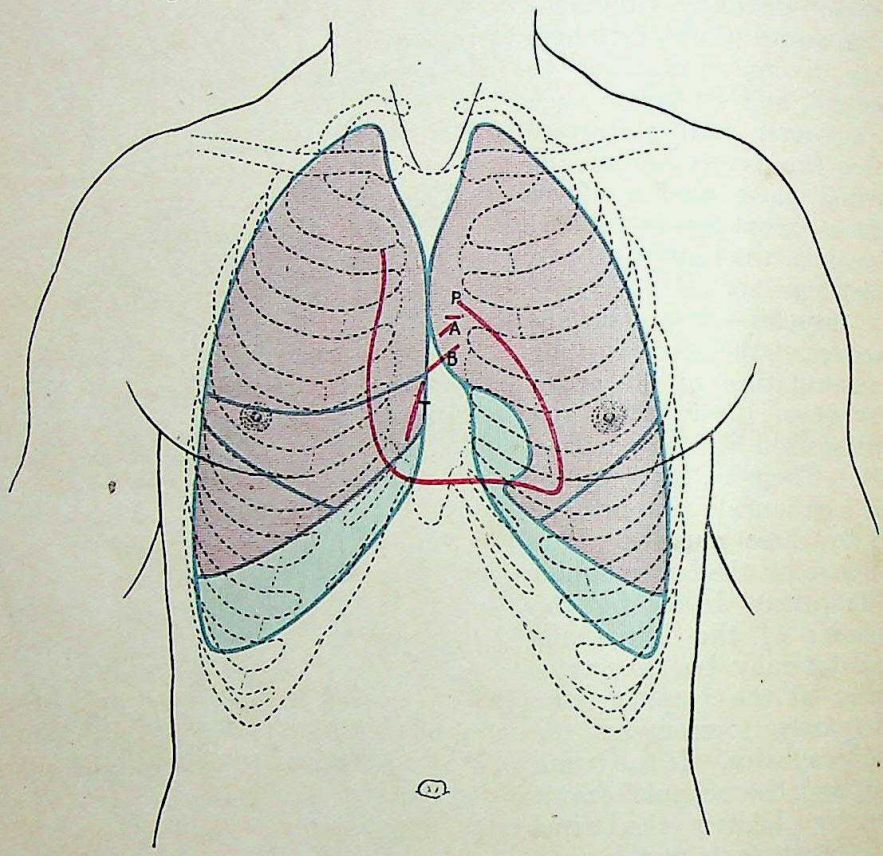

A. Aortic valve.
B. Bicuspid or mitral valve.
P. Pulmonary valve.
T. Tricuspid valve.

The **surface lines.**—For clinical purposes, and for convenience of description, the surface of the thorax has been mapped out by arbitrary lines (fig. 1241). On the front of the thorax the most important vertical lines are the *midsternal* or median line, and the *mammary* line, the latter of which descends vertically from a point midway between the centre of the jugular notch and the tip of the acromion, and, if prolonged, almost corresponds with the lateral line on the front of the abdomen. Other vertical lines are the *lateral sternal* along the sternal margin, and the *parasternal* midway between the lateral sternal and mammary lines.

On either side of the thorax the *anterior and posterior axillary* lines are drawn vertically from the corresponding axillary folds; the *midaxillary* line runs downwards from the apex of the axilla.

On the posterior surface of the thorax the *scapular* line is drawn vertically through the inferior angle of the scapula.

The **pleuræ** (figs. 1237, 1238).—The lines of reflection of the pleuræ can be indicated on the surface. On the *right* side the line passes through the sternoclavicular articulation and runs downwards and medialwards to the midpoint of the

CC-0. In Public Domain. Gurukul Kangri Collection, Haridwar

Digitized by Arya Samaj Foundation Chennai and eGangotri

unction between the manubrium and body of the sternum. It follows the mid-ernal line to the lower end of the body of the sternum or on to the xiphoid process, d then turns lateralwards and downwards across the seventh sternocostal rticulation. It crosses the eighth costochondral junction in the mammary line, he tenth rib in the midaxillary line, and is prolonged thence to the spinous process f the twelfth thoracic vertebra, to reach which it passes below the level of the edial part of the twelfth rib. The most dependent part of the pleural cavity opposite the tenth rib in the midaxillary line.

On the *left* side the line passes through the sternoclavicular articulation, reaches he midpoint of the junction between the manubrium and body of the sternum, nd extends down the midsternal line to the level of the fourth costal cartilage. then inclines to the left and is continued downwards as far as the sixth costal rtilage; it is situated at a variable distance from the midsternal line; frequently is behind the sternum all the way down, or it may be as much as 1·25 cm. from e side of the sternum. Running downwards and lateralwards from the sixth stal cartilage it crosses the seventh costal cartilage, and from this onwards it is milar to the line on the right side but at a slightly lower level.

The **lungs** (figs. 1237, 1238).—The *apex* of the lung is situated in the neck above e medial one-third of the clavicle. The average height to which it rises above the avicle is about 2·5 cm.

In order to mark out the *anterior borders* of the lungs two lines, one from each ex, are drawn downwards and medialwards across the sternoclavicular articu-tion and manubrium sterni until they meet, or almost meet; at the midpoint the sternal angle. From this point the two lines run downwards, in the mid-ernal line, as far as the level of the fourth costal cartilages. On the *right* side e line is continued in the midsternal line to the level of the sixth costal cartilage, d then it turns lateralwards and downwards. On the *left* side the line curves teralwards and downwards across the fourth sternocostal articulation to reach e parasternal line at the fifth costal cartilage, and then turns medialwards and wnwards to the sixth sternocostal articulation.

In the position of expiration the *lower border* of the lung may be marked by a e slightly curved with its convexity downwards, from the sixth sternocostal junction the tenth thoracic spinous process. This line crosses the mammary line at the xth, the midaxillary line at the eighth, and the scapular line at the tenth rib.

The *posterior borders* of the lungs are indicated by lines drawn from the level the spinous process of the seventh cervical vertebra, down either side of the rtebral column, across the costovertebral joints, as low as the spinous process the tenth thoracic vertebra.

The position of the *oblique fissure* in either lung can be shown by a line drawn om the spinous process of the second thoracic vertebra round the side of the orax to the sixth rib in the mammary line; this line corresponds roughly to at of the vertebral border of the scapula when the hand is placed on the top the head. The *horizontal fissure* in the right lung is indicated by an almost rizontal line drawn from the midsternal line at the level of the fourth costal rtilage to the point where the oblique fissure cuts the midaxillary line.

The *roots* of the lungs are placed opposite the spinous processes of the fourth, h and sixth thoracic vertebræ, i.e. they extend from just below the root of the ne of the scapula, almost to the inferior angle of the scapula.

The **trachea.**—The course of the trachea may be marked out on the back by a e from the spinous process of the sixth cervical to that of the fourth thoracic rtebra; at the latter level the trachea bifurcates, and from its bifurcation the o bronchi are directed downwards and lateralwards. Anteriorly, the point bifurcation is opposite to or a little below the sternal angle.

The **œsophagus.**—The extent of the œsophagus may be indicated on the back a line from the sixth cervical spinous process to a point 2·5 cm. on the left of ninth thoracic spinous process.

The **heart.**—The outline of the heart in relation to the front of the thorax gs. 1238, 1239) can be represented by a quadrangular figure. (*a*) The apex of e heart is first determined as a point in the fifth interspace, 9 cm. to the left the midsternal line. The other three points are: (*b*) the seventh right sterno-stal articulation; (*c*) the upper border of the third right costal cartilage 1 cm. m the right lateral sternal line; (*d*) the lower border of the second left costal rtilage 2·5 cm. from the left lateral sternal line. A line joining (*a*) to (*b*) and

CC-0. In Public Domain. Gurukul Kangri Collection, Haridwar

Digitized by Arya Samaj Foundation Chennai and eGangotri

traversing the junction of the body of the sternum with the xiphoid process represents the lower border of the heart. The right and left borders are represented respectively by lines joining (*b*) to (*c*) and (*a*) to (*c*); both lines are convex lateralwards, but the convexity is more marked on the right, where its summit is 4 cm. distant from the midsternal line opposite the fourth costal cartilage.

A portion of the area of the heart thus mapped out is uncovered by lung, and therefore gives a dull note on percussion; the remainder is overlapped by lung and gives a more or less resonant note. The former is known as the area of superficial cardiac dulness, the latter as the area of deep cardiac dulness. The area

Fig. 1239.—A diagram showing the relations of the opened heart to the front of the thoracic wall.

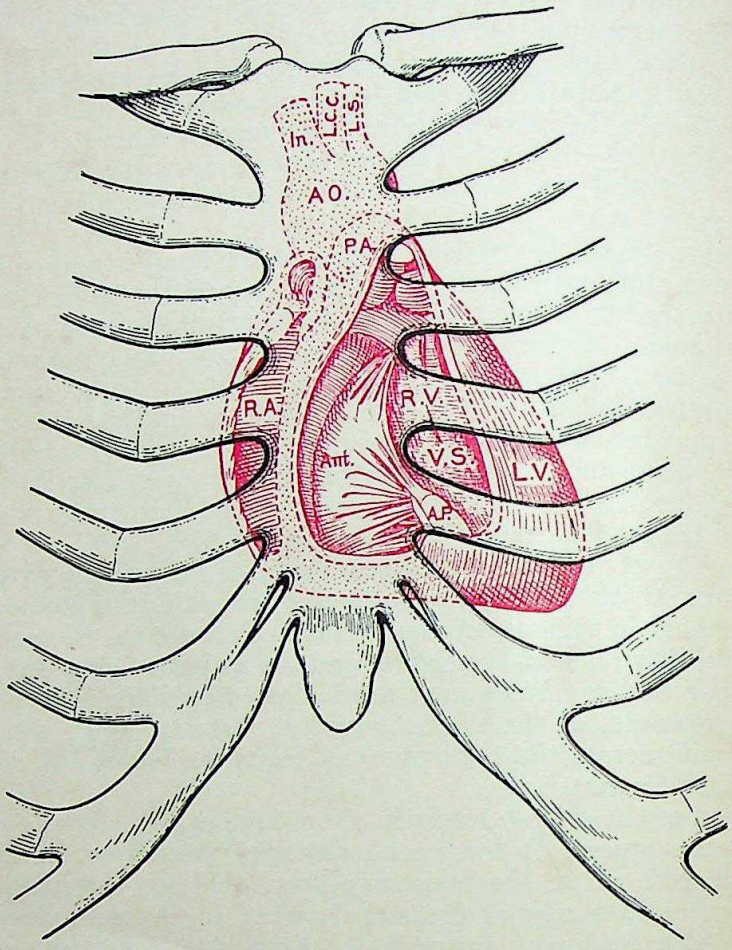

Ant. Anterior segment of tricuspid valve. AO. Aorta. A.P. Anterior papillary muscle. In. Innominate artery. L.C.C. Left common carotid artery. L.S. Left subclavian artery. L.V. Left ventricle. P.A. Pulmonary artery. R.A. Right atrium. R.V. Right ventricle. V.S. Ventricular septum.

of superficial cardiac dulness is somewhat triangular; from the apex of the heart two lines are drawn to the midsternal line, one to the level of the fourth costal cartilage, the other to the junction between the body and xiphoid process of the sternum; the portion of the midsternal line between these points is the base of the triangle. Latham lays down the following rule as a sufficient practical guide for the definition of the area of superficial dulness: 'Make a circle of two inches in diameter round a point midway between the nipple and the end of the sternum.'

The *coronary sulcus* (auriculoventricular groove) can be indicated by a line from the midsternal line opposite the third costal cartilage, to the sixth right sternocostal joint. The *anterior longitudinal sulcus* is a finger's-breadth to the right of the left margin of the heart and parallel with it.

The positions of the orifices of the heart are as follows: the *pulmonary orifice* is situated in the upper angle of the third left sternocostal articulation; the *aortic orifice* is a little below and medial to this, close to the articulation; the *left atrioventricular orifice* is opposite the fourth costal cartilage, and rather to the left of the midsternal line; the *right atrioventricular orifice* is a little lower, opposite

CC-0. In Public Domain. Panini Kanya Maha Vidyalaya Collection.

Digitized by Arya Samaj Foundation Chennai and eGangotri

the fourth interspace of the right side. The lines indicating the atrioventricular orifices are parallel with and slightly below the line of the coronary sulcus.

The **arteries.**—The line of the *ascending aorta* begins slightly to the left of the midsternal line opposite the third costal cartilage, and extends upwards and to the right to the level of the upper border of the second right costal cartilage. The *aortic arch* lies behind the lower half of the manubrium sterni. A line from the middle of the manubrium sterni to the right sternoclavicular articulation represents the site of the *innominate artery*, while another line from a point slightly to the left of the middle of the manubrium sterni to the left sternoclavicular articulation indicates the position of the thoracic part of the *left common carotid artery*.

The *internal mammary artery* descends behind the first six costal cartilages about 1 cm. from the lateral sternal line.

The **veins.**—The line of the *right innominate vein* crosses the sternal end of the right clavicle and the upper border of the first right costal cartilage about 1 cm. from the lateral sternal line; that of the *left innominate vein* extends from the sternal end of the left clavicle to meet the line of the right innominate vein at the upper border of the first right costal cartilage. The junction of the two lines indicates the origin of the *superior vena cava*, and the line of this vessel is continued vertically down to the level of the third right costal cartilage. The *inferior vena cava* opens into the right atrium at the level of the upper margin of the sixth right costal cartilage about 2 cm. from the midsternal line.

THE SURFACE ANATOMY OF THE ABDOMEN

The **skin.**—The skin of the front of the abdomen is thin. In the male it is often thickly clad with hairs, especially towards the lower part of the middle line; in the female the hairs are confined to the pubes. Just below the iliac crest is a shallow groove termed the *iliac furrow*, while in the site of the inguinal ligament a sharper fold known as the *fold of the groin* is easily distinguishable.

After distension of the abdomen from pregnancy or other causes the skin commonly presents transverse white lines which are quite smooth, being destitute of papillæ; these are known as *striæ gravidarum* or *striæ albicantes*. The *linea nigra* of pregnancy is a brown streak in the middle line between the umbilicus and symphysis pubis.

In the middle line of the front of the abdomen is a shallow furrow which extends from the junction between the body of the sternum and the xiphoid process to a short distance below the umbilicus; it corresponds to the linea alba. The umbilicus is situated in the middle line, but varies as regards its height; in an adult subject it is always placed above the middle point of the body, and is slightly below the level of the highest points of the iliac crests.

The **bones.**—The bones in relation with the surface of the abdomen are (1) the lower part of the vertebral column and the lower ribs and (2) the pelvis; the former have already been described (pp. 1272 and 1276), the latter will be considered with the lower limb.

The **muscles** (fig. 1240).—The only muscles of the abdomen which have any considerable influence on surface form are the Obliquus externus abdominis and the Rectus abdominis. The upper digitations of origin of the *Obliquus externus* are well marked and interdigitate with those of the Serratus anterior; the lower are covered by the border of the Latissimus dorsi. The attachment of the Obliquus externus and Obliquus internus to the iliac crest forms a thick oblique roll which determines the iliac furrow. On the front of the lateral region of the abdomen an undulating line sometimes marks the passing of the muscular fibres of the Obliquus externus into its aponeurosis. The posterior margin of the Obliquus externus is frequently separated from the lateral margin of the Latissimus dorsi by a small triangular interval—the *lumbar triangle*—the base of which is formed by the iliac crest, and the floor by the Obliquus internus.

The lateral margin of the *Rectus abdominis* is indicated by the *linea semilunaris*, which is easily defined when the muscle is in action. On the surface of the Rectus are three transverse furrows, the *tendinous inscriptions*: the upper two of these, viz. one opposite, or a little below the tip of the xiphoid process, and the other

CC-0. In Public Domain. Gurukul Kangri Collection, Haridwar

Digitized by Arya Samaj Foundation Chennai and eGangotri

midway between this point and the umbilicus, are usually well marked; the third, opposite the umbilicus, is not so distinct. Between the two Recti the furrow of the linea alba can be traced from the xiphoid process to a point just below the umbilicus, beyond which it disappears owing to the apposition of the muscles;

FIG. 1240.—The surface anatomy of the front of the thorax and abdomen.

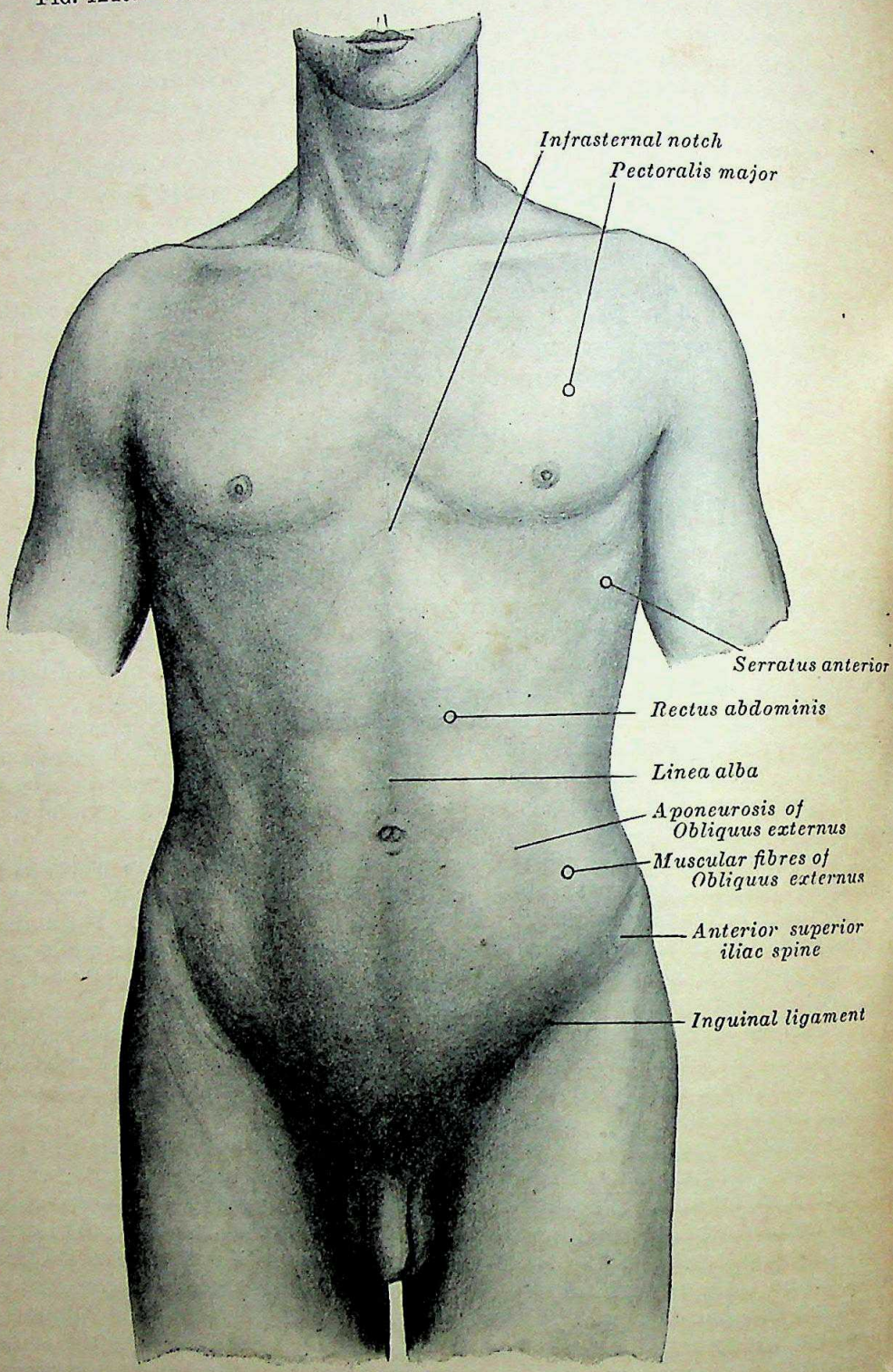

above the umbilicus the linea alba is felt as a band, whilst below, it is a rounded cord.

The **vessels.**—In thin subjects the pulsation of the *abdominal aorta* is felt on making deep pressure in the middle line above the umbilicus.

The **viscera.**—Under normal conditions the various portions of the *digestive tube* cannot be identified by simple palpation, but under certain conditions peristalsis

Digitized by Arya Samaj Foundation Chennai and eGangotri

of the coils of small intestine can be observed in persons with extremely thin abdominal walls. In cases of constipation it is commonly possible to trace portions of the great intestine by feeling the fæcal masses within the gut. In thin persons with relaxed abdominal walls the iliac portion of the descending colon can be felt in the left iliac region—rolling under the fingers when empty, and forming a distinct tumour when distended.

The *liver* lies mainly under cover of the lower ribs and their cartilages, but in the epigastric fossa a portion of it comes in contact with the abdominal wall. The position of the liver varies according to the posture of the body. In the erect posture the inferior margin of the liver projects about 1 cm. below the lower margin of the right costal cartilages, and can often be felt if the abdominal wall is thin. In the supine position the liver recedes above the lower margin of the thorax and cannot then be detected by the fingers; in the prone position it falls forwards and is then generally palpable in a patient with lax abdominal walls. Its position varies with the respiratory movements; during a deep inspiration it descends below the ribs, in expiration it is raised. Pressure from without, as in tight lacing, displaces the liver considerably, its anterior edge frequently extending as low as the iliac crest. Again, the position of the liver varies greatly with the state of the stomach and intestines; when these are empty the liver descends, when they are distended it is pushed upwards.

The *pancreas* can sometimes be felt in emaciated subjects, if the stomach and colon are empty, by making deep pressure in the middle line about 7 or 8 cm. above the umbilicus.

The *spleen*, unless it is enlarged or misplaced, cannot be felt.

The *kidneys* are deeply situated at the back of the abdominal cavity; they can be palpated bimanually, i.e. with one hand pressing forwards in the loin between the last rib and the iliac crest, and the other pressing strongly backwards under the costal margin in the lateral abdominal line.

THE SURFACE MARKINGS OF THE ABDOMEN

The **bony landmarks.**—Above, the chief bony markings are the xiphoid process, the lower six costal cartilages and the anterior ends of the lower six ribs. The junction between the body of the sternum and the xiphoid process is at the level of the fibrocartilage between the ninth and tenth thoracic vertebræ. Below, the main landmarks are the symphysis pubis, the pubic crest and tubercle, the anterior superior iliac spine, and the iliac crest.

The **muscles** (fig. 1240).—The Rectus abdominis lies between the linea alba and the linea semilunaris; the latter is indicated by a curved line, convex lateralwards, from the tip of the cartilage of the ninth rib to the pubic tubercle; at the level of the umbilicus the linea semilunaris is about 7 cm. from the middle line, i.e. about midway between the umbilicus and the anterior superior iliac spine. The line indicating the junction of the muscular fibres of Obliquus externus with its aponeurosis extends from the tip of the ninth costal cartilage to a point just medial to the anterior superior iliac spine.

The *umbilicus* is at the level of the middle of the body of the fourth lumbar vertebra.

The centre of the *subcutaneous inguinal ring* is situated 1 cm. above and lateral to the pubic tubercle; the centre of the *abdominal inguinal ring* is about 1 cm. above the middle of the inguinal ligament. The position of the *inguinal canal* is indicated by a line joining these two points.

The **surface lines.**—For convenience of description of the viscera and of reference to morbid conditions of the contained parts, the abdomen is divided into nine regions, by imaginary planes, two horizontal and two sagittal, the edges of the planes being indicated by lines drawn on the surface of the body (fig. 1241). In the older method the upper, or subcostal, horizontal line encircles the body at the level of the lowest points of the tenth costal cartilages; the lower, or intertubercular, is a line carried through the highest points of the iliac crests seen from the front, i.e. through the tubercles on the iliac crests about 5 cm. behind the anterior superior spines. An alternative method is that of Addison, who adopted the following lines: (1) an upper transverse, the *transpyloric*, halfway between the jugular notch

CC-0. In Public Domain. Gurukul Kangri Collection, Haridwar

Digitized by Arya Samaj Foundation Chennai and eGangotri

and the upper border of the symphysis pubis; this indicates the edge of the transpyloric plane which in most cases cuts through the pylorus, the tips of the ninth costal cartilages and the lower border of the first lumbar vertebra; clinically it is convenient but not so accurate to draw this line transversely through a point midway between the infrasternal notch and the umbilicus; (2) a lower transverse

FIG. 1241.—The surface lines of the front of the thorax and abdomen.

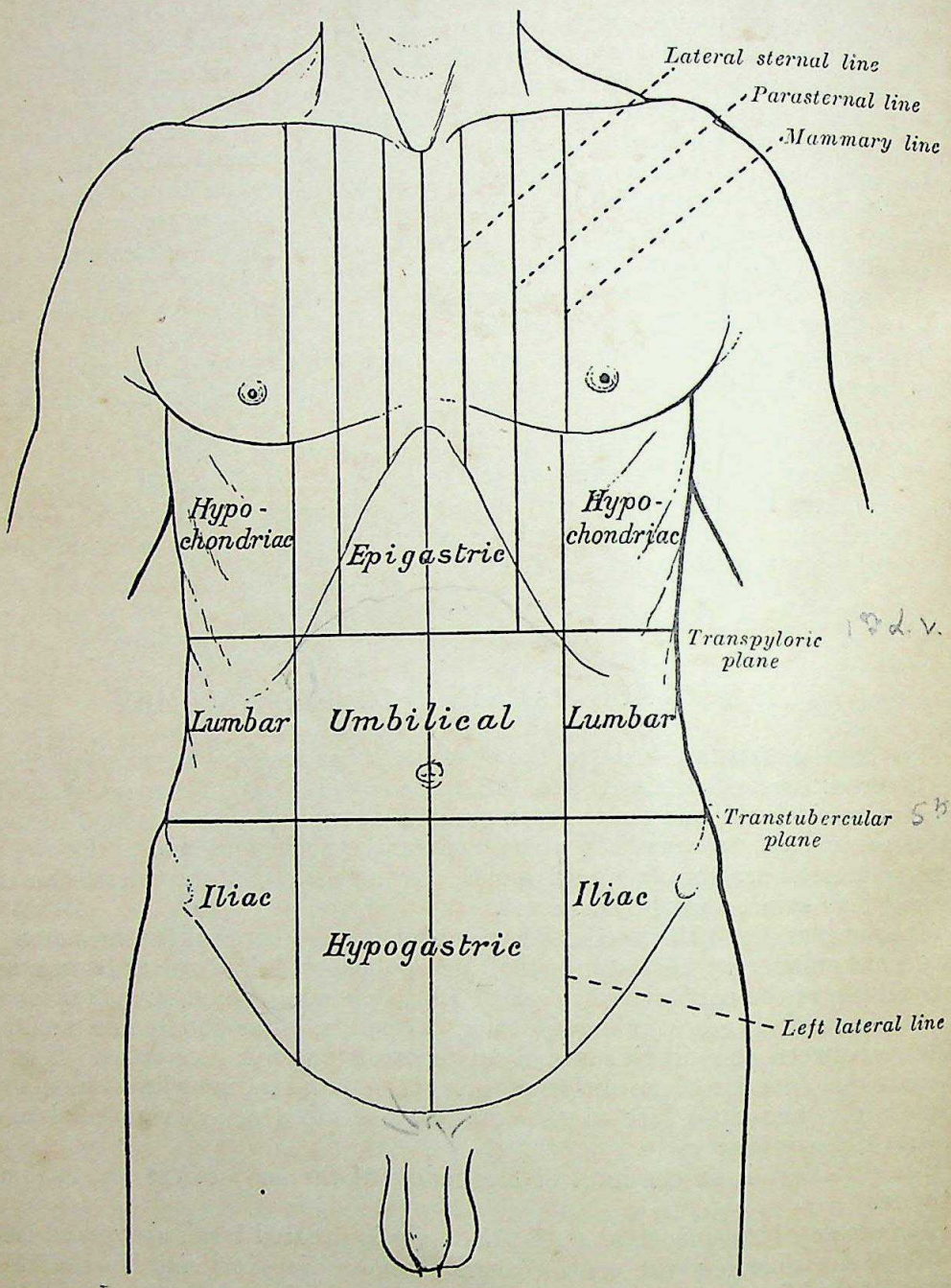

line midway between the transpyloric and the upper border of the symphysis pubis; this is termed the *transtubercular* since it very nearly corresponds to that passing through the tubercles on the iliac crests; behind, its plane cuts the body of the fifth lumbar vertebra.

By means of these horizontal planes the abdomen is divided into three zones named from above, subcostal, umbilical, and hypogastric. Each of these is further subdivided into three regions by the two sagittal planes, which are indicated on the surface by a right and a left lateral line drawn vertically through points halfway between the anterior superior iliac spine and the middle line. The middle region of the upper zone is called the epigastric, and the lateral regions the right and

CC-0. In Public Domain. Gurukul Kangri Collection, Haridwar

Digitized by Arya Samaj Foundation Chennai and eGangotri

left hypochondriac. The central region of the middle zone is the umbilical, and the lateral regions the right and left lumbar. The middle region of the lower zone is the hypogastric or pubic, and the lateral regions are the right and left iliac or inguinal. The epigastric, umbilical, and pubic regions can each be divided into right and left portions by the middle line. In the following description of the viscera the regions marked out by Addison's lines are those referred to.

The **stomach** (fig. 1243).—The shape of the stomach is constantly undergoing alteration; it is affected by the particular phase of the process of gastric digestion, by the state of the surrounding viscera, and by the amount and character of its contents. Its position also varies with that of the body (fig. 1242), so that it is impossible to indicate it on the surface with any degree of accuracy. The measurements given refer to a moderately filled stomach with the body in the supine position.

The cardiac orifice is opposite the seventh left costal cartilage about 2·5 cm. from the side of the sternum; it corresponds to the level of the tenth thoracic vertebra. The pyloric orifice is on the transpyloric line about 1 cm. to the right of the middle line, or alternatively 5 cm. below the seventh right sternocostal

FIG. 1242.—Skiagrams of a half-filled stomach, showing the influence of posture. (After A. F. Hurst.)

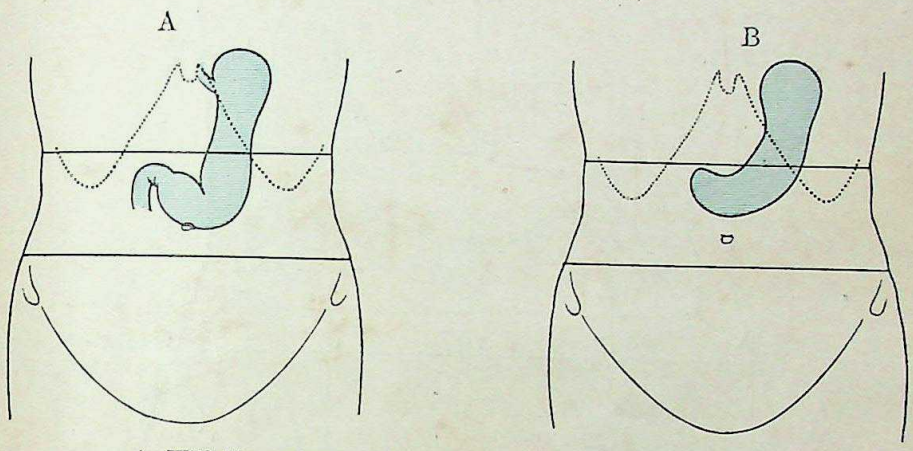

A. With the patient in the erect posture. B. With the patient lying down.

articulation; it is at the level of the first lumbar vertebra. A curved line, convex downwards and to the left, joining these points indicates the lesser curvature. In the left lateral line the fundus of the stomach reaches as high as the fifth intercostal space or the sixth costal cartilage, a little below the apex of the heart. To indicate the greater curvature a curved line is drawn from the cardiac orifice to the summit of the fundus, thence downwards and to the left, finally turning medialwards to the pyloric orifice, but passing on its way, through the intersection of the left lateral with the transpyloric line. The portion of the stomach which is in contact with the abdominal wall can be represented roughly by a triangular area, the base of which is formed by a line drawn from the tip of the tenth left costal cartilage to the tip of the ninth right cartilage, and the sides by two lines drawn from the end of the eighth left costal cartilage to the ends of the base line.

A space of some clinical importance—the *space of Traube*—overlies the stomach; it is semilunar in outline and has the following boundaries: the lower edge of the left lung, the anterior border of the spleen, the left costal margin, and the inferior margin of the left lobe of the liver.

The **duodenum** (fig. 1244).—The superior part is nearly horizontal and extends from the pylorus to the right lateral line; the descending part is situated medial to the right lateral line, and reaches from the transpyloric line to a point midway between the transpyloric and transtubercular lines. The horizontal part runs with a slight upward slope from the end of the descending part to the left of the middle line; the ascending part is vertical, and ends in the duodenojejunal flexure, about 2·5 cm. to the left of the middle line and a little below the transpyloric plane.

The **small intestine.**—The coils of small intestine occupy the front of the abdomen. For the most part those of the jejunum are situated on the left side, i.e. in the left lumbar and iliac regions, and in the left half of the umbilical region. Those

CC-0. In Public Domain. Gurukul Kangri Collection, Haridwar

Digitized by Arya Samaj Foundation Chennai and eGangotri

of the ileum lie towards the right in the right lumbar and iliac regions, in the right half of the umbilical region, and in the hypogastric region; a portion of the ileum is within the pelvis. The end of the ileum, i.e. the *ileocolic junction*, is slightly below and medial to the intersection of the right lateral and transtubercular lines.

The **cæcum** and **vermiform process.**—The *cæcum* is in the right iliac and hypogastric regions; its position varies with its degree of distension, but the midpoint of a line drawn from the right anterior superior iliac spine to the upper margin of the symphysis pubis will mark approximately the middle of its lower border.

The position of the opening of the *vermiform process* into the cæcum is indicated by a point on the right lateral line on a level with the anterior superior iliac spine.

Fig. 1243.—The front of the abdomen, showing the surface markings for the liver, stomach, and large intestine.

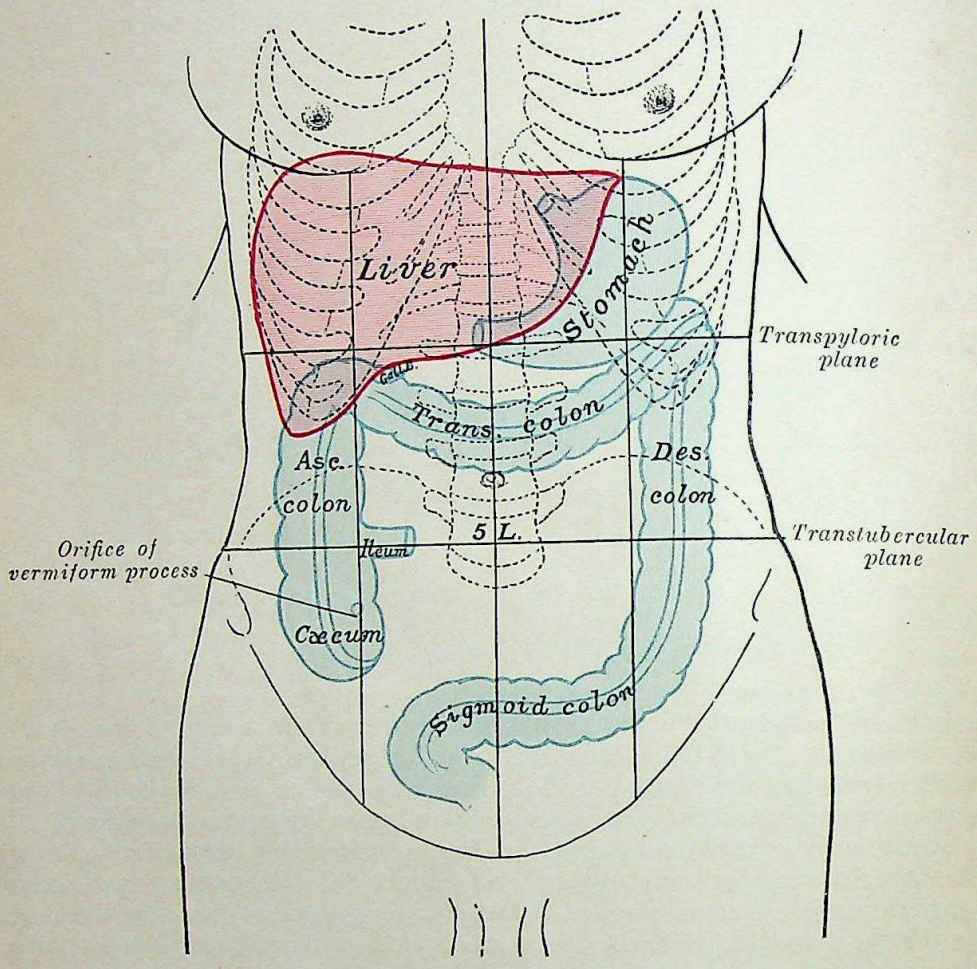

The **ascending colon.**—The ascending colon passes upwards through the right lumbar region, just lateral to the right lateral line. The *right colic flexure* is situated in the right lower angle of intersection of the transpyloric and right lateral lines.

The **transverse colon.**—The transverse colon crosses the abdomen; its lower border is slightly above the level of the umbilicus, its upper border just below the greater curvature of the stomach.

The **descending colon.**—The *left colic flexure* is situated in the upper left angle of the intersection between the left lateral and transpyloric lines. The descending colon courses down through the left lumbar region, lateral to the left lateral line, thence slightly medialwards to cross the left lateral line at the level of the anterior superior iliac spine.

The **liver** (fig. 1243).—The upper limit of the right lobe of the liver, in the middle line, is at the level of the junction between the body and xiphoid process of the sternum; on the right side the line must be carried upwards as far as the fifth costal cartilage in the mammary line, and then downwards to reach the seventh rib at the side of the thorax. The upper limit of the left lobe can be defined by continuing

CC-0. The Nanji Kanji Collection, Haridwar

Digitized by Arya Samaj Foundation Chennai and eGangotri

this line to the sixth left costal cartilage, 5 cm. from the middle line. The lower limit is represented by a line drawn 1 cm. below the lower margin of the thorax

FIG. 1244.—The front of the abdomen, showing the surface markings for the duodenum, pancreas and kidneys.

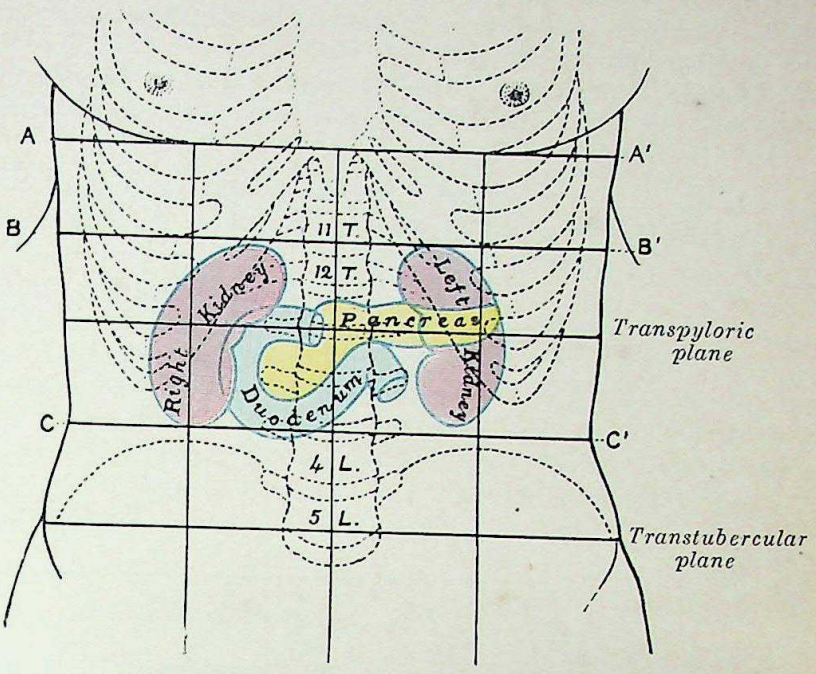

A A'. Plane through the joint between the body and xiphoid process of sternum. B B'. Plane midway between A A' and transpyloric plane. C C'. Plane midway between transpyloric and transtubercular planes.

on the right side as far as the ninth costal cartilage, thence obliquely upwards to the eighth left costal cartilage, crossing the middle line at the transpyloric plane and finally, with a slight left convexity, to the end of the line indicating the upper limit.

According to Birmingham, the limits of the normal liver may be marked out on the surface of the body in the following manner. Take three points: (*a*) 1·25 cm. below the right nipple; (*b*) 1·25 cm. below the tip of the right tenth rib; (*c*) 2·5 cm. below the left nipple. Join (*a*) and (*c*) by a line slightly concave upwards at its middle part; (*a*) and (*b*) by a line slightly convex lateralwards; and (*b*) and (*c*) by a line slightly convex downwards.

The fundus of the *gall-bladder* approaches the surface behind the anterior end of the ninth right costal cartilage close to the lateral margin of the Rectus abdominis.

FIG. 1245.—The back of the lumbar region, showing the surface markings for the kidneys, ureters, and spleen.

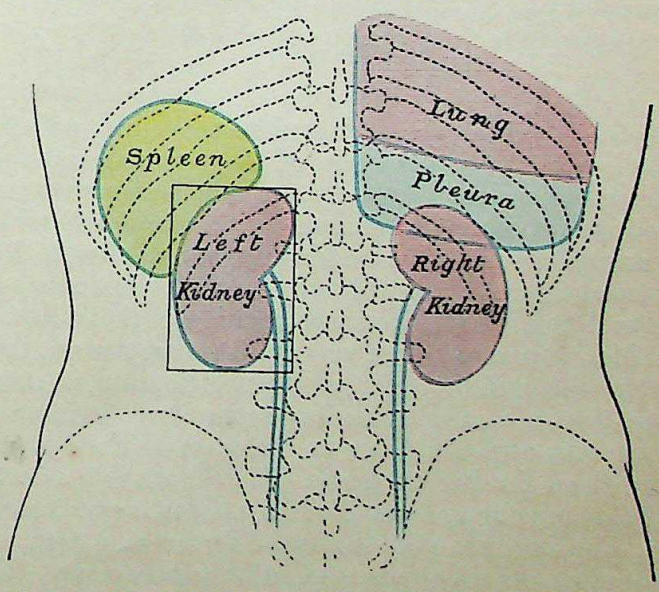

The lower portions of the lung and pleura are shown on the right side.

The **pancreas** (fig. 1244).—The pancreas lies in front of the first and second lumbar vertebræ. Its head occupies the curve of the duodenum, and is therefore indicated by the same lines as that viscus; its neck corresponds to the pylorus. Its body extends along the transpyloric line, the bulk of it lying above this line, to the tail, which is in the

CC-0. In Public Domain. Gurukul Kangri Collection, Haridwar

Digitized by Arya Samaj Foundation Chennai and eGangotri

left hypochondriac region slightly to the left of the lateral line and above the transpyloric line.

The **spleen** (figs. 1238, 1245).—To map out the spleen the tenth rib is taken as representing its long axis; vertically it extends from the upper border of the ninth rib to the lower border of the eleventh rib. The highest point is 4 cm. from the middle line of the back at the level of the tip of the ninth thoracic spinous process; the lowest and foremost point is in the midaxillary line at the level of the first lumbar spinous process.

The **kidneys** (figs. 1244, 1245).—The right kidney usually lies about 1 cm. lower than the left, but for practical purposes similar surface markings are taken for each.

Fig. 1246.—The front of the abdomen, showing the surface markings for the arteries and the inguinal canal. The line A, A is drawn at the level of the highest points of the iliac crests.

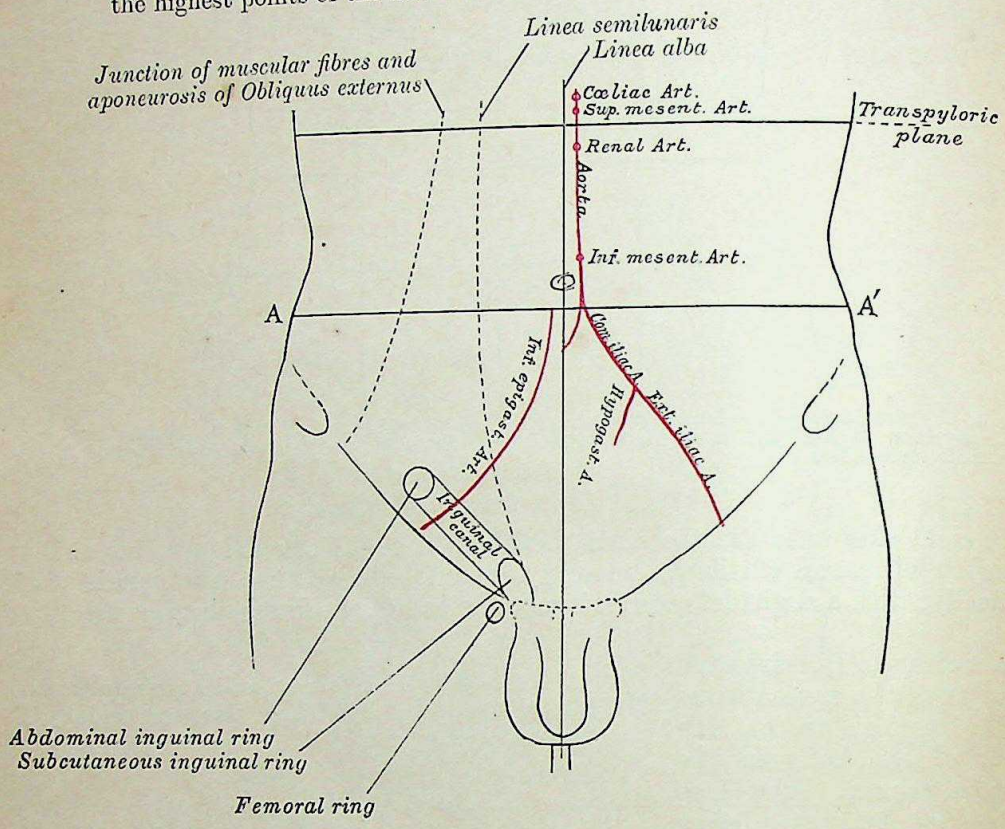

On the front of the abdomen the upper pole lies midway between the plane of the lower end of the body of the sternum and the transpyloric plane, 5 cm. from the middle line. The lower pole is situated midway between the transpyloric and transtubercular planes, 7 cm. from the middle line. The hilum is on the transpyloric plane, 5 cm. from the middle line.* Round these three points a kidney-shaped figure 4 cm. to 5 cm. broad is drawn two-thirds of which lie medial to the lateral line. To indicate the position of the kidney from the back, the parallelogram of Morris is used; two vertical lines are drawn, the first 2·5 cm., the second 9·5 cm. from the middle line; the parallelogram is completed by two horizontal lines, one drawn at the level of the tip of the spinous process of the eleventh thoracic vertebra, and the other at the level of the lower border of the spinous process of the third lumbar vertebra. The hilum is 5 cm. from the middle line at the level of the spinous process of the first lumbar vertebra.

The **ureters.**—On the front of the abdomen, the line of the ureter is from the hilum of the kidney to the pubic tubercle; on the back, from the hilum vertically downwards, passing through the posterior superior iliac spine (fig. 1245).

The **arteries** (fig. 1246).—The position of the *inferior epigastric artery* is marked by a line from a point midway between the anterior superior iliac spine and the

* Addison says that (1) one-third of the right kidney and two-fifths of the left are above the transpyloric plane, and (2) one-third of the right kidney and two-fifths of the left lie on the medial side of the corresponding lateral line.

CC-0. In Public Domain. Gurukul Kangri Collection, Haridwar

Digitized by Arya Samaj Foundation Chennai and eGangotri

pubic symphysis to the umbilicus. This line also indicates the lateral boundary of *Hesselbach's triangle*, the other boundaries of which are the lateral edge of Rectus abdominis, and the medial half of the inguinal ligament. The line of the *abdominal aorta* begins in the middle line about 4 cm. above the transpyloric line and ends at a point 2 cm. below and to the left of the umbilicus—or 2 cm. to the left of the middle line at the level of the highest points of the iliac crests (AA′, fig. 1246); the abdominal aorta ends at the level of the fourth lumbar vertebra. A line drawn from the point of termination of the abdominal aorta to a point midway between the anterior superior iliac spine and the symphysis pubis overlies the common and external iliac arteries. The *common iliac artery* is represented by the upper one-third, and the *external iliac artery* by the lower two-thirds of this line.

Of the larger branches of the abdominal aorta, the *cœliac artery* is 4 cm., and the *superior mesenteric artery* 2 cm. above the transpyloric line; the *renal arteries* are 2 cm. below this line. The *inferior mesenteric artery* is 4 cm. above the bifurcation of the abdominal aorta.

The **nerves.**—The positions of the lower six thoracic nerves on the anterior abdominal wall are represented by lines continuing those of the ribs. The seventh thoracic nerve ends at the level of the xiphoid process, the tenth at the level of the umbilicus, and the twelfth about midway between the umbilicus and the upper border of the symphysis pubis. The anterior branch of the iliohypogastric nerve becomes cutaneous about 3 cm. above the subcutaneous inguinal ring; the ilio-inguinal nerve at the ring.

THE SURFACE ANATOMY OF THE PERINÆUM

The **skin.**—In the middle line of the posterior part of the perinæum and about 4 cm. in front of the tip of the coccyx is the anal orifice, the skin around which is thrown into a series of folds which converge towards the orifice, and are continued upwards into the lower part of the anal canal. The junction of the mucous membrane of the anal canal with the skin is marked by a white line which indicates also the line of contact of the external and internal Sphincters. The external genital organs are situated in the anterior part of the perinæum. The skin covering the scrotum is rough and corrugated, but over the penis it is smooth. Extending forwards from the anus on to the scrotum and penis is a median ridge which indicates the scrotal raphe. In the *female* are seen the skin reduplications forming the labia majora and minora laterally, the prepuce of the clitoris in front, and still more anteriorly the mons pubis (fig. 1248).

The **bones.**—In the anterolateral boundaries of the perinæum, the whole outline of the pubic arch can be readily traced ending in the ischial tuberosities. Behind in the middle line is the tip of the coccyx.

The **muscles** and **ligaments.**—The margin of the *Glutæus maximus* forms the posterolateral boundary of the perinæum, and by pressing deeply the sacrotuberous ligament can be felt through the muscle. The only other muscles influencing surface form are the *Ischiocavernosus* covering the crus penis, which lies on the side of the pubic arch, and the *Sphincter ani externus*, which, in action, closes the anal orifice and causes a puckering of the skin around it.

THE SURFACE MARKINGS OF THE PERINÆUM

A line drawn transversely in front of the ischial tuberosities divides the perinæum into a posterior or rectal, and an anterior or urogenital, triangle. This line passes through the central point of the perinæum, which is situated about 2·5 cm. in front of the anal aperture, or, in the male, midway between the anus and the reflection of the skin on to the scrotum.

The **rectum** and **anal canal.**—A finger inserted through the anal orifice enters the anal canal, which passes upwards and forwards for about 2·5 cm. and then bends backwards almost at right angles into the rectum. The finger is first grasped

CC-0. In Public Domain. Gurukul Kangri Collection, Haridwar

Digitized by Arya Samaj Foundation Chennai and eGangotri

by the Sphincter ani externus, passes into the region of the Sphincter ani internus, and higher up encounters the resistance of the Puborectalis; beyond this it may reach the lowest of the transverse rectal folds. In front (fig. 1247), the urethral bulb and membranous part of the urethra are first identified, and then about 4 cm. above the anal orifice the prostate is felt: beyond this the vesiculæ seminales, if enlarged, and the fundus of the bladder, when distended, can be recognised. On either side is the ischiorectal fossa. Behind are the anococcygeal body, the pelvic surfaces of the coccyx and lower part of the sacrum, and the sacrospinous ligaments.

Fig. 1247.—A median sagittal section through the male pelvis.

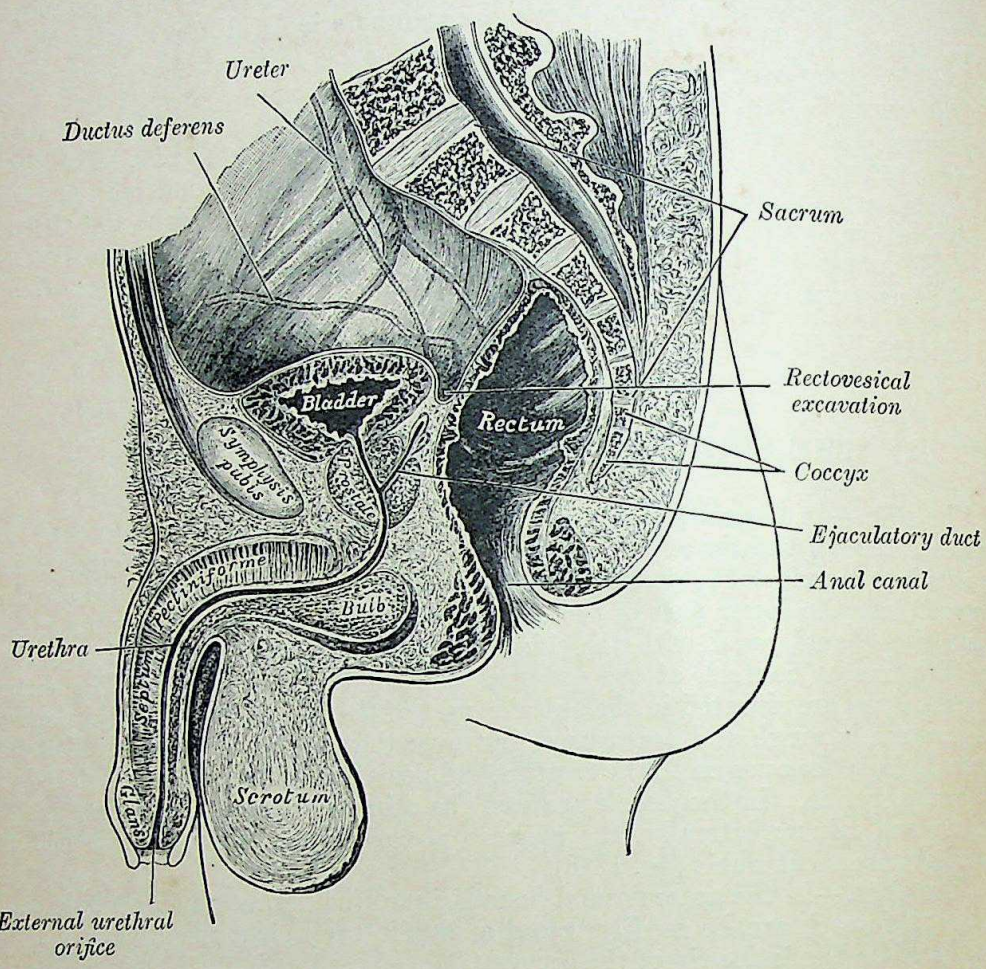

In the female the posterior wall and fornix of the vagina, and the cervix and body of the uterus can be felt in front, while somewhat laterally the ovaries can just be reached.

Further examination of the interior of the lower end of the digestive tube can be accomplished by viewing it through the proctoscope or sigmoidoscope.

The **male urogenital organs.**—The corpora cavernosa penis can be followed backwards to the crura which are attached to the sides of the pubic arch. The glans penis, covered by the prepuce, and the external urethral orifice can be examined, and the course of the urethra traced along the under surface of the penis to the urethral bulb which is situated immediately in front of the central point of the perinæum. The testes can be palpated through the wall of the scrotum, and along the posterior border of each the curved epididymis can be felt; the spermatic cord ascends on the medial side of the epididymis, and may be traced upwards to the subcutaneous inguinal ring. The ductus deferens feels like a piece of whipcord, and thus can be easily recognised in the posterior part of the spermatic cord.

By means of a sound the general topography of the urethra and bladder can be investigated; with the urethroscope the interior of the urethra can be illuminated and viewed directly; with the cystoscope the interior of the bladder may be illuminated in a similar manner for visual examination. In the bladder the main points to

CC-0. In Public Domain. Gurukul Kangri Collection, Haridwar

Digitized by Arya Samaj Foundation Chennai and eGangotri

which attention is directed are: the trigone, the torus uretericus, the plicæ uretericæ, and the openings of the ureters and urethra (see fig. 1169).

The **female urogenital organs.**—In the pudendal cleft (fig. 1248) between the labia minora are the openings of the vagina and urethra. In the virgin the vaginal opening is partly closed by the hymen—after coitus the remains of the hymen are represented by the carunculæ hymenales. Between the vaginal orifice and the frenulum of the labia is the fossa navicularis, while in the groove between the hymen and the labium minus, on either side, the small opening of the greater vestibular (Bartholin's) gland is visible. These glands when enlarged can be felt on either side of the posterior part of the vaginal orifice. By inserting a finger into the vagina the following structures may be examined through its wall (fig. 1249).

FIG. 1248.—The external genital organs of the female. The labia minora have been drawn apart.

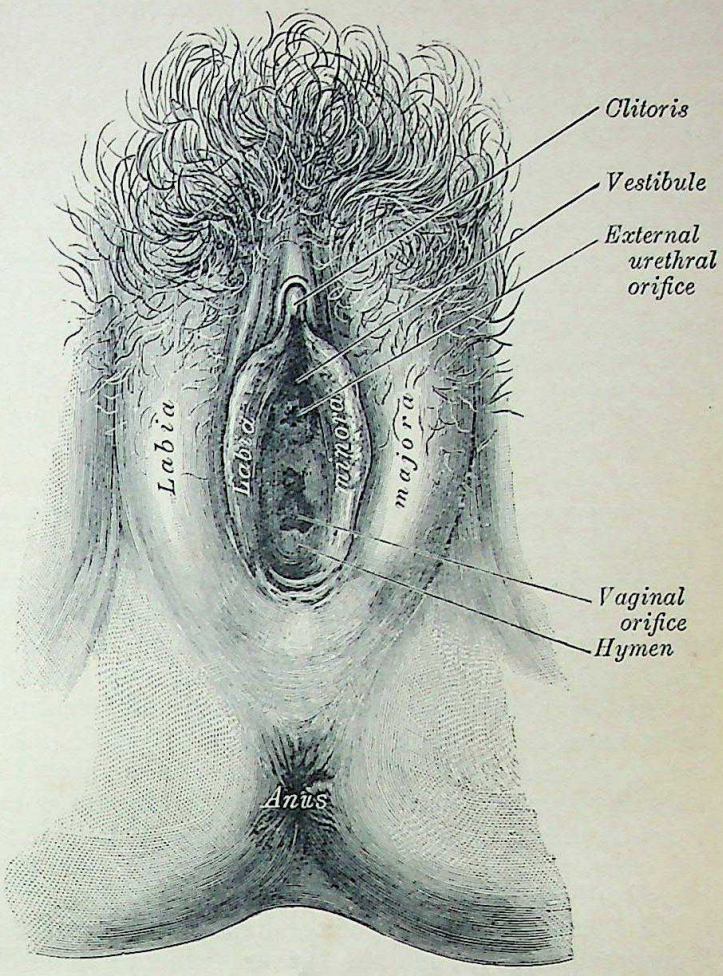

FIG. 1249.—A median sagittal section through the female pelvis.

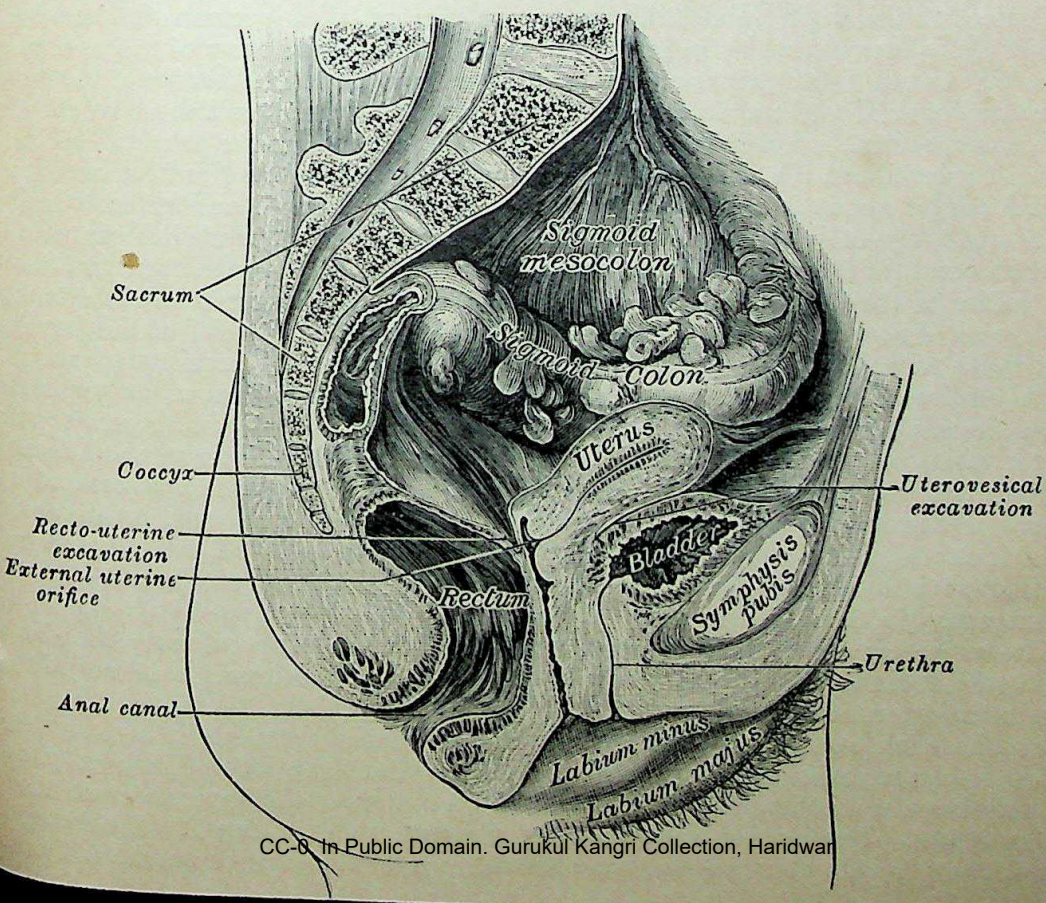

CC-0. In Public Domain. Gurukul Kangri Collection, Haridwar

Digitized by Arya Samaj Foundation Chennai and eGangotri

Behind, from below upwards, are the anal canal, the rectum, and the recto-uterine excavation. Projecting into the roof of the vagina is the vaginal portion of the cervix uteri with the external uterine orifice; in front of and behind the cervix are the anterior and posterior vaginal fornices. With a finger in the vagina and the other hand on the abdominal wall the whole of the cervix and body of the uterus, the uterine tubes, and the ovaries can be palpated; the ureter, as it crosses the lateral fornix to enter the bladder, can be rolled between the finger and the inner surface of the os pubis. If a speculum be introduced into the vagina, the walls of the passage, the vaginal portion of the cervix uteri, and the external uterine orifice can all be exposed for visual examination.

The external urethral orifice lies in front of the vaginal opening, and has rather prominent margins. The urethral canal in the female is very dilatable and can be explored with the finger. About 2·5 cm. in front of the external orifice of the urethra are the glans and prepuce of the clitoris, and still further forward, the mons pubis.

THE SURFACE ANATOMY OF THE UPPER EXTREMITY

The **skin.**—The skin covering the shoulder and arm is smooth and very movable on the underlying structures. In the axilla there are numerous hairs and many sudoriferous and sebaceous glands. On the medial side and front of the forearm the skin is thin and smooth, and contains few hairs but many sudoriferous glands; on the lateral side and back of the arm and forearm it is thicker, denser, and contains more hairs but fewer sudoriferous glands. In the region of the olecranon it is thick and rough; it is very loosely connected to the underlying tissue, and falls into transverse wrinkles when the forearm is extended. At the front of the wrist there are three transverse furrows in the skin; they correspond from above downwards to the positions of the styloid process of the ulna, the radiocarpal or wrist-joint, and the midcarpal joint.

The skin of the palm of the hand is hard and dense, and covered with a thick layer of epidermis; on the thenar eminence these characteristics are less marked than elsewhere. It is exceedingly sensitive and very vascular, but is destitute of hairs and sebaceous glands. It is tied down by fibrous bands along the lines of flexion of the digits, and exhibits certain furrows of a permanent character. One of these furrows begins in front of the wrist at the tuberosity of the navicular bone, curves round the thenar eminence, and ends on the lateral border of the hand near the level of the metacarpophalangeal joint of the index finger; a second begins at the distal end of the first and extends obliquely across the palm to reach the medial border about the middle of the fifth metacarpal bone; a third begins at the medial border about 2·5 cm. distal to the end of the second, and extends across the heads of the fifth, fourth, and third metacarpal bones. The medial part of the third line and the lateral part of the second line lie in front of the metacarpophalangeal joints of the fingers. The proximal segments of the fingers are joined to one another on the volar aspect by folds of skin constituting the 'web' of the fingers; these folds are about opposite the level of the centres of the proximal phalanges and their free margins are continuous with the transverse furrows at the roots of the fingers. Since the web is confined to the volar aspect, the fingers appear shorter when viewed from in front than from behind. Over the fingers and thumb the skin is thinner, especially at the flexures of the joints (where it is crossed by transverse furrows) and over the terminal phalanges; it is disposed in numerous ridges in consequence of the arrangement of the papillæ in it. These ridges form, in different individuals, distinctive and permanent patterns which can be used for purposes of identification.

The superficial fascia in the palm of the hand is made up of dense fibro-fatty tissue which binds the skin so firmly to the palmar aponeurosis that very little movement is permitted between the two.

On the back of the hand and fingers the subcutaneous tissue is lax, and the skin is freely movable on the underlying parts. Over the interphalangeal joints it is very loose and is thrown into transverse wrinkles when the fingers are extended.

The **bones.**—The *clavicle* can be felt throughout its entire length. The enlarged sternal end projects above the sternum at the side of the jugular notch, and from

CC-0. In Public Domain. Gurukul Kangri Collection, Haridwar

Digitized by Arya Samaj Foundation Chennai and eGangotri

this the body of the bone can be traced lateralwards under the skin. The medial part is convex forwards, but the surface is partially obscured by the attachments of the Sternocleidomastoideus and Pectoralis major; the lateral one-third is concave forwards and ends in a slight enlargement at the acromion of the scapula. The clavicle is almost horizontal when the arm is lying by the side, although in muscular subjects it may incline a little upwards at its acromial end, which is on a plane posterior to the sternal end.

The only parts of the *scapula* that are subcutaneous are the spine and acromion, but the coracoid process, the vertebral border, the inferior angle, and to a lesser extent the axillary border can be readily defined. The acromion and the posterior border of the spine are easily recognisable throughout their entire extent, forming with the clavicle the arch of the shoulder. The acromion forms the point of the shoulder; it joins the clavicle at an acute angle—the acromial angle—slightly medial to, and behind the tip of the acromion. The spine can be felt in the floor of an oblique depression and becomes less distinct when traced medialwards; it ends in a slight dimple a little lateral to the spinous process of the third thoracic vertebra. Below this point the vertebral border may be followed downwards and lateralwards to the inferior angle, which is easily identified although covered by the Latissimus dorsi. From the inferior angle the axillary border may be traced upwards through its thick muscular covering, forming with its enveloping muscles the posterior fold of the axilla; this fold is more vertical in direction than the anterior fold of the axilla, and can be seen from the front. The coracoid process is situated about 2 cm. below the junction of the intermediate with the lateral one-third of the clavicle; it is covered by the anterior border of the Deltoideus, and thus lies a little lateral to the infraclavicular fossa or depression which marks the interval between the Pectoralis major and Deltoideus.

The *humerus* is almost entirely surrounded by muscles, and the only parts which are subcutaneous are its medial and lateral epicondyles; in addition to these, however, the tubercles and a part of the head of the bone can be felt under the skin and muscles by which they are covered. The greater tubercle forms the most prominent bony point of the shoulder, extending beyond the acromion; it is best recognised when the arm is lying passive by the side, for if the arm be raised it recedes under the arch of the shoulder. The lesser tubercle, directed forwards, is medial to the greater, and is separated from it by the intertubercular sulcus, which can be made out by deep pressure. When the arm is abducted the lower part of the head of the humerus can be felt by pressing deeply in the axilla. On either side of the elbow-joint and just above it are the medial and lateral epicondyles. Of these, the former is the more prominent, but the medial supracondylar ridge is much less marked than the lateral, and as a rule is not palpable; occasionally, however, the hook-shaped supracondylar process (p. 284*) is found on this border. The position of the lateral epicondyle is best seen during semiflexion of the forearm, and is indicated by a depression; from it the strongly marked lateral supracondylar ridge runs upwards.

The most prominent part of the *ulna*, the olecranon, can always be identified at the back of the elbow-joint; when the forearm is flexed its upper quadrilateral surface is palpable, but during extension this surface recedes into the olecranon fossa. During extension the upper border of the olecranon is slightly above the level of the medial epicondyle and nearer to this than to the lateral epicondyle; when the forearm is fully flexed the olecranon and the epicondyles form the angles of an equilateral triangle. On the back of the olecranon is a smooth triangular subcutaneous surface, and running down the back of the forearm from the apex of this triangle the sinuous dorsal border of the ulna can be felt in its whole length: above, it is situated in the middle of the back of the limb; but below, where it is rounded off, it may be traced to the small subcutaneous surface of the styloid process on the medial side of the wrist. The styloid process forms a prominent tubercle continuous above with the dorsal border and ending below in a blunt apex at the level of the wrist-joint; it is most evident when the hand is in a position midway between supination and pronation. When the forearm is pronated the head of the ulna projects on the back of the wrist; between the head and styloid process of the ulna is the groove which lodges the tendon of the Extensor carpi ulnaris.

Below the lateral epicondyle of the humerus a portion of the head of the *radius* is palpable; its position is indicated on the surface by a little dimple which is best seen when the arm is extended. If a finger be placed in this dimple and the

CC-0. In Public Domain. Gurukul Kangri Collection, Haridwar

Digitized by Arya Samaj Foundation Chennai and eGangotri

semiflexed forearm pronated and supinated the head of the radius will be felt rotating in the radial notch. The upper half of the body of the bone is obscured by muscles; the lower half can be readily examined, and when traced downwards is found to end in a lozenge-shaped convex surface on the lateral side of the base of the styloid process; this is the only subcutaneous part of the bone, and from its lower end the apex of the styloid process bends medialwards towards the wrist. The styloid process of the radius is about 1·25 cm. below the level of the styloid process of the ulna. About the middle of the dorsal surface of the lower end of the radius is the dorsal radial tubercle, best perceived when the wrist is slightly flexed; it forms the lateral boundary of the oblique groove in which the tendon of the Extensor pollicis longus lies.

On the front of the wrist are two subcutaneous eminences, one, on the radial side, produced by the tuberosity of the *navicular bone*, and the ridge on the *greater multangular bone*; the other, on the ulnar side, by the *pisiform bone*. These eminences are crossed by the most distal of the three transverse skin furrows on the front of the wrist. The rest of the volar surface of the carpus is covered by tendons and the transverse carpal ligament, and is entirely concealed, with the exception of the hamulus of the *hamate bone*, which, however, is difficult to define. On the dorsal surface of the carpus the *triquetral bone* can be clearly made out, and when the wrist-joint is acutely flexed the head of the capitate bone may be felt.

The dorsal surfaces of the *metacarpal bones*, except that of the fifth, are covered by the extensor tendons, and are visible only in very thin hands; the dorsal surface of the fifth is, however, subcutaneous throughout almost its whole length. The styloid process of the third metacarpal bone is frequently well marked; it forms a prominence situated slightly lateral to the middle line of the hand and about 4 cm. distal to the dorsal radial tubercle. The heads of the metacarpal bones are rounded in contour and stand out in bold relief under the skin when the fist is clenched; the head of the third is the most prominent. In the palm of the hand the metacarpal bones of the fingers are covered by muscles, tendons, and aponeuroses, so that only their heads can be distinguished. The base of the metacarpal bone of the thumb, however, is prominent dorsally, and the body of the bone is easily palpable, ending at the head in a flattened prominence in front of which are the sesamoid bones.

The enlarged ends of the *phalanges* can be easily felt. When the digits are flexed, a slight concavity can be recognised on the distal end of each of the first phalanges; the distal ends of the second phalanges are flattened and square-shaped.

The **articulations.**—The *sternoclavicular joint* is subcutaneous, and its position is indicated by the enlarged sternal extremity of the clavicle, lateral to the long cord-like sternal head of Sternocleidomastoideus. If this muscle be relaxed a depression between the end of the clavicle and the sternum can be felt, defining the exact position of the joint.

The position of the *acromioclavicular joint* is ascertained by determining the slightly enlarged acromial end of the clavicle which projects above the level of the acromion; sometimes this enlargement is so considerable as to form a rounded eminence. The *shoulder-joint* is deeply seated and cannot be palpated.

When the forearm is slightly flexed a curved crease or fold with its convexity downwards is seen in front of the elbow, extending from one epicondyle to the other; the *elbow-joint* is slightly distal to the middle of the fold. The position of the radiohumeral part of the joint can be ascertained by feeling for a slight groove or depression between the head of the radius and the capitulum of the humerus, at the back of the elbow-joint.

The position of the *proximal radio-ulnar joint* is marked on the surface at the back of the elbow by the dimple which indicates the position of the head of the radius. The site of the *distal radio-ulnar joint* can be defined by feeling for the slight groove at the back of the wrist, between the prominent head of the ulna and the lower end of the radius, when the forearm is in a state of almost complete pronation.

Of the three transverse skin furrows on the front of the wrist, the middle corresponds fairly accurately with the *radiocarpal or wrist-joint*, and the most distal indicates the position of the *midcarpal articulation*.

The *metacarpophalangeal* and *interphalangeal joints* are readily available for surface examination; the former are situated just distal to the prominences of the knuckles, the latter are sufficiently indicated by the furrows on the volar, and the wrinkles on the dorsal, surfaces.

CC-0. In Public Domain. Gurukul Kangri Collection, Haridwar

Digitized by Arya Samaj Foundation Chennai and eGangotri

The **muscles** (figs. 1250, 1251).—The anterior border of the *Trapezius* presents as a slight ridge running downwards and forwards from the superior nuchal line of the occipital bone to the junction of the intermediate with the lateral one-third of the clavicle. The inferior border of the muscle forms an undulating ridge passing downwards and medialwards from the root of the spine of the scapula to the spinous process of the twelfth thoracic vertebra.

FIG. 1250.—The front of the right upper extremity.

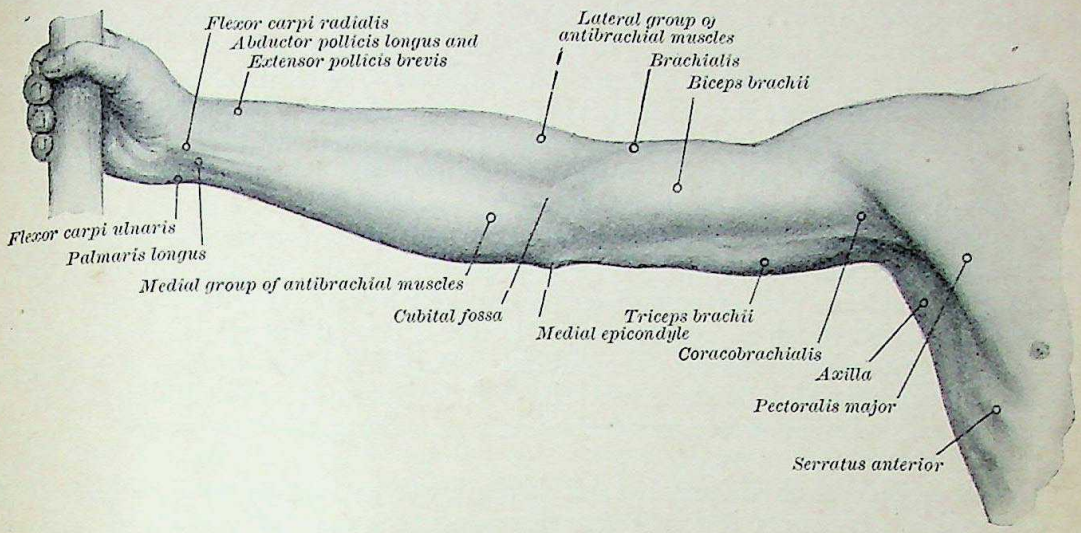

The lateral border of the *Latissimus dorsi* (fig. 1236) may be traced, when the muscle is in action, as a rounded edge starting from the iliac crest a little lateral to the Sacrospinalis, and slanting obliquely forwards and upwards to the axilla, where it takes part with the Teres major in forming the posterior axillary fold; the Latissimus dorsi forms the medial rounded muscular part of the fold, the Teres major the thinner lateral part.

The *Pectoralis major* (fig. 1240) conceals a considerable part of the thoracic wall in front. Its sternal origin presents a border which bounds and determines the width of the sternal furrow. The upper margin is generally well marked near the clavicle, and forms the medial boundary of the infraclavicular fossa, which separates the Pectoralis major from the Deltoideus; it gradually becomes less distinct as it approaches the tendon of insertion and cannot be differentiated from the Deltoideus. The lower border of the Pectoralis major forms the rounded

FIG. 1251.—The back of the right upper extremity.

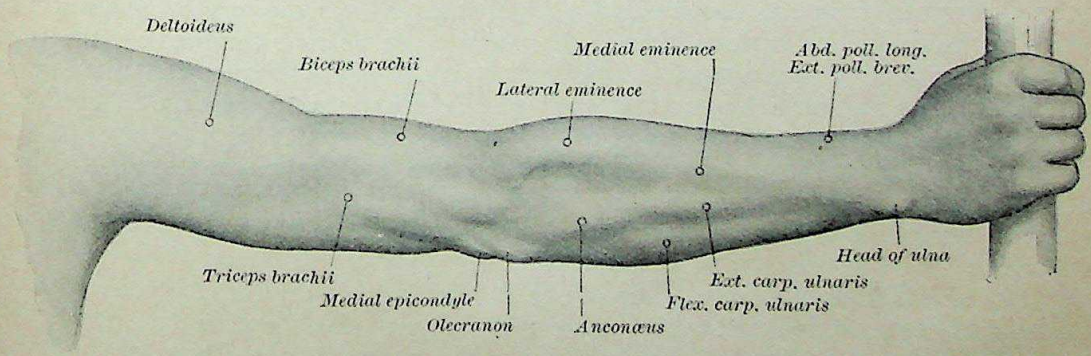

anterior axillary fold. Occasionally a gap is visible between the clavicular and sternal parts of the muscle.

When the arm is raised the lowest slip of origin of the *Pectoralis minor* produces a fulness below the anterior axillary fold and serves to break the sharp outline of the lower border of the Pectoralis major.

The origin of the *Serratus anterior* (figs. 1236, 1240) causes a very characteristic surface marking. When the arm is abducted the lower five or six serrations can

CC-0. In Public Domain. Gurukul Kangri Collection, Haridwar

Digitized by Arya Samaj Foundation Chennai and eGangotri

be seen, separated from those of the Obliquus externus abdominis by a zigzag line. When the arm is by the side the highest visible serration is that attached to the fifth rib.

The *Deltoideus* with the underlying prominence of the upper end of the humerus produces the rounded contour of the shoulder; it is rounder and fuller in front than behind, where it presents a somewhat flattened form. Above, its anterior border presents a slightly curved eminence which forms the lateral boundary of the infraclavicular fossa; below, it is closely united with the Pectoralis major. Its posterior border is thin, flattened, and scarcely evident above, but is thicker and more prominent below. The insertion of the Deltoideus is marked by a depression on the lateral side of the middle of the arm.

Of the scapular muscles the *Teres major* assists the Latissimus dorsi to form the thick, rounded posterior axillary fold.

When the arm is raised the *Coracobrachialis* appears as a narrow elevation emerging from under cover of the anterior axillary fold and running medially to the upper half of the body of the humerus.

On the front and medial aspects of the arm is the prominence of the *Biceps brachii*, bounded on either side by a depression. It determines the contour of the front of the arm and extends from the anterior axillary fold to the bend of the elbow; its upper tendons are concealed by the Pectoralis major and Deltoideus, and its lower tendon sinks into the cubital fossa. When the muscle is fully contracted it presents a globular form, and the lacertus fibrosus (bicipital fascia) attached to its tendon of insertion becomes prominent as a sharp ridge running downwards and medialwards.

On either side of the Biceps brachii at the lower part of the arm the *Brachialis* is discernible. Laterally it forms a narrow eminence extending some distance up the arm; medially it produces only a slight fulness above the elbow.

On the back of the arm the long head of the *Triceps brachii* may be seen as a longitudinal eminence, emerging from under cover of the Deltoideus and gradually passing into the flattened plane of the tendon of insertion of the muscle at the lower part of the back of the arm. When the muscle is in action its medial and lateral heads are prominent.

On the front of the elbow are two muscular elevations, one on either side, which converge below and form the medial and lateral boundaries of the cubital fossa. The medial elevation consists of the Pronator teres and the flexors, and is fusiform, pointed above at the medial epicondyle, and gradually tapering off below. The *Pronator teres* is the most lateral of the group, while the *Flexor carpi radialis*, lying to its medial side, is the most prominent and may be traced downwards to its tendon; this tendon is easily identified as far as the front of the wrist where it is placed on the medial side of the radial artery and on the lateral side of the median nerve. The *Palmaris longus* presents no surface marking above, but below, its tendon stands out when the muscle is in action as a sharp cord in front of the middle of the wrist, just medial to the tendon of the Flexor carpi radialis, and immediately in front of the median nerve. The *Flexor digitorum sublimis* does not directly influence surface form; the position of its four tendons on the front of the lower part of the forearm is indicated by an elongated depression between the tendon of the Palmaris longus and that of the Flexor carpi ulnaris. The *Flexor carpi ulnaris* determines the contour of the medial border of the forearm, and is separated from the extensor group of muscles by the ulnar furrow the floor of which is formed by the subcutaneous dorsal border of the ulna; its tendon is evident along the ulnar border of the lower part of the forearm, and stands out when the little finger is strongly abducted.

The elevation on the lateral side of the cubital fossa is produced by the Brachioradialis, the extensors, and the Supinator; it occupies the lateral and a considerable part of the dorsal surface of the forearm in the region of the elbow, and appears as a fusiform swelling which is on a higher level than that produced by the medial elevation. Its apex is between the Triceps brachii and Brachialis some distance above the elbow-joint; its greatest breadth is opposite the lateral epicondyle; below this it shades off into a flattened surface. About the middle of the forearm a furrow divides it into a lateral and a medial eminence. The lateral eminence consists of the *Brachioradialis*, the *Extensor carpi radialis longus* and the *Extensor carpi radialis brevis*. The medial border of the Brachioradialis starts as a rounded elevation above the lateral epicondyle. Lower down the muscle forms a prominent

CC-0. In Public Domain. Gurukul Kangri Collection, Haridwar

Digitized by Arya Samaj Foundation Chennai and eGangotri

mass on the radial side of the upper part of the forearm; below, it tapers to its tendon which may be traced to the base of the styloid process of the radius. The medial eminence comprises the *Extensor digitorum communis*, *Extensor digiti quinti proprius*, and the *Extensor carpi ulnaris*; it begins at the lateral epicondyle of the humerus as a tapering mass which is separated above from the Anconæus by a well-marked groove, and below from the Flexor carpi ulnaris by the ulnar furrow. The *Anconæus* produces a triangular, slightly elevated area, immediately lateral to the subcutaneous surface of the olecranon and separated from the extensor group by an oblique depression; the upper angle of the triangle is at the dimple behind the lateral epicondyle.

At the lower part of the back of the forearm in the interval between the lateral and medial eminences is an oblique elongated swelling, full above but flattened and partially subdivided below; it is caused by the *Abductor pollicis longus* and the *Extensor pollicis brevis*. It crosses the dorsal and lateral surfaces of the radius to the lateral side of the wrist-joint, whence it is continued to the dorsal surface of the thumb as a ridge which is best marked when the thumb is extended.

The tendons of most of the extensor muscles can be seen and felt on the back of the wrist. Laterally is the oblique ridge produced by the Extensor pollicis longus; it may be followed from the ridge on the dorsal surface of the lower end of the radius to the base of the distal phalanx of the thumb. When the wrist is extended the Extensor carpi radialis longus and the Extensor carpi radialis brevis can be identified running side by side from the lateral edge of the ridge on the dorsal surface of the lower end of the radius to the bases of the second and third metacarpal bones. Medial to these the extensor tendons of the fingers can be felt, the Extensor digiti quinti proprius being separated from those of the Extensor digitorum communis by a slight furrow.

The muscles of the hand are principally concerned, as regards surface form, in producing the thenar and hypothenar eminences, and cannot be individually distinguished; the thenar eminence, on the lateral side, is larger and rounder then the hypothenar, which is a long narrow elevation along the medial side of the palm. When the *Palmaris brevis* is in action it produces a wrinkling of the skin over the proximal part of the hypothenar eminence and a dimple on the medial border of the hand. On the back of the hand the *Interossei dorsales* fill the intervals between the metacarpal bones; the first forms a prominent fusiform bulging when the thumb is adducted.

The **arteries.**—Above the middle of the clavicle the pulsation of the *subclavian artery* can be detected by pressing downwards, backwards, and medialwards against the first rib. The pulsation of the *axillary artery*, where the vessel crosses the second rib, can be felt below the middle of the clavicle medial to the coracoid process; along the lateral wall of the axilla the course of the artery can be easily followed close to the medial border of the Coracobrachialis. The pulsation of the *brachial artery* can be recognised and the thickness of the vessel wall determined in the greater part of its course as it lies along the medial margin of the Biceps brachii; in the upper two-thirds of the arm it lies on the medial side of the humerus, but in the lower one-third is more directly in front of the bone. In front of the lower end of the radius, between the styloid process and Flexor carpi radialis, a portion of the *radial artery* is superficial and is used clinically for observations on the pulse.

The **veins.**—The superficial veins of the upper extremity are easily rendered visible by compressing the proximal trunks near the axilla; their arrangement is described on pp. 724 to 727.

The **nerves.**—The uppermost trunks of the *brachial plexus* can be felt for a short distance above the clavicle as they emerge from under the lateral border of Sternocleidomastoideus; the larger nerves derived from the plexus can be rolled under the finger against the lateral axillary wall, but cannot be separately identified. The *ulnar nerve* can be detected in the sulcus nervi ulnaris behind the medial epicondyle of the humerus, but is more easily felt about 2 cm. below the elbow-joint.

THE SURFACE MARKINGS OF THE UPPER EXTREMITY

The **bony landmarks.**—The bony landmarks as described above are so readily available for surface recognition that no special measurements are required to indicate them. It may be noted, however, that the medial angle of the scapula

CC-0. In Public Domain. Gurukul Kangri Collection, Haridwar

Digitized by Arya Samaj Foundation Chennai and eGangotri

is applied to the second rib, while the inferior angle lies against the seventh. The intertubercular sulcus of the humerus is vertically below the acromioclavicular joint when the arm hangs by the side of the body with the palm of the hand forwards.

FIG. 1252.—The mucous sheaths of the tendons on the front of the wrist and digits. (From a preparation by J. C. B. Grant.)

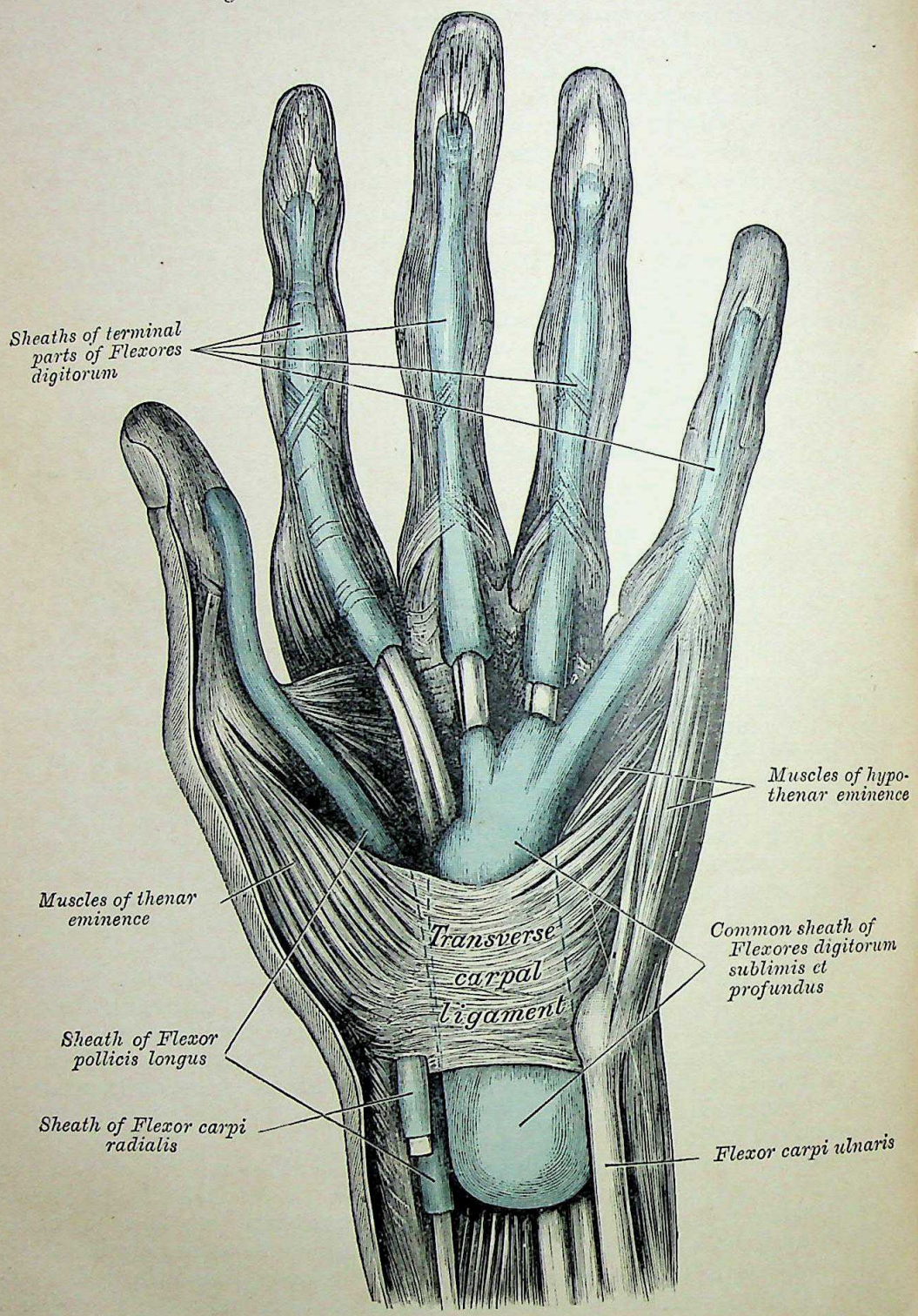

The **articulations.**—The *acromioclavicular joint* is situated in a plane passing sagitally through the middle line of the front of the arm. The line of the *elbow-joint* is not straight; the humeroradial portion is practically at right angles to the long axis of the humerus, and is situated about 2 cm. distal to the lateral epicondyle; the humero-ulnar portion is oblique, and its medial end is about 2·5 cm. distal to the medial epicondyle. The position of the *wrist-joint* can be indicated by

CC-0. In Public Domain. Gurukul Kangri Collection, Haridwar

Digitized by Arya Samaj Foundation Chennai and eGangotri

drawing a curved line, with its convexity upwards, between the styloid processes of the radius and ulna; the summit of the convexity is about 1 cm. above the centre of a straight line joining the two processes.

FIG. 1253.—The mucous sheaths of the tendons on the back of the wrist. (From a preparation by J. C. B. Grant.)

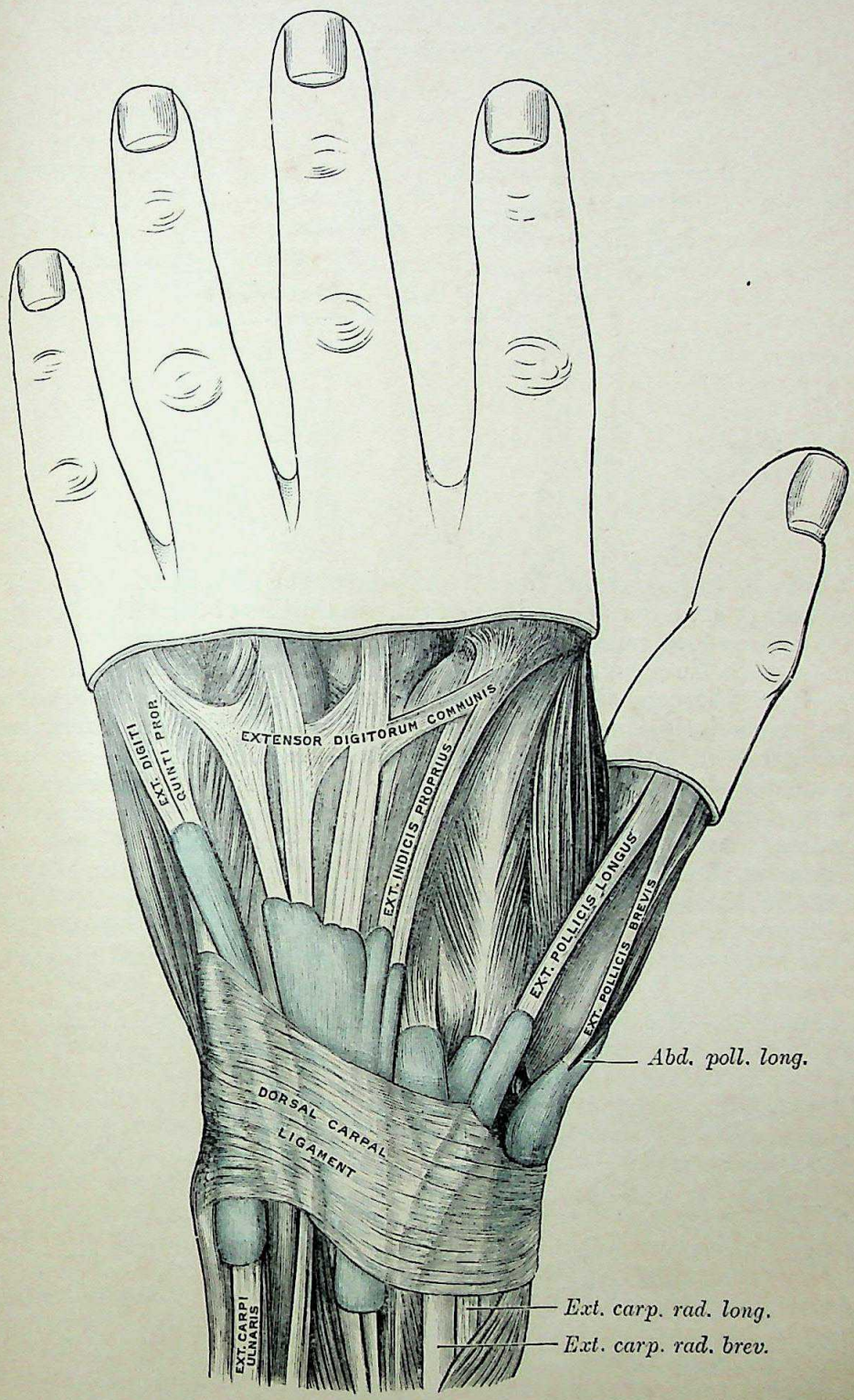

The **muscles.**—The only muscles of the upper extremity which occasionally require definition by surface lines are the Trapezius, the Latissimus dorsi and the Pectorales major et minor. The anterosuperior border of the *Trapezius* is indicated by a line from a point about 3 cm. lateral to the external occipital protuberance to the junction of the intermediate with the lateral one-third of the clavicle; the line of the lower border extends from the spinous process of the twelfth thoracic

CC-0. In Public Domain. Gurukul Kangri Collection, Haridwar

Digitized by Arya Samaj Foundation Chennai and eGangotri

vertebra to the root of the spine of the scapula. The upper border of the *Latissimus dorsi* is almost horizontal, running from the spinous process of the seventh thoracic vertebra to the inferior angle of the scapula and thence somewhat obliquely to the intertubercular sulcus of the humerus; the lower border corresponds roughly to a line drawn from the iliac crest about 2 cm. from the lateral margin of the Sacrospinalis to the intertubercular sulcus of the humerus. The upper margin

FIG. 1254.—The front of the right upper extremity, showing the surface markings for the bones, arteries, and nerves.

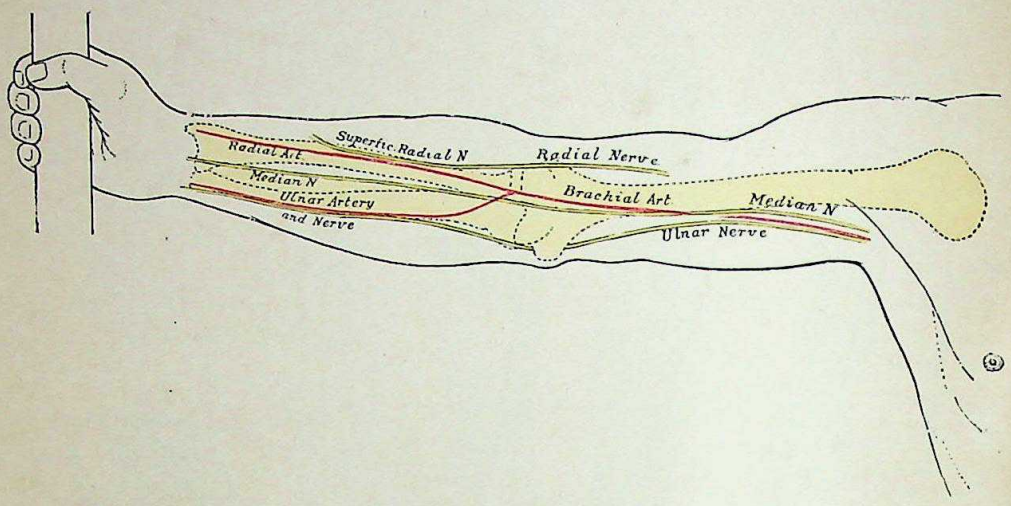

of the *Pectoralis major* extends from the middle of the clavicle to the surgical neck of the humerus; its lower border is practically in the line of the fifth rib and reaches from the fifth costochondral junction to the middle of the anterior border of the Deltoideus. The lines indicating the upper and lower borders of the *Pectoralis minor* begin at the coracoid process of the scapula and extend to the third and fifth ribs respectively, just lateral to the corresponding costal cartilages. On the front of the elbow-joint a triangular space—the cubital fossa—is mapped out for convenience of reference. The base of the triangle is a line joining the medial and lateral epicondyles of the humerus, while the sides are formed respectively by the salient margins of the Brachioradialis and Pronator teres.

The **mucous sheaths.**—On the volar surfaces of the wrist and hand the mucous sheaths of the flexor tendons (fig. 1252) can be indicated as follows. The sheath for the Flexor pollicis longus extends from a point about 3 cm. above the upper edge of the transverse carpal ligament to the base of the terminal phalanx of the

FIG. 1255.—The back of the right upper extremity, showing the surface markings for the bones and nerves.

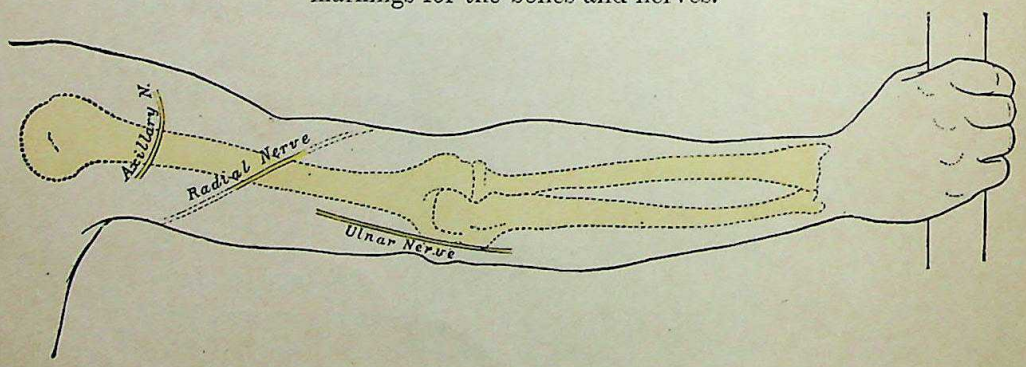

thumb. The common sheath for the tendons of the Flexor digitorum sublimis and Flexor digitorum profundus reaches about 4 cm. above the upper edge of the transverse carpal ligament and extends into the palm to about the level of the centres of the metacarpal bones. The sheath for the tendons to the little finger is continued from the common sheath to the base of the terminal phalanx of this finger; the sheaths of the tendons to the index, middle and ring fingers are separated from the common sheath by an interval; they begin opposite the necks of

CC-0. In Public Domain. Gurukul Kangri Collection, Haridwar

Digitized by Arya Samaj Foundation Chennai and eGangotri

the metacarpal bones and extend to the bases of the terminal phalanges. The mucous sheaths of the extensor tendons are shown in fig. 1253 (see also p. 519).

The **arteries** (fig. 1254).—The course of the *axillary artery* can be indicated by raising the arm to the level of the shoulder and drawing a line from the middle of the clavicle to the point where the tendon of the Pectoralis major crosses the prominence of the Coracobrachialis. The origin of the *thoraco-acromial artery* corresponds to the point where the axillary artery is crossed by the upper border of the Pectoralis minor; the *lateral thoracic artery* follows the line of the lower border of the Pectoralis minor; the *subscapular artery* is sufficiently indicated by the axillary border of the scapula; the *scapular circumflex artery* rises from the subscapular artery opposite the midpoint of a line joining the tip of the acromion to the lower edge of the deltoid tuberosity, or, alternatively, from a point on the axillary border of the scapula 5 cm. from the inferior angle; the *humeral circumflex arteries* arise from the axillary artery about 2 cm. above this. The course of the *brachial artery* is marked by a line drawn from the medial border of the Coracobrachialis at the level of the posterior axillary fold to a point in front of the elbow-joint midway between the epicondyles of the humerus, and continued distally for 2·5 cm., where the artery bifurcates. The *arteria profunda brachii* crosses the back of the humerus at the level of the insertion of Deltoideus; the *nutrient artery* of the humerus arises opposite the middle of the body of the bone; a line from this point to the back of the medial epicondyle represents the *superior ulnar collateral artery*; the *inferior ulnar collateral artery* arises about 5 cm. above the fold of the elbow-joint and runs medialwards.

FIG. 1256.—The palm of the left hand, showing the positions of the skin creases and the bones, and the surface markings for the volar arches.

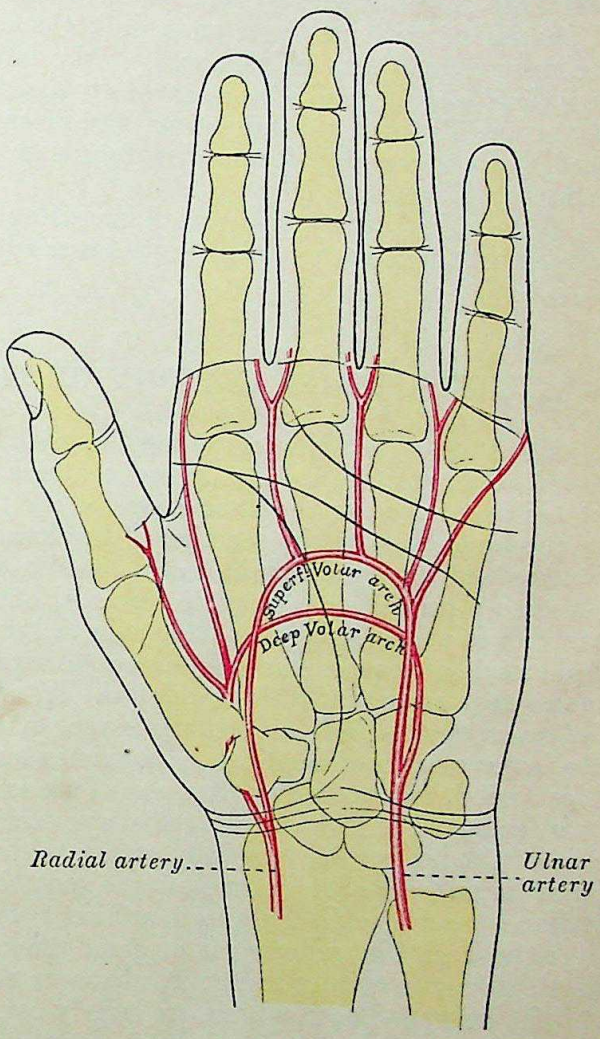

The position of the *radial artery* in the forearm is represented by a line drawn from the lateral margin of the tendon of the Biceps brachii in the centre of the cubital fossa, to the medial side of the front of the styloid process of the radius. The situation of the distal portion of the artery is indicated by continuing this line round the radial side of the wrist to the proximal end of the first intermetacarpal space.

On account of the curved direction of the *ulnar artery*, two lines are required to indicate its course in the forearm; one is drawn from the front of the medial epicondyle of the humerus to the radial side of the pisiform bone; the distal two-thirds of this line represent the distal two-thirds of the artery; the proximal one-third of the artery is represented by a line, convex medialwards, from the centre of the hollow in front of the elbow-joint to the junction of the upper with the middle one-third of the first line.

The position of the *superficial volar arch* (fig. 1256) is indicated by a curved line starting from the radial side of the pisiform bone, running distalwards for about one-half of the length of the palm, then lateralwards as far as the base of the thumb, and finally proximalwards towards the middle of the thenar eminence. The summit of the arch is usually on a level with the distal border of the outstretched

CC-0. In Public Domain. Gurukul Kangri Collection, Haridwar

Digitized by Arya Samaj Foundation Chennai and eGangotri

thumb. The *deep volar arch* is transverse in direction, and is situated about 1 cm. nearer to the carpus.

The **nerves** (figs. 1254, 1255).—In the arm the line of the *median nerve* is that for the brachial artery; at the upper part of the arm it is lateral to the artery, whereas at the bend of the elbow it is medial to it. The course of the nerve in the forearm is marked by a line starting from a point just medial to the centre of one joining the humeral epicondyles, or midway between the medial epicondyle and the tendon of Biceps brachii, and extending to the middle of the front of the wrist where it lies deep to the tendon of the Palmaris longus.

The *ulnar nerve* follows the line of the brachial artery in the upper half of the arm, but at the middle of the arm it leaves the artery and descends to the back of the medial epicondyle. In the forearm it is represented by a line from the front of the medial epicondyle to the lateral side of the pisiform bone.

The course of the *radial nerve* can be indicated by a line drawn from just below the posterior axillary fold, to the lateral side of the humerus at the junction of its middle with its lower one-third; thence it passes vertically downwards on the front of the arm to the level of the lateral epicondyle. The course of the *superficial radial nerve* is represented by a continuation of this line to the junction of the middle with the lower one-third of the radius; it then crosses the lateral border of the radius and runs distalwards to the dorsum of the base of the first metacarpal bone.

The *axillary nerve* crosses the humerus about 2 cm. above the centre of a line joining the tip of the acromion to the lower edge of the deltoid tuberosity.

THE SURFACE ANATOMY OF THE LOWER EXTREMITY

The skin.—The skin on the medial side of the thigh and in the hollow of the groin is thin, smooth, and elastic, and contains few hairs except in the neighbourhood of the os pubis; on the lateral side of the thigh it is thicker, and the hairs are more numerous. At the junction of the front of the thigh with the abdomen is a well-defined furrow which indicates the site of the inguinal ligament; the furrow presents a general convexity downwards, but its medial half, which is the better marked, is nearly straight. The skin of the buttock is fairly thick and as a rule is destitute of conspicuous hairs except towards the post-anal furrow, where in some males they are abundantly developed. An almost transverse fold—the *fold of the buttock* or *glutæal fold*—crosses the lower part of the buttock; it practically bisects the lower margin of the Glutæus maximus and is most evident when the hip-joint is extended. The skin over the front of the knee is covered by thickened epidermis; it is loose and is thrown into transverse wrinkles when the leg is extended. The skin of the leg is thin, especially on the medial side, and is covered with numerous large hairs. On the dorsum of the foot the skin is thin, loosely connected to subjacent parts, and contains few hairs; on the plantar surface, and especially over the heel, the epidermis is of great thickness, and here, as in the palm of the hand, there are neither hairs nor sebaceous glands.

The bones.—The *hip-bones* are largely covered with muscles, and only approach the surface at a few points. In front, the anterior superior iliac spine is easily recognised, and in thin subjects stands out as a prominence at the lateral end of the fold of the groin; in fat subjects its position is indicated by an oblique depression, at the bottom of which the bony process can be felt. Proceeding upwards and backwards from the anterior superior iliac spine the sinuously curved iliac crest can be traced to the posterior superior iliac spine, the site of which is indicated by a slight depression; on the outer lip of the crest, about 5 cm. behind the anterior superior spine, is the iliac tubercle. In thin subjects the pubic tubercle is very apparent, but in the obese it is obscured by the pubic fat; it can, however, be detected by following the tendon of origin of the Adductor longus. Another part of the hip-bone which is accessible to touch is the ischial tuberosity, situated beneath the Glutæus maximus and easily felt when the hip-joint is flexed, as it is then uncovered by muscle. On the boundary of the perinæum the whole outline of the pubic arch can be recognised.

The *femur* is enveloped by muscles, so that the only subcutaneous parts of it are the lateral surface of the greater trochanter and the lower expanded end of

CC-0. In Public Domain. Gurukul Kangri Collection, Haridwar

Digitized by Arya Samaj Foundation Chennai and eGangotri

the bone. The site of the greater trochanter is generally indicated by a depression owing to the thickness of the Glutæus medius and Glutæus minimus which project above it; when, however, the thigh is flexed, and especially if it be crossed over the opposite one, the trochanter produces a blunt eminence on the surface. The condyles and epicondyles can be readily identified, and at the upper part of the medial condyle the sharp adductor tubercle can be recognised without difficulty. When the knee is flexed the upper portion of the patellar surface of the femur is palpable above the patella.

The anterior surface of the *patella* is subcutaneous. When the knee is extended the medial border of the bone is a little more prominent than the lateral, and if the Quadriceps femoris be relaxed the bone can be moved from side to side. When the joint is flexed the patella recedes into the hollow between the femoral condyles and the upper end of the tibia, and is firmly applied to the femur.

FIG. 1257.—The front and medial surface of the right thigh.

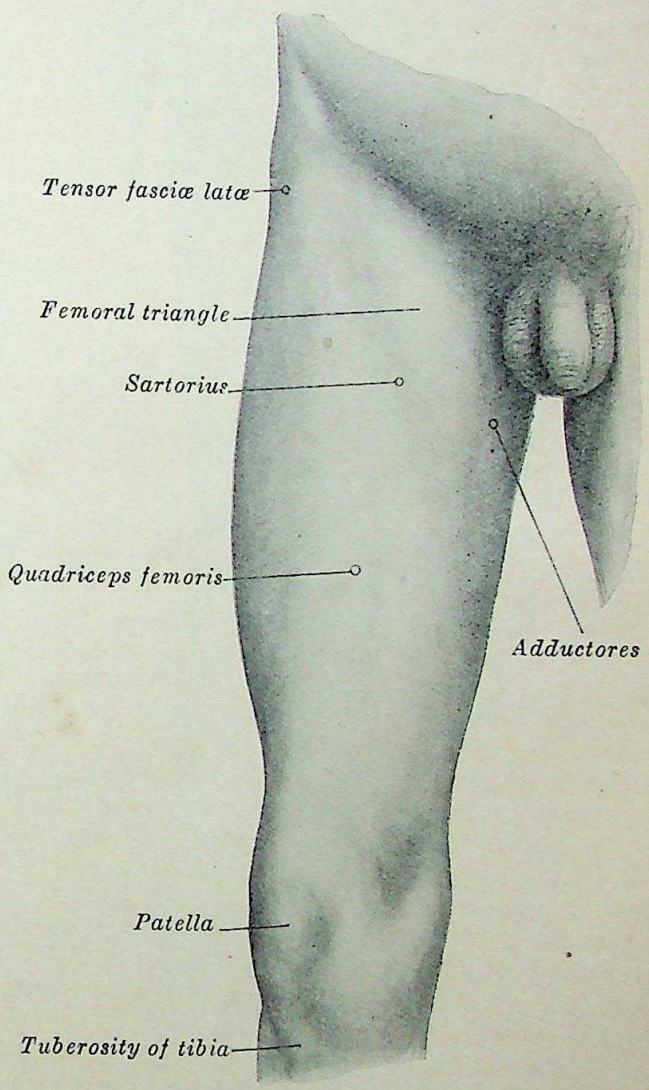

A considerable portion of the *tibia* is subcutaneous. At the upper end the condyles can be felt just below the knee; the medial condyle is broad and smooth, and merges below into the subcutaneous surface of the body or shaft of the bone; the lateral is narrower and more prominent, and on it, about midway between the apex of the patella and the head of the fibula, is the tubercle for the attachment of the iliotibial tract of the fascia lata of the thigh. In front of the upper end of the bone, between the condyles, is the tuberosity, which is continuous below with the anterior crest of the bone. This crest is subcutaneous throughout; it is sharp in its upper three-fourths but more rounded below where it ultimately becomes continuous with the anterior border of the medial malleolus. Medial to the anterior crest is the broad subcutaneous surface. The medial malleolus forms a broad prominence, situated at a higher level and somewhat farther forward than the lateral malleolus; its anterior border is nearly straight; on its posterior is a sharp edge which forms the medial margin of the groove for the tendon of the Tibialis posterior.

The only subcutaneous parts of the *fibula* are the head, the lower part of the body or shaft, and the lateral malleolus. The head lies behind and lateral to the lateral condyle of the tibia, and appears as a small prominent pyramidal eminence slightly above the level of the tibial tuberosity; its position can be located by following the tendon of Biceps femoris downwards. The lateral malleolus is a narrow elongated prominence from which the lower one-third or half of the lateral surface of the body of the bone can be traced upwards.

On the dorsum of the tarsus the individual bones cannot be distinguished, with the exception of the head of the *talus* which forms a rounded projection in front of the ankle-joint when the foot is extended. The whole dorsal surface of the foot

CC-0. In Public Domain. Gurukul Kangri Collection, Haridwar

Digitized by Arya Samaj Foundation Chennai and eGangotri

has a smooth convex outline, the summit of which is the ridge formed by the head of the talus, the navicular, the second cuneiform, and the second metatarsal bone; from this it inclines gradually lateralwards, and rapidly medialwards. On the medial side of the foot the medial process of the tuberosity of the *calcaneus* and the ridge separating the posterior from the medial surface of the bone are distinguishable; in front of this, and 2 cm. below the medial malleolus, is the sustentaculum tali. The tuberosity of the *navicular* is palpable about 2·5 cm. in front of the sustentaculum tali.

Fig. 1258.—The back of the left lower extremity.

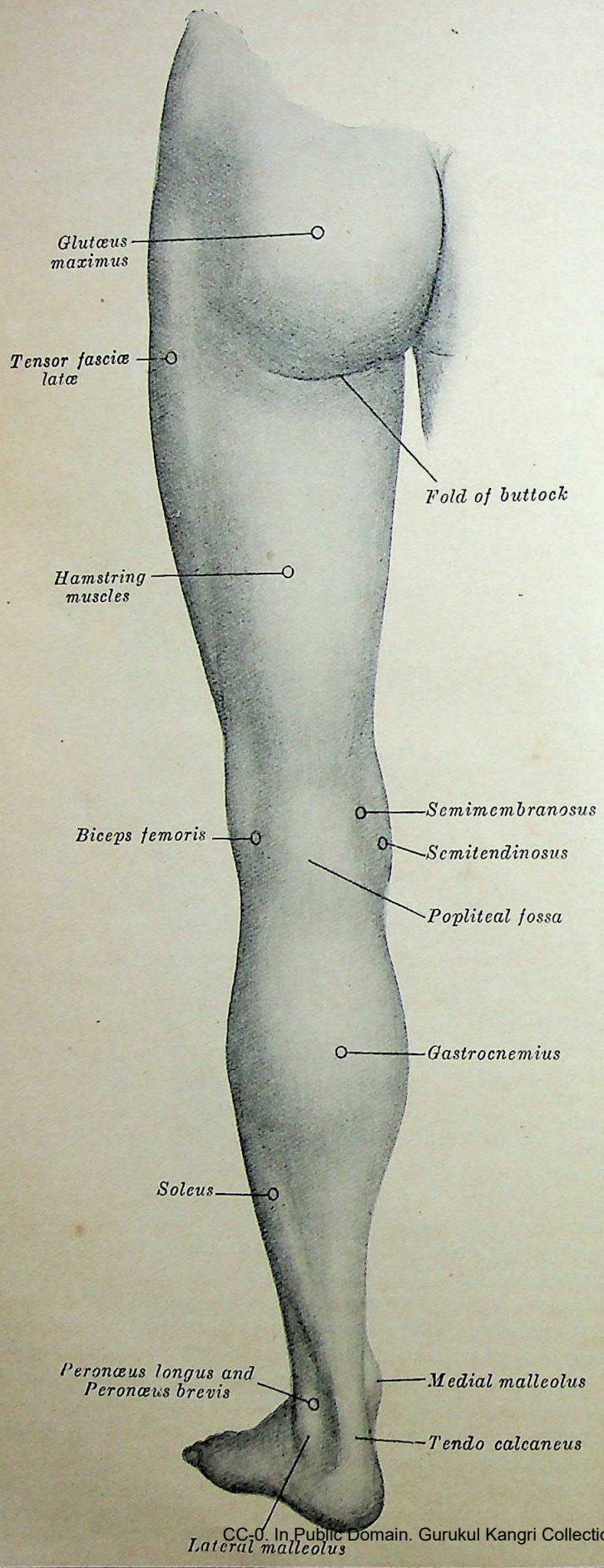

Farther forwards, the ridge formed by the base of the *first metatarsal bone* can be obscurely felt, and from this the body of the bone can be traced to the expanded head; beneath the head is the medial sesamoid bone. On the lateral side of the foot, the most posterior bony point is the lateral process of the tuberosity of the calcaneus, with the ridge separating the posterior from the lateral surface of the bone. In front of this the greater part of the lateral surface of the calcaneus is subcutaneous; on it, below and in front of the lateral malleolus, the trochlear process, when present, can be felt. Farther forwards the base of the *fifth metatarsal bone* is prominent, and from it the body of the bone can be traced forwards to the head.

As in the case of the metacarpals, the dorsal surfaces of the *metatarsal bones* are easily defined, although their heads do not form prominences;

CC-0. In Public Domain. Gurukul Kangri Collection, Haridwar

Digitized by Arya Samaj Foundation Chennai and eGangotri

the plantar surfaces are obscured by muscles. The *phalanges* in their whole extent are readily palpable.

The **articulations.**—The *hip-joint* is deeply seated and cannot be palpated.

The interval between the tibia and femur, indicating the level of the *knee-joint*, can always be easily felt. When the knee is semi-flexed, the medial border of the patella, the medial condyle of the femur, and the upper border of the medial condyle of the tibia, bound a triangular depressed area which indicates the position of the joint and is in front of the anterior end of the medial meniscus.

The *ankle-joint* can be felt in the hollows between the extensor tendons and the medial and lateral malleoli; during extension of the joint the superior articular surface of the talus projects below the anterior border of the lower end of the tibia.

The *metatarsophalangeal and interphalangeal joints* are all palpable.

FIG. 1259.—The lateral surface of the right leg.

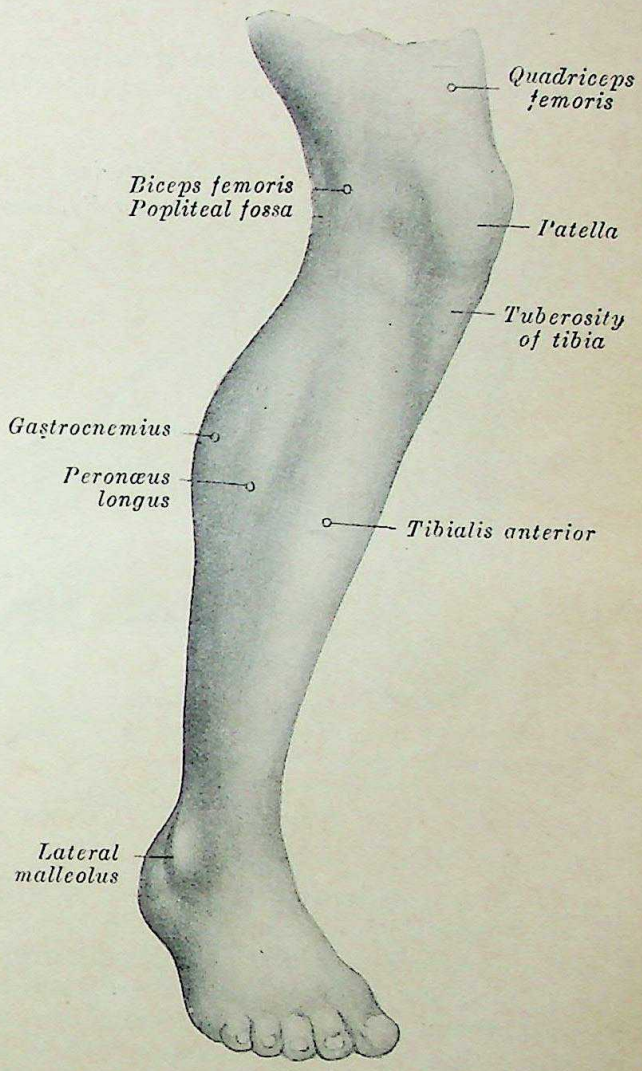

The **muscles.**—Of the muscles of the thigh, those of the anterior femoral region (fig. 1257) contribute largely to surface form. The *Tensor fasciæ latæ* produces an elevation immediately below the anterior part of the iliac crest and above and in front of the greater trochanter of the femur; it is most apparent in standing on one leg; from its lower border a groove caused by the iliotibial tract of the fascia lata extends downwards to the lateral side of the knee-joint. At the knee-joint the *iliotibial tract* forms a prominent band between the head of the fibula and the lateral margin of the patella; it is parallel with, and a finger's breadth in front of, the tendon of the Biceps femoris. The upper portion of the *Sartorius* constitutes the lateral boundary of the femoral triangle, and, when the muscle is in action, forms a prominent oblique ridge which is continued below into a flattened plane and then gradually merges into a general fulness on the medial side of the knee-joint. When the Sartorius is not in action, a depression exists between the Quadriceps femoris and the Adductores and extends obliquely downwards and medialwards from the apex of the femoral triangle to the side of the knee. In the angle between the Sartorius and Tensor fasciæ latæ, just below the anterior superior iliac spine, the *Rectus femoris* appears, and its borders can be defined when the muscle is in action. The *Vastus lateralis* forms a long flattened plane traversed by the groove of the iliotibial tract. The *Vastus medialis* causes a considerable prominence on the medial side of the lower half of the thigh; this prominence increases towards the knee and ends somewhat abruptly with a full curved outline. The *Vastus intermedius* is completely hidden. The Adductores cannot be differentiated from one another, with the exception of the tendon of origin of the Adductor longus and the lower tendon of the Adductor magnus. When the *Adductor longus* is in action, or when the limb is passively abducted, its tendon of origin stands out as a prominent ridge running obliquely downwards and lateralwards from the neighbourhood of the pubic tubercle, and forming the medial border of the

CC-0. In Public Domain. Gurukul Kangri Collection, Haridwar

Digitized by Arya Samaj Foundation Chennai and eGangotri

femoral triangle. The lower tendon of the *Adductor magnus* is felt as a short ridge extending downwards between the Sartorius and Vastus medialis to the adductor tubercle on the medial condyle of the femur. The Adductores fill the triangular space at the upper part of the thigh, between the femur and the pelvis, and to them is due the contour of the medial border of the thigh, the *Gracilis* contributing largely to the smoothness of the outline.

The *Glutæus maximus* (fig. 1258), prominent behind, compressed in front, forms the full rounded outline of the buttock; its lower border runs from the side of the coccyx, over the ischial tuberosity, to about 9 cm. below the greater trochanter of the femur, and crosses the glutæal fold obliquely downwards and lateralwards; its upper border is ill-defined, the lower part of its medial border is separated from the corresponding part of the opposite muscle by the deep glutæal cleft. The upper part of the *Glutæus medius* is visible above and behind the greater

FIG. 1260.—The mucous sheaths of the tendons round the ankle. Lateral aspect. (From a preparation by J. C. B. Grant.)

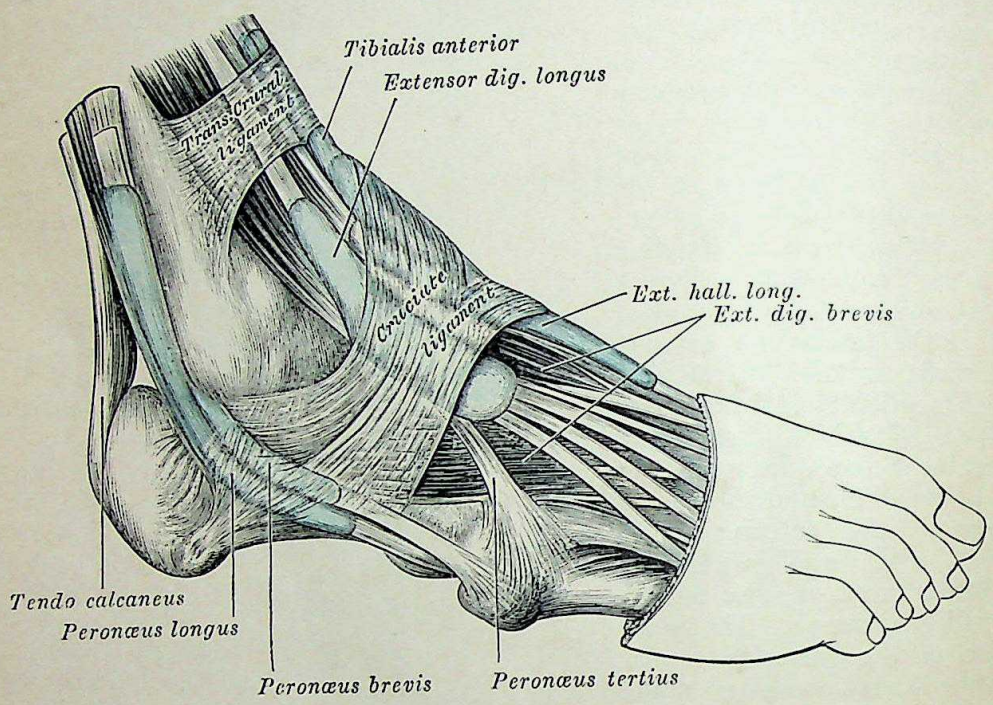

trochanter, but its lower part, together with the *Glutæus minimus* and the external rotators of the thigh, is completely hidden by the Glutæus maximus. The hamstring muscles appear from beneath the lower margin of the Glutæus maximus; at first they are narrow and not well defined, but as they descend they become more prominent and eventually divide into two well-marked ridges formed by their tendons; these constitute the upper boundaries of the popliteal fossa. The tendon of the *Biceps femoris* is a thick cord running to the head of the fibula: the tendons of the *Semimembranosus* and *Semitendinosus* run medialwards to the tibia and are separated by a slight furrow; the Semitendinosus is the more superficial, and can be felt in certain positions of the limb as a sharp cord, while the Semimembranosus is thick and rounded. The Gracilis is situated a little in front of them.

The *Tibialis anterior* (fig. 1259) presents a fusiform enlargement at the lateral side of the tibia and projects beyond the anterior crest of the bone; its tendon can be traced on the front of the tibia and ankle-joint and thence along the medial side of the foot to the base of the first metatarsal bone. The fleshy fibres of the *Peronæus longus* are strongly marked at the upper part of the lateral side of the leg; it is separated by furrows from the Extensor digitorum longus in front and the Soleus behind. Below, the fleshy fibres end abruptly in a tendon which overlaps the more flattened elevation of the *Peronæus brevis*; below the lateral malleolus the tendon of the Peronæus brevis is the more marked and can be traced to the base of the fifth metatarsal bone.

On the dorsum of the foot (fig. 1260) the tendons emerging from beneath the

CC-0. In Public Domain. Gurukul Kangri Collection, Haridwar

Digitized by Arya Samaj Foundation Chennai and eGangotri

transverse and cruciate crural ligaments spread out and can be distinguished as follows: the most medial and largest is the Tibialis anterior, the next is the Extensor hallucis proprius, then the Extensor digitorum longus dividing into four tendons to the second, third, fourth, and fifth toes, and lastly the Peronæus tertius. The *Extensor digitorum brevis* produces a rounded outline on the dorsum of the foot and a fulness in front of the lateral malleolus. The *Interossei dorsales* intervene between the metatarsal bones.

At the back of the knee is the popliteal fossa, bounded above by the tendons of the hamstrings and below by the Gastrocnemius. Below this fossa is the prominent fleshy mass of the calf of the leg produced by the Gastrocnemius and Soleus (fig. 1258). When these muscles are in action the borders of the *Gastrocnemius* form two well-defined curved lines which converge to the tendo calcaneus; the medial border is the more prominent. At the same time the edges of the *Soleus* form, on

FIG. 1261.—The mucous sheaths of the tendons round the ankle. Medial aspect. (From a preparation by J. C. B. Grant.)

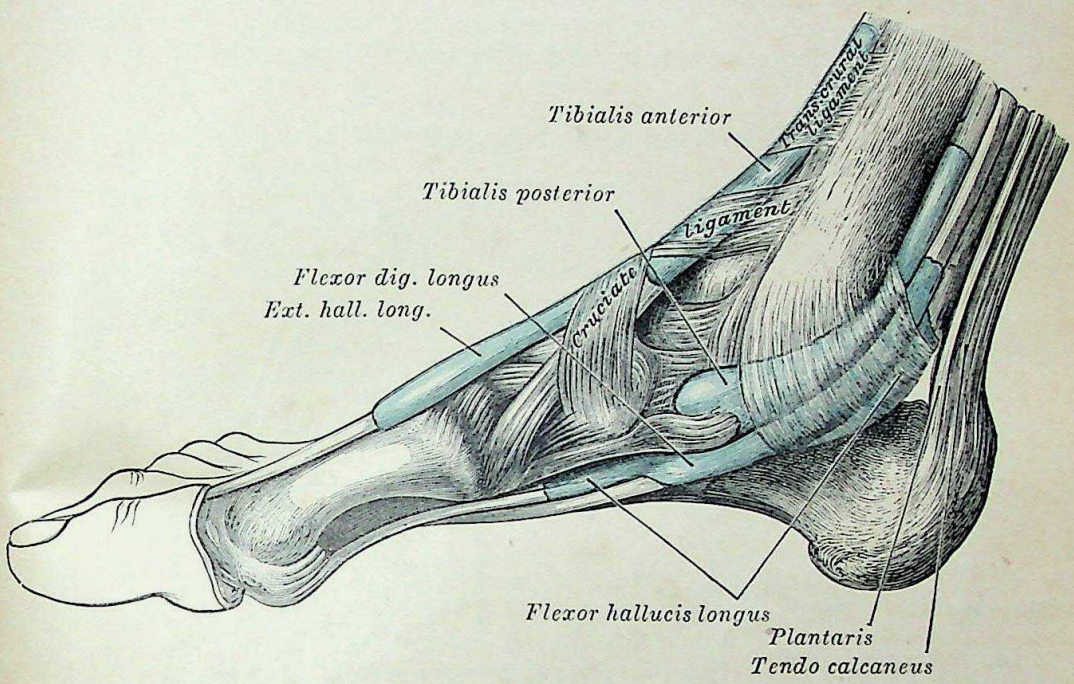

either side of the Gastrocnemius, curved eminences, of which the lateral is the longer. The fleshy mass of the calf ends somewhat abruptly in the tendo calcaneus, which tapers in the upper three-fourths of its extent but widens out slightly below. When the *Tibialis posterior* is in action, its tendon produces a well-defined ridge between the medial border of the lower part of the tibia and the tuberosity of the navicular bone; the tendon may be followed upwards behind the medial malleolus for a distance of about 5 cm.

On the sole of the foot the *Abductor digiti quinti* forms a narrow rounded elevation on the lateral side, and the *Abductor hallucis* a lesser elevation on the medial side. The *Flexor digitorum brevis*, bound down by the plantar aponeurosis, is not very apparent.

The **arteries.**—The *femoral artery* is readily felt as it crosses the brim of the pelvis; in its course down the thigh its pulsation becomes gradually more difficult of recognition. When the knee is flexed the pulsation of the *popliteal artery* can easily be detected in the popliteal fossa.

The *anterior tibial artery* is superficial on the lower part of the front of the tibia and can be traced over the ankle into the *dorsalis pedis artery*; the latter can be followed to the proximal end of the first intermetatarsal space. The pulsation of the *posterior tibial artery* is evident near the lower end of the back of the tibia, and is easily detected behind the medial malleolus.

The **veins.**—By compressing the proximal trunks, the venous arch on the dorsum of the foot and the great and small saphenous veins (pp. 733 to 735) are rendered visible.

CC-0. In Public Domain. Gurukul Kangri Collection, Haridwar

Digitized by Arya Samaj Foundation Chennai and eGangotri

The **nerves.**—The only nerves of the lower extremity which can be located by palpation are (1) the *common peronæal nerve* as it winds round the lateral side of the neck of the fibula, and (2) the *tibial nerve* as it descends behind the lower end of the tibia.

THE SURFACE MARKINGS OF THE LOWER EXTREMITY

The **bony landmarks.**—The anterior superior iliac spine is at the level of the sacral promontory—the posterior at the level of the spinous process of the second sacral vertebra. A horizontal line through the highest points of the iliac crests passes also through the spinous process of the fourth lumbar vertebra, while, as already pointed out (p. 1284), the transtubercular plane through the tubercles on the iliac crests cuts the body of the fifth lumbar vertebra. The upper margin of the greater sciatic notch is opposite the spinous process of the third sacral vertebra, and slightly below this level is the posterior inferior iliac spine. The surface markings of the posterior inferior iliac spine and the ischial spine are in a line which joins

Fig. 1262.—Nélaton's line and Bryant's triangle.

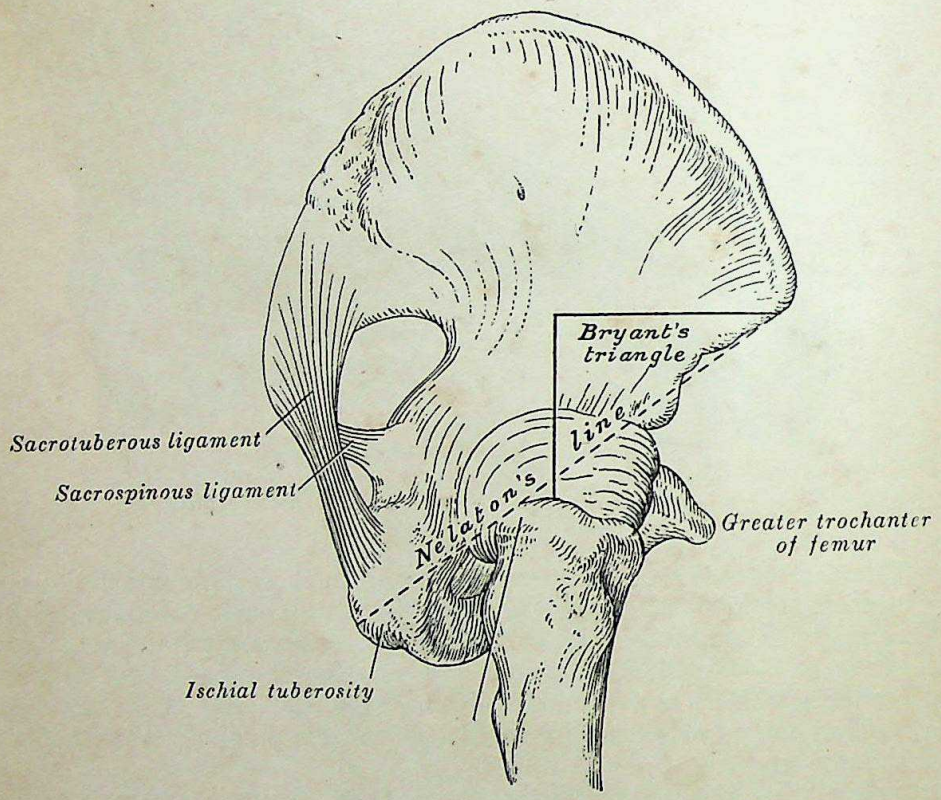

the posterior superior iliac spine to the outer part of the ischial tuberosity; the posterior inferior spine is 5 cm. and the ischial spine 10 cm. below the posterior superior spine; the ischial spine is opposite the first piece of the coccyx.

With the body in the erect posture the line joining the pubic tubercle to the top of the greater trochanter is nearly horizontal; the middle of this line overlies the acetabulum and the head of the femur.

A line used for clinical purposes is that of Nélaton (fig. 1262), which is drawn from the anterior superior iliac spine to the most prominent part of the ischial tuberosity; it crosses the centre of the acetabulum and the upper border of the greater trochanter. Another surface marking of clinical importance is Bryant's triangle, which is mapped out thus: a line from the anterior superior iliac spine to the top of the greater trochanter forms the base of the triangle; its sides are formed respectively by a horizontal line carried backwards from the anterior superior iliac spine and a vertical line from the top of the greater trochanter.

CC-0. In Public Domain. Gurukul Kangri Collection, Haridwar

Digitized by Arya Samaj Foundation Chennai and eGangotri

The **articulations.**—The posterior superior iliac spine overlies the centre of the *sacro-iliac articulation.*

The *hip-joint* may be indicated, as described above, by the centre of a horizontal line drawn from the pubic tubercle to the top of the greater trochanter; or by a point below and slightly lateral to the middle of the inguinal ligament. The *knee-joint* is superficial and requires no surface marking. The level of the *ankle-joint* is that of a transverse line about 1 cm. above the level of the tip of the medial malleolus. If the foot be extended, the head of the talus appears as a

FIG. 1263.—The front of the right thigh, showing the surface markings for the bones, the femoral artery, and the femoral nerve.

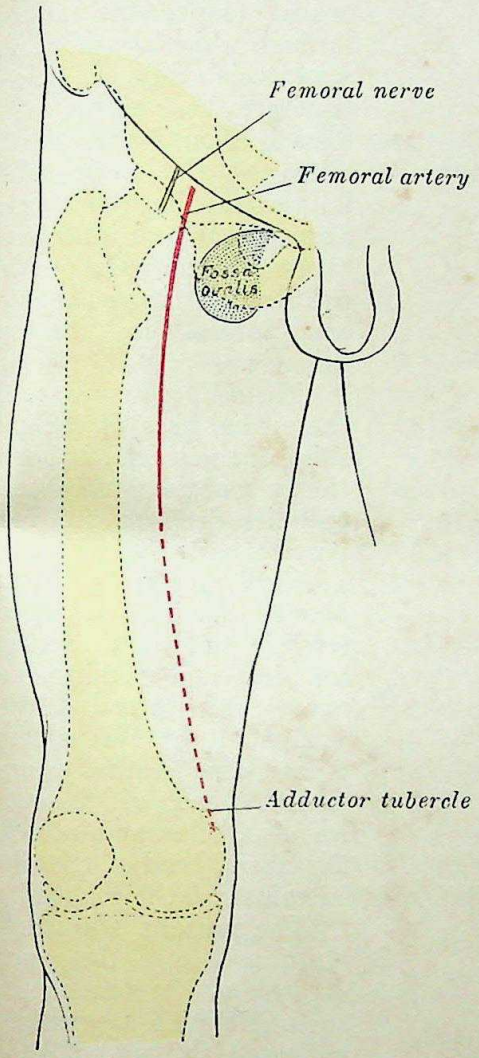

FIG. 1264.—The lateral aspect of the right leg, showing the surface markings for the bones, the anterior tibial and dorsalis pedis arteries, and the deep peronæal nerve.

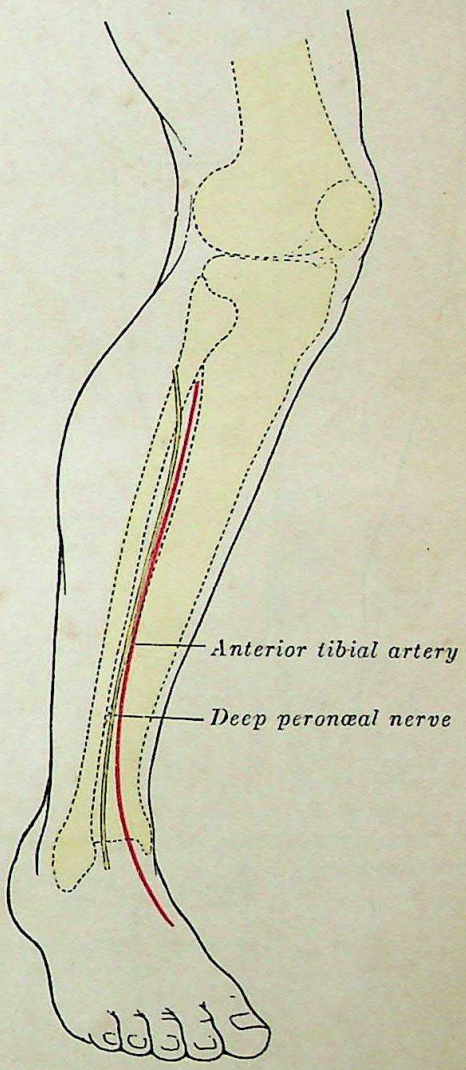

rounded prominence on the medial side of the dorsum; between it and the tuberosity of the navicular is the *talonavicular joint.* The *calcaneocuboid joint* is midway between the lateral malleolus and the prominent base of the fifth metatarsal bone; the line indicating it is parallel to that of the talonavicular joint. The line of the *fifth tarsometatarsal joint* is very oblique; it starts behind the projection of the base of the fifth metatarsal bone, and if continued would pass through the head of the first metatarsal bone. The lines of the *fourth* and *third tarsometatarsal joints* are less oblique. The *first tarsometatarsal joint* corresponds to a groove which can be felt by making firm pressure on the medial border of the foot 2·5 cm. in front of the tuberosity of the navicular; the position of the *second tarsometatarsal joint* is 1·25 cm. behind this. The *metatarsophalangeal joints* are about 2·5 cm. behind the webs of the corresponding toes.

CC-0. In Public Domain. Gurukul Kangri Collection, Haridwar

Digitized by Arya Samaj Foundation Chennai and eGangotri

FIG. 1265.—The back of the left lower extremity, showing the surface markings for the bones, vessels, and nerves.

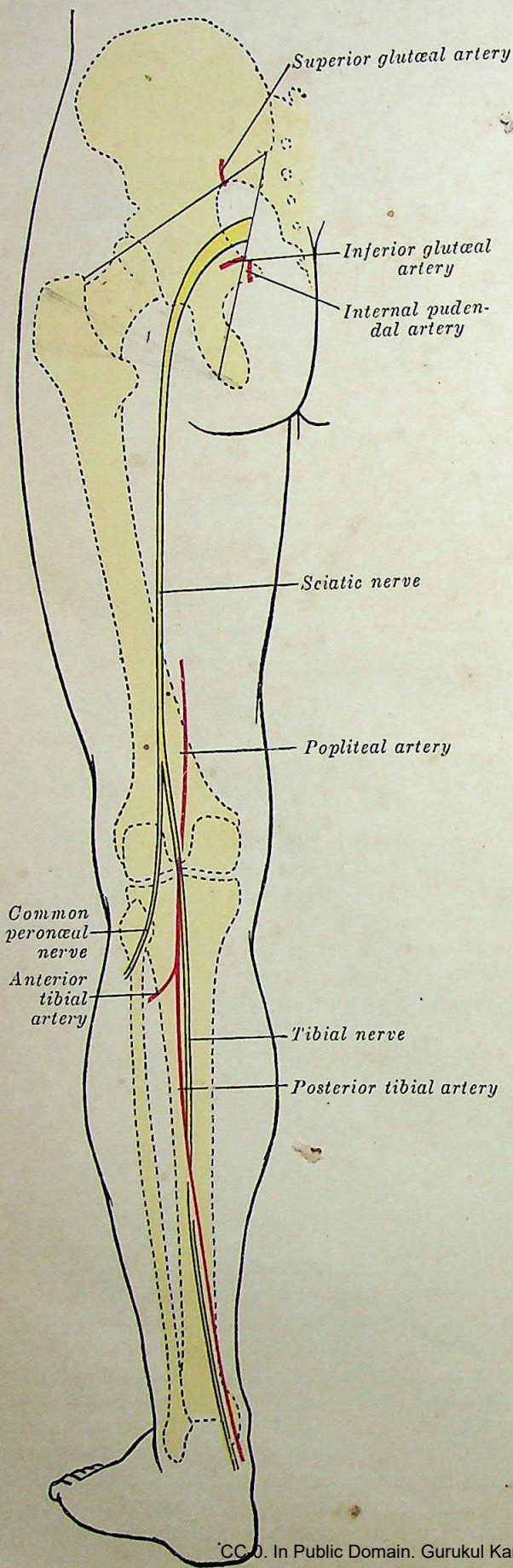

The **muscles.**—The muscles do not require surface lines to indicate them, but there are three intermuscular spaces which must be identified, viz.: the femoral triangle, the adductor canal, and the popliteal fossa.

The *femoral triangle* is bounded above by the inguinal ligament, laterally by the medial border of the Sartorius, and medially by the medial border of the Adductor longus. In the triangle is the fossa ovalis (saphenous opening), through which the great saphenous vein dips to join the femoral; the centre of this fossa is about 4 cm. below and lateral to the pubic tubercle, its vertical diameter measures about 4 cm. and its transverse about 1·5 cm. The centre of the femoral ring is about 1·25 cm. lateral to the pubic tubercle.

The *adductor canal* occupies the medial part of the middle third of the thigh; it begins at the apex of the femoral triangle and lies deep to the vertical part of the Sartorius. The *popliteal fossa* is bounded, above and medially by the tendons of the Semimembranosus and Semitendinosus, above and laterally by the tendon of the Biceps femoris, below and medially by the medial head of the Gastrocnemius, below and laterally by the lateral head of the Gastrocnemius and the Plantaris.

The **mucous sheaths.**—The positions of the mucous sheaths of the tendons round the ankle-joint are sufficiently indicated in figs. 1260, 1261 (see also p. 560).

The **arteries.**—The points of emergence of the three main arteries on the buttock, viz. the superior and inferior glutæal arteries and the internal pudendal artery, may be indicated in the following manner (fig. 1265). With the femur slightly flexed and rotated inwards, a line is drawn from the posterior superior iliac spine to the posterior superior angle of the greater trochanter;

CC-0. In Public Domain. Gurukul Kangri Collection, Haridwar

Digitized by Arya Samaj Foundation Chennai and eGangotri

the point of emergence of the *superior glutæal artery* from the upper part of the greater sciatic foramen corresponds to the junction of the upper with the middle one-third of this line. A second line is drawn from the posterior superior iliac spine to the outer part of the ischial tuberosity; the point of emergence of the *inferior glutæal* and *internal pudendal arteries* from the lower part of the greater sciatic foramen corresponds to the junction of its middle with its lower one-third. The course of the *femoral artery* (fig. 1263) is represented by the upper two-thirds of a line drawn from a point midway between the anterior superior iliac spine and the symphysis pubis to the adductor tubercle of the femur, with the thigh abducted and rotated outwards; the *arteria profunda femoris* rises from the femoral artery about 3 cm. below the inguinal ligament. The course of the upper part of the *popliteal artery* (fig. 1265) is indicated by a line drawn from the lateral margin of the Semimembranosus at the junction of the middle with the lower one-third of the thigh to the middle of the popliteal fossa; from this point it runs vertically downwards to the level of a line drawn through the lower part of the tibial tuberosity. The line indicating the *anterior tibial artery* (fig. 1264) is drawn from the medial side of the head of the fibula to a point midway between the malleoli; the artery begins about 3 cm. below the head of the fibula. The *dorsalis pedis artery* is represented by a line drawn from a point midway between the malleoli to the proximal end of the first intermetatarsal space.

The course of the *posterior tibial artery* (fig. 1265) can be shown by a line drawn from the end of the popliteal artery, i.e. 2·5 cm. below the centre of the popliteal fossa, to midway between the tip of the medial malleolus and the medial margin of the tendo calcaneus; its main branch, the *peronæal artery*, begins about 7 or 8 cm. below the level of the knee-joint and follows the line of the fibula to the back of the inferior tibio-fibular joint. The *medial* and *lateral plantar arteries* begin from the end of the posterior tibial; the medial extends to the middle of the ball of the great toe, the lateral to a finger's breadth medial to the tuberosity of the fifth metatarsal bone; from this latter point the *plantar arch* crosses the foot to the proximal end of the first intermetatarsal space.

The **veins.**—The line of the *great saphenous vein* is drawn from the front of the medial malleolus along the medial margin of the tibia to the adductor tubercle, and thence to the centre of the fossa ovalis (saphenous opening); the *small saphenous vein* runs upwards from the back of the lateral malleolus to the centre of the popliteal fossa.

The **nerves.**—When the thigh is rotated outwards the course of the *sciatic nerve* (fig. 1265) can be indicated by a line drawn from a point about midway between the outer border of the ischial tuberosity and the posterior superior angle of the greater trochanter to the upper angle of the popliteal fossa. The continuation of this line vertically through the centre of the popliteal fossa represents the position of the upper part of the *tibial nerve*, while the *common peronæal nerve* follows the line of the tendon of the Biceps femoris. The line for the *deep peronæal nerve* corresponds with that of the anterior tibial artery, and the line for the lower part of the *tibial nerve* to that of the posterior tibial artery.

CC-0. In Public Domain. Gurukul Kangri Collection, Haridwar

Digitized by Arya Samaj Foundation Chennai and eGangotri

INDEX

Abdomen, 1130
abdomen, proper, 1132
pelvis, 1133
anterolateral muscles of, 469
boundaries of, 1132
fasciæ of, 469
lymph-glands of, 763
parietal, 763
visceral, 765
lymphatic vessels of, 768
posterior muscles of, 481
regions of, 1132
surface anatomy of, 1281
lines of, 1283
veins of, 737
Abdominal aorta, 665
applied anatomy of, 666
branches of, 666
surface marking of, 1281
aortic plexus, 981
muscles, 469
ostium of uterine tube, 1230
part of œsophagus, 1129
portion of sympathetic system, 977
pregnancy, 47
ring, external, 472
inguinal, 480
internal, 480
Abducent nerve, 906
applied anatomy of, 907
nucleus of, 813
Abductor digiti quinti,
of hand, 526
of foot, 563
hallucis, 562
indicis, 526
pollicis brevis, 523
longus, 516
applied anatomy of, 518
Abernethy, fascia of, 531
Aberrant ducts of epididymis, 1217
ganglia, 926
Abnormalities of reflex action, 876
Abscess, alveolar, 1111
ischiorectal, 486, 1176
lumbar, 533
perinephric, 1200
psoas, 532
retropharyngeal, 449, 1127
superior pelvirectal, 1176
tropical of liver, 745, 1191
Accessory nerve, 912
applied anatomy of, 922
cerebral part of, 922
spinal part of, 922
surface marking of, 1272
cephalic vein, 726
glands of mouth, 1101
hemiazygos vein, 731
lacrimal glands, 1018
Accessory opening
of maxillary sinus, 266, 992
organs of digestive tube, 1093
organs of the eye, 1010
pancreatic duct, 1180
part of parotid gland, 1096
plantar ligaments, 430
processes of vertebræ, 174
renal arteries, 674, 1199
saphenous vein, 734
sinuses of the nose, 991
applied anatomy of, 992
spleens, 1254
suprarenal glands, 1251
tectorial membrane, 1046
thyreoid glands, 1245
volar ligaments, 396
Acetabular fossa, 311
ligament, transverse, 406
notch, 311
Acetabulum, 311
Achromatic spindle, 2
Acoustic meatus, external, 212, 1024
applied anatomy of, 214, 1026
development of, 108
lymphatic vessels of, 754
primary, 108
secondary, 108
Acoustic meatus, internal, 210, 264
nerve, 913, 1046
applied anatomy of, 915
development of, 108
nuclei of, 813, 914
Acromegaly, 840
Acromioclavicular articulation, 376
applied anatomy of, 377
movements of, 377
surface anatomy of, 1294, 1298
ligament, 376
Acromion, 276
fracture of, 528
Acrosome of spermatozoon, 44
Actions of valves of heart, 591
Acute margin of heart, 580
Adams-Stokes' syndrome, 591, 715
Addison's disease, 14
Adductor brevis, 539
canal, 689, 1310
hallucis, 565
longus, 539
applied anatomy of, 539
magnus, 539
minimus, 539*
pollicis, 524
tubercle, 321
Adenoids, 1127
Aditus ad antrum, 1030
laryngis, 1066
Adminiculum lineæ albæ, 473, 480
Adrenalin, 1252
Adventitious dentine, 1106
Afferent lymphatic vessels, 746
nerves, 781
vessels of kidney, 1197
After-birth, 67
Age changes in larynx, 1059
in mandible, 244
in maxilla, 235
in skull, 267
Ageusia, 903
Agger nasi, 233, 987
Aggregated lymphatic nodules, 1160
Air passages, applied anatomy of, 1076
Air sinuses, 164
accessory of nose, 911
ethmoidal, 221, 265, 266, 991
frontal, 219, 991, 1264
mastoid, 209, 1030
maxillary, 231, 992, 1264
sphenoidal, 201, 991
Akanthion, 269
Ala cinerea, 825
of ilium, 307
lobuli centralis, 815
sacralis, 176
Alæ magnæ, 202
nasi, 984
parvæ, 203
of vomer, 227
Alar cartilages of nose, 985
folds of synovial stratum of knee-joint, 411
lamina, 85
ligaments, 367
processes of ethmoidal bone, 220
thoracic artery, 648
Albinism, 14
Alcock's canal, 483
Alimentary canal, 1092
Allantoic vessels, 58*
Allantois, 58
Alveolar arch, 233
abscess, 1111
artery, anterior superior, 620
inferior, 619
posterior superior, 619
canals, 230, 232, 253
index, 271
nerve, inferior, 902
nerves, superior, 896, 897
part of mandible, 241
point, 269
process of maxilla, 233
Alveoli, formation of, for teeth, 1110

CC-0. In Public Domain. Gurukul Kangri Collection, Haridwar

Digitized by Arya Samaj Foundation Chennai and eGangotri

Alveoli of lungs, 1089
Alveus, 857, 863, 871
Amacrine cells of retina, 1004
Ameloblasts, 1107
Amitosis, 2
Amnion, 60
false, 60*
Amniotic cavity, 49, 60
ectoderm, 60
fold, 60*
Amphiarthroses, 353
symphysis, 353
syndesmosis, 353
Ampulla of ductus deferens, 1216
rectal, 1168
of uterine tube, 1230
of Vater, 1190
Ampullæ of lacrimal ducts, 1019
of semicircular canals, 1037
of semicircular ducts, 1037
of tubuli lactiferi, 1242
Amputations of foot, 349
Anæsthesia, spinal, 884
Anal canal, 1169
development of, 142
lymphatic vessels of, 771
fascia, 483, 485
orifice, 1170
pit, 142
region, muscles of, 486
valves, 1170
Anaphase of karyokinesis, 2
Anastomoses of arteries, 595
Anastomosis around elbow-joint, 652
around knee-joint, 699
Anastomosis, cruciate, 694
Anastomotic vein of Labbé, 716
of Trolard, 716
Anastomotica magna of brachial artery, 652
of femoral artery, 695
Anatomical neck of humerus, 282
Anconæus, 515
Angina pectoris, 600
Angioblast, 109
Angiology, 569
Angle, anterior of rib, 190
inferior lateral of sacrum, 176
iridial or filtration, 995
of Louis, 185*
of mandible, 242, 257
of mouth, 1094
parietal, of sphenoidal bone, 203
pubic, 311
of rib, 190
sacrovertebral, 174
sternal, 185
subcostal, 194
Angles or canthi of eyelids, 1016
Angular artery, 614
gyrus, 848
movement, 354
vein, 710
Angulus Ludovici, 185
Animal cell, 1
Ankle-joint, 420
applied anatomy of, 424
fascia around, 558
movements of, 423
relations of tendons and vessels to, 423
surface anatomy of, 1305
marking of, 1309
Annular ligament of ankle, anterior, 558, 559
external, 560
internal, 560
of base of stapes, 1033
of proximal radio-ulnar joint, 387
of wrist, anterior, 518
posterior, 519
plexus of cornea, 997
Annulus fibrosus, 359
ovalis, 582
stapedis, 108
tendineus communis, 1011
Anococcygeal body, 1170
nerves, 967
raphe, 485, 487
Anorchism, 1215
Anosmia, 887
Ansa hypoglossi, 925, 934
lentiformis, 858, 860
subclavia (Vieussenii), 975
Anterolateral fasciculus, superficial, 795
muscles of abdomen, 469
Anteroposterior diameters of pelvis, 313, 314
Antibrachial fascia, 507
cutaneous nerve, dorsal, 945
lateral, 939
medial, 939
interosseous membrane, 388
muscles, dorsal, 513
volar, 507
vein, median, 727
Anticlinal vertebra, 170*
Antihelix, 1022
Antitragicus, 1024
Antitragus, 1022
Antrum cardiacum, 1129, 1146
folliculi, 1228
of Highmore, 231, 992
applied anatomy of, 232
mastoid, 103, 209
tympanic, 209, 1030
entrance to, 1030
Anus, 1170
lymphatic vessels of, 771
Aorta, 597
abdominal, 665
applied anatomy of, 666
branches of, 666
coarctation of, 661
surface marking of, 1289
arch of, 600
applied anatomy of, 601, 661
branches of, 602
peculiarities of, 601
ascending, 598
branches of, 598
bulb of, 598
descending, 661
thoracic, 661
applied anatomy of, 663
branches of, 663
nerve-plexus of, 981
Aortæ, dorsal, 121
primitive, 110, 120
ventral, 120
Aortic arches, 111, 120, 121
bodies, 101, 1249
structure of, 1249
hiatus in diaphragm, 466
isthmus, 121, 601
lymph-glands, 764
orifice, 586
semilunar valves, 586
Aortic sinuses, 587
spindle, 601
vestibule, 586
Aorticorenal ganglion, 979
Aortopulmonary septum, 117
Ape-like hand, 947
Apertura piriformis, 266
tympanica canaliculi chordæ, 1027
Aperture, anterior nasal, 256, 266
inferior of pelvis, 314
superior, 313
posterior nasal, 266
Apertures in diaphragm, 466
Apex of fibula, 331
of heart, 579
of nose, 984
of sacrum, 176
Aponeuroses, 435
Aponeurosis, epicranial, 437
glutæal, 542
lumbar, 457
of obliquus externus abdominis, 471
palatine, 1120
palmar, 521
plantar, 561
suprahyoid, 451
Aponeurotic falx, inguinal, 476
Apoplexy, 872
Apparatus, digestive, 1092
development of, 132
excretory of liver, 1188
lacrimal, 1018
respiratory, 1059
development of, 145
reticular, of Golgi, 2
urogenital, 1191
Appendages of skin, 1054
hairs, 1055
nails, 1054
sebaceous glands, 1057
sudoriferous or sweat-glands, 1057
of testis and epididymis, 1212
Appendices epiploicæ, 1144, 1162, 1170
vesiculosæ, 1230
Appendicular artery, 672
part of skeleton, 163
Appendix of epididymis, 1212
of testis, 1212
of ventricle of larynx, 1068
vermiform, 1164
lymphatic vessels of, 770
Applied Anatomy of—
abdominal aorta, 666
abducent nerve, 907
abductor pollicis longus, 518
accessory nerve, 922
acoustic nerve, 915
acromioclavicular joint, 377
adductor longus, 539
air-passages, 1076
ankle-joint, 424
anterior facial vein, 710
anterior tibial artery, 701
antrum of Highmore, 232
arch of aorta, 601
arches of foot, 432
arteries, 595
atrioventricular bundle, 591

CC-0. In Public Domain. Gurukul Kangri Collection, Haridwar

Digitized by Arya Samaj Foundation Chennai and eGangotri

Applied Anatomy of—
auditory tube, 1035
auricula or pinna, 1026
axilla, 496, 643
axillary artery, 645
fascia, 496
lymph-glands, 759
nerve, 947
vein, 737
azygos veins, 731
biceps brachii, 505
bile-duct, 1191
bladder, urinary, 1207
bone, 25
bones of foot, 349
of forearm, 294, 529
of hand, 306
of leg, 333, 568
of pelvis, 317
of skull, 271
brachial artery, 649
plexus, 946
brain, 876
bulb of eye, 1008
cardiac septa, 118
carotid artery, common, 607
external, 609
internal, 625
carpal bones, 306
cavernous sinus, 722
cerebellum, 822
cerebrospinal fluid, 883
cervical fascia, 449
lymph-glands, 757
plexus, 934, 935
ribs, 195
chorioid, 1009
circumflex nerve, 947
clavicle, 281, 527
coccyx, 317
colon, 1175
common carotid artery, 607
iliac artery, 678
peronæal nerve, 969
conjunctiva, 1021
cornea, 1008
coronary arteries, 600
coxal articulation, 409
cranial bones, 229
cubital articulation, 409
deep cervical fascia, 449
deltoideus, 501
descending palatine artery, 620
descent of testes, 156
diaphragm, 468
dorsalis pedis artery, 703
duodenum, 1172
elbow-joint, 389
emissary veins, 724
epigastric artery, inferior, 687
extensor tendons of interphalangeal joints, 398
extensor tendons of thumb, 518
external acoustic meatus, 1026
carotid artery, 609
ear, 1026
iliac artery, 685
jugular vein, 713
maxillary artery, 614
eyelids, 1020
facial artery, 614
nerve, 912

Applied Anatomy of—
facial vein, anterior, 710
fascia colli, 449
fascia of axilla, 496
of psoas and iliacus, 532
femoral artery, 691
nerve, 967
femur, 326, 566
fertilized ovum, 47
fibula, 333, 568
filtration angle of eye, 1009
flexor sheaths of fingers, 523
foot, bones of, 349
joints of, 432
forearm, bones of, 294
gall-bladder, 1191
ganglia on posterior nerve-roots, 799
gastrocnemius, 558
glutæal arteries, 685
gums, 1094
hæmorrhoidal venous plexus, 739
hamstring tendons, 548
hand, bones of, 306
hare-lip, 82
heart, 591
hip-joint, 409
humeral articulation, 382
humerus, 286, 528
hypogastric artery, 678
hypoglossal nerve, 925
hypophysis, 840
iliac artery, common, 678
external, 686
internal, 678
iliac fascia, 533
inferior epigastric artery, 687
inferior vena cava, 740
inguinal and subinguinal glands, 762
innominate artery, 603
intercostal arteries, 664
nerves, 951
internal capsule, 872
carotid artery, 625
ear, 1048
iliac artery, 678
jugular vein, 714
mammary artery, 640
interphalangeal joints, 398
intervertebral fibrocartilages, 359
intestine, large, 1175
small, 1172
iris, 1009
ischiorectal fossa, 486
jugular vein, external, 713
internal, 714
kidneys, 1199
knee-joint, 419, 548
labyrinth of ear, 1048
lacrimal apparatus, 1022
laryngeal nerves, 921
larynx, 1076
leg, bones of, 333
lens, 1009
lienal (splenic) artery, 669
ligamentous action of muscles, 355
lingual artery, 612
liver, 1190
long thoracic nerve, 947
lumbar plexus, 967
lungs, 1091

Applied Anatomy of—
lymph-glands and lymphatic vessels, 748
mamma, 1242
mandible, 273
mandibular joint, 357
maxillary air-sinus, 232
median cubital vein, 727
nerve, 947
mediastinal cavity, 1084
medulla oblongata, 811
spinalis, 798, 876
meninges, 883
mesenteric arteries, 673
lymph-glands, 767
metacarpal bones, 306
metatarsal bones, 349, 431
metatarsophalangeal joint of great toe, 431
middle meningeal artery, 618
motor and sensory neurons, 877
muscles, 434
of bulb of eye, 1015
of leg, 558
of lower extremity, 566
of upper extremity, 527
musculospiral nerve, 947
nose and nasal cavities, 992
obturator nerve, 968
ocular muscles, 1015
oculomotor nerve, 891
œsophagus, 1130
olfactory nerves, 887
optic nerve, 889
ovary, 1229
palate, 82, 1095
palmar arches, 661
aponeurosis, 523
pancreas, 1181
parametrium, 1237
parathyreoid glands, 1247
parotid glands, 1101
patella, 334, 568
pelvic diaphragm, 486
pelvis, 317
penis, 1223
pericardium, 576
peritoneal fossæ, 1146
peronæal nerve, common, 968, 969
phalanges, 306
pharynx, 1127
phrenic nerve, 935
pigment, 14
pineal body, 837
pituitary body, 840
placenta, 66
plantar arch, 707
plantar calcaneonavicular ligament, 427
plantaris, 558
pleura, 1080
pons, 814
popliteal artery, 897
lymph-glands, 762
portal system of veins, 744
posterior tibial artery, 704
pronator teres muscle, 508
prostate, 1225
prostatic venous plexus, 739
psoas major muscle, 532
pulmonary artery, 596
quadriceps femoris muscle, 537

CC-0. In Public Domain. Gurukul Kangri Collection, Haridwar

Digitized by Arya Samaj Foundation Chennai and eGangotri

Applied Anatomy of—
radial artery, 654
nerve, 947
radiocarpal joint, 395
radio-ulnar joints, 389
radius, 295, 390, 529
recti muscles of eye, 1015
rectum, 1176
rectus femoris, 537
retina, 1009
ribs, 194
salivary glands, 1101
saphenous veins, 735
sartorius, 535
scalp, 437
scapula, 279
sciatic (inferior glutæal) artery, 685
nerve, 968, 969
sclera, 1008
scrotum, 1220
septum of tongue, 1117
serratus anterior, 500
sheath of psoas muscle, 532
sheath of rectus abdominis, 478
shoulder-joint, 382
skull, 271
small intestine, 1172
spermatic plexus, 981
veins, 741
sphenoidal bone, 206
spinal cord, 798
ganglia, 799
spleen, 1256
splenic or lienal artery, 669
sternoclavicular joint, 375
sternocleidomastoideus, 451
sternum, 194
stomach, 1153
subclavian artery, 634
superior thyreoid artery, 610
sagittal sinus, 718
vena cava, 731
suprarenal glands, 1252
sutural bones, 229
sympathetic nervous system, 982
tarsal bones, 349
joints, 428
teeth, 1111
temporal artery, superficial, 616
tendons of leg and foot, 558
testicular veins, 741
testis, 1215
thoracic aorta, 663
duct, 750
nerves, 951
thorax, 194
thymus, 1249
thyreoid artery, superior, 610
gland, 1245
tibia, 333, 568
tibial artery, anterior, 701
posterior, 704
tongue, 1118
palatine tonsils, 1119
trachea, 1076
tracheobronchial glands, 777
triceps brachii, 507

Applied Anatomy of—
trigeminal nerve, 903
trochlear nerve, 892
tympanic cavity, 1034
ulna, 294, 529
ulnar artery, 657
nerve, 947
ureter, 1202
urethra, 1210
urinary bladder, 1207
uterine tube, 1230
uterus, 1237
vagus nerve, 921
veins in front of elbow, 727
vena cava, inferior, 740
superior, 731
vermiform process, 1172
vertebral column, 184, 359, 367
vesiculæ seminales, 1218
volar arches, 661
Wormian bones, 229
wrist-joint, 395
Aquæductus cochleæ, 212, 1038
Fallopii, 211, 1030
vestibuli, 211, 264, 1036
Aqueduct, cerebral, 831
of Sylvius, 831
Aqueous humour, 1006
Arachnoid, cerebral, 881
spinal, 881
structure of, 881
Arachnoideal granulations, 882
structure of, 882
Arantii, corpus, 585, 587
ligamentum venosum, 1186
Arbor vitæ cerebelli, 817
uteri, 1233
Arc, longitudinal, of skull, 270
Arch, alveolar, 233
of aorta, 600
axillary, 495, 645
carotid, 121
of cricoid cartilage, 1062
dorsal venous, 733
glossopalatine, 1118
hyoid, 77
lumbocostal, lateral, 465
medial, 465
mandibular, 76
nasal, 710
palmar, deep, 656
superficial, 660
pharyngopalatine, 1118
plantar, 706
cutaneous venous, 734
pubic, 314
tendinous, of pelvic fascia, 484
venous jugular, 712
vertebral, 164
volar, deep, 656
superficial, 660
zygomatic, 252
Archenteron, 49
Arches, aortic, 111, 120, 121
branchial, 76
cortical, of kidney, 1196
of fauces, 1118
of foot, 431
primitive costal, 70
superciliary, 217, 247, 251, 256
visceral, 76
Arcuate artery, 703
fibres, external, 808
internal, 805

Arcuate fibres of cerebellum, 819
ligaments of diaphragm, 465
line of ilium, 306
nucleus, 808
popliteal ligament, 413
pubic ligament, 400
Arcus parieto-occipitalis, 848
Area acustica, 825
auditopsychic, 871
auditosensory, 871
facialis, 211
for heat, cold, and pain, 871
for muscular sense, 871
for sense of smell, 871
for sense of taste, 871
for tactile sense, 871
motor, 870
oval, of Flechsig, 797
parolfactory of Broca, 852
pericardial, 50
postrema, 825
striata, 871
vasculosa, 109
vestibularis inferior, 211
superior, 211
visuopsychic, 871
visuosensory, 871
Areas of Cohnheim, 30
associational, 871
Areola of mamma, 1241
Areolæ of bone, primary, 23
secondary, 23
Areolar glands, 1241
Argyll-Robertson pupil, 877
Arm, fascia of, 503
muscles of, 503
Arnold, canaliculus innominatus of, 203*
nerve of, 919
Arrectores pilorum, 32, 1057
Arteria anastomotica magna, of arm, 652
of thigh, 695
anonyma, 602
centralis retinæ, 626, 1005
cervicalis profunda, 642
comitans nervi ischiadici, 682
nervi phrenici, 640
dorsalis hallucis, 703
pedis, 702
applied anatomy of, 703
scapulæ, 647
femoris, 687
hyaloidea, 104, 1007
intercostalis suprema, 642
magna hallucis, 707
mediana, 123, 658
pancreatica magna, 669
princeps cervicis, 614
pollicis, 656
profunda brachii, 651
femoris, 693
linguæ, 611
transversa colli, 642
volaris indicis radialis, 656
Arterial circle of Willis, 630
mesocardium, 576
Arteriæ propriæ renales, 1199
Arterioles, 569
Arteriosclerosis, 595
Artery or Arteries—
abdominal aorta, 665
accessory pudendal, 682
meningeal, 619
renal, 674, 1199
alar, of nose, 614
thoracic, 648

CC-0. In Public Domain. Gurukul Kangri Collection, Haridwar

Digitized by Arya Samaj Foundation Chennai and eGangotri

Artery or Arteries (*cont.*)
alveolar, anterior superior, 620
inferior, 619
posterior superior, 619
anastomoses of, 595
anastomosis cruciate, 694
around the elbow-joint, 652
around the knee-joint, 699
anastomotica magna, of brachial, 652
of femoral, 695
angular, 614
anterior cerebral, 629
chorioidal, 630
ciliary, 627
communicating, 629
ethmoidal, 627
humeral circumflex, 647
inferior cerebellar, 638
lateral malleolar, 702
medial malleolar, 701
mediastinal, 640
meningeal, 626, 628
spinal, 637
superior alveolar, 620
tibial, 700
recurrent, 701
tympanic, 618
anterolateral ganglionic, 630
anteromedial ganglionic, 629
aorta, 597
abdominal, 665
arch of, 600
ascending, 598
descending, 661
thoracic, 661
appendicular, 672
applied anatomy of, 595
arcuate, 703
arteriosclerosis of, 595
articular, of knee, 698, 699
ascending cervical, 641
palatine, 612
pharyngeal, 610
auditory, internal, 638, 1048
auricular, anterior, 616
deep, 618
of occipital, 615
posterior, 615
axillary, 644
azygos articular of knee, 699
of vagina, 680
basilar, 637
brachial, 648
of brain, 631
cortical system, 631
ganglionic system, 631
bronchial, 663, 1091
of innominate, 602
buccinator, 619
cæcal, of ileocolic, 672
calcaneal, lateral, 705
medial, 705
caroticotympanic, 626
carotid, common, 605
external, 609
internal, 623
carpal, dorsal, 656, 660
volar, 655, 660
carpal network, dorsal, 655
volar, 656
cavernous, 626
central, of retina, 1005

Artery or Arteries (*cont.*)
cerebellar, anterior inferior, 638
posterior inferior, 637
superior, 638
cerebral, anterior, 629
middle, 629
posterior, 638
of cerebral hæmorrhage, 630, 872
cervical, ascending, 641
superficial, 642
transverse, 642
cervicalis profunda, 642
chorioidal, anterior, 630
posterior, 638
ciliary, 627
circle of Willis, 630
circulus arteriosus major, 627
minor, 672
circumflex, anterior humeral, 647
external, 693
internal, 693
lateral femoral, 693
medial femoral, 694
posterior humeral, 647
scapular, 647
superficial iliac, 693
coccygeal, of inferior glutæal, 682
cœliac, 666
colic, left, 672
of ileocolic, 672
middle, 672
right, 672
collateral circulation, 595
intercostal, 664
comitans nervi ischiadici, 682
nervi phrenici, 640
common carotid, 605
iliac, 676
interosseous, 658
volar digital, 661
communicating, anterior, 629
of dorsalis pedis, 703
of peroneal, 705
posterior, 630
of posterior tibial, 705
coronary, of heart, 598, 599
of lips, 614
of corpus cavernosum penis, 681
cortical arteries of brain, 631
costocervical, 642
cremasteric, 686, 1219
cricothyreoid, 610
cruciate anastomosis, 694
cystic, 669
deep auricular, 618
cervical, 642
epigastric, 686
external pudendal, 693
iliac circumflex, 687
palmar arch, 656
of penis, 681
plantar, 703
temporal, 619
volar branch of ulnar, 660
dental, inferior, 619
posterior, 619
descending aorta, 661
branch of occipital, 615
palatine, 620
development of, 119
digital, volar, 661
distribution of, 595
dorsal carpal of radial, 656

Artery or Arteries (*cont.*)
dorsal carpal of ulnar, 660
interosseous, 659
metacarpal, 656
first, 656
metatarsal, 703
first, 703
plantar, 707
first, 703
nasal, 626, 628
of penis, 682
segmental, 122
dorsales linguæ, 611
dorsalis hallucis, 703
pedis, 702
scapulæ, 647
of ductus deferens, 679, 1219
end, 595
epigastric, deep or inferior, 686
superficial, 693
superior, 640
ethmoidal, 627
external carotid, 609
circumflex, 693
iliac, 685
mammary, 647
maxillary, 612
plantar, 706
pudendal, deep, 693
superficial, 693
spermatic, 686
facial, 612
transverse, 616
femoral, 687
circumflex, lateral, 693
medial, 694
fibular, 705
first dorsal metacarpal, 656
dorsal metatarsal, 703
plantar metatarsal, 703
frontal, 626, 628
of superficial temporal, 616
ganglionic of brain, anterolateral, 630
anteromedial, 629
posterolateral, 631, 638
posteromedial, 630, 638
gastric, left, 667
right, 668
short, 669
gastroduodenal, 668
gastro-epiploic, right, 668
left, 669
genicular, highest, 695
inferior, 699
middle, 699
superior, 698
glomerular, of kidney, 1199
glutæal, inferior, 682
superior, 684
greater palatine, 620
hæmorrhoidal, inferior, 681
middle, 679
superior, 672
of head and neck, 605
helicine, 1222
hepatic, 667, 1188
highest genicular, 695
thoracic, 646
humeral circumflex, anterior, 647
posterior, 647
hyaloid, 104, 1007
hyoid, 610, 611
hypogastric, 592, 594, 678

CC-0. In Public Domain. Gurukul Kangri Collection, Haridwar

Digitized by Arya Samaj Foundation Chennai and eGangotri

Artery or Arteries (*cont.*)
hypophysial, 626
ileal of ileocolic, 672
of superior mesenteric, 670
ileocolic, 672
iliac, common, 676
external, 685
internal, 678
iliac branches of obturator, 680
iliac circumflex, deep, 687
superficial, 693
iliolumbar, 682
inferior alveolar, 619
articular of knee, 699
coronary, 614
dental, 619
epigastric, 686
genicular, 699
glutæal, 682
hæmorrhoidal, 681
labial, 614
laryngeal, 641
mesenteric, 672
pancreaticoduodenal, 670
phrenic, 675
profunda, 652
suprarenal, 674
thyreoid, 640
inferior tympanic, 610
ulnar collateral, 652
vesical, 679
infra-orbital, 620
infrascapular, 647
innominate, 602
intercostal of thoracic aorta, 663
anterior rami of, 663
posterior rami of, 664
of internal mammary, 640
superior, 642
intercostalis suprema, 642
interlobular, of kidney, 1199
internal auditory, 638, 1048
carotid, 623
circumflex, 694
iliac, 678
mammary, 638
maxillary, 616
plantar, 706
pudendal, in male, 681
in female, 682
spermatic, 674
interosseous, common, 658
dorsal, 659
recurrent, 660
volar, 658
intralobular, of kidney, 1199
jejunal, 670
labial, inferior, 614
superior, 614
of labyrinth, 1048
lacrimal, 626
laryngeal, inferior, 641
superior, 610
lateral calcaneal, 705
femoral circumflex, 693
malleolar network, 702
nasal, 614
posterior, 620
palpebral, 626
plantar, 706
sacral, 684
segmental, 121
striate, 630
tarsal, 703
thoracic, 647

Artery or Arteries (*cont.*)
left colic, 672
gastric, 667
gastro-epiploic, 669
lienal, 669
of limbs, development of, 123
lingual, 611
long posterior ciliary, 627
thoracic, 647
of lower extremity, 687
lumbar, 676
magna hallucis, 707
malleolar, anterior lateral, 702
anterior medial, 701
external, 702
internal, 701
posterior medial, 705
mammary branches of intercostal arteries, 664
mammary, external, 647
internal, 638
masseteric, 619
mastoid, 615
maxillary, external, 612
internal, 616
medial calcaneal, 705
femoral circumflex, 694
malleolar, anterior, 701
posterior, 703
malleolar network, 702
palpebral, 628
plantar, 706
striate, 630
tarsal, 703
mediana, 123, 659
mediastinal, from aorta, 663
from internal mammary, 640
medullary, of vertebral, 637
meningeal, accessory, 619
anterior, 626, 628
anterior, of internal carotid, 626
of ascending pharyngeal, 611
middle, 618, 1264
of occipital, 615
of ophthalmic, 628
posterior, 611
recurrent, from lacrimal, 627
of vertebral, 636
mesenteric, inferior, 672
superior, 669
metacarpal, dorsal, 656
volar, 656
metatarsal, 703, 707
middle cerebral, 629
colic, 672
genicular, 699
hæmorrhoidal, 679
meningeal, 618
sacral, 676
suprarenal, 674
temporal, 616
mode of division of, 595
of origin of branches, 595
musculophrenic, 640
mylohyoid, 619
nasal, dorsal, 626, 628
lateral, 614
posterior, 620
nerves of, 571
nutrient, of bone, 19
obturator, 680
occipital, 614
of posterior auricular, 616

Artery or Arteries (*cont.*)
œsophageal, of inferior thyreoid, 641
of aorta, 663
ophthalmic, 626
ovarian, 674
palatine, ascending, 612
descending, 620
greater, 620
smaller, 620
palmar arch, deep, 656
superficial, 660
palpebral, lateral, 626
medial, 628
pancreatic, 669
pancreatica magna, 669
pancreaticoduodenal, inferior, 670
superior, 668
parietal, of superficial temporal, 616
of penis, deep, 681
dorsal, 682
perforating, of foot, 706
of arteria profunda femoris, 695
of hand, 656, 661
of internal mammary, 640
of peronæal, 705
pericardial, 640, 663
pericardiacophrenic, 640
perinæal, 681
transverse, 681
peronæal, 705
petrosal, superficial, 618
pharyngeal, ascending, 610
of internal maxillary, 620
phrenic, inferior, 675
superior, 663
plantar arch, 706
deep, 703
lateral (external), 706
medial (internal), 706
metatarsal, 707
pontine, 638
popliteal, 696
posterior auricular, 615
cerebral, 638
ciliary, 627
communicating, 630
dental, 619
ethmoidal, 627
humeral circumflex, 647
inferior cerebellar, 637
lateral nasal, 620
medial malleolar, 705
meningeal, from ascending pharyngeal, 611
from vertebral, 626
scapular, 642
scrotal, 681
septal, 620
spinal, 637
superior alveolar, 619
tibial, 703
recurrent, 701
posterolateral ganglionic, 638
posteromedial ganglionic, 638
princeps cervicis, 615
pollicis, 656
profunda brachii, 651
cervicalis, 642
femoris, 693
inferior, 652
linguæ, 611
superior, 651
proper volar digital, 661
of pterygoid canal, 620, 626

CC-0. In Public Domain. Gurukul Kangri Collection, Haridwar

Digitized by Arya Samaj Foundation Chennai and eGangotri

Artery or Arteries (*cont.*)
pudendal, accessory, 682
deep external, 693
internal, 680
in female, 682
in male, 681
superficial external, 693
pulmonary, 595
pyloric, 668
radial, 653
recurrent, 655
ramus descendens of occipital, 614
ranine, 611
recurrent of hand, 656
interosseous, 660
radial, 655
tibial, anterior, 701
posterior, 701
ulnar, volar, 658
dorsal, 658
renal, 674, 1198
accessory, 1199
right colic, 672
gastric, 668
gastro-epiploic, 668
sacral, lateral, 684
middle, 676
scapular circumflex, 647
posterior, 642
transverse, 641
sciatic, 682
scrotal, posterior, 681
segmental, 121
semilunar, 626
septal, of nose, 614
posterior, 620
sheaths of, 570
short posterior ciliary, 627
gastric, 669
sigmoid, 672
smaller palatine, 620
spermatic, external, 686
internal, 674
sphenopalatine, 620
spinal, anterior, 637
posterior, 637
splenic, 669
stapedial, 121
sternal, 640
sternocleidomastoid, 610, 615
striate, lateral, 630
striate, medial, 630
structure of, 570
stylomastoid, 615
subclavian, left, 631
right, 632
subcostal, 664
sublingual, 611
submental, 613
subscapular, 647
superficial cervical, 642
epigastric, 693
external pudendal, 693
iliac circumflex, 693
palmar arch, 660
petrosal, 618
temporal, 616
volar, 655
volar arch, 660
superior articular of knee, 698
cerebellar, 638
coronary, 614
epigastric, 640
genicular, 698
glutæal, 684
hæmorrhoidal, 672

Artery or Arteries (*cont.*)
superior intercostal, 642
labial, 614
laryngeal, 610
mesenteric, 669
pancreaticoduodenal, 668
phrenic, 663
profunda, 651
suprarenal, 676
thoracic, 646
thyreoid, 609
ulnar collateral, 652
vesical, 679
supra-orbital, 627
suprarenal, inferior, 674
middle, 674
superior, 676
suprascapular, 641
sural, 698
tarsal, lateral, 703
medial, 703
temporal, deep, 619
middle, 616
superficial, 616
testicular, 674, 1215
thoracic aorta, 661
axis, 646
highest, 646
lateral, 647
long, 647
superior, 646
thoraco-acromial, 646
thymic branch of innominate, 602
thyreocervical trunk, 640
thyreoid axis, 640
inferior, 640
superior, 609
thyreoidea ima, 602
tibial, anterior, 700
posterior, 703
recurrent, 701
tonsillar, 613
tracheal, of inferior thyreoid, 641
transversa colli, 642
transverse cervical, 642
facial, 616
scapular, 641
of the trunk, 661
tympanic, anterior, 618
inferior, 610
superior, 618
ulnar, 656
collateral, inferior, 652
superior, 652
ulnar recurrent, dorsal, 658
volar, 658
umbilical, in fœtus, 64, 592, 678
of upper extremity, 631
urethral, 681
of urethral bulb, 681
uterine, 679
vaginal, 680
vasa aberrantia of brachial, 649
brevia, 669
intestini tenuis, 670
vasorum, 574
ventral segmental, 121
vertebral, 636
vesical, inferior, 679
superior, 679
branch of obturator, 680
Vidian, 620
volar carpal, deep, 656
superficial, 660

Artery or Arteries (*cont.*)
volar carpal of radial, 655
of ulnar, 600
volar, deep, of ulnar, 660
digital, common, 661
proper, 661
interosseous, 658
metacarpal, 656
first, 656
superficial of radial, 655
volaris indicis radialis, 656
zygomatic of lacrimal, 626
zygomatico-orbital, 616
Arterioles, 569
Arthrodia, 354
Articular arteries from popliteal, 698, 699
capsules, 351
stratum fibrosum, 351
stratum synoviale, 351
cartilage, 15, 351, 353
disc of acromioclavicular joint, 376
of distal radio-ulnar joint, 388
of mandibular joint, 356
of sternoclavicular joint, 375
end-bulbs, 1048
lamella of bone, 351
processes of vertebræ, 165
tubercle of temporal bone, 207, 252
Articularis genus, 537
Articulatio ellipsoidea, 354
sellaris, 354
sphæroidea, 354
trochoidea, 354
Articulations—
acromioclavicular, 376
amphiarthroses, 353
ankle, 420
arthrodia, 354
of atlas with epistropheus or axis, 363
of atlas with occipital bone, 366
of auditory ossicles, 1032
ball and socket, 354
calcaneocuboid, 426
carpometacarpal, 395
classification of, 352
condyloid, 354
costocentral, 367
costochondral, 372
costotransverse, 369
costovertebral, 367
coxal, 403
of cranium with vertebral column, 366
cubital, 383
cuboideonavicular, 428
cuneocuboid, 428
cuneonavicular, 427
development of, 82
diarthroses, 353
digital, of hand, 397
of foot, 430
elbow, 383
ellipsoid, 354
enarthrosis, 354
ginglymus, 354
gomphosis, 353
of heads of ribs, 367
hinge-joint, 354
hip, 403
humeral, 378
immovable, 352

CC-0. In Public Domain. Gurukul Kangri Collection, Haridwar

Digitized by Arya Samaj Foundation Chennai and eGangotri

Articulations (*cont.*)
intercarpal, 393
interchondral, 372
intercuneiform, 428
intermetacarpal, 396
intermetatarsal, 429
intertarsal, 424
knee, 410
of laryngeal cartilages, 1063
of lower extremity, 398
mandibular, 355
of manubrium with body of sternum, 372
metacarpophalangeal, 396
metatarsophalangeal, 430
movable, 353
movements permitted in, 354
pivot, 354
pubic symphysis, 400
radiocarpal, 390
radio-ulnar, distal, 388
proximal, 387
of ribs, 367
sacrococcygeal symphysis, 361
sacro-iliac, 398
saddle, 354
shoulder, 378
sphæroid, 354
sternoclavicular, 374
sternocostal, 370
sutura, 352
symphysis, 353
pubic, 400
synarthroses, 352
synchondrosis, 353
syndesmosis, 353
talocalcaneal, 424
talocalcaneonavicular, 424
talocrural, 420
tarsometatarsal, 428
temporomandibular, 355
tibiofibular, 419, 420
syndesmosis, 420
transverse tarsal, 426
trochoid, 354
of upper extremity, 374
of vertebral arches, 360
of vertebral bodies, 357
of vertebral column, 357
with cranium, 366
wrist, 390
Aryepiglottic fold, 1066
Aryepiglotticus muscle, 1069
Arytænoid cartilages, 1062
glands, 1071
swellings, 145
Arytænoideus obliquus, 1069
transversus, 1069
Ascending aorta, 598
branches of, 598
bulb of, 598
cervical artery, 641
colon, 1165
degeneration, 793
Association fibres of cerebral hemispheres, 866
of cerebellum, 819
neurons of medulla spinalis, 790
Associational areas, 871
Asterion, 270
Astragalus, 334
ossification of, 347, 348
Atavistic epiphyses, 25
Atlanto-occipital joints, 366
ligaments of, 366
movements at, 367
Atlanto-occipital membrane, anterior, 366
posterior, 366
Atlanto-epistrophic joints, 363
ligaments of, 363, 365
movements at, 366
Atlas, 167
development of anterior arch of, 69, 70
ossification of, 180
transverse ligament of, 364
Atresia, congenital, of pupil, 104
of pulmonary orifice, 596
Atria of heart, 580, 585
muscular fibres of, 588
of lungs, 1089
Atrial canal, 113, 115
septum, 580
systole, 591
Atrioventricular bundle, 33, 589
applied anatomy of, 591
node, 589
orifice, left, 586
right, 583
Atrium of heart, left, 585
right, 580
primitive, 113
division of, 115
of middle meatus of nasal cavity, 987
Attic or epitympanic recess, 209, 1027
Auditopsychic area, 871
Auditory artery, internal, 638, 1048
ossicles, 1031
articulations of, 1032
development of, 108
pit, 106
plates, 106
teeth of Huschke, 1043
tube, 1030
cartilaginous portion of, 1030
isthmus of, 1031
osseous portion of, 1030
pharyngeal ostium of, 1122
tonsil of, 1031
torus tubarius or cushion of, 1031, 1122
veins, internal, 1048
vesicle, 106
Auditosensory area, 871
Auerbach's plexus, 1162
Auricula of ear, 1022
cartilage of, 1023
development of, 108
ligaments of, 1023
lymphatic vessels of, 754
muscles of, 1023
structure of, 1022
vessels and nerves of, 1024
Auricula of heart, left, 585
right, 581
Auricular arteries, 615, 616
deep, 618
of occipital, 614
posterior, 614
lymph-glands, anterior, 751
posterior, 751
nerves, anterior, 901
great, 932
posterior, 911
nerve of vagus, 919
point, 270
surface of ilium, 309
Auricular surface of sacrum, 176
tubercle of Darwin, 1022
vein, posterior, 712
Auricularis anterior, 1024
posterior, 1024
superior, 1024
Auriculotemporal nerve, 901
Auriculoventricular groove, 578
Auscultation of lungs, 1092
Auscultation, triangle of, 495, 1277
Autacoid substances, 1243*
Autonomic nervous system, 779, 969
parasympathetic part of, 779
postganglionic fibres of, 779
preganglionic fibres of, 779
sympathetic part of, 779
nerves, 781, 928
Axes of pelvis, 314
Axial filament of spermatozoön, 44
Axial part of skeleton, 163
Axilla, 496, 643
applied anatomy of, 643
contents of, 643
Axillary arch, 495, 645
artery, 644
applied anatomy of, 645
branches of, 646
peculiarities of, 648
surface marking of, 1301
fascia, 496, 642
applied anatomy of, 496
lymph-glands, 759
applied anatomy of, 760
nerve, 938
applied anatomy of, 947
surface marking of, 1302
sheath, 645
vein, 727
applied anatomy of, 727
Axis, cerebrospinal, 779
of lens, 1007
optic, 993
thyreoid, 640
Axis cylinder process, 35, 37
cone of origin of, 36
Axis vertebra or epistropheus, 168
ossification of, 180
Axon, 35
Azygos arteries of vagina, 680
artery, articular, 699
uvulæ, 1120
vein, 731

Back, deep muscles of, 456
surface anatomy of, 1272
surface markings of, 1274
Baillarger, inner and outer bands of, 869
Ball and socket joint, 354
Band of Baillarger, inner, 869
outer, 869
diagonal of Broca, 852
furrowed, of cerebellum, 817
of Gennari, 869
of Giacomini, 852
iliotibial, 534
moderator, 584
peripheral dorsal, 796
Bar, hypochordal, 69
Bare area of liver, 1122, 1184
Barrel-shaped chest, 195
Bartholin, duct of, 1099
glands of, 158, 1240

CC-0. In Public Domain. Gurukul Kangri Collection, Haridwar

Digitized by Arya Samaj Foundation Chennai and eGangotri

Basal column, posterior, 791
Basal ganglia, 859
knobs of Engelmann, 5
lamina, 85
membrane, 1228
optic nucleus, 838
plate of placenta, 65
veins, 717
Bands, enamel, 1108
Base of sacrum, 176
of cerebral peduncle, 827
of heart, 578
of nose, 984
of skull, inferior surface, 247
superior surface, 260
Base-line, Reid's, 1262
Basement-membranes, 12
Basilar artery, 637
Basilar membrane, 1043
zona arcuata, 1043
pectinata, 1043
part of occipital bone, 198
of pons, 812
plexus, 723
Basilic vein, 726
median, 725
Basinasal length of skull, 270
Basion, 270
Basiphil leucocytes, 28
Basis bundle, anterior, 794, 806
lateral, 795, 806
Basis cranii externa, 247
interna, 257
Basivertebral veins, 733
Basket cells of cerebellum, 821
Bechterew, nucleus of, 814, 914
Bed of stomach, 1147
Bell, nerve of, 937
Bell's paralysis, 912
Bellini, ducts of, 1197
Betz, giant cells of, 869
Biceps brachii, 503
applied anatomy of, 505
femoris, 547
Bicipital fascia, 504
groove, 283
ridges, 283
Bicuspid teeth, 1103
valve, 586
Bifurcated ligament, 426
calcaneocuboid part of, 426
calcaneonavicular part of, 426
Bigelow, Y-shaped ligament of, 405
Bile-capillaries, 1188
Bile-duct, 1189
lymphatic vessels of, 771
structure of, 1190
Bipolar cells of retina, 1003
cone-bipolars, 1003
rod-bipolars, 1003
Bipolar nerve-cells, 34
Bird's nest of cerebellum, 817
Bismuth poisoning, 1095
Biventer cervicis, 460
Biventral lobules of cerebellum, 817
Bladder, gall, 1189
urinary, 1202
applied anatomy of, 1207
in child, 1204
development of, 157
extroversion of, 317, 1207
in female, 1204
interior of, 1206
ligaments of, 1204
lymphatic vessels of, 771
Bladder, urinary (*cont.*)
structure of, 1207
trigone of, 1206
vessels and nerves of, 1207
Blandin, glands of, 1117
Blastopore, 50
Blind spot, 1003
Blood, 26
cells, ichthyoid, 110
sauroid, 110
corpuscles, colourless, 27
red, 26
origin of, 109
course of, in adult, 569
in fœtus, 592
eosinophil corpuscles, 28
erythyrocytes, 26
hyaline cells, 28
islands, 109
leucocytes, 27
polymorphonuclear, 27
liquor sanguinis of, 26
lymphocytes, 28
macrocytes, 28
microcytes, 26
plasma, 26
plastids, 110
platelets, 28
thrombokinase, 28
Bloodless fold of Treves, 1146
Blood-vascular system, 569
Bodies, aortic, 101, 1249
of Call and Exner, 1228
carotid, 101, 1249
chromaffin, 1249
Malpighian, of kidney, 1197
of spleen, 1255
paraterminal, 99
polar, 42
restiform, 808
ultimobranchial, 135
Body, anococcygeal, 1170
ciliary, 998
coccygeal, 1252
of fornix, 862
geniculate, lateral, 835
medial, 835
paranephric, 1195
perinæal, 1170, 1238
pineal, 836
pituitary, 838
trapezoid, 813
of uterus, 1232, 1233
vitreous, 105, 1006
Wolffian, 150
Body-cavities, development of, 146
Body-stalk, 55, 58, 61
Bone, 17
acute diaphysitis, 25
acute infective necrosis, 25
acute infective periostitis, 25
applied anatomy of, 25
articular lamella of, 351
canaliculi of, 20, 21
cancellous tissue of, 17
cavum medullare, 18
cells, 21
centres of ossification, 23
chemical composition of, 21
compact substance of, 17
diaphysis, 25
diplöe of, 164
eminences and depressions of, 164
epiphyses, 25
formation of, 19
growth of, 22
Bone (*cont.*)
Haversian canals of, 20
systems of, 20
lacunæ of, 20, 21
lamellæ of, 20
lymphatics of, 19
marrow or medulla ossium of, 18
marrow-cells, 19
medullary membrane of, 18
megakaryocytes, 19
minute anatomy of, 19
myelocytes, 19
myeloplaxes, 19
necrosis of, 25
nerves of, 19
nutrient artery of, 19
ossein, 22
ossification of, 22
osteoblasts, 22, 23
osteoclasts, 23
osteogenic fibres, 22
perforating fibres of, 21
periosteum of, 18
premature synostosis of, 26
sequestrum, 25
spongy substance of, 17
structure and physical properties of, 17
substantia compacta of, 17
spongiosa of, 17
vessels of, 19
Bones—
astragalus, 334
atlas, 167
axis or epistropheus, 168
calcaneus, 339
capitate, 301
carpal, 298
of chest, 193
classes of, viz. long, flat, mixed or irregular, short, 163
clavicle or collar bone, 279
clavicula, 279
coccyx, 179
of columna vertebralis, 164
conchæ, inferior nasal, 224
costæ, 188
cranial, 196
cuboid, 344
cuneiform of carpus, 299
cuneiforms, of tarsus, 342
dermal or covering, 76
epihyal, 452
episternal, 187
epistropheus or axis, 168
ethmoidal, 220
facial, 230
femur, 317
fibula, 330
flat, 163
of foot, 334
frontal, 217
hamate, 302
of hand, 298
hip, 306
humerus, 282
hyoid, 246
ilium, 306
incus, 1032
of inferior extremity, 306
inferior nasal conchæ, 224
innominate, 306
interparietal, 200
irregular, 164
ischium, 309
lacrimal, 225

CC-0. In Public Domain. Gurukul Kangri Collection, Haridwar

Digitized by Arya Samaj Foundation Chennai and eGangotri

Bones (*cont.*)
lacrimal, lesser, 226
long, 163
lunate, 299
malar, 239
malleus, 1031
mandible, 240
maxillæ, 230
metacarpal, 302
metatarsal, 344
of middle ear, 1031
development of, 108
multangular, greater, 300
lesser, 300
nasal, 226
navicular of carpus, 298
of tarsus, 341
number of, in the body, 163
occipital, 196
os acetabuli, 313
calcis, 339
capitatum, 301
coccygis, 179
cordis, 587
coxæ, 306
cuboideum, 344
cuneiforme primum, 342
secundum, 342
tertium, 343
ethmoidale, 220
frontale, 217
hamatum, 302
hyoideum, 246
ilii, 306
incisivum, 234
ischii, 309
lunatum, 299
magnum, 301
multangulum majus, 300
minus, 300
naviculare manus, 298
pedis, 341
occipitale, 196
pisiforme, 300
planum of ethmoidal, 222
pubis, 310
sacrum, 174
sphenoidale, 200
trigonum, 339
triquetrum, 299
ossa carpi, 298
cranii, 196
faciei, 230
lacrimalia, 225
metacarpi, 302
metatarsi, 344
nasalia, 226
palatina, 236
parietalia, 215
suturarum, 229
tarsi, 334
temporalia, 206
zygomatica, 239
palatine, 236
parietal, 215
patella, 333
of pelvic-girdle, 274
of pelvis, 313
phalanges of foot, 346
of hand, 304
pisiform, 300
premaxilla, 234
radius, 287
ribs, 188
sacrum, 174
scapula, 274
semilunar, 299
sesamoid, 350

Bones (*cont.*)
short, 163
shoulder-blade, 274
of skull, 195
sphenoidal, 200
conchæ, 205
stapes, 1032
sternum, 185
of superior extremity, 274
of shoulder-girdle, 274
surface of, 164
sutural, 229
talus, 334
tarsal, 334
of thorax, 193
temporal, 206
tibia, 327
trapezium 300
trapezoid, 300
triquetral, 299
ulna, 291
unciform, 302
vertebra prominens, 169
vertebræ, 164
structure of, 165
cervical, 165
first, 167
second, 168
seventh, 169
coccygeal, 179
fixed, 164
lumbar, 172
fifth, 174
movable, 164
sacral, 174
thoracic, 170
eleventh, 172
first, 171
ninth, 172
tenth, 172
twelfth, 172
vertebral column, 164
vomer, 227
Wormian, 229
zygomatic, 239
Bony framework of outer nose, 984
semicircular canals, 1037
Boundary layer of decidua, 63
zone of suprarenal gland, 1251
Bowman, capsule of, 1197
glands of, 990
Brachia of corpora quadrigemina, 829
Brachia conjunctiva of cerebellum, 818, 823
pontis, 818
Brachial artery, 648
applied anatomy of, 649
branches of, 651
peculiarities of, 651
surface markings of, 1301
cutaneous nerve, lateral, 938
medial, 940
posterior, 945
fascia, 502
plexus, 935
applied anatomy of, 946
surface anatomy of, 1272, 1297
veins, 727
Brachialis, 504
Brachialis anticus, 504
Brachioradialis, 513
Brachyfacial skulls, 271
Brain, 799
applied anatomy of, 876

Brain, arteries of, 631
cerebellum, 814
cerebral hemispheres, 843
development of, 90
diencephalon, 831
divisions of, 799
general considerations of, 799
isthmus rhombencephali, 800
medulla oblongata, 800
meninges of, 877
mesencephalon or mid-brain, 825
metencephalon, 800
myelencephalon, 800
pons, 811
prosencephalon or fore-brain, 831
rhinencephalon, 851
rhombencephalon or hind-brain, 800
surface markings of, 1262
telencephalon, 842
thalamencephalon, 832
veins of, 716
ventricles—
fourth, 822
lateral, 854
of mid-brain, 831
third, 841
of Verga, 862
weight of, 872
Branchial arches, 76
grooves, 76
Breadth-index of skull, 270
Breadth of skull, 270
Breasts or mammæ, 1240
development of, 84
Bregma, 270
Bridge of nose, 256, 984
Brim of pelvis, 313
Broad ligaments of uterus, 1136, 1138, 1234
Broca, cap of, 847
diagonal band of, 852
gyrus of, 847
limbic lobe of, 850
parolfactory area of, 852
Bronchi, divisions of, 1088
intrapulmonary, 1089
Bronchial arteries, 653, 1091
branch of innominate artery, 602
lymph-glands, 776
muscle, 1089
nerves, 921
veins, 732, 1091
Bronchioles, lobular, 1089
Bronchomediastinal trunks, 750, 776
Bronchopulmonary lymph-glands, 776
Bronchus, eparterial, 1074
hyparterial, 1075
intrapulmonary, 1089
left, 1075
right, 1074
Brunner's glands, 1160
Bryant's triangle, 1308
Bubonocele, 1173
Buccæ, 1094
Buccal branches of facial nerve, 912
glands, 1094
nerve, long, 900
Buccinator artery, 619
lymph-glands, 752
muscle, 442
nerve, 900

CC-0. In Public Domain. Gurukul Kangri Collection, Haridwar

Digitized by Arya Samaj Foundation Chennai and eGangotri

Bucconasal membrane, 79
Buccopharyngeal fascia, 448
membrane, 50, 133
Bulb of aorta, 598
of corpus cavernosum penis, 1220
of eye, 993 (*see also* under Eyeball)
olfactory, 851, 872
optic, 102
of posterior cornu, 856
urethral, 1221
of vestibule, 1140
Bulbar paralysis, 811
ridges, 118
septa, 117, 118
Bulbocavernosus, in female, 491
in male, 489
Bulbo-urethral glands, 158, 1226
Bulboventricular ridge, 117
Bulbs of internal jugular vein, 713
Wolffian, 151*
Bulbus cordis, 113
Bulla ethmoidalis, 224, 266, 987
Bundle, anterior basis, 794
atrioventricular, 33, 589
ciliary, 438
lateral basis, 794
oval, 86, 91, 100
of Vicq d'Azyr, 834, 838, 862
Burdach, tract of, 795
Burns' space, 448
Bursa infracardiaca, 142
omental, 1136, 1139
development of, 139
omenti majoris, 1140
minoris, 1140
pharyngeal, 1124
Bursæ beneath glutæus maximus, 542
mucosæ, 352
near knee-joint, 380
near shoulder-joint, 415
subcutaneous, 352
subfascial, 352
submuscular, 352
subtendinous, 352

Cæcal arteries, 672
fossa, 1146
Cæcum, 1163
lymphatic vessels of, 770
surface marking of, 1286
types of, 1163
Calamus scriptorius, 824
Calcaneal arteries, lateral, 705
medial, 705
nerve, medial, 963
sulcus, 340
tuberosity, 341
Calcaneocuboid articulation, 426
ligament, dorsal, 426
plantar, 426
Calcaneofibular ligament, 423
Calcaneonavicular ligament, plantar, 427
applied anatomy of, 427
Calcaneotibial ligament, 422
Calcaneus, 339
ossification of, 347

Calcar avis, 856
Calcar femorale, 325
Calcarine fissure, 845
Call and Exner, bodies of, 1228
Callosal fissure, 850, 852
Calyces renales majores, 1194
minores, 1194
Calyculi, gustatory, 983
Camper, fascia of, 470.
Canaliculi of bone, 21
dental, 1104
Canaliculus, inferior tympanic, 212, 251
innominatus of Arnold, 203*
mastoid, 212, 251
Canalis centralis cochleæ, 211
craniopharyngeus, 136, 206
facialis, 211
musculotubarii, 212
reuniens of Hensen, 1040, 1042
Canal or Canals—
adductor, 689, 1310
Alcock's, 483
alimentary, 1092
parts of, 1092
alveolar, 230, 232, 253
anal, 1169
development of, 142
atrial, 113, 115
carotid, 211, 250, 261
central of medulla spinalis, 789
of cervix of uterus, 1233
condyloid, 199, 264
craniopharyngeal, 136, 206
ethmoidal, 219, 221
facial, 210, 1030
femoral, 689
gastric, 138, 1149
Haversian, 19
of Huguier, 208, 911, 1028
Hunter's, 689
hyaloid, 104, 1006
hypoglossal, 199, 251, 263
incisive, 234, 247
infra-orbital, 231, 258
inguinal, 481
lacrimal, 1019
mandibular, 243
mental, 243
nasolacrimal, 258, 266
neural, 52
neurenteric, 52
of Nuck, 156, 1234
of Petit, 1006
pharyngeal, 254
portal, 1188
pterygoid, 204, 250, 254
pterygopalatine, 231, 237
sacral, 176
of Schlemm, 994
semicircular, 1037
spiral of modiolus, 1037
vertebral, 184
Cancellous tissue of bone, 17
Canine eminence, 230, 256
fossa, 230, 256
teeth, 1103
Caninus, 441
Canthi of eyelids, 1016
Cap of Broca, 847
Capacity of skull, 269
Capillaries, 571
structure of, 572
Capitate bone, 301
ossification of, 305

Capitulum of humerus, 285
Capsula extrema, 858
vasculosa lentis, 104
Capsule of brain, external, 860
internal, 859
applied anatomy of, 872
of Bowman, 1197
fatty, of kidney, 1194
of Glisson, 1142, 1186
of lens, 1006
nasal, 75
of prostate, 1224
of Tenon, 1013
Capsules, articular, 351
Caput cæcum coli, 1163
Medusæ, 744
Cardiac cycle, 591
ganglion of Wrisberg, 979
glands of stomach, 1151
impression on liver, 1184
impressions on lungs, 1086
muscular tissue, 33
Purkinje's fibres, 33
nerves from vagus, 921
from sympathetic, 974, 975
notch, 1087
orifice of stomach, 1146
plexus of nerves, 978
valves, actions of, 591
veins, 708, 709
Cardinal veins, anterior, 125
posterior, 125
Cardiolysis, 577
Caroticoclinoid foramen, 204, 261
ligament, 206
Caroticotympanic artery, 626
nerves, 973, 1034
Carotid arch, 121
artery, common, 605
applied anatomy of, 607
peculiarities of, 606
surface marking of, 1272
thoracic portion of left artery, 605
external, 609
applied anatomy of, 609
branches of, 609
surface marking of, 1272
internal, 623
applied anatomy of, 625
branches of, 626
cavernous portion, 625
cerebral portion, 625
cervical portion, 623
peculiarities of, 625
petrous portion, 624
bodies, 101, 605, 1249
canal, 211, 250, 261
ganglion, 973
glomera, 101
nerve, internal, 973
nerves from glossopharyngeal, 917
Carotid plexus, internal, 973
of veins, 724
sheath, 448
sulcus, 201, 261
triangles, 621
tubercle, 167
Carpal arteries, from radial, 655, 656
from ulnar, 660
bones, 298
capitate (os magnum), 301
hamate (unciform), 302
lunate (semilunar), 299

CC-0. In Public Domain. Gurukul Kangri Collection, Haridwar

Digitized by Arya Samaj Foundation Chennai and eGangotri

Carpal bones (*cont.*)
multangular, greater (trapezium), 300
lesser (trapezoid), 300
navicular, 298
pisiform, 300
triquetral (cuneiform), 299
applied anatomy of, 306
common characteristics of, 298
fracture of, 306
surface anatomy of, 1294
ligament, dorsal, 519
transverse, 518
volar, 519
Carpometacarpal articulations, 395
Carpus, 298
applied anatomy of, 306
articulations of, 393
surface anatomy of, 1294
Cartilage, 14
alar of nose, 985
articular, 15, 351, 353
of auricula, 1023
cells, 15
cellular, 14
common paraseptal, 76
costal, 15
cricoid, 1061
elastic fibrocartilage, 17
of epiglottis, 1062
epiphysial, 23
greater alar of nose, 976
hyaline, 14, 351
intrathyreoid, 1061
lateral of nose, 984
lesser alar of nose, 977
paraseptal, common, 76
permanent, 14
of septum of nose, 984
temporary, 14
thyreoid, 1059
vomeronasal, 229, 988
white fibrocartilage, 16
yellow fibrocartilage, 17
Cartilages, arytænoid, 1062
corniculate, 1062
costal, 192
cuneiform, 1062
of larynx, 1059
structure of, 1063
Meckel's, 77, 243
of nose, 984
greater alar, 985
lesser alar, 985
lateral, 984
of septum, 984
of Santorini, 1062
of trachea, 1075
of Wrisberg, 1062
Cartilaginous ear capsules, 73, 107
framework of nose, 984
vertebral column, 69
Cartilago triticea, 1064
Caruncula lacrimalis, 1018
development of, 106
Carunculæ hymenales, 1239
Cataract, 1009
Cauda equina, 784
helicis, 1023
Caudal fold, 55
Caudate lobe of liver, 1184
nucleus of brain, 858
process of liver, 1184
Cavernous arteries, 626
Cavernous nerves, 982
plexus, 973
portion of urethra, 1209
sinuses, 720
applied anatomy of, 722
nerves in, 906
spaces of penis, 1222
Cavity or cavities—
amniotic, 49, 60
body, development of, 146
glenoid, 278
of larynx, 1065
of lesser pelvis, 314
mediastinal, anterior, 1082
middle, 1083
posterior, 1083
superior, 1082
medullary, 18, 163
of mouth, 1093
nasal, 264, 986
peritoneal, 1134
pleural, 1077
principal, of left atrium, 585
of right atrium, 580
pulp, 1104
segmentation, 49
of septum pellucidum, 864
sigmoid, greater, of ulna, 292
lesser, of ulna, 293
of radius, 290
subarachnoid, 881
thoracic, 574
tympanic, 1027
of uterus, 1233
Cavum conchæ, 1022
laryngis, 1065
Meckelii, 892
medullare, 18
oris, 1093
Cell, animal, 1
attraction sphere of, 2
centriole of, 2
centrosome of, 2
division of, 2
membrane, 2
nucleus of, 2
reproduction, 2
structure of, 1
Cell-islets, interalveolar, 1180
Cell-laminæ of cerebral cortex, 867, 868
Cell-mass, inner, 49
intermediate, 52, 54
Cells, amacrine, 1004
ameloblasts, 1107
basiphil, 28
basket, of cerebellum, 821
of Betz, 869
bipolar, of retina, 1003
bone, 21
cartilage, 15
centro-acinar, 1180
chalice, 5
chief or central, of fundus glands, 1152
chromaffin, 1149
clasmatocytes, 9
of Claudius, 1045
decidual, 63
of Deiters, 1045
of Dogiel, 926
enamel, 1107
eosinophil, 28
epithelial, 4
erythroblasts, 19
erythrocytes, 26
fat, 9
Cells (*cont.*)
germinal, 40
goblet, 5
of Golgi, 35, 869
granule, 9
gustatory, 983
of Hensen, 1045
horizontal, of retina, 1004
hyaline, 28
interstitial, of ovary, 1227
of testis, 1214
intermediate, of testis, 1214
of Kupffer, 1188
lamellar, 9
leucocytes, 27
of liver, 1187
luteal, 1229
lymphocytes, 28
macrocytes, 28
marrow, 18
of Martinotti, 869
megakaryocytes, 19
mesamœboid, 109
microcytes, 26
mitral, 872
myelocytes, 19
myeloplaxes, 19
nerve, 34
neuroblasts, 85
neutrophil, 28
normoblasts, 19
olfactory, 101, 989
oxyntic or parietal, 1052
oxyphil, 28
pigment, 9
pigmented, 13
pineal, 836
plasma, 9
polymorphonuclear, 28
prickle, 7, 1053
of Purkinje, 821
of Sertoli, 1214
somatic, 40
of spinal ganglia, 783, 926
splenic, 1254
spongioblasts, 85
stellate, of Kupffer, 1188
supporting of Hensen, 1045
of Sertoli, 1214
sympathocromaffin, 100
tendon, 11
wandering, 9
Cellular cartilage, 14
Cellulitis, pelvic, 1237
Cement of teeth, 1106
formation of, 1109
Central artery of retina, 626
canal of medulla spinalis, 789
or chief cells of fundus glands, 1152
grey stratum of cerebral aqueduct, 831
gyrus, anterior, 847
posterior, 848
nervous system, 779
sulcus of brain, 845, 1263
tendinous point of perinæum, 487
tendon of diaphragm, 466
Centres, higher or cortical visual, 841, 889
lower visual, 836, 841, 889
of ossification, 23, 24
Centrifugal nerves, 781
Centriole, 2
Centrioles of spermatozoön, 44
Centripetal nerves, 781

CC-0. In Public Domain. Gurukul Kangri Collection, Haridwar

Digitized by Arya Samaj Foundation Chennai and eGangotri

Centro-acinar cells, 1180
Centrosome, 2
Centrum ovale majus, 852
minus, 852
Cephalic flexure, ventral, 90
fold, 55
index, 270
portion of sympathetic system, 973
vein, 725
accessory, 726
Cerebellar artery, anterior inferior, 638
posterior inferior, 637
superior, 638
notches, 814
peduncles, 818, 819
systems of fibres, 876
afferent tracts, 876
efferent tracts, 876
tract, direct, 795, 806
veins, 717
Cerebello-olivary fasciculus, 807
Cerebellum, 814
applied anatomy of, 822
arteries of, 637, 638
brachia conjunctiva of, 818
pontis of, 818
development of, 92
fibræ propriæ of, 819
fissures of—
development of, 92
floccular, 92
horizontal, 815
postcentral, 815
postnodular, 92, 816
postpyramidal, 816
precentral, 815
preclivial, 815
prepyramidal, 816
grey substance of, 819
hemispheres of, 814
lobes of, 814
peduncles of, 818, 819
projection fibres of, 818
restiform bodies, 819
structure of, 817
inferior surface of, 816
superior surface of, 815
vermis of, 814
white substance of, 817
Cerebral aqueduct, 831
central grey stratum of, 831
arachnoid, 881
arteries, anterior, 629
middle, 629
posterior, 638
cortex, cell-laminæ of, 868, 869
fibre-laminæ of, 868, 869
nerve-cells of, 868, 869
nerve-fibres of, 868, 869
special types of, 869
structure of, 867
dura mater, 878
processes of, 878
venous sinuses of, 717
fissures and sulci—
calcarine, 845
callosal, 850
central, 845
cingulate, 846
circular, 846, 849
collateral, 845
development of, 99
fimbriodentate, 852, 863
frontal, 846
Cerebral fissures and sulci (*cont.*)
hippocampal, 851
incisura temporalis, 850
of insula, 850
interlobar, 844
intermedius primus, 848
intraparietal of Turner, 847
lateral, 845
limiting, of insulæ, 846
longitudinal, 843
medial frontal of Eberstaller, 847
occipital, lateral, 848
transverse, 848
olfactory, 847
paramedial, 847
parieto-occipital, 845
parolfactory, anterior, 852
postcentral, 847
precentral, 846
rhinal, external, 95
of Rolando, 845
subparietal, 846
of Sylvius, 845
temporal, 849
hæmorrhage, artery of, 630
hemispheres, 843
association fibres of, 866
borders of, 844
commissural fibres of, 866
development of, 95
fissures of, 844
grey substance of, 867
gyri or convolutions of, 844
interior of, 852
lobes of, 846
poles of, 844
projection fibres of, 866
structure of, 866
sulci of, 844
surfaces of, 844
transverse fibres of, 866
white substance of, 866
nerves, 885
development of, 100
abducent, 906
accessory, 922
acoustic, 913
facial, 907
glossopharyngeal, 915
hypoglossal, 923
oculomotor, 889
olfactory, 885
optic, 887
terminal, 885*
trigeminal, 893
mandibular division, 900
maxillary division, 895
ophthalmic division, 885
trochlear, 891
vagus, 917
peduncles, 825
structure of, 826
pia mater, 884
veins, external, 716
internal, 717
ventricle, of fornix (Verga), 862
fourth, 822
lateral, 854
of mid-brain, 831
third, 841
vesicles, 53, 90
parts derived from, 100
Cerebro-olivary fasciculus, 807
Cerebrospinal axis, 779
fasciculus, anterior, 793
lateral, 794
fibres of internal capsule, 860
uncrossed lateral, 794
fluid, 883
applied anatomy of, 883
nerves, structure of, 780
nervous system, 779
Ceruminous glands, 1026
Cervical artery, ascending, 641
superficial, 642
transverse, 642
branch of facial nerve, 912
curve of vertebral column, 182
enlargement of medulla spinalis, 786
fascia, 447
applied anatomy of, 449
flexure of embryonic brain, 90
ganglion, inferior, 975
middle, 975
superior, 974
lymph-glands, anterior, 753
deep, 754
superficial, 753
applied anatomy of, 757
muscles, superficial and lateral, 449
nerve, cutaneous or transverse, 933
nerves, anterior divisions of, 931
posterior divisions of, 928
plexus, 931
applied anatomy of, 934, 935
deep branches of, 944
superficial branches of, 932
posterior, 929
portion of sympathetic system, 974
irritation of, 982
paralysis of, 982
ribs, 169, 195
applied anatomy of, 195
vein, deep, 715
vertebræ, 165
Cervicalis ascendens, 458
profunda artery, 642
Cervix of uterus, 1233
canal of, 1233
supravaginal portion of, 1233
vaginal portion of, 1233
Chalice or goblet cells, 5
Chalones, 1243*
Chambers of the eye, 1000
Changes in vascular system at birth, 594
Chassaignac's tubercle, 167
Check ligaments, 367
of eye, 1013
Cheeks, 1094
Chemical composition of bone, 21
of teeth, 1105, 1106
Chest or thorax, 193
Chiasma, optic, 840, 888
Chief or central cells of fundus glands, 1152
motor tracts, principal, 873
secondary, 874
nerve-tracts, 873
sensory tracts, 874
muscle-sense, 874

CC-0. In Public Domain. Gurukul Kangri Collection, Haridwar

Digitized by Arya Samaj Foundation Chennai and eGangotri

Chief sensory tracts (*cont.*)
pain and temperature senses, 875
tactile sense, 874
Choanæ, 249, 266, 986
permanent, 80
primitive, 79
Choked-disc, 889
Cholecystotomy, 1191
Chondrification of the skull, 72
Chondrin, 17
Chondriosomes, 2
Chondrocranium, 72
Chondroglossus, 1116
Chondromucoid, 17
Chorda tympani nerve, 911, 1034
Chordæ tendineæ of left ventricle, 586
of right ventricle, 584
Willisii, 717
Chordal part of base of skull, 72
Chorioid coat of eyeball, 997
applied anatomy of, 1009
structure of, 997
plexuses of fourth ventricle, 823
of lateral ventricle, 864
of third ventricle, 841
vein, 717
Chorioidal artery, anterior, 630
posterior, 638
fissure of brain, 865
of optic cup, 102
Chorion, 64
frondosum, 64
læve, 64
Chorionic villi, 63, 64
Chromaffin cells, 1249
organs, 100, 1249
Chromatin, 2
Chromatolysis, 36, 793*
Chromosomes, 2
daughter, 3
number of, 2, 43
role of, 47
Chyle, 745
Chyliferous vessels, 745
Chylocele, 750
Chylous ascites, 750
pleural effusion, 750
Chyluria, 750
Cilia or eyelashes, 1016
Ciliaris muscle, 999
Ciliary arteries, 627
body, 998
bundle, 438
ganglion, 895
glands, 1016
nerves, long, 894
short, 895
processes, 998
Ciliospinal reflex, 877
Cingulate gyrus, 850
sulcus, 846
Cingulum of cerebral hemisphere, 850, 866
of tooth, 1102
Circle, arterial, of Willis, 630
Circular folds of small intestine, 1158
sinus, 722
sulcus, 846, 849
Circulating fluids, 26
blood, 26
lymph, 29
Circulation of blood in adult, 569
Circulation of blood (*cont.*)
in fœtus, 592
placental, 66
pulmonary, 569
systemic, 569
vitelline, 56
Circulus arteriosus major, 627, 1001
minor, 627, 1002
venosus of mammary papilla, 1242
Circumduction, movement of, 354
Circumferences of cranium, 270
of pelvis, 313, 314
Circumferential fibrocartilage, 17
Circumflex artery, anterior humeral, 647
posterior, 647
lateral femoral, 693
medial, 694
external, 693
internal, 694
scapular, 647
nerve, 938
applied anatomy of, 947
Circumflex iliac artery, deep, 687
superficial, 693
Cistern, periotic, 107
Cisterna basalis, 881
cerebellomedullaris, 881
chiasmatis, 881
chyli, 750
fossæ cerebri lateralis, 881
interpeduncularis, 881
magna, 881
pontis, 881
venæ magnæ cerebri, 882
Cisternæ, subarachnoid, 881
Clarke's column, 791, 795
Clasmatocytes, 9
Classification of bones, 163
of joints, 352
of skulls, 271
Claudius, cells of, 1045
Claustrum, 858
Clava, 803
Clavicle, 279
applied anatomy of, 281, 527
fracture of, 281, 527
ossification of, 281
peculiarities in sexes, 281
structure of, 281
surface anatomy of, 1292
Clavicula, 279
Cleft palate, 82, 1095
Cleft, pudendal, 1238
Clinging fibres of cerebellum, 812
Clinoid processes, anterior, 204, 261
middle, 201, 261
posterior, 201, 261
Clitoris, 1239
body of, 1239
crura of, 1239
dorsal nerve of, 967
vein of, 739
frenulum of, 1239
glans of, 1239
prepuce of, 1239
Clivus monticuli of cerebellum, 815
Cloaca, ectodermal, 142
entodermal, 142
pelvic portion of, 157
Cloaca, phallic portion of, 157
vesico-urethral portion of, 157
Cloacæ, 25
Cloacal membrane, 50, 142
duct, 142
tubercle, 158
Cloquet, lymph-gland of, 762
Closing membranes, 76
Club-foot, or talipes, 349, 558
Coarctation of aorta, 661
Coccygeal arteries, 682
body, 1252
structure of, 1252
cornua, 179
ganglion, 978
nerve, anterior division of, 958
posterior division of, 930
plexus, 967
vertebræ, 179
Coccygeus, 485
Coccygodynia, 317
Coccyx, 179
cornua of, 179
displacement of, 317
ossification of, 182
Cochlea, 1037
aqueduct of, 212, 1038
cupula of, 1037
hamulus laminæ spiralis of, 1038
helicotrema of, 1037
modiolus of, 1037
osseous spiral lamina of, 1038
scalæ of, 1037
secondary spiral lamina of, 1038
spiral canal of, 1037
vessels of, 1048
Cochlear nerve, 913, 1047
spiral ganglion of, 1047
nuclei, 813, 913
Cochleariform process, 212, 1030
Cœliac artery, 666
axis, 666
branches of vagus nerve, 921
ganglia, 979
plexus, 979
Cœlom, 49, 52, 146
Cog-tooth or spur of malleus, 1032
Cohnheim, areas of, 30
Colic artery, left, 672
middle, 672
right, 672
Colic arteries of ileocolic, 672
flexure, left, 1162, 1166
right, 1162, 1166
impression, 1185
valve, 1164
frenula of, 1164
Collagen, 11
Collar, renal, 127
Collar-bone, 279
Collateral circulation, 595
after ligature of :—
abdominal aorta, 666
axillary artery, 646
brachial artery, 651
carotid artery, common, 609
external, 609
femoral artery, 692
iliac artery, common, 678
external, 686
internal or hypogastric, 678
innominate artery, 604

CC-0. In Public Domain. Gurukul Kangri Collection, Haridwar

Digitized by Arya Samaj Foundation Chennai and eGangotri

Collateral circulation (*cont.*)
after ligature of:—
subclavian artery, 635
eminence, 857
fissure, 845
Collaterals of nerve-fibres, 37
Collecting tubules of kidney, 1197
Colles, fascia of, 470, 487
Colles' fracture, 295
Colliculi, inferior, 829
superior, 829
Colliculus of arytænoid cartilage, 1062
facialis, 814, 824
seminalis, 1209
Collum scapulæ, 278
Coloboma, congenital, 102, 1009
Colon, 1165
applied anatomy of, 1175
ascending, 1165
descending, 1167
iliac, 1167 *
left, or splenic, flexure of, 1162, 1166
right, or hepatic, flexure of, 1162, 1166
lymphatic vessels of, 770
sigmoid or pelvic, 1168
structure of, 1170
surface markings of, 1286
transverse, 1166
vessels and nerves of, 1171
Colostomy, 1175
Colostrum corpuscles, 1242
Coloured or red corpuscles, 26
Colourless corpuscles, 27
Columella, of nose, 79
Column, anterior grey, of medulla spinalis, 788
lateral, 788
posterior, 788
basal, 791
of Clarke, 791, 795
vertebral, 164, 182
cartilaginous, 69
development of, 68
membranous, 68
Columna nasi, 984
vertebralis, 164
Columns, of fornix, 862
muscle, 30
rectal, of Morgagni, 1170
renal (Bertini), 1196
of vagina, 1238
Comes nervi phrenici, 640
Comitans nervi ischiadici, 682
nervi phrenici, 640
Comma-shaped fasciculus, 796
Commissural fibres of cerebral hemispheres, 866
of cerebellum, 819
crossed, of medulla spinalis, 790
Commissure, anterior, of brain, 98, 863
middle or grey, 833
posterior, 94, 837
nucleus of, 837
habenular, 836
hippocampal, 862
of Gudden, 841, 888
labial, 1094
Commissure of medulla spinalis, grey, anterior, 789
posterior, 789
white, anterior, 787
optic, 840, 888
Commissures of brain, development of, 98
of labia majora, 1239
palpebral, 1015
Common bile-duct, 1189
carotid artery, 605
applied anatomy of, 607
peculiarities of, 606
dental germ, 1106
facial vein, 710
iliac arteries, 676
lymph-glands, 763
veins, 739
integument, 1051
interosseous artery, 658
mesentery, posterior, 138
peronæal nerve, 965
vitello-umbilical vein, 112
Communicans fibularis nerve, 965
tibialis nerve, 963
Communicantes cervicales nerves, 934
Communicating artery, anterior, 629
posterior, 630
from dorsalis pedis, 703
of peronæal, 705
of posterior tibial, 705
Compact substance of bone, 17
Comparison of bones of hand and foot, 348
Compensatory curves of vertebral column, 182
Complexus, 460
Compound palmar ganglion, 523
Compressor naris, 440
Concentric corpuscles of Hassall, 1249
Concha of auricula, 1022
cavum conchæ, 1022
cymba conchæ, 1022
inferior nasal, 224
ossification of, 225
middle nasal, 222
superior nasal, 223
Conchæ nasales inferiores, 224
sphenoidal, 205
Condyle of mandible, 243
Condyles of femur, 323
occipital, 199, 251
of tibia, 327
Condyloid articulation, 354
canal, 199, 264
foramen, anterior, 199
fossa, 199, 251
process of mandible, 243
vein, 724
Cone of origin of axon, 36
Cone-bipolars of retina, 1003
Cone-granules of retina, 1003
Cones of retina, 1005
Confluence of the sinuses, 197, 720
Congenital atresia of pupil, 104
coloboma, 102
fissures in cranium, 229
hernia, 1173
complete, 1173
incomplete, 1174
hydrocele, 1216
hypertrophic stenosis of pylorus, 1153
Coni vasculosi, 1214
Conical stump, 26
Conjoined tendon of obliquus internus and transversus, 476
Conjugate diameter of pelvis, 313
Conjunctiva, 1018
applied anatomy of, 1021
fornix of, 1018
Connecting fibrocartilages, 16
Connective tissue, extraperitoneal, 481
Connective tissues, proper, 7
adipose, 9
areolar, 7
development of, 14
lymphatics of, 13
lymphoid, 12
mucoid, 12
nerves of, 13
retiform or reticular, 12
vessels of, 12
white fibrous, 10
yellow elastic, 11
Conoid ligament, 377
tubercle, 280
Constriction, duodenopyloric, 1147
Constrictor pharyngis inferior, 1125
medius, 1126
superior, 1126
urethræ, 490
Contraction of hamstring tendons, 548
Contour lines of Owen, 1105
Conus arteriosus, 583
tendon of, 583
elasticus of larynx, 1065
medullaris, 784
Convoluted tubules of kidney, 1197
Convolutions of brain. (*See* Gyrus)
Cooper, fascia propria of, 1175
ligament of, 473
ligamenta suspensoria of, 496, 1241
Copula, 134
Cor, 577
Coraco-acromial ligament, 377
Coracobrachialis, 503
Coracoclavicular fascia, 498
ligament, 376
Coracohumeral ligament, 379
Coracoid process, 278
tuberosity, 280
Cord, genital, 151
nephrogenic, 52
oblique, 387
spermatic, 1218
spinal, 784
umbilical, 61
Cords, of brachial plexus, 935
genital, 153
vocal, false, 1066
true, 1067
Corium or cutis vera, 1053
Corium, papillary layer of, 1054
reticular layer of, 1054
Cornea, 995
applied anatomy of, 1008
nerves of, 997
structure of, 996
Corneal corpuscles, 996
epithelium, 996
spaces, 996
Corniculate cartilages, 1062
Cornua, coccygeal, 179
of fossa ovalis, 534
grey, of medulla spinalis, 788
of hyoid bone, 246

CC-0. In Public Domain. Gurukul Kangri Collection, Haridwar

Digitized by Arya Samaj Foundation Chennai and eGangotri

Cornua of lateral ventricles, 856, 857
sacral, 175
of thyreoid cartilage, 1061
Cornucommissural fasciculus, 796
Corona glandis, 1222
radiata, of brain, 860
of ovum, 42
Coronal suture, 247, 251, 260
Coronary arteries, of heart, 598, 599
applied anatomy of, 600
peculiarities of, 600
of face, 614
artery of stomach, 667
ligament of liver, 1134, 1185
ligaments of knee, 415
plexuses, 979
sinus, 708
opening of, 582
valve of, 582, 708
sulcus of heart, 578
vein of stomach, 744
Coronoid fossa, 285
process of mandible, 242
of ulna, 292
Corpora cavernosa clitoridis, 1239
penis, 1220
artery of, 681
bulbs of, 1220
crura of, 1220
mamillaria, 838
quadrigemina, 829
brachia of, 829
structure of, 830
Corpus Arantii, 585, 587
callosum, 853
development of, 98
genu of, 853
peduncle of, 852
rostrum of, 853
splenium of, 853
cavernosum urethræ, 1221
clitoridis, 1239
Highmori, 1213
luteum, 1229
spongiosum, 1221
striatum, 96, 857
subthalamicum, 838
Corpuscles, colostrum, 1242
coloured, 26
colourless, 27
concentric, of Hassall, 1249
corneal, 996
eosinophil, 28
erythrocytes, 36
genital, 1048
of Golgi and Mazzoni, 1050
of Grandry, 1049
of Hassall, 1249
of Herbst, 1050
hyaline, 28
lymphocyte, 28
oxyphil or neutrophil, 28
Pacinian, 1049
polymorphonuclear, 28
red, 26
of Ruffini, 1050
of Wagner and Meissner, 1050
Corrugator, 439
cutis ani, 486
Cortex of cerebellum, 820
of cerebrum, 867
of hair, 1057
of suprarenal gland, 1251
Corti, ganglion of, 1047
pillars or rods of, 1044
spiral organ of, 1044
tunnel of, 1044
Cortical arches of kidney, 1196
arterial system of brain, 631
substance of kidney, 1196
of lens, 1007
visual centre, 871, 889
Corticostriate fibres, 858
Corticothalamic fibres, 834
Costæ spuriæ, 188
veræ, 188
Costal cartilages, 192
arches, primitive, 70
cartilage, 15
groove, 190
pleura, 1077
process of a cervical vertebra, 167
tuberosity, 281
Costocentral articulations, 367
Costocervical artery, 642
Costochondral articulations, 372
Costoclavicular ligament, 375
Costocoracoid ligament, 498
membrane, 498
Costomediastinal sinus, 1079
Costotransverse articulations, 369
ligaments, 369
Costovertebral articulations, 367
movements at, 368
Costoxiphoid ligaments, 372
Cotyledons of placenta, 66, 67
Cotyloid ligament, 406
Covering bones, 76
Coverings of direct inguinal hernia, 1174
of femoral hernia, 1174
of oblique inguinal hernia, 1173
of ovum, 41
Cowper's glands, 158, 1226
Coxal articulation, 403
Cranial bones, 196
applied anatomy of, 229
fossa, anterior, 260
middle, 260
posterior, 261
Craniology, 269
Craniopharyngeal canal, 136, 206
Craniotabes, 229
Craniovertebral articulations, 366
Cranium, 195
bones of, 195
congenital fissures in, 229
development of, 71
Cremaster, 475
Cremasteric artery, 686, 1219
fascia, 475, 1218
Crescents of Gianuzzi, 1100
Crest or Crests—
anterior of tibia, 328
frontal, 218, 260
of greater and lesser tubercles of humerus, 283
of ilium, 309
incisor, 235
infratemporal, 203, 253
inguinal, 154
internal occipital, 197
intertrochanteric, 320
lacrimal, anterior, 232, 258
Crest or crests (*cont.*)
lacrimal, posterior, 225, 258
lateral sacral, 175
median sacral, 175
nasal, 234
neural, 52, 88
obturator, 311
occipital, internal, 197, 264
pubic, 311
sacral articular, 175
sphenoidal, 201
of spine of scapula, 275
supramastoid, 206
tympanic, 213*
urethral in female, 1211
in male, 1209
Cricket-thigh, 537
Cricoarytænoid ligament, posterior, 1063
Cricoarytænoideus lateralis, 1069
posterior, 1069
Cricoid cartilage, 1061
Cricothyreoid artery, 610
ligament, middle, 1065
membrane, 1065
Cricothyreoideus, 1069
Cricotracheal ligament, 1064
Crista ampullaris, 1040
arcuata of arytænoid cartilage, 1062
basilaris, 1042
capituli, 189
colli costæ, 190
conchalis, 231, 237
ethmoidalis, 233, 237
galli, 220, 260
quarta, 1041
terminalis of right atrium, 113, 581
transversa, 210
vestibuli, 1036
Crossed commissural fibres, 790
pyramidal tract, 794
Crosses of Ranvier, 38
Cruciate anastomosis, 694
Cruciate crural ligament, 559
eminence of occipital bone, 196
ligaments of knee, 414
Crura cerebri, 825
of diaphragm, 465
of fornix, 863
of greater alar cartilage, 985
of incus, 1032
of penis, 1220
of stapes, 1032
of subcutaneous inguinal ring, 472
Crural branch of genitocrural nerve, 953
interosseous membrane, 420
Crural ligament, cruciate, 559
transverse, 558
muscles, anterior, 549
lateral, 556
posterior, 551
nerve, anterior, 956
septum, 689
Crureus, 537
Crus commune, 1037
helicis, 1022
Crusta or pes of cerebral peduncle, 827
petrosa or cement of teeth, 1106
formation of, 1109
Crutch-paralysis, 947

CC-0. In Public Domain. Gurukul Kangri Collection, Haridwar

Digitized by Arya Samaj Foundation Chennai and eGangotri

Cruveilhier, glenoid ligaments of, 396, 430
posterior cervical plexuses of, 929
Cryptorchismus, 156
Crypts of Lieberkühn, 1600
Crystalline lens, 998 (*see also* under Lens)
Cubital articulation, 383
fossa, 649
vein, median, 725
applied anatomy of, 727
Cuboid bone, 344
ossification of, 347
Cuboideonavicular articulation, 428
Culmen monticuli of cerebellum, 815
Cumulus oöphori, 1228
Cuneate nucleus, 803
tubercle, 803
Cuneiform bone of carpus, 299
ossification of, 305
first, of tarsus, 342
ossification of, 347
second, 342
ossification of, 347
third, 343
ossification of, 347
cartilages, 1062
Cuneocuboid articulation, 428
Cuneonavicular articulation, 427
Cuneus, 848
Cup, optic, 102, 1003
Cupula of cochlea, 1037, 1038
of pleura, 1078
Curvatures of stomach, 1147
Curved lines of ilium, 307, 308
Curves of the vertebral column, 182
Cushion or torus of auditory tube, 1031, 1123
or tubercle of epiglottis, 1063
Cushions, endocardial, 115
Cuspids, 1103
Cusps of bicuspid valve, 586
of tricuspid valve, 583
Cutaneous cervical nerve, 933
Cutaneous nerves :—
anterior, of thorax, 949
dorsal antibrachial, 945
external, of musculo-spiral, 945
of thigh, 955
intermediate, of thigh, 956
intermediate dorsal, of foot, 966
internal, of forearm, 940
of musculo-spiral, 945
lateral antibrachial, 939
brachial, 938
dorsal, of foot, 963
femoral, 955
of thorax, 949
lesser internal (Wrisberg), 940
medial, antibrachial, 940
brachial, 940
dorsal, of foot, 966
medial, sural, 963
of thigh, 956
perforating, 966
posterior brachial, 945
femoral, 960
Cuticle, 1051
of hair, 1057
Cuticula dentis, 1109
Cutis-plate, 68
Cutis vera or corium, 1053
papillary layer of, 1054
reticular layer of, 1054
Cuvier, ducts of, 112, 125
Cycle, cardiac, 591
Cycloid, 324*
Cylinders, hepatic, 143
Cymba conchæ, 1022
Cystic artery, 669
duct, 1189
lymph-gland, 766
vein, 744
Cystic hygroma, congenital, 748
Cystotomy, suprapubic, 1208
Cysts, hydatid, of liver, 1191
ovarian, 1229
Cyton, 35
Cytoplasm, 40
Cytotrophoblast, 49, 64

Dacryon, 270
Dactylitis, tuberculous, 306
Dangerous area of eye, 1009
Dartos tunic, 470, 1220
Darwin, auricular tubercle of, 1022
Daughter chromosomes, 3
Decidua, 63
basalis, 63
capsularis, 63
limiting or boundary layer of, 63
parietalis or vera, 63
placentalis, 63
stratum compactum of, 63
spongiosum of, 63
Decidual cells, 63
Deciduous teeth, 1104, 1110
development of, 1106
Decussation of lemniscus, 805
of Meynert, 831
partial, of optic nerves, 888
pyramidal, 800, 874
sensory, 805
Deformities of skull, 273
Degeneration, Wallerian, 39, 793
ascending, 793
descending, 793
Deglutition, mechanism of, 1122
Deiters, cells of, 1045
nucleus of, 814, 914
Deltoid ligament, 422
tubercle, 280
tuberosity, 284
Deltoideopectoral triangle, 497
lymph-glands, 759
Deltoideus, 500
applied anatomy of, 501
Demilunes of Heidenhain, 1100
Dendrons of nerve-cells, 35
Dens of epistropheus, 168
Dens serotinus, 1104
Dental artery, inferior, 619
posterior, 619
canaliculi, 1104
formulæ, 1103
furrow, 1106
germ, common, 1106
special, 1107
index, 271
lamina, 1106
Dental nerve, inferior, 902
pulp, 1104
Dental sac, 1108
Dentate gyrus, 852, 872
nucleus of cerebellum, 821
Dentes, 1101
Dentinal canaliculi, 1104
fibres, 1105
matrix, 1105
sheath of Neumann, 1105
Dentine, 1104
chemical composition of, 1105
formation of, 1109
secondary or adventitious, 1106
Dentogingival lamina, 1106
Depression for semilunar ganglion, 261
Depressions for arachnoideal granulations, 216, 260
Depressor anguli oris, 441
septi, 440
Dermal bones, 76
Dermic coat of hair-follicle, 1056
Descendens cervicalis nerve, 934
Descending aorta, 661
colon, 1167
comma-shaped fasciculus, 796
degeneration, 793
process of lacrimal bone, 225
ramus of hypoglossal nerve, 925
Descent of testis, 154
applied anatomy of, 156
of ovaries, 156
Deuteroplasm, 2, 40
Development of—
acoustic meatus, external, 108
nerve, 108
adipose tissue, 10
allantois, 58
amnion, 60
anal canal and rectum, 142
aortic arches, 121
aortopulmonary septum, 117
aqueous chamber, 105
archenteron, 49
arteries, 119
of the limbs, 123
articulations, 82
atrial septa, 115
auditory tube, 107
auricula or pinna, 108
blood corpuscles, 109
blood-vessels, 109
body-cavities, 146
body-stalk, 55, 59,* 61
brain, 90
branchial or visceral arches, 76
caudal fold, 55
cell-laminæ of cerebrum, 99
cephalic fold, 55
cerebellum, 92
cerebral hemispheres, 95
nerves, 100
chondrocranium, 72
chorion, 64
chorionic villi, 63, 64
chromaffin organs, 100
cloaca, 142
cœlom, extra-embryonic part of, 49, 146
intra-embryonic part of, 146
commissures of brain, 98

CC-0. In Public Domain. Gurukul Kangri Collection, Haridwar

Digitized by Arya Samaj Foundation Chennai and eGangotri

Development of—
connective tissues, 14
corpus callosum, 97
striatum, 96
crystalline lens, 104
cytotrophoblast, 49, 64
decidua, 63
deciduous teeth, 1106
diencephalon, 94
digestive tube, 132
dorsal aortæ, 121
ears, 106
external organs of generation, 158
eyelids, 105
eyes, 101
face, 78
fissures or sulci of cerebrum, 99
fœtal membranes and placenta, 58
fore-brain, 93
fore-gut, 55
fornix, 99
ganglion-ridge, 52
generative and urinary organs, 149
genital glands, 153
glands of skin, 84
hairs, 84
heart, 110, 113
Hensen's knot, 50
hind-brain, 90
hind-gut, 55
hypophysis cerebri, 135
inferior vena cava, 126
intermediate cell-mass, 54
intervillous space, 63
joints, 82
kidney, 156
lacrimal apparatus, 105
laminæ of cerebral cortex, 867
larynx, 145
lateral cerebral fissure, 99
layer of Langhans, 49
lens, 104
limbs, 82
liver, 143
lungs, 145
lymphatic vessels, 131
magma reticulé, 49
mammary gland, 84
Meckel's diverticulum, 57
medulla oblongata, 91
spinalis, 85
membranous labyrinth, 106
mesencephalon, 93
mesoderm, 49
mesonephros or Wolffian body, 149
metanephros, 156
mid-brain, 93
milk-ridge, 84
morula, 49
mouth, 132
Müllerian ducts, 151
muscles, 83
muscular fibres, 33
nails, 85
nasal capsule, 75
neopallium, 96
nervous system, 85
neural crest, 52
neural groove and tube, 52
neurenteric canal, 52
nose, 78
notochord, 53

Development of—
olfactory nerves, 101
optic nerve, 103
ovary, 153
palate, 79
palatine tonsils, 134
pancreas, 144
parathyreoid bodies, 135
parietes, 68
permanent kidney, 156
teeth, 1102
pharyngeal pouches, 76
pinna or auricula, 108
placenta, 64
pons, 92
primary nail-fields, 85
primitive digestive tube, 55
aortæ, 111
segments, 49
streak, 49
pronephric duct, 149
pronephros, 149
prosencephalon, 93
prostate, 157
rectum and anal canal, 142
respiratory organs, 145
retina, 102
rhinencephalon, 95
rhombencephalon or hind-brain, 90
ribs, 70
salivary glands, 134
sebaceous glands, 84
segmental arteries, dorsal, 122
lateral, 123
ventral, 121
sense-organs, 85
sinus venosus, 113
skeleton, 68
skin and its appendages, 83
skull, 71
spermatozoön, 44
spinal nerves, 88
spleen, 145
sternum, 71
sudoriferous glands, 84
sulci and fissures of cerebrum, 99
suprarenal glands, 101
sweat-glands, 84
Sylvian fissure, 99
sympathetic nervous system, 100
syncytiotrophoblast, 49, 64
syncytium, 49
teeth, 1106
telencephalon, 94
testis, 154
thymus, 135
thyreoid gland, 134
tongue, 134
trophoblast, 49
tympanic cavity, 107
ossicles, 108
ultimobranchial bodies, 135
umbilical cord, 61
vesicle, 56
urethra, 159
urinary bladder, 157
urogenital organs, 149
valves of heart, 118
vascular system, 109
veins, 124
vena cava, inferior, 126
venous sinuses of dura mater, 128
ventral aortæ, 120

Development of—
ventricular septum, 116
vertebral column, 68
visceral or branchial arches, 76
vitelline duct, 56
vitreous body, 105
vomeronasal organs, 81
Wolffian duct, 149
yolk-sac, 56
Diagonal band of Broca, 852
Diameters of pelvis, 313, 314
Diaphragm, 464
actions of, 467
applied anatomy of, 468
arcuate ligaments of, 465
central tendon of, 466
crura of, 465
height of, 467
lumbocostal arches of, 465
lymphatic vessels of, 775
openings in, 466
relations of, 467
pelvic, 482
urogenital, 489
Diaphragma sellæ, 838, 880
Diaphragmatic lymph-glands, 775
part of pelvic fascia, 483
pleura, 1078
surface of heart, 580
Diaphysis, 163
Diaphysitis, acute, 25
Diarthroses, 353
Diencephalon, 94, 831
Differentiation of cells, 40
Digastric fossa of mandible, 241
of temporal bone, 209, 250
branch of facial nerve, 912
of mylohyoid nerve, 902
triangle, 622
Digastricus, 451
Digestive apparatus, 1092
development of, 132, 137
lymphatic vessels of, 769
tube, 1092
development of, 132
Digital arteries, common volar, 661
proper volar, 661
articulations of foot, 430
applied anatomy of, 431
of hand, 397
fossa of epididymis, 1212
nerves of deep peronæal, 965
of lateral plantar, 965
of medial plantar, 964
of median, 942
of radial, 946
of ulnar, 944
vaginal ligaments, 510, 563
veins of foot, 733, 736
of hand, 724, 725, 727, 733
Dilatator naris anterior, 440
posterior, 440
pupillæ, 105, 1000
tubæ, 1031
Diploë, 164, 199
Diploic veins, 715
frontal, 715
occipital, 716
temporal, anterior, 715
posterior, 716
Diplopia, 891, 892
Direct cerebellar tract, 795, 806
division of cells, 2
inguinal hernia, 1174
pyramidal tract, 793

CC-0. In Public Domain. Gurukul Kangri Collection, Haridwar

Digitized by Arya Samaj Foundation Chennai and eGangotri

Disc, embryonic, 49
optic, 1002
Discharge of ovum, 1228
Dislocation of—
acromioclavicular joint, 377
ankle-joint, 424
atlas from epistropheus, 367
coccyx, 317
elbow-joint, 389
head of radius, 390
hip-joint, 409
congenital, 410
knee-joint, 419
long tendon of Biceps brachii, 505
mandible, 357
menisci of knee-joint, 419
radiocarpal joint, 395
shoulder-joint, 382
sternoclavicular joint, 375
subtalar, 428
tarsal bones, 428
wrist-joint, 395
Dissociation of sensations, 876
Diverticulum, Meckel's, 57, 1156
Division of cells, 2
Divisions of bronchi, 1088
anterior, of spinal nerves, 931
posterior, of spinal nerves, 928
Dobie's line, 30
Dogiel, cells of, 926
Dolichocephalic skulls, 271
Dorsales linguæ arteries, 611
Dorsalis hallucis artery, 703
pedis artery, 702
applied anatomy of, 703
branches of, 703
peculiarities of, 703
surface marking of, 1311
scapulæ artery, 647
Dorsoepitrochlearis brachii, 495
Dorsum ilii, 307
nasi, 984
of tongue, 1111
sellæ, 201, 260, 262
Douglas, pouch of, 1136, 1234
Droplet, enamel, 1109
Duct or ducts—
aberrant of epididymis, 1217
accessory pancreatic, 144, 1180
of Bartholin, 1099
of Bellini, 1197
bile, 1189
of bulbo-urethral glands, 1226
cloacal, 142
common bile-duct, 1189
of Cuvier, 112, 125
cystic, 1189
ejaculatory, 1218
frontonasal, 220, 266
of Gärtner, 151, 1229
hepatic, 1188
lacrimal, 1019
lactiferous, 1241
lymphatic, right, 750
Müllerian, 151
nasolacrimal or nasal, 1020
pancreatic, 144, 1178
para-urethral, 1211
parotid, 1097
pronephric, 149
prostatic, 1209
of Rivinus, 1099
of Santorini, 1180
Duct or ducts—
semicircular, 1040
Skene's, 158, 1211
Stensen's, 1097
sublingual, 1099
submaxillary, 1099
thoracic, 748
thyreoglossal, 134
vitelline, 56, 57, 137
Wharton's, 1099
of Wirsung, 1179
Wolffian, 149
Ductless glands, 1243
chromaffin organs, 1249
aortic bodies, 1249
glomera carotica, 1249
paraganglia, 1249
glomus coccygeum, 1252
parathyreoids, 1247
spleen or lien, 1252
suprarenals, 1250
thymus, 1247
thyreoid, 1243
Ductuli aberrantes of testis, 1217
efferentes of testis, 1214
transversi of epoöphoron, 1229
Ductus arteriosus, 592, 594
choledochus, 1189
cochlearis, 1041
deferens, 1216
ampulla of, 1216
artery of, 679
lymphatics of, 773
structure of, 1217
endolymphaticus, 1036, 1040
longitudinalis epoöphori, 1229
paraurethralis, 1211
Santorini, 1180
utriculosaccularis, 1039
venosus, 125, 594
development of, 125
fossa for, 1183
Wirsungi, 1179
Duodenal fossa, inferior, 1145
superior, 1145
flexure, inferior, 1154
superior, 1154
fold, inferior, 1145
superior, 1145
glands, 1160
impression, 1185
papilla, 1155
Duodenojejunal flexure, 1154, 1155
fossæ, 1145
Duodenopyloric constriction, 1147
Duodenum, 1154
ascending portion, 1155
descending portion, 1154
horizontal portion, 1155
superior portion, 1154
lymphatic vessels of, 769
suspensory muscle of, 1156
vessels and nerves of, 1156
Dupuytren's contraction, 523
Dura mater, 877
cerebral, 878
arteries of, 880
diaphragma sellæ, 880
falx cerebelli, 880
falx cerebri, 879
nerves of, 880
processes of, 878
sinuses of, 880
tentorium cerebelli, 879
Dura mater (*cont.*)
cerebral, veins of, 880
venous sinuses of, 717
spinal, 880

Ear, 1022
cartilaginous ear capsules, 73
development of, 106
surface anatomy of, 1270
external ear, 1022
applied anatomy of, 1026
auricula or pinna, 1022
external acoustic meatus, 1024
internal ear or labyrinth, 1035
applied anatomy of, 1048
membranous labyrinth, 1039
basilar membrane, 1043
ductus cochlearis or scala media, 1041
reticular lamina, 1045
saccule, 1040
semicircular ducts, 1040
spiral organ of Corti, 1044
tectorial membrane, 1046
utricle, 1039
vestibular membrane, 1041
osseous labyrinth, 1036
cochlea, 1037
semicircular canals, 1037
vestibule, 1036
middle ear or tympanic cavity, 1027
applied anatomy of, 1034
attic or epitympanic recess of, 1027
auditory ossicles, 1031
auditory (Eustachian) tube, 1030
mucous membrane of, 1034
vessels and nerves of, 1034
walls of, 1027 to 1031
Ear-capsules, chondrification of, 73
Eberstaller, medial frontal sulcus of, 847
Ectoderm, 50
amniotic, 60
Ectodermal cloaca, 142
Ectopic gestation, 1231
Ectropion, 1021
Efferent lymphatic vessels, 747
nerves, 781
Ejaculator urinæ, 489
Ejaculatory ducts, 1218
Elastic fibrocartilage, 17
laminæ of cornea, 996
membrane of larynx, 1064
tissue, yellow, 11
Elastin, 12
Elbow-joint, 383
anastomoses around, 652
applied anatomy of, 389
movements of, 388
surface anatomy of, 1294, 1296
marking of, 1298
vessels and nerves of, 385
Eleidin, 6, 1053
Elephantiasis, 748
Eleventh thoracic vertebra, 172
rib, 192

CC-0. In Public Domain. Gurukul Kangri Collection, Haridwar

Digitized by Arya Samaj Foundation Chennai and eGangotri

Embolism of pulmonary artery, 597
Embryo, formation of, 54
form of, at different stages, 159
Embryology, 40
Embryonic disc, 49
ectoderm, 49
Eminence, canine, 229, 256
collateral, 857
cruciate, of occipital bone, 196
frontal, 217, 247
hypothenar, 518
iliopectineal, 309, 310, 311
intercondyloid, of tibia, 327
medial, of rhomboid fossa, 824
Müllerian, 151
parietal, 215, 247
pyramidal of tympanic cavity, 1030
thenar, 518
Eminences and depressions of bones, 164
Eminentia arcuata, 210
articularis, 207
saccularis, 838
Emissary veins, 724
applied anatomy of, 724
Emphysema, pulmonary, 195
surgical, 1091
Empyema, 1080
Enamel, 1106
bands, 1108
cells, 1107
droplet, 1109
epithelium, 1107
fibres or prisms, 1106
formation of, 1108
niche, 1108
organ, 1108
of teeth, 1106
pulp, 1108
Enarthrosis, 354
Encephalocele, 271
Encephalon, 799
Encysted calculi, 1208
hydrocele of the cord, 1216
of the epididymis, 1216
End-arteries, 595
End-bulbs of Krause, 1048
articular, 1048
End-organs, special, of nerves, 1048
End-plate, motor, 782
Endocardial cushions, 115
Endocardium, 587
Endocrine organs, 1243*
Endolymph, 1039
Endometrium, 1236
Endomysium, 29
Endoneurium, 780
Endoskeleton, 163
Endosmosis, 27
Endothelium, 4
of anterior chamber of eye, 997
Engelmann, basal knobs of, 5
Enlargements of medulla spinalis, 786, 787
Enophthalmos, 982
Entamœba histolytica, 745
Enterectomy, 1172
Enteroptosis, 1175
Entoderm, 51
Entodermal cloaca, 142
Entrance to the antrum, 1030
Entrance to the larynx, 1066
Entropion, 1021
Enucleation of tonsils, 1120
Eosinophil corpuscles, 28
Eparterial branch of right bronchus, 1074, 1088
Ependyma, 856
Ependymal layer, 85
Epicardium, 576, 587
Epicondyles of femur, 323
of humerus, 285
Epicranial aponeurosis, 437
Epicranius, 436
Epidermic coat of hair-follicle, 1056
Epidermis, development of, 83
structure of, 1051
Epididymis, 1212
aberrant ducts of, 1217
appendix of, 1212
body of, 1212
digital fossa of, 1212
globus major, 1212
minor, 1212
head of, 1212
ligaments of, 1213
lobules of, 1214
sinus of, 1212
tail of, 1212
Epidural space, 880
Epigastric artery, inferior or deep, 686
applied anatomy of, 687
peculiarities of, 687
surface marking of, 1288
superficial, 693
superior, 640
fold, 1173
lymph-glands, inferior, 764
region of abdomen, 1133
vein, inferior, 737
superficial, 734
Epiglottis, cartilage of, 1062
tubercle or cushion of, 1063
Epihyal bone, 452
Epimysium, 29
Epineurium, 780
Epiotic centre of temporal bone, 213
Epiphyses, 163
atavistic, 25
pressure, 25
traction, 25
Epiphysial cartilage, 23
Epiploic foramen, 139, 1139
Episcleral space, 1013
Epispadias, 1207, 1211
Episternal bone, 187
centres, 187
Epistropheus or axis, 168
ossification of, 180
Epithalamus, 94, 836
fasciculus retroflexus of Meynert, 836
ganglion habenulæ, 836
habenular commissure, 836
pineal body, 836
applied anatomy of, 837
structure of, 836
posterior commissure, 837
nucleus of, 837
trigonum habenulæ, 836
Epithelial cells, 4
sheath, 1109
Epithelium, 4
ciliated, 5
columnar, 4
corneal, 996
Epithelium (*cont.*)
cylindrical, 4
enamel, 1107
genital, 153
pavement, 4
pigmented, 13
simple squamous, 4
stratified, 6
transitional, 7, 1207
Epitrichium, 83
Epitympanic recess, 209, 1027
Eponychium, 85, 1055
Epoöphoron, 151, 1229
Epulis, 1095
Equator of achromatic spindle, 2
of lens, 1007
Equatorial plate, 2
Erb's paralysis, 946
Erector clitoridis, 492
penis, 489
spinæ or sacrospinalis, 457
Eruption of the teeth, 1110
Erythroblasts, 19
Erythrocytes, 26
Ethmoidal air-sinuses, 221, 991
arteries, 627
bone, 220
alar processes of, 221
conchæ of, 222, 223
crista galli of, 221
labyrinth or lateral mass of, 221
lamina cribrosa of, 221
lamina papyracea of, 222
lamina perpendicularis of, 221
os planum of, 222
ossification of, 224
uncinate process of, 222, 266
canals, 219, 221
foramina, 258, 260
nerve, anterior, 894
posterior, 895
notch, 219
process of inferior nasal concha, 225
spine, 210
sulcus, 226
Eustachian tube, 1030
valve, 582, 740
Excavation, of optic nerve, 1003
recto-uterine, 1136, 1234
rectovesical, 1136
vesico-uterine, 1232
Excision of elbow, 390
hip, 410
knee, 419
maxilla, 273
shoulder, 383
Excretory, apparatus of the liver, 1188
Exner, plexus of, 868
Exophthalmos, 1015
Exoskeleton, 163
Exosmosis, 27
Extensor carpi radialis brevis, 514
longus, 513
ulnaris, 514
coccygis, 461
digiti quinti proprius, 514
digitorum brevis, 560
communis, 514
longus, 550

CC-0.In Public Domain. Gurukul Kangri Collection, Haridwar

Digitized by Arya Samaj Foundation Chennai and eGangotri

Extensor hallucis brevis, 560
longus, 550
indicis proprius, 518
ossis metacarpi pollicis, 516
pollicis brevis, 517
longus, 517
Extensor tendons of thumb, applied anatomy of, 518
Exterior of skull, 247
External capsule of brain, 860
Exteroceptive sensory impulses, 874
Extraperitoneal connective tissue, 481
Extremities, 274
bones of the inferior, 306
of the superior, 274
Extrinsic muscles of tongue, 1115
Extroversion of bladder, 317, 1207
Eyeball, or bulb of the eye, 993
accessory organs of, 1010
applied anatomy of, 1008, 1015
aqueous humour, 1006
capsule of Tenon, 1013
chambers of, 1000
chorioid, 997
ciliaris muscle, 999
ciliary body, 998
processes, 998
conjunctiva, 1018
cornea, 995
crystalline lens, 1006
development of, 101
fascia bulbi, 1013
fibrous tunic, 993
filtration or iridial angle, 995
iris, 999
membrana pupillaris, 104, 1001
ocular muscles, 1010
optic axis, 993
orbiculus ciliaris, 998
orbital fascia, 1015
poles of, 993
pupil, 999
refracting media, 1006
retina, 1001
pigmented layer of, 1003
supporting framework of, 1005
retina proper, 1003
sclera, 993
surface anatomy of, 1269
tunics of, 993
vascular tunic, 997
vitreous body, 1006
Eyebrows, 1015
Eyelashes, 1016
Eyelids, 1015
applied anatomy of, 1020
development of, 105
muscles of, 438
structure of, 1016
surface anatomy of, 1269
tarsi of, 1016
Eye-teeth, 1103

Face, bones of, 230
development of, 78
length of, 271
lymphatic vessels of, 754
surface anatomy of, 1264
width of, 271
Facial artery, 612
transverse, 616
Facial bones, 230
canal, hiatus of, 210, 261
prominence of, 1030
hemiatrophy, progressive, 982
lymph-glands, 752
deep, 752
nerve, 907
motor root, 908
sensory root, 908
applied anatomy of, 912
nucleus of, 813
palsy, 912
vein, anterior, 710
applied anatomy of, 710
common, 710
deep, 710
Facial vein, posterior, 711
transverse, 711
Falciform ligament of liver, 1134, 1185
margin of fossa ovalis, 534
cornua of, 534
process of sacrotuberous ligament, 399
Fallopian tubes, 1230
False amnion, 60*
ligaments of bladder, 1205
ribs, 188
vocal cords, 1066
Falx cerebelli, 880
cerebri, 879
primitive, 97
inguinal aponeurotic, 476
Fascia of abdomen, 469
of Abernethy, 531
anal, 483, 485
of ankle, 558
of anterolateral region of neck, 447
antibrachial, 517
axillary, 496, 642
bicipital, 504
brachial, 502
buccopharyngeal, 448
bulbi, 1013
of Camper, 470
cervical, deep, 447
applied anatomy of, 449
superficial, 447
of Colles, 470, 487
colli, 447
applied anatomy of, 449
coracoclavicular, 498
cremasteric, 475, 1218
cribrosa, 533
cruris, 549
deep, 435
of deltoideus, 500
dentata hippocampi, 852, 872
diaphragmatic part of pelvic, 483
dorsalis pedis, 560
of forearm, 507
general description of, 435
of the head, 436
iliaca, 530
iliopectineal, 531
inferior of urogenital diaphragm, 489
infraspinata, 501
infundibuliform, 481, 1218
intercrural, 472, 1218
lacrimal, 1020
lata, 533
fossa ovalis of, 534
falciform margin of, 534
iliotibial tract or band of, 534
Fascia of leg, 549
deep transverse, 549, 553
lumbodorsal, 457
nuchal, 457
of obturator internus, 482
orbital, 1015
parotideomasseteric, 448
pectoral, 496
pelvic, 482
pharyngobasilar, 1124
pretracheal, 449
prevertebral, 448
propria of femoral hernia, 1175
of piriformis, 483
of psoas and iliacus, 530
applied anatomy of, 532
of quadratus lumborum, 481
Fascia, rectovesical, 1224*
renal, 1195
of Scarpa, 470
Sibson's, 1079
spermatic, external, 472, 1218
subscapular, 501
superficial, 435
superior, of urogenital diaphragm, 490
supraspinata, 501
temporal, 444
of thigh, 533
of thoracic region, 496
transversalis, 480
triangular, 473
of trunk, 456
of upper extremity, 492
of urogenital diaphragm, 489, 490
in female, 492
of urogenital region, 489
Fasciæ, general description of, 435
Fasciculated bladder, 1208
Fasciculi, intrafusal, 1050
superficial transverse of hand, 522
Fasciculus—
anterior basis bundle, 794
anterolateral, superficial, 795
of Burdach, 795
cerebellar, direct, 795
cerebro-olivary, 808
cerebrospinal, anterior, 793
lateral, 794
uncrossed, 794
cingulum, 866
comma-shaped, 796
cornucommissural, 796
crossed pyramidal, 794
cuneatus, 795, 805
direct cerebellar, 795, 806
direct pyramidal, 793
dorsal peripheral band, 796
of Flechsig, 795
of Goll, 795
of Gowers, 795
gracilis, 795
of Helweg, 795
inferior longitudinal, 867
lateral basis bundle, 795
of Lissauer, 795
longitudinal of pons, 813
of posterior column, 791
mamillotegmental, 838
mamillothalamic, 834, 838, 862
medial longitudinal, 806, 827

CC-0. In Public Domain. Gurukul Kangri Collection, Haridwar

Digitized by Arya Samaj Foundation Chennai and eGangotri

Fasciculus (*cont.*)
medial longitudinal, nucleus of, 827
of Monakow, 794
motor, 873
occipitofrontal, 867
olfactory, 862
olivocerebellar, 808
olivospinal, 795
oval area of Flechsig, 797
perpendicular, 867
posterior, 795
longitudinal, 806, 827
proprius anterior, 794, 806
lateralis, 795, 806
pyramidal, crossed, 794
direct, 793
retroflexus of Meynert, 836
rubrospinal 794, 827
sensory, 874
solitarius, 809, 915
spinocerebellar, anterior, 795
spino-olivary, 808
spinotectal, 795
spinothalamic, anterior, 794
lateral, 795
superficial anterolateral, 795
superior longitudinal, 866
tectospinal, 794
thalamo-olivary, 835
triangular strand, 797
uncinate, 866
uncrossed lateral cerebrospinal, 794
vestibulospinal, 794
Fasciola cinerea, 852
Fat or adipose tissue, 9
cells, 9
Fatty capsule of kidney, 1194
Fauces, 1118
arches or pillars of, 1118
Female genital organs, 1226
bulb of vestibule, 1240
carunculæ hymenales, 1239
clitoris, 1239
development of, 149
epoöphoron, 1229
external, 1238
Fallopian tubes, 1230
fourchette, 1239
greater vestibular glands, or glands of Bartholin, 1240
hymen, 1239
internal, 1226
labia majora, 1238
minora, 1238
mons pubis, 1238
navicular fossa, 1239
ovaries, 1226
paroöphoron, 1229
uterine tubes, 1230
uterus or womb, 1231
vagina, 1237
vestibule, 1239
Female pronucleus, 42
urethra, 1211
Femoral artery, 687
applied anatomy of, 691
branches of, 693
peculiarities of, 691
surface marking of, 1311
canal, 689
circumflex artery, lateral or external, 693
medial or internal, 694
cutaneous nerve, intermediate, 956
Femoral cutaneous nerve, lateral, 955
medial, 956
posterior, 960
fossa, 689
fovea, 1173
hernia, 1174
muscles, anterior, 533
medial, 538
posterior, 547
nerve, 956
applied anatomy of, 967
ring, 689
septum, 689
sheath, 687
triangle, 689, 1310
vein, 736
Femur, 317
applied anatomy of, 326
condyles of, 323
fractures of, 326, 566
head of, 318
neck of, 318
ossification of, 325
structure of, 324
surface anatomy of, 1302
trochanters of, 319, 320
Fenestra basalis, 76
Fenestra vestibuli or ovalis, 1029
Fenestræ narinæ, 75
cochleæ or rotunda, 1029, 1038
Fenestrated membrane, 12
Fertilisation of ovum, 46
Fibræ propriæ of cerebellum, 819
Fibre-laminæ of cerebral cortex, 868, 869
Fibres, external arcuate, 811
internal arcuate, 805
association or arcuate, of cerebellum, 819
of cerebrum, 866
of medulla spinalis, 792
cerebrospinal, of internal capsule, 860
clinging or tendril, of cerebellum, 821
commissural, of cerebellum, 819
of cerebrum, 866
corticostriate, 858
corticothalamic, 834
crossed commissural, 790
dentinal, 1105
enamel, 1106
frontopontine, 827
geniculate, of internal capsule, 859
intercolumnar, 472
intercrural, 472
internal arcuate, 805
intersegmental of medulla spinalis, 792
intrafusal, 1050
moss, of cerebellum, 821
muscular, 29, 32, 33
nerve, 37
osteogenetic, 22
perforating, of bone, 21
projection, of cerebellum, 818
of cerebrum, 866
of Purkinje, 33
radial, of cerebral cortex, 869
of Remak, 39
sustentacular, of Müller, 1005
tangential, of cerebral cortex, 869
Fibres of Tomes, 1105
transverse, of cerebrum, 866
of pons, 812
uncrossed lateral cerebrospinal, 794
white, of areolar tissue, 7
yellow or elastic, 8
Fibrinoid substance of placenta, 65
Fibrocartilage, circumferential, 17
connecting, 16
interarticular, 16
sacrococcygeal, 361
stratiform, 17
white, 16
yellow or elastic, 17
Fibrocartilages, 351
intervertebral, 358
applied anatomy of, 359
structure of, 359
semilunar of knee, 414
Fibrocartilaginous lamina, interpubic, 400
ring of tympanic membrane, 1028
Fibrous pericardium, 576
rings of heart, 587
sheaths of flexor tendons of fingers, 510
of toes, 563
stratum of articular capsule, 351
tissue, white, 10
tunic of eyeball, 993
cornea, 995
sclera, 993
Fibula, 330
applied anatomy of, 333
fractures of, 333, 568
ossification of, 333
surface form of, 1301
Fibular artery, 705
collateral ligament of knee joint, 413
intermuscular septa, 549
notch, 328
Fifth lumbar vertebra, 174
metacarpal bone, 304
metatarsal bone, 342
Fillet or lemniscus, 805, 828
decussation of, 805
lateral, 829
mesial, 829
Filtration angle of eye, 995
applied anatomy of, 1009
Filum terminale, 87, 785, 884
Fimbria hippocampi, 863
ovarian, 1230
Fimbriæ of uterine tube, 1230
Fimbriated end of uterine tube, 1230
Fimbriodentate fissure, 852, 863
Finger-prints, 1052
First cervical vertebra, 167
cervical nerve, anterior division, 931
posterior division, 928
cuneiform bone, 342
ossification of, 347
metacarpal bone, 303
metatarsal bone, 345
plantar interosseous muscle, 565
rib, 191
thoracic vertebra, 171
volar interosseous muscle,

CC-0. In Public Domain. Gurukul Kangri Collection, Haridwar

Digitized by Arya Samaj Foundation Chennai and eGangotri

Fissura antitragohelicina, 1023
prima of cerebellum, 92, 815
of olfactory lobe, 852
rostroventralis, 76
secunda of cerebellum, 92
vestibuli, 1038
Fissure, anterior median, of medulla oblongata, 800
chorioidal, of brain, 865
of optic cup, 102
external rhinal, 95
fimbriodentate, 852, 863
floccular, 92
Glaserian, 208, 1028
orbital, inferior, 253, 259
superior, 203, 259, 261
petro-occipital, 251, 263
petrosphenoidal, 250
petrotympanic, 208, 250, 1028
porta hepatis, 1183
postnodular, 92
pterygoid, 204
pterygomaxillary, 254
sphenomaxillary, 253
transverse of brain, 866
of liver, 1183
tympanomastoid, 250
Fissures and sulci of medulla spinalis, 787
Fissures of cerebellum, 814
development of, 92
floccular, 92
horizontal, 815
postcentral, 815
postnodular, 92, 816
postpyramidal, 816
precentral, 815
preclival, 815
prepyramidal, 816
of cerebral hemisphere, 844
development of, 99
calcarine, 845
callosal, 850, 852
collateral, 845
external rhinal, 95
fimbriodentate, 852, 863
hippocampal, 97, 851
interlobar, 844
lateral cerebral, 99, 845, 1263
longitudinal, 834
parieto-occipital, 845
of Rolando, 845, 1263
of Sylvius, 99, 845
transverse, of brain, 866
congenital, of cranium, 229
of lungs, 1087
of medulla oblongata, 800
Fixation muscles, 434
Fixed vertebræ, 164
Flat bones, 163
Flat-foot, 427, 432
Flechsig, direct cerebellar tract of, 795
oval area of, 797
Flexor accessorius, 563
carpi radialis, 508
ulnaris, 509
digiti quinti brevis of foot, 565
of hand, 526
digitorum brevis, 563
longus, 554
profundus, 510
sublimis, 509
hallucis brevis, 565
longus, 553
Flexor pollicis brevis, 523
longus, 511
Flexure, cervical, of brain, 90
duodenal, inferior, 1154
superior, 1154
duodenojejunal 1154, 1155
hepatic, 1165
left colic, 1162, 1166
perinæal, of rectum, 1168
pontine, 90
right colic, 1162, 1166
sacral, of rectum, 1168
sigmoid, 1162
splenic, 1166
ventral cephalic, 90
Floating kidney, 1199
ribs, 189
Floccular fissure, 92
Flocculus, 816
Floor of fourth ventricle, 824
Floor-plate, 85
Fluid, amniotic, 61
cerebrospinal, 883
vitelline, 56
Fluids, circulating, 26
blood, 26
lymph, 29
Fœtal circulation, 592
heart, peculiarities of, 592
membranes, 58
Fœtal portion of placenta, 64
Fœtus, circulation in, 592
foramen ovale in, 115, 592
peculiarities of vascular system in, 592
valve of inferior vena cava in, 582, 592
Fold or Folds—
alar, of synovial stratum of knee-joint, 411
amniotic, 60*
aryepiglottic, 1066
bloodless, of Treves, 1146
caudal, 55
cephalic, 55
circular, of small intestine, 1158
duodenal, inferior, 1145
superior, 1145
epigastric, 1173
glosso-epiglottic, 1062
iliocæcal, inferior, 1146
inguinal, 154
malleolar, 1028
neural, 52
palmate, of cervix uteri, 1233, 1236
paraduodenal, 1145
patellar, 411
pharyngo-epiglottic, 1062
recto-uterine, 1234
rectovesical, 1138
sacrogenital, 1138, 1234
salpingopalatine, 1123
salpingopharyngeal, 1123
transverse, of rectum, 1168
umbilical, 1173, 1205
urogenital, 150
ventricular, of larynx, 1066
vestigial, of Marshall, 128, 576, 709
vocal, of larynx, 1067
Folia linguæ, 1112
Folium vermis or cacuminis, 816
Follicle of hair, 1056
Follicles, Graafian, or vesiculæ ovarian, 1228
Fontana, spaces of, 997
Fontanelles, 267
Fonticulus, frontal, 267
mastoid, 268
occipital, 267
sphenoidal, 268
Foot, arches of, 431
applied anatomy of, 432
bones of, 334
applied anatomy of, 349
dorsal fascia of, 560
muscle of, 560
muscles of, 560
ossification of bones of, 347
plantar muscles of, 561
skeleton of, 334
applied anatomy of, 349
surface anatomy of, 1303
Foot-drop, 969
Foramen bursæ omenti majoris, 1140
cæcum of frontal bone, 218, 260
of medulla oblongata, 800
of tongue, 134, 1111
caroticoclinoid, 204, 261
condyloid, anterior, 199
epiploic, 139, 1139
frontal, 217
of Huschke, 212, 214
incisive, 234, 247
infra-orbital, 230, 256
interventricular, 863
jugular, 250, 263
lacerum, 203, 250, 261
magnum, 196, 199, 251, 260
of Majendie, 823, 882
mandibular, 242
mastoid, 208, 251, 255, 264
mental, 241, 257
of Monro, 842, 863
nutricium, 19
obturator, 312
optic, 200, 204, 259, 261
ovale of heart, 115, 592
of sphenoidal bone, 203, 250, 253, 261
palatine, greater, 249
parietal, 215, 247, 260
rotundum, 203, 254, 261
sciatic, greater, 399
lesser, 400
singulare, 211
sphenopalatine, 237, 265
spinosum, 203, 250, 253, 261
sternal, 185
stylomastoid, 212, 250
supra-orbital, 217, 256, 259
supratrochlear, 285
transversarium, 166
vena-caval, in diaphragm, 466
vertebral, 164
Vesalii, 203, 261
of Winslow, 139, 1139
zygomaticofacial, 239, 256
zygomaticotemporal, 239, 251
Foramina, ethmoidal, 258, 260
intervertebral, 164
palatine, lesser, 238, 249
parietal, 260
in roof of fourth ventricle, 823
sacral, anterior, 174
posterior, 175
of Stahr, 234, 248
of Stensen, 234, 247

CC-0. In Public Domain. Gurukul Kangri Collection, Haridwar

Digitized by Arya Samaj Foundation Chennai and eGangotri

Foramina venarum minimarum, 582, 585
zygomatico-orbital, 240
Forceps, anterior, 854
posterior, 854
Forearm, muscles of, 507
veins of, 725, 727
Forebrain, 53, 93, 799, 831
Foregut, 55, 132
Foreskin or prepuce, 1222
Form of embryo at different stages, 159
Formatio reticularis of medulla oblongata, 811
of medulla spinalis, 789
Formation of mesoderm, 49
of embryo, 54
Formative yolk, 40
Fornices of vagina, 1237
Fornix of brain, 861, 867
body of, 862
columns of, 862
crura of, 863
development of, 99
psalterium or lyra of, 862
ventricle of, 862
conjunctival, 1018
Fossa or fossæ—
acetabular, 311
anterior, of skull, 260
canine, 230, 256
cochlearis, 1036
condyloid, 199, 251
coronoid, 285
cubital, 649
digastric, of mandible, 241
of temporal bone, 209, 250
digital, of epididymis, 1212
duodenal, 1145
for ductus venosus, 1183
duodenal, inferior, 1145
superior, 1145
duodenojejunal, 1145
femoral, 689
for gall-bladder, 1183
glenoid, 207
hyaloid, 1006
hypophyseos, 200, 261
ileocæcal, inferior, 1146
superior, 1146
iliac, 309
incisive, 230, 241, 257
incudis, 1030
for inferior vena cava, 1183
infraclavicular, 497
infraspinatous, 274
infratemporal, 253
intercondyloid, of femur, 323
of tibia, 327
interpeduncular, 825, 842
intersigmoid, 1146
ischiorectal, 486
jugular, 212
lacrimal, 218, 225, 233, 257, 258
of liver, 1182
mandibular, 207, 250, 253
mesocolic, 1145
middle, of skull, 260
navicularis of urethra, 1210
of vestibule, 1239
occipital, inferior, 264
olecranon, 285
ovalis of heart, 582
of fascia lata, 534
ovarian, 1138, 1226
paraduodenal, 1145
pararectal, 1137
Fossa or fossæ (*cont.*)
paravesical, 1138, 1202
peritoneal, 1144
applied anatomy of, 1146
popliteal, 695
posterior, of skull, 261
pterygoid, 204
pterygopalatine, 254
radial, 285
retrocæcal, 1146
retroduodenal, 1145
rhomboid, 824
of Rosenmüller, 78, 1123
sagittal, of liver, 1182
scaphoid, 204
of skull, 260
anterior, 260
middle, 260
posterior, 261
sphenomaxillary, 254
subarcuata, 211, 264
subscapular, 274
supraspinatous, 274
supratonsillar, 1118
Sylvian, 99
temporal, 251
triangularis, 1022
trochanteric, 319
for umbilical vein, 1183
vermian, 197
Fountain decussation of Meynert, 831
Fourchette, 1239
Fourth metacarpal bone, 304
metatarsal bone, 346
ventricle, 822
angles of, 822
chorioid plexuses of, 823
floor of, 824
lateral boundaries of, 823
ligulæ of, 823
rhomboid fossa of, 824
roof or dorsal wall of, 823
openings in, 823
tæniæ of, 823
tela chorioidea of, 823
Fovea capitis femoris, 318
centralis retinæ, 1002, 1005
structure of, 1005
dentis, 167
femoral, 1173
inferior, of rhomboid fossa, 825
inguinal, lateral, 1173
medial, 1173
pterygoid, 243
superior, of rhomboid fossa, 825
supravesical, 1173
trochlearis, 218, 257
Foveola, Howship's, 24
Fracture, 'greenstick,' 282
Fracture-dislocations of vertebral column, 184
Fracture or fractures of—
acromion, 528
bones of foot, 349
of forearm, 294, 529, 530
of hand, 306
of leg, 333
carpal bones, 306
clavicle, 281, 527, 528
Colles, 295, 530
femur, 326, 566
fibula, 333, 568
humerus, 286, 528
mandible, 273
tibia, 333
Fracture or fractures of (*cont.*)
metatarsal bones, and phalanges, 349
nasal bone, 273
olecranon, 294, 529
patella, 334, 568
pelvis, 317
Pott, 568
radius, 295, 529, 530
ribs, 194
scapula, 279
skull, 272
sternum, 194
tarsal bones, 349
tibia, 333, 568
ulna, 294, 530
zygomatic arch, 273
bone, 273
Free nerve-endings, 1048
Freely movable joints, 353
Fremitus, vocal, 1092
Frenula of colic valve, 1164
of lips, 1094
Frenulum of clitoris, 1239
of labia minora, 1239
linguæ, 1112
of prepuce, 1222
veli, 817, 829
Frommann's lines, 38
Frontal air-sinuses, 219, 991, 1264
arteries, 616, 628
bone, 217
nasal part of, 217
orbital part of, 218
ossification of, 220
squama of, 217
structure of, 220
crest, 218, 260
Frontal eminence, 217, 247, 251
fonticulus, 267
foramen, 217
gyri, 847
lobe, 846
nerve, 893
notch (or foramen), 217
operculum, 849
process of maxilla, 232
spine, 217
sulci, 846
suture, 217, 247, 256
tuberosity, 217, 247, 251, 255
vein, 709
Frontalis, 437
Fronto-ethmoidal suture, 258, 260
Frontolacrimal suture, 256, 258
Frontomaxillary suture, 256, 258, 259
Frontonasal duct, 220, 266
process, 78
suture, 256
Frontoparietal operculum, 849
Frontopontine fibres, 827
tract, 859
Frontosphenoidal process of zygomatic bone, 239
suture, 258
Fundiform ligament of penis, 470, 1221
Fundus of stomach, 1148
glands of, 1152
tympani, 1027
of urinary bladder, 1202
of uterus, 1232
Funicular process, hernia into, 1174

CC-0. In Public Domain. Gurukul Kangri Collection, Haridwar

Digitized by Arya Samaj Foundation Chennai and eGangotri

Funiculi of medulla spinalis—
anterior, 793
lateral, 794
posterior, 795
Funiculus, nerve, 780
separans, 825
spermaticus, 1218
Funnel-breast, 195
Furcal nerve, 951
Furcula, 134, 145
Furrow, dental or labiotectal, 1106
iliac, 1281
naso-optic, 79, 105
sternal, 1276
Furrowed band of cerebellum, 817
Fusiform gyrus, 849

Galactocele, 1242
Galea aponeurotica, 437
Galen, veins of, 717
vena magna of, 717
Gall-bladder, 1189
applied anatomy of, 1191
fossa for, 1183
lymphatic vessels of, 771
structure of, 1190
surface marking of, 1287
Ganglion or ganglia, 782
aberrant, 926
aorticorenal, 979
basal, 859
cardiac, of Wrisberg, 979
carotid, 973
cervical, inferior, 975
middle, 975
superior, 974
ciliary, 895
coccygeal, 978
cœliac, 979
compound palmar, 523
of Corti, 1047
Gasserian, 892
genicular, 910
of glossopharyngeal, 916
habenulæ, 836
impar, 978
interpeduncular, 827
jugular, of glossopharyngeal, 916
of vagus, 917
Langley's, 1100
Meckel's, 898
mesenteric, inferior, 981
superior, 981
nodosum, of vagus, 918
otic, 903
petrous, 916
phrenic, 935, 979
of root of vagus, 917
of Scarpa, 1047
semilunar, of abdomen, 979
of trigeminal nerve, 889
sphenopalatine, 898
spinal, 925
structure of, 926
spiral, of cochlea, 913, 1047
splanchnicum, 976
stellate, 978
structure of, 782
submaxillary, 903
superior, of glossopharyngeal, 916
of trunk of vagus, 918
uterine cervical, 982
vestibular, 913, 1047
of Wrisberg, 979
Ganglion-ridge, 52, 88
Ganglionic arteries, anterolateral, 630
anteromedial, 629
posterolateral, 638
posteromedial, 630, 638
arterial system of brain, 631
branches of middle meningeal artery, 618
layer of retina, 1003
Gärtner, duct of, 151, 1229
Gasserian ganglion, 892
Gastric arteries, short, 669
artery, left, 667
right, 668
canal, 138, 1149
glands, 1151
impression, 1185
lymph-glands, superior, 765
inferior, 766
nerves from vagus, 921
plexus, anterior, 921
inferior, 980
posterior, 921
superior, 981
veins, short, 742
Gastric vein, right, 744
Gastrocnemius, 551
applied anatomy of, 558
Gastrocolic ligament, 1134
Gastroduodenal artery, 668
Gastro-enterostomy, 1153
Gastro-epiploic artery, left, 669
right, 668
vein, left, 742
right, 744
Gastrolienal ligament, 1139, 1253
Gastropancreatic ligament, 1140
Gastrophrenic ligament, 1148
Gastrosplenic omentum, 1139
Gastrostomy, 1153
Gastrotomy, 1153
Gemellus inferior, 546
nerve to, 958
superior, 546
nerve to, 958
General sensations, peripheral terminations of nerves of, 1048
Generative organs, development of, 149, 158
Genicular artery, highest, 695
inferior, 699
middle, 699
superior, 698
ganglion of facial nerve, 910
Geniculate body, lateral, 835
medial, 835
fibres of internal capsule, 859
Geniculum of facial nerve, 909
Genioglossus, 1115
Geniohyoideus, 453
Genital branch of genitocrural nerve, 953
Genital cord, 151
cords, 153
corpuscles, 1048
epithelium, 153
glands, 153
organs of female, 1226
external, 1238
of male, 1212
ridge, 153
swellings, 159
tubercle, 159
Genitals, external, lymphatic vessels of, 769
Genitofemoral (genitocrural) nerve, 953
Gennari, band of, 869
Genu of corpus callosum, 853
of internal capsule, 859
Gerlach, tube-tonsil of, 1031
Germ, common dental, 1106
special dental, 1107
Germ-centres of lymph-glands, 747
of palatine tonsils, 1119
Germinal cells, 40
spot, 40, 41
vesicle, 40, 41
Gestation, ectopic, 1231
Giacomini, band of, 852
Giant-cells of Betz, 869
Gianuzzi, crescents of, 1100
Gimbernat's ligament, 473
Gingivæ, 1094
Ginglymus, 354
Giraldes, organ of, 1217
Girdle, of inferior extremities, 274
pelvic, 274
shoulder, 274
of superior extremities, 274
Glabella, 217, 256, 269
Gland or glands—
accessory, of mouth, 1101
part of parotid, 1096
thyreoid, 1245
anterior lingual, 1117
areolar, 1241
arytænoid, 1071
of Bartholin, 158, 1240
of Blandin, 1117
of Bowman, 990
of Brunner, 1160
buccal, 1094
bulbo-urethral, 158, 1226
cardiac, of stomach, 1151
ceruminous, 1026
ciliary, 1016
of Cowper, 158, 1226
development of, 84
ductless, 1243
duodenal, 1160
fundus, of stomach, 1152
gastric, 1151
genital 153
greater vestibular, 158, 1240
intestinal, 1160
labial, 1094
lacrimal, 1018
accessory, 1018
of larynx, 1071
lenticular, of stomach, 1152
of Littré, 1210
mammary, 1240
development of, 84
Meibomian, 1017
molar, 1094
of Nuhn, 1117
œsophageal, 1130
oxyntic, 1151
parathyreoid, 1246
development of, 135
parotid, 1096
Peyer's, 1160
preputial, 1222
pyloric, of stomach, 1152
salivary, 1096
development of, 134
sebaceous, 1057
development of, 84

CC-0. In Public Domain. Gurukul Kangri Collection, Haridwar

Digitized by Arya Samaj Foundation Chennai and eGangotri

Glands or glands (*cont.*)
spleen or lien, 1252
sublingual, 1099
submaxillary, 1098
sudoriferous, 1057
development of, 84
suprarenal, 1250
development of, 101
sweat, 1057
development of, 84
tarsal, 1017
thymus, 1247
development of, 135
thyreoid, 1243
development of, 134
of tongue, 1117
trachoma, 1018
urethral, 1210, 1211
uterine, 1236
vestibular, greater, 158, 1240
Glandulæ Pacchionii, 882
Glans clitoridis, 1239
penis, 1221, 1222
neck of, 1222
Glaserian fissure, 208, 1028
Glaucoma, 1009
Glenohumeral ligaments, 379
Glenoid cavity, 278
fossa, 207
ligament of shoulder, 380
ligaments of Cruveilhier, 396, 430
Glenoidal labrum of hip-joint, 406
of shoulder-joint, 380
Gliding movement, 354
Glisson's capsule, 1142, 1186
Globular processes, 79
Globus major of epididymis, 1212
minor, 1212
pallidus, 858
Glomera carotica, 101, 605, 1249
structure of, 1250
Glomerular arteries of kidney, 1199
Glomeruli of kidney, 1197
of olfactory bulb, 872
Glomus caroticum, 605
coccygeum, 1252
Glosso-epiglottic fold, 1062, 1112
Glossopalatine arch, 1118
Glossopalatinus, 1120
Glossopharyngeal nerve, 915
motor fibres of, 916
sensory fibres of, 915
Glottis, respiratoria, 1067
vocalis, 1067
rima of, 1067
Glutæal aponeurosis, 542
artery, inferior, 682
applied anatomy of, 685
superior, 684
applied anatomy of, 685
surface markings of, 1310
branches of sacral plexus, 961
lines of ilium, 307, 308
muscles, 541
nerve, inferior, 960
superior, 959
tuberosity, 321
veins, 737
Glutæus maximus, 541
bursæ under, 542
medius, 542
minimus, 542
Gnathic index, 271
Goblet or chalice cells, 5
Goitre, 1246
Golgi, cells of, 35, 869
organs of, 1050
reticular apparatus of, 2
Golgi and Mazzoni, corpuscles of, 1050
Goll, tract of, 795
Gomphosis, 353
Gonion, 270
Gonorrhœa, 1210
Gower's anterolateral fasciculus, 795
Graafian follicles, 1228
Gracile nucleus, 803
Gracilis, 538
Grandry, tactile corpuscles of, 1049
Granular layer of Tomes, 1105
lids, 1008
Granulations, arachnoideal, 882
Granule-cells, 9
Granules, basiphil, 28
Greenstick fracture, 282
Grey commissures of medulla spinalis, 788
Grey nerve-substance, 34
Grey or middle commissure of brain, 883
Grey substance of cerebellum, 819
of cerebral hemisphere, 867
of cerebral cortex, 867
of medulla oblongata, 806
of medulla spinalis, 788
Grey or gelatinous nerve-fibres, 39
Groove, auriculoventricular, 578
bicipital, 283
costal, 190
infra-orbital, 230, 258
interatrial, 578
lacrimal, 225
laryngotracheal, 145
musculospiral, 283
mylohyoid, 242
nasopalatine, 227
neural, 52
obturator, 311, 312
occipital, 209
olfactory, 260
optic, 200
primary labial, 133
primitive, 50
sacral, 175
secondary labial, 133
Grooves, branchial or outer pharyngeal, 76
vertebral, 184
Gubernaculum dentis, 1110
testis, 155
Gudden, commissure of, 841, 888
Gullet, 1128
Gum-boil, 1111
Gums, 1094
applied anatomy of, 1094
spongy, 1095
Gustatory calyculi, 983
cells, 983
hair, 983
pore, 983
Gut, post-anal, 142
rotation of, 141
Gyrus or gyri
angular, 848
Gyrus or gyri (*cont.*)
anterior central, 847
arcus parieto-occipitalis, 848
of Broca, 847
cingulate, 850
cuneus, 848
dentate, 852, 872
descending, of Ecker, 848
fasciola cinerea, 852
frontal, 847
fusiform, 849
hippocampal, 850
inferior parietal lobule, 848
of insula, 849
isthmus, 850
of limbic lobe, 850
lingual, 848
marginal, 847
occipital, 848
orbital, 847
paracentral lobule, 847
posterior central, 848
præcuneus, 848
quadrate lobe, 837, 848
rectus, 847
subcallosal, 852
superior parietal lobule, 848
supracallosal, 852
supramarginal, 848
temporal, 848
transverse temporal of Heschl, 848
uncus, 850

Habenular commissure, 836
Hæmatoma auris, 1026
Hæmorrhage, postpartum, 67
Hæmorrhoidal artery, inferior, 681
middle, 679
superior, 672
nerve, inferior, 966
plexus of nerves, middle, 982
superior, 981
vein, middle, 738
superior, 743
plexus of veins, 738, 1171
applied anatomy of, 739
Hair-bulb, 1056
Hair-cells of internal ear, 1041, 1045
Hair-follicle, 1056
dermic coat of, 1056
epidermic coat of, 1056
Hair-root, 1056
Hair-shaft, 1056
cortex of, 1057
medulla of, 1056
Hairs, 1055
development of, 84
gustatory, 983
olfactory, 989
Haller, vas aberrans of, 1217
Hamate bone, 302
ossification of, 305
Hamstring tendons, applied anatomy of, 548
Hamulus, of hamate bone, 302
lacrimal, 225
laminæ spiralis, 1038
pterygoid, 204
Hand, muscles of, 518
skeleton of, 298
surface anatomy of, 1292
veins of, 724, 727
Hard palate, 248, 1095

CC-0. In Public Domain. Gurukul Kangri Collection, Haridwar

Digitized by Arya Samaj Foundation Chennai and eGangotri

Hare-lip, 82
Harrison's sulcus, 195
Hasner, plica lacrimalis of, 1020
Hassall, concentric corpuscles of, 1249
Haversian canals of bone, 20
systems of bone, 20
Head, lymph-glands of, 751
lymphatic vessels of, 754
muscles of, 436
surface anatomy of, 1257
veins of, 709
Head and neck, arteries of, 605
Head-cap of spermatozoön, 43
Head-veins, primary, 128
Hearing, organ of, 1022
Heart, 577
actions of valves, 591
annulus ovalis of, 582
aortic orifice of, 586
semilunar valves of, 586
vestibule of, 586
apex of, 579
applied anatomy of, 591
atrial septum of, 580
atrioventricular orifice, left, 586
right, 583
bundle, 589
node, 589
base of, 578
bicuspid or mitral valve of, 586
cardiac cycle, 591
component parts of, 578
conus arteriosus of, 583
coronary arteries of, 598, 599
sinus of, 582
crista terminalis of, 581
development of, 110, 113
diaphragmatic surface of, 580
endocardium, 587
fibres of the atria, 588
of the ventricles, 587
fibrous rings of, 587
fossa ovalis of, 582
left atrium, 585
ventricle, 585
limbus fossæ ovalis of, 582
lymphatic vessels of, 778
margins of, 580
musculi pectinati of, 581, 585
musculi papillares of, 584, 587
nerves of, 591
os cordis, 587
pulmonary orifice of, 583
semilunar valves of, 584
right atrium, 580
ventricle, 583
septa of, 580
sino-atrial node, 589
size and weight, 578
sternocostal surface of, 579
structure of, 587
surface marking of, 1279
trabeculæ carneæ of, 584, 587
tricuspid valve of, 583
trigonum fibrosum, 587
ventricular septum of, 580
vessels of, 591
wounds of, 591
Heart-block, 591
Heat, cold and pain, area for, 871
Heberden's nodes, 306
Heidenhain, demilunes of, 1100
Height-index of skull, 270
Helicine arteries, 1222
Helicis major, 1024
minor, 1024
Helicotrema, 1037, 1038
Helix, 1022
Helweg, olivospinal fasciculus of, 795
Hemiazygos vein, 731
accessory, 731
Hemispheres, cerebellar, 814
cerebral, 843
Henle's loop, 1197
Henle's layer of hair-follicle, 1056
Hensen, canalis reuniens of, 1040, 1042
knot of, 50
line of, 30
stripe of, 1046
supporting cells of, 1045
Hepar, 1181
Hepatic artery, 667, 1188
Hepatic branches of vagus nerve, 921
cylinders, 143
duct, 1188
flexure of colon, 1165
lymph-glands, 766
plexus, 980
veins, 741, 1186
Hepatoduodenal ligament, 1134, 1141, 1186
Hepatogastric ligament, 1134, 1141, 1186
Hepatoptosis, 1191
Hepatorenal ligament, 1134, 1185
Herbst, corpuscles of, 1050
Hernia, 1173
congenital, complete, 1173
femoral, 1174
incomplete, 1175
into funicular process or incomplete congenital, 1174
inguinal, 1173
direct, 1174
oblique, 1173
of lung, 1091
scrotal, 1173
testis, 1216
Herophilus, torcular of, 197
Heschl, gyri of, 848
Hesselbach, interfoveolar ligament of, 477
triangle of, 687, 1174, 1289
Heterotypical mitosis, 3
Hiatus, aortic, 466
of facial canal, 210, 261
œsophageal, 466
sacralis, 175
semilunaris, 266, 987
Highmore, antrum of, 231, 992
Hilum of inferior olivary nucleus, 808
of kidney, 1193
of lung, 1086
of spleen, 1253
Hind-brain, 53, 90, 800
Hind-gut, 55, 132
Hinge-joint, 354
Hip-bone, 306
acetabulum, 311
obturator foramen, 312
os ilii, 306
ischii, 309
pubis, 310
ossification of, 312
structure of, 312
Hip-bone (*cont.*)
surface anatomy of, 1302
marking of, 1308
Hip-disease, 409
Hip-joint, 403
applied anatomy of, 409
movements of, 407
muscles in relation with, 406
Hippocampal commissure, 862
Hippocampal fissure, 97, 851
gyrus, 850
Hippocampus, 97, 857
structure of, 871
His, atrioventricular bundle of, 33, 589
globular processes of, 79
Histology, 1
Histrionic spasm, 913
Holoblastic ova, 48
Homotypical mitosis, 3
Horizontal cells of retina, 1004
circumference of skull, 270
part of palatine bone, 236
sulcus of cerebellum, 814
Hormones, 1243
Horny layer of epidermis, 1051
Housemaid's knee, 419
Houston's valves of rectum, 1168
Howship's foveola, 24
Huguier, canal of, 208, 911, 1028
Human ovum, 40
Humeral articulation, 378
applied anatomy of, 382
bursæ in relation to, 380
movements of, 381
vessels and nerves of, 380
circumflex artery, anterior, 647
posterior, 647
ligament, transverse, 380
Humerus, 282
applied anatomy of, 286, 528
fractures of, 286, 528
ossification of, 286
structure of, 286
surface anatomy of, 1293
Humour, aqueous, 1006
Hunter's canal, 689
Huschke, auditory teeth of, 1043
foramen of, 212, 214
Huxley's layer of hair-follicle, 1056
Hyaline cartilage, 15
cell, 28
Hyaloid artery, 104
canal, 104, 1006
fossa, 1006
membrane, 1006
Hyaloplasm, 1
Hydatid of Morgagni, 153, 1212, 1230
pedunculated, of epididymis, 1212
Hydatid cysts of liver, 1191
Hydrocele, 1216
Hydrothorax, 1080
Hygroma, congenital cystic, 748
Hymen, 1239
Hyo-epiglottic ligament, 1063
Hyoglossal membrane, 1117
Hyoglossus, 1115
Hyoid arch, 77
artery, 610, 611
bone, 246

CC-0. In Public Domain. Gurukul Kangri Collection, Haridwar

Digitized by Arya Samaj Foundation Chennai and eGangotri

Hyoid bone (*cont.*)
body of, 246
cornua of, 246
ossification of, 247
Hyothyreoid ligaments, 1064
membrane, 1064
Hyparterial bronchi, 1075, 1088
Hypernephroma, 1200, 1252
Hypochondriac regions of abdomen, 1133
Hypochordal bar, 69
Hypogastric artery, 592, 594, 678
applied anatomy of, 678
branches of, 679
changes in, at birth, 594
in fœtus, 592
peculiarities of, 678
lymph-glands, 764
plexus, 981
region of abdomen, 1133
vein, 737
Hypoglossal nerve, 923
applied anatomy of, 925
nucleus of, 806, 923
canal, 199, 251, 263
Hypophysial arteries, 626
part of skull, 72
Hypophysis, 135, 838
applied anatomy of, 840
development of, 135
lobes of, 839
structure of, 839
Hypospadias, 1211
Hypothalami, pars mamillaris, 94
pars optica, 95
Hypothalamus, 837
corpora mamillaria, 837
hypophysis or pituitary body, 135, 838
infundibulum, 838
optic chiasma, 840
subthalamic tegmental region, 838
corpus subthalamicum, 838
stratum dorsale, 838
zona incerta, 838
tuber cinereum, 838
Hypothenar eminence, 518

Ichthyoid blood-cells, 110
Ileal arteries, 670
branches of ileocolic artery, 672
lymph-glands, 767
Ileocæcal fossæ, 1146
fold, inferior, 1146
Ileocolic artery, 672
lymph-glands, 767
Ileum, 1156
lymphatic vessels of, 770
Iliac arteries, common, 676
applied anatomy of, 678
peculiarities of, 677
surface marking of, 1289
external, 685
applied anatomy of, 685
branches of, 686
surface marking of, 1289
internal, 678
applied anatomy of, 678
branches of, 679
peculiarities of, 678
branches of obturator artery, 680
circumflex artery, deep, 687
Iliac circumflex artery, superficial, 693
lymph-glands, 764
vein, deep, 737
superficial, 734
colon, 1167*
colostomy, 1175
fascia, 530
fossa, 309
furrow, 1281
lymph-glands, common, 763
external, 763
regions of abdomen, 1133
muscles of, 530
spines, 309
tuberosity, 309
Iliac vein, common, 739
peculiarities of, 739
external, 737
right, 739
internal, 737
left, 739
Iliacus, 532
fascia covering, 531
Iliococcygeus, 485
Iliocostalis cervicis, 458
dorsi, 458
lumborum, 458
Iliofemoral ligament, 405
Iliohypogastric nerve, 952
Ilio-inguinal nerve, 952
Iliolumbar artery, 682
ligament, 398
Iliopectineal eminence, 309, 310, 311
fascia, 531
Iliopsoas, 532*
Iliosacralis, 485
Iliotibial band or tract, 534
Iliotrochanteric ligament, 405
Ilium, 306
ala of, 307
body of, 306
crest of, 309
dorsum of, 307
glutæal lines of, 307, 308
Ilium, spines of, 309
Imbedding or implantation of fertilised ovum, 62
Immovable articulations, 352
Impression, cardiac, on liver, 1184
on lung, 1086
colic, 1185
duodenal, 1185
gastric, 1185
œsophageal, 1185
renal, 1185
rhomboid, 281
suprarenal, 1184
trigeminal, 210
Incisive bone, 234
canals, 234, 242, 247
foramen, 234, 247
fossa, 230, 241, 257
Incisivus labii inferioris, 443
superioris, 443
Incisor crest, 235
Incisor teeth, 1102
Incisors, 1102
Incisura angularis of stomach, 1147
apicis cordis, 578
cardiaca, 1147
cervicalis, 319
fastigii, 92
Incisura pancreatis, 1178
temporalis, 850
tentorii, 879
umbilicalis, 1183
Incisures of medullary nerve-sheath, 38
Incus, 1032
body, 1032
crura, 1032
development of, 108
lenticular process, 1032
ligaments of, 1032
ossification of, 1032
Index, cephalic or breadth, 271
dental, 271
gnathic or aveolar, 271
nasal, 271
orbital, 271
vertical or height, 270
Indirect division of cells, 2
Indusium griseum, 852
Infantile hydrocele, 1216
paralysis, 25, 798
Inferior transverse ligament, of distal tibiofibular articulation, 420
of scapula, 378
Infraclavicular branches of brachial plexus, 937
fossa, 497
Infraglenoid tuberosity, 277
Infrahyoid lymph-glands, 753
muscles, 453
Infra-orbital artery, 620
canal, 231, 258
foramen, 230, 256
groove, 230, 258
lymph-glands, 752
nerve, 896*
plexus of nerves, 897, 912
process of zygomatic bone, 240
Infrapatellar branch of saphenous nerve, 957
pad of fat, 411
Infrascapular artery, 647
Infraspinatous fossa, 274
Infraspinatus, 501
Infrasternal notch, 1276
Infratemporal crest, 203
fossa, 253
Infratrochlear nerve, 895
Infundibula of lungs, 1089
Infundibuliform fascia, 481, 1218
Infundibulopelvic ligament, 1234
Infundibulum of brain, 838
of ethmoidal bone, 224, 266, 987
of uterine tube, 1230
Infusion, intravenous, 727
Inguinal aponeurotic falx, 476
canal, 481
crest, 154
fold, 154
fovea, lateral, 1173
medial, 1173
hernia, 1173, 1174
ligament, 473
reflected, 473
lymph-glands, 762
applied anatomy of, 762
regions of abdomen, 1133
ring, abdominal, 480
subcutaneous, 472
Inion, 270

CC-0. In Public Domain. Gurukul Kangri Collection, Haridwar

Digitized by Arya Samaj Foundation Chennai and eGangotri

Inlet of pelvis, 313
Inner cell-mass, 49
Inner surface of skull-cap, 260
Innominate artery, 602
applied anatomy of, 603
peculiarities of, 602
bone, 306
ossification of, 312
veins, 729
peculiarities of, 729
Inscriptions, tendinous, of rectus abdominis, 477
Insertion of muscles, 434
Insula, 849
circular sulcus of, 845, 849
gyri of, 850
opercula of, 849
Integument, 1051
Interalveolar cell-islets of pancreas, 1180
Interarticular fibrocartilages, 16
ligament of head of rib, 368
sternocostal ligaments, 371
Interatrial groove, 578
Intercapitular veins, 724, 733, 736
Intercarpal articulations, 393
Intercavernous sinuses, 722
Interchondral articulations, 372
ligaments, 372
Interclavicular ligament, 375
Interclinoid ligament, 206
Intercolumnar fibres, 472
Intercondyloid eminence of tibia, 327
line of femur, 323
fossa of femur, 323
fossæ of tibia, 327
Intercostal arteries, from aorta, 663
from internal mammary, 640
applied anatomy of, 664
artery, superior, 642
lymph-glands, 775
membranes, 462
nerves, 948
spaces, 189
vein, left superior, 729
right superior, 731
veins, 731
Intercostales externi, 462
interni, 462
Intercostalis suprema artery, 642
Intercostobrachial nerve, 949
Intercrural fascia, 472, 1218
fibres, 472
Intercuneiform articulations, 428
Interfoveolar ligament of Hesselbach, 477
Interglobular spaces, 1105
Interior of cerebral hemispheres, 852
of skull, 260
of urinary bladder, 1206
of uterus, 1233
Interlobar arteries of kidneys, 1199
fissures of cerebral hemispheres, 844
Interlobular arteries of kidney, 1199
plexuses, 1188
veins of kidney, 1199
Intermediate cell-mass, 52, 54
Intermetacarpal articulations, 396
Intermetatarsal articulations, 429
Intermuscular septa of arm, 503
Internal capsule, 859
Internodal segment, 38
Interoceptive sensory impulses, 874
Interorbitonasal part of skull, 72
Interossei, of foot, 565
of hand, 526
Interosseous artery, common, 658
dorsal, 659
recurrent, 660
volar, 658
membrane, antibrachial, 388
crural, 420
nerve, dorsal or posterior, 946
volar or anterior, 942
Interparietal bone, 200
Interpeduncular fossa, 825, 842
ganglion, 827
Interphalangeal joints, 397
applied anatomy of, 398
Interpubic fibrocartilaginous lamina, 400
Intersegmental neurons, 790
septa, 68
Intersigmoid fossa, 1146
Interspinal ligaments, 361
Interspinales, 461
Interstitial keratitis, 1008
lamellæ, 20
Intertarsal articulations, 424
Intertragic notch, 1022
Intertransversarii, 461
Intertransverse ligaments, 361
Intertrochanteric crest, 320
line, 320
Intertubercular plane, 1133
sulcus, 283
Intertubular capillaries of kidney, 1199
stroma of kidney, 1199
Intervenous tubercle, 582
Interventricular foramen, 863
Intervertebral fibrocartilages, 358
applied anatomy of, 359
structure of, 359
foramina, 164
veins, 733
Intervillous space, 63
Intestinal glands, 1160
lymphatic trunk, 750, 765
villi, 1158
Intestine, surface markings of, 1285, 1286
Intestine, large, 1162
cæcum, 1163
appendix or vermiform process of, 1163
colon, ascending, 1165
descending, 1167
iliac, 1167*
sigmoid or pelvic, 1168
transverse, 1166
rectum, 1168
anal canal or pars analis recti, 1169
applied anatomy of, 1175
Eohic valve of, 1164
divisions of, 1162
Intestine, large, glands of, 1171
lymphatics of, 770
structure of, 1170
tæniæ of, 1170
vessels and nerves of, 1171
Intestine, small, 1153
duodenum, 1154
ileum, 1156
jejunum, 1156
aggregated lymphatic nodules of, 1160
applied anatomy of, 1172
circular folds of, 1158
glands of, 1160
lymphatics of, 759, 1162
Meckel's diverticulum of, 57, 1156
mesenteric part of, 1156
Peyer's glands of, 1160
solitary lymphatic nodules of, 1160
structure of, 1157
valvulæ conniventes of, 1158
vessels and nerves of, 1161
villi of, 1158
Intestinum crassum, 1162
tenue, 1153
mesenteriale, 1156
Intracartilaginous ossification, 22
Intra-epithelial plexus of cornea, 997
Intrafusal fasciculi, 1050
fibres, 1050
Intrajugular process, 199
Intralobular arteries of kidneys, 1199
Intralobular veins of liver, 741, 1188
of kidney, 1199
Intramembranous ossification, 22
Intraparietal sulcus of Turner, 847
Intrapulmonary bronchi, 1089
Intrathyreoid cartilage, 1061
Intravenous infusion, 727
Intrinsic muscles of tongue, 1116
Involucrum, 25
Involuntary muscle, 32
Iodothyrin, 1245
Iridial angle, 995
applied anatomy of, 1009
Iris, 999
applied anatomy of, 1009
colour of, 1000
structure of, 1000
vessels and nerves of, 1001
Irregular bones, 164
tubule of kidney, 1197
Irritation of cervical sympathetic, 982
Ischial spine, 309
Ischiocapsular ligament, 406
Ischiocavernosus, in female, 492
in male, 489
Ischiorectal fossa, 486
applied anatomy of, 486
Ischium, 309
body of, 309
rami of, 310
spine of, 309
tuberosity of, 310
Island of Reil, 849
Islands, blood, 109
of Langerhans, 1180

CC-0. In Public Domain. Gurukul Kangri Collection, Haridwar

Digitized by Arya Samaj Foundation Chennai and eGangotri

Islets, interalveolar, of pancreas, 1180
Isthmus, aortic, 121, 601
of auditory tube, 1031
of external acoustic meatus, 1024
faucium, 1118
of limbic lobe, 850
of prostate, 1223
rhombencephali, 90, 800
of thyreoid gland, 1245
of uterine tube, 1230
of uterus, 1232
Iter chordæ anterius, 911, 1028
posterius, 911, 1027
Ivory or dentine, 1104

Jacobson, nerve of, 917, 1034
vomeronasal cartilage of, 229, 988
organs of, 81, 988
Jejunal arteries, 670
Jejunum, 1156
lymphatic vessels of, 770
Jelly of Wharton, 12, 61
Joints. *See* Articulations.
Juga alveolaria, 230
Jugal point, 270
Jugular arch, venous, 712
foramen, 250, 263
fossa, 212
ganglion, of glossopharyngeal nerve, 916
of vagus nerve, 917
lymphatic trunks, 750, 754
nerve, 974
notch, 185, 199
process, 199, 251
surface, of temporal bone, 212
vein, anterior, 712
external, 712
applied anatomy of, 713
surface marking of, 1272
internal, 713
applied anatomy of, 714
bulbs of, 713
surface marking of, 1272
posterior external, 712
primitive, 112, 125
Jugulo-digastric lymph-glands, 754
Jugulo-omohyoid lymph-glands, 754
Jugum sphenoidale, 206
Junction, sclerocorneal, 994
Junctional tubule of kidney, 1197

Karyokinesis, 2
Karyomitome, 2
Karyoplasm, 2
Kataphase, 3
Keratin, 7, 1053
Keratitis, interstitial, 1008
Keratohyalin, 6, 1053
Kerckring, ossific centre of, 200
Kidneys, 1192
applied anatomy of, 1199
blood-vessels of, 1198
calyces of, 1194
capsule of Bowman, 1197
convoluted part of, 1196
cortical substance of, 1196
development of, 156
floating, 1199
glomeruli of, 1197
Kidneys (*cont.*)
horse-shoe shaped, 1199
lymphatic vessels of, 772
Malpighian bodies of, 1197
medullary substance of, 1195
minute anatomy of, 1196
movable, 1199
nerves of, 1199
paranephric body, 1195
relations of, 1192
renal artery, 674, 1198
fascia, 1195
pelvis, 1193
pyramids, 1195
sinus, 1194
tubules, 1196
structure of, 1195
surface marking of, 1289
veins of, 741, 1199
Klumpke's paralysis, 946
Knee-joint, 410
applied anatomy of, 419
bursæ near, 415
movements of, 416
surface anatomy of, 1305, 1309
Knobs, basal, of Engelmann, 5
Knot, Hensen's, 50
Krause, end-bulbs of, 1048
membrane of, 30
Kupffer, stellate cells of, 1188
Kyphosis, 184

Labbé, posterior anastomotic vein of, 716
Labia cerebri, 852
majora, 1238
commissures of, 1238
minora, 1238
frenulum or fourchette of, 1239
oris, 1094
Labial artery, inferior, 614
superior, 614
commissure, 1094
glands, 1094
groove, primary, 133
secondary, 133
nerves, posterior, 967
superior, 897
Labiogingival lamina, 1106
Labiotectal furrow, 1106
Labrum, glenoidal, of shoulder-joint, 380
of hip-joint, 406
Labyrinth or internal ear, 1035
membranous labyrinth, 1039
development of, 106
osseous labyrinth, 1036
development of, 106
vessels of, 1048
of ethmoidal bone, 221
Lacertus fibrosus, 504
Laciniate ligament, 560
Lacrimal apparatus, 1018
applied anatomy of, 1022
development of, 105
artery, 626
bone, 225
lesser, 226
ossification of, 226
caruncle, 1018
crest, anterior, 232, 258
posterior, 225, 258
ducts or canals, 1019
ampullæ of, 1019
development of, 105
fascia, 1020
Lacrimal fossa, 218, 225, 233, 257, 258
glands, 1018
development of, 105
structure of, 1019
accessory, 1018
groove, 225
hamulus, 225
nerve, 893
notch, 230
papillæ, 1016
process of inferior nasal concha, 225
puncta, 1019
sac, 1020
development of, 105
structure of, 1020
tubercle, 233
Lacrimo-ethmoidal suture, 258
Lacrimomaxillary suture, 258
Lacteals, 745, 770, 1162
Lactiferous ducts, 1241
Lacuna magna of urethra, 1210
musculorum, 531
vasorum, 531
Lacunæ of bone, 20, 21
laterales, 717
of urethra, 1210, 1211
venous, of dura mater, 717
Lacunar ligament, 473
Lacus lacrimalis, 1016
Lagæna, 1042
Lambda, 270
Lambdoid suture, 216, 247, 251, 254, 260
Lamella, articular, of bone, 351
Lamellæ of bone, 20
circumferential, 20
interstitial, 20
primary, 20
secondary, 20
Lamellar cells, 9
Lamina affixa, 861
alar or dorsal, 85
anterior elastic, of cornea, 996
basal or ventral, 85
basalis, 998
choriocapillaris, 998
cribrosa, of ethmoidal bone, 220, 260
cribrosa scleræ, 994
of cricoid cartilage, 1061
dental, 1106
dentogingival, 1106
dorsal or alar, 85
interpubic fibrocartilaginous, 400
labiogingival, 1106
medullary, lateral, 834
medial, 834
osseous spiral, of cochlea, 1038
papyracea, of ethmoidal bone, 222, 258
perpendicularis, of ethmoidal bone, 221, 265
posterior elastic, of cornea, 996
reticular, 1045
secondary spiral, 1038
suprachorioidea, 994, 997
terminalis, 93, 838, 841
vasculosa, 998
ventral or basal, 85
Laminæ, nasal, 79
of cerebral cortex, 867
development of, 869

CC-0. In Public Domain. Gurukul Kangri Collection, Haridwar

Digitized by Arya Samaj Foundation Chennai and eGangotri

Laminæ of lentiform nucleus, 858
medullary, of thalamus, 834
pterygoid, of sphenoidal bone, 204, 250
of thyreoid cartilage, 1060
of vertebræ, 165
Laminectomy, 185
Langerhans, islands of, 1180
Langhans, layer of, 49, 64
Langley's ganglion, 1100
Lantermann, segments of, 38
Lanugo, 161
Large intestine, 1162 (*see also* under Intestine, large)
Laryngeal artery, inferior, 641
superior, 610
nerve, recurrent, 920
superior, 919
external branch, 920
internal branch, 919
part of pharynx, 1124
prominence, 1060
saccule, 1068
Laryngopharyngeal nerves, 974
Laryngotomy, 1076
Laryngotracheal groove, 145
tube, 145
Larynx, 1059
actions of muscles of, 1070
applied anatomy of, 1076
cartilages of, 1059
arytænoid, 1062
cricoid, 1062
corniculate, 1062
cuneiform, 1062
epiglottis, 1062
thyreoid, 1059
cavity of, 1065
conus elasticus of, 1065
development of, 145
elastic membrane of, 1064
entrance to, 1066
glands of, 1061
joints of, 1063
ligaments and membranes of, 1064
lower part of, 1068
lymphatic vessels of, 757, 1071
middle part of, 1066
mucous membrane of, 1071
muscles of, 1069
rima glottidis of, 1067
surface anatomy of, 1260
ventricle of, 1068
appendix to, 1068
ventricular folds of, 1066
vessels and nerves of, 1071
vestibule of, 1066
vocal folds of, 1067
Lateral cerebral fissure, 99, 845
curvature of vertebral column, 183
ligaments of liver, 1185
of uterus, 1234
parts of occipital bone, 199
mass of ethmoidal bone, 221
mesoderm, 52
sacral arteries, 684
sinuses, 719
ventricles, 853
Latissimus dorsi, 493
Lawn-tennis arm, 508
leg, 558
Layer, ependymal, 85
Henle's, 1056
Huxley's, 1056
of Langhans, 49, 64
Layer (*cont.*)
granular, of Tomes, 1105
limiting or boundary of decidua, 63
mantle, 85
marginal, 85
of nerve-fibres, 1003
pigmented, of retina, 1003
of rods and cones, 1005
scleratogenous, 68
Lead poisoning, 1095
Left atrioventricular orifice, 586
atrium, 585
oblique vein of, 128, 576
auricula, 581
vena cava, ligament of, 128, 576, 709
ventricle, 585
posterior vein of, 708
Leg, fascia of, 549
deep transverse, 549, 553
muscles of, 548
Lemniscus or fillet, 805, 828
decussation of, 805
lateral, 829, 914
nucleus of, 915
medial, 829
Length, basinasal, 270
of face, 271
of skull, 270
Lens, crystalline, 1006
applied anatomy of, 1009
axis of, 1007
capsule of, 1006
changes produced in, by age, 1007, 1008
development of, 104
equator of, 1007
poles of, 1007
radii lentis, 1007
structure of, 1007
suspensory ligament of, 1006
vascular capsule of, 104
vesicle, 102
Lenticular nucleus, 858
glands of stomach, 1152
process of incus, 1032
Lentiform nucleus, 858
Leptorhine skulls, 271
Leucocytes, 27
Leucoderma, 14
Levator anguli oris, 441
ani, 485
glandulæ thyreoideæ, 1245
menti, 441
palati, 1120
palpebræ superioris, 1010
prostatæ, 485
scapulæ, 495
veli palatini, 1120
Levatores costarum, 463
prostatæ, 1224
Lieberkühn, crypts of, 1160
Lien, 1252
Lienal artery, 669
applied anatomy of, 669
plexus, 980
recess, 1140
vein, 742
Lienorenal ligament, 1139, 1253
Ligament or ligaments—
accessory, plantar, 430
volar, 396
acromioclavicular, 376
alar, 367
of ankle, 420
annular, anterior, of ankle, 558, 559
Ligament or ligaments (*cont.*)
annular, external, 560
internal, 560
of base of stapes, 1033
of proximal radio-ulnar joint, 387
of wrist, anterior, 518
posterior, 519
anterior, of head of fibula, 420
of lateral malleolus, 420
of malleus, 1033
of uterus, 1233
anterior longitudinal, 357
antibrachial interosseous membrane, 388
of apex of dens, 367
arcuate, of diaphragm, 465
arcuate popliteal, 413
retinaculum of, 413
pubic, 400
articular disc, of sterno-clavicular joint, 375
of acromioclavicular joint, 376
of distal radio-ulnar joint, 388
atlanto-occipital membrane, anterior, 366
posterior, 366
of auditory ossicles, 1033
of auricula or pinna, 1023
bifurcated, 426
calcaneocuboid part of, 426
calcaneonavicular part of, 426
of bladder, 1204
broad, of uterus, 1136, 1138, 1234
calcaneocuboid, dorsal, 426
plantar, 426
calcaneofibular, 423
calcaneonavicular, plantar, 427
calcaneotibial, 422
caroticoclinoid, 206
carpometacarpal, dorsal, 395
interosseous, 396
volar, 395
of carpus, 393
check, 367
of eye, 1013
collateral, of carpus, 393
of elbow-joint, 384, 385
of digital joints of hand, 397
of foot, 429
of knee-joint, 413
of metacarpophalangeal joints, 396
of metatarsophalangeal joints, 430
of wrist-joint, 392
conjugal, 369
conoid, 377
conus elasticus of larynx, 1065
of Cooper, 473
coraco-acromial 377
coracoclavicular, 376
coracohumeral, 379
coronary, of knee, 415
of liver, 1134, 1185
costoclavicular, 375
costocoracoid, 498
costotransverse, 369
costoxiphoid, 372
cotyloid, 406

CC-0. In Public Domain. Gurukul Kangri Collection, Haridwar

Digitized by Arya Samaj Foundation Chennai and eGangotri

Ligament or ligaments (*cont.*)
crico-arytænoid, posterior, 1063
cricotracheal, 1064
cricothyreoid, middle, 1065
cruciate, of atlas, 366
crural, 559
of knee, 414
crural interosseous membrane, 420
of Cruveilhier, 396, 430
cuboideonavicular, 428
cuneocuboid, 428
cuneonavicular, 427
deep, of tarsus, 427
deltoid, 422
calcaneotibial, 422
talotibial, anterior, 422
posterior, 422
tibionavicular, 422
denticulate, 885
digital vaginal, 510, 563
dorsal carpal, 519
radiocarpal, 391
elastic membrane of larynx, 1064
of elbow, 383
radial collateral, 385
ulnar collateral, 384
of epididymis, 1213
falciform, of liver, 1134, 1185
fibrocartilaginous disc of sacrococcygeal symphysis, 361
fibular collateral, of knee-joint, 413
short, 413
flava, 300
fundiform, of penis, 470, 1221
gastrocolic, 1135
gastrolienal, 1139, 1253
gastropancreatic, 1140
gastrophrenic, 1148
Gimbernat's, 473
glenohumeral, 379
glenoid, of Cruveilhier, 396, 430
of shoulder-joint, 380
glenoidal labrum, of hip-joint, 406
of shoulder-joint, 380
hepatoduodenal, 1134, 1141, 1185
hepatogastric, 1134, 1141, 1185
hepatorenal, 1134, 1185
of Hesselbach, 477
of hip-joint, 404
humeral, transverse, 380
hyo-epiglottic, 1063
hyothyreoid, 1064
membrane, 1064
iliofemoral, 405
iliolumbar, 398
iliotrochanteric, 405
of incus, 1033
inferior transverse, of ankle-joint, 420
of scapula, 378
infundibulopelvic, 1234
inguinal, 473
reflected, 473
interarticular, of ribs, 368
sternocostal, 371
intercarpal, 393
interchondral, 372
interclavicular, 375

Ligament or ligaments (*cont.*)
interclinoid, 206
intercuneiform, 428
interfoveolar, 477
intermetacarpal, 396
intermetatarsal, 429
interosseous of distal tibio-fibular joint, 420
interpubic fibrocartilaginous lamina, 400
interspinal, 361
intertransverse, 361
intervertebral fibrocartilages, 358
ischiocapsular, 406
of knee-joint, 410
laciniate, 560
lacunar, 473
of larynx, 1064
of malleus, 1033
lateral, of liver, 1185
lateral or broad, of uterus, 1136, 1138, 1234
of left vena cava, 128, 576, 709
lienorenal, 1139, 1253
of liver, 1185
long plantar, 426
longitudinal, anterior, 357
posterior, 358
lumbocostal, 369
of Mackenrodt, 1234
of malleus, 1033
medial palpebral, 439
membrana sterni, 371
tectoria, 366
menisci of knee-joint, 414
metacarpophalangeal, 396
accessory volar, 396
collateral, 396
metatarsophalangeal, 430
accessory plantar, 430
collateral, 430
middle cricothyreoid, 1065
middle umbilical, 1205
mucosum, of knee, 411
of neck of rib, 369
nuchæ, 361
oblique cord, 387
oblique popliteal, 413
occipito-axial, 367
odontoid, 367
orbicular, 387
of ovary, 1226
palpebral, lateral, 1017
medial, 1017
patellar, 411
retinacula, 410
pectinate, of iris, 997
peronæal retinacula, 560
phrenicocolic, 1144, 1167
phrenicopericardiac, right, 740
of pinna or auricula, 1023
pisohamate, 393
pisometacarpal, 393
plantar, long, 426
short, 426
accessory, 430
calcaneonavicular, 427
posterior crico-arytænoid, 1063
of head of fibula, 420
of incus, 1023
of knee, 413
of lateral malleolus, 420
longitudinal, 358
of Douglas, 1234

Ligament or ligaments (*cont.*)
Poupart's, 473
pterygospinous, 206, 448
pubic, arcuate, 400
superior, 400
pubocapsular, 405
puboprostatic, 484, 1205
pulmonary, 1079
quadrate, 387
radial collateral, of elbow-joint, 385
of wrist-joint, 392
radiate, 368
sternocostal, 371
radiocarpal, 391
of radio-ulnar joints, 387, 388
recto-uterine, 1234
reflected inguinal, 473
retinacula, of hip-joint, 404
of patella, 410
peronæal, 560
retinaculum, of arcuate popliteal ligament, 413
rhomboid, 375
round, of liver, 1186
of uterus, 1234
sacrococcygeal, 361
fibrocartilage, 361
sacrogenital, 1234
sacro-iliac, anterior, 398
interosseous, 398
sacro-iliac, long posterior, 398
short posterior, 398
sacrosciatic, great, 399
small, 399
sacrospinous, 399
sacrotuberous, 399
falciform process of, 399
of scapula, 377
semilunar fibro-cartilages of knee-joint, 414
of shoulder-joint, 378
sphenomandibular, 356
spinoglenoid, 378
spring, 427
stellate, 368
sternoclavicular, 374
sternocostal, radiate, 371
sternopericardiac, 576
structure of, 351
stylohyoid, 452
stylomandibular, 356
subpubic, 400
superior, of malleus, 1033
superior transverse, of scapula, 377
suprascapular, 377
supraspinal, 360
suspensory, of axilla, 496
of eye, 1013
of lens, 1006
of mamma, 496, 1241
of ovary, 1226
of penis, 1222
sutural, 351
talocalcaneal, anterior, 424
interosseous, 425
lateral, 424
medial, 425
posterior, 424
talonavicular, 425
talofibular, anterior, 422
posterior, 422
talotibial, anterior, 422
posterior, 422
tarsometatarsal, 428
of tarsus, 424 to 428

CC-0. In Public Domain. Gurukul Kangri Collection, Haridwar

Digitized by Arya Samaj Foundation Chennai and eGangotri

Ligament or ligaments (*cont.*)
temporomandibular, 356
tendo oculi, 439
teres, of hip-joint, 406
of liver, 594, 742, 1134, 1186
thyreo-epiglottic, 1062
tibial collateral, of knee-joint, 413
tibiofibular, 420
tibionavicular, 422
transversale colli uteri, 1234
transverse acetabular, 406
of atlas, 364
crus inferius, 364
superius, 364
carpal, 518
crural, 558
humeral, 378
inferior, 420
of scapula, 378
of knee, 415
metacarpal, 396
metatarsal, 429
of pelvis, 489
superior, of scapula, 377
trapezoid, 376
triangular, of liver, 1185
of urethra, 489, 490
of tubercle of rib, 370
ulnar collateral, of elbow-joint, 384
of wrist-joint, 392
umbilical, lateral, 678, 1205
middle, 1205
of urinary bladder, 1204
uterosacral, 1234
of uterus, 1233
ventricular, of larynx, 1066
of vertebral arches, 360
bodies, 357, 358
vocal, 1067
volar carpal, 518
accessory, 396
of carpometacarpal joints, 395
of intercarpal joints, 393
of intermetacarpal joints, 396
radiocarpal, 391
of white fibrous tissue, 351
of Wrisberg, 415
of wrist-joint, 390
Y-shaped, of Bigelow, 405
of yellow elastic tissue, 351
of Zinn, 1012
zona orbicularis of hip-joint, 404
Ligamenta flava, 360
suspensoria of mamma, 496, 1241
Ligamentous action of muscles, 355
applied anatomy of, 355
Ligamentum annulare baseos stapedis, 1033
apicis dentis, 367
arteriosum, 594
carpi radiatum, 393
conjugale, 369
corniculopharyngeum, 1064
cruciatum atlantis, 366
denticulatum, 885
mucosum, 411
nuchæ, 361
patellæ, 411
teres femoris, 406
hepatis, 594, 742, 1134, 1186
Ligamentum transversale colli uteri, 1234
venosum, 594, 742, 1186
Ligature of—
abdominal aorta, 666
axillary artery, 645
brachial artery, 649
carotid artery, common, 607
external, 609
internal, 625
dorsalis pedis artery, 703
femoral artery, 692
glutæal arteries, 685
hypogastric artery, 678
iliac artery, common, 678
external, 685
internal, 678
innominate artery, 603
jugular vein, internal, 714
lingual artery, 612
popliteal artery, 697
radial artery, 655
subclavian artery, 634
tibial artery, anterior, 701
posterior, 704
ulnar artery, 657
Lightning pains, 877
Ligulæ, 823
Limbic lobe, 850
Limbs, development of, 82
development of arteries of, 123
pre-axial and postaxial borders of, 82
Limbus fossæ ovalis, 582
laminæ spiralis, 1042
Limen nasi, 986
Limiting or boundary layer of decidua, 63
membranes of retina, 1005
Line or lines—
arcuate, of ilium, 306
contour, of Owen, 1105
curved, of ilium, 307, 308
Dobie's, 30
Frommann's, 38
glutæal, of ilium, 307, 308
Hensen's, 30
intercondyloid, 323
intertrochanteric, 320
mylohyoid, 241
Nélaton's, 1308
nuchal, 196, 254, 255
oblique, of fibula, 331
of mandible, 241
of radius, 290
of thyreoid cartilage, 1061
pectineal, 321
perpendicular, of ulna, 293
popliteal, of tibia, 328
of Schreger, 1105
spiral, of femur, 321
temporal, 206, 215, 217, 247, 251
white, of pelvic fascia, 484
Linea alba, 480
aspera, 321
nuchæ suprema, 196
quadrata, 320
semicircularis, 478
splendens, 884
Lineæ semilunares, 480
Lingua, 1111
Lingual artery, 611
applied anatomy of, 612
branches of glossopharyngeal nerve, 917
gyrus, 848
Lingual lymph-glands, 752
nerve, 902
swellings, lateral, 134
tonsil, 1112, 1119
veins, 714
Linguiform lobe of liver, 1191
Lingula of cerebellum, 815
mandibulæ, 242
of sphenoidal bone, 201
Linguofacial vein, 131
Linin, 2
Lip, rhombic, 91
tympanic, 1042
vestibular, 1042
Lips, 1094
Liquor amnii, 61
folliculi, 1228
secondary, 1229
sanguinis or plasma, 26
Lissauer, fasciculus of, 795
Littré, urethral glands of, 1210
Liver, 1181
applied anatomy of, 1190
bare area of, 1184
bile-duct, 1189
cells, 1187
cystic duct, 1189
development of, 143
ducts, 1188
excretory apparatus of, 1188
fossæ of, 1182
gall-bladder, 1189
hepatic artery, 667, 1188
duct, 1188
veins, 741, 1186
ligaments of, 1185
lobes of, 1184
lobules of, 1187
lymphatic vessels of, 771
portal vein, 742, 1187
structure of, 1186
surface markings of, 1286
surfaces of, 1184
vessels and nerves of, 1186
Lobes of cerebellum, 814
of cerebral hemisphere, 846
frontal, 846
insula, 849
limbic, 850
occipital, 848
olfactory, 851
parietal, 847
quadrate, 848
temporal, 848
of hypophysis, 839
of liver, 1184
caudate, 1184
left, 1184
linguiform, 1191
quadrate, 1184
Riedel's, 1191
right, 1184
Spigelian, 1184
of lungs, 1087
of prostate, 1223
of thymus, 1248
of thyreoid gland, 1244, 1245
Lobule or lobules—
of auricula, 1022
biventral, 817
paracentral, 847
parietal, inferior, 848
superior, 848
quadrangular, of cerebellum, 815
semilunar, inferior, 817
superior, 816
Lobules of epididymis, 1214

CC-0. In Public Domain. Gurukul Kangri Collection, Haridwar

Digitized by Arya Samaj Foundation Chennai and eGangotri

Lobules of liver, 1187
Lobuli testis, 1213
Lobulus centralis, 815
Lobus clivi, 815
culminis, 815
noduli, 816
pyramidalis, 817
semilunaris, 816
tuberis, 817
uvulæ, 817
Lockwood, superior tendon of, 1012
suspensory ligament of, 1013
Locomotor ataxy, 877
Locus cæruleus, 805, 824
Long bones, 163
buccal nerve, 900
ciliary nerves, 894
or internal saphenous nerve, 957
plantar ligament, 426
root of ciliary ganglion, 894
subscapular nerve, 938
thoracic artery, 647
nerve, 937
Longissimus capitis, 458
cervicis, 458
dorsi, 458
Longitudinal arc of skull, 270
cerebral fissure, 843, 1263
fasciculi of pons, 813
fasciculus, inferior, 867
medial or posterior, 806, 827
superior, 866
ligament, anterior, 357
posterior, 358
sinus, inferior, 718
superior, 717
striæ, lateral and medial, 852
sulci of heart, 578
Longitudinalis linguæ inferior, 1116
superior, 1116
Longus colli, 454
capitis, 454
Loop of Henle, 1197
Lordosis, 184
Lower extremity, arteries of, 687
articulations of, 398
bones of, 306
fascia and muscles of, 530
lymph-glands of, 761
lymphatic vessels of, 763
surface anatomy of, 1302
markings of, 1308
veins of, 733
visual centres, 836, 841
Lower, tubercle of, 582
Lowest splanchnic nerve, 977
Lumbar arteries, 676
abscess, 533
aponeurosis, 457
curve of vertebral column, 183
enlargement of medulla spinalis, 787
lymph-glands, 764
lymphatic trunks, 750, 765
nerves, anterior divisions of, 951
posterior divisions of, 930
plexus, 952
applied anatomy of, 967
puncture, 883
regions of abdomen, 1133
triangle, 493
Lumbar vein, ascending, 741
veins, 740
vertebræ, 172
additional centres for, 181
Lumbocostal arch, lateral, 465
medial, 465
ligament, 369
Lumbodorsal fascia, 457
Lumbo-inguinal nerve, 953
Lumbosacral trunk, 951
Lumbricales muscles, of foot, 564
of hand, 526
Lunate bone, 299
ossification of, 305
surface of acetabulum, 312
Lung-buds, 145
Lungs, 1084
applied anatomy of, 1091
development of, 145
fissures and lobes of, 1087
lymphatic vessels of, 778
roots of, 1088
structure of, 1088
surface markings of, 1279
vessels and nerves of, 1089
Lunula of nail, 1055
Lunulæ of semilunar valves, 585, 587
Luteal cells, 1229
Luys, nucleus of, 838
Lymph, 29
capillaries, 29
path or sinus, 747
sacs, 131
Lymphangitis, 748
Lymph-gland or glands, 746
applied anatomy of, 748
of abdomen and pelvis, 768
of abdomen, parietal, 763
visceral, 765
aortic, 764, 765
auricular, anterior, 751
posterior, 751
axillary, 759
applied anatomy of, 760
bronchial 776
broncho-pulmonary, 776
buccinator, 752
cervical, anterior, 753
deep, 754
applied anatomy of, 757
superficial, 753
of Cloquet, 762
cystic, 766
deltoideopectoral, 759
diaphragmatic, 775
epigastric, inferior, 764
facial, 752
deep, 752
gastric, inferior, 766
superior, 765
germ-centres of, 747
of head, 751
hepatic, 766
hypogastric, 764
ileocolic, 767
iliac, circumflex, 764
common, 763
external, 763
infrahyoid, 753
infra-orbital, 752
inguinal, 762
applied anatomy of, 762
intercostal, 775
jugulo-digastric, 754
jugulo-omohyoid, 754
Lymph-gland or glands (*cont.*)
lingual, 752
of lower extremity, 761
lumbar, 764
mammary, internal, 775
mediastinal, anterior, 776
posterior, 776
mesenteric, inferior, 768
superior, 766
applied anatomy of, 767
mesocolic, 767
of neck, 752
obturator, 764
occipital, 751
pancreaticoduodenal, 769
pancreaticolienal, 766
paracardial, 766
pararectal, 768
paratracheal, 754
parietal of abdomen and pelvis, 763
of thorax, 775
parotid, 751
popliteal, 761
applied anatomy of, 762
pre-aortic, 765
prelaryngeal, 753
pretracheal, 753
pulmonary, 776
retro-aortic, 765
retropharyngeal, 752
of Rosenmüller, 762
sacral, 764
Stahr, middle lymph-gland of, 753
sternal, 775
structure of, 746
subaortic, 763
subinguinal, 762
applied anatomy of, 762
submaxillary, 753
submental, 753
subpyloric, 766
suprahyoid, 753
supramandibular, 752
supratrochlear, 758
of thorax, parietal, 775
visceral, 776
tibial, anterior, 761
tracheal, 776
tracheobronchial, 776
applied anatomy of, 777
of upper extremity, 758
deep, 759
superficial, 758
vesical, 772
visceral, of abdomen and pelvis, 765
of thorax, 775
Lymph-space, perichorioidal, 994
episcleral, 1013
Lymphatic duct, right, 750
nodules, aggregated, 1160
solitary, 1160, 1171
system, 745
development of, 131
trunks, bronchomediastinal, 750, 776
intestinal, 750, 765
jugular, 750, 754
lumbar, 750
subclavian, 750, 760
Lymphatic vessels, 29, 745
of abdomen and pelvis, 768
parietal, 768
visceral, 769

CC-0. In Public Domain. Gurukul Kangri Collection, Haridwar

Digitized by Arya Samaj Foundation Chennai and eGangotri

Lymphatic vessels (*cont.*)
of abdominal viscera, 769
of abdominal wall, 768
afferent, 747
of anal canal and rectum, 771
of anus, 771
applied anatomy of, 748
of auricula and external acoustic meatus, 754
of bile-duct, 771
bronchomediastinal trunks, 750, 765, 776
of cæcum, 770
chyliferous vessels or lacteals, 745, 770
cisterna chyli, 750
of colon, 770
deep, 748
development of, 131
of diaphragm, 777
of digestive tube (subdiaphragmatic portion), 769
of ductus deferens, 773
of duodenum, 769
efferent, 747
of external genitals, 769
of face, 754
of gall-bladder, 771
of head and neck, 754
of heart, 778
of ileum, 770
intestinal trunk, 750, 765
of jejunum, 770
jugular trunks, 750, 754
of kidney, 772
lacteals or chyliferous vessels, 745, 770
of larynx, 757
of liver, 771
of lower extremity, 763
deep, 763
superficial, 763
lumbar trunks, 750
of lungs, 778
of mamma, 777
of mouth, 755
of nasal cavities, 755
of neck, 757
of œsophagus, 778
of ovary, 774
of palatine tonsil, 755
of pancreas, 771
of perinæum, 769
of pharynx, 757
of pleura, 778
of prostate, 772
pulmonary, 778
of rectum, 771
of reproductive organs, 773
right lymphatic duct, 750
of scalp, 754
of spleen, 771
of stomach, 769
structure of, 745
subclavian trunks, 750
superficial, 748
of suprarenal gland, 771
of teeth, 755
of testis, 773
thoracic duct, 748
applied anatomy of, 750
of thoracic viscera, 778
wall, deep, 777
superficial, 777
of thymus, 778

Lymphatic vessels (*cont.*)
of thyreoid gland, 757
of tongue, 756
of tonsil, 755
of upper extremity, 760
deep, 760
superficial, 761
of ureter, 772
of urethra, 773
of urinary bladder, 772
of urinary organs, 771
of uterine tube, 774
of uterus, 774
of vagina, 774
of vermiform process, 770
vesical, 772
of vesiculæ seminales, 773
Lymphocyte, 28
Lymphoid tissue, 12
Lymph-vascular system, 569
Lyra of fornix, 862

Macewen, suprameatal triangle of, 206
Mackenrodt, ligament of, 1234
Macrocyte, 28
Macula acustica sacculi, 1040
utriculi, 1039
cribrosa media, 1036
inferior, 1037
superior, 1036
lutea, 1002, 1005
structure of, 1005
Magma réticulé, 49
Majendie, foramen of, 823, 882
Malar bones, 239
Male genital organs, 1212
bulbo-urethral glands, 158, 1226
ductus deferens, 1216
ejaculatory ducts, 1218
epididymis, 1212
penis, 1220
prostate, 1223
spermatic cord, 1218
testes, 1212
vesiculæ seminales, 1217
pronucleus, 46
urethra, 1208
cavernous portion, 1209
membranous portion, 1209
prostatic portion, 1208
Malleolar arteries, 701, 702, 705
arterial networks, 702
folds, anterior and posterior, 1028
sulcus, 330
Malleolus, lateral, 332
medial, 330
Malleus, 1031
cog-tooth or spur of, 1032
development of, 108
head, 1031
ligaments of, 1033
manubrium, 1033
neck, 1033
ossification of, 1033
process, anterior, 1032
lateral, 1032
processus brevis, 1032
gracilis, 1032
Malpighian bodies of kidney, 1197
of spleen, 1255
Mamillary bodies, 838
processes of vertebræ, 174

Mamillotegmental fasciculus, 838
Mamillothalamic fasciculus, 834, 838, 862
Mamma, 1240
applied anatomy of, 1242
development of, 84
ligamenta suspensoria of, 496, 1241
lymphatic vessels of, 777
papilla or nipple of, 1241
areola of, 1241
structure of, 1241
tubuli lactiferi of, 1242
vessels and nerves of, 1242
Mammary artery, internal, 638
applied anatomy of, 640
external, 647
branches of intercostal arteries, 664
lymph-glands, internal, 775
papilla or nipple, 1241
veins, internal, 729
Mandible, 240
alveolar part of, 241
angle of, 242, 257
applied anatomy of, 273, 357
articulation of, 355
body of, 241
changes in, due to age, 244
condyloid process of, 243
coronoid process of, 242
fracture of, 273
ossification of, 243
ramus of, 242
Mandibula, 240
Mandibular arch, 76
branch of facial nerve, 912
canal, 243
foramen, 242
fossa, 207, 250, 253
joint, 355
applied anatomy of, 357
surface anatomy of, 1258
nerve, 900
notch, 242
symphysis, 241
Mantle layer, 85
Manubrium mallei, 1032
sterni, 185
Margin, falciform of fossa ovalis, 534
Marginal layer, 85
gyrus, 847
sinus of placenta, 66
veins of foot, 733
of heart, 708
Margins, of heart, 580
supra-orbital, 217
Marrow, red, 18
yellow, 18
Marrow-cells, 19
Marshall, oblique vein of, 128, 576, 709
vestigial fold of, 128, 576, 709
Martinotti, cells of, 869
Massa intermedia, 94, 833, 842
Masses, lateral of atlas, 168
lateral, of ethmoidal bone, 221
Masseter, 444
Masseteric artery, 619
nerve, 900
Mastication, muscles of, 444
Masticatory nerve, 900
Mastoid air-sinuses, 209, 1030
antrum, 209, 1030
entrance to, 1030

CC-0. In Public Domain. Gurukul Kangri Collection, Haridwar

Digitized by Arya Samaj Foundation Chennai and eGangotri

Mastoid branch of occipital artery, 615
canaliculus, 212, 251
emissary vein, 724
fonticulus, 268
foramen, 208, 251, 255, 264
notch, 209, 250
portion of temporal bone, 208
process, 208, 253
Maternal portion of placenta, 65
Matrix of areolar tissue, 7
of dentine, 1104
of nail, 1054
Maturation of ovum, 42
Mature ovum, 42, 43
Maxilla, 230
air-sinus of, 231
applied anatomy of, 273
alveolar process of, 233
antrum of Highmore, 231, 992
applied anatomy of, 232
body of, 230
changes in, due to age, 235
excision of, 273
fracture of, 273
frontal process of, 232
ossification of, 235
palatine process of, 234
zygomatic process of, 232
Maxillary air-sinus, 231, 992
applied anatomy of, 232
surface anatomy of, 1264
artery, external, 612
applied anatomy of, 614
peculiarities of, 614
internal, 616
nerve, 895
inferior, 900
process, of inferior nasal concha, 225
of fœtus, 77, 79
of palatine bone, 237
tuberosity, 230
vein, internal, 711
Meatus, external acoustic, 212, 1024
applied anatomy of, 1026
cartilaginous portion, 1024
development of, 108
isthmus of, 1024
osseous portion, 1025
primary, 108
secondary, 108
internal acoustic, 210, 264
Meatuses of the nose, 223, 265, 266, 987
Mechanism of deglutition, 1122
of pelvis, 401
of respiration, 468
of thorax, 372
Meckel's cartilages, 77, 243
diverticulum, 57, 1156
ganglion, 898
Media, refracting of eye, 1006
Medial geniculate body, 835
longitudinal fasciculus, 806, 827
wall of nasal cavity, 265, 988
Median antibrachial vein, 727
artery, 659
basilic vein, 725
cubital vein, 725
nerve, 940
applied anatomy of, 947
surface marking of, 1302
Mediastinal arteries, from thoracic aorta, 663
from internal mammary, 640
cavity, 1080
applied anatomy of, 1084
anterior, 1082
middle, 1083
posterior, 1083
superior, 1082
lymph-glands, anterior, 776
posterior, 776
pleura, 1079
subpleural plexus, 640
Mediastinum testis, 1213
Medulla of hair, 1056
Medulla oblongata, 800, 801
anterior region of, 801
applied anatomy of, 811
arcuate fibres of, 805, 811
closed part of, 800
development of, 91
fasciculus cuneatus of, 805
gracilis of, 805
fissures and sulci of, 800
formatio reticularis of, 811
grey substance of, 806
lateral region of, 802
olive of, 802
open part of, 800
posterior region of, 802
pyramid of, 801
pyramidal decussation, 802
restiform bodies of, 808
sensory decussation, 805
structure of, 803
Medulla ossium flava, 18
rubra, 18
Medulla spinalis, 784
applied anatomy of, 798
central canal of, 788
columns of grey substance of, 788
development of, 85
enlargements of, 786
filum terminale of, 785
fissures of, 787
funiculi of, 788, 793
grey substance of, 788
internal structure of, 788
ligamentum denticulatum of, 885
meninges of, 877
applied anatomy of, 883, 884
nerve-cells in, 790
nerve-fasciculi of, 793
roots of spinal nerves, 797
sulci of, 787
veins of, 733
white substance of, 792
Medullary arteries, 637
cavity, 18, 163
laminæ of lentiform nucleus, 858
of thalamus, 834
membrane of bone, 18
portion of suprarenal gland, 1251
rays of kidney, 1196
segments of nerves, 38
sheath of nerve-fibres, 38
spaces of bone, 24
substance of kidney, 1195
velum, anterior, 817, 823
posterior, 817, 823
Medullated nerve-fibres, 37
Megacephalic skulls, 269
Megakaryocytes, 19
Megaseme skulls, 271
Meibomian glands, 1017
Meissner's plexus, 1162
tactile corpuscles, 1050
Melanin, 13
Membrana limitans externa, 1005
interna, 1005
pupillaris, 104, 1001
sterni, 371
Membrana tectoria, 367
Membrane, accessory tectorial, 1046
antibrachial interosseous, 388
arachnoid, 881
atlanto-occipital, anterior, 366
posterior, 366
basilar, 1043
zona arcuata, 1043
pectinata, 1043
bucconasal, 79
buccopharyngeal, 50, 133
cloacal, 50, 142
costocoracoid, 498
cricothyreoid, 1065
crural interosseous, 420
elastic, of larynx, 1064
fenestrated, 12
hyaloid, 1006
hyoglossal, 1117
hyothyreoid, 1064
intercostal, anterior, 462
posterior, 462
interosseous, antibrachial, 388
crural, 420
of Krause, 30
medullary, of bone, 18
of Nasmyth, 1109
nuclear, 2
obturator, 544
pleuropericardial, 149
pleuroperitoneal, 149
pupillary, 104, 1001
of Reissner, 1041
secondary tympanic, 1029, 1038
of Shrapnell, 1028
tectorial, of ductus cochlearis, 1046
accessory, 1046
tympanic, 1028
structure of, 1028
vestibular, 1041
vitelline, 42
Membranes—
basement, 12
of brain and medulla spinalis, 877
closing, 76
fœtal, 58
intercostal, 462
of larynx, 1064
Membranous labyrinth, 1039
basilar membrane, 1043
development of, 106
ductus cochlearis, 1041
saccule, 1040
semicircular ducts, 1040
spiral organ of Corti, 1044
utricle, 1039
portion of urethra, 1209
ventricular septum, 580
vertebral column, 68

CC-0. In Public Domain. Gurukul Kangri Collection, Haridwar

Digitized by Arya Samaj Foundation Chennai and eGangotri

Menière's disease, 1048
Meningeal artery or arteries, accessory, 619
anterior, 626, 628
from ascending pharyngeal, 611
middle, 618
applied anatomy of, 618
surface marking of, 1264
from occipital, 614
posterior, 611
recurrent, from lacrimal, 627
from vertebral, 637
branch of spinal nerve, 928
nerve, middle, 896
nerves from hypoglossal, 925
from vagus, 919
sinuses, middle, 723
veins, middle, 723
Meninges of brain and medulla spinalis, 877
arachnoid, 881
dura mater, 877
pia mater, 884
Meningitis, acute spinal, 884
Meningocele, 271
Menisci, 16, 353
of knee-joint, 414, 415
Mental foramen, 241, 257
canal, 243
nerve, 903
protuberance, 241, 257
spines, 241
tubercle, 241, 257
Mentalis, 441
Meroblastic ova, 48
Mesamœboids, 109
Mesaticephalic skulls, 271
Mesencephalic root of trigeminal nerve, 813, 893
nucleus of, 831
Mesencephalon, 53, 93, 799, 825
Mesenteric artery, inferior, 672
superior, 669
arteries, applied anatomy of, 673
embolism of, 673
ganglion, inferior, 981
superior, 981
lymph-glands, inferior, 768
superior, 766
part of small intestine, 1156
plexuses of nerves, 981
vein, inferior, 743
superior, 743
Mesenteries, 1143
mesentery proper, 1143
posterior common, 138
sigmoid mesocolon, 1144
transverse mesocolon, 1144
Mesenteriole of vermiform process, 1143
Mesocardium, arterial, 576
venous, 576
Mesocephalic skulls, 269
Mesocolic fossa, 1145
lymph-glands, 767
Mesocolon, fœtal, 141
pelvic, 1135
sigmoid, 1137
transverse, 1144
Mesoderm, 51
formation of, 49
lateral, 52
paraxial, 52
somatic, 52
splanchnic, 52
Mesogastrium, dorsal, 138
ventral, 137, 142
Mesognathic skulls, 271
Mesonephros, 149
Mesorchium, 153, 154
Mesorhine skulls, 271
Mesosalpinx, 1234
Mesoseme skulls, 271
Mesovarium, 153, 1226
Metacarpal arteries, dorsal, 656
volar, 656
bones, 302
fifth, 304
first, 303
fourth, 304
second, 303
third, 304
applied anatomy of, 306
common characteristics of, 302
individual characteristics of, 303
ossification of, 306
ligament, transverse, 396
veins, 724, 727
Metacarpophalangeal articulations, 396
Metacarpus, 302
Metanephros, 156
Metaphase of karyokinesis, 3
Metatarsal arteries, 703, 707
Metatarsal bones, 344
fifth, 346
first, 345
applied anatomy of, 431
fourth, 346
second, 345
third, 345
common characteristics of, 344
fracture of, 349
individual characteristics of, 345
ossification of, 348
ligament, transverse, 429
veins, 733, 736
Metatarsophalangeal articulations, 430
Metatarsus, 344
Metathalamus, 94, 835
Metencephalon, 90, 800
Metopic suture, 217
Meynert, basal optic nucleus of, 838
fasciculus retroflexus of, 836
fountain decussation of, 831
substantia innominata of, 860
Microcephalic skulls, 269
Microcytes, 26
Microfilaria nocturna, 748, 750
Microseme skulls, 271
Mid-brain, 53, 93, 799, 825
Mid-carpal joint, 393
Middle ear, 1027
Migration of muscles, 83
Milk-ridge, 84
Milk-teeth, 1101, 1104
Miosis, 877, 891
Mitochondrial sheath, 44
Mitosis, 2
heterotypical, 3
homotypical, 3
Mitral cells, 872
valve, 586
Modiolus of cochlea, 1037
Modiolus, spiral canal of, 1037
Molar glands, 1094
teeth, 1104
Molecular layer of cortex of cerebellum, 820
Moles, 14
Monakow, rubrospinal fasciculus of, 794
Monaster, 2
Monorchism, 1215
Monro, foramen of, 842, 863
sulcus of, 93, 842
Mons pubis or Veneris, 1238
Monticulus, 815
Morgagni, hydatid of, 153, 1212, 1230
rectal columns of, 1170
sinus of, 1126
Morula, 49
Moss-fibres, 821
Motor area of cerebral cortex, 870
decussation, 800, 874
end-plate, 782
fibres of posterior nerve-roots, 790*
nerves, 781
neurons, lower and upper, 874, 877
paralysis, 876
tract, principal, 873
secondary, 874
Mouth, 1093, 1266
angle of, 1094
cavity proper of, 1094
development of, 132
lymphatic vessels of, 755
mucous membrane of, 1094
muscles of, 440
orifice of, 1094
rima of, 1094
vestibule of, 1094
Movable articulations, 353
kidney, 1199
vertebræ, 164
Movements of auditory ossicles, 1033
permitted in joints, 354
angular, 354
circumduction, 354
gliding, 354
rotation, 355
Mucinogen, 5
Mucoid tissue, 12
Mucous glands of tongue, 1117
sheaths, 352
of tendons around ankle, 560
on back of wrist, 519
on front of wrist, 519
Müller, sustentacular fibres of, 1005
palpebral muscle of, 1010
Müllerian ducts, 151
eminence, 151
Multangular bone, greater, 300
ossification of, 305
lesser, 300
ossification of, 305
Multicuspids, 1104
Multifidus, 460
Muscle or muscles—
of abdomen, 469
abductor hallucis, 562
digiti quinti (foot), 563
(hand), 526
indicis, 526
pollicis brevis, 523
longus, 516

CC-0. In Public Domain. Gurukul Kangri Collection, Haridwar

Digitized by Arya Samaj Foundation Chennai and eGangotri

Muscle or muscles (*cont.*)
accessorius, of back, 458
of foot, 563
actions of, 434
adductor brevis, 539
hallucis, 565
longus, 539
magnus, 539
minimus, 539*
pollicis, 524
of anal region, 486
anconæus, 515
anterior crural, 549
anterior femoral, 533
anterior vertebral, 454
antero-lateral, of abdomen, 469
of antero-lateral region of neck, 447
antibrachial, dorsal, 513
volar, 507
antitragicus, 1024
aponeuroses of, 435
applied anatomy of, 434
of arm, 503
arrectores pilorum, 1057
articularis genus, or subcrureus, 537
aryepiglotticus, 1069
arytænoideus obliquus, 1069
transversus, 1069
of auricula or pinna, 1023
auricularis, anterior, 1024
posterior, 1024
superior, 1024
axillary arch, 495
azygos uvulæ, 1120
biceps brachii, 503
femoris, 547
biventer cervicis, 460
brachialis, 503
brachialis anticus, 503
brachioradialis, 513
bronchial, 1089
buccinator, 442
bulbocavernosus, 489, 491
caninus, 441
cardiac, 33
cervical, superficial and lateral, 449
cervicalis ascendens, 458
chondroglossus, 1116
ciliaris, 105, 999
coccygeus, 485
columns, 30
complexus, 460
compressor naris, 440
constrictor pharyngis inferior, 1125
medius, 1126
superior, 1126
urethræ, 490
coracobrachialis, 503
corrugator, 439
corrugator cutis ani, 486
cremaster, 475
cricoarytænoideus lateralis, 1069
posterior, 1069
cricothyreoideus, 1069
crureus, 537
cucullaris, 493
deep, of back, 456
deltoideus, 500
depressor septi, 440
anguli oris, 441
development of, 83
diaphragm, 464

Muscle or muscles (*cont.*)
digastricus, 451
dilatator naris, anterior, 440
posterior, 440
pupillæ, 1000
tubæ, 1031
Dobie's line of, 30
dorsal antibrachial, 513
dorsal of foot, 560
dorsoepitrochlearis brachii, 495
ejaculator urinæ, 489
endomysium of, 29
epicranius, 436
epimysium of, 29
erector clitoridis, 492
penis, 489
spinæ or sacrospinalis, 457
extensor carpi radialis brevis, 514
longus, 513
ulnaris, 515
coccygis, 461
digiti quinti proprius, 514
digitorum brevis, 560
communis, 514
longus, 550
hallucis brevis, 560
longus, 550
indicis proprius, 517
ossis metacarpi pollicis, 516
pollicis brevis, 516
longus, 516
of eyelids, 438
fasciculi of, 29
fibres, development of, 33
first plantar interosseous, 565
first volar interosseous, 524
fixation, 434
flexor accessorius, 563
carpi radialis, 508
ulnaris, 509
digiti quinti brevis, of foot, 565
of hand, 526
flexor digitorum brevis, 563
longus, 554
profundus, 510
sublimis, 509
hallucis brevis, 565
longus, 553
pollicis brevis, 523
longus, 511
of foot, 560
of forearm, 507
form of, 433
frontalis, 437
gastrocnemius, 551
gemellus inferior, 546
superior, 546
genioglossus, 1115
geniohyoideus, 453
glossopalatinus, 1120
of glutæal region, 541
glutæus maximus, 541
medius, 542
minimus, 542
gracilis, 538
of hand, 518
of head, 436
helicis major, 1024
minor, 1024
Hensen's line of, 30
hyoglossus, 1115
of iliac region, 530
iliacus, 532

Muscle or muscles (*cont.*)
iliococcygeus, 485
iliocostalis cervicis, 458
dorsi, 458
lumborum, 458
iliopsoas, 532*
iliosacralis, 485
incisivus labii inferioris, 443
superioris, 4430
infraspinatus, 501
insertion of, 434
intercostales, 462
intermediate volar, 526
interossei, of foot, 565
of hand, 526, 527
interspinales, 460
intertransversarii, 460
involuntary, 32
ischiocavernosus, 489, 492
Krause's membrane of, 30
of larynx, 1069
lateral crural, 556
vertebral, 455
volar, 523
latissimus dorsi, 493
of leg, 549
applied anatomy of, 558
levator anguli oris, 441
levator ani, 485
glandulæ thyreoideæ, 1245
menti, 441
palpebræ superioris, 1010
prostatæ, 485
scapulæ, 495
veli palatini (levator palati), 1120
levatores costarum, 463
prostatæ, 1224
longissimus capitis, 458
cervicis, 458
dorsi, 458
longitudinalis linguæ inferior, 1116
superior, 1116
longus capitis, 454
colli, 454
of lower extremity, 530
lumbricales, of foot, 564
of hand, 526
masseter, 444
of mastication, 444
meaning of the terms "origin" and "insertion" of, 434
medial femoral, 538
volar, 525
mentalis, 441
migration of, 83
of mouth, 440
of Müller, 1010
multifidus, 460
mylohyoideus, 453
nasalis, 440
nasolabialis, 443
of nose, 440
obliquus auriculæ, 1024
capitis inferior, 462
superior, 462
externus abdominis, 471
internus abdominis, 474
oculi inferior, 1012
superior, 1012
obturator externus, 546
internus, 544
occipitalis, 437
occipitofrontalis, 436
ocular, 1010
omohyoideus, 454

CC-0. In Public Domain. Gurukul Kangri Collection, Haridwar

Digitized by Arya Samaj Foundation Chennai and eGangotri

Muscle or muscles (*cont.*)
opponens digiti quinti
of foot, 565
of hand, 526
pollicis, 523
orbicularis oculi, 438
oris, 443
orbitalis, 1013
origin of, 434
of palate and fauces, 1120
palatoglossus, 1120
palatopharyngeus, 1121
palmaris brevis, 525
longus, 508
palpebral, of Müller, 1010
pectineus, 538
pectoralis major, 496
minor, 498
of pelvis, 482
of perinæum, 486
peronæus brevis, 557
longus, 556
tertius, 551
pharyngopalatinus, 1121
of pharynx, 1125
of pinna or auricula, 1024
piriformis, 543
plain, 32
plantar, first layer, 562
fourth layer, 565
second layer, 563
third layer, 565
plantaris, 553
plate, 68
platysma, 449
popliteus, 553
posterior, of abdomen, 481
crural, 551
femoral, 547
procerus, 440
pronator quadratus, 512
teres, 508
psoas major, 531
minor, 532
pterygoideus externus, 445
internus, 446
puboanalis, 485
pubococcygeus, 485
puborectalis, 485
pubovesicales, 1207
pyramidalis abdominis, 479
nasi, 440
quadratus femoris, 546
labii superioris, 440
inferioris, 441
lumborum, 481
plantæ, 563
quadriceps femoris, 536
recti of eyeball, 1011
rectococcygeal, 1171
rectovesicalis, 1207
rectus abdominis, 477
capitis anterior, 455
anticus major, 444
minor, 455
lateralis, 455
posterior major, 461
minor, 462
rectus femoris, 536
rhomboideus major, 495
minor, 495
of Riolan, 438
risorius, 444
rotatores, 460
sacrospinalis, 457
salpingopharyngeus, 1127
sarcolemma, 30
sarcomere, 31
Muscle or muscles (*cont.*)
sarcoplasm, 30
sarcostyles, 30
sarcous element of, 31
sartorius, 535
scalenus anterior, 455
medius, 456
posterior, 456
of scalp, 436
semimembranosus, 547
semispinalis capitis, 460
cervicis, 460
dorsi, 460
semitendinosus, 547
serratus anterior, 499
magnus, 499
posterior inferior, 464
superior, 464
of shoulder, 500
soleus, 552
sphincter ani externus, 487
internus, 487
pupillæ, 1000
recti, 485
urethræ membranaceæ, 490, 492
vaginæ, 491, 1228
vesicæ, 1207
spinalis capitis, 460
cervicis, 460
dorsi, 458
splenius capitis, 457
cervicis, 457
stapedius, 1033
sternocleidomastoideus, 449
sternohyoideus, 453
sternothyreoideus, 453
striped, 29
structure of, 29
vessels and nerves of, 31
styloglossus, 1116
stylohyoideus, 452
stylopharyngeus, 1126
subanconeus, 507
subclavius, 498
subcostales, 463
subcrureus or articularis genus, 537
suboccipital, 461
subscapularis, 501
superficial and lateral cervical, 449
supinator, 516
brevis, 516
longus, 513
supra- and infrahyoid, 451
supraspinatus, 501
suspensory, of duodenum, 1156
synergic, 434
temporalis, 444
tendons of, 435
tensor fasciæ latæ, 534
tarsi, 438
tympani, 1033
veli palatini (tensor palati), 1120
teres major, 502
minor, 502
of thigh, 533
of thorax, 462
thyreoarytænoideus, 1069
thyreoepiglotticus, 1070
thyreohyoideus, 453
tibialis anterior, 550
posterior, 555
of tongue, 1114
trachealis, 1075
Muscle or muscles (*cont.*)
trachelomastoideus, 458
tragicus, 1024
transversalis cervicis, 458
transversus abdominis, 476
auriculæ, 1024
linguæ, 1116
menti, 441
nuchæ, 437
pedis, 565
perinæi profundus, 490, 492
superficialis, 488, 491
thoracis, 463
trapezius, 493
triangularis, 441
sterni, 463
triceps brachii, 506
suræ, 552
of trunk, 456
of tympanic cavity, 1033
of upper extremity, 492
of ureters, 1207
unstriped, 32
of urogenital region (female), 491
(male), 487
uvulæ, 1120
vastus intermedius, 537
lateralis, 536
medialis, 537
ventricularis, 1069
vertebral, anterior, 454
lateral, 455
verticalis linguæ, 1116
vocalis, 1070
volar antibrachial, 507
voluntary, 29
zygomaticus, 441
Muscle-sense, 874
Muscular fibres of heart, 588
process of arytænoid cartilage, 1062
sense, area for, 871
tissue, 29
cardiac, 33
striped or voluntary, 29
unstriped, plain or involuntary, 32
triangle of neck, 621
ventricular septum, 580
Musculi papillares of left ventricle, 587
of right ventricle, 584
pectinati of left auricula, 585
of right auricula, 581
pubovesicales, 1207
Musculocutaneous nerve of arm, 938
of leg, 966
Musculophrenic artery, 640
Musculospiral groove, 283
nerve, 944
applied anatomy of, 947
Musculus accessorius, 458
cucullaris, 493*
incisivus labii inferioris, 443
superioris, 443
nasolabialis, 443
rectovesicalis, 1207
suspensorius duodeni, 1156
uvulæ, 1120
Myelencephalon, 90, 800
Myelitis, spinal, 798
Myelocytes, 19
Myeloplaxes, 19
Myenteric plexus, 1162

CC-0. In Public Domain. Gurukul Kangri Collection, Haridwar.

Digitized by Arya Samaj Foundation Chennai and eGangotri

Mylohyoid artery, 619
groove, 242
line, 241
nerve, 902
Mylohyoideus, 453
Myocardium, 587
Myocœl, 54, 68
Myology, 433

Nævi, 14
Nail-fields, primary, 85
Nail matrix, 1054
Nails, 1054
development of, 85
Nares, 984, 986
Nasal apertures, anterior, 256, 266
posterior, 266
artery, dorsal, 628
lateral, 614
posterior lateral, 620
bones, 226
fracture of, 273
ossification of, 227
capsule, development of, 75
cartilages, 984, 985
cavities, 262, 986
applied anatomy of, 992
lymphatic vessels of, 755
mucous membrane of, 989
nerves of, 990
olfactory region of, 987, 989
respiratory region of, 987 989
vessels of, 990
vestibule of, 986
concha, inferior, 224
ossification of, 225
middle, 222
superior, 223
crest, 234
duct, 1020
index, 271
laminæ, 79
mucous membrane, 989
nerve or nerves, from anterior ethmoidal, 894
from anterior superior alveolar, 897
external, from maxillary, 897
posterior inferior, from anterior palatine, 899
posterior superior, from sphenopalatine ganglion, 899
notch of frontal bone, 217
of maxilla, 230
Nasal part of frontal bone, 217
of pharynx, 1122
process of frontal bone, 217
processes of fœtus, 79
septum, 265, 988
spine, anterior, 230,235, 256
posterior, 236, 249
surface of maxilla, 231
venous arch, 710
Nasalis, 440
Nasion, 269
Nasmyth's membrane, 1109
Nasociliary nerve, 894
Nasolabial sulcus, 1094
Nasolabialis, 443
Nasolacrimal canal, 258, 266
duct, 1020
development of, 105
Naso-optic furrow, 79, 105
Nasopalatine nerve, 899
groove, 227
recess, 988
Nasopharynx, 1122
Navicular bone of carpus, 298
ossification of, 305
of tarsus, 341
ossification of, 347
fossa, 1239
Neck, lymph-glands of, 752
lymphatic vessels of, 757
muscles of, 447
surface anatomy of, 1271
triangles of, 620
veins of, 712
Neck of rib, ligament of, 369
Necrosis, acute infective, of bone, 25
Nélaton's line, 1308
Neopallium, 96
Nephrectomy, 1200
Nephrogenic cord, 52
Nephrolithotomy, 1200
Nephropexy, 1200
Nephrotomy, 1200
Nerve-cells, 34
axon or axis-cylinder process of, 35
bipolar, 34
of cerebellar cortex, 820
of cerebral cortex, 867, 869
dendrons or protoplasmic processes of, 35
of medulla spinalis, 790
multipolar, 35
unipolar, 34
Nerve-deafness, 915, 1048
Nerve-endings, free, 1048
Nerve-fasciculi of medulla spinalis, 793
Nerve-fibres, 37
of cerebral cortex, 867, 868
grey or gelatinous, 39
medullated, 37
non-medullated, 39
of Remak, 39
preganglionic, 779
postganglionic, 779
white, 37
Nerve-roots, anterior, 797, 925
posterior, 797, 925
Nerve or nerves—
abducent, 906
accessory, 929
obturator, 955
acoustic, 912, 1046
development of, 108
afferent or centripetal, 781
alveolar, anterior superior, 897
middle superior, 896
posterior superior, 896
inferior, 902
anococcygeal, 967
anterior cutaneous branches of thoracic nerve, 949
crural, 956
interosseous, 942
superior alveolar, 897
thoracic, 938
tibial, 965
antibrachial cutaneous, dorsal, 945
lateral, 939
medial, 940
Arnold's, 919
auricular, anterior, 911
great, 932
Nerve or nerves (*cont.*)
auricular, posterior, 911
of smaller occipital, 932
of vagus, 919
auriculotemporal, 901
autonomic, 781
axillary, 938
of Bell, 937
brachial cutaneous, lateral, 938
medial, 940
posterior, 945
bronchial, anterior, 921
posterior, 921
buccal, of facial, 912
long, 900
buccinator, 900
calcaneal, medial, 963
cardiac, of sympathetic, 975
of vagus, 921
caroticotympanic, 973, 1034
carotid, of glossopharyngeal, 917
internal, 973
cavernous, of penis, 982
centrifugal or efferent, 781
centripetal or afferent, 781
cerebral, 885
abducent, 906
accessory, 922
acoustic, 913
development of, 100
facial, 907
glossopharyngeal, 915
hypoglossal, 923
oculomotor, 889
olfactory, 885, 990
optic, 887
terminal, 885*
trigeminal, 893
trochlear, 891
vagus, 917
cerebrospinal, structure of, 780
cervical, anterior divisions of, 931
posterior divisions of, 928
cutaneous or transverse, 933
of facial, 912
chorda tympani, 911, 1034
ciliary, long, 894
short, 895
circumflex, 938
clunium inferiores, 961
medii, 930
coccygeal, anterior division of, 958
posterior division of, 930
cochlear, 914, 1047
cœliac branches of vagus, 921
common peronæal, 965
communicans fibularis, 965
tibialis, 963
communicantes cervicales, 934
crural, anterior, 956
cutaneous cervical, 933
internal, 940
lesser internal, 940
deep branch of radial, 946
of ulnar, 944
peronæal, 965
petrosal, 898, 973
temporal, 900
dental, inferior, 902
descendens cervicalis, 934

CC-0. In Public Domain. Gurukul Kangri Collection, Haridwar

Digitized by Arya Samaj Foundation Chennai and eGangotri

Nerve or nerves (*cont.*)
descending ramus of hypoglossal, 925
development of, 88, 100
digastric branch of facial nerve, 912
of mylohyoid nerve, 902
digital, of lateral plantar, 965
of medial plantar, 964
of median, 942
of radial, 946
of superficial peronæal, 966
of ulnar, 944
dorsal antibrachial cutaneous, 945
branch of ulnar, 944
of clitoris, 967
cutaneous, intermediate, 966
lateral, 963
medial, 966
of penis, 967
scapular, 937
of dura mater, 880
efferent or centrifugal, 781
endings, free, 1048
end-organs, special, 1048
endoneurium of, 780
epineurium of, 780
ethmoidal, anterior, 894
posterior, 895
to external acoustic meatus, 901
external cutaneous, of musculospiral, 945
of thigh, 955
external nasal, 894, 897
petrosal, 975
popliteal, 965
saphenous, 963
spermatic, 953
facial, 907
femoral, 956
cutaneous, lateral, 955
posterior, 960
first cervical, posterior division, 928
anterior division, 931
frontal, 893
funiculi of, 780
furcal, 951
ganglia, 34, 782
gastric branches of vagus, 921
to gemellus inferior and quadratus femoris, 958
to gemellus superior and obturator internus, 958
genitofemoral (genitocrural), 953
glossopharyngeal, 915
glutæal, inferior, 960
superior, 959
great auricular, 932
greater occipital, 929
splanchnic, 976
superficial petrosal, 898, 910
hæmorrhoidal, inferior, 966
hepatic branches of vagus, 921
hypoglossal, 923
iliohypogastric, 952
ilio-inguinal, 952
incisive, 903
inferior dental, 902
maxillary, 900
pudendal, 961
infra-orbital, 896*

Nerve or nerves (*cont.*)
infrapatellar, 957
infratrochlear, 895
intercostal, 948
anterior and lateral cutaneous branches of, 949
intercostobrachial 949
intermediate cutaneous of thigh, 956
intermedius of Wrisberg, 907
internal carotid, 973
cutaneous, of arm, 940
lesser, 940
of musculospiral, 945
popliteal, 963
saphenous, 957
interosseous, anterior, 942
dorsal, 946
posterior, 946
volar, 942
Jacobson's, 917, 1034
jugular, 974
labial, posterior, 967
superior, 897
lacrimal, 893
laryngeal, recurrent, 920
superior, 919
external branch, 920
internal branch, 919
laryngopharyngeal, of sympathetic, 974
lateral antibrachial cutaneous, 939
brachial cutaneous, 938
cutaneous branches of thoracic nerves, 949
dorsal cutaneous, 963
femoral cutaneous, 955
plantar, 964
lesser splanchnic, 976
superficial petrosal, 903, 1034
lingual, 902
of glossopharyngeal, 917
long ciliary, 894
saphenous, 957
subscapular, 938
thoracic, 937
lowest splanchnic, 977
lumbar, anterior divisions of, 951
posterior divisions of, 930
lumbo-inguinal, 953
lumbosacral trunk, 951
mandibular, 900
of facial, 912
masseteric, 900
masticatory, 900
maxillary, 895
inferior, 900
medial antibrachial cutaneous, 940
brachial cutaneous, 940
calcaneal, 963
cutaneous of thigh, 956
plantar, 963
sural cutaneous, 963
median, 940
meningeal, of hypoglossal, 924
of maxillary, 896
middle, 896
of spinal nerves, 928
of vagus, 919
mental, 903
motor, 781
ending of in involuntary or striped muscles, 781

Nerve or nerves (*cont.*)
motor, ending of in voluntary or striped muscles, 781
motor cerebral, 885
musculocutaneous of arm, 938
of leg, 966
musculospiral, 944
mylohyoid, 902
nasal of anterior superior alveolar, 897
external, 894, 897
internal, 894
posterior, inferior, 899
superior, 899
from sphenopalatine ganglion, 899
nasociliary, 894
nasopalatine, 899
nervi nervorum, 780
neuron theory, 784
obturator, 955
accessory, 955
of obturator internus and gemellus superior, 958
of nose, 990
occipital, greater, 929
smaller, 932
third, 929
oculomotor, 889
œsophageal, 921
olfactory, 885, 990
development of, 101
ophthalmic, 893
optic, 897
orbital, their relation, in cavernous sinus, 906
in orbit, 907
in superior orbital fissure, 907
branches of sphenopalatine ganglion, 899
origins of, 781
palatine, anterior, 899
middle, 899
posterior, 899
palmar cutaneous, of median, 942
of ulnar, 944
palpebral, inferior, 897
parasympathetic, 779, 928, 969
pelvic splanchnics, 928, 969
perforating cutaneous, 966
perinæal, 967
superficial, 967
perineurium of, 780
peripheral terminations of, 781
peronæal anastomotic, 965
common, 965
deep, 965
superficial, 966
petrosal, deep, 898, 973
external, 975
greater superficial, 898, 910
lesser superficial, 903, 1034
pharyngeal, of glossopharyngeal, 917
of sphenopalatine ganglion, 900
of vagus, 919
phrenic, 934
to piriformis, 959
plantar, lateral or external, 964
medial or internal, 963

CC-0. In Public Domain. Gurukul Kangri Collection, Haridwar

Digitized by Arya Samaj Foundation Chennai and eGangotri

Nerve or nerves (*cont.*)
plexus, 781
popliteal, external, 965
internal, 963
of pterygoid canal, 898
to pterygoideus externus, 900
internus, 900
pudendal, 966
inferior, 961
pudic, 966
to quadratus femoris and gemellus inferior, 958
radial, 944
deep branch, 946
superficial branch, 946
rami communicantes, grey and white, 927, 971, 972
ramus colli, 912
marginalis mandibulæ, 912
recurrent (laryngeal), 920
roots, spinal, 797, 925
sacral, anterior divisions of, 958
posterior divisions of, 930
saphenous, 957
external, 963
internal or long, 957
scapular, dorsal, 937
sciatic, 962
small, 960
scrotal, posterior, 967
second cervical, anterior division of, 931
posterior division of, 929
sensory cerebral, 885
short ciliary, 895
smaller occipital, 932
special end-organs of, 1048
spermatic, external, 953
sphenoidal, of otic ganglion, 903
sphenopalatine, of maxillary, 896
of nerve of pterygoid canal, 898
spinal, 925
anterior divisions of, 931
posterior divisions of, 928
autonomic fibres of, 928
connexions with sympathetic trunks, 927
development of, 88
ganglia of, 925
roots of, 797, 925
size and direction, 926
somatic fibres of, 928
structure of, 927
spinal accessory, 922
spinosus, 900
splanchnic, greater, 976
lesser, 976
lowest, 977
splanchnics, pelvic, 928, 969
to stapedius, 910
structure of, 780
to stylohyoideus, 912
to stylopharyngeus, 917
to subclavius, 937
suboccipital, anterior division of, 931
posterior division of, 928
subscapular, 938
long, 938
substance, grey, 34
white, 34
superficial branch of radial, 946

Nerve or nerves (*cont.*)
superficial branch of ulnar, 944
peronæal, 966
petrosal, greater, 898, 910
superior labial, 897
supraclavicular, 933
supra-orbital, 894
suprascapular, 937
supratrochlear, 893
sural, 963
cutaneous, lateral, 965
medial, 963
sympathetic, 779, 911
of taste, 984
temporal, deep, 900
superficial, 902
of facial, 912
temporomalar, 896
terminal, 885
terminations of motor, 781
of general sensations, 1048
third cervical, posterior division of, 929
thoracic, anterior divisions of, 948
first, 948
lateral anterior, 938
long, 937
medial anterior, 938
posterior divisions of, 930
twelfth, 950
thoracodorsal, 938
to thyrehyoideus, 925
tibial, 963
anterior, 965
of tongue, 1118
tonsillar, 917
tracts, chief, 873
transverse cervical, 933
trigeminal, 892
trochlear, 891
tympanic, of glossopharyngeal, 917, 1034
ulnar, 942
collateral, 945
of urethral bulb, 967
vagus, 917
vasomotor fibres, 780
vestibular, 913, 1047
Vidian, 898
volar digital, 942, 944
interosseous, 942
of ulnar, 944
of Wrisberg, 940
zygomatic, 896
of facial, 912
zygomaticofacial, 896
zygomaticotemporal, 896
Nerve-deafness, 915, 1048
Nervi erigentes, 978
nervorum, 780
terminales, 885
Nervous substance, grey, 34
white, 34
Nervous system, 779
autonomic, 779, 969
parasympathetic, 779, 969
sympathetic, 779, 969
cerebrospinal, 779
central part, 779
peripheral part, 779
development of, 85
Nervous tissue, 33
Nervus communicans fibularis, 965
tibialis, 963
furcalis, 951

Nervus intermedius, of Wrisberg, 907
masticatorius, 900
spinosus, 900
tentorii, 893
Network, dorsal carpal, 656, 660
dorsal venous, 724
lateral malleolar, 702
medial malleolar, 702
pericellular, 36
plantar cutaneous, 734
volar carpal, 655, 660
Neumann, dentinal sheath of, 1105
Neural canal, 52
crest, 52, 88
folds, 52
groove, 52
tube, 52
Neurenteric canal, 52
Neuroblasts, 85
Neurocentral synchondroses, 179
Neuroglia, 34
Neurokeratin, 38
Neurolemma, 39
Neurology, 779
Neuromeres, 785
Neuromuscular spindles, 1050
Neuron theory, 784
Neurons, association or intersegmental, 790
highest sensory, 876
intermediate sensory, 876
lower motor, 874, 877
lowest sensory, 876, 877
upper motor, 874, 877
Neuropore, anterior, 52
posterior, 52
Neurotendinous spindles, 1050
Neutrophil leucocytes, 28
Niche, enamel, 1108
Nidus avis of cerebellum, 817
Ninth thoracic vertebra, 172
Nipple or mammary papilla, 1241
Nissl's spindles, 36
Node, atrioventricular, 589
sino-atrial, 589
Nodes of Parrot, 273
of Heberden, 306
of Ranvier, 38
Nodule of cerebellum, 816
Nodules, aggregated lymphatic, 1160
solitary lymphatic, 1160, 1171
Non-medullated nerve-fibres, 39
Norma basalis, 247
frontalis, 255
lateralis, 251
occipitalis, 254
verticalis, 247
Normoblasts, 19
Nose, 984, 1266
accessory air-sinuses of, 991
alæ of, 984
alar cartilages of, 985
apex of, 984
applied anatomy of, 992
arteries of, 986, 990
base of, 984
bony framework of, 984
bridge of, 256, 984
cartilage of septum of, 984
cartilaginous framework of, 984

CC-0. In Public Domain. Gurukul Kangri Collection, Haridwar

Digitized by Arya Samaj Foundation Chennai and eGangotri

Nose (*cont.*)
cavities of, 986
choanæ, 986
columna of, 984
development of, 78
dorsum of, 984
external, 984
lateral cartilage of, 984
wall of, 987
lymphatics of, 755
meatuses of, 987, 988
medial wall of, 988
mucous membrane of, 989
muscles of, 440
nares, 986
nerves of, 990
olfactory region, 989
cells, 989
hairs, 989
septum mobile nasi, 984
vessels of, 990
vestibule of, 986
Notch, acetabular, 311
anterior cerebellar, 814
cardiac, 1087
ethmoidal, 219
fibular, 328
frontal, 217
intertragic, 1022
jugular, 185, 199
lacrimal, 230
mandibular, 242
mastoid, 209, 250
nasal, of frontal bone, 217
of maxilla, 230
parietal, 208
posterior cerebellar, 814
pre-occipital, 844
radial, of ulna, 293
of Rivinus, 1027
scapular, 277
sciatic, greater, 309
lesser, 310
semilunar, 292
sphenopalatine, 237, 238
superior thyreoid, 1060
supra-orbital, 217, 256, 259
ulnar, of radius, 290
Notches, cerebellar, 814
vertebral, 165
Notochord, 53
Nuchal fascia, 457
lines, 196, 254, 255
Nuck, canal of, 156, 1234
Nuclear layer of cerebellar cortex, 821
of retina, inner, 1003
outer, 1004
membrane, 2
Nucleated sheath of Schwann, 37
Nuclei of acoustic nerve, 814, 913, 914
of cochlear nerve, 814, 914
of glossopharyngeal nerve, 807, 915, 916
of oculomotor nerve, 889
olivary, 808
of origin of cerebral nerves, 874
pontis, 813
of termination of cerebral nerves, 885
of trigeminal nerve, 813, 829
of vestibular nerve, 814, 914
Nucleus of abducent nerve, 813
of accessory nerve, 912
ambiguus, 805, 807, 916
Nucleus (*cont.*)
amygdalæ, 859
of animal cell, 2
arcuatus, 808
basal optic, 838
of Bechterew, 814, 914
caudate, 858
cervical, 791
cochlear, 814, 914
cuneatus, 803
of Deiters, 814, 914
dentatus of cerebellum, 821
dorsal, of medulla spinalis, 791
emboliformis, 822
of facial nerve, 813, 908
fastigii, 822
globosus, 822
gracilis, 803
of hypoglossal nerve, 806, 923
intercalatus, 824
of lateral lemniscus, 915
lateralis, 805, 811
lentiform (or lenticular), 858
of Luys, 838
of medial longitudinal fasciculus, 827
of mesencephalic root of trigeminal nerve, 831
of oculomotor nerve, 831, 889
olivary, accessory dorsal, 808
inferior, 808
connexions of, 808
medial accessory, 808
superior, 813
of posterior commissure, 837
pulposus, 70, 359
red, 827
of Roller, 811
sacral, 791
segmentation, 48
tecti, 822
tractus solitarii, 909, 916
trapezoid, 813
of trochlear nerve, 831, 891
of vagus, 807, 917
vestibular, 814, 914
Nuel, space of, 1045
Nuhn, glands of, 1117
Nutrient artery of bone, 19
Nutritive yolk, 40

Obelion, 270
Obex, 823
Oblique cord, 387
diameter of pelvis, 314
inguinal hernia, 1173
line of the fibula, 331
of mandible, 241
of radius, 290
of thyreoid cartilage, 1061
popliteal ligament, 413
ridge of clavicle, 280
sinus of pericardium, 576
vein of left atrium, 128, 576, 709
vein of Marshall, 128, 576, 709
Obliquus auriculæ, 1024
capitis inferior, 462
superior, 462
externus abdominis, 471
aponeurosis of, 471
internus abdominis, 474
oculi inferior, 1012
actions of, 1013
superior, 1012
actions of, 1013
Obliterated ductus venosus, 742
umbilical vein, 742, 1134
Obliteration of sutures, 269
Obturator artery, 680
peculiarities of, 680
relation of, to femoral ring, 680
crest, 311
externus, 546
foramen, 312
groove, 311, 312
internus, 544
fascia of, 482
nerve to, 958
lymph-gland, 764
membrane, 544
nerve, 955
applied anatomy of, 968
accessory, 955
tubercle, anterior, 312
posterior, 309, 312
vein, 737
Obtuse margin of heart, 580
Occipital artery, 614
bone, 196
basilar part of, 198
foramen magnum of, 199
lateral parts of, 199
ossification of, 199
squama of, 196
structure of, 199
condyles, 199, 251
crest, internal, 197, 264
fonticulus, 267
fossæ, 196
groove, 209
gyri, 848
lobe, 848
lymph-glands, 751
nerve, greater, 929
smaller, 932
third, 929
plate, 71
point, 270
protuberance, external, 196, 251, 254
internal, 197
Occipital sinus, 720
sulcus, lateral, 848
transverse, 848
triangle, 622
vein, 712
Occipitalis, 437
Occipito-axial ligament, 367
Occipitofrontal or longitudinal arc of skull, 270
Occipitofrontal fasciculus, 867
Occipitofrontalis, 436
Occipitomastoid suture, 251, 254, 262
Ocular muscles, 1010
applied anatomy of, 1015
Oculomotor sulcus, 826
nerve, 889
applied anatomy of, 891
nucleus of, 831, 889
Odontoblasts, 1104, 1109
Odontoid ligaments, 367
process of epistropheus or axis, 168
Odontoma, 1111
Œdema of the glottis, 1076
Œsophageal arteries, 641, 663
glands, 1130
hiatus in diaphragm, 466
impression on liver, 1185
nerves, 921
plexus, 918, 919, 921

CC-0. In Public Domain. Gurukul Kangri Collection, Haridwar

Digitized by Arya Samaj Foundation Chennai and eGangotri

Œsophagus, 1128
abdominal portion of, 1129
applied anatomy of, 1130
cervical portion of, 1128
glands of, 1130
lymphatic vessels of, 778
structure of, 1129
surface marking of, 1279
thoracic portion of, 1128
vessels and nerves of, 1130
Olecranon, 292
fracture of, 294, 529
fossa, 285
Olfactory bulb, 851, 872
structure of, 861
cells, 101, 989
fasciculus, 862
groove, 260
hairs, 989
lobe, 851
nerves, 885
applied anatomy of, 887
development of, 101
pits, 78, 79
plates, 78
region of nasal cavities, 987, 989
striæ, 851
sulcus of frontal lobe, 847
of nasal cavity, 987
tract, 851
trigone, 851
Olive, 802
peduncle of, 808
Olivary nucleus, dorsal accessory, 808
inferior, 808
medial accessory, 808
superior, 813
Olivospinal fasciculus (Helweg), 795
Omental bursa, 1136, 1139
boundaries of, 1140
bursa majoris, 1140
bursa minoris, 1140
epiploic foramen, or foramen of Winslow, 1139
foramen bursæ majoris, 1140
recess, inferior, 1140
lienal, 1140
middle, 1140
superior, 1140
septum bursarum, 1140
vestibule of, 1140
Omentum, gastrosplenic, 1139
greater, 1142
lesser, 1135, 1141
Omohyoideus, 454
Oöcytes, primary, 40
secondary, 43
Oögonia, 40
Oöplasm, 40
Opening of aorta in left ventricle, 586
aortic, in diaphragm, 466
atrioventricular, left, 586
right, 583
of coronary sinus, 582
of inferior vena cava, 582
œsophageal, in diaphragm, 466
of pulmonary artery, 583
veins, 585
saphenous, 534
of superior vena cava, 581
of thorax, lower, 574
upper, 574
Opening, vena-caval, in diaphragm, 466
Openings in diaphragm, 466
in roof of fourth ventricle, 823
Opercula of insula, 849
Ophryon, 270
Ophthalmic artery, 626
nerve, 893
veins, 722
Opisthion, 270
Opisthotic centre of temporal bone, 213
Opponens digiti quinti, of hand, 526, of foot, 565
pollicis, 523
Optic axis, 993
bulb, 102
chiasma or commissure, 840, 888
cup, 102, 1003
disc, 1002
foramen, 200, 204, 259, 261
groove, 200
nerve, 887
applied anatomy of, 889
papilla of, 1003
sheaths of, 887
radiations, 835, 841, 889
recess, 841
stalks, 93, 102
tracts, 840, 889
vesicles, 93, 101
Ora serrata, 1002, 1005
Oral part of pharynx, 1124
of tongue, 1111
Orbicular ligament, 387
Orbicularis oculi, 438
ciliary bundle of, 438
lacrimal portion of, 438
orbital portion of, 438
palpebral portion of, 438
pars tarsalis, 439
tensor tarsi, 438
oris, 443
Orbiculus ciliaris, 998
Orbital fascia, 1015
fissure, inferior, 253, 259
superior, 203, 259, 261
gyri, 847
index, 271
nerves, from sphenopalatine ganglion, 899
operculum, 849
part of frontal bone, 218
plates of frontal bone, 218
process of palatine bone, 238
of zygomatic bone, 240
septum, 1017
sulcus, 847
surface of maxilla, 230
tubercle, 259
vein, 711
Orbitalis muscle, 1013
Orbits, 257
relation of nerves in, 907
Organ, enamel, 1108
of Giraldès, 1217
of hearing, 1022
subdivisions of, 1022
of Rosenmüller, 151, 1229
of sight, 993
of smell, 984
spiral, of Corti, 1044
of taste, 983
Organic reflexes, 877
Organs, accessory, of the digestive tube, 1093
Organs (*cont.*)
accessory, of the eye, 1010
chromaffin, 100, 1249
endocrine, 1243
genital, of female, 1226
external, 1238, 1291
of male, 1212, 1290
development of, 149, 158
of Golgi, 1050
of the senses, 983
peripheral, of the special senses, 983
respiratory, 1059
development of, 145
urinary, 1191
urogenital, 1191
development of, 149
vomeronasal, of Jacobson, 81, 988
Orifice, aortic, 586
atrioventricular, left, 586
right, 582
cardiac, of stomach, 1146
of mouth, 1094
of pulmonary artery, 583
pyloric, of stomach, 1147
urethral, external, in female, 1240
in male, 1210
internal, 1207
of uterus, external, 1233
internal, 1232
vaginal, 1239
Orifices of ureters, 1206
Origin of muscles, 434
Origin of nerves, 781
Orthognathous skulls, 271
Os acetabuli, 313
calcis, 339
capitatum, 301
centrale, 305
coccygis, 179
cordis, 587
coxæ, 306
cuboideum, 344
cuneiforme primum, 342
secundum, 342
tertium, 343
ethmoidale, 220
frontale, 217
hamatum, 302
hyoideum, 246
ilii, 306
ala of, 307
body of, 306
crest of, 309
glutæal lines of, 307, 308
spines of, 309
tuberosity of, 309
incisivum, 234
innominatum, 306
ischii, 309
body of, 309
ramus inferior, 310
superior, 310
tuberosity of, 310
lunatum, 299
magnum, 301
multangulum majus, 300
minus, 300
naviculare manus, 298
pedis, 341
occipitale, 196
pisiforme, 300
planum of ethmoidal bone, 222
pubis, 310
angle of, 311

CC-0. In Public Domain. Gurukul Kangri Collection, Haridwar

Digitized by Arya Samaj Foundation Chennai and eGangotri

Os pubis (*cont.*)
body of, 310
crest of, 311
iliopectineal eminence of, 311
obturator crest of, 311
pecten, 311
ramus, inferior, 311
superior, 310
spine of, 311
tubercle of, 311
sacrum, 174
sphenoidale, 200
trigonum of talus, 339, 348
triquetrum, 299
Ossa carpi, 298
cranii, 196
cuneiformia, 342
faciei, 230
lacrimalia, 225
metacarpi, 302
metatarsi, 344
nasalia, 226
palatina, 236
parietalia, 215
suturarum, 229
tarsi, 334
temporalia, 206
zygomatica, 239
Ossein, 22
Osseous labyrinth, 1036
bony semicircular canals, 1037
cochlea, 1037
spiral lamina, 1038
secondary, 1038
vestibule, 1036
Ossicle, pterion, 229
Ossicles, auditory, 1031
incus, 1032
malleus, 1031
stapes, 1032
development of, 108
ligaments of, 1033
Ossification, centre of, 23
intracartilaginous, 22
intramembranous, 22
Ossification of—
atlas, 180
axis, 180
carpals, 305
clavicle, 281
coccyx, 182
epistropheus, 180
ethmoidal, 224
femur, 325
fibula, 333
frontal, 220
hip-bone, 312
humerus, 286
hyoid, 247
incus, 1032
inferior nasal concha, 225
lacrimal, 226
lumbar vertebræ, 181
malleus, 1032
mandible, 243
maxilla, 235
metacarpals, 306
metatarsals, 348
nasal, 227
occipital, 199
os coxæ or innominatum, 312
palatine, 238
parietal, 217
patella, 334
phalanges of fingers, 306
Ossification of (*cont.*)
phalanges of toes, 348
radius, 291
ribs, 192
sacrum, 181
scapula, 279
seventh cervical vertebra, 181
sphenoidal, 205
stapes, 1032
sternum, 187
tarsals, 347
temporal, 213
tibia, 330
ulna, 294
vertebral column, 179
vomer, 228
zygomatic, 240
Osteoblasts, 18, 22, 23
Osteoclasts, 24, 1110
Osteogenetic fibres, 22
Osteology, 161
Osteomalacia, 317
Osteomyelitis, 25
Ostium, abdominal, of uterine tube, 1230
maxillare, 266, 988
pharyngeal, of auditory tube, 1122
primitive urogenital, 159
primum, of heart, 115
secundum, of heart, 115
Otic ganglion, 903
Otoconia, 1041
Otocyst, 106
Outlet of pelvis, 314
Ova, holoblastic, 48
human, 40
meroblastic, 48
primitive, 153
Oval area of Flechsig, 797
bundle, 86, 91, 100
Ovarian arteries, 674
cysts, 1229
fimbria, 1230
follicles, 1228
fossa, 1138, 1226
plexus of nerves, 981
pregnancy, 47
veins, 741
Ovaries, 1226
applied anatomy of, 1229
corpora lutea of, 1229
descent of, 156
development of, 153
interstitial cells of, 1227
ligaments of, 1226
lymphatic vessels of, 774
structure of, 1227
vessels and nerves of, 1229
vesicular or Graafian follicles of, 1228
Ovariotomy, 1229
Ovula Nabothi, 1236
Ovum, 40
corona radiata of, 42
coverings of, 41
discharge of, 1228
fertilisation of, 46
germinal spot of, 40
vesicle of, 41
implantation or imbedding of, 62
maturation of, 42
mature, 43
oöplasm of, 40
segmentation of, 48
structure of, 40
Ovum (*cont.*)
yolk of, 40
zona pellucida or striata of, 41
Owen, contour lines of, 1105
Oxyntic cells, 1152
glands, 1151
Oxyphil leucocytes, 28

Pacchionian glands, 882
Pacinian corpuscles, 1049
Pad, infrapatellar, 411
retropubic, 1202
suctorial, 443
Pain sense, 875
Palate, 1095
aponeurosis of, 1120
applied anatomy of, 82, 1095
arches of, 1118
cleft, 82
development of, 79
hard, 248, 1095
primitive, 79
soft, 1095
muscles of, 1120
mucous membrane of, 1095
paralysis of, 1096
vessels and nerves of, 1095
Palatine aponeurosis, 1120
artery, ascending, 612
descending, 620
applied anatomy of, 620
greater, 620
smaller, 620
bone, 236
horizontal part of, 236
maxillary process of, 237
orbital process of, 238
ossification of, 238
pyramidal process or tuberosity of, 238
sphenoidal process of, 238
vertical part of, 236
foramen, greater, 249
foramina, lesser, 238, 249
nerves, 899
process of maxilla, 234
processes of fœtus, 80
tonsils, 1118
development of, 134
lymphatic vessels of, 755
uvula, 1095
velum, 1095
Palatoglossus, 1120
Palatopharyngeus, 1121
Palatum durum, 1095
molle, 1095
Palmar aponeurosis, 521
applied anatomy of, 523
arch, deep, 656
superficial, 660
cutaneous branch of median nerve, 942
of ulnar nerve, 944
ganglion, compound, 523
Palmaris brevis, 525
longus, 508
Palmate folds of cervix uteri, 1233, 1236
Palpebræ, 1015
Palpebral arteries, lateral, 626
medial, 628
commissures, 1015
fissure, 1016
ligament, lateral, 1017
medial, 439, 1017
nerves, from maxillary, 897
raphe, lateral, 439

CC-0. In Public Domain. Gurukul Kangri Collection, Haridwar

Digitized by Arya Samaj Foundation Chennai and eGangotri

Pampiniform plexus, 741, 1219, 1229
Pancreas, 1176
accessory duct of, 144, 1180
applied anatomy of, 1181
body of, 1178
development of, 144
duct of, 144, 1179
head of, 1176
lymphatic vessels of, 771
neck of, 1178
relations of, 1176
structure of, 1180
surface marking of, 1287
tail of, 1179
uncinate process of, 1176
vessels and nerves of, 1181
Pancreatic branches of splenic (lienal) artery, 669
Pancreatic duct, 144, 1179
accessory, 144, 1180
veins, 742
Pancreatica magna artery, 669
Pancreaticoduodenal artery, inferior, 667
superior, 668
lymph-glands, 769
veins, 744
Pancreaticolienal lymph-glands, 766
Pannus, 1008
Papilla duodeni, 1155, 1190
lacrimal, 1016
mammary, 1241
of optic nerve, 1003
Papillæ lacrimales, 1016, 1019
of corium, 1054
renal, 1194
of tongue, 1113
conicæ, 1114
fungiformes, 1113
lenticulares, 1113
simplices, 1114
vallatæ, 1113
Papillary layer of corium, 1054
process of liver, 1184
Paracardial lymph-glands, 766
Paracentesis of pericardium, 577
thoracis, 1080
Paracentral lobule, 847
Paradidymis, 151, 1217
Paraduodenal fold, 1145
fossa, 1145
Paraganglia, 1249
Parallel sulcus, 849
Paralyses, alternate, 814
Paralysis, of cervical sympathetic, 982
conjugate, 814
Erb's, 946
Klumpke's, 946
infantile, 25, 798
lower segment, 814
motor, 876
sensory, 876
Paramastoid process, 199
Paramedial sulcus, 847
Parametritis or pelvic cellulitis, 1237
Parametrium, 1233
Paranephric body, 1195
Paranucleus, 1180
Paraplasm, 2
Pararectal fossa, 1137
lymph-glands, 768
Paraseptal cartilage, anterior, 76, 229
Paraseptal cartilage (*cont.*)
common, 76
posterior, 76
Parasympathetic nervous system, 779, 969
cranial fibres, 969
sacral fibres, 969
Paraterminal bodies, 99
Parathyreoid glands, 1246
applied anatomy of, 1247
development of, 135
structure of, 1247
Paratracheal lymph-glands, 754
Para-umbilical veins, 744
Paravesical fossa, 1138, 1202
Paraxial mesoderm, 52
Parietal bone, 215
ossification of, 217
branch of superficial temporal artery, 616
cells of fundus glands, 1152
eminence, 215, 247, 251
emissary vein, 724
foramen, 215, 247, 260
lobe, 847
gyri of, 847
sulci of, 847
lobules, 848
lymph-glands of abdomen and pelvis, 763
of thorax, 775
notch, 208
pleura, 1077
tuberosity, 215, 247, 251
veins of embryo, 125
Parietes, development of, 68
Parietomastoid suture, 251, 254, 262
Parieto-occipital fissure, 845
Parolfactory area of Broca, 852
sulcus, anterior, 852
Paronychia, thecal, 523
Paroöphoron, 151, 1229
Parosmia, 887
Parotid duct, 1097
surface marking of, 1265
gland, 1096
accessory part of, 1096
applied anatomy of, 1101
duct of, 1097
retromandibular process of, 1096
structure of, 1100
structures within, 1097
surface marking of, 1265
vessels and nerves of, 1098
lymph-glands, 751
plexus, 910
Parotideomasseteric fascia, 448
Parrot's nodes, 273
Pars analis recti, 1169
basilaris, 847
ciliaris retinæ, 102, 999, 1002, 1005
flaccida of tympanic membrane, 1028
intermedia of vestibular bulb, 1240
iridica retinæ, 102, 1000, 1002, 1005
mamillaris hypothalami, 94
optica hypothalami, 95
orbitalis, 847
tensa of tympanic membrane, 1028
triangularis, 847
uterina tubæ, 1230
Passages, pleural, 147
Patella, 333
applied anatomy of, 334
fractures, 334, 568
movements of, 418
ossification of, 334
structure of, 334
surface anatomy of, 1303
Patellar fold, 411
plexus, 955, 957
retinacula, 410
surface of femur, 323
Pecten pubis, 311
Pectinate ligament of iris, 997
Pectineal line, 321
Pectineus, 538
nerve to, 957
Pectiniform septum, 1221
Pectoral fascia, 496
Pectoralis major, 496
minor, 498
Peculiarities in vascular system of fœtus, 592
Pedicles of a vertebra, 164
Peduncle of corpus callosum, 852
of olive, 808
Peduncles, cerebellar, 818, 819
cerebral, 825
Pedunculated hydatid, 1212
Pelvic brim, 313
cellulitis, 1237
colon, 1162
curve of vertebral column, 183
diaphragm, 482,
applied anatomy of, 486
fascia, 482
diaphragmatic part of, 483
girdle, 274
mesocolon, 1135
plexuses, 981
portion of cloaca, 157
portion of sympathetic system, 978
splanchnic nerves, 928, 969, 978
Pelvis, 313, 1133
applied anatomy of, 317
axes of, 314
brim of, 313
cavity of lesser, 314
diameters of, 313, 314
fractures of, 317
in fœtus, 317
greater, 313
inferior aperture or outlet of, 314
inlet of, 313
lesser, 313
lymph-glands of, 763
lymphatic vessels of, 768
major, 313
male and female, differences between, 315
mechanism of, 401
minor, 313
muscles of, 482
in osteomalacia, 317
outlet of, 314
position of, 315
renal, 1193
in rickets, 317
superior aperture or inlet of, 313
transverse ligament of, 489
Penis, 1220

CC-0. In Public Domain. Gurukul Kangri Collection, Haridwar

Digitized by Arya Samaj Foundation Chennai and eGangotri

Penis (*cont.*)
applied anatomy of, 1223
body of, 1222
corona glandis, 1222
corpora cavernosa, 1220
corpus cavernosum urethræ or corpus spongiosum, 1221
crura of, 1220
deep artery of, 681
dorsal artery of, 682
nerve of, 967
veins of, 739
extremity of, 1222
fundiform ligament of, 1221
glans, 1221, 1222
neck of, 1222
prepuce or foreskin of, 1222
root of, 1221
septum pectiniforme of, 1221
structure of, 1222
suspensory ligament of, 1222
vessels and nerves of, 1222
Perforated substance, anterior, 852
posterior, 825
Perforating arteries, of hand, 656
from internal mammary, 640
from peronæal, 705
from plantar arch, 706
from profunda femoris, 694
cutaneous nerve, 966
fibres of bone, 21
Perforator of spermatozoön, 44
Pericardiacophrenic artery, 640
Pericardial area, 50
arteries, 640, 663
Pericardiotomy, 577
Pericardium, 574
applied anatomy of, 576
fibrous, 576
nerves of, 576
oblique sinus of, 576
relations of, 574
serous, 576
structure of, 575
transverse sinus of, 576
vessels of, 576
vestigial fold of, 576
Pericellular network, 36
Perichondrium, 15, 23
Perichorioidal lymph-space, 994
Perilymph, 1039
Perimetritis, 1230
Perimysium, 29
Perinæal artery, 681
transverse, 681
body, 1170, 1238
branch of fourth sacral nerve, 967
branches of sacral plexus, 961
ectopia testis, 1215
flexure of rectum, 1168
nerve, 966
nerves, superficial, 967
Perinæum, boundaries of, 486
central tendinous point of, 487
lymphatic vessels of, 769
muscles of, 486
surface anatomy of, 1289
Perinephric abscess, 1200
Perineurium, 780
Periods of activity and rest of cardiac cycle, 591
Periosteum, 18
internal, 18
Periostitis, acute infective, 25
Periotic cistern, 107
Peripheral band, dorsal, 796
Peripheral end-organs, 1048
Peripheral organs of the special senses, 983
terminations of motor nerves, 781
of nerves of general sensations, 1048
Peritoneal cavity, 1134
fossæ or recesses, 1144
applied anatomy of, 1146
Peritoneum, 1134
epiploic foramen of, 1139
lesser sac or omental bursa of, 1139
ligaments of, 1140
main cavity or greater sac of, 1134
horizontal disposition of, in lower abdomen, 1138
in upper abdomen, 1139
in pelvis, 1137
vertical disposition of, 1134
mesenteries of, 1143
omental bursa of, 1139
vertical disposition of, 1136
omentum, greater, 1142
lesser, 1141
parietal portion of, 1134
recesses or fossæ of, 1144
applied anatomy of, 1146
visceral portion of, 1134
Permanent cartilage, 14
choanæ, 80
kidney, 156
teeth, 1102
development of, 1106
successional, 1110
superadded, 1110
Peronæal anastomotic nerve, 965
artery, 705
peculiarities of, 705
nerve, common, 965
applied anatomy of, 969
surface marking of, 1311
deep, 965
superficial, 966
retinacula, 560
sulcus, 344
tubercle, 340
veins, 736
Peronæus brevis, 557
longus, 556
tertius, 551
Perpendicular fasciculus, 867
line of ulna, 293
Pes or base of cerebral peduncle, 827
cavus, 432
hippocampi, 857
planus or flat-foot, 432
Petit, canal of, 1006
triangle of, 495
Petro-occipital fissure, 251, 263
Petromastoid part of temporal bone, 213
Petrosal artery, superficial, 618
nerve, deep, 898, 973
external, 910, 975
greater superficial, 898, 910
lesser superficial, 903, 1034
process, 201
Petrosal sinuses, inferior, 714, 723
superior, 722
sulci, inferior, 198
Petrosphenoidal fissure, 250
Petrosquamosal suture, 208, 210, 212
Petrosquamous sinus, 720
Petrotympanic fissure, 208, 250, 1028
Petrous ganglion, 916
portion of temporal bone, 210
Peyer's glands, 1160
Phalangeal processes of Corti's rods, 1045
of Deiters' cells, 1045
Phalanges of cochlea, 1046
digitorum manus, 304
pedis, 346
of foot, 346
ossification of, 348
of hand, 304
applied anatomy of, 306
ossification of, 306
Phallic portion of cloaca, 157
Phallus, 159
Pharyngeal aponeurosis, 1126
artery, ascending, 610
branch of internal maxillary artery, 620
bursa, 1124
canal, 254
grooves, 76
nerve, from sphenopalatine ganglion, 900
nerves, from glossopharyngeal, 917
from vagus, 919
ostium of auditory tube, 1122
part of tongue, 1112
plexus of nerves, 917, 919, 974
of veins, 714
pouches, 76
recess, 1123
tonsil, 1123
tubercle, 198, 250
veins, 714
Pharyngobasilar fascia, 1124
Pharyngo-epiglottic folds, 1062
Pharyngopalatine arch, 1118
Pharyngopalatinus, 1121
Pharynx, 1122
applied anatomy of, 1127
laryngeal part of, 1124
lymphatic vessels of, 757
muscles of, 1125
nasal part of, 1122
oral part of, 1124
structure of, 1124
Philtrum, 443, 1094
Phrenic arteries, inferior, 675
superior, 663
ganglion, 935, 981
nerve, 934
applied anatomy of, 935
plexus of nerves, 980
veins, inferior, 741
superior, 729
Phrenicocolic ligament, 1144, 1167
Phrenicocostal sinus, 1079
Phrenicopericardiac ligament, right, 740
Phthisical chest, 195

CC-0. In Public Domain. Gurukul Kangri Collection, Haridwar

Digitized by Arya Samaj Foundation Chennai and eGangotri

Pia mater, cerebral, 884
spinal, 884
Pigeon-breast, 195
Pigment, 13
applied anatomy of, 14
cells, 9
of iris, 1000
of skin, 1053
Pigmented connective-tissue cells, 13
epithelial cells, 13
layer of retina, 1003
Piles, 739
Pillars of Corti, 1044
of fauces, 1118
of fornix, 862, 863
of subcutaneous inguinal ring, 472
Pineal body, 836
applied anatomy of, 837
development of, 94
stalk of, 836
structure of, 836
cells, 836
recess, 842
Pinna, 1022
development of, 108
Piriformis, 543
fascia of, 483
nerve to, 959
Pirogoff's amputation, 349
Pisiform bone, 300
ossification of, 305
Pisohamate ligament, 393
Pisometacarpal ligament, 393
Pit, anal, 142
auditory, 106
Pits, olfactory, 78, 79
Pituitary body, 838
applied anatomy of, 840
development of, 135
Pivot-joint, 354
Placenta, 64
applied anatomy of, 66
basal plate of, 65
circulation through, 66, 592
cotyledons of, 66, 67
fibrinoid substance of, 65
fœtal portion of, 64
marginal sinus of, 66
maternal portion of, 65
prævia, 67
separation of, 67
septa of, 66
Placodes, 100
Plain muscle, 32
Plane, intertubercular or transtubercular, 1133
transpyloric, 1133
Plantar aponeurosis, 561
arch, 706
applied anatomy of, 707
artery, medial or internal, 706
surface markings of, 1311
deep, 703
lateral or external, 706
surface marking of, 1311
calcaneocuboid ligament, 426
calcaneonavicular ligament, 427
applied anatomy of, 427
cutaneous venous arch, 734
network, 734
digital veins, 736
interosseus muscle, first, 565
ligament, long, 426
short, 426
Plantar metatarsal arteries, 707
muscles of foot, 561
nerve, lateral, 964
medial, 963
process of navicular bone, 342
veins, 736
venous arch, cutaneous, 734
deep, 734
network, cutaneous, 734
Plantaris, 553
rupture of tendon of, 558
Planum nuchale, 196, 255
occipitale, 196, 254
Plasma cells, 9
Plasma or liquor sanguinis, 26
Plate or plates—
auditory, 106
basal, of placenta, 65
orbital, of frontal bone, 218
occipital, 71
olfactory, 78
sternal, 71, 187
urethral, 159
Platelets of blood, 28
Platyrhine skulls, 271
Platysma, 449
Pleura, 1077
applied anatomy of, 1080
cavity of, 1077
costal, 1077
cupula of, 1078
diaphragmatic, 1078
lymphatic vessels of, 778
mediastinal, 1079
parietal, 1077
pulmonary, 1077
structure of, 1080
surface markings of, 1278
vessels and nerves of, 1080
Pleural passages, 147
Pleurisy, 1080
Pleuropericardial membrane, 149
Pleuroperitoneal membrane, 149
Plexiform layer of retina, inner, 1003, outer, 1004
Plexus or plexuses—
abdominal aortic, 981
annular, of cornea, 997
aorticus thoracalis, 976
Auerbach's, 1162
basilar, 723
brachial, 935
cardiac, deep part, 978
superficial part, 979
carotid, internal, 973
of veins, 724
cavernous, 973
cervical, 931
posterior, 929
chorioid of fourth ventricle, 823
of lateral ventricle, 864
of third ventricle, 841
coccygeal, 967
cœliac, 979
of cornea, annular, 997
intra-epithelial, 997
subepithelial, 997
coronary, 979
of Exner, 868
gastric, anterior, 921
inferior, 980
posterior, 921
gastro-epiploic, 980
great, of sympathetic, 979
Plexus or plexuses (*cont.*)
hæmorrhoidal, middle, 982
superior, 981
venous, 738, 1171
hepatic, 980
hypogastric, 981
infra-orbital, 897, 912
interlobular, 1188
intra-epithelial, of cornea, 997
lienal, 980
lumbar, 952
Meissner's, 1162
mesenteric, inferior, 981
superior, 981
myenteric, 1162
œsophageal, 918, 919, 921
ovarian, 981
pampiniform, 741, 1219, 1229
parotid, 910
patellar, 955, 957
pelvic, 981
pharyngeal, 917, 919, 974
venous, 714
phrenic, 980
prostatic, 982
venous, 739
pterygoid, 711
pudendal, 966
venous, 738
pulmonary, 918, 921
renal, 981
sacral, 958
sagittal, 130
solar, 979
spermatic, 981
splenic, 980
of submucosa, 1162
subepithelial, of cornea, 997
subpleural, mediastinal, 640
subsartorial, 957
suprarenal, 981
of sympathetic, 978
tympanic, 916, 1034
uterine, 982
venous, 739
vaginal, 982
venous, 739
vesical, 982
venous, 739
Plica fimbriata of tongue, 1112
gubernatrix, 155
lacrimalis of Hasner, 1020
semilunaris of conjunctiva, 1018
of tonsil, 1118
sublingualis, 1099
supratonsillaris, 1118
triangularis of tonsil, 1118
vascularis, 155
vesicalis transversa, 1138
Plicæ transversales recti, 1168
ureterícæ, 1206
Pneumothorax, 1080, 1091
Pogonion, 269
Point, central tendinous of perinæum, 487
Polar bodies or polocytes, 42, 43
Pole, embryonic, 49
Poles of cerebral hemispheres, 844
of bulb of eye, 993
of lens, 1007
Poliomyelitis, acute anterior, 798
Polocytes or polar bodies, 42, 43

CC-0. In Public Domain. Gurukul Kangri Collection, Haridwar

Digitized by Arya Samaj Foundation Chennai and eGangotri

Polymorphonuclear leucocytes, 28
Polyspermy, 47
Pomum Adami, 1060
Pons, 811
applied anatomy of, 814
development of, 92
dorsal or tegmental part, 813
structure of, 812
ventral or basilar part, 812
hepatis, 1183
Ponticulus of auricula, 1023
Pontine arteries, 638
flexure of embryonic brain, 90
Popliteal artery, 696
applied anatomy of, 697
branches of, 698
peculiarities of, 697
surface marking of, 1311
fossa or space, 695
ligament, arcuate, 413
retinaculum of, 413
oblique, 413
line of tibia, 328
lymph-glands, 761
nerve, external, 965
internal, 963
surface of femur, 321
vein, 736
Popliteus, 553
Pore, gustatory, 983
Porta hepatis, 1183
Portal canals, 1188
pyæmia, 745
vein, 742
applied anatomy of, 744
development of, 124
Porus acusticus externus, 212, 213, 252
internus, 210
Position of pelvis, 315
Postanal gut, 142
Postaxial borders of limbs, 82
Postcentral sulcus, 847
Posterolateral ganglionic arteries, 631, 638
Posteromedial ganglionic arteries, 631, 638
Postganglionic nerve-fibres, 779, 928
Postglenoid tubercle, 207
Postnodular fissure, 92, 816
Postpartum hæmorrhage, 67
Postpyramidal fissure, 816
Postsphenoidal part of sphenoidal bone, 205
Pott's fracture, 568
Pouch of Douglas, 1136, 1234
of Prussak, 1034
of Rathke, 136
of Seessel, 136
Pouches, pharyngeal, 76
Poupart's ligament, 473
Præcuneus, 848
Præputium clitoridis, 1239
Pre-aortic lymph-glands, 765
Pre-auricular sulcus of ilium, 309
Pre-axial borders of limbs, 82
Precentral fissure of cerebellum, 815
Precentral sulcus of cerebrum, 846
Prechordal part of base of skull, 72
Preclival fissure, 815
Preganglionic nerve-fibres, 779, 928
Pregnancy, abdominal, 47
ovarian, 47
tubal, 47
Prelaryngeal lymph-glands, 753
Premature synostosis, 26
Premaxilla, 234, 248
Premolar teeth, 1103
Pre-occipital notch, 844
Prepuce of clitoris, 1239
of penis, 1222
development of, 159
Preputial glands, 1222
sac, 1222
Prepyramidal fissure, 816
Presbyopia, 1009
Presphenoidal part of sphenoidal bone, 205
Pressure epiphyses, 25
Pretarsal space, 1010
Pretracheal fascia, 449
lymph-glands, 753
Prevertebral fascia, 448
Prickle-cells, 7, 1053
Primary areolæ of bone, 23
blood-vessels of head, 128
curves of vertebral column, 182
head-veins, 128
labial groove, 133
lamellæ of bone, 20
meatus, 108
nail-fields, 85
oöcytes, 40
spermatocytes, 44
Primitive aortæ, 110, 120
choanæ, 79
costal arches, 70
falx cerebri, 97
groove, 50
jugular veins, 112, 125
ova, 153
palate, 79
segments, 54, 68
sheath of nerve-fibre, 37, 39
streak, 49
urogenital ostium, 159
Princeps cervicis artery, 614
pollicis artery, 656
Principal cavity of left atrium, 585
of right atrium, 580
motor tracts, 873
Prismata adamantina, 1106
Prisms, enamel, 1106
Procerus, 440
Process or processes—
accessory, of vertebræ, 174
alar, of ethmoidal bone, 220
alveolar, of maxilla, 233
anterior, of malleus, 1032
articular, of vertebræ, 165
axis-cylinder, of nerve-cell, 35
caudate, of liver, 1184
ciliary, 998
clinoid, anterior, 204, 261
middle, 201, 261
posterior, 201, 261
condyloid, of mandible, 243
coracoid, 278
coronoid, of mandible, 242
of ulna, 292
costal, of a cervical vertebra, 167
descending, of lacrimal bone, 225
Process or processes (*cont.*)
of dura mater, 878
ethmoidal, of inferior nasal concha, 225
falciform, of sacrotuberous ligament, 399
frontal, of maxilla, 232
frontonasal, 78
frontosphenoidal, of zygomatic bone, 239
globular, 79
infra-orbital, of zygomatic bone, 240
intrajugular, 199
jugular, 199, 251
lacrimal, of inferior nasal concha, 225
lateral, of malleus, 1032
lateral nasal, 79
lenticular, of incus, 1032
mamillary, of vertebræ, 174
mastoid, 208, 253
maxillary, of fœtus, 77, 79
of inferior nasal concha, 225
of palatine bone, 237
medial nasal, 79
muscular, of arytænoid, 1062
nasal, of fœtus, 79
of frontal bone, 217
odontoid, of axis or epistropheus, 168
orbital, of palatine bone, 238
of zygomatic bone, 240
palatine, of fœtus, 80
of maxilla, 234
papillary, of liver, 1184
paramastoid, 199
petrosal, 201
phalangeal, of Corti's rods, 1045
of Deiters' cells, 1045
plantar of navicular bone, 342
protoplasmic, of nerve-cells, 35
pterygoid, of sphenoidal bone, 204
pyramidal, of palatine bone, 238, 249
retromandibular, of parotid gland, 1096
sphenoidal, of palatine bone, 238
of septal cartilage of nose, 984
spinous, of ilium, 309
of vertebræ, 165
styloid, of fibula, 331
of radius, 291
of temporal bone, 213, 250, 253
of third metacarpal bone, 304
of ulna, 294
supracondylar, 284*
temporal, of zygomatic bone, 240
transverse, of vertebræ, 165
trochlear, of calcaneus, 340
uncinate, of ethmoidal bone, 222, 266
of head of pancreas, 1176
vaginal, of sphenoidal bone, 202, 204
of temporal bone, 212
vermiform, 1164
vocal, of arytænoid, 1062

CC-0. In Public Domain. Gurukul Kangri Collection, Haridwar

Digitized by Arya Samaj Foundation Chennai and eGangotri

Process or processes (*cont.*)
xiphoid, 187
zygomatic, of frontal bone, 217
of maxilla, 232
of temporal bone, 206
Processus brevis of malleus, 1032
cochleariformis, 212, 1030
gracilis of malleus, 1032
tubarius, 205
Proctodæum, 142
Prodentine, 1109
Profunda artery, inferior, 652
superior, 651
brachii artery, 651
cervicalis artery, 642
femoris artery, 693
vein, 737
linguæ artery, 611
Prognathous skulls, 271
Progressive facial hemiatrophy, 982
Projection fibres of cerebral hemispheres, 866
of cerebellum, 818
Prominence, of facial canal, 1030
laryngeal, 1060
Promontory, of sacrum, 176
of tympanic cavity, 1029
Pronation, movement of, 387, 389
Pronator quadratus, 512
teres, 508
applied anatomy of, 508
Pronephric duct, 149
Pronephros, 149
Pronucleus, female, 42
male, 46
Pro-otic centre of temporal bone, 213
Proper fasciculus, anterior, 794
lateral, 795, 799
Proprioceptive sensory impulses, 874
Prosencephalon, 53, 93, 831
Prostate, 1223
applied anatomy of, 1225
capsule of, 1224
development of, 157
isthmus of, 1223
lobes of, 1223
lymphatic vessels of, 772
sheath of, 1224
structure of, 1224
vessels and nerves of, 1225
Prostatectomy, 1225
Prostatic ducts, orifices of, 1209
plexus of nerves, 982
of veins, 739
applied anatomy of, 739
portion of urethra, 1208
sinus, 1209
utricle, 1209
veins, 739
Prosthion, 269
Protoplasm, 1
Protoplasmic processes of nerve-cells, 35
Protuberance, mental, 241, 257
occipital, external, 196, 251, 254
internal, 197
Prussak, pouch of, 1034
Psalterium, 862
Pseudonucleoli, 2
Pseudopodium, 28
Psoas abscess, 532
major, 531
applied anatomy of, 532
fascia covering, 530
minor, 532
Pterion, 270
ossicle, 229
Pterotic centre of temporal bone, 213
Pterygoid canal, 204, 250, 254
artery of, 620, 626
nerve of, 898
fissure, 204
fossa, 204
fovea, 243
hamulus, 204
lamina, medial, 204, 250
lateral, 204, 250
muscles, 445, 446
plexus of veins, 711
processes of sphenoidal bone, 204
tubercle, 204, 250
Pterygoideus externus, 445
nerve to, 900
internus, 446
nerve to, 900
Pterygomandibular raphe, 443
Pterygomaxillary fissure, 254
Pterygopalatine canal, 231, 237
fossa, 254
sulcus, 204, 237
Pterygospinous ligament, 206, 448
Ptosis of upper eyelid, 891, 1021
of liver, 1191
Pubic angle, 311
arch, 314
bone, 310
branch of inferior epigastric artery, 686
of obturator artery, 680
crest, 311
ligaments, 400
symphysis, 400
tubercle or spine, 311
vein, 737
Puboanalis, 485
Pubocapsular ligament, 405
Pubococcygeus, 485
Puboprostatic ligaments, 484, 1205
Puborectalis, 485
Pubovesicales, 1207
Pudendal artery, accessory, 682
deep external, 693
internal, 680
in female, 682
in male, 681
superficial external, 693
surface marking of, 1311
cleft or rima, 1238
nerve, 966
inferior, 961
plexus of nerves, 966
of veins, 738
veins, internal, 737
Pudendum, 1238
Pudic nerve, 966
veins, internal, 737
Pulmonary artery, 595
applied anatomy of, 596
atresia of, 596
embolism of, 597
orifice of, in right ventricle, 583
stenosis of, 596
circulation, 569
Pulmonary emphysema, 195, 1091
ligament, 1079
lymph-glands, 776
pleura, 1077
plexus, anterior, 918, 921
posterior, 919, 921
ridge, 149
semilunar valves, 584
substance, 1099
veins, 708
openings of, in left atrium, 585
Pulmones, 1084
Pulp, dental, 1104
enamel, 1108
splenic, 1254
Pulp-cavities of teeth, 1104
Pulvinar, 832
Puncta lacrimalia, 1016, 1019
vasculosa, 852
Pupil, 999
congenital atresia of, 104
Pupillary membrane, 104, 1001
Purkinje, cells of, 821
fibres of, 33
Purple, visual, 14, 1002
Putamen, 858
Pyæmia, 25
portal, 745
Pylephlebitis, suppurative or septic, 745
Pyloric artery, 668
glands, 1152
orifice of stomach, 1147
part of stomach, 1147, 1148
sphincter, 1149
vein, 744
Pyopneumothorax, 1080
Pyorrhea alveolaris, 1095
Pyosalpinx, 1231
Pyramid of cerebellum, 817
of medulla oblongata, 801
of temporal bone, 210
of vestibule, 1036
Pyramidal cells of cerebral cortex, 868
decussation, 874
eminence of tympanic cavity, 1030
lobe of thyreoid gland, 1245
process of palatine bone, 238, 249
tract, crossed, 794
direct, 793
Pyramidalis abdominis, 479
nasi, 440
Pyramids, renal, 1195

Quadrangular lobules of cerebellum, 815
Quadrate ligament, 387
lobe of cerebrum, 848
of liver, 1184
Quadratus femoris, 546
nerve to, 958
labii inferioris, 441
superioris, 441
lumborum, 481
fascia covering, 481
plantæ, 563
Quadriceps femoris, 536
Quadrigeminal bodies, 829

Radial artery, 653
applied anatomy of, 654
branches of, 655
peculiarities of, 654

CC-0. In Public Domain. Gurukul Kangri Collection, Haridwar

Digitized by Arya Samaj Foundation Chennai and eGangotri

Radial artery (*cont.*)
surface marking of, 1301
collateral ligament of elbow-joint, 385
of wrist-joint, 392
fibres of cerebral cortex, 869
fossa, 285
nerve, 944
applied anatomy of, 947
deep branch, 946
superficial branch, 946
surface marking of, 1302
notch of ulna, 293
recurrent artery, 655
tuberosity, 290
Radiate ligament, 368
sternocostal ligaments, 371
Radiations, optic, 889
Radii lentis, 1007
Radiocarpal articulation, 390
applied anatomy of, 395
movements of, 392
surface anatomy of, 1294, 1298
ligament, dorsal, 391
volar, 391
Radio-ulnar articulation, distal, 388
movements of, 389
surface anatomy of, 1294
proximal, 387
movements of, 389
surface anatomy of, 1294
union, middle, 387
Radius, 287
applied anatomy of, 295, 390, 529
fracture of, 295, 529, 530
oblique line of, 290
ossification of, 291
sigmoid cavity of, 290
structure of, 291
styloid process of, 291
surface anatomy of, 1293
tuberosity of, 290
ulnar notch of, 290
Rami communicantes, 927
dorsales linguæ, 611
Ramus colli, 912
descendens of occipital artery, 614
of mandible, 242
of ischium, inferior, 310
superior, 310
marginalis mandibulæ, 912
perforans cruris, 123
tarsi, 123
of os pubis, inferior, 311
superior, 310
Ranine artery, 611
vein, 714
Ranvier, crosses of, 38
nodes of, 38
Raphe, anococcygeal, 485, 487
lateral palpebral, 439
of medulla oblongata, 800
of palate, 1095
pterygomandibular, 443
of scrotum, 1219
Rathke, pouch of, 136
Rays, medullary, of kidney, 1196
Recess, epitympanic, 209, 1027
lienal, 1140
nasopalatine, 988
omental, inferior, 1140
middle, 1140
superior, 1140
Recess (*cont.*)
optic, 841
pharyngeal, 1123
pineal, 842
spheno-ethmoidal, 266, 987
tubotympanic, 107
Recesses, peritoneal, 1144
applied anatomy of, 1145
of Troltsch, 1024
Recessus ellipticus, 1036
infundibuli, 841
pinealis, 842
piriformis, of pharynx, 1124
sacciformis, 388
sphæricus, 1036
suprapinealis, 842
Rectal ampulla, 1168
columns of Morgagni, 1171
sinus, 1170
Rectococcygeal muscles, 1170
Recto-uterine excavation, 1136, 1232
folds, 1234
Rectovesical excavation, 1136
folds, 1138
layer of pelvic fascia, 1224*
septum, 1224*
Rectovesicalis, 1207
Rectum, 1168
ampulla of, 1168
anal part of, 1169
applied anatomy of, 1176
columns of, 1170
development of, 142
flexures of, 1168
Houston's valves of, 1168
lymphatic vessels of, 771
relations of, 1168
transverse folds of, 1168
Rectus abdominis, 477
sheath of, 478
tendinous inscriptions of, 477
capitis anterior, 455
anticus major, 454
minor, 455
lateralis, 455
posterior major, 461
minor, 462
femoris, 536
applied anatomy of, 537
muscles of eyeball, 1011
actions of, 1013
applied anatomy of, 1015
Recurrent artery, interosseous, 660
meningeal branch of lacrimal, 627
radial, 655
tibial, anterior, 701
posterior, 701
ulnar, dorsal, 658
volar, 658
branches from deep volar arch, 666
nerve (laryngeal), 920
Red blood-corpuscles, 26
marrow, 18
nucleus, 827
Reflected inguinal ligament, 472
Reflex actions, abnormalities of, 876
Reflex, ciliospinal, 877
Reflexes, deep or tendon, 877
organic, 877
superficial or skin, 876
trigeminal, 903
Refraction media of eye, 1006
Region, anterior, of medulla oblongata, 801
lateral, 802
posterior, 802
subthalamic tegmental, 838
Regions of abdomen, 1132
Reid's base-line, 1262
Reil, island of, 849
Reissner, vestibular membrane of, 1041
Remak, fibres of, 39
Renal arteries, 674, 1198
calyces, 1194
collar, 127
columns (Bertini), 1196
fascia, 1195
impression, 1185
papillæ, 1194
pelvis, 1198
plexus, 981
pyramids, 1195
sinus, 1194, 1195
tubules, 1196
veins, 741
vessels, afferent and efferent, 1197
Renes, 1192
Reproduction of cells, 2
Resection of rib, 195
Respiration, mechanism of, 468
Respiratory organs, 1059
development of, 145
region of nasal cavities, 987, 989
Rest, period of, in cardiac cycle, 591
Restiform bodies, 808, 819
Resting condition of cell, 2
Rete canalis hypoglossi, 724
foraminis ovalis, 724
testis, 1214
Reticular lamina, 1045
apparatus of Golgi, 2
layer of corium, 1054
tissue, 12
Reticulum, stellate, 1108
Retiform tissue, 12
Retina, 1001
applied anatomy of, 1009
central artery of, 626, 1005
development of, 102
fovea centralis of, 1002, 1005
layers of, 1003
macula lutea of, 1002, 1005
membrana limitans interna, 1005
externa, 1005
ora serrata of, 1002, 1005
pigmented layer of, 1003
rhodopsin or visual purple of, 1002
structure of, 1003
supporting framework of, 1005
Retinacula, of hip-joint, 404
patellar, 410
peronæal, 560
Retinaculum of arcuate popliteal ligament, 413
Retro-aortic lymph-glands, 765
Retrocæcal fossa, 1146
Retroduodenal fossa, 1145
Retromandibular process of parotid gland, 1096
Retropharyngeal abscess, 449, 1127

CC-0. In Public Domain. Gurukul Kangri Collection, Haridwar

Digitized by Arya Samaj Foundation Chennai and eGangotri

Retropharyngeal lymph-glands, 752
space, 448
Retropubic pad, 1202
Retzius, space of, 1208
Rhinal fissure, external, 95
Rhinencephalon, 95, 851
Rhinion, 269
Rhodopsin, or visual purple, 14, 1002
Rhombencephalon, 53, 90, 800
Rhombic grooves, 92
lip, 91
Rhomboid fossa, 824
impression, 281
ligament, 375
Rhomboideus major, 495
minor, 495
Rib or ribs, 188
angle of, 190
applied anatomy of, 194
articulations of, 367
cervical, 169, 195
common characteristics of, 189
costal groove, 190
crest of neck, 190
development of, 70
eleventh, 192
false, 188
first, 191
floating or vertebral, 189
fracture of, 194
ossification of, 192
peculiar, 191
resection of, 195
second, 191
structure of, 192
tenth, 192
true, 188
tubercles of, 190
twelfth, 192
vertebral, or floating, 189, 374
vertebrochondral, 189, 374
vertebrosternal, 373
Rickets, 195, 317
Rickety rosary, 195
Rider's bone, 434, 539
Ridge, bulboventricular, 117
ganglion, 52, 88
genital, 153
lateral supracondylar, 283
medial supracondylar, 284
pulmonary, 149
trapezoid or oblique, 280
Ridges, bicipital, 283
bulbar, 118
Riedel's lobe of the liver, 1191
Right atrioventricular orifice, 583
atrium of heart, 580
margin of heart, 580
ventricle of heart, 583
Rima glottidis, 1067
intercartilaginous part, 1067
intermembranous part, 1067
oris, 1094
palpebrarum, 1016
pudendi, 1238
vestibuli, 1065
Ring, abdominal inguinal, 480
external abdominal, 472
femoral, 689
fibrocartilaginous, of tympanic membrane, 1028
Ring (*cont.*)
internal abdominal, 480
subcutaneous inguinal, 472
tympanic, 213
Rings, fibrous, of heart, 587
Riolan, muscle of, 438
Ripening of ovum, 42
Risorius, 444
Rivinus, ducts of, 1099
notch of, 1027
Rod-bipolars of retina, 1003
Rod-granules of retina, 1004
Rods and cones, layer of, 1005
Rods of Corti, 1044
of retina, 1005
Rolando, fissure of, 845, 1263
substantia gelatinosa of, 788
tubercle of, 803
Roller, nucleus of, 811
Roof or dorsal wall of fourth ventricle, 823
Roof-plate, 85
Root of penis, 1221
Root-sheaths of hair, 1056
Roots of lungs, 1088
of spinal nerves, 797, 925
of teeth, 1102
of vertebral arches, 164
of zygomatic process, 206
Rosenmüller, fossa of, 78, 1123
lymph-gland of, 762
organ of, 151, 1229
Rostrum of corpus callosum, 853
sphenoidal, 202
Rotation, movement of, 354
of gut, 141
of limbs, 82
Rotatores, 460
Round ligament of liver, 1186
of uterus, 1234
Rubrospinal fasciculus (Monakow), 789
Ruffini, corpuscles of, 1050
Rust-coloured layer of cerebellar cortex, 821

Sac, dental, 1108
greater, of peritoneum, 1134
lacrimal, 1020
lesser, of peritoneum, 1136
preputial, 1222
Sacculated bladder, 1208
Saccule, laryngeal, 1068
of vestibule, 1040
macula acustica sacculi, 1040
structure of, 1040
Saccus vaginalis, 155
endolymphaticus, 1040
Sacral ala, 176
arteries, lateral, 684
artery, middle, 676
canal, 178
cornua, 175
crest, median, 175
crests, articular, 175
lateral, 175
flexure of rectum, 1168
foramina, anterior, 174
posterior, 175
groove, 175
hiatus, 175
lymph-glands, 764
nerves, anterior divisions of, 958
posterior divisions of, 930
Sacral nucleus of medulla spinalis, 791
plexus, 958
applied anatomy of, 968
tuberosity, 176
veins, lateral, 737
middle, 739
Sacrococcygeal fibrocartilage, 361
ligaments, 361
symphysis, 361
Sacrogenital folds, 1138, 1234
Sacro-iliac articulation, 398
ligaments, 398
Sacrosciatic ligament, great, 399
small, 399
Sacrospinalis, 457
Sacrospinous ligament, 399
Sacrotuberous ligament, 399
Sacrovertebral angle, 174
Sacrum, 174
ala of, 176
apex of, 176
auricular surface of, 176
base of, 176
differences between male and female, 178
dorsal surface of, 174
foramina of, 174, 175
inferior lateral angle of, 176
lateral parts of, 174
surfaces of, 176
ossification of, 181
pelvic surface of, 174
promontory of, 176
structure of, 178
variations of, 178
Saddle articulation, 354
Sagittal fossæ, of liver, 1182
plexus, 130
sinus, inferior, 718
superior, 717
applied anatomy of, 718
sulcus, 197, 216, 218, 260
suture, 216, 247, 260
Salivary glands, 1096
parotid, 1096
sublingual, 1099
submaxillary, 1088
applied anatomy of, 1101
development of, 134
structure of, 1100
Salpingitis, 1231
Salpingopalatine fold, 1123
Salpingopharyngeal fold, 1123
Salpingopharyngeus, 1127
Santorini, cartilages of, 1062
duct of, 1180
Saphenous nerve, 957
external, 963
long or internal, 957
opening, 534
vein, accessory, 734
great, 734
surface marking of, 1311
small, 734
surface marking of, 1311
veins, applied anatomy of, 735
Sarcolemma, 30
Sarcomere, 31
Sarcoplasm, 30
Sarcostyles, 30
Sarcous element, 31
Sartorius, 535
applied anatomy of, 535
nerve to, 957
relations of, 535

CC-0. In Public Domain. Gurukul Kangri Collection, Haridwar

Digitized by Arya Samaj Foundation Chennai and eGangotri

Sauroid blood-cells, 110
Scala media, 1041
tympani, 1038
vestibuli, 1038
Scalene tubercle, 191
Scalenus, anterior, 455
medius, 456
posterior, 456
Scalp, applied anatomy of, 437
lymphatic vessels of, 754
structure of, 1261
Scapha, 1022
Scaphoid fossa, 204, 250
Scapula, 274
acromion of, 276
applied anatomy of, 279
coracoid process of, 278
fracture of, 279
glenoid cavity of, 278
head of, 278
inferior transverse ligament of, 378
superior, 377
ligaments of, 377
neck of, 278
ossification of, 279
spine of, 275
structure of, 279
surface anatomy of, 1293
Scapulæ alatæ, 279
Scapular artery, posterior, 642
transverse, 641
circumflex artery, 647
nerve, dorsal, 937
notch, 276
Scapus or shaft of hair, 1056
Scarpa, fascia of, 470
foramina of, 234, 248
ganglion of, 1047
triangle of, 689
Schlemm, canal of, 994
Schreger, lines of, 1105
Schwann, nucleated sheath of, 37
white substance of, 38
Sciatic artery, 682
foramen, greater, 399
lesser, 400
nerve, 962
applied anatomy of, 968
surface marking of, 1311
small, 960
notch, greater, 309
lesser, 310
veins, 737
Sclera, 993
applied anatomy of, 1008
structure of, 994
Scleral spur, 995
Scleratogenous layer, 68
Sclerocorneal junction, 994
Sclerotome, 68
Scoliosis, 184
Scrotal arteries, posterior, 681
hernia, 1173
nerves, posterior, 967
Scrotum, 1219
applied anatomy of, 1220
dartos tunic of, 1220
raphe of, 1219
skin of, 1220
vessels and nerves of, 1220
Sebaceous glands, 1057
development of, 84
Sebum cutaneum, 1057
Second cervical nerve, anterior division of, 931
posterior division of, 929
Second cervical vertebra, 168
cuneiform bone, 342
ossification of, 347
metacarpal bone, 303
metatarsal bone, 345
rib, 191
Secondary areolæ of bone, 23
curves of vertebral column, 182
dentine, 1106
labial groove, 133
lamellæ of bone, 20
meatus, 108
motor tracts, 874
oöcyte, 43
spermatocytes, 44
spiral lamina, 1038
tympanic membrane, 1029, 1038
Secretion, internal, 1243
Seessel's pouch, 136
Segments, internodal, 38
of Lantermann, 38
medullary, 38
primitive, 54, 68
spinal, 785
Segmental arteries, dorsal, 122
lateral, 123
ventral, 121
Segmentation of cells, 40
cavity, 49
of fertilised ovum, 48
nucleus, 47
Sella turcica, 200, 261
Semicanalis m. tensoris tympani, 212, 1030
tubæ auditivæ, 212, 250, 1030
Semicircular canals, 1037
ducts, 1040
structure of, 1040
Semilunar branches of internal carotid artery, 626
bone, 299
fibrocartilages of knee, 414
ganglia of cœliac plexus, 979
ganglion of trigeminal nerve, 889
lobule, inferior, 817
superior, 816
notch of ulna, 292
valves, aortic, 586
pulmonary, 584
Semimembranosus, 547
Seminal vesicles, 1217
Seminiferous tubules, 1214
Semispinalis capitis, 460
cervicis, 460
dorsi, 460
Semitendinosus, 547
Sensations, general, peripheral terminations of nerves of, 1048
Senses, special, peripheral organs of, 983
Sensory decussation, 805
impulses, 874
exteroceptive, 874
interoceptive, 874
proprioceptive, 874
neurons, highest, intermediate, and lowest, 876, 877
paralysis, 876
tracts, 874
Separation of placenta, 67
Septa, intersegmental, 68
[illegible], 502
placental, 66
Septal arteries, posterior, 620
cartilage of nose, 984
Septula testis, 1213
Septum, aortopulmonary, 117
atrial, 580
bulbar, distal, 117
proximal, 118
bursarum, 1140
canalis musculotubarii, 212, 1030
crural, 689
femorale, 689
inferius of heart, 116
intermedium of heart, 115
lateral intermuscular, of arm, 503
medial intermuscular, of arm, 503
mobile nasi, 984
nasi, 265
orbital, 1017
pectiniforme, 1221
pellucidum, 864
cavity of, 864
of penis, 1221
primum of heart, 115
rectovesical, 1224*
secundum, 115, 594
sinus, 114
spurium of heart, 114
subarachnoid, 882
of tongue, 1117
applied anatomy of, 1117
transversum, of fœtus, 112, 147
of semicircular duct, 1040
urorectal, 142
ventricular, 116, 580
Sequestrum, 25
Serosa, or false amnion, 60*
Serous glands of tongue, 1117
pericardium, 576
Serratus anterior, 499
applied anatomy of, 500
magnus, 499
posterior inferior, 464
superior, 464
Sertoli, supporting cells of, 1214
Sesamoid bones, 350
Seventh cervical vertebra, 169
centres for costal processes of, 181
Sex differences in the skull, 269
Shaft of hair, 1056
Sheath, carotid, 448
axillary, 645
dentinal, of Neumann, 1105
epithelial, 1109
femoral, 687
medullary, 38
mitochondrial, of spermatozoön, 44
nucleated, of Schwann, 37
primitive, 37, 39
of prostate, 1224
of psoas and iliacus, 530, 531
applied anatomy of, 532
of rectus abdominis, 478
applied anatomy of, 478
Sheaths, fibrous, of flexor tendons of fingers, 510
of toes, 563
fibro-areolar, of arteries, 570
mucous, 352
of tendons around ankle, 560
on back of wrist, 519
on front of wrist, 519

CC-0. In Public Domain. Gurukul Kangri Collection, Haridwar

Digitized by Arya Samaj Foundation Chennai and eGangotri

Sheaths of optic nerve, 887
Shin, 328
Shingles, 799
Short bones, 163
fibular collateral ligament of knee-joint, 413
gastric veins, 742
Shoulder, muscles of, 500
Shoulder-blade, 274
Shoulder girdle, 274
joint, 378
applied anatomy of, 382
bursæ in relation to, 380
movements of, 381
muscles in relation to, 380
vessels and nerves of, 380
Shrapnell, membrane of, 1028
Sibson's fascia, 1079
Sight, organ of, 993
Sigmoid arteries, 672
cavity of radius, 290
greater, of ulna, 292
lesser, of ulna, 293
colon, 1162
mesocolon, 1137, 1144
sinus, 719
Sino-atrial node, 589
Sinus or sinuses—
aortic, 587
cervicalis, 77
confluence of, 197, 720
coronary, 582, 708
valve of, 582, 708
costomediastinal, 1079
cranial, 201*
of dura mater, 717
basilar plexus, 723
cavernous, 720
circular, 722
confluence of, 720
intercavernous, 722
lateral, 719, 1264
longitudinal, inferior, 718
superior, 717
meningeal, middle, 723
occipital, 720
petrosal, inferior, 723
superior, 722
petrosquamous, 720
sagittal, inferior, 718
superior, 717
sigmoid, 719
sphenoparietal, 721
straight, 718
torcular Herophili, 720
transverse, 719, 1264
of epididymis, 1212
ethmoidal, 221, 991
of external jugular vein, 712
frontal, 219, 991
marginal, of placenta, 66
mastoid, 209
maxillary, 231, 992
of Morgagni, 1126
of pericardium, oblique, 576
transverse, 576
phrenicocostal, 1079
prostatic, 1209
pulmonary, 585
rectal, 1170
renal, 1194, 1195
septum, 114
sphenoidal, 201, 991
tarsi, 338, 340
tonsillaris, 78, 1118
transverse, of pericardium, 576
urogenital, 157
Sinus or sinuses (*cont.*)
of Valsalva, 585, 587
venarum, 581
venosus, 112, 113
scleræ, 994
Sinusoids, 124, 143, 572, 1188
Skein, or spirem, 2, 3
Skeleton, 163
appendicular part of, 163
axial part of, 163
development of, 68
of foot, 334
of hand, 298
Skene's ducts, 158, 1211
Skin, 1051
appendages of, 1054
hairs, 1055
nails, 1054
sebaceous glands, 1057
sudoriferous or sweat glands, 1057
arteries of, 1054
corium or cutis vera, 1053
papillary layer of, 1054
reticular layer of, 1054
development of, 83
epidermis or cuticle, 1051
stratum corneum, 1053
germinativum, 84, 1052
granulosum, 1053
lucidum, 1053
mucosum, 1053
epitrichium, 83
finger-prints of, 1052
nerves of, 1054
reflexes, 876
Skull, 195
applied anatomy of, 271
base, inner surface of, 260
bones of, 196
breadth index of, 270
capacity of, 269
cephalic index of, 270
chondrification of, 72
chordal part of, 72
craniology, 269
deformities of, 273
dental index of, 271
development of, 71
differences in, due to age, 267
diploë of bones, 164
exterior of, 247
fossa, anterior, 260
middle, 260
posterior, 261
fractures of, 272
gnathic or alveolar index of, 271
height of, 270
horizontal circumference of, 270
hypophysial part of, 72
interior of, 260
interorbitonasal part of, 72
length of, 270
nasal index of, 271
norma basalis, 247
frontalis, 255
lateralis, 251
occipitalis, 254
verticalis, 247
occipitofrontal longitudinal arc of, 270
orbital index of, 271
prechordal part of, 72
sex differences in, 269
surface anatomy of, 1257
tables of, 164, 199
Skull (*cont.*)
upper surface of base of, 260
vertical circumference of, 270
vertical or height index of, 271
Skull-cap, inner surface of, 260
Sleep palsies, 947
Slightly movable joints, 353
Small intestine, 1153
duodenum, 1154
ileum, 1156
jejunum, 1156
aggregated lymphatic nodules of, 1160
applied anatomy of, 1172
circular folds of, 1158
glands of, 1160
lymphatic vessels of, 769
Meckel's diverticulum of, 57, 1156
mesenteric part of, 1156
Peyer's glands of, 1160
solitary lymphatic nodules of, 1160
structure of, 1157
valvulæ conniventes of, 1158
vessels and nerves of, 1161
villi of, 1158
cardiac vein, 708
saphenous vein, 734
sciatic nerve, 960
wings of sphenoid, 203
Smaller occipital nerve, 932
superficial petrosal nerve, 903, 1034
Smallest cardiac veins, 709
Smegma præputii, 1222
Smell, area for sense of, 871
organ of, 984
Soft palate, 1095
aponeurosis of, 1120
muscles of, 1120
paralysis of, 1096
Solar plexus, 979
Sole of foot, muscles of, first layer, 562
fourth layer, 565
second layer, 563
third layer, 565
Soleus, 552
Solitary cells of medulla spinalis, 791
lymphatic nodules, 1160, 1171
Somatic cells, 40
fibres of spinal nerves, 928
mesoderm, 52
Somatopleure, 53
Space of Burns, 448
epidural, 880
episcleral, 1013
intervillous, 63
of Nuel, 1045
popliteal, 695
pretarsal, 1010
retropharyngeal, 448
of Retzius, 1208
subdural, 881
suprasternal, 448
Spaces of angle of iris, 997
cavernous, of penis, 1222
corneal, 996
of Fontana, 997
intercostal, 189
interglobular, 1105
medullary of bone, 23
Spasm, histrionic, 913

CC-0. In Public Domain. Gurukul Kangri Collection, Haridwar

Digitized by Arya Samaj Foundation Chennai and eGangotri

Spasmodic torticollis, 451
Spatia zonularia, 1006
Special dental germs, 1107
end-organs of nerves, 1048
types of cerebral cortex, 869
Special senses, peripheral organs of, 983
Spermatic artery, external, 686
internal, 674
Spermatic cord, 1218
coverings of, 1218
structure of, 1218
fascia, external, 472, 1218
nerve, external, 953
plexus of nerves, 981
applied anatomy of, 981
veins, 741
applied anatomy of, 741
Spermatids, 44, 1214
Spermatocele, 1216
Spermatocytes, 44, 1214
Spermatogonia, 44, 1214
Spermatozoön, 43, 1214
acrosome of, 43
axial filament of, 44
body or connecting piece of, 44
centrioles of, 44
head of, 43
head-cap of, 43
mitochondrial sheath of, 44
neck of, 44
perforator of, 43
spiral thread of, 44
tail of, 44
end-piece of, 44
terminal disc or ring of, 44
Spheno-ethmoidal recess, 266, 987
suture, 260
Sphenofrontal suture, 251, 260
Sphenoidal air-sinuses, 201, 991
bone, 200
applied anatomy of, 206
body of, 200
great wings of, 202
ossification of, 205
postsphenoidal part of, 205
presphenoidal part of, 205
pterygoid processes of, 204
small wings of, 203
conchæ, 205
crest, 201
fonticulus, 268
nerve, from otic ganglion, 903
process of palatine bone, 238
of septal cartilage of nose, 984
rostrum, 202
Sphenomandibular ligament, 356
Sphenomaxillary fissure, 253
fossa, 254
Sphenopalatine artery, 620
foramen, 237, 265
ganglion, 898
nerves, 896
notch, 237, 238
Sphenoparietal sinus, 721
suture, 251, 261
Sphenopetrosal suture, 261
Sphenosquamosal suture, 251, 261
Sphenozygomatic suture, 259
Sphere, attraction, 2
Sphincter ani externus, 487
Sphincter ani internus, 487
pupillæ, 105, 1000
pyloric, 1149, 1151
recti, 485
urethræ membranaceæ, in female, 492
in male, 490
vaginæ, 491, 1238
vesicæ, 1207
Spigelian lobe of liver, 1184
Spina angularis, 202, 250
bifida, 184
helicis, 1023
trochlearis, 218, 257
vestibuli, 114
Spinal accessory nerve, 922
anæsthesia, 884
arachnoid, 881
arteries, 636, 637
column, 164, 182
cord, 784
applied anatomy of, 798
dura mater, 880
structure of, 881
ganglia, 925
applied anatomy of, 799
structure of, 926
medulla, 784
meningitis, acute, 884
myelitis, 798
nerves, 925
anterior divisions of, 931
autonomic fibres of, 928
connexions with sympathetic trunks, 927
development of, 88
ganglia of, 925
posterior divisions of, 928
roots of, 797, 925
size and direction of, 926
somatic fibres of, 928
structure of, 928
paralysis, infantile, 798
pia mater, 884
root of vestibular nerve, 914
segments, 785
tract of trigeminal nerve, 813, 892
Spinalis capitis, 460
cervicis, 460
dorsi, 458
Spindle, achromatic, 2
aortic, 601
Spindles, neuromuscular, 1050
neurotendinous, 1050
Nissl's, 36
Spine or spines—
ethmoidal, 200
frontal, 217
iliac, 309
ischial, 309
mental, 241
nasal, anterior, 230, 235, 256, 266
posterior, 236, 249
pubic, 311
of scapula, 275
suprameatal, 213, 252
tibial, 327
trochlear, 218, 257
Spinocerebellar fasciculus, anterior, 795
posterior, 795
Spinoglenoid ligament, 378
Spino-olivary fasciculus, 808
Spinotectal fasciculus, 795
Spinothalamic fasciculus, anterior, 794
lateral, 795
Spiral canal of modiolus, 1037
ganglion of cochlea, 1047
lamina, osseous, 1038
secondary, 1038
line of femur, 321
organ of Corti, 1044
thread of spermatozoön, 44
tubule of kidney, 1197
Spirem or skein, 2, 3
Splanchnic mesoderm, 52
nerve, greater, 976
lesser, 976
lowest, 977
pelvic, 969
Splanchnology, 1059
Splanchnopleure, 52
Spleen or lien, 1252
applied anatomy of, 1256
blood-vessels of, 1254
development of, 145
lymphatic vessels of, 771
Malpighian bodies of, 1255
structure of, 1254
surface marking of, 1288
Spleens, accessory, 1254
Splenial centre of ossification, 244
Splenic artery, 669
applied anatomy of, 669
distribution of, 1254
cells, 1254
flexure of colon, 1166
plexus, 980
pulp, 1254
vein, 742
Splenium of corpus callosum, 853
Splenius capitis, 457
cervicis, 457
Spongioblasts, 85
Spongioplasm, 1
Spongy gums, 1095
Spot, germinal, 40, 41
Spring ligament, 427
Spur, or cog-tooth, of malleus, 1032
scleral, 995
Squama, frontal, 217, 255
occipital, 196
temporal, 206
Squamosal suture, 208, 251, 261
Squamous epithelium, 4
Stahr, middle lymph-gland of, 753
Stalk of pineal body, 836
Stalks, optic, 93, 102
of thalamus, 835
Stapedial artery, 121
Stapedius, 1033
nerve to, 910
Stapes, 1032
annular ligament of base of, 1033
base of, 1032
crura of, 1032
development of, 108
head of, 1032
neck of, 1032
ossification of, 1032
Stellate cells of Kupffer, 1188
ganglion, 978
ligament, 368
reticulum, 1108
veins of kidney, 1199

CC-0. In Public Domain. Gurukul Kangri Collection, Haridwar

Digitized by Arya Samaj Foundation Chennai and eGangotri

Stenosis of pulmonary orifice, 596
of pylorus, 1153
Stensen, duct of, 1097
foramina of, 234, 248
Stephanion, 270
Sternal angle, 185
branches of internal mammary artery, 640
end of clavicle, 281
foramen, 185
furrow, 1276
lymph-glands, 775
plates, 71, 187
Sternebræ, 185
Sternoclavicular articulation, 374
applied anatomy of, 375
movements of, 375
surface anatomy of, 1294
ligament, 374
Sternocleidomastoid arteries, 610, 615
Sternocleidomastoideus, 449
applied anatomy of, 451
Sternocostal articulations, 370
movements at, 372
ligaments, interarticular, 371
radiate, 371
surface of heart, 579
Sternohyoideus, 453
Sternopericardiac ligaments, 576
Sternothyreoideus, 453
Sternum, 185
applied anatomy of, 194
body of, 185
development of, 71
fracture of, 194
manubrium of, 185
ossification of, 187
structure of, 187
xiphoid process of, 187
Stomach, 1146
antrum cardiacum of, 1146
applied anatomy of, 1153
bed, 1147
cardiac glands of, 1151
orifice of, 1146
component parts of, 1148
curvatures of, 1147
development of, 137
fundus of, 1148
fundus glands of, 1152
gastric canal, 1149
incisura angularis of, 1147
cardiaca of, 1147
interior of, 1148
lenticular glands of, 1152
lymphatic vessels of, 769
mucous membrane of, 1151
muscular coat of, 1150
openings of, 1146
pyloric glands, 1152
orifice, 1147
part of stomach, 1147
sphincter, 1149
shape and position of, 1146
as seen by *x*-rays, 1148
structure of, 1149
sulcus intermedius of, 1147
surface marking of, 1285
surfaces of, 1147
vessels and nerves of, 1152
Stomodæum, 133
Strabismus, 891, 1015
Straight sinus, 718
tubules of kidney, 1197
Strand, triangular, 797
Stratiform fibrocartilage, 17
Stratum, central grey of cerebral aqueduct, 831
cinereum, 830
compactum of decidua, 63
corneum of epidermis, 1053
dorsale, 838
fibrosum of articular capsule, 351
germinativum of epidermis, 84, 1052
granulosum of epidermis, 1052
of Graafian follicle, 1228
of hippocampus, 872
intermedium of chorioid, 998
of enamel-organ, 1108
laciniosum, 872
lemnisci, 830
lucidum of epidermis, 1053
mucosum of epidermis, 1053
opticum of retina, 1003
of superior colliculus, 830
radiatum, 872
spongiosum of decidua, 63
synoviale of articular capsule, 351
zonale of superior colliculus, 830
of thalamus, 834
Streak, primitive, 49
Stria terminalis, 861
vascularis, 1042
Striæ acusticæ, 825
gravidarum or albicantes, 1281
longitudinal, lateral and medial, 852
medullares, of rhomboid fossa, 825
of olfactory tract, 851
Striate arteries, 630
veins, inferior, 717
Stripe of Hensen, 1046
Striped muscular fibres, 29
Stroke or apoplexy, 872
Stroma, intertubular of kidney, 1199
of iris, 1000
of ovary, 1227
Stump, conical, 26
Stye, 1021
Styloglossus, 1116
Stylohyal part of styloid process, 214
Stylohyoid ligament, 452
nerve from facial, 912
Stylohyoideus, 452
Styloid process of fibula, 331
of radius, 291
of temporal bone, 213, 250, 253
of third metacarpal bone, 304
of ulna, 294
Stylomandibular ligament, 356
Stylomastoid artery, 614
foramen, 212, 250
Stylopharyngeus, 1126
Subanconeus, 507
Subarachnoid cavity, 881
cisternæ, 881
septum, 882
Subastragalar amputation, 349
Subcallosal gyrus, 852
Subcardinal veins, 126
Subclavian artery, 631
Subclavian artery (*cont.*)
applied anatomy of, 634
branches of, 636
first part of left, 632
of right, 632
peculiarities of, 633
second portion of, 632
surface anatomy of, 1260
marking of, 1272
third portion of, 632
lymphatic trunks, 750
triangle, 623
vein, 728
Subclavius, 498
nerve to, 937
Subcostal angle, 194
arteries, 664
Subcostales, 463
Subcrureus, 537
Subcutaneous inguinal ring, 472
Subdural space, 881
Subepithelial plexus of cornea, 997
Sublingual artery, 611
ducts, 1099
gland, 1099
vessels and nerves of, 1099
lymph-glands, 762
Sublobular veins, 741, 1188
Submaxillary duct, 1099
ganglion, 903
gland, 1098
surface anatomy of, 1261
vessels and nerves of, 1099
lymph-glands, 753
triangle, 622
Submental artery, 613
lymph-glands, 753
Submucosa, plexus of, 1162
Subnasal point, 269
Suboccipital muscles, 461
nerve, anterior division, 931
posterior division, 928
triangle, 462, 636
Subparietal sulcus, 846
Subperitoneal connective tissue, 481
Subpleural mediastinal plexus, 640
Subpubic ligament, 400
Subpyloric lymph-glands, 766
Subsartorial plexus, 957
Subscapular artery, 647
fascia, 501
fossa, 274
nerves, 938
Subscapularis, 501
Subserous areolar tissue, 1134
Substance, anterior perforated, 852
cortical of kidney, 1196
fibrinoid of placenta, 65
medullary of kidney, 1195
posterior perforated, 825
Substantia adamantina, 1106
alba of medulla spinalis, 792
compacta, 17
eburnea, 1104
ferruginea, 825
gelatinosa centralis, 789
of Rolando, 788
nerve-cells in, 791
grisea of medulla spinalis, 788
innominata of Meynert, 860
nigra, 827
ossea, 1106
propria of cornea, 996

CC-0. In Public Domain. Gurukul Kangri Collection, Haridwar

Digitized by Arya Samaj Foundation Chennai and eGangotri

Substantia reticularis alba, 811
grisea, 811
spongiosa, 17
Subtalar dislocation, 428
Subthalamic tegmental region, 833, 838
Successional permanent teeth, 1110
Suctorial pad, 443
Sudoriferous glands, 1057
development of, 84
Sulci of cerebral hemisphere (*see under* cerebral fissures and sulci)
of medulla oblongata, 801
of medulla spinalis, 787
Sulcus or sulci—
anterior longitudinal, of heart, 578
antihelicis transversus, 1023
arteriæ vertebralis, 167
basilaris, 812
calcanei, 340
carotid, 201, 261
central, 845, 1263
chiasmatis, 200, 260, 261
cingulate, 846
circular, 845, 849
circularis corneæ, 995
coronary, of heart, 578
ethmoidal, 226
frontal, 846
habenulæ, 833
Harrison's, 195
horizontal, of cerebellum, 815
inferior petrosal, 198
intermedius primus, 848
secundus, 848
of stomach, 1147
intertubercular, of humerus, 283
intraparietal, of Turner, 847
lacrimalis, 231
lateral cerebral, 845
lateral, of cerebral peduncle, 826
limitans insulæ, 846
of rhomboid fossa, 824
malleolar, 330
malleolaris, of tympanic ring, 213*
medial frontal, of Eberstaller, 847
median, of rhomboid fossa, 824
of medulla oblongata, 801
of medulla spinalis, 787
of Monro, 93, 842
nasolabial, 1094
nervi radialis, 283
ulnaris, 285
occipital, lateral, 848
transverse, 197, 848
oculomotor, 826
olfactorius, 987
olfactory of frontal lobe, 847
orbital, 847
parallel, 849
paramedial, 847
parolfactory, anterior, 852
peronæal, 344
petrosal, inferior, 198
postcentral, 847
posterior longitudinal, of heart, 578
median of medulla spinalis, 787
pre-auricular, of ilium, 309
Sulcus or sulci (*cont.*)
precentral, 846
pterygopalatine, 204, 237
sagittal, 197, 216, 218, 260
sigmoideus, 209
spiralis externus, 1042
internus, 1042
subparietal, 848
tali, 338
temporal, 849
terminalis of right atrium, 581
of tongue, 134, 1111
transverse, 197, 262
tubæ auditivæ, 203, 250
tympanic, 212, 1025, 1028
valleculæ, 816
Sun-bath, effects of, 14
Superadded permanent teeth, 1110
Superciliary arches, 217, 247, 251, 256
Supination, movement of, 387, 389
Supinator, 516
brevis, 516
longus, 513
Supporting cells of Hensen, 1045
of olfactory mucous membrane, 989
of Sertoli, 1214
of taste-buds, 983
framework of retina, 1005
Supra-auricular point, 270
Supracallosal gyrus, 852
Supracardinal system of veins, 127
Supraclavicular branches of brachial plexus, 937
nerves of cervical plexus, 933
Supracondylar process, 284*
ridge, lateral, 283
medial, 284
Supraglenoid tuberosity, 278
Suprahyoid aponeurosis, 451
lymph-glands, 753
muscles, 451
triangle, 622
Supramandibular lymph-glands, 752
Supramarginal gyrus, 848
Supramastoid crest, 206
Suprameatal spine, 213, 252
triangle, 206, 252
Supra-orbital artery, 627
foramen, 217, 256, 259
margin, 217, 256
nerve, 894
notch, or foramen, 217, 256, 259
vein, 710
Suprarenal arteries, inferior, 674
middle, 674
superior, 676
glands, 1250
accessory, 1251
applied anatomy of, 1252
boundary zone of, 1251
cortex of, 1251
development of, 101
lymphatic vessels of, 771
medulla of, 1251
structure of, 1251
vessels and nerves of, 1252
impression, 1184
plexus, 981
Suprarenal veins, 741
Suprascapular artery, 641
ligament, 377
nerve, 937
Supraspinal ligament, 360
Supraspinatous fossa, 274
Supraspinatus, 501
Suprasternal space, 448
Supratonsillar fossa, 1118
Supratrochlear foramen, 285
lymph-glands, 758
nerve, 893
Supravesical fovea, 1173
Sural arteries, 698
cutaneous nerve, lateral, 965
medial, 963
nerve, 963
Surface anatomy and surface markings of—
abdomen, 1281, 1283
regions of, 1283
surface lines of, 1283
accessory nerve, 1272
acoustic meatus, external, 1270
acromioclavicular joint, 1294, 1298
adductor canal, 1310
air-sinuses, 1264
anal canal, 1289
angulus Ludovici, 1276
ankle-joint, 1305, 1309
aorta, abdominal, 1282, 1289
ascending, 1281
aortic arch, 1281
arteria profunda brachii, 1301
femoris, 1311
auricular artery, posterior, 1260
auscultation, triangle of, 1277
axillary artery, 1297, 1301
lines, 1278
nerve, 1302
back, 1272, 1274
biceps brachii, 1296
bones of cranium, 1257
of lower extremity, 1308
of thorax, 1276, 1277
of upper extremity, 1292
brachial artery, 1297, 1301
plexus, 1272, 1297
brachialis, 1296
brain, 1262
Bryant's triangle, 1308
cæcum, 1286
calcaneocuboid joint, 1309
calcaneus, 1304
carpal bones, 1294
caruncula lacrimalis, 1269
central sulcus, 1263
cerebellum, 1263
cerebral hemisphere, 1262
cervical cutaneous nerve, 1272
circumflex or axillary nerve, 1302
clavicle, 1292
cœliac artery, 1289
colic flexure, left, 1286
right, 1286
colon, ascending, 1286
descending, 1286
transverse, 1286

CC-0. In Public Domain. Gurukul Kangri Collection, Haridwar

Digitized by Arya Samaj Foundation Chennai and eGangotri

Surface anatomy and surface markings of (*cont.*)
common carotid artery, 1260, 1272
left, thoracic part of, 1281
iliac artery, 1289
peronæal nerve, 1308, 1311
coracobrachialis, 1296
cranium, 1261
deep peronæal nerve, 1311
deltoideus, 1296
diaphragm, 1278
dorsalis pedis artery, 1307, 1311
duodenum, 1285
ear, 1270
elbow-joint, 1294, 1298
epigastric artery, inferior, 1288
external carotid artery, 1260, 1272
main branches of, 1272
iliac artery, 1289
eye, 1269
face, 1264
facial artery, 1260, 1264, 1272
nerve, 1272
vein, common, 1272
femoral artery, 1307, 1311
triangle, 1310
femur, 1302
fibula, 1303
fissures of brain, 1263
of lungs, 1279
fold of buttock, 1302
fold of groin, 1281
fossa ovalis or saphenous opening, 1310
frontal air-sinus, 1264
sulci, 1264
gall-bladder, 1287
glutæal artery, inferior, 1311
superior, 1311
glutæal fold, 1302
great auricular nerve, 1272
head and neck, 1257
heart, 1279
coronary sulcus, 1280
longitudinal sulcus, anterior, 1280
orifices of, 1280
Hesselbach's triangle, 1289
hip-bones, 1302
hip-joint, 1305, 1309
humeral circumflex arteries, 1301
humerus, 1293
hyoid bone, 1258
ileocolic junction, 1286
iliac artery, common, 1289
external, 1289
furrow, 1281
infra-orbital nerve, 1265
infrasternal notch, 1276
inguinal rings and canal, 1283
innominate artery, 1281
vein, left, 1281
right, 1281
internal pudendal artery, 1311
interphalangeal joints, 1294, 1305

Surface anatomy and surface markings of (*cont.*)
intestines, 1285
intraparietal sulcus, 1264
joints of hand, 1294
of foot, 1309
jugular notch, 1276
vein, anterior, 1272
external, 1272
internal, 1272
kidneys, 1281, 1288
knee-joint, 1305, 1309
lacrimal puncta, 1269
sac, 1269
large intestine, 1286
larynx, 1260, 1268
lateral cerebral fissure, 1262
plantar artery, 1311
sternal lines, 1278
thoracic artery, 1301
ventricle of brain, 1264
latissimus dorsi, 1295, 1300
left common carotid artery, in thorax, 1281
lesser occipital nerve, 1272
linea alba, 1282
nigra, 1281
semilunaris, 1281
lingual artery, 1272
nerve, 1267
veins, 1267
liver, 1281, 1286
longitudinal fissure, 1263
lower extremity, 1302, 1308
lumbar triangle, 1281
lungs, 1279
mamma, 1277
mammary artery, internal, 1281
line, 1278
papilla or nipple, 1277
mandibular joint, 1258
mastoid or tympanic antrum, 1270
maxillary artery, external, 1260, 1264, 1272
air-sinus, 1264
medial plantar artery, 1311
median nerve, 1302
medulla spinalis, 1275
mental nerve, 1265
mesenteric artery, inferior, 1289
superior, 1289
metacarpal bones, 1294
metacarpophalangeal joints, 1294
metatarsal bones, 1304
metatarsophalangeal joints, 1305, 1309
midaxillary line, 1278
midcarpal articulation, 1294
middle meningeal artery, 1264
midsternal line, 1278
mouth, 1266
mucous sheaths around ankle, 1310
of wrist and hand, 1300
muscles of abdomen, 1281, 1283
of arm, 1296
of back, 1274
of buttock, 1306
of chest, 1300, 1307

Surface anatomy and surface markings of (*cont.*)
muscles of forearm, 1296
of hand, 1297
of head and neck, 1258
of leg, 1306
of neck, 1271
of perinæum, 1289
of thigh, 1305
of thorax, 1277
of upper extremity, 1295
nasal part of pharynx, 1268
nasolacrimal duct, 1269
navicular tuberosity, 1304
neck, 1263, 1271
Nélaton's line, 1308
nerves of abdominal wall, 1289
nipple, 1277
nose, 1266
occipital artery, 1260
nerve, lesser, 1272
œsophagus, 1279
palatine arches, 1267
tonsil, 1267
palmar or volar arches, 1301, 1302
palpebral fissure, 1269
pancreas, 1281, 1287
parasternal line, 1278
parieto-occipital fissure, 1264
parotid duct, 1265
gland, 1265
patella, 1303
pectoralis major, 1295, 1300
minor, 1295, 1300
perinæum, 1289
peronæal artery, 1311
nerves, 1311
phalanges of foot, 1304
of hand, 1294
phrenic nerve, 1272
plantar arch, 1311
arteries, 1311
pleuræ, 1278
plica semilunaris, 1269
popliteal artery, 1307, 1311
fossa, 1307, 1310
postcentral sulcus, 1264
posterior tibial artery, 1307, 1311
precentral sulcus, 1264
profunda brachii artery, 1301
profunda femoris artery, 1311
ribs, 1276
pudendal artery, internal, 1311
pupil, 1269
radial artery, 1297, 1301
nerve, 1302
radiocarpal joint, 1294
radio-ulnar joints, 1294
radius, 1293
rectum, 1289
Reid's base-line, 1262
renal arteries, 1289
Rolandic fissure, 1263
roots of lungs, 1279
sacro-iliac articulation, 1309
saphenous opening, 1310
veins, 1307, 1311
scalp, 1261

CC-0. In Public Domain. Gurukul Kangri Collection, Haridwar

Digitized by Arya Samaj Foundation Chennai and eGangotri

Surface anatomy and surface markings of (*cont.*)
scapula, 1293
scapular circumflex artery, 1301
line, 1278
sciatic nerve, 1311
semilunar ganglion, 1265
serratus anterior, 1295
shoulder-joint, 1294
small intestine, 1285
space of Traube, 1285
sphenopalatine ganglion, 1265
spinal cord or medulla spinalis, 1275
nerves, 1275
spleen, 1281, 1287
sternal angle, 1276
sternoclavicular joint, 1294
sternocleidomastoideus, 1259
sternum, 1276
stomach, 1285
cardiac orifice, 1285
pyloric orifice, 1285
striæ gravidarum or albicantes, 1281
subclavian artery, 1260, 1272, 1297
subdural and subarachnoid cavities, 1275
submaxillary duct, 1267
gland, 1261
subscapular artery, 1301
superior thyreoid artery, 1272
supraclavicular nerves, 1272
supra-orbital artery, 1260
nerve, 1265
supratrochlear nerve, 1265
Sylvian fissure, 1263
talonavicular joint, 1309
talus, 1303
tarsometatarsal joints, 1309
tarsus and foot, 1304
temporal artery, superficial, 1260
tendinous inscriptions of rectus abdominis, 1281
thoraco-acromial artery, 1301
thorax, 1276, 1277
surface lines of, 1278
tibia, 1303
tibial artery, anterior, 1307, 1311
posterior, 1307, 1311
nerve, 1308, 1311
tongue, 1266
trachea, 1260, 1279
transpyloric line, 1283
transtubercular line, 1284
transverse cervical artery, 1260
transverse sinus, 1264
trapezius, 1259, 1295, 1298
Traube, space of, 1285
triangle of auscultation, 1277
triceps brachii, 1296
trigeminal nerve, 1265
tympanic antrum, 1270
membrane, 1270
ulna, 1293

Surface anatomy and surface markings of (*cont.*)
ulnar artery, 1301
collateral arteries, 1301
nerve, 1297, 1302
umbilicus, 1281, 1283
upper extremity, 1292, 1297
ureters, 1288
urogenital organs, female, 1291
male, 1290
vena cava, inferior, 1281
superior, 1281
veins of upper extremity, 1297
vermiform process, 1286
vertebral column, 1272
vocal cords, 1260
volar or palmar arches, 1301, 1302
wrist and hand, 1292, 1294
wrist-joint, 1294, 1298
xiphoid process, 1276
Surfaces of bones, 164
Surgical emphysema, 1091
neck of humerus, 282
Suspensory ligament of axilla, 496
of eye, 1013
of lens, 1006
of ovary, 1226
of penis, 1222
muscle of duodenum, 1156
Sustentacular fibres of Müller, 1005
Sustentaculum lienis, 1144
tali, 340
Sutura, 352
harmonia, 352
serrata, 352
squamosa, 352
Sutural bones, 229
applied anatomy of, 229
ligament, 351
Suture, coronal, 247, 251, 260
frontal, 217, 247, 256
fronto-ethmoidal, 258, 260
frontolacrimal, 256, 258
frontomaxillary, 256, 258, 259
frontonasal, 256
frontosphenoidal, 258
lacrimo-ethmoidal, 258
lacrimomaxillary, 258
lambdoid, 216, 247, 251, 254, 260
metopic, 217
occipitomastoid, 251, 254, 262
parietomastoid, 251, 254, 262
petro-occipital, 262
petrosquamosal, 208, 210, 212
sagittal, 216, 247, 260
spheno-ethmoidal, 258, 260
sphenofrontal, 251, 260
sphenoparietal, 251, 261
sphenopetrosal, 261
sphenosquamosal, 251, 261
sphenozygomatic, 259
squamosal, 208, 251, 261
zygomaticofrontal, 259
zygomaticomaxillary, 259
Sutures, obliteration of, 269
Sweat-glands, 1057
development of, 84
Swellings, arytænoid, 145
genital, 159
Swellings, lateral lingual, 134
Sylvian fossa, 99
vein, deep, 717
veins, superficial, 716
Sylvius, aqueduct of, 831
fissure of, 99, 845, 1263
Syme's amputation, 349
Sympathetic nervous system, 779, 969, 979
abdominal portion, 977
cephalic portion, 973
cervical portion, 974
pelvic portion, 978
thoracic portion, 975
applied anatomy of, 982
connexions with spinal nerves, 927
development of, 100
ganglia, central, 971
collateral, 971
terminal, 971
great plexuses of, 978
cardiac, 978
cœliac, 999
hypogastric, 981
pelvic, 981
solar, 979
trunks, 973
Sympathoblasts, 100
Sympathochromaffin cells, 100
Symphysis, 353
of mandible, 241
pubis, 400
sacrococcygeal, 361
Synarthroses, 352
gomphosis, 353
synchondrosis, 353
sutura, 352
Synchondrosis, 353
neurocentral, 179
Syncytiotrophoblast, 49, 64
Syncytium, 49
Syndesmology, 351
Syndesmosis, 353
Synechia, 1009
Synergic muscles, 434
Synostosis, premature, 26
Synovia, 352
Synovial stratum of articular capsule, 351
Syringomyelia, 798
Systems, Haversian, 20
Systemic circulation, 569
veins, 708
Systole, atrial, 591
ventricular, 591

Tabes dorsalis, 877
Tables of the skull, 164, 199
Tactile corpuscles of Golgi and Mazzoni, 1050
of Grandry, 1049
of Herbst, 1049
of Pacini, 1050
of Ruffini, 1050
of Wagner and Meissner, 1050
sense, 874
area for, 871
Tænia libera, 1170
mesocolica, 1170
omentalis, 1170
pontis, 825
semicircularis, 861
thalami, 833
Tæniæ coli, 1170
of fourth ventricle, 823

CC-0. In Public Domain. Gurukul Kangri Collection, Haridwar

Digitized by Arya Samaj Foundation Chennai and eGangotri

Talipes or club foot, 558
Talocalcaneal articulation, 424
ligament, anterior, 424
interosseous, 425
lateral, 424
medial, 425
posterior, 424
Talocalcaneonavicular articulation, 425
Talocrural articulation, 420
applied anatomy of, 424
movements of, 423
relations of tendons and vessels to, 423
surface anatomy of, 1305
Talofibular ligament, anterior, 422
posterior, 422
Talonavicular ligament, 425
Talotibial ligament, anterior, 422
posterior, 422
Talus, 334
ossification of, 347, 348
Tangential fibres of cerebral cortex, 869
Tapetum of chorioid, 998
of corpus callosum, 853
Tarsal arteries, 703
bones, 334
calcaneus (os calcis), 339
cuboid, 344
cuneiform, first, 342
third, 343
second, 342
navicular, 341
talus (astragalus), 334
applied anatomy of, 349
fractures of, 349
ossification of, 347
surface anatomy of, 1303
glands, 1017
structure of, 1017
joints, 424
applied anatomy of, 428
Tarsi of eyelids, 1016
Tarsometatarsal articulations, 428
Tarsus, 334
applied anatomy of, 349
ossification of, 347
surface anatomy of, 1303
Taste, area for sense of, 871
nerves of, 984
organ of, 983
Taste-buds, 983
Tectorial membrane, 1046
accessory, 1046
Tectospinal fasciculus, 794
Tectum anterius, 73
intermedius, 73
posterius, 73
Teeth, 1101
applied anatomy of, 1111
bicuspids, 1103
canines, 1103
cement or crusta petrosa of, 1106
crowns of, 1102
cuspids, 1103
deciduous, 1101, 1104
dens serotinus, 1104
dental formulæ, 1101
dentine of, 1104
chemical composition of, 1105
development of, 1106, 1110
enamel of, 1106
Teeth (*cont.*)
enamel, chemical composition of, 1106
eruption of, 1110
eye-teeth, 1103
general characteristics of, 1102
incisors, 1102
ivory or dentine of, 1104
lymphatic vessels of, 755
milk, 1104
molars, 1104
multicuspids, 1104
necks of, 1102
permanent, 1101, 1102
premolars, 1103
pulp-cavity of, 1104
roots of, 1102
structure of, 1104
substantia adamantina of, 1106
eburnea of, 1104
ossea of, 1106
successional permanent, 1110
superadded permanent, 1110
wisdom, 1104
Teeth, auditory of Huschke, 1043
Tegmen tympani, 209, 210, 1027
Tegmental or dorsal part of pons, 813
Tegmentum, 827
Tela chorioidea of fourth ventricle, 823
of third ventricle, 865
Telencephalon, 94, 842
Telophase, 3
Temperature sense, 875
Temporal arteries, deep, 619
middle, 616
superficial, 616
applied anatomy of, 616
bone, 206
mastoid portion of, 208
ossification of, 213
petrous portion of, 210
pyramid of, 210
squama of, 206
structure of, 213
styloid process of, 213
tympanic part of, 212
fascia, 444
fossa, 251
gyri, 849
lines, 206, 215, 217, 247, 251
lobe, 848
nerves, deep, 900
superficial, 902
of facial, 912
operculum, 850
process of zygomatic bone, 240
sulci, 849
vein, middle, 719
superficial, 710
Temporalis, 444
Temporary cartilage, 14
Temporomalar nerve, 896
Temporomandibular ligament, 356
Temporomaxillary vein, 711
Tendo Achillis, 552
calcaneus, 552
rupture of, 558
oculi, 439, 1017
Tendinous arch of pelvic fascia, 484
Tendinous inscriptions of rectus abdominis, 477
point, central, of perinæum, 487
Tendon-cells, 11
Tendon, central, of diaphragm, 466
conjoined, of internal oblique and transversus, 476
of conus arteriosus, 583
reactions, 877
structure of, 11
superior, of Lockwood, 1012
of Zinn, 1012
Tendons, 435
on back of wrist, mucous sheaths of, 519
Tendril fibres of cerebellum, 821
Tenon, capsule of, 1013
Tenosynovitis, 518
Tensor fasciæ latæ, 534
palati, 1120
tarsi, 438
tympani, 1033
semicanal for, 212, 1030
veli palatini, 1120
Tenth rib, 192
Tenth thoracic vertebra, 172
Tentorium cerebelli, 879
Teres major, 502
minor, 502
Terminal vein, 717
ventricle, 86, 789
Terminations of motor nerves, 781
of nerves of general sensations, 1048
Testes, 1212
appendages of, 1212
applied anatomy of, 156, 1215
coni vasculosi of, 1214
corpus Highmori of, 1213
descent of, 154
development of, 154
ductuli efferentes of, 1214
ductus deferens of, 1216
epididymis, 1212
gubernaculum testis, 155
interstitial cells of, 1214
lobuli testis, 1212
lymphatic vessels of, 773
mediastinum testis, 1212
rete testis, 1214
septula testis, 1212
structure of, 1212
tubuli seminiferi contorti, 1212
tubuli seminiferi recti, 1214
tunica albuginea, 1212
vaginalis, 1212
vasculosa, 1212
vessels and nerves of, 1215
Testicular arteries, 674, 1215
veins, 741, 1215
applied anatomy of, 741
Testis-cords, 154
Thalamencephalon, 832
Thalami, 832
connexions of, 834
development of, 94
massa intermedia, 94, 833
stalks of, 835
structure of, 834
Thalamocortical fibres, 834
Thalamo-olivary fasciculus, 835

CC-0. In Public Domain. Gurukul Kangri Collection, Haridwar

Digitized by Arya Samaj Foundation Chennai and eGangotri

Thebesius, valve of, 582
Theca folliculi, 1228
Thecal paronychia, 523
Thenar eminence, 518
Thigh, fascia lata of, 533
muscles of, 533
superficial fascia of, 533
Third cervical nerve, posterior division of, 929
cuneiform bone, 343
ossification of, 347
metacarpal bone, 304
styloid process of, 304
metatarsal bone, 345
occipital nerve, 929
trochanter, 321
ventricle of the brain, 841
chorioid plexuses of, 841
Thoracic aorta, 661
applied anatomy of, 663
branches of, 663
peculiarities of, 661
Thoracic artery, highest, 646
lateral, 647
long, 647
superior, 646
axis, 646
cavity, 574
curve of vertebral column, 182
duct, 748
applied anatomy of, 750
nerve, long, 937
applied anatomy of, 947
first, 948
twelfth, 950
nerves, anterior, 938
anterior divisions of, 948
applied anatomy of, 951
posterior divisions of, 930
part of œsophagus, 1128
portion of sympathetic, 975
vertebræ, 170
viscera, lymphatic vessels of, 778
wall, lymphatic vessels of, 777
Thoraco-acromial artery, 646
Thoracodorsal nerve, 939
Thoraco-epigastric vein, 734
Thorax, 193
boundaries of, 193
cavity of, 574
inspection of, 1092
lower opening of, 193, 574
lymph-glands of, 775
lymphatic vessels of, 777
mechanism of, 372
muscles of, 462
palpation of, 1092
parts passing through upper opening of, 574
through lower opening of, 574
percussion of, 1092
in rickets, 195
skeleton of, 193
subcostal angle, 194
surface anatomy of, 1276
lines of, 1278
markings of, 1277
upper opening of, 193, 574
veins of, 729
Thrombokinase, 28
Thumb, carpometacarpal articulation of, 395
Thymic asthma, 1249
Thymic branch of innominate artery, 602
Thymus, 1247
applied anatomy of, 1249
concentric corpuscles of, 1249
cortical portion of, 1248
development of, 135
lymphatic vessels of, 778
medullary portion of, 1249
structure of, 1248
vessels and nerves of, 1249
Thymus-death, 1249
Thyreoarytænoideus, 1069
Thyreocervical trunk, 640
Thyreo-epiglottic ligament, 1062
Thyreoepiglotticus, 1070
Thyreoglossal duct, 134
Thyreohyoideus, 453
nerve to, 925
Thyreoid artery, inferior, 640
superior, 609
applied anatomy of, 610
axis, 640
cartilage, 1059
development of, 146
gland, 1243
applied anatomy of, 1245
development of, 134
isthmus of, 1245
lobes of, 1244
lymphatic vessels of, 757
pyramidal lobe of, 1245
structure of, 1245
vessels and nerves of, 1245
notch, superior, 1060
veins, inferior, 729
middle, 714
superior, 714
Thyreoidea ima artery, 602
Thyreoids, accessory, 1245
Thyreotomy, 1076
Tibia, 327
applied anatomy of, 333
condyles of, 327
fractures of, 333, 568
intercondyloid eminence of, 327
ossification of, 330
spine of, 327
structure of, 330
surface anatomy of, 1303
tuberosity of, 327
Tibial artery, anterior, 700
applied anatomy of, 701
branches of, 701
peculiarities of, 700
surface marking of, 1311
posterior, 703
applied anatomy of, 704
branches of, 705
peculiarities of, 704
surface marking of, 1311
collateral ligament of knee-joint, 413
lymph-gland, anterior, 761
nerve, 963
surface marking of, 1311
anterior, 965
recurrent artery, anterior, 701
posterior, 701
spine, 327
surfaces of femur, 323
veins, 736
Tibialis anterior, 550
posterior, 555
Tibiofibular articulation, distal, 420
proximal, 419
syndesmosis, 420
Tibionavicular ligament, 422
Tinnitus aurium, 915
Tissue, adipose, 9
areolar, 7
cancellous, 17
connective, 7
lymphoid, 12
mucoid, 12
muscular, 29
nervous, 33
retiform or reticular, 12
subserous areolar, 1134
white fibrous, 10
yellow elastic, 11
Tomes, fibres of, 1105
granular layer of, 1105
Tongue, 1111
apex of, 1111
applied anatomy of, 1118
development of, 134
dorsum of, 1111
folia linguæ of, 1112
foramen cæcum of, 1111
frenulum of, 1112
glands of, 1117
lingual tonsil, 1112
lymphatic vessels of, 756
mucous membrane of, 1117
muscles of, 1114
oral part of, 1111
papillæ of, 1113
pharyngeal part of, 1112
plica fimbriata of, 1112
root of, 1111
septum of, 1117
applied anatomy of, 1117
structure of, 1117
sulcus terminalis of, 1111
vessels and nerves of, 1117
Tonsil, lingual, 1112, 1119
palatine, 1118
Tonsillæ of cerebellum, 817
Tonsillar artery, 613
nerves from glossopharyngeal, 917
sinus, 1118
Tonsils, palatine, 1118
applied anatomy of, 1119
development of, 134
lymphatic vessels of, 755
structure of, 1119
vessels and nerves of, 1119
Torcular Herophili, 197, 720
Torsion of spermatic cord, 1215
Torticollis or wryneck, 451, 922
Torus tubarius, 1031, 1122
uretericus, 1206
uterinus, 1138
Trabeculæ carneæ of left ventricle, 587
of right ventricle, 584
Trabeculæ of penis, 1222
of spleen, 1254
Trachea, 1072
applied anatomy of, 1076
mucous membrane of, 1076
relations of cervical part, 1072
of thoracic part, 1074
surface marking of, 1279
structure of, 1075
vessels and nerves of, 1076

CC-0. In Public Domain. Gurukul Kangri Collection, Haridwar

Digitized by Arya Samaj Foundation Chennai and eGangotri

Tracheal branches of inferior thyreoid artery, 641
lymph-glands, 776
Tracheal tugging, 601
Trachealis muscle, 1075
Trachelomastoideus, 458
Tracheobronchial lymph-glands, 776
applied anatomy of, 777
Tracheotomy, 1077
Trachoma glands, 1018
Tract or tracts—
anterior basis bundle, 783
of Burdach, 795
cerebellar, afferent, 876
direct, 795, 806
efferent, 876
cerebro-olivary, 808
cerebrospinal, anterior, 793
lateral, 794
uncrossed lateral, 794
comma-shaped, 796
cornucommissural, 796
crossed pyramidal, 794
direct cerebellar, 795, 806
dorsal peripheral band, 796
of Flechsig, 795
frontopontine, 859
of Goll, 795
of Gowers, 795
iliotibial, 534
lateral basis bundle, 795
of Lissauer, 795
of Monakow, 794
motor, principal, 873
secondary, 874
olfactory, 851
olivocerebellar, 808
olivospinal (Helweg), 795
optic, 840, 889
oval area of Flechsig, 797
proprius anterior, 794
lateralis, 795
pyramidal, crossed, 794
pyramidal, direct, 793
rubrospinal of Monakow, 794, 827
sensory, 874
spinal, of trigeminal nerve, 813, 892
spinocerebellar, anterior, 795
spino-olivary, 808
spinotectal, 795
spinothalamic, 794, 795
tectospinal, 794
thalamo-olivary, 835
triangular strand, 797
vestibulospinal, 794
Traction epiphyses, 25
Tractus peduncularis transversus, 827*
solitarius, 91, 100
spiralis foraminosus, 211, 1037, 1047
Tragicus, 1024
Tragus, 1022
Transpyloric plane, 1133
Transtubercular plane, 1133
Transversa colli artery, 642
Transversalis cervicis, 458
fascia, 480
Transverse acetabular ligament, 406
carpal ligament, 518
cervical artery, 642
ascending branch, 642
descending branch, 642
nerve, 933
Transverse colon, 1166
crural ligament, 558
diameter of pelvis, 314
facial artery, 616
vein, 711
fasciculi, superficial of hand, 522
fibres of cerebral hemispheres, 866
of pons, 812
fissure of brain, 865
of liver, 1183
folds of rectum, 1168
humeral ligament, 380
ligament of atlas, 364
crus inferius, 364
crus superius, 364
inferior, of distal tibiofibular articulation, 420
of knee, 415
metacarpal, 396
metatarsal, 429
of pelvis, 489
ligaments of scapula, 377, 378
mesocolon, 1144
occipital sulcus, 848
processes of a vertebra, 165
scapular artery, 641
sinus of pericardium, 576
sinuses of dura mater, 719, 1264
sulcus, 197, 264
tarsal joint, 426
temporal gyri, 848
Transversus abdominis, 476
auriculæ, 1024
linguæ, 1116
menti, 441
nuchæ, 437
pedis, 565
perinæi profundus,
in female, 492
in male, 490
superficialis,
in female, 491
in male, 488
thoracis, 463
Trapezium, 300
Trapezius, 493
Trapezoid, 300
Trapezoid body, 813
ligament, 376
nucleus, 813
ridge, 280
Treitz, suspensory muscle of, 1156
Treves, bloodless fold of, 1146
Triangle or triangles—
anterior of neck, 621
of auscultation, 495, 1277
Bryant's, 1308
carotid, 621
inferior, 621
deltoideopectoral, 497
digastric, 622
femoral, 689, 1310
of Hesselbach, 1173, 1289
lumbar, 495
muscular, 621
occipital, 622
of Petit, 495
of Scarpa, 689
posterior of neck, 621
subclavian, 623
submaxillary, 622
suboccipital, 462, 636
suprahyoid, 622
Triangular fascia, 473
ligament, 489
deep layer of, 490
superficial layer of, 489
left, of liver, 1134, 1185
right, of liver, 1134, 1185
strand, 797
Triangularis, 441
Triangularis sterni, 463
Triceps brachii, 506
applied anatomy of, 507
suræ, 552
Tricuspid valve, 583
Trigeminal impression, 210
nerve, 892
applied anatomy of, 903
divisions of, 892
mesencephalic root of, 813, 893
motor root of, 893
nuclei of, 813, 831, 893
sensory root of, 892
spinal tract of, 813, 892
surface marking of, 1265
nerve-reflexes, 903
Trigone, olfactory, 851
Trigonum collaterale, 857
fibrosum, 587
habenulæ, 836
hypoglossi, 806, 824, 923
vesicæ, 1206
Triquetral bone, 299
ossification of, 305
Trochanter, greater, 319
lesser, 320
third, 321
Trochanteric fossa, 319
Trochlea of humerus, 285
of talus, 338
Trochlear fovea, 218, 257
nerve, 891
applied anatomy of, 892
nucleus of, 831
process of calcaneus, 340
spine, 218, 257
Trochoid articulation, 354
Trolard, great anastomotic vein of, 716
Tröltsch, recesses of, 1034
Trophoblast, 49
Tropical abscess of liver, 745, 1191
True ligaments of urinary bladder, 1204
ribs, 188
vocal cords, 1067
Truncus arteriosus, 113
Trunk, arteries of, 661
fasciæ and muscles of, 456
Trunks, sympathetic, 973
Tubal pregnancy, 47
Tube, auditory or Eustachian, 1030
pharyngeal ostium of, 1122
tonsil of, 1031
digestive, 1092
laryngotracheal, 145
neural, 52
Tube-tonsil, 1031
Tuber cinereum, 838
omentale of liver, 1185
of pancreas, 1178
vermis, 817
Tubercle, adductor, 321
articular, of temporal bone, 207, 250
articular, of Darwin, 1022

CC-0. In Public Domain. Gurukul Kangri Collection, Haridwar

Digitized by Arya Samaj Foundation Chennai and eGangotri

Tubercle (*cont.*)
of Chassaignac, 167
cloacal, 158
conoid, 280
cuneate, 803
deltoid, 280
of epiglottis, 1063
of femur, 320
genital, 159
of humerus, greater, 282
lesser, 282
intervenous, 582
lacrimal, 233
of Lower, 582
mental, 242, 257
obturator, anterior, 312
posterior, 309, 312
orbital, 259
peronæal, 340
pharyngeal, 198, 250
postglenoid, 207
pterygoid, 204, 250
pubic, 311
of rib, 190
ligament of, 370
of Rolando, 803
scalene, 191
Tuberculum anterius, 167
caroticum, 167
cinereum, 803
impar, 134
jugulare, 199
posterius, 167
sellæ, 200, 261
Tuberosity, calcaneal, 341
coracoid, 280
costal, 281
of cuboid bone, 344
deltoid, 284
of fifth metatarsal bone, 346
frontal, 217, 247, 251, 255
glutæal, 321
iliac, 309
infraglenoid, 277
of ischium, 310
maxillary, 230
of navicular bone, 342
of palatine bone, 238
parietal, 215, 247, 251
radial, 290
sacral, 176
supraglenoid, 278
of tibia, 327
ulnar, 292
Tubes, uterine or Fallopian, 1230
Tubotympanic recess, 107
Tubules, renal, 1196
Wolffian, 150
Tubuli lactiferi, 1242
seminiferi contorti, 1214
recti, 1214
Tunic, dartos, 464, 470, 1220
Tunica adventitia, 570, 573
albuginea of ovary, 1227
of testis, 1213
elastica externa, 570
intima, 570, 573
media, 570, 573
vaginalia of testis, 156, 1213
vasculosa of testis, 1213
Tunics of eye, 993
fibrous, 993
cornea, 995
sclera, 993
nervous (retina), 1001
vascular, 997
chorioid, 997
Tunic, vascular, of eye (*cont.*)
ciliary body, 998
iris, 999
Tunnel of Corti, 1044
Turner, intraparietal sulcus of, 847
Twelfth rib, 192
thoracic nerve, 950
vertebra, 172
Tympanic antrum, 209, 1030
entrance to, 1030
surface marking of, 1270
artery, anterior, 618
inferior, 611
superior, 618
branch of glossopharyngeal nerve, 1034
canaliculus, inferior, 212, 251
cavity, 1027
applied anatomy of, 1034
attic or epitympanic recess of, 1027
auditory (Eustachian) tube, 1030
carotid or anterior wall of, 1030
development of, 108
jugular wall or floor of, 1027
labyrinthic or medial wall of, 1029
mastoid or posterior wall of, 1030
membranous or lateral wall of, 1027
mucous membrane of, 1034
muscles of, 1033
ossicles of, 1031
development of, 108
movements of, 1033
tegmental wall or roof of, 1027
vessels and nerves of, 1034
crests, superior and inferior, 213*
lip, 1042
membrane, 1028
fibrocartilaginous ring of, 1208
malleolar folds of, 1208
pars flaccida, 1028
pars tensa, 1028
secondary, 1029, 1038
structure of, 1028
umbo of, 1208
vessels and nerves of, 1028
nerve (Jacobson's), 917, 1034
part of temporal bone, 212
plexus, 917, 1025
ring, 213
sulcus, 212, 1025, 1028
Tympanohyal part of styloid process, 214
Tympanomastoid fissure, 250
Typical vertebra, 164

Ulna, 291
applied anatomy of, 294
coronoid process of, 292
fracture of, 294, 530
olecranon of, 292
ossification of, 294
radial notch of, 293
semilunar notch of, 292
sigmoid cavities of, 292, 293
structure of, 294
styloid process of, 294
Ulna (*cont.*)
surface anatomy of, 1293
tuberosity of, 292
Ulnar artery, 657
applied anatomy of, 657
branches of, 658
peculiarities of, 657
surface marking of, 1301
Ulnar collateral artery, inferior, 652
superior, 652
Ulnar collateral ligament of elbow-joint, 384
of wrist-joint, 392
Ulnar collateral nerve, 945
Ulnar recurrent artery, dorsal, 658
volar, 658
Ulnar nerve, 942
applied anatomy of, 947
surface marking of, 1302
notch of radius, 290
tuberosity, 292
Ultimobranchial bodies, 135
Umbilical arteries in fœtus, 64, 592, 678
cord, 61
velamentous insertion of, 67
folds, 1173, 1205
ligament, lateral, 678
middle, 1205
region, 1133
vein, fossa for, 1183
veins, 65, 112, 594
vesicle, 56
Umbilicus, 480, 1281
Umbo of tympanic membrane, 1028
Unciform bone, 302
Uncinate fasciculus, 866
process of ethmoidal bone, 222, 266
of head of pancreas, 1176
Uncrossed lateral cerebrospinal fibres, 794
Uncus, 850
Ungual phalanges of foot, 347
of hand, 306
Unipolar nerve-cells, 34
Unstriped muscle, 32
Upper extremity, arteries of, 631
articulations of, 374
bones of, 274
fasciæ and muscles of, 492
lymph-glands of, 758
deep, 759
superficial, 758
lymphatic vessels of, 760
deep, 760
superficial, 761
surface anatomy of, 1292
surface markings of, 1297
veins of, 724
Upper motor neurons, 877
Urachus, 157, 1202
Ureter, 1200
abdominal part of, 1200
applied anatomy of, 1202
arteries of, 1202
lymphatic vessels of, 772
muscles of, 1207
nerves of, 1202
orifices of, 1206
pelvic part of, 1201
structure of, 1201
surface marking of, 1288

CC-0. In Public Domain. Gurukul Kangri Collection, Haridwar

Digitized by Arya Samaj Foundation Chennai and eGangotri

Urethra, development of, 159
female, 1211
male, 1208
applied anatomy of, 1210
cavernous portion of, 1209
crest or verumontanum of, 1209
fossa navicularis of, 1210
lacunæ of, 1210, 1211
lymphatic vessels of, 773
membranous portion of, 1209
prostatic portion of, 1208
prostatic sinus, 1209
utricle, 1209
structure of, 1211
Urethral artery, 681
bulb, 1221
artery of, 681
nerve of, 967
crest, in female, 1211
in male, 1209
glands, 1210, 1211
orifice, external, 1210, 1240
internal, 1207
plate, 159
Urinary bladder, 1202
applied anatomy of, 1207
development of, 157
lymphatic vessels of, 772
organs, 1191
bladder, 1202
kidneys, 1192
ureters, 1200
urethra, female, 1211
male, 1208
development of, 159
lymphatic vessels of, 771
Urogenital apparatus, 1191
development of, 149
diaphragm, 489
fasciæ of, 489, 490
fold, 150
ostium, primitive, 159
region, fascia of, 487, 489
muscles of, in female, 491
in male, 487
sinus, 157
Urorectal septum, 142
Uterine artery, 679
cervical ganglion, 982
glands, 1236
plexus of nerves, 982
plexuses of veins, 739
tube, 1230
abdominal ostium of, 1230
ampulla of, 1230
appendices vesiculosæ of, 1230
applied anatomy of, 1230
development of, 153
fimbriæ of, 1230
hydatids of Morgagni, 1230
infundibulum of, 1230
isthmus of, 1230
lymphatic vessels of, 774
pars uterina tubæ, 1230
structure of, 1230
Uterosacral ligaments, 1234
Uterus, 1231
applied anatomy of, 1237
body of, 1232
canal of cervix, 1233
cavity of body, 1233
cervix of, 1233
development of, 153
in fœtus, 1234
fundus of, 1232
Uterus (*cont.*)
interior of, 1233
isthmus of, 1232
ligaments of, 1233
lymphatic vessels of, 774
during menstruation, 1235
in old age, 1335
orifice of, external, 1233
internal, 1232
after parturition, 1235
during pregnancy, 1235
at puberty, 1234
structure of, 1235
vessels and nerves of, 1236
virgin state of, 1231
Uterus masculinus, or prostatic utricle, 1209
Utricle, prostatic, 1209
of vestibule, 1039
ductus utriculosaccularis, 1039
macula acustica utriculi, 1039
structure of, 1040
Uvea, 1000, 1002
Uvula of cerebellum, 817
palatine, 1095
vesicæ, 1207

Vagina, 1237
columns of, 1238
development of, 153
fornices of, 1237
lymphatic vessels of, 774
orifice of, 1239
structure of, 1238
vestibule of, 1239
Vagina processus styloidei, 212, 250
Vaginæ mucosæ, 352
Vaginal artery, 680
hydrocele, 1216
ligaments of foot, 563
of hand, 510
orifice, 1239
plexus of nerves, 982
plexuses of veins, 739
process of sphenoidal bone, 202, 204
of temporal bone, 212
Vagus nerve, 917
applied anatomy of, 921
ganglion nodosum of, 917
jugular ganglion of, 917
motor fibres of, 917
nuclei of, 917, 918
sensory fibres of, 917
Vallecula cerebelli, 814
Vallecula of tongue, 1062
Valsalva, sinuses of, 585, 587
Valve or valves—
anal, 1170
aortic semilunar, 586
bicuspid, 586
colic, 1152
of coronary sinus, 114, 582, 708
of Eustachius, 582, 740
of heart, actions of, 591
development of, 118
of Houston, 1168
of inferior vena cava, 114, 582, 592, 740
of lymphatic vessels, 746
mitral, 586
pulmonary semilunar, 584
right and left venous, 114
of Thebesius, 582, 708
tricuspid, 583
Valve or valves (*cont.*)
of veins, 573
of Vieussens, 817
Valvulæ conniventes, 1158
Varicocele, 741
Varicosity of saphenous veins, 735
Vas aberrans of Haller, 1217
deferens, 1216
spirale, 1044
Vasa aberrantia, from brachial artery, 649
brevia of stomach, 669
intestini tenuis, 670
vasorum of arteries, 571
of veins, 574
Vascular area of yolk-sac, 109
capsule of lens, 104
system, changes in, at birth, 594
development of, 109
peculiarities of, in fœtus, 592
tunic of eye-ball, 997
chorioid, 997
ciliary body, 998
iris, 999
Vasomotor nerve-fibres, 780
Vastus intermedius, 537
lateralis, 536
medialis, 537
Vater, ampulla of, 1190
Vein or veins—
of abdomen and pelvis, 737
accessory hemiazygos, 731
saphenous, 734
anastomotic, of Labbé, 716
of Trolard, 716
angular, 710
antibrachial, median, 727
ascending lumbar, 741
auditory, internal, 1048
auricular, posterior, 712
axillary, 727
applied anatomy of, 727
azygos, 731
basal, 717
basilic, 726
basivertebral, 733
brachial, 727
of the brain, 716
bronchial, 732, 1091
cardiac, 708, 709
cardinal, anterior, 125
posterior, 125
carotid plexus, internal, 724
cava, inferior, 740
applied anatomy of, 740
superior, 729
applied anatomy of, 731
cephalic, 725
accessory, 726
cerebellar, 717
cerebral, 716
anastomotic of Labbé, 716
of Trolard, 716
anterior, 717
basal, 717
basilic, median, 726
chorioid, 717
deep middle, 717
external, 716
of Galen, 717
great, of Galen, 717
inferior, 716
inferior striate, 717
internal, 717
middle, 716
superior, 716

CC-0. In Public Domain. Gurukul Kangri Collection, Haridwar

Digitized by Arya Samaj Foundation Chennai and eGangotri

Vein or veins (*cont.*)
cerebral, Sylvian, deep, 717
superficial, 716
terminal, 717
cervical, deep, 715
transverse, 712
chorioid, 717
ciliary, 1008
of clitoris, dorsal, 739
comitans, of hypoglossal nerve, 714
comitantes, 707
common facial, 710
iliac, 739
vitello-umbilical, 112
condyloid, 724
coronary, of stomach, 744
sinus of heart, 708
cubital, median, 725
cystic, 744
deep, 707
cervical, 715
facial, 710
of forearm, 727
of hand, 727
of lower extremity, 736
of upper extremity, 727
development of, 124
digital, of foot, 733, 736
of hand, 724, 725
diploic, 715, 716
dorsal, of clitoris, 739
digital, 724, 733
metacarpal, 724
metatarsal, 733
of penis, 739
venous arch of foot, 733
network of hand, 724
emissary, 724
applied anatomy of, 724
epigastric, inferior, 737
superficial, 734
facial, anterior, 710
applied anatomy of, 710
common, 710
deep, 710
posterior, 711
transverse, 711
femoral, 736
of foramen cæcum, 724
of foramen of Vesalius, 724
of forearm, 725, 726
frontal, 709
of Galen, 717
gastric, right, 744
short, 742
gastro-epiploic, left, 742
right, 744
glutæal, 737
great cardiac, 708
saphenous, 734
hæmorrhoidal, inferior, 738
middle, 738
superior, 743
plexus, 738
applied anatomy of, 739
of hand, 724
of head and neck, 709
of heart, 708
hemiazygos, 731
accessory, 731
hepatic, 741
hypogastric, 7[illegible]
iliac, circumflex, deep, 737
superficial, 734
common, 739
external, 737
internal, 737

Vein or veins (*cont.*)
inferior vena cava, 740
thyreoid veins, 729
innominate, 729
intercapitular, 725, 733, 736
intercostal, 731
left superior, 729
right superior, 731
interlobular, of kidney, 1199
internal mammary, 729
maxillary, 711
intervertebral, 733
intralobular, of liver, 741, 1188
of kidney, 1199
jugular, anterior, 712
external, 712
applied anatomy of, 713
posterior, 712
internal, 713
applied anatomy of, 714
primitive, 112, 125
of Labbé, posterior anastomotic, 716
lateral sacral, 737
lienal or splenic, 742
lingual, 714
linguofacial, 131
of lower extremity, deep, 733
superficial, 733
lumbar, 740
ascending, 741
mammary, internal, 729
marginal, of foot, 733
of heart, 708
mastoid emissary, 724
maxillary, internal, 711
median antibrachial, 727
basilic, 725
applied anatomy of, 727
cubital, 725
of medulla spinalis, 733
mesenteric, inferior, 743
superior, 743
metatarsal, 733, 736
middle cardiac, 708
meningeal, 723
sacral, 739
nasal arch, 710
of neck, 712
oblique, of left atrium (Marshall), 128, 576, 709
obliterated umbilical, 1134
obturator, 737
occipital, 712
ophthalmic, 722
orbital, 711
ovarian, 741
pampiniform plexus, 741
pancreatic, 742
pancreaticoduodenal, 744
parietal, of embryo, 125
emissary, 724
para-umbilical, 744
of penis, dorsal, 739
peronæal, 736
pharyngeal, 714
plexus, 714
phrenic, inferior, 741
superior, 729
plantar, digital, 736
lateral, 736
medial, 736
metatarsal, 736
venous arch, cutaneous, 734
[illegible]

Vein or veins (*cont.*)
plantar venous network, cutaneous, 734
popliteal, 736
portal, 742
applied anatomy of, 744
posterior of left ventricle, 708
primary head, 128
primitive jugular, 125
profunda femoris, 737
prostatic plexus, 739
applied anatomy of, 739
veins, 739
pterygoid plexus, 711
pubic, 737
pudendal, internal, 737
superficial external, 734
plexus, 738
pudic, internal, 737
pulmonary, 708
pyloric, 744
ranine, 714
renal, 741
rete canalis hypoglossi, 724
foraminis ovalis, 724
sacral, lateral, 737
middle, 739
saphenous, accessory, 734
great, 734
small, 734
applied anatomy of, 735
sciatic, 737
short gastric, 742
small cardiac, 708
saphenous, 734
smallest cardiac, 709
spermatic, 741
splenic or lienal, 742
stellate, of kidney, 1199
striate, inferior, 717
structure of, 572
subcardinal, 126
subclavian, 728
sublobular, of liver, 741, 1188
superficial, 707
of upper extremity, 724
applied anatomy of, 727
of lower extremity, 733
applied anatomy of, 735
superior vena cava, 729
intercostal, left, 729
right, 731
mesenteric, 743
phrenic, 729
supracardinal, 127
supra-orbital, 710
suprarenal, 741
Sylvian, deep, 717
superficial, 716
systemic, 708
temporal, middle, 710
superficial, 710
temporomaxillary, 711
terminal, 717
testicular, 741, 1209
thoraco-epigastric, 734
of thorax, 729
thyreoid, inferior, 729
middle, 714
superior, 714
tibial, 736
transverse cervical, 712
facial, 711
scapular, 712
of Trolard, great anastomotic, 716

CC-0. In Public Domain. Gurukul Kangri Collection, Haridwar

Digitized by Arya Samaj Foundation Chennai and eGangotri

CC-0. In Public Domain. Gurukul Kangri Collection, Haridwar

Digitized by Arya Samaj Foundation Chennai and eGangotri

04584

श्री धर्मदत्त वैद्य संग्रह

CC-0. In Public Domain. Gurukul Kangri Collection, Haridwar

Digitized by Arya Samaj Foundation Chennai and eGangotri

CC-0. In Public Domain. Gurukul Kangri Collection, Haridwar

Digitized by Arya Samaj Foundation Chennai and eGangotri